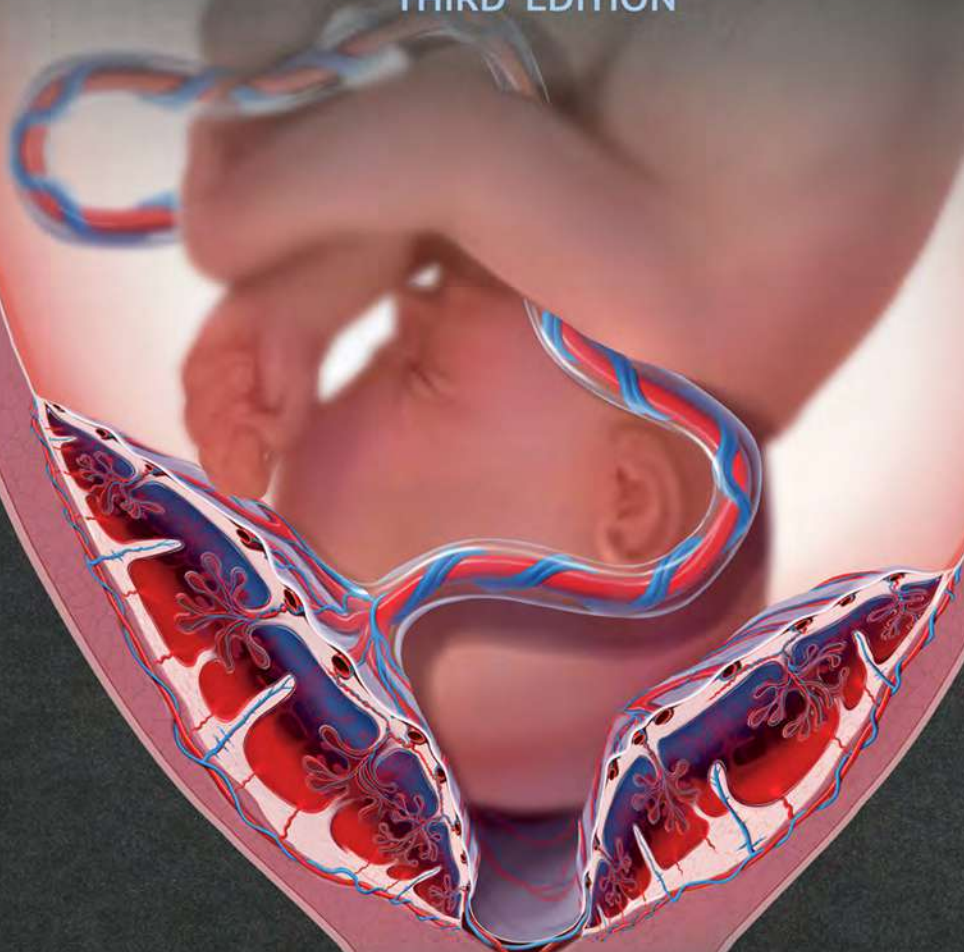


Get Full Access and More at

ExpertConsult.com

Diagnostic Imaging
Obstetrics

THIRD EDITION

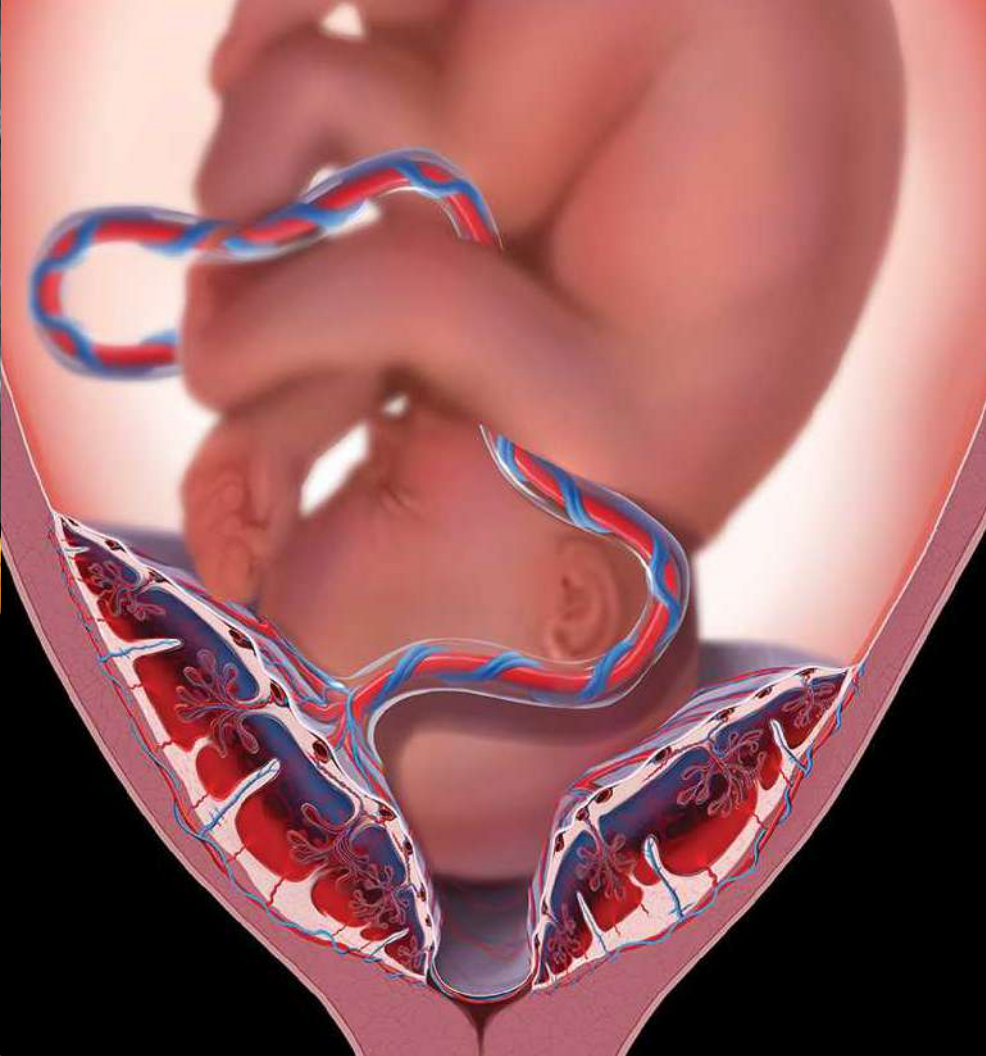
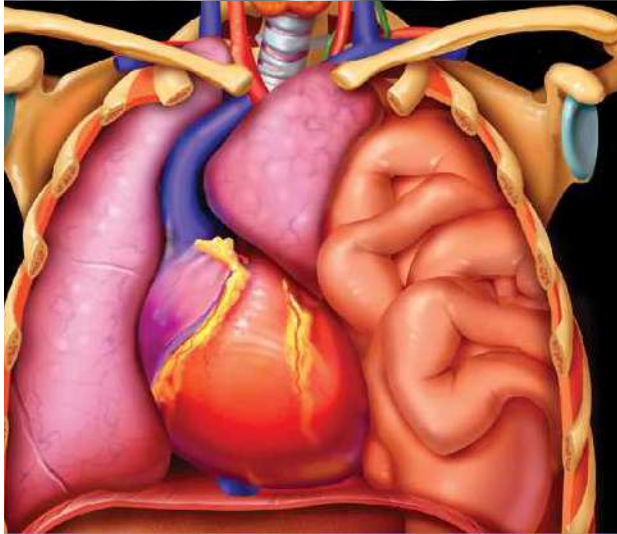
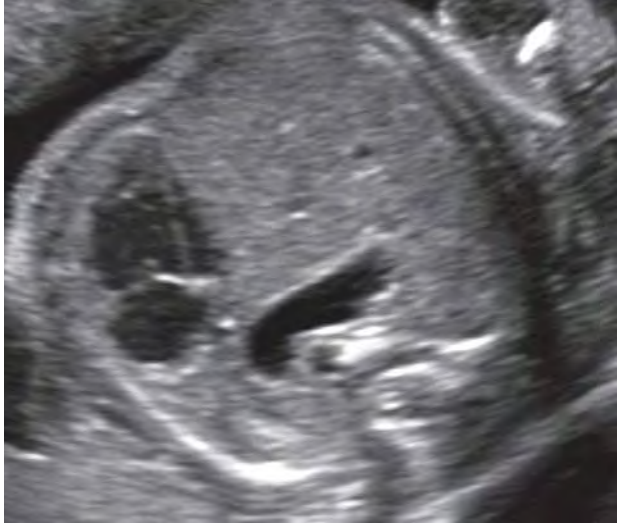

AMIRSYS®

ELSEVIER

Woodward | Kennedy | Sohaey

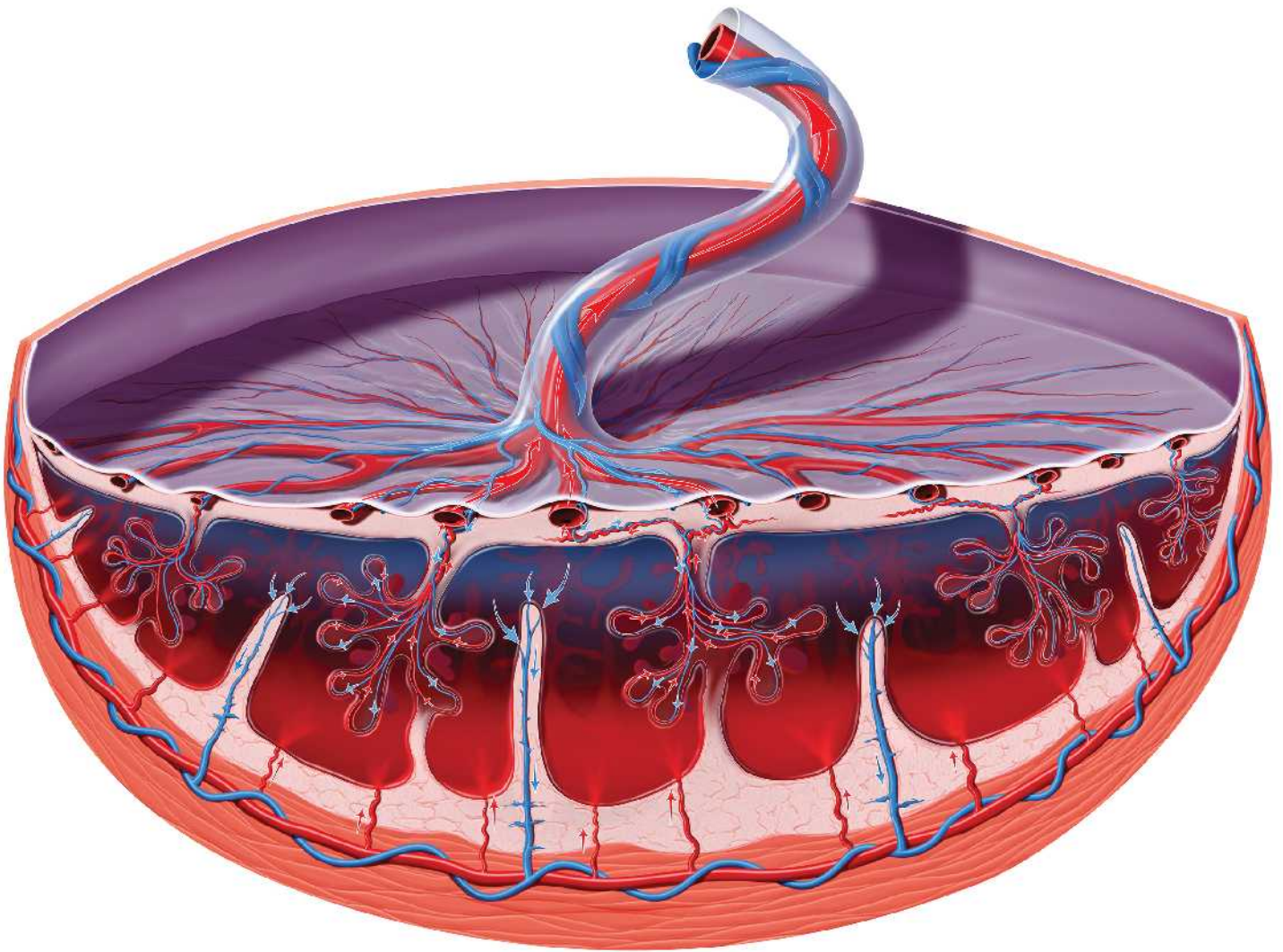
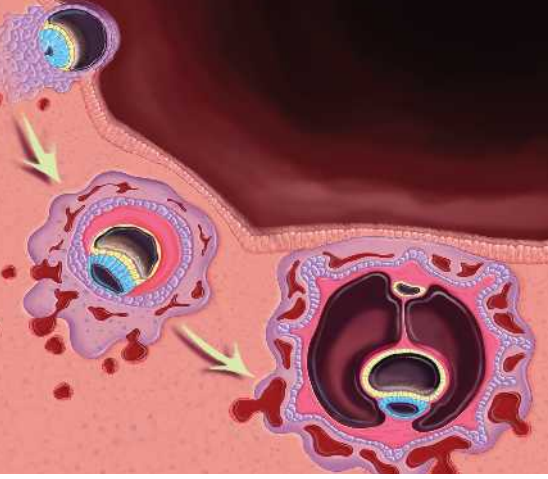
BYRNE • OH • PUCHALSKI



Diagnostic Imaging

Obstetrics

THIRD EDITION



Diagnostic Imaging
Obstetrics

THIRD EDITION

Paula J. Woodward, MD

David G. Bragg, MD and Marcia R. Bragg Presidential
Endowed Chair in Oncologic Imaging
Professor of Radiology
Adjunct Professor of Obstetrics and Gynecology
University of Utah School of Medicine
Salt Lake City, Utah

Anne Kennedy, MD

Professor of Radiology
Adjunct Professor of Obstetrics and Gynecology
Executive Vice Chair of Radiology
Co-Director of Maternal Fetal Diagnostic Center
University of Utah School of Medicine
Salt Lake City, Utah

Roya Sohaey, MD

Professor of Radiology
Adjunct Professor of Obstetrics and Gynecology
Director of Fetal Imaging
Oregon Health & Science University
Portland, Oregon

Janice L.B. Byrne, MD

Professor of Obstetrics and Gynecology/Maternal-Fetal Medicine
Adjunct Professor of Pediatrics/Medical Genetics
Co-Director of Utah Fetal Center
Primary Children's Hospital
University of Utah School of Medicine
Salt Lake City, Utah

Karen Y. Oh, MD

Associate Professor of Radiology
Adjunct Associate Professor of Obstetrics and Gynecology
Section Chief, Women's Imaging
Oregon Health & Science University
Portland, Oregon

Michael D. Puchalski, MD

Professor of Pediatrics
Adjunct Professor of Radiology
Associate Director of Pediatric Cardiology/Director of Non-Invasive Imaging
University of Utah/Primary Children's Hospital
Salt Lake City, Utah

Copyright © 2016 by Elsevier. All rights reserved.

No part of this publication may be reproduced or transmitted in any form or by any means, electronic or mechanical, including photocopying, recording, or any information storage and retrieval system, without permission in writing from the publisher. Details on how to seek permission, further information about the Publisher's permissions policies and our arrangements with organizations such as the Copyright Clearance Center and the Copyright Licensing Agency, can be found at our website: www.elsevier.com/permissions.

This book and the individual contributions contained in it are protected under copyright by the Publisher (other than as may be noted herein).

Notices

Knowledge and best practice in this field are constantly changing. As new research and experience broaden our understanding, changes in research methods, professional practices, or medical treatment may become necessary.

Practitioners and researchers must always rely on their own experience and knowledge in evaluating and using any information, methods, compounds, or experiments described herein. In using such information or methods they should be mindful of their own safety and the safety of others, including parties for whom they have a professional responsibility.

With respect to any drug or pharmaceutical products identified, readers are advised to check the most current information provided (i) on procedures featured or (ii) by the manufacturer of each product to be administered, to verify the recommended dose or formula, the method and duration of administration, and contraindications. It is the responsibility of practitioners, relying on their own experience and knowledge of their patients, to make diagnoses, to determine dosages and the best treatment for each individual patient, and to take all appropriate safety precautions.

To the fullest extent of the law, neither the Publisher nor the authors, contributors, or editors, assume any liability for any injury and/or damage to persons or property as a matter of products liability, negligence or otherwise, or from any use or operation of any methods, products, instructions, or ideas contained in the material herein.

Publisher Cataloging-in-Publication Data

Names: Woodward, Paula J.

Title: Diagnostic imaging. Obstetrics / [edited by] Paula J. Woodward.

Other titles: Obstetrics.

Description: Third edition. | Salt Lake City, UT : Elsevier, Inc., [2016] | Includes bibliographical references and index.

Identifiers: ISBN 978-0-323-39256-3

Subjects: LCSH: Prenatal diagnosis--Handbooks, manuals, etc. | Diagnostic imaging--Handbooks, manuals, etc. | Generative organs, Female--Imaging--Handbooks, manuals, etc. | MESH: Diagnostic Imaging--methods--Atlases. | Prenatal Diagnosis--methods--Atlases. | Genital Diseases, Female--diagnosis--Atlases. | Pregnancy Complications--diagnosis--Atlases.

Classification: LCC RG628.D48 2016 | NLM WQ 209 | DDC 618.2'0754--dc23

International Standard Book Number: 978-0-323-39256-3

Cover Designer: Tom M. Olson, BA

Cover Art: Lane R. Bennion, MS

Printed in Canada by Friesens, Altona, Manitoba, Canada

Last digit is the print number: 9 8 7 6 5 4 3 2 1



Dedications

The Past: To my parents—your support is my confidence, your encouragement is my achievements, your love is the person I am.

The Present: To the FWCCM family—a mix of wonderful souls woven together with laughter and love. Proof family is what you make it.

The Future: To Anthony—a bundle of excitement, joy, and delight. When viewing the world through your eyes, there is hope and promise in all things.

PJW

This one is for my mum and mothers everywhere. The umbilical cord is cut but the bond is never severed.

AK

To my David, whose generous love and spirit gives me strength and shelter.

RS

To all my wonderful patients who, often in times of great stress, have allowed me the privilege of photographing their children.

To Drs. Theresa Werner and Mark Dodson: With cancer survivors, there comes a point when you have to re-define your purpose in life. Often, it's when you discover that there's more to survival than just being alive—you have to go on living.

JLBB

To my families, both at home and at work—thank you for your support, guidance, and collaboration. I am ever grateful for your presence in my life.

KYO

To Brenda, for your neverending love and faith in me, I reach higher because of you. To Luli and Tristan, thank you for the love and laughter you bring into my life and for reminding me to see the world through a child's eyes.

MDP

Contributors

Contributing Authors

Thomas A. Miller, DO

Assistant Professor of Pediatrics
Division of Pediatric Cardiology
University of Utah
Salt Lake City, Utah

Marcia L. Feldkamp, PhD, PA

Associate Professor
Division of Medical Genetics
Department of Pediatrics
University of Utah
Salt Lake City, Utah

Nicole S. Winkler, MD

Assistant Professor of Radiology
University of Utah
Salt Lake City, Utah

Image Contributors

Jessica Pittman, MD

Denise Pugash, MD

Lance K. Erickson, PA (ASCP), HTL, MB

Anna A. Kuang, MD

Carolina Rossi Palmieri, MD

Mark S. Molitor, Jr., MD

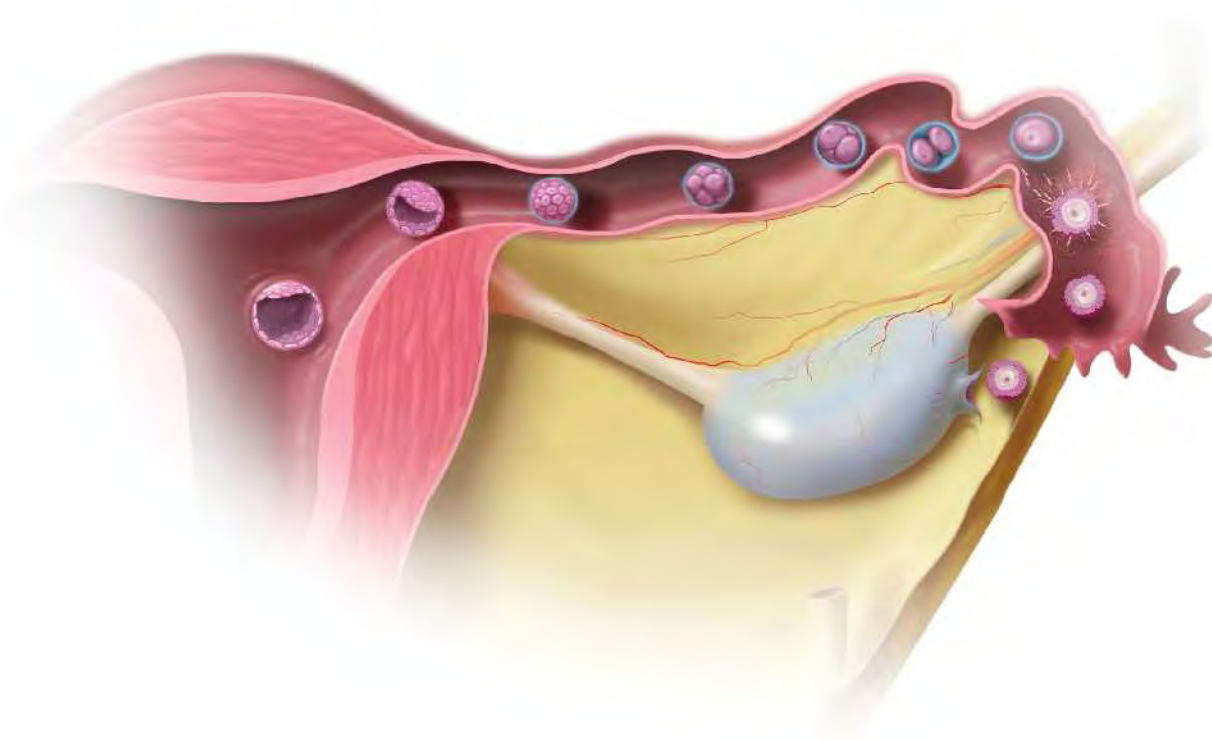
Steven J. Skoog, MD

Diane M. Twickler, MD, FACR

Harshwardhan M. Thaker, MD, PhD

Angelica R. Putnam, MD

Juliana Szakacs, MD

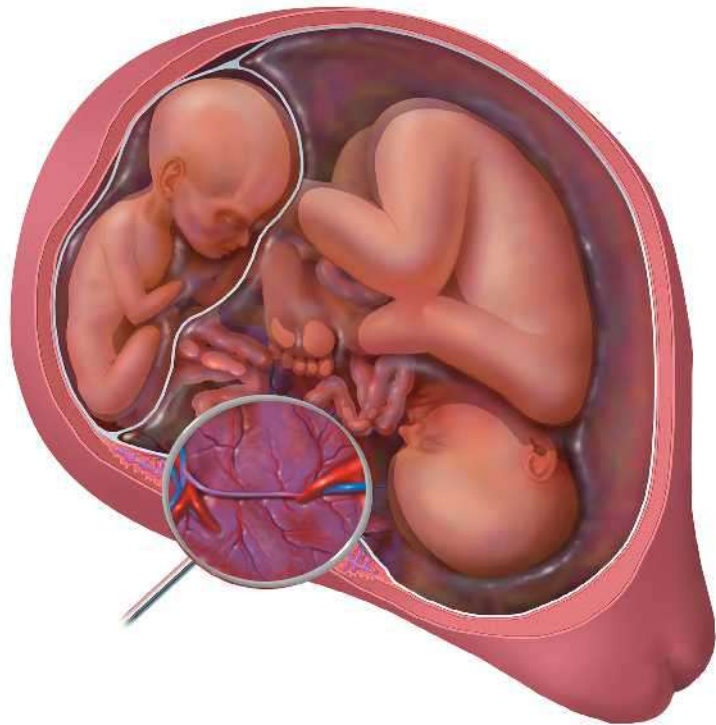


Sonographers

Jason Allen, RDMS
Brooke Axberg, RDMS
Jeanne Baker, RDMS
Leesha Baker, RDMS
Kara Bridges, RDMS
Jenny Burke, RDMS
Andrea Clarke, RDMS
Angela Crist, RDMS
Sami Cruz, RDMS
Chelsea Day, RDMS
Karina Calderon-Diaz, RDMS
Suzie Diston, RDMS
Porsche Fletcher, RDMS
Loriann Forbush, RDMS
Danielle Galbreath, RDMS
Perpetua Lynn Gennett, RDMS
Sheryl Gutierrez, RDMS
Pamela Guy, RDMS
Latoya Hatch, RDMS
Lydia Hays, RDMS
Deanna Hecker, RDMS
Adrian Lethbridge, RDMS
Alia Martin, RDMS
Johanna Meier, RDMS
April Nelson, RDMS
Benjamin Reed, RDMS
Ashley Reimann, RDMS
Nataliya Revyakina, RDMS
Leticia Seals, RDMS
Jo Semon, RDMS
Kara Soisson, RDMS
Belva Stanton, RDMS
Keisha Stefanoff, RDMS
Kasey Zimmer-Stucky, RDMS
Oxana Sumacheva, RDMS
Fariba Tehranchi, RDMS
Catherine Townsend, RDMS
Beth Traeger, RDMS
Devon Weinmann, RDMS
Amy Young, RDMS

MR Technologists

Josh Bertola, RT (R) (MR)
Karl Bohman, RT (R) (MR)
Angela Rowley, RT (R) (MR)
Kimberly Teerlink, RT (R) (MR)
Riley Hamilton, RT (R) (MR)
Lisa Pinkney, RT (R) (MR)
Judy Eldredge, RT (R) (MR)
David Shea, RT (R) (MR)
Logan Bramwell, RT (R) (MR)
Nicole Cottam, RT (R) (MR)
Ryan Hardman, RT (R) (MR)



Preface

Truly, the third time is THE CHARM!

I have never been so excited about spearheading a project. My extraordinary team (and dear friends) includes a diverse group of fetal imaging experts, including authorities in radiology, perinatology, cardiology, and clinical genetics. The collaborative effort among the team members elevates each chapter to its highest attainable level of excellence. We are all dedicated to advancing the understanding and diagnosis of fetal diseases and remain humbly aware of how devastating these diagnoses can be for the affected family. This is why we, like you, carry a passion for making the correct diagnosis and providing the most complete information possible to patients and their families. Each chapter was written with the excitement of sharing our collective knowledge and life's work with you.

The first edition was revolutionary in that it offered a totally new style of textbook. Each chapter followed a highly structured, information-dense, bulleted style that yielded more “pearls per pound” than a standard prose-style textbook. This allowed for extensive image galleries, far more than in any other text of comparable size. In the second edition, we built on that foundation, adding section introductions, embryology, and anatomy chapters. Our first two editions were well received (thank you), and a question may rise, “Why write a third edition?” or better yet, “Why buy a third edition?” Realistically, our field has changed greatly in the last few years. The advent of new fetal testing and better fetal imaging equipment coupled with the patient's and referring physician's desire for earlier and more specific diagnoses has led to a need and call for “an update.” We have been moved, like you, to not “rest on our laurels.” No doubt, the third edition is different, bigger, and better. Here are just a few of the highlights:

- **New Pertinent Differential Diagnoses Sections:** Sometimes you have a finding but not a clear diagnosis. The cavum is absent, the kidneys look big, the head shape is funny—what could that mean? Each anatomic area now has a list of Pertinent Differential Diagnoses designed to address that very problem. Each chapter begins with an ordered list (most to least common). For each finding, there are imaging and clinical pearls, not to mention extensive image galleries, helping to distinguish the various entities. We feel this provides the user with a pragmatic approach to imaging findings.

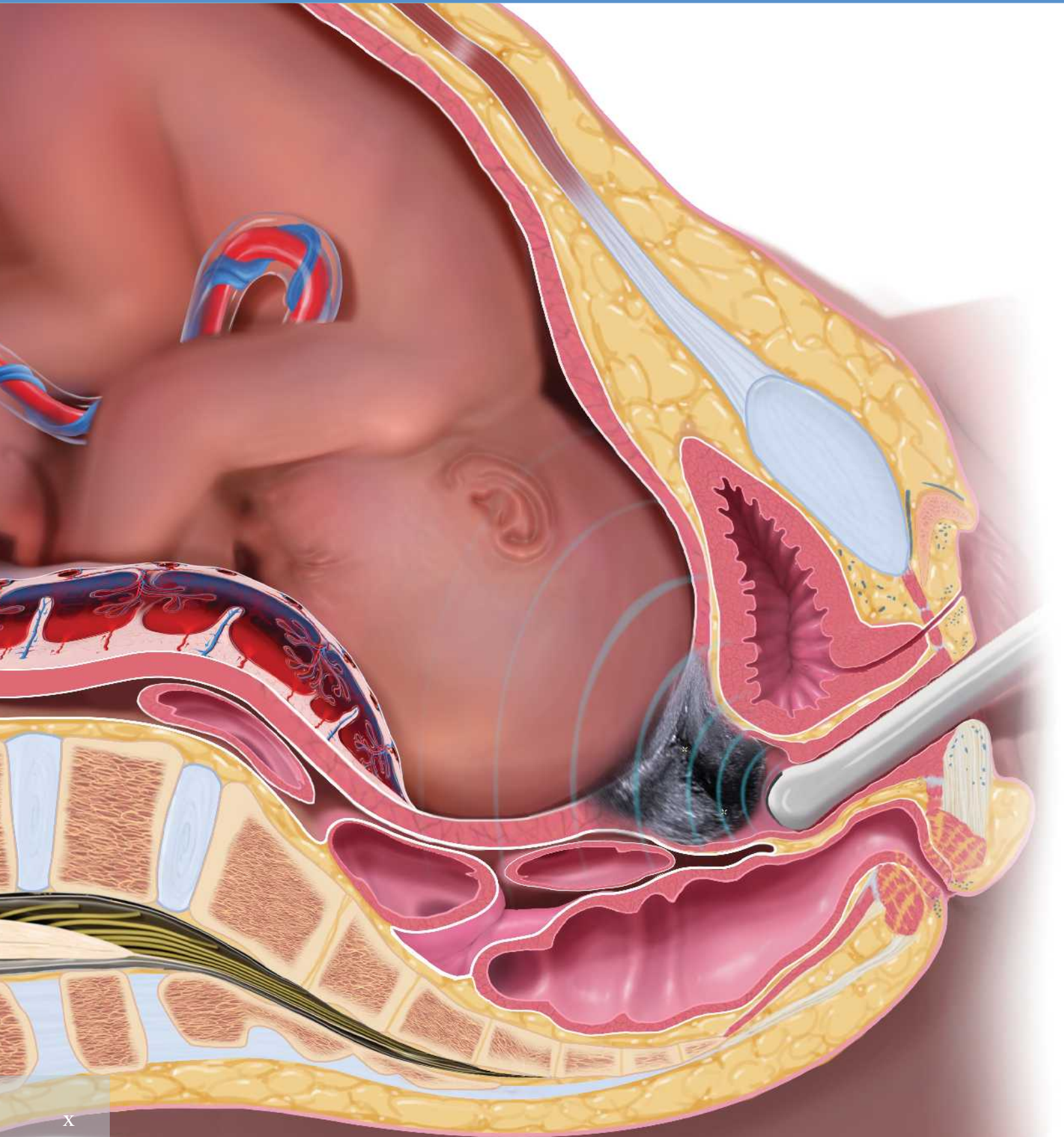
- **Updated and New Chapters:** All previous chapters have been meticulously “revamped” and reflect the most up-to-date information and references. New chapters have been added where appropriate. Since the second edition, multiple specialty society consensus panels have convened and numerous guidelines have been published, all included in this third edition. These guidelines are considered new “standards of care.” We have added many new tables for rapid reference to the most important information.
- **Updated Image Galleries:** Most importantly, all of the image galleries have been updated and are richly illustrated with multiple new graphics: 3D, grayscale, and Doppler ultrasound; fetal MR; and extensive clinical &/or pathologic correlation. There are more than 3,500 images, making this textbook, along with the digital gallery, one of the most comprehensive imaging reference resources on the market.

In addition to the physicians who worked on this book, it is important to acknowledge the talented sonographers and MR technologists for their fine work, which is used extensively throughout this text. I would also like to thank the wonderful Elsevier Salt Lake City editorial staff—with a special shout out to Jeff—and the medical illustrators who make this book truly special (Lane, you rocked it). I am most grateful to my co-leads, Anne and Roya—if I could put all our names as first author, you know I would.

It is with a great deal of pride that we present to you the third edition of *Diagnostic Imaging: Obstetrics*.

Paula J. Woodward, MD

David G. Bragg, MD and Marcia R. Bragg Presidential
Endowed Chair in Oncologic Imaging
Professor of Radiology
Adjunct Professor of Obstetrics and Gynecology
University of Utah School of Medicine
Salt Lake City, Utah



Acknowledgments

Text Editors

Arthur G. Gelsinger, MA
Nina I. Bennett, BA
Karen E. Concannon, MA, PhD
Tricia L. Cannon, BA
Emily C. Fassett, BA
Lisa A. Gervais, BS
Matt Hoecherl, BA

Image Editors

Jeffrey J. Marmorstone, BS
Lisa A. M. Steadman, BS

Medical Editors

Kelli Barbour, MD, MSc, MA
Christina A. Herrera, MD

Illustrations

Lane R. Bennion, MS
Richard Coombs, MS
Laura C. Sesto, MA

Art Direction and Design

Tom M. Olson, BA
Laura C. Sesto, MA

Lead Editor

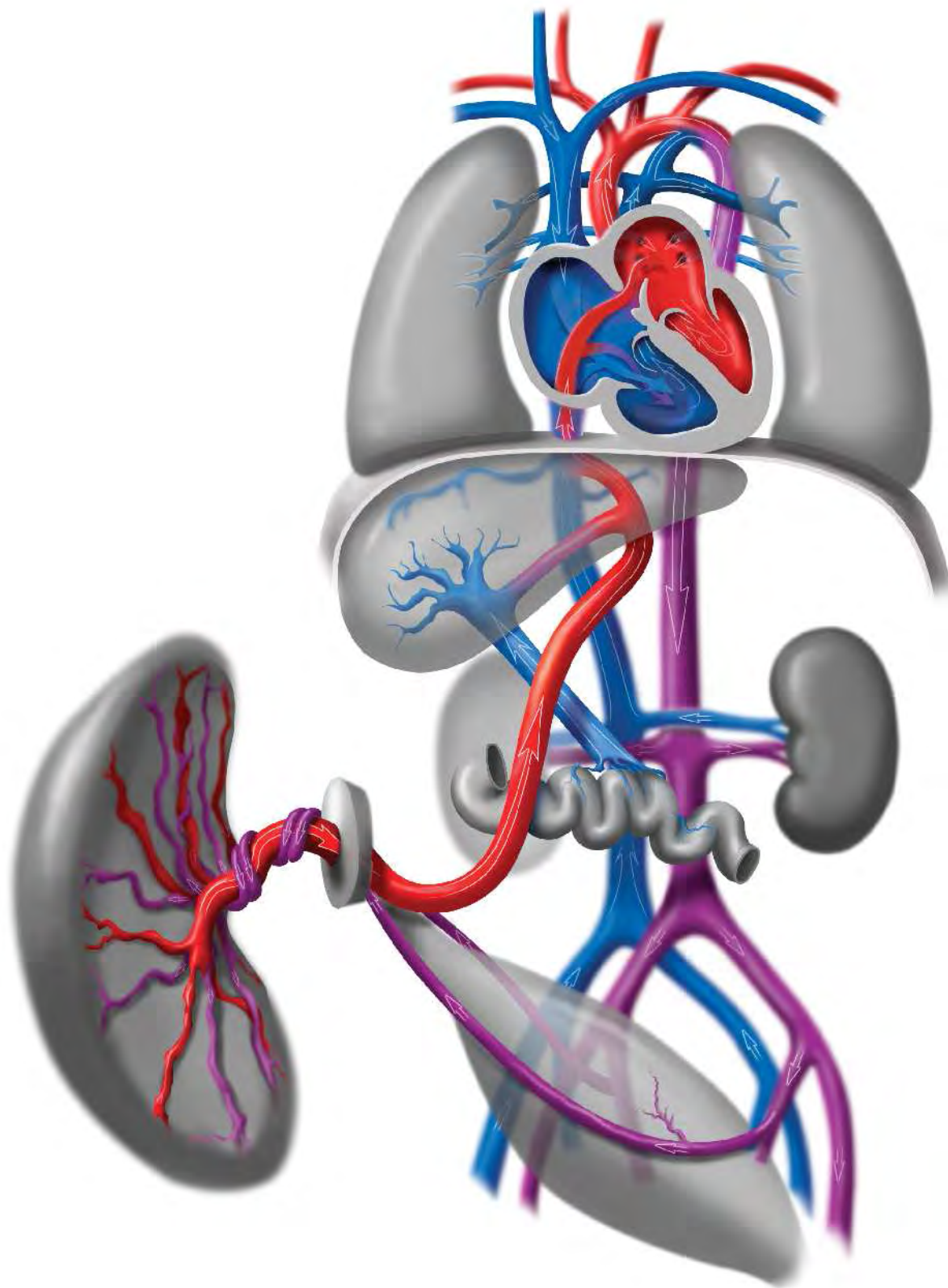
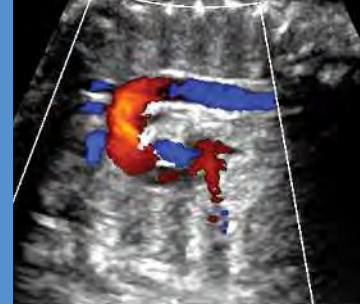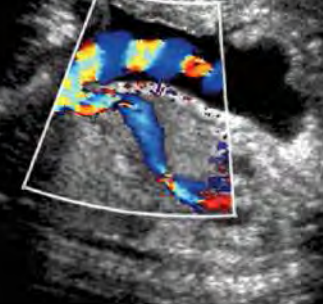
Terry W. Ferrell, MS

Production Coordinators

Rebecca L. Hutchinson, BA
Angela M. G. Terry, BA

ELSEVIER





Sections

SECTION 1: First Trimester

SECTION 2: Brain

SECTION 3: Spine

SECTION 4: Face and Neck

SECTION 5: Chest

SECTION 6: Heart

SECTION 7: Abdominal Wall and Gastrointestinal Tract

SECTION 8: Genitourinary Tract

SECTION 9: Musculoskeletal

SECTION 10: Placenta, Membranes, and Umbilical Cord

SECTION 11: Multiple Gestations

SECTION 12: Aneuploidy

SECTION 13: Syndromes and Multisystem Disorders

SECTION 14: Infection

SECTION 15: Fluid, Growth, and Well-Being

SECTION 16: Maternal Conditions in Pregnancy

TABLE OF CONTENTS

SECTION 1: FIRST TRIMESTER

INTRODUCTION AND OVERVIEW

- 4 **Embryology and Anatomy of the First Trimester**
Anne Kennedy, MD
- 16 **Approach to the First Trimester**
Anne Kennedy, MD

ABNORMAL INTRAUTERINE GESTATION

- 20 **Failed First-Trimester Pregnancy**
Anne Kennedy, MD
- 24 **Perigestational Hemorrhage**
Roya Sohaey, MD
- 28 **Chorionic Bump**
Anne Kennedy, MD
- 30 **Complete Hydatidiform Mole**
Paula J. Woodward, MD

ECTOPIC GESTATION

- 34 **Tubal Ectopic**
Anne Kennedy, MD and Roya Sohaey, MD
- 40 **Interstitial Ectopic**
Paula J. Woodward, MD
- 44 **Cervical Ectopic**
Karen Y. Oh, MD
- 48 **Cesarean Scar Ectopic**
Karen Y. Oh, MD
- 50 **Abdominal Ectopic**
Karen Y. Oh, MD
- 52 **Ovarian Ectopic**
Roya Sohaey, MD
- 54 **Heterotopic Pregnancy**
Karen Y. Oh, MD

PERTINENT DIFFERENTIAL DIAGNOSES

- 56 **Abnormal Gestational Sac and Contents**
Anne Kennedy, MD
- 62 **Adnexal Mass in Pregnancy**
Karen Y. Oh, MD

SECTION 2: BRAIN

INTRODUCTION AND OVERVIEW

- 68 **Embryology and Anatomy of the Brain**
Anne Kennedy, MD
- 84 **Approach to the Supratentorial Brain**
Anne Kennedy, MD
- 90 **Approach to the Posterior Fossa**
Anne Kennedy, MD

CRANIAL DEFECTS

- 96 **Exencephaly, Anencephaly**
Paula J. Woodward, MD
- 100 **Occipital, Parietal Cephalocele**
Paula J. Woodward, MD
- 104 **Atretic Cephalocele**
Paula J. Woodward, MD
- 106 **Frontal Cephalocele**
Roya Sohaey, MD

MIDLINE DEVELOPMENTAL ANOMALIES

- 108 **Agensis/Dysgenesis of the Corpus Callosum**
Karen Y. Oh, MD
- 112 **Interhemispheric Cyst/AVID**
Karen Y. Oh, MD
- 116 **Aprosencephaly, Atelencephaly**
Anne Kennedy, MD
- 118 **Alobar Holoprosencephaly**
Anne Kennedy, MD
- 122 **Semilobar Holoprosencephaly**
Anne Kennedy, MD
- 124 **Lobar Holoprosencephaly**
Anne Kennedy, MD
- 126 **Septo-Optic Dysplasia**
Anne Kennedy, MD
- 130 **Syntelencephaly**
Anne Kennedy, MD

CORTICAL DEVELOPMENTAL ANOMALIES

- 134 **Schizencephaly**
Karen Y. Oh, MD
- 138 **Lissencephaly**
Anne Kennedy, MD
- 142 **Gray Matter Heterotopia**
Anne Kennedy, MD
- 144 **Pachygyria, Polymicrogyria**
Anne Kennedy, MD

CYSTS

- 148 **Choroid Plexus Cyst**
Roya Sohaey, MD
- 150 **Arachnoid Cyst**
Anne Kennedy, MD

DESTRUCTIVE LESIONS

- 154 **Intracranial Hemorrhage**
Karen Y. Oh, MD

TABLE OF CONTENTS

158 Encephalomalacia, Porencephaly

Anne Kennedy, MD

162 Hydranencephaly

Anne Kennedy, MD

POSTERIOR FOSSA MALFORMATIONS

164 Aqueductal Stenosis

Paula J. Woodward, MD

168 Chiari 2 Malformation

Roya Sohaey, MD

172 Chiari 3 Malformation

Roya Sohaey, MD

174 Dandy-Walker Malformation

Karen Y. Oh, MD

178 Vermian Dysgenesis

Karen Y. Oh, MD

180 Blake Pouch Cyst

Anne Kennedy, MD

184 Mega Cisterna Magna

Karen Y. Oh, MD

186 Cerebellar Hypoplasia

Anne Kennedy, MD

190 Rhombencephalosynapsis

Anne Kennedy, MD

VASCULAR MALFORMATIONS

194 Vein of Galen Aneurysmal Malformation

Paula J. Woodward, MD and Karen Y. Oh, MD

198 Arteriovenous Fistula

Anne Kennedy, MD

200 Dural Sinus Malformation

Anne Kennedy, MD

TUMORS

202 Brain Tumors

Paula J. Woodward, MD

204 Choroid Plexus Papilloma

Paula J. Woodward, MD

206 Intracranial Lipoma

Paula J. Woodward, MD

PERTINENT DIFFERENTIAL DIAGNOSES

208 Absent Cavum Septi Pellucidi

Anne Kennedy, MD

212 Mild Ventriculomegaly

Roya Sohaey, MD

216 Abnormal Calvarium

Anne Kennedy, MD

222 Posterior Fossa Cyst/Fluid Collection

Anne Kennedy, MD

SECTION 3: SPINE

228 Embryology and Anatomy of the Spine

Paula J. Woodward, MD

234 Approach to the Fetal Spine

Paula J. Woodward, MD

236 Spina Bifida

Roya Sohaey, MD

242 Iniencephaly

Paula J. Woodward, MD

244 Caudal Regression Sequence

Paula J. Woodward, MD

248 Kyphosis, Scoliosis

Paula J. Woodward, MD

250 Tethered Cord

Roya Sohaey, MD

252 Diastematomyelia

Paula J. Woodward, MD

254 Sacrococcygeal Teratoma

Paula J. Woodward, MD

SECTION 4: FACE AND NECK

262 Embryology and Anatomy of the Face and Neck

Roya Sohaey, MD

274 Approach to the Fetal Face and Neck

Roya Sohaey, MD

278 Cleft Lip, Palate

Roya Sohaey, MD

284 Dacryocystocele

Roya Sohaey, MD

286 Coloboma

Anne Kennedy, MD

288 Epignathus

Paula J. Woodward, MD

292 Epulis

Anne Kennedy, MD

294 Goiter

Roya Sohaey, MD

298 Cystic Hygroma

Roya Sohaey, MD

302 Cervical Teratoma

Paula J. Woodward, MD

PERTINENT DIFFERENTIAL DIAGNOSES

304 Abnormal Orbits/Eyes

Roya Sohaey, MD

310 Abnormal Ears

Roya Sohaey, MD

314 Micrognathia

Anne Kennedy, MD

318 Macroglossia

Anne Kennedy, MD

SECTION 5: CHEST

322 Embryology and Anatomy of the Chest

Paula J. Woodward, MD

330 Approach to the Fetal Chest

Paula J. Woodward, MD

332 Congenital Diaphragmatic Hernia

Paula J. Woodward, MD

336 Congenital Pulmonary Airway Malformation

Paula J. Woodward, MD

340 Bronchopulmonary Sequestration

Paula J. Woodward, MD

344 Bronchogenic Cyst

Paula J. Woodward, MD

TABLE OF CONTENTS

346 Congenital High Airway Obstruction Sequence (CHAOS)

Paula J. Woodward, MD

348 Pulmonary Agenesis

Roya Sohaey, MD and Anne Kennedy, MD

350 Lymphangioma

Karen Y. Oh, MD and Roya Sohaey, MD

354 Mediastinal Teratoma

Paula J. Woodward, MD

PERTINENT DIFFERENTIAL DIAGNOSES

356 Solid/Echogenic Chest Mass

Paula J. Woodward, MD

360 Cystic Chest Mass

Paula J. Woodward, MD

SECTION 6: HEART

INTRODUCTION AND OVERVIEW

364 Embryology and Anatomy of the Cardiovascular System

Thomas A. Miller, DO and Michael D. Puchalski, MD

374 Approach to the Fetal Heart

Michael D. Puchalski, MD

ABNORMAL LOCATION

380 Heterotaxy, Cardiosplenic Syndromes

Michael D. Puchalski, MD and Thomas A. Miller, DO

384 Ectopia Cordis

Anne Kennedy, MD

SEPTAL DEFECTS

388 Ventricular Septal Defect

Michael D. Puchalski, MD

390 Atrioventricular Septal Defect

Michael D. Puchalski, MD

394 Atrial Septal Aneurysm

Paula J. Woodward, MD

RIGHT HEART MALFORMATIONS

396 Ebstein Anomaly

Michael D. Puchalski, MD

400 Tricuspid Dysplasia

Michael D. Puchalski, MD

402 Tricuspid Atresia

Michael D. Puchalski, MD

404 Pulmonary Stenosis, Atresia

Michael D. Puchalski, MD

LEFT HEART MALFORMATIONS

408 Hypoplastic Left Heart

Michael D. Puchalski, MD

412 Coarctation and Interrupted Aortic Arch

Michael D. Puchalski, MD

416 Aortic Stenosis

Michael D. Puchalski, MD

420 Total Anomalous Pulmonary Venous Return

Michael D. Puchalski, MD and Anne Kennedy, MD

CONOTRUNCAL MALFORMATIONS

424 Tetralogy of Fallot

Michael D. Puchalski, MD

428 Transposition of the Great Arteries

Michael D. Puchalski, MD

432 Truncus Arteriosus

Michael D. Puchalski, MD

436 Double-Outlet Right Ventricle

Michael D. Puchalski, MD

MYOCARDIAL AND PERICARDIAL ABNORMALITIES

438 Echogenic Cardiac Focus

Roya Sohaey, MD

440 Cardiomyopathy

Michael D. Puchalski, MD

444 Rhabdomyoma

Michael D. Puchalski, MD and Thomas A. Miller, DO

448 Pericardial Effusion

Anne Kennedy, MD

450 Pericardial Teratoma

Paula J. Woodward, MD

ABNORMAL RHYTHM

452 Irregular Rhythm

Michael D. Puchalski, MD and Thomas A. Miller, DO

454 Tachyarrhythmia

Michael D. Puchalski, MD and Thomas A. Miller, DO

458 Bradyarrhythmia

Michael D. Puchalski, MD and Thomas A. Miller, DO

PERTINENT DIFFERENTIAL DIAGNOSES

462 Abnormal Cardiac Axis

Anne Kennedy, MD

468 Chamber Asymmetry

Michael D. Puchalski, MD

SECTION 7: ABDOMINAL WALL AND GASTROINTESTINAL TRACT

INTRODUCTION AND OVERVIEW

474 Embryology and Anatomy of the Abdominal Wall and GI Tract

Janice L. B. Byrne, MD, Marcia L. Feldkamp, PhD, PA, and Paula J. Woodward, MD

484 Approach to the Abdominal Wall and GI Tract

Paula J. Woodward, MD and Janice L. B. Byrne, MD

ABDOMINAL WALL DEFECTS

490 Gastroschisis

Roya Sohaey, MD

496 Omphalocele

Roya Sohaey, MD

502 Pentalogy of Cantrell

Paula J. Woodward, MD

504 Body Stalk Anomaly

Anne Kennedy, MD

TABLE OF CONTENTS

508 Bladder Exstrophy

Anne Kennedy, MD

512 Cloacal Exstrophy/OEIS Syndrome

Anne Kennedy, MD

BOWEL ABNORMALITIES

516 Esophageal Atresia

Karen Y. Oh, MD and Paula J. Woodward, MD

520 Duodenal Atresia

Karen Y. Oh, MD and Paula J. Woodward, MD

524 Jejunal, Ileal Atresia

Karen Y. Oh, MD

528 Colonic Atresia

Roya Sohaey, MD

530 Anal Atresia

Anne Kennedy, MD

532 Cloacal Malformation/Urogenital Sinus

Paula J. Woodward, MD and Nicole S. Winkler, MD

536 Volvulus

Paula J. Woodward, MD

538 Enteric Duplication Cyst

Paula J. Woodward, MD

PERITONEAL ABNORMALITIES

540 Meconium Peritonitis, Pseudocyst

Paula J. Woodward, MD

544 Mesenteric Lymphangioma

Paula J. Woodward, MD

HEPATOBIILIARY ABNORMALITIES

546 Gallstones

Roya Sohaey, MD

548 Choledochal Cyst

Roya Sohaey, MD

550 Congenital Hepatic Hemangioma

Paula J. Woodward, MD

552 Mesenchymal Hamartoma

Paula J. Woodward, MD

554 Malignant Liver Tumors

Paula J. Woodward, MD

PERTINENT DIFFERENTIAL DIAGNOSES

558 Echogenic Bowel

Roya Sohaey, MD

560 Ascites

Karen Y. Oh, MD

562 Cystic Abdominal Mass

Paula J. Woodward, MD

SECTION 8: GENITOURINARY TRACT

INTRODUCTION AND OVERVIEW

570 Embryology and Anatomy of the Genitourinary Tract

Paula J. Woodward, MD

580 Approach to the Fetal Genitourinary Tract

Paula J. Woodward, MD

584 Urinary Tract Dilation

Roya Sohaey, MD

RENAL DEVELOPMENTAL VARIANTS

588 Unilateral Renal Agenesis

Karen Y. Oh, MD

590 Duplicated Collecting System

Karen Y. Oh, MD

594 Pelvic Kidney

Karen Y. Oh, MD

596 Horseshoe Kidney

Karen Y. Oh, MD

598 Crossed Fused Ectopia

Karen Y. Oh, MD

RENAL MALFORMATIONS

600 Bilateral Renal Agenesis

Karen Y. Oh, MD

604 Ureteropelvic Junction Obstruction

Roya Sohaey, MD

608 Urinoma

Roya Sohaey, MD

610 Obstructive Renal Dysplasia

Roya Sohaey, MD

614 Multicystic Dysplastic Kidney

Roya Sohaey, MD

618 Autosomal Recessive Polycystic Kidney Disease

Anne Kennedy, MD

622 Mesoblastic Nephroma

Paula J. Woodward, MD

ADRENAL ABNORMALITIES

626 Adrenal Hemorrhage

Anne Kennedy, MD

628 Neuroblastoma

Paula J. Woodward, MD

632 Congenital Adrenal Hyperplasia

Roya Sohaey, MD

BLADDER MALFORMATIONS

634 Posterior Urethral Valves

Karen Y. Oh, MD

638 Prune-Belly Syndrome

Karen Y. Oh, MD

642 Ureterocele

Karen Y. Oh, MD

646 Urachal Anomalies

Paula J. Woodward, MD

GENITAL ABNORMALITIES

650 Disorders of Sexual Development

Roya Sohaey, MD

656 Hypospadias

Roya Sohaey, MD

658 Ovarian Cyst

Anne Kennedy, MD

662 Hydrocolpos

Paula J. Woodward, MD and Nicole S. Winkler, MD

TABLE OF CONTENTS

PERTINENT DIFFERENTIAL DIAGNOSES

- 664 **Hydronephrosis**
Roya Sohaey, MD
- 668 **Echogenic Kidneys**
Paula J. Woodward, MD
- 670 **Unilateral Enlarged Kidney**
Paula J. Woodward, MD
- 674 **Suprarenal Mass**
Roya Sohaey, MD
- 676 **Scrotal Mass**
Paula J. Woodward, MD

SECTION 9: MUSCULOSKELETAL

DYSPLASIAS

- 680 **Approach to Skeletal Dysplasias**
Janice L. B. Byrne, MD
- 686 **Bone Length Charts**
Janice L. B. Byrne, MD
- 688 **Achondrogenesis, Hypochondrogenesis**
Janice L. B. Byrne, MD
- 694 **Achondroplasia**
Paula J. Woodward, MD and Janice L. B. Byrne, MD
- 698 **Amelia/Phocomelia**
Janice L. B. Byrne, MD
- 702 **Atelosteogenesis**
Janice L. B. Byrne, MD
- 706 **Campomelic Dysplasia**
Janice L. B. Byrne, MD
- 710 **Chondrodysplasia Punctata**
Janice L. B. Byrne, MD
- 714 **Hypophosphatasia**
Janice L. B. Byrne, MD
- 718 **Osteogenesis Imperfecta**
Janice L. B. Byrne, MD
- 722 **Short Rib-Polydactyly Syndromes**
Janice L. B. Byrne, MD
- 726 **Thanatophoric Dysplasia**
Janice L. B. Byrne, MD

EXTREMITY MALFORMATIONS

- 732 **Clubfoot**
Roya Sohaey, MD
- 736 **Rocker-Bottom Foot**
Roya Sohaey, MD
- 738 **Sandal Gap Foot**
Roya Sohaey, MD
- 740 **Radial Ray Malformation**
Janice L. B. Byrne, MD
- 744 **Clinodactyly**
Roya Sohaey, MD
- 746 **Polydactyly**
Janice L. B. Byrne, MD
- 750 **Syndactyly**
Janice L. B. Byrne, MD
- 754 **Split Hand/Foot Malformation**
Janice L. B. Byrne, MD

- 758 **Arthrogryposis, Akinesia Sequence**
Janice L. B. Byrne, MD
- 764 **Proximal Focal Femoral Dysplasia**
Karen Y. Oh, MD
- 768 **Fibular/Tibial Hemimelia**
Karen Y. Oh, MD

PERTINENT DIFFERENTIAL DIAGNOSES

- 770 **Mildly Short Femur/Humerus**
Karen Y. Oh, MD
- 774 **Angulated Bones**
Janice L. B. Byrne, MD
- 780 **Abnormal Ossification**
Janice L. B. Byrne, MD

SECTION 10: PLACENTA, MEMBRANES, AND UMBILICAL CORD

INTRODUCTION AND OVERVIEW

- 784 **Approach to the Placenta and Umbilical Cord**
Roya Sohaey, MD

PLACENTA AND MEMBRANE ABNORMALITIES

- 790 **Placental Abruption**
Roya Sohaey, MD
- 794 **Placenta Previa**
Roya Sohaey, MD
- 798 **Vasa Previa**
Roya Sohaey, MD
- 800 **Morbidly Adherent Placenta**
Anne Kennedy, MD
- 806 **Placental Lake, Intervillous Thrombus**
Roya Sohaey, MD
- 810 **Succenturiate Lobe**
Roya Sohaey, MD
- 812 **Circumvallate Placenta**
Roya Sohaey, MD
- 814 **Marginal and Velamentous Cord Insertion**
Roya Sohaey, MD
- 816 **Chorioangioma**
Paula J. Woodward, MD
- 820 **Placental Teratoma**
Paula J. Woodward, MD
- 822 **Placental Mesenchymal Dysplasia**
Anne Kennedy, MD

UMBILICAL CORD ABNORMALITIES

- 824 **Single Umbilical Artery**
Roya Sohaey, MD
- 826 **Umbilical Vein Varix**
Anne Kennedy, MD
- 828 **Persistent Right Umbilical Vein**
Roya Sohaey, MD

PERTINENT DIFFERENTIAL DIAGNOSES

- 830 **Placental Cysts and Masses**
Roya Sohaey, MD

TABLE OF CONTENTS

- 834 **Umbilical Cord Cysts and Masses**
Roya Sohaey, MD

SECTION 11: MULTIPLE GESTATIONS

- 840 **Approach to Multiple Gestations**
Anne Kennedy, MD
- 846 **Dichorionic Diamniotic Twins**
Anne Kennedy, MD
- 850 **Monochorionic Diamniotic Twins**
Anne Kennedy, MD
- 854 **Monochorionic Monoamniotic Twins**
Anne Kennedy, MD
- 858 **Discordant Twin Growth**
Anne Kennedy, MD
- 862 **Twin-Twin Transfusion Syndrome**
Anne Kennedy, MD
- 866 **Twin Reversed Arterial Perfusion**
Anne Kennedy, MD
- 870 **Conjoined Twins**
Anne Kennedy, MD
- 874 **Triplets and Beyond**
Anne Kennedy, MD
- 878 **Fetus-in-Fetu**
Anne Kennedy, MD

SECTION 12: ANEUPLOIDY

- 884 **Approach to Genetic Screening**
Roya Sohaey, MD
- 890 **Trisomy 21**
Roya Sohaey, MD
- 896 **Trisomy 18**
Roya Sohaey, MD
- 902 **Trisomy 13**
Roya Sohaey, MD
- 908 **Turner Syndrome (45,X)**
Roya Sohaey, MD
- 912 **Triploidy**
Roya Sohaey, MD

SECTION 13: SYNDROMES AND MULTISYSTEM DISORDERS

- 918 **22q11 Deletion Syndrome**
Janice L. B. Byrne, MD
- 920 **Aicardi Syndrome**
Anne Kennedy, MD
- 924 **Amniotic Band Syndrome**
Anne Kennedy, MD
- 928 **Apert Syndrome**
Janice L. B. Byrne, MD
- 932 **Beckwith-Wiedemann Syndrome**
Paula J. Woodward, MD and Janice L. B. Byrne, MD
- 936 **Carpenter Syndrome**
Janice L. B. Byrne, MD
- 938 **CHARGE Syndrome**
Anne Kennedy, MD
- 940 **Cornelia de Lange Syndrome**
Janice L. B. Byrne, MD

- 944 **Cystic Fibrosis**
Janice L. B. Byrne, MD
- 946 **Diabetic Embryopathy**
Janice L. B. Byrne, MD
- 950 **Fraser Syndrome**
Paula J. Woodward, MD
- 952 **Fryns Syndrome**
Janice L. B. Byrne, MD
- 954 **Goldenhar Syndrome**
Anne Kennedy, MD
- 956 **Holt-Oram Syndrome**
Janice L. B. Byrne, MD
- 960 **Idiopathic Infantile Arterial Calcification**
Anne Kennedy, MD
- 962 **Joubert Syndrome**
Anne Kennedy, MD
- 966 **Klippel-Trenaunay-Weber Syndrome**
Roya Sohaey, MD
- 970 **Meckel-Gruber Syndrome**
Paula J. Woodward, MD
- 974 **Multiple Pterygium Syndromes**
Janice L. B. Byrne, MD
- 976 **Neu-Laxova Syndrome**
Anne Kennedy, MD
- 978 **Noonan Syndrome**
Janice L. B. Byrne, MD
- 980 **PHACES Syndrome**
Anne Kennedy, MD
- 982 **Pfeiffer Syndrome**
Janice L. B. Byrne, MD
- 986 **Pierre Robin Sequence**
Janice L. B. Byrne, MD
- 988 **Sirenomelia**
Janice L. B. Byrne, MD
- 992 **Smith-Lemli-Opitz Syndrome**
Janice L. B. Byrne, MD
- 996 **Treacher Collins Syndrome**
Roya Sohaey, MD
- 1000 **Tuberous Sclerosis**
Karen Y. Oh, MD
- 1004 **VACTERL Association**
Janice L. B. Byrne, MD
- 1008 **Valproate Embryopathy**
Janice L. B. Byrne, MD
- 1010 **Warfarin (Coumadin) Embryopathy**
Janice L. B. Byrne, MD
- 1012 **Walker-Warburg Syndrome**
Anne Kennedy, MD

SECTION 14: INFECTION

- 1016 **Cytomegalovirus**
Janice L. B. Byrne, MD and Anne Kennedy, MD
- 1020 **Parvovirus**
Janice L. B. Byrne, MD
- 1022 **Toxoplasmosis**
Janice L. B. Byrne, MD
- 1024 **Varicella**
Janice L. B. Byrne, MD

TABLE OF CONTENTS

SECTION 15: FLUID, GROWTH, AND WELL-BEING

1028 Approach to Fetal Well-Being

Roya Sohaey, MD

1034 Fetal Growth Restriction

Roya Sohaey, MD

1038 Macrosomia

Roya Sohaey, MD

1040 Fetal Anemia

Karen Y. Oh, MD

PERTINENT DIFFERENTIAL DIAGNOSES

1044 Polyhydramnios

Roya Sohaey, MD

1048 Oligohydramnios

Roya Sohaey, MD

1052 Hydrops

Anne Kennedy, MD and Roya Sohaey, MD

SECTION 16: MATERNAL CONDITIONS IN PREGNANCY

1060 Cervical Insufficiency/Short Cervix

Anne Kennedy, MD

1066 Myoma in Pregnancy

Roya Sohaey, MD

1070 Müllerian Duct Anomalies in Pregnancy

Anne Kennedy, MD

1074 Synechiae

Anne Kennedy, MD and Roya Sohaey, MD

1076 Uterine Rupture

Anne Kennedy, MD

1080 Retained Products of Conception

Paula J. Woodward, MD

PERTINENT DIFFERENTIAL DIAGNOSES

1082 Acute Abdomen in Pregnancy

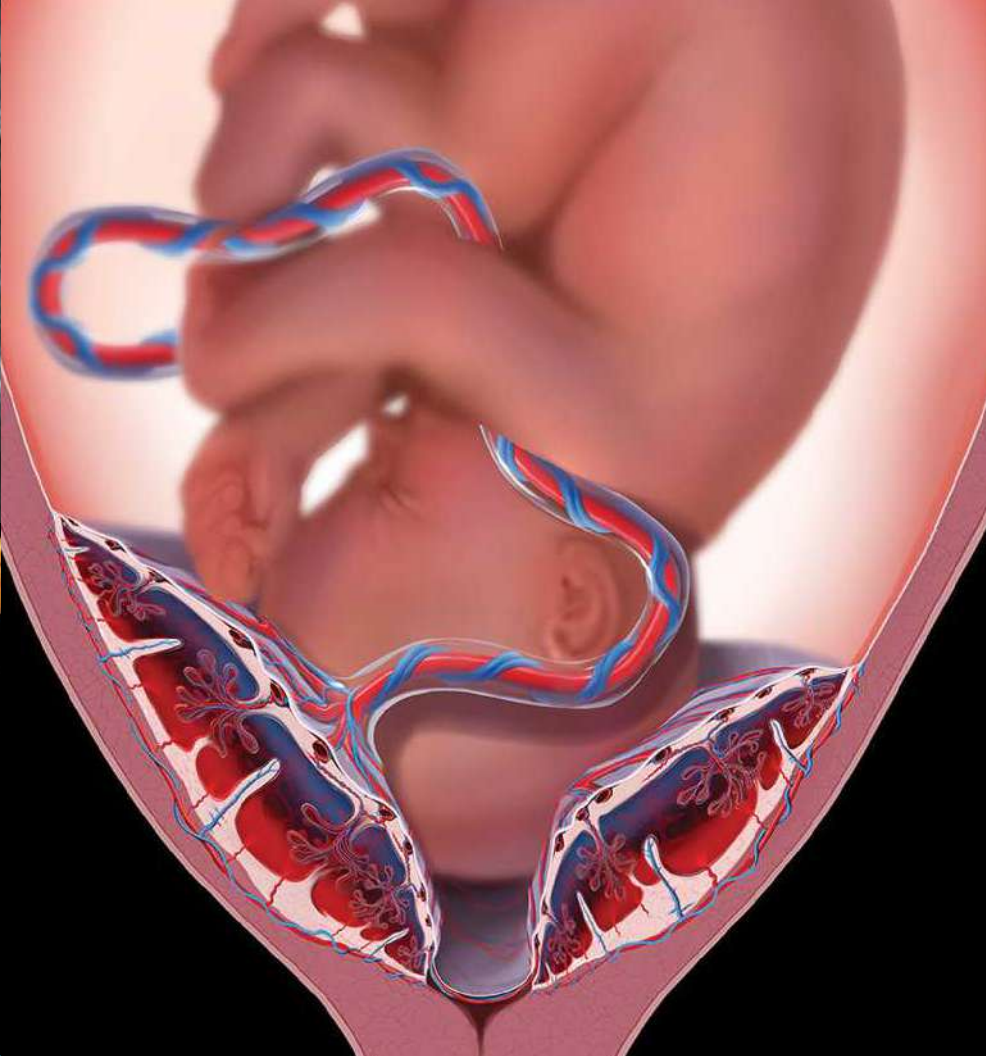
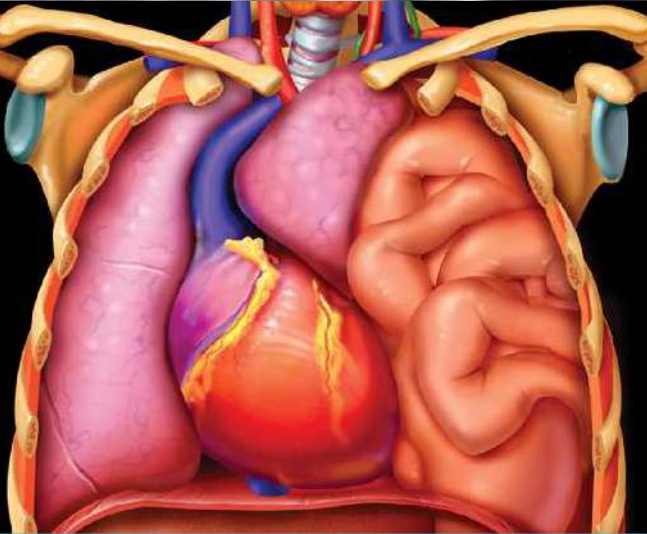
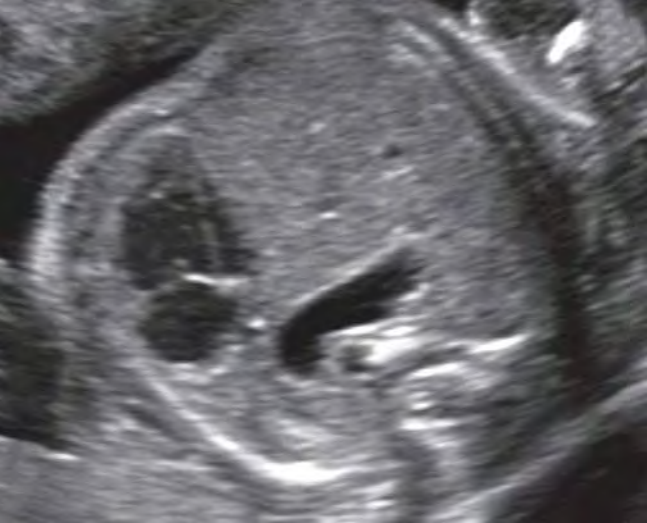Anne Kennedy, MD

1086 Intrauterine Linear Echoes

Roya Sohaey, MD

This page intentionally left blank

This page intentionally left blank



Diagnostic Imaging

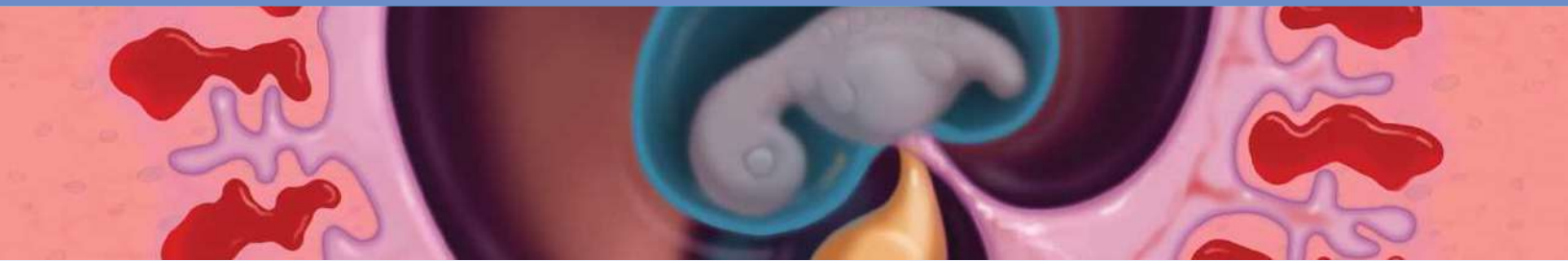Obstetrics

THIRD EDITION

This page intentionally left blank

SECTION 1

First Trimester



Introduction and Overview

Embryology and Anatomy of the First Trimester	4
Approach to the First Trimester	16

Abnormal Intrauterine Gestation

Failed First-Trimester Pregnancy	20
Perigestational Hemorrhage	24
Chorionic Bump	28
Complete Hydatidiform Mole	30

Ectopic Gestation

Tubal Ectopic	34
Interstitial Ectopic	40
Cervical Ectopic	44
Cesarean Scar Ectopic	48
Abdominal Ectopic	50
Ovarian Ectopic	52
Heterotopic Pregnancy	54

Pertinent Differential Diagnoses

Abnormal Gestational Sac and Contents	56
Adnexal Mass in Pregnancy	62

TERMINOLOGY

Definitions

- 1st trimester covers time from 1st day of last menstrual period to end of 13th postmenstrual week

EMBRYOLOGY

Embryologic Events

- 1st trimester includes
 - Ovulation
 - Fertilization
 - Cleavage
 - Implantation
 - Embryonic development
 - Organogenesis
 - Placental development
 - Umbilical cord development

Ovulation

- Primordial follicles → 5-12 primary follicles per cycle
- All but 1 degenerate, leaving single dominant follicle
- Pituitary gonadotrophin surge → ovulation → oocyte extruded onto ovarian surface
- Oocyte surrounded by tough zona pellucida as well as layers of cumulus cells
- Fimbria sweep oocyte into fallopian tube
- Remaining "empty" follicle becomes corpus luteum producing estrogen and progesterone

Fertilization

- Occurs in fallopian tube
- Oocyte can be fertilized for ~ 24 hours
- Sperm penetrates oocyte, cell membranes fuse → zygote
- Spermatozoon and oocyte nuclei become male and female pronuclei
- Nuclear membranes disappear, chromosomes replicate in preparation for zygote cleavage

Cleavage

- Zygote → 2 cells → 4 cells → 8 cells → morula → blastocyst
- Several cell divisions result in smaller parts called blastomeres
- At 8 cell stage, compaction occurs with some cells → inner cell mass or embryoblast, some cells → peripheral trophoblast
 - Inner cell mass/embryoblast = embryonic pole of blastocyst
- 16-32 blastomeres = morula
- Morula absorbs fluid → central cavity called blastocoel within blastocyst

Implantation

- Blastocyst "hatches" from zona pellucida
- "Naked" blastocyst then interacts directly with maternal endometrium
- Trophoblast cells give rise to membranes and placenta, not embryo proper
 - Trophoblast cells at embryonic pole → syncytiotrophoblast, which burrows into endometrial lining
 - Remaining trophoblast cells become cytotrophoblast

- Maternal endometrial cells differentiate into decidual cells in response to
 - Progesterone secreted by corpus luteum
 - β human chorionic gonadotrophin produced by syncytiotrophoblast

Embryonic Development

- Bilaminar embryonic disc forms when embryoblast splits into epiblast and hypoblast
- Hypoblast = primitive endoderm
 - Hypoblast cells migrate around cavity of blastocyst to create primary yolk sac
 - Hypoblast + primary yolk sac give rise to extraembryonic mesoderm (loosely associated cells filling blastocyst cavity around primary yolk sac)
 - 2nd wave of migrating hypoblast cells create secondary yolk sac, which displaces primary yolk sac
 - Extraembryonic mesoderm splits into 2 layers, creating chorionic cavity (extraembryonic coelom)
 - Chorionic cavity separates embryo/amnion/yolk sac from chorion (outer wall of blastocyst)
- Epiblast contributes to embryo and gives rise to amnion
 - Fluid collects between epiblast and overlying trophoblast → cavity
 - Layer of epiblast differentiates into amniotic membrane separating new cavity from cytotrophoblast
- Trilaminar disc
 - Develops by process of gastrulation, which moves cells to new locations with resulting induction
 - 3 primary germ layers = ectoderm, mesoderm, endoderm
 - Body axes also determined by gastrulation
- Disc elongates and folds → series of tubular structures → major organ systems
- Ectoderm → neural plate → neural tube + neural crest cells
 - Neural tube → brain and spinal cord
 - Neural crest cells migrate from neural tube → many differing structures and cell types
- Mesoderm
 - Head mesoderm → muscles of face, jaw, and throat
 - Notochordal process
 - Cardiogenic mesoderm
 - Somites → most of axial skeleton
 - Intermediate mesoderm → genitourinary system
 - Lateral plate mesoderm → abdominal wall and gut walls
- Endoderm
 - Foregut, midgut, hindgut (oropharyngeal membrane → mouth)

Organogenesis

- **Central nervous system**
 - Arises from neural folds → neural tube + neural crest
 - Cranial/rostral 2/3 of neural tube → brain
 - Caudal 1/3 of neural tube → spinal cord, nerves
 - Neural crest → peripheral nerves, autonomic nervous system
- **Cardiovascular system**
 - Arises from cardiac tube → heart and great vessels
 - Cardiogenic precursors form 1° heart field at cranial end of embryo

- Lateral endocardial tubes brought together by embryonic folding → primitive heart tube
- Looping, remodeling, septation of primitive heart tube → definitive 4-chamber heart
- Conotruncus = primitive outflow tract that splits → ventricular outflow tracts
- **Respiratory system**
 - Foregut → respiratory diverticulum → 1° bronchial buds → 3 right + 2 left 2° bronchial buds → terminal bronchioles → respiratory bronchioles → primitive alveoli
- **Gastrointestinal system**
 - Early embryonic folding → endodermal tube → foregut, midgut, hindgut
 - Foregut (blind-ending at oropharyngeal membrane) → esophagus, stomach, proximal duodenum
 - Liver, gallbladder, cystic duct, and pancreas arise from duodenal diverticula
 - Midgut (initially open to yolk sac) → distal duodenum to proximal 2/3 transverse colon
 - Future ileum elongates rapidly → 1° intestinal loop, which herniates into base of umbilical cord rotating 90°
 - During retraction into peritoneal cavity, additional 180° rotation secures normal bowl orientation with cecum right, duodenojejunal flexure left
 - Hindgut (blind-ending at cloacal membrane) → distal 1/3 transverse colon to rectum
 - Terminal expansion of primitive hindgut tube → cloaca
 - Urorectal septum divides cloaca into urogenital sinus + dorsal anorectal canal
- **Genitourinary system**
 - Intermediate mesoderm → pronephros, mesonephros, metanephros
 - Mesonephros → rudimentary kidneys connected to cloaca by mesonephric ducts
 - Mesonephric ducts → ureteral bud → collecting system
 - Ureteral bud connection to metanephric blastema → induction of nephron formation
 - Bladder arises from cloaca and allantois
 - Bladder separated from rectum by urogenital sinus
- **Musculoskeletal system**
 - Upper and lower extremities develop from individual limb buds

Placental Development

- Chorionic sac initially covered in villi, atrophy of those adjacent to uterine cavity → chorion laeve
- In villi adjacent to implantation site, burrowing syncytiotrophoblast develops trophoblastic lacunae
 - Adjacent maternal capillaries expand → maternal sinusoids, anastomose with trophoblastic lacunae
 - Budding/proliferation of cytotrophoblast into syncytiotrophoblast and maternal lacunae → mature tertiary villi
 - Tertiary villi contain fully differentiated blood vessels for gas exchange in chorion frondosum
- Chorion frondosum + decidua basalis = placenta

Umbilical Cord Development

- Embryonic disc lies between amnion and yolk sac

- Embryo initially connected to chorion by connecting stalk, which arises from extraembryonic mesoderm
 - Allantois (endodermal hindgut diverticulum) arises as outpouching of yolk sac
 - Allantois and allantoic vessels extend into connecting stalk (become umbilical vessels)
- Embryonic growth and folding result in blind-ended foregut and hindgut tubes with midgut open to yolk sac
 - As body wall forms by lateral folding and midgut becomes tubular, yolk sac is "pinched off"
 - Narrow elongated neck of yolk sac = vitelline duct, which connects yolk sac to closing midgut tube
- As embryo enlarges and folds, amniotic cavity expands to encompass embryo completely except at umbilical ring
 - Connecting stalk, allantois, vitelline duct become incorporated as umbilical cord
 - Amnion continues to enlarge and forms tubular covering over incorporated cord elements → dense epithelial covering
- Progressive cord elongation and coiling occur with embryonic/fetal growth and movement

ANATOMY IMAGING ISSUES

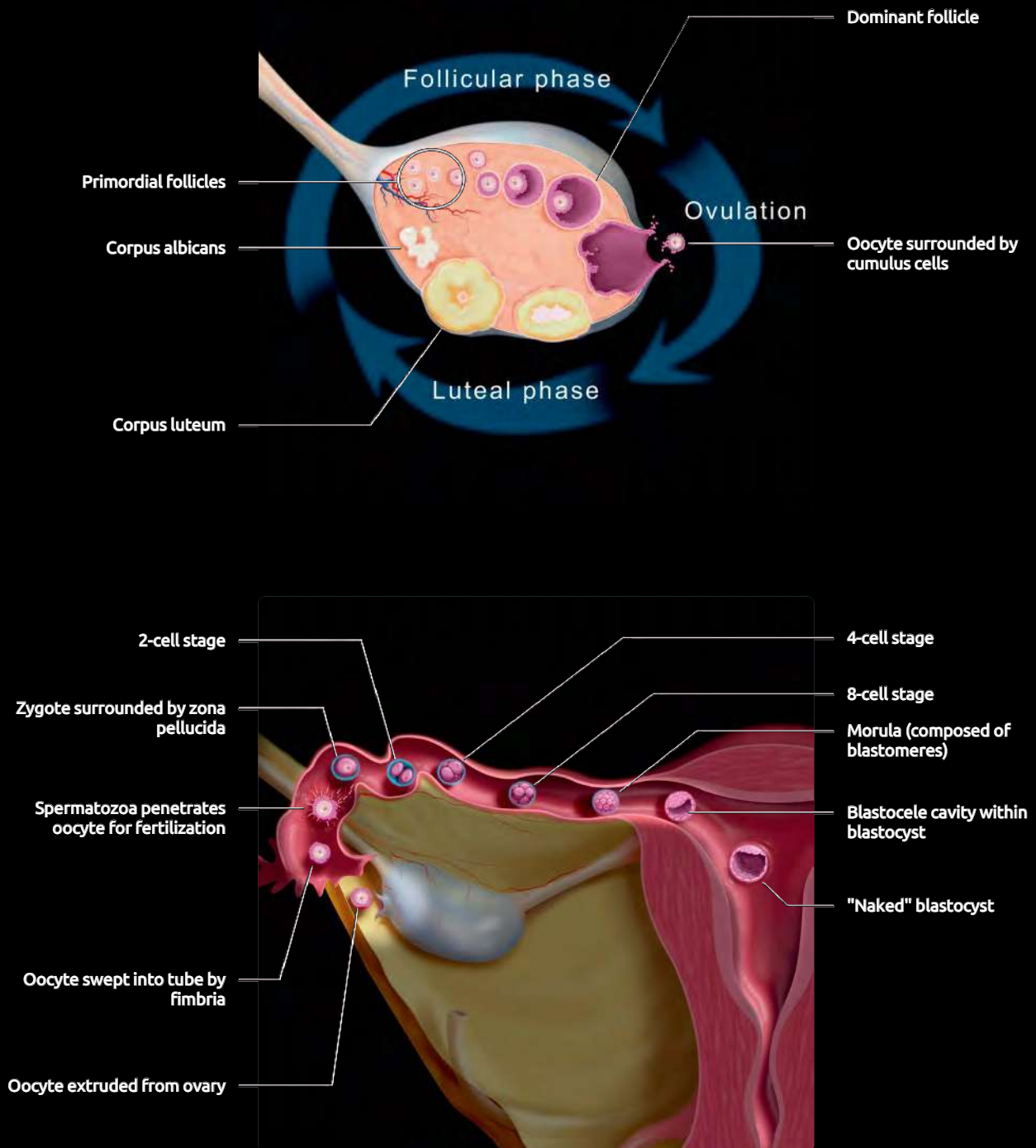
Questions

- Developmental milestones (in weeks post LMP)
 - Gestational sac (intradecidual sac sign) usually visible by 4.0-4.5 weeks
 - Yolk sac usually visible by 5.0-5.5 weeks
 - Distinct embryo with cardiac activity usually visible by 6.0-6.5 weeks
- Developmental milestones based on mean sac diameter (MSD)
 - Embryo should be visible if MSD > 25 mm EV
- Embryo of > 7 mm in length must have cardiac activity
 - If embryo seen within visible amnion, cardiac activity should be present (expanded amnion sign)
- Gestational age assessment most accurate in 1st trimester
 - Biological variations take effect after 13 weeks
- Determination of chorionicity best done in multiple pregnancies
 - Most important factor in prognosis
- Is there evidence of increased risk for aneuploidy
 - 11- to 13-week scan can be used to adjust priori risk of aneuploidy, determine need for invasive testing
- Is anatomy normal
 - Organogenesis is complete by end of 13th week
 - Use EV sonography for best resolution
- 1st trimester is time of complex cell multiplication and differentiation
 - Great potential for error if normal processes are not clearly understood

SELECTED REFERENCES

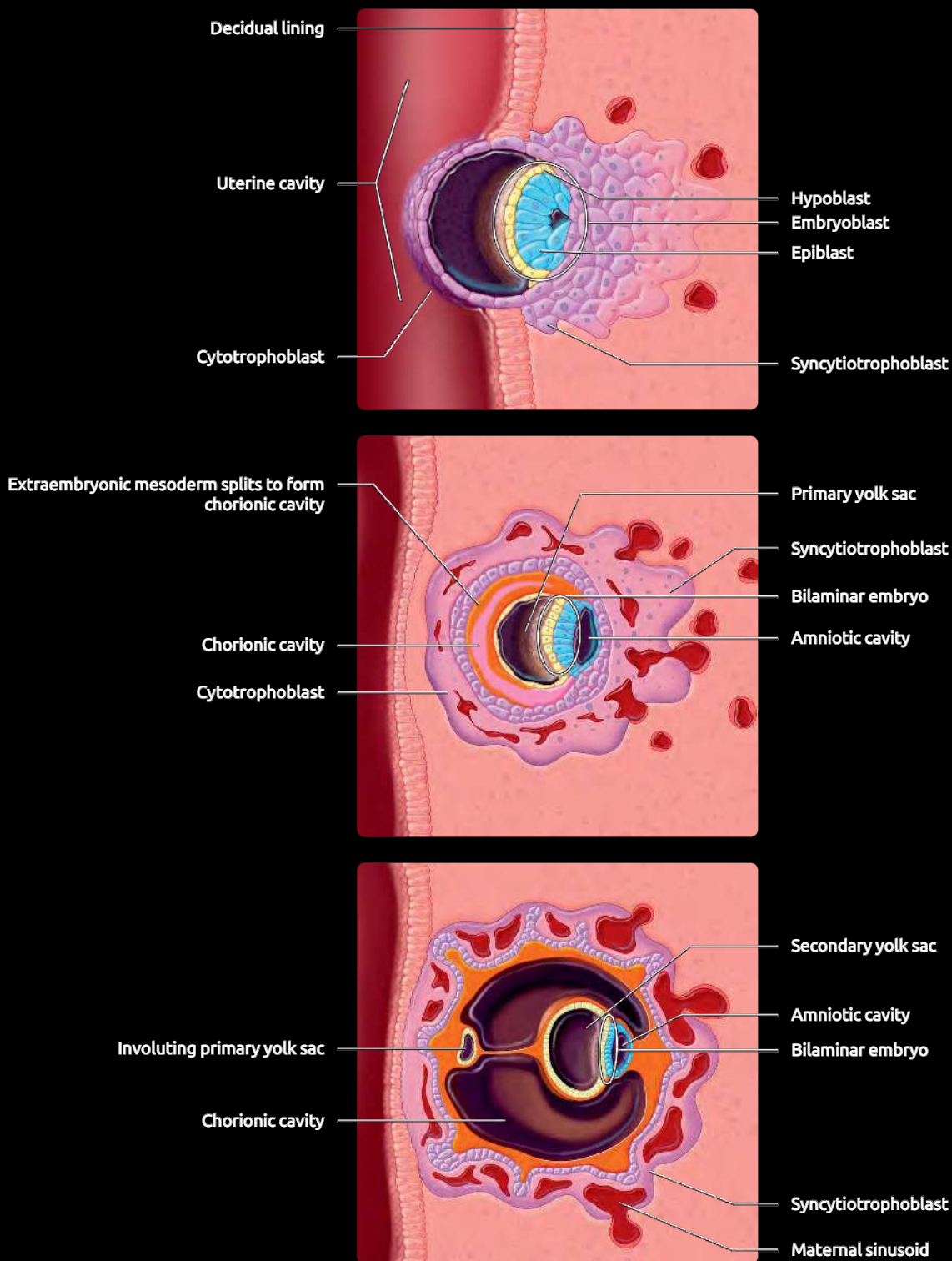
1. Doubilet PM et al: Diagnostic criteria for nonviable pregnancy early in the first trimester. *N Engl J Med.* 369(15):1443-51, 2013
2. Barnhart K et al: Pregnancy of unknown location: a consensus statement of nomenclature, definitions, and outcome. *Fertil Steril.* 95(3):857-66, 2011

OVULATION AND FERTILIZATION



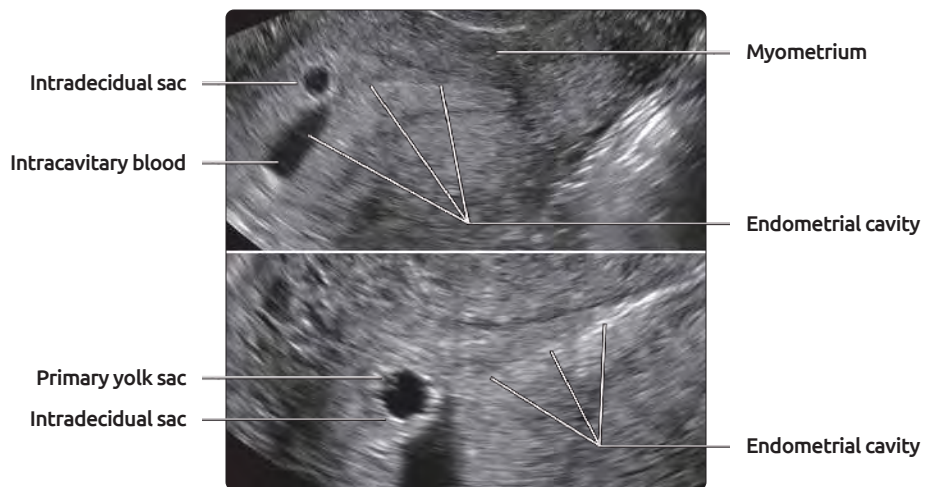
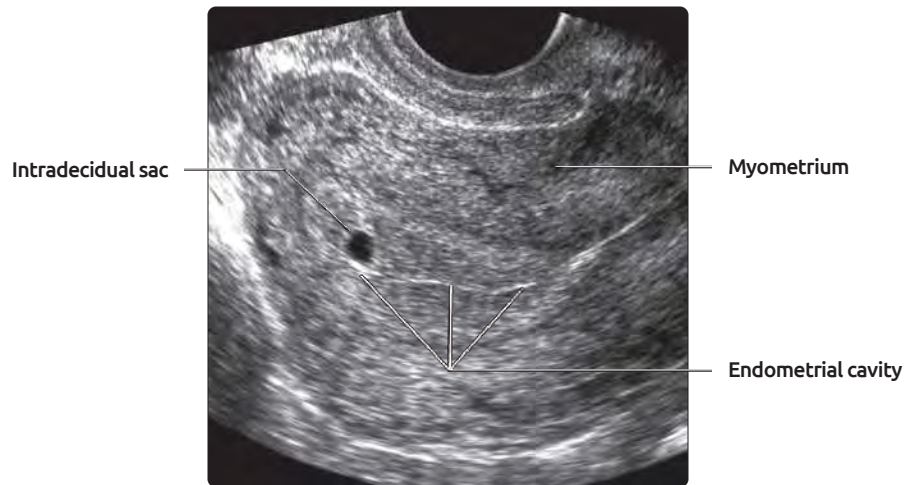
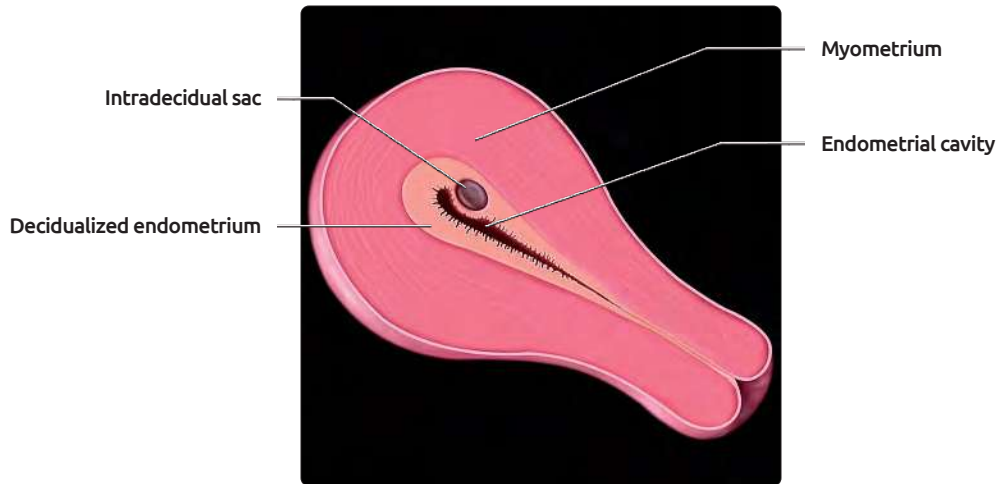
(Top) During the follicular phase of the menstrual cycle, several follicles begin to develop; 1 becomes dominant and eventually a mature oocyte is extruded from the ovarian surface at the time of ovulation. The remaining follicle becomes the corpus luteum, which produces progesterone and helps to maintain the early pregnancy until the placenta is formed. If fertilization does not occur, the corpus luteum degenerates into a corpus albicans. **(Bottom)** The oocyte is swept into the fallopian tube where it is fertilized. The fertilized ovum divides repeatedly during passage along the tube such that by the time it reaches the endometrial cavity, a blastocyst has formed. The blastocyst "hatches" from the zona pellucida and implants into the maternal endometrium.

CLEAVAGE AND IMPLANTATION



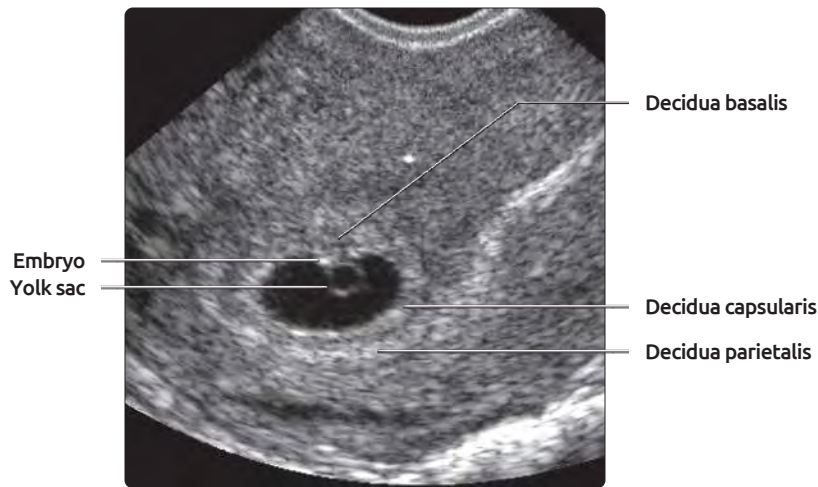
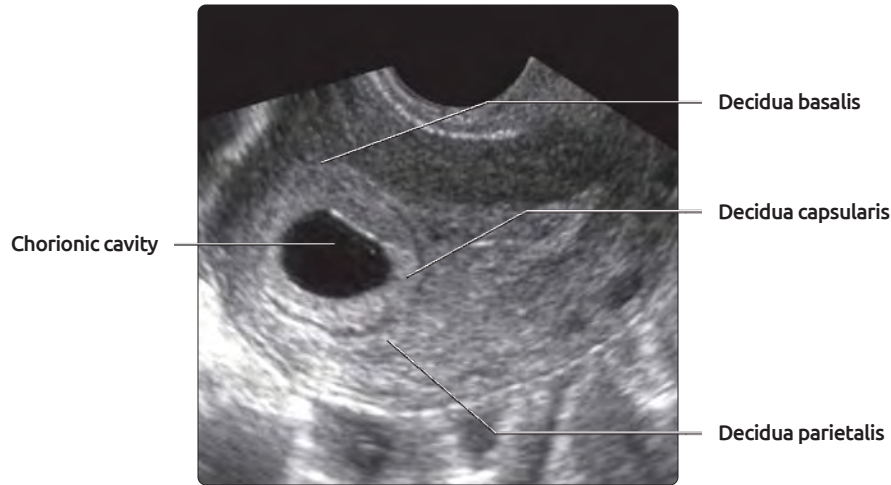
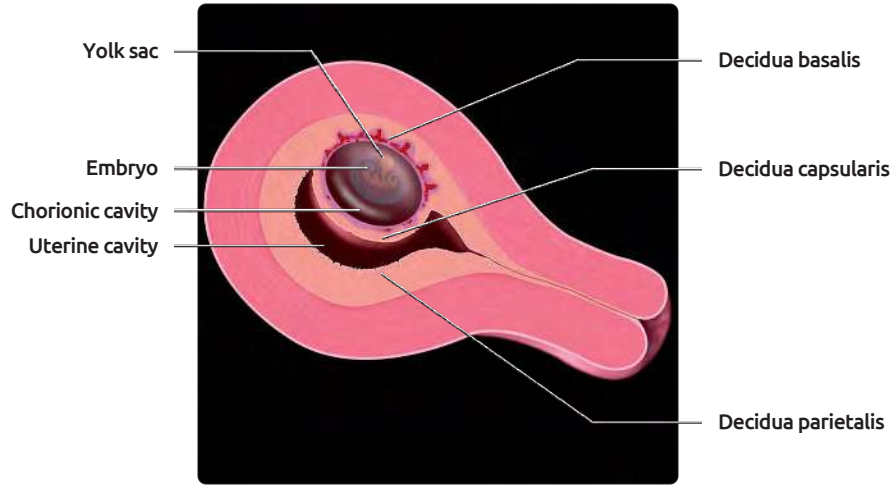
(Top) While the dividing zygote is still in the fallopian tube (8-cell stage), cells differentiate into embryoblast and trophoblast. Syncytiotrophoblast interacts with the endometrium to form the placenta; the remainder is the cytotrophoblast. Embryoblast cells will give rise to the embryo, amnion, and yolk sac. **(Middle)** The embryoblast splits into 2 layers: Epiblast and hypoblast. The hypoblast gives rise to the primary and secondary yolk sacs and extraembryonic mesoderm. The latter splits, forming the chorionic cavity. The epiblast gives rise to the embryo and the amnion. **(Bottom)** As the primary yolk sac involutes, the secondary yolk sac develops. It is the secondary yolk sac that is visible sonographically; however, by convention, it is usually referred to as simply the yolk sac on ultrasound images. The chorionic cavity enlarges. The embryo is still a bilaminar disc.

INTRADECIDUAL SAC SIGN



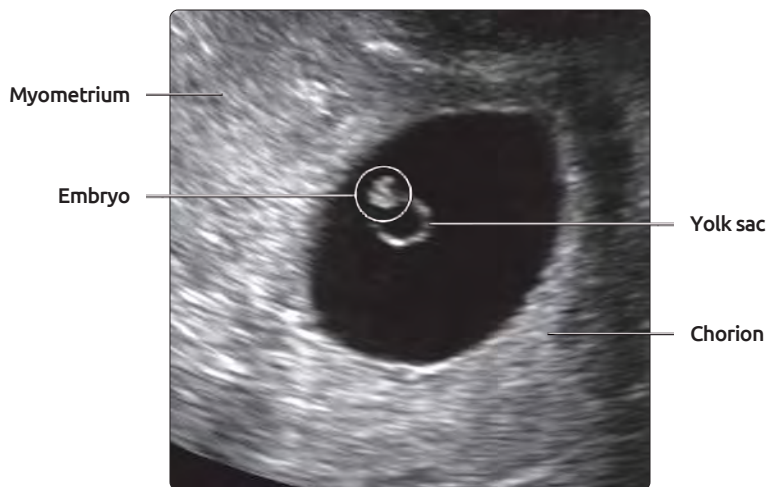
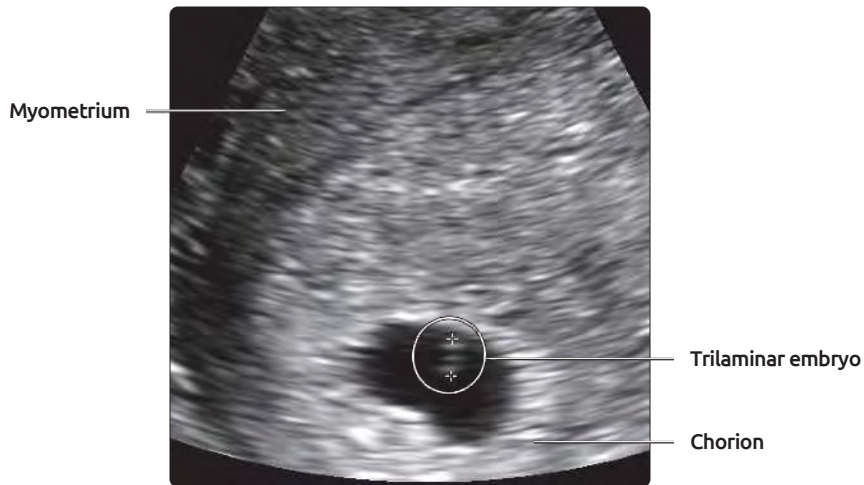
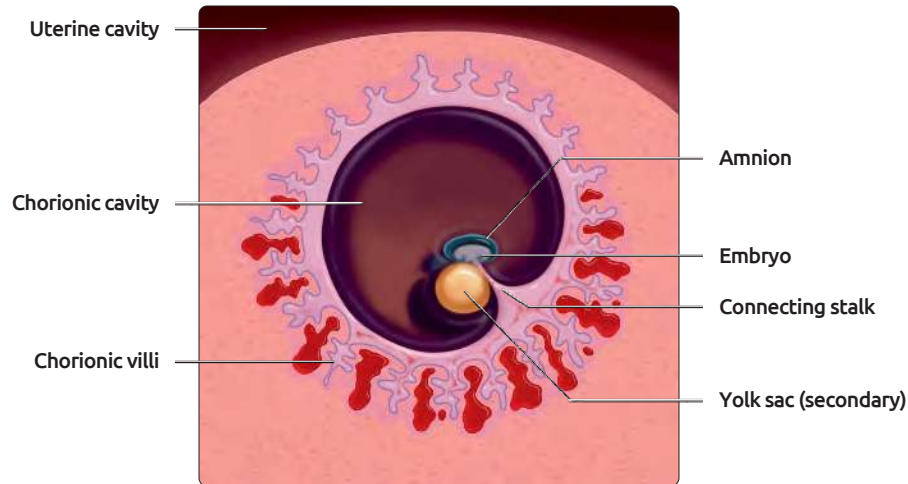
(Top) The graphic illustrates the earliest sonographic manifestation of the embryological development illustrated previously. The gestational sac has burrowed into the decidualized endometrium, creating an asymmetrically placed echogenic ring with a lucent center. This was initially described as the intradecidual sac sign (IDSS). It is not always visible in early pregnancy and it is subject to considerable interobserver variability. **(Middle)** The intradecidual gestational sac is an echogenic ring eccentric to the line created by apposition of the endometrial surfaces. Currently, recommended terms for such an observation are intrauterine sac-like structure or probable intrauterine pregnancy. **(Bottom)** This is an example of the IDSS. In this example, bleeding has resulted in accumulation of blood in the endometrial cavity. Again, note the eccentric location of the 4-mm diameter sac. In the lower image, a tiny circular structure within the gestational sac is likely the primary yolk sac, which can be seen with high-resolution modern transducers.

DOUBLE DECIDUAL SAC SIGN



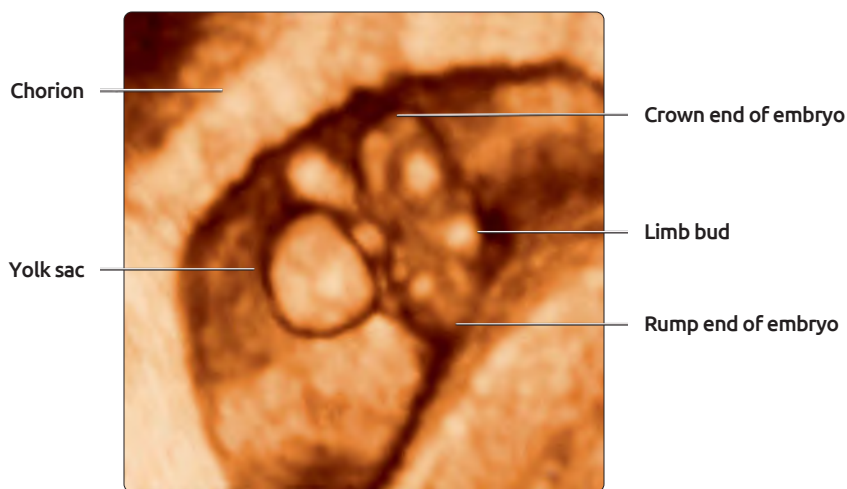
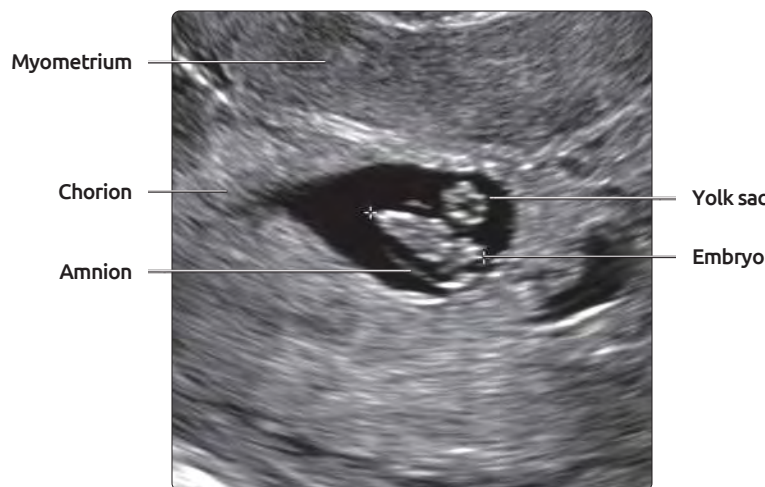
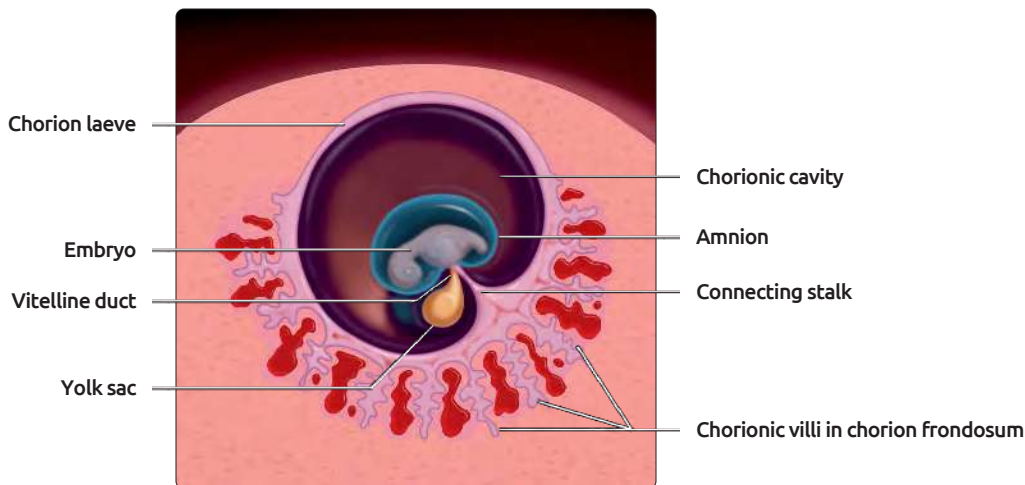
(Top) This graphic illustrates the double decidual sac sign (DDSS). This is seen when the enlarging gestational sac protrudes from the site of implantation and starts to expand into the uterine cavity, exerting mass effect on the opposite uterine wall. The decidua covering the expanding sac is decidua capsularis; that which is being pushed ahead of the expanding sac is the decidua parietalis. The decidua basalis is where the sac is adherent to the uterine wall and marks the site where the placenta will develop. Internal structures may be seen on transvaginal scans. **(Middle)** The decidual layers are easily seen on this transvaginal scan. The concentric rings created by the decidua capsularis and parietalis create the DDSS. This finding is characterized as a probable intrauterine pregnancy. **(Bottom)** In this example, the embryo and yolk sac are visible in addition to the DDSS; this indicates a definite intrauterine pregnancy. It would also be a pregnancy of uncertain viability if there was no cardiac activity in an embryo < 7 mm in length.

EMBRYONIC DEVELOPMENT: 6 WEEKS



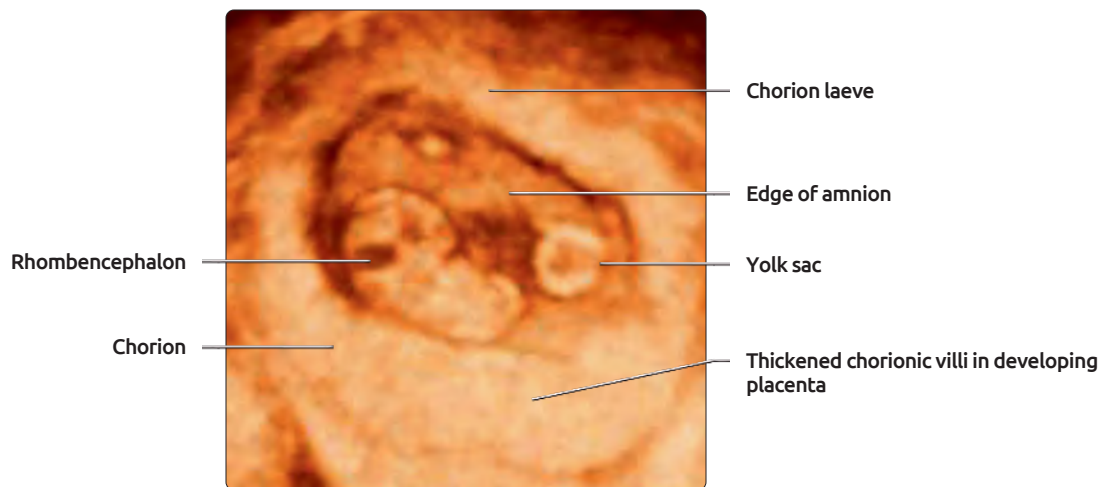
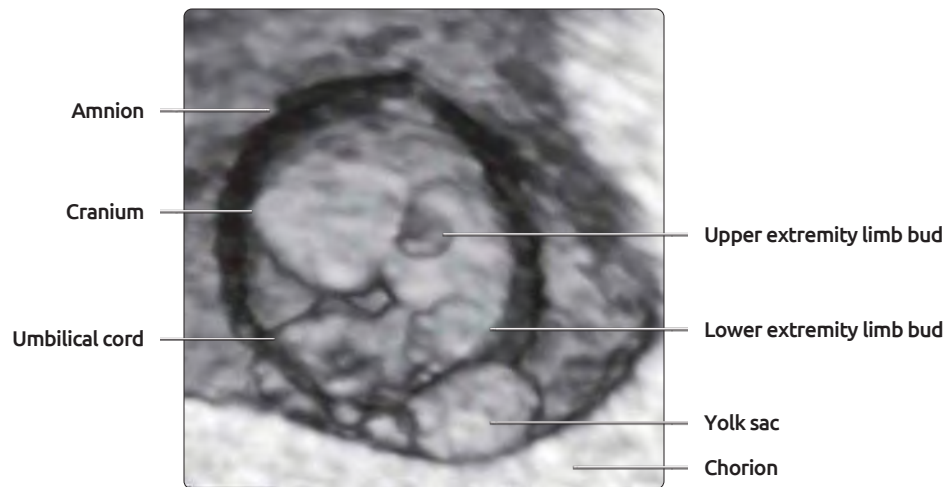
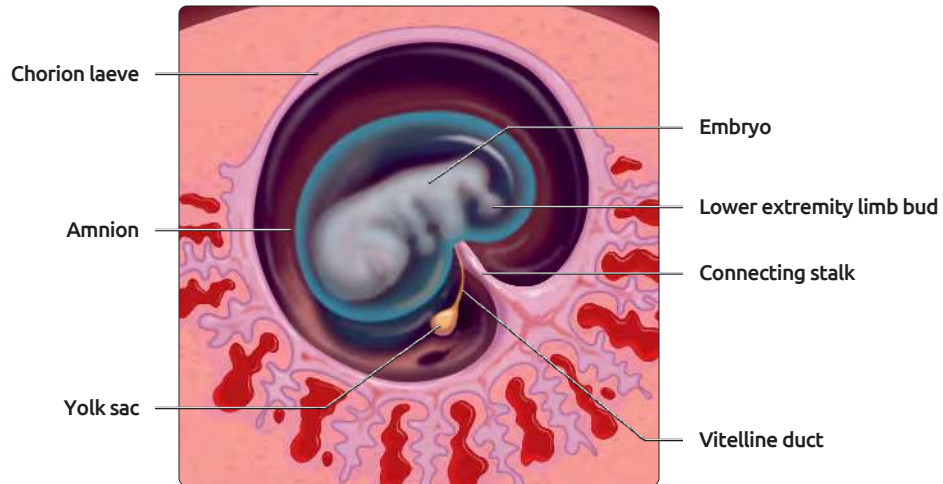
(Top) The graphic illustrates normal early development. The embryo is intimately associated with the yolk sac such that the amnion and yolk sac appear as a double bleb with the embryo sandwiched between them. The embryo is within the amniotic sac; both the embryo and yolk sac are inside the chorionic sac. **(Middle)** Vaginal ultrasound at 5 weeks, 5 days from last menstrual period shows a 2-mm embryo. There are 3 linear echoes, which resemble an Oreo cookie. The process of gastrulation results in cellular movement with creation of the 3 primary germ layers; the endoderm, the mesoderm, and the ectoderm. Despite the tiny size of this embryo, cardiac activity was visible in real time. **(Bottom)** Vaginal ultrasound shows the embryo immediately adjacent to the yolk sac. The amnion is not yet visible. At this gestational age, the abdominal wall is still open, and the midgut is in continuity with the yolk sac. After the abdominal wall closes, the "discarded" yolk sac is compressed between the expanding amnion and the chorion.

EMBRYONIC DEVELOPMENT: 7-8 WEEKS



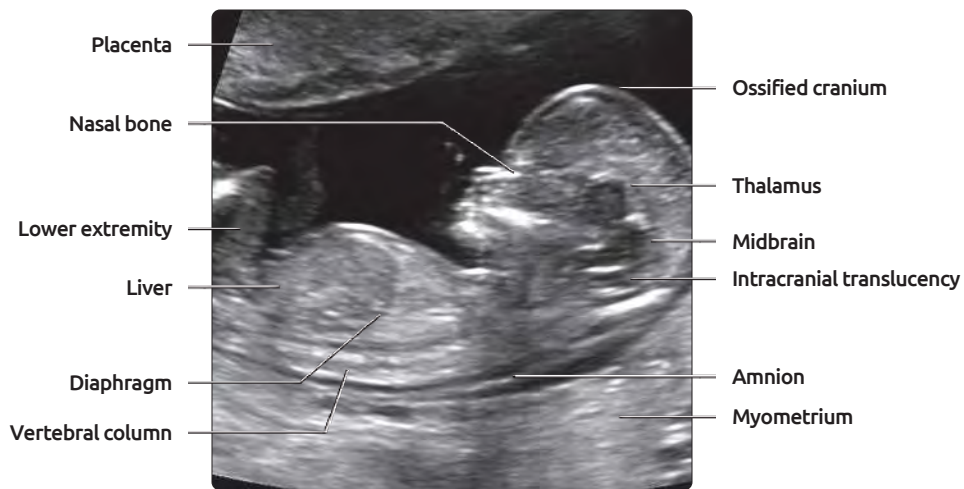
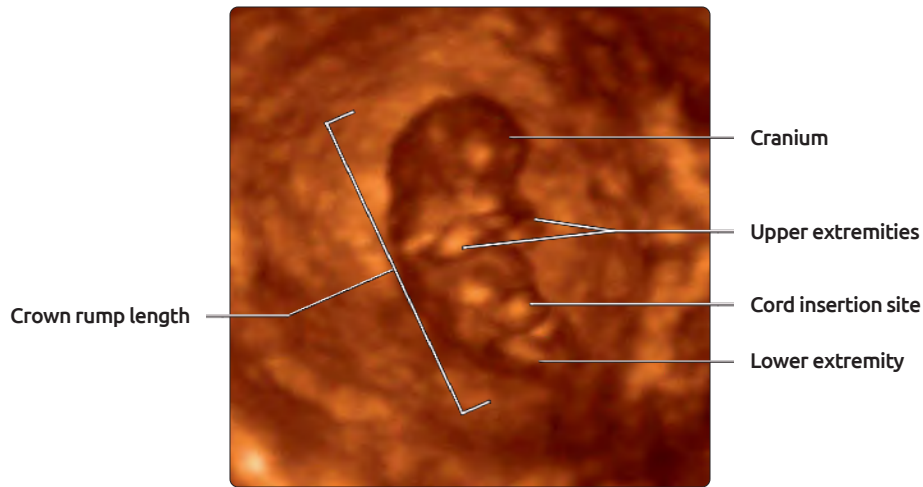
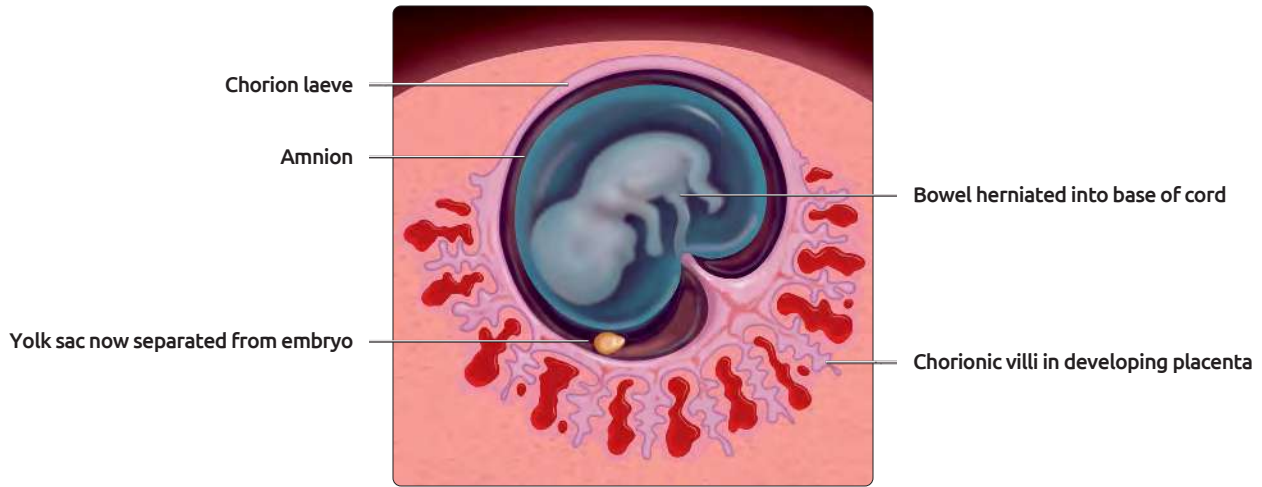
(Top) Curvature and folding of the embryo result in closure of the abdominal wall and pinching off of the yolk sac. The elongated neck forms the vitelline duct. Eventually the yolk sac separates from the embryo, dropping into the chorionic cavity. At the same time, it becomes clear which end of the embryo is which, and limb buds start to form. The chorion adjacent to the uterine cavity is now completely smooth. Chorionic villi in the developing placenta become more complex in structure. **(Middle)** Vaginal ultrasound at 7 weeks, 4 days from LMP shows the yolk sac is separate from the embryo. It lies outside the amnion, which is now expanded enough to be just visible as it surrounds the embryo. Remember that the yolk sac will always be outside the amnion; the embryo lies inside the amniotic sac. **(Bottom)** 3D surface-rendered ultrasound shows the yolk sac separate from the embryo, which now has an elongated configuration with defined cranial or crown and pelvic or rump ends. The crown rump length is measured to confirm menstrual dating.

EMBRYONIC DEVELOPMENT: 8-9 WEEKS



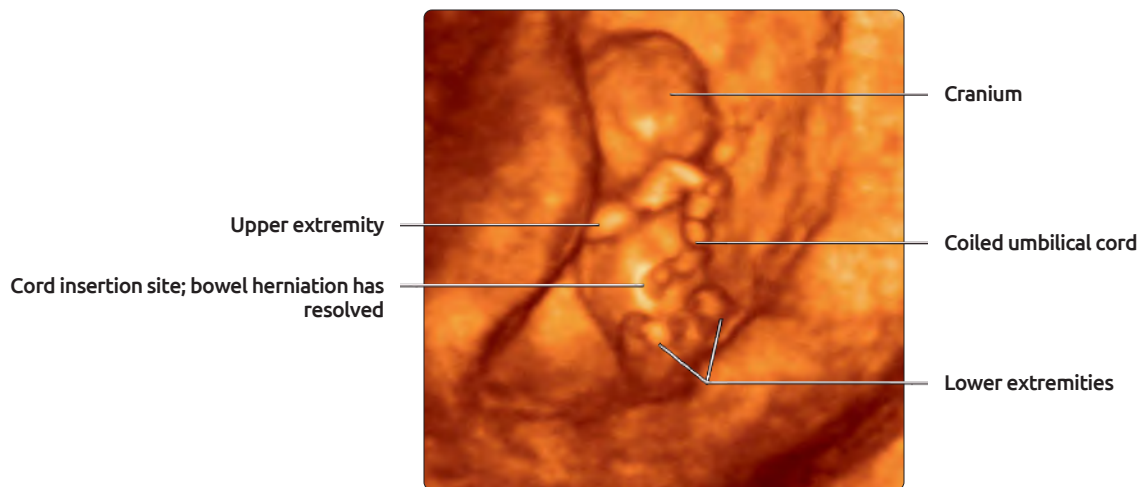
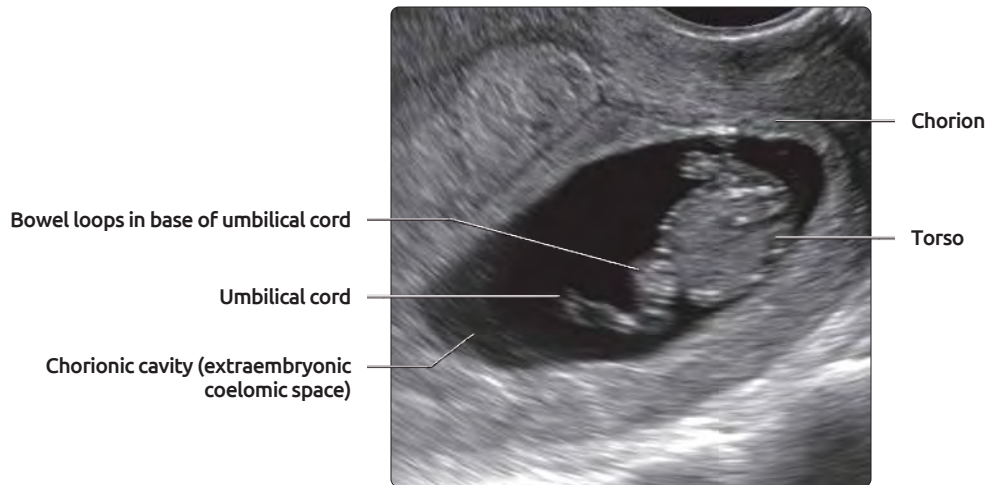
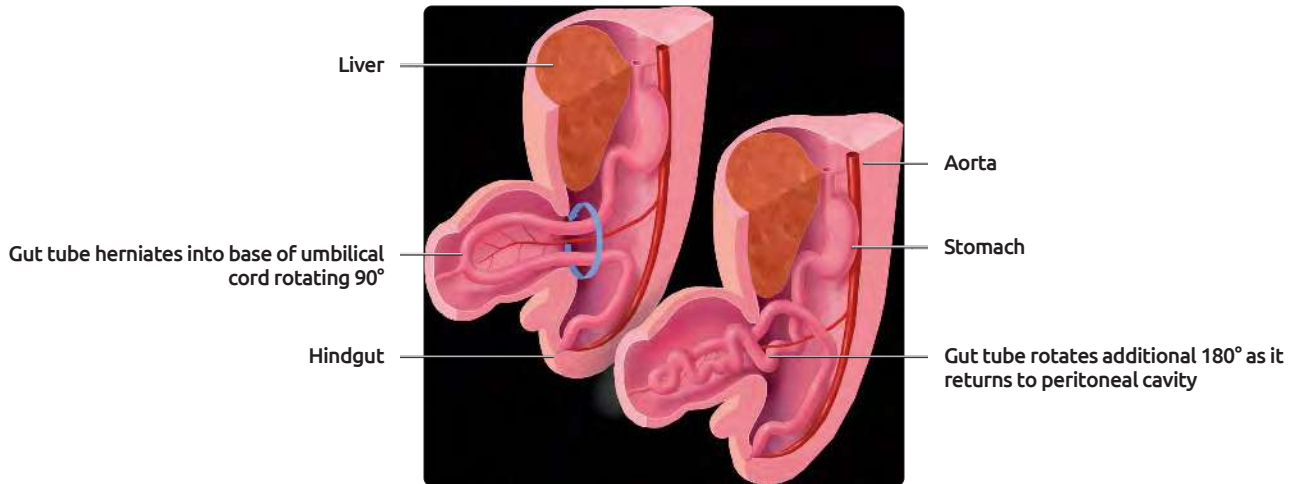
(Top) The graphic illustrates continued embryonic development; the limb buds are evident, the head has grown dramatically, and the embryo is assuming a recognizable human form. The umbilical cord forms as a result of fusion of the vitelline duct, allantois, and connecting stalk. Once formed, it elongates rapidly until the embryo is suspended within the enlarging amniotic sac. Cord elongation allows for free mobility of the developing fetus. **(Middle)** 3D surface-rendered ultrasound of an 8-week embryo show the short limb buds and the relatively thick umbilical cord. The crown end is assuming a more recognizable head shape and the embryo is curling into the typical fetal position. **(Bottom)** Another 3D ultrasound in the sagittal plane shows the rhombencephalic vesicle in the cranial part of the embryo. This fluid-filled space is a precursor of the 4th ventricle and should not be confused with a pathological intracranial cyst.

EMBRYONIC DEVELOPMENT: 10-13 WEEKS



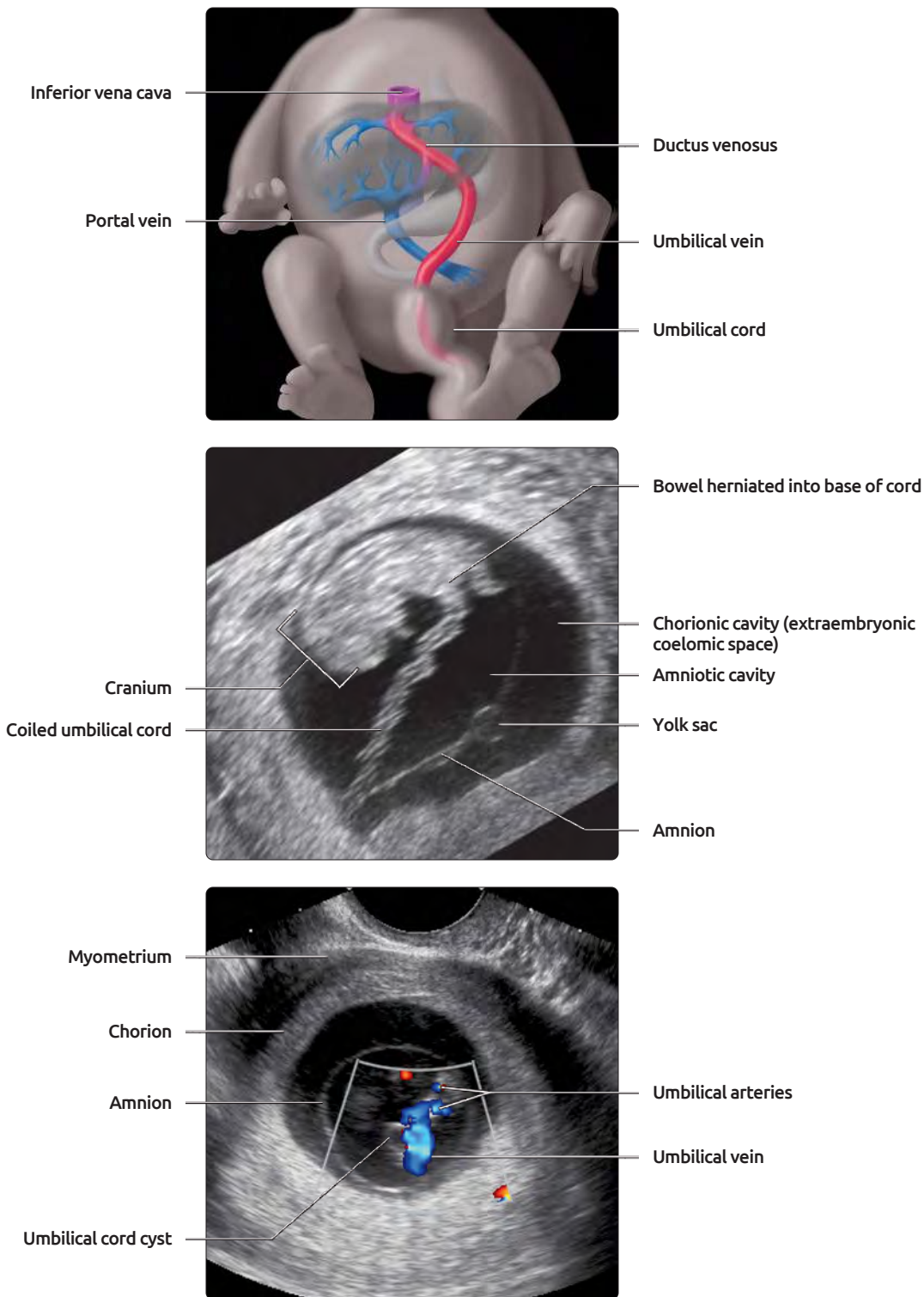
(Top) Toward the end of the 1st trimester, the amnion fills the chorionic cavity. The membranes do not "fuse" until 14-16 weeks. The placenta continues to grow, and the chorionic villi develop an increasingly complex branching pattern. **(Middle)** 3D surface-rendered ultrasound at 10 weeks shows increasingly recognizable fetal anatomy with a well-developed cranium and extremities. The abdominal wall cord insertion site is quite broad due to the physiologic herniation of bowel into its base. This occurs as the peritoneal cavity is too small to accommodate the rapidly growing bowel at this gestational age. **(Bottom)** Sagittal transabdominal ultrasound at 12 weeks, 6 days from LMP shows recognizable anatomic features. Organogenesis is completed by the end of the 13th week. Growth and maturation of the various organ systems occurs during the remainder of gestation.

ABDOMINAL WALL AND GI TRACT



(Top) The graphic illustrates herniation of bowel into the base of the cord in the 1st trimester. This happens as the gut tube elongates before there is adequate room to accommodate it in the peritoneal cavity. The gut undergoes a 90° counterclockwise rotation as it herniates and an additional 180° rotation as it is retracted into the peritoneal cavity. Only the gut herniates; liver is never normally seen at the base of the cord. **(Middle)** Vaginal ultrasound at 10 weeks, 3 days shows echogenic bowel at the base of the umbilical cord. This is normal at this gestational age and should not be misinterpreted as a bowel-containing omphalocele. **(Bottom)** 3D surface-rendered ultrasound of a 12-week fetus shows a normal abdominal wall contour. The cord insertion is normal, and there is no residual bowel herniation. Three of the extremities are seen, the cranial contour is normal, and the cord is already coiled.

UMBILICAL CORD DEVELOPMENT



(Top) The graphic illustrates fetal circulation in which oxygenated blood from the placenta returns to the fetus via the umbilical vein. The umbilical vein courses through the left lobe of the liver to the left portal vein, across the ductus venosus into the inferior vena cava. The umbilical cord also contains 2 arteries, which arise from the internal iliac arteries. **(Middle)** At 10 weeks, there is some residual herniation of bowel into the base of the cord. The embryo is freely suspended within the amniotic sac by the cord, which already shows evidence of coiling. The yolk sac will be obliterated as the amnion apposes to the chorion. **(Bottom)** Color Doppler ultrasound shows a small umbilical cord cyst as an avascular area adjacent to the cord vessels. As a 1st-trimester finding this is usually of no significance; the cysts form at 8-9 weeks and usually resolve by ~ 12 weeks.

Imaging Techniques and Normal Anatomy

Transvaginal ultrasound (TVUS) is the imaging modality of choice in the evaluation of the first-trimester pregnancy. In rare instances, a transabdominal ultrasound (TAUS) may be sufficient. For example, in cases where there is a known intrauterine pregnancy (IUP), but fetal cardiac activity is not heard, TAUS may be used to verify that the embryo is still alive.

The sonologist performing the examination must be familiar with the appearance of a normal early pregnancy, ectopic gestation, and failed pregnancy. Misunderstanding of normal anatomy and developmental milestones may lead to an incorrect diagnosis and incorrect treatment. Administration of methotrexate to a patient with an IUP must be avoided.

In 2013, the Consensus Panel on Diagnostic Criteria for Nonviable Pregnancy Early in the First Trimester published guidelines for determination of pregnancy failure and established definitions for terms that, though commonly used, were often misunderstood. As defined by the Consensus Panel, a viable pregnancy is one that can potentially result in a liveborn baby.

Additionally, new descriptive terms have been suggested for use in early pregnancy. The term probable IUP is defined as an intrauterine echogenic sac-like structure without a yolk sac or embryo. The term definite IUP is defined as an intrauterine sac-like structure with a yolk sac or embryo, whether or not there is cardiac activity.

The consensus panel discouraged the use of the terms intradecidual sac sign (IDSS) and double decidual sac sign (DDSS), as they are not present in all early pregnancies and are subject to interobserver error. Nonetheless, they are described below, and both fit under the umbrella term probable IUP.

The IDSS manifests as a spherical, cystic structure eccentric to the central echo of the uterine cavity. Embryologically, it corresponds to the time of implantation when the early embryo burrows into the decidualized endometrium.

The expanding gestational sac creates two echogenic rings or the DDSS. The decidual capsularis is the outward expansion of the trophoblastic tissue; it creates the inner ring, whereas the decidual parietalis of the surrounding uterine cavity creates the second peripheral, outer ring. The focal thickened decidua at the site of implantation is referred to as the decidua basalis.

When a gestational sac without a yolk sac is seen in the uterus, the lack of a live embryo 14 days later is diagnostic of pregnancy failure.

Following visualization of the DDSS, the next visible sonographic milestone is the yolk sac. The amnion forms embryologically before the yolk sac, but it is such a thin, delicate membrane that it is resolved later, even with TVUS. The yolk sac has a distinct wall, smooth outline, and spherical shape with a maximum diameter of 6 mm. An intrauterine sac with a yolk sac is considered a definite IUP. When a yolk sac is seen, the lack of a live embryo 11 days later is diagnostic of pregnancy failure.

The embryo is first resolved as a focal thickening at the circumference of the yolk sac. Cardiac activity may be seen as a flickering in this area before the embryo is sufficiently large enough to allow accurate measurement. Once the embryo is discretely resolved, the longest axis is measured and referred to as the crown rump length.

When the abdominal wall closes during the process of gastrulation, the yolk sac is pinched off the embryo and will eventually be compressed between the amnion and chorion at the time of membrane fusion. Thus, if the yolk sac is seen separate from the embryo, that embryo has undergone the process of gastrulation and should have a visible heart beat. Lack of cardiac activity in this setting is called the yolk stalk sign.

Initially, the embryo fills the amnion. As the pregnancy progresses, the embryo becomes suspended from the umbilical cord within the enlarging amniotic sac. This is a very important observation; the embryo is always inside the amnion, and the yolk sac is always outside the amnion. If the amnion is visible, the embryo should also be visible. If not, this is the empty amnion sign. If an embryo is present within a visibly expanded amniotic cavity, it should manifest cardiac activity. If absent, this is the expanded amnion sign. Although not included in the consensus guidelines, the empty amnion, expanded amnion, and yolk stalk signs of failed pregnancy are described in peer-reviewed articles.

The embryo visibly changes shape from a dot to a grain of rice to a more kidney bean-shaped structure. Then, limb buds develop, and the head, torso, and extremities can be resolved. At 10 weeks post last menstrual period (LMP), the embryo officially becomes a fetus. By 13 weeks post LMP, organogenesis is complete.

Approach to the First Trimester

Where is the pregnancy?

Many patients present to the sonologist with a history of a positive pregnancy test and vaginal bleeding. In this situation, the differential diagnosis includes a normal IUP vs. abnormal pregnancy vs. complete abortion vs. ectopic pregnancy.

The term pregnancy of unknown location (PUL) has been coined to describe the situation in which there is a chemical pregnancy with no evidence of either an IUP or an ectopic by TVUS. Thus, it is vital that the sonologist knows the signs of IUP as well as those of ectopic pregnancy. In particular, it is important to evaluate the adnexa carefully for mass, tubal ring, and echogenic free fluid. The normal corpus luteum should not be mistaken for an ectopic pregnancy. Prominent flow around the corpus luteum is a normal observation and should not be confused with the ring of fire sign of trophoblastic flow around an ectopic gestation. Blood products may appear as an oval or flattened fluid collection placed centrally in the uterine cavity in association with an ectopic pregnancy. The term pseudosac of ectopic pregnancy is discouraged as it is imprecise and can be misleading. The shape of the fluid collection should be characterized as round/oval or pointy edged with the former much more likely to represent an IUP than the latter.

If the patient is stable, it is always wise to be conservative. Normal early pregnancies develop in a standard manner with rapid changes in a short time frame. In the case of PUL, either an IUP or an ectopic gestation should become visible within days.

In heterotopic pregnancy, an IUP coexists with an ectopic gestation. This is rare in the normal population but is not uncommon in patients with risk factors, such as tubal scarring or a history of assisted reproduction. Medical management is contraindicated in heterotopic pregnancy as systemic methotrexate administration would be harmful to the IUP.

Nomenclature in First Trimester

Recommended Terminology	Definition
Viable pregnancy	One that may potentially result in liveborn baby
Nonviable pregnancy	One that cannot possibly result in liveborn baby; examples include ectopic and failed intrauterine pregnancies (IUPs)
Pregnancy of unknown location	Positive pregnancy test (urine or serum) with no signs of intrauterine or extrauterine gestation on transvaginal ultrasound
IUP of uncertain viability	IUP with embryo < 7 mm without cardiac activity or mean sac diameter < 25 mm without embryo
Definite IUP	Intrauterine gestational sac with yolk sac ± embryo ± cardiac activity
Probable IUP	Intrauterine echogenic sac-like structure without yolk sac or embryo
Definite ectopic	Extrauterine gestational sac with yolk sac ± embryo ± cardiac activity
Probable ectopic	Inhomogeneous adnexal mass or extrauterine sac-like structure

Use of consistent terminology is important to avoid confusion and to collect accurate information for outcome studies.

Terminology reproduced from Doubilet PM et al: Diagnostic criteria for nonviable pregnancy early in the first trimester. N Engl J Med. 369(15):1443-51, 2013 and from Barnhart K et al: Pregnancy of unknown location: a consensus statement of nomenclature, definitions, and outcome. Fertil Steril. 95(3):857-66, 2011.

First-Trimester Milestones

Embryo Should Be Visible	
	When mean sac diameter is ≥ 25 mm by transvaginal ultrasound (TVUS)
Cardiac Activity Should Be Present	
	If embryo is ≥ 15 mm in length by transabdominal ultrasound
	If embryo is ≥ 7 mm in length by TVUS
	≥ 14 days from visualization of a gestational sac without yolk sac
	≥ 11 days from visualization of a gestational sac with yolk sac

Reproduced from Doubilet PM et al: Diagnostic criteria for nonviable pregnancy early in the first trimester. N Engl J Med. 369(15):1443-51, 2013.

Criteria to Change Menstrual Dating

Gestational Age by Last Menstrual Period	Use Sonographic Dates if Difference Is
≤ 8 6/7 weeks	> 5 days
9 0/7 weeks to 15 6/7 weeks	> 7 days
16 0/7 weeks to 21 6/7 weeks	> 10 days
22 0/7 weeks to 27 6/7 weeks	> 14 days
28 0/7 weeks onward	> 21 days

Sonographic gestational age is assessed by crown rump length to 13 6/7 weeks. Thereafter, use head circumference, biparietal diameter, femur length, and abdominal circumference.

Committee opinion no. 611: method for estimating due date. Obstet Gynecol. 124(4):863-6, 2014.

How Many Embryos Are There?

Once the diagnosis of IUP is established, it is essential to scan the entire pelvis to document the number of embryos. Müllerian duct anomalies are a possible pitfall; if an incomplete scan is performed, a bicornuate or septate uterus may not be appreciated. Multiple pregnancies may occur with implantation in one or both horns.

Perigestational hemorrhage (PGH) should not be confused with an IUP. A PGH is usually crescentic in shape and located deep to the echogenic ring of chorionic tissue; there will be neither an embryo nor a yolk sac.

Determination of chorionicity is crucial in all multiple gestations. The chorion forms a thick echogenic ring that

completely encompasses the embryo. If more than one embryo is seen within a single chorionic ring, the pregnancy is monochorionic. The next step is to determine amnionicity. As mentioned, the amnion is a very delicate membrane that may not be seen in early gestation. However, the number of yolk sacs often parallel the number of amnions; therefore, if there are two embryos and two yolk sacs, it is likely that the pregnancy is a monochorionic diamniotic twin gestation. If only one yolk sac is seen after a complete sweep through the gestational sac in longitudinal and transverse planes, the pregnancy may be monoamniotic or the embryos may be conjoined. Conjoined twins maintain a fixed relationship to each other and have an area of contiguous skin covering differentiating them from monoamniotic twins that move

independently of each other and are completely separate, even if mobility is limited by cord entanglement.

What Is the Gestational Age?

The normal menstrual cycle is 28 days, and the assumption is made that conception occurs on day 14 of the cycle. In the absence of a menstrual history, a first-trimester ultrasound is the most accurate way to determine gestational age as there is little biological variation in the first trimester. Correct gestational age is essential for assessment of growth in the second and third trimesters.

Is the Pregnancy Normal?

Modern equipment provides exquisite resolution and allows for a quite detailed anatomic assessment by the end of the first trimester. Between 11 and 13 weeks, nuchal translucency, facial angle, tricuspid regurgitation, ductus venosus flow, and nasal bone assessment can be used to select a group of fetuses at higher risk for aneuploidy. The availability of cell-free fetal DNA testing has changed prenatal screening for aneuploidy; however, early anatomy scans have the additional benefit of allowing detection of structural abnormalities, such as abdominal wall defects, limb reduction abnormalities, and central nervous system malformations, including neural tube defects and alobar holoprosencephaly. None of these major birth defects can be detected by cell-free fetal DNA testing.

In multiple gestations, evaluation of nuchal translucency and ductus venosus flow can be used to detect monochorionic pairs at increased risk for complications, such as twin-twin transfusion syndrome as well as for aneuploidy screening.

Assessment of uterine artery Doppler waveforms may be helpful to select patients at increased risk for preeclamptic toxemia, thus allowing more intensive surveillance.

What About the Uterus and Adnexa?

The first-trimester scan is not restricted to evaluation of the embryo/fetus. It is important to look at the uterine contour, document fibroid size and location, assess for possible müllerian duct anomalies, and note the presence of nabothian cysts or Gartner duct cysts that might cause a confusing appearance on a TAUS evaluation of the cervix later in gestation.

The majority of adnexal masses seen in pregnancy are benign. However, particularly with advancing maternal age, ovarian neoplasms may be detected. Even a benign neoplasm, such as teratoma, may undergo torsion. If the presence of an adnexal mass is known, the evaluation of a patient with acute onset of abdominal or pelvic pain in pregnancy is much simplified.




The appearance of the corpus luteum is highly variable from a small, crenulated, involuting, thick-walled cyst to the complex appearance seen with hemorrhage. Corpus luteal cysts may reach several centimeters in diameter; they should resolve by 16 weeks post LMP.

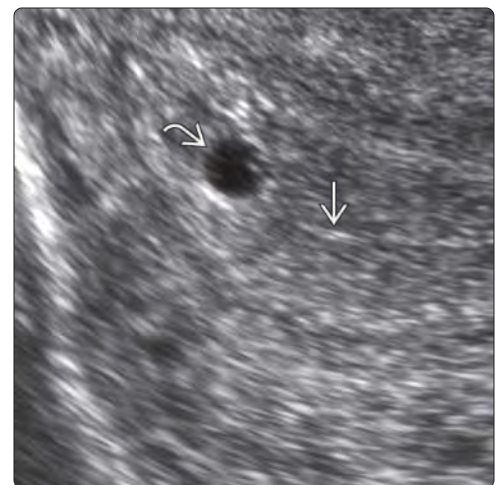
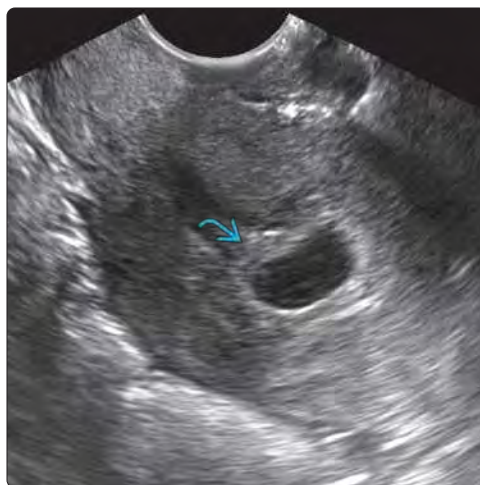
Clinical Implications

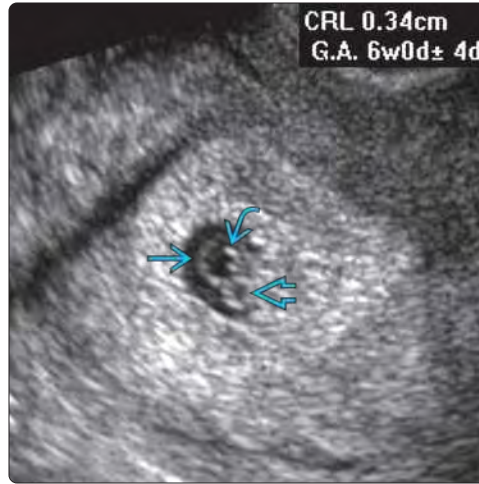
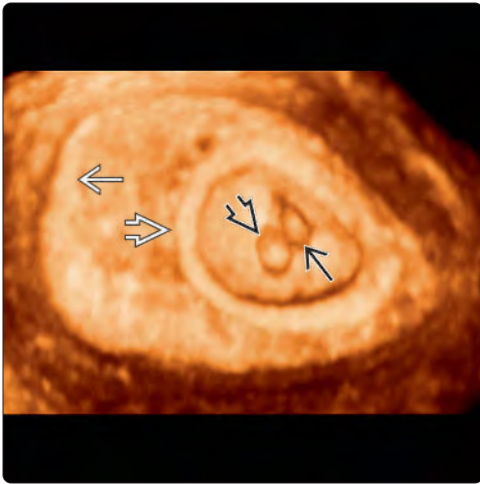
First-trimester scans provide accurate information on gestational age, assist in screening for aneuploidy, exclude several major malformations, and are vital in determination of chorionicity in multiple pregnancies. It behooves all US practitioners to use stringent standards in the determination of embryonic demise or early pregnancy failure. "First do no harm...to early pregnancies" is a good rule of thumb to practice.

Selected References

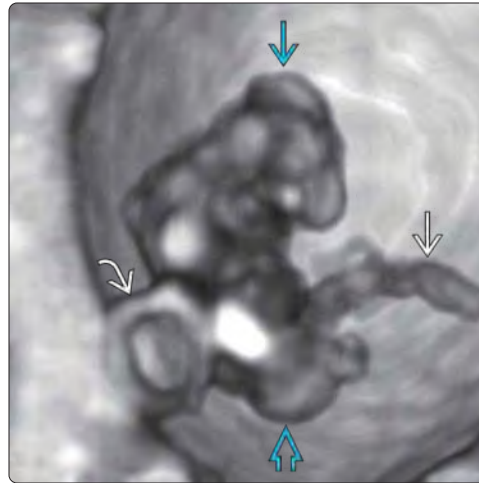
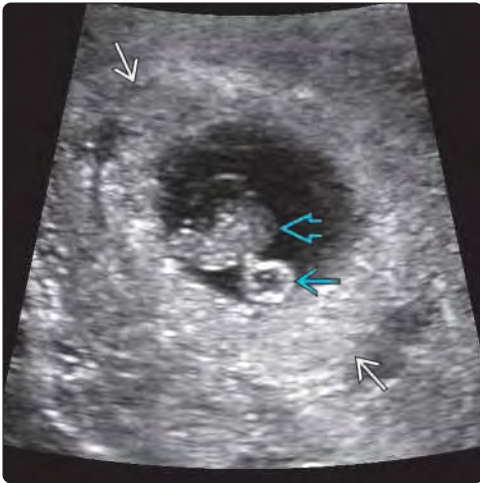
1. Mazzariol FS et al: Pearls and pitfalls in first-trimester obstetric sonography. *Clin Imaging.* 39(2):176-185, 2015
2. Committee opinion no 611: method for estimating due date. *Obstet Gynecol.* 124(4):863-6, 2014
3. Papageorgiou AT et al: International standards for early fetal size and pregnancy dating based on ultrasound measurement of crown-rump length in the first trimester of pregnancy. *Ultrasound Obstet Gynecol.* 44(6):641-8, 2014
4. Doubilet PM et al: Diagnostic criteria for nonviable pregnancy early in the first trimester. *N Engl J Med.* 369(15):1443-51, 2013
5. Barnhart K et al: Pregnancy of unknown location: a consensus statement of nomenclature, definitions, and outcome. *Fertil Steril.* 95(3):857-66, 2011
6. Doubilet PM et al: First, do no harm... To early pregnancies. *J Ultrasound Med.* 29(5):685-9, 2010

(Left) TVUS shows an intrauterine sac-like structure . In the setting of a positive pregnancy test, this finding is statistically most likely to represent an intrauterine pregnancy (IUP). This example is of a normal pregnancy in which the DDSS is not appreciated. Recommended description for this sort of finding is probable IUP. **(Right)** TVUS shows the IDSS  with a small, round fluid collection eccentric to midline uterine cavity echo . The more generic term, intrauterine sac-like structure, is now preferred to describe this observation.

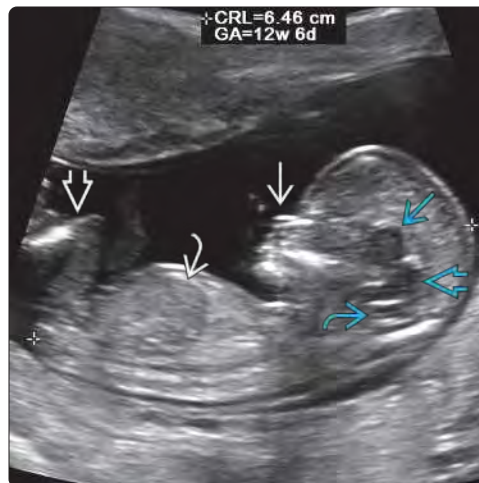
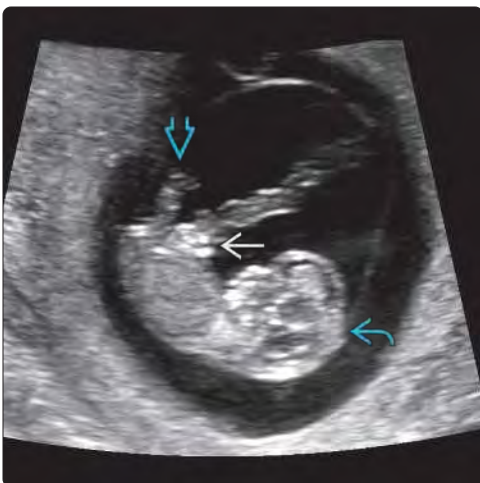




(Left) 3D US shows the layers of the DDSS sign. The inner decidua capsularis is surrounded by the outer decidua parietalis. The amnion and yolk sac are inside the gestational sac. The generic term, intrauterine sac-like structure, is now recommended rather than DDSS. (Right) TVUS shows a more advanced definite IUP in which the yolk sac is adjacent to the amnion, which surrounds the more elongated embryo. The embryonic shape is now closer to a grain of rice than a dot.



(Left) TVUS shows a definite IUP: An intrauterine gestational sac with a yolk sac and an embryo. Note that neither an embryo nor cardiac activity is a prerequisite for use of this descriptor. (Right) 3D US shows the more kidney bean-shaped embryo with a defined crown or head end and a smaller tail or rump end. Note the separated yolk sac and elongated umbilical cord.



(Left) TVUS shows bowel herniation into the base of the umbilical cord. This is a normal embryological event. Note how clearly the cranial structures and facial profile are seen, whereas the rump end of the embryo looks smaller, and the lower extremities are still quite short. (Right) At 13 weeks, organogenesis is complete. In this fetus, the nose, diaphragm, and a lower extremity are clearly visible, as are the thalamus, midbrain, and the early 4th ventricle a.k.a. intracranial translucency.

KEY FACTS

TERMINOLOGY

- Pregnancy is considered viable if it can potentially result in live birth
- Nonviable pregnancy is one that will not result in live birth

IMAGING





- Criteria for nonviable pregnancy on transvaginal sonography
 - Mean sac diameter > 25 mm without embryo
 - Crown rump length \geq 7 mm without cardiac activity
 - Cessation of previously documented cardiac activity regardless of crown rump length
- Time follow-up intervals for definitive diagnosis of failure
 - Lack of live embryo 11 days after demonstration of gestational sac **with** yolk sac (YS)
 - Lack of live embryo 14 days after demonstration of gestational sac **without** YS
- Other published signs of failed pregnancy
 - Empty amnion sign
 - Expanded amnion sign
 - Yolk stalk sign

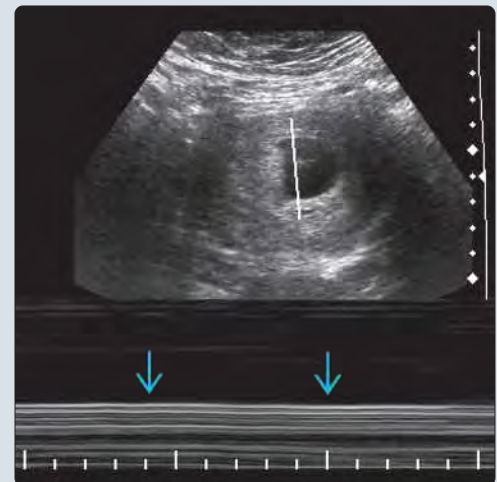
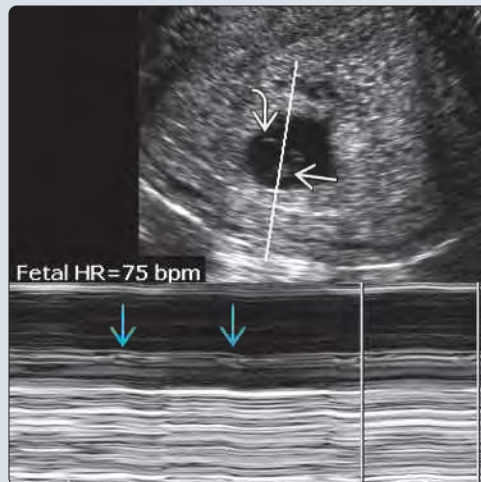
TOP DIFFERENTIAL DIAGNOSES




- Probable intrauterine pregnancy (IUP)
 - Intrauterine sac-like structure without yolk sac or embryo
- Intrauterine pregnancy of uncertain viability
- Retained products of conception
- Gestational trophoblastic disease

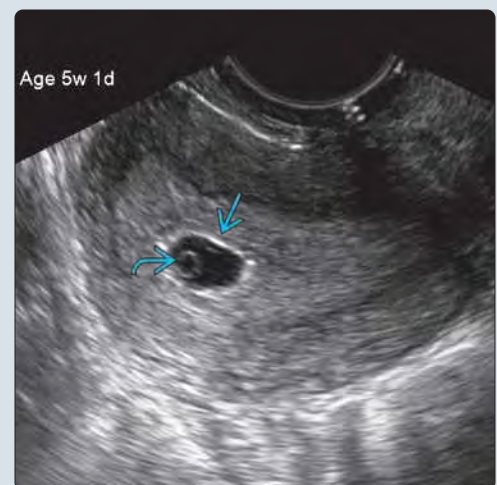
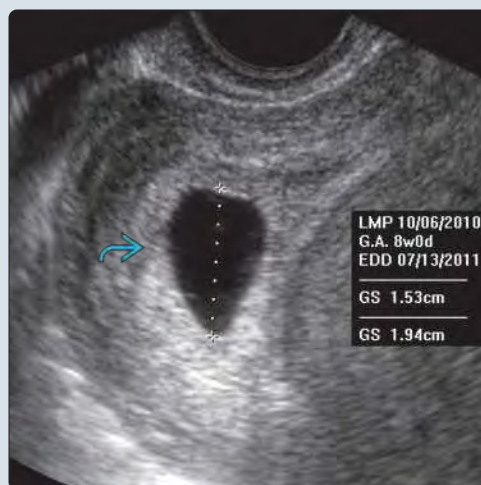
DIAGNOSTIC CHECKLIST

- Failed 1st-trimester pregnancy simplifies terminology
- Positive pregnancy test with intrauterine fluid collection with rounded edges is statistically most likely to be IUP
 - Probable IUP if no YS or embryo
 - Definite IUP if YS or embryo visible
- If in doubt, wait and see

(Left) M-mode ultrasound shows embryonic bradycardia with heart rate of 75 beats per minute  in this tiny embryo  seen immediately adjacent to the yolk sac . Cardiac activity is often visible before the crown rump length (CRL) can be measured accurately. Embryonic bradycardia is associated with poor outcome. **(Right)** Follow-up 1 week later in the same patient shows cessation of cardiac activity . This is diagnostic of embryonic demise regardless of the CRL.



(Left) TVUS shows an oval gestational sac  smaller than expected for menstrual dates with mean sac diameter 17.2 mm. This is not indicative of pregnancy failure. Lack of a live embryo 14 days after demonstration of a sac without a yolk sac indicates a nonviable pregnancy. **(Right)** TVUS shows a gestational sac  with a yolk sac  in a patient with pain and bleeding. This is not indicative of pregnancy failure. Lack of a live embryo 11 days after demonstration of a sac with a yolk sac indicates a nonviable pregnancy.



TERMINOLOGY

Definitions

- Pregnancy is considered viable if it can **potentially** result in live birth
- Nonviable pregnancy is one that will not result in live birth
- Intrauterine pregnancy (IUP) of uncertain viability
 - Intrauterine gestational sac, no embryonic heartbeat but no definite signs of pregnancy failure on transvaginal ultrasound (TVUS)

IMAGING

General Features

- Criteria for definite diagnosis of nonviable pregnancy are now based on TVUS

Ultrasonographic Findings

- Grayscale ultrasound
 - **Nonviable pregnancy**
 - Mean sac diameter (MSD) ≥ 25 mm without embryo
 - Embryo with crown rump length (CRL) ≥ 7 mm without cardiac activity on TVUS
 - ◻ Although new criteria are on TVUS, CRL ≥ 15 mm without cardiac activity on TAUS can be used to call demise
 - Lack of live embryo 11 days after demonstration of gestational sac **with** yolk sac (YS)
 - Lack of live embryo 14 days after demonstration of gestational sac **without** YS
 - Cessation of cardiac activity in embryo of any size
 - **Expanded amnion sign**
 - Amnion visible surrounding embryo without cardiac activity implies embryonic demise regardless of CRL
 - **Empty amnion sign**
 - Gestational sac with visible amnion, without visible embryo
 - **Yolk stalk sign**
 - Embryo without cardiac activity with visible YS separate from embryo
 - Other findings of concern for abnormal gestation
 - Abnormal sac contour (e.g., pointed edges)
 - Poor decidual reaction
 - Sac positioned low in uterus
 - ◻ Beware scar implantation if prior cesarean section
- Color Doppler
 - Poor color Doppler signal around sac
 - Use Doppler to support abnormal diagnosis

Imaging Recommendations

- Be sure to scan through entire uterus in longitudinal and transverse planes
- Measure MSD by averaging 3 planes; do not include chorion
- Verify date of last menstrual period/cycle length/regularity
 - When was 1st positive pregnancy test
- If possible normal early pregnancy, follow-up at intervals timed to normal milestones
- Know anatomy and developmental stages
 - Intrauterine sac-like structure = **probable IUP**
 - Round or oval shape more likely normal early IUP

- Fluid collection with "pointed" edges less likely to be IUP
 - ◻ More likely blood or decidual cast in association with ectopic
- Gestational sac with YS = **definite IUP**
- Double bleb: Embryonic disc between amnion and YS
 - As pregnancy progresses embryo and amnion enlarge
 - ◻ Embryo initially fills amniotic cavity
 - ◻ As umbilical cord forms embryo "suspended" by cord within expanded amniotic sac
 - ◻ YS lies outside amniotic cavity
 - ◻ YS eventually compressed between amnion and chorion as membranes "fuse"
- Normal YS round in shape, ≤ 6 mm diameter

DIFFERENTIAL DIAGNOSIS

Probable Intrauterine Pregnancy (Intrauterine Sac-Like Structure)

- Intradecidual sac sign (IDSS) and double decidual sac sign (DDSS) are classic descriptors for developing sac
 - IDSS
 - Spherical, echogenic ring "burrowed" into decidualized endometrium
 - DDSS
 - 2 thick echogenic rings (decidual capsularis, parietalis) project into uterine cavity
- Not all normally developing sacs show IDSS or DDSS
 - **Intrauterine sac-like structure** now preferred generic descriptor for rounded fluid collection in endometrial cavity
 - No yolk sac or embryo
- Term pseudosac of ectopic pregnancy no longer recommended
 - Was used to describe central fluid collection in uterus without features of IDSS or DDSS
 - Due to decidual cast/blood products in setting of ectopic pregnancy
 - Often angular shape with pointed edges
 - Potential for incorrect administration of methotrexate to normal early IUP

Intrauterine Pregnancy of Uncertain Viability

- Definite IUP with MSD < 25 mm without embryo
- Definite IUP with embryo < 7 mm without cardiac activity

Pregnancy of Unknown Location

- Positive pregnancy test, no signs of intra- or extrauterine pregnancy on TV scans
 - Could be normal early, ectopic, or failed pregnancy
 - Requires laboratory analysis and follow-up scanning for definitive diagnosis

Retained Products of Conception

- Disorganized material in uterine cavity
- If echogenic with flow on color Doppler \rightarrow most likely retained products of conception
- Retained clot is usually hypoechoic, nonperfused

Gestational Trophoblastic Disease

- Classic 2nd-trimester hydatidiform mole has Swiss cheese appearance

Ultrasound in Failed Pregnancy

Findings Diagnostic for Pregnancy Failure	Findings Suspicious for Pregnancy Failure
No heartbeat in embryo \geq 7 mm crown rump length (CRL)	No heartbeat in embryo $<$ 7 mm CRL
No embryo with mean sac diameter (MSD) \geq 25 mm	No embryo with MSD 16-24 mm
Absence of embryo with heartbeat \geq 14 days after demonstration of gestational sac without yolk sac	Absence of embryo \geq 6 weeks post last menstrual period
Absence of embryo with heartbeat \geq 11 days after demonstration gestational sac with yolk sac	Absence of embryo with heartbeat 7-13 days after demonstration of gestational sac without yolk sac
	Absence of embryo with heartbeat 7-10 days after demonstration gestational sac with yolk sac
	Empty amnion sign
	Enlarged yolk sac ($>$ 7 mm)
	Embryo to sac size discrepancy ($<$ 5 mm difference between MSD and CRL)

Reproduced from: Diagnostic Criteria for Nonviable Pregnancy Early in the First Trimester. N Engl J Med. 2013 Oct 10;369(15):1443-51. Diagnostic criteria are based on TVUS measurements.

- Early in 1st trimester may just see amorphous tissue or abnormal-appearing gestational sac
- May see associated ovarian theca lutein cysts

PATHOLOGY

General Features

- Etiology
 - Failure of implantation vs. failed embryonic development vs. early embryonic demise
 - 60% of spontaneous abortions $<$ 12 weeks due to abnormal chromosomes

CLINICAL ISSUES

Presentation

- May be asymptomatic
- Vaginal bleeding, pain, contractions suggest imminent spontaneous abortion

Demographics

- Epidemiology
 - 30-60% documented elevations of β -hCG end as failed pregnancy
 - Up to 20% of confirmed 1st-trimester pregnancies fail
 - Increased incidence of early pregnancy failure with
 - Advanced maternal age
 - History of recurrent abortions
 - Poor diabetic control

Treatment

- Most will spontaneously abort without treatment
- Vaginal misoprostol \rightarrow successful evacuation of uterus in majority of patients
 - Many patients prefer definitive treatment to expectant management
 - Some will require curettage but overall expect 50% reduction in need for surgical management
- Suction curettage
 - Small associated risk of excessive bleeding, uterine perforation, synechiae development

DIAGNOSTIC CHECKLIST

Consider

- Abnormalities common in early pregnancy
- Diagnosis of failed pregnancy depends on knowledge of normal early pregnancy milestones

Image Interpretation Pearls

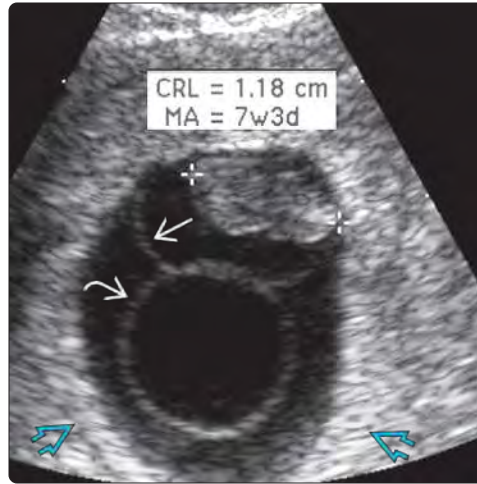
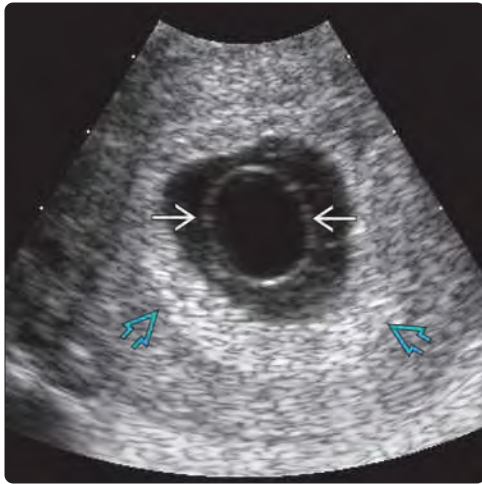
- 1st, do no harm
 - If in doubt regarding viability, wait and see

Reporting Tips

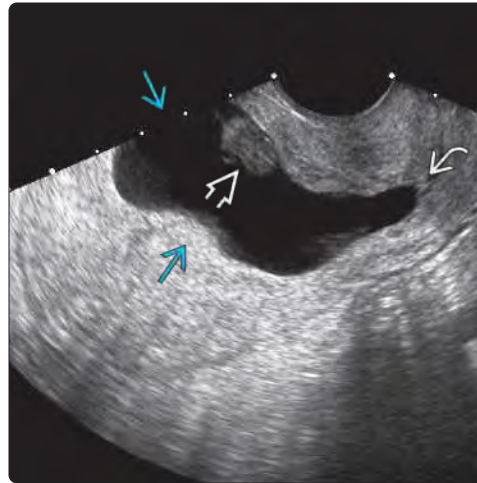
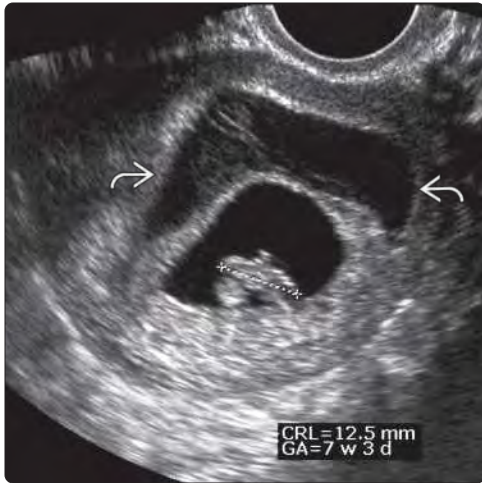- Positive pregnancy test with intrauterine fluid collection with rounded edges is statistically most likely to be IUP
 - Probable IUP if no YS or embryo
 - Definite IUP if YS or embryo visible
- Term failed 1st-trimester pregnancy simplifies terminology
 - Avoids confusion with terms such as blighted ovum, missed abortion
- Live intrauterine pregnancy more accurate than viable as fetus $<$ 24-weeks gestation not viable independent of mother
- Empty amnion, expanded amnion, yolk stalk signs are described in peer-reviewed literature but are not part of 2013 consensus panel statement

SELECTED REFERENCES

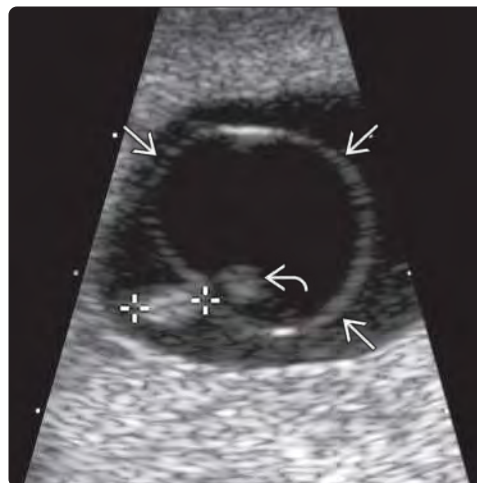
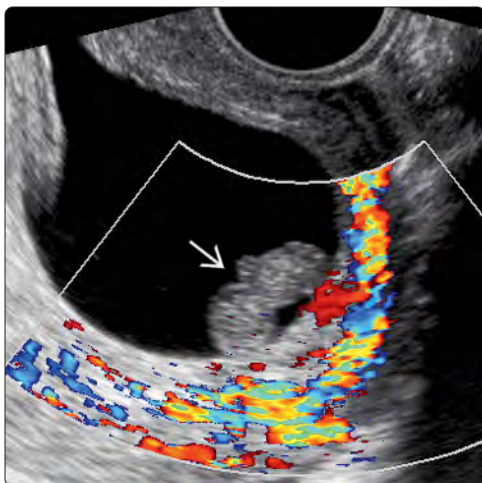
1. Benson CB et al: Intrauterine fluid with ectopic pregnancy: a reappraisal. J Ultrasound Med. 32(3):389-93, 2013
2. Doubilet PM et al: Double sac sign and intradecidual sign in early pregnancy: interobserver reliability and frequency of occurrence. J Ultrasound Med. 32(7):1207-14, 2013
3. Doubilet PM et al: Diagnostic criteria for nonviable pregnancy early in the first trimester. N Engl J Med. 369(15):1443-51, 2013
4. Barnhart K et al: Pregnancy of unknown location: a consensus statement of nomenclature, definitions, and outcome. Fertil Steril. 95(3):857-66, 2011
5. Doubilet PM et al: First, do no harm... To early pregnancies. J Ultrasound Med. 29(5):685-9, 2010
6. Filly MR et al: The yolk stalk sign: evidence of death in small embryos without heartbeats. J Ultrasound Med. 29(2):237-41, 2010
7. Yegul NT et al: The expanded amnion sign: evidence of early embryonic death. J Ultrasound Med. 28(10):1331-5, 2009



(Left) TVUS shows an example of the empty amnion sign in which the amnion is visible inside the gestational sac. No embryo is present. Do not confuse this sign with the finding of a sac with a yolk sac. (Right) TVUS shows an 11.8-mm dead embryo (calipers) surrounded by visible amnion. This is the expanded amnion sign. The yolk sac is abnormal. Normal diameter is < 6 mm, but this one measured 9 mm. The embryo is inside the amnion, and the yolk sac is outside the amnion, inside the chorion.



(Left) TVUS shows a 12.5-mm embryo (calipers). There was no visible heart motion. Note the large perigestational hemorrhage in this patient who presented with pelvic pain and vaginal bleeding. (Right) TVUS shows a large irregular gestational sac collapsing in on itself as the cervical canal dilates. There was no cardiac activity in the embryo, which was 11 mm in length. This case shows definite pregnancy failure.



(Left) Color Doppler shows lack of cardiac motion in this embryo, which measured 13 mm. (Right) TVUS shows the expanded amnion sign with a dead embryo and a collapsed yolk sac (calipers). Embryologically, if the amnion has expanded enough to be visible around the embryo, there should be cardiac activity. The collapsed yolk sac was incorrectly measured as the crown rump length. Remember, the embryo is inside the amnion and the yolk sac is outside.

KEY FACTS

TERMINOLOGY

- Perigestational hemorrhage (PGH): Hematoma in subchorionic space adjacent to gestational sac

IMAGING

- Acute hematoma is echogenic
- Subacute hematoma is complex, more hypoechoic
- Old hematoma approaches sonolucent
- PGH has no blood flow on color Doppler

TOP DIFFERENTIAL DIAGNOSES

- Diamniotic twinning in early 1st trimester
- Chorioamniotic separation in late 1st trimester

PATHOLOGY

- Large PGH
 - > 50% of gestational sac surrounded by blood
 - PGH volume > 30 cc

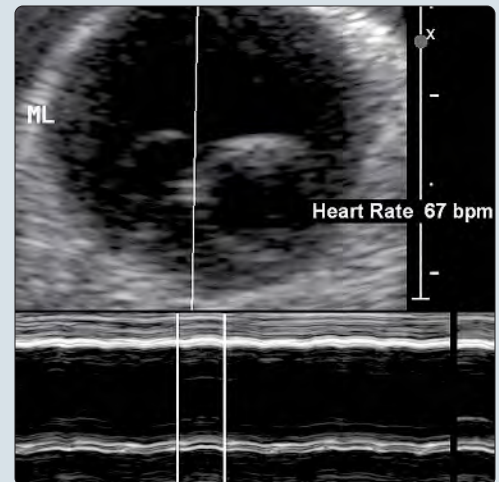
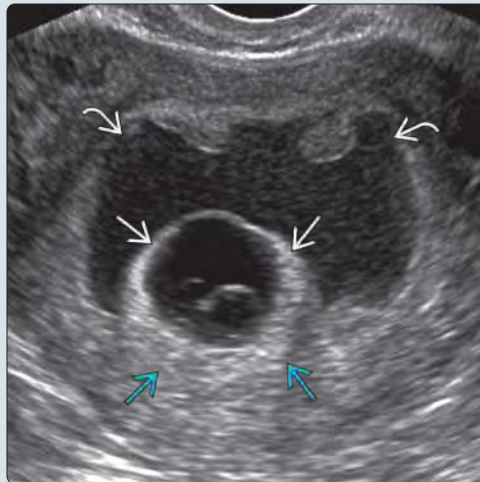
CLINICAL ISSUES

- Presence of living embryo with normal heart rate is most reassuring sign
- Most resolve without sequelae
- 2% of all 1st-trimester patients have PGH
- 20% of patients with vaginal bleeding have PGH
- PGH associated with 2nd- and 3rd-trimester complications
 - Elevated maternal serum α -fetoprotein
 - 2nd-/3rd-trimester abruption
 - Preterm delivery
- > 90% pregnancy success rate if living embryo + small PGH
- Guarded prognosis if embryonic bradycardia
- Guarded prognosis with large PGH

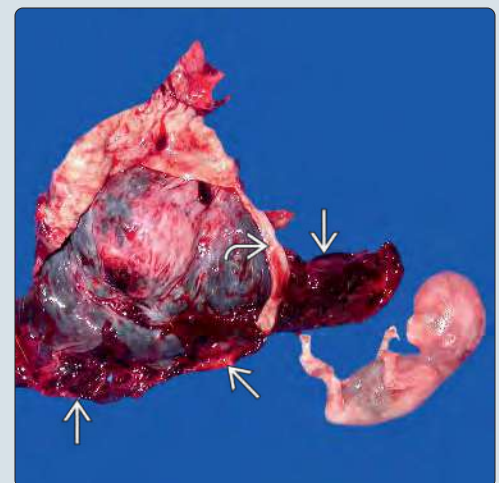
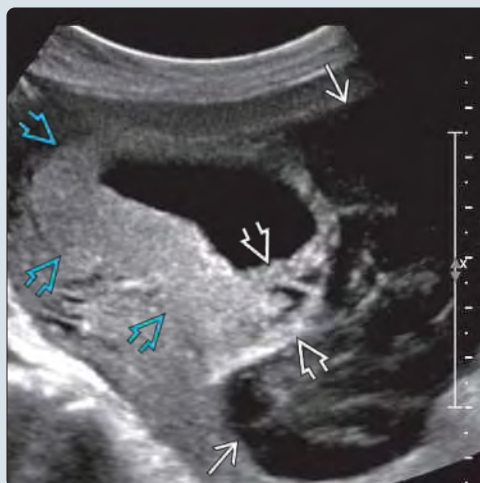
DIAGNOSTIC CHECKLIST

- Beware of twins mimicking PGH and vice versa

(Left) A large perigestational hemorrhage (PGH) surrounds an early gestational sac (GS). The GS is attached posteriorly with 2/3 of the circumference of the sac surrounded by blood. (Right) A living embryo was seen within the gestational sac, but the heart rate was slow. The combination of embryonic bradycardia and PGH is associated with a poor prognosis, and this pregnancy failed shortly after the scan.



(Left) In this 12-week pregnant patient from the fertility center, a large PGH with complex echogenicity lifts the inferior edge of the chorionic frondosum (CF), or early placenta. The majority of the CF is otherwise well attached, and the fetus survived. (Right) In a case of an 11-week pregnancy loss from subchorionic hemorrhage, gross pathology shows a large perigestational hemorrhage that extends from behind the membranes and placenta.



TERMINOLOGY

Abbreviations

- Perigestational hemorrhage (PGH)

Synonyms

- Subchorionic hematoma

Definitions

- Hematoma in subchorionic space adjacent to gestational sac (GS)
- Bleeding from chorionic frondosum (CF) later in 1st trimester

IMAGING

General Features

- Best diagnostic clue
 - Crescentic fluid collection between GS and uterine wall

Ultrasonographic Findings

- PGH appearance depends on age of bleed
 - Acute hematoma is echogenic
 - Isoechoic to GS or CF
 - Progression to hypoechoic/anechoic with time
 - Complex fluid collection
 - Fibrin strands resemble septations
 - Most PGH resolves, with delivery of normal infant
- Shape is variable
 - Round, mass-like bleed
 - Curvilinear/lenticular follows contour of uterus
- Findings associated with poor prognosis
 - Large hematoma
 - > 50% of sac circumference, > 30 cc volume
 - Misshapen GS, abnormal intrasac anatomy
 - Bradycardia: Embryo heart rate \leq 90 beats/minute
 - Cervical os dilatation \rightarrow miscarriage
- Color Doppler can help identify PGH separate from GS

DIFFERENTIAL DIAGNOSIS

Twin Gestation

- 2nd GS can mimic PGH
- Follow-up to see yolk sac/embryo development in sac

Pseudogestational Sac (Ectopic Pregnancy)

- This term now discouraged as it is imprecise and may lead to confusion
- Represents blood centrally located in endometrial cavity
- Look for adnexal mass and echogenic cul-de-sac fluid

Chorioamniotic Separation

- Amnion seen separate from uterine wall
- Placental edge remains attached

PATHOLOGY

General Features

- Etiology
 - Bleeding from area of trophoblastic tissue implantation

Staging, Grading, & Classification

- Compare PGH to GS size

- Small PGH surrounds < 20% of sac circumference
- Medium PGH surrounds 20-50% of sac circumference
- Large PGH surrounds > 50% of sac circumference
- PGH volume estimation (length x width x depth/2)
 - > 30 cc associated with 50% loss rate
 - > 60 cc associated with 93% loss rate

CLINICAL ISSUES

Presentation

- Most common signs/symptoms
 - Asymptomatic (incidentally seen PGH)
 - Threatened abortion/miscarriage
 - Post procedure (chorionic villus sampling)

Demographics

- Epidemiology
 - 2% of all 1st-trimester pregnancies have PGH
 - 20% of patients with vaginal bleeding have PGH
 - 2x higher incidence with in vitro fertilization pregnancy

Natural History & Prognosis

- Excellent prognosis if living embryo + small PGH
 - > 90% pregnancy success rate
- Guarded prognosis with large PGH
 - 25% loss rate even if living embryo seen
 - > 50% GS/CF detachment has greatest loss rate
- Poor prognosis if associated embryonic bradycardia
 - 80% loss rate
- Failed pregnancy if cervix is open
 - Regardless of appearance of PGH
 - Clinical diagnosis but may see with US
- Associated maternal/fetal morbidity
 - Placental abruption (2.6-5.7x \uparrow risk)
 - Preterm delivery (1.3x \uparrow risk)
 - Elevated maternal serum α -fetoprotein

Treatment

- Surveillance and maternal support
- Short-term follow-up for early and large PGH
 - Look for signs of viable pregnancy
 - Hematoma should \downarrow in size and echogenicity
- Follow-up growth scans for large PGH
 - \uparrow risk for placental insufficiency

DIAGNOSTIC CHECKLIST

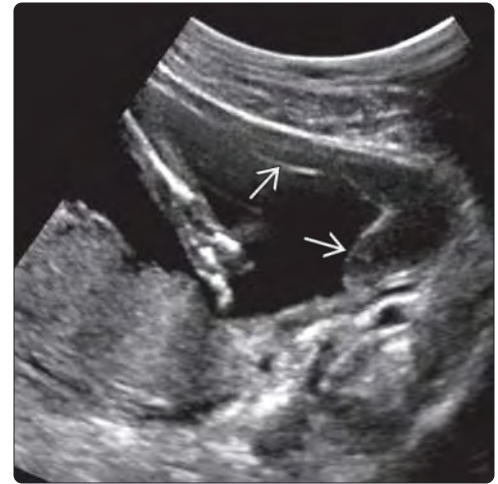
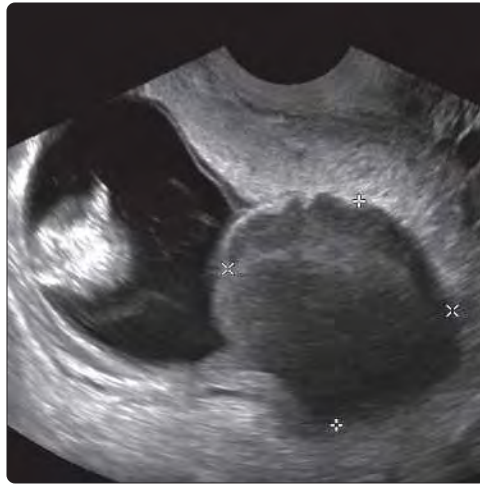Image Interpretation Pearls

- Presence of living embryo is most reassuring sign
- Look for usual signs of viable pregnancy
- Beware of twins mimicking PGH and vice versa

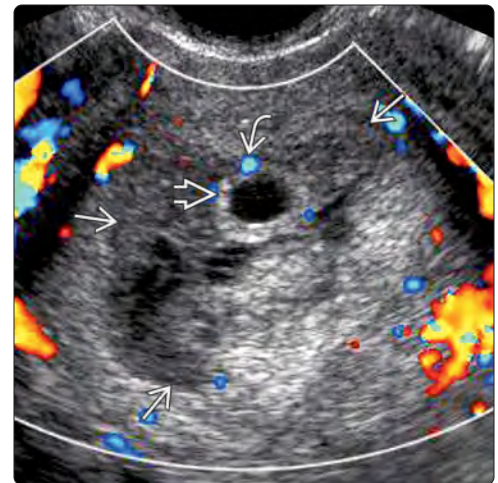
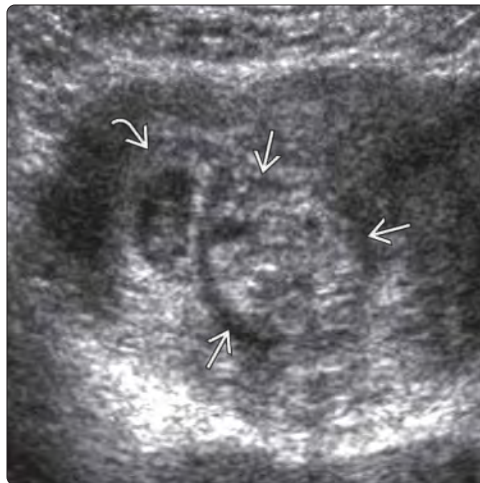
SELECTED REFERENCES

1. Asato K et al: Subchorionic hematoma occurs more frequently in in vitro fertilization pregnancy. *Eur J Obstet Gynecol Reprod Biol.* 181:41-4, 2014
2. Ozkaya E et al: Significance of subchorionic haemorrhage and pregnancy outcome in threatened miscarriage to predict miscarriage, pre-term labour and intrauterine growth restriction. *J Obstet Gynaecol.* 31(3):210-2, 2011
3. Tuuli MG et al: Perinatal outcomes in women with subchorionic hematoma: a systematic review and meta-analysis. *Obstet Gynecol.* 117(5):1205-12, 2011
4. Dighe M et al: Sonography in first trimester bleeding. *J Clin Ultrasound.* 36(6):352-66, 2008

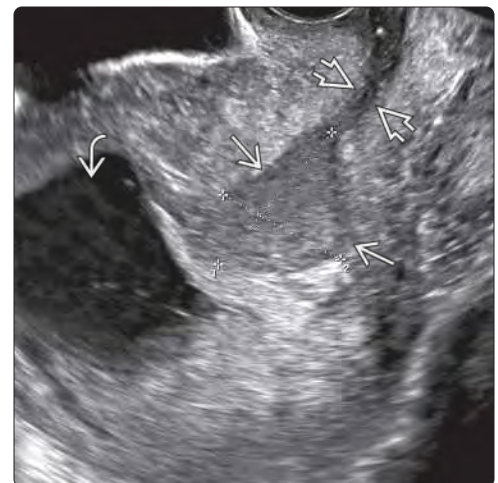
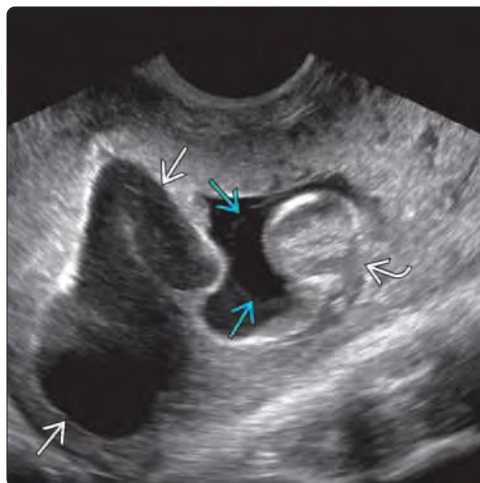
(Left) Calipers measure a large, mass-like, round PGH. Although this appearance can mimic a myoma in pregnancy, the lack of internal blood flow and the symptomatic presentation favored the diagnosis of PGH. **(Right)** On follow-up several weeks later, the subchorionic hematoma is now smaller, almost anechoic, lenticular, and follows the uterine contour.



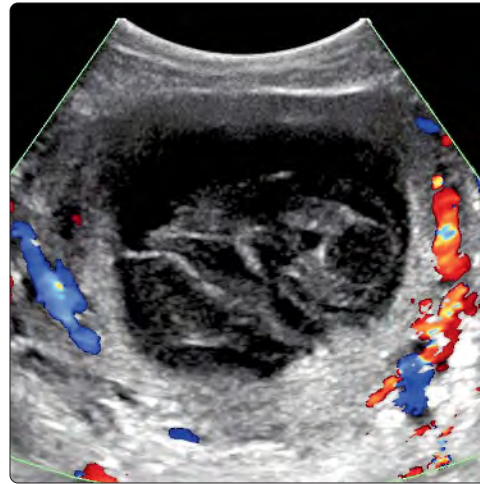
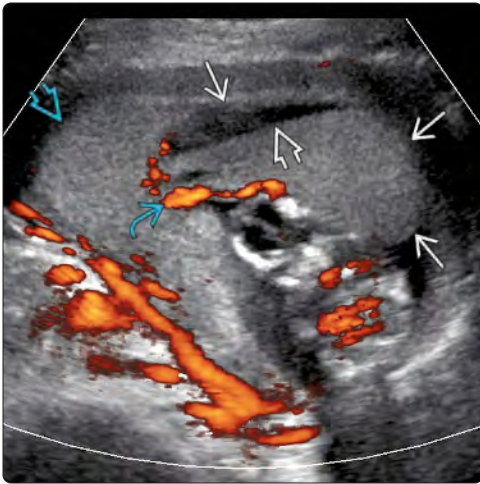
(Left) Transverse US shows an echogenic, mass-like, acute PGH. The GS is compressed by the hematoma. There was a living embryo at the time of this study, and the pregnancy was successful. The round echogenic PGH is a blood clot that eventually retracted and resolved. **(Right)** Color Doppler shows a large avascular hemorrhage surrounding a gestational sac. A small chorionic vessel is seen at the attachment site. Surprisingly, this pregnancy was also successful.



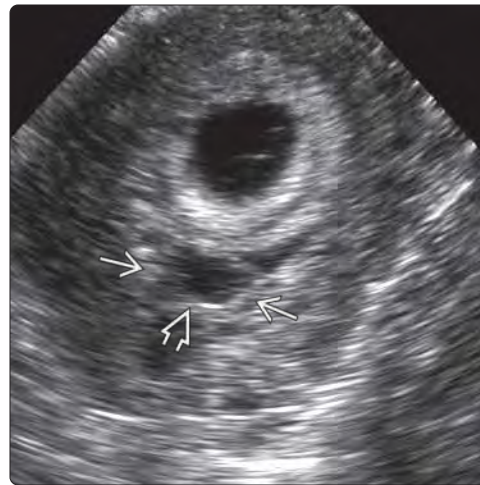
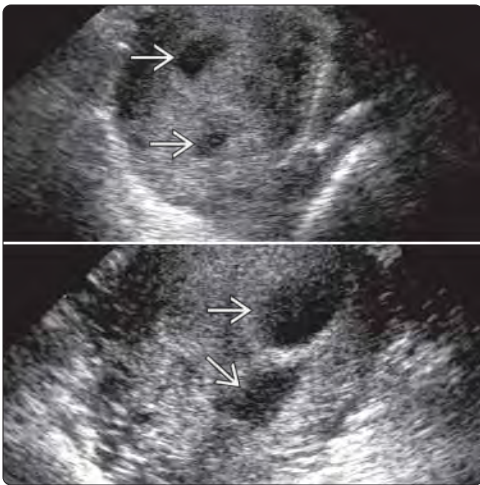
(Left) This early GS is misshapen by hypoechoic and echogenic hematomas, most likely from hemorrhages occurring at different times. Intrasac anatomy is abnormal with a thin, echogenic line probably representing an empty amnion. This pregnancy failed. **(Right)** Sagittal TVUS shows a PGH extending through a mildly dilated cervical canal. The sac is misshapen and contains neither an embryo nor a yolk sac. The patient miscarried a few hours later.



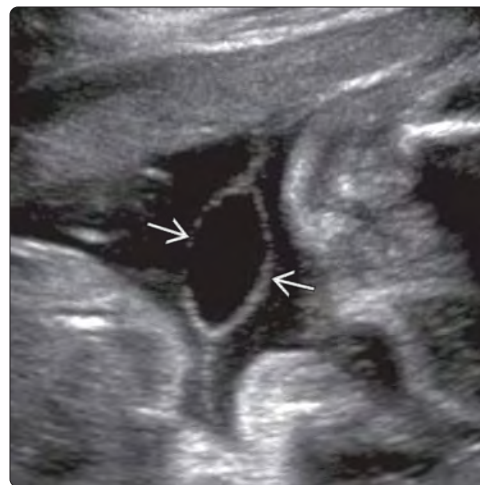
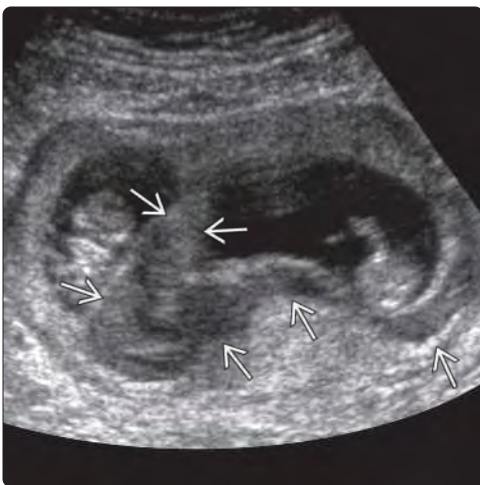Perigestational Hemorrhage



(Left) This atypical subchorionic hematoma is located in the preplacental subchorionic space, near the placental cord insertion, and has a fluid-fluid level and no flow with power Doppler. The uteroplacental attachment is normal. This patient was asymptomatic. **(Right)** In another case with a large PGH, color Doppler helps show that the hematoma has no blood flow. Color and power Doppler help differentiate hematoma from placenta and myometrium.



(Left) US images from a transabdominal scan show 2 fluid collections within the uterus mimicking the appearance of a twin gestation. The inferior posterior collection is the PGH. **(Right)** The PGH mimics a misshapen dichorionic GS with a yolk sac. On follow-up, the PGH was more anechoic and lenticular. A PGH may mimic a twin gestation and vice versa.



(Left) In this case of dichorionic twinning, a subacute PGH is seen extending along the posterior uterus and between the 2 sacs. **(Right)** Later, in the same pregnancy, a sonolucent fluid collection was seen between the membranes that separate the dichorionic diamniotic twins. Presumably, this is old anechoic blood products from the PGH that occurred earlier in the pregnancy.

KEY FACTS

IMAGING

- Focal protrusion of chorion
 - Continuous with surface of chorion
 - Margins form acute angles with chorionic plate surface
- Central hypoechogenic area in 20%
- Low-level swirling echoes seen in central area on real-time evaluation in 27%

TOP DIFFERENTIAL DIAGNOSES

- Failed 1st-trimester pregnancy
- Abnormal yolk sac
- Perigestational hemorrhage







CLINICAL ISSUES

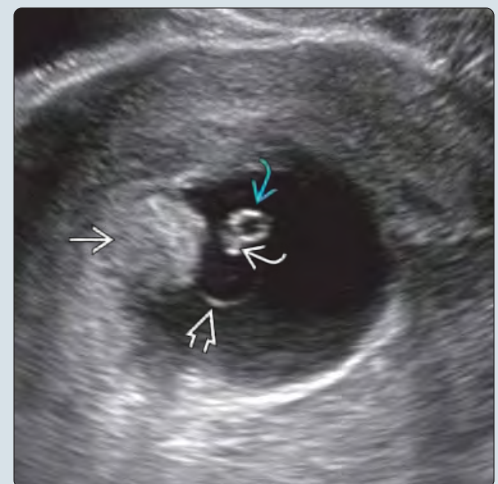
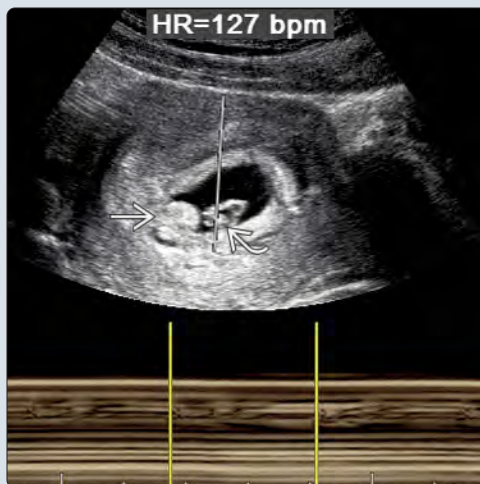
- Prevalence 0.15% in retrospective case-control study
- Thought to be arterial hematoma arising from developing intervillous space or chorionic plate
- In continuing pregnancy, chorionic bump becomes smaller, less echogenic, eventually resolves



- Enlarging CB associated with increased chance of failure
 - Strong association with partial mole in failed pregnancies where tissue obtained
- Prognosis
 - 50% failure rate documented in initial cohort
 - 80% survived if embryo with normal heart rate seen
 - Subsequent studies have shown better outcome
 - Sana et al: Live birth rate 62% with ~ 2x loss rate in CB group vs. controls
 - Arleo et al: Overall live birth rate 65%
 - ◻ If live embryo at some point → live birth rate 83%
 - In 1 series, all pregnancies with multiple bumps were nonviable
- No specific therapy

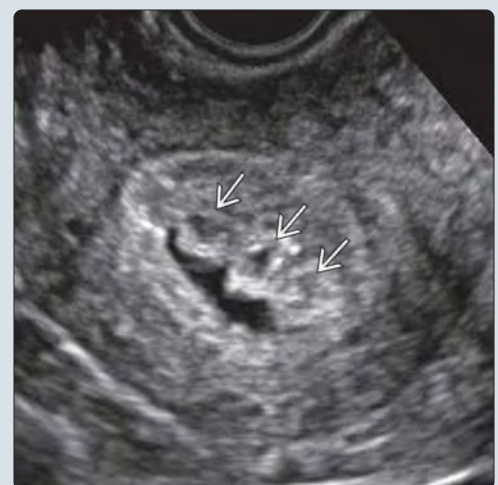
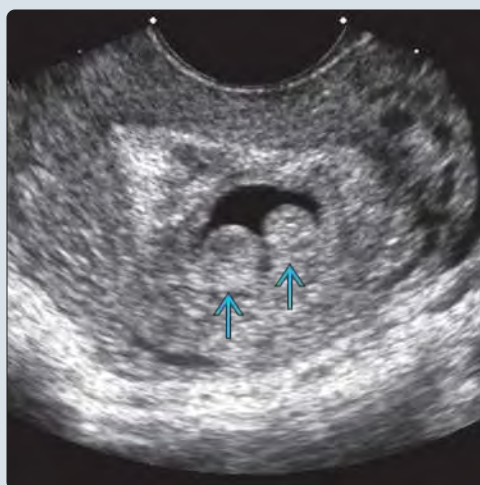
DIAGNOSTIC CHECKLIST

- Must know normal appearance of early pregnancy
 - Avoid confusion with embryonic demise
 - Avoid confusion with abnormal yolk sac

(Left) TVUS show a chorionic bump . In this case, there was a live embryo  the size of which was concordant with menstrual dates. This was a successful pregnancy. (Right) TVUS shows a chorionic bump  with a visible embryo , which is far smaller than expected for menstrual dates, which were confirmed on an earlier scan. The embryo is surrounded by the expanded amnion . The yolk sac  is normal. This is a failed 1st-trimester pregnancy with a dead embryo.



(Left) TVUS shows multiple chorionic bumps . No normal early pregnancy structures (e.g., yolk sac, embryo, amnion) were ever visible. Dilatation and curettage confirmed triploidy in this case. (Right) TVUS shows multiple chorionic bumps  with hypoechoic centers in a patient who presented with vaginal bleeding. This case ended in complete, spontaneous abortion.



TERMINOLOGY

Abbreviations

- Chorionic bump (CB)

IMAGING

General Features

- Best diagnostic clue
 - Persistent focal protuberance from chorion into gestational sac
- Size
 - Reported size ranged from 0.5-3.8 cm max diameter; volumes 0.04-11.2 mL
 - No correlation between size and outcome
- Morphology
 - Continuous with surface of chorionic plate
 - Margins form acute angles with chorionic plate surface

Ultrasonographic Findings

- Grayscale ultrasound
 - Focal protrusion of chorion
 - Echogenicity usually similar to that of chorion
 - Central hypoechogenic area in 20%
 - Low-level swirling echoes seen in central area on real-time evaluation in 27%
 - Avascular on Doppler interrogation
 - Persistent throughout duration of scan
 - Usually single but can be multiple

DIFFERENTIAL DIAGNOSIS

Failed 1st-Trimester Pregnancy

- Chorionic sac may be flattened or irregular in contour
 - CB projects into round or oval sac
- In embryonic demise, dead embryo is inside amnion, not flush with chorion

Abnormal Yolk Sac

- Seen outside amnion, in extraembryonic coelomic space, not flush with chorion
- Yolk sac has more distinct linear echo

Perigestational Hemorrhage

- Occurs in decidua or cytotrophoblastic shell
 - Venous bleed so low pressure → crescentic or oval shape on myometrial side of chorion
 - Hypoechoic
 - CB round, often similar echogenicity to chorion

PATHOLOGY

General Features

- Focal round shape suggests arterial rather than venous bleed
- Thought to be arterial hematoma arising from developing intervillous space or chorionic plate

CLINICAL ISSUES

Presentation

- Most common signs/symptoms
 - Often asymptomatic

- May present with vaginal bleeding

Demographics

- Epidemiology
 - Prevalence 0.7% in index cohort
 - Mean gestational age at demonstration was 6.7 weeks
 - 0.15% in retrospective case-control study

Natural History & Prognosis

- 50% failure rate documented in initial cohort of patients with assisted reproduction
 - Presence of embryo with normal heart rate conferred better prognosis (80% survived)
- Subsequent studies have shown better outcome
 - Sana et al: Live birth rate 62% with ~ 2x loss rate in CB group vs. controls
 - Arleo et al: Single institution/single reader review 1st-trimester scans for any indication
 - 52 pregnancies with CB → overall live birth rate 65%
 - 41 with live embryo at some point → live birth rate 83%
 - 6 with gestational sac with yolk sac but no embryo → 4 live births
 - 8 with gestational sac only → 2 live births
 - 3 with gestational sac with yolk sac + embryo but no cardiac activity → 0 live births
 - 18 nonviable (7 anembryonic, 11 early demise)
- In 1 series, all pregnancies with multiple bumps were nonviable
- Serial changes over follow-up suggestive of focal hematoma
 - In continuing pregnancy, CB becomes smaller, less echogenic, eventually resolves
- Enlarging CB associated with increased chance of failure

Treatment

- No specific therapy
- Consider tissue analysis of failed pregnancies
 - Strong association with gestational trophoblastic disease, particularly partial mole

DIAGNOSTIC CHECKLIST

Consider

- Must know normal appearance of early pregnancy
 - Avoid confusion with embryonic demise
 - Avoid confusion with abnormal yolk sac

SELECTED REFERENCES

1. Arleo EK et al: Chorionic bump on first-trimester sonography: not necessarily a poor prognostic indicator for pregnancy. *J Ultrasound Med.* 34(1):137-42, 2015
2. Sana Y et al: Clinical significance of first-trimester chorionic bumps: a matched case-control study. *Ultrasound Obstet Gynecol.* 42(5):585-9, 2013
3. Tan S et al: The chorionic bump: Radiologic and pathologic correlation. *J Clin Ultrasound.* 39(1):35-7, 2011
4. Harris RD et al: The chorionic bump: a first-trimester pregnancy sonographic finding associated with a guarded prognosis. *J Ultrasound Med.* 25(6):757-63, 2006

Complete Hydatidiform Mole

KEY FACTS

TERMINOLOGY

- Trophoblastic proliferation (both cytotrophoblast and syncytiotrophoblast) and vesicular swelling of placental villi associated with absent fetus

IMAGING

- Classic findings described as "Swiss cheese" or "cluster of grapes" endometrium
 - No fetus or embryo
 - Increased vascularity on color Doppler
 - Areas of hemorrhage common
- 1st-trimester CHM
 - Very different appearance than seen later
 - Thickened, irregular endometrium
 - Appearance may mimic retained products of conception or anembryonic pregnancy
- Ovarian theca lutein cysts in 50% of cases
 - Result from ovarian hyperstimulation due to ↑ hCG
 - Rare < 13 weeks

- Occur more frequently with invasive mole and choriocarcinoma than in CHM
- Must distinguish CHM with coexistent fetus (dizygotic twin pregnancy) from partial mole (triploidy)

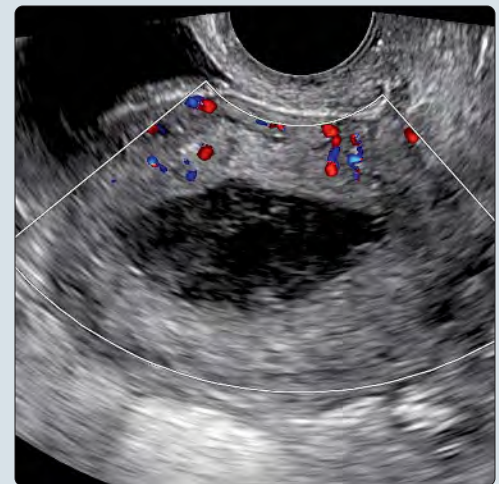
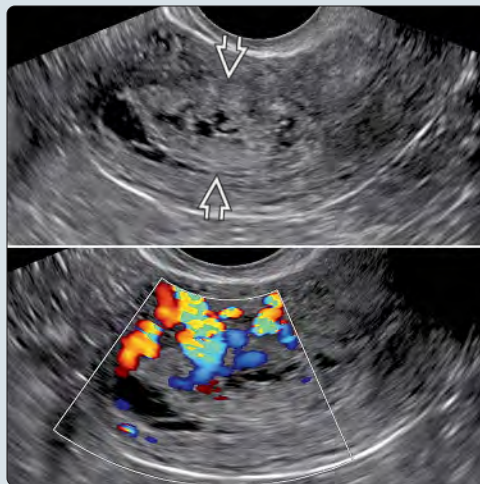
TOP DIFFERENTIAL DIAGNOSES

- Placental hydropic degeneration
- Triploidy
- Placental mesenchymal dysplasia

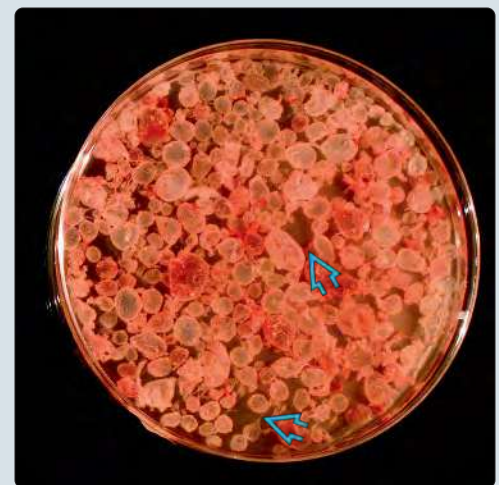
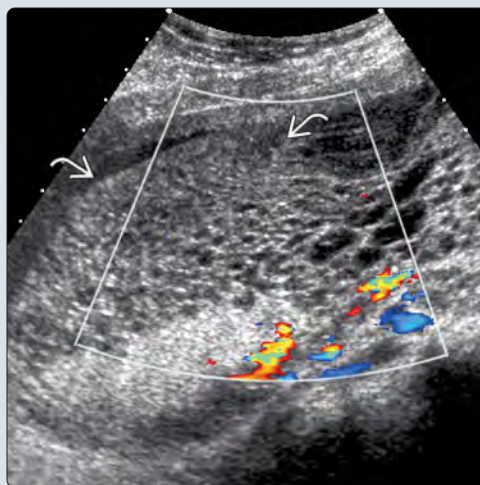
CLINICAL ISSUES

- Normal hCG levels do not rule out CHM if < 13 weeks
- Treatment
 - Evacuation with suction curettage
 - Measure hCG weekly until undetectable for 3 weeks and then monthly for 6 months
- Invasive mole in 12-15%
- Choriocarcinoma in 5-8%
 - Excellent prognosis even with metastases

(Left) Do not expect the classic bunch of grapes appearance of a complete hydatidiform mole (CHM) in the 1st trimester. It often appears a thickened endometrium & can mimic retained products of conception or anembryonic pregnancy. In this case, the endometrium is thickened [E], with a few scattered lucencies and significant flow on color Doppler. (Right) This is another CHM in the 1st trimester that is hypovascular. The 1st-trimester appearance is quite variable and it is essential to compare with the hCG levels.



(Left) By the 2nd trimester, a CHM will have a more classic Swiss cheese appearance. This longitudinal transabdominal ultrasound shows a large cystic endometrial mass [E] with multiple small cystic areas representing the hydropic villi. (Right) This Petri dish is filled with hydropic villi from a CHM. They are attached by thin fibrous strands [E]. Evidence of prior hemorrhage is typically present.



TERMINOLOGY

Abbreviations

- Complete hydatidiform mole (CHM)

Definitions

- Trophoblastic proliferation (both cytotrophoblast and syncytiotrophoblast) and vesicular swelling of placental villi associated with absent fetus
- Most common (~ 76% of all cases) type of gestational trophoblastic disease, which also includes
 - Partial mole (triploidy)
 - Invasive mole (chorioadenoma destruens)
 - Choriocarcinoma
 - Placental-site trophoblastic tumor
 - Epithelioid trophoblastic tumor

IMAGING

General Features

- Best diagnostic clue
 - Enlarged uterus with "Swiss cheese" or "cluster of grapes" endometrium
 - "Snowstorm": Older term used before technology was capable of discerning individual cysts
 - Bilateral, complex ovarian cysts (theca lutein cysts)
 - No fetus or embryo

Ultrasonographic Findings

- Uterine findings
 - **1st-trimester CHM**
 - Very different appearance than classic 2nd-trimester CHM
 - Only 1/2 will show cysts in 1st trimester
 - Thickened, irregular endometrium similar to retained products of conception
 - Can look identical to anembryonic gestation
 - **Late 1st-/2nd-trimester CHM**
 - Hydropic villi appear as multiple anechoic spaces, 1-30 mm in size, within echogenic intrauterine mass ("Swiss cheese" endometrium)
 - No embryo or fetus
- Ovarian theca lutein cysts
 - Bilateral multiseptated cysts
 - Enlarged ovaries, sometimes massive
 - Only in 50% of all CHM
 - Rare < 13 weeks
 - β -hCG not extremely elevated yet
- Doppler findings
 - Mass is vascular
 - Color Doppler easily shows flow
 - High-velocity, low-resistance flow
 - Mean resistive index (RI) of 0.55
 - Normally, uterine arcuate artery flow is low velocity until 3rd trimester
 - Normal RI often > 0.66 if < 20 weeks
- **CHM with coexistent fetus**
 - Dizygotic twin pregnancy
 - 1 normal fetus, 1 CHM
 - Normal fetus has normal placenta
 - Must differentiate from partial mole (triploidy)

- CHM often associated with hemorrhage
 - Adjacent sonolucent hematoma
 - Mimics perigestational hemorrhage
 - Hemorrhage within mass
 - Disrupts typical appearance

CT Findings

- CECT
 - Limited role in evaluation of CHM
 - Heterogeneously enhancing endometrial mass
 - Enhancing septa give uterine contents reticular appearance
 - Usually performed when metastatic disease suspected

MR Findings

- T1WI
 - Uterine mass isointense to myometrium
 - Areas of hemorrhage are hyperintense
- T2WI
 - Markedly hyperintense mass distends endometrial cavity
- Avidly enhancing with gadolinium
 - Excellent modality to evaluate for myometrial invasion

DIFFERENTIAL DIAGNOSIS

Placental Hydropic Degeneration

- Hydropic change without proliferation
- Seen after pregnancy failure
 - Embryonic demise
 - Anembryonic gestation
- Can look identical to CHM
 - Need histologic diagnosis
- Less vascular than CHM
 - \downarrow velocity, \downarrow resistance
- \downarrow hCG levels

Triploidy (Partial Mole)

- Fetus is present but abnormal
 - Severe growth restriction
 - Multiple anomalies
- 3 complete sets of chromosomes
 - 2 paternal + 1 maternal (diandry)
 - Placenta is cystic
 - Most likely aneuploidy to be confused with CHM
 - 2 maternal + 1 paternal (digyny)
 - Placenta normal or small
- Must differentiate from twin pregnancy with 1 CHM
 - Normal fetus and placenta + CHM

Placental Mesenchymal Dysplasia

- Also called pseudopartial mole
- Thickened, cystic placenta
- Associated with maternal/fetal morbidity
 - Fetal growth restriction
 - Often early onset and severe
 - Preterm labor and fetal death common
 - Preeclampsia
- Absence of trophoblastic proliferation differentiates it from partial mole
- ~ 20% have Beckwith-Wiedemann syndrome

PATHOLOGY

General Features

- Etiology
 - Risk factors
 - Pregnancy at very young or advanced reproductive ages and in grand multiparas
 - Risk of recurrence in future pregnancy is 1.2-1.4%
 - Increases to 20% after 2 moles
 - *NLRP7* and *KHDC3L* gene mutations found in this group
- Genetics
 - Diploid karyotype of paternal origin
 - Single haploid sperm fertilizing ovum lacking maternal genes followed by duplication
 - 90% of cases
 - (46, XX) karyotype
 - Abnormal ovum more likely at both ends of reproductive years
 - 2 haploid sperm fertilizing ovum lacking maternal genes
 - 10% of cases
 - (46, XX) or (46, XY) karyotype
 - May be tetraploid
- Associated abnormalities
 - Ovarian theca lutein cysts
 - Result from ovarian hyperstimulation due to hCG
 - Usually not seen in 1st trimester
 - Occur more frequently with invasive mole and choriocarcinoma than in CHM

Gross Pathologic & Surgical Features

- Large mass, sometimes consisting of > 500 mL of bloody tissue
- Classic bunch of grapes appearance
 - Large villi forming transparent vesicles of variable size (1-30 mm) attached to one another by thin fibrous strands
 - Size of villi ↑ as gestation progresses
- Absent fetus
- No normal placental tissue

CLINICAL ISSUES

Presentation

- Most common signs/symptoms
 - Most CHM present in late 1st trimester
 - Vaginal bleeding
 - Absence of fetal heart tones
 - Rapid uterine enlargement
 - Hyperemesis
 - ↑ hCG levels
 - hCG may not be elevated < 13 weeks
 - Preeclampsia
- Other signs/symptoms
 - Enlarged ovaries with theca lutein cysts
 - Preeclampsia
 - Thyroid storm

Demographics

- Age
 - Young or advanced maternal age

- Ethnicity
 - Higher incidence in Asia (3.2-9.9 per 1,000 gestations) compared with Western countries (0.6-1.1 per 1,000 gestations)

Natural History & Prognosis

- Excellent prognosis
 - Evacuation often curative
- Invasive or metastatic disease may develop
 - Invasive mole in 12-15%
 - Choriocarcinoma in 5-8%
 - Excellent prognosis even with metastases

Treatment

- Evacuation with suction curettage
 - Measure hCG weekly until undetectable for 3 weeks and then monthly for 6 months
 - If serum hCG levels plateau or rise, there is concern for invasive mole or choriocarcinoma
 - Requires work-up for metastatic disease
 - Should not become pregnant during monitoring period
 - Cannot interpret hCG results; complicates management
 - Options include hormonal contraception or barrier methods
 - Intrauterine device should not be used because of risk of uterine perforation
- Hysterectomy if childbearing has been completed

DIAGNOSTIC CHECKLIST

Consider

- CHM with atypical anembryonic gestation
- Rule out CHM when hCG levels are ↑
- Normal hCG levels do not rule out CHM if < 13 weeks
- Careful evaluation for invasive disease
 - Color Doppler of myometrium

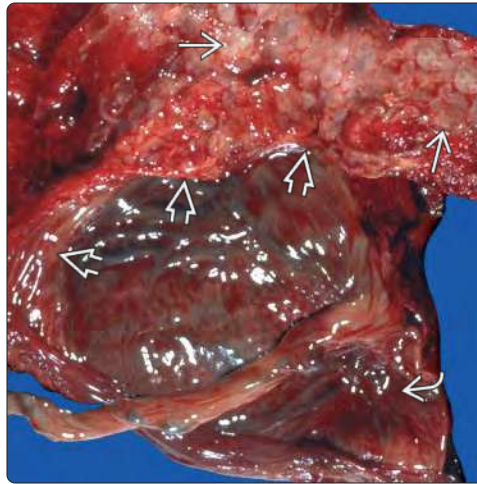
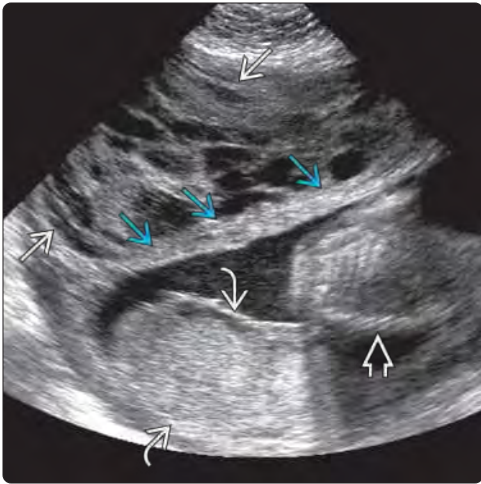
Image Interpretation Pearls

- Repeat imaging if hCG levels ↑ after treatment
 - Ultrasound to look for myometrial vascular cysts
 - MR for local invasion
- CHM can look identical to anembryonic pregnancy

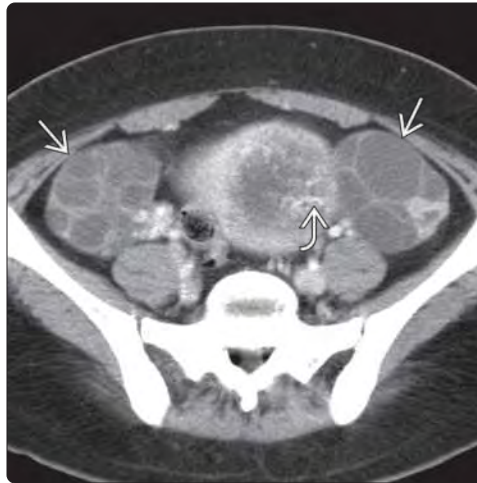
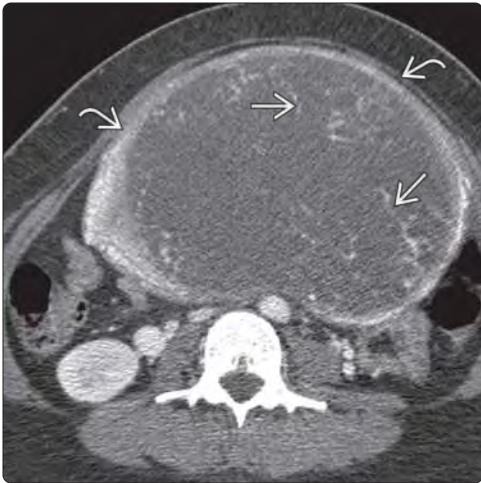
SELECTED REFERENCES

1. Eysbouts YK et al: Trends in incidence for gestational trophoblastic disease over the last 20 years in a population-based study. *Gynecol Oncol.* 140(1):70-5, 2016
2. Carey L et al: Molecular genetic studies of complete hydatidiform moles. *Transl Pediatr.* 4(2):181-8, 2015
3. Eagles N et al: Risk of recurrent molar pregnancies following complete and partial hydatidiform moles. *Hum Reprod.* 30(9):2055-63, 2015
4. Gadducci A et al: Reproductive outcomes after hydatiform mole and gestational trophoblastic neoplasia. *Gynecol Endocrinol.* 31(9):673-8, 2015
5. Jean-Jacques C: The hydatidiform mole. *Cell Adh Migr.* 1-10, 2015
6. Froeling FE et al: Gestational trophoblastic tumours: an update for 2014. *Curr Oncol Rep.* 16(11):408, 2014
7. Shanbhogue AK et al: Gestational trophoblastic disease. *Radiol Clin North Am.* 51(6):1023-34, 2013
8. Ronnett BM et al: Hydatidiform moles: ancillary techniques to refine diagnosis. *Int J Gynecol Pathol.* 30(2):101-16, 2011
9. Lurain JR: Gestational trophoblastic disease I: epidemiology, pathology, clinical presentation and diagnosis of gestational trophoblastic disease, and management of hydatidiform mole. *Am J Obstet Gynecol.* 203(6):531-9, 2010

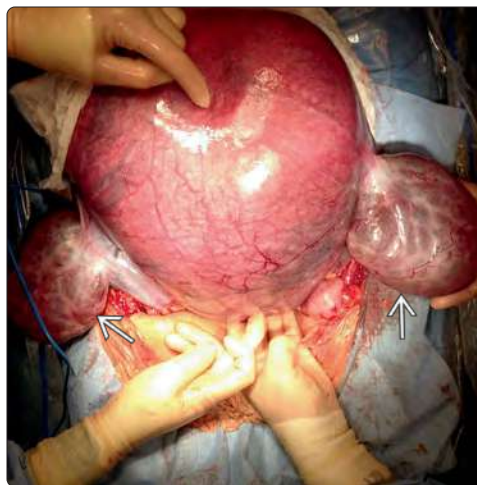
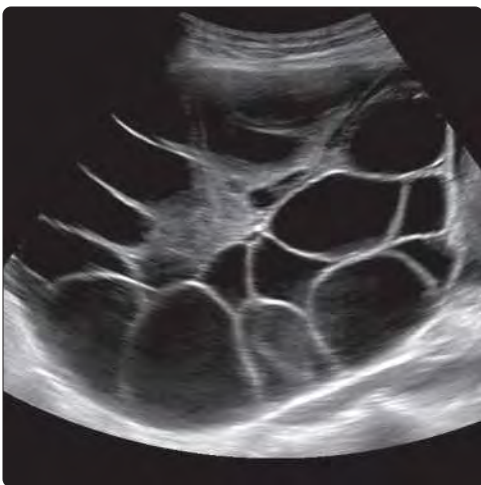Complete Hydatidiform Mole



(Left) Axial ultrasound in a 39-year-old woman shows a normal fetus with coexistent mole. This is the result of a dizygotic pregnancy. The normal twin and placenta are seen adjacent to a CHM. A thick membrane separates the 2. (Right) She elected to have a cesarean hysterectomy. The specimen shows the normal placenta below with a thick membrane separating it from the CHM above. Note the classic hydropic villi.



(Left) Axial CECT shows marked enlargement of the uterus that is filled with predominantly low-attenuation tissue representing abnormal hydropic villi in a CHM. Enhancing septa give the uterine contents a reticular appearance. (Right) This CECT, at the fundus of the uterus in a different patient, shows a small portion of the CHM (enhancing septa). In addition, there is bilateral ovarian enlargement. The ovaries contain multiple large theca lutein cysts.



(Left) Transvaginal ultrasound shows an enlarged ovary (15 cm in longest dimension) with theca lutein cysts. Theca lutein cysts cause a multiseptated appearance, are often bilateral, and are associated with high maternal serum hCG levels. They are only seen in 50% of CHM cases and usually not in the 1st trimester. (Right) This intraoperative photograph shows an enlarged uterus and bilateral enlarged ovaries from theca lutein cysts.

KEY FACTS

IMAGING

- No intrauterine pregnancy (IUP) with tubal mass with echogenic cul-de-sac fluid (blood)
- Nonspecific adnexal mass is commonest finding
- Variable appearance
 - Adnexal mass [probable ectopic pregnancy (EP)]
 - Well-developed gestational sac with recognizable embryo (definite EP)
- Blood in cul-de-sac is important sign
 - Obtain sagittal cul-de-sac view in every case

TOP DIFFERENTIAL DIAGNOSES

- Incidental adnexal mass (especially corpus luteum cyst)
 - Use endovaginal probe as palpation tool
 - EP moves independent of ovary, corpus luteum (CL) moves with ovary




CLINICAL ISSUES

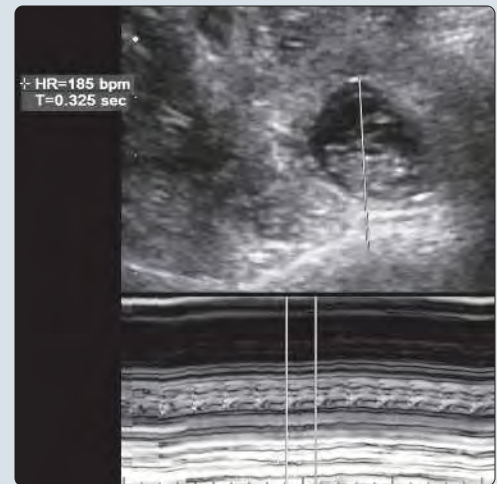
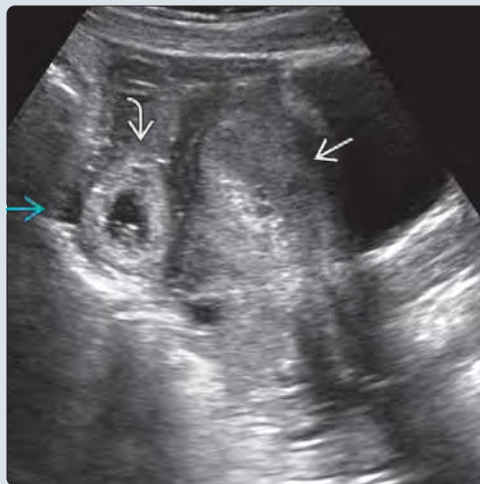
- May be incidental finding on early 1st-trimester scan






- 90% of all EPs are tubal
- Recurrent EP in 10-25%
- EP fatality rates have ↓ from 3.5 to 0.5:1,000
 - Earlier diagnosis
- Overall trend is toward less invasive treatment
 - Medical management with systemic methotrexate (MTX)
 - Success rate of methotrexate 88-93%
 - Surgical management
 - Laparoscopy rather than laparotomy
 - Salpingostomy preferred if nonruptured, salpingectomy required for rupture
 - Expectant management in carefully selected, clinically stable group

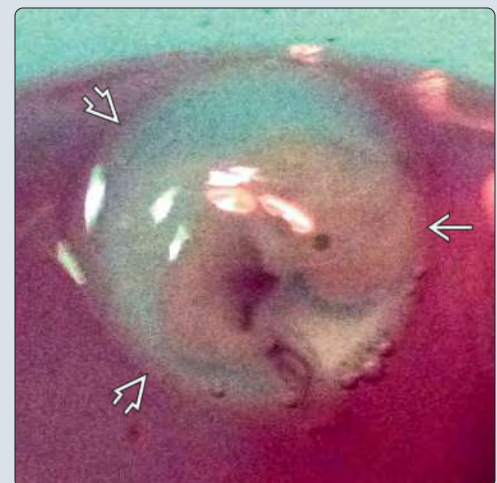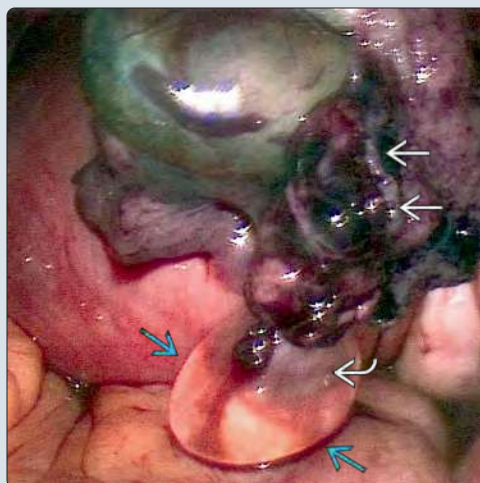DIAGNOSTIC CHECKLIST

- IUP is best negative predictor of EP
- If patient with pregnancy of unknown location is hemodynamically stable, do not use single hCG level as basis to treat for EP

(Left) TAUS shows an echogenic tubal ring  adjacent to, but not in, the uterus . Note the free fluid  adjacent to the ectopic gestational sac. (Right) On closer inspection in the same patient, a live embryo is seen within the sac. Embryonic heart rate is rapid at 185 BPM. The patient was clinically stable but opted for surgical treatment due to the decreased success of medical therapy in the presence of a live embryo.



(Left) At laparoscopy, the fallopian tube  had ruptured and the intact amniotic sac  containing the embryo  literally fell into the cul-de-sac. (Right) Clinical photograph shows the embryo  inside the intact amniotic sac  after laparoscopic retrieval. The tubal damage was such that salpingectomy was required. (Courtesy J. Pittman, MD.)



TERMINOLOGY**Abbreviations**

- Ectopic pregnancy (EP)

Definitions

- Ectopic gestational sac (GS) developing in fallopian tube
 - Definite ectopic: Extrauterine GS with yolk sac ± embryo (± cardiac activity)
 - Probable ectopic: Heterogeneous adnexal mass or extrauterine sac-like structure

IMAGING**General Features**

- Best diagnostic clue
 - No intrauterine pregnancy (IUP) with tubal mass with echogenic cul-de-sac fluid (blood)
- Location
 - In adnexa but separate from ovary
- Morphology
 - Variable from adnexal mass (probable EP) to well-developed gestational sac with recognizable embryo (definite EP)
 - Live embryo visible in < 10% in modern series vs. up to 24% in series from 1990s

Ultrasonographic Findings

- **Uterine appearance is variable**
 - Endometrium thin, thick, or cystic
 - Intrauterine sac-like structure
 - Recommended terminology for any fluid collection in endometrial cavity if pregnancy test positive
 - Probable IUP defined as intrauterine echogenic sac-like structure
 - In EP, fluid collection is central in uterine cavity with "pointy" edges, due to blood accumulation
 - Heterotopic pregnancy: IUP with EP is rare
- **Adnexal findings are variable**
 - Adnexal mass seen in 94.4% of series published 2013
 - Nonspecific mass 54%
 - Echogenic tubal ring 24.7%
 - Mass with yolk sac but no embryonic heart beat 8.3%
 - Mass with live embryo 7.4%
 - Ring of fire in trophoblastic tissue with color Doppler
- Ovary evaluation: Identify corpus luteum (CL)
 - 85% of EPs on same side as CL; appearance variable
 - Hypoechoic or anechoic cyst
 - Echogenic ring (can mimic EP but intraovarian)
 - Complex cyst from hemorrhage
 - Color Doppler: CL ring of fire is in ovary (tubal ring is separate from ovary)
 - Low-velocity, low-resistance flow
- Blood in cul-de-sac is important: May be only finding
 - May need ↑ gain settings to see echoes
 - Normal physiologic fluid is anechoic
 - Clotted blood is mass-like and complex
 - Obscure interfaces; can be very confusing
 - Check for blood in hepatorenal fossa and subphrenic space
 - Can have blood without tube rupture

- EP may present as pregnancy of unknown location (PUL)
 - Positive pregnancy test with no signs of IUP or EP

Imaging Recommendations

- Best imaging tool
 - TVUS with color Doppler
- Protocol advice
 - Use endovaginal probe as palpation tool
 - EP moves independent of ovary, CL moves with ovary
 - Human chorionic gonadotropin levels (hCG) can be helpful, although discriminatory hCG no longer used
 - 50% of EPs demonstrate rising hCG (usually slower than with IUP)
 - 50% of EPs demonstrate falling hCG
 - Lack of IUP at low hCG levels does **not** rule out EP
 - No cutoff level of hCG to predict tubal rupture
 - 9.7% patients with hCG < 500 mIU/mL had ruptured fallopian tubes at surgery in 1 series
 - Correlation with serum progesterone levels helps predict normal IUP vs. EP/failing IUP
 - Cannot differentiate EP from failed IUP

DIFFERENTIAL DIAGNOSIS**Incidental Adnexal Mass**

- Ovarian CL may mimic EP
 - May show ring of fire, which is within ovary
 - Look for crescent of normal ovarian tissue (claw sign) around cyst
- Paraovarian cyst is unilocular, anechoic, thin walled
- Incidental ovarian mass
 - Teratoma, cystadenoma
 - Tumor with low malignant potential, malignant neoplasm

Interstitial Ectopic

- Pregnancy in interstitial (cornual) portion of tube can mimic adnexal mass
- Incomplete myometrial coverage: Sac within 5 mm of uterine serosa
- Tend to rupture later than tubal EP, may cause massive intraperitoneal hemorrhage

Ovarian Ectopic

- EP implanted on or in ovary
- Look for yolk sac/embryo

PATHOLOGY**General Features**

- Etiology
 - Damage to fallopian tubes
 - Abnormal blastocyst implantation in tube

CLINICAL ISSUES**Presentation**

- Most common signs/symptoms
 - 1st-trimester pain/bleeding (nonspecific)
- Other signs/symptoms
 - Palpable adnexal mass
 - Cardiovascular shock
- May be incidental finding on early 1st-trimester scan

Demographics

- Age
 - ↑ incidence in 35-40 year olds
- Epidemiology
 - 1.5-2.0% of all pregnancies are EP
 - 90% of all EPs are tubal
 - 1.6% of fertility patient pregnancies were EP in 2011 series
 - Risk increased with multiple embryo transfers
 - 25-50% of pregnancies in patients with IUD or tubal ligation are EP

Natural History & Prognosis

- EP fatality rates have ↓ from 3.5 to 0.5:1,000
 - Delayed diagnosis → morbidity and death
- Prognosis for future pregnancies
 - Recurrent EP in 10-25%
 - Future IUP in 64-71% in DEMETER trial
 - No significant difference in subsequent fertility related to management
- EP may spontaneously resolve

Treatment

- Overall trend is toward less invasive treatment
 - UK 2000: 35% laparoscopy, 63% laparotomy, 1% medical management
 - UK 2014 survey of early pregnancy units: 57% laparoscopy, 5% laparotomy, 31% medical, 6% conservative
- Medical management with systemic methotrexate (MTX)
 - Patient must be hemodynamically stable
 - Ultrasound criteria
 - EP < 3.5-4.0 cm
 - Little or no peritoneal fluid
 - Living embryo is not absolute contraindication
 - Single-dose treatment regimen used more often than multidose
 - Success rate
 - 88% for single-dose regimen, 93% for multidose regimen
 - Factors associated with failed treatment
 - hCG > 5,000 mIU/mL
 - hCG rising > 50% in 48 hours
 - Living embryo
 - Moderate or large amount of peritoneal fluid
 - Ultrasound during/after treatment often confusing
 - ↑ hemorrhage around EP, ↑ size of EP
- Ultrasound-guided local injection of EP with MTX or potassium chloride (KCl)
 - With live embryo
 - 93.3% successful treatment with combined US-guided local injection with systemic MTX
 - 73.0% successful treatment with systemic MTX alone
- Surgical management
 - Salpingotomy for nonruptured EP
 - Small lengthwise incision in tube with removal of EP
 - Salpingectomy is only choice for ruptured EP
 - Segment of tube removed, ends reconnected if technically feasible
- Expectant management

- Selection criteria for expectant management in series with 71.2% success rate
 - Clinical stability with no/minimal abdominal pain
 - No evidence of significant hemoperitoneum
 - EP < 30 mm mean diameter, no embryonic cardiac activity
 - hCG < 1500 IU/L (likely selects tubal miscarriages with degenerating trophoblast)
- Authors note that ~ 33% of all tubal ectopics could be managed expectantly with cost savings and decreased risk of side effects
- Expectant management discontinued/surgery advised if hCG level shows sustained rise or increases to ≥ 2,000 IU/L
- Outpatient protocol
 - Patient must avoid travel, sexual intercourse, return to the clinic if increased pain
 - Serial hCG measured until level declines to < 20 IU/L or urine pregnancy test becomes negative

DIAGNOSTIC CHECKLIST

Image Interpretation Pearls

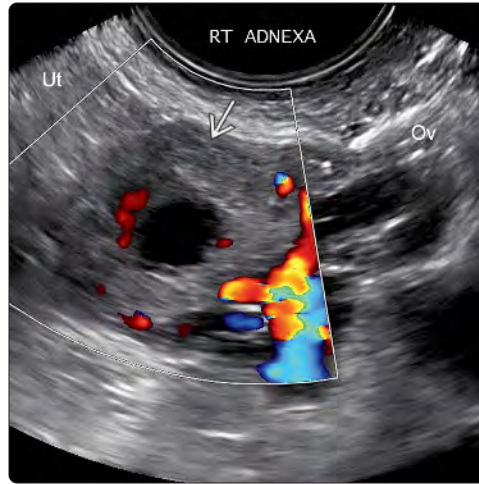
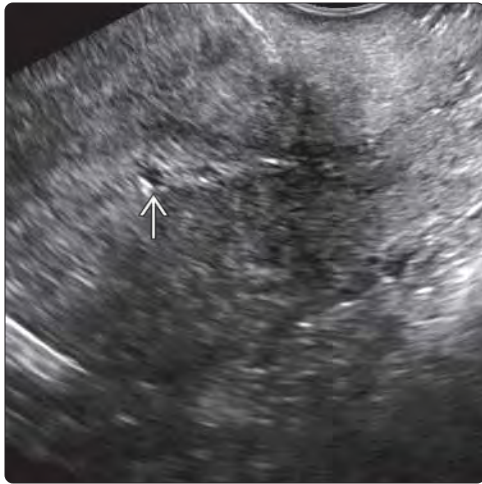
- Do not base decision to scan on serum β-hCG levels
 - May see EP with low levels, may see other causes of pain/bleeding
- Avoid decisions based on single piece of information
 - If patient with PUL is hemodynamically stable, do not use single hCG level as basis to treat for EP
 - Highest hCG level associated with subsequent IUP was 9,083 mIU/mL in patient with triplet pregnancy
- Presence of IUP is best negative predictor of EP
- Look for ring of fire in adnexa with color Doppler
 - May detect small EP when grayscale findings are negative
- PUL and blood in cul-de-sac has high risk of having EP
- Beware of corpus luteum
 - Find CL, since EP is often on same side
 - Look carefully at adnexal cyst
 - EP may have yolk sac or embryo
 - Hemorrhagic CL may be cause of pain

Reporting Tips

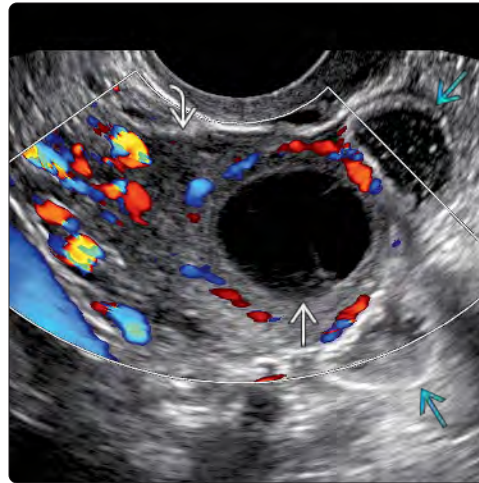
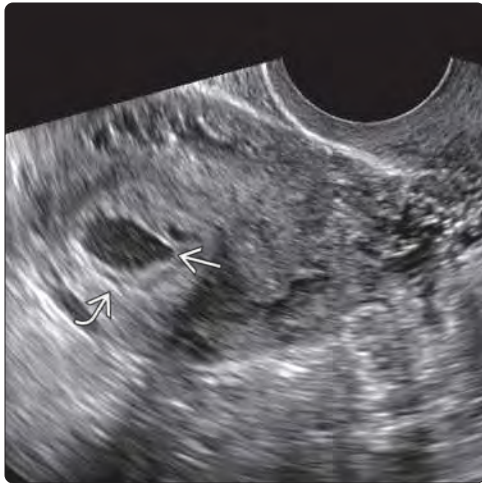- PUL in stable or asymptomatic patients requires close follow-up
 - Must state clearly that ectopic gestation has **not** been excluded

SELECTED REFERENCES

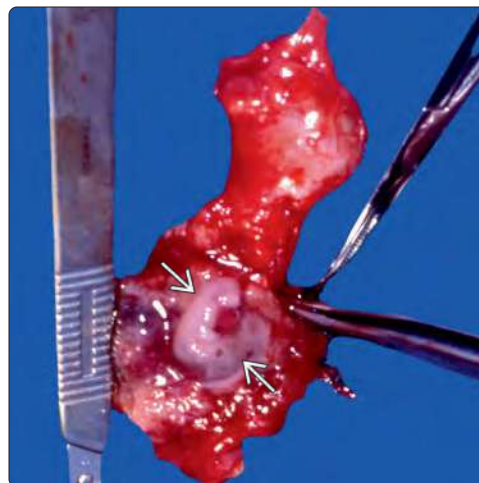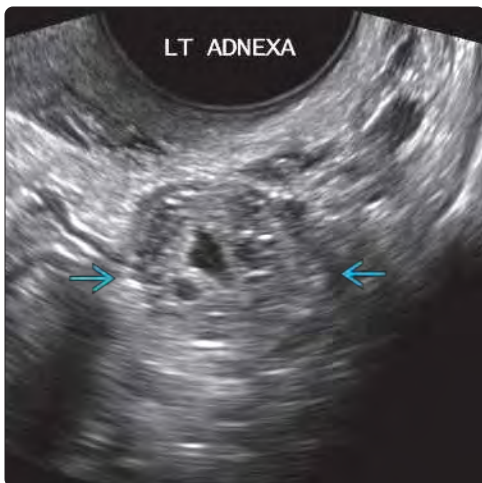
1. Frates MC et al: Adnexal sonographic findings in ectopic pregnancy and their correlation with tubal rupture and human chorionic gonadotropin levels. *J Ultrasound Med.* 33(4):697-703, 2014
2. Ko JK et al: Time to revisit the human chorionic gonadotropin discriminatory level in the management of pregnancy of unknown location. *J Ultrasound Med.* 33(3):465-71, 2014
3. Taheri M et al: A United Kingdom national survey of trends in ectopic pregnancy management. *J Obstet Gynaecol.* 34(6):508-11, 2014
4. Wang M et al: Nonsurgical management of live tubal ectopic pregnancy by ultrasound-guided local injection and systemic methotrexate. *J Minim Invasive Gynecol.* 21(4):642-9, 2014
5. Benson CB et al: Intrauterine fluid with ectopic pregnancy: a reappraisal. *J Ultrasound Med.* 32(3):389-93, 2013
6. Rodrigues SP et al: Ectopic pregnancy: when is expectant management safe? *Gynecol Surg.* 9(4):421-426, 2012





(Left) TVUS shows a tiny, but round, cystic structure in an otherwise empty uterus. This type of intrauterine sac-like structure is considered statistically to be most likely an IUP; however, careful evaluation of the adnexa is mandatory in every pelvic scan. (Right) TVUS in the same patient shows an adnexal mass without a yolk sac or embryo (i.e., "probable ectopic") situated between the uterus (Ut) and the left ovary (Ov). The patient declined medical management. This was a surgically proven, unruptured left tubal ectopic.

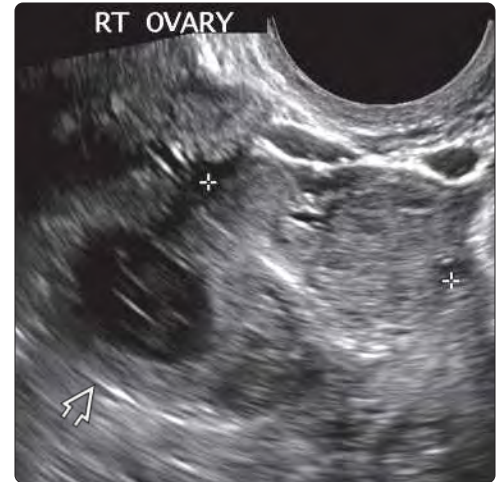
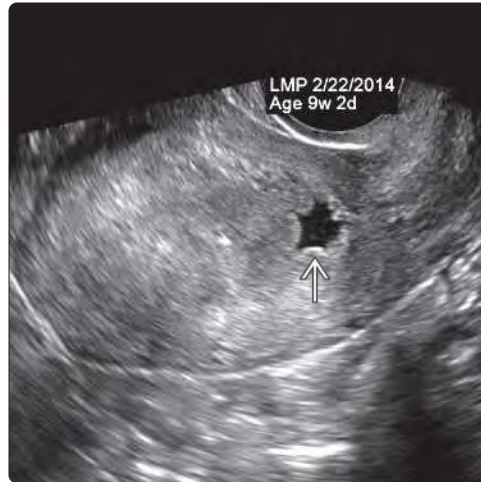





(Left) TVUS shows an intrauterine sac-like structure with 1 pointed edge. It is situated centrally in the uterus but has an appearance suggestive of the double decidual sac sign. Cases often have overlapping findings. (Right) TVUS in the same patient shows a hemorrhagic corpus luteum in the left ovary with adjacent bowel loops. Ectopic pregnancies can be very difficult to find, and this case could have been categorized as a probable IUP without a more complete evaluation.

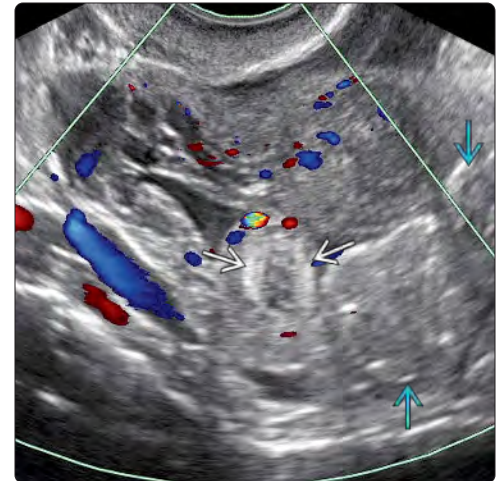
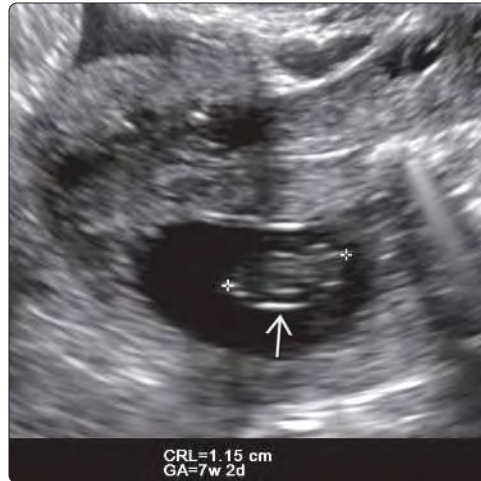






(Left) TVUS in the same patient shows a heterogeneous left adnexal mass separate from the ovary. Thus, this is now better characterized as a probable ectopic pregnancy. Repeat scans showed increased size of the mass and changed shape of the intrauterine fluid. Left tubal ectopic was confirmed laparoscopically. (Right) In this case of ruptured tubal ectopic pregnancy, an embryo is seen within the tubal specimen from a salpingectomy.

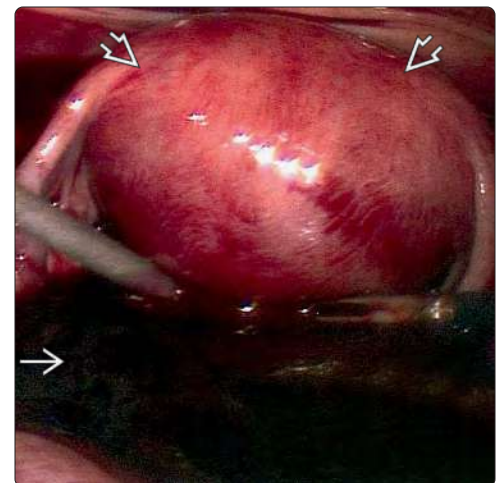
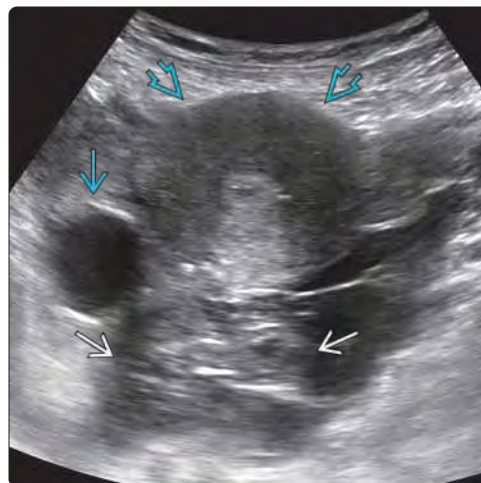
(Left) TVUS shows an irregular fluid collection  low in the uterus. This sac-like structure is much smaller than would be expected for dates. The pointed edges and low position are concerning findings making it unlikely to represent an IUP. (Right) TVUS in the same patient shows an adnexal ring representing a tubal ectopic pregnancy  adjacent to the ovary (calipers). Color Doppler (not shown) showed increased flow (ring of fire).

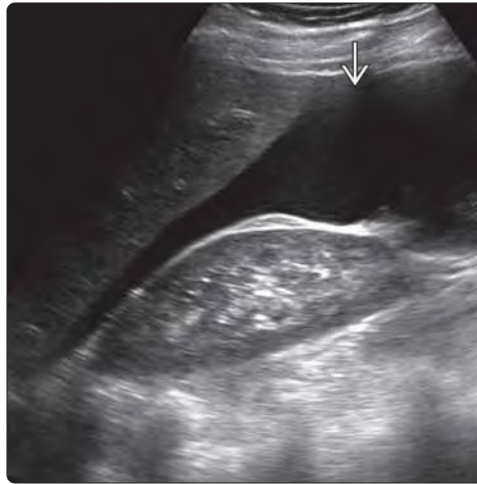
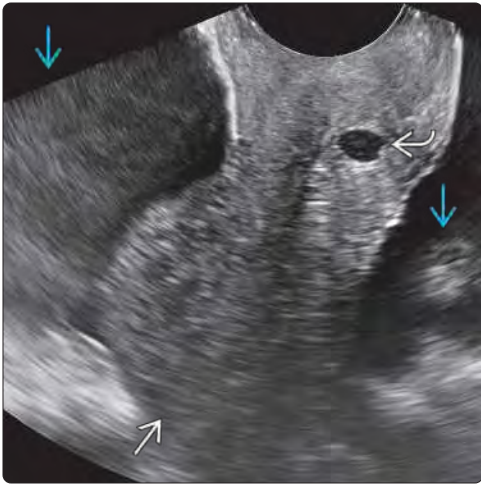


(Left) TVUS interrogation of the adnexal mass shows a well-developed embryo (calipers) with visible surrounding amnion  inside the extrauterine gestational sac. The appropriate terminology in this case is definite ectopic pregnancy. (Right) TVUS shows the utility of using color Doppler to help with evaluation of the adnexa. Flow around the adnexal ring  makes it easier to separate from adjacent bowel loops .

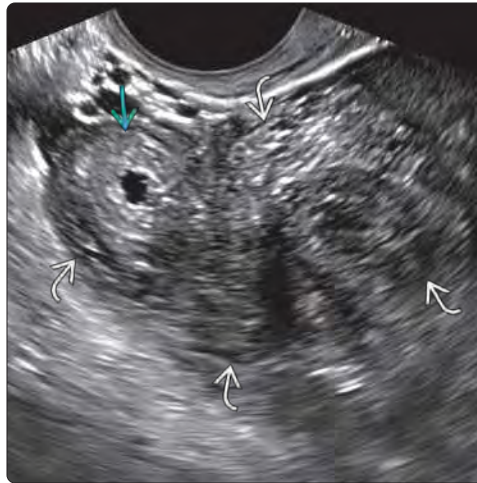
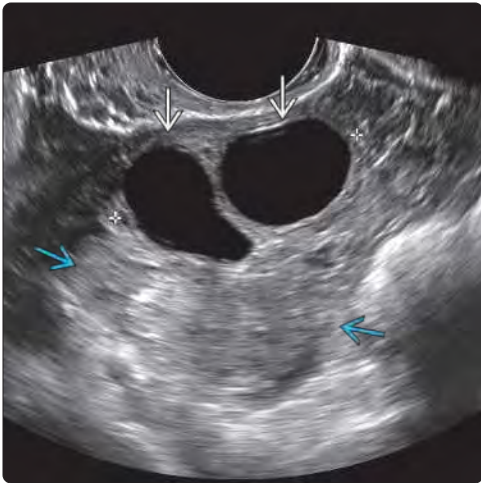


(Left) TAUS shows an homogeneous mass of echogenic clot in the cul-de-sac . The cystic structure on the right is the corpus luteum . The uterus  was empty. These findings can be categorized as a probable ectopic. A heterogeneous mass is the commonest sonographic finding in a tubal ectopic pregnancy. (Right) Laparoscopic image from the same patient confirms a substantial amount of blood  posterior to the uterus  in this patient with a ruptured right tubal ectopic.

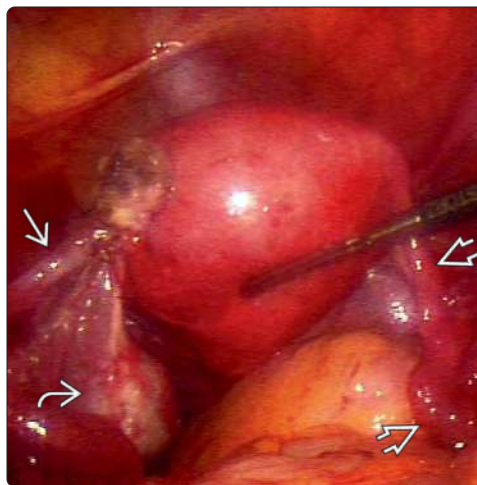
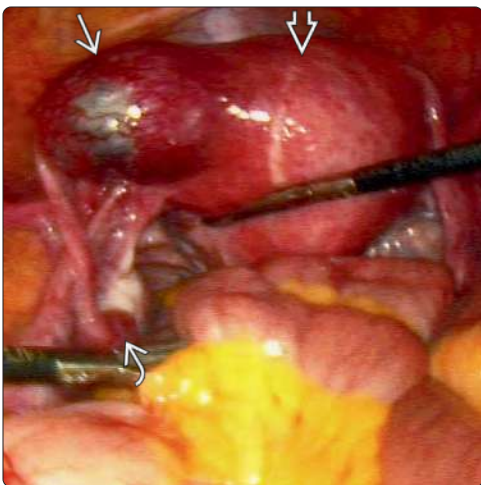




(Left) TVUS shows a large amount of echogenic fluid surrounding an empty uterus. The anterior component should not be mistaken for the bladder as it is not surrounded by a muscular wall. There is an incidental nabothian cyst. (Right) TAUS in the same patient confirms a large amount of intraperitoneal hemorrhage with fluid in the hepatorenal fossa. This was a ruptured ectopic. The patient was hemodynamically stable at the time of the study but is at risk for acute circulatory collapse.



(Left) TVUS shows a potential source of confusion. As a result of ovulation induction, the ovary (calipers) is enlarged with several large follicles. Clotted blood may be seen in the cul-de-sac as a result of egg retrieval, but a more complete evaluation is needed. (Right) Another image in the same patient shows an ectopic gestational sac. There is an echogenic adnexal ring surrounded by clotted blood. The presence of the clot makes the ectopic more difficult to see. These cases are often difficult and require meticulous scanning.



(Left) Laparoscopic image shows the distended, unruptured tube with the ectopic gestation implanted close to the interstitial portion of the tube. The uterine fundus and fimbrial end of the tube are also shown. (Courtesy J. Pittman, MD.) (Right) Intraoperative photograph after salpingectomy shows the ipsilateral round ligament and ovary and the normal contralateral tube. (Courtesy J. Pittman, MD.)

Interstitial Ectopic

KEY FACTS

TERMINOLOGY

- Blastocyst implants in interstitial portion of fallopian tube

IMAGING

- Pregnancy or ectopic pregnancy or sac eccentrically located with respect to endometrial cavity
- Interstitial line sign
 - Echogenic line from endometrium to ectopic sac
 - Reported sensitivity of 80% and specificity of 98%
- < 5 mm of surrounding myometrium very suggestive
- 3D ultrasound shown to improve diagnosis
- Covered by myometrium so can grow to larger size than tubal ectopic
- Early interstitial pregnancy often difficult to diagnose

TOP DIFFERENTIAL DIAGNOSES

- Angular pregnancy
 - Pregnancy implanted at lateral angle of uterine cavity medial to uterotubal junction

- Should always have normal myometrial coverage
- Requires close follow-up to document gestational sac growing into uterine cavity

- Septate uterus most likely congenital anomaly to cause confusion with interstitial ectopic

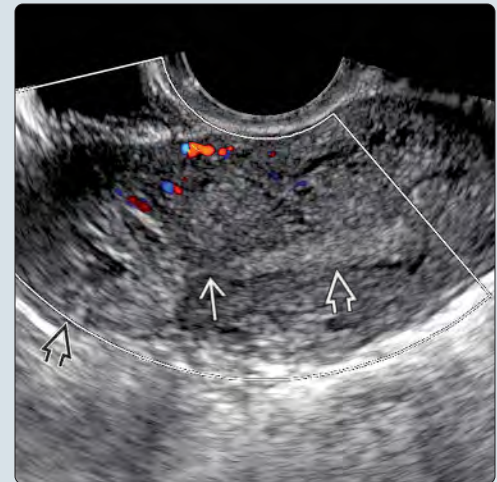
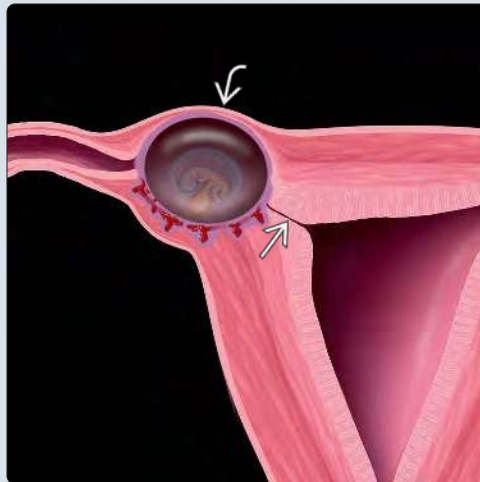
CLINICAL ISSUES

- 2-4% of ectopic pregnancies are interstitial
- Significantly greater morbidity and mortality than tubal ectopic
- No standardized treatment but general migration to more conservative therapy

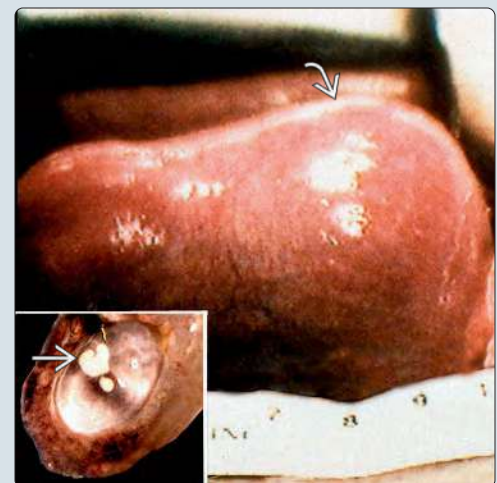
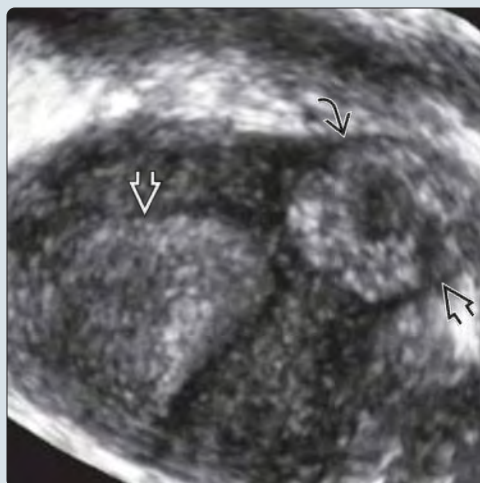DIAGNOSTIC CHECKLIST

- Despite technical advances, diagnosis of interstitial ectopic pregnancy remains difficult
 - Must have high degree of suspicion, especially in high-risk patient
- Short-term follow-up for any sac that appears high and eccentric

(Left) Coronal graphic shows an interstitial ectopic pregnancy. It distorts the cornual contour of the uterus with bulging and thinning of the overlying myometrium. The coapted margins of the interstitial portion of the tube create the interstitial line sign. (Right) TVUS shows an interstitial ectopic pregnancy, with no clear myometrial covering. An interstitial line sign can be seen connecting the empty endometrial cavity to the sac.



(Left) 3D ultrasound shows an interstitial ectopic pregnancy clearly separate from the endometrial cavity. Note the claw of myometrium, which becomes imperceptibly thin along the fundal border of the sac. Rupture can lead to catastrophic bleeding. (Right) Intraoperative photograph shows the bulging, thinned myometrium at the site of the interstitial ectopic. The gestational sac was resected (inset) and has a clearly defined embryo and adjacent yolk sac.



TERMINOLOGY

Definitions

- Terminology in literature is confusing and inconsistently applied
- **Interstitial ectopic pregnancy is preferred term**
 - Blastocyst implants in interstitial portion of fallopian tube
- **Intramural ectopic pregnancy**
 - Descriptively correct as interstitial portion of fallopian tube does transverse uterine wall but not technically accurate as blastocyst implants in tube not myometrium
- **Angular pregnancy**
 - Pregnancy implanted at lateral angle of uterine cavity medial to uterotubal junction
 - Located medial to round ligament
- **Cornual pregnancy** often used interchangeably with interstitial ectopic, but there is great ambiguity
 - Some authors use term for any pregnancy in cornual region, which overlaps with angular pregnancy
 - Others use cornual to refer to pregnancy in 1 horn of duplication anomaly (septate or bicornuate uterus)
 - Recent literature recommends this term be dropped

IMAGING

General Features

- Best diagnostic clue
 - Combination of findings
 - Interstitial line sign: Echogenic line from endometrium to ectopic sac
 - Myometrium thinned to < 5 mm
- Location
 - Interstitial (intramural) portion of fallopian tube
 - Connects uterine cavity to isthmus (extrauterine portion of tube)
 - 1-2 cm in length, 1 mm in diameter
- Size
 - Covered by myometrium so can grow to larger size than tubal ectopics

Ultrasonographic Findings

- Gestational sac located high in fundus
 - Eccentrically located with respect to endometrial cavity
 - Sac seen separately > 1 cm from endometrial cavity
- Appearance of sac contents quite variable
 - Gestational sac ± yolk sac, embryo
 - Gestational sac and embryo can be quite large
 - May appear as echogenic mass within cornua
 - Combination of trophoblastic tissue, hematoma
 - No definable sac
- Thinned myometrium
 - < 5 mm of surrounding myometrium very suggestive
 - May have areas where no definable myometrium is seen
 - Normal myometrium may be seen early and does not exclude an interstitial ectopic
 - Early interstitial pregnancy often difficult to diagnose
 - 42% of cases missed in 1 large series
- Interstitial line sign has reported sensitivity of 80% and specificity of 98%

- Echogenic line can be followed from endometrium to ectopic sac
 - More difficult to see as gestational sac enlarges
- Best evaluated in transverse plane near fundus of uterus
- Myometrial mantle sign
 - Myometrium surrounds sac in all planes
 - Becomes incomplete as sac enlarges
- 3D ultrasound shown to improve diagnosis
 - Improved spatial orientation of ectopic in relation to uterine cavity
- Doppler findings
 - Trophoblastic tissue is highly vascular
 - Marked flow identified on color and power Doppler
 - Pulsed Doppler shows high-velocity, low-resistance waveform
 - May see prominent arcuate vessels in outer 1/3 of myometrium

MR Findings

- Generally avoided in 1st trimester unless clinical situation warrants
- Has been shown accurate in diagnosis
 - Eccentric sac separated from endometrium by junctional zone
- Generally not necessary
- Consider when ultrasound findings are equivocal or preoperative planning for large ectopics

Imaging Recommendations

- Always document location of sac with respect to endometrium in both transverse and longitudinal views
- 3D ultrasound should be performed in every case of questionable implantation site
- Measure surrounding myometrium if it appears thin
 - < 5 mm more likely to be interstitial ectopic
- Look for echogenic line leading to myometrium (interstitial line sign)
- If unclear, short-term follow-up with careful instructions to patient to return immediately if symptoms occur
- Consider MR for further characterization

DIFFERENTIAL DIAGNOSIS

Angular Pregnancy

- Pregnancy implanted at lateral angle of uterine cavity medial to uterotubal junction
- On spectrum between normal, centrally located intrauterine pregnancy and interstitial ectopic
 - Use 3D ultrasound to document location of sac as precisely as possible
 - Requires close follow-up to document gestational sac growing into uterine cavity
- Should always have normal myometrial coverage
- Most result in live birth but has increased complication rate
 - Spontaneous abortion (38.5%) and uterine rupture (13.6%) reported; however, true complication rate not known as cases reported as angular may have actually been interstitial

Pregnancy in Uterine Duplication

- Septate uterus most likely congenital anomaly to cause confusion with interstitial ectopic

- Implantation within 1 horn gives eccentric appearance
- May give false appearance of interstitial line sign
- 3D ultrasound helpful to show 2 uterine cavities

Tubal Ectopic Pregnancy

- Can occasionally be confusing if adjacent to cornua of uterus
- Use ultrasound probe to gently separate structures

PATHOLOGY

General Features

- Etiology
 - Risk factors
 - History of prior tubal surgery, especially salpingectomy
 - Prior ectopic pregnancy
 - Assisted reproductive technology (ART) pregnancies
 - May see heterotopic pregnancy with ART with 1 sac in interstitial portion of tube
 - Intrauterine contraceptive devices (IUD) are not associated with interstitial ectopics
 - Ectopic pregnancies more likely to be in tube when IUD present

Microscopic Features

- Interstitial portion of tube composed of multiple layers
 - Endosalpinx (mucosa)
 - Myosalpinx
 - 3 layers of muscle
 - Highly vascularized
 - Serosa is directly contiguous with peritoneum

CLINICAL ISSUES

Presentation

- Most common signs/symptoms
 - Pelvic/abdominal pain
 - Vaginal bleeding
- Other signs/symptoms
 - Hypotension and shock if presenting with rupture
- May be incidental finding on routine 1st-trimester scan
 - Easy to miss on early scan

Demographics

- Epidemiology
 - 2-4% of ectopic pregnancies are interstitial
 - Mortality rate 2.0-2.5%, ~ 15x tubal ectopic rate

Natural History & Prognosis

- Significantly greater morbidity and mortality than for tubal ectopics
 - Surrounding myometrium is distensible, allowing for greater gestational sac size
 - Uterine rupture most commonly occurs at 9-12 weeks
 - Reported as late as 16 weeks
 - Potential exsanguination
 - Large accurate vessels run in outer 1/3 of myometrium
- Good outcome, with preserved future fertility, with appropriate treatment

Treatment

- No standardized treatment but general migration to more conservative therapy
 - Depends on size of sac and patient symptoms
- Expectant management
 - Considered only if small sac and no living embryo
- Systemic methotrexate most common therapy
 - Multiple dosing regimens described
 - Some include uterine artery injection
 - Follow hCG after initial dose
 - Treatment failure in 10-20%
 - Failed treatment goes to surgery
- Sac injection
 - Generally with methotrexate
 - Via laparoscopy or ultrasound guidance
 - Potassium chloride, etoposide also used
 - Most commonly used in setting of heterotopic pregnancy to preserve intrauterine pregnancy
- Cornuostomy with sac excision
 - May be done with laparoscopy or laparotomy
- Rupture may require hysterectomy
 - May consider uterine artery embolization prior to surgery

DIAGNOSTIC CHECKLIST

Consider

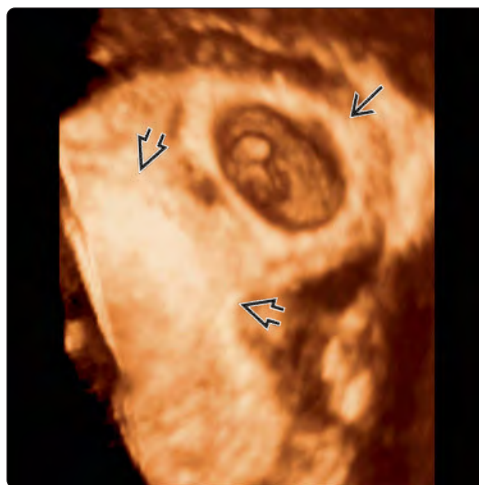
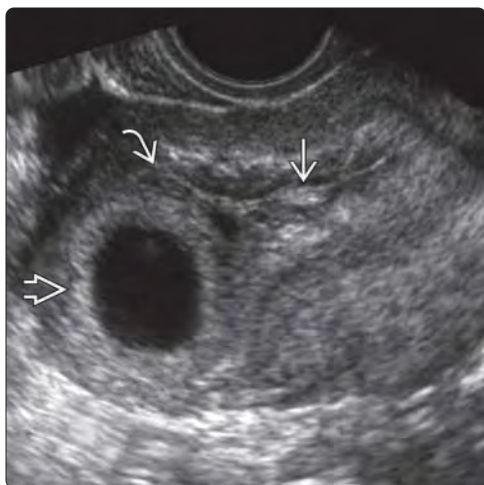
- 3D ultrasound for improved spatial orientation of sac to endometrial cavity

Image Interpretation Pearls

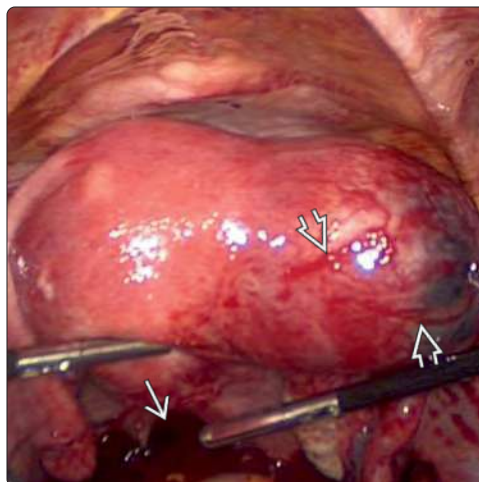
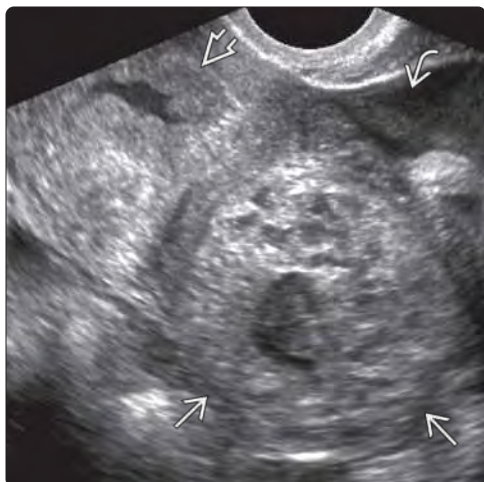- Despite technical advances, diagnosis of interstitial ectopic pregnancy remains difficult
 - Must have high degree of suspicion, especially in high-risk patient
 - Short-term follow-up for any sac that appears high and eccentric

SELECTED REFERENCES

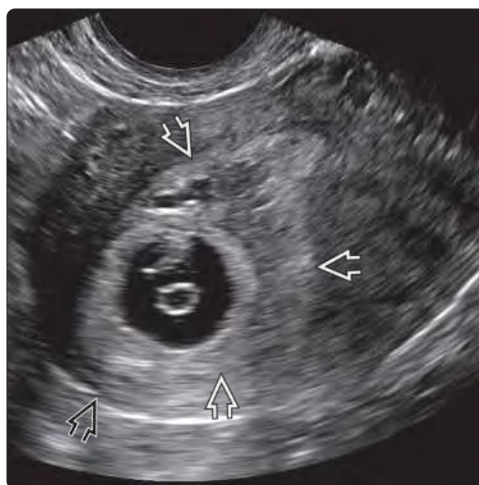
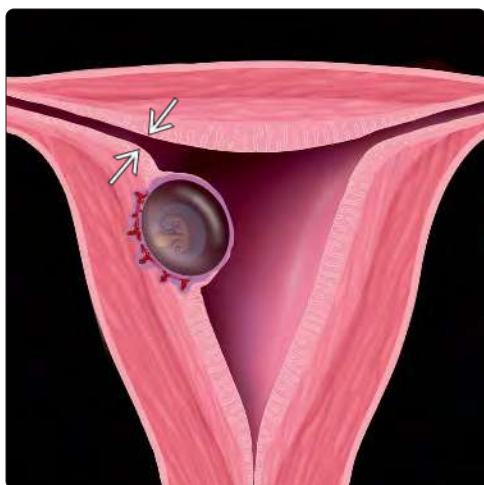1. Chukus A et al: Uncommon implantation sites of ectopic pregnancy: thinking beyond the complex adnexal mass. *Radiographics*. 35(3):946-59, 2015
2. Tanaka K et al: Management of interstitial ectopic pregnancy with intravenous methotrexate: An extended study of a standardised regimen. *Aust N Z J Obstet Gynaecol*. 55(2):176-80, 2015
3. Arleo EK et al: Cornual, interstitial, and angular pregnancies: clarifying the terms and a review of the literature. *Clin Imaging*. 38(6):763-70, 2014
4. Hirsch L et al: Effectiveness of medical treatment with methotrexate for interstitial pregnancy. *Aust N Z J Obstet Gynaecol*. 54(6):576-80, 2014
5. Nezhad CH et al: Laparoscopically-assisted, hysteroscopic removal of an interstitial pregnancy with a fertility-preserving technique. *J Minim Invasive Gynecol*. 21(6):1091-4, 2014
6. Tanaka Y et al: Three-dimensional sonography in the differential diagnosis of interstitial, angular, and intrauterine pregnancies in a septate uterus. *J Ultrasound Med*. 33(11):2031-5, 2014
7. Sagiv R et al: Interstitial pregnancy management and subsequent pregnancy outcome. *Acta Obstet Gynecol Scand*. 92(11):1327-30, 2013
8. Cucinella G et al: Laparoscopic management of interstitial pregnancy: the "purse-string" technique. *Acta Obstet Gynecol Scand*. 91(8):996-9, 2012
9. Tamarit G et al: Combined use of uterine artery embolization and local methotrexate injection in interstitial ectopic pregnancies with poor prognosis. *Fertil Steril*. 93(4):1348, 2010
10. Moon HS et al: The outcomes of pregnancy following laparoscopic cornuotomy for interstitial pregnancy. *Fertil Steril*. 92(2):e24; author reply e25, 2009
11. Lin EP et al: Diagnostic clues to ectopic pregnancy. *Radiographics*. 28(6):1661-71, 2008



(Left) Transverse TVUS shows an interstitial line sign extending from the empty endometrial cavity to the interstitial ectopic gestational sac. (Right) 3D ultrasound of an interstitial ectopic pregnancy with an embryo shows the sac is clearly separate from the distorted endometrial cavity. 3D ultrasound is very helpful for more precisely identifying the location of the sac and should be performed in every case of questionable sac implantation.



(Left) Ultrasound of a large interstitial ectopic pregnancy shows a heterogeneous mass in the fundal region of the uterus. Complex fluid (blood) is present in the endometrial cavity and cul-de-sac. (Right) Intraoperative photograph in the same case shows distortion of the uterine contour with multiple oozing blood vessels on the serosal surface and blood in the cul-de-sac. Because an interstitial ectopic is covered by myometrium, it can grow to a larger size and present later than a tubal ectopic.



(Left) Graphic shows an angular pregnancy implanted at the lateral angle of the uterus, medial to the uterotubal junction. (Right) Oblique coronal ultrasound of the endometrial cavity shows a high lateral implantation of the gestational sac. The surrounding myometrium measured 7 mm. This is the typical appearance of an angular pregnancy. Close interval follow-up should be done if there is any question regarding the diagnosis.

KEY FACTS

TERMINOLOGY

- Implantation of gestational sac within cervical stroma

IMAGING

- Gestational sac within cervical stroma ± live embryo
 - Gestational sac usually round/elliptical
 - Circumferential echogenic chorionic ring
 - Marked peritrophoblastic flow around sac
 - Endocervical canal visualized separately, adjacent to sac
- Hourglass-shaped uterus
 - Secondary to cervical distention from pregnancy, with "waist" due to closed internal os
 - Bladder neck in sagittal plane is anatomic landmark for internal os

TOP DIFFERENTIAL DIAGNOSES

- Normal pregnancy with low uterine implantation
- Spontaneous abortion
 - Irregular, deformed, flattened sac in cervical canal

- Never live embryo
- C-section scar ectopic pregnancy

PATHOLOGY





- Prior instrumentation key risk factor
 - Endometrium is injured, adversely impacting implantation of pregnancy

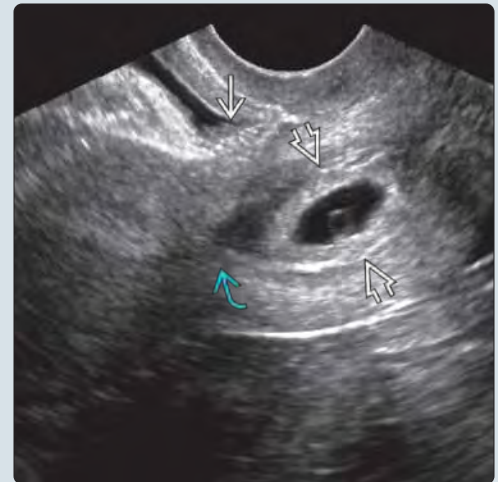
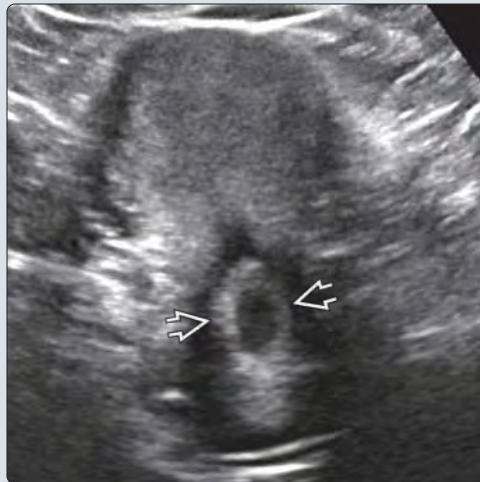
CLINICAL ISSUES




- Bleeding can be significant due to local vascularity
- Often larger and presents later than tubal ectopic
- Conservative management advisable if possible
 - Aim to preserve fertility
- Avoid isolated curettage as uncontrolled bleeding possible

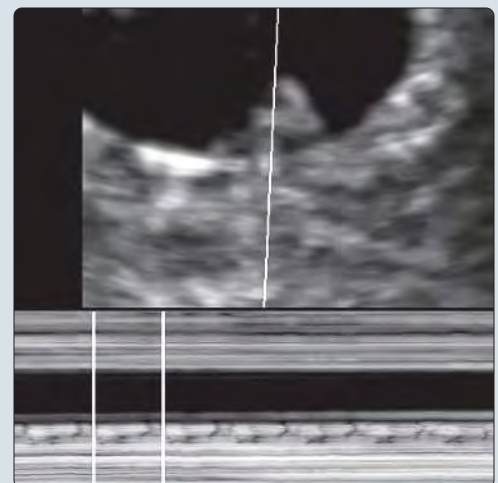
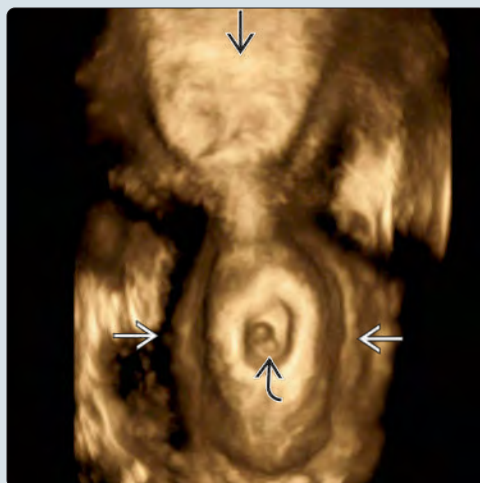DIAGNOSTIC CHECKLIST

- Always consider if gestational sac has low implantation
- Transvaginal US should always be performed to evaluate location and contents of sac

(Left) Transabdominal US (TAUS) for viability shows a low-lying gestational sac with surrounding echogenic chorionic ring . **(Right)** Detailed transvaginal imaging in the same case identified the classic features of cervical ectopic pregnancy. The internal os  is closed. The bladder neck  is a landmark for the level of the internal os. The oval gestational sac , which contains a yolk sac, is clearly implanted in the cervix, not the uterine cavity.



(Left) 3D reconstructions can help to visualize the hourglass shape typically seen with cervical ectopic pregnancy. The uterine cavity  is empty and the gestational sac expands the cervix . In this case, the yolk sac and amnion are also visible . **(Right)** M-mode US confirms the presence of a live embryo. This observation excludes miscarriage from the differential diagnosis.



TERMINOLOGY

Definitions

- Implantation of gestational sac within cervical stroma

IMAGING

General Features

- Best diagnostic clue
 - Gestational sac within cervical stroma ± live embryo
- Morphology
 - Gestational sac usually round/elliptical
 - Similar appearance to normal pregnancy
 - Usually circumferential, echogenic chorionic ring

Ultrasonographic Findings

- Grayscale ultrasound
 - Eccentric sac within cervical stroma
 - Endocervical canal visualized separately, adjacent to sac
 - Hourglass-shaped uterus
 - Secondary to cervical distention from pregnancy
 - "Waist" due to closed internal os
 - Bladder neck in sagittal plane is anatomic landmark for internal os
 - Embryo with heartbeat often present
 - Thick, echogenic, decidualized endometrium
- Color Doppler
 - Marked peritrophoblastic flow around sac embedded in cervical stroma
 - Mild vascularity in isolation can be deceiving without other signs of cervical ectopic
 - Early demise can also have some persistent minimally vascularized tissue
- 3D
 - Best demonstrates hourglass contour of uterus

Imaging Recommendations

- Transabdominal US aids in identifying anatomic landmarks
 - Uterine shape
 - Uterine position
 - Internal os
 - Bladder and bladder wall
- Transvaginal US used to characterize early gestational sac
 - Aids in evaluating uterine cavity
 - Differentiate from abortion in progress
 - Sac should be more flattened in appearance
 - Never live embryo
 - Exclude rare heterotopic pregnancy
 - Especially in setting of assisted reproductive technology or hormonal stimulation
- US localization for medical treatment
 - Used for guidance of needle into sac for injection

DIFFERENTIAL DIAGNOSIS

Normal Pregnancy With Low Uterine Implantation

- Sac will be above internal os
- Eccentric location in uterine cavity

Spontaneous Abortion

- Sac is not normal in appearance

- Irregular, flattened
- Centered in cervical canal
- Mobile with gentle pressure (sliding sign)
 - Use transvaginal probe to visualize
 - Bimanual exam with probe can help elicit
- Lacks surrounding echogenic ring
- May see spontaneous movement of sac through endocervical canal
 - Repeat scan in a few hours
 - May show complete passage
- No embryo/fetal heart beat
- Typical hourglass shape of cervical ectopic not present
- Internal os open
 - External os may or may not be open at time of clinical exam
 - Diagnosis may not be obvious on clinical speculum exam if external os closed
- Correlate with serial hCG and follow-up US if diagnosis uncertain
 - hCG should be decreasing with miscarriage
 - US will show progression of sac toward external os or verify expulsion

Cesarean Section Scar Ectopic Pregnancy

- Can be difficult to distinguish from cervical ectopic if located in anterior lip of cervix
- Should be above internal os
- Correlate with history of C-section(s)
- Look for thinned or absent myometrium at scar
- Medical treatment is similar to cervical ectopic
 - Helpful to distinguish if surgery planned

Nabothian Cyst

- Obstructed mucus-secreting endocervical glands
 - Thought to result from prior inflammation
- Asymptomatic, incidentally noted on pelvic US
- Anechoic or low-level echoes
- No surrounding increased vascularity on Doppler evaluation

Cervical Mass

- Cervical fibroid
 - Hypoechoic cervical mass
 - May see prolapse of pedunculated uterine fibroid
- Polyp
 - Either from cervix or prolapsed from endometrium
 - Solid lesion in cervical canal
 - Polyps may have cystic areas
 - May see feeding vessel with color Doppler US
- Cervical cancer
 - Irregular cervical mass

PATHOLOGY

General Features

- Etiology
 - Prior instrumentation key risk factor
 - Endometrium is injured
 - Adversely impacts implantation of pregnancy
 - Multiple etiologies of endometrial injury
 - Dilatation and curettage
 - In vitro fertilization with embryo transfer

- Fertilized ovum not released in endometrial cavity
- Travels with catheter tip out to cervix when catheter removed
- Subsequently implants in cervical stroma
- Previous cervical procedure
 - Loop electrosurgical excision procedure
 - Conization
 - Cryosurgery
- Prior C-section
- Previous uterine surgery
- Asherman syndrome

Gross Pathologic & Surgical Features

- Trophoblastic invasion into cervical stroma
- Insufficient vascularity within cervix to support gestation

Microscopic Features

- Cervical mucosa vulnerable to trophoblast proliferation
 - Allows deep penetration of chorionic villi

CLINICAL ISSUES

Presentation

- Most common signs/symptoms
 - Bleeding
 - Usually painless
- Other signs/symptoms
 - Abdominal/pelvic pain
 - Hypotension and shock if ruptured
 - Urinary problems
 - Distended cervix
 - External os dilation
- May be incidental finding on early viability scan
 - Often larger and presents later than tubal ectopic

Demographics

- Epidemiology
 - ~ 1% of ectopic pregnancies

Natural History & Prognosis

- Potentially fatal if unrecognized
 - May rupture; uncontrolled hemorrhage can result
- Good prognosis with appropriate treatment
- Preservation of fertility usually successful when treated conservatively

Treatment

- Medical management advisable if possible
 - Methotrexate
 - Injected into sac
 - Systemic administration
 - Potassium chloride injection into sac
 - May use combined approach of sac injection followed by systemic methotrexate
 - Close follow-up required to document regressing pregnancy
 - Follow-up US to show embryonic demise &/or sac involution; however, trophoblastic tissue can show delayed resorption despite adequate treatment
 - Serial hCGs should show declining levels
- Avoid isolated curettage as uncontrolled bleeding may occur

- Uterine artery embolization (UAE)
 - Can be used to attempt hemostasis if significant bleeding occurs
 - Often used in conjunction with methotrexate or potassium chloride for conservative management
 - Most studies show successful subsequent pregnancies possible
 - May require repeat embolization (delayed)
 - Occurs if uterine arteries recanalize or local collateral flow to cervix develops
 - Reported success with UAE, subsequent dilation and curettage
 - ± methotrexate
 - Rarely endometrial atrophy can result from UAE
 - 2-7% can have permanent amenorrhea
 - Questionable effects on future pregnancies
- If emergently bleeding, Foley balloon tamponade could be attempted or Shirodkar cerclage, intracervical vasopressin injection
- Other methods also reported
 - Curettage of pregnancy following injection of methotrexate or potassium chloride into sac
 - Hysteroscopic resection of sac and tissue
- Hysterectomy
 - Utilized only if conservative therapy fails
 - Required in setting of uncontrolled, massive hemorrhage

DIAGNOSTIC CHECKLIST

Consider

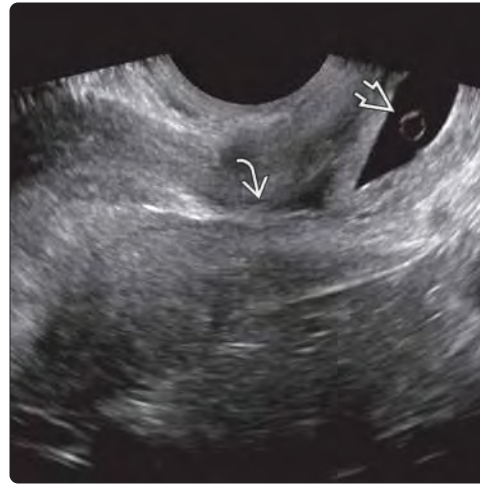
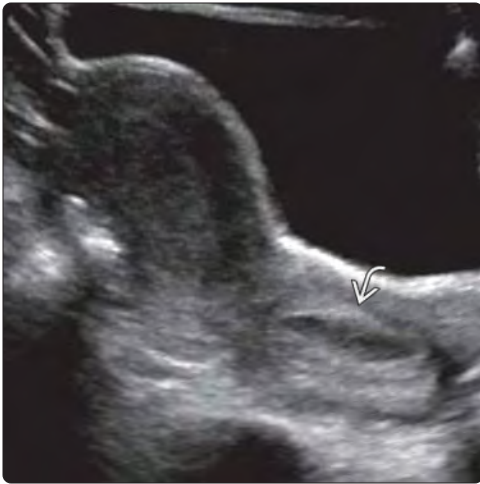- Always consider cervical ectopic if gestational sac has low implantation
 - Transabdominal US important for identifying overall uterine contour and anatomic landmarks
 - Transvaginal US should always be performed to evaluate location and contents of sac
- If located in anterior cervix, can be confused with C-section scar ectopic

Image Interpretation Pearls

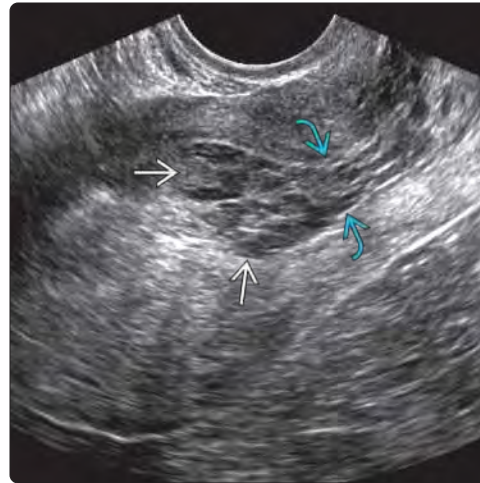
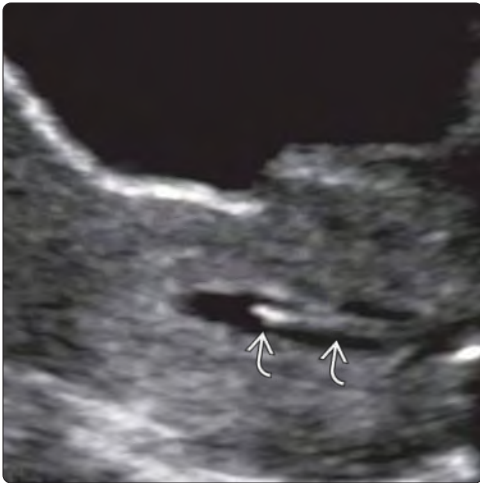- Living embryo within eccentric cervical sac is highly suspicious for ectopic pregnancy
 - Look for peritrophoblastic Doppler flow
- With spontaneous abortion, follow-up scan in a few hours will show change or passage of sac

SELECTED REFERENCES

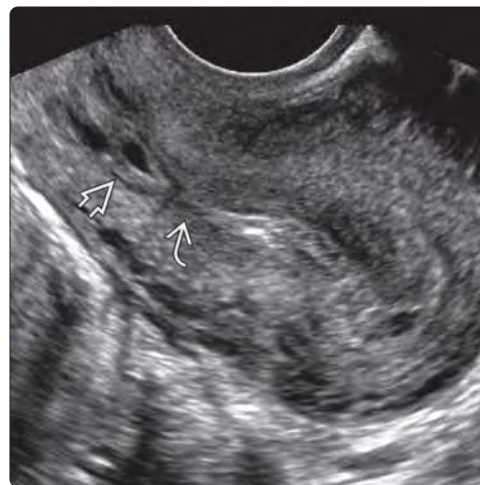
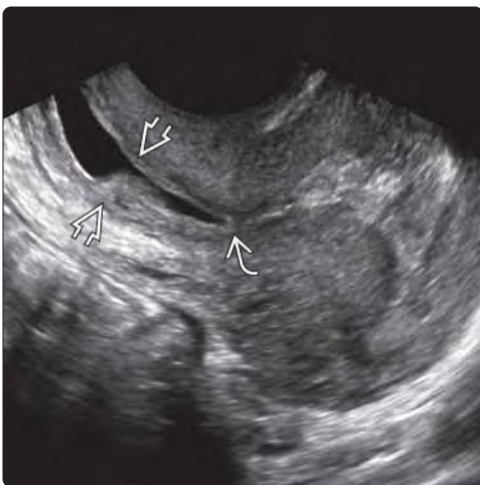
1. Chukus A et al: Uncommon implantation sites ectopic pregnancy: thinking beyond the complex adnexal mass. *Radiographics*. 140202, 2015
2. Samal SK et al: Cervical ectopic pregnancy. *J Nat Sci Biol Med*. 6(1):257-60, 2015
3. Hosni MM et al: Diagnostic and therapeutic dilemmas of cervical ectopic pregnancy. *Obstet Gynecol Surv*. 69(5):261-76, 2014
4. Krissi H et al: Outcome, complications and future fertility in women treated with uterine artery embolization and methotrexate for non-tubal ectopic pregnancy. *Eur J Obstet Gynecol Reprod Biol*. 182:172-6, 2014
5. Chaudhary V et al: Conservative management of cervical pregnancy: a report of two cases. *J Reprod Med*. 58(9-10):451-7, 2013
6. Hirakawa M et al: Uterine artery embolization along with the administration of methotrexate for cervical ectopic pregnancy: technical and clinical outcomes. *AJR Am J Roentgenol*. 192(6):1601-7, 2009
7. Verma U et al: Conservative management of cervical ectopic pregnancy. *Fertil Steril*. 91(3):671-4, 2009



(Left) TAUS shows the uterus with a cervical gestational sac [A]. Based on this appearance, the differential diagnosis is cervical ectopic vs. miscarriage. (Right) Closer inspection with TVUS shows the closed internal os [B] with an intact gestational sac with a yolk sac [C], consistent with cervical ectopic at 6 weeks gestation. The internal os should be open in a patient with a miscarriage in progress. Embryonic cardiac activity also excludes miscarriage.



(Left) TAUS guidance was used to guide injection of methotrexate into the gestational sac via the external os. There is a catheter [A] within the collapsing intracervical gestational sac. (Right) Subsequent TVUS shows that the gestational sac has passed and that there is clot [B] in the endometrial cavity. Note the open internal os [C]. This can be seen after treatment and is also the appearance during miscarriage, in contradistinction to the closed appearance in a cervical ectopic.



(Left) In this case with a retroverted uterus, the cervical gestational sac [A] is flattened and not round as typically seen. However, given the closed internal os [B] and rising β -hCG, this represents a cervical ectopic. (Right) After injection of the gestational sac, the internal os [C] remains closed and the sac [D] is markedly decreased in size.

KEY FACTS

TERMINOLOGY

- Pregnancy developing within C-section scar

IMAGING

- Eccentric gestational sac within anterior myometrium at site of C-section scar
- Empty uterine cavity and normal cervical canal
- Color Doppler may show marked peritrophoblastic flow around sac

TOP DIFFERENTIAL DIAGNOSES

- Prominent C-section scar
 - Cystic fluid collection within incision site
- Cervical ectopic

PATHOLOGY

- 2 types of C-section scar ectopic pregnancies
 - Deep implantation into defect, with subsequent rupture and life-threatening bleeding

- Implantation at scar, with progression toward uterine cavity; rarely can lead to live birth
 - High-risk morbidly adherent placentation

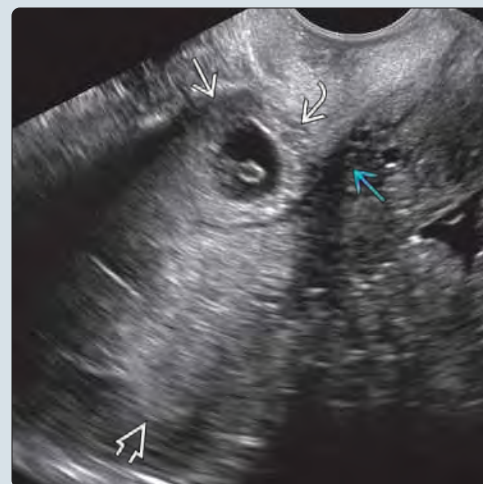
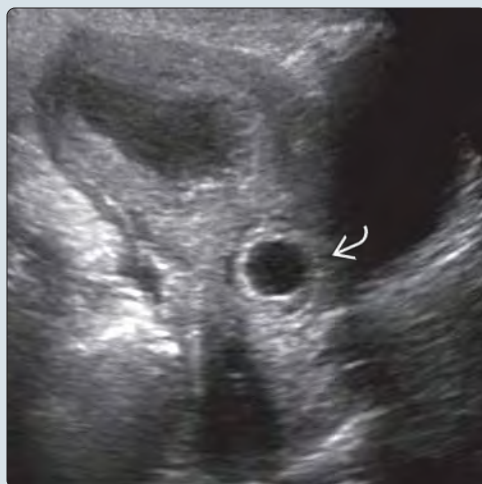
CLINICAL ISSUES

- Incidence rising with rising rate of operative deliveries
 - Majority occur with 2 or more prior C-sections
- Treatment goal is to preserve future fertility
 - Medical treatment preferred
 - Locally injected methotrexate or KCl ± systemic methotrexate
- Avoid isolated dilatation and curettage
 - Could result in incomplete removal and massive bleeding

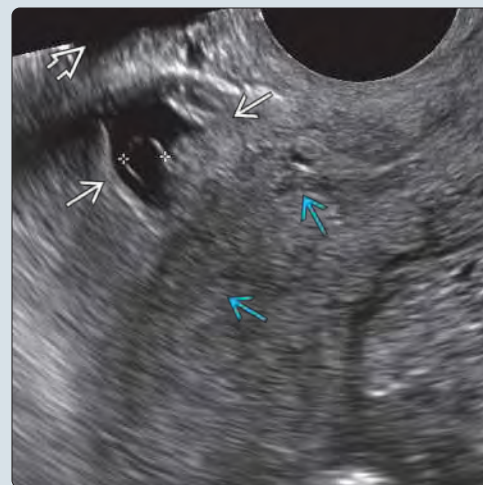
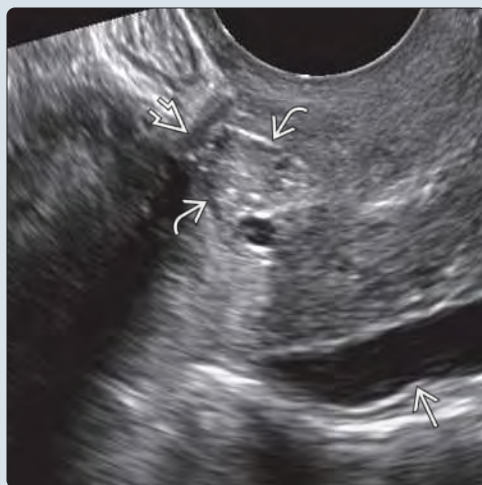
DIAGNOSTIC CHECKLIST

- Look for sac at C-section scar with peritrophoblastic flow and thinned or absent anterior myometrium
- Prominent, cystic C-section scar can mimic early ectopic gestational sac; need to follow closely

(Left) TAUS shows a gestational sac in the low anterior myometrium. (Right) Closer evaluation with TVUS shows the gestational sac eccentrically located in the C-section scar, with only a thin, residual layer of hypoechoic myometrium. Decidualized endometrium is present in the uterine cavity. The sac is implanted above the internal os, differentiating it from a cervical ectopic.



(Left) TVUS shows trophoblastic tissue within the scar without a defined sac, making the diagnosis more difficult; however, note the thinned myometrium and echogenic fluid in the pelvis. On short-term follow-up, the β -hCG continued to rise, and this area became more complex. Close monitoring is mandatory in equivocal cases. (Right) The gestational sac is growing through the anterior myometrium toward the bladder. The sac is outside the endometrial canal. Calipers indicate yolk sac.



TERMINOLOGY

Definitions

- Pregnancy developing within cesarean section scar
- C-section scar pregnancy considered more appropriate terminology than C-section scar ectopic

IMAGING

General Features

- Best diagnostic clue
 - Eccentric gestational sac within anterior myometrium at site of C-section scar
 - Empty uterine cavity and normal cervical canal
 - Thinned or absent myometrium at scar between sac and bladder
- Sac may initially implant on scar, then grow into endometrial cavity
- Color Doppler may show marked peritrophoblastic flow around sac
 - Useful to detect invasion into bladder

Imaging Recommendations

- Use TVUS, careful assessment of implantation site in patients with prior C-section

DIFFERENTIAL DIAGNOSIS

Prominent C-Section Scar Niche

- Varied appearances
 - Wedge-shaped, anechoic defect in anterior myometrium
 - Cystic fluid collection within incision site
- Consider evaluation of C-section scar and uterine wall integrity prior to conception in patients with high risk of complications
 - In vitro fertilization patients
 - Multiple prior C-sections

Cervical Ectopic

- Located within cervical stroma
- Can be difficult to distinguish from C-section scar ectopic, especially if sac is large
- May be lateral or posterior location, not just anterior as with C-section scar ectopic
- Below level of internal os

Adenomyosis

- Ectopic glands create small cysts, which could be confused with C-section scar ectopic
 - Most cysts are 2-3 mm but can be as large as 4 cm
 - Appearance may change over menstrual cycle
- Ill-defined, hypoechoic, thickened junctional zone

PATHOLOGY

Gross Pathologic & Surgical Features

- 2 types of C-section scar ectopic pregnancies
 - Deep implantation into defect, with subsequent rupture and life-threatening bleeding
 - Diagnosis and symptoms usually in 1st trimester of pregnancy
 - Implantation at scar, with progression toward uterine cavity

- Rarely can lead to live birth
- High-risk morbidly adherent placentation

CLINICAL ISSUES

Presentation

- Most common signs/symptoms
 - At least 1/3 asymptomatic
 - Vaginal bleeding
 - Abdominal or pelvic pain
 - Hypotension due to hemorrhage

Demographics

- Epidemiology
 - Incidence rising with rising rate of operative deliveries
 - 1:1,800 to 1:2,226 pregnancies
 - Majority occur with 2 or more prior C-sections

Natural History & Prognosis

- Life-threatening condition
 - Massive bleeding usually occurs by late 1st trimester if not treated
- High risk for uterine rupture
- Multiple prior C-sections may increase risk of scar ectopic

Treatment

- Goal is to preserve future fertility
- Medical treatment preferred
 - Locally injected methotrexate or KCl ± systemic methotrexate
 - Rupture of scar and bleeding may still occur
 - Consider concurrent uterine artery embolization or vasopressin injection
- Avoid isolated dilatation and curettage
 - Trophoblastic tissue invading myometrium unlikely to be fully removed
 - Risk of perforating uterine wall &/or damaging bladder
 - May lead to massive bleeding
- Surgical management reserved for acute hemorrhage/failed medical therapy

DIAGNOSTIC CHECKLIST

Image Interpretation Pearls

- C-section scar implantation may be 1st-trimester manifestation of morbidly adherent placenta
 - Placenta accreta, increta, or percreta
- Look for sac at C-section scar with thinned or absent anterior myometrium

SELECTED REFERENCES

1. Cok T et al: Transvaginal ultrasound-guided local methotrexate administration as the first-line treatment for cesarean scar pregnancy: Follow-up of 18 cases. *J Obstet Gynaecol Res.* 41(5):803-8, 2015
2. Timor-Tritsch IE et al: Cesarean scar pregnancies: experience of 60 cases. *J Ultrasound Med.* 34(4):601-10, 2015
3. Timor-Tritsch IE et al: Cesarean scar pregnancy is a precursor of morbidly adherent placenta. *Ultrasound Obstet Gynecol.* 44(3):346-53, 2014
4. Osborn DA et al: Cesarean scar pregnancy: sonographic and magnetic resonance imaging findings, complications, and treatment. *J Ultrasound Med.* 31(9):1449-56, 2012

KEY FACTS

TERMINOLOGY

- Pregnancy outside of uterus, within peritoneal cavity

IMAGING

- Gestational sac with embryo or fetus in abdomen
- Abdominal MR or CT useful to delineate anatomy
 - Identify location of placenta(s)
- Consider MR or CT angiography to identify vascular supply

TOP DIFFERENTIAL DIAGNOSES

- Tubal ectopic pregnancy
 - Fallopian tube can occasionally rotate to unexpected locations; ectopic pregnancy appears abdominal but is actually in tube
- Pregnancy in uterine duplication






CLINICAL ISSUES

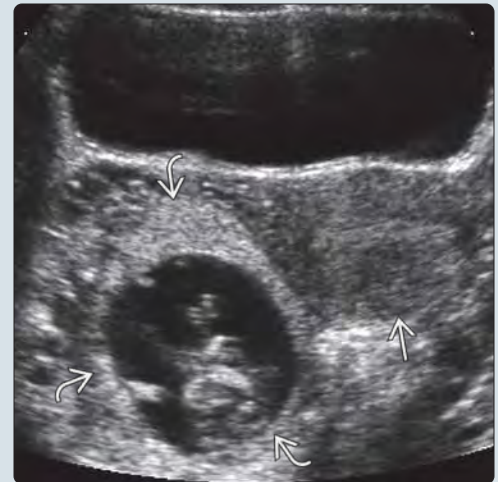
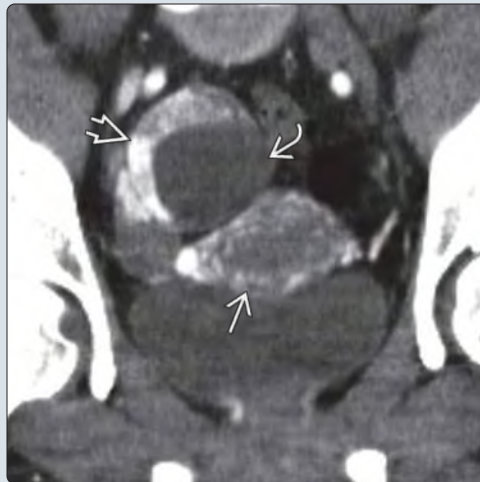
- Occasionally incidentally noted on routine viability sonogram or anatomic survey




- May present with significant abdominal pain and hypotension
 - Significant rate of maternal morbidity and mortality
- 1st trimester managed with injection of methotrexate or potassium chloride into sac
 - May require surgical excision if bleeding persists
- Consider presurgical embolization of placental vessels prior to surgical evacuation if 2nd-trimester fetus
- Rarely sufficient blood supply to carry pregnancy to term
 - Consider watchful waiting if mother stable and potential for live birth
 - Surgical delivery of fetus
 - Placenta not necessarily removed surgically
- Serial β -hCG after evacuation to document appropriately declining levels

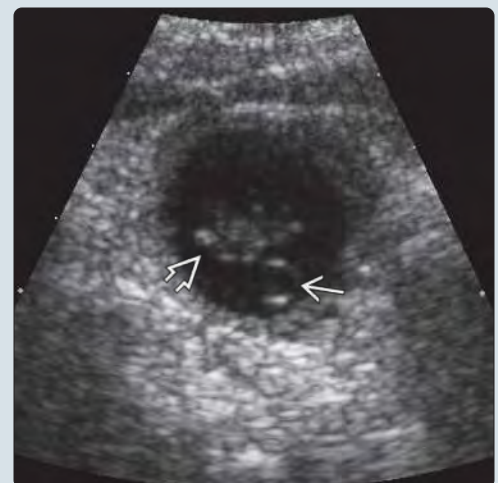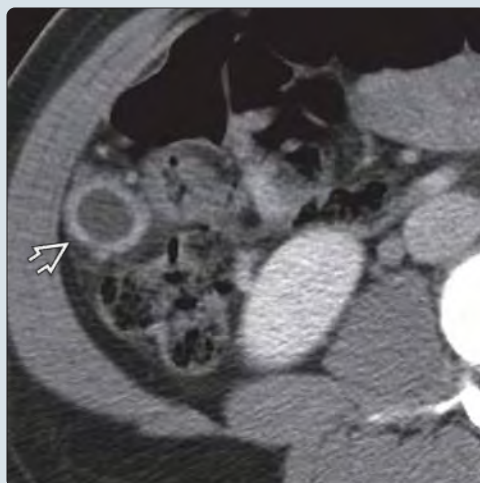
DIAGNOSTIC CHECKLIST

- Always assess for hypoechoic myometrium around embryo/fetus to prove intrauterine location

(Left) Coronal reconstruction of a contrast-enhanced CT scan performed for evaluation of right lower quadrant pain shows a gestational sac  and developing placenta  outside the uterus . The patient had denied the possibility of pregnancy. **(Right)** Subsequent transabdominal ultrasound confirmed an empty uterus  and an abdominal ectopic gestation . This was treated with intrasac KCl injections and systemic methotrexate.



(Left) Cross-sectional imaging can be used to find pregnancies of unknown location. Serial US failed to demonstrate either an intrauterine or an ectopic pregnancy in the setting of rising β -hCG. CT was performed in this case after laparoscopy was also negative. The developing gestational sac is in the right lower quadrant , adjacent to the ascending colon. **(Right)** Targeted US confirmed abdominal ectopic pregnancy with gestational sac, yolk sac , and embryo  just deep to the abdominal wall.



TERMINOLOGY

Definitions

- Pregnancy outside of uterus and within peritoneal cavity

IMAGING

General Features

- Best diagnostic clue
 - Gestational sac with embryo or fetus in abdomen
 - Empty uterus identified separately

Ultrasonographic Findings

- Lack of normal, hypoechoic rim of myometrium surrounding gestational sac
 - Most often sac located in pouch of Douglas
- Various abdominal placental implantation sites, may be multiple
 - Omentum, mesentery, bowel, liver, spleen
- Echogenic free fluid (hemorrhage) may be present

Imaging Recommendations

- Abdominal MR or CT useful
 - Identify location of placenta(s)
 - Plan incision site for surgical intervention
 - Assess for secondary complications
 - Uterine/solid organ invasion, bowel obstruction, hydronephrosis
- Consider MR or CT angiography to identify vascular supply
 - For embolization/surgical planning

DIFFERENTIAL DIAGNOSIS

Tubal Ectopic Pregnancy

- Less likely to see large embryo/fetus
- Echogenic tubal ring or hematoma most common findings
- Fallopian tube can occasionally rotate to unexpected locations
 - Ectopic pregnancy appears abdominal but is actually in tube

Pregnancy in Uterine Duplication

- Pregnancy in rudimentary horn of unicornuate uterus may mimic abdominal ectopic
 - Some abdominal pregnancies thought to be secondary to ruptured rudimentary horn
- Possible to have pregnancy in both horns of didelphys uterus
 - Potential source of confusion if horns widely separated and duplication not known/recognized

PATHOLOGY

Gross Pathologic & Surgical Features

- **Primary abdominal pregnancy**
 - Extremely uncommon
 - Studdiford criteria
 - Normal tubes and ovaries present
 - No evidence of uteroperitoneal fistula
 - Pregnancy related exclusively to peritoneal surface from early gestation
- **Secondary abdominal pregnancy**
 - More common type

- Tubal, or rarely rudimentary horn/scar implantation pregnancy, ruptures with subsequent reimplantation in abdomen

CLINICAL ISSUES

Presentation

- Most common signs/symptoms
 - Abdominal pain
 - Hypotension
 - Hypovolemic shock may occur secondary to massive hemorrhage
 - Incidentally noted on routine viability sonogram or anatomic survey

Demographics

- Epidemiology: ~ 1% of ectopic pregnancies

Natural History & Prognosis

- Significant rate of maternal morbidity and mortality
 - Higher maternal mortality rate than with other types of ectopic pregnancy
- Most will cause intraperitoneal bleeding
- Spontaneous demise of embryo/fetus occurs when blood supply becomes insufficient
- Rarely results in live birth

Treatment

- 1st trimester
 - Potassium chloride injection into sac or embryo
 - Methotrexate injection into sac ± systemic treatment
 - Surgical evacuation of pregnancy may be necessary if bleeding persists
- 2nd trimester
 - Surgical evacuation of fetus
 - Consider presurgical embolization of placental vessels
- 3rd trimester (rare)
 - Consider watchful waiting if mother stable and potential for live birth
 - Immediate delivery for signs of bleeding
 - Surgical delivery of fetus
 - Placenta not necessarily removed
 - ◻ Umbilical cord ligation
 - ◻ Placental embolization reported to be successful in decreasing placental mass
 - ◻ ± methotrexate
 - ◻ CT may be used to follow regression of residual placental tissue in abdomen
- Serial β -hCG after evacuation to document appropriately declining levels

DIAGNOSTIC CHECKLIST

Image Interpretation Pearls

- Always assess for hypoechoic myometrium around embryo/fetus to prove intrauterine location

SELECTED REFERENCES

1. Dabiri T et al: Advanced extrauterine pregnancy at 33 weeks with a healthy newborn. *Biomed Res Int.* 2014;102479, 2014
2. Srinivasan A et al: Laparoscopic management of an abdominal pregnancy. *Case Rep Obstet Gynecol.* 2014;562731, 2014

KEY FACTS

TERMINOLOGY

- Ectopic pregnancy implanted on or in ovary

IMAGING

- Echogenic ring in ovary with central fluid and peripheral vascularity
 - Often more echogenic than corpus luteum
 - Look for yolk sac and embryo
 - Ring of fire with color Doppler
 - Nonspecific as also seen with corpus luteum
 - Show mass moves with ovary, not tube
- Uterine findings similar to tubal ectopic
 - No intrauterine pregnancy
 - Decidual reaction
 - Uterine cavity blood
- Look for blood in cul-de-sac
 - Ovarian ectopics often present ruptured
 - May be impossible to tell from tubal pregnancy if ruptured

TOP DIFFERENTIAL DIAGNOSES

- Corpus luteum cyst
 - Will not have yolk sac or embryo
- Tubal ectopic
 - Moves separate from ovary with probe pressure
- Incidental ovarian mass
 - Will not have ring of fire color Doppler flow

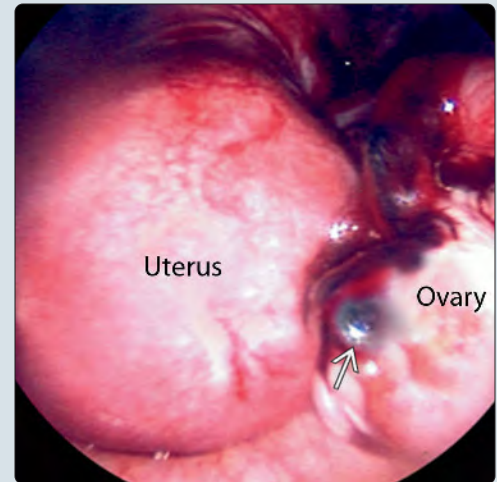
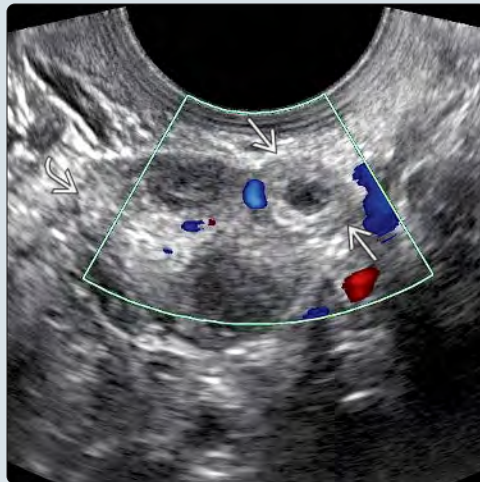
PATHOLOGY

- Normal fertilization occurs in tube with retrograde reflux of conceptus and implantation on ovary
- Intrafollicular fertilization (rare)
 - Mature ovum fertilized in ovary (preovulation)
- Surgical path shows ovarian tissue in sac wall

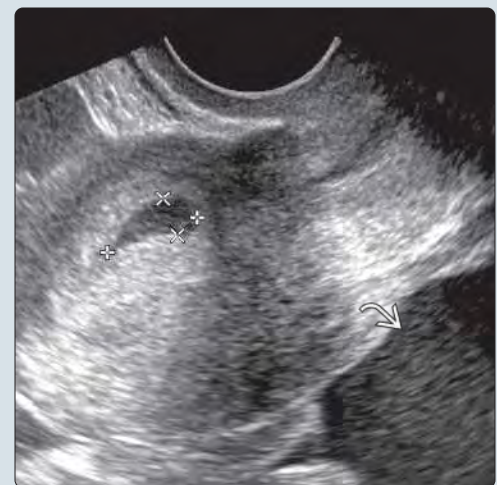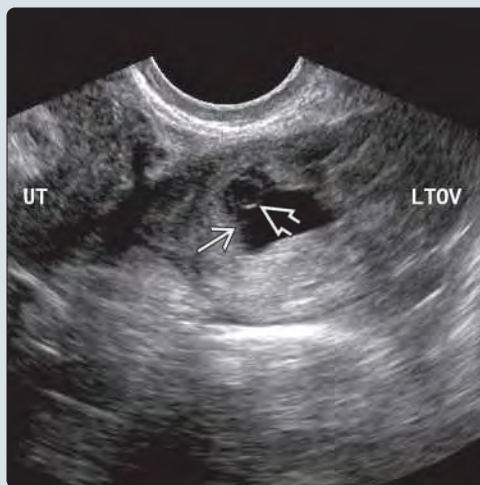
CLINICAL ISSUES

- Treatment most often with laparoscopic surgical resection
- Ovarian preservation is goal
- Medical management is successful only 50% of time

(Left) An exophytic echogenic gestational sac with peripheral flow is seen on the surface of the ovary. The uterus was empty, and the patient had adnexal pain out of proportion to what would be expected for a corpus luteum. An ovarian ectopic is often more echogenic than a typical corpus luteum. (Right) Laparoscopic image in the same patient shows the ectopic gestational sac on the surface of the ovary. This small ovarian ectopic was easily resected, and the ovary was salvaged.



(Left) In this patient with an ovarian ectopic pregnancy, the gestational sac is surrounded by ovarian tissue and contains a yolk sac. In this case, a 3-mm living embryo was also seen (not shown). (Right) TVUS in the same patient shows blood in the cul-de-sac. The intrauterine fluid collection (calipers) is flat in shape and has pointed edges most consistent with blood, although such collections may mimic an intrauterine pregnancy. An ovarian ectopic was resected from the ovary at laparoscopy.



TERMINOLOGY

Abbreviations

- Ovarian ectopic pregnancy (OEP)
- Intrauterine pregnancy (IUP)

Definitions

- Ectopic pregnancy implanted on or in ovary

IMAGING

General Features

- Best diagnostic clue
 - Echogenic vascular ring in ovary with yolk sac ± embryo
- Morphology
 - Round if not ruptured

Ultrasonographic Findings

- OEP appearance
 - Echogenic ring with central fluid and peripheral vascularity
 - Can look identical to corpus luteum
 - Ring of fire with color Doppler
 - Look for yolk sac and embryo
- Uterine findings similar to tubal ectopic
 - Empty uterus, often with decidual reaction
 - Intrauterine blood may mimic IUP
 - Fluid collection with pointed edges much more likely with ectopic
- Cul-de-sac findings
 - Echogenic fluid (blood) or clot

Imaging Recommendations

- Best imaging tool
 - Transvaginal scanning with gentle external abdominal pressure
- Protocol advice
 - Show mass moves with ovary, not tube
 - Look carefully for yolk sac and embryo

DIFFERENTIAL DIAGNOSIS

Corpus Luteum Cyst

- Can look identical to OEP (no yolk sac/embryo)
 - Internal hemorrhage can mimic embryo
- More likely to be asymptomatic
- Most OEPs are initially misdiagnosed as corpus luteum

Tubal Ectopic

- Gestational sac between uterus and ovary
- Moves separate from ovary with probe pressure

Incidental Ovarian Mass

- Less likely to demonstrate ring of fire
- Endometrioma: Diffuse medium level echoes
- Teratoma: Complex cystic mass ± fat and calcifications

PATHOLOGY

General Features

- Etiology
 - Normal fertilization in tube with retrograde reflux of conceptus

- Intrafollicular fertilization (rare)
 - Fertilization of mature ovum in ovary
- Associated abnormalities
 - Previous ectopic pregnancy
 - Pelvic inflammatory disease
 - Endometriosis

Staging, Grading, & Classification

- Spiegelberg criteria of 1878 considered still valid
 - Gestational sac occupies normal position of ovary
 - OEP is attached to uterus by ovarian ligament
 - Fallopian tube is otherwise intact
 - Ovarian tissue in gestational sac wall proven histologically

CLINICAL ISSUES

Presentation

- Most common signs/symptoms
 - Adnexal pain, vaginal bleeding
 - Often present ruptured

Demographics

- Epidemiology
 - OEP in 4% of ectopic pregnancies conceived naturally
 - OEP in 6% of ectopic pregnancies conceived with assisted conception
 - No reported cases of recurrent OEP

Natural History & Prognosis

- Excellent prognosis when treated early
- Ovarian preservation is goal

Treatment

- Laparoscopic surgical resection
 - Dissection of ectopic pregnancy off ovary
 - Partial oophorectomy or wedge resection often necessary
- Medical management
 - 50% success rate with methotrexate alone
- Postsurgical methotrexate may be necessary for persistent residual trophoblast tissue

DIAGNOSTIC CHECKLIST

Image Interpretation Pearls

- Look for yolk sac and embryo in what may initially be thought to be corpus luteum (especially if symptoms are out of proportion to imaging findings)
- Corpus luteum is much more common than OEP; do not overdiagnose OEP

SELECTED REFERENCES

1. Goyal LD et al: Ovarian ectopic pregnancy: A 10 years' experience and review of literature. *Iran J Reprod Med.* 12(12):825-30, 2014
2. Alkatout I et al: Clinical diagnosis and treatment of ectopic pregnancy. *Obstet Gynecol Surv.* 68(8):571-81, 2013
3. Joseph RJ et al: Ovarian ectopic pregnancy: aetiology, diagnosis, and challenges in surgical management. *J Obstet Gynaecol.* 32(5):472-4, 2012
4. Bontis J et al: Intrafollicular ovarian pregnancy after ovulation induction/intrauterine insemination: pathophysiological aspects and diagnostic problems. *Hum Reprod.* 12(2):376-8, 1997

Heterotopic Pregnancy

KEY FACTS

TERMINOLOGY

- 2 concurrent pregnancies, at least 1 of which is ectopic in location
- Most commonly 1 intrauterine pregnancy (IUP) with tubal ectopic pregnancy

IMAGING

- Identify IUP
- Look for echogenic free fluid or adnexal mass/ring outside of uterus
- Use color Doppler whenever ectopic is suspected
 - Increased trophoblastic flow creates ring of fire
 - Beware ring of fire of corpus luteum, especially with ovulation induction

TOP DIFFERENTIAL DIAGNOSES

- Ectopic pregnancy with intrauterine fluid creating sac-like structure
- Pregnancy in uterine duplication

PATHOLOGY

- Damage to endometrium or fallopian tubes predisposes to ectopic pregnancy implantation

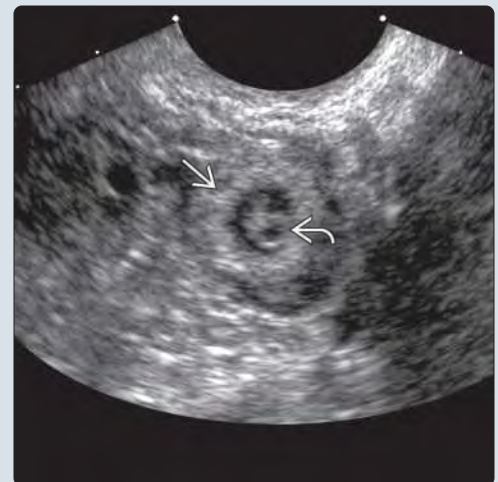
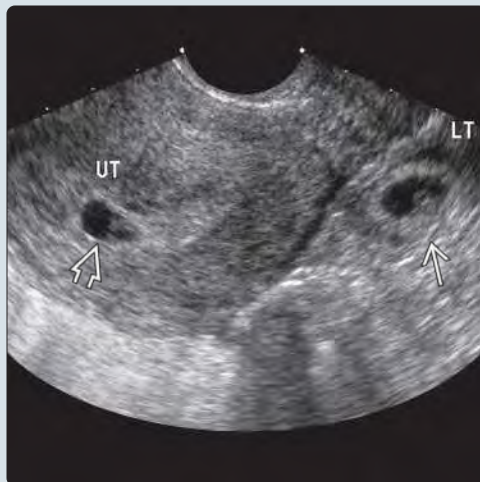
CLINICAL ISSUES

- < 1:30,000 naturally conceived pregnancies
 - Incidence increased with use of assisted reproductive technology
- ~ 66% of treated heterotopic pregnancies result in live delivery
- Surgical management treatment of choice to preserve IUP
- Potassium chloride (KCl) or hyperosmolar solution injection into ectopic sac is alternative

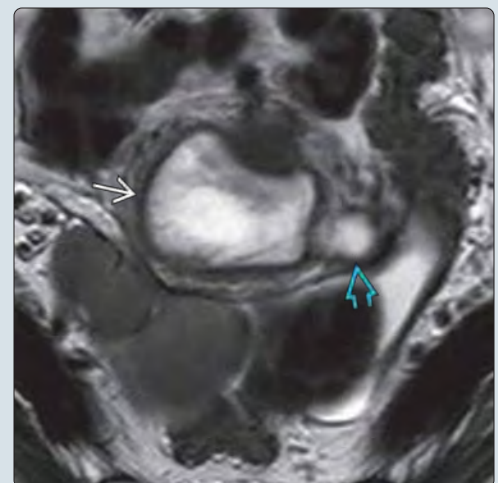
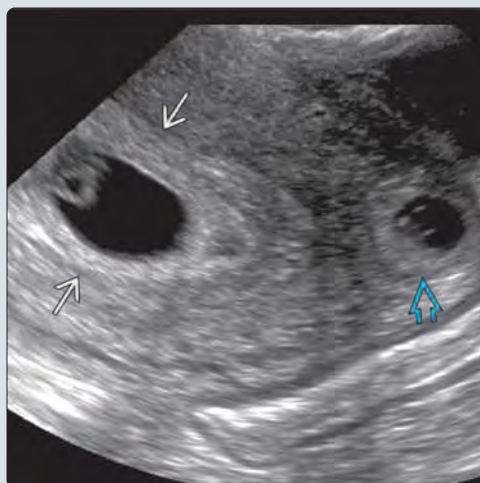
DIAGNOSTIC CHECKLIST

- Careful evaluation of high-risk patients warranted
- Always check adnexa, even if IUP identified

(Left) TVUS shows a gestational sac within the uterus. In addition, an ectopic gestational sac is present in the left adnexa. (Right) Further imaging of the left adnexa shows the ectopic pregnancy has the typical echogenic decidual reaction seen in intrauterine pregnancies; within the gestational sac is a well-defined yolk sac and a 6-week embryo. Treatment for a heterotopic gestation is focused on preserving the intrauterine pregnancy.



(Left) A normal gestational sac is present in the endometrial cavity. A 2nd smaller sac is present in the interstitial portion of the left fallopian tube. (Right) MR was used to confirm the interstitial ectopic prior to definitive treatment with injection of KCl. The high-signal fluid in the uterus is the intrauterine pregnancy, which was preserved. This type of medical treatment is especially useful for nontubal heterotopic pregnancies as these are challenging to manage surgically.



TERMINOLOGY

Definitions

- 2 concurrent pregnancies, at least 1 of which is ectopic in location
 - Tubal, cervical, interstitial, abdominal, cesarean scar implantation
- Most commonly 1 intrauterine pregnancy (IUP) with tubal ectopic pregnancy

IMAGING

General Features

- Best diagnostic clue
 - IUP with 2nd ectopic pregnancy

Imaging Recommendations

- Identify IUP
- Look for echogenic free fluid or adnexal mass/ring outside of uterus
- Use color Doppler whenever ectopic is suspected
 - Increased trophoblastic flow creates ring of fire
 - Helpful for identifying small ectopic pregnancies
 - Beware ring of fire of corpus luteum especially with ovulation induction

DIFFERENTIAL DIAGNOSIS

Tubal Ectopic Pregnancy

- Much more common than heterotopic pregnancy
- Intrauterine fluid creates sac-like structure, which may mimic IUP
 - If central in cavity with pointed edges, more likely blood collection
 - Normal, very early IUP is round or oval in shape, eccentric to central cavity echo
 - Look for yolk sac as sign of definite IUP

Pregnancy in Uterine Duplication

- May initially appear to be heterotopic pregnancy
 - Twins with 1 sac in each horn
 - Single sac with fluid in other horn
- Myometrium completely surrounds each sac
- No adnexal masses or echogenic free fluid

PATHOLOGY

General Features

- Damage to endometrium or fallopian tubes predisposes to ectopic pregnancy implantation
 - Tubal damage
 - Endometriosis, pelvic inflammatory disease, prior salpingostomy, prior ectopic pregnancy
 - History of pelvic surgery
 - Intrauterine contraceptive device
 - Uterine anomalies

CLINICAL ISSUES

Presentation

- Most common signs/symptoms
 - Abdominal pain
 - Adnexal mass

- Vaginal bleeding
- Hypovolemic shock if ruptured
- Must have high index of suspicion in assisted reproductive technology (ART) population
 - Presence of IUP in this group does not exclude ectopic
 - Making diagnosis may be difficult
 - Stimulated ovaries may be large with confusing appearance
 - Trauma during oocyte harvest may cause bleeding → echogenic fluid in abdomen

Demographics

- Epidemiology
 - < 1:30,000 naturally conceived pregnancies
 - Incidence increased with use of ART
 - In series of 553,577 ART pregnancies: 1.7% ectopic, 0.1% heterotopic

Natural History & Prognosis

- Depends on size and location of ectopic
- Live birth in ~ 66% of treated heterotopic pregnancies

Treatment

- Surgical for tubal ectopic
 - Salpingotomy
 - Small lengthwise incision in tube with removal of ectopic pregnancy
 - Salpingectomy
 - Segment of tube removed, ends reconnected if technically feasible
- Medical treatment
 - Best if ectopic is difficult to manage surgically (e.g., cervical, interstitial, cesarean implantation)
 - Potassium chloride (KCl) or hyperosmolar solution injection into ectopic sac
 - Kills embryo, trophoblastic tissue involutes
 - Methotrexate injection into sac is only performed if IUP is undesired

DIAGNOSTIC CHECKLIST

Image Interpretation Pearls

- Careful evaluation of high-risk patients warranted to exclude heterotopic pregnancy
 - Always carefully check adnexa, even if IUP identified
 - Especially important if patient presents with pelvic pain

SELECTED REFERENCES

1. Avitabile NC et al: Two cases of heterotopic pregnancy: review of the literature and sonographic diagnosis in the emergency department. *J Ultrasound Med.* 34(3):527-30, 2015
2. Perkins KM et al: Risk of ectopic pregnancy associated with assisted reproductive technology in the United States, 2001-2011. *Obstet Gynecol.* 125(1):70-8, 2015
3. OuYang Z et al: Heterotopic cesarean scar pregnancy: diagnosis, treatment, and prognosis. *J Ultrasound Med.* 33(9):1533-7, 2014
4. Savelli L et al: Heterotopic interstitial pregnancy successfully treated with ultrasound-guided potassium chloride injection in the ectopic embryo. *J Obstet Gynaecol.* 34(3):276-7, 2014
5. Talbot K et al: Heterotopic pregnancy. *J Obstet Gynaecol.* 31(1):7-12, 2011

DIFFERENTIAL DIAGNOSIS

Common

- Failed 1st-Trimester Pregnancy
- Intrauterine Sac-Like Structure Associated With Ectopic Pregnancy (Mimic)
- Retained Products of Conception
- Abnormal Sac Location

Less Common

- Abnormal Yolk Sac
- Chorionic Bump
- Gestational Trophoblastic Disease
 - Complete Hydatidiform Mole
 - Partial Mole (Triploidy)
 - Invasive Mole
 - Choriocarcinoma

Rare but Important

- Abnormal Embryo or Fetus

ESSENTIAL INFORMATION

Key Differential Diagnosis Issues

- Be familiar with normal appearances of early pregnancy
 - Intrauterine sac-like structure
 - Generic descriptor includes intradecidual sac sign (IDSS) and double decidual sac sign (DDSS)
 - IDSS: Cystic structure within endometrium, eccentric in relation to cavity
 - DDSS: Rounded fluid collection with 2 surrounding echogenic rings
 - If structure is round in shape statistically most likely intrauterine pregnancy (IUP)
 - If pointed edges are present, less likely to be viable IUP
 - Double bleb sign
 - Yolk sac (YS) and amnion on either side of embryonic disc
 - Seen for short period in early pregnancy
- Extraembryonic coelom (chorionic cavity): Space between amnion and chorion
 - Normally more echogenic compared to anechoic fluid inside amnion
 - Space is obliterated as amnion enlarges to fill chorionic cavity
 - Do not confuse with perigestational hemorrhage
 - Perigestational hemorrhage located outside of chorion
 - Crescentic in shape
 - Echogenic-to-hypoechoic blood products depending on age
- Normal IUP milestones
 - When mean sac diameter (MSD) \geq 25 mm, embryo should be visible
 - Embryo with crown rump length (CRL) \geq 7 mm must have cardiac activity

Helpful Clues for Common Diagnoses

- **Failed 1st-Trimester Pregnancy**
 - Gestational sac with MSD $>$ 25 mm without embryo
 - Embryo \geq 7 mm without cardiac activity

- Cessation of previously documented cardiac activity in embryo of any size
- Lack of live embryo 14 days after visible intrauterine gestational sac without YS
- Lack of live embryo 11 days after visible intrauterine gestational sac with YS
- Features concerning for, but not diagnostic of, pregnancy failure
 - CRL $<$ 7 mm with no heartbeat
 - MSD 16–24 mm with no embryo
 - Lack of live embryo 7-13 days after visible intrauterine gestational sac without YS
 - Lack of live embryo 7-10 days after visible intrauterine gestational sac with YS
 - Absence of embryo \geq 6 weeks after last menstrual period
 - Empty amnion
 - YS diameter $>$ 7 mm
 - Small sac size in relation to embryo
 - $<$ 5 mm difference between MSD and CRL
- **Intrauterine Sac-Like Structure Associated With Ectopic Pregnancy (Mimic)**
 - Pseudosac no longer accepted terminology as it is imprecise and may lead to confusion
 - Oval/flat/irregular shape
 - Fluid collection with pointed edges
 - Central in cavity
 - IUP is eccentrically implanted
 - Look for adnexal mass and echogenic fluid when see intrauterine fluid collection with pointed edges
- **Retained Products of Conception**
 - Irregular collapsed sac or echogenic, chorionic remnants
 - If Doppler shows flow in intracavitary material, retained products of conception most likely diagnosis
 - Lack of flow does not exclude diagnosis
 - May be hard to differentiate from gestational trophoblastic disease
 - Correlate with β -hCG level/trend
- **Abnormal Sac Location**
 - Angular pregnancy
 - Implanted high and lateral in cavity
 - Mimic of interstitial ectopic
 - Low implantation site
 - Mimic of abortion in progress and cesarean scar implantation
 - Abortion in progress
 - Detached sac moves from implantation site through uterus/cervix in process of spontaneous abortion
 - No cardiac activity
 - No trophoblastic flow
 - Interstitial ectopic
 - Very eccentric location at cornua of fundus
 - Thin surrounding myometrium ($<$ 5 mm)
 - Look for interstitial line sign
 - Cervical ectopic
 - Implanted in cervical stroma, below isthmus
 - Look for hourglass shape of uterus
 - Cesarean scar implantation
 - Low in cavity

- Implanted on scar with extension to uterine serosa-bladder interface
- Often associated with acute uterine retroflexion due to adhesions at hysterotomy site

Helpful Clues for Less Common Diagnoses

- **Abnormal Yolk Sac**
 - Flattened
 - Calcified
 - Large (> 6 mm diameter)
- **Chorionic Bump**
 - Focal protuberance from chorionic surface
 - Thought to represent early arterial bleed
 - Strong association with partial mole
 - 1st described in vitro fertilization (IVF) population but also seen with spontaneous conception
 - 50% loss rate documented in initial series, but newer data suggests better outcomes, particularly if live embryo is present
- **Complete Hydatidiform Mole**
 - Presents with hyperemesis, hypertension, size > dates, vaginal bleeding
 - Classic bunch of grapes or snowstorm appearance more common in 2nd trimester
 - Cavity distended by mass with multiple cysts
 - In 1st trimester may just see odd-looking trophoblastic tissue
 - May be associated with ovarian theca lutein cysts
- **Partial Mole (Triploidy)**
 - 1st trimester: Unusual-looking sac/chorionic bump
 - 2nd-trimester presentation depends on source of 3rd set of chromosomes
 - Large, cystic placenta if paternal
 - Small placenta if maternal
 - Abnormal fetus
- **Invasive Mole**
 - Complex vascular mass without visible embryo
 - Loss of endometrial-myometrial interface due to invasion into myometrium
- **Choriocarcinoma**

- Very variable imaging findings
 - Infiltrative heterogeneous mass
 - Small or even no visible mass with distant metastases
 - Also associated with ovarian theca lutein cysts

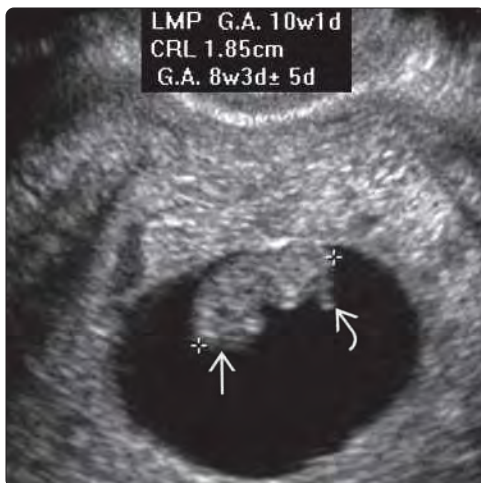
Helpful Clues for Rare Diagnoses

- **Abnormal Embryo/Fetus**
 - 1st-trimester detection of fetal anomaly is possible
 - Increased nuchal translucency
 - Cystic hygroma
 - Central nervous system: Holoprosencephaly, hydranencephaly, acalvaria/exencephaly
 - Abdominal wall defects: Gastroschisis, omphalocele
 - Abnormal cardiac axis
 - Limb reduction defects
 - Megacystis

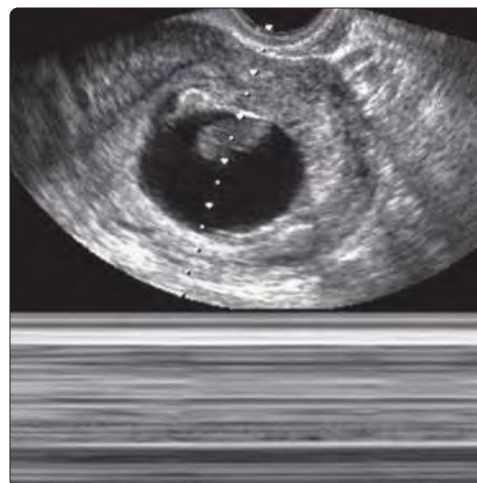
Other Essential Information



- Differentiate abnormal gestational sac from abnormality adjacent to normal sac
 - Perigestational hemorrhage
 - Crescentic shape
 - Mixed echogenicity between chorion and myometrium
 - May present with vaginal bleeding
 - Early twin demise
 - Smaller MSD than normal sac
 - May be irregular in shape
 - Uterine myomata
 - Variable, echogenic, round mass adjacent to sac
 - Degenerated fibroid may appear similar to abnormal gestational sac but location is in myometrium
 - Focal myometrial contraction
 - Will change shape or resolve in duration of scan
 - Adenomyotic cyst
 - Diffuse adenomyosis may react to pregnancy hormones
 - Prominent cystic change in myometrium **not** in trophoblast

Failed 1st-Trimester Pregnancy





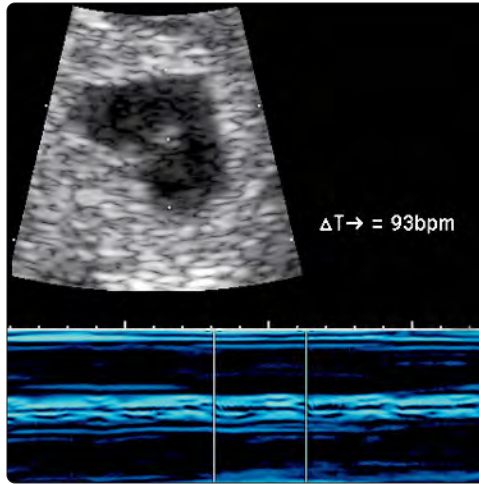
Failed 1st-Trimester Pregnancy



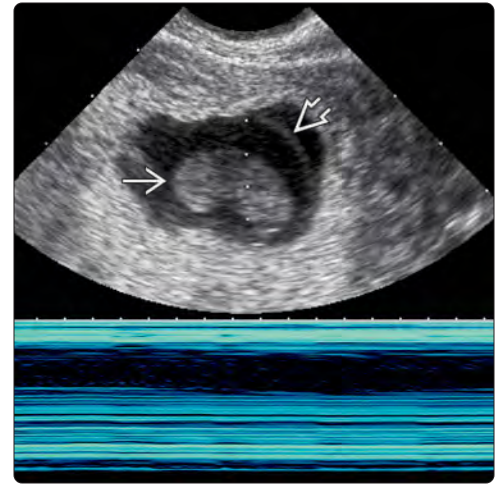
(Left) TVUS shows an 18.5-mm embryo with a well-developed crown or cranial component  as well as early limb buds . The size, however, is much less than expected based on the last menstrual period. (Right) M-mode ultrasound in the same case shows absent cardiac activity. In an embryo of this size (≥ 7 mm), this is diagnostic of embryonic demise and no additional follow-up is required.

Failed 1st-Trimester Pregnancy







(Left) M-mode ultrasound at 6 weeks and 3 days shows embryonic bradycardia with a heart rate of 93 BPM. This finding can be seen with heart block and structural heart defects. It is a poor prognostic indicator. (Right) TVUS in the same patient at 7 weeks and 4 days shows cessation of cardiac activity, a somewhat ghost-like, amorphous appearance to the embryo , and an expanded amnion . This is embryonic demise.

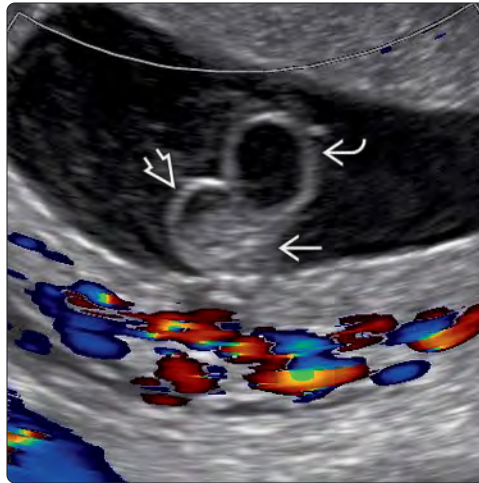


Failed 1st-Trimester Pregnancy

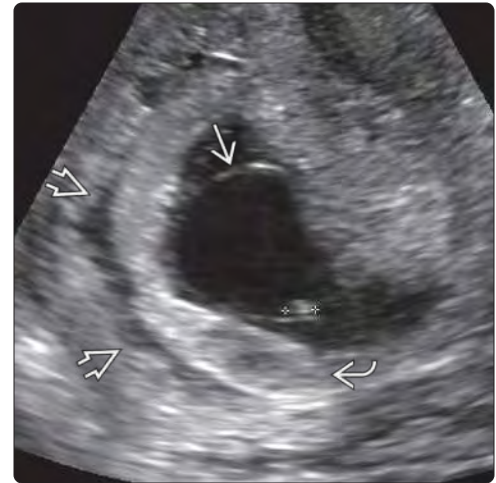


Failed 1st-Trimester Pregnancy




(Left) TVUS shows a dead, 9-mm embryo  inside an expanded amnion , with an adjacent, abnormally large yolk sac . Doppler should be used sparingly in early pregnancy, but in this case, color Doppler was used appropriately to illustrate absence of cardiac pulsation. (Right) TVUS shows the embryo (calipers) inside an expanded amnion . There are often multiple findings in failed pregnancies; in this case, note the hydropic chorionic villi  and the perigestational hemorrhage .

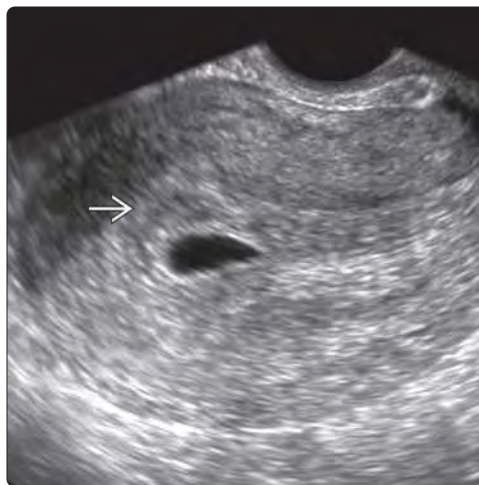


Failed 1st-Trimester Pregnancy

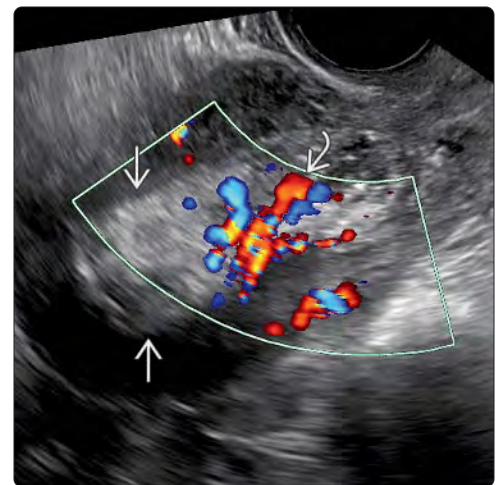


Intrauterine Sac-Like Structure Associated With Ectopic Pregnancy (Mimic)

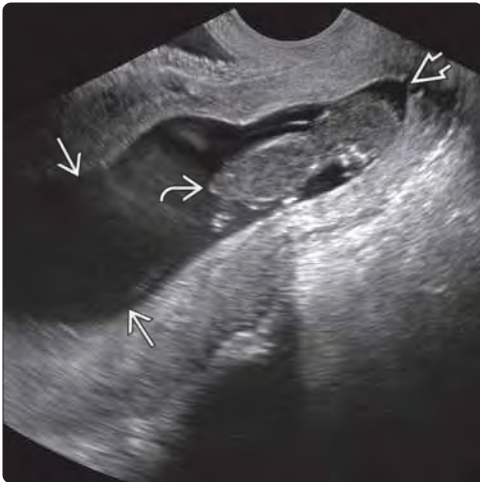
(Left) TVUS shows a small, "pointy" fluid collection , without a double decidual sac sign, centrally located in the endometrial cavity. This is an ectopic (thus, nonviable) pregnancy, and if it is not recognized as such, the patient is placed at great risk. (Right) TVUS in patient with vaginal bleeding after a crash C-section shows echogenic tissue  with several large vessels  in the uterine cavity. There was concern for gestational trophoblastic disease, but pathology only revealed retained products of conception.



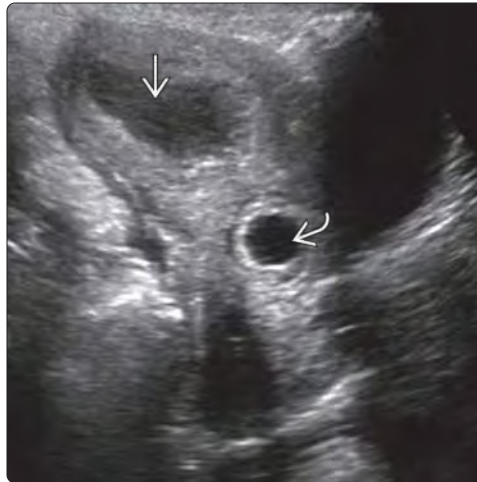
Retained Products of Conception



Abnormal Sac Location

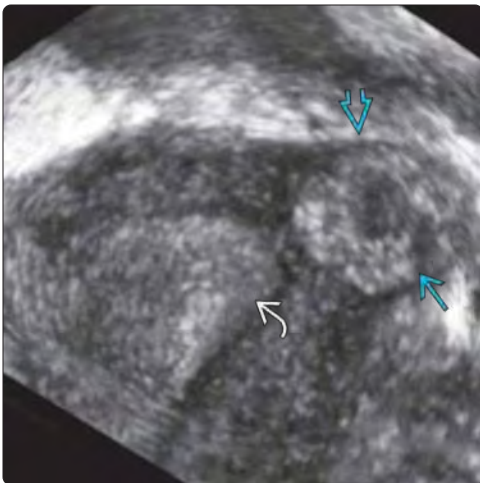


Abnormal Sac Location

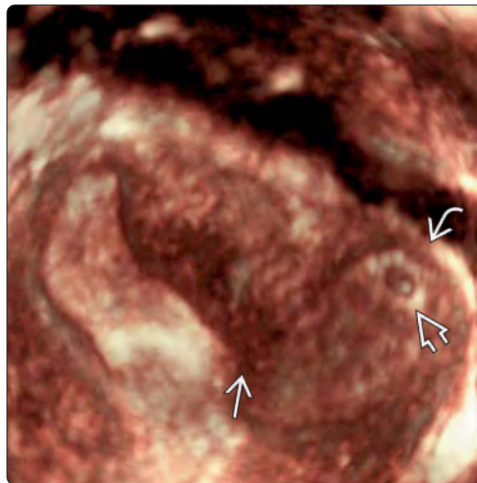


(Left) TVUS shows an abortion in progress. The fetus is in the cervix, the external os is open, and the gestational sac is elongated and flattened. (Right) Sagittal TAUS shows the gestational sac implanted low and centered in the myometrium at the site of a prior hysterotomy. This is a cesarean scar implantation. Note the intrauterine sac-like structure in the endometrial cavity. This is just blood and not an intrauterine pregnancy.

Abnormal Sac Location

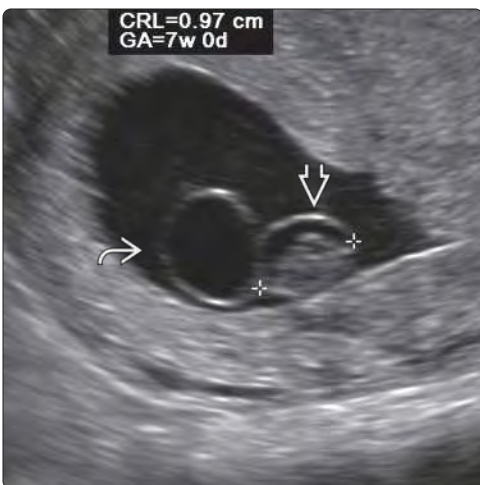


Abnormal Sac Location

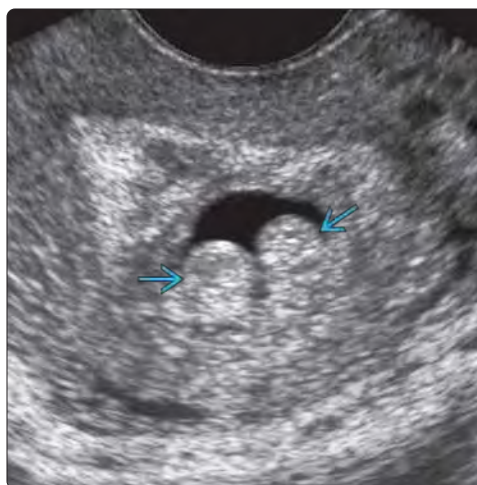


(Left) 3D coronal reconstruction shows an interstitial ectopic pregnancy implanted away from the uterine cavity with surrounding myometrium becoming imperceptible. (Right) 3D US in a septate uterus shows a gestational sac implanted in the left horn, which may mimic an interstitial ectopic pregnancy. An apparent abnormal location can be created by a müllerian duct anomaly. Note the normal surrounding myometrium.

Abnormal Yolk Sac



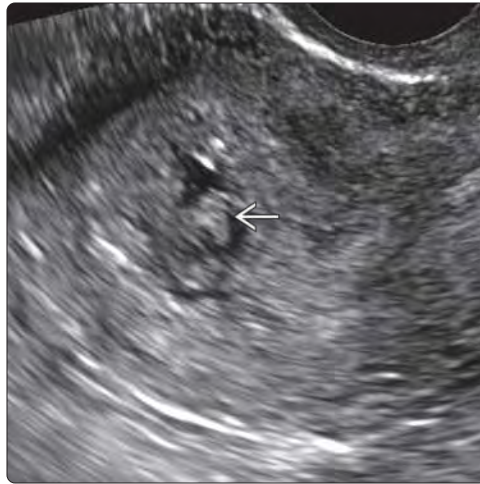Chorionic Bump



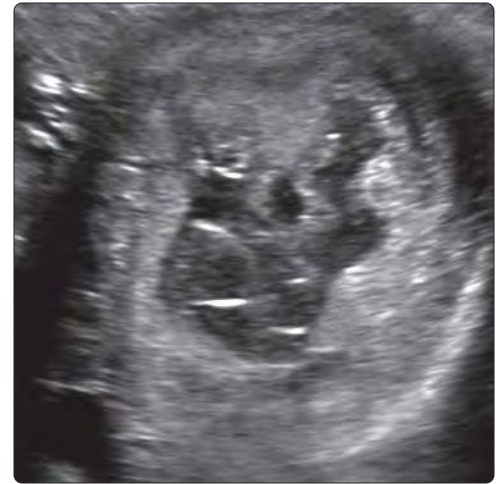
(Left) TVUS shows an abnormally large yolk sac adjacent to the expanded amnion surrounding a dead 0.97-cm embryo in this patient with certain dates who should have been 14 weeks and 2 days pregnant. The normal yolk sac is < 6 mm. (Right) TVUS shows an intrauterine gestation sac distorted by 2 focal projections (i.e., chorionic bumps) into the cavity. A live embryo was also seen. A short interval follow-up study showed embryonic demise and D&C revealed partial mole.

Chorionic Bump

(Left) TVUS shows an intrauterine sac-like structure with irregular walls and a chorionic bump. (Right) Follow-up US 11 days later shows very irregular, thick trophoblastic tissue with no normal gestational sac structures. D&C was performed with final diagnosis of complete mole. The typical bunch of grapes appearance may not be apparent in the 1st trimester. Chorionic bump is associated with partial mole more frequently than with complete mole as occurred in this patient.

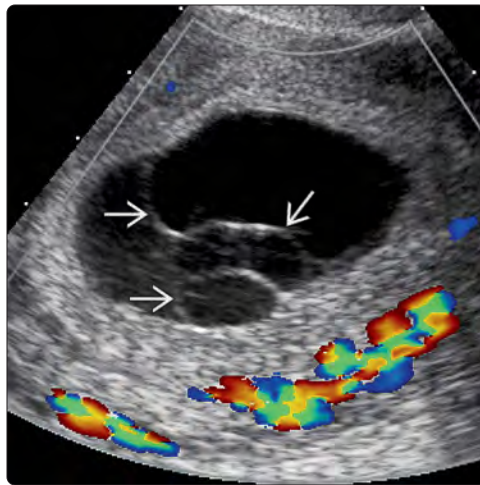


Complete Hydatidiform Mole

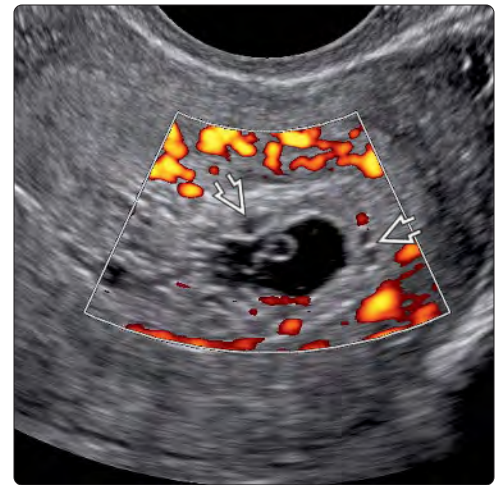


Partial Mole (Triploidy)

(Left) TVUS shows an intrauterine sac containing fine avascular membranes but neither embryo nor yolk sac. Tissue diagnosis after D&C was partial mole. (Right) TVUS shows a gestational sac with a yolk sac and tiny adjacent embryo. Note the cystic changes in the trophoblast. Embryonic demise occurred, and D&C revealed a partial mole.

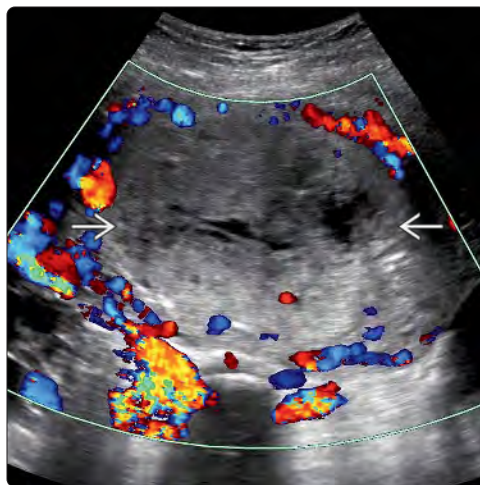


Partial Mole (Triploidy)

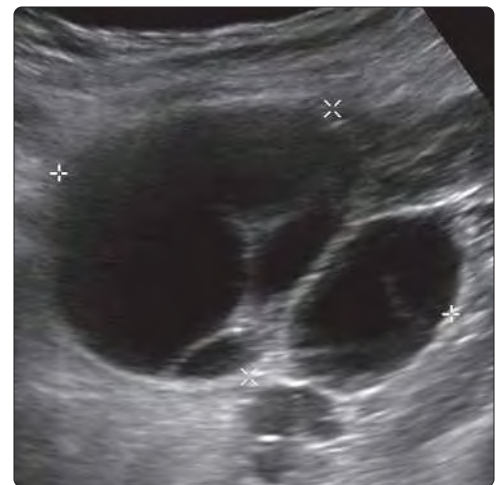


Choriocarcinoma

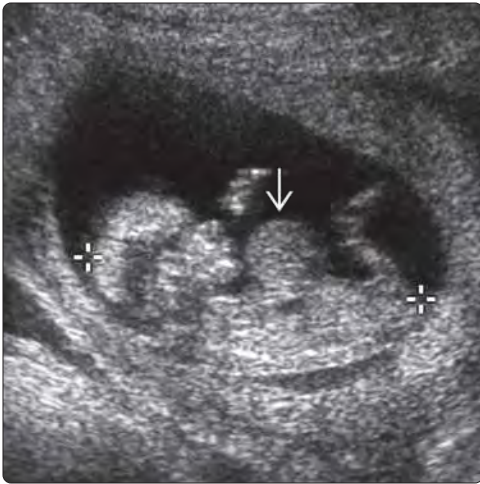
(Left) TAUS in a woman with persistent bleeding 2 months postpartum shows a largely avascular mass in the uterus. Her β -hCG level was high, and D&C showed choriocarcinoma. She had lung metastases on subsequent CT but responded well to chemotherapy. (Right) TAUS in the same patient shows theca lutein cysts in an enlarged ovary measuring 6.7 x 4.9 cm. Theca lutein cysts are associated with gestational trophoblastic disease.



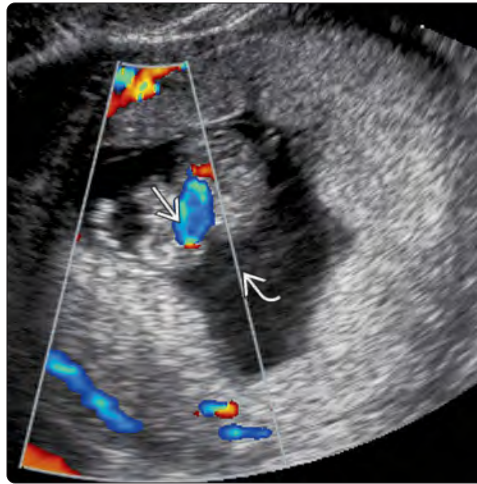
Choriocarcinoma



Abnormal Embryo or Fetus

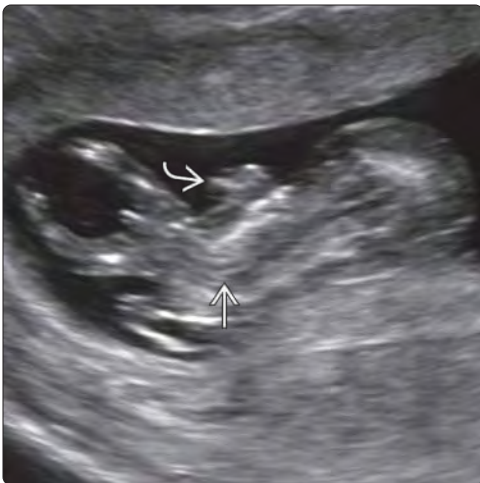

Abnormal Embryo or Fetus

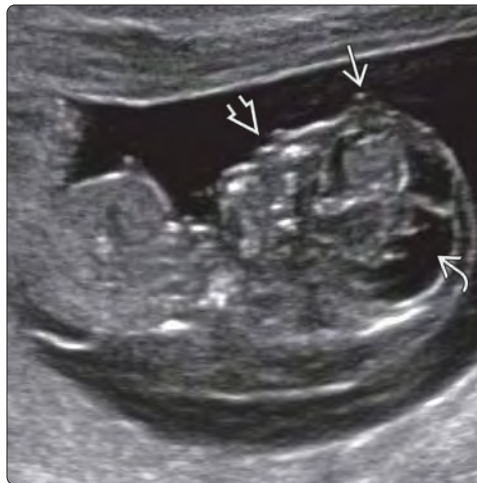


(Left) There is a focal protrusion from the abdominal wall in this 12-week fetus (1 of a pair of dichorionic twins). This is a liver-containing omphalocele. (Right) Axial US through the abdomen of a 13-week fetus shows extruded bowel loops adjacent to the cord insertion site. This is the typical appearance of gastroschisis. Normal bowel herniation is into the cord, and bowel should be back in the abdomen by this gestational age.

Abnormal Embryo or Fetus

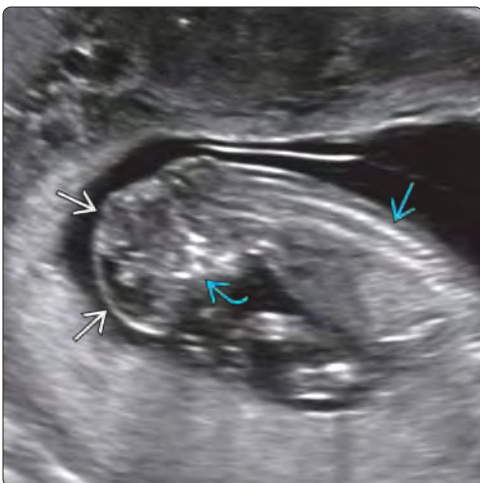


Abnormal Embryo or Fetus

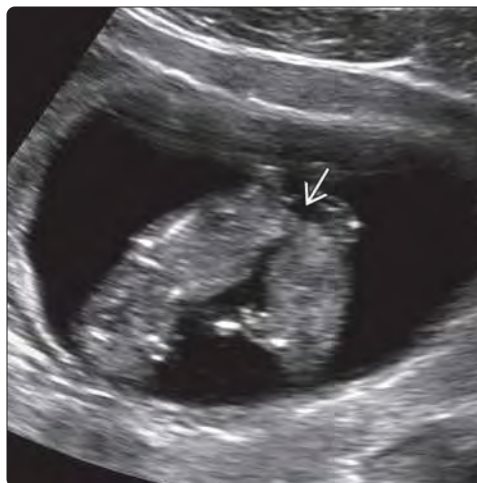

(Left) Coronal US at the time of nuchal translucency measurement shows fixed scoliosis and a limb reduction defect involving the right upper extremity. (Right) Sagittal US in the same patient shows an abnormal flat profile, abnormal fluid in the developing brain, and possible proboscis. Other findings included facial cleft and single orbit. The pregnancy was terminated; chromosomes were normal. With careful scanning, many anomalies can be diagnosed in the 1st trimester.

Abnormal Embryo or Fetus



Abnormal Embryo or Fetus



(Left) Sagittal US at 12-weeks gestational age (GA) shows lack of normal calvarium. Note the facial and spine bones are easily visible. This is acalvaria. The exposed brain is subject to direct trauma with the end result of anencephaly, which is lethal. (Right) TAUS performed at 11-weeks GA to follow-up known monoamnioticity shows conjoined twins with contiguous tissue bridge at the level of the pelvis. This pregnancy ended in intrauterine demise early in the 2nd trimester.

DIFFERENTIAL DIAGNOSIS

Common

- **Ovarian**
 - Corpus Luteum Cyst
 - Hemorrhagic Cyst
 - Teratoma (Dermoid)
 - Endometrioma
 - Theca Lutein Cysts
- **Nonovarian Adnexal Masses**
 - Paraovarian Cyst
 - Pedunculated Fibroid
 - Ectopic Pregnancy
 - Hydrosalpinx
 - Tuboovarian Abscess
- **Adnexal Mass Mimics**
 - Stool-Filled Colon
 - Other Soft Tissue "Masses"
 - Adenopathy
 - Pelvic Kidney

Rare but Important

- **Ovarian Neoplasms**
 - Cystadenoma
 - Epithelial Ovarian Carcinoma
 - Sex-Cord Stromal Tumor

ESSENTIAL INFORMATION

Key Differential Diagnosis Issues

- Adnexa should be routinely evaluated during pregnancy
 - Usually with transvaginal ultrasound in 1st trimester
 - Adnexal masses diagnosed in up to 5% of pregnancies
 - Identify and characterize ovaries
 - If not visible in pelvis, use transabdominal approach
 - Ovary can be displaced by large associated mass or torsion
 - If mass present, characterize as ovarian vs. paraovarian in location
- Ovarian mass
 - Cystic ovarian mass usually related to corpus luteum
 - Most often simple cyst of varying sizes
 - Can be complicated (hemorrhagic) or even solid appearing
 - If large (> 5 cm) but sonographically benign in appearance, consider close follow-up and postpartum ultrasound to exclude benign ovarian tumor
 - Corpus luteum cyst should completely regress or decrease in size by fetal anatomy scan mid 2nd trimester
 - Incidental solid ovarian mass most often dermoid
 - Most have classic appearance
 - May be bilateral
 - If ovarian mass is suspicious with cystic and solid components, consider removal during pregnancy
 - Usually early 2nd trimester
- Paraovarian cysts will not change over time and may have been seen on prior pelvic ultrasounds
- If in right lower quadrant, assess for appendicitis/appendiceal abscess
- Adnexal mass in 1st trimester
 - Could this be ectopic or heterotopic pregnancy?
 - Correlate with any history of in vitro fertilization (IVF) or reproductive assistance

Helpful Clues for Common Diagnoses

- **Corpus Luteum Cyst**
 - May be anechoic or complicated from hemorrhage
 - Can have thick, vascular, hyperechoic cyst wall
 - Look for claw sign to prove it is intraovarian
 - Moves with ovary with transducer pressure
 - Ovarian ectopic pregnancy is exceedingly rare
 - Should decrease in size over pregnancy
 - Most commonly significantly smaller by 2nd trimester
 - Placental progesterone production takes over
 - Allows for obliteration of corpus luteum cyst
 - Some functional cysts may persist
 - Can follow expectantly if no malignant features
 - Postpartum pelvic ultrasound to exclude benign ovarian neoplasm
 - Check for any prior pelvic ultrasounds to see if present before pregnancy
- **Hemorrhagic Cyst**
 - Lacy, thin, echogenic fibrin strands are characteristic
 - May have clot retraction with angular/concave margins
 - Avascular
 - Decreases in size on follow-up as blood products resorb
- **Teratoma (Dermoid)**
 - Most common incidental ovarian mass seen in pregnancy
 - 10% bilateral
 - May have hair, teeth, and osseous structures, which gives characteristic complex sonographic appearance
 - Dermoid plug often present
 - Echogenic keratin "plug"
 - Posterior acoustic shadowing
 - If large, risk of ovarian torsion
- **Endometrioma**
 - Homogeneous, low-level echoes with increased through transmission
 - Echogenic foci in wall of cyst are most specific finding
 - Represent cholesterol crystals
 - May have ring-down artifact
 - Most remain stable, but may become decidualized in pregnancy
 - Increased progesterone levels promote hypertrophy of endometrial stromal cells
 - Creates vascular mural nodule, which can mimic carcinoma
 - Will spontaneously regress after delivery
 - Consider diagnosis if prior documentation of endometrioma
- **Theca Lutein Cysts**
 - Multiple cysts within enlarged ovaries bilaterally
 - May see typical spoke-wheel appearance
 - Occasionally unilateral
 - Reaction of ovaries to elevated hormone levels
 - Multiple gestation pregnancies
 - Assisted reproduction patients
 - Rarely singleton pregnancy with underlying high level of β -hCG
 - Associated pregnancy may be abnormal

- Complete hydatidiform mole
- Triploidy (partial mole): Multiple fetal anomalies, growth restriction
- Hydrops: Skin edema, ascites, pleural effusions
- Look for signs of hyperstimulation syndrome
 - Maternal effusions, ascites, oliguria
 - Seen in setting of IVF due to hormonal stimulation
 - May occur before intrauterine pregnancy identified
- **Paraovarian Cyst**
 - Located in broad ligament
 - Nonvascular, anechoic cyst
 - Does not change in size with hormonal fluctuations
 - Use gentle transducer pressure to show it separate from ovary
- **Pedunculated Fibroid**
 - Attached somewhere to uterine wall even if exophytic or pedunculated
 - Look for bridging myometrium/uterine vessels
 - Can be very heterogeneous if degeneration present
 - Red degeneration associated with infarction/hemorrhage
 - Cystic degeneration can appear anechoic
 - May present with acute pain
- **Ectopic Pregnancy**
 - Empty uterus with extrauterine gestational sac ± yolk sac/embryo
 - Should be clearly distinct from ovary; moves away from ovary with transducer pressure
 - Tubal ring sign with increase flow
 - May only see heterogeneous adnexal mass from hematoma
 - Echogenic free fluid often seen but nonspecific
- **Hydrosalpinx**
 - Dilated, fluid-filled fallopian tube
 - Folded configuration with C- or S-shape
 - Incomplete septations
 - Cogwheel sign: Longitudinal folds within tube have nodular appearance when viewed in cross section
- **Tuboovarian Abscess**

- More complicated-appearing dilated tube; may have fluid-debris level
- Consider ruptured appendix if in right lower quadrant
- **Stool-Filled Colon**
 - Occasionally echogenic stool within colon can mimic dermoid plug
 - Should have typical bowel wall appearance at periphery with gut signature
 - Will change position/shape at different time points
- **Other Soft Tissue "Masses"**
 - Adenopathy along pelvic sidewall
 - Pelvic kidney
 - May be dysmorphic or small
 - Check ipsilateral renal fossa

Helpful Clues for Rare Diagnoses

- **Cystadenoma**
 - Serous: Unilocular anechoic cyst, thin septations
 - Mucinous: Hypoechoic with internal mucin, more often multilocular with thicker septations
- **Epithelial Ovarian Carcinoma**
 - Complex cystic ovarian mass
 - Vascular, thick septations and mural nodules
 - Look for ascites or other indications of peritoneal spread
- **Sex-Cord Stromal Tumor**
 - Solid, homogeneous ovarian mass
 - May be hormonally active

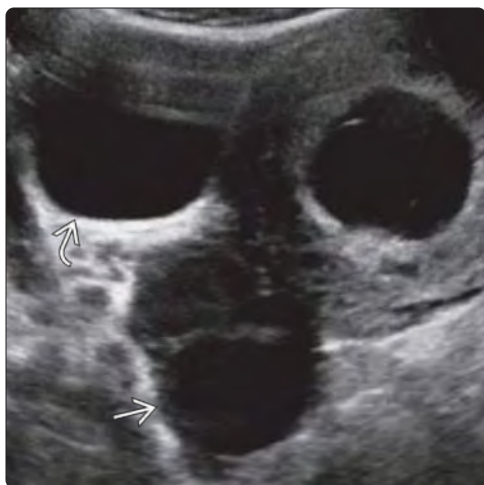Other Essential Information

- Be sure to define origin of mass for more accurate differential (ovarian, extraovarian, uterine)
- If patient has had hormonal manipulation &/or IVF, always consider possible heterotopic pregnancy

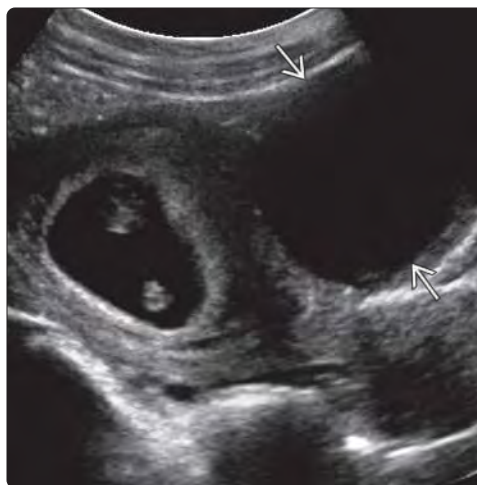SELECTED REFERENCES




1. de Haan J et al: Management of ovarian cysts and cancer in pregnancy. *Facts Views Vis Obgyn.* 7(1):25-31, 2015
2. Mukhopadhyay A et al: Ovarian cysts and cancer in pregnancy. *Best Pract Res Clin Obstet Gynaecol.* pii: S1521-6934(15)00199-6, 2015

Corpus Luteum Cyst



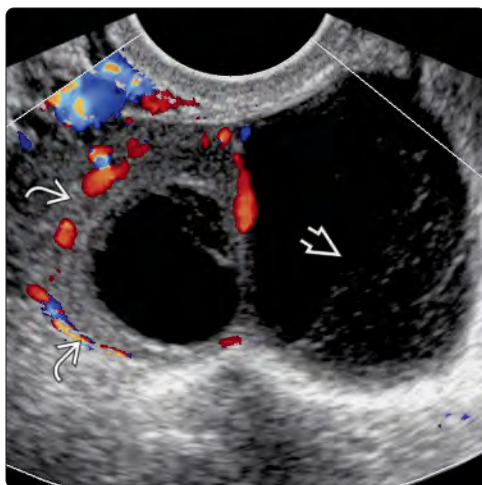
Corpus Luteum Cyst



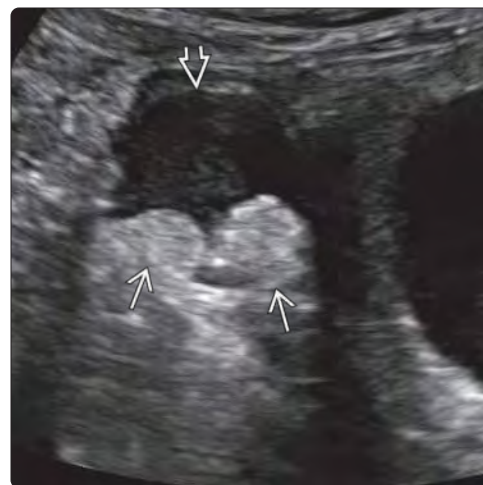
(Left) In the 1st trimester, the corpus luteum cyst  supports the pregnancy with progesterone production. The bladder  can mimic a cystic adnexal mass on a single image but should be anterior to the uterus on real-time imaging. (Right) Corpus luteum cysts can be quite large . Unless suspicious features are present to suggest a malignant lesion, follow-up in the 2nd trimester at the time of fetal anatomy scan should show a significant decrease in size.

Hemorrhagic Cyst

(Left) A typical corpus luteum has a thick, vascular, hyperechoic cyst wall. In this case, an adjacent thin-walled hemorrhagic cyst is also present, with layering reticular echoes consistent with blood products. (Right) This fat-containing adnexal mass is consistent with a dermoid. At times, the echogenic Rokitansky nodules appear to layer dependently in the otherwise cystic dermoid fluid.

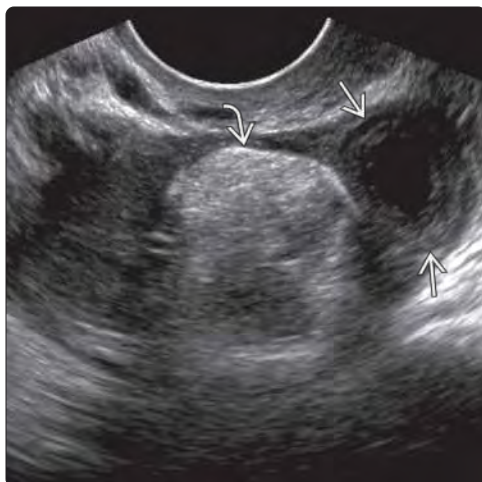


Teratoma (Dermoid)

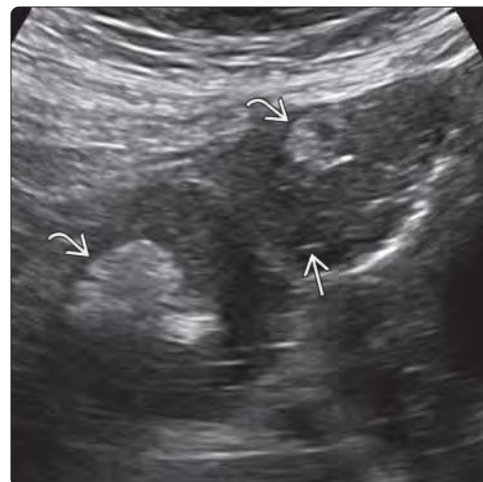


Teratoma (Dermoid)

(Left) Occasionally, an echogenic, solid-appearing dermoid can be seen in the same ovary as the thick-walled corpus luteum cyst. (Right) Dermoids are often complex in appearance, with echogenic plugs as well as linear echoes, consistent with hair. 10-20% of dermoids are bilateral.

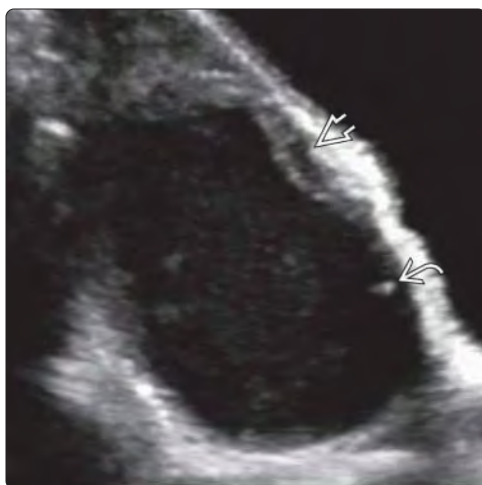

Teratoma (Dermoid)

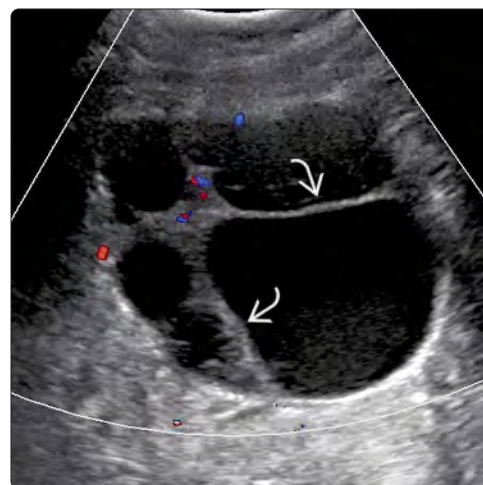


Endometrioma

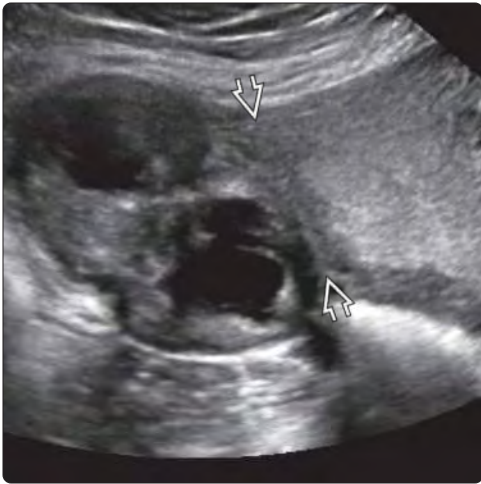
(Left) This ovarian cyst has diffuse low-level internal echoes with a punctate echogenicity in the cyst wall, characteristic of an endometrioma. Mild wall thickening may be present. Rarely, an endometrioma can become decidualized in pregnancy and mimic a tumor. (Right) Separated by thin nonvascular septa in a spoke-wheel orientation, theca lutein cysts during pregnancy can be seen in association with exogenous hormones, multiple gestations, hydrops, and gestational trophoblastic disease.



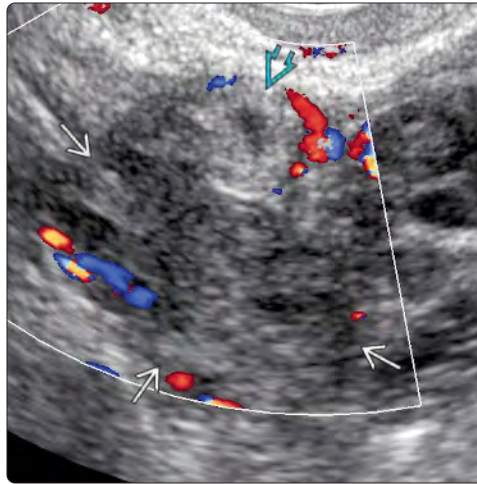
Theca Lutein Cysts






Pedunculated Fibroid

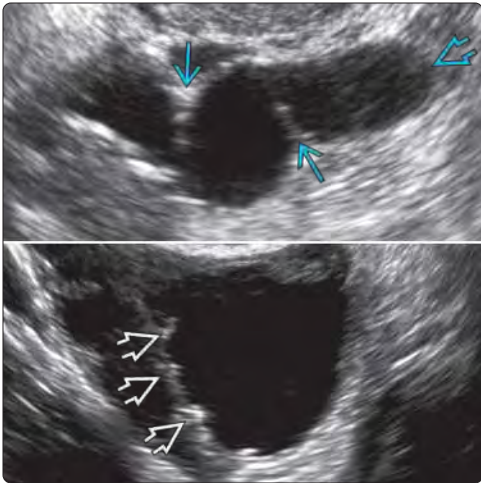


Ectopic Pregnancy

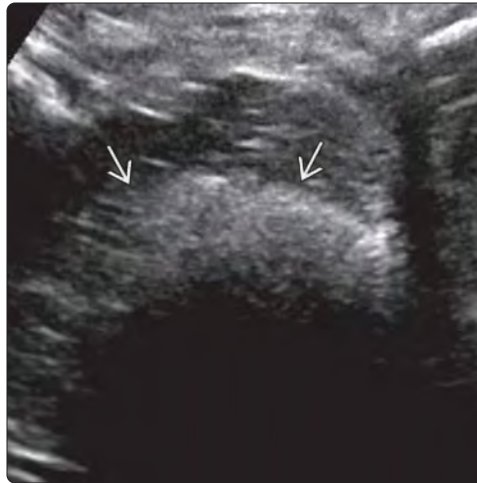






(Left) This 7-cm complex cystic adnexal mass is actually a degenerated pedunculated fibroid. Note the bridging myometrium , confirming it is from the uterus, not the ovary. The patient presented with significant right-sided pain. **(Right)** In this patient with 1st-trimester bleeding, there is a tubular ring sign  in the right adnexa next to the ovary , with peripheral vascularity. No sac was seen in the uterus and curettage showed no chorionic villi. The appearance is consistent with an ectopic pregnancy.

Hydrosalpinx

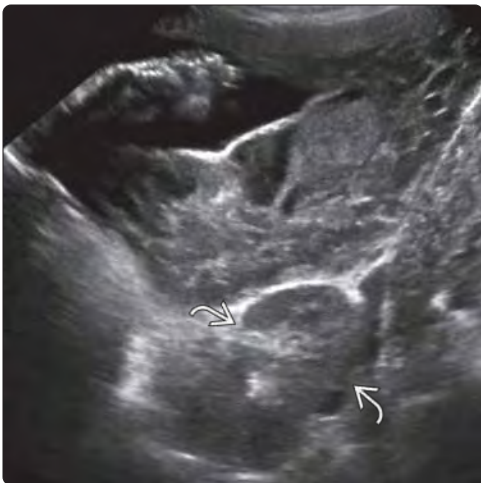

Stool-Filled Colon

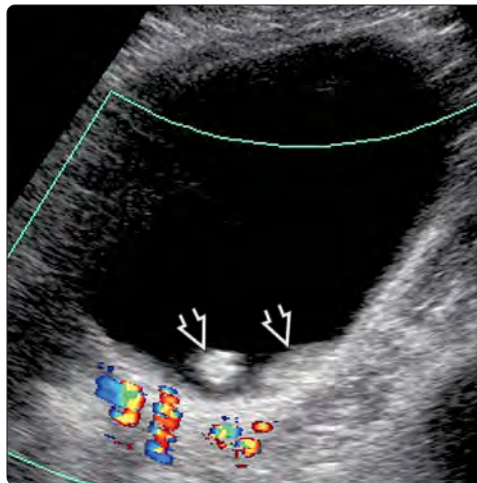




(Left) This composite shows features of a hydrosalpinx in longitudinal (top) and cross-sectional (bottom) views. You should always try to elongate any cystic mass to see if it has a tubular configuration; note it is blind-ending  and there are incomplete septa . In cross section, a cogwheel appearance is created by the endosalpingeal folds . **(Right)** Occasionally, the stool-filled colon will appear as an echogenic "mass" , suggestive of a large dermoid. Turning the probe 90° should show elongation of the mass into bowel.

Pelvic Kidney



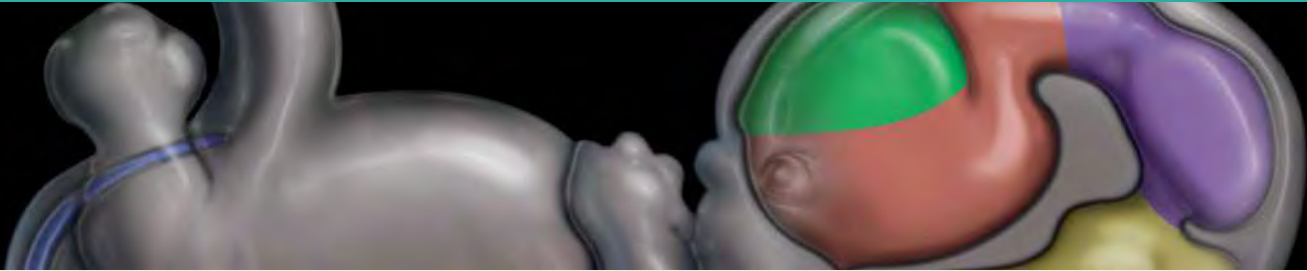Cystadenoma



(Left) Occasionally, unusual incidental adnexal masses can be identified at the time of the anatomy ultrasound. In this case, a maternal right pelvic kidney was seen . Renal anomalies can be familial. **(Right)** Close evaluation of the ovarian cyst wall is warranted, especially when large. In this 8-cm serous tumor with a borderline component, there are subtle soft tissue nodules . If there is low suspicion for epithelial ovarian cancer, some masses can be followed until after delivery.

SECTION 2

Brain



Introduction and Overview

Embryology and Anatomy of the Brain	68
Approach to the Supratentorial Brain	84
Approach to the Posterior Fossa	90

Cranial Defects

Exencephaly, Anencephaly	96
Occipital, Parietal Cephalocele	100
Atretic Cephalocele	104
Frontal Cephalocele	106

Midline Developmental Anomalies

Agensis/Dysgenesis of the Corpus Callosum	108
Interhemispheric Cyst/AVID	112
Aprosencephaly, Atelencephaly	116
Alobar Holoprosencephaly	118
Semilobar Holoprosencephaly	122
Lobar Holoprosencephaly	124
Septo-Optic Dysplasia	126
Syntelencephaly	130

Cortical Developmental Anomalies

Schizencephaly	134
Lissencephaly	138
Gray Matter Heterotopia	142
Pachygyria, Polymicrogyria	144

Cysts

Choroid Plexus Cyst	148
Arachnoid Cyst	150

Destructive Lesions

Intracranial Hemorrhage	154
Encephalomalacia, Porencephaly	158
Hydranencephaly	162

Posterior Fossa Malformations

Aqueductal Stenosis	164
Chiari 2 Malformation	168
Chiari 3 Malformation	172
Dandy-Walker Malformation	174
Vermian Dysgenesis	178
Blake Pouch Cyst	180
Mega Cisterna Magna	184
Cerebellar Hypoplasia	186
Rhombencephalosynapsis	190

Vascular Malformations

Vein of Galen Aneurysmal Malformation	194
Arteriovenous Fistula	198
Dural Sinus Malformation	200

Tumors

Brain Tumors	202
Choroid Plexus Papilloma	204
Intracranial Lipoma	206

Pertinent Differential Diagnoses

Absent Cavum Septi Pellucidi	208
Mild Ventriculomegaly	212
Abnormal Calvarium	216
Posterior Fossa Cyst/Fluid Collection	222

TERMINOLOGY

Definitions

- Rostral: Cranial (i.e., toward head end of embryo)
- Caudal: Tail (i.e., toward sacral end of embryo)

MAJOR EMBRYOLOGIC EVENTS

Neurulation

- Ectodermal cells give rise to dorsal, midline neural plate
 - Neural folds develop then fuse → neural tube + neural crest
- **Neural tube** → brain, spinal cord
- **Neural crest** → peripheral nerves, autonomic nervous system
- **Errors in neurulation**
 - Anencephaly
 - Cephalocele
 - Myelomeningocele
 - Chiari 2: Abnormal neurulation of hindbrain

Neuronal Proliferation

- Begins in rhombencephalon; neuroepithelial proliferation → neurons, glial cells, ependymal cells
 - Neurons "born" in ventricular zone (around central lumen) are called young neurons
 - Migrate peripherally to form mantle zone (i.e., gray matter precursor)
 - Axons extending peripherally to mantle zone establish marginal zone (i.e., white matter precursors)
 - White matter is outside, gray matter is inside
 - Glioblast cells → astrocytes, oligodendrocytes
 - Provide metabolic/structural support to neurons
 - Ependymal cells line ventricles/spinal canal
 - Produce cerebrospinal fluid
- **Errors in neuronal proliferation**
 - Holoprosencephaly
 - Agenesis of corpus callosum
 - Pituitary maldevelopment
 - Dandy-Walker malformation
 - Rhombencephalosynapsis

Histogenesis

- Process of proliferation, migration, differentiation → development of mature cerebral cortex
- Unique difference between **cerebral hemisphere neuroepithelium** and that of other parts of neural tube
 - Made up of several layers (6 in dominant neocortex)
 - Inside-out arrangement of gray/white matter
 - Unlike rest of CNS, cerebral hemispheres have white matter inside and gray matter outside
 - Mechanism poorly understood
- Specialized neurogenesis in cerebellum → gray matter of cerebellar cortex/deep cerebellar nuclei
- **Errors in histogenesis**
 - Abnormal histogenesis of periaqueductal gray matter is 1 cause of aqueduct stenosis

Neuronal Migration

- Peak activity at 11-15 weeks
 - Majority of neurons in correct location by 24 weeks
 - Migration continues up to 35 weeks

- Newly proliferated cells migrate along predetermined pathways of radial glial fibers → organized cortical layering
 - Inside-out pattern of 6 layers with newest arrivals "outside" those that migrated earlier
 - Process governed by multiple genes, circulating factors
- **Errors in migration**
 - Microcephaly
 - Megalencephaly
 - Heterotopia
 - Cortical dysplasia
 - Lissencephaly: Arrested neuronal migration
 - Phakomatoses

Myelination

- Can be detected as early as 20 weeks
- Occurs in orderly, predictable manner
 - Caudal → cranial, deep → superficial, posterior → anterior
- Continues into adulthood

Operculization

- Development of insular cortex and infolding of sylvian fissures
- During weeks 11-28
- **Errors in operculization**
 - Defective speech and language processing

Gyral and Sulcal Development

- Occurs earlier in vivo than can be detected by current imaging modalities
 - 4- to 6-week time lag before structures become visible by imaging
- Gestational age by which sulcus/fissure should always be seen
 - Callosal: US 14 weeks, MR 22 weeks
 - Sylvian: US 18 weeks, MR 24 weeks
 - Parietooccipital: US 18 weeks, MR 22-23 weeks
 - Calcarine: US 18 weeks, MR 22-23 weeks
- Continues through end of 35th week

CEREBRUM, CEREBELLUM, AND VENTRICLES

Cerebral Hemispheres

- **Notochord development**
 - Bilaminar germ disc evolves into trilaminar germ disc with ectoderm, mesoderm, endoderm
 - Mesoderm forms midline, hollow, central tube: Notochordal process
 - Notochordal process evolves into solid notochord
 - Notochord + mesoderm induce formation of neural plate
 - Neural plate grows in length and width until day 21 when neurulation begins
- Formation of **neural tube** (primary neurulation)
 - Neural plate folds elevate, forming trough (neural groove) between them
 - Neural folds fuse → neural tube
 - Neural crest cells (derived from neuroectoderm) split from neural tube as it fuses
 - Neural tube temporarily open at both ends; openings are called neuropores
 - Rostral 2/3 of neural tube → brain
 - Caudal 1/3 of neural tube → spinal cord, nerves

- Bidirectional closure begins at occipitocervical level
 - Rostral/cranial neuropore closes at day 24
 - Caudal/sacral neuropore closes at day 25
- **Primary vesicles** form by middle of 4th week
 - **Prosencephalon** (forebrain)
 - **Mesencephalon** (midbrain)
 - **Rhombencephalon** (hindbrain)
- **Secondary vesicles** form during 5th week
 - Prosencephalon → anterior telencephalon + posterior diencephalon
 - **Diencephalon** → hypothalamus, thalamus, posterior pituitary, eyes
 - **Telencephalon** → cerebral hemispheres (by sagittal cleavage), basal ganglia
 - Rhombencephalon → anterior metencephalon + posterior myelencephalon
 - **Metencephalon** → pons + cerebellum
 - **Myelencephalon** → medulla oblongata
- Tube elongates at same times as vesicles form; flexures develop at specific locations
 - **Midbrain (mesencephalic) flexure**
 - **Cervical flexure** at junction of brainstem with spinal cord
 - **Pontine flexure** develops between midbrain and cervical flexures
- **Cerebral hemispheres** formed by 11th week
 - Arise as lateral outpouchings of telencephalon
 - Grow rapidly to cover diencephalon, mesencephalon
- Cerebral hemispheres connected by **lamina terminalis** ("zip" of cranial neuropore closure)
 - Thickening of lamina terminalis at rostral end → lamina reuniens + massa commissuralis
 - Lamina reuniens → anterior commissure
 - Massa commissuralis → corpus callosum, hippocampal commissure
 - Hippocampal commissure merges with splenium of corpus callosum
 - **Corpus callosum** should be complete by 20 weeks
 - Composed of 4 parts, from front to back these are **rostrum, genu, body, splenium**

Cerebellum

- Thickening of alar plate of rhombencephalon → rhombic lips
- Rhombic lips → cerebellar hemispheres by intense neuronal proliferation
- Rhombic lips fuse → cerebellar commissures in roof of 4th ventricle
- **Cerebellar hemispheric fusion starts cranially**, forming flocculi of hemispheres and nodulus of vermis in 9th week
 - **Proliferation and fusion continue caudally** until complete by 15th week
- Flocculonodular fissure separates flocculi of hemispheres and nodulus of vermis

Ventricles

- Cavities within brain vesicles → ventricles during weeks 4-12
 - **Lateral ventricles** develop as diverticula from telencephalic primitive ventricle
 - **3rd ventricle** develops from cavity of diencephalon
 - **4th ventricle** develops from cavity of rhombencephalon

- Foramina of Monro connect lateral ventricle to 3rd ventricle
- **Aqueduct of Sylvius** connects 3rd to 4th ventricles
 - Develops from cavity of mesencephalon
- Vessels from diencephalon and myelencephalon invade ventricular walls → **choroid plexus**
- **4th ventricle roof**
 - Highly complex area
 - Ridge of developing choroid plexus divides roof → anterior and posterior membranous areas
 - Anterior superior part incorporated into choroid plexus
 - Posterior inferior persists, midline cavitation → foramen of Magendie

IMAGING ISSUES

Protocol Advice

- Ultrasound
 - Use highest resolution transducer possible
 - 3D volume acquisition allows manipulation of dataset to "create" true orthogonal image planes
 - Use color Doppler to evaluate course of marker vessels
- Magnetic resonance imaging
 - Use fast sequences with single slice rather than volume acquisition
 - Diffusion tensor imaging can be performed for tractography
 - T2WI for global anatomy
 - T1WI for blood, fat, myelination

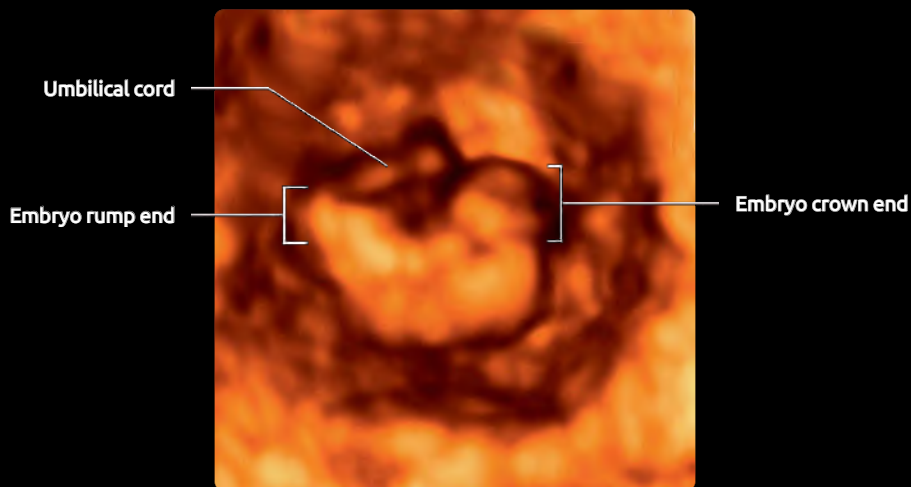
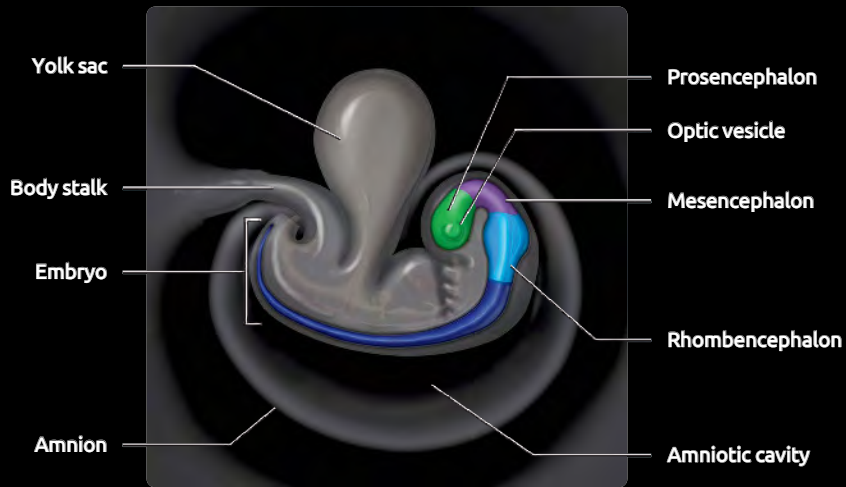
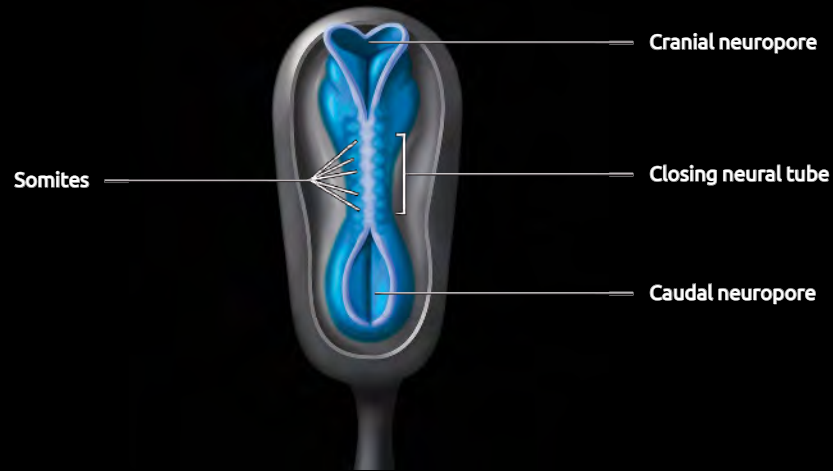
Imaging Pitfalls

- Normal structures mistaken for pathology
 - Yolk sac confused with cephalocele
 - Rhombencephalic vesicle confused with posterior fossa cyst
 - Corner of ventricular atrium mistaken for choroid plexus cyst
 - Fornices mistaken for cavum septi pellucidi
- Subtle lesions that may be missed if normal development not understood
 - Absent cavum septi pellucidi
 - Heterotopia
 - Lissencephaly
 - Cortical dysplasia
- Posterior fossa
 - Rotation of vermis may be mistaken for vermian dysgenesis
 - Rhombencephalosynapsis may be confused with cerebellar hypoplasia

SELECTED REFERENCES

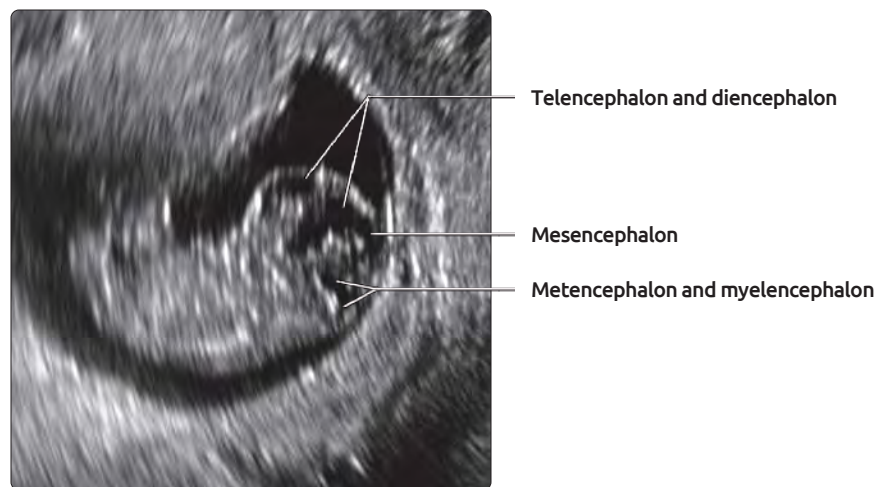
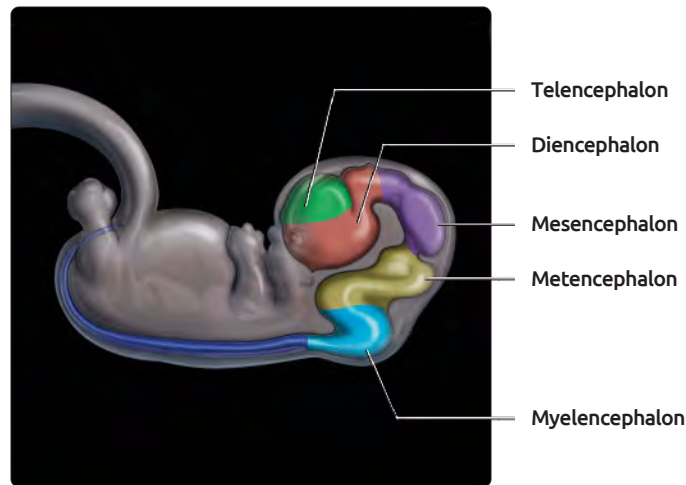
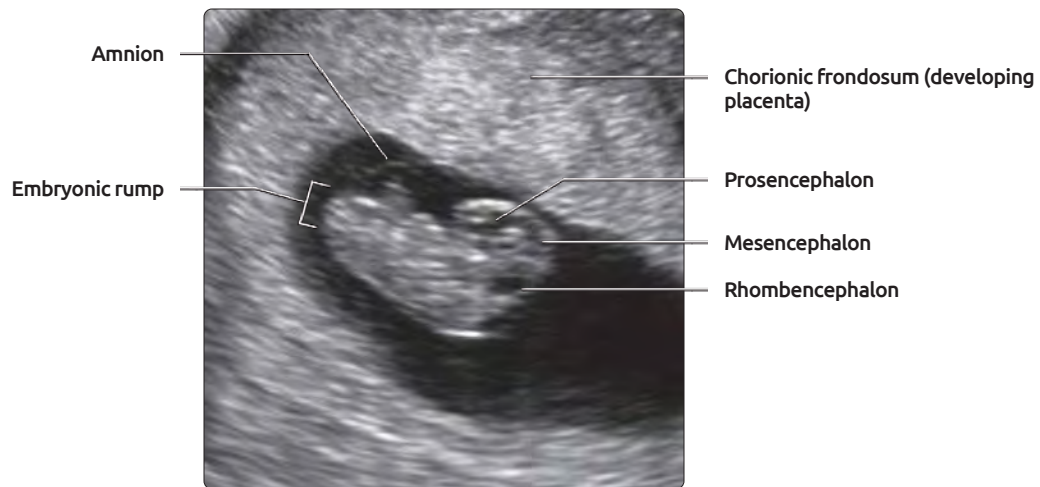
1. Pooh RK et al: Novel application of three-dimensional HDlive imaging in prenatal diagnosis from the first trimester. *J Perinat Med.* 43(2):147-58, 2015
2. Blaas HG: Detection of structural abnormalities in the first trimester using ultrasound. *Best Pract Res Clin Obstet Gynaecol.* 28(3):341-53, 2014
3. Pooh RK et al: Imaging of the human embryo with magnetic resonance imaging microscopy and high-resolution transvaginal 3-dimensional sonography: human embryology in the 21st century. *Am J Obstet Gynecol.* 204(1):77.e1-16, 2011
4. Kim MS et al: Three-dimensional sonographic evaluations of embryonic brain development. *J Ultrasound Med.* 27(1):119-24, 2008

1ST-TRIMESTER EMBRYO



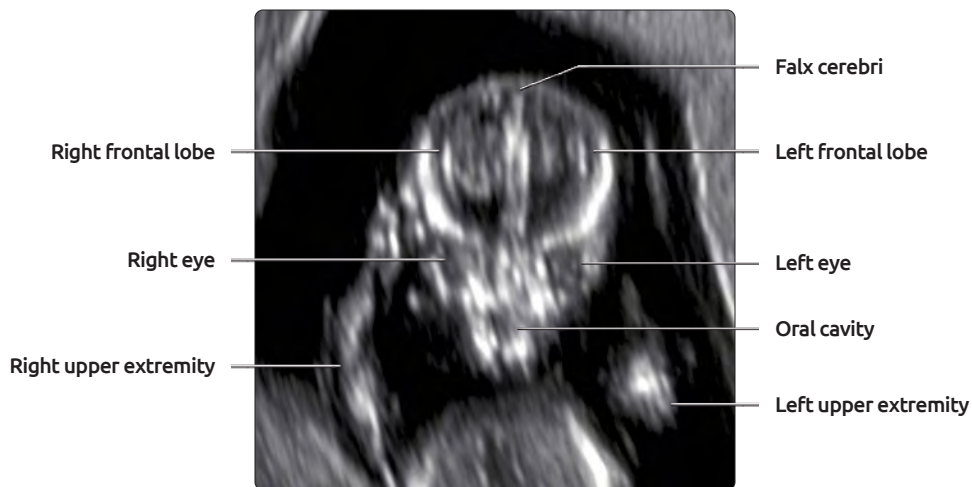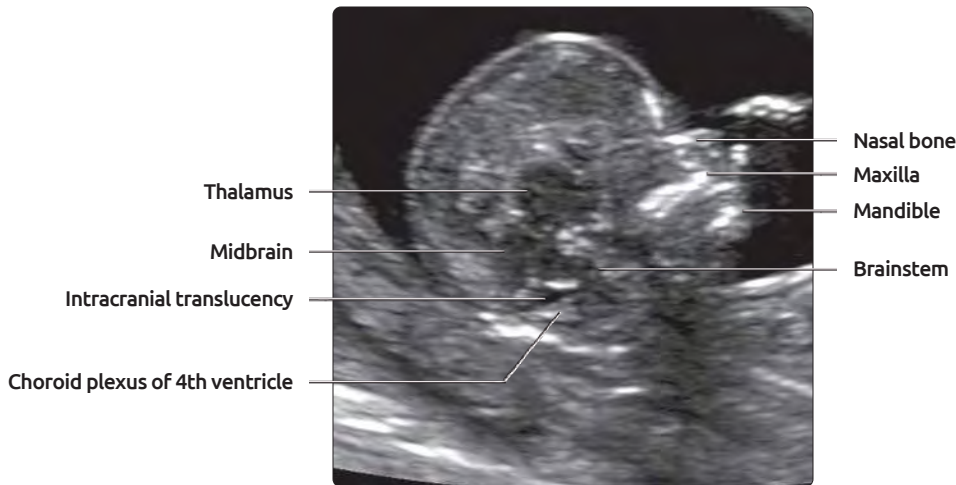
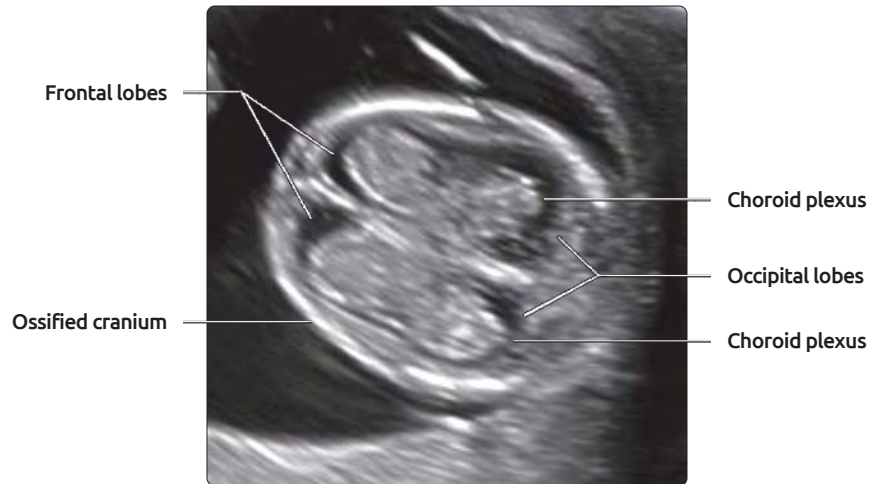(Top) The neural tube closes in a bidirectional manner. The cranial neuropore closes at day 24, while the caudal neuropore closes at day 25. **(Middle)** A series of vesicles develop at the same time the head end of the embryo enlarges and the flat embryonic disc becomes curved in profile and tubular in cross section. These are the precursors to the adult brain. The prosencephalon (green) gives rise to the forebrain, the mesencephalon (purple) to the midbrain, and the rhombencephalon (light blue) to the hindbrain. **(Bottom)** Surface-rendered 3D ultrasound of a 7-week embryo shows the external contour with a recognizable head end. The abdominal wall has closed, the yolk sac has detached, and the umbilical cord has formed. The torso is relatively small, the limb buds have not yet developed, but as shown above, the neural tube within it has already developed the precursors to the forebrain, midbrain, and hindbrain.

1ST-TRIMESTER EMBRYO



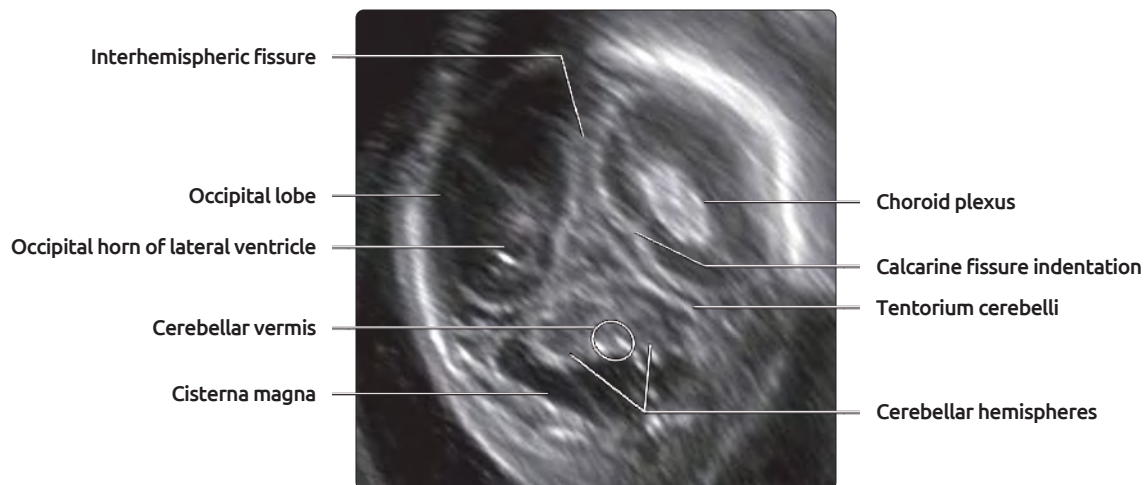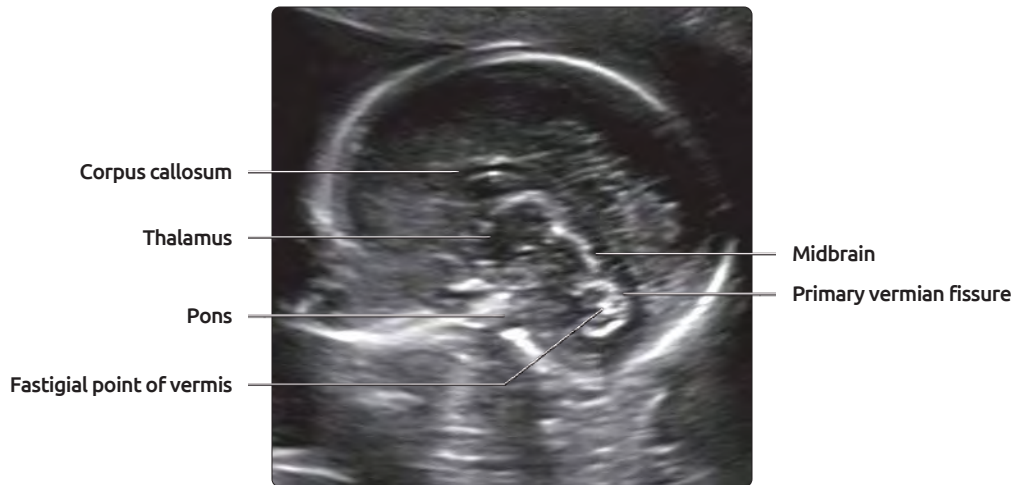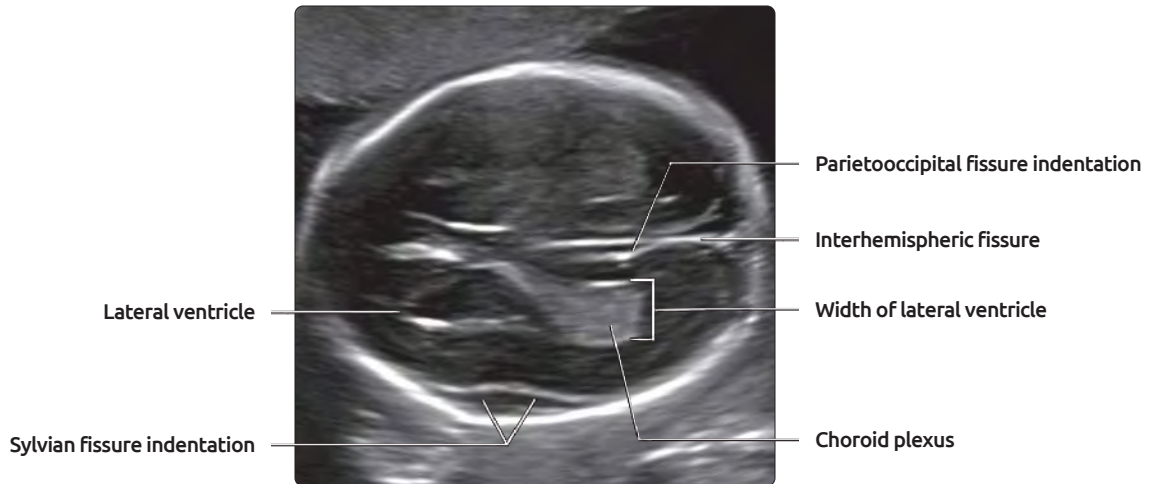
(Top) This is a vaginal ultrasound of an 8-week, 2-day embryo in which the primitive brain vesicles are visible. This is a normal finding with high-resolution modern equipment and should not be mistaken for holoprosencephaly or other brain malformation. **(Middle)** With further embryonic growth, the prosencephalon gives rise to secondary vesicles known as the telencephalon and diencephalon. The mesencephalon elongates, while the rhombencephalon gives rise to the secondary vesicles, metencephalon, and myelencephalon. At this point, several flexures develop in the neural tube so that it adapts to the contour of the developing cranium. **(Bottom)** Another midline sagittal scan of a slightly older embryo, this time 9 weeks, 6 days, shows further neural tube growth with development of multiple flexures in the lengthening tube so that it adapts to the contour of the developing cranium. Again, it is important to recognize that this is normal for gestational age.

1ST-TRIMESTER FETUS



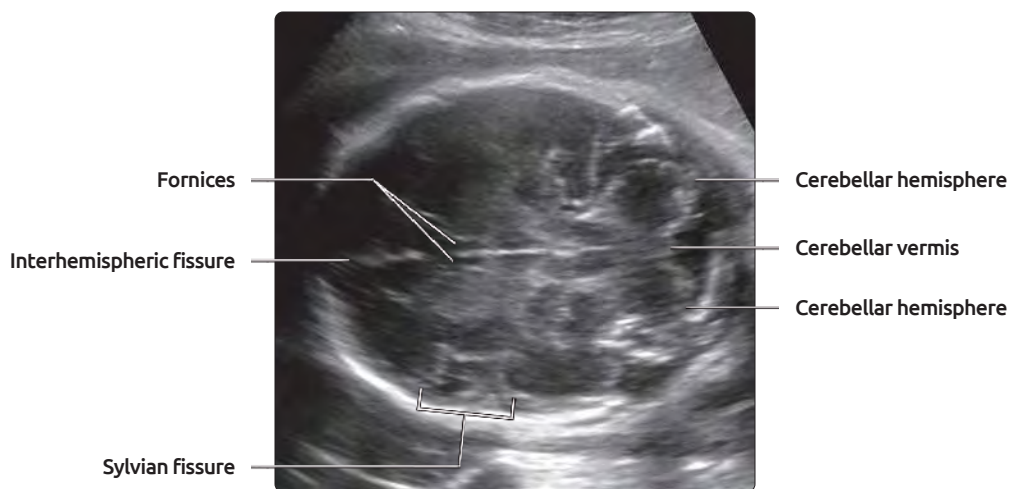
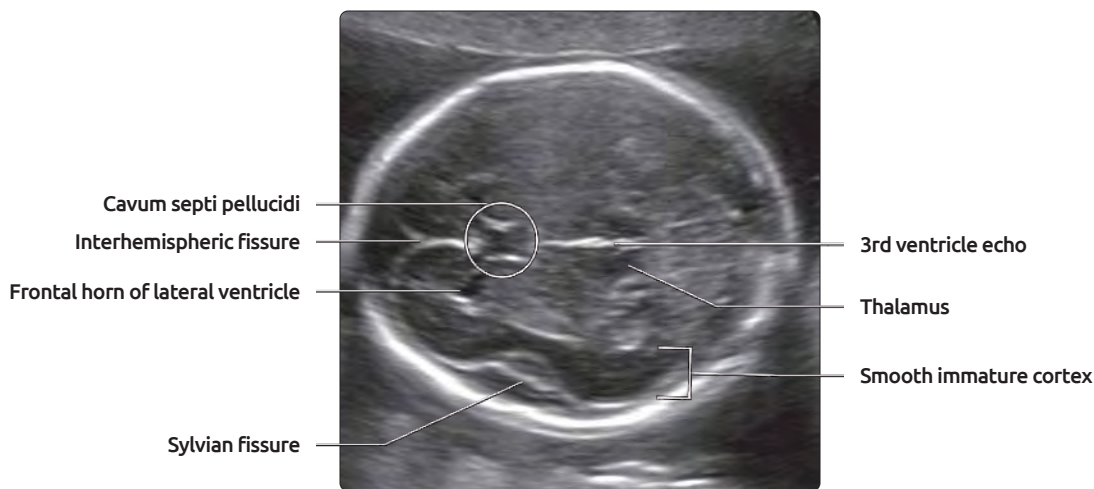
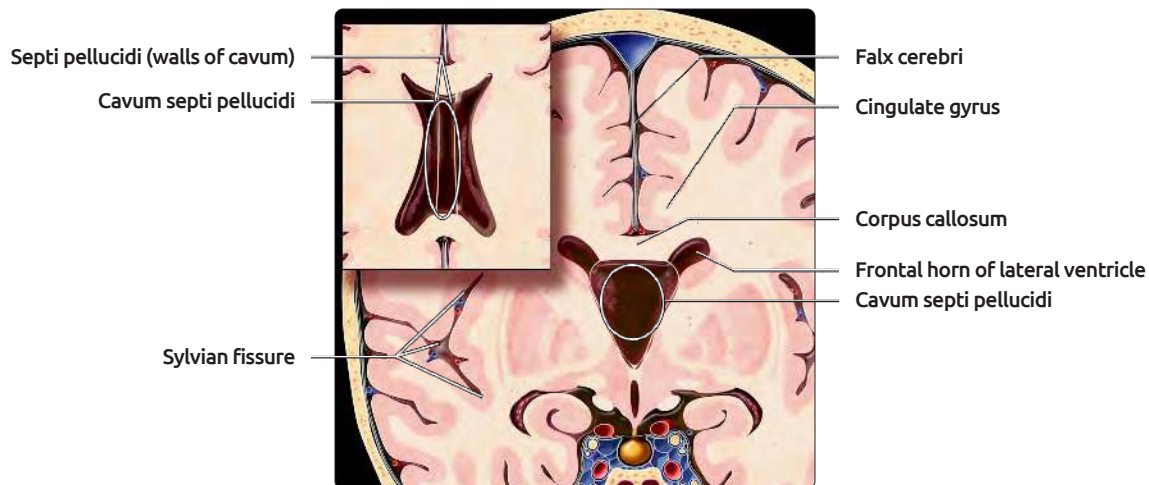
(Top) At 12 weeks, the choroid plexus fills most of the ventricular cavity and the brain parenchyma is thin and smooth. The choroid plexus echogenicity and shape on an axial image gives rise to the butterfly sign in which the choroid forms the butterfly wings. This confirms 2 cerebral hemispheres. **(Middle)** Sagittal abdominal ultrasound at 13 weeks shows a normal thalamus, midbrain, and brainstem. The intracranial translucency (the future 4th ventricle) is seen between the brainstem and the choroid plexus of the 4th ventricle. Intracranial translucency assessment may be used for early detection of open neural tube defects. **(Bottom)** Transabdominal ultrasound at 13 weeks, 1 day shows clear separation of the cerebral hemispheres by the falx cerebri. The ocular globes are visible within the bony orbits and the oral cavity is visible between the bright echoes of the maxilla and mandible.

2ND-TRIMESTER FETUS



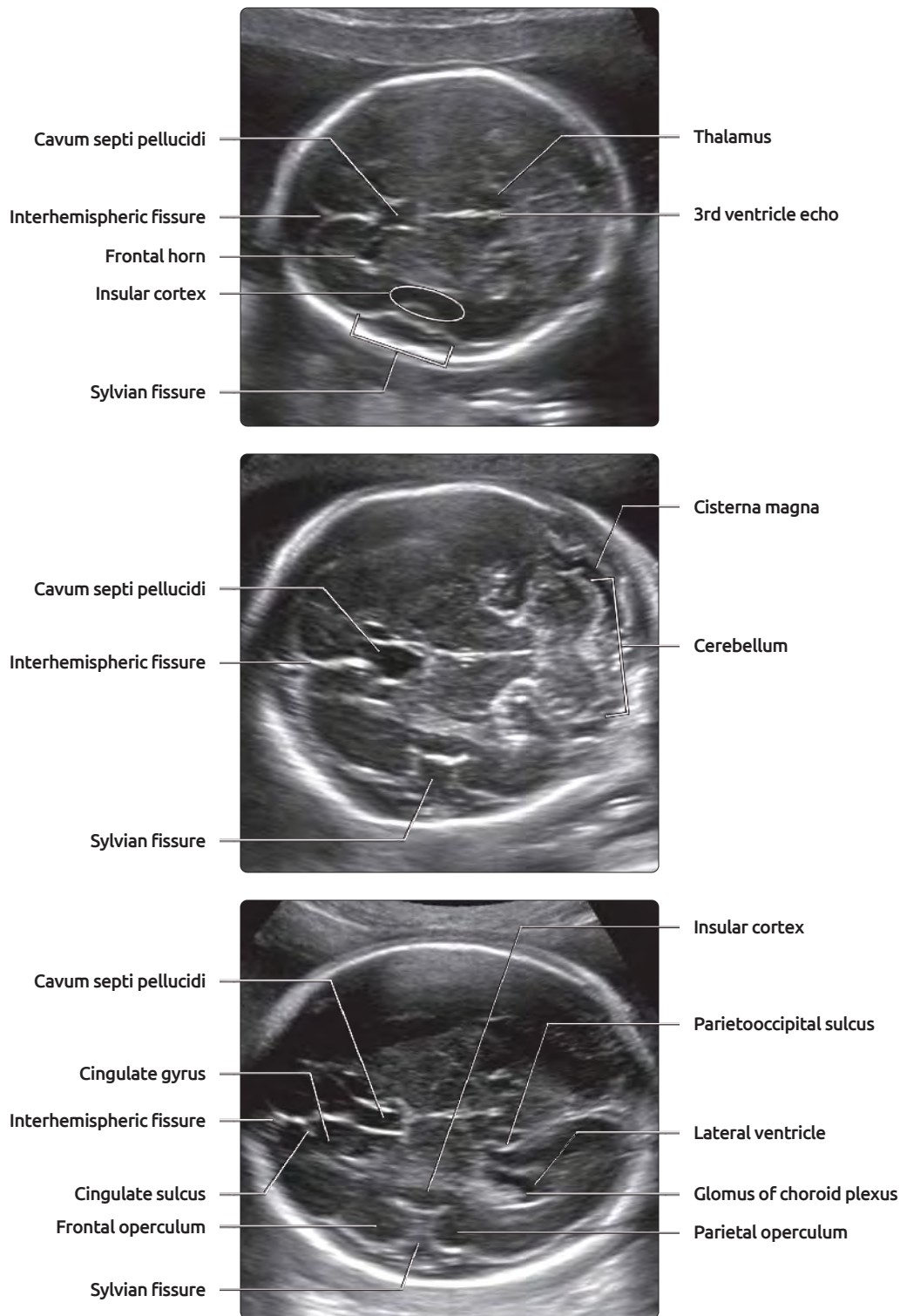
(Top) At 18 weeks, the cerebral mantle is quite smooth with just the earliest "thumb print" indentation for the sylvian fissure and a tiny indentation at the site of the developing parietooccipital fissure. The latter marks the anatomic location at which the width of the lateral ventricle should be measured. **(Middle)** A sagittal transabdominal ultrasound at 20 weeks shows normal midline structures very well. Although not a standard image in a 2nd-trimester scan, this is as easy to obtain as a profile view of the face. **(Bottom)** This coronal image in a 22-week fetus shows another nonstandard, but easily obtainable, view of the fetal brain. Turning the transducer 90° from the standard axial images provides another way to assess symmetry of the hemispheres, ventricles, and the cortical mantle. The cisterna magna cannot be measured in this plane as it is artificially deepened by the extension into the foramen magnum.

CAVUM SEPTI PELLUCIDI



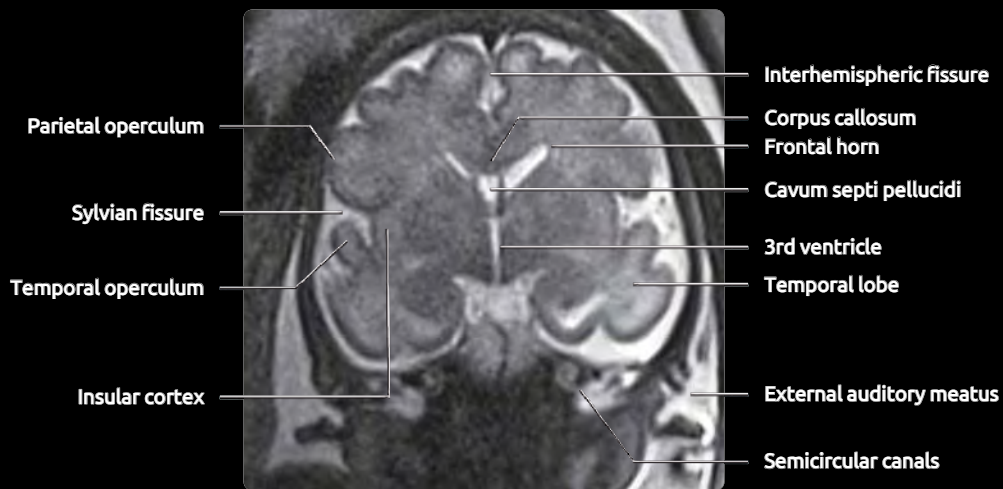
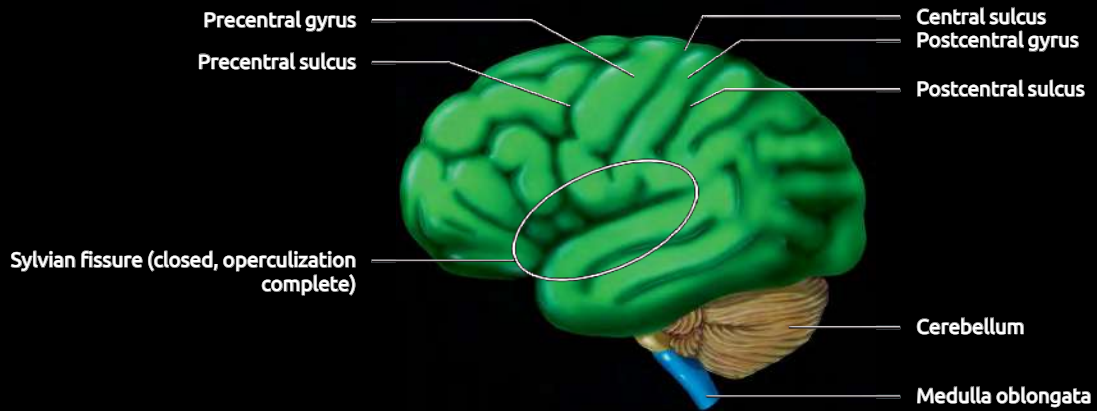
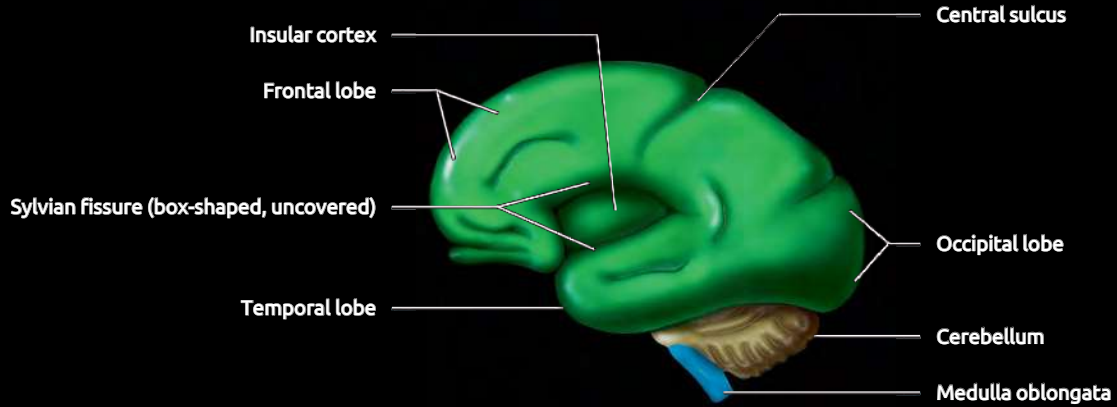
(Top) Coronal graphic (with axial insert) illustrates the cavum septi pellucidi, which is a marker for normal midline brain development. **(Middle)** The cavum should be demonstrated on all routine obstetric scans between 18 and ~37 weeks. It is a box-shaped, anechoic space in the midline between the frontal horns of the lateral ventricles. It can also be seen on coronal views obtained transabdominally or transvaginally. **(Bottom)** A pitfall for the unwary is to confuse the normal fornices with the cavum. The fornices may be normal in a fetus with an absent cavum. They are seen just inferior (toward the skull base) to the normal location of the cavum. They form a series of parallel, black and white lines around the intact midline. The cavum is a box-shaped structure that interrupts the midline echo.

SYLVIAN FISSURE



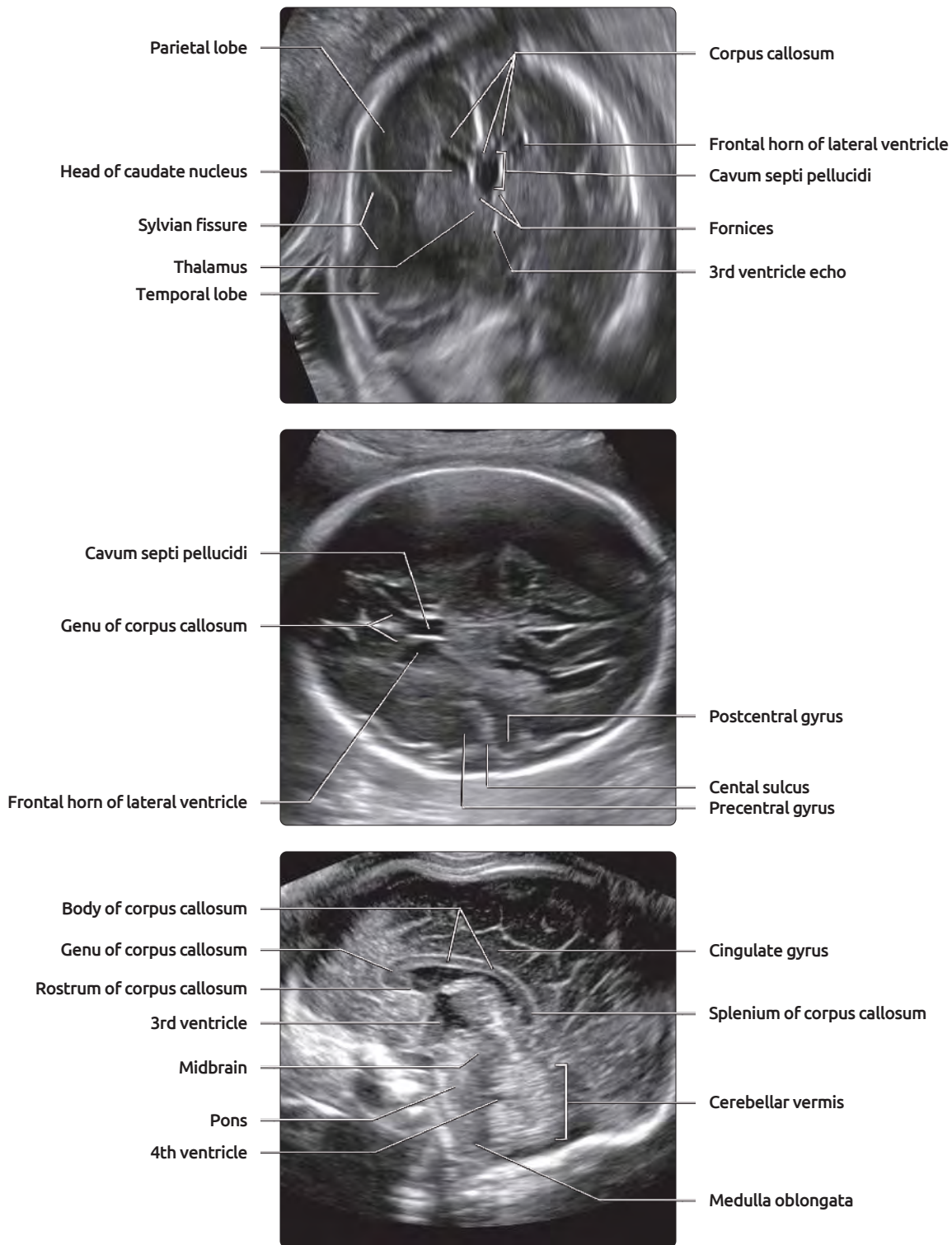
(Top) The sylvian fissure is one of the easiest cortical indentations to see in the fetus. In this 19-week fetus, the sylvian fissure is seen as a shallow groove on the surface of the brain; it creates obtuse angles with the insular cortex. The cortical mantle is quite smooth at this gestational age. As the brain grows, the sylvian fissure deepens and the cortical mantle becomes convoluted. **(Middle)** As the brain grows and the surface becomes more convoluted, the sylvian fissure deepens and becomes square in profile, like an open box. This is a 25-week, 3-day gestation. **(Bottom)** In this fetus, at 28-week gestation, the process of operculization results in the sylvian fissure "closing." The floor of the box is the insular cortex and the lid of the box is composed of the frontal and temporoparietal opercula. The sylvian fissure separates the parietal lobe superiorly from the temporal lobe inferiorly. The surface of the brain is becoming more convoluted with visible parietooccipital sulcus, cingulate sulcus, and shallow surface gyri.

TELENCEPHALON: CEREBRAL HEMISPHERES



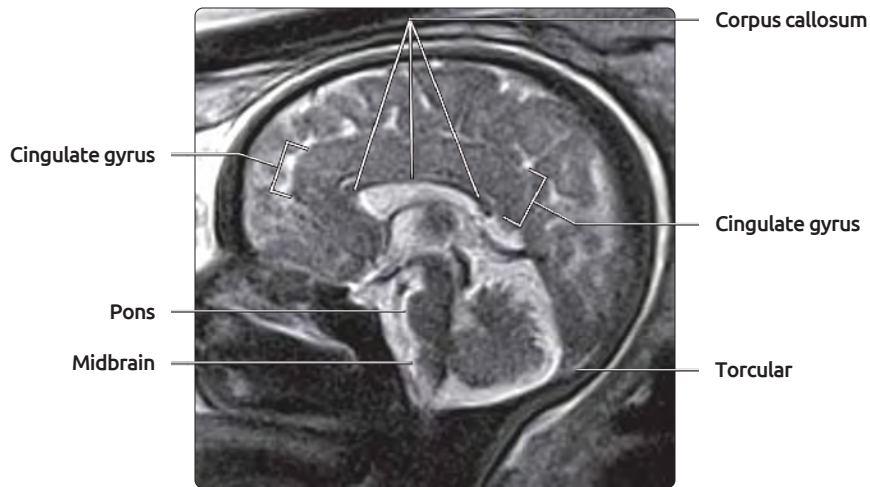
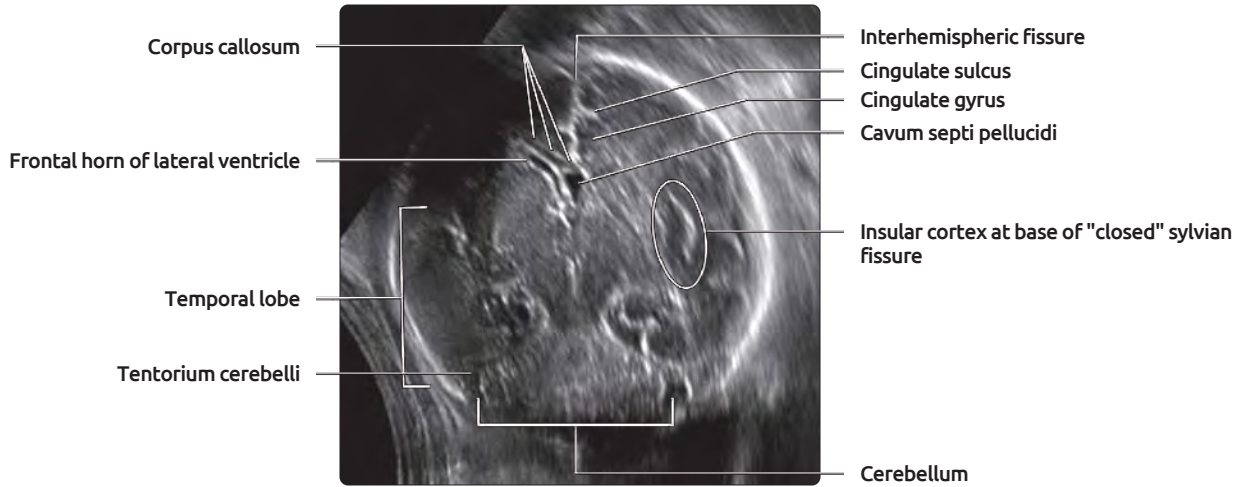
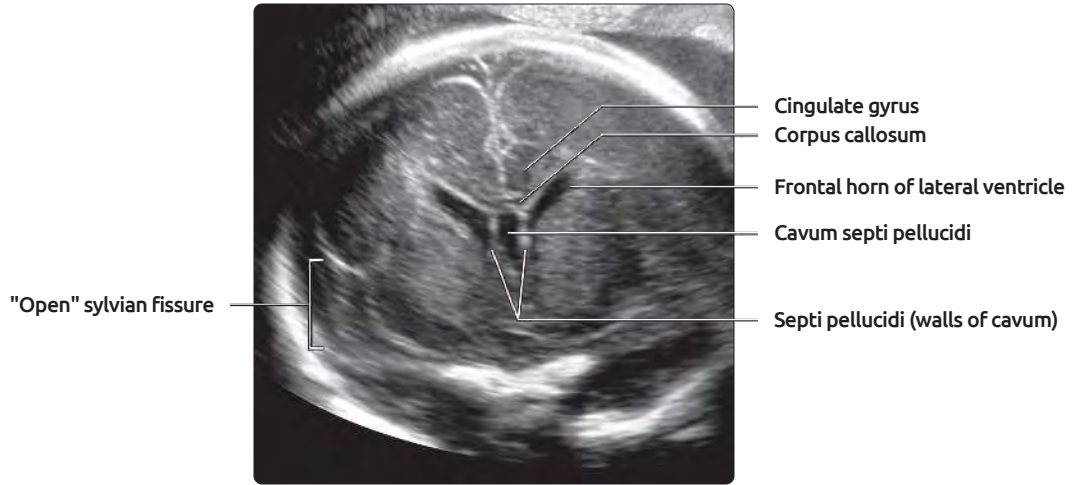
(Top) With advancing gestational age, the forebrain enlarges dramatically in comparison to the mid- and hindbrain. The telencephalon and diencephalon arise from the prosencephalon; between them they give rise to most of the supratentorial brain. This graphic illustrates the relative proportions of the brain arising from the prosencephalon (green), metencephalon (yellow), and myelencephalon (light blue). The mesencephalic, midbrain structures are not visible. **(Middle)** With advancing gestational age, multiple secondary and tertiary gyri develop and the number and complexity of the cerebellar folia increases. **(Bottom)** Coronal T2WI in the 3rd trimester shows the appearance of a mature brain with well-developed surface sulci and gyri and opercularized sylvian fissures.

CORPUS CALLOSUM, CINGULATE GYRUS



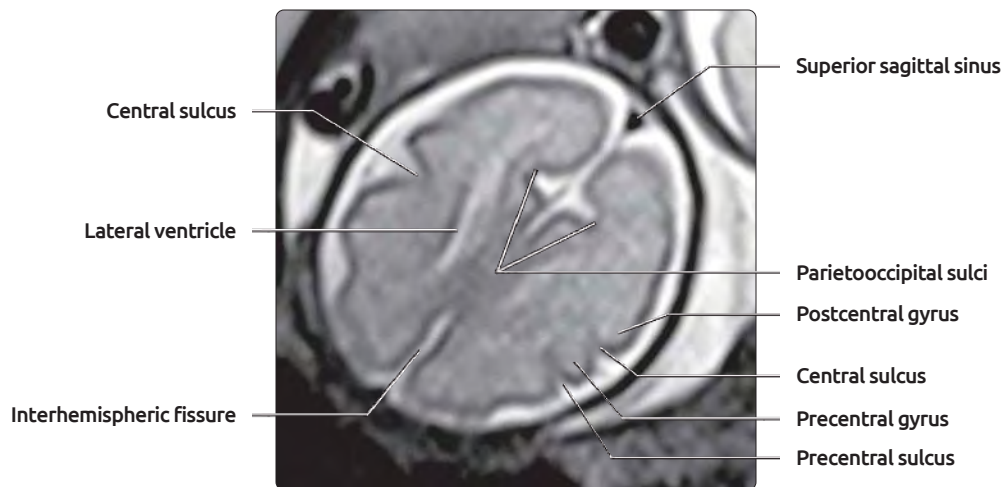
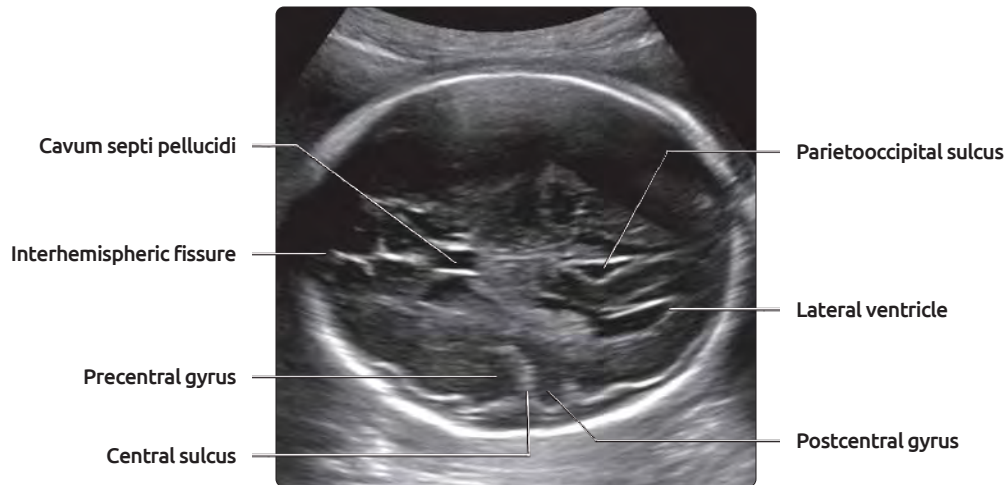
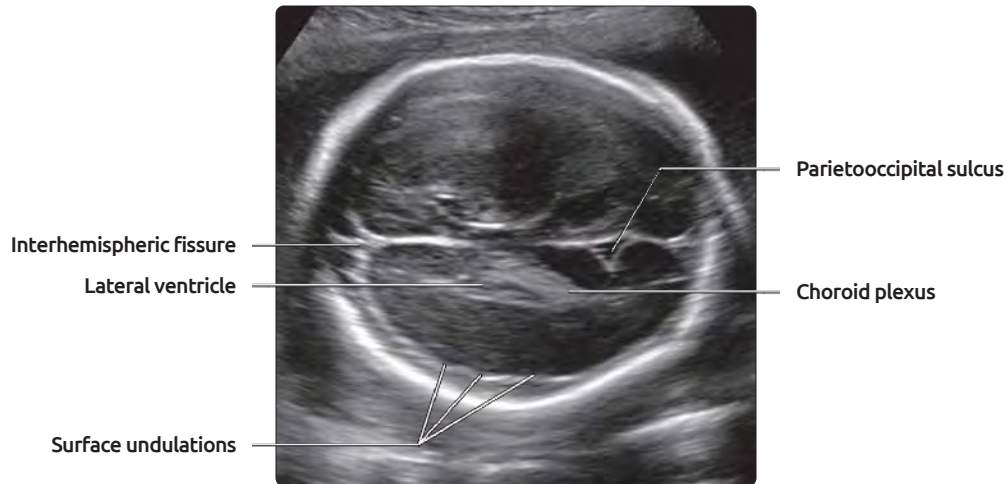
(Top) Vaginal ultrasound allows for exquisite anatomical assessment of the fetal brain. At 21 weeks, the corpus callosum is visible, forming the roof of the cavum septi pellucidi, which sits between the frontal horns of the lateral ventricles, above the 3rd ventricle. The cingulate gyrus has not yet developed. **(Middle)** Even though the corpus callosum is best seen on direct sagittal view, the genu can be identified on the standard axial image obtained at the level of the cavum septi pellucidi. The genu of the corpus callosum forms the curved part of the "anchor complex" in the normal anterior brain. The stem of the anchor is created by the interhemispheric fissure. This fetus is at 28 weeks of gestation. **(Bottom)** If the fetus is in cephalic presentation, transvaginal ultrasound in the 3rd trimester produces exquisite images of normal brain anatomy. In this image, the cingulate gyrus is seen running parallel to the body of the corpus callosum, which is seen in its entirety.

CORPUS CALLOSUM, CINGULATE GYRUS



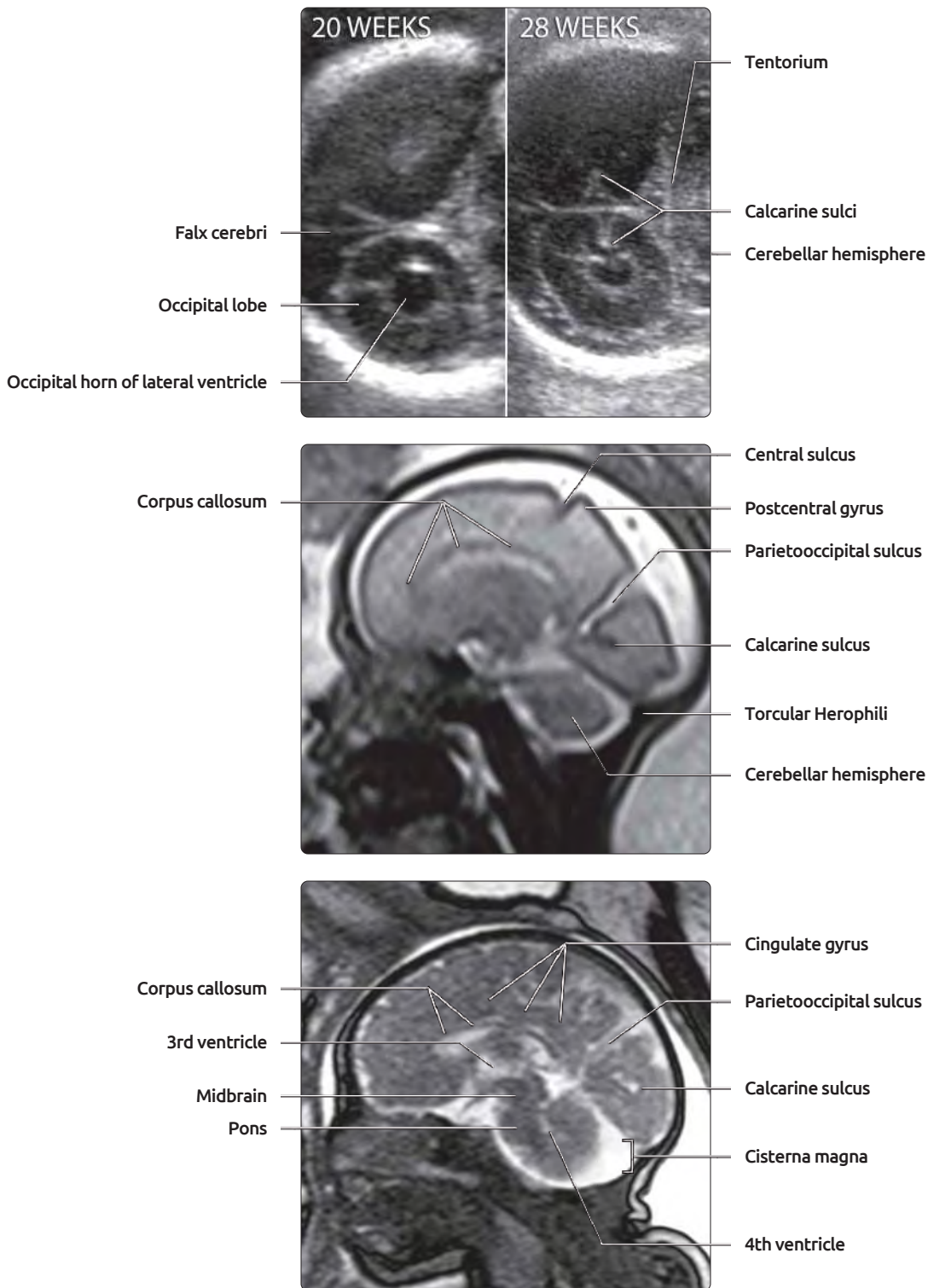
(Top) A complete neuroanatomic survey requires multiplanar imaging. In this coronal image at 24-weeks gestation, the brain surface is still relatively smooth but the corpus callosum and cingulate gyrus are well seen. **(Middle)** Later in the 3rd trimester (this is a 31-week fetus), the ventricles appear relatively small compared to scans at 20 and 24 weeks. The corpus callosum is thicker and easier to see. The cingulate gyrus and sulcus are well developed. Note that opercularization of the sylvian fissure is also complete in this fetus. **(Bottom)** MR was performed to evaluate focal dilation of the occipital horn and confirmed occipital lobe cortical dysplasia. This midline sagittal MR shows the normal curved corpus callosum with the cingulate gyrus wrapped around it. In agenesis of the corpus callosum, the cingulate gyrus does not form, and the medial surface gyri are oriented in a sunburst pattern called stenogyria.

PARIETOOCCIPITAL SULCUS



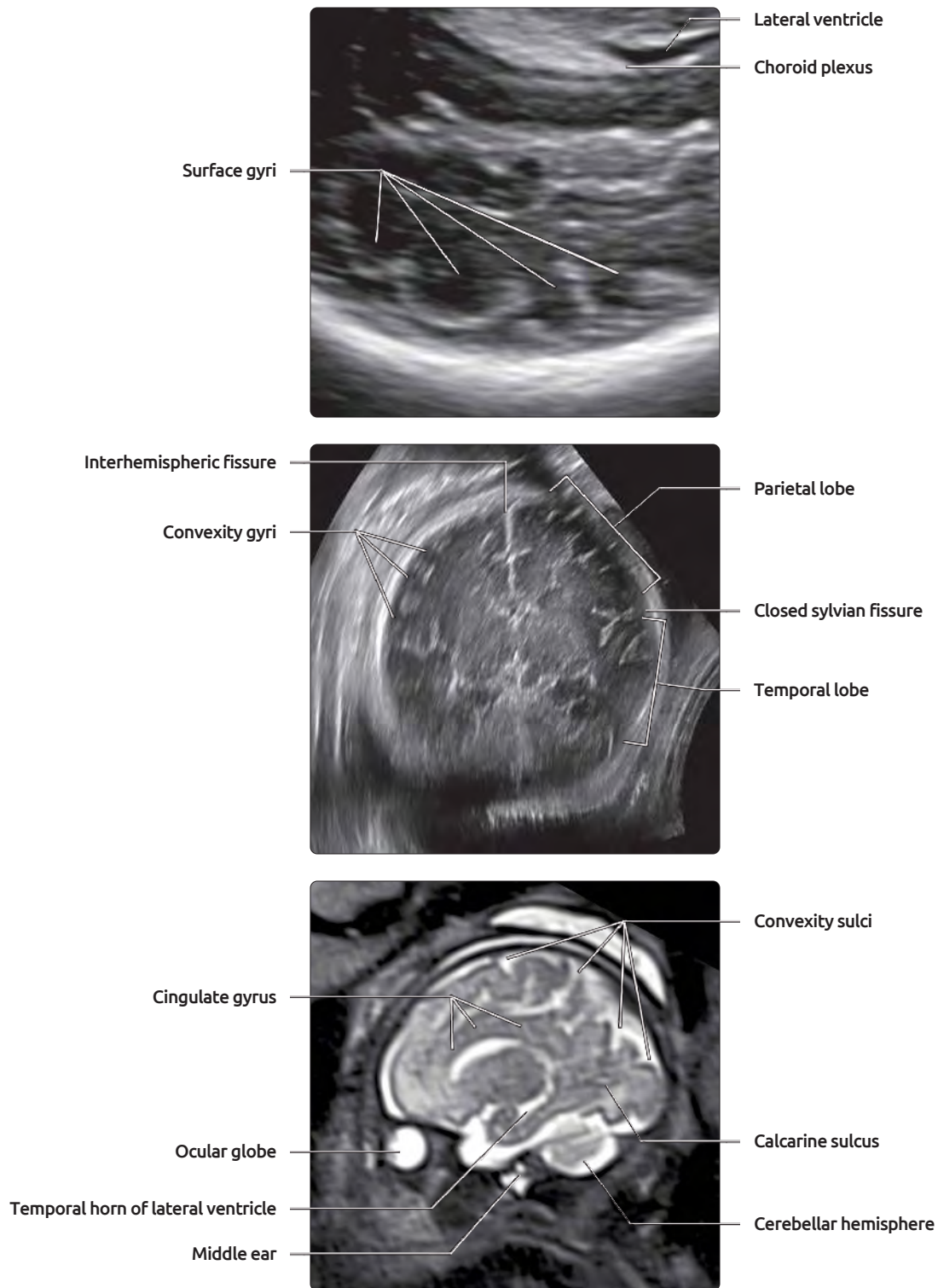
(Top) High axial ultrasound at 25-weeks, 3-days gestational age shows a well-developed parietooccipital sulcus. The surface of the brain is starting to develop some undulations as the convexity sulci begin to form. **(Middle)** By 28 weeks, the parietooccipital sulcus is well established, the surface of the brain has more pronounced undulations, and there are now some named convexity sulci and gyri visible. **(Bottom)** At 30 weeks, the parietooccipital sulcus is clearly visible on MR. The convexity sulci are more established with clear visibility of the central sulcus and adjacent gyri.

CALCARINE SULCUS



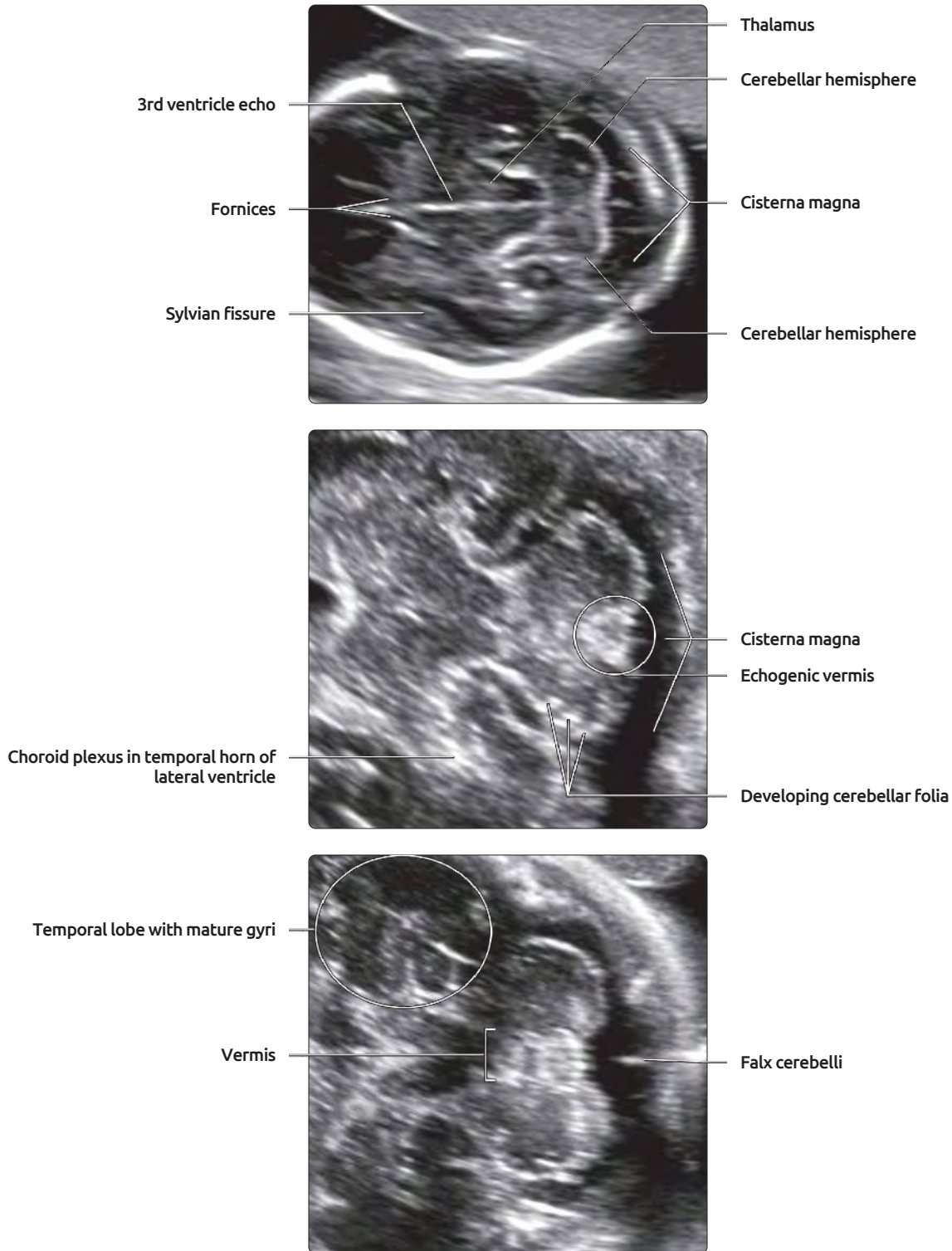
(Top) The calcarine sulcus develops on the medial surface of the occipital lobe branching from the parietooccipital sulcus. It is best seen on the coronal plane since the ultrasound beam is then perpendicular to the plane of the sulcus. In this composite image, note how smooth the medial occipital cortex is at 20 weeks. By 28 weeks, the calcarine sulcus is easily visible in the same fetus. **(Middle)** Sagittal MR nicely shows the orientation of the calcarine sulcus as a branch of the parietooccipital sulcus. **(Bottom)** At 37 weeks, the convexity sulci are well established. Note the relative decrease in the cerebrospinal fluid volume over the surface of the brain. This is normal, as is the relative decrease in size of the ventricular system compared to the size of the brain.

CONVEXITY SULCI AND GYRI



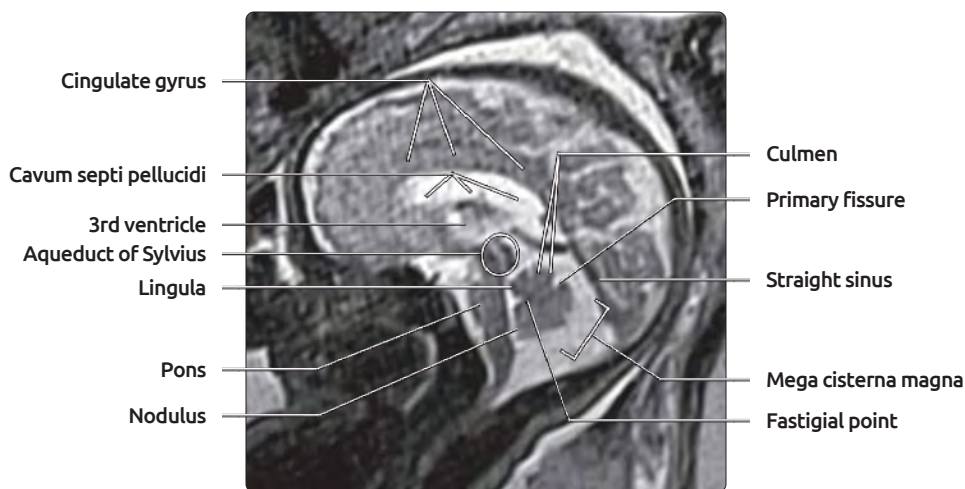
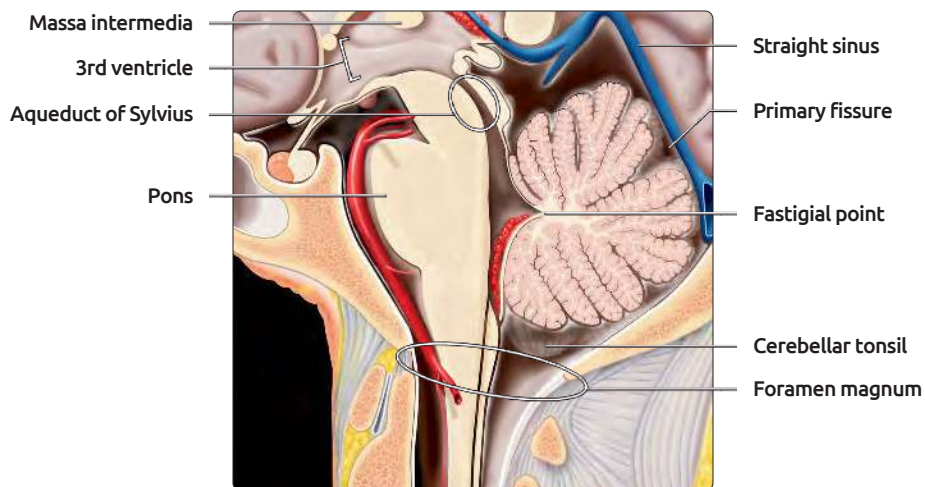
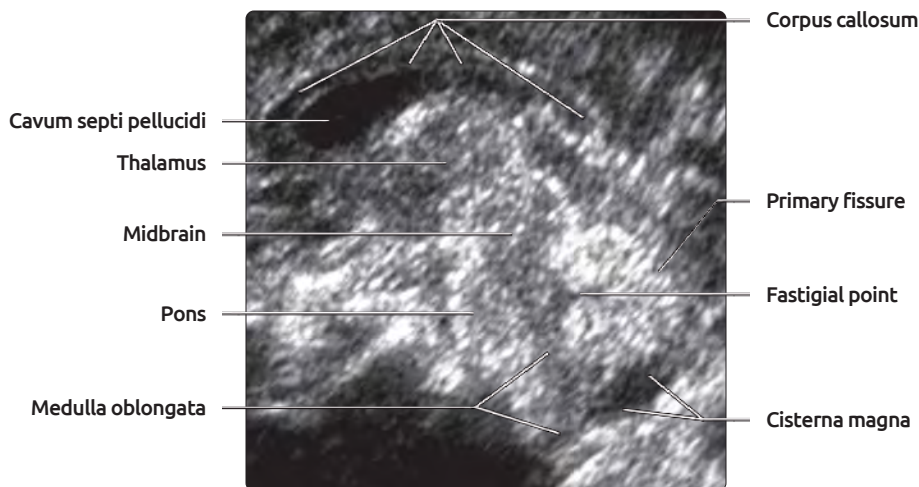
(Top) "Zoomed" view of an axial ultrasound in the 3rd trimester shows numerous convexity sulci and gyri in the far field. There is usually loss of detail in the near field due to reverberation of the beam at the ossified skull vault. It is important to examine the brain from multiple directions as well as in multiple planes if there is any concern for structural malformation. **(Middle)** Coronal ultrasound in the 3rd trimester in a fetus with osteogenesis imperfecta type III shows how an underossified skull vault allows for beautiful images of the brain. This is described as the brain too well seen sign. **(Bottom)** Parasagittal MR late in the 3rd trimester shows well-developed sulci and gyri over the convexity of the brain.

POSTERIOR FOSSA



(Top) The posterior fossa structures are evaluated on an axial oblique view. For measurement of the nuchal fold and cisterna magna depth, the cavum septi pellucidi is used as a landmark to confirm the appropriate obliquity. This image is slightly underangled, so it includes the fornices. At 18 weeks, the hemispheres are round with relatively simple architecture. The vermis is visible between the hemispheres but does not differ markedly in echogenicity from them. **(Middle)** With advancing gestational age, the echogenicity of the vermis increases in relation to that of the hemispheres. The cerebellar folia become visible as bright, echogenic lines around the margin of the hemispheres. **(Bottom)** In the late 3rd trimester, the vermis is plainly seen. Note the increasing complexity of the temporal lobe gyri. The cisterna magna is stable in size throughout gestation. It should always measure < 10 mm from the posterior surface of the vermis to the inner table of the occipital bone.

POSTERIOR FOSSA



(Top) This is a transabdominal scan of a 3rd-trimester fetus in breech presentation. Use of the metopic suture allows acquisition of a very nice sagittal image with superb detail of the posterior fossa structures. **(Middle)** This sagittal graphic illustrates normal anatomy and landmarks in the cerebellar vermis. The primary fissure divides the vermis into an anterior lobe (lingula, central, and culmen lobules) and a posterior lobe (declive, folium, tuber, pyramis, and uvula). The nodulus is referred to as the flocculonodular lobe. **(Bottom)** MR in a fetus with Gorlin syndrome (done at 37 weeks to exclude an oral cavity mass) shows normal vermian anatomy and location with a mega cisterna magna. Note the complexity of the convexity sulci, as well as those on the medial surface of the brain at this gestational age.

Imaging Techniques and Normal Anatomy

Transabdominal Ultrasound

The standard obstetric ultrasound examination is performed using an abdominal approach with a 4-6 MHz transducer. The guidelines for performance set forth the list of images that must be obtained in order to consider the study of adequate diagnostic quality. These include **axial images of the cerebral hemispheres demonstrating the midline falx, lateral ventricles, choroid plexus, cavum septi pellucidi (CSP), and thalami**. Biometric parameters are measured on these views. The **head circumference (HC) and biparietal diameter (BPD)** are measured on an axial image through the thalami at the level of the CSP. The HC is measured along the outer edge of the skull and does not include soft tissues. The BPD is measured from the outer edge of the near-field bone to the inner edge of the far-field bone. The diameter of the **lateral ventricle** is measured inner edge to inner edge, perpendicular to the long axis of the ventricle at the glomus of the choroid plexus. This measurement should be < 10 mm throughout gestation, although male fetuses may have slightly larger ventricles than female fetuses. Many articles define mild ventriculomegaly as ventricular diameter ≥ 10 and ≤ 12 mm. An axial oblique view (including the CSP but angled to include the posterior fossa) is used to document normal cerebellum and cisterna magna.

The **CSP** is the space between the septi pellucidi; it normally obliterates by late gestation but should **always be seen between 18 and 37 weeks**. Failure to visualize it after 37 weeks is almost certainly due to normal obliteration if the brain is otherwise normal. Although often visible earlier than 16 weeks, failure to demonstrate it at this stage is not necessarily abnormal. In an otherwise normal-appearing fetus, follow-up should be scheduled for after 18-weeks gestation before there is any assumption of brain malformation. If the CSP appears to extend posterior to the level of the columns of the fornix, this is an anatomic variant known as **cavum septi pellucidi et vergae** and should not be confused with pathological processes such as interhemispheric cysts.

The CSP is included in the oblique view of the cerebellum to ensure the correct angulation. If the scan plane is too steep (i.e., approaching coronal) it may cause spurious abnormalities such as an apparent mega cisterna magna, cerebellar cleft, or increased nuchal fold. The cisterna magna depth is ≤ 10 mm throughout pregnancy; it is measured in the midline, from the posterior surface of the cerebellum to the inner table of the occiput. This is also the appropriate plane at which to measure nuchal fold thickness.

Transvaginal Ultrasound

Transvaginal ultrasound is very helpful for fetal brain assessment if the fetus is in cephalic presentation. The high-transducer frequency (up to 9 MHz) produces high-resolution images and allows for direct acquisition of sagittal and coronal scan planes using the metopic suture and anterior fontanelle as acoustic windows. A complete neurosonographic evaluation of the fetus requires documentation of four coronal and three sagittal planes, in addition to the standard axial planes. The coronal images are transfrontal, transcaldate, transthalamic, and transcerebellar. The sagittal planes are midsagittal and right and left parasagittal.

3D Ultrasound

3D sonography allows for acquisition of a volume through the fetal brain, which can be manipulated and displayed in

orthogonal axial, sagittal, and coronal planes. This technique overcomes difficulties with obtaining a true sagittal plane directly if the fetal head is not in a suitable position. Surface rendering has been used to provide visualization of structures not seen on standard views, such as the optic chiasm in the suprasellar cistern.

Doppler Ultrasound

Color or power Doppler is used to identify the vessels of the **circle of Willis**. If flow is present in the circle of Willis in a fetus with marked ventriculomegaly, hydranencephaly is excluded as in that condition the carotid circulation is occluded. The **middle cerebral artery** is easily identified on axial brain images. Measurement of the peak systolic velocity in this vessel is now used as a noninvasive method to diagnose **fetal anemia**. Technique is crucial; the fetus should be at rest and the near-field middle cerebral artery is evaluated with a zero angle of insonation with the sample volume placed within two mm of the takeoff from the circle of Willis.

When measuring **resistive or pulsatility indices** or **systolic:diastolic ratio**, the vessel can be sampled at any angle of insonation as the use of ratios between systolic and diastolic flow velocity negates any angle-related changes in actual velocity. Measurements are compared to those of the umbilical artery to assess **"brain-sparing" flow** in fetuses with fetal growth restriction. The systolic diastolic ratio in the middle cerebral artery should always be greater than that of the umbilical artery.

The **anterior cerebral artery** is a useful marker for normal midline development. On a midline sagittal image, the anterior cerebral artery extends cranially from the circle of Willis, then turns and gives rise to the **pericallosal and callosomarginal arteries**, which run along the corpus callosum. In **agenesis of the corpus callosum**, this branching pattern does not occur. Similarly, in **lobar holoprosencephaly**, there is an aberrant course of the artery described as "crawling under the skull." A single or **azygos anterior cerebral artery** is also described in lobar holoprosencephaly.

Doppler evaluation is essential in characterization of any apparently cystic intracranial lesion. Vascular lesions that may be seen include vein of Galen aneurysm, arteriovenous malformations, and dural sinus malformations.

Magnetic Resonance Imaging

Rapid T2-weighted sequences are the mainstay of fetal brain evaluation. This sequence allows assessment of anatomy and development. Gray matter is of lower signal than white matter. Flowing blood is seen as a signal void, and clotted blood is low in signal. CSF is high signal (i.e., white).

T1-weighted images are excellent for detection of blood products (e.g., intracranial hemorrhage) and fat (e.g., a lipoma in association with agenesis of the corpus callosum). They are also used to assess myelination, although the role for this in fetal imaging is limited.

Diffusion imaging can be performed, especially in the third trimester when the head is engaged in the maternal pelvis and there is less movement. It is primarily used to assess the extent of brain injury in association with fetal intervention, maternal illness, or trauma and also in cases of fetal infection or intracranial hemorrhage.

Tractography and spectroscopy can also be performed, but they are still considered experimental.

Approach to Fetal Brain

Normal or Not?

The fetal brain changes dramatically during gestation. Thus, "normal" is determined by gestational age. It is important to have a systematic approach to the assessment of the brain and to "check off" a list of structures or observations in every case evaluated.

The brain is protected by the skull vault; therefore brain assessment starts with evaluation of the head size and shape. The normal skull vault is oval in shape and longer anterior to posterior than side to side. The contour is smooth and the skull echo should be continuous around the circumference of the brain. A typical "rookie" mistake is to confuse refraction of the ultrasound beam from the posterior skull vault for a bony defect. Refraction by a cystic hygroma may also be confused with a cephalocele. If the skull shape is irregular, considerations include **craniosynostosis**. If the head shape is round in all scan planes, consideration should be given to abnormality of the underlying brain (particularly in the holoprosencephaly spectrum, where fusion of the anterior hemispheres causes **brachycephaly**). **Microcephaly** is associated with a sloped forehead, which is best seen in the sagittal profile view.

Next, make sure that there are two cerebral hemispheres separated by a complete falx. The **falx** is a midline linear echo dividing the cerebral hemispheres. It is present in severe hydrocephalus and hydranencephaly, but it is not seen in alobar holoprosencephaly. There is a variable degree of anterior brain fusion in semilobar holoprosencephaly, so the falx may be present posteriorly but will be absent anteriorly. In the mildest forms of lobar holoprosencephaly, the hemispheres may be completely separate with a complete falx. On coronal images, the midline echo continues from the falx to line up with the cavum septi pellucidi and the linear echo of the third ventricle. A subtle finding in the coronal plane is described as distortion of the interhemispheric fissures; it is defined by impaction of the medial borders of the frontal lobes and loss of the parallel orientation of the medial parts of the frontal lobes. It is associated with midline malformations including septo-optic dysplasia and syntelencephaly as well as more diffuse malformations such as Chiari 2 and schizencephaly.

The septi pellucidi are separated by a fluid-filled space, the cavum septi pellucidi. This space is obliterated from posterior to anterior as a normal developmental process and therefore may not be seen after 37 weeks. Between the ages of 18 and 37 weeks, the cavum should be seen as a box-like structure with bright linear echoes forming the walls and an anechoic space between the linear echoes. It is situated between the frontal horns of the lateral ventricles. Parts of the **foramina** can be seen on an axial plane just caudal to the cavum. These structures are seen as a series of parallel black and white lines and do not form a box shape between the frontal horns.

Absence of the cavum has been described in isolated septal dysgenesis, but it is also associated with many complex brain malformations. Because it is an important marker of normal midline brain development, demonstration of the cavum is now part of the American Institute of Ultrasound in Medicine (AIUM) guidelines for performance of obstetric ultrasound.

The **lateral ventricles** should be symmetric in size and have a butterfly wing configuration; they are not normally parallel. The frontal horns are narrow, almost slit-like at term. The

largest part of the ventricular system is the **atrium**, which is the confluence of the body of the lateral ventricle with the occipital and temporal horns. The ventricular diameter is measured at the atrium, perpendicular to the long axis of the ventricle, inner edge to inner edge. Once visible, the parietooccipital fissure is a nice landmark for this measurement, which should always be 10 mm or less. **Mild ventriculomegaly** is defined as ventricular measurement of 10-12 mm. While this may be a benign finding, it may also be the earliest indication of significant brain pathology.

As the cortical mantle grows and matures, several fissures and sulci develop. **Fissures** are deeper infoldings than sulci and have a fixed position on the cerebral surface. **Sulci** are shallower and are more subject to individual variation. The **interhemispheric fissure** seats the falx cerebri and, as discussed above, should traverse the brain from anterior to posterior. The **sylvian fissure** initially appears as a shallow indentation on the lateral surface of the brain (at about 18 weeks), as seen on axial images. This indentation deepens, becomes "squared off" and shaped like an open box, and eventually becomes covered by the process of operculization, which is not complete until term. This fissure is well seen on axial and coronal images.

Next, look at the posterior fossa. Increased knowledge regarding the anatomy and function of the cerebellum is such that a detailed approach to assessment of the posterior fossa contents is presented separately. In all cases, however, it is important to check that the cerebellum is composed of two lobes with an intervening vermis and that the cisterna magna depth is ≤ 10 mm.

Characterize Abnormality

Is it intraaxial or extraaxial? Is the lesion within the substance of the brain or not? The differential diagnosis is different for lesions within the brain (intraaxial) vs. those that displace brain parenchyma (extraaxial). An interhemispheric cyst is an extraaxial lesion because it lies between the cerebral hemispheres and may displace one or both hemispheres. A solid tumor, such as a teratoma, arises within brain parenchyma. Although it, too, may displace adjacent brain, it is an intraaxial lesion.

Is it cystic or solid? A brain mass may be anechoic or have some internal echoes. Anechoic lesions may be cystic or vascular; therefore, the use of Doppler is essential. **Vascular lesions** are quite rare in the fetus; the main considerations would be a vein of Galen aneurysm vs. a dural sinus malformation or an arteriovenous malformation. **Simple cystic structures** may be extraaxial (e.g., arachnoid or gliopendymal cysts), or they may be part of an intrinsic brain malformation, such as the dorsal cyst or monoventricle in alobar holoprosencephaly. Some apparent cysts are, in fact, due to cerebrospinal fluid accumulation in a space created by an underlying brain malformation. Schizencephaly or focal areas of cortical dysplasia may first come to attention because of a prominent adjacent cerebrospinal fluid space.

Complex "cysts" may be seen when a thrombosed vascular lesion contains clot with low-level internal echoes. A dural sinus malformation may present in this way; the typical location at the torcular Herophili is a hint to the correct diagnosis.

Fetal brain tumors are typically complex in architecture with internal blood flow; they grow rapidly, and most present in the 3rd trimester.

Fetal Neurosonography

Landmarks		Structures Seen
Axial		
BPD/HC	Thalami, CSP	Thalami, V3 cerebral hemispheres, frontal horns, falx
Lateral ventricle	Oval head shape, midline falx, craniad to BPD/HC plane	Cerebral hemispheres, lateral ventricles, choroid plexus, falx
Cerebellum	Cerebellum, CSP	Cerebellar hemispheres, peduncles, vermis, cisterna magna
Coronal		
Transfrontal	Interhemispheric fissure	Anterior falx, frontal lobes, sphenoid bone, orbits
Transcaudate	Caudate nuclei, CSP, frontal horns	Genu of corpus callosum, CSP
Transthalamic	Thalami, CSP	Foramina of Monroe, V3, body of corpus callosum
Transcerebellar	Posterior interhemispheric fissure, tentorium cerebelli	Occipital lobes, cerebellar hemispheres, vermis
Sagittal		
Median	Corpus callosum	Corpus callosum, CSP, vermis, pons, brainstem
Parasagittal	Occipital horn of lateral ventricle	Lateral ventricle, choroid plexus, cerebral cortex
<p><i>BPD = biparietal diameter; CSP = cavum septi pellucidi; HC = head circumference; V3 = 3rd ventricle. Data extracted from the AIUM guidelines for performance of obstetrical ultrasound and the ISUOG guidelines for performance of the fetal neurosonogram.</i></p>		

Is it a developmental abnormality or a destructive process?

Porencephaly and encephalomalacia are manifestations of brain injury. In many cases there will be a history of a normal early scan. A **porencephalic cyst** is a focal area of brain destruction that eventually becomes cystic as the destroyed brain parenchyma is absorbed. **Encephalomalacia** is a more diffuse form of this destructive process, often due to an insult occurring later in gestation after the age at which gliosis can occur in response to brain injury. This results in a Swiss cheese appearance to the deep white matter most often in a periventricular distribution.

Is this an isolated finding? Are there additional brain findings beyond the initial observation? If the initial observation is mild ventriculomegaly, go back and pan through the ventricles. If the walls are nodular, there may be gray matter heterotopia. If the ependyma is echogenic and thick, there may have been an intracranial hemorrhage. If the cavum is absent, look for the corpus callosum and scan it in the sagittal plane to look for callosal dysgenesis. Carefully evaluate the surface of the brain for a schizencephalic cleft. 3D ultrasound may be used to directly evaluate the optic chiasm, while transocular views can identify the optic nerve to assess for septo-optic dysplasia. The olfactory nerve and groove can be identified from 32 weeks on by MR imaging; absence of these structures indicates arrhinencephaly, which is at the milder end of the lobar holoprosencephaly spectrum.

Look Elsewhere

A fetus with holoprosencephaly is likely to have facial anomalies (e.g., cyclopia, proboscis, midline cleft, ethmocephaly, and cebocephaly are all described). Fetuses with trisomy 13 typically have facial anomalies as well as other stigmata, such as polydactyly and echogenic kidneys. Trisomy 18 is associated with major birth defects as well as growth restriction. Chiari 2 malformations are associated with neural tube defects, some of which can be extremely subtle. Aqueductal stenosis as a cause of hydrocephalus may be associated with adducted thumbs when X-linked. Observation of abnormalities in addition to the brain findings may lead to a

specific diagnosis or at the very least will narrow the list of differential diagnoses.

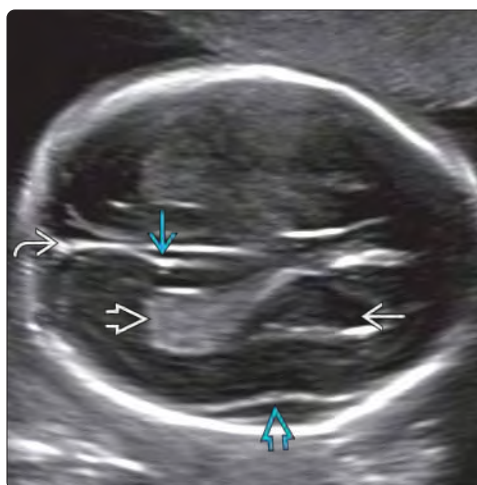
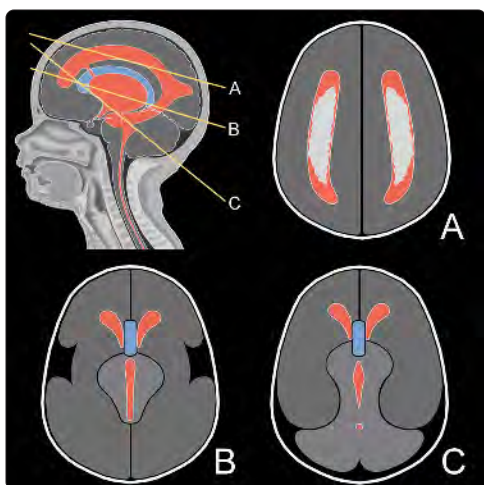
If a brain abnormality is associated with growth restriction or multiple other findings, aneuploidy or a syndromic diagnosis becomes much more likely.

Clinical Implications

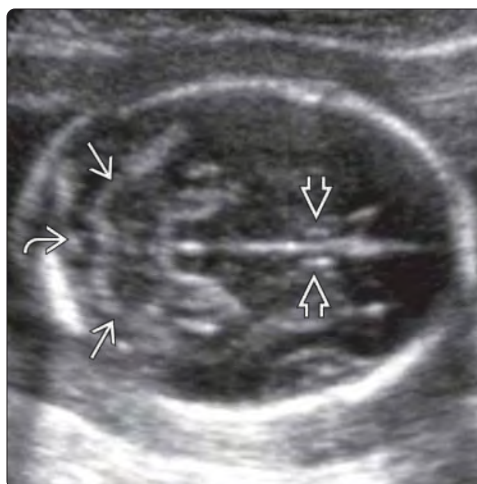
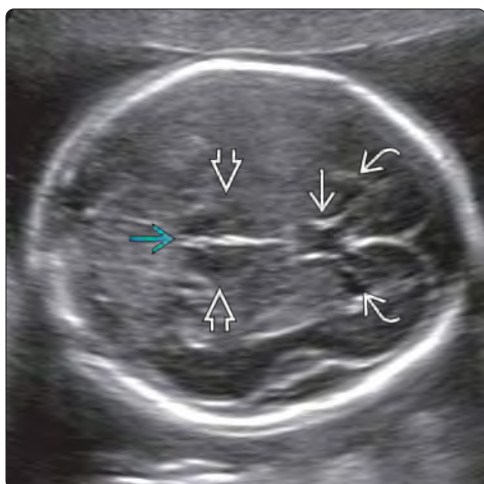
Brain malformations are some of the most devastating birth defects seen. Affected infants may have profound developmental delay, seizure disorders, cerebral palsy, blindness, and feeding and respiratory difficulties. In some cases, the brain malformation is associated with a genetic condition or syndrome resulting in intrauterine fetal demise or neonatal or infantile death. Autosomal recessive syndromes are associated with a 25% recurrence risk in future pregnancies. Fetal brain abnormalities leading to macrocephaly or arthrogryposis may require operative delivery, and in some cases, extension of the uterine incision is needed. This places mothers of those fetuses at increased risk for placenta accreta and uterine rupture in future pregnancies. Some families may choose to terminate a pregnancy with a fetal brain malformation. For those patients with personal or religious reasons to avoid termination, accurate diagnosis of brain malformation is essential to determine the best individual delivery plan. It goes without saying that recurrence risk can only be assessed if there is a firm diagnosis in the index case. Therefore, every attempt should be made to provide as much information as possible to families of fetuses with anomalies. In the case of brain abnormalities, transvaginal ultrasound and MR provide additional information to that obtained by transabdominal ultrasound alone. The techniques are not mutually exclusive and can, in fact, be complementary.

Selected References

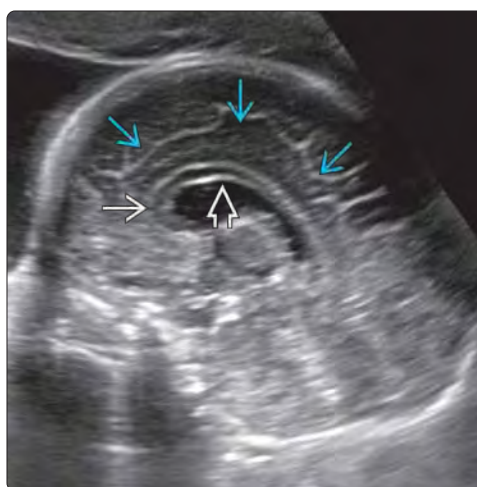
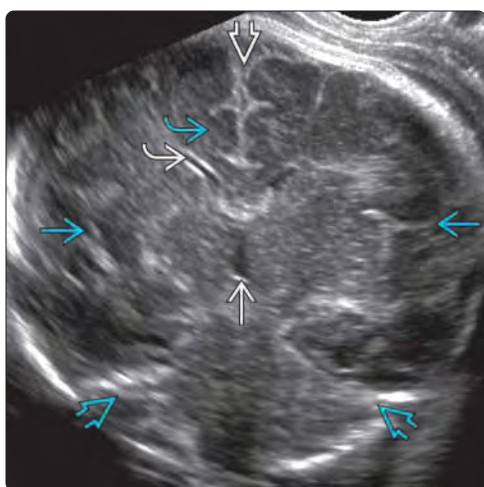
1. International Society of Ultrasound in Obstetrics & Gynecology Education Committee: Sonographic examination of the fetal central nervous system: guidelines for performing the 'basic examination' and the 'fetal neurosonogram'. *Ultrasound Obstet Gynecol.* 29(1):109-16, 2007








(Left) Graphic shows the scan planes for evaluation of the fetal brain with transabdominal US. These include the lateral ventricles (A), the level of the thalami and cavum to measure BPD and HC (B), and the angled view of the posterior fossa (C). (Right) Axial US corresponding to scan plane A shows the choroid plexus in the lateral ventricle and the intact midline echo of the falx cerebri. Note the early development of the sylvian and parietooccipital fissures, which are visible even in this 18-week fetus.

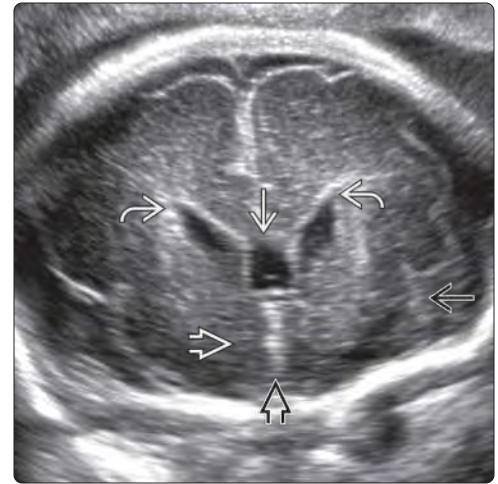
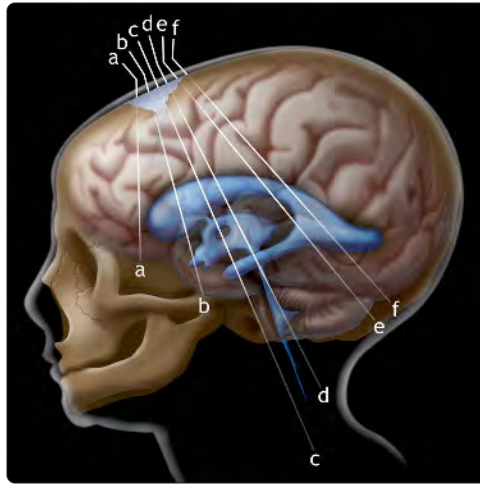








(Left) Axial US corresponding to scan plane B shows the thalami on either side of the 3rd-ventricle echo and the box-shaped cavum septi pellucidi between the frontal horns of the lateral ventricles. (Right) Axial oblique US corresponding to scan plane C shows the cerebellum, vermis, and cisterna magna. This image is slightly caudal to the cavum septi pellucidi and shows the parallel linear echoes of the paired fornices. These should not be mistaken for the cavum, which is a box-like structure.

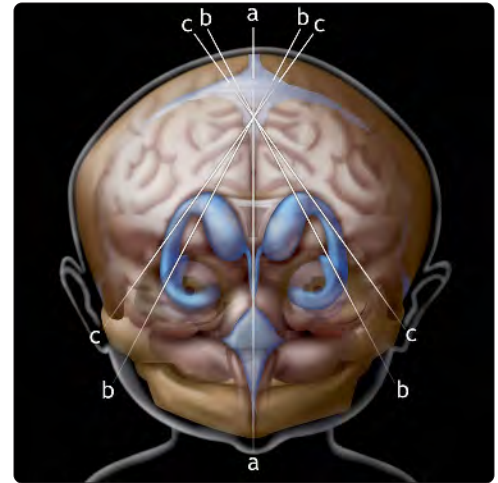
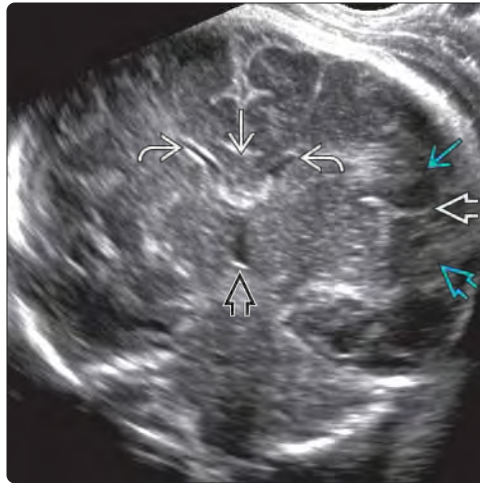









(Left) Coronal and sagittal images can be obtained with transabdominal or transvaginal US and are excellent for complete evaluation of brain anatomy. In this transvaginal US in the 3rd trimester, note the falx, frontal horns, cingulate gyrus, 3rd ventricle, opercularized sylvian fissures, and tentorium cerebelli. (Right) Sagittal transabdominal scan in a different case beautifully demonstrates the corpus callosum genu and body as well as the cingulate gyrus.

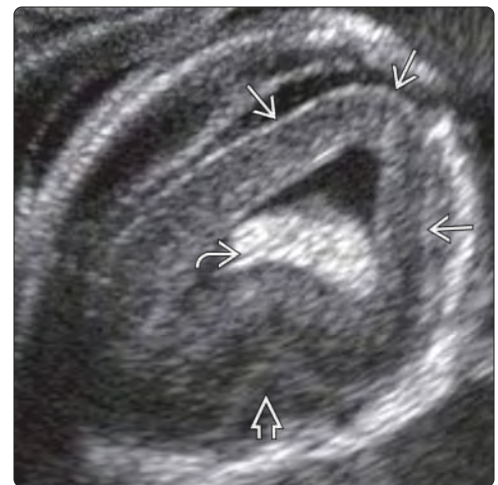
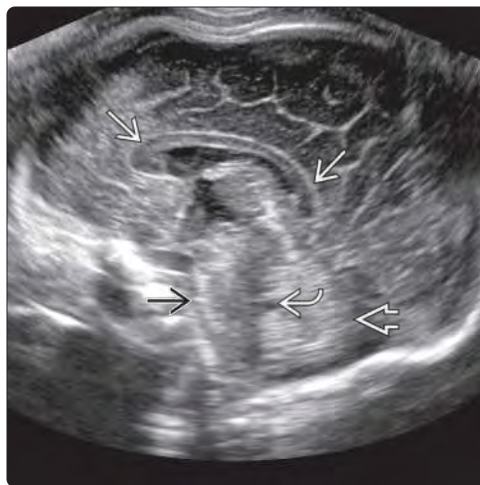
(Left) Sagittal graphic illustrates the scan planes that can be obtained using the anterior fontanelle as an acoustic window for transvaginal imaging of the fetal brain. Plane C will be a true coronal scan; the other planes will be oblique coronal. (Right) Coronal transvaginal US corresponding to plane C shows the cavum , the frontal horns , the thalami , and the linear 3rd ventricle echo . The anterior sylvian fissure  is just visible.

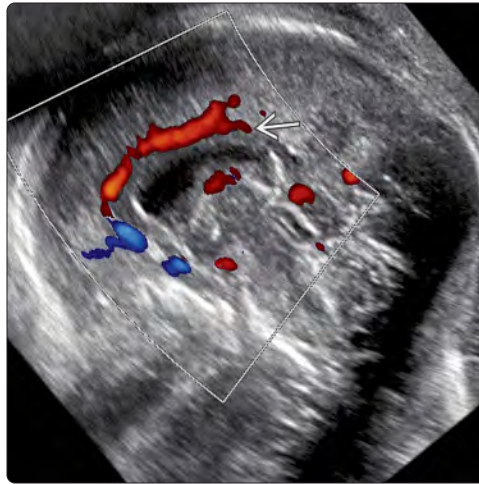
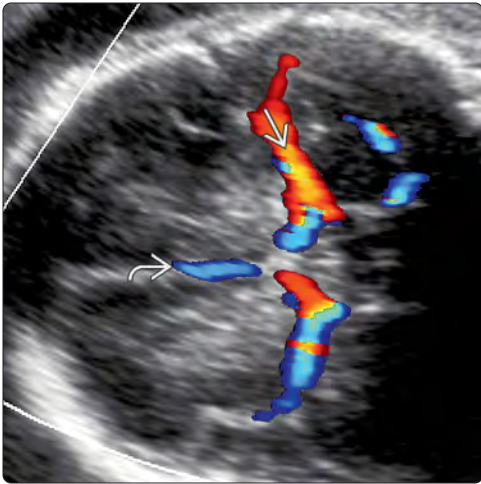





(Left) A more posteriorly angled coronal transvaginal US in an older fetus shows increased complexity of the brain gyration and sulcation. Note the lateral ventricles , the corpus callosum , and the 3rd ventricle  between the thalami. The sylvian fissure  is closed by the parietal  and temporal  opercula. (Right) Coronal graphic illustrates the sagittal scan planes obtained through the anterior fontanelle during fetal neurosonography. Image A is true midline.

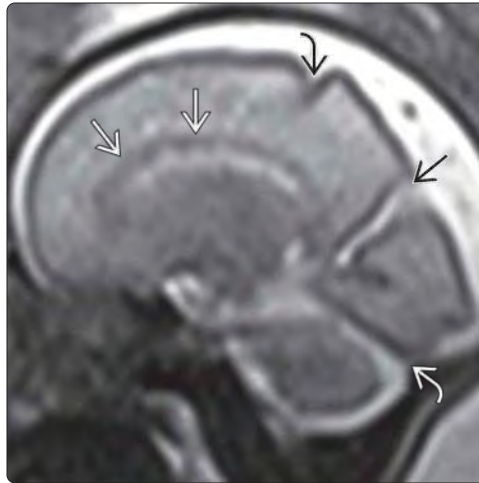
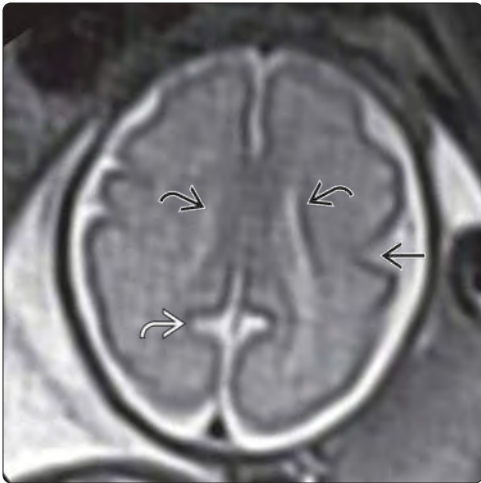









(Left) Sagittal transvaginal US, corresponding to plane A, shows the corpus callosum , the cerebellar vermis , the 4th ventricle, and the fastigial point . The pontine bulge  is visible directly anterior to the vermis. (Right) Parasagittal transvaginal US corresponding to plane B in a younger fetus shows the choroid plexus  curving around from the body of the lateral ventricle into the temporal horn. The sylvian fissure  is just visible. The cortical mantle  in this fetus is still quite smooth.

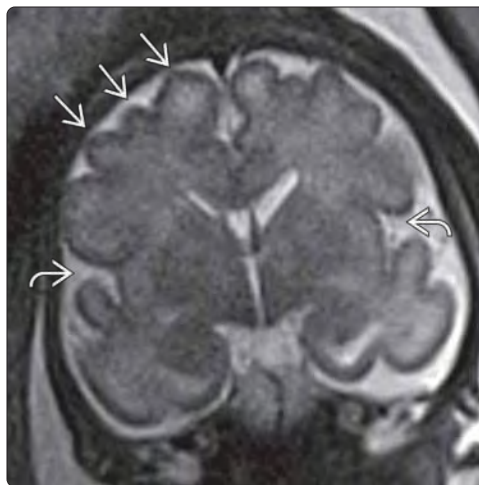
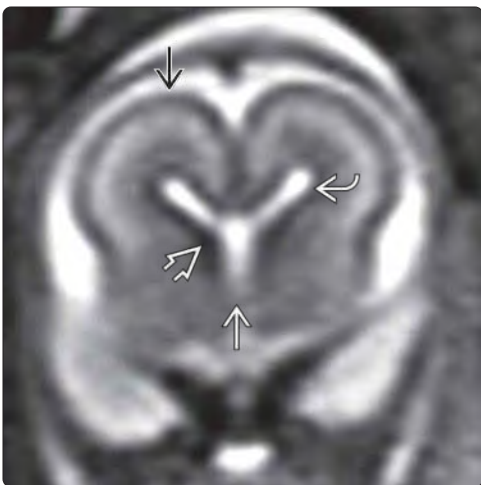










(Left) Axial color Doppler US shows the circle of Willis with the middle  and anterior cerebral  branches. SD ratios can be obtained at any angle, but peak systolic velocity must be measured with a zero angle of insonation. (Right) Sagittal color Doppler US shows the pericallosal artery , which only takes this course if the corpus callosum is present. If maternal habitus or fetal position precludes direct visualization, demonstration of a normal course of this vessel implies that the corpus callosum is intact.



(Left) Axial T2WI MR in a 30-week fetus shows normal cortex (low signal), deep white matter (intermediate signal), the sylvian fissure , parietooccipital sulcus , and narrow, divergent lateral ventricles . (Right) Sagittal T2WI MR in the same fetus shows the corpus callosum , central sulcus , parietooccipital fissure , and the tentorium cerebelli .



(Left) Coronal T2WI MR at 17 weeks shows simple brain architecture. The frontal horns  and 3rd ventricle  are easily seen. Note the very low signal germinal matrix  in the floor of the lateral ventricles with migrating neurons creating a layered appearance of the cortical mantle . (Right) Coronal T2WI MR at 37 weeks shows mature brain architecture with well-developed convexity gyri , fully opercularized sylvian fissures , and loss of the simple 3-layered appearance seen in the immature brain shown in the previous image.

Imaging Techniques and Normal Anatomy

Transabdominal Ultrasound

Transabdominal ultrasound is the mainstay of fetal imaging. The American Institute of Ultrasound in Medicine (AIUM) guidelines for performance of obstetric ultrasound mandate an oblique axial image through the posterior fossa in a plane that includes the cavum septi pellucidi to demonstrate the **cerebellar hemispheres, vermis, and cisterna magna**. The **transverse cerebellar diameter** is measured on this view and nomograms are available for cerebellar size in relation to gestational age. The vermis is best seen in the sagittal plane on 2D images, especially with vaginal ultrasound or on 3D reconstructions. Nomograms are available for vermian height and a number of other measurements, including clivotentorial distance, tectooccipital distance, posterior fossa area and perimeter. These are not standard measurements but can be useful in evaluation of posterior fossa malformations. It is now understood that the cerebellum and vermis play an important role in brain function and, as such, merit careful evaluation, which requires use of both axial and midline sagittal views. Even with the use of multiple scan planes and 3D volumes, the brainstem remains difficult to assess sonographically.

The **rhombencephalon** is the embryonic precursor to the posterior fossa structures. It first appears as a cystic structure in the embryo visible from about nine weeks gestational age. As the neural tube elongates, several flexures develop in the rhombencephalon; these are visible at the time of nuchal translucency screening (i.e., 11-14 weeks). The brainstem precursors are used as landmarks to verify a true midline sagittal scan plane. After about 14 weeks, the cranial structures are routinely imaged in axial planes; however, direct coronal and sagittal images can be obtained both abdominally and vaginally with transducer manipulation.

Complete sonographic evaluation of the posterior fossa requires **multiplanar images**. The axial plane is used to measure transcerebellar diameter, fourth ventricle size, and the cerebellar peduncle thickness. The coronal plane allows for improved differentiation between the vermis and the hemispheres. After 18 weeks, the inferior vermis should extend as far as the inferior level of the hemispheres. The midsagittal plane allows for assessment of the **vermian lobules, fissures, and fastigial point** as well as direct visualization of the **pons, cisterna magna, and tentorium**.

Transvaginal Ultrasound

Higher frequency vaginal transducers produce high-resolution images. This technique allows for direct acquisition of sagittal and coronal scan planes using the metopic suture and anterior fontanelle as acoustic windows when the fetus is in cephalic presentation. This is especially useful in the third trimester when skull ossification and head position deep in the maternal pelvis limit abdominal image quality. A complete neurosonographic evaluation of the fetus requires documentation of four coronal and three sagittal planes, in addition to the standard axial planes. The coronal transcerebellar and sagittal planes are of most benefit in the assessment of the posterior fossa structures.

Sonographic milestones for visualization of vermian structures have been published. The **primary fissure is observed at around 27-weeks** gestation and should be seen in all fetuses by 30 weeks. At that time, the white matter of the vermis (the arbor vitae) can also be observed. In most fetuses, some degree of differentiation between lobules is possible starting

from 30-32 weeks of gestation. The **fourth ventricle should be seen as a triangular structure anterior and caudal to the vermis**.

3D Ultrasound

3D sonography allows for acquisition of a fetal brain volume data set, which can then be manipulated to display orthogonal views. It is important to obtain the best 2D acoustic windows prior to acquiring a volume through the brain, as areas of shadowing in the acquisition plane will compromise reconstructions. Examples include sagittal acquisition through the anterior fontanelle or metopic suture, and axial acquisition from the standard posterior fossa view in the second trimester or through a mastoid approach in the third trimester.

Doppler Ultrasound

A dural sinus malformation has a characteristic appearance and location at the confluence of the venous sinuses. The majority are thrombosed at the time of fetal diagnosis and present as a "mass" at the torcular Herophili. Doppler should be used to assess any posterior fossa abnormality to avoid missing the diagnosis of a vascular anomaly. Although not in the posterior fossa per se, a vein of Galen malformation may first be seen as a midline "cyst" in the region of the tentorium. Doppler of the structure will confirm flow with evidence of arteriovenous shunting.

Magnetic Resonance Imaging

MR can be used regardless of fetal position; it is also less compromised by maternal obesity than ultrasound. Rapid T2WI sequences are used to obtain orthogonal images through the posterior fossa. T1WI is useful for evaluation of blood products. The anatomic detail is quite exquisite and structures may be visualized with more confidence and at an earlier gestational age than with US.

Sagittal MR provides excellent images of the brainstem, pons, and cerebellar peduncles. Pontocerebellar dysplasias have a grim prognosis; observation of a thinned brainstem with lack of a normal pontine bulge is important for prognostication. In families with a history of autosomal recessive inheritance, a combination of genetic testing and fetal MR may assist in prenatal diagnosis.

Approach to Posterior Fossa

As with the supratentorial brain, it is wise to have a mental checklist when examining the posterior fossa.

Occipital Contour

The first step is to evaluate the occipital bone contour, head position, and upper cervical spine. Cephaloceles may be quite small and subtle and can be missed if the occipital bone contour is not reviewed in its entirety. Chiari 3 malformation is associated with a high cervical spine defect. In Chiari 2 malformation, the posterior fossa is diminished in volume with a smaller, more funnel-like shape due to cerebellar tonsillar herniation.

Scalloping of the inner table of the calvarium is a classic finding in an arachnoid cyst and Dandy-Walker malformation due to mass effect in the confined space.

It is important to assess the occipital contour from different scan planes. Refraction of the ultrasound beam may simulate a cranial defect and lead to erroneous diagnosis of an occipital cephalocele in a fetus with a cystic hygroma.

Cisterna Magna

The depth of the cisterna magna is measured from the posterior surface of the vermis to the inner table of the calvarium in the midline. This should be **< 10 mm** throughout gestation. Linear echoes in the cisterna magna are thought to be vestigial remnants of the walls of the Blake pouch. Obliteration of the cisterna magna occurs in Chiari 2 malformation. The associated tonsillar herniation causes the cerebellum to wrap around the brainstem, producing the **"banana" cerebellum**. When seen, this should prompt thorough evaluation of the spine for the associated neural tube defect.

Falx Cerebelli and Torcular Herophili

The normal falx cerebelli is centrally inserted such that the posterior fossa is bisected. Asymmetric position of the falx is a clue to look for displacement by space-occupying lesions (such as an arachnoid cyst) or displacement due to asymmetry of the hemispheres (such as can be seen with cerebellar disruption or cerebellar hemihypoplasia). A unilateral, small cerebellar hemisphere may alert the sonologist to rare diagnoses such as PHACES syndrome.

The **torcular Herophili** marks the position of the confluence of venous sinuses. The transverse sinus meets the straight and superior sagittal sinuses. Enlargement of the cisterna magna (e.g., in Dandy-Walker malformation) causes elevation of the torcular and torcular-lambdoid inversion. The angle between the straight and superior sagittal sinuses (i.e., the **tentorial angle**) is usually between 50° and 75°. An angle > 80° indicates posterior fossa enlargement.

Cerebellum

The normal cerebellum is composed of two rounded lobes joined in the midline by the vermis. The banana sign (Chiari 2) and the **molar tooth sign** (Joubert syndrome) are examples of deviation from the norm. **Rhombencephalosynapsis** implies absence of the vermis with fusion of the cerebellar hemispheres. You will not miss this diagnosis if you visually check for hemisphere-vermis-hemisphere in every case.

The cerebellar hemispheres should be symmetric in size. As with the progressive gyration and sulcation in the supratentorial brain, cerebellar folia become more complex with increasing gestational age. This is visible on ultrasound and MR. The superior, middle, and inferior cerebellar peduncles may be visible on MR depending on gestational age.

Cerebellar disruptions may be unilateral. If so, the pons is often asymmetric with contralateral volume reduction. Infection, hemorrhage, and infarction have all been implicated.

Vermis

The vermis is measured on axial and sagittal planes. On the oblique axial view of the posterior fossa (including the cavum), the transverse diameter of the echogenic vermis is measured at the level of the fourth ventricle. On the sagittal view, the craniocaudal diameter is measured from the culmen to the uvula and the anteroposterior diameter from the central lobule to the tuber. If resolution is limited, the craniocaudal diameter can be measured at the limits of a line drawn perpendicular to the **fastigial declive line**. This line connects the fastigial point of the fourth ventricle to the uppermost surface of the declive, which is the lobule immediately inferior to the primary fissure. The fastigial declive line also allows assessment of superior and inferior lobar growth. Both grow

linearly and symmetrically, on either side of the primary fissure.

The **primary fissure** separates the anterior from posterior vermis; it runs between the culmen and the declive. It is visible by about 17.5 weeks on MR. On transvaginal ultrasound, it should be seen in all fetuses by 30 weeks. The secondary fissure, located between the pyramis and uvula, becomes visible on MR at about 24 weeks. By 27 weeks, all the vermian lobules should be evident.

The degree of vermian rotation is assessed by measuring the **tegmentovermian angle**. This is the angle between a line drawn along the dorsal surface of the brainstem, parallel to the tegmentum, and a line along the ventral surface of the vermis. The normal angle is close to zero, angles < 30 are likely due to Blake pouch cyst. Angles of > 45° are strongly associated with Dandy-Walker malformation.

Assessment of the fourth ventricle shape and size is an integral part of vermian evaluation. The **fastigial point** is the posterior, superior recess of the fourth ventricle; it forms an acute angle at the apex of the triangular-shaped fourth ventricle as seen on sagittal images.

Fourth Ventricle

The fourth ventricle is an ependymal cavity situated in the bulbopontine area of the brain, bordered anteriorly by the pons and the upper half of the medulla oblongata, posteriorly by the cerebellum, and laterally by the superior and inferior cerebellar peduncles. It can be assessed from 18 weeks onward. In the midline sagittal view, it appears triangular; the highest point or apex of the triangle is the fastigium. This is an important landmark for normal vermian development. On axial views, it is quadrangular with the anteroposterior diameter smaller than the transverse diameter.

Brainstem and Pons

The **normal pons creates a prominent bulge** anterior to the fourth ventricle. This is visible on both US and MR on a true sagittal image through the posterior fossa.

Pediatric MR has shown us that at the normal craniocervical junction, the angle between the medulla and the upper cervical cord ranges from 135-180°. In Dandy-Walker malformation, there is often an abnormal flexure at the craniocervical junction with smaller angles as low as 110°. The fetal correlate of this observation is referred to as the **"kinked brainstem,"** in which the brainstem has an abnormal, elongated, Z-shaped configuration. This is also referred to as a primitive brainstem configuration because it mimics the shape seen embryologically in the first trimester as the mesencephalic, pontine, and cervical flexures develop.

Is There Associated Supratentorial Brain Abnormality?

Cerebellar abnormalities are rarely isolated. Rhombencephalosynapsis is often associated with holoprosencephaly. Cerebellar hypoplasia is seen as part of some syndromes (e.g., Walker-Warburg) that are autosomal recessive and therefore carry a 25% recurrence risk in future pregnancies.

Is Fetus Otherwise Normal?

Mega cisterna magna has been described in association with trisomy 18. Affected fetuses usually have multiple anomalies, including omphalocele, diaphragmatic hernia, facial clefting, and congenital heart disease. The Chiari 2 malformation is associated with open neural tube defects, some of which can be very subtle and difficult to demonstrate.

Posterior Fossa Abnormalities: Imaging Findings

	Vermis Position	Vermis Size	Torcular Position	Cerebellar Hemispheres	4th Ventricle
Mega cisterna magna	N	N	N	N	N
Blake pouch cyst	Rotated	N	N	N	Enlarged, communicates with posterior fossa via valleculae
Arachnoid cyst	May be displaced	N or compressed	N	N or compressed	N or compressed
Vermian dysgenesis	May be rotated	Small or absent	N	N	Abnormal shape, lacks normal fastigial point
Dandy-Walker malformation	Rotated	Small or absent	Elevated	Often small	Dilated, enlarged, lacks normal fastigial point
Cerebellar hypoplasia	N	Small	N	Small	N or small
Pontocerebellar hypoplasia	N	Small	N	Small	Pontine bulge missing
Cerebellar disruption	N	N or small	N	Asymmetric; 1 smaller, abnormal structure	Variable depending on part of cerebellum disrupted
Joubert syndrome		Small or absent	N	Small	Large (associated with elongated superior cerebellar peduncles and molar tooth sign)
Rhombencephalosynapsis		Absent	N	Fused with continuous horizontal folia	Small, lacks normal fastigial point

N = Normal.

Pitfalls in Evaluation of Posterior Fossa

Rhombencephalon

This should not be mistaken for a posterior fossa cystic mass.

Incorrect Scan Plane

The cavum septi pellucidi should be included in the oblique axial plane used to measure the cisternal magna. If this is not done, the scan plane may be too steep (i.e., approaching a coronal plane) and the cisterna magna may look enlarged as it extends inferiorly toward the foramen magnum. The image obtained in this incorrect plane, through the fourth ventricular cavity rather than through the vermis, may erroneously suggest vermian dysgenesis or hypoplasia.

Premature Diagnosis of Vermian Abnormality

The vermis grows to "cover" the fourth ventricle. As fenestration of the Blake pouch occurs, the vermis takes up its normal position almost parallel to the brainstem. A vermian abnormality should not be diagnosed before 18-weeks gestational age. If the superior and inferior vermis are symmetrical and the fetus is otherwise normal, follow-up should be scheduled at 24 weeks before making a confident diagnosis of vermian hypoplasia.

Medially Displaced Cerebellar Hemispheres

If the vermis is deficient, or superiorly rotated, the cerebellar hemispheres may move medially into the space that would normally have been occupied by the vermis. Thus, the inexperienced imager may assume that the vermis is normal. This can be avoided by careful evaluation of the fastigial point and primary fissure in every case.

Normal but Rotated Vermis

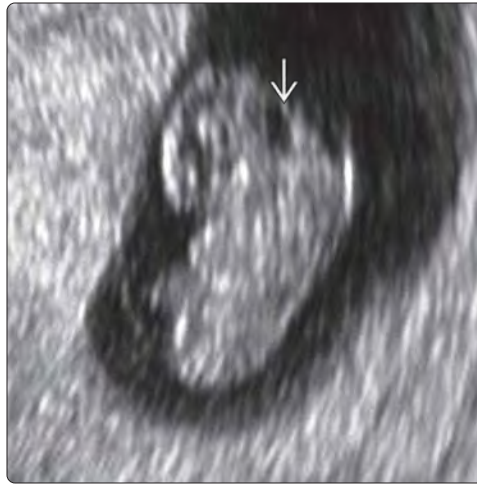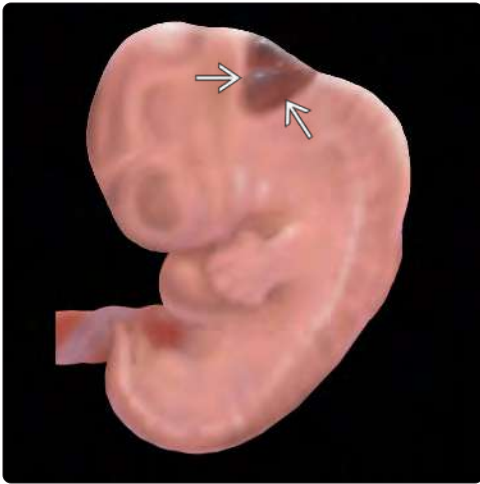
A Blake pouch cyst has a much better prognosis than vermian agenesis or dysgenesis. The normal but rotated vermis has a normal fastigial point and symmetric growth above and below the fastigial declive line but an increased tegmentovermian angle.

Atrophy/Unilateral Cerebellar Anomalies

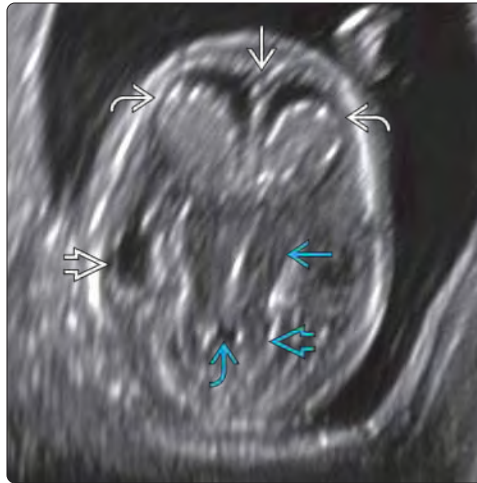
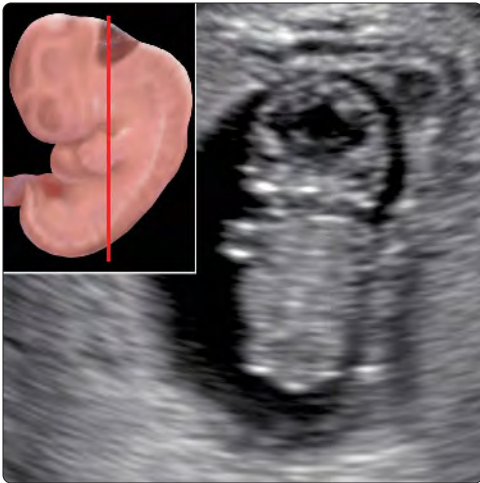
Cerebellar atrophy implies reduction in volume of a normally developed vermis or cerebellar hemisphere. This will only be detected if there is a normal study at 18-20 weeks with subsequent volume loss demonstrated on a later scan. Infection, hemorrhage, and the rarer pontocerebellar atrophy syndromes are considerations in the differential diagnosis of cerebellar atrophy.

Clinical Implications

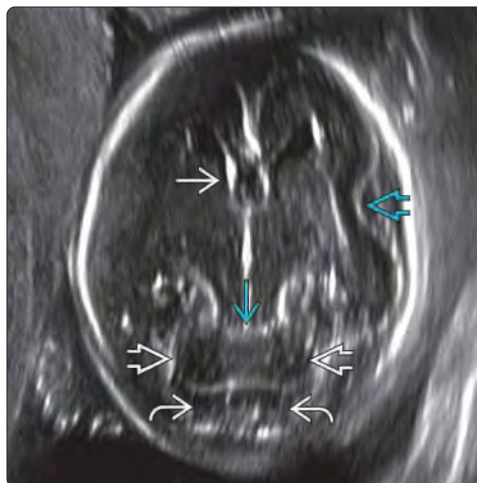
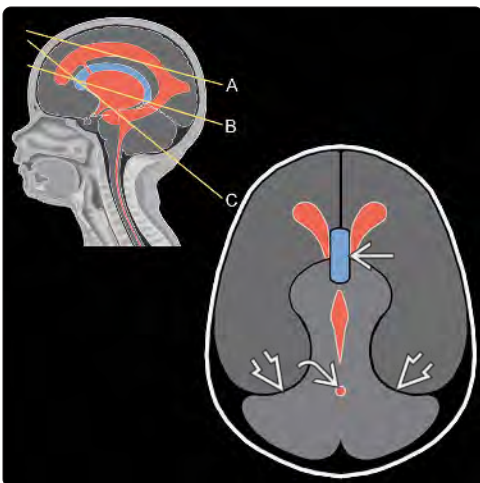
Postnatal correlation with prenatal diagnosis in the posterior fossa has been disappointingly poor. As a result of the pitfalls described above, it is possible that normal pregnancies have been terminated and certainly many parents have been needlessly worried about brain malformations in fetuses that turn out to have normal neuroimaging studies at birth. If pregnancy termination occurs, it is important to encourage autopsy for correlation. In liveborn infants, the postnatal imaging should be reviewed in all cases where a prenatal diagnosis of cerebellar anomaly was found. **A consistent, anatomically based approach to the posterior fossa is the best way to avoid misdiagnosis.**








(Left) Sagittal graphic shows the prominent cystic space created by the folding of the rhombencephalon. (Right) Sagittal US at 8 weeks, 2 days shows the normal rhombencephalon at the "crown" or cranial end of the embryo. Knowledge of normal developmental anatomy is essential to avoid making diagnostic errors. Modern equipment literally demonstrates embryology in vivo!

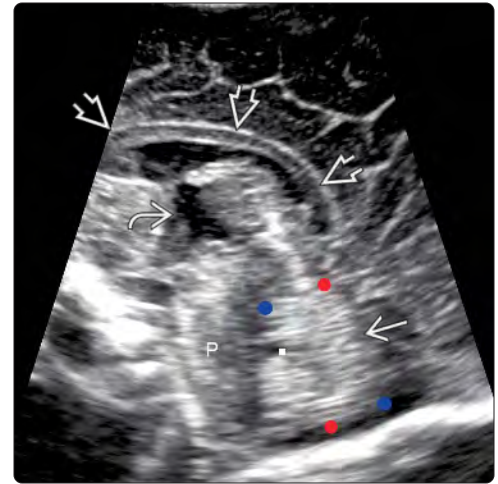
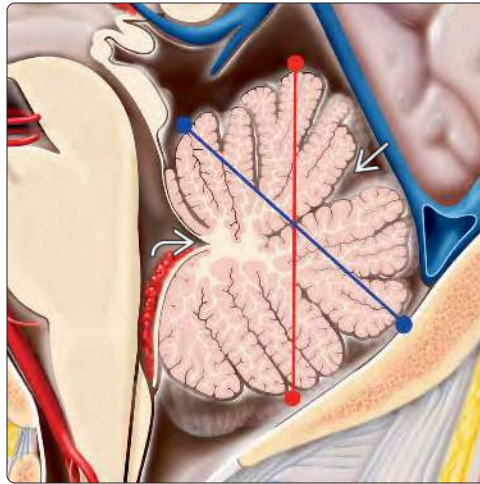










(Left) Coronal US through an 8-week, 6-day embryo shows what appears (at least to the unwary) to be a large intracranial cyst. This appearance is created by scanning through the normal rhombencephalon, as shown in the inset. (Right) Follow-up in the same case at 12 weeks shows normal early brain anatomy. Note the interhemispheric fissure between the frontal lobes, choroids, temporal lobe, thalamus, cerebellar peduncles, and 4th ventricle. The patient delivered a normal infant.

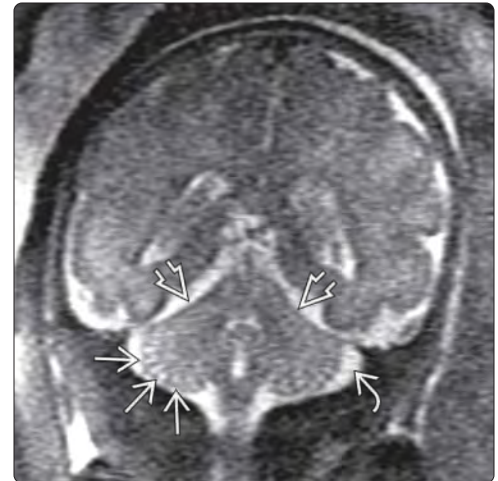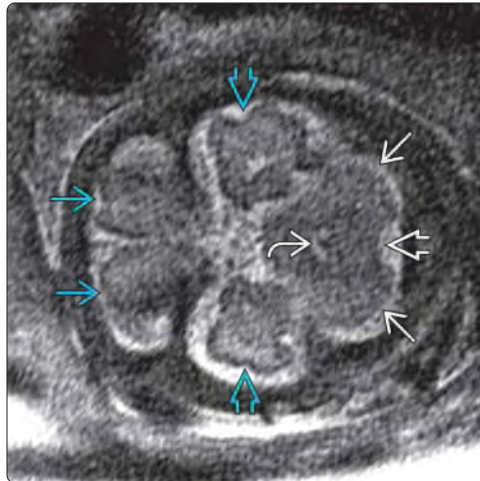




(Left) Graphic shows the correct scan plane (C) for evaluation of the posterior fossa contents on transabdominal US (4th ventricle, cerebellar hemispheres). The cavum septi pellucidi is included to ensure that the plane is not too steep. (Right) Axial oblique transabdominal US shows the cavum septi pellucidi, cisterna magna (measure depth from posterior vermian margin to inner table of skull), symmetric cerebellar hemispheres, and normal vermis. The sylvian fissure is also visible.

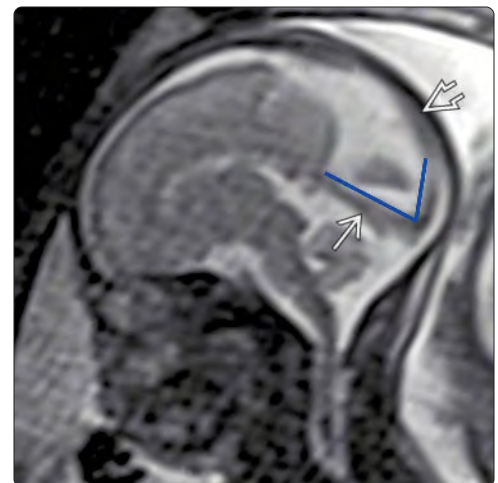
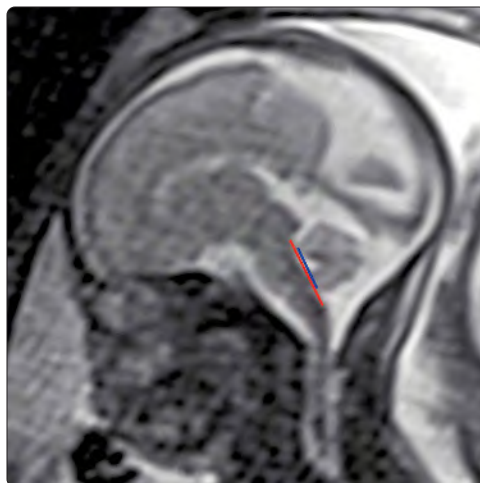
(Left) Measure craniocaudal diameter (red line) from the culmen superiorly to the uvula inferiorly and the AP diameter (blue line) from the central lobule anteriorly to the tuber posteriorly. Other important landmarks are the fastigial point  and primary fissure . **(Right)** Transvaginal US shows markers for vermian measurement: Culmen to uvula (red) and central lobule to tuber (blue). Note the fastigial point (white square), the primary fissure , the corpus callosum , the 3rd ventricle , and the pons (P).



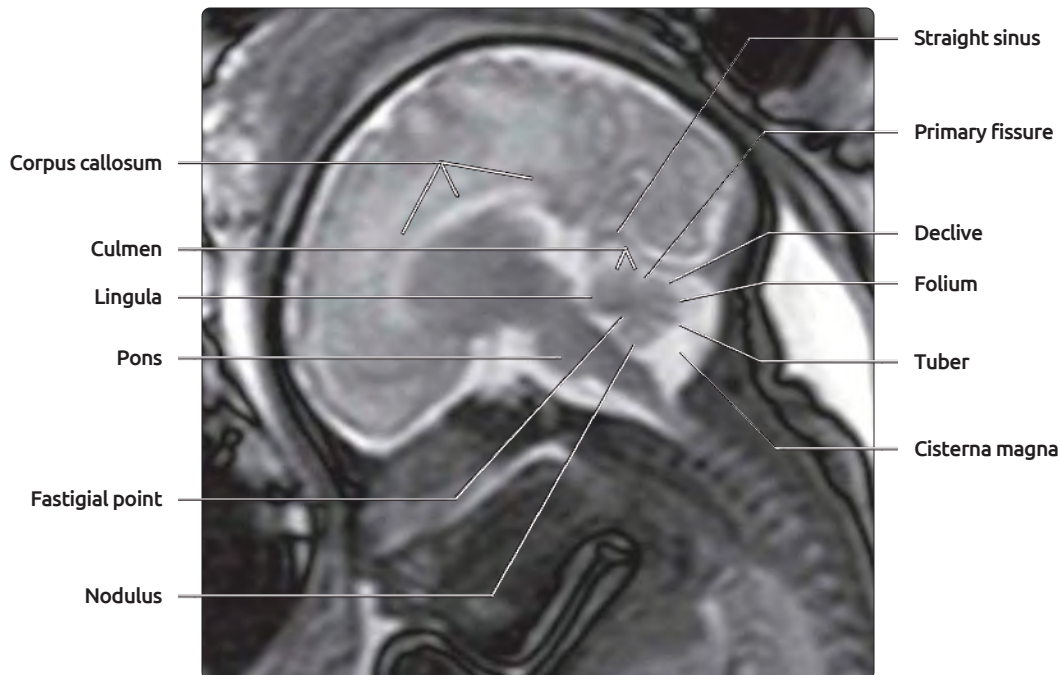
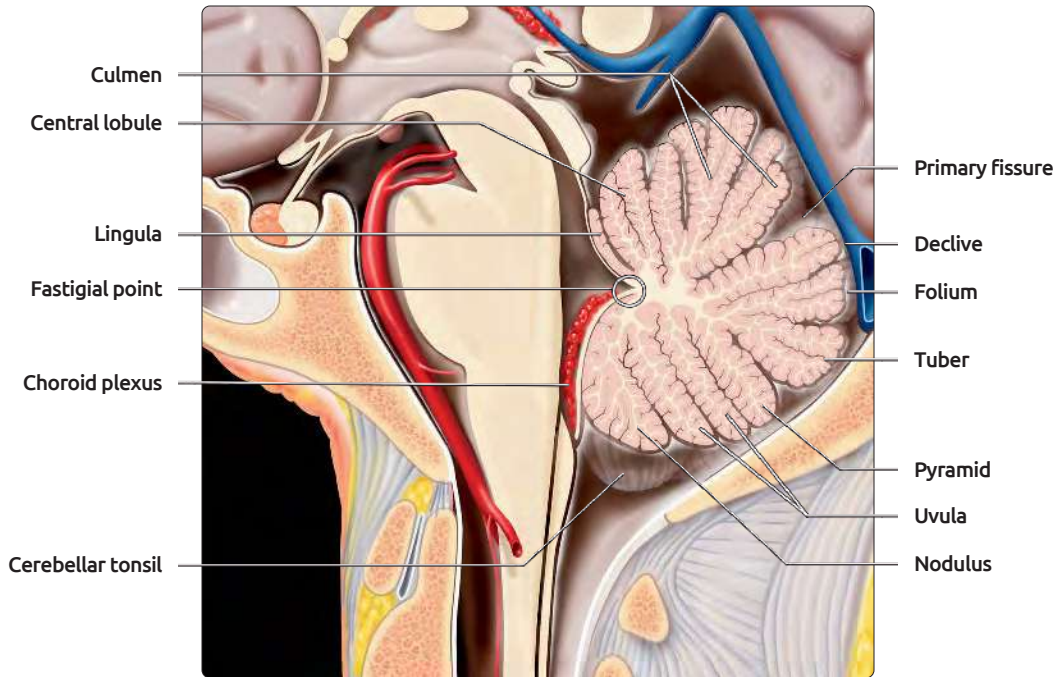
(Left) Axial T2WI MR shows the cerebellar hemispheres , the vermis , and 4th ventricle  in the posterior fossa. The temporal lobes  and inferior frontal lobes  are in the middle and anterior cranial fossae, respectively. **(Right)** Coronal T2WI MR through the level of the 4th ventricle in the 3rd trimester shows the cerebellar hemispheres  with well-developed folia . The cerebrospinal fluid  in the cisterna magna is high signal (i.e., white) on this sequence.



(Left) Sagittal T2WI MR shows the normal tegmentovermian angle, which should be about 0°. The red line is drawn along the dorsal surface of the brainstem, parallel to the tegmentum. The blue line is drawn along the ventral surface of the vermis. Angles > 40° are considered abnormal. **(Right)** Sagittal T2WI MR shows the normal tentorial angle between the straight sinus  and the superior sagittal sinus . If the torcular is elevated, this angle becomes obtuse. It normally measures 50-75°.



VERMIAN ANATOMY



(Top) Sagittal graphic through the vermis and 4th ventricle shows the vermicular lobules. Clockwise beginning with the lingula, these include the central lobule, culmen, declive, folium, tuber, pyramid, uvula, and nodulus. The 4th ventricle is triangular in shape in this plane with the apex of the triangle formed by the fastigial point. Note that the arbor vitae (white matter) and the fissures radiate from this point. **(Bottom)** The corresponding sagittal T2WI MR shows how much anatomic detail is visible in the 3rd trimester. MR also allows detailed assessment of the pons and brainstem, which can be quite difficult to see on US, particularly later in gestation.

KEY FACTS

TERMINOLOGY

- Exencephaly-anencephaly sequence
 - Exencephaly is early manifestation of anencephaly

IMAGING

- No calvarium with absence of neural tissue above orbits
 - Neural tissue wears away during gestation
 - No organized neural tissue remaining
 - Cranial defect covered by angiomatous stroma (area cerebrovasculosa)
 - Often contiguous with cervical spine defect
- Should be able to diagnose routinely at 10-14 weeks
 - Neural tissue is still present (exencephaly)
 - Head has irregular, flattened, splayed appearance
- Proptotic eyes
- Polyhydramnios common

TOP DIFFERENTIAL DIAGNOSES

- Amniotic band syndrome




- Calvarium may be absent but large amount of intact brain often remains
- Look for other defects
- Important distinction for counseling
 - Sporadic, no increased recurrence risk

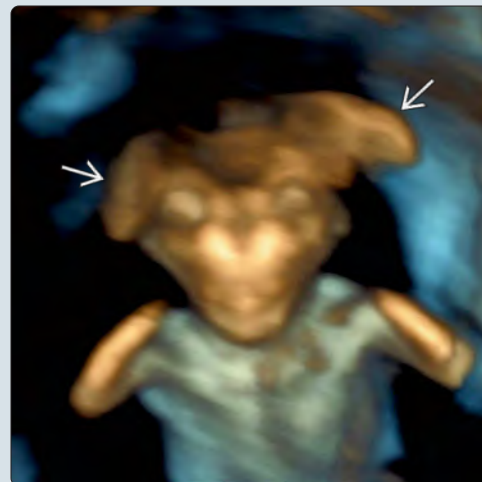
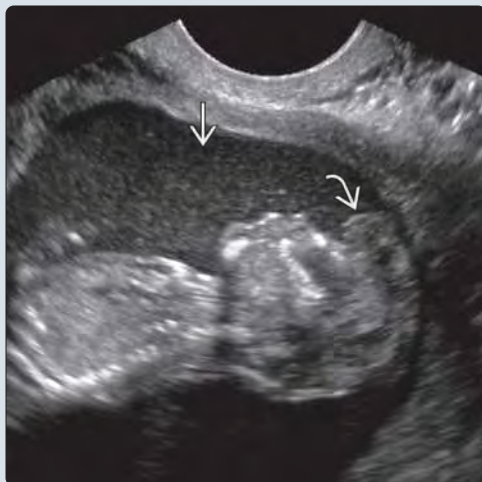
CLINICAL ISSUES



- Elevated maternal serum α -fetoprotein
- 2-5% recurrence risk
- Preconceptional folic acid should be given for future pregnancies
 - 4 mg/d reduces risk of recurrence by 70%

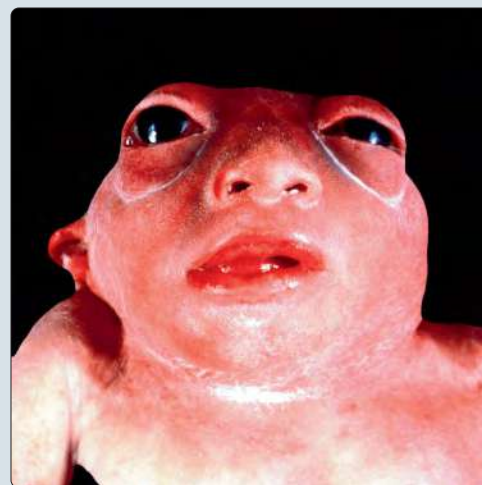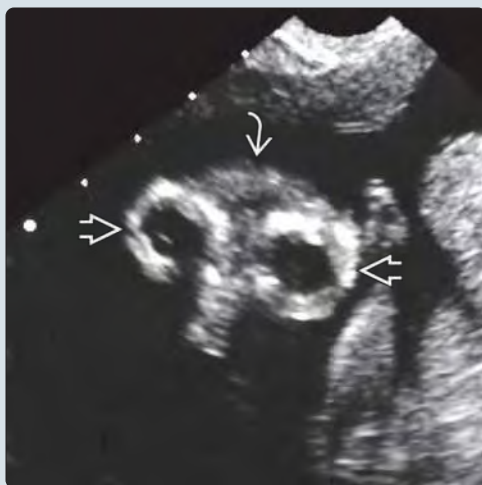
DIAGNOSTIC CHECKLIST

- Lethal malformation, which should be recognized in 1st trimester
- CRL < expected is not always due to incorrect dates
- Short-term follow-up for any case when head looks asymmetric or irregular

(Left) Sagittal ultrasound of a 13-week fetus with exencephaly shows no normal cranium and lobular exposed brain . As brain tissue erodes, the appearance changes from exencephaly to anencephaly. Note the increased echogenicity of the amniotic fluid  from dissolving neural tissue. **(Right)** This 3D surface reconstruction, in the same case, confirms no cranium and splaying of remaining brain tissue .



(Left) By the 2nd trimester, the neural tissue has worn away and there is now anencephaly. There is marked proptosis of the eyes (frog-like)  and there is near-complete absence of neural tissue  above the orbits. **(Right)** Autopsy photograph of an anencephalic fetus illustrates the classic proptotic, frog-like appearance of the eyes. This is secondary to shallow orbits and an abnormally formed skull base. The eyes themselves are normal in size.



TERMINOLOGY

Synonyms

- Exencephaly-anencephaly sequence

Definitions

- **Exencephaly** is precursor to **anencephaly**, part of sequence of destruction of exposed neural tissue

IMAGING

General Features

- Best diagnostic clue
 - No calvarium with absence of neural tissue above orbits
 - Detectable at time of nuchal translucency scan
 - Diagnosis should never be missed with routine views in 2nd trimester
- Morphology
 - Exencephaly/anencephaly sequence
 - Neural tissue wears away during gestation
 - Result of fetal movement and exposure to amniotic fluid
 - Small amounts of dysmorphic tissue may still be present in 2nd trimester
 - **Exencephaly**
 - Prominent neural tissue present
 - Remaining tissue abnormal with irregular contour
 - Typically seen in 1st trimester
 - **Anencephaly**
 - No organized neural tissue remaining
 - Cranial defect covered by angiomatous stroma (area cerebrovasculosa)

Ultrasonographic Findings

- **1st trimester**
 - Neural tissue is still present (exencephaly)
 - Abnormal head contour
 - Head has irregular, flattened, splayed appearance
 - Exposed brain has lobulated (Mickey Mouse) or spiked (Bart Simpson) appearance
 - Crown-rump length (CRL) less than expected
 - Endovaginal scan is mandatory in all suspected cases
- **2nd and 3rd trimesters**
 - Neural tissue has dissolved
 - No soft tissue above orbits
 - Remaining surface is irregular
 - Area cerebrovasculosa
 - Face
 - Proptotic eyes
 - Secondary to shallow orbits and abnormally formed skull base
 - Eyes themselves normally formed
 - Frog-like appearance when face viewed in coronal plane
 - Cleft lip/palate may be seen
 - Often have other open neural tube defects
 - Most commonly contiguous with cervical spine defect
 - Lumbar myelomeningocele
 - Polyhydramnios common
 - Secondary to impaired swallowing

- Amniotic fluid often echogenic secondary to dissolved neural tissue

- 3D ultrasound
 - More detailed depiction of cranial contour
 - May potentially increase accuracy in 1st trimester

MR Findings

- Not needed for diagnosis
- May be useful if ultrasound is compromised or equivocal (e.g., maternal habitus, oligohydramnios)
- Little or no supratentorial brain remains
- Brainstem and cerebellum often dysplastic

Imaging Recommendations

- Endovaginal scanning in 1st trimester for earlier diagnosis
 - Often difficult diagnosis to make before 10 weeks
 - Visible tissue of exencephaly may be mistaken for normal brain
 - Should be able to diagnose routinely at 10-14 weeks
 - Short-term follow-up if suspicious
 - Examine cranial contour carefully
 - Splayed, flattened, lobular, or spiked
 - Can measure crown-chin length (CCL)
 - 77% of anencephaly < 5th percentile
 - CCL:CRL ratio
 - 62% of anencephaly < 5th percentile
 - Correlate with maternal serum α -fetoprotein
- Routine 2nd-trimester cranial views detect 100%

DIFFERENTIAL DIAGNOSIS

Amniotic Band Syndrome

- Calvarium may be absent but large amount of intact brain often remains
- "Slash" defects
 - Asymmetric defects in nonanatomic distribution
- Other body parts often affected
- Bands are often difficult to see
 - Fetus may appear "stuck"
- Sporadic, no increased recurrence risk

Encephalocele

- Cranium present
- Neural tissue protrudes through defect
 - Most commonly occipital in Western countries
- May be difficult to differentiate in 1st trimester
 - Becomes obvious with advancing gestational age

Severe Microcephaly

- Cranium intact
- Sloped forehead
- Cerebrum present
- Multiple etiologies, including developmental and infectious

Atelencephaly, Aprosencephaly

- Severe microcephaly \pm limb abnormalities
- Fluid-filled, small calvarium with absence of supratentorial structures
- Severe craniofacial anomalies
 - May have no recognizable facial features
- Cranium intact

PATHOLOGY

General Features

- Etiology
 - Risk factors
 - Folic acid deficiency
 - Insulin-dependent diabetes
 - Obesity
 - Methotrexate, valproic acid, carbamazepine, aminopterin (folic acid antagonists)
 - Hyperthermia
 - Mycotoxins in contaminated corn meal
 - Arsenic
 - Embryology
 - Anterior neuropore closes on day 24
 - Failure of closure results in cranial defects, including anencephaly, encephaloceles, and iniencephaly
 - Skull complete by 10 weeks
- Genetics
 - Genes involved in folate metabolism are believed to be important (*MTHFR*)
 - Reported in trisomy 13 and 18
 - 2-5% recurrence risk
- Associated abnormalities
 - Reported in 41% but lack importance given lethality
 - Spina bifida ± myelomeningocele, especially cervical spine: 27%
 - Genitourinary: 16%; cleft lip/palate: 10%; gastrointestinal: 6%; and cardiac: 4%
- Multifactorial disorder that likely results from combination of etiologic agents
 - Genetic, environmental, metabolic, and nutritional

Gross Pathologic & Surgical Features

- Absent calvarium and prosencephalic structures
- Rhombencephalic structures remain
- Defect is covered by angiomatous stroma (area substantia cerebrovasculosa)

CLINICAL ISSUES

Presentation

- Most common signs/symptoms
 - Abnormal 1st-trimester scan
 - Can be reliably diagnosed by 10-14 weeks
 - Elevated maternal serum α -fetoprotein
 - > 2.5 multiples of median abnormal
 - Detects 90% of anencephaly
 - Obvious finding on routine midtrimester scan
- Other signs/symptoms
 - Large for dates secondary to polyhydramnios

Demographics

- Epidemiology
 - 1:1,000 births
 - Whites and Hispanics more often affected than those of African descent
 - United Kingdom: Highest European incidence
 - Decline of 21% in USA from 1996-2001 with fortification of wheat flour with folic acid

- Females disproportionately represented among anencephalics (~ 4:1), vs. 1:1 sex ratio in myelomeningocele
 - Reason for unequal ratio not well understood

Natural History & Prognosis

- Lethal malformation
 - May live hours to days
 - 5-10% live to 1 week

Treatment

- Termination offered
- Supportive care for family
- Genetic counseling regarding family history and recurrence risks
- Nonintervention for fetal distress
- Avoid cesarean section
- Anencephalic fetuses do not have functioning pituitary gland, which plays role in spontaneous labor
 - May need to induce labor
- May potentially be considered for organ donation
 - Legal and ethical consideration still make this difficult
- Preconceptual folic acid
 - 4 mg/d reduces risk of recurrent neural tube defect by 70%
 - 0.4 mg/d for all women

DIAGNOSTIC CHECKLIST

Consider

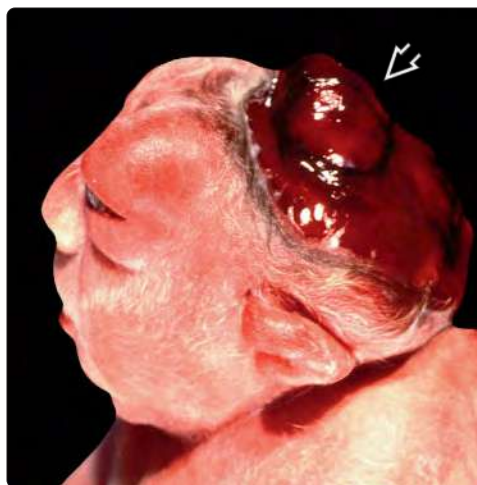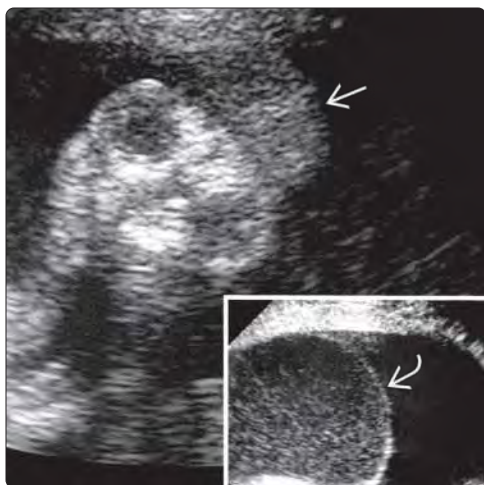
- CRL < expected is not always due to incorrect dates
 - May be early indicator of anencephaly
 - Short-term follow-up for any case when head looks asymmetric or irregular

Image Interpretation Pearls

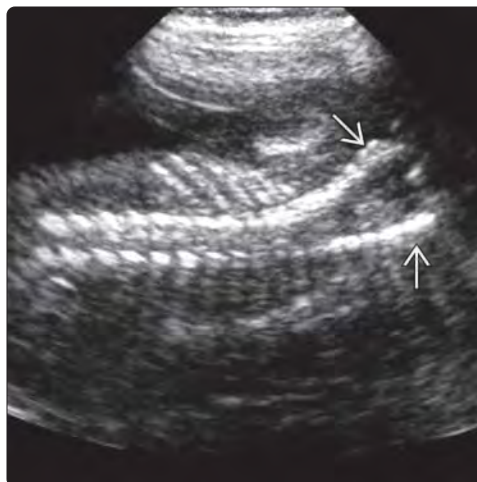
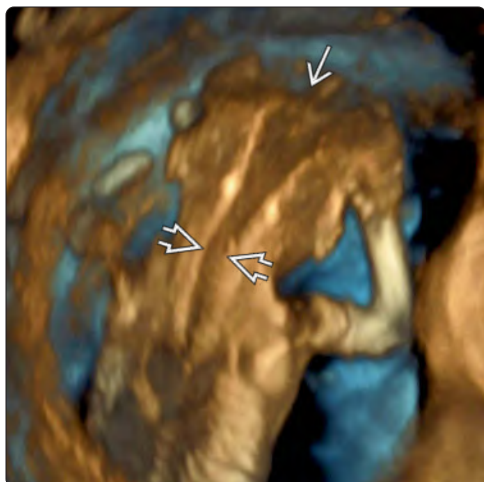
- Lethal malformation, which should be recognized in 1st trimester
- Exencephaly evolves into anencephaly

SELECTED REFERENCES

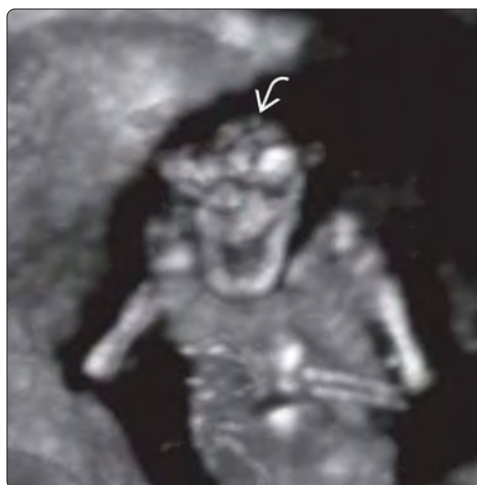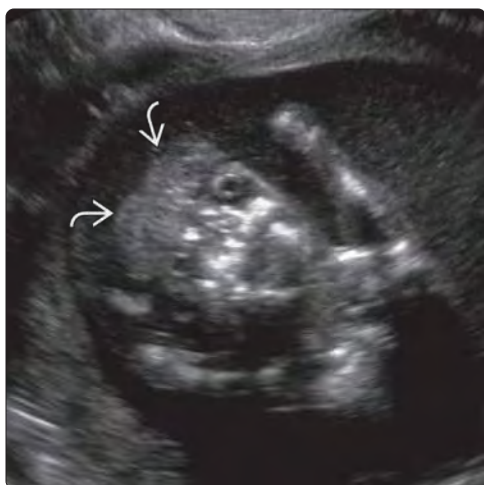1. Fleurke-Rozema JH et al: Timing of detection of anencephaly in the Netherlands. *Prenat Diagn.* 35(5):483-5, 2015
2. Pelizzari E et al: Characteristics of fetuses evaluated due to suspected anencephaly: a population-based cohort study in southern Brazil. *Sao Paulo Med J.* 133(2):101-8, 2015
3. Wilson RD et al: Pre-conception folic acid and multivitamin supplementation for the primary and secondary prevention of neural tube defects and other folic acid-sensitive congenital anomalies. *J Obstet Gynaecol Can.* 37(6):534-52, 2015
4. Wilson RD et al: Prenatal screening, diagnosis, and pregnancy management of fetal neural tube defects. *J Obstet Gynaecol Can.* 36(10):927-42, 2014
5. Copp AJ et al: Neural tube defects: recent advances, unsolved questions, and controversies. *Lancet Neurol.* 12(8):799-810, 2013
6. Youngblood ME et al: 2012 Update on global prevention of folic acid-preventable spina bifida and anencephaly. *Birth Defects Res A Clin Mol Teratol.* 97(10):658-63, 2013
7. Johnson S et al: Exencephaly: a first-trimester diagnosis. *Ultrasound Q.* 28(3):209-11, 2012
8. Obeidi N et al: The natural history of anencephaly. *Prenat Diagn.* 30(4):357-60, 2010
9. Stothard KJ et al: Maternal overweight and obesity and the risk of congenital anomalies: a systematic review and meta-analysis. *JAMA.* 301(6):636-50, 2009
10. Copp AJ: Neurulation in the cranial region—normal and abnormal. *J Anat.* 207(5):623-35, 2005



(Left) Coronal ultrasound in a twin pregnancy with 1 normal twin and 1 anencephalic twin shows that some neural tissue still remains. The amniotic fluid (inset) is markedly echogenic when compared to the adjacent sac of the normal twin. This is common in anencephaly and represents dissolved neural tissue. **(Right)** Lateral view of the angiomasous stroma (area cerebrovasculosa) covering the defect results in the ultrasound appearance.



(Left) 3D image in the 1st trimester shows not only anencephaly but also an extensive open neural defect of the cervical spine. Spina bifida, especially cervical, is often seen with anencephaly; both a result of failure of anterior neuropore closure. **(Right)** Coronal ultrasound of the cervical spine in a midtrimester fetus with anencephaly shows the defect continuing inferiorly to involve the cervical spine.



(Left) Transvaginal ultrasound of a 1st-trimester fetus with exencephaly shows a flattened, lobular appearance of the exposed neural elements. Recognition of the 1st-trimester appearance of anencephaly is important for early diagnosis of this lethal malformation. **(Right)** 3D image of an early midtrimester fetus with anencephaly shows complete absence of the calvarium above the forehead with a small mound of residual angiomasous stroma.

KEY FACTS

TERMINOLOGY

- Defect in skull and dura with protrusion of intracranial structures

IMAGING

- Bony defect with paracranial mass
- Diverse appearance of herniated tissue
 - Gyral pattern may be identified (more organized than anencephaly)
 - Cyst within cyst or target sign suggests prolapsed 4th ventricle
- Ventriculomegaly in 70-80%
- Microcephaly in 25%
- Other CNS anomalies common

TOP DIFFERENTIAL DIAGNOSES

- Amniotic band syndrome
- Cystic hygroma

PATHOLOGY




- Associated with multiple syndromes
- Meckel-Gruber most common genetic disorder
 - Encephalocele, polydactyly, polycystic kidneys

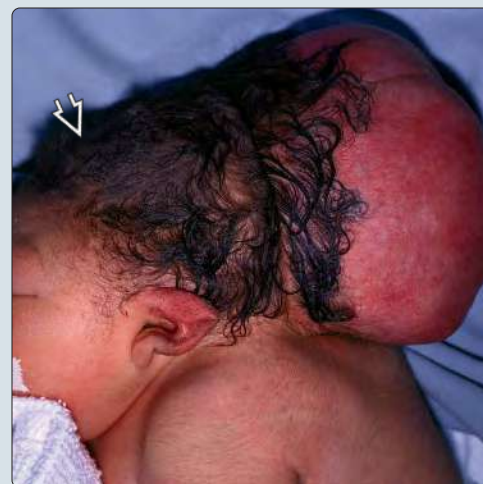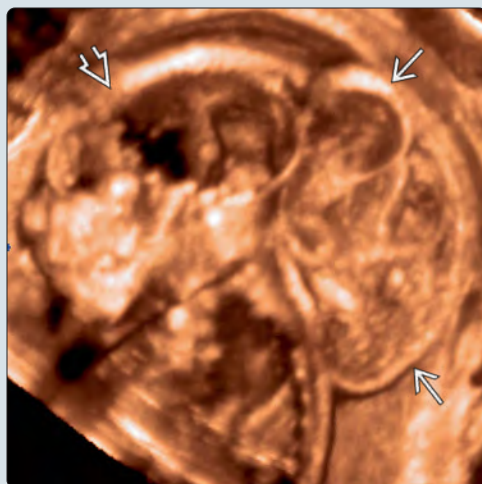
CLINICAL ISSUES





- 80% of all cephaloceles in white populations of North America and Europe are occipital
- Prognosis varies with amount of brain tissue in defect and associated malformations
 - Isolated cranial meningocele better prognosis
 - 79% mortality in fetal series
- Most are skin covered so maternal serum α -fetoprotein usually not elevated

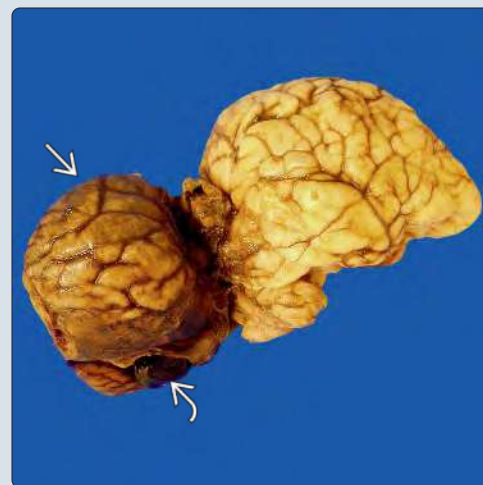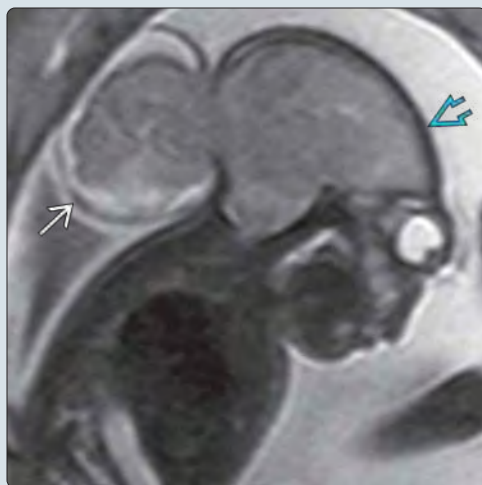DIAGNOSTIC CHECKLIST

- Edge artifacts may simulate cranial defect
- In early pregnancy, cystic hygroma often misdiagnosed as cephalocele and vice versa

(Left) Sagittal 3D reconstruction shows dramatic sloping of the forehead , indicating microcephaly with most of the brain  contained within the cephalocele. (Right) Clinical photograph after delivery shows a similar sloping forehead and microcephaly , as well as the large encephalocele. Encephaloceles are generally skin covered so maternal serum α -fetoprotein is usually not elevated. This degree of brain herniation cannot be repaired.



(Left) Sagittal T2WI fetal MR shows a large occipital encephalocele . Other images showed herniation of the brainstem and cerebellum such that this cephalocele was deemed inoperable. Note the sloped forehead  indicating associated microcephaly. (Right) Gross pathology in the same patient shows the brain after removal during autopsy. Almost 1/2 of the cerebral tissue  was involved in the defect. There was also hemorrhagic infarction of the cerebellar tonsils .



TERMINOLOGY

Definitions

- Cephalocele: Defect in skull and dura with protrusion of intracranial structures
- Further described by contents
 - Encephalocele (meningoencephalocele): Cerebrospinal fluid (CSF), brain tissue, and meninges
 - Meningocele: Meninges and CSF
 - Atretic cephalocele: Forme fruste of cephalocele with protrusion of dura, fibrous tissue, and ectopic neuroglial rests
- May also be categorized by location of bony defect
- Other related terms
 - Cranioschisis: Congenital failure of skull to close, typically accompanied by defective brain development
 - Craniorachischisis: Congenital fissure of cranium and vertebral column

IMAGING

General Features

- Best diagnostic clue
 - Bony defect with paracranial mass
- Location
 - Categorized by location of bony defect
 - Occipitocervical, occipital, parietal, frontal, temporal, frontoethmoidal, sphenomaxillary, sphenoorbital, nasopharyngeal, and lateral
 - High percentage of all cephaloceles are atretic, especially parietal
- Size
 - Variable: May be atretic and mistaken for scalp mass; may be enormous
- Morphology
 - Equal frequency for supra- and infratentorial involvement
 - Supratentorial and infratentorial structures and tentorium may all be included within cephalocele
 - Occipital horn of lateral ventricle and 4th ventricle may be included within cephalocele

Ultrasonographic Findings

- **1st trimester**
 - Head may look small or irregular
 - Must do endovaginal examination
 - Can see cranial defect in late 1st trimester
- **Brain**
 - Diverse appearance of herniated tissue
 - Gyral pattern may be identified (more organized than anencephaly)
 - Mixed cystic/solid mass
 - Purely cystic
 - Cyst within cyst or target sign
 - Suggests prolapsed 4th ventricle through defect
 - Normal intracranial landmarks distorted
 - Posterior (occipital and occipitocervical) cephaloceles may cause changes similar to Chiari 2
 - Ventriculomegaly in 70-80%
 - Impaired CSF flow
 - Primary brain malformation

- Microcephaly in 25%
- Other CNS anomalies common
 - Absent cavum septi pellucidi
 - Anomalous corpus callosum
 - Dorsal interhemispheric cysts
 - Chiari malformations, including spina bifida
 - Gray matter heterotopia
 - Dandy-Walker malformation
 - Cerebellar cortical dysplasia
 - Venous sinus anomalies
- **Cranium**
 - Osseous defect should be demonstrated
 - Occipital: Usually midline posterior ± involvement of foramen magnum
 - Parietal: Usually midline and higher
 - Assess crucial relationship to superior sagittal sinus
 - May be difficult to see defect with atretic cephalocele
 - Lemon sign in 30%
 - Depression of frontal bones
- Both polyhydramnios and oligohydramnios described
 - Oligohydramnios more likely to have concurrent defects (e.g., cystic kidneys in Meckel-Gruber syndrome)

MR Findings

- Best for determining contents of cephalocele and associated CNS anomalies
 - Herniated brain tissue often dysplastic with abnormal signal intensity

Imaging Recommendations

- Always image from several directions to exclude edge artifact as mimic for calvarial discontinuity
- Use endovaginal sonography in 1st trimester
- Fetal MR best for evaluation of herniated contents and associated parenchymal malformations
 - Content of cephalocele is major determining factor in prognosis
 - Define relationship with dural sinuses and patency of sinuses

DIFFERENTIAL DIAGNOSIS

Amniotic Band Syndrome

- May cause cranial defect and cephalocele
- Facial "slash" defects common
 - Large, obliquely oriented facial clefts
- Bands may be visible
- Other body parts often affected

Body Stalk Anomaly

- Severe disorganization with multiple body wall defects
- Scoliosis
- Absent/short umbilical cord

Exencephaly, Anencephaly, Acrania

- No cranium
- Variable amounts of brain tissue

Cystic Hygroma

- Septated cystic neck mass without contained neural tissue
- Cranium intact
- Hydrops common

Iniencephaly

- Neck in hyperextension ("stargazer" position)
- Encephalocele
- Rachischisis involving spine
- Absent cervical vertebrae

Chiari 3

- Hindbrain herniation (Chiari 2) with occipital or high cervical encephalocele

Scalp Masses

- Usually confused with atretic cephalocele
- Cranium intact

PATHOLOGY**General Features**

- Etiology
 - Several proposed mechanisms
 - Primary failure of cranial neuropore closure
 - Secondary event with pressure erosion and herniation of neural tissue
 - Failure of induction of membranous bone
 - Maternal obesity implicated as risk factor
 - Teratogens
 - Warfarin embryopathy: Nasal hypoplasia, ocular defects, thrombocytopenia, multiple CNS anomalies including cephalocele
- Genetics
 - Multifactorial, many sporadic
 - Many autosomal recessive syndromes
 - Meckel-Gruber syndrome most common
 - ◻ Encephalocele, polydactyly, polycystic kidneys
 - Walker-Warburg syndrome
 - ◻ Lissencephaly, hydrocephalus, encephalocele, microphthalmia, cataracts
 - Knobloch syndrome
 - ◻ Vitreoretinal degeneration and encephalocele
 - Trisomy 13, 18, triploidy
- Associated abnormalities
 - Cephalocele may be 1 feature of more complex defect
 - Chiari 3, rachischisis, iniencephaly
 - Body malformations common, either isolated or as part of syndrome

Gross Pathologic & Surgical Features

- Herniated brain is dysplastic

CLINICAL ISSUES**Presentation**

- Cranial defect
- Most are skin covered so maternal serum α -fetoprotein usually not elevated

Demographics

- Epidemiology
 - 1-3:10,000 in United States
 - 80% of all cephaloceles in white populations of North America and Europe are occipital
 - 10% parietal

- Frontal encephaloceles more common in Southeast Asia

Natural History & Prognosis

- Varies with amount of brain tissue in defect and associated malformations
- 79% mortality in fetal series
 - Fetal anomalies of any type are generally more severe than corresponding postnatal anomalies
- 40% mortality in neonatal series
 - Isolated cranial meningocele has better prognosis
- Survivors: 80% neurologic impairment
 - Developmental delay, often significant
 - Seizures
- 2-5% recurrence risk, unless associated with syndrome
- 25% recurrence risk for autosomal recessive disorders

Treatment

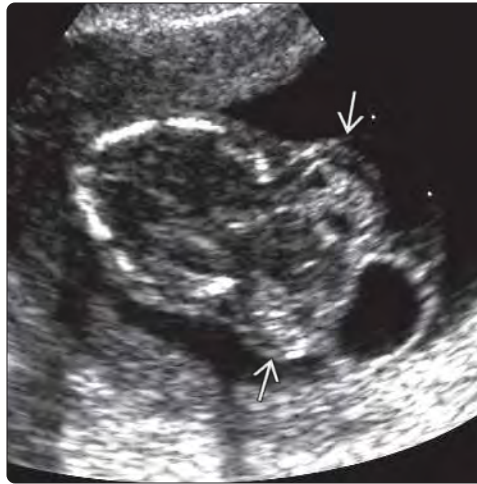
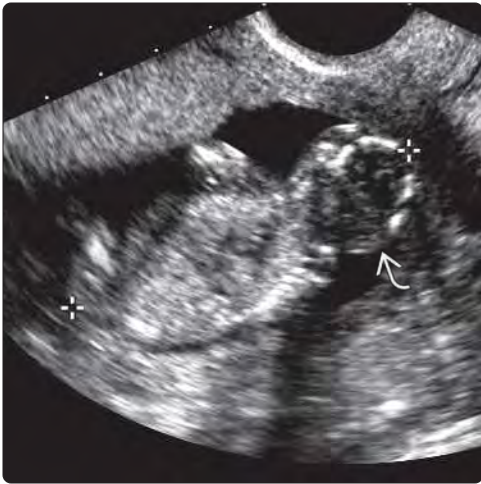- Offer karyotype
 - Thorough family history and genetic counseling
- Termination offered
- If pregnancy continues
 - Monitor head size
 - Microcephaly poor prognostic sign
 - Ventriculomegaly may be progressive
 - Herniated contents may become more cystic over time
 - Small cephaloceles may "disappear" (atretic connection found after delivery)
 - Antepartum neurosurgery referral for surgical planning
 - Deliver at tertiary care facility
 - Cesarean section considered to reduce birth trauma

DIAGNOSTIC CHECKLIST**Image Interpretation Pearls**

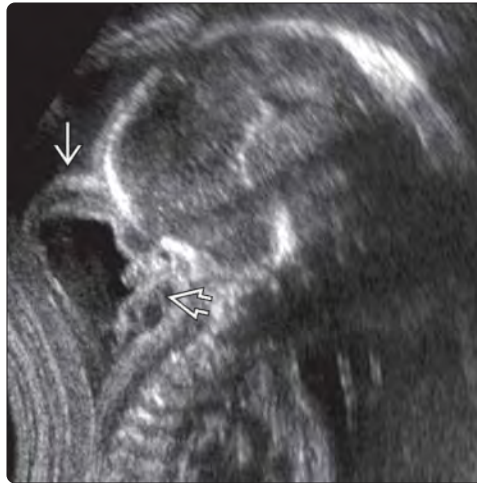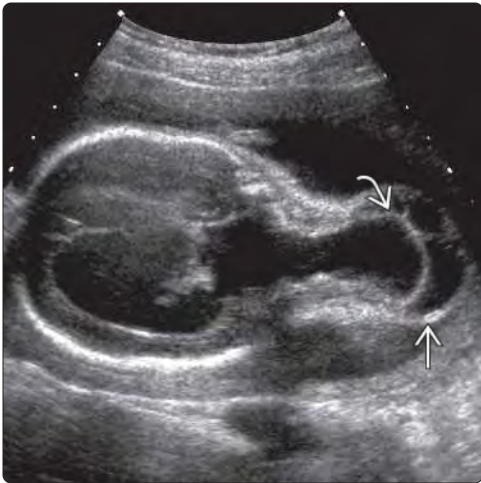
- Edge artifacts may simulate cranial defect
- In early pregnancy, cystic hygroma often misdiagnosed as cephalocele and vice versa
- For isolated encephaloceles, prognosis most impacted by volume of herniated parenchyma, microcephaly, and ventriculomegaly

SELECTED REFERENCES

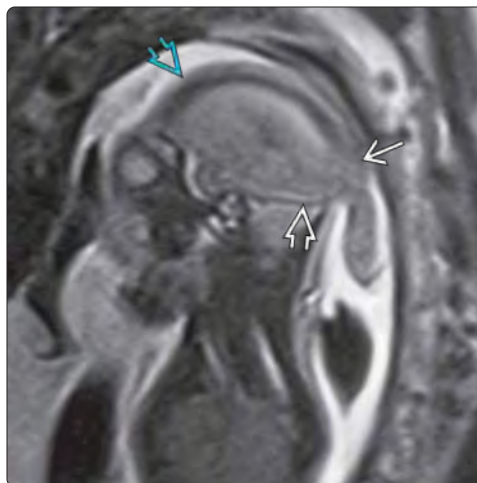
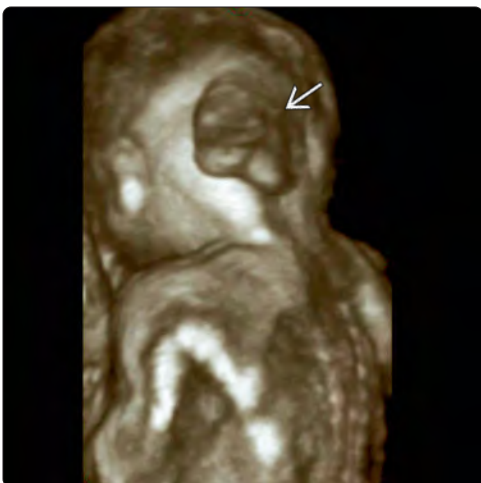1. Da Silva SL et al: Risk factors for hydrocephalus and neurological deficit in children born with an encephalocele. *J Neurosurg Pediatr.* 15(4):392-8, 2015
2. Kasprian CJ et al: Prenatal imaging of occipital encephaloceles. *Fetal Diagn Ther.* 37(3):241-8, 2015
3. Jones D et al: First-trimester diagnosis of Meckel-Gruber syndrome by fetal ultrasound with molecular identification of CC2D2A mutations by next-generation sequencing. *Ultrasound Obstet Gynecol.* 44(6):719-21, 2014
4. Sepulveda W et al: Fetal cephalocele: first-trimester sonographic spectrum in a review of 35 cases. *Ultrasound Obstet Gynecol.* 46(1):29-33, 2014
5. Gudu W et al: Encephalocele following a periconceptional exposure to efavirenz: a case report. *J Perinatol.* 33(12):987-8, 2013
6. Bađci S et al: Intestinal atresia, encephalocele, and cardiac malformations in infants with 47,XXX: Expansion of the phenotypic spectrum and a review of the literature. *Fetal Diagn Ther.* 27(2):113-7, 2010
7. Kıymaz N et al: Prognostic factors in patients with occipital encephalocele. *Pediatr Neurosurg.* 46(1):6-11, 2010
8. Baradaran N et al: Cephalocele: report of 55 cases over 8 years. *Pediatr Neurosurg.* 45(6):461-6, 2009
9. Jalali A et al: Linkage to chromosome 2q36.1 in autosomal dominant Dandy-Walker malformation with occipital cephalocele and evidence for genetic heterogeneity. *Hum Genet.* 123(3):237-45, 2008



(Left) Sagittal transabdominal ultrasound in the 1st trimester shows the head appearing irregular and small. (Right) Axial transvaginal ultrasound of the same fetus shows an obvious large encephalocele. Cephaloceles may be identified in the 1st trimester, and any head irregularity on a transabdominal scan should be further investigated with endovaginal sonography. Genetic counseling should be offered as cephaloceles may be seen with multiple genetic syndromes, most commonly Meckel-Gruber syndrome.



(Left) Axial oblique ultrasound through an occipital cephalocele shows the cyst within a cyst or target sign, which is created when the 4th ventricle herniates into the cephalocele. (Right) Sagittal ultrasound in another occipital meningoencephalocele shows that most of the herniated mass represents cerebrospinal fluid (CSF), with only a small component of brain. An occipital encephalocele containing predominately CSF can be confused with a cystic hygroma.



(Left) 3D surfaced-rendered ultrasound shows a parietal encephalocele, which occur higher on the cranium than an occipital encephalocele. (Right) Sagittal MR in the same patient shows the defect is just above the tentorium cerebelli. This is the location of the torcular Herophili, the confluence of the superior, straight, and transverse sinuses. This makes repair of even small cephaloceles difficult. Also note the sloping forehead and microcephaly.

KEY FACTS

TERMINOLOGY

- Form fruste of encephalocele consisting of dura, fibrous tissue, and dysplastic neuroglial rests

IMAGING

- Midline interparietal most common location
 - Occasionally occipital
- Small scalp mass with variable echogenicity
- Calvarial defect often difficult to see
- MR very helpful in work-up
 - CSF tract and vertical falcine venous sinus "point" to subcutaneous scalp mass
 - Prominent superior cerebellar cistern and peaked tentorium

TOP DIFFERENTIAL DIAGNOSES

- Scalp masses
 - Hemangioma
 - Lymphangioma

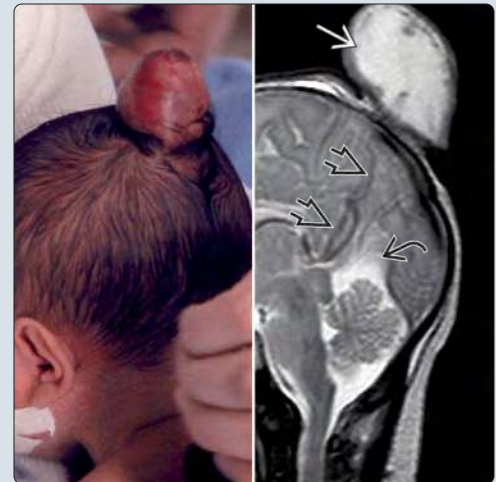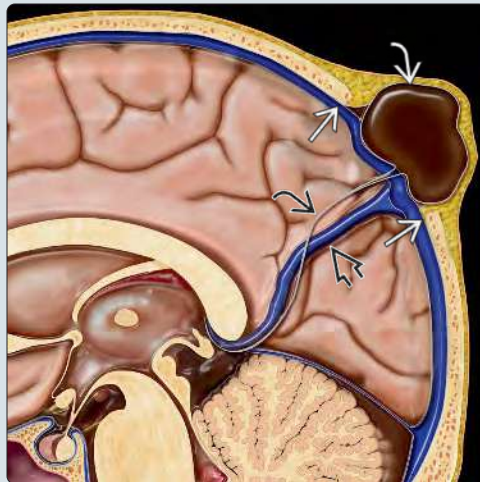
PATHOLOGY

- Considered involuted true cephalocele (meningocele or encephalocele)
- Other brain and eye abnormalities common
 - Callosal agenesis/dysgenesis, holoprosencephaly, interhemispheric cyst

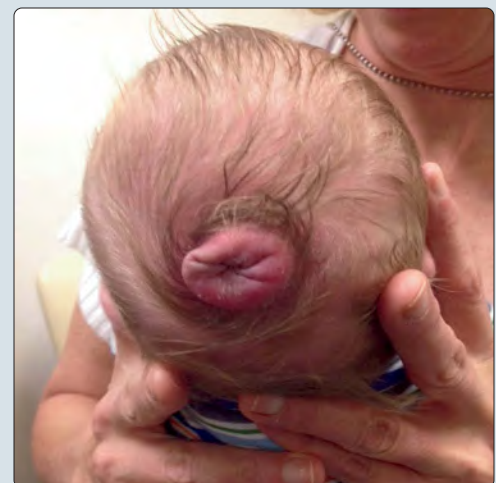
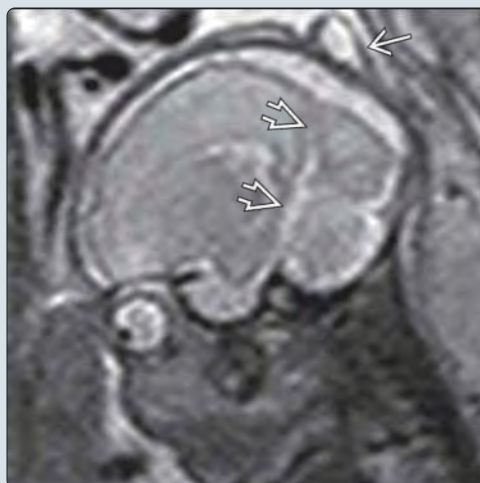
CLINICAL ISSUES

- Small cephaloceles may "disappear" with advancing gestation
 - Postnatal MR shows atretic connection
- Outcome determined more by associated anomalies
- Those with no associated intracranial anomalies usually have normal clinical outcome
- Occipital atretic cephalocele has better prognosis than parietal location
 - Less likely to involve dural sinuses
- Always consider atretic cephalocele in differential of fetal scalp mass even if no obvious bone defect seen

(Left) Sagittal graphic of an atretic cephalocele shows a subcutaneous cystic mass overlying a small calvarial defect. The persistent primitive falcine venous sinus and fibrous communicating stalk "point" to the defect. **(Right)** This newborn had a prenatal scalp mass suspected to be an atretic cephalocele. The MR shows it is fluid-filled with obvious neural tissue. There is a typical vertically oriented persistent falcine venous sinus and peaked tentorium. The fibrous stalk is difficult to see without contrast.



(Left) Sagittal T2WI MR shows a fetus with a cystic scalp mass. While a distinct falcine vein and fibrous cord are not seen, the high signal CSF tract shows the vertical course toward the scalp mass. **(Right)** Postnatal photo (same case) shows the scalp mass. It has a collapsed appearance with redundant skin. Cephaloceles may show involution over the pregnancy, becoming atretic. Pathology showed a small focus of dysplastic brain tissue with a simple meningotheial lining underlying an unremarkable epidermal surface.



TERMINOLOGY**Definitions**

- Form fruste of encephalocele consisting of dura, fibrous tissue, and dysplastic neuroglial rests

IMAGING**General Features**

- Best diagnostic clue
 - Cerebrospinal fluid (CSF) tract and vertical falcine venous sinus "point" to subcutaneous scalp mass
- Location
 - Midline interparietal most common, occasionally occipital
- Size
 - Usually small (5-15 mm)

Ultrasonographic Findings

- Small scalp mass with variable echogenicity
 - May be cystic (CSF) or solid (predominately fibrous tissue)
- Calvarial defect often difficult to see
 - If fetus in cephalic presentation use endovaginal technique
- Look for associated brain abnormalities
 - Callosal agenesis/dysgenesis, holoprosencephaly, and interhemispheric cyst most common

MR Findings

- Best for showing vertical falcine sinus and fibrous cord
 - May be difficult to see, but look for high signal surrounding CSF tract on T2-weighted sequences
- Prominent superior cerebellar cistern and peaked tentorium

DIFFERENTIAL DIAGNOSIS**Scalp Masses**

- Cranium intact
 - Must scan from multiple angles for confirmation
 - Edge artifact may give erroneous appearance of cranial defect
- Includes lymphovascular and soft tissue tumors
 - Hemangioma
 - Lymphangioma
 - Sinus pericranii
 - Anomalous communication between intracranial dural venous sinus and extracranial venous circulation
 - Epidermoid cyst
 - Lipoma
 - Fibromatosis, myofibromatosis
 - Mesenchymal neoplasms

PATHOLOGY**General Features**

- Etiology
 - Considered involuted true cephalocele (meningocele or encephalocele)
 - Originates from overdilated rhombencephalic vesicle at 7-10 weeks of fetal life

- Presence of persistent midline neural crest cells may prevent mutual induction of ectoderm and mesoderm

- Genetics
 - Typically sporadic; some cases syndromic
- Associated abnormalities
 - Other brain and eye abnormalities common
- High percentage of all cephaloceles are atretic, especially parietal
 - Very high incidence of associated anomalies

Gross Pathologic & Surgical Features

- Connects to dura mater via fibrous stalk terminating in falx or tentorium
- CSF tracts to supracerebellar, suprapineal, and quadrigeminal cisterns

CLINICAL ISSUES**Presentation**

- Most common signs/symptoms
 - Incidental scalp mass on screening exam
- Other signs/symptoms
 - Palpable mass in neonate
 - May enlarge with crying

Demographics

- Epidemiology
 - 4-17% of all cephaloceles

Natural History & Prognosis

- Small cephaloceles may "disappear" with advancing gestation
- Occipital atretic cephalocele has better prognosis than parietal location
 - Less likely to involve dural sinuses
- Outcome determined more by associated anomalies
- Those with no associated intracranial anomalies usually have normal clinical outcome
- Additional intracranial anomalies (more common in syndromic patients) → worse outcome

Treatment

- All fetuses with scalp mass should have postnatal MR to evaluate for atretic connection to brain
- Surgical resection of cephalocele with dural repair

DIAGNOSTIC CHECKLIST**Image Interpretation Pearls**

- Always consider atretic cephalocele in differential of fetal scalp mass even if no obvious bone defect seen

SELECTED REFERENCES

1. Bick DS et al: A scalp lesion with intracranial extension. Atretic cephalocele. *JAMA Otolaryngol Head Neck Surg.* 141(3):289-90, 2015
2. Siverino RO et al: Parietal atretic cephalocele: Associated cerebral anomalies identified by CT and MR imaging. *Neuroradiol J.* 28(2):217-21, 2015
3. Leykamm S et al: Atretic cephalocele and associated anomalies in a newborn child. *Clin Neuroradiol.* 23(1):37-40, 2013
4. Hsu SW et al: Atretic parietal cephalocele associated with sinus pericranii: embryological consideration. *Brain Dev.* 34(4):325-8, 2012
5. Wong SL et al: Atretic cephalocele - an uncommon cause of cystic scalp mass. *Malays J Med Sci.* 17(3):61-3, 2010
6. Güzel A et al: Atretic parietal cephalocele. *Pediatr Neurosurg.* 43(1):72-3, 2007

KEY FACTS

TERMINOLOGY

- Definition: Frontal bone defect with protrusion of intracranial structures
 - Frontoethmoidal (most common): Defect between frontal and ethmoidal bones
 - Nasofrontal: Defect between frontal and nasal bones
 - Nasoorbital: Defect through medial orbit

IMAGING

- Fetus with facial mass
 - Hypertelorism common
 - Small frontal encephaloceles often missed
- Consider MR for better anatomic delineation
- Look for associated midline brain anomalies
 - Dysgenesis of corpus callosum (common)

TOP DIFFERENTIAL DIAGNOSES

- Nasal glioma
- Dermoid cyst

PATHOLOGY

- Classification based on content
 - Meningoencephalocele: Meninges + brain tissue
 - Meningocele: Only meninges
 - Atretic cephalocele: Dura + fibrous tissue

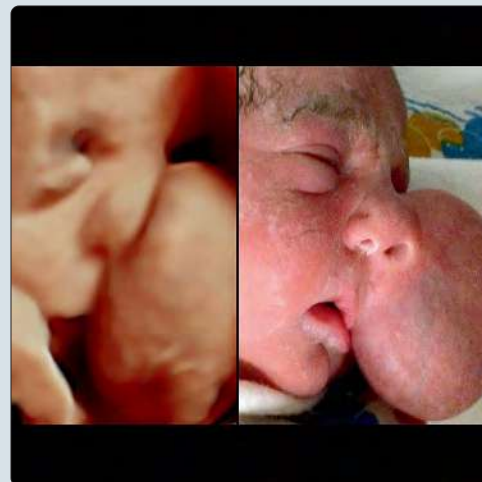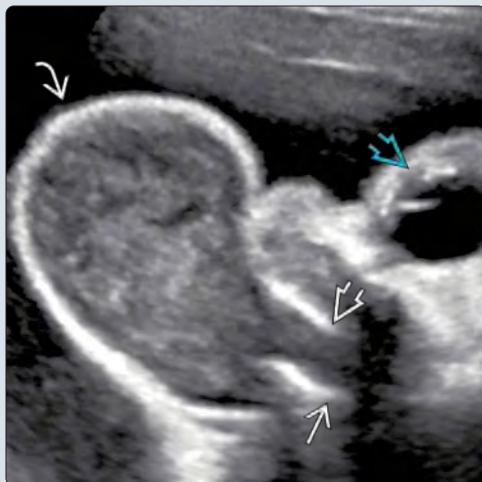
CLINICAL ISSUES

- Frontoethmoidal region is most common location for cephalocele in Southeast Asian population
- If isolated, prognosis is generally good
- Cesarean section considered to reduce birth trauma
- Treatment with surgical resection
 - Endoscopic resection often performed
- Complications include meningitis and brain abscess

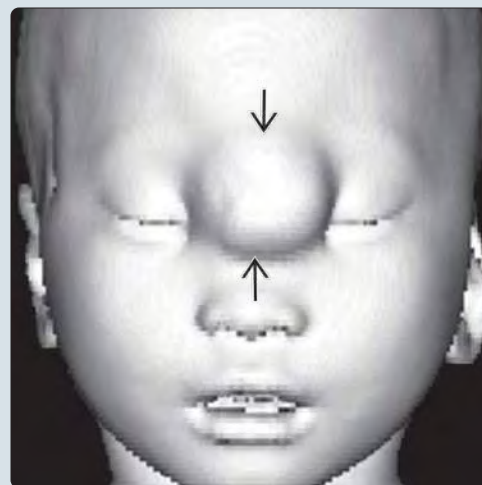
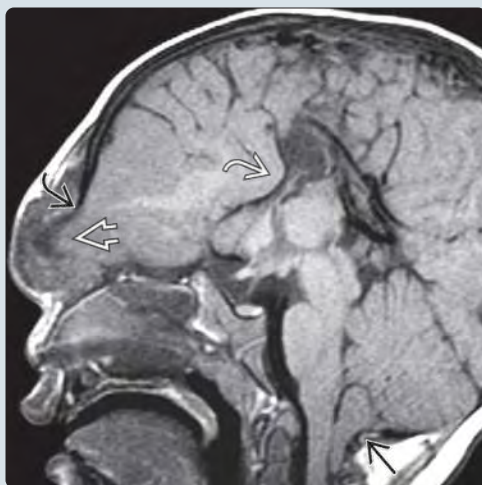DIAGNOSTIC CHECKLIST

- Consider frontal cephalocele when unexplained hypertelorism present

(Left) Axial US view through the upper face in a fetus with a skin-covered facial mass shows the mass extending from the cranium, through a defect between the nasal bone and left medial orbit (nasoorbital encephalocele). The left eye was displaced laterally (right eye). **(Right)** 3D US at 29 weeks in fetus with a large frontoethmoidal cephalocele shows nasal distortion caused by the mass. These images helped prepare the family and enabled the surgeons to provide a more accurate prenatal consultation.



(Left) Sagittal T1WI MR in a patient with a skin-covered nasofrontal cephalocele shows dysmorphic frontal brain tissue herniating through a frontal bone defect. Other midline anomalies present include dysgenesis of the corpus callosum and Chiari 1 malformation (inferior vermian herniation). **(Right)** 3D CT soft tissue reconstruction in an infant with a nasofrontal encephalocele shows a soft tissue mass protruding anteriorly between the eyes. (From Osborn's Brain.)



TERMINOLOGY

Synonyms

- Meningoencephalocele

Definitions

- Frontal bone defect with protrusion of intracranial structures
 - Frontoethmoidal (most common) = sincipital cephalocele
 - Bone defect between frontal and ethmoidal bones
 - Nasofrontal: Defect between frontal and nasal bones
 - Nasoorbital: Defect through medial orbit

IMAGING

General Features

- Best diagnostic clue
 - Brain parenchyma herniating through anterior skull defect
- Location
 - Frontoethmoidal (involving nose)
 - Midline frontal (between eyes)

Ultrasonographic Findings

- Forehead/nasal mass
 - Seen best on routine profile view of fetal face
 - ± facial anomalies
 - Hypertelorism
 - Nasal distortion
 - Midline craniofacial dysraphism
- May be missed on prenatal US if small

MR Findings

- Shows intracranial communication through defect
- Best for identifying associated midline anomalies
 - Dysgenesis of corpus callosum (most common association)
 - Interhemispheric cyst or lipoma
 - Malformations of cerebral cortical development (heterotopia)

Imaging Recommendations

- Protocol advice
 - US techniques
 - 3D US is additive
 - Always insonate from several directions to exclude edge artifact, which may mimic calvarial discontinuity
 - Diagnosis possible at time of nuchal translucency assessment
 - Endovaginal technique best
 - Fetal MR
 - Thin-section orthogonal T2 HASTE sequences work best
 - MR may show bone defect best
 - Lack of shadowing, which hampers US

DIFFERENTIAL DIAGNOSIS

Nasal Glioma

- Collection of dysplastic brain tissue without bony defect
- Think of cephalocele that has lost its intracranial connection

Dermoid Cyst

- Persistent dural projection through foramen cecum
 - Arise from misplaced ectodermal elements when neural tube closes at midline (3rd-5th week of embryonic life)
 - Dermoid or epidermoid develops along tract

Other Facial Masses

- Nasal teratoma
- Dacryocystocele: Obstructed distended nasolacrimal duct

PATHOLOGY

Gross Pathologic & Surgical Features

- Meningoencephalocele
 - Meninges + brain tissue
- Meningocele
 - Meninges only
- Atretic cephalocele
 - Dura + fibrous tissue ± degenerated brain tissue
- Discussions often group frontoethmoidal cephaloceles, nasal dermoids, and nasal gliomas together
 - All 3 present as congenital midline nasal masses
 - All 3 result from similar embryologic derivation
 - All exhibit lack of regression of dural projection through embryologic foramen cecum, between developing nasal cartilage and nasal bone

CLINICAL ISSUES

Presentation

- Fetal facial mass ± hypertelorism
- Postnatal
 - Skin-covered facial or nasal mass
 - Nasal congestion
 - CSF rhinorrhea and recurrent meningitis

Demographics

- 1 in 2,000-12,500 live births in USA
- 1:5,000 in Southeast Asia (frontoethmoid most common)
- 1.8:1 = F:M

Natural History & Prognosis

- If isolated, prognosis is generally good and associated with normal IQ/motor development
- Complications: Meningitis, pneumocephalus, brain abscess

Treatment

- C-section considered to reduce birth trauma
- Surgical excision with closure of dural/skull defect
 - Endoscopic sinonasal repair possible
- Antepartum neurosurgery referral for surgical planning

DIAGNOSTIC CHECKLIST

Image Interpretation Pearls

- Consider frontal cephalocele when unexplained hypertelorism seen

SELECTED REFERENCES

1. Zabsonre DS et al: Frontoethmoidal cephalocele: our experience of eleven cases managed surgically. *Pediatr Neurosurg*. 50(1):7-11, 2015
2. Sepulveda W et al: Fetal cephalocele: first-trimester sonographic spectrum in a review of 35 cases. *Ultrasound Obstet Gynecol*. ePub, 2014

KEY FACTS

TERMINOLOGY

- Agenesis: Complete absence of corpus callosum (CC)
- Hypogenesis: Partial or incomplete formation of CC
- Dysgenesis: Defective development of CC (e.g., callosal abnormalities seen in holoprosencephaly)

IMAGING

- Axial plane: Absent cavum septi pellucidi (CSP), teardrop-shaped ventricles (colpocephaly), parallel lateral ventricles
- Coronal plane: Absent CSP, Texas longhorn morphology to anterior horns of lateral ventricles, nonvisualization of CC
- Midline sagittal plane: Absent or abnormal CC complex
- Mild ventriculomegaly is often 1st clue
- Elevation of 3rd ventricle
- Look for associated anomalies in brain and body
 - Other CNS anomalies in 50%
 - Fetal body anomalies seen in 60%
- Fetal MR recommended: Finds other abnormalities missed on US in over 1/2 of cases

TOP DIFFERENTIAL DIAGNOSES

- Mild ventriculomegaly
- Lobar holoprosencephaly

PATHOLOGY

- Association with multiple named syndromes and malformations in 50-80%
 - > 80 chromosomal, genetic, and sporadic syndromes
 - Chromosomal anomalies in 10-20%

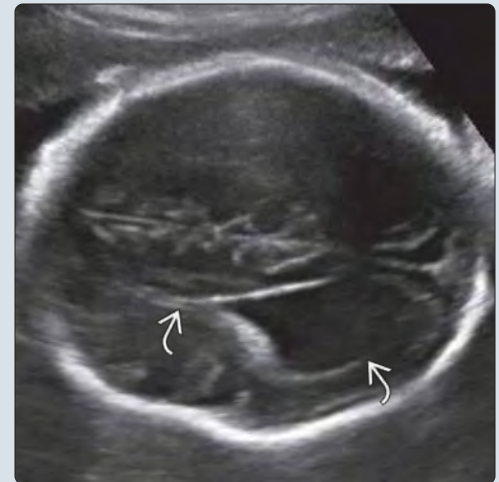
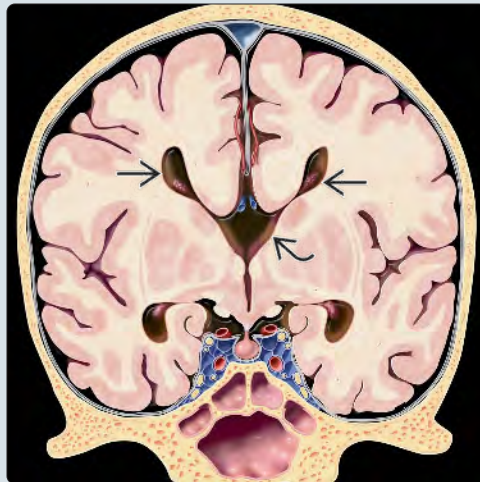
CLINICAL ISSUES

- Karyotype recommended even if isolated finding
- ~ 15% of cases thought to be isolated prenatally have associated abnormalities after birth

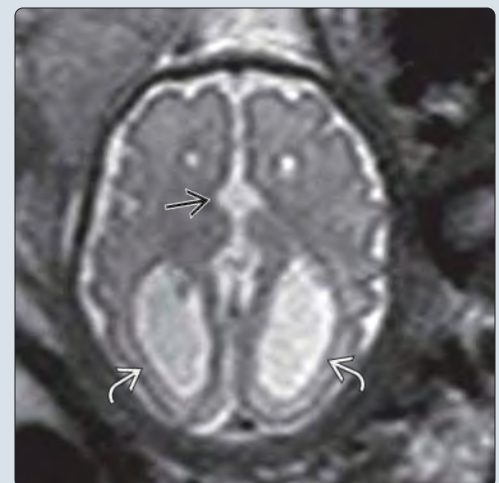
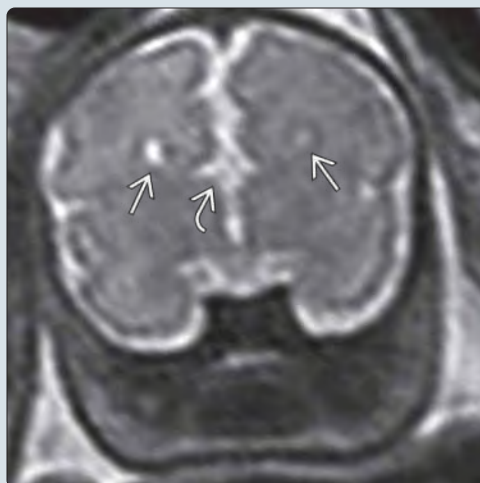DIAGNOSTIC CHECKLIST

- Absent CSP crucial clue
- Do not mistake paired fornices for CSP
- ACC often missed or confused with hydrocephalus

(Left) Coronal graphic shows callosal agenesis with widely spaced lateral ventricles [A]. The 3rd ventricle [B] is elevated and is contiguous dorsally with the interhemispheric fissure. **(Right)** Ultrasound of the fetal head shows the typical appearance of the lateral ventricles, with a teardrop shape [C] (colpocephaly). This helps distinguish agenesis of the corpus callosum (ACC) from hydrocephalus of another etiology.



(Left) MR of the same fetus at 31 weeks shows the steerhorn appearance [D], with widely spaced frontal horns. The cavum septi pellucidi (CSP) is absent, and the hemispheres are separated by a cerebrospinal fluid (CSF) space [E]. **(Right)** In the axial plane, the dilated occipital horns [F] are noted with an absent interhemispheric connection [G]. Care should be taken to avoid mistaking the CSF space between the hemispheres for a CSP, especially on ultrasound.



TERMINOLOGY

Abbreviations

- Agenesis of corpus callosum (ACC)

Definitions

- Failure of axons to cross midline and form corpus callosum (CC)
 - Agenesis: Complete absence of CC
 - Hypogenesis: Partial or incomplete formation of CC
 - More common than dysgenesis
 - Dysgenesis: Defective development of CC (e.g., callosal abnormalities seen in holoprosencephaly)

IMAGING

General Features

- Best diagnostic clue
 - Absent cavum septi pellucidi (CSP), teardrop-shaped ventricles (colpocephaly), and parallel lateral ventricles in axial plane
 - Absent CSP, Texas longhorn morphology to anterior horns of lateral ventricles, and nonvisualization of CC in coronal plane
 - Absent or abnormal CC complex on midline sagittal views
- Morphology
 - CC: Largest cerebral commissure; > 10x larger than anterior commissure
 - Composed of 4 parts (from front to back)
 - **Rostrum:** Projects posteriorly and inferiorly from anterior aspect of genu
 - **Genu:** Anterior curved portion (genu means knee)
 - **Body:** Midportion, between genu and splenium
 - **Splenium:** Posterior portion

Ultrasonographic Findings

- Grayscale ultrasound
 - Mild ventriculomegaly is often 1st clue
 - Colpocephaly: Dilation of trigones and occipital horns
 - Teardrop-shaped ventricles
 - Medial wall of ventricle is further from midline at frontal horn
 - Lateral ventricles widely spaced and parallel
 - Multiple descriptors for ventricular configuration
 - Trident-shaped, steer horn, Viking helmet, moose head, Texas longhorn
 - Prominent interhemispheric fissure
 - Elevation of 3rd ventricle
 - Contiguous with interhemispheric fissure anteriorly
 - Best seen in coronal plane
 - **Absent CSP crucial clue:** Do not mistake paired fornices for CSP
 - Should be anechoic box-shaped midline structure between frontal horns of lateral ventricles
 - Gyri
 - Cingulate gyrus absent
 - Radial, spoke-wheel, sunray appearance in sagittal plane
 - Radiate to 3rd ventricle
 - Dysgenesis

- Classic holoprosencephaly is main exception to more common front-to-back sequence of hypogenesis
 - Splenium may be present without genu or body
- In syntelencephaly genu and splenium may be present without callosal body

- Color Doppler
 - "Meandering" anterior cerebral arteries
 - May have azygous anterior cerebral artery
 - Abnormal course of pericallosal artery
- Other CNS anomalies in 50%
 - Most common anomalies include Dandy-Walker malformation, Chiari 2 malformation, anomalies of neuronal migration/organization, encephaloceles, and midline facial anomalies
 - Disorders of other telencephalic commissures
 - Interhemispheric cyst/AVID complex
 - **A**symmetric **v**entriculomegaly with **i**nterhemispheric **c**yst and **d**ysgenesis of CC
 - Cyst may or may not communicate with ventricle
 - Interhemispheric lipomas
 - Hyperechoic midline mass, often associated with calcifications
 - 50% of lipomas have ACC
 - Heterotopias and gyral abnormalities
 - Microcephaly
- Body anomalies (ACC not just associated with CNS anomalies)
 - Cardiac defects
 - Congenital diaphragmatic hernia
 - Gastrointestinal and genitourinary anomalies

MR Findings

- T2WI: Similar to ultrasound, but findings more obvious
 - Sagittal
 - Absent CC and cingulate gyrus
 - Abnormal radially oriented gyri that converge toward 3rd ventricle (sunray or spoke-wheel appearance)
 - May see Probst bundles
 - Noncrossing commissural fibers that would normally form CC run front to back instead of crossing midline
 - Indent medial wall of lateral ventricles, giving them crescentic shape, thus accounting for Texas longhorn shape of anterior horn of lateral ventricles in coronal plane

Imaging Recommendations

- Best imaging tool
 - Diagnosis typically made with ultrasound but fetal MR recommended in routine work-up
 - Prenatal MR finds other abnormalities missed on US in over 1/2 of cases
 - Many of these, such as gray matter heterotopia, are too subtle to be readily detected by ultrasound
 - MR often adds particular value in patients in whom sonography is difficult (e.g., maternal obesity and oligohydramnios)
- Protocol advice
 - Meticulous sonographic technique needed to make diagnosis
 - Often missed or misdiagnosed as hydrocephalus, especially in 2nd trimester

Conditions/Syndromes Associated With Agenesis of Corpus Callosum

Syndrome	Findings in Addition to Callosal Abnormalities
Dandy-Walker	Enlarged posterior fossa with cyst, vermian hypoplasia/agenesis, cerebellar hypoplasia
Chiari 2	Banana-shaped cerebellum, ventriculomegaly, neural tube defect
Aicardi	Gray matter heterotopia, polymicrogyria, cerebellar hypoplasia, microphthalmia, X-linked dominant
Walker-Warburg	Hypotonia, ocular abnormalities, cobblestone lissencephaly, ventriculomegaly, brainstem and cerebellar malformations
Meckel-Gruber	Renal cystic dysplasia, occipital cephalocele, ventriculomegaly, Dandy-Walker malformation, holoprosencephaly
Apert	Craniosynostosis (coronal sutures) with brachyurricephaly, "mitten" syndactyly, ventriculomegaly, absent cavum, cardiac and genitourinary defects

- If fetal presentation is cephalic, consider endovaginal scan for better evaluation
- o Look for associated anomalies in brain **and** body
- o Thin-section HASTE (SSFSE) in 3 orthogonal planes if MR performed
 - Midline sagittal and coronal planes often more helpful than routine axial planes

- Embryology
 - o CC forms in midline lamina between 8-20 weeks
 - Thickening continues until after birth
 - o CC generally forms front to back
 - Actually, posterior genu/anterior body → anterior genu/posterior body → splenium → rostrum

DIFFERENTIAL DIAGNOSIS

Mild Ventriculomegaly

- Normal configuration of ventricles, CSP present, normal gyral pattern

Lobar Holoprosencephaly

- Falx may be absent or abnormal
- Absent CSP, fused frontal horns, fused fornices, fused thalami

Septo-Optic Dysplasia

- Absent CSP with fused frontal horns
 - o Frontal horns have flat or squared off appearance
- CC present but may be thinned

Destructive Lesions of Corpus Callosum

- Callosal fibers may be destroyed in unusual configurations

PATHOLOGY

General Features

- Genetics
 - o Most sporadic
 - o Multiple genes contribute to CC; thus, multiple potential sites of disruption
 - o Chromosomal anomalies in 10-20%
 - Trisomy 18, 13, 8
 - Triploidy
- Associated abnormalities
 - o Fetal body anomalies seen in 60%
 - Cardiac, genitourinary, gastrointestinal, and musculoskeletal
 - o Associations with multiple named syndromes and malformations in 50-80%
 - > 80 chromosomal, genetic, and sporadic syndromes
 - o Most common anomaly seen with other CNS malformations
 - Dandy-Walker malformation is one of more common associations

CLINICAL ISSUES

Presentation

- Most common signs/symptoms
 - o Mild ventriculomegaly
 - 3% of mild ventriculomegaly cases have ACC

Demographics

- Epidemiology
 - o 0.3-0.7% of general population

Natural History & Prognosis

- Isolated ACC
 - o 75% normal or near normal at 3 years
- Poor prognosis if associated with other malformations, syndrome, or chromosomal abnormalities
- ~ 15% of cases thought to be isolated prenatally have associated abnormalities after birth

Treatment

- Karyotype recommended even if isolated finding

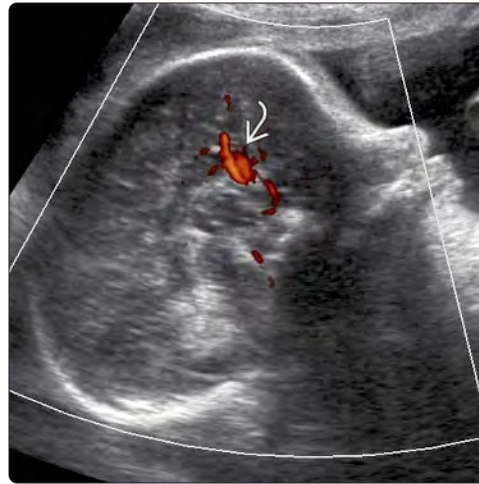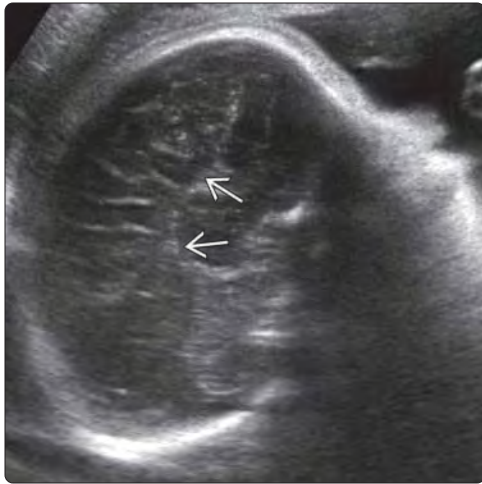DIAGNOSTIC CHECKLIST

Image Interpretation Pearls

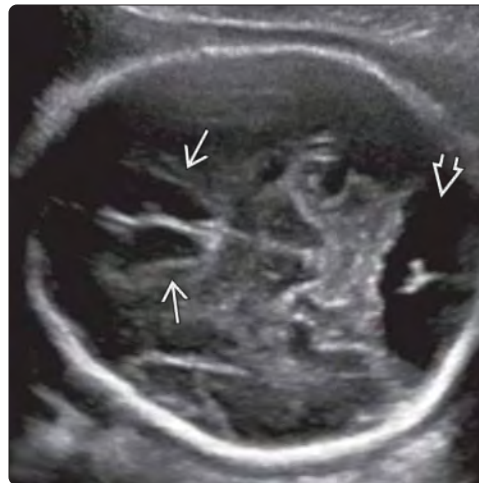
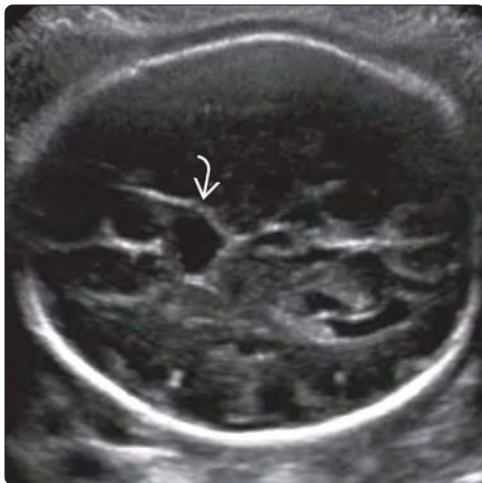- Isolated ACC is challenging diagnosis before 20-22 weeks
 - o May be missed or confused with hydrocephalus even later in gestation
- MR is very helpful in making diagnosis and evaluating for associated anomalies

SELECTED REFERENCES

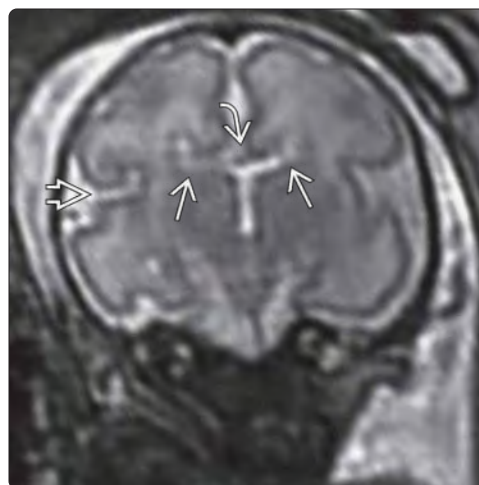
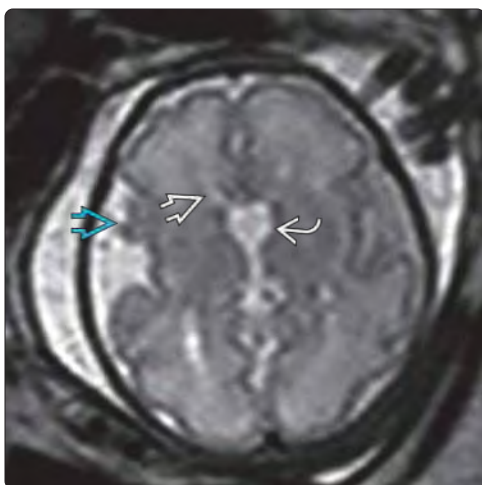
1. Craven I et al: Antenatal diagnosis of agenesis of the corpus callosum. Clin Radiol. 70(3):248-53, 2015
2. Rüländ AM et al: Prenatal diagnosis of anomalies of the corpus callosum over a 13-year period. Ultraschall Med. ePub, 2015
3. Noguchi R et al: Outcomes of patients with prenatally diagnosed agenesis of the corpus callosum in conjunction with ventriculomegaly. Arch Gynecol Obstet. 290(2):237-42, 2014
4. Paladini D et al: Agenesis of the fetal corpus callosum: sonographic signs change with advancing gestational age. Ultrasound Obstet Gynecol. 42(6):687-90, 2013



(Left) With callosal agenesis, the sagittal view shows the cingulate gyrus is missing and the gyri are radially oriented, converging toward the 3rd ventricle . (Right) Doppler evaluation shows an abnormal course of the pericallosal artery , which normally extends anterior to posterior along the cingulate gyrus. This finding can be useful to confirm the diagnosis of ACC.



(Left) Posterior to the expected location of the CSP, there is an anechoic cyst in this 35-week fetus. Midline interhemispheric cysts can be seen with callosal anomalies, and should not be confused with the CSP, which should be located between the frontal horns of the lateral ventricles. (Right) Anterior to the cyst, the frontal horns are slit-like and the CSP is absent . In addition, there is a mega cisterna magna . Amniocentesis confirmed trisomy 18.



(Left) Axial T2WI fetal MR in the same patient shows the midline interhemispheric cyst and diminutive frontal horns , as typically seen in ACC. There is also heterotopia with abnormal formation of the sylvian fissure. (Right) Coronal MR shows the absent midline CC, with a typical Texas longhorn appearance of the frontal horns . The CSP is absent . Also note the abnormal right sylvian fissure .

KEY FACTS

TERMINOLOGY

- Intracranial cyst centered near midline
 - ± communication with ventricles
- AVID: **A**symmetric **V**entriculomegaly with **I**nterhemispheric cyst and **D**ysgenesis of corpus callosum

IMAGING

- Smooth-walled, anechoic interhemispheric cyst (IHC), which displaces adjacent brain
- Uniloculated or multiloculated
- AVID presents with asymmetric ventriculomegaly, often marked
 - Due to type 1a IHC in continuity with ipsilateral ventricle
 - Cyst wall often difficult to visualize, especially medially
 - Absent cavum septi pellucidi
 - Callosal anomaly
 - Progressive macrocephaly due to associated hydrocephalus
 - Best evaluated with MR

TOP DIFFERENTIAL DIAGNOSES

- Porencephalic cyst
 - Occurs in area of brain destruction, no mass effect
- Arachnoid cyst
- Schizencephaly

PATHOLOGY

- May obstruct CSF flow and cause hydrocephalus
- Aberrant neuronal migration may cause IHC with callosal anomalies, heterotopia, pachygyria, polymicrogyria

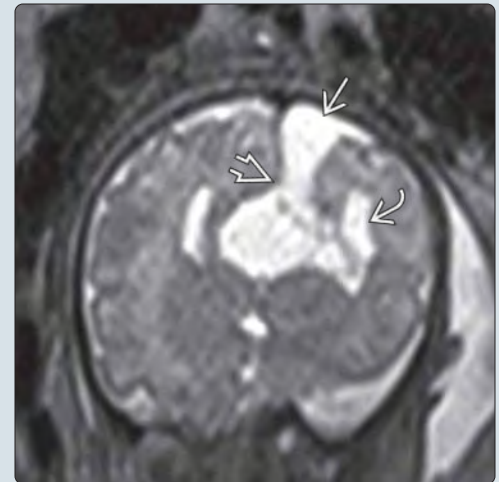
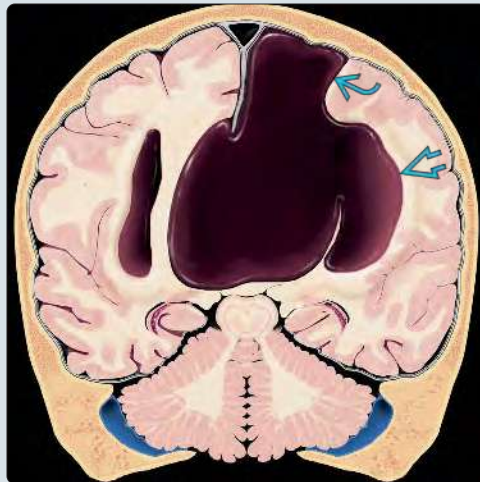CLINICAL ISSUES

- Follow for hydrocephalus/macrocephaly
 - Either may influence timing and mode of delivery

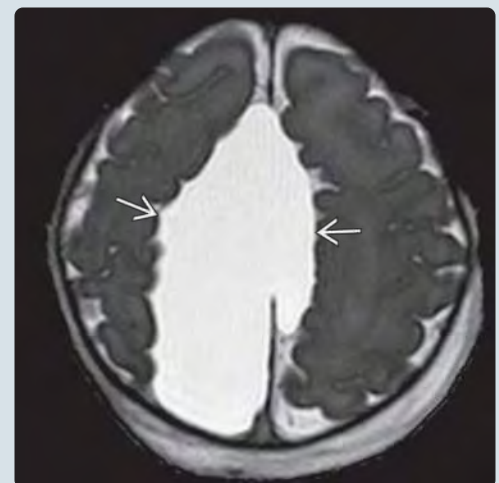
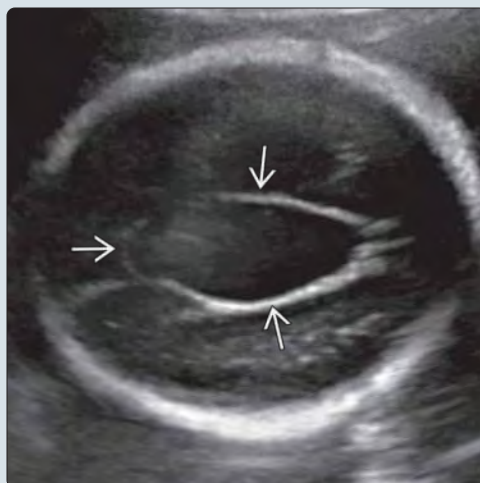
DIAGNOSTIC CHECKLIST

- Consider AVID triad if markedly asymmetric ventriculomegaly present

(Left) Coronal graphic shows an IHC with callosal agenesis. The cyst is communicating with the enlarged left lateral ventricle. These findings often occur together and can be remembered by the acronym AVID (asymmetric ventriculomegaly, interhemispheric cyst, dysgenesis of the corpus callosum). (Right) Coronal fetal MR shows an IHC splaying the frontal horns and communicating with the left lateral ventricle. There is also agenesis of the corpus callosum.



(Left) Ultrasound at 26-weeks gestation shows an extraaxial midline interhemispheric cyst. There was also agenesis of the corpus callosum (not shown). In this case the cyst was isolated and did not communicate with the ventricles. (Right) Postnatal MR confirms the presence of the midline cyst. Note the splayed appearance of the cerebral hemispheres. The cyst causes mass effect and should not be confused with porencephaly.



TERMINOLOGY**Abbreviations**

- Interhemispheric cyst (IHC)
- **A**symmetric ventriculomegaly with interhemispheric cyst and **d**ysgenesis of corpus callosum (AVID)

Synonyms

- Ependymal cyst
- Neuroepithelial cyst
- Gliependymal cyst

Definitions

- Intracranial cyst centered near midline/interhemispheric fissure
 - ± communication with ventricles
 - Type 1 cysts communicate with ventricular system
 - Type 2 cysts are intraparenchymal

IMAGING**General Features**

- Best diagnostic clue
 - Smooth-walled, benign-appearing cyst
 - Fluid-filled; signal characteristics similar to CSF on MR
 - Surrounding brain shows minimal to no abnormal signal intensity
- Location
 - Intra- or extraparenchymal
 - Intraparenchymal location is more common
 - May be intraventricular
 - Typically midline
- Morphology
 - Displaces normal-appearing adjacent brain
 - Smooth bordered
 - Unilocular or multiloculated
 - May be multiple
 - If interhemispheric, displaces roof of 3rd ventricle inferiorly

Ultrasonographic Findings

- Grayscale ultrasound
 - Smooth-walled, anechoic
 - May have multiple loculations
 - May cause hydrocephalus
 - Can compress cerebral aqueduct, interventricular foramen, or median aperture
 - Reported association with partial agenesis of cerebral aqueduct
 - AVID typically presents with asymmetric ventriculomegaly, often marked
 - Usually affected ventricle with underlying cyst is at least 50% greater in diameter
 - Due to type 1a interhemispheric cyst in continuity with ipsilateral ventricle
 - Associated callosal anomaly
 - Absent cavum septi pellucidi
 - May be difficult to define extent of callosal anomaly given ventriculomegaly
 - Macrocephaly present due to associated hydrocephalus
 - Increases throughout pregnancy

- May result in misshapen head at term
- Skin covered meningocele at posterior fontanelle possible

- Color Doppler
 - No internal flow
 - Normal vessels may be displaced by cyst

MR Findings

- Signal intensity usually follows CSF
- May be slightly hyperintense to CSF on T1WI, hypointense to CSF on T2WI (proteinaceous fluid)
 - Occasional fluid-fluid level if high protein content
- AVID findings on MR much more clearly identified than on ultrasound
 - Hydrocephalus present but with asymmetrically enlarged ventricle due to type 1a interhemispheric cyst
 - Cyst wall often difficult to visualize, especially medially
 - Can be mistaken for area of porencephaly
 - Gray matter preserved at margin of cyst, suggesting against destructive etiology
 - Callosal anomaly better seen on fetal MR
 - If severe hydrocephalus, skin covered meningocele may be present at posterior fontanelle
 - More easily identified and characterized on MR

Imaging Recommendations

- Protocol advice
 - Look for other anomalies, growth discordance
 - Anomalies or abnormal growth → ↑ suspicion for aneuploidy/syndrome
 - Consider MR in any fetus with intracranial cyst
 - Prognosis different if associated with structural brain malformation (e.g., callosal dysgenesis)

DIFFERENTIAL DIAGNOSIS**Arachnoid Cyst**

- Located over cerebral convexities rather than midline
- More likely if cyst in posterior fossa
- More likely if extracranial anomalies present
 - Stronger association with aneuploidy

Porencephalic Cyst

- Associated with brain destruction; surrounding brain tissue is abnormal
- Does not have mass effect
- Cyst usually communicates with adjacent ventricle

Schizencephaly

- Gray matter lined wedge-shaped defect
- Extends from cortical surface to ventricular wall

Physiologic Entities

- Distinct, characteristic appearances
 - Enlarged cavum septi pellucidi
 - Cavum vergae
 - Cyst of cavum velum interpositum
- Do not increase in size; many regress with advancing gestational age
 - Pathologic cysts often enlarge with advancing gestational age

Alobar Holoprosencephaly

- Large intracranial cyst may simulate monoventricle
 - Brain surrounding monoventricle is abnormal

PATHOLOGY**General Features**

- Etiology
 - Heterotopically displaced embryonic neural tube elements
- Associated abnormalities
 - Agenesis of corpus callosum
 - IHC may interfere with development of corpus callosum
 - Aberrant neuronal migration may independently produce IHC and other neural anomalies
 - Polymicrogyria
 - Pachygyria
 - Heterotopia
 - Cerebellar hypoplasia
 - Not usually associated with extracranial anomalies

Gross Pathologic & Surgical Features

- Smooth-walled
- Contain clear to xanthochromic fluid

Microscopic Features

- Epithelial lining
 - Ciliated or nonciliated
 - Columnar to cuboidal to simple squamous (nonkeratinizing)
- Generally no basement membrane
- Usually little if any surrounding gliosis

CLINICAL ISSUES**Presentation**

- Intracranial cyst detected on routine obstetric ultrasound
- Asymmetric ventriculomegaly often most obvious finding with AVID

Natural History & Prognosis

- Depends on
 - Size
 - Associated abnormalities
 - Location
 - May obstruct CSF flow → hydrocephalus
 - Shunt placement for hydrocephalus not without complication
 - Infection
 - Obstruction
 - Reoperation
 - Mass effect on adjacent brain
 - Seizure disorder attributed to local hypoxemia or cortical dysplasia
- IHC + callosal agenesis → ↑ risk of progressive hydrocephalus
 - Commonly seen with AVID triad
 - Often leads to severe macrocephaly
 - May result in asymmetric skull shape from hydrocephalus and cyst

Treatment

- No documented association of IHC with aneuploidy
 - Amniocentesis may not be necessary if isolated anomaly
 - Amniocentesis recommended if additional findings or growth restriction
- Follow for hydrocephalus/macrocephaly
 - Either may influence timing and mode of delivery
 - Hydrocephalus increases likelihood of postnatal intervention
- Intellectual outcome dependent on associated structural abnormalities
- Progressive signs and symptoms require surgical intervention
 - Raised intracranial pressure
 - Seizure disorder reportedly improved with cyst decompression
- Type of surgical intervention controversial
 - Fenestration
 - Cyst-peritoneal shunting
 - Cyst wall resection
 - Has been complicated by recurrence if cyst wall elements overlooked during surgery
 - Literature conflicted whether decompression preferable to resection
 - Will depend on local surgical expertise

DIAGNOSTIC CHECKLIST**Consider**

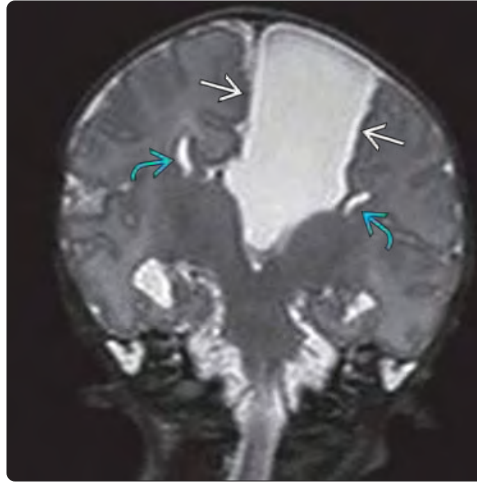
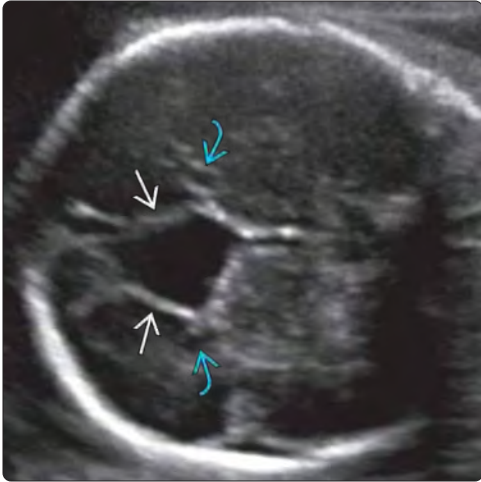
- AVID triad if markedly asymmetric ventriculomegaly present
 - Warrants careful evaluation to look for underlying interhemispheric cyst and callosal anomaly
- Fetal MR
 - Confirm diagnosis of cyst
 - Shows benign physiologic entities clearly
 - Evaluates for associated structural abnormalities

Image Interpretation Pearls

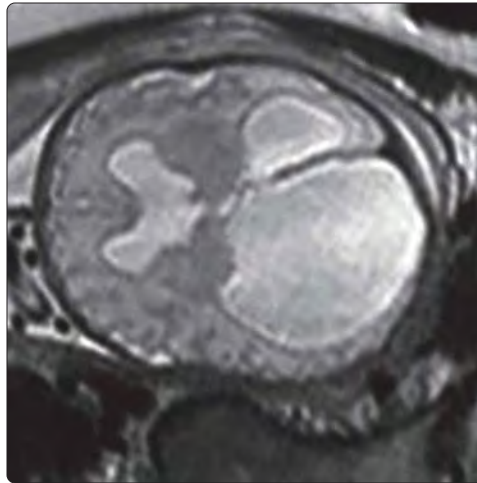
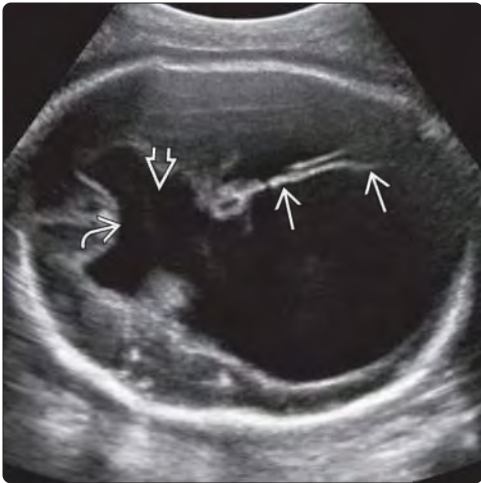
- Differentiation of IHC vs. arachnoid cyst often not possible by imaging
 - Same treatment
 - Different prognostic implications
- More likely IHC if cyst is midline/frontal
 - Assess for associated callosal anomaly

SELECTED REFERENCES

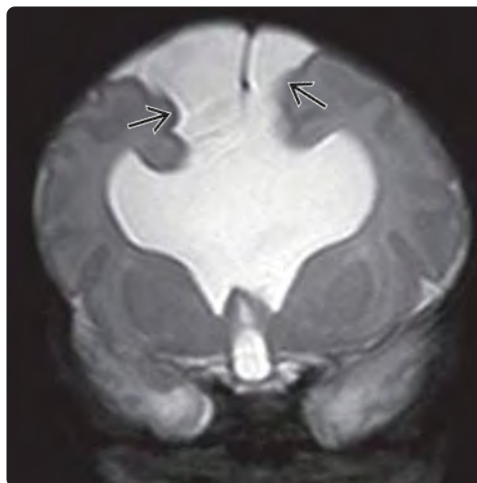
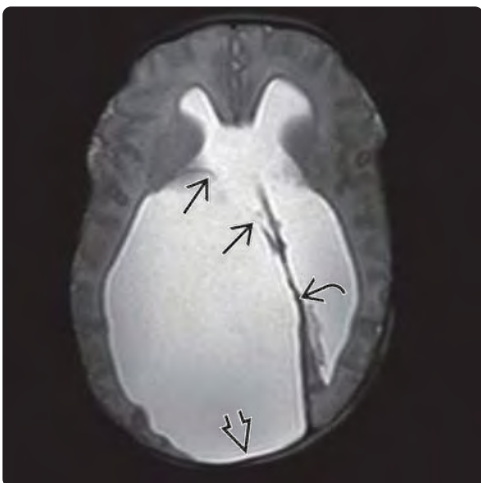1. Cagneaux M et al: Agenesis of the corpus callosum with interhemispheric cyst, associated with aberrant cortical sulci and without underlying cortical dysplasia. *Ultrasound Obstet Gynecol.* 42(5):603-5, 2013
2. Paladini D et al: Agenesis of the fetal corpus callosum: sonographic signs change with advancing gestational age. *Ultrasound Obstet Gynecol.* 42(6):687-90, 2013
3. Oh KY et al: Asymmetric ventriculomegaly, interhemispheric cyst, and dysgenesis of the corpus callosum (AVID): an imaging triad. *J Ultrasound Med.* 31(11):1811-20, 2012
4. Winter TC et al: The cavum septi pellucidum: why is it important? *J Ultrasound Med.* 29(3):427-44, 2010
5. Wong SK et al: Supratentorial abnormalities in the Chiari II malformation, III: The interhemispheric cyst. *J Ultrasound Med.* 28(8):999-1006, 2009
6. Moriyama E et al: Interhemispheric multiloculated ependymal cyst with dysgenesis of the corpus callosum: a case in a preterm fetus. *Childs Nerv Syst.* 23(7):807-13, 2007
7. Mühler MR et al: Fetal MRI demonstrates gliopendymal cyst in a case of sonographic unilateral ventriculomegaly. *Pediatr Radiol.* 37(4):391-5, 2007



(Left) Coronal ultrasound at 30-weeks gestation shows an interhemispheric anechoic cyst at the midline extending leftward in this fetus with callosal dysgenesis. Note the barely visible splayed frontal horns. **(Right)** Corresponding postnatal MR confirms the IHC and typical steerhorn appearance of the frontal horns seen with agenesis of the corpus callosum.



(Left) Axial ultrasound shows absence of the cavum septi pellucidum and genu of the corpus callosum. The most striking feature, however, is asymmetric ventriculomegaly typical of AVID. The medial wall of the ventricle is displaced across the midline. **(Right)** Fetal MR in the same patient demonstrates a similar ventricular appearance due to a type 1a IHC, which is continuous with the underlying ventricle. The cyst wall is often not visible, but its presence is inferred by the mass effect.



(Left) Axial postnatal T2 MR in the same case shows the type 1a IHC with bulging medial wall of the right lateral ventricle. A portion of the cyst wall can be seen. The cyst extends posteriorly to about the skull. **(Right)** Coronal T2 HASTE MR through the frontal horns in the same patient shows absence of the normal midline structures (i.e., cavum septi pellucidum, corpus callosum). Note the preserved gray matter along the cortical margin, indicating the cyst is not due to a destructive process such as porencephaly.

KEY FACTS

TERMINOLOGY

- Aprosencephaly: Failed development of prosencephalon (forebrain precursor)
- XK aprosencephaly: Syndromal aprosencephaly associated with limb, heart, genital defects
- Atelencephaly: Abnormal prosencephalon division into telencephalon/diencephalon with only rudimentary diencephalic structures formed.

IMAGING

- Severe microcephaly ± limb abnormalities
- Fluid-filled, small calvarium with absence of supratentorial structures
- Severe craniofacial anomalies
 - May have no recognizable facial features
- Use endovaginal US in early gestation to confirm abnormal brain with intact skull
- Consider MR to confirm diagnosis

TOP DIFFERENTIAL DIAGNOSES

- Anencephaly
- Holoprosencephaly
- Hydranencephaly

PATHOLOGY







- Generally sporadic
- Autosomal recessive in some families
- Partial monosomy 13q

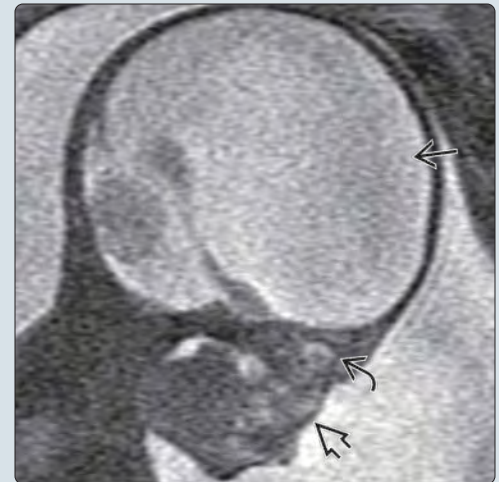
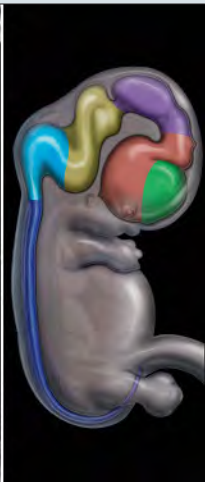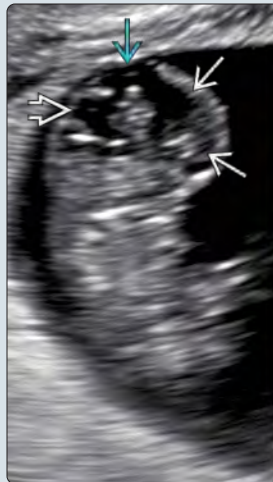CLINICAL ISSUES




- Prenatal or neonatal death
- Offer termination or avoid fetal monitoring/operative delivery in confirmed cases

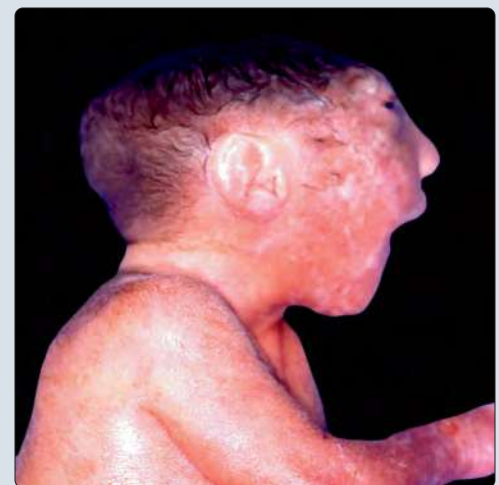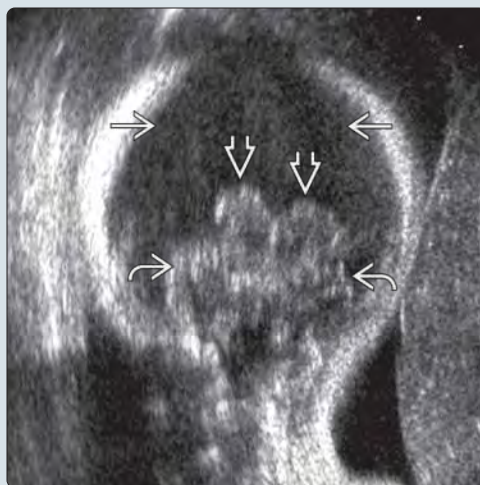DIAGNOSTIC CHECKLIST

- Severe microcephaly is associated with bad outcome regardless of etiology

(Left) TVUS of a 48-day-old embryo shows the developing telencephalon/diencephalon , midbrain , and hindbrain . The graphic shows the telencephalon in green and diencephalon in red. The mesencephalon (midbrain precursor) is purple; hindbrain precursors are metencephalon (yellow) and myelencephalon (blue). Although small at this stage of development, the telencephalon will form the bulk of the supratentorial brain. (Right) Sagittal MR of aprosencephaly shows no normal brain , eye , or nose  formation.



(Left) Coronal sonogram of the fetal head shows no evidence of supratentorial brain or falx  but normal cerebellum  and possibly some thalamic remnants . (Right) This stillborn infant with aprosencephaly has severe microcephaly due to failed development of the prosencephalon, which normally divides into the telencephalon (precursor of the cerebrum) and diencephalon (precursor of the thalamus and hypothalamus). The cranium and scalp are intact. In some cases, there are no identifiable facial features.



TERMINOLOGY**Definitions**

- Aprosencephaly: Failed development of prosencephalon (forebrain precursor)
- XK aprosencephaly: Syndromal aprosencephaly associated with limb, heart, genital defects
- Atelencephaly: Abnormal prosencephalon division into telencephalon/diencephalon with only rudimentary diencephalic structures formed

IMAGING**General Features**

- Best diagnostic clue
 - Severe microcephaly ± limb abnormalities

Ultrasonographic Findings

- Brain
 - Severe microcephaly
 - Intact skull and scalp
 - No normal cerebral structures
 - Replaced with fluid
 - Amorphous mass
 - Cerebellum may be hypoplastic
- Craniofacial anomalies, often severe
 - Micrognathia
 - Midline oculofacial defects including cyclopia
 - May have no recognizable facial features
 - Cleft palate
- Urogenital anomalies
 - Ambiguous genitalia, hypoplastic penis, cryptorchidism
 - Anorectal atresia
 - Renal agenesis
- Extremities
 - Radial ray malformation including absent thumbs
 - Hypoplastic or missing thumbs and great toes
 - Clinodactyly: Medial or lateral deviation of 1 or more digits
 - Camptodactyly: Persistent finger flexion
 - Clubfoot
- Cardiac
 - Atrial/ventricular septal defects

Imaging Recommendations

- Best imaging tool
 - Endovaginal US in early gestation to confirm abnormal brain with intact skull
- Protocol advice
 - Consider MR to confirm diagnosis

DIFFERENTIAL DIAGNOSIS**Anencephaly**

- No calvarium or soft tissue structures above orbits
 - Intact scalp and calvarium in aprosencephaly, atelencephaly
- Often associated with cervical myelomeningocele, rachischisis
- Eyes present, protuberant due to shallow orbits

Alobar Holoprosencephaly

- Absent falx, monoventricle
- Craniofacial anomalies common
 - Proboscis
 - Cyclopia, hypotelorism
 - Orofacial clefts

Hydranencephaly

- Falx present
- No visible cerebral tissue
- Craniofacial development normal

PATHOLOGY**General Features**

- Genetics
 - Generally sporadic
 - Autosomal recessive in some families
 - Partial monosomy 13q
- Associated abnormalities
 - Dysmorphic facial features
 - Extremity malformations
 - Urogenital anomalies
 - Cardiac anomalies

CLINICAL ISSUES**Presentation**

- Most common signs/symptoms
 - Severe microcephaly on midtrimester US
 - Cranial contour may resemble that of anencephaly, but calvarium is present

Natural History & Prognosis

- Prenatal or neonatal death
 - 1 case with survival for 13 months

Treatment

- Offer amniocentesis
- Offer termination or avoid fetal monitoring/operative delivery in confirmed cases

DIAGNOSTIC CHECKLIST**Consider**

- MR may be helpful for confirmation of diagnosis

Image Interpretation Pearls

- Severe microcephaly is associated with bad outcome regardless of etiology
- Differentiate from anencephaly
 - Preconceptual folic acid given in future pregnancies to decrease risk of anencephaly

SELECTED REFERENCES

1. Volpe P et al: Disorders of prosencephalic development. *Prenat Diagn.* 29(4):340-54, 2009
2. Pasquier L et al: First occurrence of aprosencephaly/atelencephaly and holoprosencephaly in a family with a SIX3 gene mutation and phenotype/genotype correlation in our series of SIX3 mutations. *J Med Genet.* 42(1):e4, 2005
3. Renzetti G et al: XK-aprosencephaly and related entities. *Am J Med Genet A.* 138(4):401-10, 2005
4. Townes PL et al: XK aprosencephaly and anencephaly in sibs. *Am J Med Genet.* 29(3):523-8, 1988

KEY FACTS

TERMINOLOGY

- Alobar holoprosencephaly (HPE) implies complete or nearly complete lack of separation of cerebral hemispheres

IMAGING

- 1st trimester: Absent butterfly sign
- 2nd/3rd trimester
 - Monoventricle, absent midline structures, fused thalami, facial anomalies

TOP DIFFERENTIAL DIAGNOSES

- Atelencephaly, aprosencephaly
- Hydranencephaly
- Aqueductal stenosis

PATHOLOGY

- Chromosomal abnormalities in 25-50% of cases
 - Trisomy 13 most common
- Infants of diabetic mothers have 1% risk

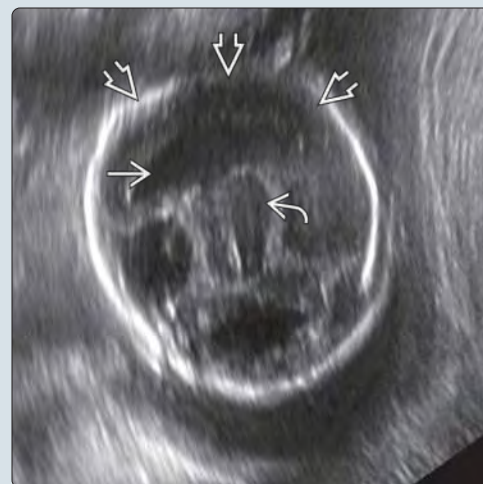
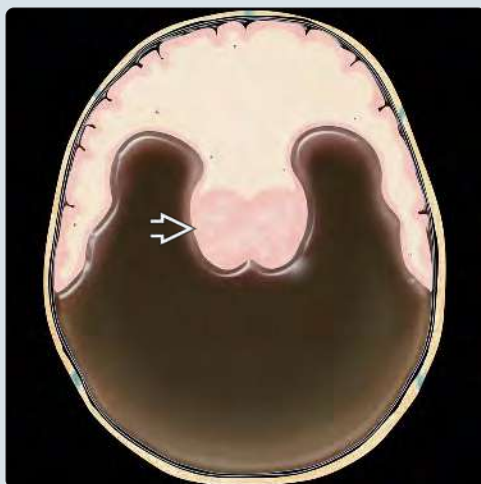CLINICAL ISSUES

- Offer karyotype
- Offer termination
- In utero demise and stillbirth common
- 50% of alobar HPE patients die < 5 months, 80% die < 1 year
- Survivors have hypotonia, feeding difficulties, seizure disorder

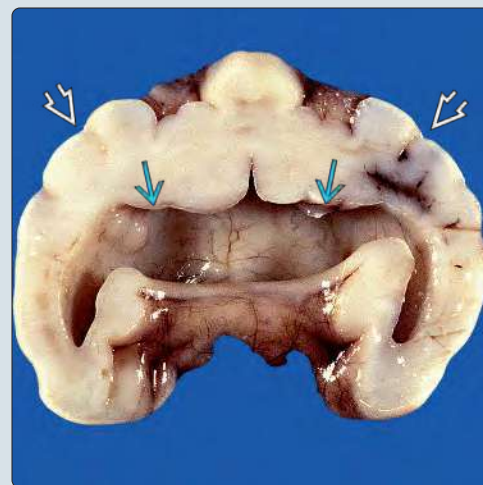
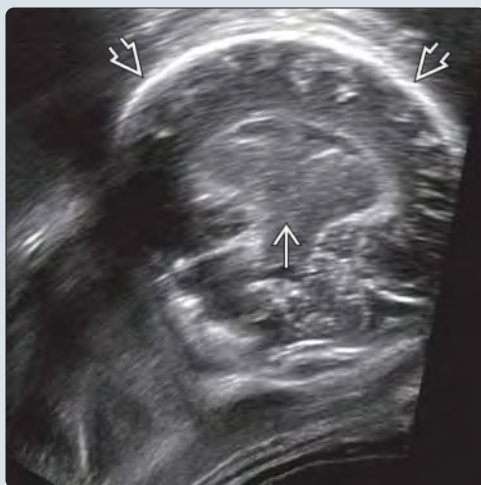DIAGNOSTIC CHECKLIST

- Diagnosis of alobar HPE may be made at time of nuchal translucency screening
- Facial malformations of any kind should trigger very careful evaluation of brain
 - "The face predicts the brain"
- Firm diagnosis essential for pregnancy, delivery management

(Left) Axial graphic illustrates alobar holoprosencephaly (HPE), the most severe form of the HPE spectrum. There is a large dorsal cyst created by a monoventricle incompletely covered by cerebral tissue dorsally. The thalami are completely fused or, more correctly, noncleaved, and there is no midline cleavage of the ventral gray and white matter. **(Right)** Axial transabdominal US at 17 weeks shows the characteristic monoventricle, continuous mantle of brain, and fused thalami.



(Left) Coronal transvaginal ultrasound of the fetal brain shows the continuous mantle of noncleaved cerebral cortex above a fused thalamus that is characteristic of alobar HPE. **(Right)** Coronal section through the brain of an infant with alobar HPE demonstrates no evidence of an interhemispheric fissure with fusion of the rudimentary hemispheres across the midline. The central monoventricle is horseshoe-shaped. (From Osborn's Brain.)



TERMINOLOGY

Definitions

- **Alobar holoprosencephaly (ALHPE)**
 - Most severe form of holoprosencephaly (HPE)
 - Complete/near complete lack of separation of cerebral hemispheres (i.e., no lobes)

IMAGING

General Features

- Best diagnostic clue
 - 1st trimester
 - Absent butterfly sign, monoventricle
 - 2nd/3rd trimester
 - Fused thalami with monoventricle

Ultrasonographic Findings

- **1st trimester**
 - Absent butterfly sign
 - Both choroids normally seen as "butterfly wings"
 - If absent, increases suspicion for HPE
- **2nd and 3rd trimester**
 - **Head**
 - Size usually decreased
 - Look at shape; normal head shape is oval in cross section
 - If head is round in all scan planes, look for brain malformation
 - **Monoventricle**
 - Crescent-shaped, centered on midline
 - **Dorsal cyst** in 92%
 - Monoventricle often communicates with dorsal cyst
 - Large dorsal cyst may result in macrocephaly
 - Can cause confusion with hydranencephaly but falx is present in that diagnosis
 - **Absent midline structures**
 - Cavum septi pellucidi
 - Falx cerebri
 - 3rd ventricle
 - Corpus callosum
 - **Fused thalami**
 - More correctly noncleaved thalami
 - **Brain morphology**
 - Variable; 3 common patterns described
 - "Pancake"
 - Mantle flattened at skull base
 - Large dorsal monoventricle/cyst
 - "Cup"
 - Brain mantle anterior and at base of skull
 - Partial crescent around monoventricle
 - "Ball"
 - Brain mantle surrounds monoventricle
 - **Facial anomalies** are common
 - Cyclopia
 - Ethmocephaly
 - Cebocephaly
 - Facial clefts
- 3D
 - Helps to define severity of malformation

- Inversion rendering of developing ventricular system in 1st trimester
- Axial acquisition can be manipulated to create sagittal and coronal planes
- Serial slices akin to viewing CT and MR scans
- Surface rendering to characterize facial malformations

MR Findings

- Not required to make diagnosis of ALHPE but can be helpful with difficult cases

Imaging Recommendations

- Protocol advice
 - Look for features of trisomy 13
 - Congenital heart disease (hypoplastic left heart and intracardiac echogenic foci highly associated)
 - Large echogenic kidneys in 50%
 - Musculoskeletal anomalies (e.g., postaxial polydactyly in 75%)
 - Omphalocele
 - Fetal growth restriction, often early onset
 - Careful evaluation of face/rest of fetus if brain looks abnormal
 - 50% of HPE spectrum with extrafacial malformations are aneuploid
 - Lack of extrafacial anomalies suggests isolated, euploid HPE

DIFFERENTIAL DIAGNOSIS

Atelencephaly, Aprosencephaly

- Absent brain above tentorium
- Maldevelopment of face
 - May have complete absence of orbits ± nose
- Facial skin tags may cause confusion with facial clefting

Hydranencephaly

- Falx present
- No cerebral tissue
- Brainstem may bulge superiorly and mimic fused thalami
- Normal face

Aqueductal Stenosis

- Falx present
- Cerebral hemispheres present but cortex thinned
- Dilated 3rd ventricle
- Thalami not fused
- Normal face
- Head size normal or large
- Look for adducted thumbs in X-linked form

PATHOLOGY

General Features

- Etiology
 - Infants of diabetic mothers have 1% risk
 - Teratogens include retinoic acid and alcohol
- Genetics
 - Most cases sporadic
 - Autosomal recessive, dominant, and X-linked forms described
 - Chromosomal abnormalities in 25-50% of HPE

Abnormal Facial Features Associated With Alobar Holoprosencephaly

Descriptive Term	Definition
Proboscis	Fleshy protuberance akin to elephant's trunk, on forehead
Cyclopia	Single midline orbit or absent eyes, absent nose, ± proboscis superior to single orbit
Ethmocephaly	Severe hypotelorism with proboscis set between eyes
Cebocephaly	Hypotelorism with rudimentary nose, often single nostril; cleft lip uncommon
Premaxillary agenesis	Midline cleft associated with absence of philtrum ± hypotelorism or cleft palate
Median philtrum-premaxilla anlage	Bilateral lateral cleft lip with median process representing philtrum-premaxillary anlage; associated with flattening of nose

DeMyer coined the term "the face predicts the brain" in 1964 based on clinical observations, however, as many as 20% of ALHPE cases have only minor facial dysmorphism.

Winter TC et al: Holoprosencephaly: a survey of the entity, with embryology and fetal imaging. *RadioGraphics*. 35(1):275-90, 2015.

- 70% of trisomy 13 fetuses have HPE
- Also trisomy 18, triploidy, monosomy 21
- At least 12 different chromosomal regions contain genes involved in HPE pathogenesis
 - Sonic hedgehog (*SHH*) was 1st gene identified (1996)
 - *SHH* mutations in 33% of familial HPE
 - *SHH* mutation in < 5% of sporadic cases
- Other implicated genes include *ZIC2*, *SIX3*, *TGIF*
- Multihit genetic/environmental factors hypothesis proposed
- Associated with multiple syndromes
 - Smith-Lemli-Opitz
 - Aicardi syndrome
 - Fryns syndrome
 - Meckel-Gruber
 - Velocardiofacial
- Embryology
 - Primitive brain develops 3 vesicles at day 22-24
 - Prosencephalon
 - Mesencephalon
 - Rhombencephalon
 - Prosencephalon normally divides into telencephalon and diencephalon at 32 days
 - Telencephalon gives rise to
 - Cerebral hemispheres
 - Putamen
 - Caudate nucleus
 - Diencephalon gives rise to
 - Thalamus
 - Hypothalamus
 - Globus pallidus
 - Optic vesicles (eye/orbit precursor)
 - Failed cleavage of prosencephalon therefore results in severe brain malformation
 - Associated defect in midline cranial cartilage differentiation rostral to notochord results in midface anomalies

CLINICAL ISSUES

Presentation

- Abnormal screening ultrasound
- Can be diagnosed at time of nuchal translucency screening

Demographics

- Epidemiology
 - 1:15,000 births
 - 1:250 terminated pregnancies

Natural History & Prognosis

- In utero demise and stillbirth common
- 50% of alobar HPE patients die < 5 months, 80% die < 1 year
- Among euploid patients, < 1-week survival if cyclopia or ethmocephaly
- Survivors have hypotonia, feeding difficulties, seizure disorder

Treatment

- Offer karyotype
 - In absence of chromosomal abnormalities, recurrence risk quoted at 6%
 - Includes sporadic and hereditary forms so recurrence risk of true sporadic cases is not this high
- Offer termination
- Fetal intervention not indicated

DIAGNOSTIC CHECKLIST

Consider

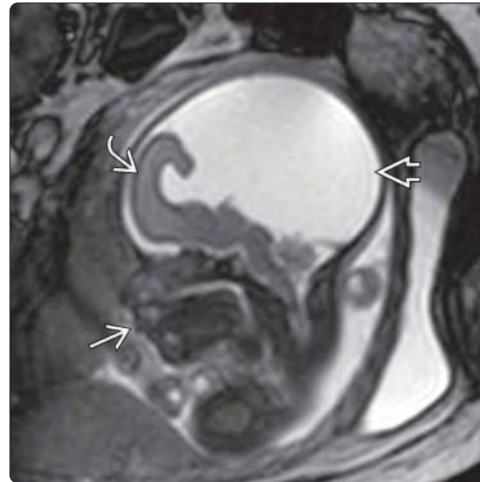
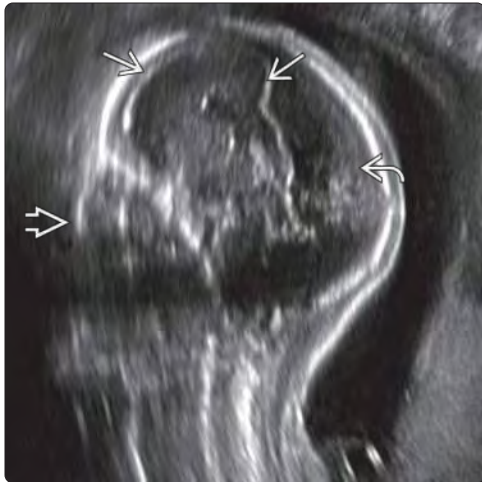
- Diagnosis of alobar HPE may be made as early as 11 weeks with transvaginal ultrasound
- Fetal MR if findings equivocal or acoustic access limited
 - Firm diagnosis essential for pregnancy, delivery management

Image Interpretation Pearls

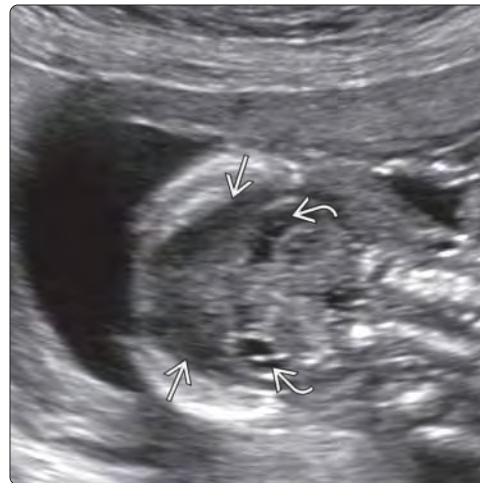
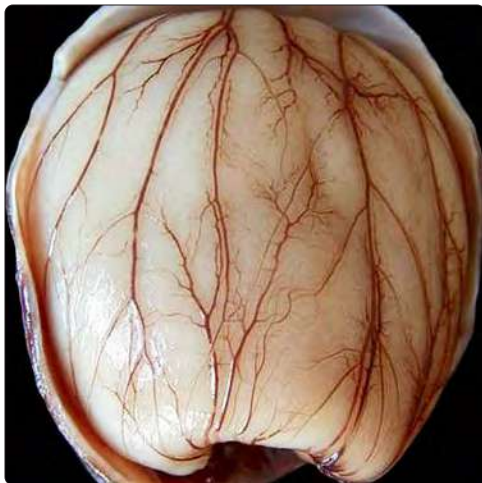
- Facial malformations of any kind should trigger very careful evaluation of brain

SELECTED REFERENCES

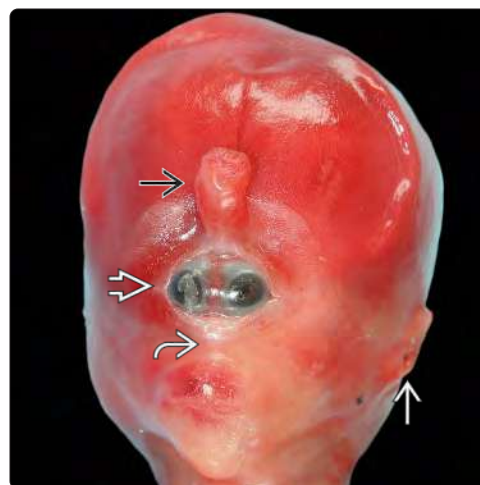
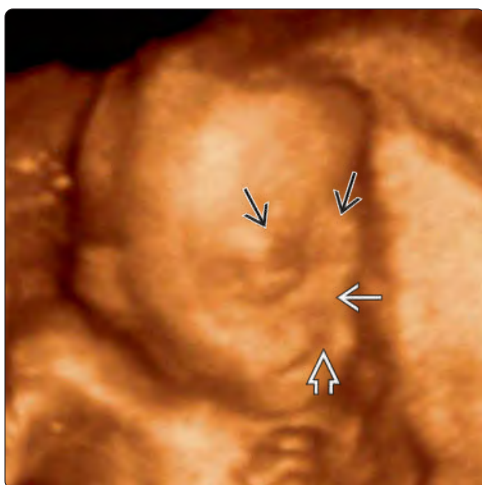
1. Winter TC et al: Holoprosencephaly: a survey of the entity, with embryology and fetal imaging. *Radiographics*. 35(1):275-90, 2015
2. Hahn JS et al: Neuroimaging advances in holoprosencephaly: Refining the spectrum of the midline malformation. *Am J Med Genet C Semin Med Genet*. 154C(1):120-32, 2010
3. Marcorelles P et al: Neuropathology of holoprosencephaly. *Am J Med Genet C Semin Med Genet*. 154C(1):109-19, 2010
4. Timor-Tritsch IE et al: Three-dimensional inversion rendering in the first- and early second-trimester fetal brain: its use in holoprosencephaly. *Ultrasound Obstet Gynecol*. 32(6):744-50, 2008



(Left) Sagittal ultrasound of a 2nd-trimester fetus shows the cup morphology of the brain in ALHPE in which the brain cups the large dorsal cyst. Note the abnormal flat profile and the brachycephaly due to frontal lobe hypoplasia. (Right) Sagittal T2WI MR in a different case shows similar cup brain morphology, but, in this case, the dorsal cyst is larger, meaning the head circumference is not small. The profile is normal, illustrating the fact that not all fetuses with ALHPE have dysmorphic facies.



(Left) Surface view of the brain during autopsy shows a completely smooth, featureless surface with no evidence of sulcation, gyration, or midline structures such as the falx or interhemispheric fissure in this case of ALHPE. (From Osborn's Brain.) (Right) Coronal scan at 17 weeks shows the posterior continuous cortical mantle with the ball morphology in which the brain encircles the monoventricle. With the cranium removed, this brain would appear just as that shown in the autopsy image.



(Left) 3D US surface rendering of the face shows midline cleft lip, severe hypotelorism, and an abnormal, flattened nose in a fetus with premaxillary agenesis associated with ALHPE. Remember "the face predicts the brain" and any facial abnormality should trigger a careful evaluation of the brain. (Right) Autopsy image following termination of pregnancy for trisomy 13 shows a proboscis, cyclopia with a single orbit, absent philtrum, and low-set ears.

KEY FACTS

TERMINOLOGY

- Intermediate severity in holoprosencephaly (HPE) spectrum due to partial cleavage of prosencephalon

IMAGING

- Best diagnostic clue is absent cavum septi pellucidi (CSP) with incomplete interhemispheric fissure
 - Fused frontal lobes but separate occipital lobes
 - Frontal lobe hypoplasia → brachycephaly → round head shape
 - Microcephaly common
- Thalami completely/partly fused
 - Dorsal cyst in 28%, associated with thalamic fusion
 - Large dorsal cyst may cause macrocephaly
- Facial anomalies milder than seen with alobar HPE

TOP DIFFERENTIAL DIAGNOSES

- Alobar HPE
- Other causes of absent CSP

- Syntelencephaly
- Lobar HPE
- Agenesis/dysgenesis of corpus callosum (CC)
- Open-lip schizencephaly

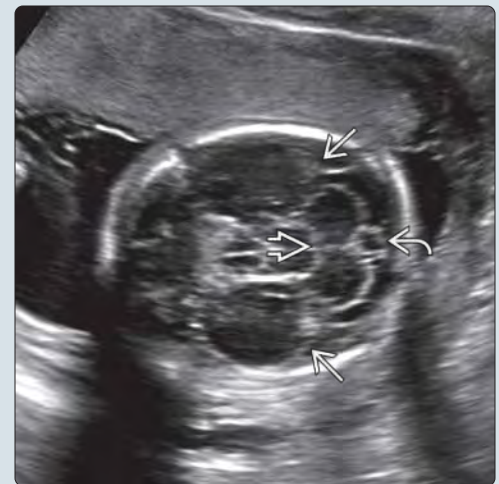
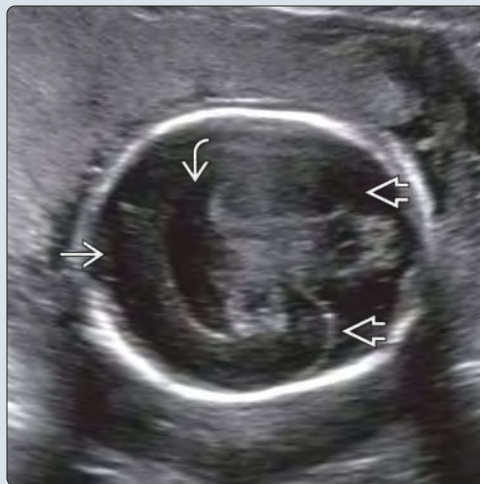
CLINICAL ISSUES

- Offer amniocentesis
- Offer termination
- Liveborn infants rarely survive beyond 1st year
- Small number with mild semilobar HPE survive into teens

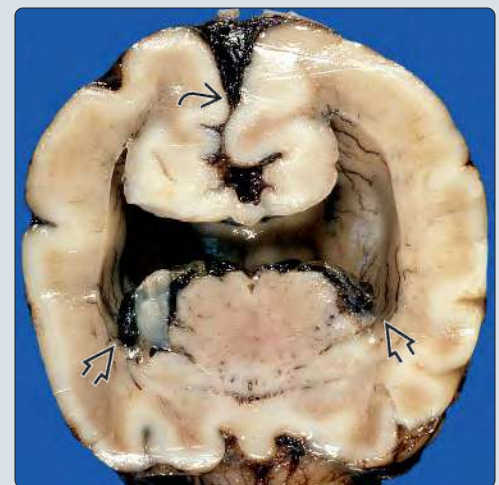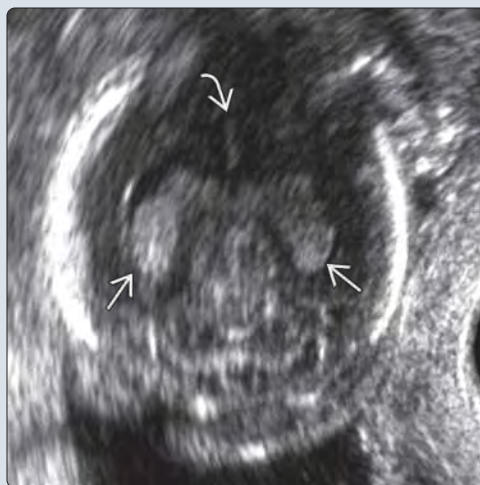
DIAGNOSTIC CHECKLIST

- Absent CSP can be associated with significant brain malformations
 - Use all scan planes ± vaginal US and 3D volume acquisition
- HPE spectrum is only brain malformation where posterior CC is present but anterior CC is absent

(Left) This fetus was found to have an absent CSP on standard views. An oblique US obtained after careful scanning from different angles demonstrates frontal lobe fusion anteriorly and a monoventricle, but the occipital lobes are separate. **(Right)** A steeper axial oblique plane in the same patient shows separate parietal lobes and a normal cerebellum and cisterna magna. Thus, the cause of absent CSP in this case is semilobar HPE with frontal lobe fusion but separate occipital and parietal lobes.



(Left) Coronal oblique US shows a single ventricle with fused choroids and anterior horns but separate occipital horns. There is a rudimentary interhemispheric fissure. **(Right)** Coronal autopsy at a more anterior level in a case of semilobar HPE shows ventricular communication across the midline with the development of primitive temporal horns and a rudimentary interhemispheric fissure. This is more lobar differentiation than seen in alobar HPE. (From Osborn's Brain.)



TERMINOLOGY

Definitions

- **Semilobar holoprosencephaly (SLHPE)**
 - Intermediate severity in holoprosencephaly (HPE) spectrum due to partial cleavage of prosencephalon

IMAGING

General Features

- Best diagnostic clue
 - Absent cavum septi pellucidi (CSP) with incomplete interhemispheric fissure (IHF)

Ultrasonographic Findings

- Grayscale ultrasound
 - Absent CSP with anterior communication of ventricles, separate occipital horns
 - Fused frontal lobes but separate occipital lobes
 - Frontal lobe hypoplasia → brachycephaly → round head shape
 - Microcephaly common
 - Thalami completely/partly fused
 - Dorsal cyst in 28%, associated with thalamic fusion
 - Large dorsal cyst may cause macrocephaly
 - Posterior corpus callosum (CC) may be present but anterior portion is absent
 - Facial anomalies milder than seen with alobar HPE
 - Hypotelorism, median cleft, cebocephaly
- Color Doppler
 - Azygous (i.e., single) anterior cerebral artery
 - "Snake under the skull" sign as it runs over fused frontal lobes just deep to calvarium
- 3D
 - Helps to determine extent of hemispheric fusion, characterize facial malformations

MR Findings

- Helpful for detailed evaluation of brain

DIFFERENTIAL DIAGNOSIS

Alobar Holoprosencephaly

- No differentiation of midline structures, falx absent
- Severe facial anomalies common

Other Causes of Absent Cavum Septi Pellucidi

- **Syntelencephaly**
 - Midline interhemispheric fusion variant of HPE
 - Anterior and posterior horns separate but hemispheres fused centrally
- **Lobar HPE**
 - May be very subtle with absent CSP as only finding
 - MR very helpful to demonstrate gyrus in continuity across midline
- **Agenesis/dysgenesis of CC**
 - IHF is complete
 - Parallel lateral ventricles with colpocephaly
 - Callosal dysgenesis results in short or thin CC
 - Anterior portion present, posterior portion deficient
- **Septo-optic dysplasia**
 - IHF is complete

- Downward pointed frontal horns on coronal view
- **Open-lip schizencephaly**
 - IHF is complete
 - Cortical clefts lined by gray matter

PATHOLOGY

General Features

- Embryology
 - Primitive brain develops 3 vesicles at 22-24 days
 - Prosencephalon, mesencephalon, rhombencephalon
 - Cleavage of prosencephalon gives rise to telencephalon and diencephalon at 32 days
 - Telencephalon gives rise to
 - Cerebral hemispheres, putamen, caudate nucleus
 - Diencephalon gives rise to
 - Thalamus, hypothalamus, globus pallidus, optic vesicles,
 - Impaired cleavage of prosencephalon results in spectrum of brain malformations
- Genetics
 - Most are sporadic
 - Autosomal dominant, recessive, and X-linked forms described
 - Associated with aneuploidy, especially trisomy 13

CLINICAL ISSUES

Presentation

- Most common signs/symptoms
 - Abnormal screening ultrasound

Natural History & Prognosis

- Liveborn infants rarely survive beyond 1st year
- Small number with mild SLHPE survive into teens
 - Variable cognitive impairment

Treatment

- Offer amniocentesis
- Offer termination
- Discuss delivery plan in ongoing pregnancies with respect to monitoring in labor and intervention at birth

DIAGNOSTIC CHECKLIST

Consider

- Absent CSP can be associated with significant brain malformations
- Use all scan planes ± vaginal US and 3D volume acquisition

Image Interpretation Pearls

- HPE spectrum is only brain malformation where posterior CC is present but anterior CC is absent

SELECTED REFERENCES

1. Winter TC et al: Holoprosencephaly: a survey of the entity, with embryology and fetal imaging. *Radiographics*. 35(1):275-90, 2015
2. Mallick S et al: Semilobar holoprosencephaly with 21q22 deletion: an autopsy report. *BMJ Case Rep*. 2014, 2014
3. Oncel MY et al: Severe semilobar holoprosencephaly and lissencephaly associated with cebocephaly in a newborn. *Genet Couns*. 23(3):341-6, 2012
4. Hahn JS et al: Neuroimaging advances in holoprosencephaly: Refining the spectrum of the midline malformation. *Am J Med Genet C Semin Med Genet*. 154C(1):120-32, 2010

KEY FACTS

TERMINOLOGY

- Lobar holoprosencephaly (HPE) is least severe form of HPE
- Interhemispheric fissure present along entire midline with differentiation of cerebral hemispheres
- Neuropathology definition specifies at least 1 gyrus in continuity across midline

IMAGING

- Absent CSP may be only finding at 2nd-trimester scan
- Small head size may progress to microcephaly
- Fused fornices have been described as specific sign of lobar HPE on fetal US; however, have been seen in other conditions
- Gyral continuity, which by definition must be present, easier to see on MR than on US

TOP DIFFERENTIAL DIAGNOSES

- Septo-optic dysplasia
- Agenesis of corpus callosum (CC)

- Syntelencephaly

PATHOLOGY





- Most are sporadic but some known mutations/deletions
 - Autosomal recessive *STIL* mutation, 10q24.3-25.1 deletion

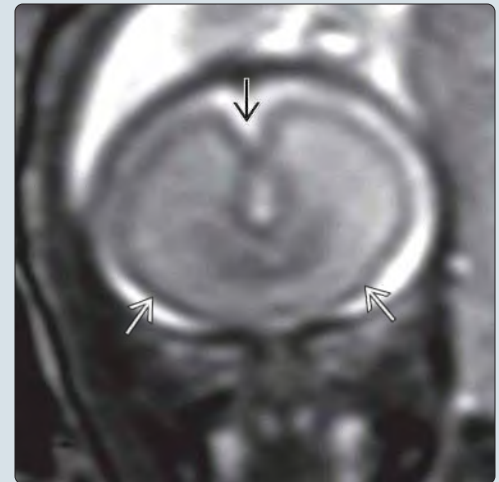
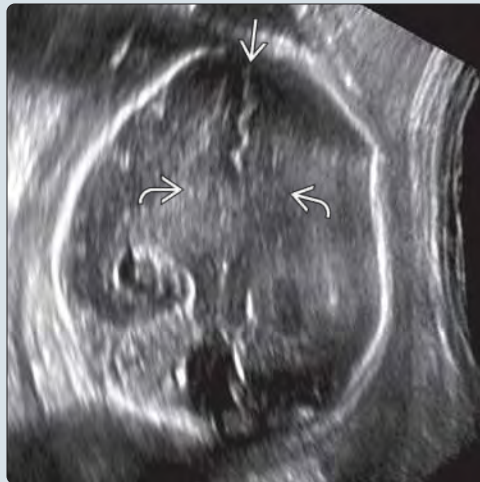CLINICAL ISSUES






- Misconception exists that HPE is lethal
 - Significant proportion with mild HPE survive into childhood and beyond
 - > 50% with isolated semilobar or lobar HPE alive at 1 year

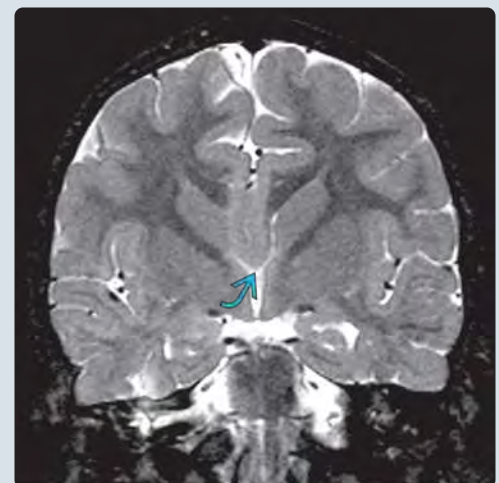
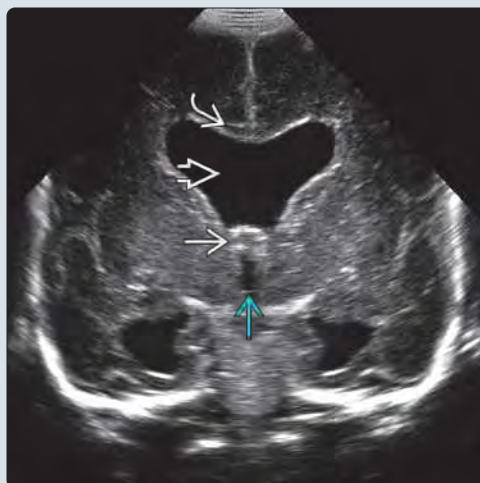
DIAGNOSTIC CHECKLIST

- Absent CSP is important marker for midline malformation
- HPE is only brain malformation where posterior CC is present but anterior CC is absent

(Left) Coronal US at 32 weeks shows the interhemispheric fissure  between the frontal lobes, but there is inferior parenchymal fusion , indicating lobar HPE. The only finding at the 20-week anatomy scan was absent CSP. **(Right)** Coronal T2WI MR in another fetus with lobar HPE shows gyral continuity  across the midline anteriorly and inferiorly. Note the interhemispheric fissure  is present all the way anteriorly. This gyral continuity is very difficult to demonstrate sonographically, particularly at the time of anatomy scan.



(Left) Coronal neonatal head US shows an absent CSP , thin dysplastic body of the corpus callosum , and fused fornices  running anterior to posterior in the 3rd ventricle . This is associated with lobar HPE but is not as specific as once thought. **(Right)** Coronal postnatal T2WI MR shows a thin band of gray matter fused across the midline . This form of lobar HPE is referred to as cingulosynapsis; the anterior cingulate gyrus is the site of fusion.



TERMINOLOGY

Definitions

- **Lobar holoprosencephaly (HPE)**
 - Least severe end of holoprosencephaly spectrum
 - Interhemispheric fissure present along entire midline with differentiation of cerebral hemispheres
 - Neuropathology definition of lobar HPE specifies at least 1 gyrus in continuity across midline

IMAGING

General Features

- Best diagnostic clue
 - Absent cavum septi pellucidi (CSP)

Ultrasonographic Findings

- Grayscale ultrasound
 - Absent CSP may be only finding at 2nd-trimester scan
 - Small head size may progress to microcephaly
 - Thalami generally separate, but may be connected by mass thicker than normal massa intermedia
 - Dorsal cyst consequently rare ~ 9% in lobar HPE
 - Fused fornices have been described as specific sign of lobar HPE on fetal US; however, have been seen in other conditions
- Color Doppler
 - Azygos anterior cerebral artery usually present in anterior interhemispheric fissure
 - Displaced anteriorly over contiguous fused frontal gyri
 - Single vessel on sagittal view → snake under skull sign

MR Findings

- Helps to differentiate lobar HPE from other causes of absent CSP
 - Much easier to see gyral continuity on MR than on US
- Corpus callosum (CC) dysgenesis involving rostrum or genu but not splenium

DIFFERENTIAL DIAGNOSIS

Septo-Optic Dysplasia

- Flat-top or squared-off appearance of frontal horns
- Downward point to anterior horns

Agenesis of Corpus Callosum

- Lateral ventricles parallel and do not communicate
- Colpocephaly (teardrop-shaped ventricles)
- Steer horn shape of anterior horns of lateral ventricles

Syntelencephaly

- Anterior and posterior horns separate
- Hemispheres fused centrally

Schizencephaly

- Cerebral cortical cleft lined by gray matter
- Ventricular wall "tented" toward cleft

PATHOLOGY

General Features

- Features specific to lobar HPE
 - Cerebral lobes nearly fully formed
 - Deep gray nuclei are nearly completely formed
 - CC may be normal
 - If CC dysgenesis, only anterior portion is abnormal
- Generally classified as lobar if frontal lobes are < 50% fused (difficult/arbitrary to quantitate)
- Genetics
 - Most are sporadic
 - Autosomal recessive *STIL* mutation, 10q24.3-25.1 deletion

CLINICAL ISSUES

Presentation

- Most common signs/symptoms
 - Absent CSP

Natural History & Prognosis

- Microcephaly, developmental delay
 - Mild lobar HPE may not be clinically evident in neonates
- Misconception exists that HPE is lethal
 - Not true for mild forms
 - > 50% with isolated semilobar or lobar HPE alive at 1 year
 - Some isolated mild HPE survive into teens
 - Speak and function with variable degrees of cognitive impairment

Treatment

- Offer amniocentesis
- Requires careful postnatal evaluation
 - Mild HPE difficult diagnosis to make even postnatally

DIAGNOSTIC CHECKLIST

Consider

- Fetal MR to look for gyral continuity if CSP absent and US otherwise looks normal

Image Interpretation Pearls

- Absent CSP is important marker for midline malformation
 - Isolated septal deficiency is diagnosis of exclusion
- HPE is only brain malformation where posterior CC is present but anterior CC is absent

SELECTED REFERENCES

1. Kakar N et al: *STIL* mutation causes autosomal recessive microcephalic lobar holoprosencephaly. *Hum Genet.* 134(1):45-51, 2015
2. Peltekova IT et al: Novel interstitial deletion of 10q24.3-25.1 associated with multiple congenital anomalies including lobar holoprosencephaly, cleft lip and palate, and hypoplastic kidneys. *Am J Med Genet A.* 164A(12):3132-6, 2014
3. Radojicic J et al: Rare disease: lobar holoprosencephaly with a median cleft lip-case report. *Cleft Palate Craniofac J.* 53(1):109-17, 2014

KEY FACTS

TERMINOLOGY

- Septo-optic dysplasia is defined as association of
 - Optic nerve hypoplasia (ONH)
 - Midline brain malformation
 - ± hypopituitarism

IMAGING

- Absent cavum septi pellucidi (CSP)
 - Frontal horns in communication across midline
 - Coronal view though frontal horns shows flat-top or squared shape coming to point inferiorly
- MR may reveal additional findings not appreciated on US

TOP DIFFERENTIAL DIAGNOSES

- Agenesis of corpus callosum
- Lobar holoprosencephaly
- Open-lip schizencephaly
- Isolated agenesis of septum pellucidum

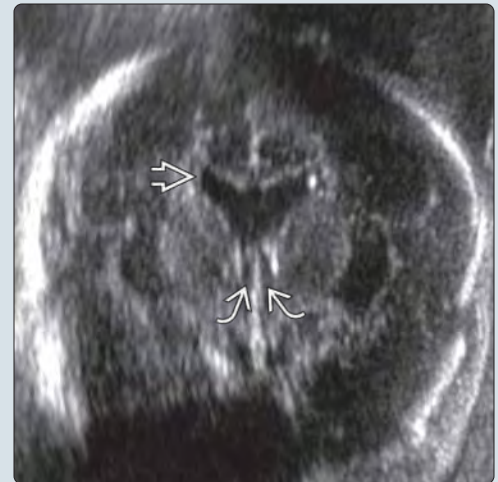
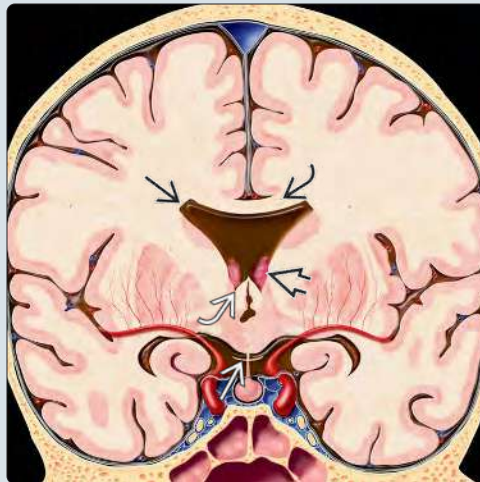
CLINICAL ISSUES

- Prognosis depends on severity and associated abnormalities
- ONH is a leading cause of congenital blindness
- Children with ONH require careful monitoring for associated conditions
- Risk of endocrine dysfunction highest in children ≤ 2 years of age when ONH + SP/CC dysgenesis present

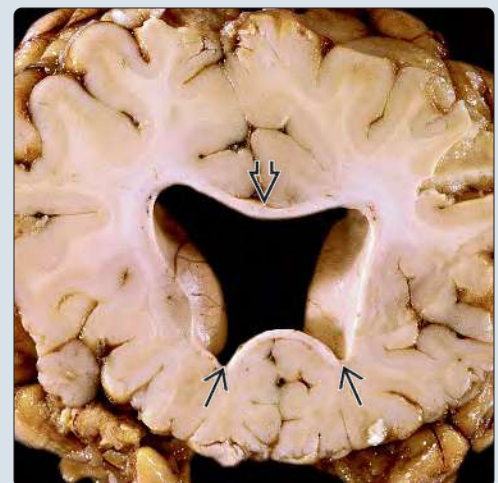
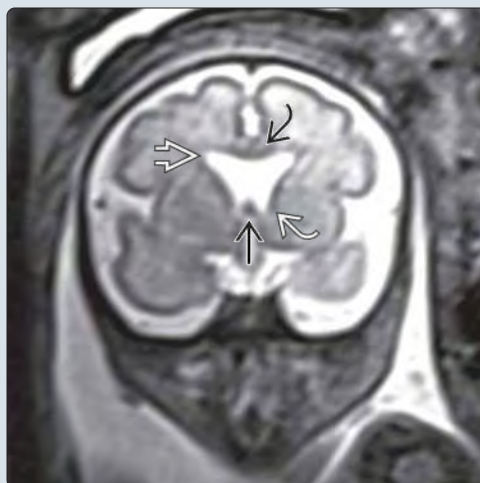
DIAGNOSTIC CHECKLIST

- CSP is marker of normal fetal CNS development
 - Do not assume absent CSP is "technical"
- Even if absent CSP not embryologically linked to ONH, affected fetuses need evaluation for midline brain/optic chiasm abnormalities
 - Diagnosis of isolated septal dysgenesis is clinical in neonate
 - Requires normal ophthalmologic exam and normal endocrine function

(Left) Coronal graphic shows features of septo-optic dysplasia, including downward-pointing frontal horns with a squared-off appearance of the roof. The fornices are not fused; the corpus callosum is present, but the CSP is absent. The optic chiasm is small. **(Right)** Coronal US in a 28-week fetus shows a similar appearance with the frontal horns squared-off superiorly and pointed inferiorly as they drape over the columns of the fornices, which are not fused in this case.



(Left) Coronal T2WI MR in a 29-week fetus shows absent cavum and the flattop appearance of the communicating frontal horns, which also have the typical downward-pointing shape. The corpus callosum is normal but the fornices are fused in the midline. **(Right)** Coronal section through the anterior brain at autopsy shows absent CSP and box-like lateral ventricles with inferiorly pointed frontal horns. In this example, the corpus callosum (though present) is abnormally thin. (From Osborn's Brain.)



TERMINOLOGY

Abbreviations

- Septo-optic dysplasia (SOD)

Definitions

- Association of optic nerve hypoplasia (ONH) with midline brain malformations ± hypopituitarism
- Recent studies suggest that ONH, hypopituitarism, and absent septum pellucidum, though frequently associated under umbrella term of SOD, do not have embryologic linkage
 - ONH is leading cause of congenital blindness
- **SOD plus:** Term coined for cases with additional brain malformations
 - May just reflect association of ONH, endocrine dysfunction, and developmental delay with complex brain malformation

IMAGING

General Features

- Best diagnostic clue
 - Absent cavum septi pellucidi (CSP)
 - Presence of vestigial anterior leaflets does not exclude diagnosis

Ultrasonographic Findings

- Absent CSP
 - Frontal horns in communication across midline
 - Coronal view though frontal horns shows flat-top or squared shape coming to a point inferiorly
- Corpus callosum (CC) present but may be thinned
- Mild ventriculomegaly (ventricular wall nodularity suggests gray matter heterotopia)
- Use vitreous as acoustic window through ocular globe to visualize optic nerve sheath complex
 - US resolution is insufficient to differentiate nerve from surrounding nerve sheath
 - Mean optic nerve sheath diameter (ONSD) in orbit 1.2 mm at 22 weeks, 2.6 mm at 36 weeks
- 3D
 - Surface reconstruction of optic chiasm allows measurement of posterior optic tracts
 - Fetal optic tract diameter in mm = $0.0451951 + 0.0925759 \times \text{gestational age in weeks}$
- Series of 13 fetuses with absent CSP, 3D US and follow-up
 - 9 with normal optic tract and normal vision on follow-up
 - 4 with hypoplastic optic tract
 - 2 terminated with autopsy confirmation of ONH
 - 2 live births: 1 infant blind, 1 with unilateral hypoplasia, impaired vision, abnormal eye movement

MR Findings

- Same as sonographic findings
- MR may reveal additional findings not appreciated on US
 - Gray matter heterotopia, schizencephaly, dysgenesis of corpus callosum
 - Fused fornices (commonly overlooked finding in SOD)
 - Was thought to be specific sign of lobar holoprosencephaly; now known to occur in other midline brain malformations

- In 3rd trimester, use T1WI to see low signal optic nerve in high signal orbital fat
 - Optic nerve thickness ~ extraocular muscle thickness

Imaging Recommendations

- Protocol advice
 - Careful evaluation of brain is mandatory in all fetuses with absent CSP
 - Look for anchor-shaped anterior complex in all detailed brain scans
 - From posterior to anterior, this consists of CSP (bordered by frontal horns), genu of CC, pericallosal sulcus, and anterior interhemispheric fissure
 - MR very helpful, especially if maternal habitus or fetal position challenging

DIFFERENTIAL DIAGNOSIS

Other Causes of Absent CSP

- **Agensis of Corpus Callosum**
 - Parallel lateral ventricles
 - Colpocephaly (teardrop shape of lateral ventricles)
 - Abnormal course of callosomarginal/pericallosal arteries
- **Lobar Holoprosencephaly**
 - Gyrus in continuity across midline (easiest to see on MR)
 - Azygos anterior cerebral artery
 - Facial anomalies may be present
- **Open-Lip Schizencephaly**
 - Unilateral or bilateral cleft in cerebral parenchyma lined with gray matter
 - Cleft extends from brain surface to ventricular wall
 - Ventricular wall may be "tented" toward defect
- **Isolated Agensis of Septum Pellucidum**
 - Infants with absent CSP require careful postnatal evaluation
 - Isolated septal deficiency is diagnosis of exclusion

PATHOLOGY

General Features

- Etiology
 - Most cases of ONH are sporadic
 - Only definite associations with ONH are younger maternal age/primiparity
- Genetics
 - Difficult to determine mutations for ONH vs. other midline brain malformations

Gross Pathologic & Surgical Features

- Small optic chiasm and nerves
 - Sparse/absent myelinated fibers
 - ONH unilateral in 20%

CLINICAL ISSUES

Presentation

- SOD diagnosed on clinical basis, with ongoing debate as to exact diagnostic criteria

Demographics

- Age
 - ONH associated with young maternal age, primiparity
- Epidemiology

Reference Ranges for Fetal Optic Tract Diameter

GA in Weeks	n	3rd	5th	50th	95th	97th
21	5	1.6	1.7	2.0	2.3	2.3
22	7	1.7	1.8	2.1	2.4	2.4
23	6	1.8	1.9	2.2	2.5	2.5
24	7	1.9	2.0	2.3	2.6	2.6
25	5	2.0	2.1	2.4	2.6	2.7
26	5	2.1	2.2	2.5	2.7	2.8
27	6	2.2	2.3	2.5	2.8	2.9
28	4	2.3	2.4	2.6	2.9	3.0
29	5	2.4	2.4	2.7	3.0	3.1
30	5	2.5	2.5	2.8	3.1	3.2
31	5	2.6	2.6	2.9	3.2	3.3
32	17	2.7	2.7	3.0	3.3	3.3
33	5	2.7	2.8	3.1	3.4	3.4
34	6	2.9	2.9	3.2	3.5	3.5
35	5	2.9	3.0	3.3	3.6	3.6
36	5	3.0	3.1	3.4	3.7	3.7

GA = gestational age, all measurements are of the posterior optic tracts in millimeters, n = number of fetuses examined at each GA.

Bault JP et al. Role of three-dimensional ultrasound measurement of the optic tract in fetuses with agenesis of the septum pellucidum. *Ultrasound Obstet Gynecol.* May;37(5):570-5, 2011.

- o SOD in 1:10,000 live births
- o Septal agenesis in 2-3/100,000 in general population
- o M = F

Natural History & Prognosis

- Retrospective analysis of 80 children with SOD based on presence of ≥ 2 of following criteria
 - o ONH, agenesis/dysgenesis of septum pellucidum (SP) or CC, hypothalamic pituitary dysfunction
 - ONH in 96% (diagnosed after evaluation for strabismus or nystagmus)
 - Hypothalamic pituitary dysfunction in 55%
 - Seen in 36% with ONH + SP/CC dysgenesis
 - Seen in 15% with ONH but without SP/CC dysgenesis
 - Seen in only 4% with SP/CC dysgenesis but no ONH
- ONH associated with
 - o Hypothalamic dysfunction
 - Body temperature regulation
 - Over-/undereating, water-seeking behavior
 - Abnormal sleep wake cycles
 - o Hypopituitarism in 75%
 - o Developmental delay in 71%
 - o Autism spectrum disorder
- Children with ONH often have abnormal CC
 - o Fetal presentation may be absent CSP
 - o CC abnormalities are associated with developmental delay but not hypopituitarism
- Prognosis depends on severity and associated abnormalities
 - o Fetal presentation probably implies more severe end of spectrum

Treatment

- Careful assessment of infant by pediatric endocrinologist and ophthalmologist
- Risk of endocrine dysfunction highest in children ≤ 2 years of age when ONH + SP/CC dysgenesis present

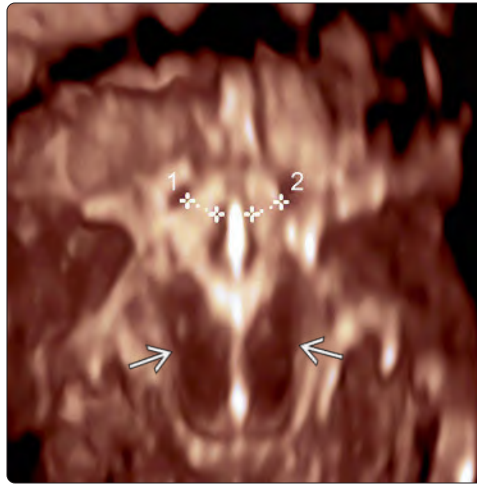
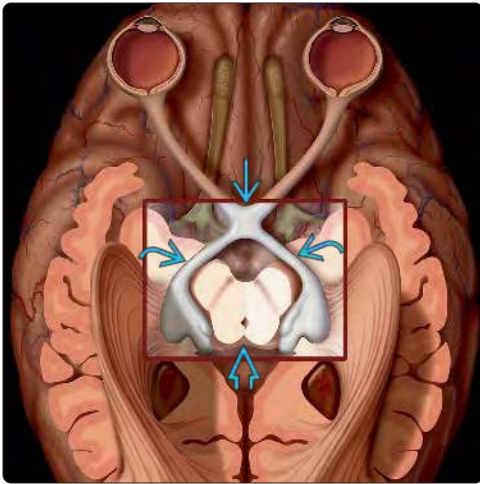
DIAGNOSTIC CHECKLIST

Image Interpretation Pearls

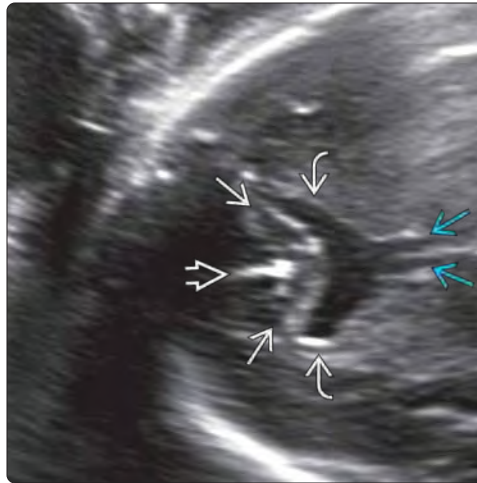
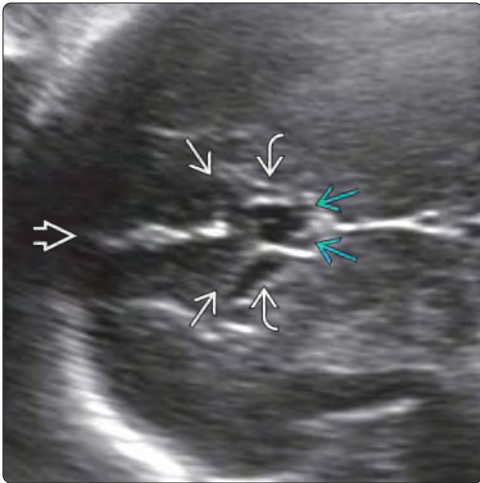
- Do not assume absent CSP is "technical"
- CSP is marker of normal fetal CNS development
 - o If absent, significant neurological condition may exist
- Diagnosis of isolated septal dysgenesis is clinical in neonate
 - o Requires normal ophthalmologic exam and normal endocrine function
 - o Not possible in fetus
- Even if absent CSP not embryologically linked to ONH, affected fetuses need evaluation for midline brain/optic chiasm abnormalities

SELECTED REFERENCES

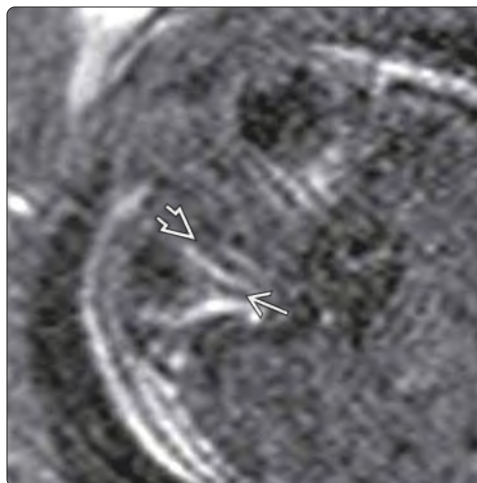
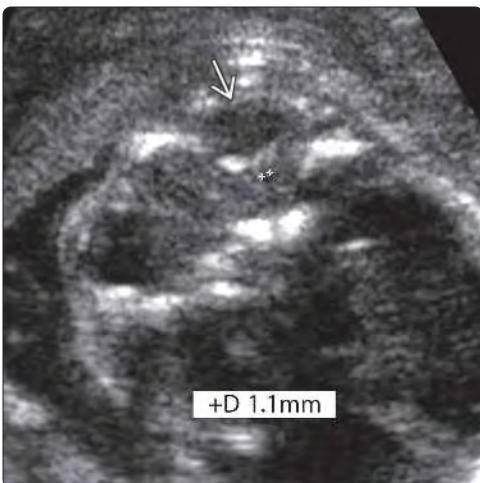
1. Cemeroglu AP et al: Spectrum of clinical presentations and endocrinological findings of patients with septo-optic dysplasia: a retrospective study. *J Pediatr Endocrinol Metab.* 28(9-10):1057-63, 2015
2. Cagneaux M et al: From cavum septi pellucidum to anterior complex: how to improve detection of midline cerebral abnormalities. *Ultrasound Obstet Gynecol.* 42(4):485-6, 2013
3. Garcia-Filion P et al: Prenatal determinants of optic nerve hypoplasia: review of suggested correlates and future focus. *Surv Ophthalmol.* 58(6):610-9, 2013
4. Bault JP et al: Role of three-dimensional ultrasound measurement of the optic tract in fetuses with agenesis of the septum pellucidum. *Ultrasound Obstet Gynecol.* 37(5):570-5, 2011



(Left) Graphic shows the visual pathway, with the box highlighting where the adjacent 3D ultrasound volume was obtained. This includes the optic chiasm and optic tracts wrapping around the brainstem. (Right) This slightly angled 3D US reconstruction shows the optic tracts (calipers) anterior to the brainstem. Measurements can be compared to normative data. In a small series, fetuses with absent CSP but normal measurements had no visual impairment. (Courtesy D. Pugash, MD.)



(Left) Magnified view of the normal anterior complex at 30 weeks shows the interhemispheric fissure, the anterior corpus callosum (the genu), the fornices, and the CSP, which is the box-like structure between the frontal horns of the lateral ventricles. (Right) Similar view of the anterior complex in a different case shows the interhemispheric fissure, anterior corpus callosum (the genu), and separate fornices but absence of the CSP, which should be between the frontal horns. SOD was confirmed at birth.



(Left) Oblique US looking into the orbit through the ocular globe shows the optic nerve sheath complex (calipers). At 32 weeks, 1.1 mm is abnormally small, suggesting optic nerve hypoplasia in this fetus with absent CSP. (Right) T1 MR through orbits shows normal optic nerve (as opposed to optic nerve sheath complex seen on US) visible in orbital fat. As a rule of thumb, the nerve should be approximately equal in size to the extraocular muscles. Always look at optic nerves when performing MR for absent CSP.

KEY FACTS

TERMINOLOGY

- Variant of holoprosencephaly characterized by midline fusion of posterior frontal and parietal lobes

IMAGING

- Absent cavum septi pellucidi (CSP)
- Interhemispheric fissure present anteriorly and posteriorly
 - Separate frontal and occipital lobes
 - Fusion of posterior frontal and parietal lobes across midline
- Sylvian fissures connect across midline over vertex, creating anomalous coronally oriented fissure
- Dorsal cyst in 25%
- Thalamic fusion in 33%
- Face is generally normal





TOP DIFFERENTIAL DIAGNOSES

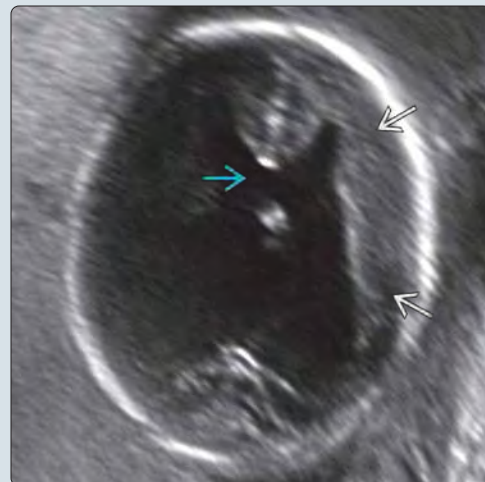
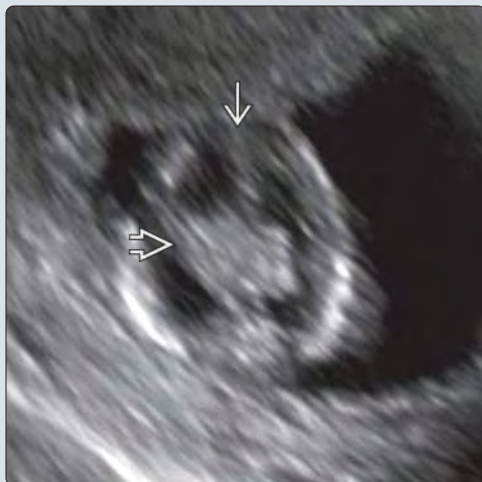- **Bilateral schizencephaly**







- Schizencephalic clefts extend from pia mater to wall of ventricle
- Ventricular wall often "tented" toward cleft
- Do not confuse connected midline sylvian fissures of syntelencephaly with bilateral schizencephaly
- **Semilobar holoprosencephaly**
 - Interhemispheric fissure deficient anteriorly with variable fusion of anterior cerebral hemispheres
- **Lobar holoprosencephaly**
 - Interhemispheric fissure present with minimal fusion of anterior cerebral hemispheres
- **Septo-optic dysplasia**
 - Absent CSP with complete separation of cerebral hemispheres

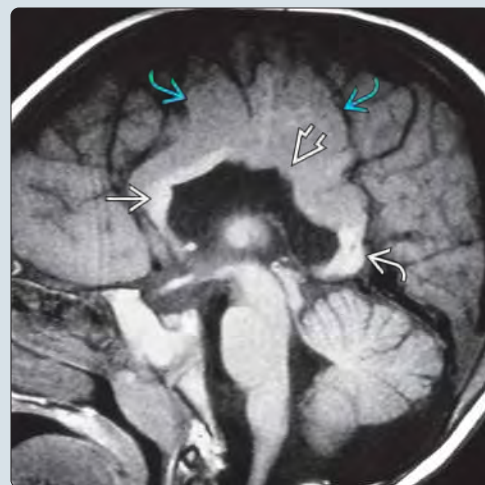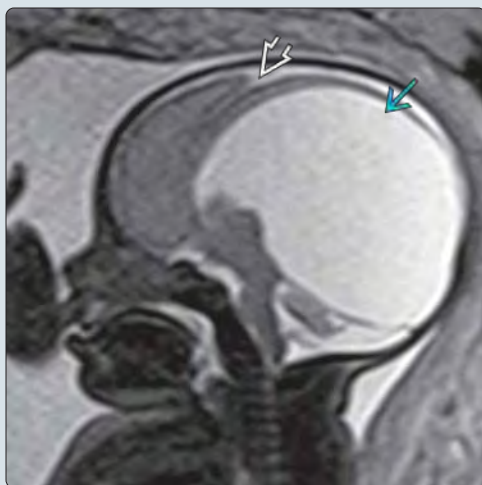CLINICAL ISSUES

- Spasticity, hypotonia, seizures, visual impairment, developmental delay

(Left) Transabdominal US through the fetal brain at the time of nuchal translucency screening shows abnormal morphology of the choroids , which appear stuck together. There is a normal anterior midline echo . **(Right)** Follow-up scan at 20 weeks in the same case shows that the brain is clearly abnormal. The cavum septi pellucidi is absent , the ventricles communicate in the midline, and the cortical mantle  is abnormally smooth.



(Left) Sagittal MR in the same case in the 3rd trimester shows a large dorsal cyst . Note the abnormal sylvian fissures  connecting over the midline. **(Right)** Sagittal postnatal MR in a different case shows the characteristic abnormality of the corpus callosum with intact genu  and splenium  but deficient body . This can be hard to resolve on fetal MR. Also note the fusion of the posterior frontal and parietal lobes .



TERMINOLOGY

Synonyms

- Middle interhemispheric variant of holoprosencephaly (HPE)

Definitions

- Variant of HPE characterized by midline fusion of posterior frontal and parietal lobes

IMAGING

General Features

- Best diagnostic clue
 - Separate frontal and occipital lobes
 - Fusion of posterior frontal and parietal lobes across midline
- Location
 - Dorsal telencephalon
- Morphology
 - Interhemispheric fissure is present anteriorly and posteriorly
 - Sylvian fissures connect across midline, over vertex in majority
 - Genu and splenium of corpus callosum present
 - Body of corpus callosum absent
 - Fused thalami in 33%
 - More likely to have dorsal cyst in this subgroup
 - Normal basal ganglia, hypothalamus
 - Optic chiasm generally normal

Ultrasonographic Findings

- Grayscale ultrasound
 - Absent cavum septi pellucidi (CSP)
 - Communication of ventricles across midline
 - Interhemispheric fissure present anteriorly and posteriorly
 - Midhemispheric fusion of cortex
 - Not visible on standard axial views
 - Coronal images most helpful
 - Use endovaginal scan if fetus in vertex presentation
 - Dorsal cyst in 25%
 - More likely in cases with thalamic fusion
 - Microcephaly
 - Face is generally normal
 - Some reported cases with cleft lip/palate
 - No hypotelorism
- Color Doppler
 - Azygos anterior cerebral artery
 - Single vessel arising from circle of Willis
 - Seen in 100% of postnatal cases

MR Findings

- Absent CSP
- Fused posterior frontal ± parietal lobes
 - May be small cortical bridge near vertex
- Abnormal corpus callosum
 - Only genu and splenium present, with absence of body
 - This pattern only reported in syntelencephaly
- Abnormal sylvian fissures

- Connected across midline over vertex creating an anomalous coronal fissure
 - 86% of postnatal cases
- Heterotopic gray matter, cortical dysplasia
 - 66-86% postnatal series
 - 71% have decreased sulcation

Imaging Recommendations

- Best imaging tool
 - Fetal MR
- Protocol advice
 - Rapid T2-weighted sequence (HASTE, SSFSE)
 - Coronal plane best to confirm interhemispheric fusion
 - Sagittal plane for characteristic abnormal corpus callosum
 - Axial plane for connection of sylvian fissures (SFs) → abnormal coronal fissure

DIFFERENTIAL DIAGNOSIS

Schizencephaly

- Absent CSP
- Complete interhemispheric fissure
- Unilateral or bilateral wedge-shaped cleft lined by gray matter
- Cleft extends from pia mater to ventricles
 - Apparent cleft in syntelencephaly is abnormal SF
 - Abnormal SF does not extend to ventricular wall
 - Bilateral, symmetric
 - SFs meet over vertex of brain without large parenchymal defects seen in bilateral open-lip schizencephaly
- Ventricular wall often "tenting" toward cleft

Semilobar Holoprosencephaly

- Absent CSP
- Anterior hemispheric fusion with incomplete interhemispheric fissure
- Posterior hemispheres separate
- Often small head size

Lobar Holoprosencephaly

- Absent CSP
- Complete interhemispheric fissure
- Neuropathologic criterion is at least 1 gyrus in continuity across midline
 - Anterior (not posterior) frontal lobe
 - Often inferior frontal, cingulosynapsis
 - May not be visible on US even on transvaginal scan
 - Requires MR for confident diagnosis

Septo-Optic Dysplasia

- Absent CSP
- Complete interhemispheric fissure
- May be associated with schizencephaly
- Gray matter heterotopia uncommon

PATHOLOGY

General Features

- Etiology
 - Embryology

Syntelencephaly vs. Holoprosencephaly

Syntelencephaly	Holoprosencephaly
Interhemispheric fissure present anteriorly and posteriorly, deficient centrally	Interhemispheric fissure intact in lobar, absent or deficient anteriorly in alobar/semilobar forms
Hemispheric fusion at posterior frontal and parietal lobes	Range of fusion from complete to minimal anterior fusion, never separate anterior hemispheres with central fusion
Characteristic callosal dysgenesis with deficient body but intact genu and splenium	Absent corpus callosum in alobar, deficient anterior/intact posterior in semilobar
Usually normal facies	Often associated with severe facial dysmorphism
Associated with 13q deletion	Associated with trisomy 13, other aneuploidies
Associated with syndactyly	Associated with polydactyly

Imaging and clinical features that help to differentiate syntelencephaly from classic holoprosencephaly.

- Neural tube closes
- Mitosis/apoptosis of embryonic roof plate → interhemispheric fissure (IHF) formation
- Faulty dorsal IHF formation results in incomplete separation of cerebral hemispheres
- Genetics
 - Mutations in **dorsal** induction genes (e.g., *ZIC2*, chromosome 13q deletions)
 - Abnormal differentiation of embryonic roof plate
 - Not associated with midline facial anomalies
 - Mutations linked to classic HPE primarily affect **ventral** induction
 - May explain associated midline facial anomalies
- Associated abnormalities
 - Broad flat nose
 - Dysmorphic facies
 - Reported association with nonmedian cleft lip/palate
 - Normal interocular distance or occasional hypertelorism
 - HPE associated with hypotelorism/cyclopia
- 86% spasticity
- 50% motor dysfunction in series of 15 children
 - 7% walk independently
 - 21% unable to sit/crawl
 - 57% speak in single words
- 47% microcephalic
- Dorsal cyst may cause macrocephaly
 - May need shunt placement to control head size
- Low incidence of endocrinopathy/choreoathetosis

Gross Pathologic & Surgical Features

- Noncleavage of midline structures in different pattern from alobar/semilobar HPE

Microscopic Features

- Callosal fibers identified anteriorly and posteriorly but missing in middle

CLINICAL ISSUES

Presentation

- Most common signs/symptoms
 - Absent CSP

Demographics

- Epidemiology
 - Rare, 1st postnatal descriptions in 1993
 - Handful of prenatal cases reported
 - Outcome information based on small series of 15-21 children

Natural History & Prognosis

- Spasticity, hypotonia, seizures, mild visual impairment, developmental delay
 - 40% seizure disorder
 - 43% feeding difficulties

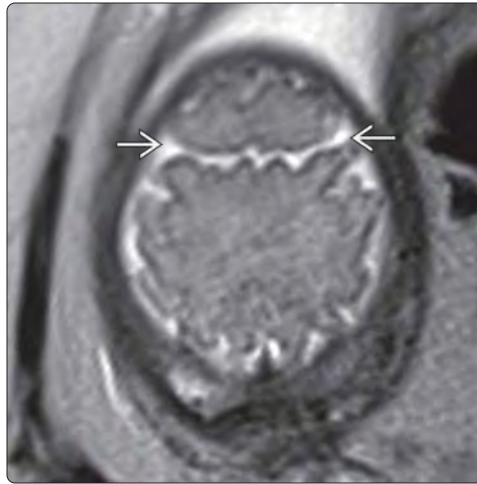
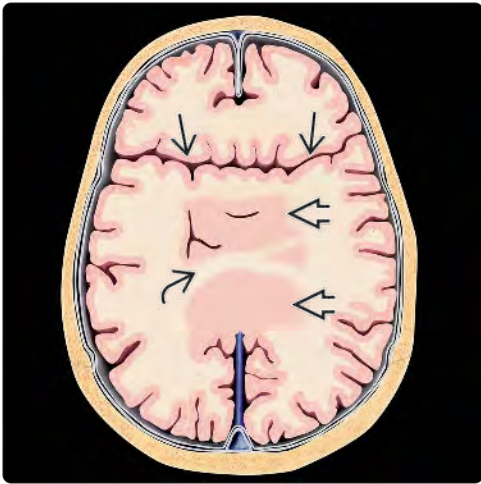
DIAGNOSTIC CHECKLIST





Image Interpretation Pearls

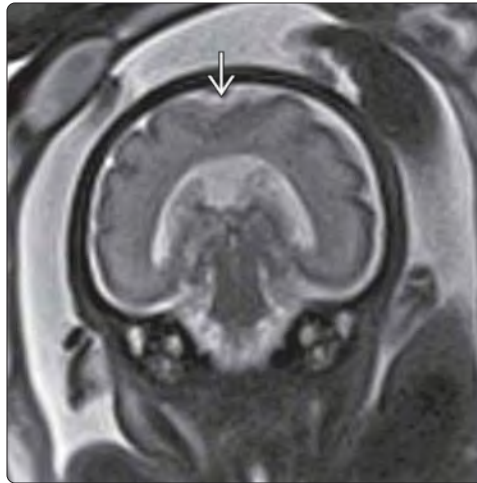
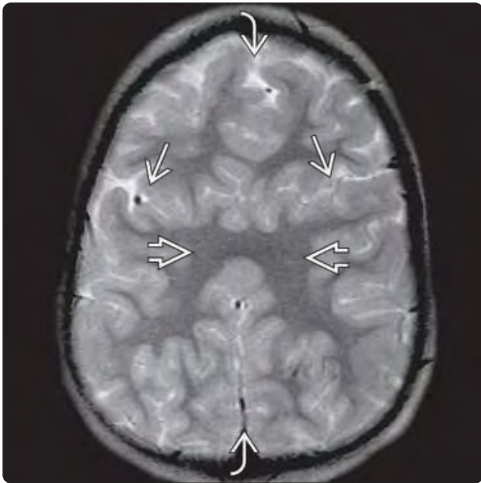
- Absent CSP is key observation
- Look for
 - Fused posterior frontal/parietal cortex
 - Normal separation of anterior frontal and occipital lobes
 - Continuous midline band of cortical tissue





SELECTED REFERENCES

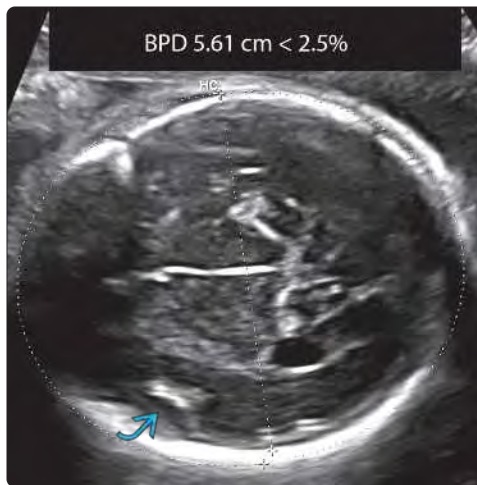
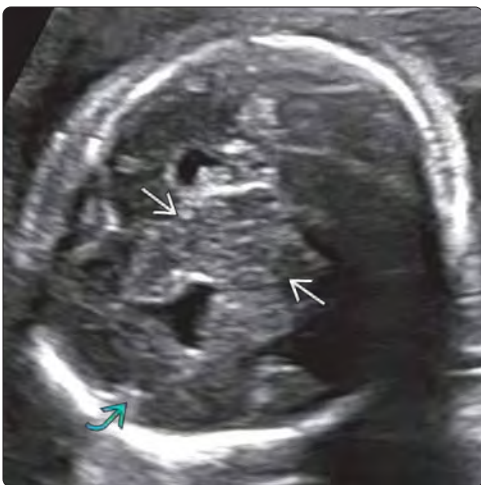
1. Winter TC et al: Holoprosencephaly: a survey of the entity, with embryology and fetal imaging. *Radiographics*. 35(1):275-90, 2015
2. Vinurel N et al: Distortion of the anterior part of the interhemispheric fissure: significance and implications for prenatal diagnosis. *Ultrasound Obstet Gynecol*. 43(3):346-52, 2014
3. Arora A et al: Teaching neuroImages: syntelencephaly: middle interhemispheric fusion. *Neurology*. 79(10):e86, 2012
4. Atalar MH et al: Middle interhemispheric variant of holoprosencephaly associated with bilateral perisylvian polymicrogyria. *Pediatr Int*. 50(2):241-4, 2008
5. Picone O et al: Prenatal diagnosis of a possible new middle interhemispheric variant of holoprosencephaly using sonographic and magnetic resonance imaging. *Ultrasound Obstet Gynecol*. 28(2):229-31, 2006
6. Pulitzer SB et al: Prenatal MR findings of the middle interhemispheric variant of holoprosencephaly. *AJNR Am J Neuroradiol*. 25(6):1034-6, 2004
7. Takanashi J et al: Middle interhemispheric variant of holoprosencephaly associated with diffuse polymicrogyria. *AJNR Am J Neuroradiol*. 24(3):394-7, 2003
8. Lewis AJ et al: Middle interhemispheric variant of holoprosencephaly: a distinct cliniconoradiologic subtype. *Neurology*. 59(12):1860-5, 2002
9. Marcorettes P et al: Unusual variant of holoprosencephaly in monosomy 13q. *Pediatr Dev Pathol*. 5(2):170-8, 2002
10. Simon EM et al: The middle interhemispheric variant of holoprosencephaly. *AJNR Am J Neuroradiol*. 23(1):151-6, 2002
11. Fujimoto S et al: Syntelencephaly associated with connected transhemispheric cleft of focal cortical dysplasia. *Pediatr Neurol*. 20(5):387-9, 1999
12. Barkovich AJ et al: Middle interhemispheric fusion: an unusual variant of holoprosencephaly. *AJNR Am J Neuroradiol*. 14(2):431-40, 1993






(Left) Axial graphic shows findings of syntelencephaly with an anomalous coronal fissure  created by the vertically oriented sylvian fissures connecting across the midline. Both gray matter  and white matter  tracts cross the midline. The gray matter appears thickened and dysplastic. Note the normal separation of the frontal and occipital lobes. **(Right)** Axial fetal MR shows similar findings with the abnormal coronal fissure  and bridging brain tissue across the midline.



(Left) Axial postnatal T2WI MR in a different case shows midline continuity of the posterior frontal and parietal lobes with an anomalous fissure  and bridging white matter tracts . Note the separation of the anterior frontal and occipital lobes . **(Right)** Coronal fetal MR shows the characteristic midline interhemispheric fusion  that is the hallmark of this condition; the anterior frontal and posterior occipital lobes were separate.



(Left) Axial US at 25 weeks in a case of syntelencephaly shows a visible anterior interhemispheric fissure  but midline fusion . No normal CSP was seen. **(Right)** Head measurement in the same case in the late 3rd trimester shows severe microcephaly with both the head circumference and biparietal diameter (BPD) measuring ~ 23 weeks in size. Brain detail is obscured by skull ossification but the anteriorly placed and abnormally shaped sylvian fissure  is still visible.

KEY FACTS

TERMINOLOGY

- Gray matter-lined cleft in brain parenchyma
 - May be either closed lip or open lip

IMAGING

- Defect of brain parenchyma extending from inner table of skull to underlying ventricle
 - Wedge-shaped configuration
 - Ventricular wall tented toward defect
 - Cavum septi pellucidi absent in 70%
- Fetal MR detects other associated anomalies
 - Mirror image migrational abnormality in contralateral hemisphere if cleft unilateral
 - Migrational anomalies
 - Heterotopia
 - Polymicrogyria

TOP DIFFERENTIAL DIAGNOSES

- Arachnoid cyst

- Porencephalic cyst
- Hydranencephaly

PATHOLOGY

- Neuronal migration anomaly
- Early prenatal vascular injury has also been implicated

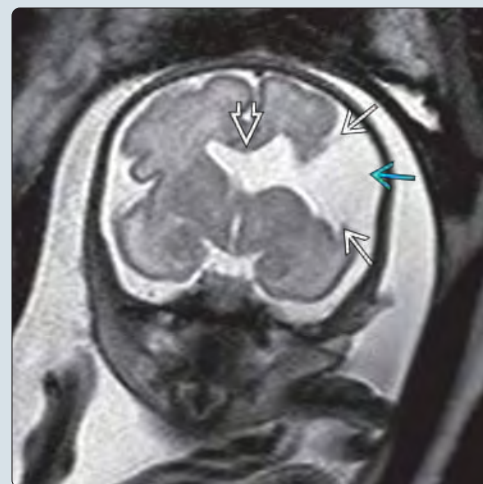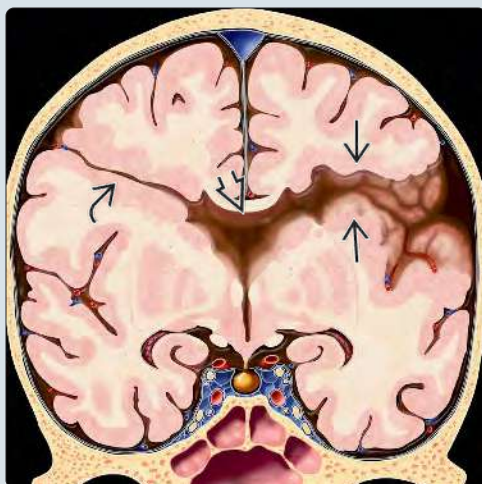
CLINICAL ISSUES

- Unilateral defect in 60%
 - If small or closed lip, neurologic deficit more mild
 - Worse if medium or large-sized cleft
- Bilateral defect in 40%
 - More severely impaired intellectual and speech development compared to unilateral

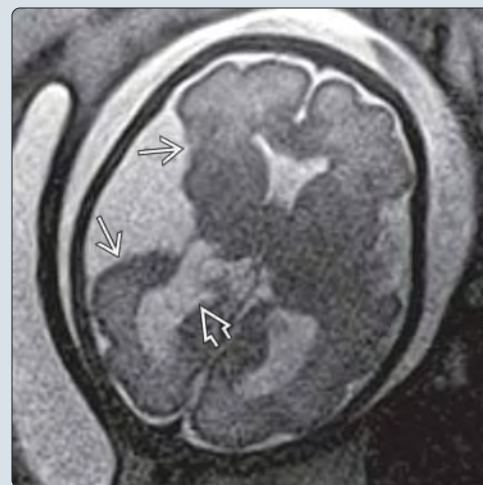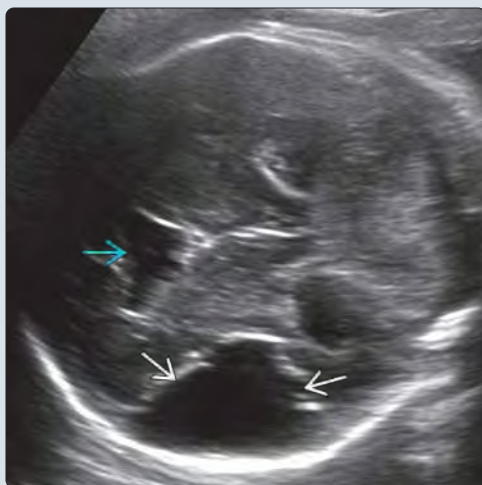
DIAGNOSTIC CHECKLIST

- If diagnosis suspected, fetal MR should be performed
- Small open-lip defects can be difficult to detect, especially in near field

(Left) Coronal graphic shows right closed-lip and left open-lip schizencephaly defects, both lined by gray matter. The cavum septi pellucidi (CSP) is absent. In schizencephaly the defect extends from the inner table of the skull to the underlying ventricle. (Right) Second-trimester coronal MR shows an absent CSP and a wedge-shaped cleft of CSF extending from the skull to the underlying left ventricle. In this case, a thin roofing membrane can be seen covering the cerebral defect.



(Left) Oblique coronal US at 31-weeks gestation shows the CSP is absent and a wedge-shaped cortical defect is present. (Right) Axial MR of the same fetus shows the full extent of the large schizencephaly defect, with low signal gray matter lining the cleft. This cleft extends into the occipital horn, which is less commonly seen.



TERMINOLOGY**Definitions**

- Gray matter-lined cleft extending from brain surface to ventricle
 - Closed lip (type 1)
 - Gray matter lips, which are in contact with each other
 - Open lip (type 2)
 - Separated gray matter lips with intervening cleft of cerebral spinal fluid (CSF)
 - CSF cleft extends to underlying ventricle

IMAGING**General Features**

- Best diagnostic clue
 - Defect of brain parenchyma extending from inner table of skull to underlying ventricle
 - Gray matter lines cleft
- Location
 - Cerebral hemispheres
 - Unilateral
 - Bilateral
 - Uncommonly occipital
 - Usually unilateral in this location
- Size
 - Any size possible, may be very large (giant open-lipped schizencephaly)
- Morphology
 - Wedge-shaped, CSF-filled defect seen in open-lip schizencephaly
 - Apex points to ventricle
 - Base at surface of brain, facing inner table of skull

Ultrasonographic Findings

- Most often will detect only open-lip type
 - Small open-lip defects can be difficult to detect especially in near field
 - Reverberation artifact obscures cleft
- Closed-lip type frequently missed
 - Beware of penetrating vascular structures
 - Echogenic linear structure in parenchyma
 - Extending from pial surface
 - May mimic closed-lip schizencephaly
- Open-lip: CSF-filled cleft extending from surface of brain to ventricle
 - Ventricular wall tented toward defect
 - Ventriculomegaly
 - Roofing membrane covering cerebral defect
 - Uncommonly identified
- Cavum septi pellucidi
 - Absent in 70%
 - Almost always absent in bilateral schizencephaly
- Associated brain developmental abnormalities
 - Heterotopia
 - Polymicrogyria
 - Pachygyria
 - Septo-optic dysplasia
 - Optic nerve hypoplasia
- Calvarium may be remodeled over open-lip defect

- Likely due to CSF pulsation originating from ventricle
- Face and profile are normal
 - Differentiates schizencephaly from holoprosencephaly

MR Findings

- Higher resolution imaging of brain parenchyma than US
- Confirms gray matter lining cleft, differentiating schizencephaly from other cystic brain lesions
- Detects other developmental anomalies
 - Heterotopic nodules follow cortical gray matter signal on all sequences
 - Subependymal: Nodular or linear areas along ventricular lining
 - Subcortical: Nodules extend from ventricular surface into hemispheric white matter
 - Pachygyria-polymicrogyria shows abnormal gyral pattern and gray-white junction
 - May be missed until postnatal MR
 - Mirror image migrational abnormality in contralateral hemisphere
 - Can be seen with unilateral schizencephaly defects
 - Gray matter aligns along where cleft would have been

DIFFERENTIAL DIAGNOSIS**Arachnoid Cyst**

- Extraaxial location
 - Mass effect on adjacent brain
 - Scalloping of inner table of skull
 - Most over convexities
 - Does not communicate with ventricle

Porencephalic Cyst

- Destructive lesion
 - Often associated with intracranial hemorrhage
- Round or irregular shape
- CSF-filled defect in brain parenchyma
- Not lined with gray matter
- May be associated with ventriculomegaly

Hydranencephaly

- Complete destruction of cerebral hemispheres
 - Preserved cerebellum and brainstem
- Replacement of supratentorial structures with CSF
- Falx present
- Absent Doppler flow
 - Middle cerebral artery
 - Anterior cerebral artery
- Small amounts of residual brain may cause confusion with bilateral, giant, open-lip schizencephaly

Other Causes of Absent Cavum

- **Agenesis of corpus callosum ± interhemispheric cyst**
 - Colpocephaly
 - Elevation of 3rd ventricle
 - Absent cingulate gyrus
 - Radial arrangement of medial sulci; sunburst pattern
 - Interhemispheric cyst is midline, displacing brain
 - Schizencephalic cleft is lateral, replacing brain
- **Septo-optic dysplasia**
 - Downward pointing frontal horns

- Flat-top or squared-off appearance of frontal horns on coronal view
- Use 3D US to image optic chiasm
- Transocular view allows measurement of optic nerve
- May be associated with schizencephaly
- **Semilobar/lobar holoprosencephaly**
 - Variable fusion of anterior brain
 - Fused frontal lobes to single anterior gyrus continuing across midline
 - May see fused fornices running anterior to posterior in 3rd ventricle
 - Abnormal anterior corpus callosum
 - Deficient anterior falx
 - May be associated with facial anomalies
- **Syntelencephaly**
 - Midline continuity of posterior frontal/parietal lobes
 - Normal separation of frontal, occipital lobes
 - Azygos anterior cerebral artery

PATHOLOGY

General Features

- Etiology
 - Neuronal migration anomaly
 - Final common pathway for several possible etiologies
 - Most likely primary malformation from abnormal neuronal migration
 - Could also be related to early vascular injury
 - Early prenatal injury has also been implicated
 - Drug abuse
 - Maternal abdominal trauma
 - Infection (CMV)
- Genetics
 - Most felt to be sporadic
 - Familial schizencephaly has been reported
 - Was thought to be associated with heterozygous mutations of *EMX2* gene
 - Normally expressed in germinal matrix
 - Not verified in current literature

Gross Pathologic & Surgical Features

- Gray matter-lined cleft extending from brain pial surface to ependymal lining of ventricle
 - Cleft lining is dysplastic gray matter
 - Abnormal cortical lamination
- Most often found near precentral and postcentral gyri
- Associated migrational anomalies
 - Polymicrogyria
 - Pachygyria

CLINICAL ISSUES

Presentation

- Prenatal
 - Most often incidental finding on screening 2nd-trimester US
 - Can be difficult to detect until 3rd trimester for small unilateral defects
- Postnatal
 - Seizures

- Severity of seizures not related to size or extent of defect
- Developmental delay
 - Severity correlates with extent of defect
- Intellectual impairment
 - Severity correlates with extent of defect
- Motor impairment
 - Severity correlates with extent of defect
 - Symptoms usually minimal if motor cortex not involved
- Blindness
 - Optic nerve hypoplasia
 - Up to 1/3 of patients with schizencephaly

Natural History & Prognosis

- Unilateral defect in 60%
 - If small or closed lip, neurologic deficit is more mild
 - Worse if medium or large in size
 - Late-onset seizure disorder
 - Drug-resistant epilepsy
 - Compatible with long lifespan
- Bilateral defect in 40%
 - Severe neurologic impairment
 - Worse intellectual and speech development compared to unilateral
 - Often have less tendency for seizures
 - If epileptic, not drug resistant

Treatment

- No prenatal treatment
- Termination may be offered
- Postnatal treatment for seizures

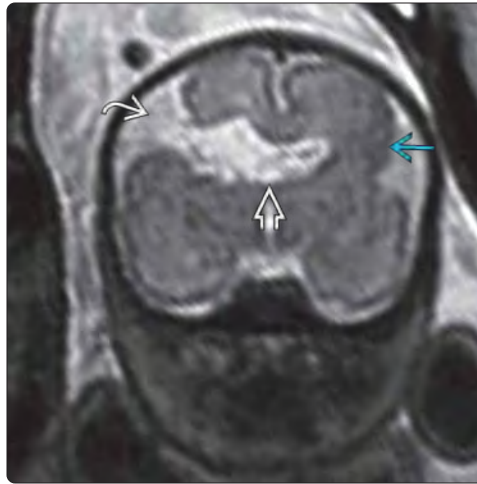
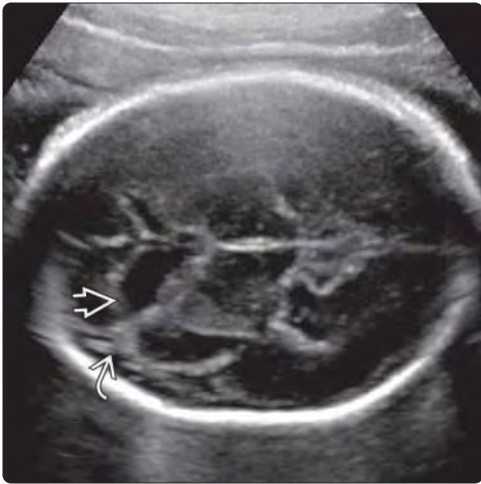DIAGNOSTIC CHECKLIST

Image Interpretation Pearls

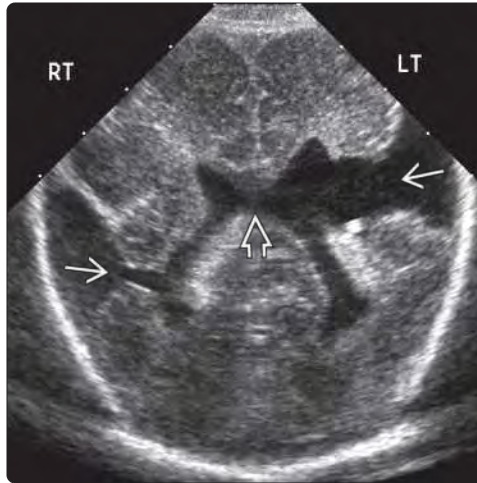
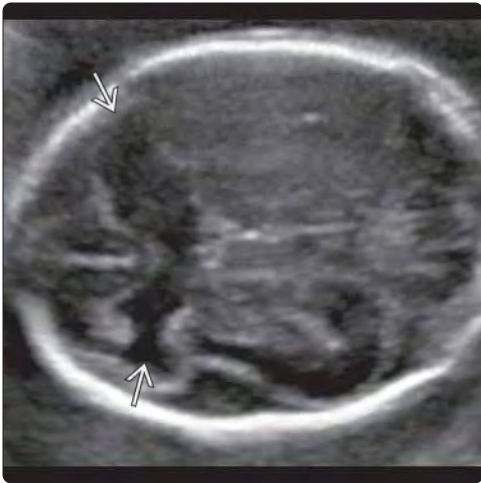
- If diagnosis suspected, fetal MR should be performed
 - Confirms diagnosis with demonstration of gray matter lining cleft
- US may miss small defect
 - Defect in near field may not be seen
 - Reverberation artifact can obscure finding
- Bilateral defects have worse clinical outcome than unilateral

SELECTED REFERENCES

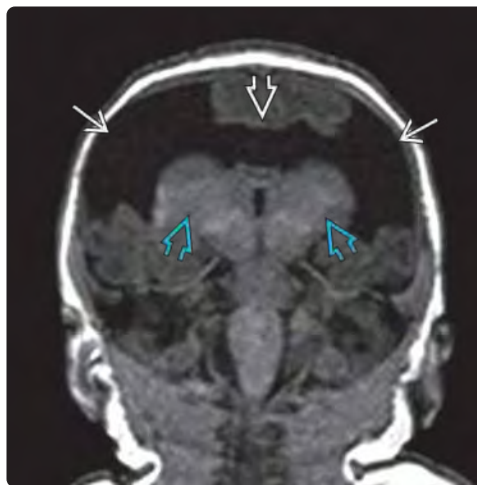
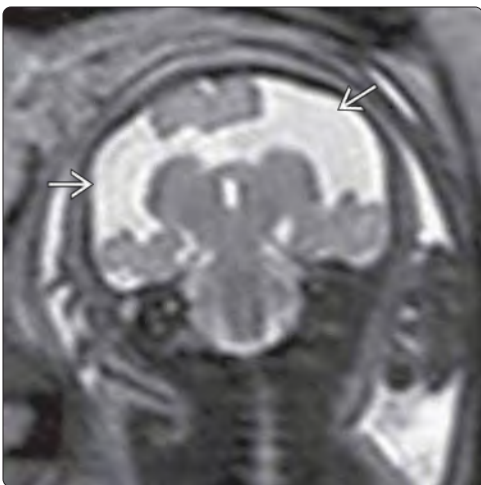1. Halabuda A et al: Schizencephaly-diagnostics and clinical dilemmas. *Childs Nerv Syst.* 31(4):551-6, 2015
2. Kutuk MS et al: Prenatal diagnosis and postnatal outcome of schizencephaly. *J Child Neurol.* 30(10):1388-94, 2014
3. Nabavizadeh SA et al: Correlation of prenatal and postnatal MRI findings in schizencephaly. *AJNR Am J Neuroradiol.* 35(7):1418-24, 2014
4. Dies KA et al: Schizencephaly: association with young maternal age, alcohol use, and lack of prenatal care. *J Child Neurol.* 28(2):198-203, 2013
5. Gedikbasi A et al: Prenatal diagnosis of schizencephaly with 2D-3D sonography and MRI. *J Clin Ultrasound.* 37(8):467-70, 2009
6. Lee W et al: Prenatal diagnostic challenges and pitfalls for schizencephaly. *J Ultrasound Med.* 28(10):1379-84, 2009
7. Oh KY et al: Fetal schizencephaly: pre- and postnatal imaging with a review of the clinical manifestations. *Radiographics.* 25(3):647-57, 2005



(Left) At 28 weeks, the cleft lined in gray matter in smaller schizencephaly defects can be subtle on US. However, tenting of the adjacent ventricle can be a clue that a cleft is present. (Right) Coronal fetal MR at 32 weeks shows the absent CSP and right open-lip cleft. There is also a subtle left closed-lip schizencephaly with gray matter and CSF extending to the ventricle on sequential images. Defects are bilateral in 40% of patients and areas of heterotopia or migrational abnormalities can be present at the cleft.



(Left) Axial US at 22-weeks gestation shows bilateral schizencephaly clefts extending into the anterior portions of the lateral ventricles. Open-lip defects are more likely to be detected in utero compared to closed lip. (Right) Coronal neonatal head US shows an absent CSP with bilateral schizencephaly, larger on the left. Schizencephaly defects are bilateral in ~ 40% of cases.



(Left) Large bilateral defects are present on fetal MR, consistent with giant open-lip schizencephaly. (Right) Postnatal imaging confirms the giant open-lip defects and absent CSP. There is also microcephaly. Note the thalami are not fused, as would be seen with alobar holoprosencephaly. Bilateral defects, especially when this large, cause severe neurologic impairment.

KEY FACTS

TERMINOLOGY

- Lissencephaly is abnormally smooth brain surface; it can be isolated or part of specific syndrome

IMAGING

- Remember to use multiple scan planes as fissures are best seen when beam is perpendicular
- Use transvaginal US if fetus is in cephalic presentation
- Gyri and sulci appear in progressive sequence at predictable gestational age
- Identifiable sulci
 - Medial hemispheric surface: Parietooccipital, calcarine, cingulate sulci
 - Lateral hemispheric surface: Central, postcentral, superior temporal sulci
- Temporal lobe asymmetry is normal

TOP DIFFERENTIAL DIAGNOSES

- Incorrect dates




- Hydrocephalus of any cause may obscure sulcal development

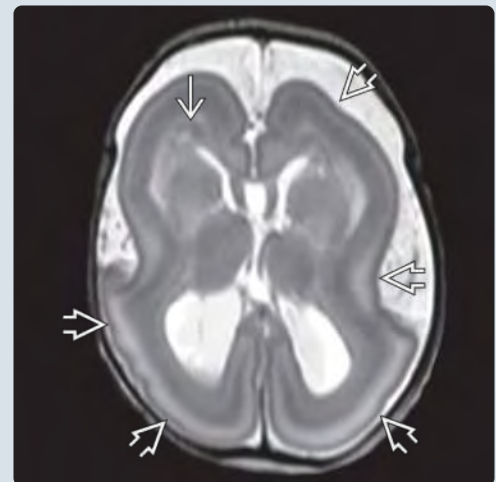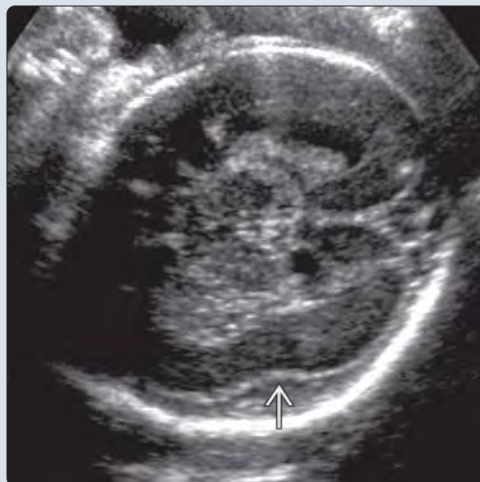
CLINICAL ISSUES




- Miller-Dieker syndrome has universally poor outcome
- Walker-Warburg syndrome often fatal in 1st year of life
- Outcome in nonsyndromic lissencephaly
 - Failure to thrive
 - Developmental delay, severe psychomotor retardation
 - Seizures

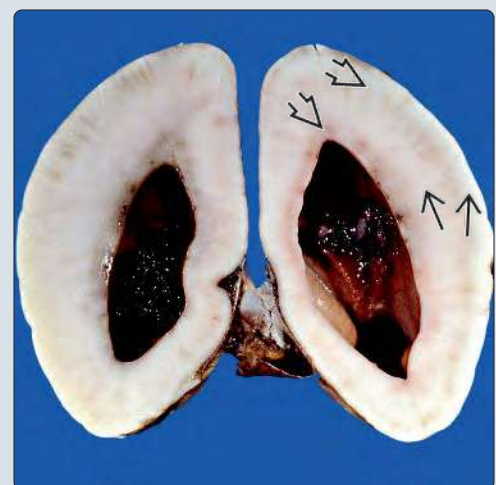
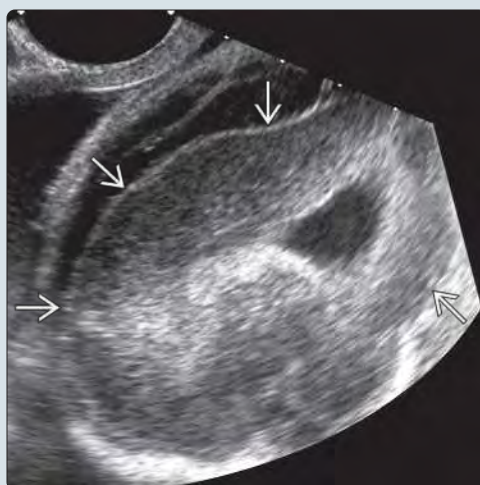
DIAGNOSTIC CHECKLIST

- Do not suggest delayed cortical development before 20 weeks of gestation
- Sylvian fissure should be easily seen on late 2nd- and 3rd-trimester scans
 - If not visible, perform more detailed evaluation

(Left) This patient was transferred with unexplained polyhydramnios. Evaluation of the brain shows it is abnormally smooth for 31-week gestation. The sylvian fissure  is barely evident. The fetus also had micrognathia. Polyhydramnios could have been caused by micrognathia, neurologic impairment, or both. **(Right)** Postnatal MR in the same case confirms lissencephaly  and shows cortical heterotopia . Micrognathia was due to Pierre Robin syndrome.



(Left) Transvaginal US imaging allows exquisite visualization of the brain when the fetus is in cephalic presentation. The brain surface is completely smooth , which is abnormal at 28 weeks. Lissencephaly was confirmed on postnatal examination. **(Right)** Posterior coronal section through the brain shows dilated ventricles and a complete lack of sulcation. There are alternating bands of gray  and white  matter creating the thick, 4-layer cortex seen in lissencephaly. (From Osborn's Brain.)



TERMINOLOGY

Definitions

- **Lissencephaly:** Abnormally smooth brain surface; isolated or as part of specific syndrome
 - **Agyria:** Most severe form with no gyri on brain surface, thick cortex
 - **Pachygyria:** Abnormally broad, flattened gyri, thick cortex
 - **Polymicrogyria:** Many small gyri
 - **Cobblestone lissencephaly:** Fine, diffusely nodular, cortical surface due to neuronal overmigration
 - **Subcortical band heterotopia:** Layer of heterotopic gray matter embedded in subcortical white matter

IMAGING

Ultrasonographic Findings

- Failure to reach normal cortical developmental milestones
- Mild ventriculomegaly may be presenting feature
- Abnormal head size or shape
- **Walker-Warburg syndrome:** Hydrocephalus, agenesis/dysgenesis of corpus callosum, may have microphthalmia/anophthalmia
- **Miller-Dieker syndrome:** Congenital heart defects, growth restriction, facial dysmorphism

MR Findings

- Ganglionic eminence (GE) (germinal matrix) cavitation described as sign of halted brain development
 - Bilateral, symmetric, high-signal cavities in GE, which is often larger than age-related controls
 - Lack of associated signs of hemorrhage indicate malformation rather than destruction
 - Association with abnormal corpus callosum in series of 5 cases
- Z-shaped brainstem, cerebellar hypoplasia, and eye anomalies associated with Walker-Warburg syndrome
- Temporal lobe asymmetry is normal
 - Right lobe matures before left → L-shaped right lobe, C-shaped left lobe
 - **Absence** of this pattern can be used to identify lissencephaly while brain surface is still relatively smooth

Imaging Recommendations

- US is useful for evaluation of primary sulci
 - Medial hemispheric surface: Parietooccipital, calcarine, cingulate sulci
 - Lateral convex hemispheric surface: Central, postcentral, superior temporal sulci
 - Developing sulci change in appearance
 - Earliest sign is small dot or dimple on brain surface
 - Next, V-shaped indentation forms
 - Indentation deepens → surface notch with echogenic, Y-shaped line extending into brain
 - Sylvian fissure
 - Gentle depression deepens to box with obtuse angle between insular cortex and temporal lobe
 - By 32-week temporal lobe should override posterior half of insula
- Use multiple scan planes as fissures are best seen when beam is perpendicular

- Calcarine sulcus, cingulate gyrus best seen on coronal view
- Sylvian fissure, parietooccipital sulcus well seen on axial view
- Central, precentral, postcentral sulci well seen on sagittal view
- 3D volume acquisition helpful for accurate rendering of orthogonal planes
- Use transvaginal US if fetus is in cephalic presentation
- Fetal MR can be performed with any fetal position and is less compromised by maternal habitus

DIFFERENTIAL DIAGNOSIS

Incorrect Dates

- Correct gestational age imperative in order to confirm appropriate gyral and sulcal formation
- Look at ossification centers in 3rd trimester if no early scans to establish dates
 - Distal femoral present by ~ 32 weeks
 - Proximal tibial present by ~ 35 weeks
 - Proximal humeral present by ~ 38 weeks

Other Brain Malformations

- Hydrocephalus → marked cortical thinning → obscured visualization of sulcal pattern
- Ischemia, encephalitis, intracranial hemorrhage may distort/disrupt cortical development

PATHOLOGY

General Features

- Etiology
 - Abnormal neuronal migration (during 3rd and 4th months of gestation)
 - Single gene disorders, inborn errors of metabolism, hypoxia
 - Maternal disorders, teratogen exposure
- Genetics
 - Cobblestone cortical malformation (lissencephaly type 2)
 - About 1/2 have mutations in *POMT1*, *POMT2*, *POMGNT1*, *FKTN*, *FKRP*, *LARGE*
 - Miller-Dieker syndrome
 - 17p13.3 mutations in *LIS1* (also called *PAFAH1B1*), *YWHAE*, *CRK* genes and possibly others
 - X-linked lissencephaly: *DCX* (a.k.a. *XLIS*) mutation at Xq22.3-q23
 - Lissencephaly with ambiguous genitalia: *ARX* gene mutation at Xp22.13
 - Isolated lissencephaly syndrome (i.e., no major congenital anomalies or dysmorphic features)
 - 65% have deletions or mutations in *LIS1* (also called *PAFAH1B1*)
 - 10% *DCX* (also known as *XLIS*) mutations
 - Large number of mutations in *TUBA1A* have been discovered in lissencephaly patients
 - Tubulin gene defects in *TUBB2B*, *TUBB3*, *TUBB5*, *TUBA8*, *TUBG1* are associated with polymicrogyria, pachygyria, congenital microcephaly
 - Homozygous mutations in *NDE1* cause microlissencephaly

Gestational Age Milestones for Sulcation

Structure	US (Cohen-Sacher et al)	MR (Ghia et al)
Callosal sulcus	18	22
Sylvian fissure	18	24
Parietooccipital fissure	20	22-23
Calcarine fissure	22	22-23
Cingulate sulcus	24	28-29
Central sulcus	28	26-27
Convexity sulci	28	28-29

Sulci were visible on transvaginal ultrasound in > 75% of brains by the stated gestational age. The MR dates are those by which the sulci should always be seen (i.e., often seen earlier, but if not seen by the stated GA, there is a cortical abnormality). In general, medial sulci are seen before lateral sulci, and the appearance on all imaging modalities lags behind the time of appearance based on anatomical descriptions by several weeks.

Classification Systems

- Traditional
 - **Type I or classic lissencephaly**
 - Many neurons fail to reach cortical plate
 - Normal, 6-layer cortex replaced by abnormal, thick, remodeled, 4-layer cortex with variable degrees of severity
 - Diffuse agyria
 - Mixed agyria and pachygyria
 - Pachygyria only
 - Subcortical band heterotopia
 - **Type II**
 - Characterized by disorganized, unlayered cortex
 - Many neurons move too far into subpial space → cobblestone complex
 - Associated with congenital muscular dystrophy
 - Walker-Warburg syndrome
 - Muscle-eye-brain disease
 - Fukuyama-type congenital muscular dystrophy
- **Barkovich 2001** classification of cortical maldevelopment
 - Group A: Lissencephaly: Subcortical band heterotopia spectrum
 - Classic lissencephaly (type I)
 - Lissencephaly with agenesis of corpus callosum
 - Lissencephaly with cerebellar hypoplasia
 - Lissencephaly not yet classified
 - Group B: Cobblestone complex (type II)
 - Group C: Heterotopias other than subcortical band heterotopia

CLINICAL ISSUES

Demographics

- Rare: Prevalence estimated 11.7-40.0 per million live births

Natural History & Prognosis

- Severe psychomotor retardation, developmental delay, seizures, failure to thrive
 - Prognosis depends on degree of failure of cortical development
 - In severe cases, death occurs in infancy or early childhood
- Walker-Warburg syndrome: Fatal in 1st year of life
 - Congenital hydrocephalus → progressive macrocephaly

- Cobblestone lissencephaly → hypotonia, no psychomotor development
- Ocular anomalies
- X-linked lissencephaly ambiguous genitalia syndrome causes neonatal-onset severe epilepsy
- Miller-Dieker syndrome has universally poor outcome
- Overall prognosis for cortical dysplasia is difficult to forecast due to poor correlation between phenotypic, genotype, and clinical expression

Treatment

- Parents of Miller-Dieker fetuses should be offered chromosomal analysis to rule out chromosomal rearrangements
- If mutation is known to be present, early prenatal diagnosis can be achieved with DNA analysis
- Offer termination if available at gestational age at diagnosis

DIAGNOSTIC CHECKLIST

Image Interpretation Pearls

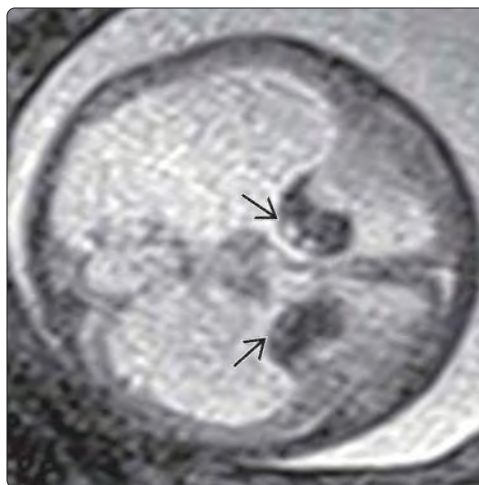
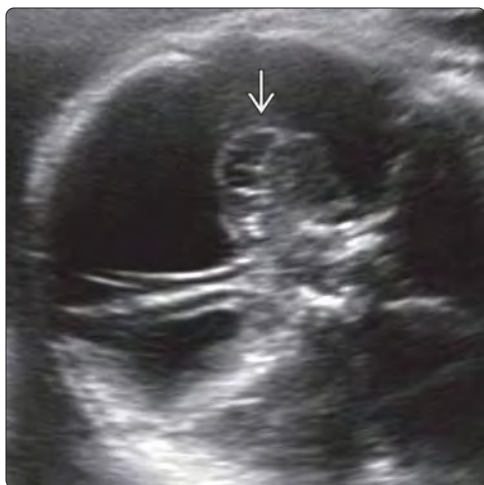
- Check for normal development of sylvian fissure on late 2nd- and 3rd-trimester scans
 - Seen on standard obstetric scan planes; if not visible, look again and consider additional scan planes
 - After 23 weeks, specific gyri and sulci should be present
- If cavum septi pellucidi absent, look at sulcation carefully



Reporting Tips

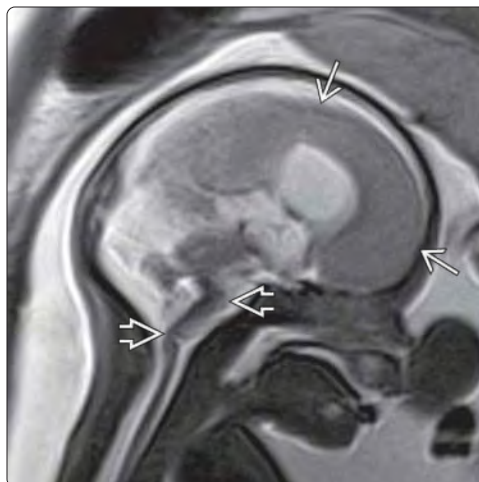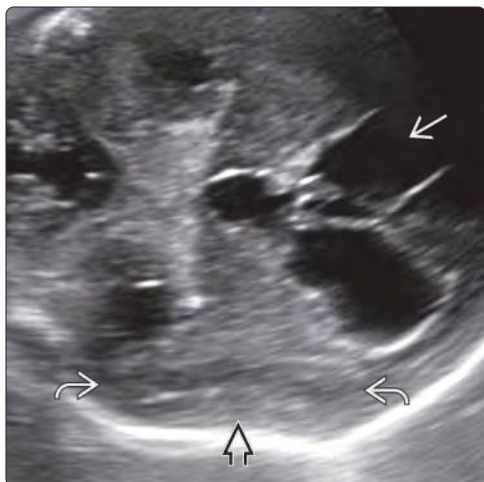
- Cerebral fissures and sulci appear in progressive sequence on prenatal US and MR images
 - Allows estimation of extent of fetal brain maturation
- Primary sulci are indentations that appear on brain surface
 - Secondary and tertiary sulci are ramifications of primary sulci and appear at later stage of development
- Do not suggest delayed cortical development before 20 weeks of gestation






SELECTED REFERENCES

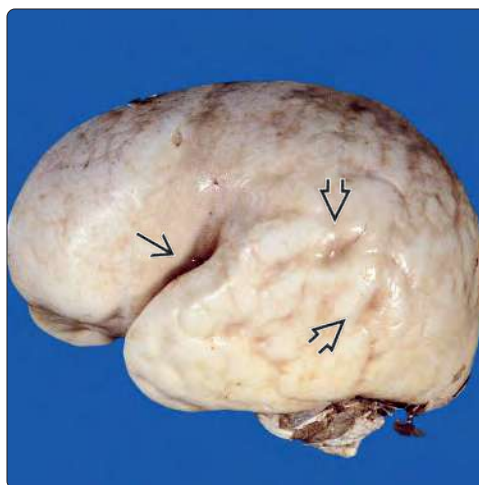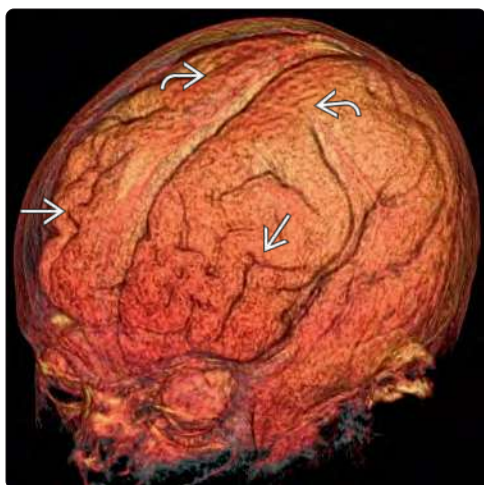
1. Viñals F et al: Anterior and posterior complex: A step forward towards improving neurosonographic screening of midline and cortical anomalies. *Ultrasound Obstet Gynecol.* 46(5):585-94, 2014
2. Righini A et al: Bilateral cavitations of ganglionic eminence: a fetal MR imaging sign of halted brain development. *AJNR Am J Neuroradiol.* 34(9):1841-5, 2013







(Left) Axial US in a fetus with AVID (asymmetric ventriculomegaly, interhemispheric cyst, dysgenesis of the corpus callosum) shows cavitation of the germinal matrix . This is a sign of arrested brain development described in fetuses with lissencephaly and callosal malformations. **(Right)** T2WI MR in the same fetus shows cavitation of the germinal matrix (ganglionic eminence) , which is often more prominent than in age-matched controls. This is thought to be due to arrested neuronal migration.



(Left) Axial US in a different case at 30 weeks shows abnormal echotexture of the brain with ventriculomegaly , a layered appearance to the cerebral mantle , and no sylvian fissure formation . **(Right)** Sagittal T2WI MR in the same fetus confirms abnormally smooth cortex  with no gyral or sulcal formation and an abnormal Z-shaped brainstem . Initially described in Walker-Warburg syndrome, this configuration can be seen in other conditions. It confers a very poor prognosis.



(Left) Anterosuperior perspective of a volume-rendered surface-shaded reconstruction shows relative preservation of sulcation anteriorly  with many fewer cortical sulci over the vertex further posteriorly . Lissencephaly can be graded based on the pattern of sulcation. (From Pediatric Neuro.) **(Right)** Autopsy image of a lissencephalic brain shows a shallow sylvian fissure  and near-complete lack of sulcation. A few shallow surface indentations  are present posteriorly. (From Osborn's Brain.)

KEY FACTS

TERMINOLOGY

- Abnormal location of nerve cells (in nodular or laminar distribution) in areas other than cortex

IMAGING

- Mild ventriculomegaly
- Nodular appearance to walls of lateral ventricles on US
 - Dot-dash ependyma
- Heterotopic nodules follow cortical gray matter signal on all MR sequences
- Patterns of involvement
 - Asymmetric, few nodules, involve trigone/temporal and occipital horns
 - Multiple nodules essentially lining walls of lateral ventricle
 - Rare descriptions of smooth, linear bands lining walls of ventricles
- Look for heterotopia with any other brain malformation

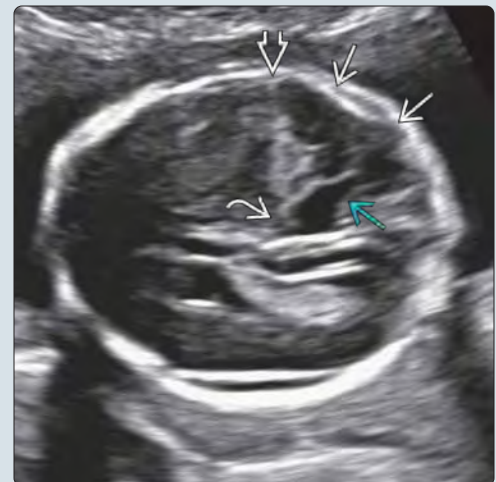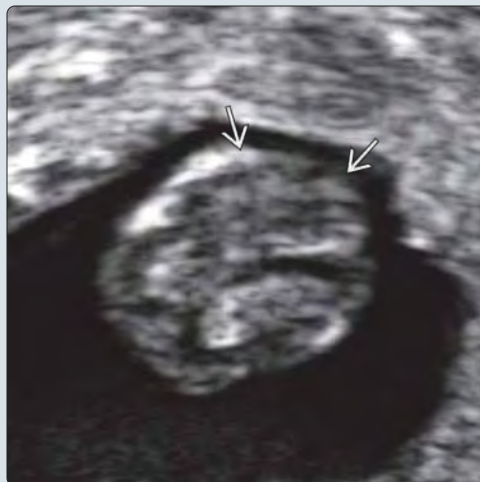
TOP DIFFERENTIAL DIAGNOSES

- Tuberous sclerosis
 - Tubers do not follow gray matter signal on MR
- Intracranial hemorrhage
 - Look for clot at caudothalamic groove, intraventricular blood
- Infection
 - Often associated with sick fetus; hydrops, growth restriction

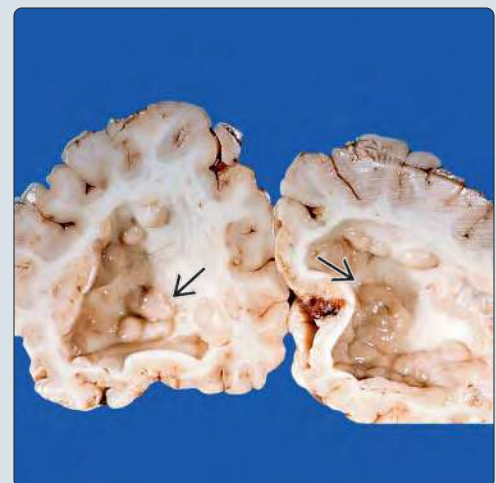
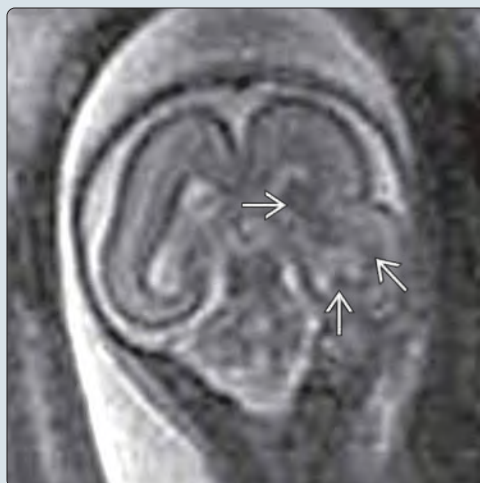DIAGNOSTIC CHECKLIST

- Cortical dysplasia can be quite subtle; descriptions are based on postnatal studies, which are less compromised by movement and are performed with several sequences not typically used in fetal MR
- Always check for associated cortical dysplasia in fetuses with obvious brain abnormality, such as agenesis of corpus callosum

(Left) US imaging in the 1st trimester shows a disorganized posterior hemisphere with loss of the normal butterfly appearance. The nuchal translucency measurement was within the normal range at 1.3 mm. **(Right)** Follow-up axial US at 22 weeks confirms an abnormal posterior left cerebral hemisphere with disorganized cortex, possible closed-lip schizencephaly, abnormal contour of the ipsilateral ventricle, and a subependymal nodule.



(Left) Follow-up T2WI MR at 23.5 weeks shows asymmetric, low signal gray matter lining the left ventricle. Other scan planes confirmed schizencephaly and showed additional polymicrogyria. The pregnancy was terminated but autopsy was declined. This case illustrates the importance of looking at all of the visible anatomy at the time of nuchal translucency screening. **(Right)** Autopsy image shows nodular subependymal heterotopic gray matter with ventriculomegaly and thin cortex. (From Osborn's Brain.)



TERMINOLOGY

Definitions

- Abnormal location of nerve cells (in nodular or laminar distribution) in areas other than cortex
 - Subependymal: Nodular or linear areas along ventricular lining
 - Subcortical: Nodules extend from ventricular surface into hemispheric white matter
 - Band: Layer of gray matter between ventricles and cortex (a.k.a. double cortex)

IMAGING

Ultrasonographic Findings

- Mild ventriculomegaly
 - Nodular appearance to walls of lateral ventricles on US
 - Dot-dash ependyma
- Often associated with other brain malformations

MR Findings

- Heterotopic nodules follow cortical gray matter signal on all sequences, seen as early as 20 weeks
 - Smooth, ovoid shape with long axis parallel to ventricular wall
- Patterns described on postnatal imaging
 - Asymmetric distribution
 - Few to multiple nodules essentially lining walls of lateral ventricle
 - Most common in trigone/temporal and occipital horns

DIFFERENTIAL DIAGNOSIS

Tuberous Sclerosis

- Tubers irregular in shape
- Long axis perpendicular to ventricular wall
- Do not follow gray matter signal on MR

Intracranial Hemorrhage

- May cause thick, nodular echogenic ependyma
- Look for clot at caudothalamic groove, intraventricular blood
- May be associated with parenchymal destruction

Infection

- Cytomegalovirus infection in particular may actually cause abnormal neuronal migration
- Often associated with sick fetus; hydrops, growth restriction

PATHOLOGY

General Features

- Etiology
 - Arrested radial neuronal migration
- Genetics
 - X-lined and autosomal dominant pattern inheritance described
 - *FLN1* mutation at Xq28, *FLNA* (perinatal lethal in males)
 - *LIS1* 17p13.3, *ARGF2*, *DCX* on Xq22.3-q23
- Associated abnormalities

- In series of children with MR (performed for developmental delay, seizures etc.)
 - Abnormal corpus callosum (25%)
 - Schizencephaly (20%)
 - Absent cavum septi pellucidi (20%)
 - Arachnoid cyst (20%)
 - Pachygyria (10%)
 - Chiari 2 malformation (10%)
- Often multiple findings in single patient
- Agenesis of corpus callosum and heterotopia are associated with constitutional mismatch repair deficiency (CMMR-D) syndrome
 - Childhood cancer predisposition syndrome
 - Biallelic germline mutations in 1 of 4 mismatch repair genes *MLH1*, *MSH2*, *MSH6*, *PMS2*

CLINICAL ISSUES

Natural History & Prognosis

- Series of children diagnosed with heterotopia had clinical symptoms of
 - Developmental delay (27%)
 - Hemiparesis (27%)
 - Seizures (23%)
 - Autism, emotional disturbances (11%)
- Syndromic heterotopia may result in severe intellectual impairment with prognosis determined by associated malformations
- Subcortical heterotopia: Majority develop seizure disorder
 - Bilateral large areas → moderate to severe developmental delay
 - Unilateral → hemiplegia with less developmental delay

DIAGNOSTIC CHECKLIST

Consider

- Cortical dysplasia can be quite subtle; descriptions are based on postnatal studies, which are less compromised by movement and are performed with several sequences not typically used in fetal MR
- Cortical malformations account for ~ 40% of drug-resistant epilepsy

Image Interpretation Pearls

- Always check for associated cortical dysplasia in fetuses with obvious brain abnormality, such as agenesis of corpus callosum
 - Subependymal heterotopias are most common around body/occipital horns of lateral ventricles
 - Subcortical heterotopias most common in frontoparietal areas

SELECTED REFERENCES

1. Watrin F et al: Causes and consequences of gray matter heterotopia. *CNS Neurosci Ther*. 21(2):112-22, 2015
2. Zając-Mnich M et al: Clinical and morphological aspects of gray matter heterotopia type developmental malformations. *Pol J Radiol*. 79:502-7, 2014
3. Baas AF et al: Agenesis of the corpus callosum and gray matter heterotopia in three patients with constitutional mismatch repair deficiency syndrome. *Eur J Hum Genet*. 21(1):55-61, 2013
4. Manganaro L et al: Bilateral subependymal heterotopia, ventriculomegaly and cerebellar asymmetry: fetal MRI findings of a rare association of brain anomalies. *J Radiol Case Rep*. 7(11):38-45, 2013

KEY FACTS

TERMINOLOGY

- Pachygyria: Broad, flattened gyri; thickened cortex
- Polymicrogyria: Many small gyri
- Pachygyria and polygyria often occur together

IMAGING

- Distortion of normal gyral/sulcal formation; seen in 3rd trimester
- Most often seen in fetus as part of complex brain malformation
- Pachygyria
 - Flatter, broader lumpy shape to gyri compared to normal
- Polymicrogyria (PMG)
 - Fine sawtooth or zigzag appearance to cortex

TOP DIFFERENTIAL DIAGNOSES





- Lissencephaly syndromes
- Congenital CMV infection

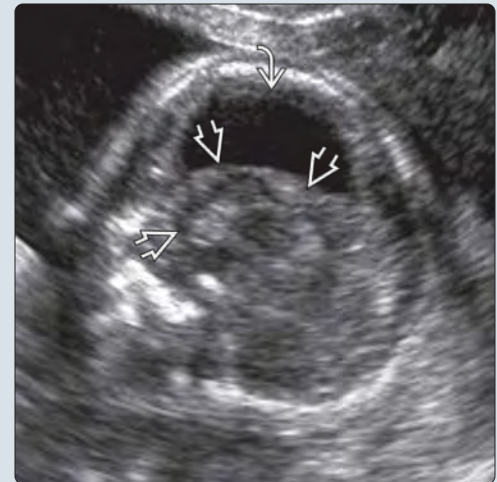
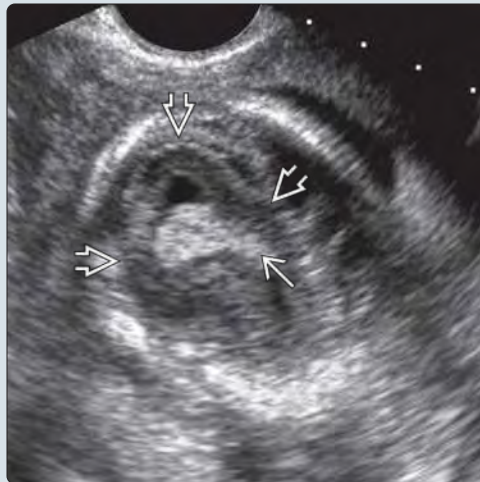
CLINICAL ISSUES








- PMG accounts for ~ 20% of cortical development malformations
- Cortical malformations may or may not be associated with severe neurologic symptoms
 - Depends on location/extent of cortical defects
 - Presence of additional brain malformations
- Confer worse prognosis if seen in conjunction with other abnormalities (e.g., agenesis of corpus callosum)
- Deliver at tertiary center for availability of subspecialists
 - Many syndromes have autosomal recessive inheritance and therefore carry 25% recurrence risk for each subsequent pregnancy
 - Recurrence risk cannot be assessed without accurate diagnosis

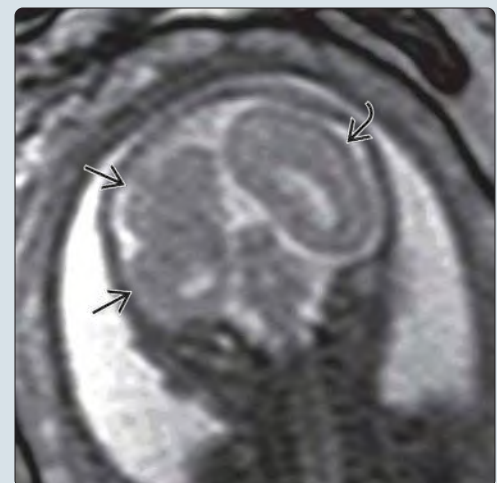
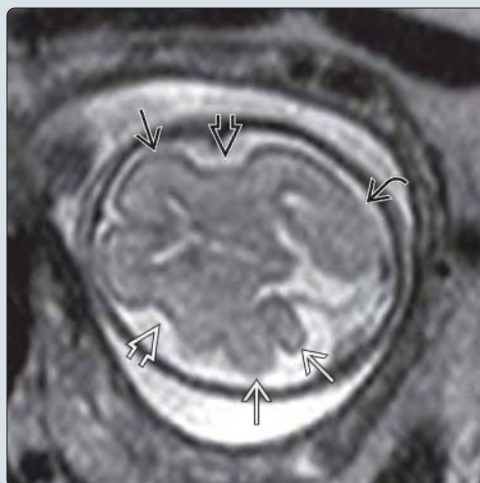DIAGNOSTIC CHECKLIST

- PMG is probably common endpoint of variety of aberrations of cortical development

(Left) Sagittal transvaginal ultrasound at 22-weeks gestation was performed to better evaluate an intracranial lucency seen transabdominally at 18 weeks. The choroid plexus  and smooth left cerebral hemisphere  are well seen. **(Right)** Sagittal transvaginal ultrasound through the right cerebral hemisphere in the same case shows disorganized cortex in the occipital lobe  and a crescentic extraaxial CSF space  without mass effect.



(Left) Axial T2WI MR in the same case shows the normal left frontal lobe  sylvian fissure  and occipital lobe . The right sylvian fissure  is abnormal and there is adjacent pachygyria  with increased surrounding CSF space. **(Right)** Coronal T2WI MR in the same case again shows the asymmetry between the hemispheres. The left posterior cortex is smoothly margined (normal for gestational age) , whereas there are broad shallow gyri  on the right.



TERMINOLOGY

Definitions

- **Pachygyria:** Broad, flattened appearance to compared to normal gyri, thickened cortex
- **Polymicrogyria:** Many small gyri (multiple, excessive small convolutions)
- Pachygyria and polygyria often occur together

IMAGING

Ultrasonographic Findings

- Distortion of normal gyral/sulcal formation; seen in 3rd trimester
 - Large, lumpy, thick gyri instead of normal appearance with pachygyria
 - Serrated appearance to cortex with polymicrogyria (PMG)
- Most often seen in association with other brain abnormalities

MR Findings

- **Pachygyria**
 - Flatter, broader shape to gyri than normal, thick cortex
- **Polymicrogyria**
 - Initially irregular cortex progressing to too many infoldings of cerebral surface
 - Fine sawtooth or zigzag appearance to cortex

DIFFERENTIAL DIAGNOSIS

Lissencephaly Syndromes

- Cobblestone lissencephaly results in fine nodular brain surface
 - Look for associated ocular findings in Walker-Warburg syndrome
 - Persistent hyperplastic primary vitreous, retinal detachment in 3rd trimester

Congenital Infection

- Cytomegalovirus (CMV) infection associated with abnormal neuronal migration
 - CMV inclusion bodies may only be seen in brain; not in other tissues (e.g., kidneys)
 - Look for associated hepatosplenomegaly, cardiomegaly, hydrops, growth restriction ± abnormal amniotic fluid volume

PATHOLOGY

General Features

- Etiology
 - Metabolic disorders: Zellweger syndrome, congenital disorders of glycosylation, mitochondrial diseases such as Leigh disease and PDH deficiency
 - Infection: CMV, toxoplasmosis, parvovirus
 - Ischemia, teratogens
- Genetics
 - Pachygyria
 - X-linked most marked in posterior frontal lobes
 - Focal (bilateral, posterior) seen with 17p13.3 mutation
 - Polymicrogyria

- Mutations of *OCLN, ALX4, MSX2, GNAQ, GPR56, WDR62, EOMES*
- Mutations in *LAMC3* and *GPR56* genes associated with PMG but also overlap with cobblestone lissencephaly
 - Single genetic cause may result in variable PMG patterns
 - Single PMG syndrome may have multiple genetic causes
- Associated abnormalities
 - Callosal dysgenesis/agenesis
 - Cerebellar hypoplasia

Gross Pathologic & Surgical Features

- Pachygyria: Smooth cortical white matter junction
- Polymicrogyria: Irregular cortical white matter junction

CLINICAL ISSUES

Presentation

- Most often seen in association with other brain malformations

Demographics

- PMG accounts for ~ 20% of cortical development malformations

Natural History & Prognosis

- Cortical malformations may or may not be associated with severe neurologic symptoms
 - Depends on location/extent of cortical defects, associated brain malformations
- Confer worse prognosis if seen in conjunction with other abnormalities (e.g., agenesis of corpus callosum)
 - Often associated with specific syndrome (e.g., Aicardi)
- PMG is most common malformation of cortical development seen at pediatric centers
 - Patients often present with seizures
- Case reports of focal pachygyria associated with asymmetric arthrogryposis

Treatment

- Genetic counseling
- Infection screening: Much less recurrence risk for CMV than for genetic syndromes
- Deliver at tertiary center for availability of subspecialists
 - Many syndromes have autosomal recessive inheritance and therefore carry 25% recurrence risk for each subsequent pregnancy

DIAGNOSTIC CHECKLIST

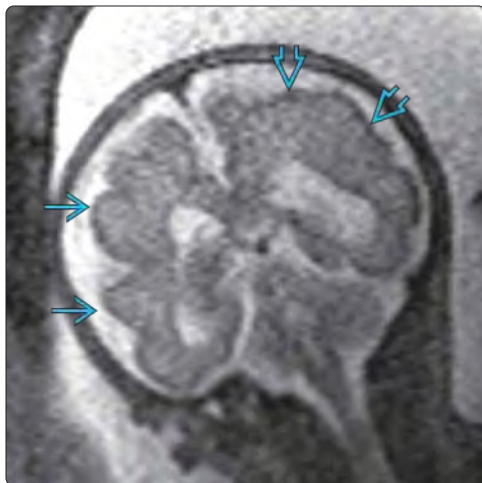
Consider

- PMG is probably common endpoint of variety of aberrations of cortical development

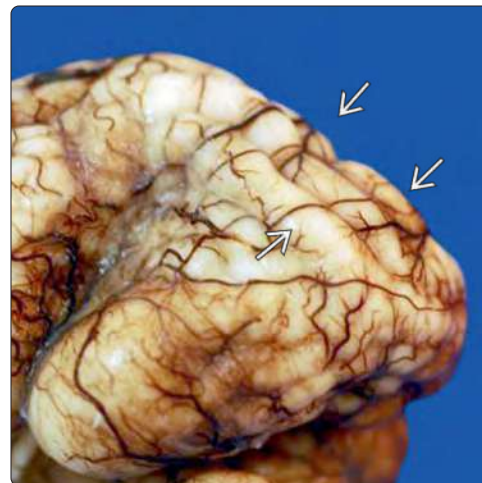SELECTED REFERENCES

1. Fallet-Bianco C et al: Mutations in tubulin genes are frequent causes of various foetal malformations of cortical development including microlissencephaly. *Acta Neuropathol Commun.* 2:69, 2014
2. Squier W et al: Polymicrogyria: pathology, fetal origins and mechanisms. *Acta Neuropathol Commun.* 2:80, 2014
3. De Keersmaecker B et al: Prenatal diagnosis of MPPH syndrome. *Prenat Diagn.* 33(3):292-5, 2013

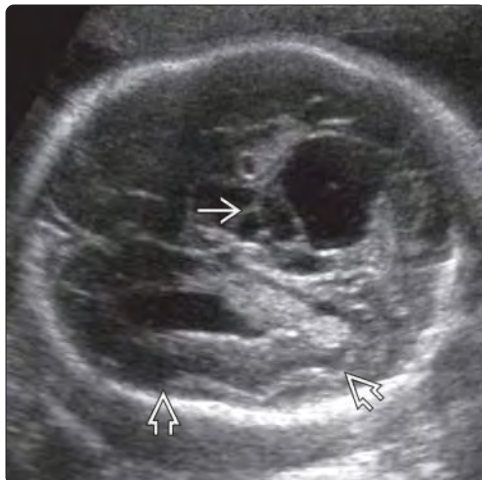
(Left) Coronal T2WI MR in a fetus with a 15-q8 translocation excludes associated holoprosencephaly but shows a diffuse cortical malformation with pachygyria and areas of agyria.



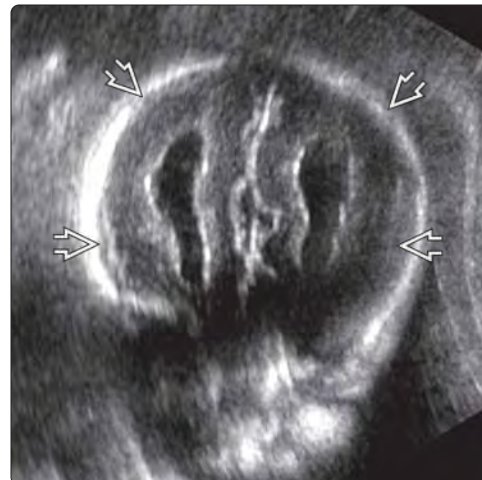
(Right) Autopsy from a twin with multiple anomalies shows broad smooth gyri at term, indicating pachygyria. There was polymicrogyria in other areas of the brain, which is common. The fetus was hydropic and expired shortly after delivery; no etiology was ever apparent. The co-twin was normal.



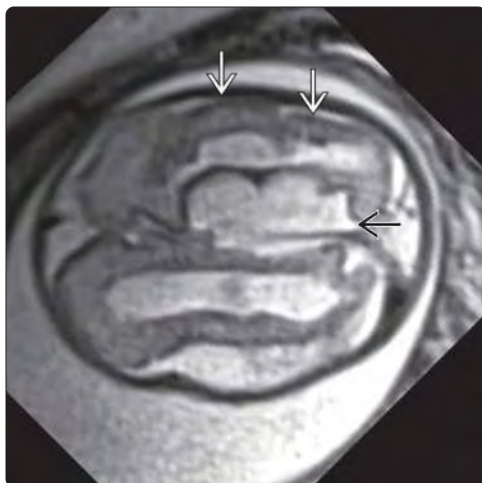(Left) Axial ultrasound in a 3rd-trimester fetus with agenesis of the corpus callosum and an interhemispheric cyst shows an abnormally smooth appearance to the cerebral hemisphere, concerning for lissencephaly.



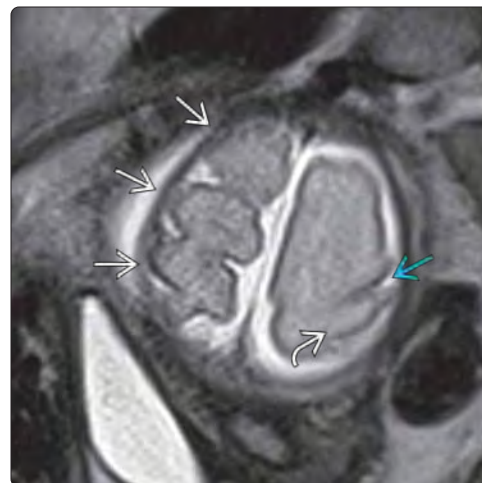
(Right) Coronal ultrasound in the same case again shows smooth cortex with lack of the expected gyral and sulcal markings as well as ventriculomegaly and agenesis of the corpus callosum.

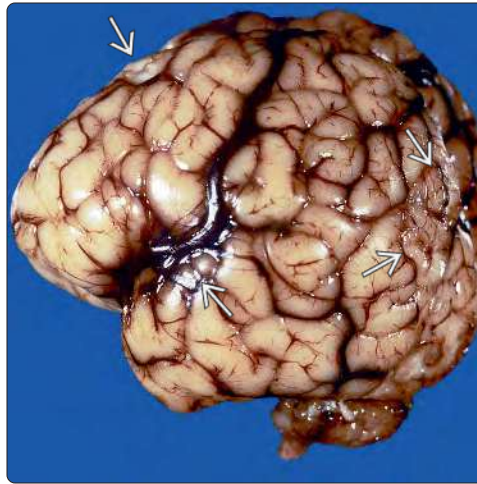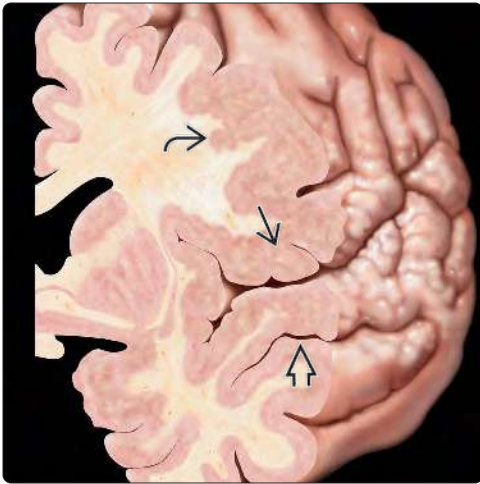


(Left) Axial T2WI MR in the same case shows some broad, smooth gyri (i.e., pachygyria). Note the complex interhemispheric cyst, probably a gliependymal cyst in association with callosal agenesis. Final diagnosis in this case was Aicardi syndrome.

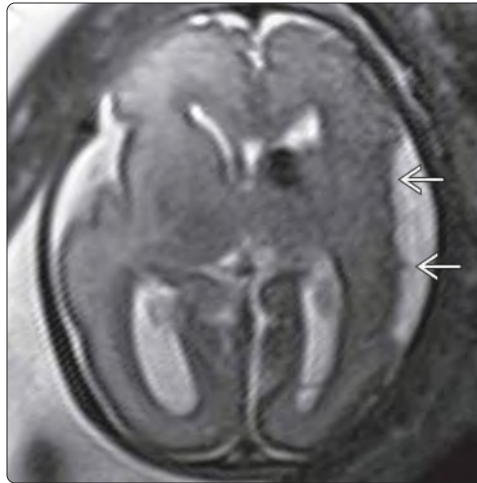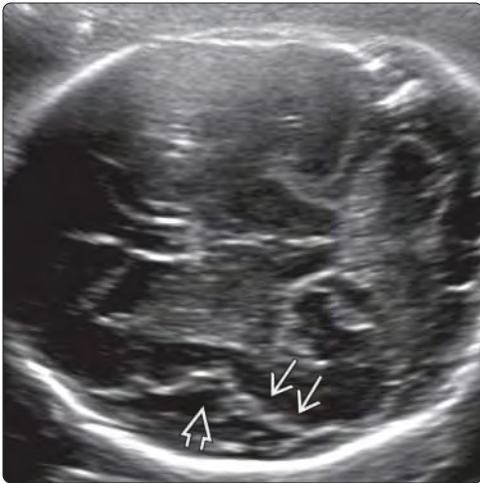


(Right) Axial HASTE MR in a different fetus with agenesis of the corpus callosum shows pachygyria with broad, smooth gyri over the surface of the right cerebral hemisphere. The left hemisphere is normal; note the central sulcus and postcentral gyrus.

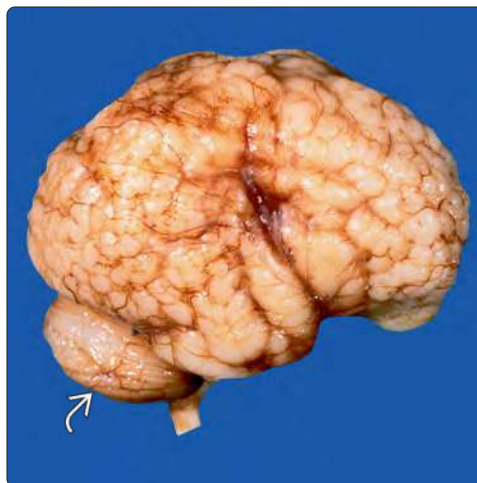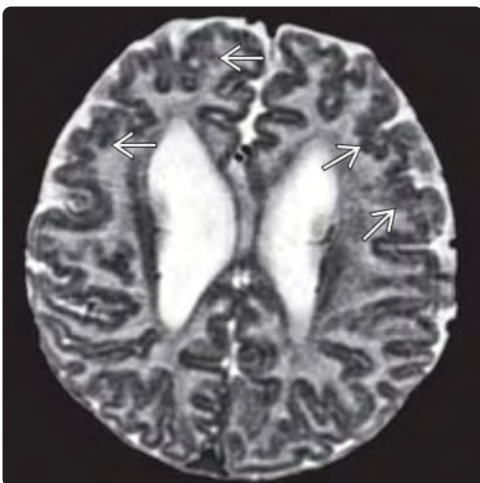




(Left) Coronal oblique graphic shows the thickened, pebbly gyri of polymicrogyria involving the frontal and temporal opercula. Note abnormal sulcation and the irregular cortical white matter interface in the affected regions. (Right) Autopsy from a case with microcephaly shows areas of polymicrogyria on the surface of the brain. (From Osborn's Brain.)



(Left) Axial ultrasound at 26 weeks shows abnormal configuration of the sylvian fissure with polymicrogyria over the temporal lobe. The fetus was known to have complex congenital heart disease but the brain findings had not been appreciated at the referring facility. (Right) Axial MR in the same case confirms the sonographic observation of cortical dysplasia and polymicrogyria .



(Left) Axial T2WI MR of an infant with bilateral frontal polymicrogyria shows multiple tiny irregularities at the junction of the cortex and white matter throughout the frontal lobes. The volume of the frontal white matter is diminished, and the frontal horns are large. (Right) Gross pathology shows multiple, tiny gyri all over the brain surface indicating diffuse polymicrogyria. The cerebellum in this case is normal in size; cerebellar hypoplasia is often associated with diffuse cortical malformation.

KEY FACTS

IMAGING

- Isolated choroid plexus cyst (CPC)
 - 0.3-3.6% of all midgestation fetuses have CPC
 - Almost all resolve by 32 weeks
 - No need for follow-up to show resolution
 - Not associated with aneuploidy in low-risk patients
- CPC and trisomy 18 (T18)
 - 30-50% of fetuses with T18 have CPC
 - Look for other T18 markers/anomalies
 - Fetal growth restriction, cardiac anomalies, extremity anomalies
- Large cysts may be mistaken for ventriculomegaly
- CPC morphology and risk
 - Multiple and bilateral CPC do not ↑ risk for T18
 - CPC > 10 mm might ↑ risk for T18
- CPC can be seen at time of nuchal translucency scan
 - Look for other anomalies

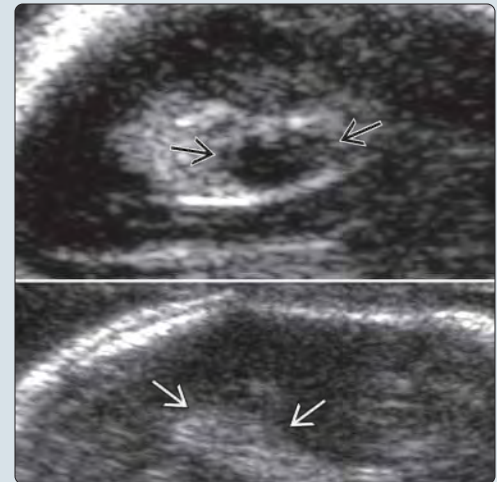
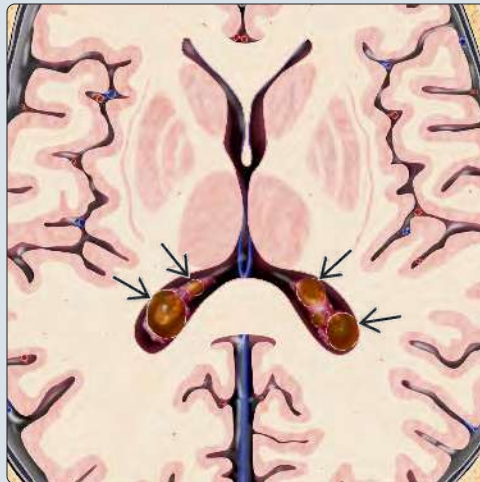
TOP DIFFERENTIAL DIAGNOSES

- Choroid plexus papilloma
 - Rare, often vascular
 - Papilloma makes cerebrospinal fluid → ventriculomegaly
- Intraventricular hemorrhage
 - Blood clot adherent to CPC might mimic cyst
 - Often with ventriculomegaly

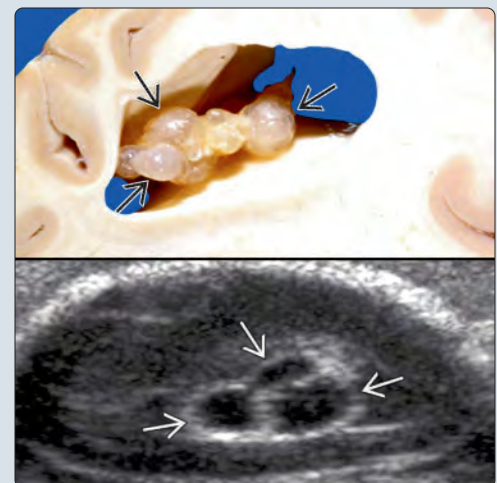
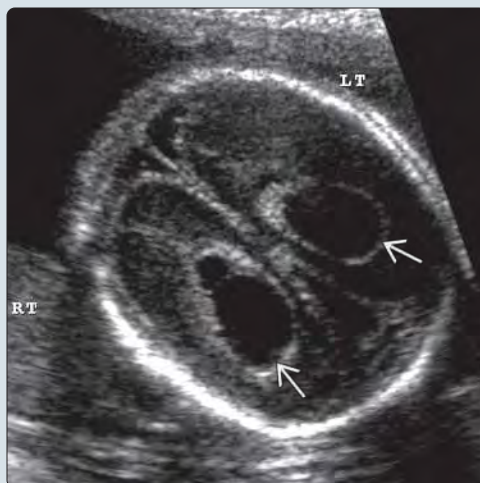
DIAGNOSTIC CHECKLIST

- When CPC seen, assess patient risk for aneuploidy
 - Maternal serum biochemistry results
 - Noninvasive prenatal testing results
 - Maternal age
 - Pregnancy history
- Refer for genetic counseling if assessment cannot be done by US reader
 - Time-sensitive referral

(Left) Graphic representation of choroid plexus cyst (CPC) occurring in the glomus portion of the choroid plexus (CP) is shown. The CP produces cerebrospinal fluid, and CPCs are entrapment cysts. **(Right)** Top image shows an isolated right simple CPC at 20 weeks. The bottom image shows a normal CP at 28 weeks in the same fetus. Almost always, CPCs resolve by the 3rd trimester. An isolated CPC in a low-risk patient is not associated with aneuploidy. Follow-up to show resolution is not necessary.



(Left) Bilateral, symmetrical, large CPCs mimic ventriculomegaly when imaged in the axial view. Large CPCs in the glomus fill the atria of the lateral ventricles. **(Right)** Gross pathology of clustered CPC matches the US finding of clustered CPCs from another midgestation case. Clustered cysts are common and can mimic a mass on US. However, they are transient, regardless of morphologic appearance.



TERMINOLOGY

Abbreviations

- Choroid plexus cyst (CPC)

Definitions

- Choroid plexus are organs in cerebral ventricular system that produce cerebrospinal fluid (CSF)
- CPCs are entrapment of CSF in choroid plexus (CP)

IMAGING

General Features

- Best diagnostic clue
 - 1 or more cysts in CP in 2nd-trimester fetus
- Location
 - More often in glomus of lateral ventricle, rather than body of lateral ventricle
 - Glomus is posterior thick portion in atria
 - Unilateral or bilateral
- Size
 - Variable
 - > 10 mm considered large CPC
- Morphology
 - Single, multiple, clustered

Ultrasonographic Findings

- CPCs are benign, transient, and common
 - Seen in 0.3-3.6% of 2nd-trimester fetuses
 - Weak marker for trisomy 18 (T18)
 - No ↑ risk for aneuploidy if isolated and low-risk patient
 - Most resolve by 32 weeks
 - Do not need follow-up to show resolution
- Typical CPC appearance
 - Discrete anechoic avascular mass (often > 2 mm)
 - Surrounded by choroid plexus
 - Large CPC (> 10 mm)
 - Possibly greater association with T18
 - May be mistaken for ventriculomegaly
 - Resolve slower
 - Rarely cause obstruction
 - Multiple and bilateral CPC are common
 - Does not increase risk for T18
- **CPC and T18 association**
 - 40-50% of T18 fetuses have CPC
 - Isolated CPC not associated with T18 in low-risk patients
 - Likelihood ratio < 2 for T18
 - Confirm patient is low risk by checking results of genetic screening
 - ◻ Maternal serum biochemistry testing
 - ◻ Noninvasive prenatal testing
 - Look for T18 anomalies when CPC seen
 - Cardiac defects
 - Fetal growth restriction
 - Clenched hands with overlapping fingers
 - Rocker-bottom feet
 - Single umbilical artery
- Isolated CPC is not associated with trisomy 21 (T21)
- CPC can be seen at time of nuchal translucency scan
 - Increased risk for T18 (not T21)
 - Look for anomalies at this time

Imaging Recommendations

- Best imaging tool
 - Evaluate choroid plexus routinely
 - Transverse image of lateral ventricle
 - ◻ Show cyst in 2 orthogonal planes
 - Do not confuse posterior atria fluid with CPC
- Protocol advice
 - Careful anatomic survey when CPC seen
 - Show normal growth, cardiac views, extremity views
 - No need for follow-up to show CPC resolution

DIFFERENTIAL DIAGNOSIS

Choroid Plexus Papilloma

- Rare vascular choroid plexus tumor
- Tumor produces CSF → ventriculomegaly

Intraventricular Hemorrhage

- Intraventricular blood clings to choroid
- Often with ventriculomegaly ± parenchymal bleed

CLINICAL ISSUES

Presentation

- Most common signs/symptoms
 - Isolated incidental finding
- Other signs/symptoms
 - CPC + anomaly associated with T18

Demographics

- Epidemiology
 - 0.3-3.6% in 2nd trimester
 - 30-50% of T18 fetuses

Natural History & Prognosis

- Transient benign finding
 - Almost all resolve
 - No prognostic importance if they do not resolve
 - Not associated with neurodevelopment delay
- Guarded prognosis for CPC and other anomalies
 - Depends on karyotype result

DIAGNOSTIC CHECKLIST

Consider

- Know patient's risk profile
 - Refer for genetic counseling if not known
 - Referral is time sensitive

SELECTED REFERENCES

1. Reddy UM et al: Fetal imaging: executive summary of a joint Eunice Kennedy Shriver National Institute of Child Health and Human Development, Society for Maternal-Fetal Medicine, American Institute of Ultrasound in Medicine, American College of Obstetricians and Gynecologists, American College of Radiology, Society for Pediatric Radiology, and Society of Radiologists in Ultrasound Fetal Imaging Workshop. *J Ultrasound Med.* 33(5):745-57, 2014
2. Sonek J et al: Second trimester ultrasound markers of fetal aneuploidy. *Clin Obstet Gynecol.* 57(1):159-81, 2014
3. DiPietro JA et al: Isolated prenatal choroid plexus cysts do not affect child development. *Prenat Diagn.* 31(8):745-9, 2011
4. Beke A et al: Risk of chromosome abnormalities in the presence of bilateral or unilateral choroid plexus cysts. *Fetal Diagn Ther.* 23(3):185-91, 2008
5. Dagklis T et al: Choroid plexus cyst, intracardiac echogenic focus, hyperechogenic bowel and hydronephrosis in screening for trisomy 21 at 11 + 0 to 13 + 6 weeks. *Ultrasound Obstet Gynecol.* 31(2):132-5, 2008

KEY FACTS

TERMINOLOGY

- Cerebrospinal fluid (CSF) collection enclosed within layers of arachnoid

IMAGING

- Extraaxial, CSF-containing cyst with thin membranous wall
 - 2/3 supratentorial
 - 1/3 in posterior fossa
 - Usually single
 - Displaces adjacent normal brain parenchyma
- > 90% discovered after 20-weeks gestation
- Remaining brain sonographically normal in majority of cases
- Adjacent calvarium may be thinned, scalloped
- Avascular lesion; no flow on color Doppler
- MR
 - Follows CSF signal; low T1WI, high T2WI
 - Buckles adjacent gray/white matter interface
- Rarely, may exhibit rapid growth and cause obstructive hydrocephalus

TOP DIFFERENTIAL DIAGNOSES

- Interhemispheric cyst/AVID
 - Asymmetric ventriculomegaly with interhemispheric cyst and dysgenesis of corpus callosum
- Porencephalic cyst
- Schizencephaly
- Dandy-Walker malformation

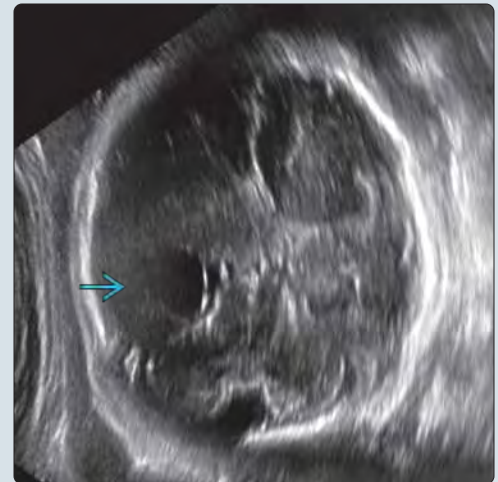
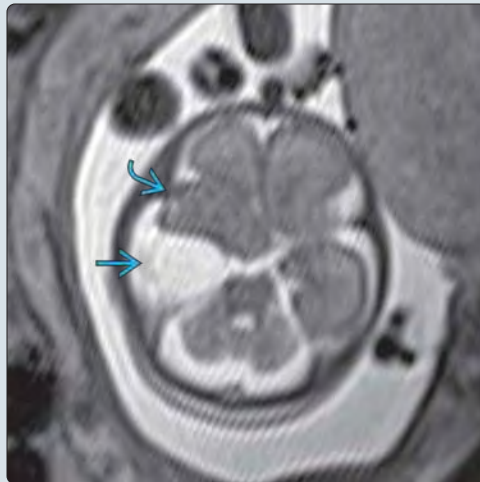
CLINICAL ISSUES

- Monitor for growth of cyst (occurs in ~ 20% of cases)
- Evolving hydrocephalus in < 2%
- May be syndromic but not typically associated with aneuploidy when isolated
- Prognosis good if isolated abnormality
- May require shunt or excision if significant mass effect

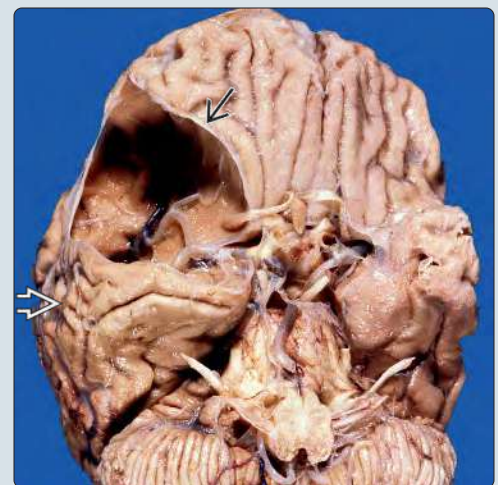
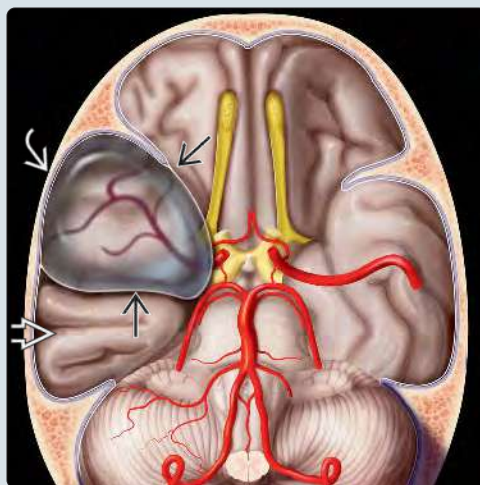
DIAGNOSTIC CHECKLIST

- Always check Doppler in apparent cyst to rule out vascular malformation

(Left) T2WI MR of a 24-week fetus shows an arachnoid cyst (AC) in the middle cranial fossa with mass effect on the ipsilateral temporal lobe. The MR was requested to differentiate a porencephalic cyst from an AC. (Right) Follow-up US at 31 weeks shows the cyst is stable in an otherwise normal brain. ACs are space-occupying lesions that displace adjacent brain (normal or abnormal). Porencephalic cysts replace destroyed brain, do not have mass effect, and are often associated with hemorrhage or ischemia.



(Left) A middle cranial fossa AC with split arachnoid enclosing cerebrospinal fluid (CSF) is shown. The middle fossa is expanded, the overlying bone is thin, and the temporal lobe is displaced posteriorly. (Right) The undersurface of an autopsied brain shows a middle cranial fossa AC. The arachnoid is split around the cyst (i.e., CSF collection), which was drained during brain removal. The temporal lobe is displaced posteriorly, and the middle cranial fossa is expanded. (From *DI: Pediatric Neuro*, 2e.)



TERMINOLOGY**Abbreviations**

- Arachnoid cyst (AC)

Definitions

- Cerebrospinal fluid (CSF) collection enclosed within layers of arachnoid

IMAGING**General Features**

- Best diagnostic clue
 - Extraaxial, CSF-containing cyst with thin, membranous wall
 - > 90% discovered after 20-weeks gestation
- Location
 - Fetal series
 - Usually single
 - 2/3 supratentorial
 - 1/3 in posterior fossa
 - Collicular, interhemispheric locations more common prenatally
 - Sylvian fissure unusual prenatally, although, most common site in adults
- Size
 - Variable
 - Rarely, may exhibit rapid growth and cause obstructive hydrocephalus
 - Interhemispheric and skull base cysts more likely to progress
- Morphology
 - Simple, smooth-walled, unilocular or multilocular cyst
 - Displaces adjacent normal brain parenchyma

Ultrasonographic Findings

- Grayscale ultrasound
 - Smoothly marginated, anechoic cyst
 - Remaining brain sonographically normal in majority of cases
- Color Doppler
 - Avascular lesion
 - Large cyst may displace major cerebral vessels
- 3D
 - May help to confirm extraaxial location
 - May clarify origin (e.g., floor of middle cranial fossa)

MR Findings

- Adjacent calvarium may be scalloped
- Buckles gray/white matter interface of adjacent brain
- Follows CSF signal
 - Low-signal T1WI
 - High-signal T2WI

Imaging Recommendations

- Best imaging tool
 - Sonographic screening with confirmation by fetal MR
 - Fetal MR
 - Confirm diagnosis and differentiate from other intracranial cysts
 - Evaluate associated structural abnormalities

- 50% of fetal cases have additional findings seen on MR
- May detect subtle cortical malformations not apparent on US

- Protocol advice
 - Look for associated findings
 - Agenesis of corpus callosum
 - Hydrocephalus
 - Careful search for other anomalies
 - AC may be part of multiple malformation syndrome
 - Additional anomalies increase suspicion for
 - Aneuploidy
 - Inherited conditions

DIFFERENTIAL DIAGNOSIS**Interhemispheric Cyst**

- Part of AVID complex: **A**symmetric ventriculomegaly with **i**nterhemispheric cyst and **d**ysgenesis of corpus callosum
- Centered on midline
 - ACs usually over convexities in fetus
- Has mass effect with displacement of adjacent brain
- Asymmetric ventriculomegaly may be marked and is often most obvious feature
- Cyst may communicate with ventricle
- May have multiple loculations

Porencephalic Cyst

- Results from infarction of damaged brain
- Does not have mass effect
- Often associated with intracranial hemorrhage
- US findings can be subtle
 - Loss of normal architecture
 - Mild ventriculomegaly
- Look for encephaloclastic changes
 - Abnormal, high-signal cerebral cortex on T2WI

Schizencephaly

- Cleft in brain substance
- Wedge-shaped rather than round
- May be bilateral and symmetric
- Lined with gray matter on MR

Choroid Plexus Cyst

- Located within choroid plexus of lateral ventricles
- May be associated with trisomy 18
 - Look for multiple anomalies

Dandy-Walker Malformation

- Differential consideration for posterior fossa AC
- Torcular elevation is hallmark
- 4th ventricle in communication with cisterna magna
- Vermian agenesis/dysgenesis

Teratoma

- Can be predominately cystic
- Soft tissue component and calcifications can usually be identified
- Rapid growth
- Macrocephaly

Physiologic Entities

- Differential
 - Enlarged cavum septi pellucidi
 - Cavum vergae
 - Cyst of cavum velum interpositum
- Do not increase in size
- May regress with advancing gestational age
- Median size: 10 mm (range: 10-30 mm)
- Pathologic cysts often larger and may grow as pregnancy progresses

PATHOLOGY**General Features**

- Etiology
 - Duplication of arachnoid during embryologic development creates potential space
 - CSF fills potential space
 - Active fluid secretion by cyst wall
 - Slow distention by CSF pulsations
 - CSF accumulates by 1-way (ball valve) flow
- Genetics
 - Mostly sporadic
 - Can be seen as part of genetic syndromes
 - Neurofibromatosis type 1
 - Familial AC
 - Multiple congenital anomaly disorders with single gene mutation: Xq22, 9q22, 14q32.3, 11p15
 - Aicardi syndrome X-linked dominant, male lethal
 - Trisomies 8, 13, 18, 20
 - Usually multiple other anomalies
- Associated abnormalities
 - Rare
 - Hydrocephalus
 - Mass effect on foramen of Munro/aqueduct of Sylvius → impaired CSF drainage
 - Agenesis of corpus callosum

CLINICAL ISSUES**Presentation**

- Most common signs/symptoms
 - Most present on screening ultrasonography at > 20-weeks gestational age
 - Reported cases diagnosed as early as 1st trimester (on endovaginal scans)

Demographics

- Epidemiology
 - True prenatal incidence unknown
 - 1% of space-occupying lesions in childhood
 - 1% of intracranial masses in newborns
 - 0.5% of autopsies
 - M > F
 - Left > right

Natural History & Prognosis

- Evolving hydrocephalus in < 2%
- Hydrocephalus more likely if
 - Early gestational age at diagnosis
 - Progressive increase in size

- ~ 20% of ACs in fetuses and 23% in children increase in size
- Supratentorial location, especially interhemispheric or collicular cysts
- Other anomalies determine prognosis when present
- Prognosis good if isolated abnormality
 - Developmental and intelligence quotients parallel normal range ± treatment
 - Outcome correlated with integrity of brain parenchyma rather than cyst volume, location
 - Many spontaneously resolve
 - May require shunt or excision if significant mass effect
- Suprasellar cistern AC associated with hypothalamic hamartoma
 - Risk for precocious puberty, visual disturbances
- Posterior fossa AC seem to do well with no adverse consequences related to compression of cerebellum
- Reports of associated aphasia, developmental disability, and attention deficit hyperactivity disorder warrant further exploration

Treatment

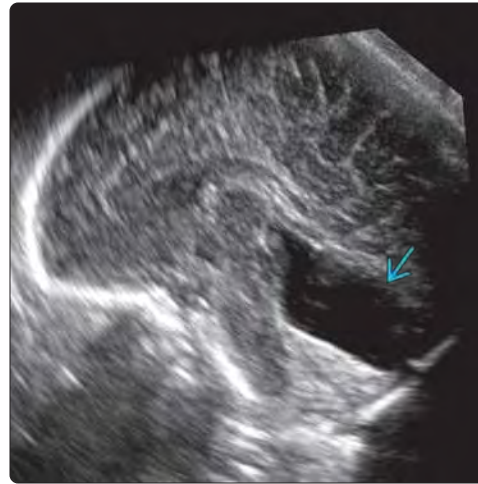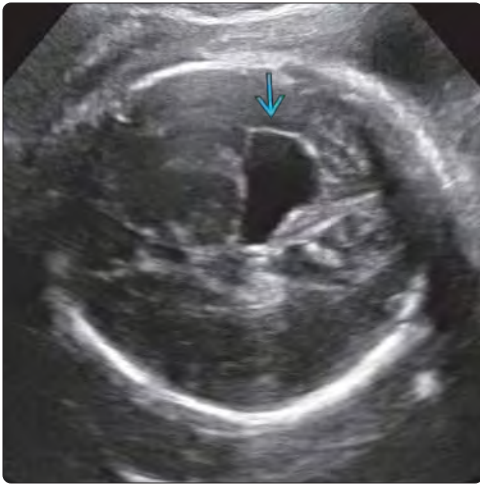
- No prenatal intervention indicated
- May be syndromic but not typically associated with aneuploidy when isolated
- Monitor for growth of cyst (occurs in ~ 20% of cases)
 - Secondary hydrocephalus if CSF flow obstructed
 - Macrocephaly; head size may impact timing and mode of delivery
- Traditional surgical intervention includes cyst-peritoneal shunt vs. excision/marsupialization of cyst
- Postnatal endoscopic cyst fenestration, cystoventriculostomy, and cystocisternostomy are emerging alternatives to traditional approaches
 - Avoid shunt placement with complications thereof
- Surgery is not without risk: Postsurgical complete recovery in 64%
 - Mild neurological deficit in 15%, severe deterioration in 13%, demise in 8%

DIAGNOSTIC CHECKLIST**Image Interpretation Pearls**

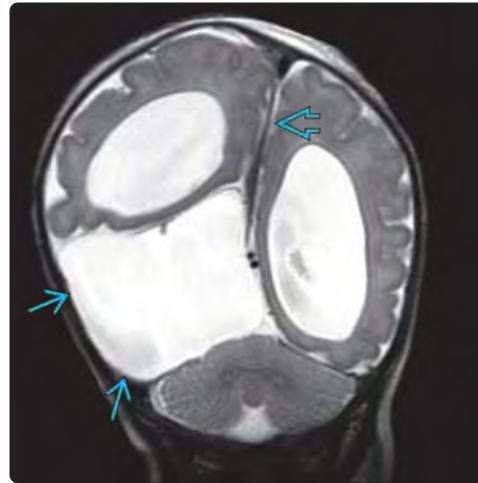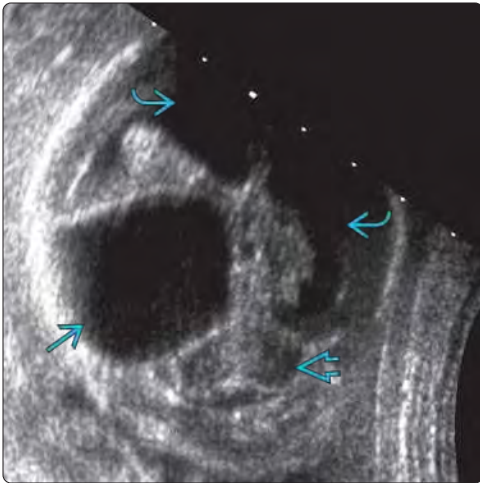
- Always check Doppler in apparent cyst
 - Arteriovenous malformation or vein of Galen aneurysm immediately apparent
 - Very different prognosis

SELECTED REFERENCES

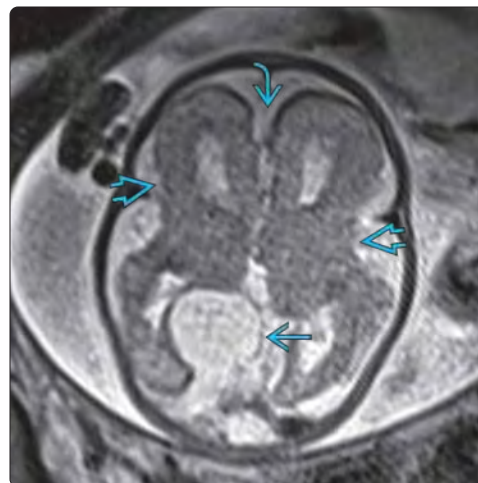
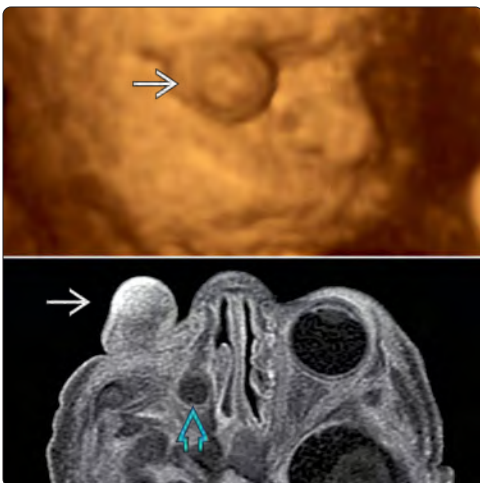1. De Keersmaecker B et al: Outcome of 12 antenatally diagnosed fetal arachnoid cysts: Case series and review of the literature. *Eur J Paediatr Neurol.* 19(2):114-121, 2015
2. Goksu E et al: Spontaneous shrinkage of a suprasellar arachnoid cyst diagnosed with prenatal sonography and fetal magnetic resonance imaging: case report and review of the literature. *Turk Neurosurg.* 25(4):670-3, 2015
3. Lee JY et al: Enlarging arachnoid cyst: a false alarm for infants. *Childs Nerv Syst.* 28(8):1203-11, 2012
4. Miric Tesanic D et al: Prenatal diagnosis of ambient cistern cyst. *Ultraschall Med.* 33(7):E350-1, 2012
5. Al-Holou WN et al: Prevalence and natural history of arachnoid cysts in children. *J Neurosurg Pediatr.* 5(6):578-85, 2010
6. Chen CP: Prenatal diagnosis of arachnoid cysts. *Taiwan J Obstet Gynecol.* 46(3):187-98, 2007



(Left) Axial US at 33 weeks (for poor maternal weight gain) shows an unexpected finding of a well-circumscribed cyst in the middle cranial fossa. The fetus was otherwise normal, and growth was appropriate. **(Right)** Left parasagittal neonatal head US in the same patient shows stable size and shape of the cyst. The head size was normal, and the infant was asymptomatic. He is being followed by neurosurgery, but no intervention is planned.



(Left) Coronal 3rd-trimester US shows a large, extraaxial, supratentorial, simple cyst elevating the right occipital lobe. Note the associated ventriculomegaly with bilateral dilated occipital horns (cerebellum). **(Right)** Coronal postnatal T2WI MR in the same patient confirms that the cyst is extraaxial, displacing the right cerebral hemisphere superiorly. Ventriculomegaly is due to kinking of the ipsilateral foramen of Munro, as well as the midline shift, which compromises contralateral CSF circulation.



(Left) 3D US shows a mass protruding from the right orbit in the same patient. The postnatal T1 C+ FS MR shows a vestigial globe in the right orbit. Pathology of the mass revealed hamartoma. The child has callosal dysgenesis and severe developmental delay. **(Right)** Axial MR in a different fetus shows agenesis of the corpus callosum, diffuse cortical dysplasia, and an AC. The AC in such cases is an incidental finding; the prognosis is determined by the severe brain abnormality.

KEY FACTS

IMAGING

- Nonperfused intracranial mass of varying echogenicity
 - Subependymal and intraventricular most common
- Most bleeds appear echogenic initially
 - Over time usually become isoechoic → hypoechoic
- Hemorrhage usually extensive if seen in utero
- Anemia secondary to hemorrhage increases risk for nonimmune hydrops
- Evaluation with MR useful
 - T1WI high signal (methemoglobin)
 - T2WI low signal

TOP DIFFERENTIAL DIAGNOSES

- Intracranial tumor
 - Tumors may bleed and mask underlying mass
- Infection

PATHOLOGY

- Alterations in maternal and fetal blood pressure

- Trauma
- Maternal thrombocytopenia/coagulation disorders
- Neonatal germinal matrix hemorrhage grading does not have same prognostic implications for fetus

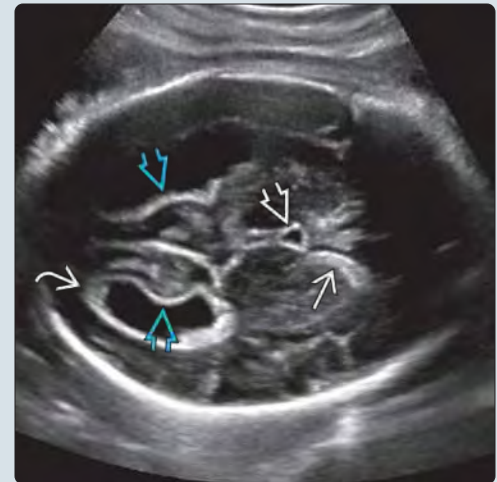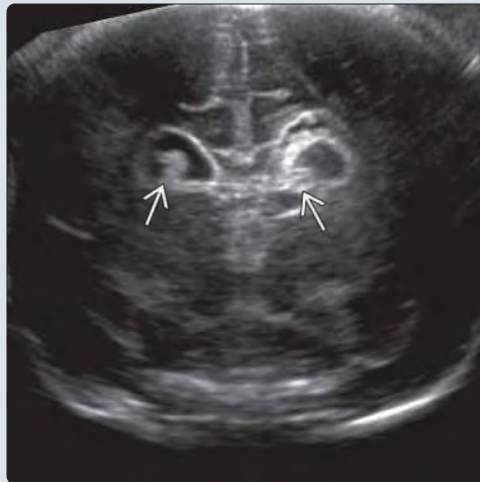
CLINICAL ISSUES

- Usually diagnosed between 26-33 weeks gestation
- Maternal testing for coagulation/platelet disorder may be warranted
- Outcome relates to severity and extent of bleed
- Long-term sequelae
 - Developmental delay
 - Cerebral palsy, seizure disorder
 - Fetal or neonatal death
- Fetal transfusion may be required, platelets or whole blood
- Consider delivery by cesarean section

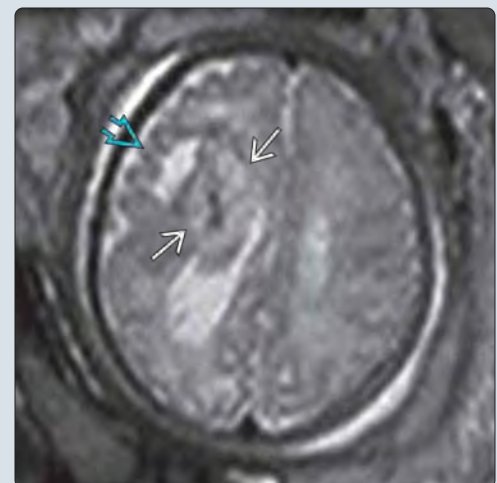
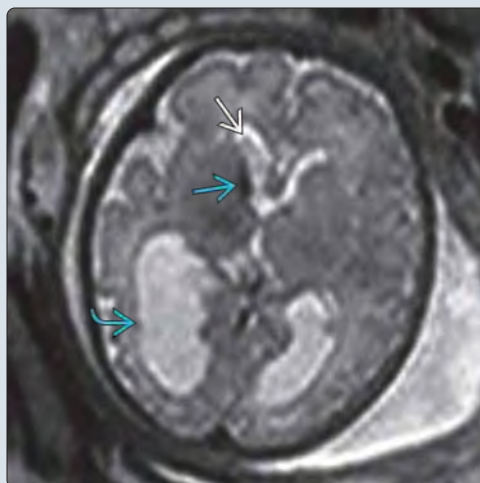
DIAGNOSTIC CHECKLIST

- Fetal MR helpful for counseling regarding prognosis

(Left) Coronal ultrasound of the brain at 35 weeks shows intraventricular clot in the frontal horns. Although potentially echogenic clot can be mistaken for choroid, the choroid should not extend into the frontal horns. **(Right)** In this more subtle case, layering clot is present in the frontal and occipital horns. In addition, the ependymal lining of the ventricles is thickened and echogenic, and the 3rd ventricle is mildly dilated.



(Left) In this 3rd-trimester fetus with intracranial hemorrhage (ICH), hypointense clot is present in the right frontal horn with ipsilateral ventriculomegaly. Hemosiderin staining along the ventricle wall is further evidence of evolving hemorrhage. **(Right)** In addition, there is hemorrhage extending into the adjacent right frontal lobe parenchyma with peripheral high T2 signal and overlying cortical thinning, indicative of developing pencephaly.



TERMINOLOGY

Abbreviations

- Intracranial hemorrhage (ICH)

Definitions

- Bleeding within fetal cranium

IMAGING

General Features

- Best diagnostic clue
 - Nonperfused intracranial mass of varying echogenicity
- Location
 - Classified by anatomic location
 - Subependymal (common)
 - Germinal matrix hemorrhage (GMH)
 - Intraventricular (common)
 - Intraparenchymal
 - Most are supratentorial
 - Subdural
 - Subarachnoid
 - Epidural (very rare)

Ultrasonographic Findings

- Hemorrhage usually extensive when seen in utero
 - Normal intracranial landmarks often obscured
 - Most bleeds appear echogenic initially
 - Over time usually become isoechoic → hypoechoic
- GMH is similar to neonatal appearance
- Intraventricular bleed may have varying appearances
 - Intraventricular clot
 - Irregular bulky choroid plexus
 - Echogenic, irregular thickened ependyma
 - Often associated with hydrocephalus
- Porencephaly can develop at site of intraparenchymal hemorrhage
 - Usually anechoic parenchymal cyst connected to adjacent ventricle
- Subdural bleed separates sylvian fissure from calvarium
 - Hyperechoic (acute) or hypoechoic (subacute-chronic) material outlining cortex
 - Normal distance from cortex to skull vault ≤ 4 mm

MR Findings

- Blood products
 - T1WI high signal (methemoglobin)
 - T2WI low signal
- Confirm location of clot on multiple planes
- Do not confuse with flow artifact
 - Turbulent cerebrospinal fluid (CSF) flow in dilated system
 - Less defined swirl signal, not mass-like
 - Location changes between sequences
- Septations in CSF spaces/ventricles correlate with hemorrhage and infection
- Blood/CSF levels
 - Large flow voids on T2WI = feeding/draining vessels from vascular malformation
- Look for periventricular leukomalacia /porencephaly

Imaging Recommendations

- Look for hydrops
 - Anemia secondary to hemorrhage increases risk for nonimmune hydrops
- Look for vascular malformation as cause
 - Thrombosis of vascular malformation → venous hypertension → bleed
 - Shape/location may suggest vein of Galen malformation
 - Tubular components suggest thrombosed feeding or draining vessels
 - Use color Doppler

DIFFERENTIAL DIAGNOSIS

Intracranial Tumor

- Large, heterogeneous, rapid growth
- Caution: Intracranial tumors may bleed
 - Look for blood flow in periphery of mass with color Doppler
- Macrocephaly common
- Choroid plexus papilloma is potential mimic for intraventricular clot
 - Echogenic intraventricular mass

Infection

- May cause destructive brain lesions
- Look for intracranial/liver calcifications, hydrops

Ischemia

- Periventricular leukomalacia
 - Abnormal echogenicity/signal in periventricular white matter
 - May evolve into porencephaly

PATHOLOGY

General Features

- Etiology
 - Alterations in maternal and fetal blood pressure
 - Drug use: Cocaine, aspirin
 - Preeclamptic toxemia (PET)
 - Hemolysis-elevated liver enzymes: Low platelets (HELLP) syndrome
 - Monochorionic twin demise
 - Can result in severe fetal hypotension or potential emboli from dead twin
 - Subsequent bleed in survivor related to brain edema → small vessel occlusion → infarct/bleed
 - Trauma
 - Motor vehicle accident or domestic violence
 - Most commonly results in intraparenchymal or subdural/epidural bleed
 - Maternal thrombocytopenia/coagulation disorders
 - Fetal and neonatal alloimmune thrombocytopenia (FNAIT)
 - Fetal ICH in 10-30%
 - Maternal idiopathic thrombocytopenia
 - Fetal ICH in $< 1\%$
 - Factor V or X deficiency
 - Coumadin or heparin therapy
 - Bacterial/viral infection

- Infarcts secondary to parenchymal inflammation
 - Results in small vessel ischemia
- Umbilical cord abnormalities
 - Thrombosis, knot, hematoma
- Placental abnormalities
 - Uteroplacental insufficiency
 - Abruptio/placenta previa
- Fetal arteriovenous malformation/fistula
- Amniocentesis complication
 - Should be avoidable with US guidance

Staging, Grading, & Classification

- **Neonatal GMH grading system** does not have same prognostic implication for fetus
 - Uncommon to find isolated small GMH in fetus
 - Up to 25% of neonatal cases are limited to germinal matrix
- **Fetal classification of intraventricular hemorrhage (IVH)** can be linked with outcomes
 - Good outcome = normal or mild neurological impairment
 - Grade 1: 100% good outcome
 - Isolated small GMH, mild ventriculomegaly (VM) → atria < 15 mm
 - Grade 2: 50% good outcome
 - Focal periventricular bleed < 1 cm, severe VM
 - Grade 3: 0% good outcome
 - VM with periventricular bleed > 1 cm

Microscopic Features

- Likely common pathway to explain eventual hemorrhage or infarct
 - Maternal/fetal hypotension/hypoxia → brain edema
 - Small vessel occlusion or rupture results
- Subependymal bleed
 - Germinal matrix cells present after 20-weeks gestation
 - Bleed related to fragile germinal matrix capillaries
 - Germinal matrix more susceptible < 32 weeks
 - Poor autonomic control of fetal cerebral vascularity
 - Results in capillary rupture → hemorrhage, venous infarct
 - Usually extends into ventricles

CLINICAL ISSUES

Presentation

- May be asymptomatic
- Decreased fetal movement
- Nonreactive fetal heart rate tracing
- Sinusoidal fetal heart rate tracing secondary to fetal hypoxia
 - Fetal anemia → impaired oxygen delivery
- Preterm labor
 - Especially if polyhydramnios present
 - Secondary to impaired fetal swallowing

Demographics

- Epidemiology
 - Uncommonly diagnosed in utero
 - Usually diagnosed between 26- to 33-weeks gestation if identified

- 6% of autopsies for stillbirth have some type of hemorrhage

Natural History & Prognosis

- Long-term sequelae
 - Developmental delay
 - Hydrocephalus
 - Cerebral palsy, seizure disorder
 - Fetal or neonatal death
- Outcome related to severity and extent of bleed
 - Poor outcome = demise or severe neurological impairment
 - In 92% of parenchymal bleeds
 - In 88% of subdural/subarachnoid bleeds
 - In 45% of intraventricular bleeds
 - Isolated germinal matrix bleed → good outcome

Treatment

- Maternal testing for coagulation disorder/platelet antibodies
 - Fetal transfusion may be required, platelets or whole blood
 - FNAIT: Consider immune globulin infusions ± steroids
 - Prior to this therapy, outcome was poor
- Consider delivery by cesarean section
 - Avoids mechanical stress of vaginal delivery and potential for repeat bleed
 - May attempt vaginal delivery if severe parenchymal damage already present
 - Neurological impairment results from brain destruction, mode of delivery does not alter outcome

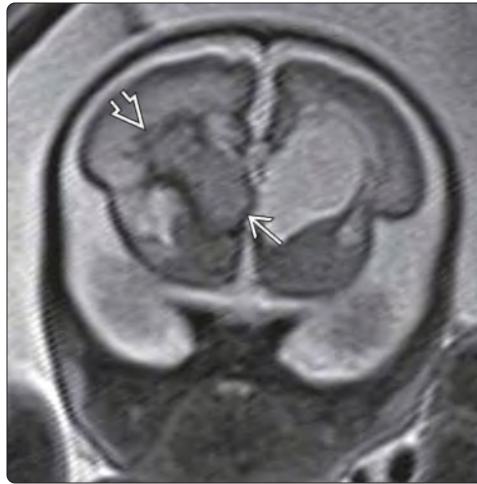
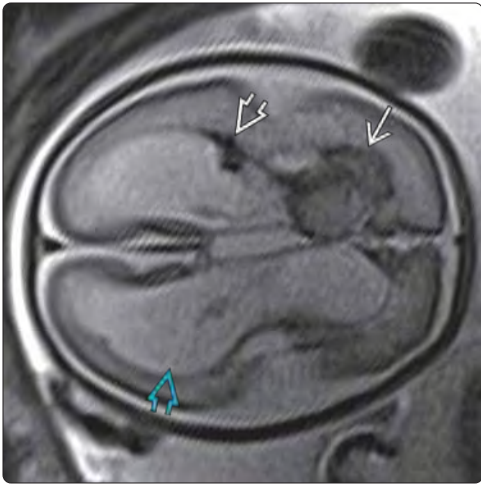
DIAGNOSTIC CHECKLIST

Consider

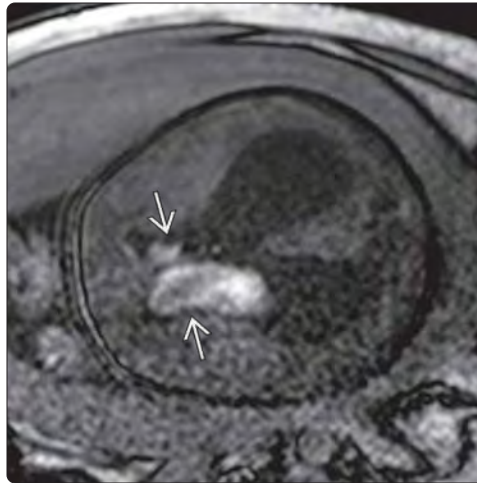
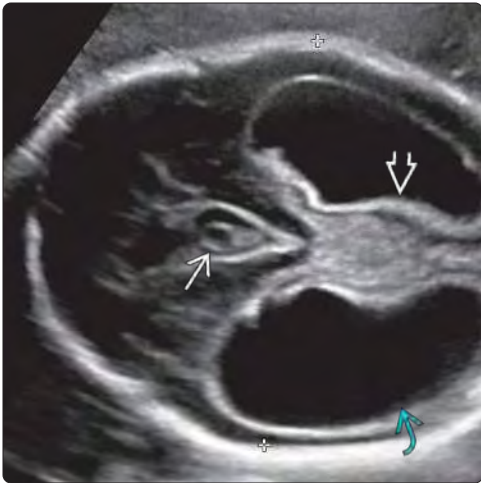
- Fetal MR can be useful for counseling regarding prognosis
 - Hemorrhage may be difficult to see on ultrasound
 - Fetal MR useful for patients at risk for hemorrhage
 - If incidentally detected on ultrasound, MR can be useful to assess
 - Extent of bleed
 - Intraparenchymal involvement
 - Areas of porencephaly

SELECTED REFERENCES

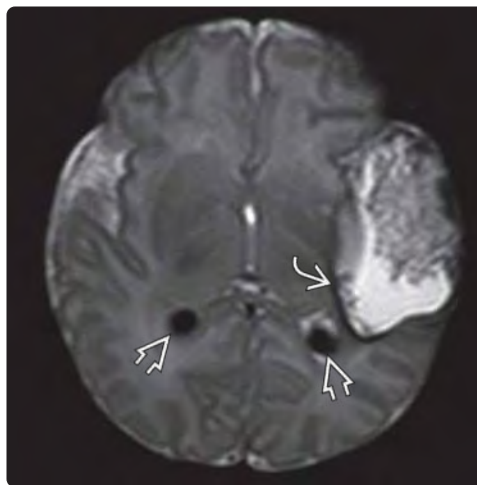
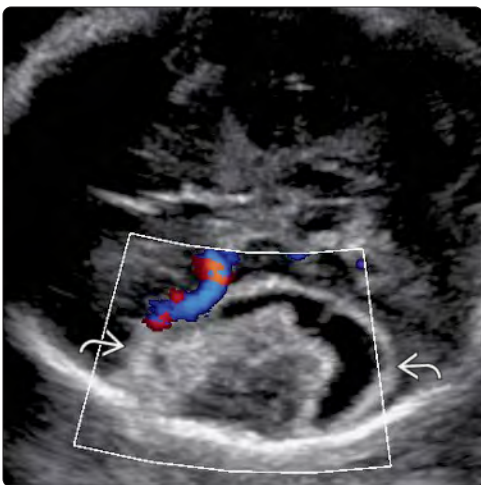
1. Van Der Lugt NM et al: Neonatal outcome in alloimmune thrombocytopenia after maternal treatment with intravenous immunoglobulin. *Blood Transfus.* 13(1):66-71, 2015
2. Gherman RB et al: Placental abruption and fetal intraventricular hemorrhage after airbag deployment: a case report. *J Reprod Med.* 59(9-10):501-3, 2014
3. Kutuk MS et al: Fetal intracranial hemorrhage related to maternal autoimmune thrombocytopenic purpura. *Childs Nerv Syst.* 30(12):2147-50, 2014
4. Kutuk MS et al: Prenatal diagnosis and postnatal outcome of fetal intracranial hemorrhage. *Childs Nerv Syst.* 30(3):411-8, 2014
5. Tiller H et al: Fetal intracranial haemorrhages caused by fetal and neonatal alloimmune thrombocytopenia: an observational cohort study of 43 cases from an international multicentre registry. *BMJ Open.* 3(3), 2013
6. Zeina AR et al: Computed tomographic diagnosis of traumatic fetal subdural hematoma. *Emerg Radiol.* 20(2):169-72, 2013
7. Bussel J: Diagnosis and management of the fetus and neonate with alloimmune thrombocytopenia. *J Thromb Haemost.* 7 Suppl 1:253-7, 2009
8. Hines N et al: What is the clinical importance of echogenic material in the fetal frontal horns? *J Ultrasound Med.* 28(12):1629-37, 2009



(Left) In this early 3rd-trimester fetus, a mass-like area of hypointense clot extends through the ventricular wall and into the adjacent parenchyma. Hemosiderin is present along the lateral ventricle and there is ventriculomegaly. **(Right)** Coronal T2 MR in the same case confirms the intraparenchymal extension. The mass-like clot extends toward the midline in the frontal horn. Although an underlying solid mass could be considered, this is a typical location for ICH arising from the germinal matrix.



(Left) Axial US of the brain in this 3rd-trimester fetus shows obvious hydrocephalus with clot in the 3rd ventricle. Also note the thickened echogenic ependyma, a common finding with prior hemorrhage. **(Right)** Axial T1WI MR, in the same case, shows high signal material in the ventricles, confirming hemorrhage. T2WI is generally the most helpful sequence in a fetus, as it provides the most anatomic information. However, T1WI is very helpful when looking for blood products.



(Left) In this 34-week fetus with NAIT, there is an avascular cystic and solid left temporal lobe mass-like hemorrhage, which simulates a neoplasm. At delivery, neonatal platelet count was 5. **(Right)** Postnatal MR, in the same case, shows the hematoma with hemosiderin staining of the margin of the bleed and of the choroid plexus, confirming blood products. High T1 signal and lack of enhancement further substantiated a complex hematoma rather than neoplasm.

KEY FACTS

TERMINOLOGY

- Encephalomalacia
 - Regional brain parenchymal damage
- Porencephaly
 - Focal cavitory lesion in communication with ventricle

IMAGING

- Encephalomalacia findings often subtle; ventriculomegaly may be 1st clue
 - Affected periventricular white matter tracts have variable echogenicity
- Porencephalic cyst: Intraaxial, avascular, fluid-filled structure without mass effect

TOP DIFFERENTIAL DIAGNOSES






- Schizencephaly
- Arachnoid cyst
- Vascular malformation

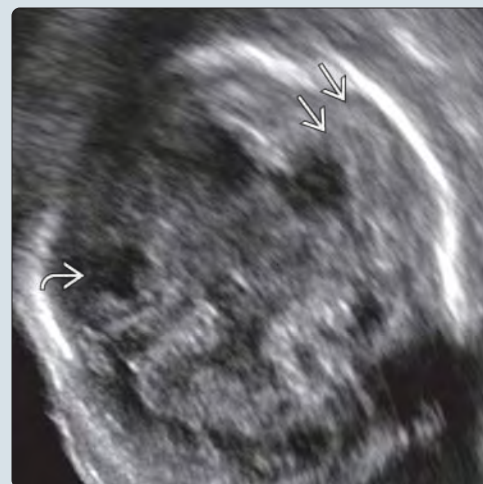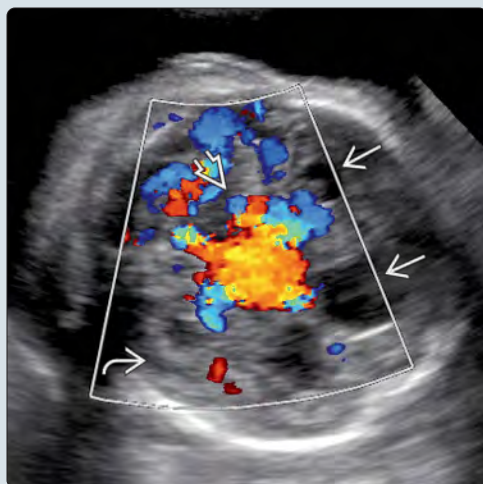
CLINICAL ISSUES




- Emergency delivery at time of acute event does not alter outcome
 - Apparently mild maternal trauma may cause devastating fetal cerebral injury
 - Monochorionic twin at risk if co-twin demise
 - Potential complication of fetal intervention
- Neurodevelopmental outcome generally poor
 - Severe developmental delay
 - Seizures, often refractory to anticonvulsant therapy

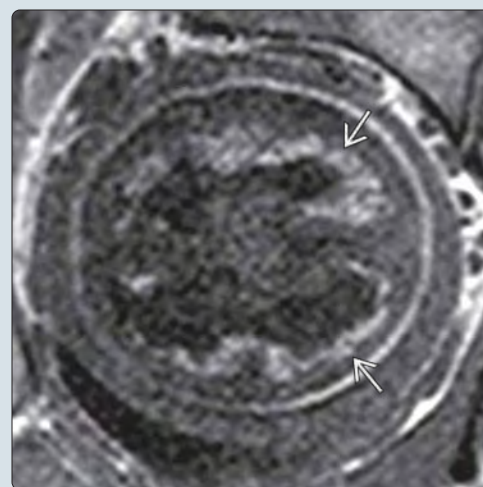
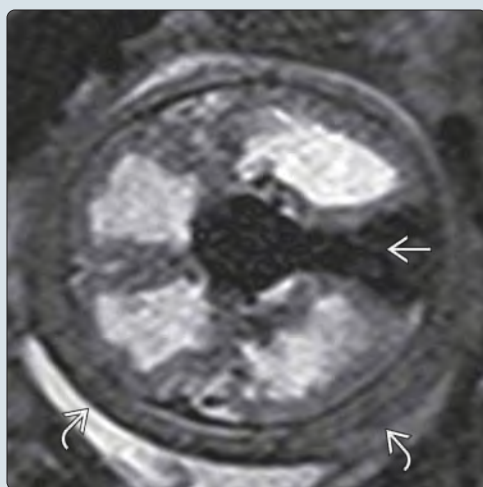
DIAGNOSTIC CHECKLIST

- Consider fetal MR in all suspicious cases and at-risk patients
 - US findings can be subtle despite severe damage
- Normal US at time of acute event does not exclude brain injury
 - Repeat imaging at 10-14 days from acute event
- Always check for flow in any apparently cystic lesion

(Left) Color Doppler US at 30-weeks gestation shows a vein of Galen malformation . The thin cerebral tissue  and ventriculomegaly  are evidence of associated ischemic encephalomalacia. **(Right)** Coronal US of the fetal brain in the same case confirms abnormal echogenicity of the cerebral mantle , absence of normal gyral and sulcal landmarks (the sylvian fissures should be well seen in this plane at this gestation), and ventriculomegaly .



(Left) Axial T2 HASTE MR in the 3rd trimester confirms diffuse cortical atrophy in the same fetus with ischemic encephalomalacia secondary to a vein of Galen malformation . Note the scalp edema ; the fetus was also hydropic due to high-output cardiac failure. **(Right)** Axial T1WI MR (same case) shows diffuse hemorrhage in the periventricular white matter . The infant expired within moments of delivery. Because the extent of the brain injury was known, the patient elected no intervention for the infant.



TERMINOLOGY

Definitions

- **Encephalomalacia**
 - Regional brain parenchymal damage
- **Porencephaly**
 - Focal cavitary lesion in communication with ventricle

IMAGING

General Features

- Best diagnostic clue
 - Encephalomalacia
 - Ventriculomegaly often 1st clue
 - Porencephalic cyst
 - Intraaxial, avascular, fluid-filled structure without mass effect

Ultrasonographic Findings

- **Encephalomalacia**
 - Hydrocephalus
 - Parenchymal destruction → increased cerebrospinal fluid (CSF) spaces
 - Hemorrhage → ependymitis → obstructed CSF flow
 - Periventricular white matter (PVWM) echogenicity may be normal or increased
 - Often normal at time of acute event
 - Edema, hemorrhage occur as response to insult
 - Diffuse increased PVWM echogenicity
 - Loss of normal architecture
 - Periventricular leukomalacia results in Swiss cheese appearance to PVWM
 - Late finding
 - Result of glial response to injury
- **Porencephalic cyst**
 - Round or irregular-shaped cyst in communication with ventricular system
 - Avascular
 - Vascular malformations may be associated with ischemic encephalomalacia
 - Always check for flow in any apparently cystic structure
 - No mass effect as it forms in area of destroyed brain
 - True cysts (e.g., arachnoid) are space occupying, displace adjacent brain
 - Findings evolve over time
 - Initial periventricular hemorrhagic infarction → echogenic mass
 - Echogenic mass of infarcted brain starts to resorb → mixed echogenicity debris, focal expansion of adjacent ventricle
 - Eventually anechoic cavity → cyst in communication with ventricle

MR Findings

- T1WI
 - Increased signal in areas of hemorrhage
- T2WI
 - **Encephalomalacia**
 - Diffusely abnormal high T2 signal in brain parenchyma indicates edema

- Foci of low T2 signal may represent areas of hemorrhage or calcification

- **Porencephaly**

- Cavity usually communicates with ventricles
- Cyst fluid follows CSF signal
 - Blood products from antecedent hemorrhage high T1, low T2
 - Hemosiderin deposition leaves tell-tale low-signal rim on T2WI

- DWI
 - Increased sensitivity for ischemia
 - Ongoing research for utility in fetus

Imaging Recommendations

- Best imaging tool
 - MR best for demonstration of blood products, parenchymal destruction
- Look for vascular malformation
 - Vascular steal ± venous hypertension → parenchymal destruction
 - Vein of Galen malformation
 - Dural arteriovenous fistula
- Check for placental abruption
 - Include placental bed in scout view for fetal MR
 - Abruption easier to see on MR than US due to signal changes of clot; US findings may be subtle
- Look for signs of infection
 - Liver or intracranial calcifications
 - Hepatosplenomegaly
 - Hydrops
- Check for ischemic injury elsewhere
 - Fetal hypotension has systemic impact; heart, kidneys very susceptible to ischemic injury as well as brain
 - Look for progressive cardiomegaly
 - Monitor amniotic fluid volume

DIFFERENTIAL DIAGNOSIS

Schizencephaly

- Wedge-shaped cortical cleft, lined with gray matter
 - Porencephalic defect is destructive therefore **not** gray matter lined

Arachnoid Cyst

- Extraaxial, displaces adjacent brain
 - May be associated with other structure brain malformations (e.g., agenesis corpus callosum)
 - Cause hydrocephalus by mass effect (e.g., kinked foramen of Monro)

Vascular Malformation

- Flow on Doppler interrogation

PATHOLOGY

General Features

- Etiology
 - Fetal cerebral hypoperfusion
 - Monochorionic twin demise
 - Surviving twin has > 20% risk for cystic encephalomalacia
 - Vascular steal from arteriovenous malformation

- Fetal intervention (e.g., intrauterine transfusion, twin vessel laser coagulation)
 - 4-7% incidence of severe neonatal cerebral lesions seen in cohort of liveborn infants following laser treatment for twin-twin transfusion
 - Premature delivery is major risk factor rather than laser therapy itself
 - 21% incidence central nervous system injury in 33 patients with fetal surgery
- Maternal causes
 - Hypotension
 - Maternal trauma may cause acute, severe fetal hypotension
 - Significant fetal injury can occur despite successful maternal resuscitation
 - **Must** scan 10-14 days following acute event
 - Hypoxia
 - Drug use, especially cocaine
- Infection
 - TORCH (congenital fetal infection)
 - Chorioamnionitis
 - Particularly if premature rupture of membranes with > 48 hr to delivery
- Metabolic (e.g., homozygous methylenetetrahydrofolate reductase mutation)
- Teratogen exposure (e.g., vitamin A)
- Fetomaternal alloimmune thrombocytopenia
 - Maternal antibodies to fetal platelet antigens inherited from father
 - 7-26% FMAIT cases develop intracranial hemorrhage
 - ~ 80% intrauterine
 - ~ 40% occur < 30 weeks of gestation
- *COL4A1/A2* mutations
 - Autosomal dominant, variable phenotype, incomplete penetrance
 - Porencephaly, small-vessel disease with hemorrhagic stroke, leukoencephalopathy
 - Hereditary angiopathy with nephropathy, aneurysms and muscle cramp syndrome
 - Walker-Warburg syndrome
 - If fetal intracranial hemorrhage and fetal cataracts think *COL4A1/A2* mutation

Gross Pathologic & Surgical Features

- Encephalomalacia
 - Diffuse brain insult
 - Astrocytic proliferation, glial septations
 - Multiple small parenchymal defects appear cystic defects
 - Can have calcifications
 - Not in communication with CSF spaces
 - May have shaggy walls
- Porencephaly
 - Focal destruction of normal parenchyma
 - Usually unilateral
 - Surrounding brain structural normal
 - Smooth-walled cavity
 - Minimal glial reaction

CLINICAL ISSUES

Presentation

- Ventriculomegaly may be presenting feature in encephalomalacia
- Porencephaly presents as debris or CSF-filled space in fetal cranium
 - Debris earlier, evolves to CSF-filled space over time

Demographics

- Epidemiology
 - Rare

Natural History & Prognosis

- Neurodevelopmental outcome generally poor
 - Severe developmental delay
 - Seizures, often refractory to anticonvulsant therapy

Treatment

- Screen for infection, bleeding diathesis
- Offer termination/nonintervention in labor (encourage autopsy for definitive diagnosis)
- Emergency delivery at time of acute event does not alter outcome, just adds risks of prematurity
- Postnatal cyst uncapping/fenestration may help
 - Hemiparesis improved in 30%
 - Severe seizures resolved in 62%, improved in 24%
- Functional imaging allows for individualized surgical planning for resection
 - Minimizes volume resected, spares areas recruited for new functionality

DIAGNOSTIC CHECKLIST

Consider

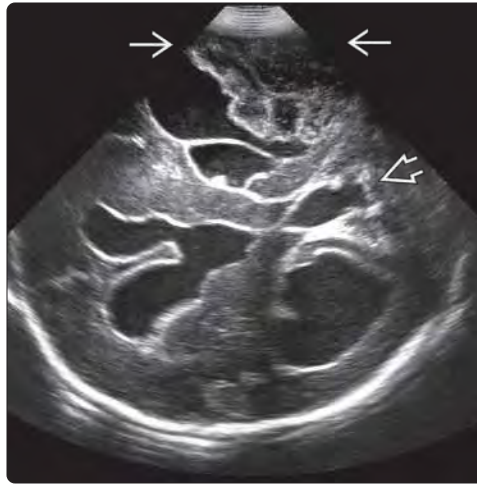
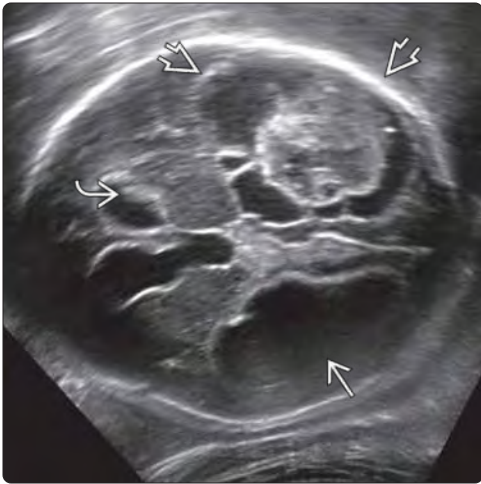
- Fetal MR in all suspicious cases and at-risk patients
- US findings can be subtle despite severe damage

Image Interpretation Pearls

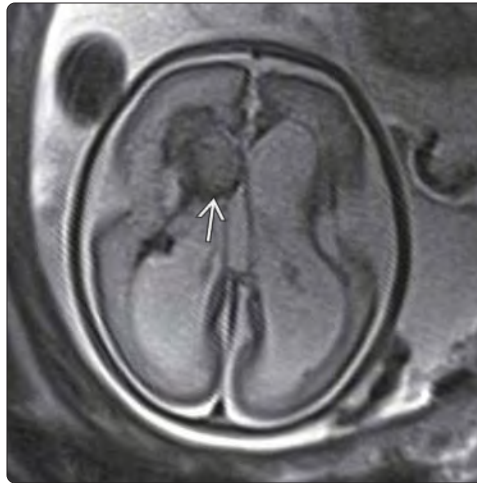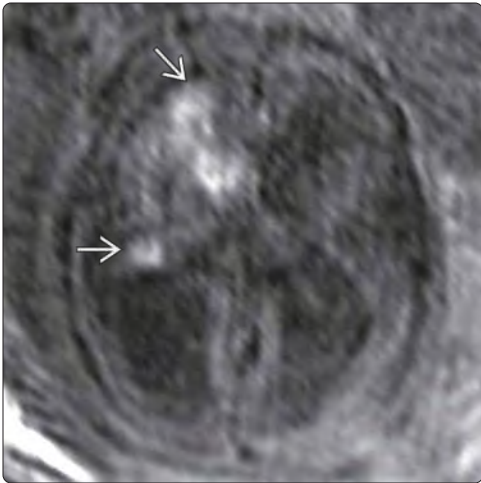
- Normal US at time of acute event does not exclude brain injury
 - Scan at 10-14 days from acute event
- Always check for flow in any apparently cystic lesion
 - Vascular malformations may cause ischemic encephalomalacia

SELECTED REFERENCES

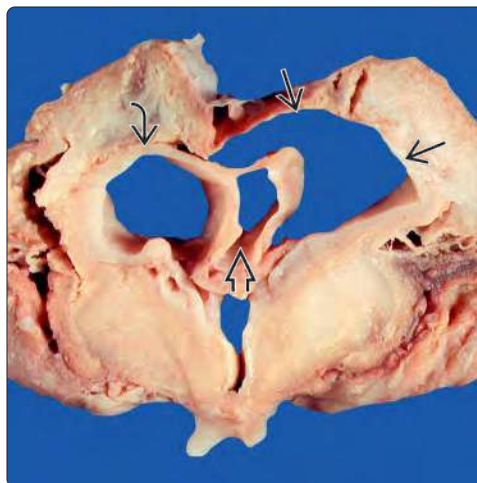
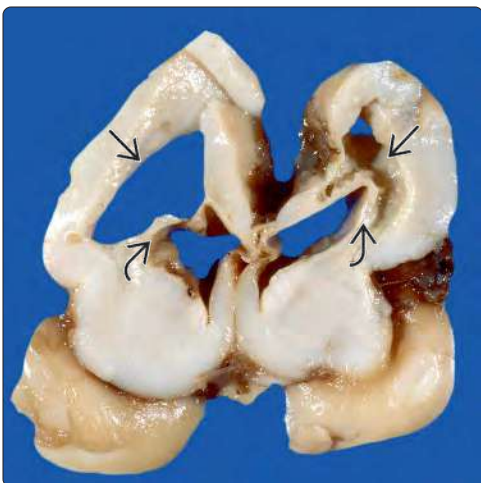
1. Giorgio E et al: Two families with novel missense mutations in COL4A1: When diagnosis can be missed. *J Neurol Sci.* 352(1-2):99-104, 2015
2. Takenouchi T et al: Porencephaly in a fetus and HANAC in her father: variable expression of COL4A1 mutation. *Am J Med Genet A.* 167A(1):156-8, 2015
3. Williams T et al: Antenatal diagnosis of intracranial haemorrhage and porencephalic cyst. *BMJ Case Rep.* 2015, 2015
4. Colin E et al: Fetal intracerebral hemorrhage and cataract: think COL4A1. *J Perinatol.* 34(1):75-7, 2014
5. Spruijt M et al: Cerebral injury in twin-twin transfusion syndrome treated with fetoscopic laser surgery. *Obstet Gynecol.* 120(1):15-20, 2012
6. Vanderbilt DL et al: Prevalence and risk factors of cerebral lesions in neonates after laser surgery for twin-twin transfusion syndrome. *Am J Obstet Gynecol.* 207(4):320.e1-6, 2012
7. Kokkinos V et al: Hemispherotomy or lobectomy? The role of presurgical neuroimaging in a young case of a large porencephalic cyst with intractable epilepsy. *Pediatr Neurosurg.* 47(3):204-9, 2011
8. Kim DH et al: Diffusion-weighted imaging of the fetal brain in vivo. *Magn Reson Med.* 59(1):216-20, 2008



(Left) Axial fetal US shows ventriculomegaly, clot in the frontal horn, and a large amount of debris and clot within a porencephalic cavity in the parietal lobe. (Right) Mastoid view neonatal head US in the same case confirms extensive parenchymal destruction and dilation of the entire ventricular system indicates a dilated 4th ventricle.



(Left) Axial T1WI MR in a surviving monozygotic twin 2 weeks after co-twin death shows periventricular hemorrhagic infarction. (Right) Axial T2WI, in the same case, confirms intraventricular clot, ventriculomegaly, and diffuse abnormal cortical signal, indicating diffuse ischemic encephalomalacia as a consequence of twin demise. The US images obtained at the time twin demise was diagnosed showed no definite abnormality. Early scans are often normal and follow-up is required.



(Left) Autopsy specimen shows confluent areas of white matter destruction secondary to periventricular hemorrhagic infarction. The cavities are shaggy and irregular. The adjacent ventricular walls are intact. (Right) A different autopsy specimen shows porencephaly from an in utero bleed. The right ventricular roof and cavum septi pellucidi are intact. The left ventricular wall has been completely destroyed, leaving 1 large, irregular, porencephalic cyst.

KEY FACTS

TERMINOLOGY

- Destruction of cerebral hemispheres

IMAGING

- Fluid-filled cranium with intact falx
- Preserved thalami, cerebellum, brainstem
- End stage is anechoic fluid replacing cerebral hemispheres
- MR excellent for differentiating absent from thinned, compressed cerebral cortex

TOP DIFFERENTIAL DIAGNOSES

- Alobar holoprosencephaly
 - Falx absent
- Aqueductal stenosis
 - Thin mantle of tissue compressed against cranium
 - Head size often very large
- Giant open-lip schizencephaly
 - Large, symmetric cortical defects lined by gray matter

PATHOLOGY

- Usually sporadic
- Fowler syndrome: Autosomal recessive, *FLVCR2* mutation
- Attributed to destruction of normal brain in distribution of carotid arteries
 - Medial temporal tissue may be present but never anterior temporal
 - Anterior temporal lobes supplied by carotid arteries
 - Medial temporal lobes supplied by basilar circulation

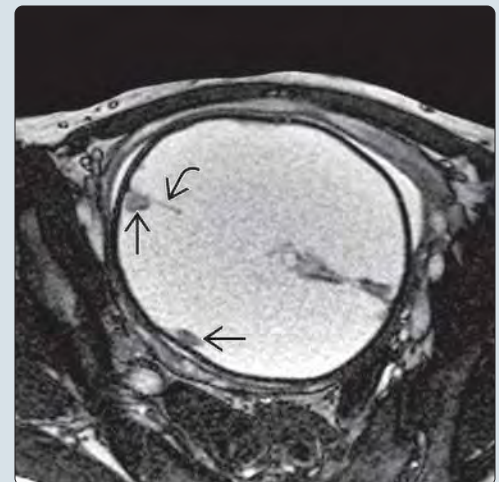
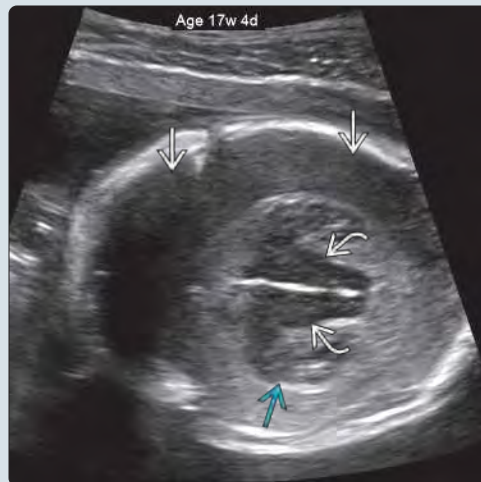
CLINICAL ISSUES

- Offer termination as prognosis is dismal
- If pregnancy continues avoid monitoring in labor or neonatal resuscitation

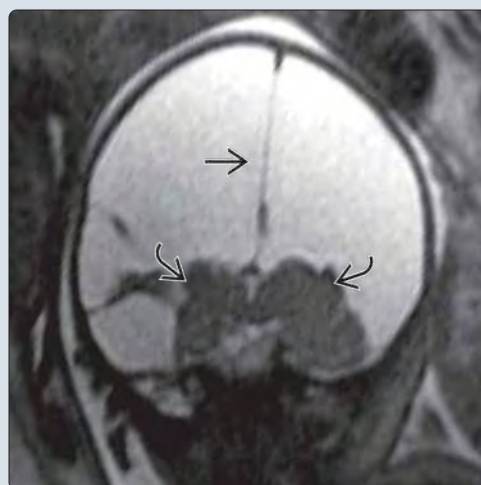
DIAGNOSTIC CHECKLIST

- Bulging brainstem may mimic fused thalami and be confused with holoprosencephaly

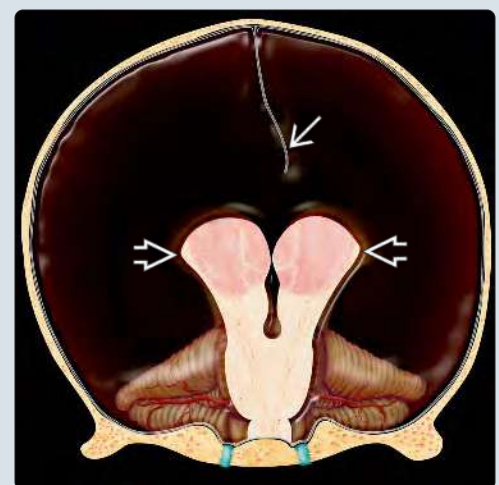
(Left) Axial US in the 2nd trimester shows the calvarium full of echogenic fluid as a result of liquefaction of the supratentorial brain. The thalami are preserved and there are fragments of medial cerebral hemisphere tissues. (Right) Axial T2WI MR in a different case shows the normal falx and only residual fragments of supratentorial brain. The lack of a normal cortical rind is the hallmark observation in hydranencephaly.



(Left) This patient was told that her baby had hydrocephalus and that she would need to deliver by C-section. The falx divides a fluid-filled calvarium with no cerebral tissue but preserved thalami. With the correct diagnosis of hydranencephaly (with dismal prognosis) labor was induced at 32 weeks to avoid operative delivery.



(Right) Coronal graphic shows absent cerebral hemispheres in hydranencephaly. The thalami, brainstem, and cerebellum are intact and the falx floats in the CSF-filled calvarium.



TERMINOLOGY**Definitions**

- Destruction of cerebral hemispheres

IMAGING**General Features**

- Best diagnostic clue
 - Fluid-filled cranium with intact falx

Ultrasonographic Findings

- Variable findings
 - Focal hemorrhage → echogenic mass
 - Global ischemia → loss of normal landmarks
 - Diffuse parenchymal destruction → liquefied brain → echogenic fluid
 - Occasional islands of residual tissue
 - End stage is anechoic fluid replacing cerebral hemispheres
- Preserved thalami, cerebellum, brainstem
 - Brainstem can bulge into supratentorial fluid; do not confuse with fused thalami in holoprosencephaly
- Structural survey usually normal apart from brain
- Head size usually normal
 - Macrocephaly may occur if continued cerebral spinal fluid (CSF) production with lack of resorption

MR Findings

- Excellent for differentiating absent from thinned, compressed cerebral cortex

DIFFERENTIAL DIAGNOSIS**Alobar Holoprosencephaly**

- Some cortical mantle present
- Absent falx
- Fused thalami
- Frequently associated with abnormal facies

Aqueductal Stenosis

- Cortical mantle thin but intact, may be extremely thinned
- Dilated lateral and 3rd ventricles
- Head often very large

Open-Lip Schizencephaly

- Bilateral giant open lip may mimic hydranencephaly
 - Large symmetric cortical defects lined by gray matter

PATHOLOGY**General Features**

- Etiology
 - Attributed to destruction of normal brain
 - Occurs in distribution of carotid arteries
 - Tissues supplied by posterior cerebral arteries usually preserved
 - Collateral blood flow from vertebrobasilar system through posterior communicating arteries protective
- Genetics
 - Usually sporadic

- Fowler syndrome: Autosomal recessive, *FLVCR2* mutation
 - Hydranencephaly, ischemic lesions of brain stem, basal ganglia, and spinal cord
 - Glomeruloid vasculopathy of CNS and retinal vessels
 - Fetal akinesia deformation sequence with muscular neurogenic atrophy

Gross Pathologic & Surgical Features

- Cerebral hemispheres replaced by thin sacs containing CSF and necrotic debris
- Small portions of frontal, temporal, occipital lobes may be preserved
- Preserved thalamus, cerebellum, brainstem

CLINICAL ISSUES**Demographics**

- Epidemiology
 - 1-2 per 10,000 live births
 - Scattered case reports of hemihydranencephaly

Natural History & Prognosis

- Prognosis is dismal
 - 50% of liveborn infants die in 1st month
 - 85% mortality by end of 1st yr
 - Occasional long-term survivors with no cognitive function

Treatment

- Offer termination
- If pregnancy progresses
 - No monitoring in labor or neonatal resuscitation
- If macrocephaly, consider cephalocentesis to allow vaginal delivery
 - Avoids morbidity of C-section, especially extended incision

DIAGNOSTIC CHECKLIST**Consider**

- Fetal MR can be used to confirm diagnosis

Image Interpretation Pearls

- Anterior temporal lobes supplied by carotids, medial temporal lobes by basilar circulation
 - In hydranencephaly medial temporal tissue may be present but never anterior temporal
- Bulging brainstem may mimic fused thalami and be confused with holoprosencephaly
 - Important as different recurrence risk
 - Hydranencephaly is sporadic apart from rare Fowler syndrome
 - Holoprosencephaly recurrence risk is quoted at 6%

SELECTED REFERENCES

1. Cecchetto G et al: Looking at the missing brain: hydranencephaly case series and literature review. *Pediatr Neurol.* 48(2):152-8, 2013
2. Ghosh PS et al: Fetal magnetic resonance imaging in hydranencephaly. *J Paediatr Child Health.* 49(4):335-6, 2013
3. Sepulveda W et al: Prenatal sonography in hydranencephaly: findings during the early stages of disease. *J Ultrasound Med.* 31(5):799-804, 2012
4. Meyer E et al: Mutations in *FLVCR2* are associated with proliferative vasculopathy and hydranencephaly-hydrocephaly syndrome (Fowler syndrome). *Am J Hum Genet.* 86(3):471-8, 2010

KEY FACTS

TERMINOLOGY

- Narrowing or occlusion at aqueduct of Sylvius, causing obstructive hydrocephalus
 - Causes increased intraventricular pressure

IMAGING

- Moderate to severe ventricular dilatation (> 15 mm)
- Dilatation may be so extreme that normal ventricular anatomy may not be discernible
- Dangling choroid
- Double dangle
 - Choroid from opposite side may fall through dilated foramen of Monroe into dependent ventricle
- Head size often large
- Normally formed posterior fossa
 - Cerebellum may be compressed by supratentorial ventriculomegaly
- Corpus callosum often thinned or not visible
- Cavum septi pellucidi may be absent

- MR gives more precise anatomic evaluation of aqueduct, thinned cortical mantle, and subtle CNS malformations
- Consider X-linked hydrocephalus in male fetus
 - Carefully assess hands for adduction-flexion deformity of thumbs

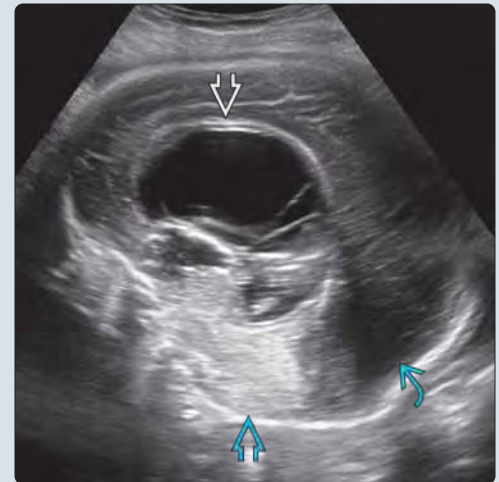
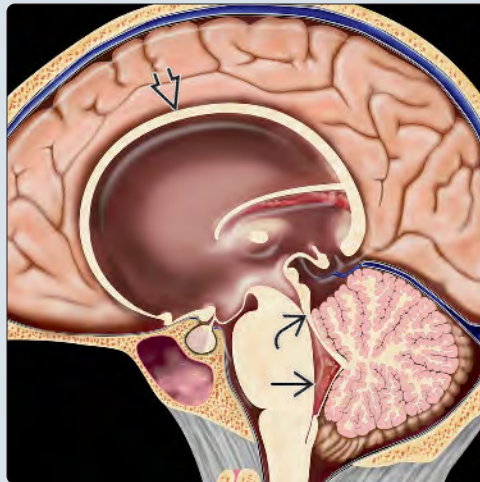
TOP DIFFERENTIAL DIAGNOSES

- Hydranencephaly
- Holoprosencephaly

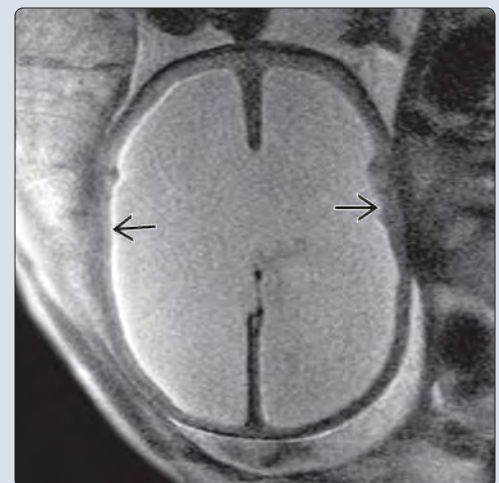
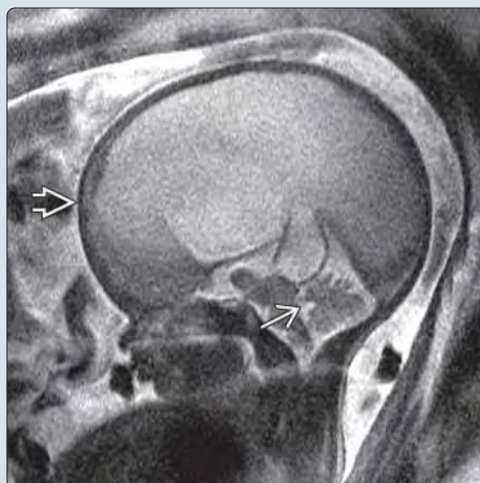CLINICAL ISSUES

- Developmental delay in up to 90%
- X-linked hydrocephalus → severe intellectual impairment
 - 50% recurrence risk for male fetuses
- 4% recurrence risk for non-X-linked cases
- Genetic counseling for future pregnancies
- Ventricular shunting or endoscopic 3rd ventriculostomy after delivery

(Left) Sagittal midline graphic of aqueductal stenosis (AS) shows a markedly enlarged 3rd ventricle, stretched (thinned) corpus callosum, and a funnel-shaped, narrowed cerebral aqueduct. Note the normal 4th ventricle. (Right) This midline sagittal ultrasound of a fetal brain at 29 weeks shows a similar appearance with a stretched corpus callosum. A portion of the dilated occipital horn is seen. The mass effect of the supratentorial ventricular dilatation is compressing the cerebellum.



(Left) Sagittal T2WI MR shows severe hydrocephalus. Dilatation is so severe that normal ventricular anatomy is not discernible. Note the markedly enlarged cranium as compared to the face. The posterior fossa is normal, including a well-seen normal 4th ventricle and vermis. (Right) Axial T2WI MR shows symmetrically thinned parenchyma compressed against the calvarium. MR can be very helpful in evaluating the remaining cortical mantle and to distinguish AS from hydranencephaly and porencephaly.



TERMINOLOGY

Abbreviations

- Aqueductal stenosis (AS)

Definitions

- Narrowing or occlusion at aqueduct of Sylvius causing obstructive hydrocephalus
- Hydrocephalus vs. ventriculomegaly
 - **Hydrocephalus**
 - Increased intraventricular pressure
 - Increased ventricular size
 - Increased head size
 - Noncommunicating (obstructive)
 - CSF flow blocked within ventricular system
 - Communicating
 - Failure of CSF resorption
 - **Ventriculomegaly**
 - Result of abnormal parenchymal development or destructive process
 - Normal intraventricular pressure
 - Increased ventricular size
 - Head size normal or small

IMAGING

General Features

- Best diagnostic clue
 - Hydrocephalus with normal posterior fossa
- Location
 - Aqueduct of Sylvius
 - Connects 3rd and 4th ventricles
 - More proximal stenoses cause greater hydrocephalus
- Size
 - Normal diameter of aqueduct at birth: 0.5 mm² (range: 0.2-1.8 mm²)
 - Narrowest portion of ventricular system

Ultrasonographic Findings

- Moderate to severe ventricular dilatation (> 15 mm)
 - Often extreme
 - Cortical mantle thinned
 - May be severe, mimicking hydranencephaly
- Dangling choroid
 - Choroid plexus does not fill lateral ventricle
- Double dangle
 - Choroid from opposite side may fall through dilated foramen of Monroe into dependent ventricle
- 3rd ventricle dilated
 - Dilatation may be so extreme that normal ventricular anatomy may not be discernible
- Posterior fossa normal
 - 4th ventricle is not dilated
 - Cerebellum may be inferiorly displaced and cisterna magna obliterated with severe hydrocephalus
 - Chiari 1 appearance
- Corpus callosum often thinned or not visible
- Cavum septi pellucidi (CSP) may be absent
 - Severe hydrocephalus causes fenestrations within walls of CSP
- Head size often large

- May cause severe macrocephaly
- Color Doppler
 - Look for flow in compressed cerebral mantle
 - Follow middle cerebral artery (MCA)
- Additional findings in **X-linked hydrocephalus**
 - Male fetus
 - Adduction-flexion deformity of thumbs
 - Present in 50% of cases

MR Findings

- More precise anatomic evaluation
 - Better for assessing presence of thinned cortical mantle
 - Midline sagittal view best for evaluating aqueduct of Sylvius
 - May see aqueduct "funnel" to point of obstruction
 - Posterior fossa, 4th ventricle are normal
 - 3rd ventricle dilated with displacement of both roof and floor
 - Corpus callosum thinned
 - Periventricular interstitial edema may be present
 - Evaluate for other brain anomalies
- Pitfall: Often see flow artifacts with very distended ventricles
 - CSF is turbulent within obstructed systems

Imaging Recommendations

- Use endovaginal probe if head is cephalic
- Fetal MR adds valuable information in most cases
- Rule out other causes of ventriculomegaly
 - Posterior fossa images of critical importance
 - Normal in AS, although can be compressed if hydrocephalus is severe
 - Often abnormal with other malformations
- Carefully assess remaining cortical mantle
 - Differentiates AS from destructive lesions or other congenital malformations
 - Doppler to look for flow in MCA and compressed parenchyma
- Be suspicious of X-linked form
 - Document gender
 - Carefully image hands
 - Adducted thumbs have been reported in 1st trimester
- Complete genetic work-up and amniocentesis
- Follow-up scans every 2-3 weeks for progression
- If history of prior child with AS, continue to follow even if initial scans are normal
 - Hydrocephalus may not develop until late in pregnancy or neonatal period

DIFFERENTIAL DIAGNOSIS

Hydranencephaly

- No cerebral tissue
 - Doppler: Absent anterior/MCA flow
 - MR may be necessary for confirmation
- Head size usually normal

Holoprosencephaly

- Absent falx
- Fused thalami
- Facial malformations often present

- Head size often small

Chiari 2 Malformation

- Hindbrain herniation with posterior fossa compression
 - Obliteration of cisterna magna
 - Cerebellum curves around midbrain (banana sign)
- Frontal bone concavity (lemon sign)
- Myelomeningocele
- Ventriculomegaly
 - Usually borderline or mild
- Head size not typically large

Encephalomalacia/Porencephaly

- Destructive process of brain parenchyma
- Most commonly ischemic or infectious etiology
- Focal areas of destruction
- Progressive ventriculomegaly
- Head size not enlarged

PATHOLOGY

General Features

- Etiology
 - Incompletely understood and likely multifactorial
 - Stenosis may result from developmental, inflammatory, or infectious causes
 - Disruption of ependymal lining
 - White matter edema
 - Gliosis and fibrosis (irreversible at this point)
 - Infections: Cytomegalovirus, toxoplasmosis, rubella, influenza, mumps, syphilis
 - Hemorrhage and tumors also implicated
- Genetics
 - Most sporadic
 - **X-linked hydrocephalus** (Bickers-Adams syndrome)
 - ~ 7% of AS cases in males
 - Single gene disorder caused by mutation in neural cell adhesion molecule-encoding *L1CAM* (L1) gene
 - Males
 - Adducted thumbs
 - Severe intellectual impairment
- Associated abnormalities
 - CRASH: **C**allosal hypoplasia, **m**ental retardation, **a**dducted thumbs, **s**pastic paraplegia, **X**-linked hydrocephalus
 - MASA: **M**ental retardation, **a**phasia, **s**huffling gait, **a**dducted thumbs
 - 30% may have extracranial abnormalities
- Pathophysiology
 - Aqueductal lumen normally decreases throughout gestation
 - Narrowing secondary to growth of adjacent mesencephalic structures
 - AS obstructs normal CSF flow
 - CSF production continues in lateral and 3rd ventricles
 - Ventricular fluid pressure increases (intracranial hypertension) compressing adjacent parenchyma, stretching corpus callosum
 - Pressure may disrupt ependymal cell junctions, causing periventricular edema, axonal shear, and gliosis

CLINICAL ISSUES

Presentation

- Most common signs/symptoms
 - Hydrocephalus on routine obstetrical US
- May have history of prior child with AS
 - Hydrocephalus may not be seen until 3rd trimester or neonatal period

Demographics

- M:F = 2:1
- 0.3-1.5:1,000 births
- ~ 20% of congenital hydrocephalus cases

Natural History & Prognosis

- 10-30% neonatal mortality
- Developmental delay in up to 90%
- X-linked hydrocephalus → severe intellectual impairment
 - 50% recurrence risk for male fetuses (females may be carriers)
- 4% recurrence risk for non-X-linked cases

Treatment

- Amniocentesis
 - Karyotype
 - Infection screen
- Large head size may cause dystocia
- Genetic counseling for future pregnancies
- Fetal shunting abandoned but now renewed interest with better, more accurate diagnosis and improved techniques
 - Preliminary research being performed
- Postnatal
 - Ventricular shunting
 - Thickness of cortical mantle improves after shunting
 - Endoscopic 3rd ventriculostomy
 - Small perforation made in thinned floor of 3rd ventricle
 - Allows movement of CSF out of blocked ventricular system into interpeduncular cistern (normal CSF space)
 - Risk of injury to surrounding structures

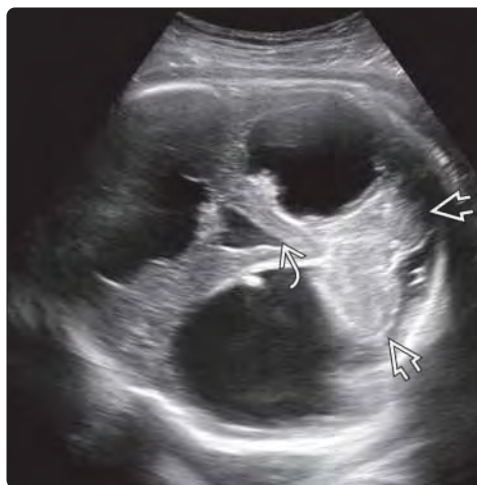
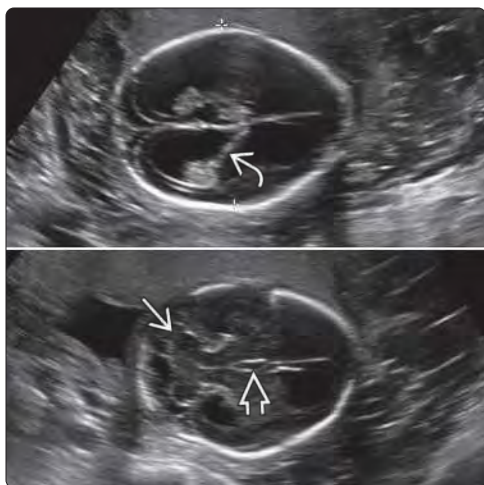
DIAGNOSTIC CHECKLIST






Image Interpretation Pearls

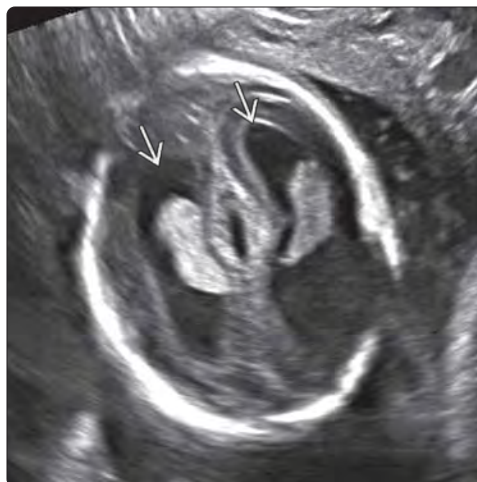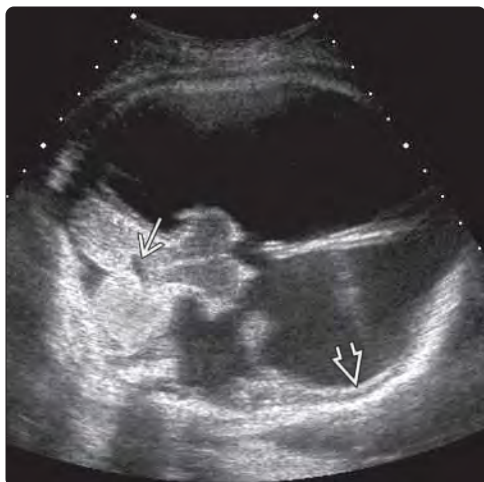- Careful search for other anatomic causes of hydrocephalus before AS is diagnosed




SELECTED REFERENCES

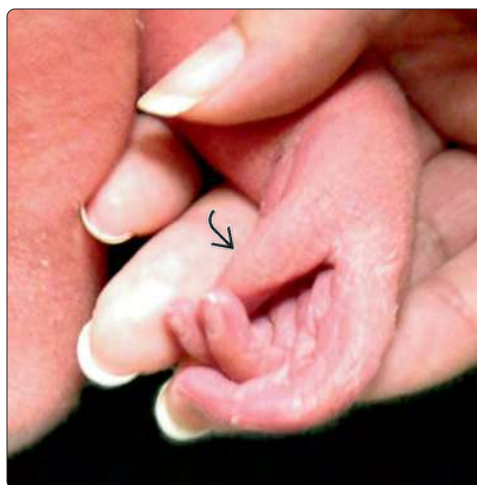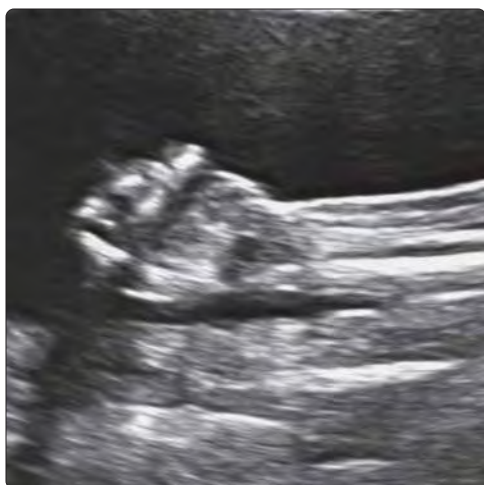1. Corral E et al: Prenatal three-dimensional ultrasound detection of adducted thumbs in X-linked hydrocephaly: two case reports with molecular genetic studies. *Case Rep Obstet Gynecol.* 2015;561713, 2015
2. Emery SP et al: Fetal therapy for isolated aqueductal stenosis. *Fetal Diagn Ther.* 38(2):81-5, 2015
3. Emery SP et al: Accuracy of prenatal diagnosis of isolated aqueductal stenosis. *Prenat Diagn.* 35(4):319-24, 2015
4. Serikawa T et al: Prenatal molecular diagnosis of X-linked hydrocephalus via a silent C924T mutation in the L1CAM gene. *Congenit Anom (Kyoto).* 54(4):243-5, 2014
5. Whitehead MT et al: Rhombencephalosynapsis as a cause of aqueductal stenosis: an under-recognized association in hydrocephalic children. *Pediatr Radiol.* 44(7):849-56, 2014
6. Spennato P et al: Endoscopic third ventriculostomy for idiopathic aqueductal stenosis. *World Neurosurg.* 79(2 Suppl):S21.e13-20, 2013




(Left) This 17-week fetus has marked ventriculomegaly (note the dangling choroid ). On the posterior fossa view, the cerebellum is normal , but there is dilation of the 3rd ventricle  (note this is too far posterior to be the CSP). Even at this early gestational age, the head was measuring 10 days ahead of the other measurements. **(Right)** The same fetus at 29 weeks shows severe hydrocephalus with the 3rd ventricle "funneling" to a point  at the aqueduct of Sylvius. The cerebellum  is normal, an important feature of AS.



(Left) Axial oblique ultrasound through the posterior fossa in a more severe case of AS shows a very thinned, compressed cortical mantle  but a normal cerebellum and 4th ventricle , indicating the point of obstruction is above this level at the aqueduct of Sylvius. **(Right)** Axial transvaginal ultrasound shows bilateral mild ventriculomegaly  at 20 weeks. This fetus was male and had a sibling with X-linked AS.



(Left) Longitudinal ultrasound of the upper extremity in the same fetus shows a clenched hand. Neither hand ever opened, and the thumbs were adducted. This finding is strongly suggestive of recurrent X-linked AS, which was confirmed with genetic testing. This condition is associated with severe intellectual impairment and carries a 50% recurrence risk in male fetuses. **(Right)** Clinical photograph of the hand shows the typical adducted position of the thumb  as seen in X-linked hydrocephalus.

KEY FACTS

TERMINOLOGY

- Small posterior fossa with cerebellar compression and hindbrain herniation through foramen magnum
- Open neural tube defect (ONTD) almost always present

IMAGING

- Posterior fossa compression is key finding
 - Small or obliterated cisterna magna
 - Banana sign when severe
- Ventriculomegaly
 - 55% at diagnosis and > 90% at delivery
- Frontal bone concavity (lemon sign)
 - Nonspecific and transient
- Associated supratentorial anomalies common and seen best with MR
- Can be diagnosed in 1st trimester
 - Loss of intracranial translucency is clue to diagnosis at time of nuchal translucency scan

TOP DIFFERENTIAL DIAGNOSES

- Aqueductal stenosis
 - Progressive ventriculomegaly with macrocephaly
 - Cisterna magna not obliterated
- Small cerebellum from other causes
 - Cerebellar hypoplasia
 - Rhombencephalosynapsis

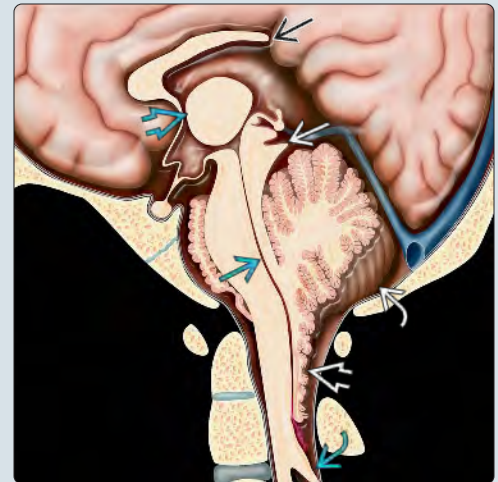
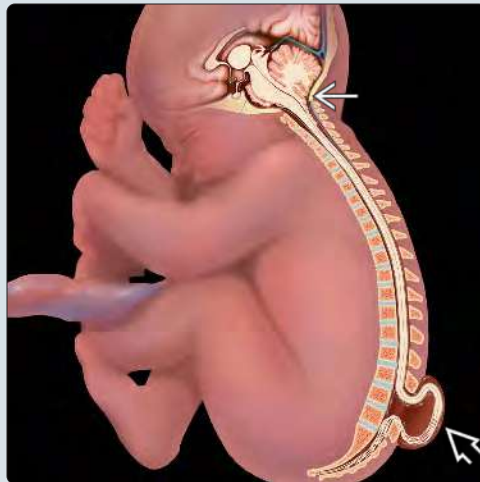
CLINICAL ISSUES

- ↑ maternal serum α-fetoprotein
- Offer genetic counseling/testing
- Cesarean section delivery at term
- Immediate postnatal ONTD surgery
- 80% need ventriculoperitoneal shunt

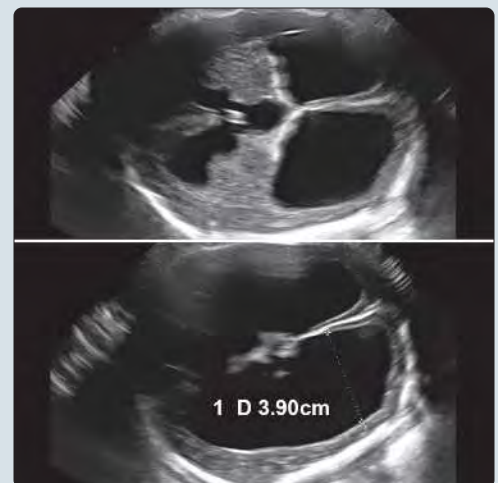
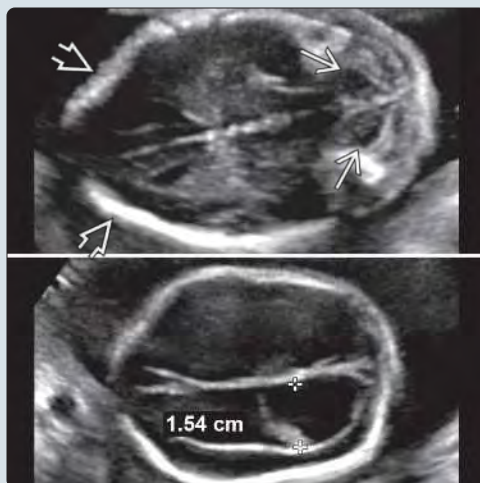
DIAGNOSTIC CHECKLIST

- Obliteration of cisterna magna is best clue
 - Do not wait for banana sign to diagnose Chiari 2
- Look meticulously for ONTD when Chiari 2 seen

(Left) Sagittal view of Chiari 2 malformation shows the hallmark finding of hindbrain herniation with a lumbar meningomyelocele. (Right) A detailed hindbrain view shows inferior displacement of the cerebellum, 4th ventricle compression, and obliteration of the cisterna magna. Other findings include callosal dysgenesis, tectal beaking, an enlarged massa intermedia, and a medullary spur at the cervicomedullary junction. With improving fetal MR, many of these more subtle findings can now be seen.



(Left) Classic features of Chiari 2 on routine axial views of the midgestation fetal brain include cerebellar compression (banana sign), frontal bone concavity (lemon sign), and ventriculomegaly (calipers). (Right) On follow-up, in the same case, the frontal concavity has resolved and the ventriculomegaly has worsened. Progressive ventriculomegaly is common with Chiari 2, most likely because of progressive compressive pressure on the 4th ventricle.



TERMINOLOGY**Definitions**

- Small posterior fossa with cerebellar compression and hindbrain herniation through foramen magnum
- Almost always associated with open neural tube defect (ONTD), typically lumbar meningocele

IMAGING**General Features**

- Best diagnostic clue
 - Cerebellar compression
 - Loss of cisterna magna (CM)
 - Banana sign if cerebellum wraps around midbrain
 - Frontal bone concavity (lemon sign)
 - Ventriculomegaly
 - ONTD

Ultrasonographic Findings

- **Posterior fossa** compression variable
 - Small or obliterated CM is most important finding
 - Seen on routine axial posterior fossa view
 - CM < 3 mm is considered small
 - Compressed cerebellum
 - Cerebellum loses bilobed shape
 - Cerebellum pressed against occiput
 - Severe compression leads to banana sign
 - Cerebellum curves around midbrain
 - Absent cerebellum rarely seen
 - Complete herniation through foramen magnum
- **Ventriculomegaly:** 55% of cases at time of diagnosis
 - Often progresses during pregnancy
 - 90% with ventriculomegaly at birth
 - Variable head size progression
 - Most often normal or small
 - Macrocephaly if severe obstructive ventriculomegaly
- **Frontal bone concavity** (lemon sign)
 - Nonspecific finding (1% of all midgestation fetuses)
 - Transient finding regardless of ± ONTD
- **ONTD findings**
 - Dorsal vertebral defect (seen best on axial view)
 - Splayed dorsal ossification centers
 - No overlying skin
 - Coronal view best for evaluating extent
 - Sagittal view best for seeing sac
 - 80% with overlying sac
 - Myelomeningocele (complex sac) most common
 - Contains meninges with neural elements
 - Meningocele (simple anechoic sac)
 - Sac with meninges only
 - 20% of ONTD with no sac (more subtle)
 - Vertebral findings same as above with skin defect
 - Neural tissue directly exposed to amniotic fluid
 - Closed spina bifida (skin covered) most often without Chiari 2 findings
- **Associated findings**
 - 40% with additional anomalies
 - Supratentorial anomalies
 - Callosal dysgenesis

- Interhemispheric cyst
- Heterotopia
- Club foot (24%)
- Scoliosis, kyphosis, tethered spinal cord
 - Seen at level of ONTD
- 1st-trimester suggestion of Chiari 2 at time of nuchal translucency screening is possible by looking for intracranial translucency (IT)
 - Obliteration of IT suggests Chiari 2
 - Normal IT and CM fluid not present
 - Brain stem dorsally displaced
 - Confirm in early 2nd trimester

MR Findings

- MR allows more detailed evaluation of both brain and spine
- Tight posterior fossa
 - ↓ or loss of water signal space around hindbrain
 - Can see hindbrain herniation in multiple planes
- Additional brain findings
 - Dysgenesis/agenesis of corpus callosum
 - Abnormal gyri, heterotopia
 - Compressed "soda straw" 4th ventricle
 - "Beaked" tectum: Secondary to compression/deformation of quadrigeminal plate
 - Enlarged mass intermedia: Central adhesion between thalami, seen in 3rd ventricle
- Additional spine findings
 - Cervicomedullary "kink" with medullary "spur"
 - Cord syrinx
- Helpful for fetal surgery planning

Imaging Recommendations

- Best imaging tool
 - Routine 2nd-trimester views of fetal brain
 - Axial angled posterior fossa view
 - Look for normal bilobed cerebellum with CM
 - Axial lateral ventricle view
 - Measure ventricle at atria
 - Biparietal diameter view
 - Look at frontal bones
 - Targeted sagittal and coronal views are additive
 - Routine axial and longitudinal views of spine
- Protocol advice
 - Search meticulously for ONTD if Chiari 2 seen
 - ONTD is subtle when there is no sac
 - Use endovaginal US for better imaging
 - Cranial anatomy or spinal defect (cephalic vs. breech)
 - Follow-up for ventriculomegaly even if not present at time of diagnosis
 - Fetal MR for associated central nervous system findings

DIFFERENTIAL DIAGNOSIS**Aqueductal Stenosis**

- Obstruction of aqueduct of Sylvius
 - Noncommunicating hydrocephalus
- Posterior fossa remains normal
- Progressive severe hydrocephalus with macrocephaly

Rhombencephalosynapsis

- Small globular cerebellum

- Folia cross midline and vermis is absent
- Fluid-filled cisterna magna is present
- Not associated with ONTD

Cerebellar Hypoplasia

- Small cerebellum but not compressed
 - Bi-cerebellar diameter is small
- Might be asymmetric
- CM is not compressed

PATHOLOGY

General Features

- Etiology
 - Unified theory
 - Failed caudal neuropore closure → failed posterior fossa embryonic vesicle distention
 - Sequelae of small posterior fossa
 - Unable to contain developing cerebellum
 - Hindbrain herniation through foramen magnum
 - Cerebellar disorganization
 - Secondary ventriculomegaly
 - ONTD etiology
 - Mostly sporadic and multifactorial
 - Folate deficiency
 - Teratogens such as anticonvulsants
- Genetics
 - Aneuploidy rate with ONTD is 3-5%
 - Trisomy 18 (most common)

Staging, Grading, & Classification

- Chiari 1
 - Cerebellar tonsil herniation only
 - Rarely diagnosed prenatally
- Chiari 3
 - Hindbrain herniation with encephalocele
 - Low occipital/upper cervical bony defect

Gross Pathologic & Surgical Features

- Downward displacement of medulla oblongata, cerebellar tonsil, pons, and 4th ventricle
 - Cerebellar vermis and tonsils herniate inferiorly below foramen magnum

CLINICAL ISSUES

Presentation

- Most common signs/symptoms
 - ↑ maternal serum α -fetoprotein in 2nd trimester
 - > 2.5 multiples of median in 80% of ONTD

Demographics

- Ethnicity
 - Hispanic > Caucasian, African American, Asian
 - USA data
- Epidemiology
 - 0.4:1,000 births
 - 3% of all spontaneous abortions
 - 2-3% recurrence risk

Natural History & Prognosis

- High morbidity and mortality

- 35% liveborn die within 1st 5 years
- 50% with IQ > 80
- In utero findings do not predict outcome
- Obstructive hydrocephalus often needs shunting
- Musculoskeletal dysfunction depends on level of ONTD
 - 25% complete lower limb dysfunction
- Gastrointestinal/genitourinary dysfunction
 - Only 17% with normal continence

Treatment

- C-section delivery at term
 - ↓ infection rate
 - ↓ meningocele sac rupture rate
- Immediate postnatal ONTD surgery
 - Cover exposed spinal cord
- 80% need ventriculoperitoneal shunt
- In utero surgery may be considered
 - Performed at specialized fetal surgery centers
 - Chiari 2 can reverse
 - ↓ shunt dependence
 - 54% vs. 80%
 - Paralysis and continence rates unchanged
 - ↑ preterm delivery risk
- Preventive treatment with folic acid
 - Preconceptional therapy best
 - 4 mg/day reduces recurrence risk by 70% (high-risk dose)
 - 0.4 mg/day for all women (low-risk dose)

DIAGNOSTIC CHECKLIST

Consider

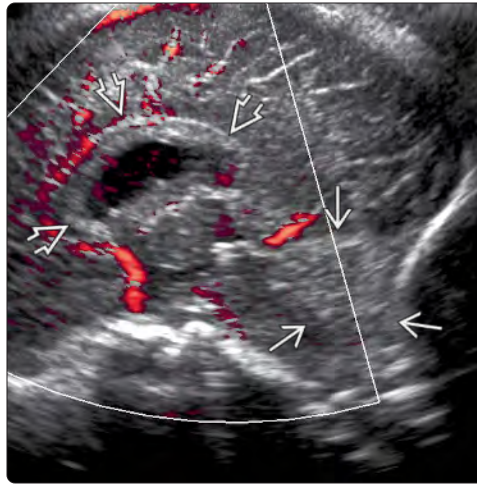
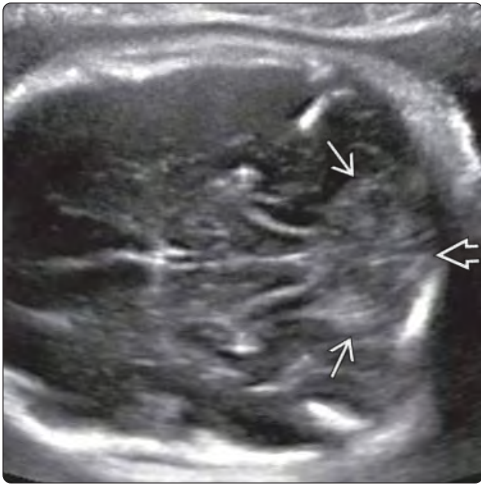
- Genetic amniocentesis
- Search for ONTD when Chiari 2 seen

Image Interpretation Pearls

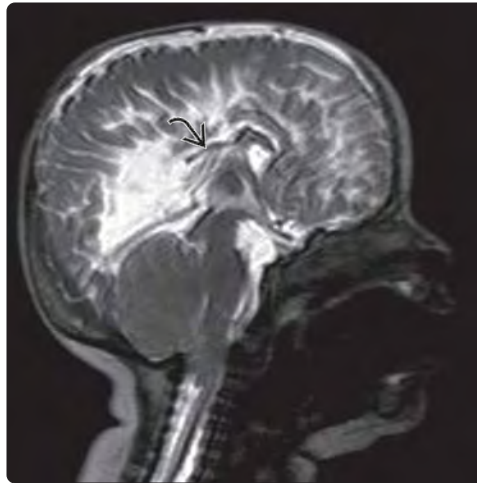
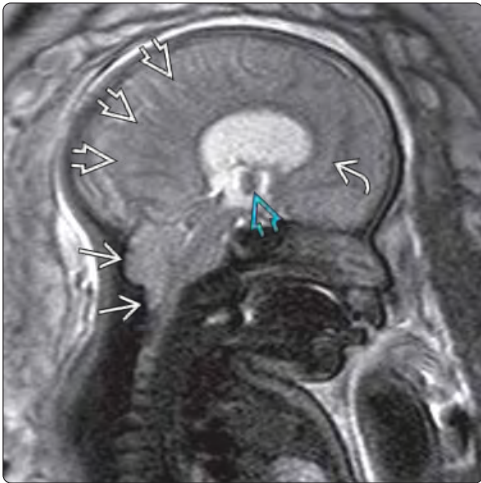- Compressed CM may be only finding in brain
 - Do not wait for banana sign and ventriculomegaly to make diagnosis
- Cranial findings easier to see than ONTD

SELECTED REFERENCES

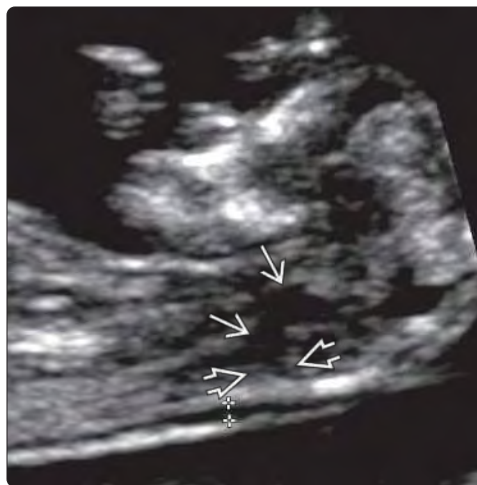
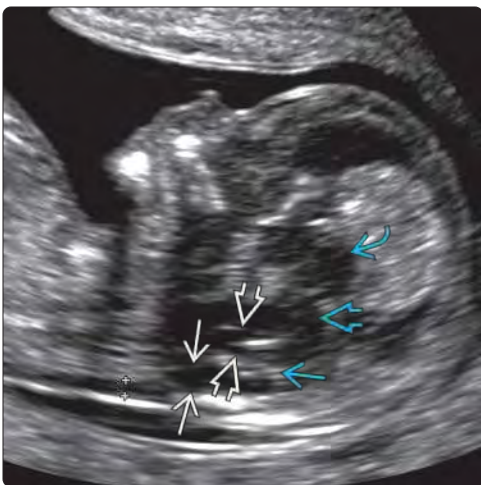
1. Chapman T et al: Diagnostic imaging of posterior fossa anomalies in the fetus and neonate: part 2, posterior fossa disorders. *Clin Imaging*. 39(2):167-175, 2015
2. Chaoui R et al: Prospective detection of open spina bifida at 11-13 weeks by assessing intracranial translucency and posterior brain. *Ultrasound Obstet Gynecol*. 38(6):722-6, 2011
3. Adzick NS: Fetal myelomeningocele: natural history, pathophysiology, and in-utero intervention. *Semin Fetal Neonatal Med*. 15(1):9-14, 2010
4. Chaoui R et al: Assessment of intracranial translucency (IT) in the detection of spina bifida at the 11-13-week scan. *Ultrasound Obstet Gynecol*. 34(3):249-52, 2009
5. D'Addario V et al: Comparison of six sonographic signs in the prenatal diagnosis of spina bifida. *J Perinat Med*. 36(4):330-4, 2008
6. Ando K et al: MRI tight posterior fossa sign for prenatal diagnosis of Chiari type II malformation. *Neuroradiology*. 49(12):1033-9, 2007
7. Fujisawa H et al: New ultrasonographic criteria for the prenatal diagnosis of Chiari type 2 malformation. *Acta Obstet Gynecol Scand*. 85(12):1426-9, 2006
8. Stevenson KL: Chiari Type II malformation: past, present, and future. *Neurosurg Focus*. 16(2):E5, 2004
9. Tubbs RS et al: Treatment and management of the Chiari II malformation: an evidence-based review of the literature. *Childs Nerv Syst*. 20(6):375-81, 2004



(Left) In this fetus with Chiari 2, the normal fluid-filled cisterna magna is obliterated and the cerebellum has lost its normal bilobed shape. (Right) A sagittal view obtained via endovaginal technique shows the cerebellum herniated inferiorly through the foramen magnum. The corpus callosum (CC) is normally developed. This fetus had subtle sacral spina bifida without a sac. It is imperative to notice the lack of fluid in the cisterna magna as a clue to Chiari 2 and not wait for the banana sign to make the correct diagnosis.



(Left) In utero MR in this fetus with known Chiari 2 shows cerebellar herniation. In addition, only the anterior cingulate gyrus is seen with radially oriented sulci posteriorly, which suggested dysgenesis of the CC. Also note the prominent massa intermedia in the enlarged 3rd ventricle. (Right) MR of the same child after spinal surgery and shunt placement confirms that the posterior CC is deficient. Chiari 2 is associated with other midline brain anomalies, most commonly involving the CC.



(Left) In this normal 13-week fetus, the normal intracranial translucency (IT) is the 4th ventricle, located behind the hypoechoic brainstem. The future cisterna magna is a 2nd lucency behind the echogenic linear choroid plexus within the 4th ventricle. The thalamus is also seen. (Right) In this 12-week fetus with spina bifida, the IT and cisterna magna are obliterated. The brainstem is inferiorly and dorsally displaced ("kinked"). Follow-up US at 16 weeks confirmed Chiari 2 and spina bifida.

KEY FACTS

TERMINOLOGY

- Hindbrain herniation (Chiari 2) with cephalocele at craniocervical junction

IMAGING

- Brain
 - Low occipital, high cervical meningoencephalocele
 - Posterior fossa features of Chiari 2 malformation obligatory for diagnosis
 - Ventriculomegaly
 - ± supratentorial brain malformation
- Spinal cord
 - Tethered to upper dysraphism
 - ± syringomyelia
- Technique
 - Use TVUS if fetus cephalic
 - 3D may be helpful for extent/sac content
 - MR useful for better anatomic detail

TOP DIFFERENTIAL DIAGNOSES

- Iniencephaly
 - Fixed extended head position
- Occipital cephalocele not associated with cervical dysraphism
 - Isolated or syndromic

CLINICAL ISSUES

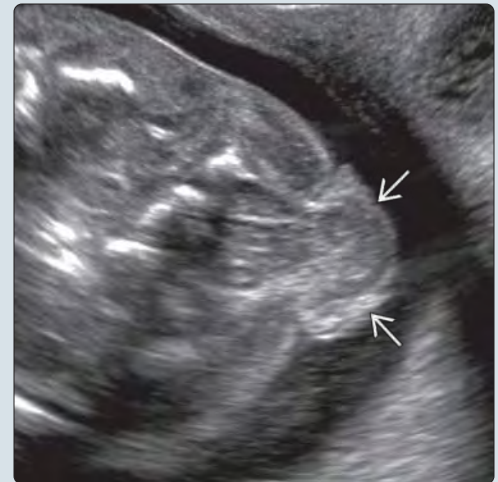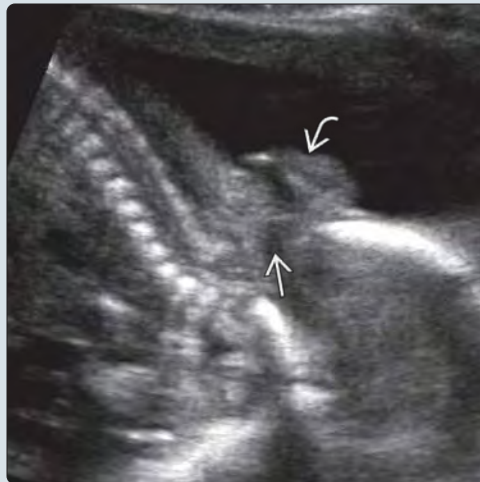
- Poor prognosis if large amount of brain involved or associated brain malformation
- Severe disabilities even if repaired
 - Respiratory, feeding difficulties
 - Developmental delay
 - Spasticity
 - Seizure disorder

DIAGNOSTIC CHECKLIST

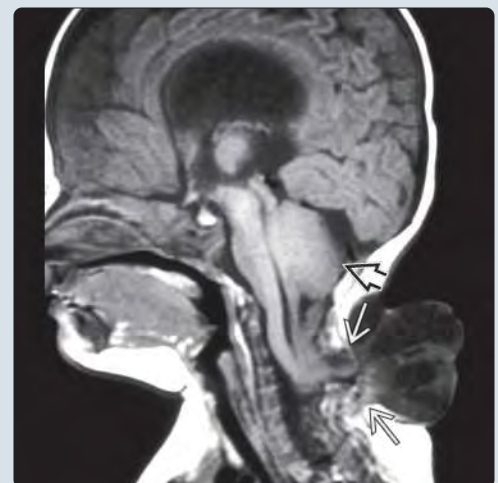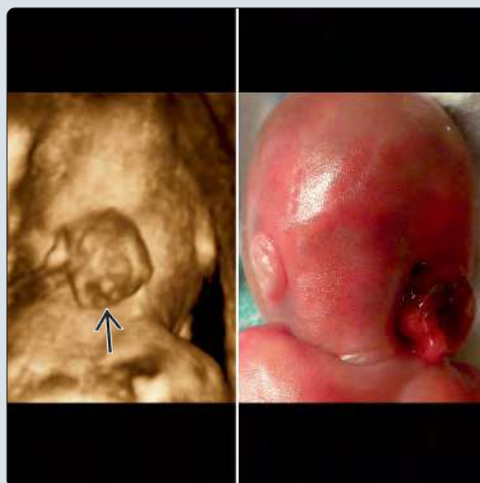- Always check cervical spine in fetuses with occipital cephalocele

(Left) Sagittal view of the craniocervical spine junction shows a lower calvarial/upper spine bony defect [E], as well as herniation of neural tissue into the amniotic cavity [E].

(Right) Axial view of a transvaginal ultrasound of the skull base in the same fetus confirmed the finding of an occipital cephalocele with herniated dysmorphic cerebellum [E]. The bony defect also involved the upper cervical spine (not shown). This case was an open Chiari 3. The lack of neck hyperextension rules out iniencephaly.



(Left) 3D ultrasound (left) of an encephalocele [E] matches the clinical photograph of this fetus with a Chiari 3 malformation. **(Right)** Sagittal postnatal T1WI MR shows features of Chiari 2 malformation, with a small posterior fossa and inferior cerebellar herniation [E]. In addition, there is an upper cervical defect [E] containing dysmorphic neural tissue, meninges, and cerebrospinal fluid. This combination of findings is diagnostic of a Chiari 3 malformation.



TERMINOLOGY**Definitions**

- Hindbrain herniation (Chiari 2) with occipital or high cervical encephalocele
- Spinal dysraphism: Spectrum of anomalies affecting dorsal neural arch and spinal contents

IMAGING**Ultrasonographic Findings**

- Low occipital, high cervical meningoencephalocele
 - Bony defect variable
 - Occiput
 - Foramen magnum
 - Upper cervical spine dysraphism
 - Encephalocele content variable
 - Cerebellum
 - Cervical spinal cord
 - Often tissue is dysmorphic
 - Skin-covered more common than open
- Features of Chiari 2 malformation obligatory for diagnosis
 - Hindbrain compression and inferiorly displaced cerebellum
 - Ventriculomegaly common
 - Associated supratentorial anomalies
 - Dysgenesis of corpus callosum
 - Absent cavum septi pellucidi
 - Heterotopia
- Microcephaly often present

MR Findings

- Better evaluation of encephalocele contents and cerebellar position
- Supratentorial brain malformation
- Associated cord anomalies seen best with MR
 - Syringomyelia
 - Tethered cord

Imaging Recommendations

- Use TVUS if fetus cephalic
- 3D may be helpful for overview of extent of defect and sac contents
- Information from MR may be useful for pregnancy management
 - Large amount of brain involved or associated brain malformation confers poor prognosis
 - MR in difficult sonographic cases

DIFFERENTIAL DIAGNOSIS**Iniencephaly**

- Fused extensive cervical/thoracic/lumbar spinal dysraphism with occipital bone defect
- Fixed hyperextension of neck → "stargazer" fetus

Occipital Cephalocele: Isolated or Syndromic

- Not associated with cervical dysraphism
- Meckel-Gruber syndrome (autosomal recessive)
 - Encephalocele, cystic kidneys, and polydactyly

CLINICAL ISSUES**Presentation**

- Elevated maternal serum α -fetoprotein if open cephalocele
- Offer genetic counseling/testing

Natural History & Prognosis

- High morbidity and mortality
 - Respiratory failure
 - Swallowing dysfunction
 - Hypertonia or amyotonia
- Poor prognostic indicators
 - Large amount of neuronal tissue within cephalocele
 - Severe ventriculomegaly
- Series of 8 cases with cephalocele repair (2 days to 2 years)
 - 1 postoperative death
 - 7 survivors
 - 2 with shunt malfunction
 - 2 with severe neurological deficit
 - 5 with normal motor and mental development (reached age-appropriate milestones)
 - Authors note that if > 20-cc brain tissue involved in cephalocele, outcome was poor
 - Mean amount: 19.4 cc (range: 0.1-87.9 cc)
 - Associated findings
 - 4 with tethered cord
 - 5 with syringomyelia
 - All had additional brain anomalies on MR

Treatment

- Shunt placement for obstructive hydrocephalus
- Primary closure of encephalocele
 - After shunt placement if large fluid-filled sac
 - Emergent if open defect

DIAGNOSTIC CHECKLIST**Consider**

- Worse prognosis if large amount of brain involved or additional severe brain malformation
- Offer genetic counseling/testing

Image Interpretation Pearls

- Always check cervical spine in fetuses with occipital cephalocele
 - Isolated small occipital cephalocele has better prognosis than Chiari 3 malformation

SELECTED REFERENCES

1. Jeong DH et al: Arnold-Chiari malformation type III with meningoencephalocele: a case report. *Ann Rehabil Med.* 38(3):401-4, 2014
2. Rani H et al: Chiari III Malformation: a rare case with review of literature. *Fetal Pediatr Pathol.* 32(3):169-74, 2013
3. Ambekar S et al: Large occipito-cervical encephalocele with Chiari III malformation. *J Pediatr Neurosci.* 6(2):116-7, 2011
4. İşik N et al: Chiari malformation type III and results of surgery: a clinical study: report of eight surgically treated cases and review of the literature. *Pediatr Neurosurg.* 45(1):19-28, 2009
5. Taricco MA et al: Retrospective study of patients with Chiari: malformation submitted to surgical treatment. *Arq Neuropsiquiatr.* 66(2A):184-8, 2008
6. Smith AB et al: Diagnosis of Chiari III malformation by second trimester fetal MRI with postnatal MRI and CT correlation. *Pediatr Radiol.* 37(10):1035-8, 2007
7. Häberle J et al: Cervical encephalocele in a newborn—Chiari III malformation. Case report and review of the literature. *Childs Nerv Syst.* 17(6):373-5, 2001

KEY FACTS

TERMINOLOGY

- Classic Dandy-Walker malformation
 - Cystic dilatation of 4th ventricle (4V)
 - Enlarged PF with tentorial elevation
 - Complete or partial agenesis of cerebellar vermis

IMAGING

- Large PF cyst
 - Elevated torcular, transverse sinus, tentorium
- Abnormal widened configuration of 4V
- Absent or partially absent vermis
 - Vermian remnant rotated/displaced superiorly
- Hydrocephalus may be present
- Fetal MR may allow better definition of intracranial findings and extent of vermian agenesis
 - Midline sagittal view best demonstrates vermis
- ~ 70-90% have additional supratentorial or extracranial anomalies

TOP DIFFERENTIAL DIAGNOSES






- Persistent Blake pouch cyst
- Mega cisterna magna
- Arachnoid cyst

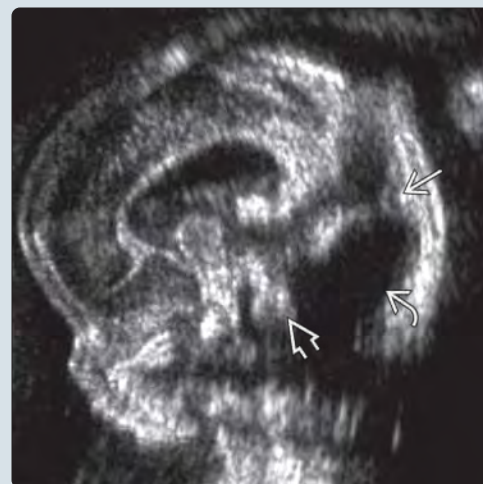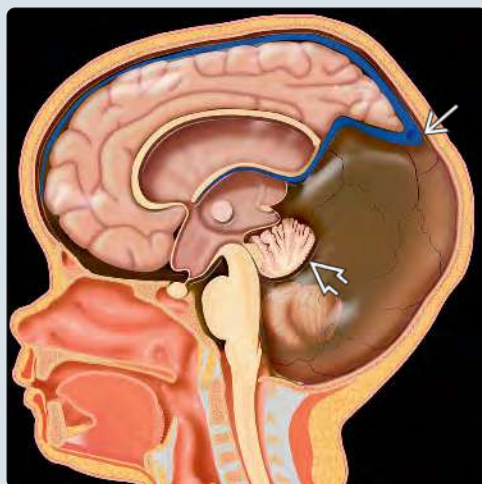
PATHOLOGY




- Majority sporadic
- Can be present as part of more global syndromes
 - Meckel-Gruber, Walker-Warburg, PHACES syndrome
- Aneuploidy in ~ 50%
 - Trisomy 9, 13, 18, Turner syndrome (45, XO)

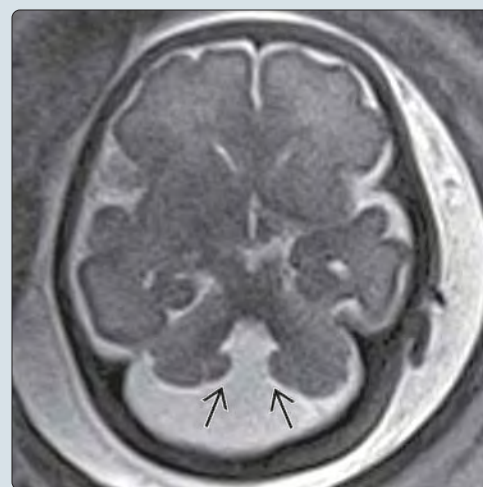
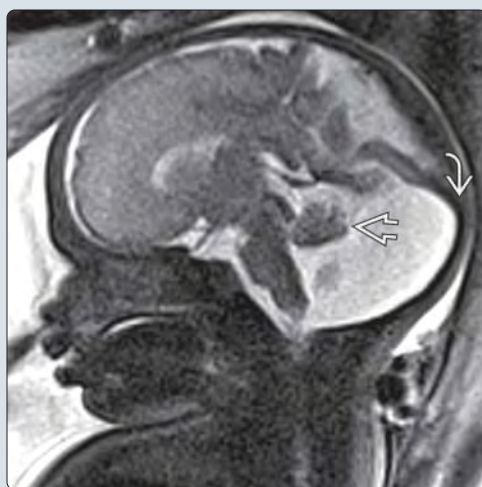
DIAGNOSTIC CHECKLIST

- Go beyond routine US views and scan in sagittal plane to document position of torcular
- Fetal MR useful to detect associated CNS anomalies and evaluate fetal vermis
- Look for additional extracranial anomalies

(Left) Graphic shows a superiorly rotated vermian remnant , an uncovered 4th ventricle communicating with a posterior fossa (PF) cyst, and elevation of the torcular . These are the requisite findings of a Dandy-Walker malformation (DWM). **(Right)** The routine brain views of this fetus showed a cystic fluid collection in the PF. A DWM was suspected, so a sagittal scan plane was performed, which shows a vermian remnant , PF cyst , and elevation of the torcular .



(Left) Sagittal fetal MR in the 3rd trimester in a similar case shows an elevated torcular  and a superiorly rotated hypoplastic vermian remnant , diagnostic of a DWM. **(Right)** Axial MR confirms the midline open communication of the 4th ventricle  with a large cystic PF. MR is ideally suited to evaluate for other associated abnormalities such as polymicrogyria or gray matter heterotopias, which may be difficult to detect with US and have an adverse affect on prognosis.



TERMINOLOGY

Abbreviations

- Dandy-Walker malformation (DWM)

Synonyms

- Dandy-Walker complex, Dandy-Walker spectrum

Definitions

- Classic DWM
 - Complete or partial agenesis of cerebellar vermis
 - Cystic dilation of 4th ventricle (4V)
 - Enlarged posterior fossa (PF) due to elevation of cerebellar tentorium and torcular
- Dandy-Walker continuum used to encompass spectrum of PF malformations, including classic DWM, vermian agenesis/dysgenesis, persistent Blake pouch, mega cisterna magna
 - Important to be as precise as possible and not lump together, as these have different prognostic implications

IMAGING

General Features

- Best diagnostic clue
 - Enlarged PF with large cerebrospinal fluid (CSF) cyst
 - 4V appears uncovered and contiguous with PF cyst

Ultrasonographic Findings

- Abnormal widened configuration of 4V
 - Communication of 4V with PF cyst/cisterna magna
- Elevated torcular, transverse sinus, tentorium
 - Best seen in sagittal view
- Partial or complete agenesis of vermis
 - Vermian remnant rotated/displaced superiorly
- Often associated with cerebellar hypoplasia
- Hydrocephalus may be present
 - If present in utero, requires follow-up to evaluate for progression
 - May develop postnatally
- 3D US
 - Useful for reconstruction of sagittal plane from axial acquisition
 - Look for fastigial point of 4V
 - Vermian orientation

MR Findings

- Midline sagittal T2WI most useful
 - Residual vermis superiorly rotated
 - Torcular Herophili elevated
- Evaluate brainstem
 - Thinned, kinked, or Z-shaped all confer worse prognosis

Imaging Recommendations

- MR recommended for better definition of PF abnormalities and extent of vermian agenesis
 - Identifies associated supratentorial anomalies
 - Objective evaluation of torcular position
 - Normal angle at junction of straight/superior sagittal sinus is 50-75°
 - With DWM, angle becomes more obtuse

- Occasionally, anterior tentorium elevated with relatively normal torcular position
- Look for associated fetal anomalies
 - Classic DWM: ~ 70-90% have additional supratentorial or extracranial anomalies
 - CNS
 - Callosal dysgenesis
 - Occipital encephalocele
 - Neural tube defects
 - Holoprosencephaly
 - Polymicrogyria
 - Heterotopias
 - Extracranial
 - Cleft lip/palate
 - Cardiac anomalies
 - Polycystic kidneys
 - Extremity defects
- Consider gestational age
 - Normal rhombencephalon appears cystic in 1st trimester
 - "Incomplete" vermis in 56% at 14-weeks gestation, 6% at 17-weeks gestation

DIFFERENTIAL DIAGNOSIS

Blake Pouch Cyst

- Isolated elevation or rotation of vermis due to persistent Blake pouch
 - No primary vermian hypoplasia or cerebellar dysplasia
- Mild pressure-related vermian &/or cerebellar atrophy may be present

Mega Cisterna Magna

- Cisterna magna > 10 mm
- Vermis intact, no rotation
- Vast majority considered normal variant, although no long-term studies

Arachnoid Cyst

- Vermis intact, no rotation
- Arachnoid cyst is space occupying → displacement/compression of cerebellum, 4V
- Generally off midline

Vermian Dysgenesis

- Vermis is absent/partially deficient, usually rotated
- PF not enlarged by cyst
- Normal torcular position

Cerebellar Disruption

- Defects of cerebellar hemispheres
 - Due to early insult during development (e.g. cerebellar hemorrhage, infarct)

Joubert Syndrome

- Actually complex group of syndromes: Joubert syndrome and related disorders
- Abnormal superior cerebellar peduncles with vermian dysgenesis
 - Results in molar tooth configuration
- No PF cyst but may have occipital cephalocele

PATHOLOGY

General Features

- Etiology
 - Embryology
 - Neural tube develops dorsal pontine flexure → crease in roof of rhombencephalic vesicle dividing it into anterior and posterior membranous areas (PMAs)
 - Anterior membranous area (AMA) is more cranial
 - ◻ Vermis develops from rhombic lip at superior margin AMA
 - PMA is more caudal
 - ◻ As cerebellum grows PMA bulges between vermis and nucleus gracilis → Blake pouch
 - ◻ Blake pouch eventually fenestrates, neck → foramen of Magendie
 - DWM now thought to be global developmental defect of rhombencephalic roof → variable vermian hypoplasia, variable fenestration of 4V outlets ± associated anomalies
 - Arrest of vermian development → vermis does not cover 4V
 - ◻ Histopathology shows all lobules present but arrested (as early as ~ 12-week fetus level)
 - ◻ Mechanical effects 2° to distend 4V
 - ◻ Genetic gradients influence cellular development/neurofilament protein expression
 - Failed fenestration → enlarged Blake pouch → elevation/compression of abnormal vermis
 - Environmental factors implicated but not proven
 - Maternal diabetes
 - Alcohol
 - Intrauterine infection
- Genetics
 - Majority sporadic
 - Can be present as part of more global syndromes
- Associated abnormalities
 - Chromosomal abnormalities in ~ 50%
 - Trisomy 9, 13, 18
 - Turner syndrome (45, XO)
 - Meckel-Gruber syndrome
 - Encephalocele, polydactyly, polycystic kidneys
 - Walker-Warburg syndrome
 - Lissencephaly, hydrocephalus, encephalocele, microphthalmia, and cataracts
 - PHACES syndrome
 - PF malformation, facial hemangioma, and arterial, cardiac, eye abnormalities, sternal defect

CLINICAL ISSUES

Presentation

- Prenatal
 - Incidental finding on routine antenatal US
 - Hydrocephalus
- Postnatal
 - Enlarging head circumference or signs and symptoms of hydrocephalus
 - Hydrocephalus in 75% at 3-months postpartum
 - Developmental delay

Demographics

- Gender
 - F ≥ M
- Epidemiology
 - 1:25,000-35,000 live births

Natural History & Prognosis

- Available prognostic information is compromised due to inconsistencies in nomenclature with poor prenatal to postnatal correlation
- Published outcomes range from near normal psychomotor development to severe handicap or death
 - Large vermian remnant with normal lobulation and absence of supratentorial abnormalities → more favorable outcome
 - Absent or small vermian with abnormal lobulation, supratentorial abnormalities → poor outcome
 - Severely delayed motor development, hypotonia, ataxia, seizures
- 40% mortality in infancy and early childhood
- Intellectual development dependent on vermian abnormality, associated supratentorial anomalies, and associated syndromes
 - Intelligence normal in 35-50% in those living beyond early childhood
- Recurrence risk 1-5% for nonsyndromic DWM
- 25% if associated with autosomal recessive syndromes
 - Walker-Warburg, Meckel-Gruber

Treatment

- Amniocentesis for fetal karyotype
- May require postnatal ventricular &/or cyst shunt

DIAGNOSTIC CHECKLIST

Consider

- Use 3D US &/or fetal MR to detect associated anomalies and evaluate fetal vermis
- Go beyond routine views and scan in sagittal plane to document position of torcular

Image Interpretation Pearls

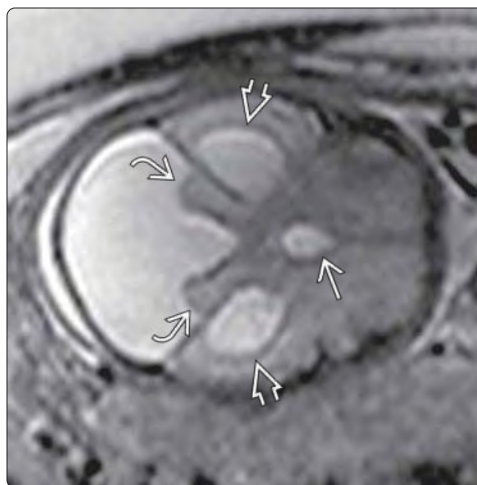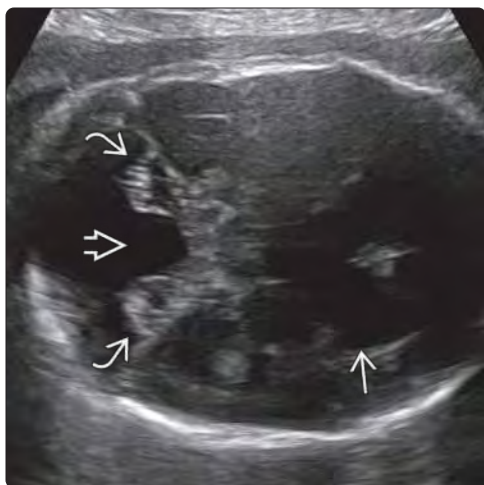
- Classic DWM should have large PF cyst with open 4V and elevated torcular

Reporting Tips

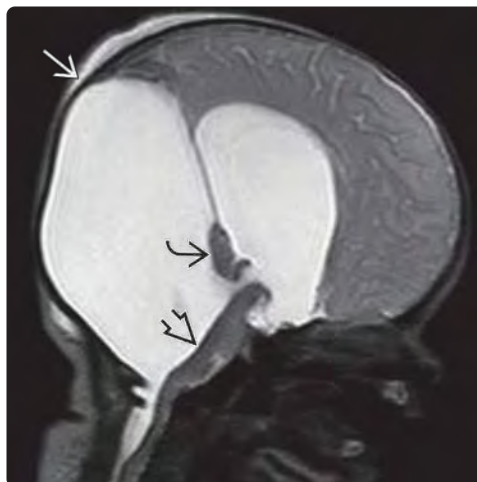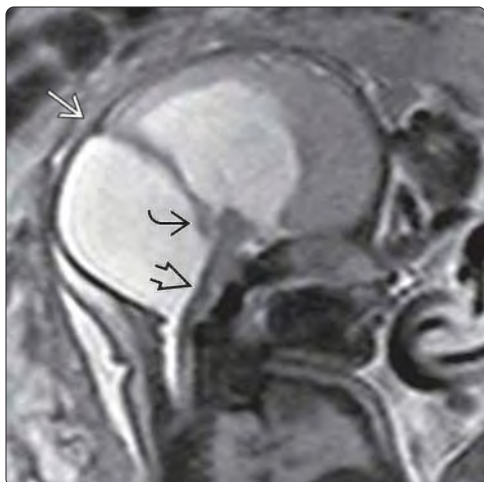- Document vermian size, anatomy, and degree of rotation for more precise classification of posterior fossa (PF) malformations

SELECTED REFERENCES

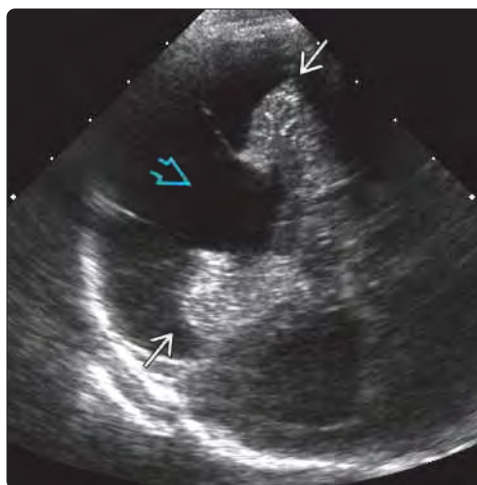
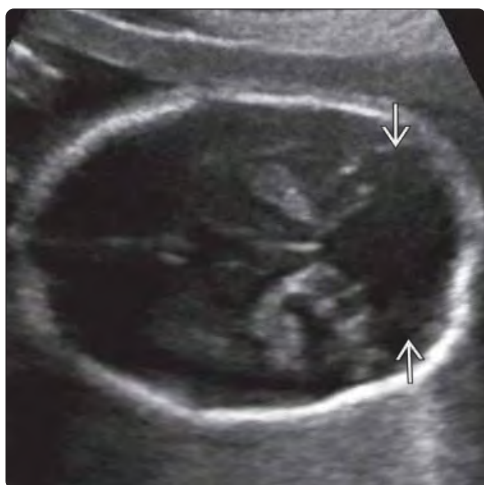1. Chapman T et al: Diagnostic imaging of posterior fossa anomalies in the fetus and neonate: part 2, posterior fossa disorders. *Clin Imaging.* 39(2):167-175, 2015
2. Ghali R et al: Perinatal and short-term neonatal outcomes of posterior fossa anomalies. *Fetal Diagn Ther.* 35(2):108-17, 2014
3. Leibovitz Z et al: Fetal posterior fossa dimensions: normal and anomalous development assessed in mid-sagittal cranial plane by three-dimensional multiplanar sonography. *Ultrasound Obstet Gynecol.* 43(2):147-53, 2014
4. Robinson AJ: Inferior vermian hypoplasia—preconception, misconception. *Ultrasound Obstet Gynecol.* 43(2):123-36, 2014
5. Gandolfi Colleoni G et al: Prenatal diagnosis and outcome of fetal posterior fossa fluid collections. *Ultrasound Obstet Gynecol.* 39(6):625-31, 2012
6. Limperopoulos C et al: How accurately does current fetal imaging identify posterior fossa anomalies? *AJR Am J Roentgenol.* 190(6):1637-43, 2008



(Left) Axial US at 29-weeks gestation shows small hypoplastic cerebellar hemispheres, with the uncovered 4th ventricle. There is associated hydrocephalus. **(Right)** Axial image from the correlative fetal MR confirms the large PF cyst and the hypoplastic cerebellar hemispheres. The temporal horns of the lateral ventricles are dilated as well as the 3rd ventricle.



(Left) Sagittal fetal MR shows the classic appearance of a DWM, with an elevated torcular and large PF cyst. There is a tiny vermian remnant rotated superiorly. In addition, the brainstem is markedly thinned. These findings confer a very poor prognosis. **(Right)** Postnatal MR confirms the vermian remnant as well as the elevated appearance of the torcular and thinned brainstem.



(Left) Axial US in the mid-2nd trimester shows the cerebellar hemispheres are splayed and there is open communication between the 4th ventricle and the PF cyst. **(Right)** Neonatal head US mastoid view confirms the uncovered 4th ventricle and the splayed cerebellar hemispheres. Similar views can be obtained prenatally using an endovaginal probe if the fetus is in a cephalic presentation.

KEY FACTS

TERMINOLOGY

- Partial or complete agenesis of cerebellar vermis
 - Dandy-Walker variant terminology should be abandoned

IMAGING

- Keyhole appearance of 4th ventricle (4V) in axial plane on US
- Unlike Dandy-Walker malformation no large posterior fossa cyst, tentorium normally positioned
- Midline sagittal view best demonstrates vermis
 - Vermis should cover 4V
 - Failure of closure results in communication of 4V with posterior fossa
 - Vermis incompletely developed and morphologically abnormal
 - MR best to look for normal midsagittal 4V fastigial point and primary/secondary vermian fissures
- Incomplete vermis prior to 18 weeks may be normal

TOP DIFFERENTIAL DIAGNOSES

- Persistent Blake pouch cyst
 - Superior rotation of normal vermis
- Mega cisterna magna
 - Vermis is normally formed

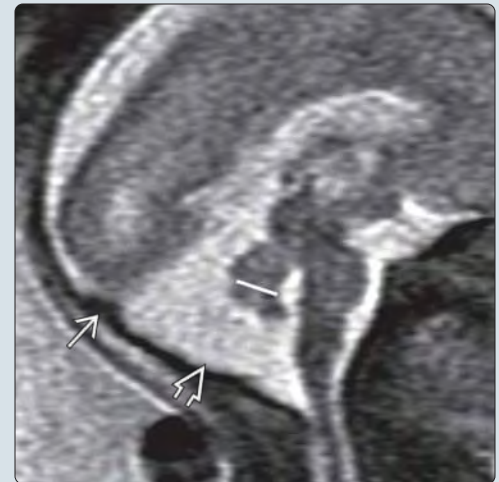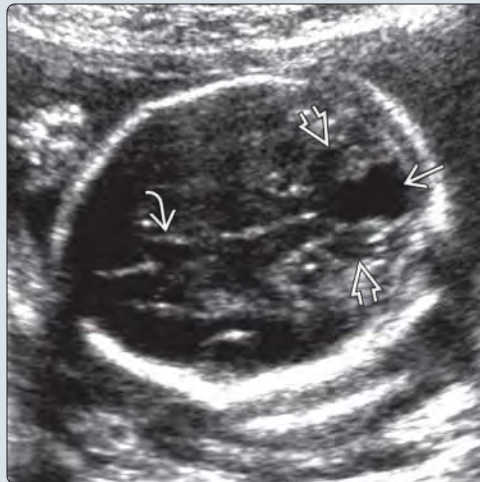
CLINICAL ISSUES

- Diagnosis more accurate if delayed until early 3rd trimester
 - As high as 32% of fetuses with diagnosis of inferior vermian agenesis have normal postnatal MR
 - Delayed rotation or closure of vermis may account for overdiagnosis in utero
- Variable outcome reported but generally good outcomes with isolated inferior defect

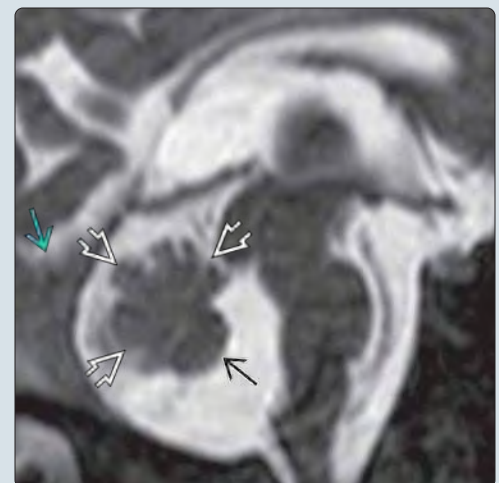
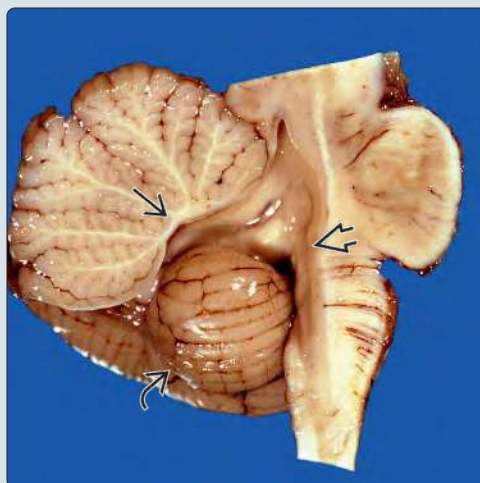DIAGNOSTIC CHECKLIST

- Steep oblique or coronal scan plane may simulate vermian defect

(Left) An appropriately positioned posterior fossa view (cavum septi pellucidi) shows partial vermian agenesis with mildly splayed cerebellar lobes. Superiorly, the vermis was intact and the torcular was not elevated, differentiating this from DWM. **(Right)** Sagittal fetal MR shows the fastigial-decline line drawn on the vermis. The fastigial point is flattened and there is less vermian tissue below the line than above, indicating partial vermian agenesis. The cisterna magna is large but the torcular position is normal.



(Left) Pathology specimen shows how the cerebellar hemisphere can simulate the inferior vermis. The fastigial point is flattened and there is loss of the triangular shape of the 4th ventricle, which is open to the cisterna magna. **(Right)** Postnatal MR shows a small dysgenetic vermis. A cerebellar hemisphere has rotated into the position of the inferior vermis, similar to the prior path specimen. This is a potential pitfall in both fetal and postnatal imaging. Note the torcular is normally located.



TERMINOLOGY

Synonyms

- Dandy-Walker variant: This terminology best avoided as it is imprecise

Definitions

- Partial or complete agenesis of cerebellar vermis

IMAGING

General Features

- Best diagnostic clue
 - Vermis absent or partially deficient
 - 4th ventricle (4V) at least partially open to posterior fossa

Ultrasonographic Findings

- Vermis is absent or partially deficient, leaving 4V incompletely covered
 - Unlike Dandy-Walker malformation no large posterior fossa cyst, Torcular Herophili normal location
- Keyhole appearance of 4V in axial plane
- Partial agenesis may reflect deficient craniocaudal growth reduction due to hypoplasia of entire vermis
 - Older teaching was that inferior vermis was deficient in partial vermian agenesis

MR Findings

- Midline sagittal view best demonstrates vermis
 - Vermis should cover 4V
 - Failure of closure results in apparent communication of 4V with posterior fossa
 - Vermis incompletely developed and morphologically abnormal
 - Potential pitfall: Cerebellar lobe may rotate medially, creating appearance of intact inferior vermis
- Tegmento-vermian angle can be measured
 - Between posterior margin of brainstem and vermis; close to 0°
 - Significantly elevated angle > 40° often associated with vermian/cerebellar abnormality

Imaging Recommendations

- Visualize cavum septi pellucidi to confirm correct axial plane
- Use TV scans for best image resolution if fetus cephalic
- Use 3D volume to reconstruct true midline sagittal plane
- Consider gestational age
 - Normal rhombencephalon appears cystic in 1st trimester
 - Formation of vermis somewhat variable
 - Open vermis in 56% at 14-weeks gestation
 - Only 6% open at 17-weeks gestation
 - Diagnosis more accurate if delayed until early 3rd trimester
 - Best not to diagnose isolated vermian abnormality until after 24-weeks gestation
- Assess vermian morphology and biometry
 - Look for normal midsagittal 4V fastigial point and primary/secondary vermian fissures
 - Obtain accurate measurements of vermian diameter and compare to normative tables

DIFFERENTIAL DIAGNOSIS

Blake Pouch Cyst

- Isolated elevation or rotation of vermis due to persistent Blake pouch
- Vermis is normally formed

Joubert Syndrome

- Absent or incomplete vermis
- Abnormal superior cerebellar peduncles

Mega Cisterna Magna

- Cisterna magna > 10 mm
- Vermis is normally formed

PATHOLOGY

General Features

- Etiology
 - Defective formation of vermis from rhombic lip at superior margin of anterior area membranacea in rhombencephalic roof
 - Craniocaudal growth of vermis does not progress to cover entire 4th ventricle
 - Likely entire vermis is hypoplastic
 - Evidence suggests development of vermis and cerebellum progresses ventral → dorsal
- Genetics
 - Mostly sporadic
 - Abnormal karyotype in ~ 30%

CLINICAL ISSUES

Natural History & Prognosis

- Variable outcome reported
 - Good outcomes with isolated inferior defect
 - Can still have motor or language delays
- In some fetal cases of partial agenesis, diagnosis refuted on postnatal MR
 - As high as 32% of fetuses with diagnosis of inferior vermian agenesis have normal postnatal MR
 - Delayed rotation or closure of vermis may account for overdiagnosis in utero

DIAGNOSTIC CHECKLIST

Image Interpretation Pearls

- Confirm correct scan plane before diagnosis of subtle vermian defect
- Fetal MR can help differentiate vermian agenesis/dysgenesis from other vermian or cerebellar abnormalities

SELECTED REFERENCES

1. Robinson AJ: Inferior vermian hypoplasia—preconception, misconception. *Ultrasound Obstet Gynecol.* 43(2):123-36, 2014
2. Patek KJ et al: Posterior fossa anomalies diagnosed with fetal MRI: associated anomalies and neurodevelopmental outcomes. *Prenat Diagn.* 32(1):75-82, 2012
3. Robinson AJ et al: The fetal cerebellar vermis: assessment for abnormal development by ultrasonography and magnetic resonance imaging. *Ultrasound Q.* 23(3):211-23, 2007

KEY FACTS

TERMINOLOGY

- Persistent cystic evagination of area membranacea under inferior vermis in cerebellar valliculae

IMAGING

- Normal appearance to vermis
 - Blake pouch cyst (BPC) is actually inferior to structurally normal vermis
 - This causes upward rotation of the vermis
- Causes abnormal tegmentovermian angle (TVA)
 - Normal is close to 0° (< 18° in 80 controls from 20- to 24-weeks gestational age)
 - Angle > 18° but < 30° likely BPC (range: 23.0 ± 2.8)
- No or minimal enlargement of cisterna magna
- Cisterna magna septa may be bowed laterally
- Cyst fluid anechoic whereas cerebrospinal fluid in cisterna magna has internal echoes
- Multiplanar imaging essential for this diagnosis
 - Must see sagittal plane

TOP DIFFERENTIAL DIAGNOSES

- Dandy-Walker malformation
- Vermian dysgenesis
- Arachnoid cyst
- Mega cisterna magna

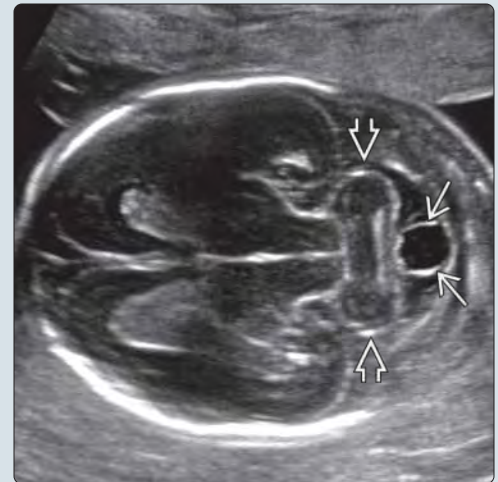
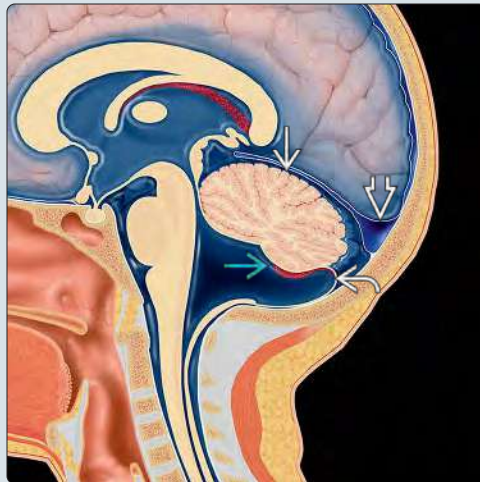
CLINICAL ISSUES

- Patients with isolated BPC have good prognosis

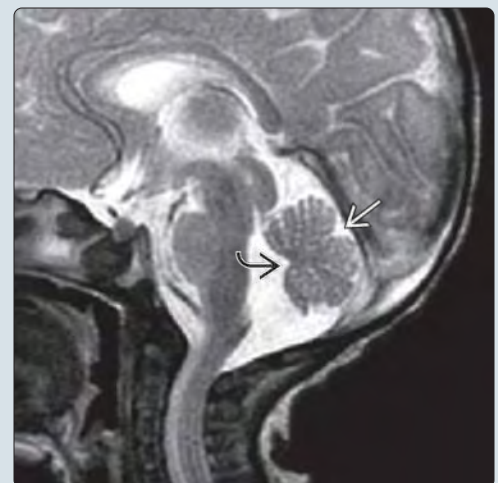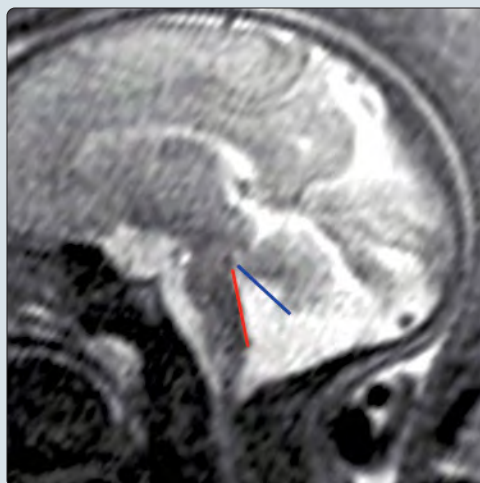
DIAGNOSTIC CHECKLIST

- Differences between posterior fossa malformations are subtle and difficult to appreciate even on full postnatal studies
- Look for fastigial point and measure TVA angle in any case where cerebellar abnormality is possible
- If BPC seen, "look and look again" for other findings

(Left) Graphic illustrates a Blake pouch cyst causing upward rotation of the vermis and displacement of the 4th ventricle choroid plexus to its superolateral margin. Torcular location is normal. The cyst communicates with the 4th ventricle but not with the cistern magna. (Right) Axial US at 17 weeks shows the walls of the Blake pouch, which are convex outward. The cerebellum and supratentorial brain were normal. This resolved in follow-up, consistent with interval fenestration of the foramen of Magendie.



(Left) Sagittal T2WI MR shows vermian rotation. The tegmentovermian angle (TVA) is measured between a line drawn along the ventral surface of the vermis (blue) and a line along the tegmentum, the dorsal surface of the medulla (red). It is normally close to zero; here it is ~ 25°. (Right) Neonatal T2WI MR in the same case confirms Blake pouch cyst with rotation and elevation of a normal vermis. Note the normal fastigial point and normal primary fissure.



TERMINOLOGY

Abbreviations

- Blake pouch cyst (BPC)

Synonyms

- Persistent Blake pouch (BP)

Definitions

- Persistent cystic evagination of the area membranacea under inferior vermis in cerebellar vallicula
- Diagnostic criteria
 - Normal vermian size, anatomy in midline sagittal view
 - $< 30^\circ$ anticlockwise rotation of vermis
 - Normal size of cisterna magna
 - Cisterna magna septa may be bowed laterally
 - 4th ventricle choroid plexus at superior margin of BPC

IMAGING

General Features

- Best diagnostic clue
 - Posterior fossa (PF) cyst with structurally normal vermis and normal torcular position

Ultrasonographic Findings

- PF cyst with keyhole appearance on standard image planes
 - Suggesting communication between 4th ventricle and cisterna magna
 - Suggests vermian abnormality
- BPC is actually inferior to structurally normal vermis
 - Cyst fluid anechoic whereas cerebrospinal fluid (CSF) in cisterna magna has internal echoes
- Cisterna magna may appear prominent but is usually not significantly enlarged
- Linear echoes in PF represent falx cerebelli, BP walls
 - Midline posterior fossa echo is falx cerebelli
 - BP walls arise at cerebellovermian junction
 - Run anterior to posterior
- Ventriculomegaly may be present
 - Delayed fenestration of foramen of Magendie impairs CSF circulation
- Sagittal images are essential to show vermian rotation
 - Obtain directly or with 3D volume manipulation
 - Curvilinear echo ("vermian tail") extending from inferior vermian edge toward occiput on sagittal scan plane is roof of BPC

MR Findings

- Cerebellar hemispheres are normal
- Vermis is normal in size and structure
- May see roof of BPC as delicate membrane on sagittal view
- Abnormal brainstem-vermis or tegmentovermian angle (TVA)
 - Draw line along ventral surface of vermis
 - Draw line along dorsal surface of brainstem
 - Parallel to tegmentum (dorsal surface of medulla)
 - Should transect nucleus gracilis at obex
 - TVA is angle at junction of these lines
 - Normal is close to 0° ($< 18^\circ$ in 80 controls from 20- to 24-weeks gestational age)
 - Angle $> 18^\circ$ but $< 30^\circ$ likely BPC (range: 23.0 ± 2.8)

- Angle $> 45^\circ$ seen in Dandy-Walker malformation (range: 63.5 ± 17.6)
 - Vermian hypoplasia/dysgenesis associated with angles of 34.9 ± 5.4

- Apparent communication between 4th ventricle and cisterna magna
 - Cyst communicates with 4th ventricle via valliculae
 - Does not actually communicate with cisterna magna until foramen of Magendie fenestrates
 - Cyst lies inferiorly in PF
- May exert mass effect on inferior vermis and medial cerebellar hemispheres
- 4th ventricle choroid plexus sits above BPC

Imaging Recommendations

- Attempt to answer following questions in any case of PF cyst
 - Is cerebellum normal?
 - Evaluate vermis and lobes
 - Are there additional brain anomalies?
 - Adverse impact on prognosis if present
 - Is aqueduct of Sylvius patent?
 - May not be possible on fetal imaging studies
- Use transvaginal US, 3D US, and fetal MR as determined by available expertise
 - Sagittal plane key to identify vermian position/anatomy
 - Measure TVA
 - Look for cerebellar fissures radiating from fastigial point
 - Best anatomic detail on 3D with thick slab reconstruction
 - Both US and MR allow "walk through" posterior fossa in multiple planes
 - See orientation of vermis
 - Relationship of cyst to other structures

DIFFERENTIAL DIAGNOSIS

Dandy-Walker Malformation

- Torcular elevated
- Vermis abnormal
 - May see complete vermian agenesis
- Cisterna magna is compressed and reduced to virtual space between dilated 4th ventricle (PF cyst) and dura mater

Vermian Dysgenesis

- Torcular position variable
- Vermis abnormal

Arachnoid Cyst

- Torcular position is normal
- Posterior fossa may be enlarged
 - May see occipital scalloping depending on cyst size
- Vermis intact
 - May be compressed by mass effect of cyst
- Foramen of Magendie and aqueduct of Sylvius are patent
 - Mass effect may hinder CSF flow \rightarrow hydrocephalus

Mega Cisterna Magna

- Torcular position normal
- May see occipital scalloping mimicking arachnoid cyst
- Free communication of basal subarachnoid space and 4th ventricle through mildly widened vallicula

PATHOLOGY**General Features**

- Etiology
 - BPC represents posterior ballooning of superior medullary velum into cisterna magna
 - Defined by failure of regression of BP due to nonperforation of foramen of Magendie
 - Embryology
 - 5th week: Neural tube develops sharp bend (pontine flexure) resulting in large 4th ventricle with thin rhombencephalic roof
 - 6th week: 2 areas in rhombencephalic roof form ependymal cells
 - Anterior area membranacea (AMA)
 - Posterior area membranacea (PMA)
 - AMA normally incorporated into vermis &/or tela choroidea
 - Defective formation of AMA thought to cause Dandy-Walker malformation, vermian dysgenesis spectrum
 - PMA eventually perforates and forms foramen of Magendie
 - Defective formation of PMA thought to cause mega cisterna magna and BPC
 - Inadequate fenestration of BP and foramina of Luschka
 - imbalance of CSF flow to cisterna magna
 - BP is in continuity with 4th ventricle
 - BP does not communicate with cisterna magna subarachnoid space
- Associated abnormalities
 - Major anomalies present in 42% of one prenatal series of 19 cases (mostly cardiac)
 - 2/12 with karyotype had trisomy 21

Gross Pathologic & Surgical Features

- Cyst wall composed of
 - Inner layer of ependyma-like epithelium on astroglial membrane
 - Outer layer of arachnoid elements without features, suggesting secondary cyst formation in response to infection or hemorrhage

CLINICAL ISSUES**Presentation**

- Cyst or enlargement of posterior fossa

Natural History & Prognosis

- 30-50% fetal cases resolve spontaneously
- Good prognosis with isolated BPC
 - Series of 7 fetuses in patients considering termination for possible Dandy-Walker malformation (DWM)
 - Demonstration of isolated vermian rotation (rather than DWM) led to decision to continue pregnancy
 - All children developmentally normal on follow-up
 - 3 had been followed to age 7 at time of publication
- Normal outcome at 1-5 years in series of 5 neonates with fetal diagnosis of isolated BPC
- Unfavorable prognosis if
 - Associated supratentorial anomalies
 - Uncontrolled or progressive hydrocephalus

DIAGNOSTIC CHECKLIST**Consider**

- Differences between PF malformations are subtle and difficult to appreciate even on full postnatal studies
 - Important to establish correct diagnosis as treatment and prognosis are impacted
 - Outcome for isolated vermian rotation is excellent
 - Not reason for termination of pregnancy
- Studies show poor autopsy correlation with prenatal sonographic diagnosis
 - 8/14 aborted fetuses had incorrect US diagnosis of cerebellar anomaly in series reported in 2000
 - 26/44 fetuses with sonographic diagnosis of Dandy-Walker malformation were incorrect based on postmortem
 - False-positive rate of MR diagnosis of inferior vermian abnormality is as high as 32% in some studies
- Aqueduct patency crucial to evaluation and management of hydrocephalus
 - Will be determined on evaluation of infants

Image Interpretation Pearls

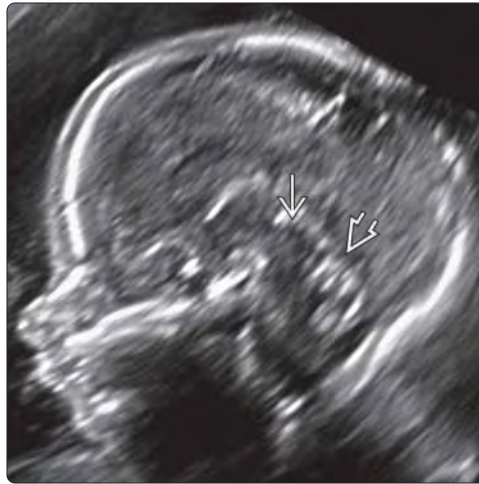
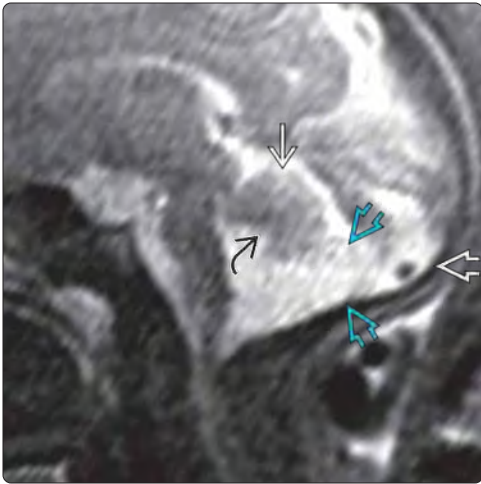
- Image in multiple planes with US, MR, or both
- Look for fastigial point and measure TVA angle in any case where cerebellar abnormality is possible
- If BPC seen, "look and look again" for other findings
 - Prognosis, risk for aneuploidy very different if multiple abnormalities

Reporting Tips

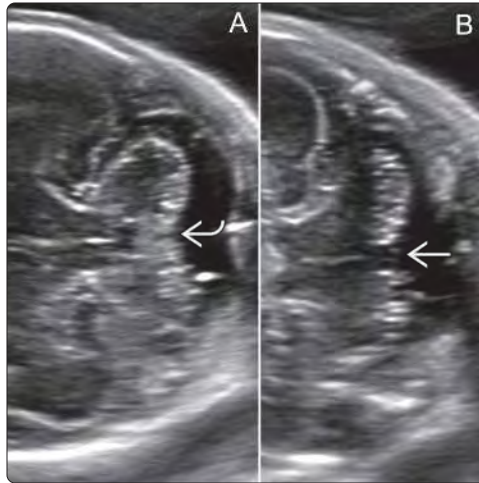
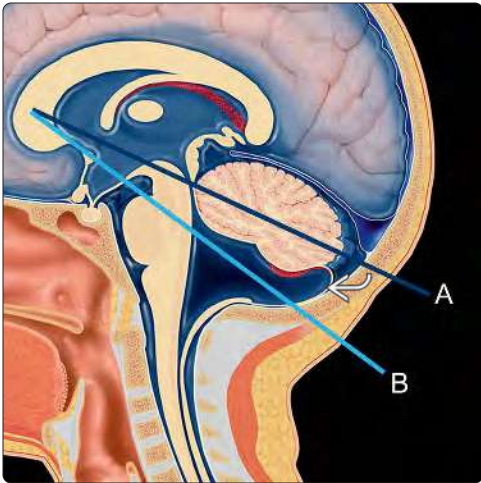
- Good prognosis is expected if vermis is normal in size and morphology
- Do not diagnose vermian abnormality before 18-week gestation, as growth is incomplete
- Up to 24 weeks, normal rotated vermis (i.e., BPC) may cause confusion with vermian dysgenesis

SELECTED REFERENCES

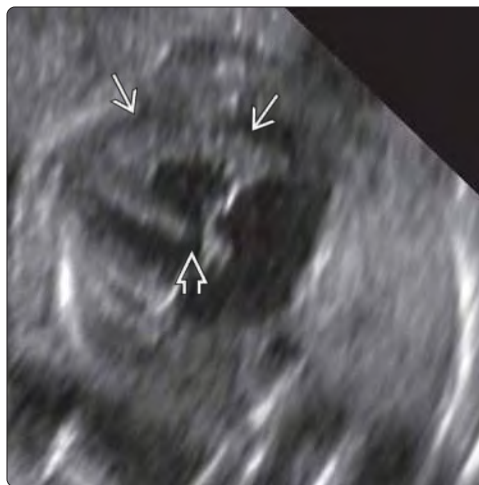
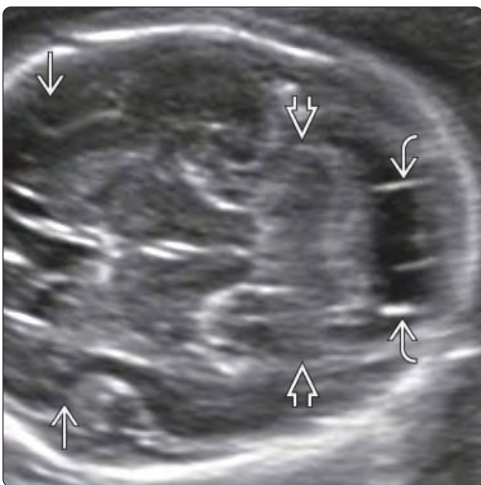
1. Azab WA et al: Blake's pouch cyst. *Surg Neurol Int.* 5:112, 2014
2. Contro E et al: Open fourth ventricle prior to 20 weeks' gestation: a benign finding? *Ultrasound Obstet Gynecol.* 43(2):154-8, 2014
3. Robinson AJ: Inferior vermian hypoplasia—preconception, misconception. *Ultrasound Obstet Gynecol.* 43(2):123-36, 2014
4. Gandolfi Colleoni G et al: Prenatal diagnosis and outcome of fetal posterior fossa fluid collections. *Ultrasound Obstet Gynecol.* 39(6):625-31, 2012
5. Paladini D et al: Abnormal or delayed development of the posterior membranous area of the brain: anatomy, ultrasound diagnosis, natural history and outcome of Blake's pouch cyst in the fetus. *Ultrasound Obstet Gynecol.* 39(3):279-87, 2012
6. Volpe P et al: Brainstem-vermis and brainstem-tentorium angles allow accurate categorization of fetal upward rotation of cerebellar vermis. *Ultrasound Obstet Gynecol.* 39(6):632-5, 2012
7. Bertucci E et al: Vermian biometric parameters in the normal and abnormal fetal posterior fossa: three-dimensional sonographic study. *J Ultrasound Med.* 30(10):1403-10, 2011
8. Malingier G et al: The fetal cerebellum. Pitfalls in diagnosis and management. *Prenat Diagn.* 29(4):372-80, 2009



(Left) Sagittal T2WI fetal MR shows normal torcular position and normal vermian with visible primary fissure and fastigial point. The increased TVA indicates vermian rotation, due to a Blake pouch cyst in this case. **(Right)** Sagittal or profile view of the fetal face is very popular with families and thus is commonly obtained. The same image often shows the brainstem and vermian. The TVA is normal (i.e., 0°) here. Remember, you see what you look for!



(Left) Graphic illustrates how Blake pouch cyst and rotation of a normal vermian can be confused with vermian dysgenesis depending on scan plane. Plane A will show the vermian but plane B will show an apparent vermian defect as it goes through the cyst. **(Right)** US images in differing obliquity show a normal vermian (scan plane A) and a "keyhole" (scan plane B) mistakenly interpreted as vermian dysgenesis (scan plane B). This is a Blake pouch that resolved in utero. The infant delivered at term and was completely normal.



(Left) Axial oblique US shows a relatively large, persistent Blake pouch cyst with normal cerebellum and supratentorial brain. **(Right)** Four-chamber view of the heart in the same fetus was concerning for right ventricular hypertrophy and possible VSD. Fetal echo was normal; the cyst resolved and the infant was normal at birth. One prenatal series showed an apparent association between congenital heart disease and Blake pouch cyst.

KEY FACTS

TERMINOLOGY

- Cisterna magna measuring > 10 mm
- Most benign entity within spectrum of abnormalities involving roof of rhombencephalon

IMAGING

- Enlarged posterior fossa CSF space
 - Measured in axial oblique plane at level of cerebellar hemispheres with cavum septi pellucidi in image
- Cerebellar hemispheres normally formed
- Normal cisterna magna septa often bowed outward
- Sagittal view shows vermis completely covering 4th ventricle
- May show scalloping of inner table of skull due to CSF pulsations
- < 20% have associated anomalies
 - Ventriculomegaly is most common

TOP DIFFERENTIAL DIAGNOSES

- Blake pouch cyst
 - Vermis normally formed but rotated superiorly
- Arachnoid cyst
 - Look for mass effect on vermis/brainstem
- Dandy-Walker malformation
- Vermian agenesis (partial or complete)

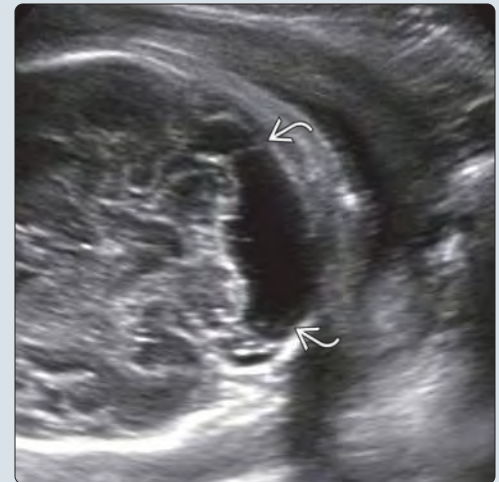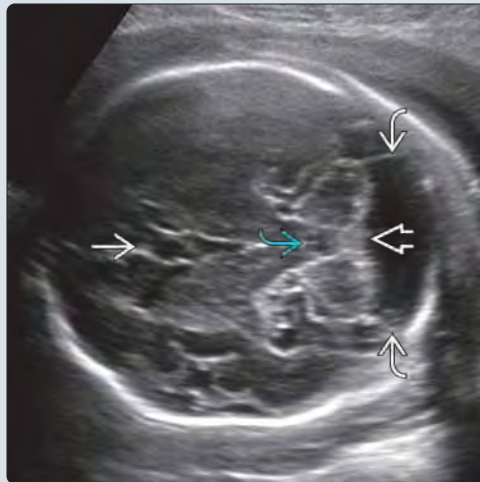
CLINICAL ISSUES

- Usually incidental finding
 - If isolated, excellent prognosis with low risk of aneuploidy and high probability of normal development
- Can be part of multiple findings seen with trisomy 18

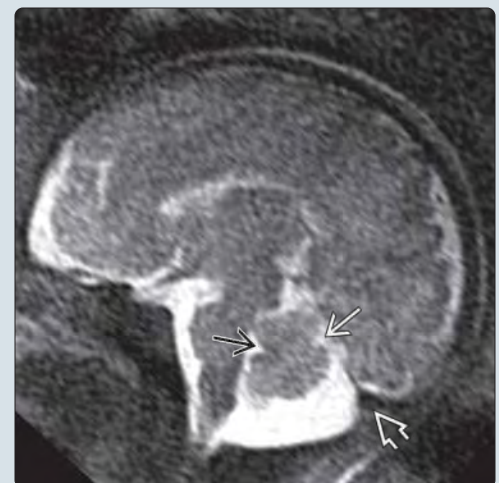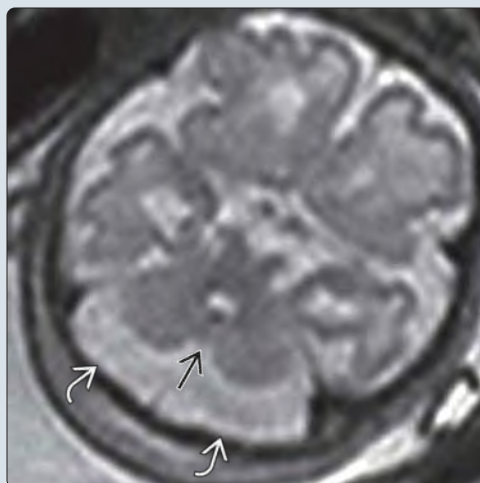
DIAGNOSTIC CHECKLIST

- Steep scanning angle may simulate MCM
- Carefully document vermis to rule out partial vermian agenesis

(Left) Axial oblique ultrasound shows a mega cisterna magna (MCM). The vermis is intact and the 4th ventricle is normal. The cavum septi pellucidi is visible, confirming the correct scan plane for measurement of the cisterna magna depth. **(Right)** Axial oblique ultrasound shows the bowed cisterna magna septa. These represent remnants of the walls of Blake pouch, which enlarges when fenestration is delayed. In some instances MCM would probably be more correctly described as mega Blake pouch.



(Left) Axial fetal MR at 35-weeks gestation shows the typical appearance of an MCM. The 4th ventricle roof remains covered by the vermis. **(Right)** Sagittal T2WI MR shows an MCM. There is increased cerebrospinal fluid volume in the posterior fossa, but the vermis is structurally normal and not rotated. Note the fastigial point and primary vermian fissure. The torcular position is also normal.



TERMINOLOGY**Abbreviations**

- Mega cisterna magna (MCM)

Definitions

- Cisterna magna measuring > 10 mm

IMAGING**General Features**

- Best diagnostic clue
 - Enlarged posterior fossa cerebrospinal fluid (CSF) space
- Size
 - Normal cisterna magna \leq 10 mm
 - Some data suggest males have slightly higher mean cisterna magna measurement

Ultrasonographic Findings

- Measured in axial oblique plane at level of cerebellar hemispheres
 - Should also see cavum septi pellucidi in image
 - Avoid angled semicoronal plane
 - Mimics MCM or inferior vermian defect
- Should see normal septa traversing cisterna magna
 - Often bowed outward in MCM
 - Typically arise at cerebellovermian junction inferior to vermian
 - Extend posteriorly to occipital bone
- 4th ventricle is normal
- Cerebellar hemispheres normally formed
- Cerebellar vermian is complete and normal

MR Findings

- Axial view shows enlarged cisterna magna
- Sagittal view shows vermian completely covering 4th ventricle
 - Normal tegmento-vermian angle
 - Normal vermian fastigial point and primary fissure
- May show scalloping of inner table of skull
 - Due to CSF pulsations

Imaging Recommendations

- Evaluate carefully for associated abnormalities
 - < 20% will have associated anomalies
 - Ventriculomegaly most common if additional abnormality present
 - Trisomy 18
 - Cardiac defects
 - Choroid plexus cysts
 - Omphalocele
 - Clenched hands
 - Rocker-bottom feet

DIFFERENTIAL DIAGNOSIS**Blake Pouch Cyst**

- Persistent Blake pouch in posterior fossa
- Vermian normally formed but rotated superiorly

Arachnoid Cyst

- Extraaxial CSF-containing lesion

- Mass effect on adjacent brain
- Displacement or obliteration of cisterna magna septa

Dandy-Walker Malformation

- Cystic dilation of 4th ventricle in direct communication with enlarged cisterna magna
- Associated with vermian deficiency

Vermian Agenesis: Partial or Complete

- Partially absent inferior vermian without large posterior fossa cyst

PATHOLOGY**General Features**

- Embryology
 - Cisterna magna forms in 2 compartments
 - Midline compartment between cisterna magna septa (i.e., walls of Blake pouch) contains intraventricular CSF
 - Lateral compartments develop from cavitation of meninx primitiva (i.e., true subarachnoid space)
 - Fenestration at Blake metapore creates communication between Blake pouch (which is in continuity with 4th ventricle) and cisterna magna
 - Blake metapore becomes foramen of Magendie when fenestration occurs
 - Delayed fenestration results in enlarged Blake pouch/posterior fossa
 - After fenestration Blake pouch decompresses
 - Vermian comes to lie flat against brainstem
 - Increased space in posterior fossa fills with CSF → MCM

CLINICAL ISSUES**Presentation**

- Usually incidental finding
- Can be part of multiple findings seen with trisomy 18

Natural History & Prognosis

- Most benign entity within spectrum of abnormalities involving roof of rhombencephalon
 - Spectrum previously described as Dandy-Walker continuum
- If isolated, excellent prognosis with low risk of aneuploidy and high probability of normal development

DIAGNOSTIC CHECKLIST**Image Interpretation Pearls**

- Too steep scanning angle may simulate MCM
- Carefully document vermian to rule out partial vermian agenesis

SELECTED REFERENCES

1. D'Antonio F et al: Systematic review and meta-analysis of isolated posterior fossa malformations on prenatal ultrasound: nomenclature, diagnostic accuracy and associated anomalies. *Ultrasound Obstet Gynecol.* ePub, 2015
2. Ghali R et al: Perinatal and short-term neonatal outcomes of posterior fossa anomalies. *Fetal Diagn Ther.* 35(2):108-17, 2014
3. Robinson AJ et al: The cisterna magna septa: vestigial remnants of Blake's pouch and a potential new marker for normal development of the rhombencephalon. *J Ultrasound Med.* 26(1):83-95, 2007

KEY FACTS

TERMINOLOGY

- Hypoplasia refers to small but complete anatomical structure with congenital volume diminution

IMAGING

- May involve vermis, hemispheres, or entire cerebellum
- Must differentiate between large cisterna magna, often of no clinical significance, and small cerebellum
 - Measure cerebellum and compare to normative data
- MR recommended for more detailed evaluation including brainstem and cerebral peduncles

TOP DIFFERENTIAL DIAGNOSES




- Other causes of enlarged posterior fossa
 - Dandy-Walker malformation
 - Arachnoid cyst
 - Mega cisterna magna
- Cerebellar disruption
- Rhombencephalosynapsis

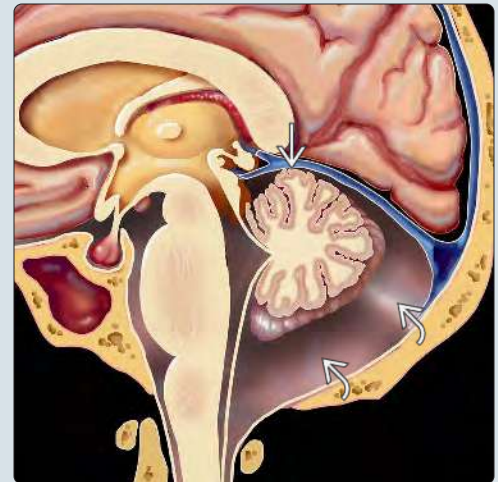
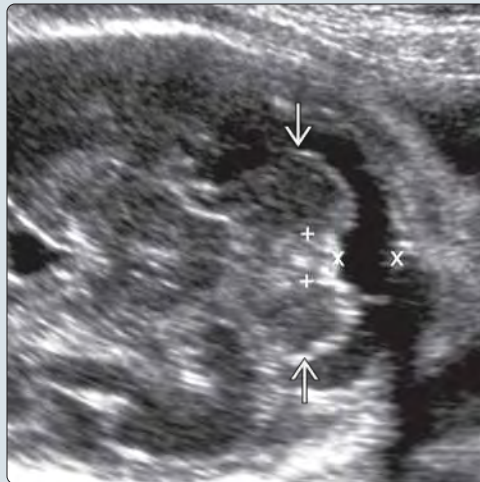
CLINICAL ISSUES







- If isolated, variable but stable neurological consequences
- Seen in many genetic/chromosomal disorders
- As part of pontocerebellar hypoplasias
 - Often progressive condition with poor outcome
 - May have autosomal recessive inheritance → 25% recurrence risk

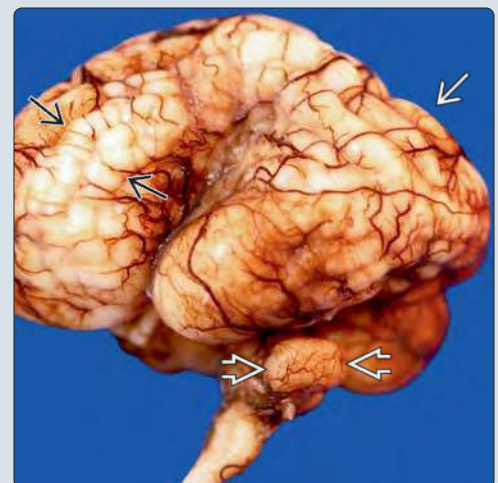
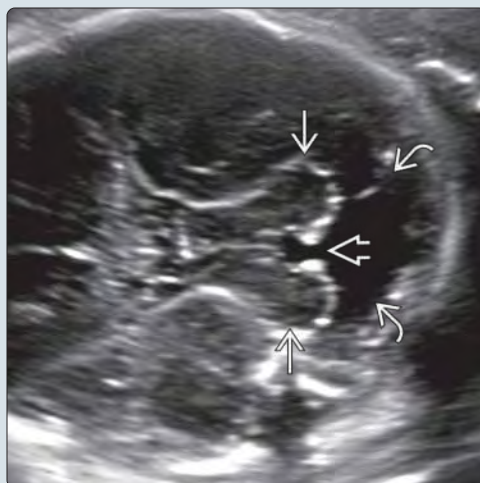
DIAGNOSTIC CHECKLIST

- In sagittal view, vermis should be same size as hemispheres
- In coronal view, vermis should extend inferiorly to same level as hemispheres after 18-20 weeks
- Beware of confusing vermian rotation with vermian hypoplasia or dysgenesis
 - Up to 24 weeks, normal rotated vermis may cause confusion
 - Sagittal views vital for differentiation

(Left) Axial US shows how to measure transverse cerebellar diameter (TCD) (between ) , vermian width (+ to +), and cisterna magna depth (x to x). This is the best plane for TCD and 4th ventricle evaluation. **(Right)** Sagittal graphic shows cerebellar hypoplasia. The vermis  is structurally normal but decreased in volume. This makes the posterior fossa cerebrospinal fluid space  seem large.



(Left) Axial oblique posterior fossa view shows small cerebellar hemispheres  and an apparently "roomy" cisterna magna . The vermis was present in this case but rotated superiorly, resulting in the keyhole appearance  seen between the cerebellar hemispheres. **(Right)** Lateral surface view of the brain from a dichorionic twin of a dichorionic pair shows areas of pachygyria , polymicrogyria , and severe cerebellar hypoplasia . The other twin was normal. There was no final diagnosis in this case.



TERMINOLOGY

Definitions

- **Hypoplasia** refers to small but complete anatomical structure with congenital volume diminution
- **Atrophy** refers to initially normal cerebellum with progressive increase in size of fissures compared to size of folia
- **Agenesis** refers to absence of structure; may be partial or complete

IMAGING

General Features

- May involve vermis, hemispheres, or entire cerebellum

Ultrasonographic Findings

- Cerebellum normal in morphology but small
 - Must differentiate between large cisterna magna and small cerebellum
- Asymmetry in size between cerebellar hemispheres if only 1 is involved
- Apparent posterior fossa "cyst" between cerebellar hemispheres if only vermis is small

MR Findings

- Similar to ultrasound but may be easier to visualize anatomy
 - Scan planes not as compromised by fetal position
 - Also useful for evaluation of additional brain malformation in late gestation or with maternal obesity
- Brainstem and pons more easily seen
 - May see abnormally small pons
 - May see primitive Z-shaped brainstem morphology

Imaging Recommendations

- Protocol advice
 - Ultrasound
 - If fetus is in cephalic presentation, TVUS provides high-resolution sagittal and coronal images
 - Midsagittal plane enables visualization of all vermian lobules, fissures, and shape of fastigium and 4th ventricle
 - Measurement technique for vermis
 - Magnify or zoom onto posterior fossa once correct scan plane obtained
 - Anteroposterior length defined as maximal distance between most anterior central lobule and most posterior tuber
 - Craniocaudal length defined as maximal distance between most cranial part of culmen and most caudal uvula
 - Transverse diameter is maximal side-to-side measurement of echogenic vermis between hemispheres at level of 4th ventricle
 - Calculate mean of 2-3 measurements
 - Transverse cerebellar diameter defined as maximal side-to-side measurement of hemispheres at level of 4th ventricle
 - 3D volume acquisition

- Use mastoid foramen transabdominally; ensure no shadowing from petrous apex before acquiring 3D volume
- MR excellent for multiplanar imaging
 - Coronal view best for evaluation of hemispheres and vermis
 - Axial view best for measurement of transverse cerebellar diameter/4th ventricle size
 - Also best view for thickness of cerebellar peduncles
 - Sagittal image best for vermian diameters, ratio of superior to inferior parts
 - Also look at pons, cisterna magna, tentorium

DIFFERENTIAL DIAGNOSIS

Enlarged Posterior Fossa

- Dandy-Walker malformation
- Arachnoid cyst
- Mega cisterna magna

Cerebellar Disruption

- Cerebellum developed normally, but insult → damage/destruction
 - Infection (rubella, parvovirus, CMV)
 - Hemorrhage/ischemic infarction
- Most are unilateral

Pontocerebellar Hypoplasia Syndromes

- Pontine bulge small or absent
- Brainstem thin, often kinked or Z-shaped

Rhombencephalosynapsis

- Fusion of cerebellar lobes with absent vermis
- Folia run horizontally

PATHOLOGY

General Features

- Etiology
 - Nonspecific result of interference with normal migration of Purkinje cells from 4th ventricle germinal matrix or of neurons from rhombic lips
- Genetics
 - Seen in many genetic/chromosomal disorders
 - Trisomies 9, 13, 18
 - *KIAA1279* gene → Goldberg-Shprintzen syndrome with pachygyria
 - *VLDRL* mutation → Hutterite form with microcephaly
 - Xp11.21-q24 → cerebellar hypoplasia with ophthalmoplegia
 - Fragile X syndrome
- Associated abnormalities
 - Part of many complex syndromes (e.g., Goldenhar, Moebius)
 - Congenital muscular dystrophies
 - Pontocerebellar hypoplasias

CLINICAL ISSUES

Presentation

- Abnormal posterior fossa

Cerebellar Biometry

Vermis Measured on Sagittal Transvaginal Image

GA (weeks)	AP (mm)	CC (mm)	Circumference (mm)	Area (cm ²)
21-22	10.6 ± 1.4	11.1 ± 1.1	43.8 ± 3.3	0.9 ± 0.2
29-30	17.5 ± 1.2	17.7 ± 2.1	64.7 ± 6.5	2.3 ± 0.4
39-40	25.7 ± 2.3	25.0 ± 2.6	86.7 ± 7.0	4.9 ± 0.7

Vermis Measured on Axial Oblique Transabdominal Image

GA (weeks)	AP (mm)			
21	5.76 ± 0.83			
28-29	10.4 ± 1.17			
37-38	15.4 ± 1.01			

Cerebellar Hemisphere Circumference/Area on Axial Oblique Transabdominal Image

GA (weeks)			Circumference (mm)	Area (cm ²)
20			30.3 ± 2.5	0.74 ± 0.11
30			56.0 ± 5.2	2.5 ± 0.41
40			81.6 ± 5.8	5.28 ± 0.62

Transverse Cerebellar Diameter on Axial Oblique Transabdominal Image

GA (weeks)	TCD (mm)			
20	20.4 ± 0.9			
30	37.3 ± 1.6			
40	55.8 ± 2.3			

AP = anteroposterior; CC = craniocaudal; TCD = transverse cerebellar diameter; GA = gestational age. Data summarized from Sherer et al 2007, Zalel et al 2002, and Malinge et al 2001.

Natural History & Prognosis

- Isolated
 - Nonprogressive
 - Variable neurological consequences
 - Ataxia, hypotonia, tremor
 - Cognitive, speech impairment
 - Strabismus, nystagmus
- Unilateral hemispheric "hypoplasia" (better described as "cerebellar disruption")
 - Bleed, infection, other insult
 - Prognosis relatively good if vermis not involved and rest of brain normal
 - Consider syndromes such as PHACES
- As part of pontocerebellar hypoplasias
 - Often progressive condition with poor outcome
 - May have autosomal recessive inheritance → 25% recurrence risk

- Beware of confusing, medially displaced cerebellar hemispheres for inferior vermis
 - Look at 4th ventricular shape and primary/secondary fissures originating from fastigial point

Reporting Tips

- When vermis or part of it is small but all lobules are present and there are no other associated anomalies, vermian hypoplasia should be diagnosed
- When vermian hypoplasia is associated with a small transverse cerebellar diameter and pontine bulge is missing, pontocerebellar hypoplasia should be diagnosed
 - Prognosis is universally grim
- When part of vermis is missing, vermian dysgenesis should be diagnosed
 - Do not diagnose vermian agenesis before 18 weeks
 - Prognosis depends on existence of associated malformations
- Up to 24 weeks, normal rotated vermis (i.e., delayed fenestration of Blake pouch) may cause confusion with vermian dysgenesis
- Cerebellar atrophy can only be diagnosed if early studies show normal size and morphology with later inadequate growth

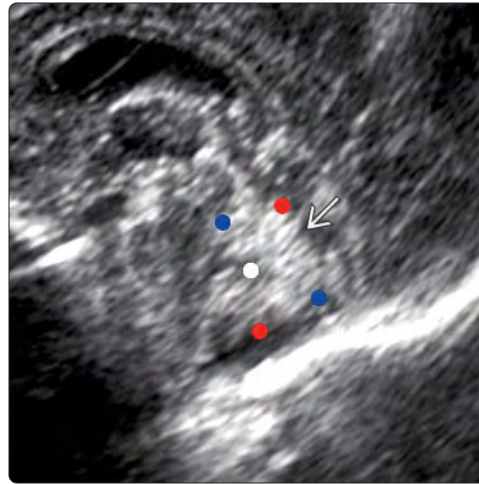
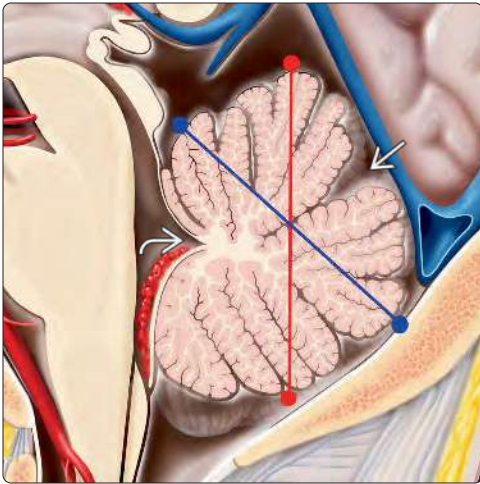
DIAGNOSTIC CHECKLIST




Image Interpretation Pearls

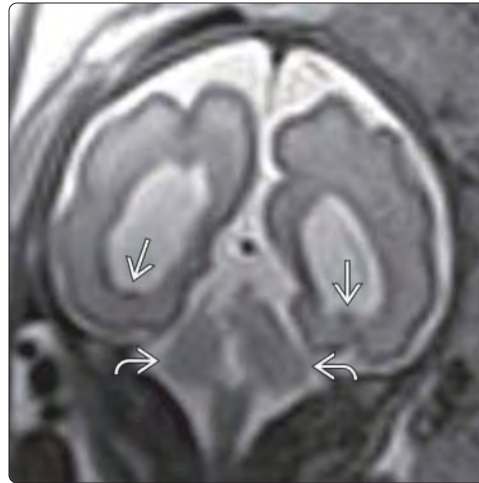
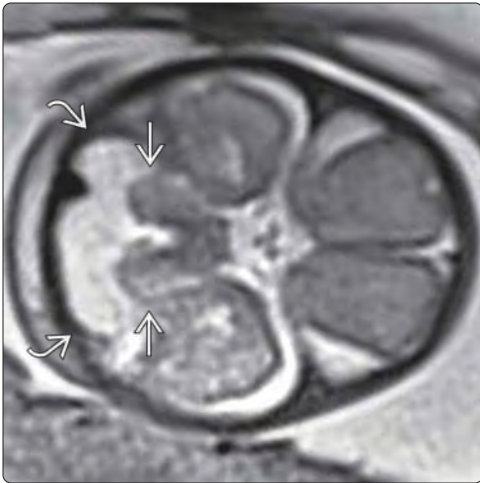
- In coronal ultrasound view, vermis should extend inferiorly to same level as hemispheres after 18-20 weeks
- In sagittal view (MR or US), vermis should be same size as hemispheres
 - Small vermis → vermian hypoplasia, which may be isolated phenomenon
- Beware of confusing vermian rotation with vermian hypoplasia; sagittal views vital for differentiation
 - Measure vermis and tegmentovermian angle





SELECTED REFERENCES

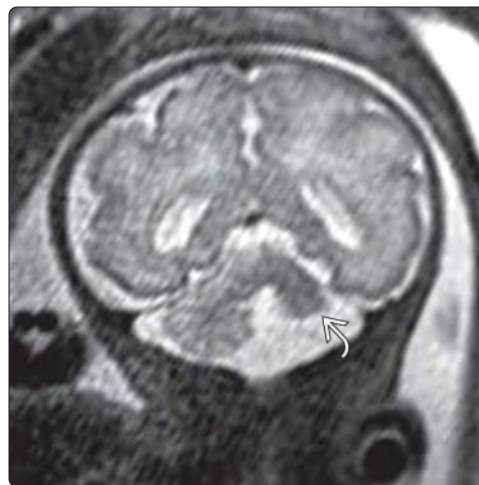
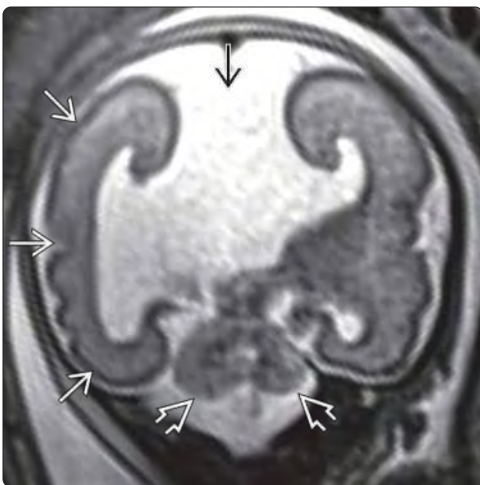
1. D'Antonio F et al: Systematic review and meta-analysis of isolated posterior fossa malformations on prenatal ultrasound: Nomenclature, diagnostic accuracy and associated anomalies. *Ultrasound Obstet Gynecol.* ePub, 2015
2. D'Antonio F et al: Systematic review and meta-analysis of isolated posterior fossa malformations on prenatal imaging (part 2): neurodevelopmental outcome. *Ultrasound Obstet Gynecol.* ePub, 2015







(Left) Sagittal graphic shows the vermian lobules. Measure craniocaudal diameter (red line) from culmen superiorly to uvula inferiorly. Measure the AP diameter (blue line) from the central lobule anteriorly to the tuber posteriorly (fastigial point , primary fissure ). (Right) Sagittal transabdominal US (as often obtained when showing parents the profile) shows measurement points. Red dots indicate the CC diameter, blue dots the AP diameter, and white dot the fastigium. Primary fissure  is also noted.



(Left) Axial oblique MR shows normal but small cerebellar hemispheres  with increased space in the posterior fossa  due to the diminished cerebellar volume. (Right) Coronal T2 HASTE MR in the same case shows mild ventriculomegaly and nodular gray matter heterotopia  as additional supratentorial findings in addition to cerebellar hypoplasia . MR often yields additional information regarding associated findings.



(Left) Coronal MR shows agenesis of the CC  and abnormal sulcation of the right cerebral hemisphere  in addition to cerebellar hypoplasia . This infant died shortly after birth. (Right) Coronal MR shows a small left cerebellar hemisphere  in a fetus with PHACES syndrome. Technically this is not hypoplasia because this hemisphere is structurally abnormal. However, the term hemihypoplasia is widely used to describe this appearance. Unilateral cerebellar disruption would be more correct.

KEY FACTS

TERMINOLOGY

- Midline fusion of cerebellar hemispheres with partial or complete loss of vermis

IMAGING

- Abnormal cerebellar morphology
- Horizontally oriented folia cross midline
 - May be difficult to demonstrate in fetus
- May be other intracranial anomalies
 - Hydrocephalus
 - Callosal dysgenesis/agenesis
 - Septo-optic dysplasia
 - Holoprosencephaly

TOP DIFFERENTIAL DIAGNOSES

- Cerebellar hypoplasia
- Unilateral cerebellar disruption
- Dandy-Walker malformation
- Vermian agenesis: Partial or complete

- Joubert syndrome

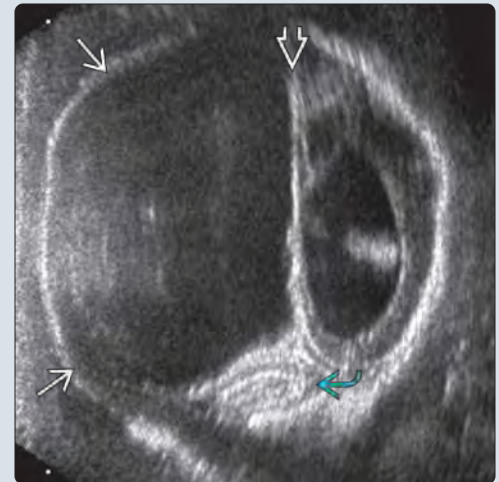
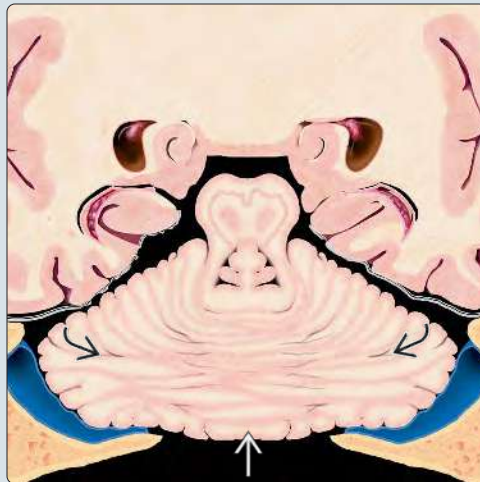CLINICAL ISSUES

- Neurological defects vary from mild to severe
 - Prenatal hydrocephalus seems to be unfavorable prognostic feature
- Majority have some cognitive impairment
- Treatment
 - Careful postnatal evaluation by pediatric neurologist and endocrinologist
 - Hydrocephalus may require shunt placement

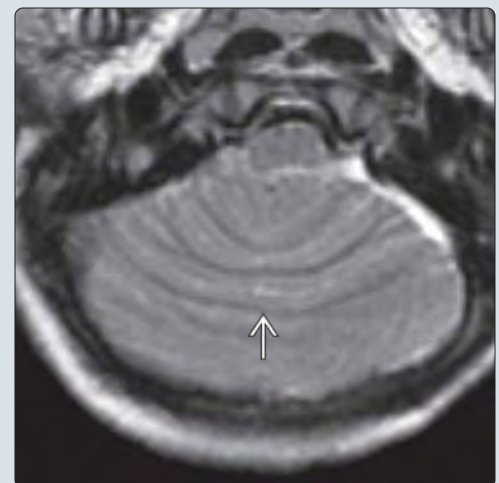
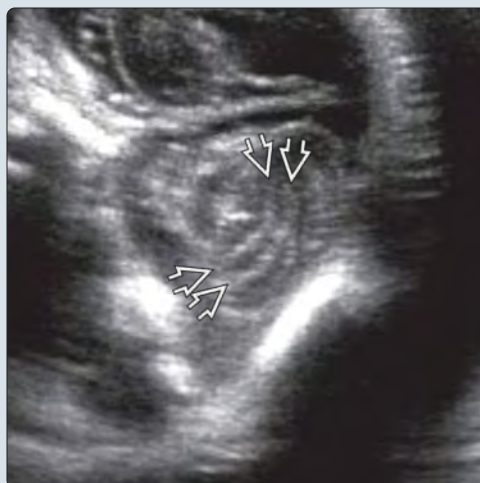DIAGNOSTIC CHECKLIST

- Small, single-lobed cerebellum is hallmark of rhombencephalosynapsis
- Fetal presentation, particularly with marked ventriculomegaly, likely represents severe end of spectrum
- Detailed evaluation of posterior fossa structure mandatory in any fetus with severe ventriculomegaly

(Left) Coronal graphic demonstrates the appearance of rhombencephalosynapsis (RES). There is a single-lobed cerebellum with no vermis. The folia are horizontally aligned. **(Right)** Coronal US of the fetal brain shows the characteristic horizontal folia in a small, but recognizable, cerebellum. Note the asymmetric placement of the falx and large interhemispheric cyst in this fetus with AVID as well as RES. Supratentorial brain abnormalities are associated with worse outcome.



(Left) US of the posterior fossa shows a small cerebellum with horizontally aligned folia. The vermis is absent. This fetus also had agenesis of the corpus callosum. **(Right)** Axial postnatal MR demonstrates fusion of the cerebellar hemispheres and no normal midline vermian tissue. The horizontal folia are beautifully demonstrated on high-resolution MR studies.



TERMINOLOGY**Abbreviations**

- Rhombencephalosynapsis (RES)

Definitions

- Midline fusion of cerebellar hemispheres with partial or complete loss of vermis

IMAGING**Ultrasonographic Findings**

- Small posterior fossa
- Reduced volume of cerebellum
 - Decrease in transverse diameter much more marked than that of AP diameter
- Abnormal cerebellar morphology
 - Less severe end of spectrum has recognizable shape of cerebellum with deficient vermis
 - Most severe is tiny, featureless blob of tissue in midline
- Look for horizontal orientation of folia crossing midline
 - May be difficult to demonstrate in fetus especially in severe cases
- Fetal cases generally seen in association with severe ventriculomegaly
 - Absent cavum septi pellucidi
 - Fused fornices
 - AVID
 - Asymmetric ventriculomegaly
 - Interhemispheric cyst
 - Dysgenesis of corpus callosum

MR Findings

- Abnormal midline sagittal view of cerebellum
 - No normal fastigial point
 - No primary vermian fissure
- Posterior pointing of 4th ventricle creates keyhole or diamond configuration
 - Not open defect as in Dandy-Walker continuum
- Multiple other intracranial findings described: Incidence based on postnatal series
 - 50% hydrocephalus: Impaired cerebrospinal fluid (CSF) flow at 4th ventricle
 - 71% dysgenesis/agenesis corpus callosum
 - 62% absent cavum septi pellucidi (70% of these with fused fornices)
 - 24% pontine hypoplasia
 - 17% cortical dysplasia
 - 7% holoprosencephaly

Imaging Recommendations

- If fetus cephalic, transvaginal ultrasound may provide improved visualization
- 3D volume acquisition to reconstruct sagittal image through posterior fossa
- Fetal MR
 - Confirm diagnosis
 - Evaluate supratentorial brain for subtle cortical dysplasia
 - Assess pons/brainstem
 - Infants with Z-shaped brainstem/pontine hypoplasia may not be able to breath independently

- Important information for planning delivery, neonatal resuscitation

DIFFERENTIAL DIAGNOSIS**Cerebellar Hypoplasia**

- Implies small, but anatomically complete, cerebellum
 - Intact vermis
 - Cerebellar lobes not fused

Unilateral Cerebellar Disruption

- Transverse cerebellar diameter decreased due to reduction in size of 1 hemisphere
- Vermis may be normal or deficient
- Strong association with PHACES syndrome

Dandy-Walker Malformation

- Enlarged posterior fossa
 - Elevated torcular of Herophili
- Complete or partial vermian agenesis with upward rotation of any remnant
- Cerebellar hemispheres separated by posterior fossa cyst

Vermian Agenesis: Partial or Complete

- Morphologically abnormal vermis
- Keyhole appearance of 4th ventricle
- Normal location of torcular of Herophili

Joubert Syndrome

- Molar tooth cerebellar peduncles
- Anterior convexity of floor of 4th ventricle
- Midline cerebellar cleft
 - Cerebellar lobes are not fused

PATHOLOGY**General Features**

- Etiology
 - Teratogens
 - Maternal diabetes mellitus
 - Maternal hyperpyrexia
 - Phencyclidine
- Genetics
 - Defective "isthmus organizer" → abnormal dorsal patterning
 - *FGF8* and *LMX1A* genes being considered
 - Case reports of interstitial deletion 2q-, tetrasomy 9p
 - Consanguinity: Possible autosomal recessive inheritance
- Associated abnormalities
 - Gómez-López-Hernández syndrome (a.k.a. cerebello-trigeminal-dermal dysplasia)
 - VACTERL
 - Septo-optic dysplasia
 - Facial, cardiovascular, respiratory, and urinary tract anomalies also described
- Embryology
 - Very early defect, probably 33- to 34-days gestation
 - Primary failure of vermian differentiation

Gross Pathologic & Surgical Features

- Vermian agenesis
- Fusion of
 - Cerebellar hemispheres

Features of Syndromes Associated With Rhombencephalosynapsis

Gómez-López-Hernández Syndrome	VACTERL Association
Cerebellar abnormalities	Vertebral defects
Craniofacial anomalies	Anal atresia
Craniosynostosis	Cardiac anomalies
Trigeminal nerve anesthesia	Tracheoesophageal fistula
Parietooccipital alopecia	Esophageal atresia
Short stature	Renal anomalies
Intellectual impairment	Limb defects (mostly radial ray)

(1) Sukhudyant B et al: Gómez-López-Hernández syndrome: reappraisal of the diagnostic criteria. *Eur J Pediatr.* 169(12):1523-8, 2010; (2) Solomon BD et al: Clinical geneticists' views of VACTERL/VATER association. *Am J Med Genet A.* 158A(12):3087-100, 2012.

- Dentate nuclei
- Superior cerebellar peduncles

CLINICAL ISSUES

Presentation

- Ventriculomegaly with abnormal posterior fossa

Demographics

- Rare but increasingly recognized
 - Isolated cases previously misdiagnosed as aqueductal stenosis
- Pediatric series exclude cases of pregnancy termination and neonatal demise
 - True incidence unknown
- 90 postnatal cases described in 2012 review
- Incidence of 0.13% in series of 3,000 pediatric MR scans

Natural History & Prognosis

- Prenatal diagnosis series of 4 cases
 - 1 termination of pregnancy (RES, aqueduct stenosis, no supratentorial brain malformation)
 - 2 neonatal demise (both with multiple anomalies in several organ systems)
 - 1 infantile death at 18 months (associated with holoprosencephaly and multiple other anomalies)
- Often short lifespan
 - Occasional survivors to early adulthood
 - Oldest reported survivor age 55 at diagnosis
- Neurological defects vary from mild to severe
 - Severity relates to associated supratentorial malformation
 - Ataxia (truncal or limb)
 - Involuntary head movements
 - Persistent figure 8 and side-to-side head shaking
 - May contribute to social isolation of affected children
- Seizure disorder
- Developmental delay
 - Full scale IQ reported in few cases
 - Range: 73-114 (pathological defined as < 85)
 - Majority have some cognitive impairment
 - Normal cognitive/language functions described with isolated RES
- Hypothalamic pituitary axis dysfunction
- Ocular abnormalities
 - Abnormal eye movements

- Strabismus
- Optic nerve atrophy
- Microphthalmia
- Older survivors
 - Bipolar disorder
 - Self-injurious behavior
 - Hyperactivity
 - Attention-deficit disorders
 - Cerebellar cognitive affective syndrome

Treatment

- Careful postnatal evaluation by pediatric neurologist and endocrinologist
 - Gómez-López-Hernández syndrome can easily be missed
- Hydrocephalus may require shunt placement

DIAGNOSTIC CHECKLIST

Consider

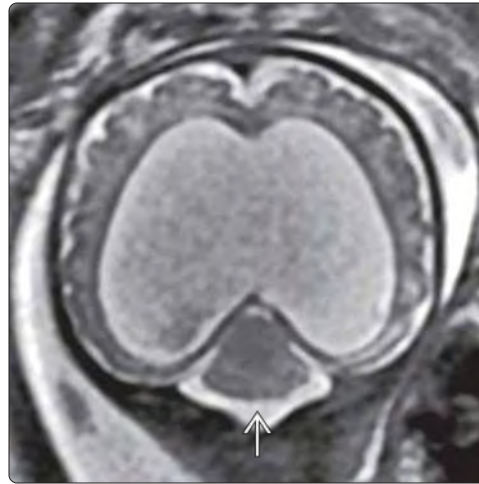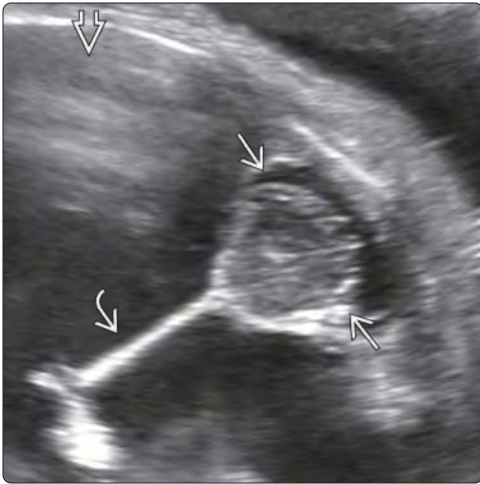
- Fetal MR invaluable to clarify posterior fossa malformations
- Fetal presentation, particularly with marked ventriculomegaly, likely represents severe end of spectrum

Image Interpretation Pearls

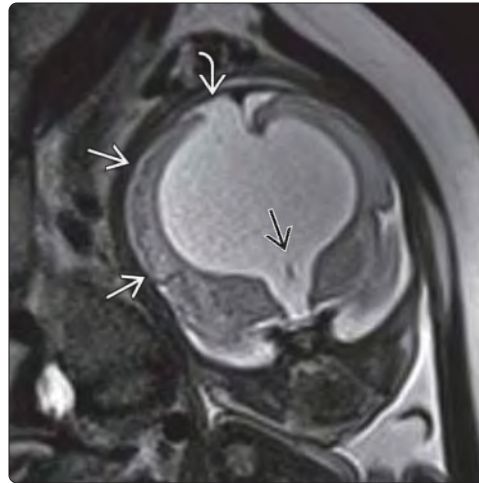
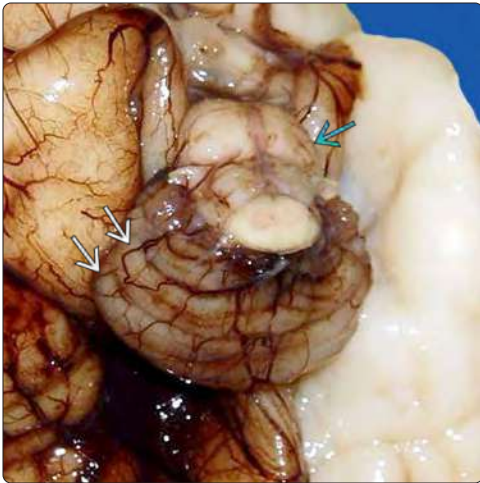
- Small, single-lobed cerebellum is hallmark of RES
- Detailed evaluation of posterior fossa structure mandatory in any fetus with severe ventriculomegaly

SELECTED REFERENCES

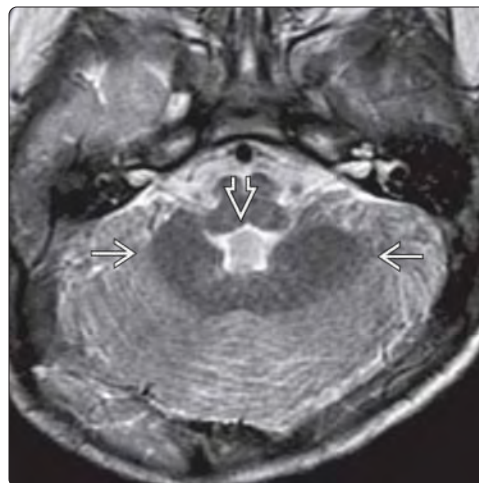
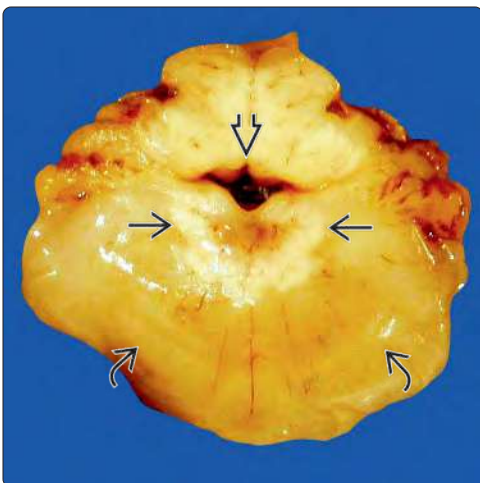
- Kobayashi Y et al: Gómez-López-Hernández syndrome in a Japanese patient: a case report. *Brain Dev.* 37(3):356-8, 2015
- Passi GR et al: Rhombencephalosynapsis. *Pediatr Neurol.* 52(6):651-2, 2015
- Whitehead MT et al: Rhombencephalosynapsis as a cause of aqueductal stenosis: an under-recognized association in hydrocephalic children. *Pediatr Radiol.* 44(7):849-56, 2014
- Cagneux M et al: Severe second-trimester obstructive ventriculomegaly related to disorders of diencephalic, mesencephalic and rhombencephalic differentiation. *Ultrasound Obstet Gynecol.* 42(5):596-602, 2013
- Barth PG: Rhombencephalosynapsis: new findings in a larger study. *Brain.* 135(Pt 5):1346-7, 2012
- Ishak GE et al: Rhombencephalosynapsis: a hindbrain malformation associated with incomplete separation of midbrain and forebrain, hydrocephalus and a broad spectrum of severity. *Brain.* 135(Pt 5):1370-86, 2012
- Koprivsek KM et al: Partial rhombencephalosynapsis: prenatal MR imaging diagnosis and postnatal follow up. *Acta Neurol Belg.* 111(2):157-9, 2011
- Pasquier L et al: Rhombencephalosynapsis and related anomalies: a neuropathological study of 40 fetal cases. *Acta Neuropathol.* 117(2):185-200, 2009



(Left) Axial oblique fetal US shows the more severe end of the spectrum of appearances. The cerebellum is tiny and featureless. Note that there is severe ventriculomegaly in this case. The falx cerebri is shown. (Right) Fetal MR in a similar patient shows the tiny, featureless cerebellum in a fetus with severe ventriculomegaly. The horizontal folia are not always visible in fetal imaging due to limitations with field of view, sequence selection, and image resolution.



(Left) View of the undersurface of the fixed brain shows horizontal folia. This was not demonstrable on US or MR due to the limitations of field of view and resolution. The cerebellum is tiny in relation to the size of the brain and brainstem. (Right) Coronal T2WI MR illustrates the associated abnormalities of fused fornices, interhemispheric cyst, and cortical dysplasia (abnormal sylvian fissure and gyral pattern) in this fetus with RES and AVID.



(Left) Gross pathology from an infant who died within hours of birth shows fusion of the cerebellar hemispheres and dentate nuclei, along with a diamond-shaped 4th ventricle. These are all classic findings of RES. (Right) Axial MR in a child with RES shows the fused dentate nuclei and the resultant abnormal shape of the 4th ventricle.

KEY FACTS

TERMINOLOGY

- Arteriovenous fistula between deep choroidal arteries and embryonic median prosencephalic vein of Markowski
- Vein of Galen aneurysmal malformation (VGAM) is actually misnomer

IMAGING

- Elongated midline cystic structure
 - Extends from quadrigeminal plate cistern posteriorly toward occiput
 - Drains via straight sinus or, more commonly, embryonic falcine sinus
- Flow on color Doppler with arterialized venous flow on pulsed wave tracing
- Other brain findings include both destructive (e.g., porencephaly) or developmental (e.g., migrational) lesions
- Serial US utilized to evaluate for developing hydrops or intracranial parenchymal damage

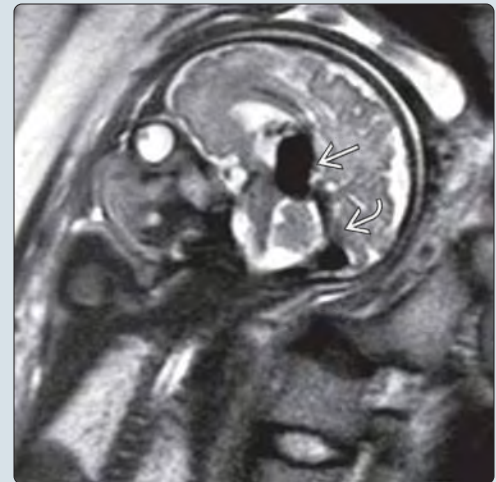
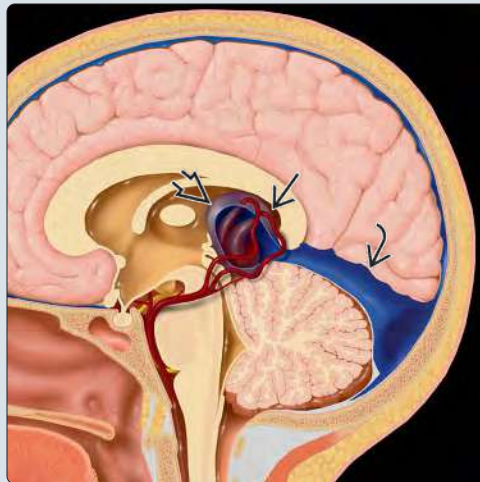
TOP DIFFERENTIAL DIAGNOSES

- Dural sinus malformation
- Arachnoid cyst

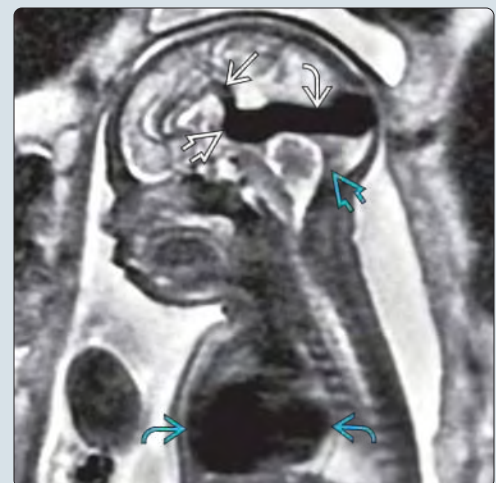
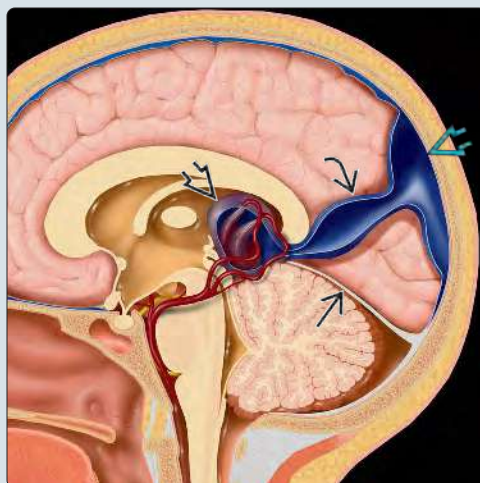
CLINICAL ISSUES

- Up to 80% of fetal cardiac output may be diverted to cerebral circulation
- Presence of any associated finding confers poor outcome
 - High mortality; survivors with neurologic or cardiac impairment
 - Most common associated findings include cardiomegaly (66.7%) and ventriculomegaly (38.9%)
 - Even mild cardiomegaly correlated with poor outcome
- Better prognosis for isolated VGAM without other findings
- At birth, vascular shunt usually increases
 - Cessation of flow to low-resistance placenta
- Aggressive treatment needed for congestive heart failure present at birth
 - Emergency embolization may be necessary

(Left) Sagittal graphic of a vein of Galen aneurysmal malformation (VGAM) shows enlarged posterior choroidal arteries fistulizing with a very dilated median prosencephalic vein (MPV) of Markowski. In this example, the MPV drains into an enlarged straight sinus. **(Right)** Sagittal T2WI MR shows a flow void in a dilated MPV, the typical appearance of a VGAM. In this case, the malformation drains into the straight sinus, as depicted previously.



(Left) In this example, the MPV drains into the superior sagittal sinus via an embryonic falcine sinus. The straight sinus is absent; this is the more common drainage pattern. **(Right)** Sagittal T2WI MR of a large VGAM shows the choroidal arteries fistulizing with the MPV. Drainage is via the embryonic falcine sinus. There is no flow void where the straight sinus should be seen. Also note the enlarged heart, a complication of the high-output state. This confers a very poor prognosis.



TERMINOLOGY

Definitions

- Vein of Galen aneurysmal malformation (VGAM) is actually misnomer
- Arteriovenous fistula (AVF) between deep choroidal arteries and embryonic median prosencephalic vein (MPV) of Markowski
 - High flow through MPV prevents formation of vein of Galen

IMAGING

General Features

- Best diagnostic clue
 - Enlarged midline vascular structure
- Location
 - Cistern of velum interpositum and quadrigeminal plate cistern
- Size
 - Variable depending on volume of shunt

Ultrasonographic Findings

- Grayscale ultrasound
 - **Brain findings**
 - Elongated midline cystic structure
 - Extends from quadrigeminal plate cistern posteriorly toward occiput
 - Drains via straight sinus or embryonic falcine sinus (more common)
 - Calcifications may be seen in thrombus (rare)
 - Ventriculomegaly
 - Intracranial hemorrhage uncommon but important complication
 - Other findings reported include both destructive and developmental lesions
 - Porencephaly
 - Periventricular leukomalacia
 - Cortical volume loss
 - Polymicrogyria, gray matter heterotopia, and other migrational abnormalities
 - Poor gray-white differentiation
 - Schizencephaly
 - **Findings of high-output state**
 - Cardiomegaly
 - Variable degrees depending on size of shunt
 - Tricuspid regurgitation
 - Enlarged jugular veins, inferior vena cava, and ductus venosus
 - Hydrops
- Color Doppler
 - Confirms mass is vascular
 - Turbulent flow
- Pulsed Doppler
 - High-velocity, low-resistance arterial flow in choroidal arteries
 - Arterialized flow in MPV

MR Findings

- T1WI
 - Useful for hemorrhage (high-signal foci)

- T2WI
 - Flow voids or mixed signal due to turbulent flow
- Ongoing research on diffusion weighted imaging to evaluate for ischemic changes

Imaging Recommendations

- Color and pulsed Doppler for any cystic brain mass
- Requires close follow-up for signs of impending hydrops
- Fetal MR better evaluates for associated brain findings
 - Hemorrhage, ischemic changes etc.
 - Valuable for patient counseling and postnatal planning

DIFFERENTIAL DIAGNOSIS

Other Arteriovenous Fistulae

- AVF can occur anywhere in brain
 - 85% supratentorial, 15% infratentorial

Dural Sinus Malformation

- Triangular extraaxial mass centered around torcular Herophili
- Generally thrombose and decrease in size over time

Venous Sinus Engorgement

- Can potentially be seen in any high cardiac output state

Arachnoid Cyst

- Extraaxial cerebral spinal fluid (CSF)-filled lesion
- Displaces adjacent brain
- No Doppler flow

Porencephaly

- CSF-filled intraparenchymal lesion
 - Irregular or round shape
- No Doppler flow
- No mass effect
- Ventriculomegaly

PATHOLOGY

General Features

- Etiology
 - In early embryologic development choroidal arterial tributaries drain via temporary midline vein (MPV)
 - MPV normally regresses during 11th week of gestation
 - By 12th week drainage is via internal cerebral/basal veins to form vein of Galen
 - VGAM forms when MPV fails to degenerate
 - Primitive arteriovenous fistula persists developing high-flow state
- Genetics
 - Sporadic
 - Rare reports of hereditary vascular dysplasia syndromes
 - Not associated with aneuploidy

Gross Pathologic & Surgical Features

- Dilated arterial vessels
- Midline engorged MPV
- Venous drainage
 - Straight sinus
 - Embryonic falcine sinus
 - More common

- If embryonic falx sinus present, straight sinus usually absent
- Hydrocephalus
 - Various theories on etiology
 - Compression of aqueduct
 - Venous hypertension impairing resorption of CSF
 - Ex vacuo from cerebral atrophy
- Cerebral atrophy: 2 possible etiologies
 - Secondary to vascular steal phenomenon
 - From chronic venous hypertension

Microscopic Features

- Direct arterial → venous connections
 - No intervening capillaries
 - Allows rapid, high-volume flow

CLINICAL ISSUES

Presentation

- Most common signs/symptoms
 - Hydrops
 - Most cases detected in 3rd trimester; usually > 34 weeks
 - Sporadic reports of 2nd-trimester detection as early as 22 weeks
- Other signs/symptoms
 - Cardiomegaly
 - Hydrocephalus

Demographics

- Gender
 - M:F = 2:1
- Epidemiology
 - Rare
 - < 1% of all cerebral vascular malformations but up to 30% of pediatric vascular malformations
 - Most common prenatally diagnosed cerebral vascular malformation

Natural History & Prognosis

- In utero high-output state
 - Up to 80% of fetal cardiac output may be diverted to cerebral circulation
 - High-output heart failure
 - Hydrops
- In study of 21 fetuses from 1 institution, presence of **any** associated finding conferred poor outcome (defined as death, neurologic, or cardiac impairment)
 - Most common associated findings include cardiomegaly (66.7%) and ventriculomegaly (38.9%)
 - Even mild cardiomegaly correlated with poor outcome
- Good outcome (normal neurologic or cardiac status) only when VGAM present without other findings
 - In same study of 21 fetuses only 3 (14.3%) had good outcome
- At birth, vascular shunt usually increases
 - Cessation of flow to low-resistance placenta
 - Can cause acute hemodynamic decompensation
- For those diagnosed at birth up to 62% mortality rate despite treatment
- Cognitive impairment in survivors may be present secondary to chronic venous hypertension
 - Wide range of manifestations

- Can be developmentally normal
 - More likely for those presenting later in childhood
 - Improved outcomes overall since advent of endovascular treatment
 - Early diagnosis and treatment imperative
- Some degree of impairment usually present for those diagnosed in utero
 - Delayed milestones
 - Intellectual impairment
 - Seizures

Treatment

- No in utero treatment
- Consider steroids and early delivery for any sign of developing hydrops
- Must deliver at tertiary care center where postnatal treatment can be immediately instituted
- Aggressive medical treatment of congestive heart failure
 - "Buy time" before fistula repair
 - Intervention easier and safer at 4-6 months of age
- Eventually requires transcatheter embolization
 - Reduce shunt flow
 - Improve high-output CHF
 - Prevent consequences of chronic cerebral venous hypertension
- Emergency embolization may be necessary
 - Neonates with refractory CHF

DIAGNOSTIC CHECKLIST

Consider

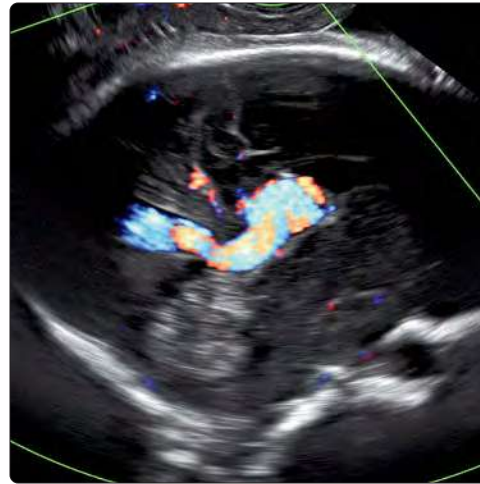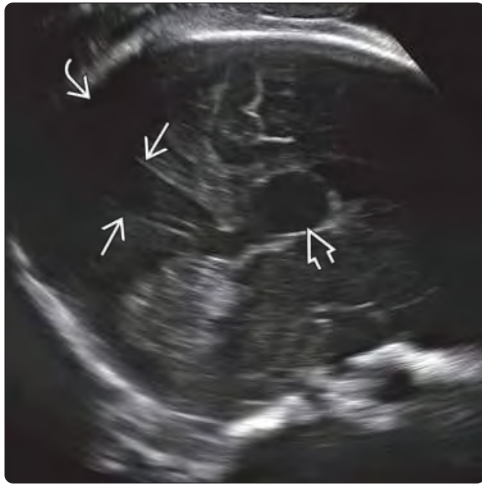
- Fetal MR to assess associated brain abnormalities

Image Interpretation Pearls

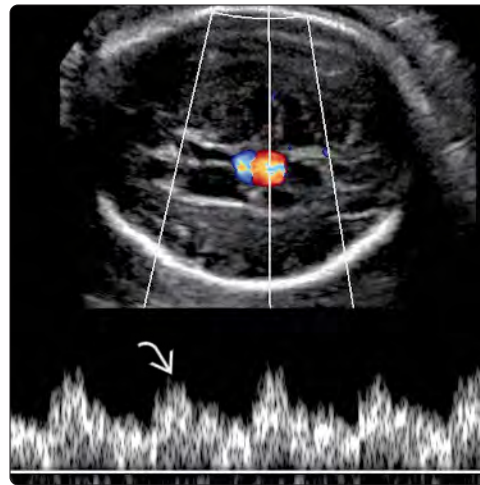
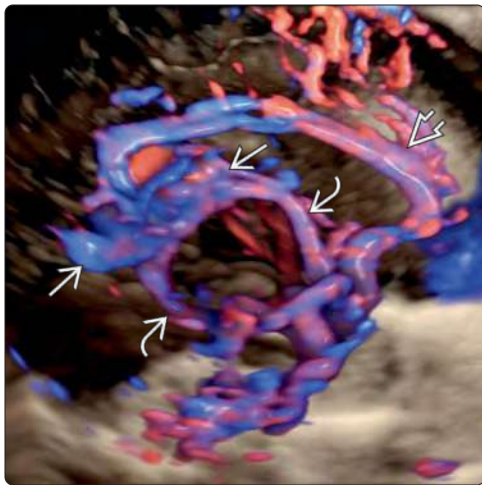
- Color Doppler should always be performed on any apparently cystic brain lesion
- Early prenatal detection imperative for aggressive management
 - Requires close sonographic follow-up
 - Delivery and treatment planning essential

SELECTED REFERENCES

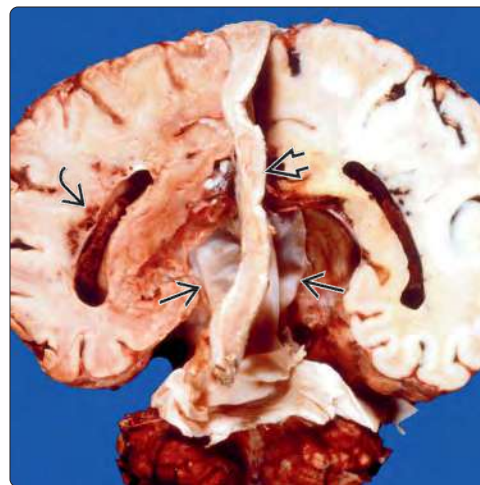
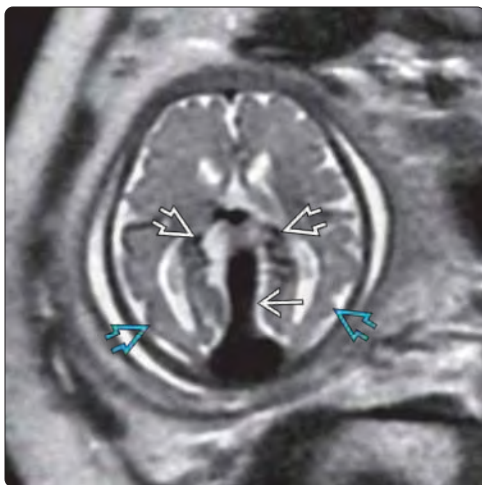1. Kwong Y et al: Fetal MRI demonstrating vein of Galen malformations in two successive pregnancies—a previously unreported occurrence. *Childs Nerv Syst.* 31(7):1033-5, 2015
2. Deloison B et al: Hidden mortality of prenatally diagnosed vein of Galen aneurysmal malformation: retrospective study and review of the literature. *Ultrasound Obstet Gynecol.* 40(6):652-8, 2012
3. Rios LT et al: Prenatal diagnosis of an aneurysm of the vein of Galen by three-dimensional power and color Doppler ultrasonography. *Clin Med Insights Case Rep.* 5:77-80, 2012
4. Gün I et al: Is prenatal volumetric evaluation of aneurysm of the vein of Galen important in the prediction of adverse fetal outcome? *J Clin Ultrasound.* 38(8):443-5, 2010
5. Heuer GG et al: Diagnosis and treatment of vein of Galen aneurysmal malformations. *Childs Nerv Syst.* 26(7):879-87, 2010
6. Kalra V et al: Fetal MR diagnosis of vein of Galen aneurysmal malformation. *Pediatr Radiol.* 40 Suppl 1:S155, 2010
7. McSweeney N et al: Management and outcome of vein of Galen malformation. *Arch Dis Child.* 95(11):903-9, 2010
8. Lasjaunias PL et al: The management of vein of Galen aneurysmal malformations. *Neurosurgery.* 2006 Nov;59(5 Suppl 3):S184-94; discussion S3-13. Review. Erratum in: *Neurosurgery.* 60(4 Suppl 2):393, 2007
9. Vijayaraghavan SB et al: Prenatal diagnosis of thrombosed aneurysm of vein of Galen. *Ultrasound Obstet Gynecol.* 27(1):81-3, 2006



(Left) Sagittal US of an incidentally noted hypoechoic, midline mass in the 3rd trimester shows it elongates posteriorly towards the superior sagittal sinus. (Right) Color Doppler US in the same plane confirms the VGAM, with turbulent flow, as typically seen within a fistula. VGAM is most commonly detected in the 3rd trimester. Subsequent evaluation for signs of high-output cardiac failure should be performed.



(Left) 3D color Doppler reconstruction of the same case shows an enlarged pericallosal artery and the body of the VGAM, with multiple deep choroidal arteries feeding into the fistula. Up to 80% of the fetal cardiac output can be shunted to the brain. (Right) Pulsed Doppler US shows arterialization of the venous waveform, which is typical for a fistula. The high-flow state can eventually lead to cardiac decompensation.



(Left) Axial fetal T2WI MR shows flow voids in the choroidal arteries, with an enlarged midline flow void typical of a VGAM. The cortex appears abnormal and thinned, particularly in the occipital lobes. (Right) Coronal gross section through the brain shows a collapsed, dilated VGAM seen behind the dissected superior sagittal sinus. There are diffuse ischemic changes (R > L) with areas of hemorrhage, which are common complications, especially with large shunts.

KEY FACTS

TERMINOLOGY

- Abnormal arterial to venous connection without intervening capillary network
 - 85% supratentorial, 15% posterior fossa
 - Pial, dural, or mixed
- Vein of Galen malformation is a specific, named arteriovenous fistula (AVF)

IMAGING

- Ultrasound
 - Cyst-like structure on grayscale images
 - "Tangle" of dilated vessels with alternating direction of flow on color Doppler
 - Cardiomegaly
 - Hydrops
 - Fetal growth restriction
- MR
 - Shunt vessels seen as flow voids on T2WI
 - Ischemic encephalomalacia

- Intracranial hemorrhage

TOP DIFFERENTIAL DIAGNOSES




- Vascular tumor
- Intracranial cyst

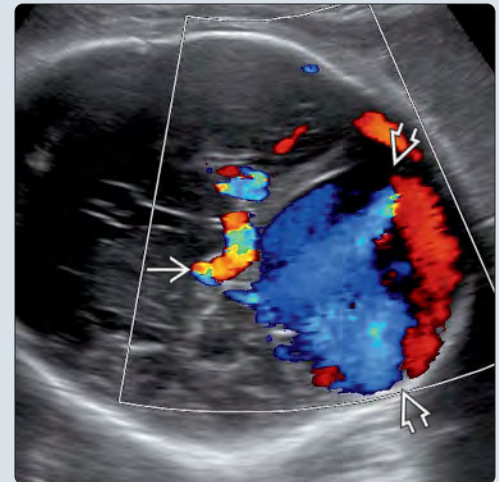
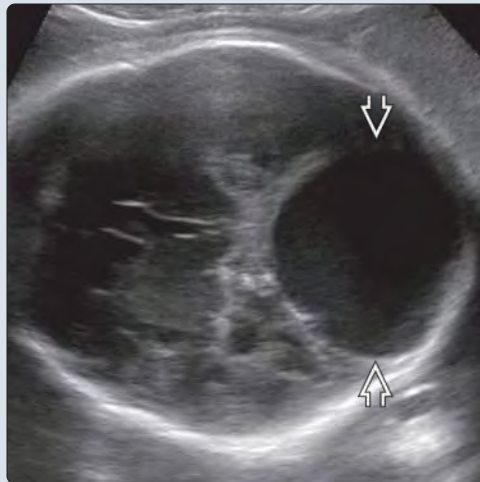
CLINICAL ISSUES

- Prognosis depends on associated findings, early delivery does not prevent ischemic damage
- High perinatal mortality rate when fetus is "symptomatic" (e.g., hydropic)
 - Consider comfort care if evidence of ischemic brain injury
- Embolization/surgery are options for survivors

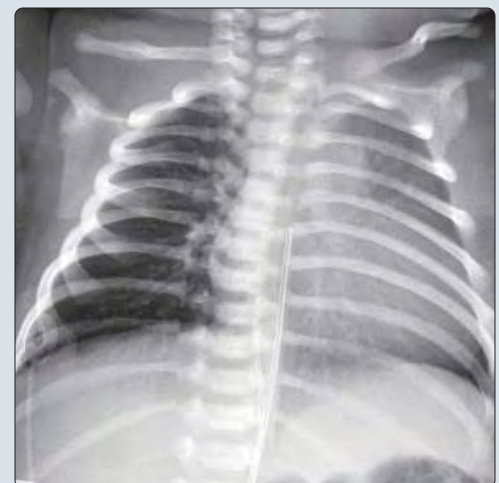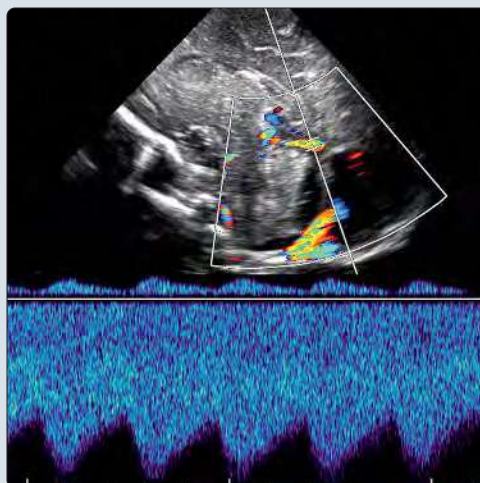
DIAGNOSTIC CHECKLIST

- Careful search for AVF in fetuses with apparent isolated cardiomegaly
- Always check Doppler of fluid-filled intracranial lesions

(Left) Transabdominal US in the 3rd trimester shows an intracranial "cyst" . This case was referred as a possible Dandy-Walker malformation. **(Right)** Color Doppler shows that the "cyst" is, in fact, a vascular structure . It was centered on the tentorium rather than in the posterior fossa. The supratentorial brain looked normal on ultrasound and MR (intracranial AVFs may cause ischemic encephalomalacia as a result of a vascular steal). Note the enlarged feeding vessels of the circle of Willis .



(Left) Spectral Doppler as part of the neonatal head ultrasound in the same patient shows the high-velocity, extremely low-resistance flow in the feeding vessels to this large dural AVF. **(Right)** Frontal chest radiograph in the same patient shows cardiomegaly. AVFs anywhere may cause high-output cardiac strain and hydrops. In this case, the lesion clotted spontaneously without any venous hypertension. The infant is alive and well at 18 months.



TERMINOLOGY**Definitions**

- Arteriovenous fistula (AVF) is abnormal arterial to venous connection without intervening capillary network
 - Vein of Galen malformation is specific, named AVF

IMAGING**General Features**

- Best diagnostic clue
 - Enlarged vessels with alternating direction of flow on color Doppler evaluation
- Location
 - May occur anywhere in brain
 - 85% supratentorial, 15% posterior fossa
 - Postnatal series in children up to 6 years of age 70.6% paramedian, 76.5% supratentorial
 - Pia, dural or mixed

Ultrasonographic Findings

- Brain findings
 - Cyst-like structure on grayscale images
 - "Tangle" of dilated vessels
 - Intracranial hemorrhage or ischemia
- Other findings
 - Enlarged neck vessels
 - Cardiomegaly
 - Up to 80% of fetal cardiac output may be diverted to cerebral circulation in presence of AVF
 - Hydrops may develop if sufficient shunt volume
- Doppler findings
 - High-velocity, low-resistance arterial flow
 - Arterialized venous structures
 - Alternating red and blue within vessel cross section

MR Findings

- Shunt vessels seen as flow voids on T2WI
- Intracranial hemorrhage, ischemic encephalomalacia
- DWI more sensitive for ischemic changes

Imaging Recommendations

- Protocol advice
 - Formal fetal echocardiography
 - Monitor for hydrops
 - Look for other vascular malformations
 - Look for ischemic brain injury

DIFFERENTIAL DIAGNOSIS**Vein of Galen Malformation**

- Specific AVF between deep choroidal arteries and embryonic median prosencephalic vein of Markowski
- Midline; characteristic appearance

Vascular Tumor

- Solid mass component but may be necrotic
- Dilated draining veins/neck vessels unlikely

Intracranial Cyst

- No Doppler flow

PATHOLOGY**General Features**

- Associated abnormalities
 - High-output cardiac failure
 - Ischemic brain injury
 - Vascular "steal" phenomenon
 - Hydrops → hypoperfusion, hypoxia
 - Direct compression of malformation limits brain perfusion → atrophy
 - Venous hypertension → hemorrhage
 - Venous thrombosis
 - Large lesions may lead to Kasabach-Merritt sequence in fetus
 - Hemolytic anemia, platelet consumption, disseminated intravascular coagulopathy

CLINICAL ISSUES**Presentation**

- Intracranial "cyst" with ventriculomegaly
- Most present in 3rd trimester; may have even had normal early scan
- Pediatric series presenting symptoms
 - Seizure 23.5%, headache 17.6%, enlarging head circumference 11.7%
 - Congestive heart failure 11.7%

Natural History & Prognosis

- No recurrence risk
- High perinatal mortality rate when fetus is "symptomatic"
- Pediatric series of 17 cases
 - 56.3% endovascular therapy only, 6.3% open surgery only, 37.5% multimodality approach
 - 18.8% complication rate, 11.7% demise

Treatment

- No intrauterine intervention
- Early delivery does not prevent ischemic damage
- Offer comfort care if evidence of hydrops, brain ischemia
- Deliver at tertiary center if postnatal embolization/surgery desired

DIAGNOSTIC CHECKLIST**Consider**

- Fetal MR best to demonstrate extent of lesion/associated encephalopathy

Image Interpretation Pearls

- Careful search for AVF in fetuses with apparent isolated cardiomegaly

SELECTED REFERENCES

1. Zaidi HA et al: Multimodal treatment strategies for complex pediatric cerebral arteriovenous fistulas: contemporary case series at Barrow Neurological Institute. *J Neurosurg Pediatr.* 1-10, 2015
2. Appaduray SP et al: Pediatric dural arteriovenous malformations. *J Neurosurg Pediatr.* 14(1):16-22, 2014

KEY FACTS

TERMINOLOGY

- Dural sinus malformation is focal dilatation of dural venous sinuses

IMAGING

- Posterior dural sinus malformation is grossly triangular, apex anterior
- Majority of fetal cases are thrombosed at presentation
- Ultrasound
 - Mixed echogenicity mass centered on tentorium, involving torcular Herophili
 - May appear round in cross section on axial images
- MR
 - High-signal areas within mass on T1WI due to clotted blood
 - Low/mixed signal on T2WI
 - Tubular areas of high T1/low T2 signal seen with clot extension within venous sinuses

TOP DIFFERENTIAL DIAGNOSES

- Arachnoid cyst
- Intracranial hemorrhage of other cause

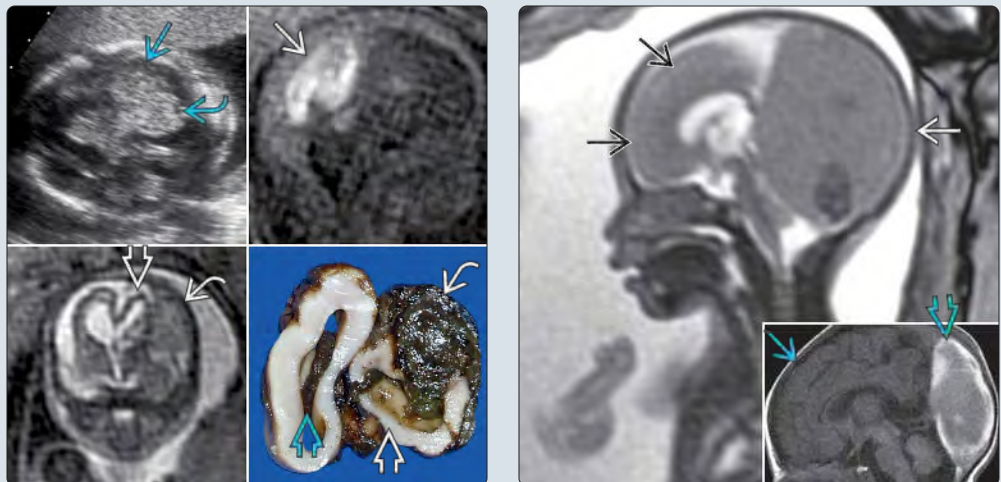
CLINICAL ISSUES

- Not associated with coagulopathy in mothers or fetuses
- Outcome highly variable
 - If no associated venous hypertension/ischemia outcome is excellent
 - If associated with venous hypertension then thrombosis/periventricular hemorrhagic infarction may lead to brain destruction

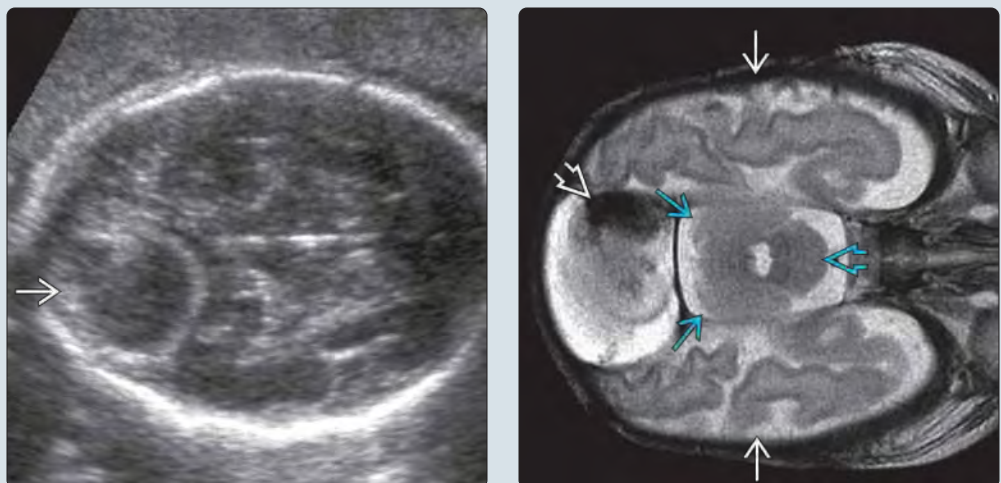
DIAGNOSTIC CHECKLIST

- Dilated or thrombosed dural pouch in region of confluens sinuum (torcular Herophili) suggests posterior dural sinus malformation

(Left) Composite shows US, MR, and autopsy pictures from a case with bad outcome. US shows intraventricular clot and hemorrhagic infarction. Sagittal T1WI MR shows a thrombosed malformation. Coronal T2WI MR and autopsy show extraaxial clot, ischemic cerebral cortex, and intraventricular clot. **(Right)** Fetal T2WI MR shows large thrombosed DSM. The brain looked normal. The neonatal T1WI MR (inset) confirmed normal brain and showed decrease in size of the thrombus. The infant was neurologically intact.



(Left) Third-trimester US shows the typical appearance of a thrombosed DSM in the conventional US axial plane. It is a well-circumscribed, extraaxial mass. The brain looks normal in this case and the infant was developmentally normal on follow-up. **(Right)** Axial postnatal T2WI MR in another case with good outcome shows a normal cerebrum, cerebellum, and brainstem with a small retracted clot in a DSM. At 20 weeks, this mass occupied almost 1/2 of the skull volume; it shrank as the brain grew.



TERMINOLOGY

Definitions

- Dural sinus malformation (DSM): Focal dilatation of dural venous sinuses
 - Lesion has also been referred to as thrombosis of torcular Herophili

IMAGING

General Features

- Location
 - Posterior
 - Involves torcular Herophili, superior sagittal sinus
 - Posterior to vermis, which can be displaced anteriorly
 - Lateral
 - Lateral sinus or jugular bulbs (rare in fetus)
- Morphology
 - Posterior DSM is grossly triangular, apex anterior

Ultrasonographic Findings

- Majority of fetal cases are thrombosed at presentation
- Mixed echogenicity mass centered on tentorium
- Doppler findings
 - Pulsatile flow in cystic mass if seen prior to thrombosis
 - No internal flow if thrombosis complete

MR Findings

- DSM
 - High signal T1WI due to clotted blood
 - Low/mixed signal on T2WI
- Clot extension
 - Tubular areas of high T1/low T2 signal conforming to venous sinus anatomy
- If thrombosed, may see
 - Intracranial hemorrhage
 - Cortical destruction

DIFFERENTIAL DIAGNOSIS

Arachnoid Cyst

- Should be anechoic with no flow on Doppler
- Mass effect but no parenchymal ischemia

Intracranial Hemorrhage of Other Cause

- Associated with history of trauma, co-twin demise, thrombocytopenia
- No extraaxial mass

PATHOLOGY

Gross Pathologic & Surgical Features

- Thrombus in enlarged veins centered on torcular Herophili
 - Venous hypertension can lead to infarction
 - Cases with numerous venous anastomoses do better, as venous drainage is not compromised by thrombosis
 - Arachnoid villi not developed in fetus; therefore, no CSF resorption, which leads to venous hypertension
- White matter petechial hemorrhage

CLINICAL ISSUES

Presentation

- Posterior fossa mixed echogenicity mass

Natural History & Prognosis

- Not associated with coagulopathy in mothers or fetuses
- Outcome highly variable
 - If no associated venous hypertension/ischemia, outcome is excellent
 - If associated with venous hypertension, thrombosis, periventricular hemorrhagic infarction
 - Cerebral palsy (may be severe)
 - ◻ Encephalomalacia
 - ◻ Cortical blindness
 - Seizure disorder
- Size of mass at diagnosis is not predictive of outcome
- Reducing size does not equate with decreased risk of neurological complication
- Good prognostic markers
 - Lack of brain damage
 - Flow in superior sagittal and straight sinuses
- 43 cases from literature + author's experience
 - Live birth in 78%, single intrauterine demise, remaining terminated pregnancy
 - 9% neonatal demise
 - Of survivors beyond neonatal period
 - 66% normal development
 - 20% developmental delay of which 30% severe
 - No developmental outcome in remaining cases

Treatment

- No specific therapy available
- If flow present, monitor for high-output cardiac decompensation
- If brain appears normal, reassure parents
 - Perform follow-up MR at 1-2 months of age
 - Careful clinical evaluation of children for neurodevelopmental delay
- If brain appears abnormal
 - Offer termination
 - Consider nonintervention in labor

DIAGNOSTIC CHECKLIST

Image Interpretation Pearls

- Triangular shape and posterior location are typical
- Prognosis likely to be good if isolated finding and no evidence of brain damage

Reporting Tips

- Dilated or thrombosed dural pouch in region of confluens sinuum (torcular Herophili) suggests midline DSM

SELECTED REFERENCES

1. Corral E et al: Thrombosis of the torcular herophili in the fetus: a series of eight cases. *Prenat Diagn.* 34(12):1176-81, 2014
2. Rayssiguier R et al: Thrombosis of torcular herophili: diagnosis, prenatal management, and outcome. *Prenat Diagn.* 34(12):1168-75, 2014
3. Byrd SE et al: Fetal MR imaging of posterior intracranial dural sinus thrombosis: a report of three cases with variable outcomes. *Pediatr Radiol.* 42(5):536-43, 2012

KEY FACTS

IMAGING

- Most are supratentorial
 - Point of origin can often not be determined
- Often massive, filling entire cranial vault
 - Gross distortion of cerebral architecture
 - May extend through skull base into oral cavity
- Macrocephaly and hydrocephalus common presenting signs
- Often exhibit rapid growth over short period of time
- Intratumoral hemorrhage not uncommon
- Considerable overlap in appearance of tumor types
 - Differentiation between histologic types often not possible or even necessary
- Color Doppler essential to look for flow

TOP DIFFERENTIAL DIAGNOSES

- Intracranial hemorrhage
 - Typically hyperechoic but echogenicity varies according to age of hemorrhage

- No flow with Doppler

PATHOLOGY




- Histologic types in order of frequency
 - Teratoma ~ 50% of fetal brain tumors
 - Astrocytoma
 - Craniopharyngioma
 - Primitive neuroectodermal tumor
 - Meningioma
 - Ependymoma

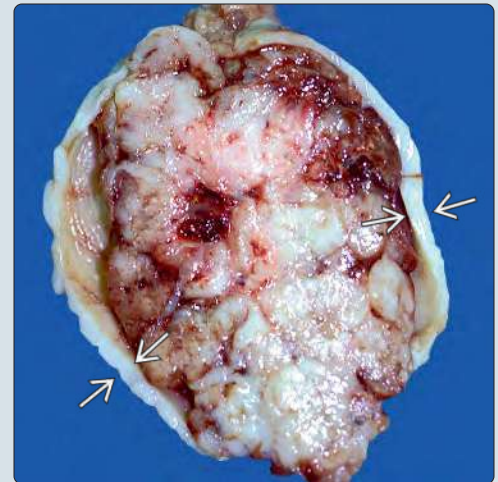
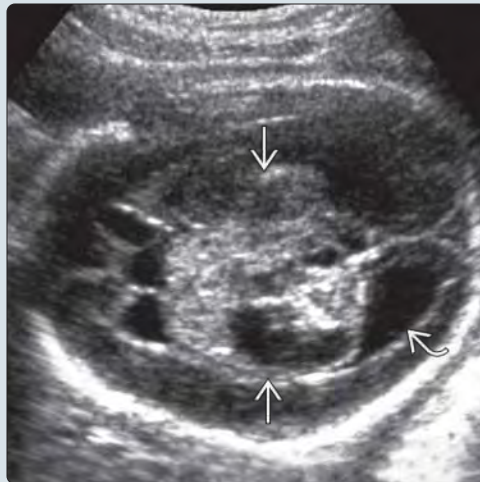
CLINICAL ISSUES



- 97% mortality if diagnosed before 30 weeks
- Large size portends grave prognosis regardless of histology
 - Benign tumors equally as lethal as malignant ones

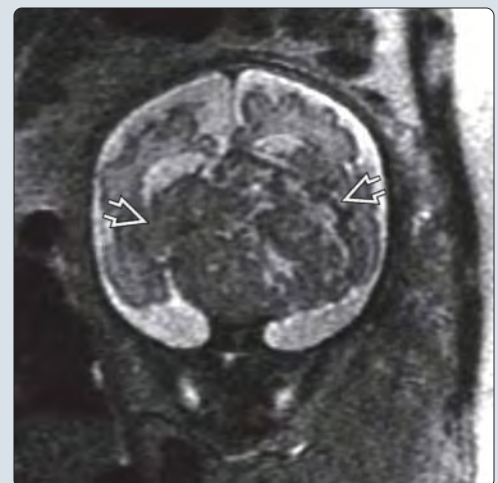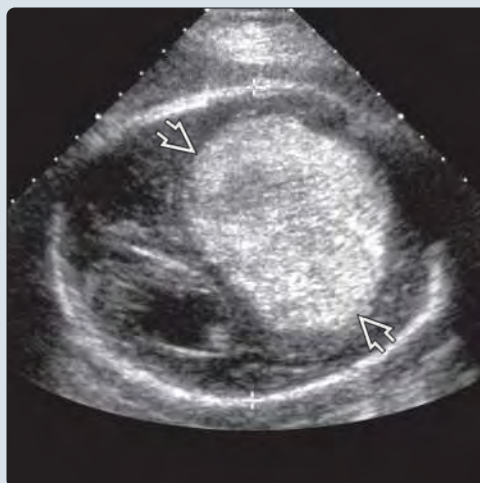
DIAGNOSTIC CHECKLIST

- Underlying neoplasm should always be considered in setting of spontaneous intracranial hemorrhage

(Left) Transverse ultrasound of a fetal brain shows a mixed cystic and solid echogenic midline mass , which is causing obstructive hydrocephalus . The fetus was delivered at 32 weeks and died at 6 days of life. Histology showed a teratoma. Because of compression of normal structures, benign intracranial tumors are equally as lethal as malignant ones. **(Right)** Gross specimen from a different case of a teratoma shows how massive they can get with the normal cortical mantle  being severely compressed. (From DP: Neuro.)



(Left) Transverse ultrasound of the fetal brain shows a homogeneously echogenic mass . The grayscale appearance overlaps with that seen with intracranial hemorrhage, so careful evaluation with Doppler is needed. **(Right)** Sagittal T2WI MR in the same case shows a predominately solid, low signal suprasellar mass . This was a craniopharyngioma, but the imaging characteristics are indistinguishable from a teratoma.



IMAGING**General Features**

- Best diagnostic clue
 - Solid intracranial mass with Doppler flow
- Location
 - 70% are supratentorial
 - May extend through skull base into oral cavity
- Often massive and exhibit rapid growth
- Macrocephaly common
- Gross distortion of cerebral architecture
- Intratumoral hemorrhage not uncommon, causing further distortion
- Hydrocephalus from obstruction by mass
- Polyhydramnios from decreased swallowing secondary to hypothalamic dysfunction

Ultrasonographic Findings

- Considerable overlap in appearance of tumor types
 - Differentiation often not possible or even necessary
- **Teratoma**
 - Most common tumor (~ 50%)
 - Complex masses with cystic and solid components
 - Calcifications are helpful to make diagnosis if seen but often not present
 - Typically midline
 - May fill entire cranial vault and erode skull
- **Astrocytoma**
 - Solid tumors
 - Arise in cerebral hemispheres
 - Unilateral echogenic mass with shift of midline structures
 - Low-grade astrocytomas may show slow growth
- **Craniopharyngioma**
 - Suprasellar mass
 - Arise from Rathke pouch, ectodermal diverticulum from roof of mouth
 - Heterogeneous complex mass
 - Frequently calcify
 - Indistinguishable from teratoma
- **Primitive neuroectodermal tumor**
 - Highly aggressive malignant tumor, which may occur anywhere in central nervous system
- **Meningioma**
 - Unilateral mass that often deforms fetal skull
- **Ependymoma/ependymoblastoma**
 - Ependymomas reported to originate from lateral and 4th ventricles
 - Ependymoblastomas too large to determine point of origin

Imaging Recommendations

- Protocol advice
 - Color Doppler essential to look for flow
 - Tumors have variable degrees of vascularity
 - Important to distinguish from intracranial hemorrhage
 - Intracranial tumors have propensity to bleed
 - Carefully evaluate periphery of mass
 - Close surveillance if pregnancy continued

DIFFERENTIAL DIAGNOSIS**Intracranial Hemorrhage**

- Typically hyperechoic but echogenicity varies according to age of hemorrhage
- Develops areas of encephalomalacia/porencephaly
- No flow with Doppler

Interhemispheric Cyst

- Complicated midline cyst is part of AVID complex (asymmetric ventriculomegaly with interhemispheric cyst and dysgenesis of corpus callosum)
- No solid component

PATHOLOGY**General Features**

- Genetics
 - Sporadic, no recurrence risk
- Associated abnormalities
 - Usually isolated finding, not associated with syndromes

CLINICAL ISSUES**Presentation**

- Most commonly presents in 3rd trimester with macrocephaly, hydrocephalus, or obvious mass
 - Very rapid growth potential
 - May have had normal scan as recently as 2 weeks prior

Demographics

- Epidemiology
 - Rare, 0.31 per million live births
 - 0.5-1.5% of pediatric central nervous system tumors
 - 10% of antenatal neoplasms

Natural History & Prognosis

- Dismal prognosis
 - In utero demise common, 1/3 stillborn
 - 97% mortality if diagnosed before 30 weeks
 - Most die within hours to few days after delivery
 - Some survivors reported with low-grade astrocytoma
- Large size portends grave prognosis regardless of histology
 - Benign tumors equally as lethal as malignant ones

Treatment

- Termination offered
- Cephalocentesis may be considered for delivery
 - Cesarean section may be required to prevent dystocia but should be avoided if possible
- Postnatal
 - Surgical resection often not possible
 - Radiation contraindicated
 - Severe adverse effect on normal brain growth and development
 - Chemotherapy has been used
 - Survivors left with significant psychomotor deficits

SELECTED REFERENCES

1. Milani HJ et al: Fetal brain tumors: Prenatal diagnosis by ultrasound and magnetic resonance imaging. *World J Radiol.* 7(1):17-21, 2015
2. Isaacs H: Fetal brain tumors: a review of 154 cases. *Am J Perinatol.* 26(6):453-66, 2009

KEY FACTS

TERMINOLOGY

- Benign, intraventricular, papillary neoplasm derived from choroid plexus epithelium

IMAGING

- Well-defined, lobular, hyperechoic mass
- Lateral ventricle most common site
 - Most arise in atrium
- Hydrocephalus may be from both overproduction of CSF and obstruction by tumor
 - Often severe, causing marked macrocephaly
 - May be rapid onset
- Intraparenchymal extension suggests choroid plexus carcinoma

TOP DIFFERENTIAL DIAGNOSES

- Choroid plexus cyst
 - Clustered small cysts may mimic complex mass
 - Does not cause hydrocephalus

- Intraventricular hemorrhage
 - Will usually have intraparenchymal component
 - Unusual to have isolated intraventricular hemorrhage
- Intraventricular lipoma
 - Usually in midline but may extend into ventricle

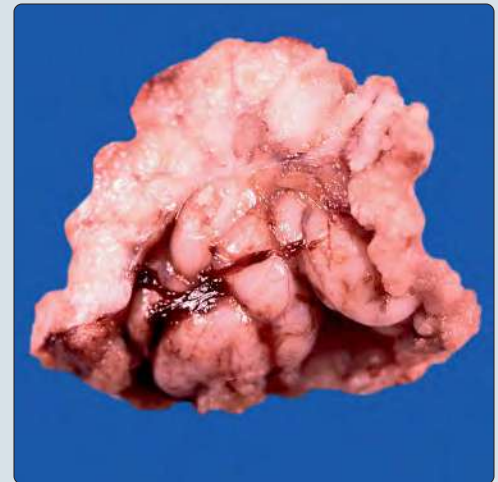
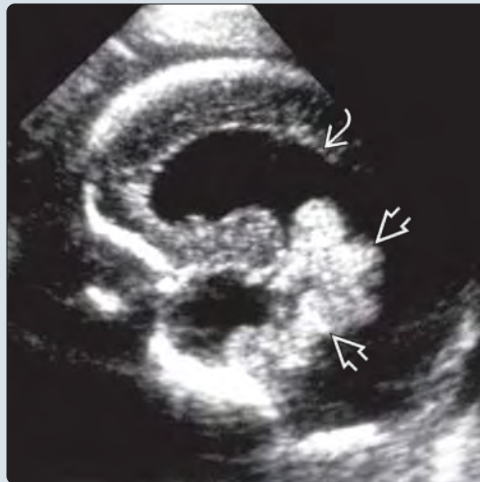
CLINICAL ISSUES

- 5-10% of congenital brain tumors
- Complete surgical resection is often possible
 - If completely resected, 5-year survival approached 100%
 - Significant neurologic sequelae, including psychomotor retardation, seizures, and quadriplegia, have been reported
- Consider early delivery for rapidly progressing hydrocephalus

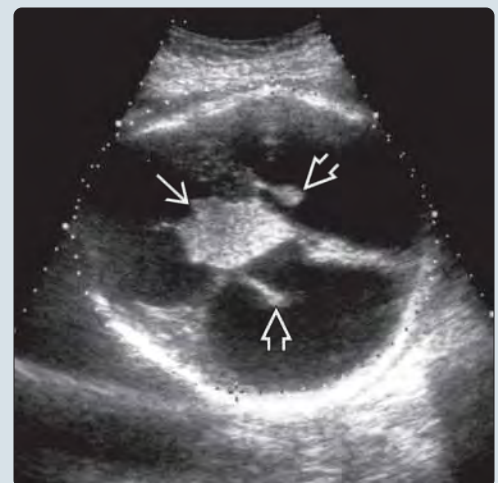
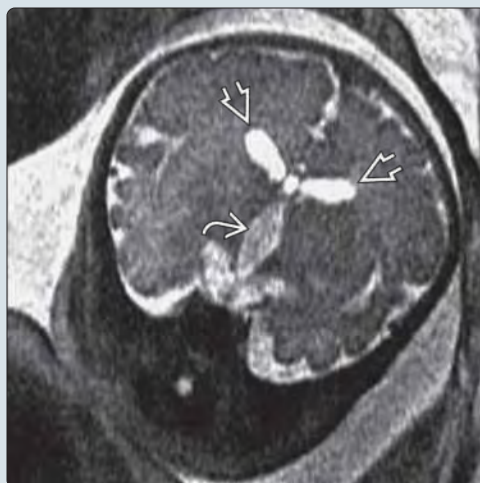
DIAGNOSTIC CHECKLIST

- While still guarded prognosis, outcome is better than for other fetal brain tumors

(Left) Parasagittal US of a fetal head shows a well-defined, lobular, hyperechoic mass within the atrium of the right lateral ventricle. Hydrocephalus is also present. The most common site of choroid plexus papilloma (CPP) occurrence is the lateral ventricle, but they can form anywhere there is choroid in the ventricular system. Rapid onset of hydrocephalus may occur from increased production of CSF. **(Right)** Photograph of the resected tumor shows the characteristic lobular, cauliflower-like contour.



(Left) Coronal T2 MR of the fetal brain shows a soft tissue mass within the 3rd ventricle. It is causing mild dilatation of the lateral ventricles. Postnatal imaging showed avid enhancement, typical of a CPP. **(Right)** Transverse US of a fetal brain in a different patient shows an echogenic mass filling and expanding the 3rd ventricle. There is severe hydrocephalus with dangling choroid plexuses. Hydrocephalus in this case may be from a combination of obstruction and overproduction.



TERMINOLOGY

Abbreviations

- Choroid plexus papilloma (CPP)

Definitions

- Benign, intraventricular, papillary neoplasm derived from choroid plexus epithelium

IMAGING

General Features

- Best diagnostic clue
 - Echogenic intraventricular mass associated with hydrocephalus
- Location
 - Occur in proportion to amount of normally occurring choroid plexus
 - Lateral ventricle most common site
 - Most arise in atrium
 - May be bilateral
 - 3rd ventricle next most common site in fetus
- Size
 - May be large and fill entire ventricle

Ultrasonographic Findings

- Well-defined, lobular, hyperechoic mass
- Hydrocephalus common associated feature
 - CPPs produce large quantities of cerebrospinal fluid (CSF) so hydrocephalus often severe
 - May be rapid onset
 - May cause marked macrocephaly
- Hypervascular on color Doppler
- Intraparenchymal extension suggests choroid plexus carcinoma

MR Findings

- T2WI: Iso- to hyperintense frond-like mass
- Postnatal MR with gadolinium will show dramatic enhancement of tumor

DIFFERENTIAL DIAGNOSIS

Choroid Plexus Cyst

- Thin-walled, anechoic cyst in choroid plexus
 - Single or multiple
 - Clustered small cysts may mimic complex mass
- Does not cause hydrocephalus
- Most are transient and of no consequence
- Can be seen in trisomy 18

Intraventricular Hemorrhage

- Will usually have intraparenchymal component
 - Isolated intraventricular hemorrhage would be very unusual
- Encephalomalacia/porencephaly develop over time

Intraventricular Lipoma

- Usually midline lipoma is present with secondary extension into ventricle
- Associated with agenesis of corpus callosum
 - Will see colpocephaly but not usually hydrocephalus

PATHOLOGY

General Features

- Associated abnormalities
 - Association with Aicardi and Li-Fraumeni syndromes

Microscopic Features

- Fibrovascular connective tissue fronds, covered by cuboidal or columnar epithelium
- Histologically benign resembling nonneoplastic choroid plexus

CLINICAL ISSUES

Presentation

- Most common signs/symptoms
 - Hydrocephalus
 - May be from both overproduction of CSF and obstruction by tumor

Demographics

- Epidemiology
 - 5-10% of congenital brain tumors
 - Only rare case reports of choroid plexus carcinoma

Natural History & Prognosis

- Although series are small, 75-96% successful resection reported
 - If completely resected, 5-year survival approached 100%
 - Significant neurologic sequelae, including psychomotor retardation, seizures, and quadriplegia, have been reported
- Histologically malignant choroid plexus carcinoma has much poorer prognosis
 - Complete resection in 61% with 40% 5-year survival

Treatment

- Consider early delivery for rapidly progressing hydrocephalus
- In utero cephalocentesis to decompress hydrocephalus
 - Case reports of improved survival
- C-section may be required to prevent dystocia
- Delivery at tertiary center with planned early resection
- Embolization prior to resection has been reported
 - Decreases tumor vascularity

DIAGNOSTIC CHECKLIST

Consider

- While still guarded prognosis, outcome is better than for other fetal brain tumors

SELECTED REFERENCES

1. Verma SK et al: Giant choroid plexus papilloma of the lateral ventricle in fetus. *J Pediatr Neurosci.* 9(2):185-7, 2014
2. Anselm O et al: Fetal tumors of the choroid plexus: is differential diagnosis between papilloma and carcinoma possible? *Ultrasound Obstet Gynecol.* 38(2):229-32, 2011
3. Hartge DR et al: Prenatal diagnosis and successful postnatal therapy of an atypical choroid plexus papilloma-Case report and review of literature. *J Clin Ultrasound.* 38(7):377-83, 2010
4. Isaacs H: Fetal brain tumors: a review of 154 cases. *Am J Perinatol.* 26(6):453-66, 2009

KEY FACTS

TERMINOLOGY

- CNS lipomas are actually congenital malformations, not true neoplasms

IMAGING

- 80% supratentorial
- 2 kinds of interhemispheric lipoma
 - Tubulonodular type forms bulky mass and is most common type in fetus
 - Curvilinear type curves around corpus callosum (CC)
- Echogenicity usually \geq parietal bone
- Borders may be irregular with local extension
 - Most commonly through choroidal fissure into ventricles
- Look for signs of agenesis of corpus callosum (ACC)
 - Absent cavum septi pellucidi
 - Colpocephaly
- Associated agenesis of CC reported in 50-90% of fetuses with lipomas
- Fetal MR recommended

- Very specific for fat so definitive diagnosis can be made and associated abnormalities better evaluated

TOP DIFFERENTIAL DIAGNOSES

- Intracranial hemorrhage
 - Appearance evolves over time with developing porencephaly
- CNS tumors
 - Large aggressive masses

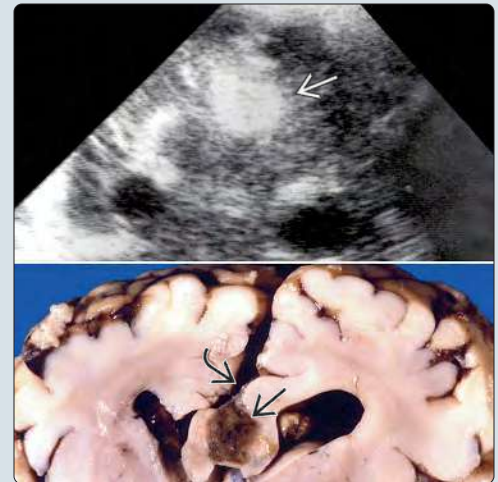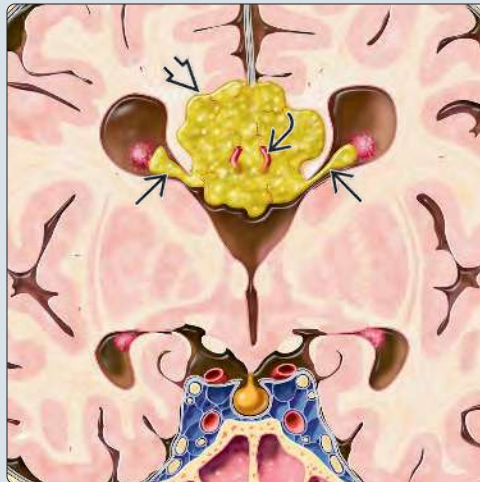
CLINICAL ISSUES

- Prognosis dependent on presence of other anomalies
 - Consider karyotype if present
- Generally excellent prognosis when isolated

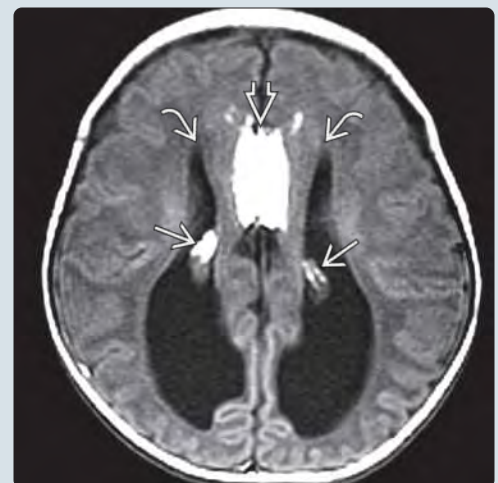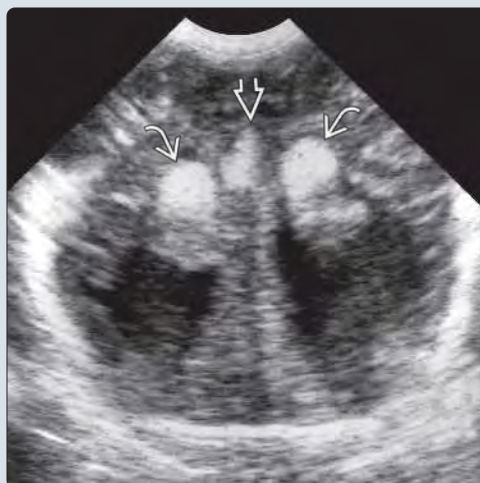
DIAGNOSTIC CHECKLIST

- Presence of lipoma is highly suspicious for ACC
- Conversely, in setting of ACC look for lipoma or cyst in midline

(Left) Coronal graphic shows callosal agenesis with a bulky interhemispheric lipoma that encases the anterior cerebral arteries and extends into the lateral ventricles. This is the most common site and appearance of fetal lipomas. **(Right)** Composite image shows a midline echogenic mass in a fetus with agenesis of the corpus callosum. Autopsy shows the corresponding lipoma. Note absence of the corpus callosum, which would normally be seen as a band of tissue connecting the 2 cerebral hemispheres.



(Left) Axial oblique ultrasound shows a midline lipoma, which has extended into both lateral ventricles. Also note the teardrop-shaped ventricles (colpocephaly) typical of agenesis of the corpus callosum. **(Right)** Axial postnatal T1-weighted MR in a different but similar case shows the high signal midline lipoma, which has extended through the choroidal fissures into the ventricles. Colpocephaly, with the pointed anterior frontal horns, is well demonstrated in this case.



TERMINOLOGY

Definitions

- Mass of mature nonneoplastic adipose tissue
 - CNS lipomas are actually congenital malformations, not true neoplasms

IMAGING

General Features

- Best diagnostic clue
 - Well-defined, echogenic, midline mass
- Location
 - 80% supratentorial
 - Most common lipomas to be diagnosed in utero
 - Those in other locations often too small to be seen in utero
- Morphology
 - Lobulated fatty mass that may encase vessels and cranial nerves
 - 2 kinds of interhemispheric lipoma
 - Tubulonodular type most common in fetus
 - Bulky mass
 - Usually associated with callosal agenesis/dysgenesis
 - Curvilinear type
 - Thin lipoma, which curves around corpus callosum
 - Harder to visualize in utero

Ultrasonographic Findings

- Echogenicity usually \geq parietal bone
 - Borders may be irregular with extension into parenchyma or ventricles
- Look for signs of agenesis of corpus callosum (CC)
 - Absent cavum septi pellucidi
 - Colpocephaly
 - Teardrop-shaped ventricles
 - Lateral ventricles widely spaced anteriorly
 - Elevation of 3rd ventricle creating trident shape in coronal plane
 - Associated agenesis of CC reported in 50-90% of fetuses with lipomas

MR Findings

- Signal follows subcutaneous fat with loss of signal on fat-suppression sequences
- T1 \pm fat suppression is best sequence for diagnosis

Imaging Recommendations

- Protocol advice
 - Fetal MR recommended
 - Very specific for fat, can make definitive diagnosis
 - Evaluate for other anomalies (agenesis CC, etc.)

DIFFERENTIAL DIAGNOSIS

Intracranial Hemorrhage

- Variable echogenicity, usually not as echogenic as lipoma
- Appearance evolves over time

CNS Tumors

- Usually large and aggressive
- Normal brain anatomy disrupted

PATHOLOGY

General Features

- Etiology
 - Persistent maldevelopment of embryonic meninx primitiva
 - Normally differentiates into leptomeninges, cisterns
 - Maldifferentiates into fat instead
 - Developing pia-arachnoid invaginates through embryonic choroid fissure
 - Explains frequent intraventricular extension of interhemispheric lipomas
- Associated abnormalities
 - Agenesis/dysgenesis of CC
 - Migrational abnormalities, gray matter heterotopia
 - Goldenhar syndrome (oculo-auriculo-vertebral syndrome)
 - Incomplete development of ear, nose, soft palate, lip, and mandible
 - Anomalous development of 1st and 2nd branchial arches

CLINICAL ISSUES

Presentation

- Most common signs/symptoms
 - Generally incidental finding or seen in conjunction with agenesis CC
 - Usually not seen until late 2nd or 3rd trimester

Demographics

- Rare, but in utero incidence likely underestimated given small size and slow growth
- 1:2,500-25,000 in autopsy series

Natural History & Prognosis

- Prognosis dependent on presence of other anomalies
- Generally excellent prognosis when isolated
- Growth of lipoma has been reported in infancy so should be followed
- Increased incidence of seizures has been reported

Treatment

- Consider karyotype if other abnormalities present
- MR recommended in all suspected cases

DIAGNOSTIC CHECKLIST

Consider

- Presence of lipoma is highly suspicious for agenesis of CC

SELECTED REFERENCES

1. Cowda VK et al: Ohtahara syndrome associated with hemimegalencephaly and intracranial lipoma. *J Pediatr Neurosci.* 10(2):185-7, 2015
2. Nanni M et al: Prenatal and postnatal imaging of multiple intracranial lipomas: report of a case. *Fetal Diagn Ther.* 30(2):160-2, 2011
3. Puvabanditsin S et al: Intracranial lipomas in neonate. *J Perinatol.* 22(5):414-5, 2002
4. Ickowitz V et al: Prenatal diagnosis and postnatal follow-up of pericallosal lipoma: report of seven new cases. *AJNR Am J Neuroradiol.* 22(4):767-72, 2001
5. Kieslich M et al: Midline developmental anomalies with lipomas in the corpus callosum region. *J Child Neurol.* 15(2):85-9, 2000

DIFFERENTIAL DIAGNOSIS**Common**

- Incorrect Scan Plane
- Agenesis of Corpus Callosum
- Chiari 2 Malformation
- Severe Hydrocephalus

Less Common

- Holoprosencephaly Spectrum
 - Alobar Holoprosencephaly
 - Semilobar Holoprosencephaly
 - Lobar Holoprosencephaly

Rare but Important

- Septo-Optic Dysplasia
- Schizencephaly
- Syntelencephaly

ESSENTIAL INFORMATION**Key Differential Diagnosis Issues**

- Cavum septi pellucidi (CSP) is critical anatomic landmark of normal midline development
- Must differentiate technical failure to demonstrate from true absence of CSP
- Scan technique is very important
 - CSP should be landmark for measurement of biparietal diameter and head circumference
 - Images obtained too high, too low, or at incorrect angle fail to demonstrate CSP
 - Coronal images also helpful if fetal head position makes correct axial plane difficult
 - CSP seen between frontal horns inferior to corpus callosum
- **Cavum septi pellucidi et vergae** is anatomic variant that may cause confusion
 - Cavum vergae is posterior continuation of CSP, obliterates posterior to anterior so usually not seen in standard 18- to 20-week scan
 - If present, → elongated, larger, fluid-filled space that may be confused with interhemispheric cyst
 - No other abnormalities present
- Normal CSP signifies normal midline brain development
 - If absent, significant malformation may be present, though not immediately apparent

Helpful Clues for Common Diagnoses

- **Incorrect Scan Plane**
 - If scan plane too high or too low, CSP not seen
 - Fornices are normal structures, which create parallel echoes inferior to normal location of CSP
 - CSP appears as fluid-filled box: White line/black space/white line appearance
 - Fornices: Series of parallel black and white lines without intervening fluid-filled space
- **Agenesis of Corpus Callosum**
 - Mild ventriculomegaly or colpocephaly
 - Lateral ventricles are parallel instead of divergent
 - Coronal images show steer horn appearance of frontal horns

- Lack of normal anterior cerebral artery branch pattern into callosomarginal and pericallosal arteries on midline sagittal view
- Stenogyria: Radiating sunburst pattern of medial cerebral gyri
- MR very helpful to look for additional brain malformations
 - Heterotopia, lissencephaly, gyral abnormalities

- **Chiari 2 Malformation**

- Ventriculomegaly with boxy or angular appearance of ventricles
- Banana sign: Cerebellar prolapse into foramen magnum causes cerebellum to curve around brainstem
- Obliteration of cisterna magna
- Lemon sign: Bifrontal concavity
- May see absence of intracranial translucency at time of nuchal translucency screening

- **Severe Hydrocephalus**

- Severe hydrocephalus leads to "blown-out cavum"
 - Fenestrations appear in leaves of septum secondary to elevated cerebrospinal fluid pressure
 - Eventually leaves of cavum may be so thinned as to be invisible or torn
- Most likely to occur with aqueductal stenosis

Helpful Clues for Less Common Diagnoses

- **Alobar Holoprosencephaly**

- Supratentorial brain without division into cerebral hemispheres
- Residual cerebral tissue forms ball, cup, or pancake of brain associated with monoventricle ± dorsal cyst
- Head may be large if large dorsal cyst or small and round in shape
- Associated with severe facial malformation
- Look for stigmata of trisomy 13

- **Semilobar Holoprosencephaly**

- Some division into cerebral hemispheres posteriorly but fusion anteriorly
- Head shape often round
- Look for stigmata of trisomy 13 or 18

- **Lobar Holoprosencephaly**

- 2 cerebral hemispheres are formed
- May be single gyrus in continuity across midline
- Midline fusion anomalies seen
 - Fused fornices create round mass in 3rd ventricle
 - Not pathognomonic for lobar holoprosencephaly; also seen with rhombencephalosynapsis, septo-optic dysplasia

Helpful Clues for Rare Diagnoses

- **Septo-Optic Dysplasia**

- Absent CSP associated with variable hypothalamic pituitary dysfunction and visual impairment
- Mild dilatation of frontal horns
- Flat top appearance to frontal horns
- MR used to exclude additional malformations
 - Optic nerves and chiasm beyond resolution of fetal MR at present
- Diagnosis is confirmed by clinical and ophthalmological evaluation of infant

- **Schizencephaly**

- Cortical defect extending from ventricular surface to pia
- May be "closed" or "open," unilateral or bilateral
- Size of defect varies from very small to giant, involving most of frontoparietal cortex
- Lateral ventricle on side of defect is distorted → tenting toward area of parenchymal loss
- Bilateral giant open lip schizencephaly looks very similar to hydranencephaly
 - Key observation is that walls of schizencephalic cleft are lined by grey matter
 - Important distinction as hydranencephaly is lethal
 - Giant open lip schizencephaly is associated with neurological impairment but is not necessarily lethal
- **Syntelencephaly**
 - Considered variant of holoprosencephaly spectrum
 - 2 hemispheres are present, but with some fusion of dorsal aspect of cerebral hemispheres
 - Most common site of fusion is posterior frontal lobe

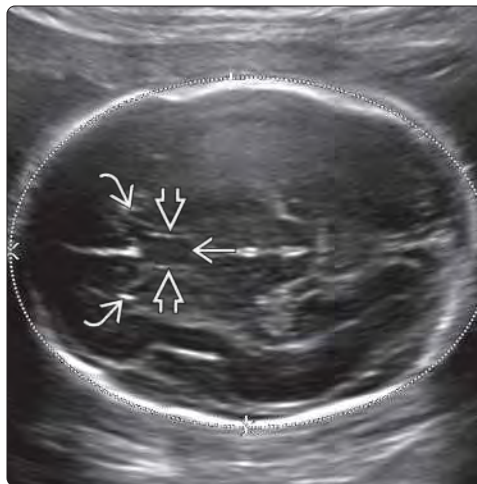
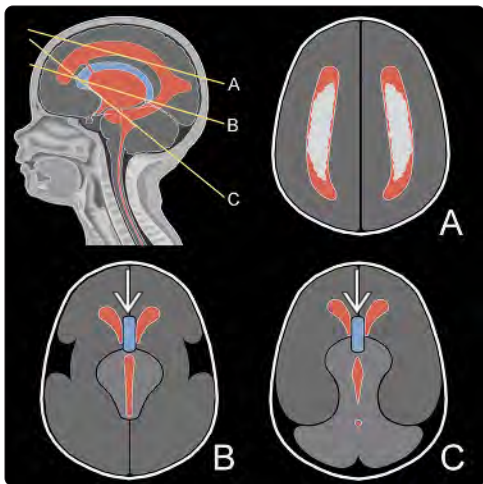
- Agenesis of corpus callosum is associated with many other brain malformations, as well as innumerable syndromes
 - Counsel parents whose outcome is highly variable
- Septo-optic dysplasia associated with visual impairment/blindness, as well as potential hypothalamic pituitary dysfunction

SELECTED REFERENCES

1. Hosseinzadeh K et al: Non-visualisation of cavum septi pellucidi: implication in prenatal diagnosis? Insights Imaging. 4(3):357-67, 2013
2. Malingier G et al: Non-visualization of the cavum septi pellucidi is not synonymous with agenesis of the corpus callosum. Ultrasound Obstet Gynecol. 40(2):165-70, 2012
3. Winter TC et al: The cavum septi pellucidi: why is it important? J Ultrasound Med. 29(3):427-44, 2010

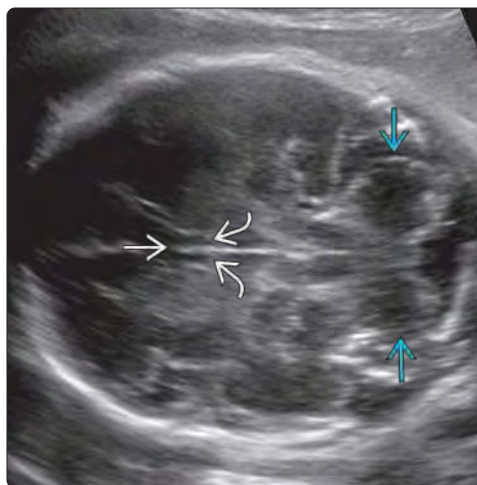
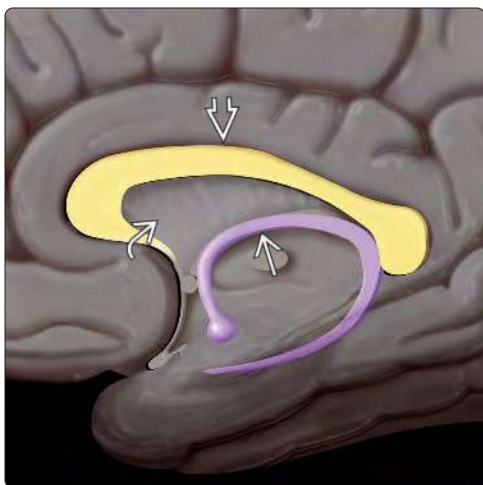
Other Essential Information

- Absent CSP is often tip-off for underlying brain abnormality






(Left) Graphic shows the standard scan planes for fetal brain evaluation. Plane A is through the lateral ventricles, plane B is through the cavum septi pellucidi (CSP) and thalami, and plane C is through the cerebellum using the CSP as a landmark to prevent too steep an angle. (Right) Axial oblique US in scan plane B demonstrates the box-like structure of the normal CSP, which is described as a "space between 2 lines" between the frontal horns of the lateral ventricles.

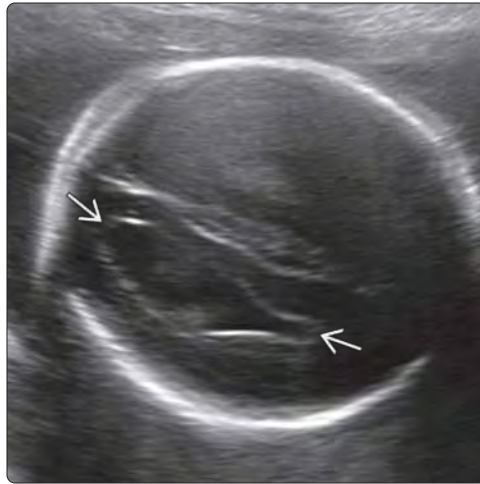
Incorrect Scan Plane



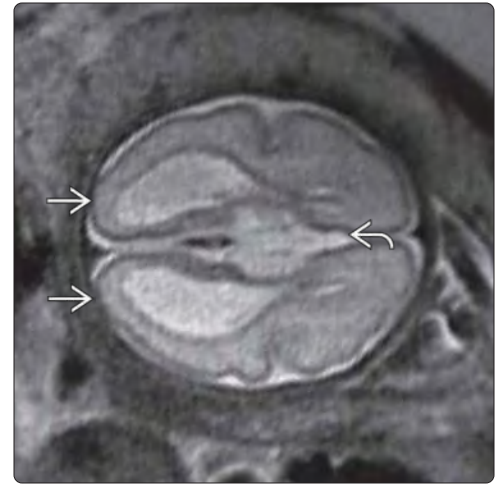
(Left) Graphic illustrates a fornix (violet) in relation to the CSP (yellow) under the corpus callosum (yellow). A scan plane just inferior to the CSP cuts across the body of the fornices; these paired, tubular structures do not create a box-like space. (Right) US shows the paired forniceal bodies with an intact midline echo between them. This is similar to scan plane C (for the cerebellum) but inferior to the CSP. Do not mistake the fornices for the cavum; though close in proximity, they are quite different structures.

Agenesis of Corpus Callosum





(Left) High axial US through the brain of a fetus with absent cavum shows the classical teardrop shape of the ventricle  in agenesis of the corpus callosum. This is described as colpocephaly. (Right) T2WI in a similar case again shows colpocephaly  and confirms absent corpus callosum as the cause. Note the gap  between the cerebral hemispheres where the normal corpus callosum should be visible. In this case, agenesis of the corpus callosum was isolated and the infant did well.

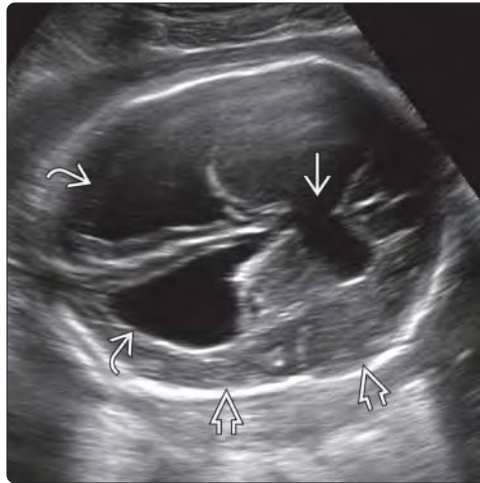


Agenesis of Corpus Callosum

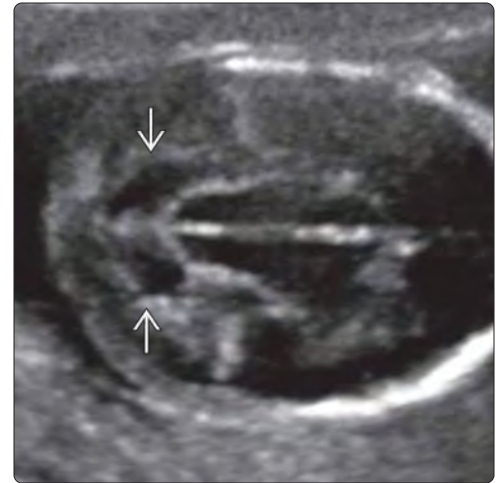


Chiari 2 Malformation





(Left) Axial oblique US shows an absent cavum  and ventriculomegaly with a boxy, angular configuration , as seen in Chiari 2 malformation. Note also how the extraaxial cerebrospinal fluid spaces  are obliterated so that the brain surface is not seen as an echo separate from the cranium; this is another common observation in Chiari 2. (Right) Posterior fossa view shows the typical "banana" cerebellum  seen with open neural tube defects.

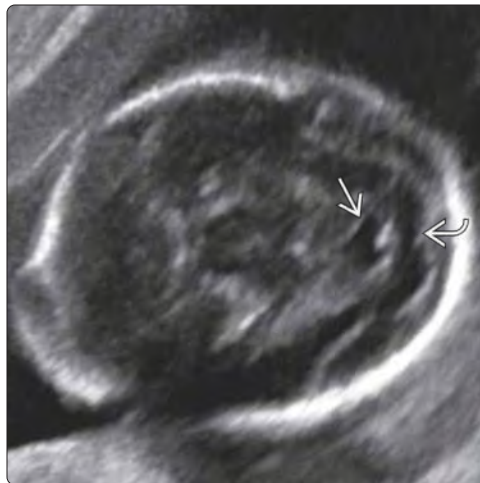


Chiari 2 Malformation

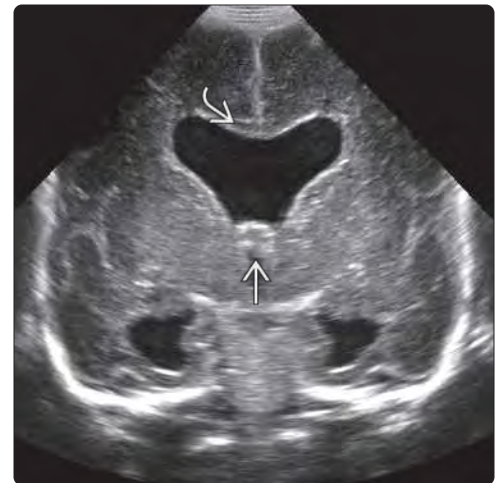

Semilobar Holoprosencephaly

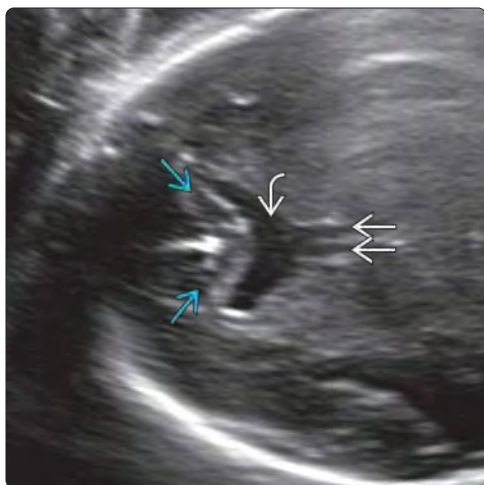
(Left) Axial oblique US in an early 2nd-trimester fetus shows continuity of the cerebral cortex across the midline . The anterior "space"  is not the cavum; it is fused, abnormal frontal horns in semilobar holoprosencephaly. (Right) Head US displays a neonate with an absent CSP and communication of the ventricles across the midline, thin corpus callosum , and fused fornices . MR confirmed the diagnosis of lobar holoprosencephaly by demonstrating a gyrus in continuity across the midline.



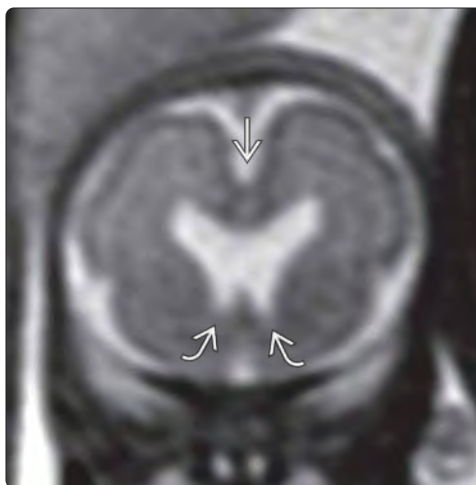
Lobar Holoprosencephaly








Septo-Optic Dysplasia

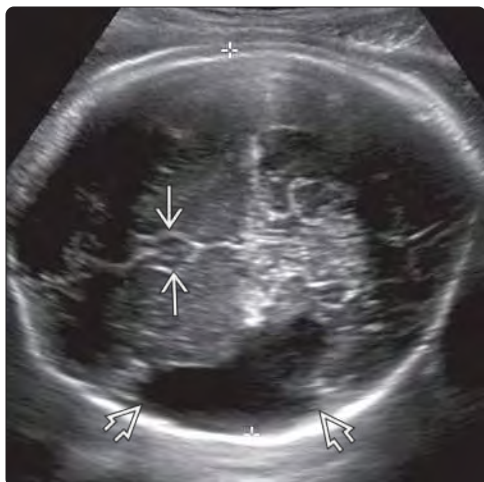


Septo-Optic Dysplasia

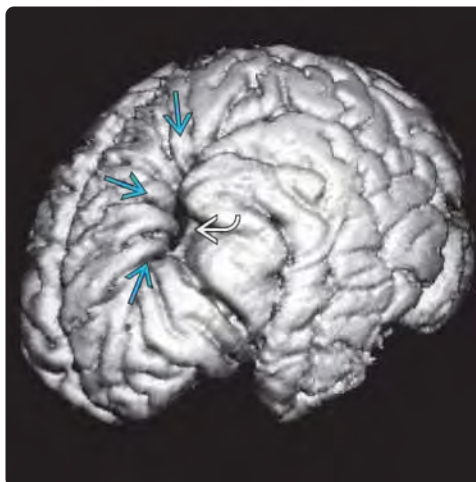






(Left) Zoomed anterior view shows absent cavum , normal fornices , and normal genu of the corpus callosum . Septo-optic dysplasia was confirmed by ophthalmologic examination of the infant. Isolated septal dysgenesis would look the same, but it is a diagnosis of exclusion. (Right) Coronal T2WI confirms absent cavum with intact corpus callosum . Note the downward point to the frontal horns . This is described in septo-optic dysplasia. The diagnosis must be confirmed by ophthalmologic exam.

Schizencephaly

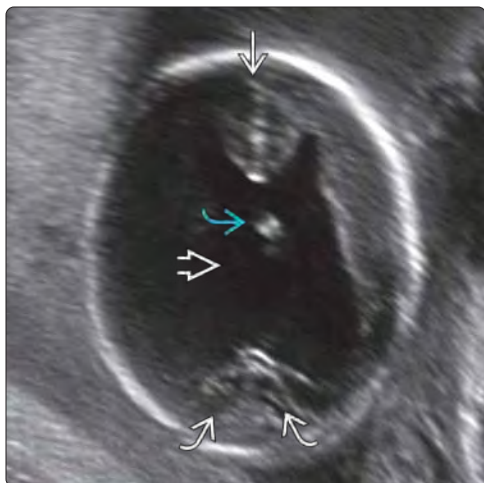


Schizencephaly

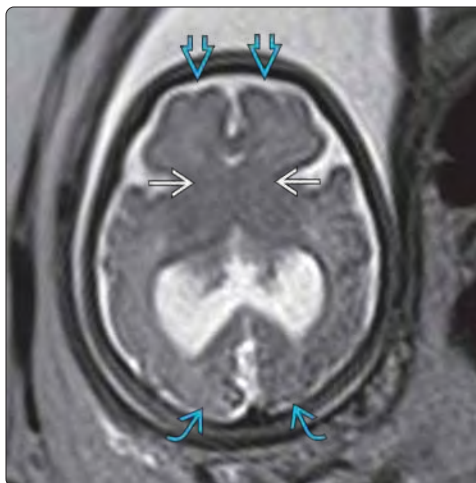









(Left) Axial oblique US shows the fornices , the CSP was absent. There is a wedge-shaped parenchymal defect  extending to the skull vault. This is typical of open-lip schizencephaly. Beware of reverberation in the near field obscuring bilateral defects. Always look at the brain in multiple planes and from different access points. (Right) MR surface reconstruction in a child with open-lip schizencephaly shows that the gyri  "dive" into the cleft . Extensive cortical dysplasia is common in the region of the clefts.

Syntelencephaly



Syntelencephaly



(Left) Axial oblique US shows the intact anterior midline , and separate occipital lobes , but a large monoventricle  and midline fused choroids . A 12-week scan had shown lack of the normal butterfly sign and choroid fusion. MR confirmed syntelencephaly. The infant expired within days of birth. (Right) Axial T2WI MR shows formation of 2 cerebral hemispheres with frontal  and occipital  lobes, but there is interhemispheric fusion , which is the hallmark finding in syntelencephaly.

DIFFERENTIAL DIAGNOSIS**Common**

- Idiopathic/Isolated
- Aneuploidy
 - Trisomy 21
 - Trisomy 18
 - Trisomy 13
- Abnormal Corpus Callosum
- Aqueductal Stenosis, Early
- Chiari 2 Malformation, Early
- Septo-Optic Dysplasia

Less Common

- Congenital Infection
- Intracranial Hemorrhage
- Encephalomalacia

ESSENTIAL INFORMATION**Key Differential Diagnosis Issues**

- Definition of mild ventriculomegaly (VM)
 - Lateral ventricle measures ≥ 10 mm but ≤ 12 mm
 - Mild VM: 10-12 mm
 - Older literature uses 10-15 mm
 - 12-15 mm now considered moderate VM by most
- Bilateral more common than unilateral
- Prevalence is 0.15-0.70%
- Measure lateral ventricles as part of anatomic survey
 - Measure at atria
 - Level of dorsal choroid plexus glomus
 - Normal measurements
 - < 10 mm from 14-40 weeks
 - Mean diameter of 7.6 mm (± 0.6 mm)
 - Normal ventricular width is 70% of hemicalvarium at 18 weeks and 30% of hemicalvarium at 28 weeks
- Fetal MR additive in 6-10% of cases
 - Show more subtle anomalies; best if > 28 weeks, but even early MR can be additive

Helpful Clues for Common Diagnoses

- **Idiopathic/Isolated**
 - More common in male fetuses
 - Larger calvarial volume, especially when > 20 weeks
 - 88-92% with normal outcome
 - 34% resolve in utero
 - Progressive VM with worse outcome
 - 71% with additional anomalies on follow-up
- **Aneuploidy**
 - Likelihood ratio is 9 for isolated VM
 - Majority of low-risk patients become high-risk patients
 - Genetic testing almost always offered
 - **Trisomy 21**
 - Most common; look for other markers and associated anomalies
 - Nuchal thickening (≥ 6 mm)
 - Absent/small nasal bone
 - Short femur/humerus
 - Cardiac anomalies and intracardiac echogenic focus
 - Bowel atresia; duodenal, esophageal
 - Echogenic bowel

- **Trisomy 18**
 - Hallmark is multiple major anomalies and fetal growth restriction (FGR)
 - Brain anomalies in 30%
 - VM
 - Chiari 2 malformation
 - Dandy-Walker continuum, cerebellar hypoplasia
 - 2nd-trimester markers
 - Choroid plexus cyst
 - Strawberry-shaped skull (brachycephaly)
 - Single umbilical artery, umbilical cord cyst
- **Trisomy 13**
 - Multiple major anomalies in $> 90\%$ and FGR
 - Holoprosencephaly is hallmark anomaly
 - Variable severity
 - Monoventricle with fused thalamus
 - Associated facial anomalies
 - 2nd-trimester markers rarely isolated
- **Abnormal Corpus Callosum**
 - Complete or partial absence of corpus callosum (CC)
 - CC forms mostly from anterior to posterior
 - Posterior portions may be absent
 - Colpocephaly seen best on axial view
 - Teardrop-shaped lateral ventricle
 - Pointed frontal horns parallel to falx
 - Dilated atria of lateral ventricle
 - Trident-shaped frontal horns in coronal view
 - Elevated 3rd ventricle displaces frontal horns laterally
 - Absent cavum septi pellucidi (CSP) if complete absence of CC
 - 50% with other brain anomalies
 - 10-20% with aneuploidy
 - 3% of all mild VM cases have dysgenesis of CC
- **Aqueductal Stenosis, Early**
 - Narrowing or occlusion of aqueduct of Sylvius
 - Between 3rd and 4th ventricles
 - Progressive obstructive hydrocephalus
 - Lateral and 3rd ventricles dilate
 - VM often absent or mild in 2nd trimester
 - Progressive VM and head enlargement
 - X-linked form ($< 5\%$ of all cases)
 - 50% recurrence risk in male fetuses
 - Look for associated adducted thumbs
 - 90% with developmental delay
 - More severe if X-linked diagnosis
- **Chiari 2 Malformation, Early**
 - Hindbrain herniation + open spina bifida
 - Posterior fossa compression
 - Cisterna magna obliteration
 - Compressed cerebellum
 - Banana shape if cerebellum wraps around midbrain
 - Frontal calvarial findings are nonspecific and transient
 - Lemon-shaped skull from narrow anterior-pointing frontal bones and dolichocephaly
 - VM often mild in 2nd trimester, 1/3 progress
 - Majority with obstructive VM needing treatment
 - 40% with additional anomalies
 - 4% with aneuploidy
- **Septo-Optic Dysplasia**

- Abnormal anterior midline brain development
 - Hypoplasia of optic nerves and chiasm
 - Hypothalamus-pituitary axis hypoplasia/dysfunction
 - Absent CS
- Imaging findings (US and MR)
 - Absent CSP ± mild VM
 - Classic frontal horn morphology
 - Boxed upper portion and downward pointing inferior portion seen best on coronal views
 - Cerebral hemispheres otherwise completely separated
 - Differentiates from lobar holoprosencephaly

Helpful Clues for Less Common Diagnoses

- **Congenital Infection**
 - 1.5% of cases with VM
 - Maternal serum testing offered for all unexplained VM
 - CMV infection most common: 18% of fetuses with CMV have VM
 - Toxoplasmosis is 2nd most common (rare)
 - Imaging findings in brain
 - Periventricular calcifications (late sequelae)
 - Subependymal cysts
 - Cerebellar hypoplasia
 - Abnormal gyration and WM signal: MR findings
 - Imaging findings elsewhere in fetus
 - Fetal growth restriction, hydrops, oligohydramnios, placentomegaly
 - Liver calcifications, hepatosplenomegaly, ascites, echogenic bowel
- **Intracranial Hemorrhage**
 - Most often from fetoneonatal alloimmune thrombocytopenia
 - Search for antiplatelet antibodies
 - US findings in addition to VM
 - Hyperechoic ventricular walls
 - Intraventricular echogenic blood clots
 - Parenchymal hemorrhage
 - MR excellent for showing blood
 - ↑ signal on T1 and ↓ signal on T2 images

- **Encephalomalacia**
 - Brain parenchyma destruction
 - Early findings often subtle
 - Variable periventricular WM heterogeneity
 - Mild VM
 - Cystic degeneration is late finding
 - Vascular causes
 - Hypoperfusion from any cause
 - Intracranial hemorrhage
 - Infectious and teratogen causes
 - CMV
 - Toxoplasmosis
 - Varicella/zoster
 - Vitamin A

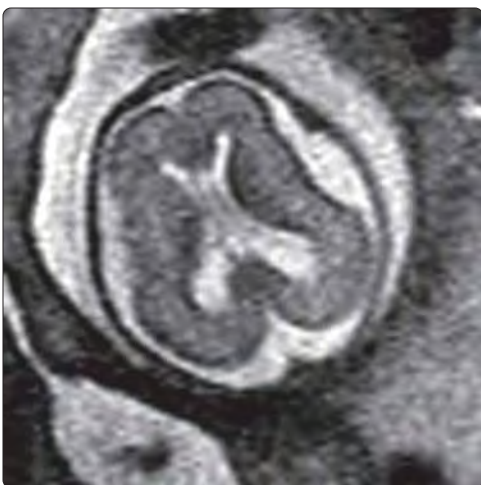Other Essential Information

- Should we offer amniocentesis?
 - 5% with aneuploidy (likelihood ratio is 9)
 - 1:12 if associated anomalies seen
 - 1:33 if isolated
 - ↑ diagnosis of congenital infection
- Monitoring mild VM as pregnancy progresses
 - Stable in 56%, ↑ in 16%, ↓ in 34%
 - 7-13% with late-onset brain anomalies
 - Mostly cortical malformations
 - Surveillance depends on age at diagnosis
 - 1st follow-up in 2-3 weeks after diagnosis
 - At least 1 additional detailed exam in 3rd trimester: Best at 30-34 weeks

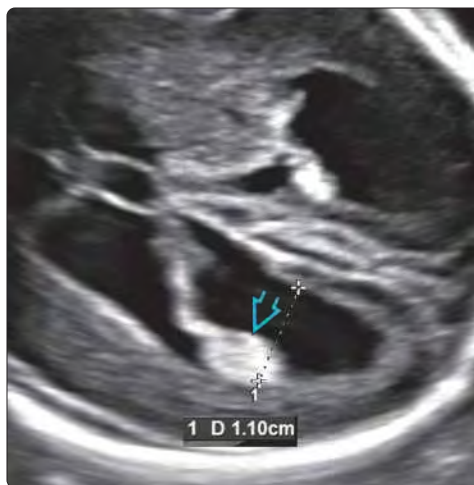
Alternative Differential Approaches

- Pay attention to head size
- VM and small head
 - Trisomy 18
 - Trisomy 13
 - Encephalomalacia
- VM and big head
 - Aqueductal stenosis
 - Trisomy 21 (brachycephaly is common)
 - Choroid plexus papilloma

Idiopathic/Isolated



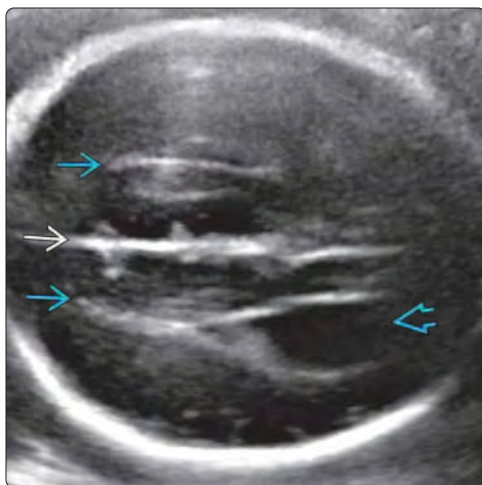
Trisomy 21



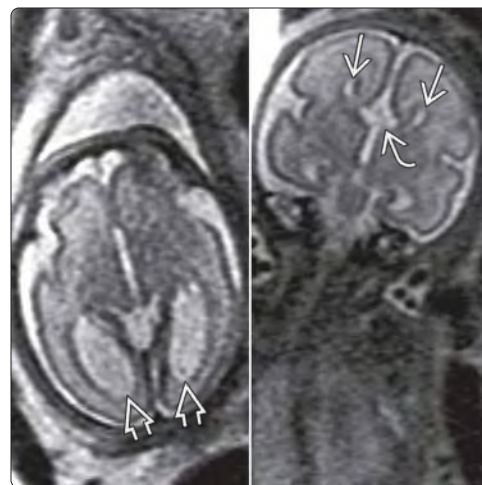
(Left) Fetal MR was performed in this 23-week fetus with isolated mild ventriculomegaly (VM). No other anomalies were seen, and the VM eventually resolved. Most cases of mild VM seen with US are isolated, but fetal MR may show additional CNS findings in up to 10%. (Right) Mild VM is diagnosed in this fetus with trisomy 21, which also had increased nuchal fold and atrioventricular septal defect. The measurement (calipers) was taken at the level of the atrium where the dorsal choroid plexus (the glomus) resides.

Abnormal Corpus Callosum

(Left) In this fetus with dysgenesis of the corpus callosum and absent cavum septi pellucidi (CSP), the ventricle is teardrop-shaped with dilation posteriorly and laterally displaced frontal horns parallel to the falx. Colpocephaly is another term used for this lateral ventricle morphology. (Right) Axial and coronal T2WI MR in another case shows colpocephaly, elevated 3rd ventricle, and parallel frontal horns. The coronal view shows the trident-shaped morphology of the frontal horns.

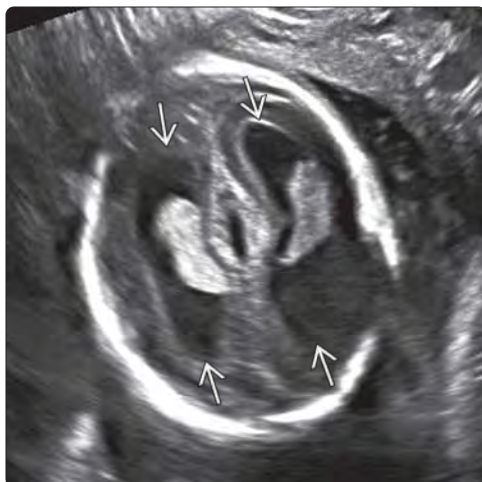

Abnormal Corpus Callosum

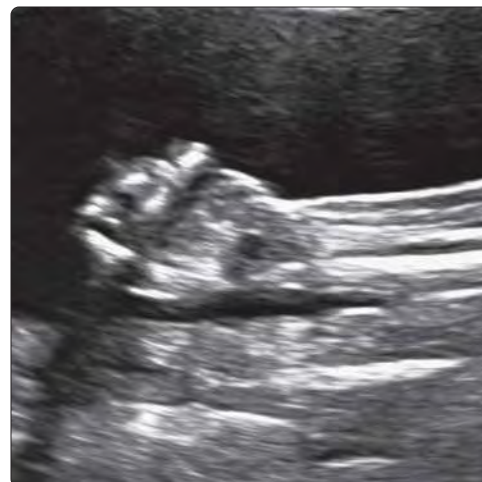

Aqueductal Stenosis, Early

(Left) Axial transvaginal US shows bilateral mild VM at 20 weeks. This fetus was male and had a sibling with X-linked aqueductal stenosis. (Right) Coronal US of the hand in the same case shows a fist. Neither of the hands ever opened, and the thumbs were adducted. The findings, along with amniocentesis results, were diagnostic of a 2nd child affected with X-linked aqueductal stenosis.

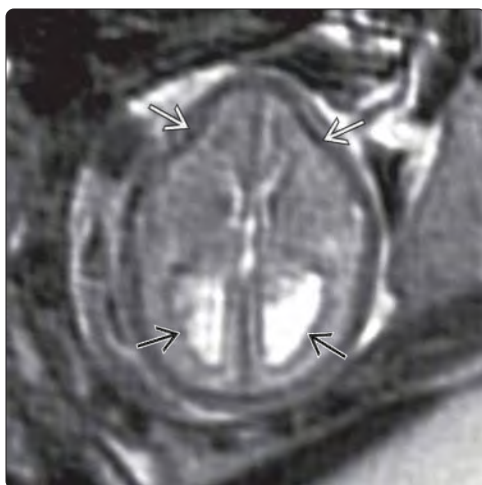


Aqueductal Stenosis, Early

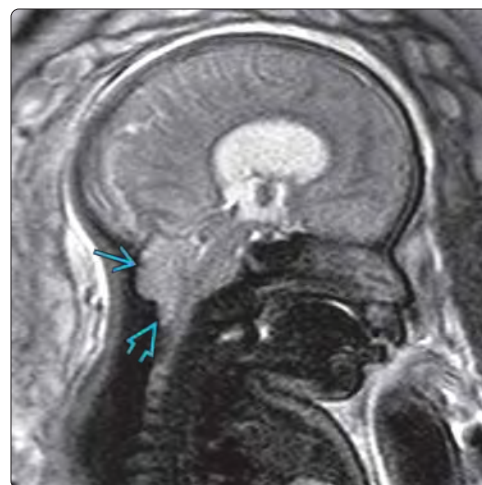

Chiari 2 Malformation, Early

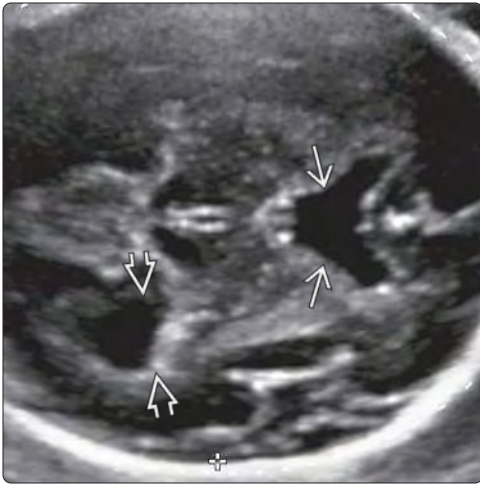
(Left) Axial T2WI MR shows frontal bone concavity (lemon-shaped calvarium) and mild VM. (Right) Sagittal view of the hindbrain in another fetus shows cerebellar compression and inferior cerebellar tonsil herniation, diagnostic of Chiari 2 malformation. Spina bifida and mild VM were also seen. VM tends to increase with advancing pregnancy in fetuses with spina bifida.



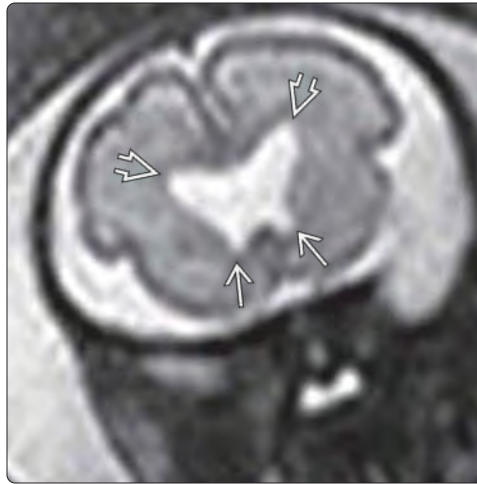
Chiari 2 Malformation, Early



Septo-Optic Dysplasia

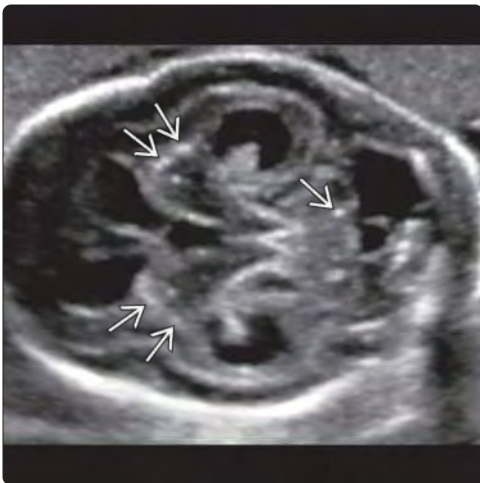

Septo-Optic Dysplasia

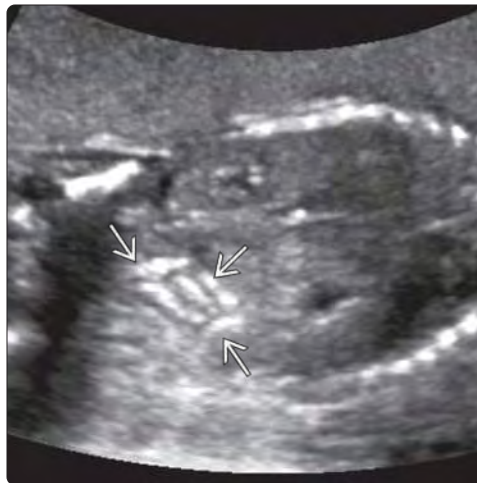


(Left) This fetus has mild VM and an absent CSP. The frontal horns do not have an internal "box" that is seen when the CSP is present. **(Right)** Coronal T2 MR performed in the same case shows the classic frontal horn morphology of septo-optic dysplasia. Superior frontal horn is somewhat "squared", and the inferior frontal horns point down. The CSP is absent, but, otherwise, the cerebral hemispheres are separate, without any fusion, making holoprosencephaly a less likely diagnosis.

Congenital Infection

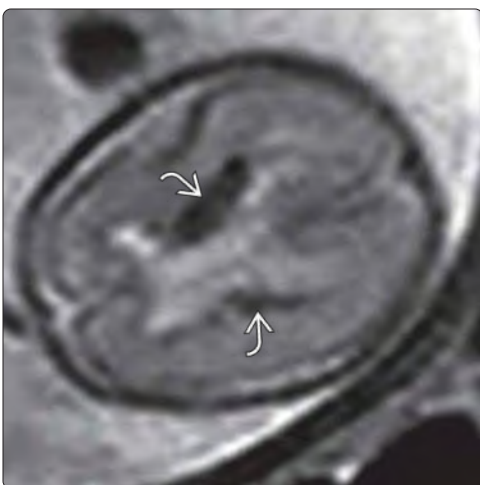


Congenital Infection

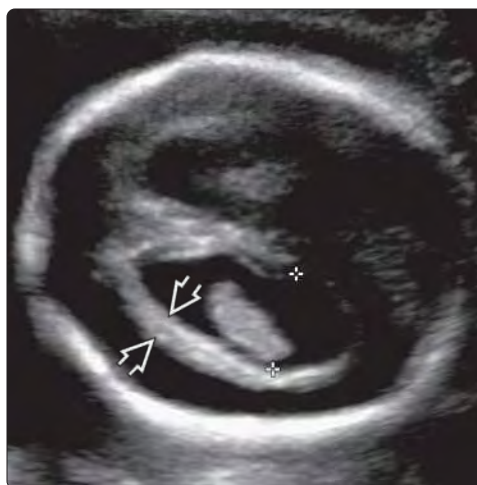


(Left) Axial US shows subtle echogenic brain calcifications in this fetus with mild VM and amniocentesis-proven CMV infection. **(Right)** Views through the fetal abdomen, in the same fetus with CMV, show echogenic bowel and oligohydramnios. An infectious work-up in fetuses with VM is recommended because it can be one of the 1st findings with congenital infection, before calcifications and fetal growth restriction.

Intracranial Hemorrhage



Encephalomalacia



(Left) In this monozygotic twin with twin-twin transfusion, US showed new VM and increased echogenicity within the ventricles 1 week after laser treatment. MR was then performed (23 weeks) showing low signal hemosiderin within the lateral ventricles, diagnostic of hemorrhage. **(Right)** Mild VM and periventricular-increased echogenicity is seen in this monozygotic twin, a week after demise of its co-twin. Progressive VM and parenchymal cystic change ensued.

DIFFERENTIAL DIAGNOSIS**Common**

- **Abnormal Shape**
 - Scan Technique
 - Dolichocephaly
 - Brachycephaly
 - Lemon-Shaped
 - Strawberry-Shaped
 - Round
 - Spaulding Sign
 - Craniosynostosis
- **Calvarial Defect**
 - Exencephaly, Anencephaly
 - Encephalocele
 - Amniotic Band Syndrome
- **Abnormal Size**
 - Macrocephaly
 - Microcephaly

Less Common

- **Skeletal Dysplasias**
 - Decreased Ossification
 - Osteogenesis Imperfecta
 - Achondrogenesis
 - Hypophosphatasia
 - Abnormal Shape
 - Achondroplasia
 - Thanatophoric Dysplasia Type 2
- **Scalp Masses**
 - Hemangioma
 - Lymphangioma

ESSENTIAL INFORMATION**Key Differential Diagnosis Issues**

- Assess calvarial size, shape, and mineralization in all cases
 - Size
 - Is size concordant with gestational age and other biometric parameters?
 - Shape
 - Can you see standard scan plane anatomy?
 - If not, is it because of fetal position or maternal habitus?
 - Use transvaginal sonography for better resolution
 - 3D ultrasound allows volume acquisition
 - Data manipulation allows reproduction of true axial plane
 - Mineralization
 - Skull is formed after 10 weeks; use EV sonography from 10-14 weeks for better resolution if questions
 - If brain seen "too well" consider conditions with poor mineralization
 - Transducer pressure cannot deform normally ossified cranium
- Is there a bony defect?
 - Essential to look at skull vault from several scan planes
 - Refraction of beam may create artifactual defect
 - Must know normal anatomy

Helpful Clues for Common Diagnoses

- **Scan Technique**
 - Make sure thalami and cavum septi pellucidi are visible
 - Falx should bisect cranium anterior to posterior in axial plane
- **Dolichocephaly**
 - Boat-shaped
 - Long back-to-front, narrow side-to-side
 - Seen with breech presentation, oligohydramnios, myelomeningocele
- **Brachycephaly**
 - Short back-to-front, wide side-to-side
 - Described in trisomy 21
 - Increased diameter of head and shortened femur/humerus accounts for short femur marker for trisomy 21
- **Lemon-Shaped**
 - Bifrontal concavity seen with Chiari 2 malformation
 - Resolves in 3rd trimester in all cases
 - Occurs in various other conditions and 1% of normal fetuses
- **Strawberry-Shaped**
 - Triangular configuration described in trisomy 18
 - Most fetuses with trisomy 18 have multiple other anomalies
- **Round**
 - May be technical if measurement obtained in wrong scan plane
 - If normal anatomic markers are not identified and head shape appears round from multiple acoustic windows, underlying brain is usually abnormal
 - Look carefully for signs of aprosencephaly/holoprosencephaly spectrum
- **Spaulding Sign**
 - Bones of skull vault overlap as brain collapses following demise
- **Craniosynostosis**
 - Abnormal head shape secondary to premature closure of sutures
 - Look for features of associated conditions (e.g., Crouzon, Pfeiffer, Apert, skeletal dysplasia)
- **Exencephaly, Anencephaly**
 - Exencephaly: Lack of cranial vault but brain tissue present
 - Anencephaly: Cranial vault absent, no brain tissue, skull base contains gelatinous angiomatous stroma
- **Encephalocele**
 - Occipital: Herniation of intracranial structures through occipital defect
 - Look for other anomalies/signs of aneuploidy
 - Frontal: Herniation of intracranial structures through anterior skull defect
 - Look for associated hypertelorism, callosal dysgenesis, midline lipoma
- **Amniotic Band Syndrome**
 - Look for linear echoes from bands in amniotic fluid
 - Look for associated extremity amputation or constriction defects
 - Anencephaly with asymmetric orbits or facial cleft → bands highly likely ("slash" defects)

- **Macrocephaly**
 - Enlarged head: Biparietal diameter (BPD) (\pm head circumference) > 2 SD above mean
 - Look for underlying abnormalities (e.g., hydrocephalus, tumor, megalencephaly)
- **Microcephaly**
 - Small head: BPD (\pm head circumference) > 2 SD below mean
 - Seen with infection, ischemia, syndromes, malformations

Helpful Clues for Less Common Diagnoses

- **Osteogenesis Imperfecta**
 - See brain too well, compressible skull
 - Associated with fractures in long bones, beaded ribs
- **Achondrogenesis**
 - Hallmark is lack of vertebral ossification
- **Hypophosphatasia**
 - Associated with micromelia and thin, bowed bones in perinatal lethal form
- **Achondroplasia**

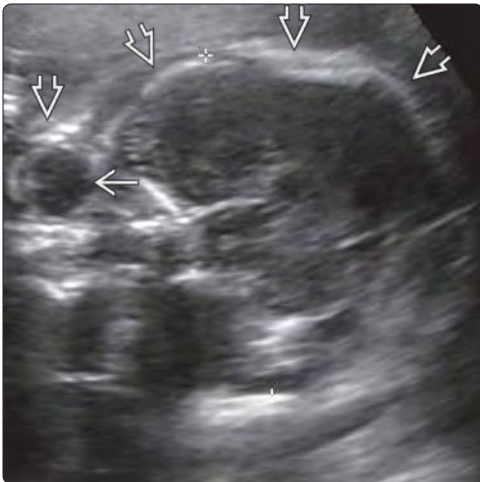
- Frontal bossing, lumbar lordosis, progressive long bone shortening
- **Thanatophoric Dysplasia Type 2**
 - Kleeblattschädel skull, micromelia, tiny chest, platyspondyly

- **Scalp Masses**
 - Calvarium normal
 - Mass (e.g., lymphangioma, hemangioma) arises from scalp

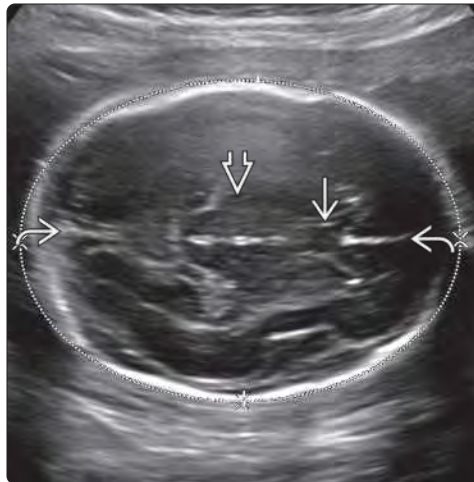
Other Essential Information

- Technique very important in head measurement and evaluation of calvarial contour
- BPD
 - Measure at level of thalami and cavum septi pellucidi
 - Cerebellar hemispheres should not be visible
 - Midline echoes in center of oval-shaped cross section
 - Measure outer edge proximal skull to inner edge distal skull
- Head circumference: Measure around outer edge of skull in same plane as BPD

Scan Technique

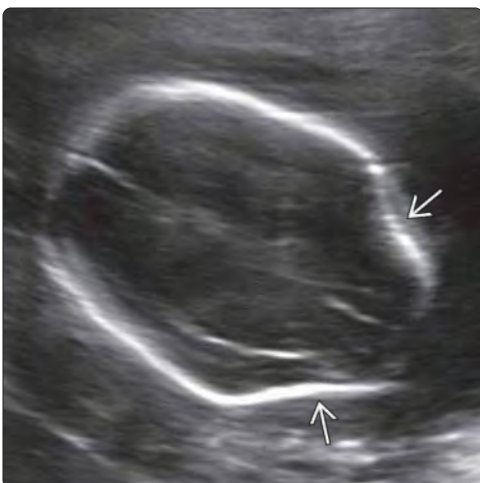


Scan Technique

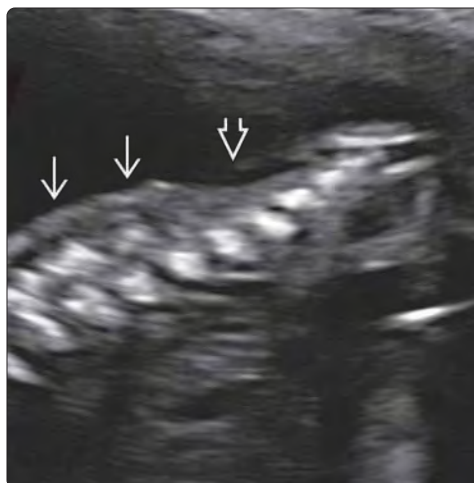


(Left) Axial ultrasound shows an odd calvarial contour because the orbits are included in the scan plane, which is incorrect. The thalami and cavum are markers for the correct scan plane to measure the biparietal diameter (BPD); neither is visible here. (Right) Compare the prior image to this one obtained moments later in the same fetus. The correct scan plane shows the cavum, thalami, and central midline echo, and the head shape is oval as it should be. The cursors mark the BPD and the dots outline the head circumference.

Lemon-Shaped



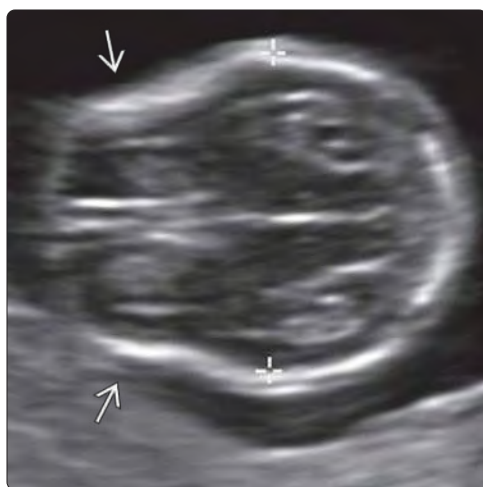Lemon-Shaped



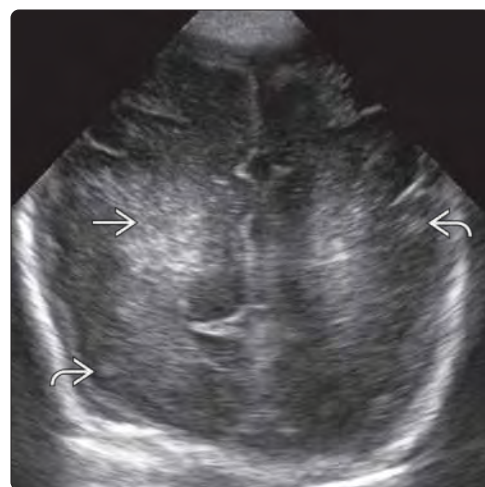
(Left) Axial ultrasound shows bifrontal concavity in a 19-week fetus. This sign should prompt careful evaluation for a Chiari 2 malformation. It is not pathognomonic as it may be seen in normal fetuses and in association with other abnormalities. (Right) The fetus spine shows an open neural tube defect (ONTD). This is myeloschisis (i.e., there is no sac) illustrating why you must check the skin line on the sagittal view. It is disrupted at the site of an ONTD. Axial and sagittal spine images are essential when a lemon-shaped head is seen.

Lemon-Shaped

(Left) Axial ultrasound shows bifrontal concavity in a 14-week fetus. The brain echogenicity is also diffusely abnormal. Many additional abnormalities were seen, and there was severe growth restriction. CMV testing was positive. (Right) Neonatal head ultrasound in the same case shows abnormal deep white matter echogenicity and multiple nodular subcortical echoes indicating cortical dysplasia. While a lemon-shaped head can be a normal variant, it should trigger a careful evaluation of the fetus.

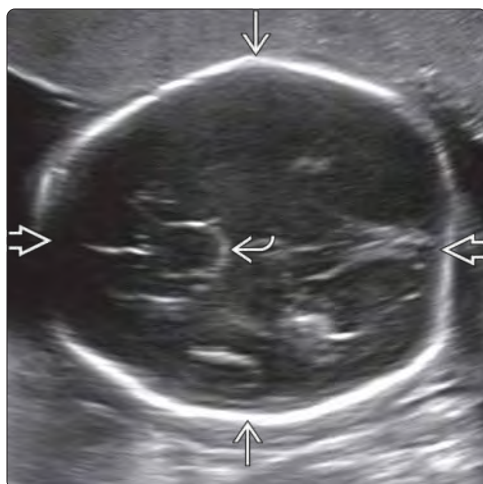


Lemon-Shaped

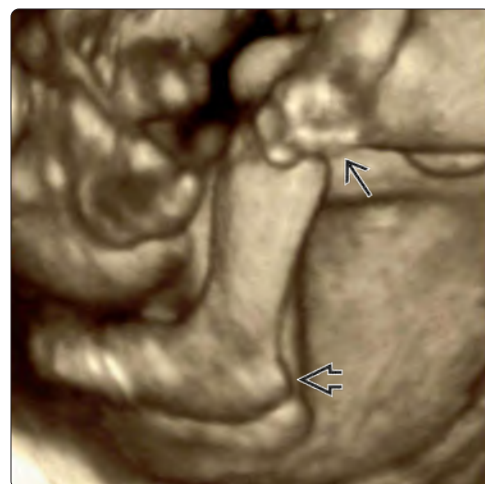


Strawberry-Shaped

(Left) Axial ultrasound shows the typical configuration of the strawberry-shaped head, which is wide side-to-side and shortened front-to-back. Note the large cavum septi pellucidi; this has been observed in aneuploid fetuses. CSP width above the 95th percentile was seen in 92% of fetuses with trisomy 18 in 1 series. (Right) 3D surface-rendered ultrasound in the same fetus shows a clenched hand and rocker-bottom foot. These are typical extremity findings in trisomy 18.

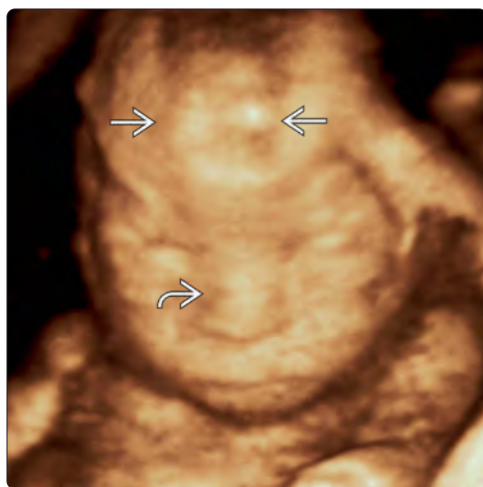


Strawberry-Shaped

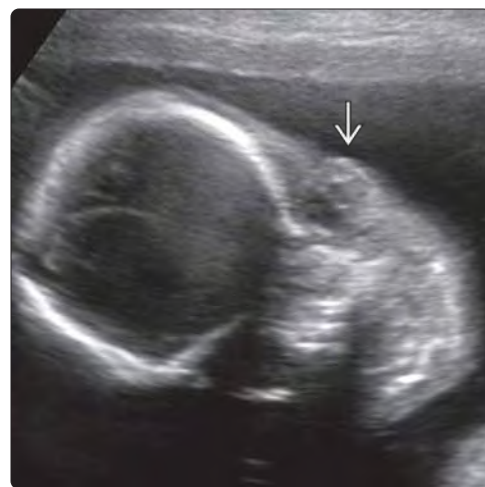

Craniosynostosis

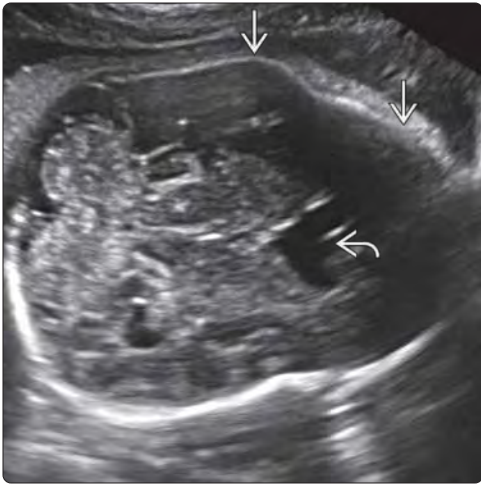(Left) 3D surface-rendered ultrasound shows a prominent frontal "bulge" and broad flat nose in a fetus eventually diagnosed with Beare-Stevenson cutis gyrata syndrome. (Right) Coronal ultrasound through the fetal face in the same patient shows proptosis. The infant has multiple medical problems and exposure keratosis was so bad that she had to have bilateral tarsorrhaphy (surgery to partially close the eyelids).



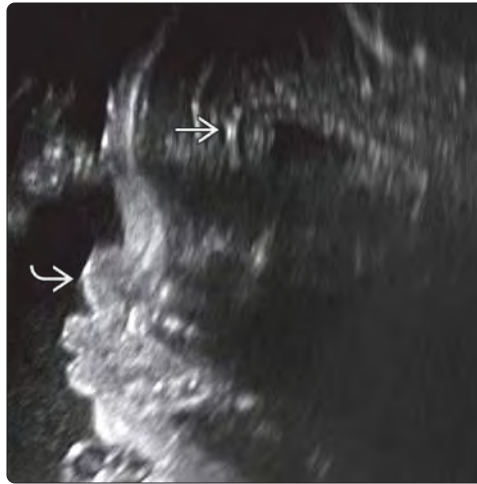
Craniosynostosis



Craniosynostosis

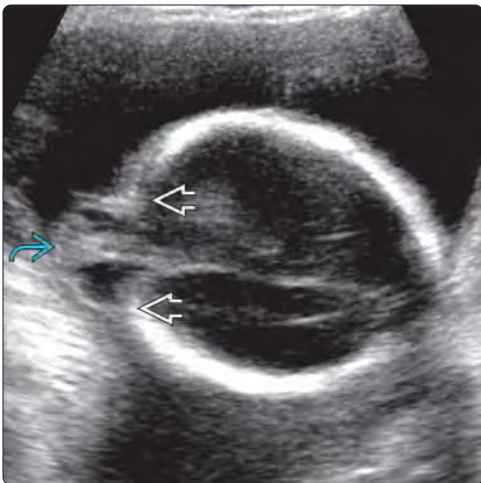


Craniosynostosis

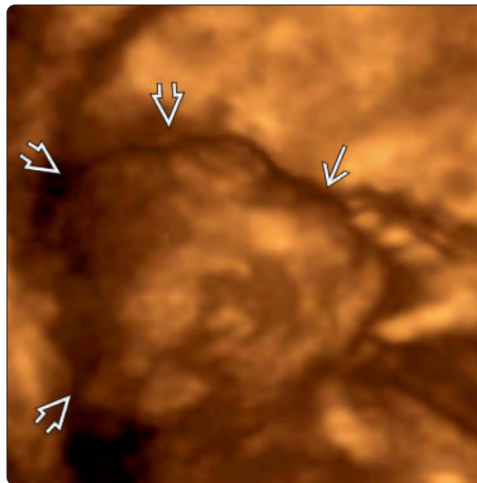


(Left) Axial oblique ultrasound shows abnormal cranial contour in a fetus with a final diagnosis of Pfeiffer syndrome. Note that the cavum septi pellucidi is absent. Brain anomalies can be seen in syndromes with craniosynostosis, including thanatophoric dysplasia, Apert syndrome, and conditions associated with mutations in the FGFR gene family. (Right) Profile view in the same fetus shows a short, upturned nose. The anterior corpus callosum is clearly present, excluding agenesis as the cause of the absent cavum.

Encephalocele

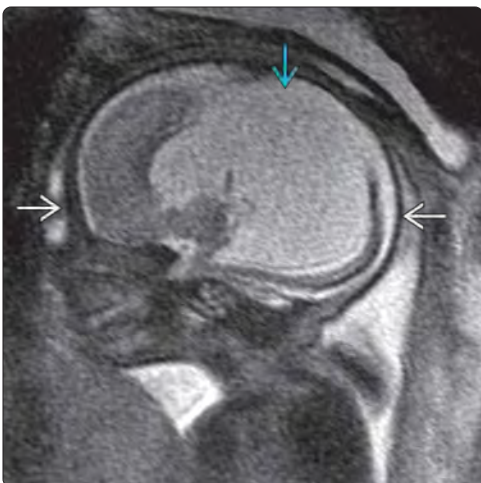


Exencephaly, Anencephaly

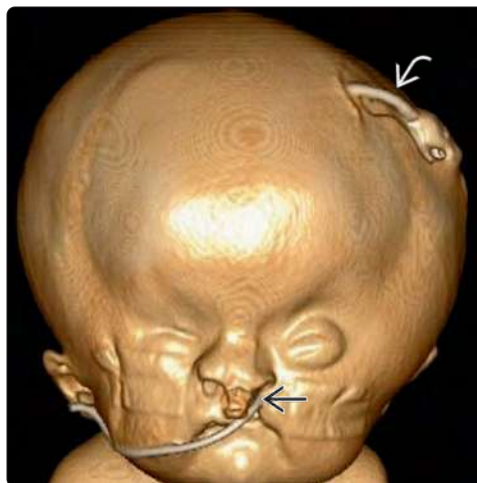

(Left) Axial oblique ultrasound shows a focal contour abnormality in the posterior skull caused by an occipital encephalocele. Note the calvarial defect. (Right) 3D surface-rendered US shows a relatively normal face but no appreciable calvarium. Dysplastic brain tissue (angiomatous stroma) may be seen sitting in the "bowl" of the skull base, which is present in anencephaly: The missing part is the skull vault that forms by intramembranous ossification.

Macrocephaly



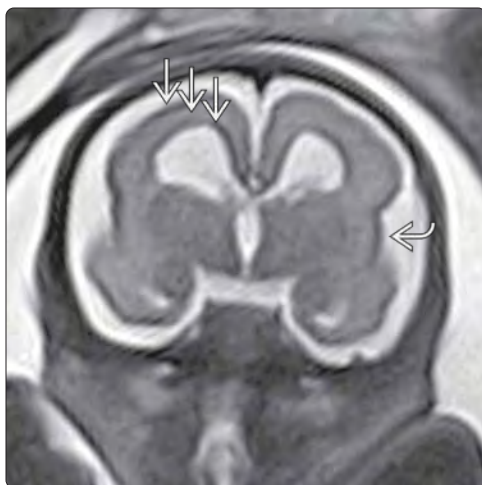Macrocephaly



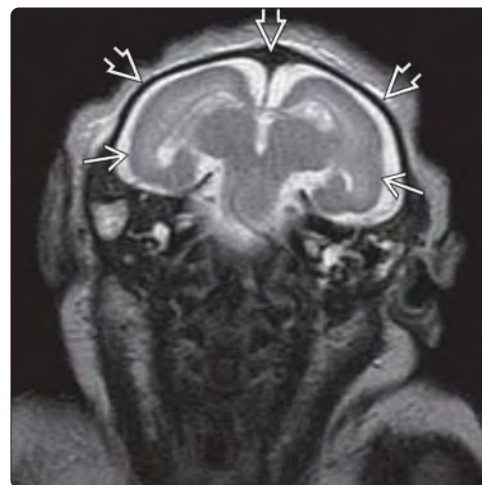
(Left) Sagittal fetal MR shows macrocephaly due to hydrocephalus in a fetus with agenesis of the corpus callosum and a large interhemispheric cyst. (Right) 3D surface-rendered CT in an infant with hydrocephalus and macrocephaly shows the head is still dramatically enlarged despite the presence of a ventriculoperitoneal shunt. The infant clearly has feeding problems (feeding tube) and was developmentally delayed.

Microcephaly

(Left) Coronal T2WI in a 32-week fetus with a small head shows an abnormal brain in which the sylvian fissures are wide open and the brain still has the immature 3-layer appearance. Final diagnosis was congenital cytomegalovirus infection. **(Right)** T2WI in a newborn with a head circumference 4 SD below the mean shows lissencephaly and a very small cranium. The most common causes of pediatric microcephaly include congenital infection, ischemia, and malformations, such as lissencephaly.

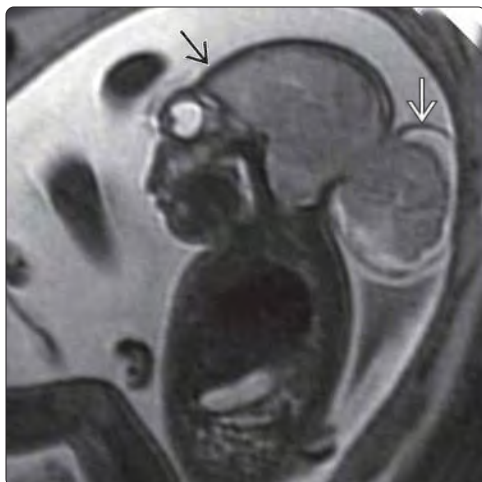

Microcephaly

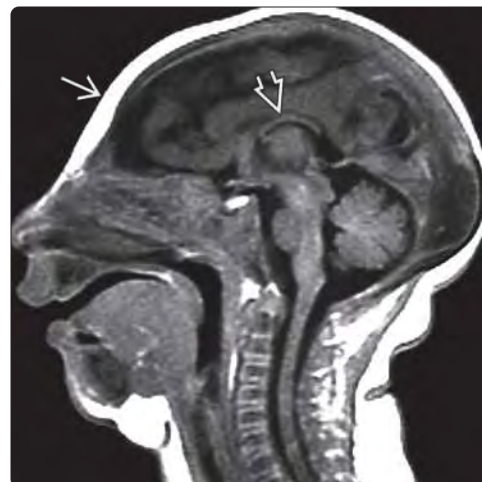

Microcephaly

(Left) Late 2nd-trimester fetal MR shows the typical sloping forehead appearance of microcephaly. In this case, the cause is the large occipital encephalocele, which contains a lot of the brain parenchyma. **(Right)** Sagittal T1 MR in a microcephalic infant shows markedly reduced cranial:facial ratio, with a sloping forehead. The corpus callosum is hypoplastic. The brain shows shallow sulci and broad flat gyri (pachygyria).

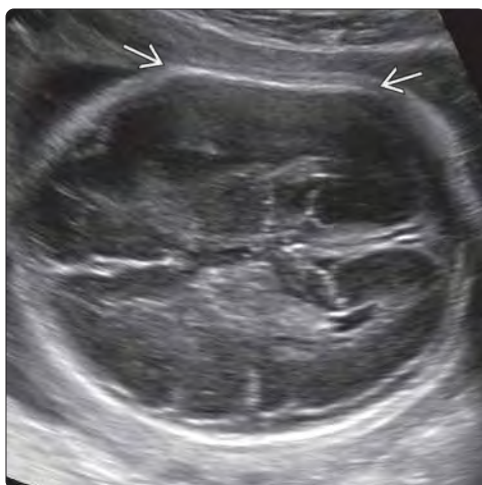

Microcephaly

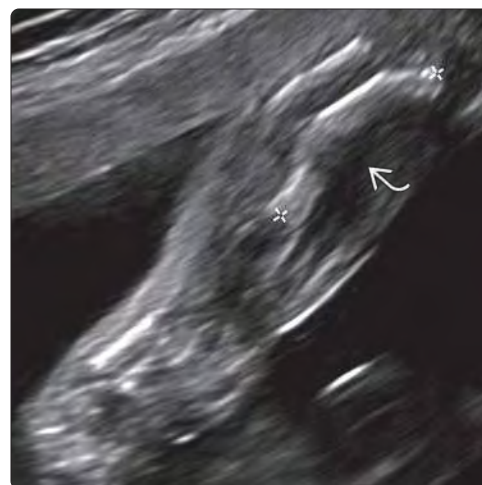

Osteogenesis Imperfecta

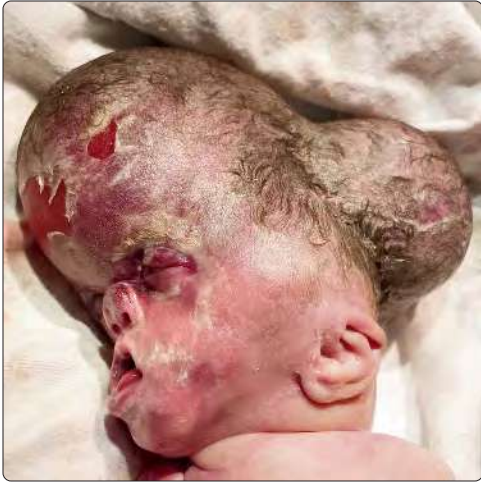(Left) Axial transabdominal ultrasound shows that the fetal cranium can be deformed by transducer pressure. This proves that the bone is underossified. Also note how well the nearfield brain is seen; in the 3rd trimester, reverberation from the skull usually completely obscures details of the upside brain hemisphere. **(Right)** In the same fetus with osteogenesis imperfecta type 3, angulation of the forearm bones is secondary to fractures.



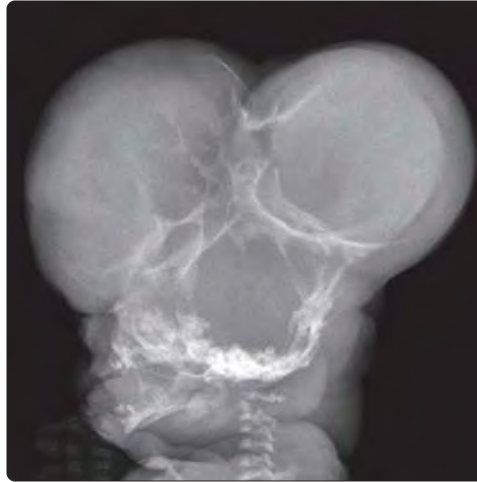Osteogenesis Imperfecta



Thanatophoric Dysplasia Type 2

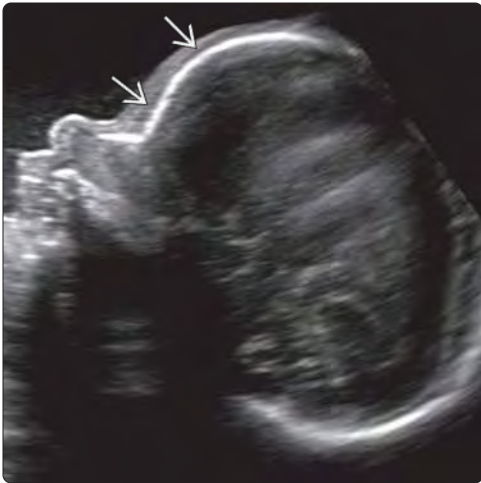

Thanatophoric Dysplasia Type 2

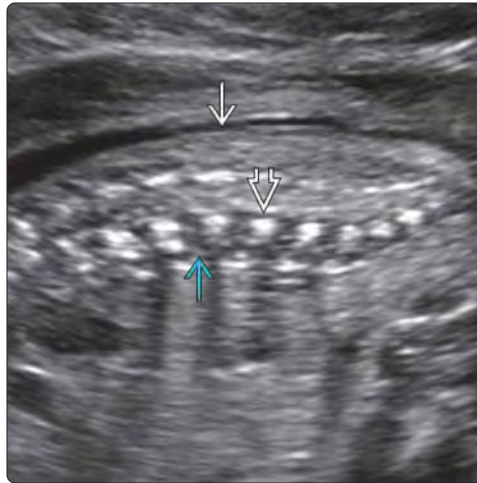


(Left) Clinical photograph shows the marked distortion of the skull seen in thanatophoric dysplasia type 2. This is described as a cloverleaf deformity or kleeblattschädel. (Right) Autopsy radiograph in the same patient shows the severe skull deformity. This is a characteristic feature of thanatophoric dysplasia type II. The head shape is much more normal in thanatophoric dysplasia type I; the hallmark finding in that entity is the "telephone receiver" femur.

Achondroplasia

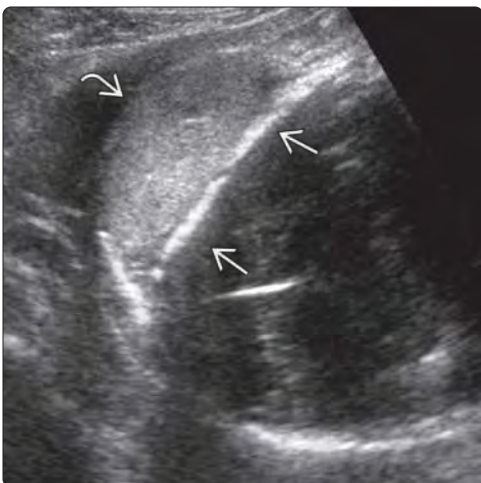


Achondroplasia

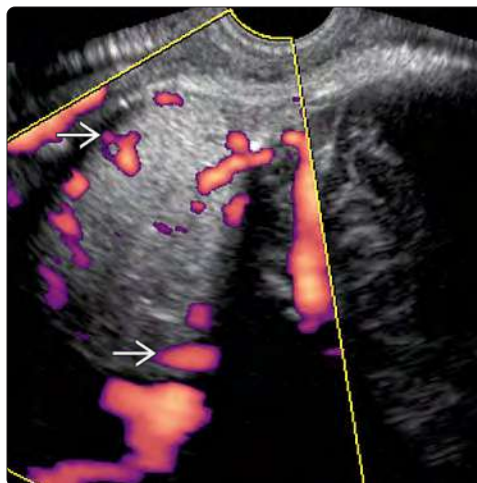

(Left) Profile view of a fetus with achondroplasia shows frontal bossing. In fetuses with short limbs, it is important to look at the skull shape, profile view, extremities, and spine to help with differential diagnosis. (Right) Sagittal ultrasound of the spine in the same patient shows the characteristic lumbar lordosis seen in achondroplasia. This is also a good view to check for platyspondyly, as you can compare the disc height to the vertebral body height.

Hemangioma



Hemangioma



(Left) Transabdominal ultrasound shows a uniformly echogenic mass in the fetal scalp. It is causing local mass effect with flattening of the skull. (Right) Vaginal ultrasound with power Doppler in the same patient shows multiple small vessels within the mass. This is a typical appearance for a scalp hemangioma. It is always important to show that the underlying skull is intact to rule out an encephalocele.

DIFFERENTIAL DIAGNOSIS

Common

- Incorrect Scan Plane
- Mega Cisterna Magna
- Dandy-Walker Malformation
- Vermian Dysgenesis
- Blake Pouch Cyst
- Arachnoid Cyst

Less Common

- Cerebellar Hypoplasia
- Dural Sinus Malformation
- Vein of Galen Malformation

Rare but Important

- Joubert Syndrome

ESSENTIAL INFORMATION

Key Differential Diagnosis Issues

- Make sure to use correct technique
 - Cisterna magna depth is measured on oblique axial view plane with both cavum septi pellucidi and cerebellum visible
- Use multiple scan planes
 - Standard axial images are insufficient to differentiate between various posterior fossa "cysts"
 - Sagittal view essential for evaluation of vermian, tegmentovermian angle (TVA)
- Assess cerebellar size and shape
 - Measure transcerebellar diameter
 - Use normative tables for exact percentiles
 - Confirm that cerebellum is small, not that posterior fossa enlargement makes it look small
 - If cerebellum normal, options are mega cisterna magna or posterior fossa arachnoid cyst
- Assess vermian size, shape, and rotation
 - If vermian present but distorted/compressed, consider arachnoid cyst in posterior fossa
 - If vermian normal shape but rotated, Blake pouch cyst is most likely diagnosis
- Always use Doppler to evaluate any cystic appearing structure

Helpful Clues for Common Diagnoses

- **Incorrect Scan Plane**
 - Overly coronal image gives false impression of mega cisterna magna
 - Also overestimates nuchal fold thickness
- **Mega Cisterna Magna**
 - Enlarged cisterna magna measuring > 10 mm
 - Make sure this is correct measurement
 - Should see cavum septi pellucidi in plane with cerebellum
 - Can give overall impression of relatively small cerebellum
 - Actual cerebellar diameter normal for gestational age
 - Usually incidental finding of no clinical consequence
 - May be part of multiple findings seen with trisomy 18
- **Dandy-Walker Malformation**
 - Absence or severe dysgenesis of vermian
 - Large posterior fossa cyst

- 4th ventricle open to posterior fossa cyst
- Elevated torcular Herophili (confluence of superior sagittal, straight, & occipital sinuses)
- Look for other associated anomalies (seen in 70-90%)
 - Callosal dysgenesis
 - Heterotopia, cortical dysplasia
 - Chromosomal abnormalities
 - Cardiac anomalies

- **Vermian Dysgenesis**

- Milder form of Dandy-Walker malformation
- Vermis incompletely developed and morphologically abnormal
- 4th ventricle open to cisterna magna
 - Keyhole appearance of 4th ventricle on axial ultrasound
- No torcular elevation
- Avoid overdiagnosis
 - Vermis not always completely formed until 17 weeks
 - Overly coronal oblique scan plane can simulate vermian defect

- **Blake Pouch Cyst**

- Blake pouch cyst lies inferior to structurally normal vermian
 - Cyst elevates and rotates vermian
 - Rotation causes abnormal TVA
 - ◻ Normal is close to 0°, angle < 30° likely Blake pouch cyst
 - No or minimal enlargement of cisterna magna
 - Cisterna magna septa may be bowed laterally
 - Cyst fluid anechoic whereas cerebrospinal fluid in cisterna magna has internal echoes
- **Arachnoid Cyst**
 - Extraaxial cyst containing cerebrospinal fluid
 - Simple cyst; variable in size
 - Avascular
 - 1/3 of cases occur in posterior fossa
 - Cyst does not communicate with 4th ventricle
 - Vermian is intact
 - Cerebellum ± vermian may be distorted by mass effect

Helpful Clues for Less Common Diagnoses

- **Cerebellar Hypoplasia**
 - Cerebellar axial diameter less than expected for gestational age
 - Normally formed cerebellar hemispheres present
 - Folia appear normal (prominent sulci seen with atrophy, not hypoplasia)
 - Look for other anatomic abnormalities
 - Associated with aneuploidy particularly trisomy 18
- **Dural Sinus Malformation**
 - Grossly triangular in shape, apex anterior but may appear round in cross section on axial images
 - Majority of fetal cases are thrombosed at presentation
 - Ultrasound shows mixed echogenicity cystic mass centered on tentorium, involving torcular Herophili
 - MR shows high signal areas on T1WI due to clotted blood, low/mixed signal on T2WI
 - Tubular areas of high T1/low T2 signal seen with clot extension into venous sinuses

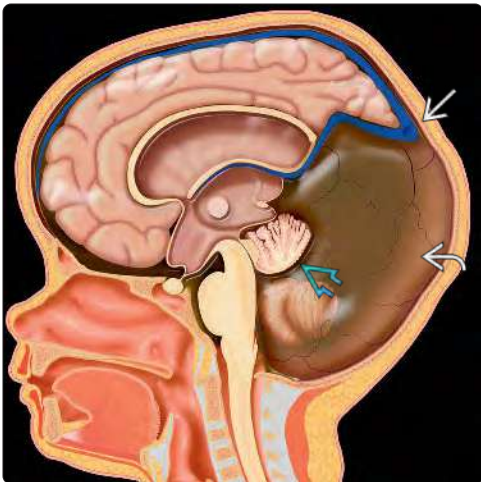
- **Vein of Galen Malformation**
 - Arteriovenous fistula between deep choroidal arteries and embryonic median prosencephalic vein of Markowski
 - Elongated midline cystic structure
 - Extends from quadrigeminal plate cistern posteriorly toward occiput
 - Drains via straight sinus or, more commonly, embryonic falxine sinus
 - Flow on color Doppler with arterialized venous flow on pulsed Doppler tracing
- **Joubert Syndrome**
 - Cerebellar cleft at midline between hemispheres
 - Represents prominent interpeduncular fossa
 - May be seen in conjunction with ventriculomegaly, encephalocele, polydactyly, micropenis
 - Can be confused with Dandy-Walker malformation but no torcular elevation
 - Molar tooth sign on fetal MR and ultrasound
 - Deepened interpeduncular fossa
 - Thick, straight superior cerebellar peduncles

- Hypoplastic vermis
- Abnormal midbrain (↓ anteroposterior diameter)
- May see fetal hyperpnea up to 140-160 breaths/min
- Autosomal recessive disorder
 - Careful family history
 - Genetic counseling useful for future pregnancy planning

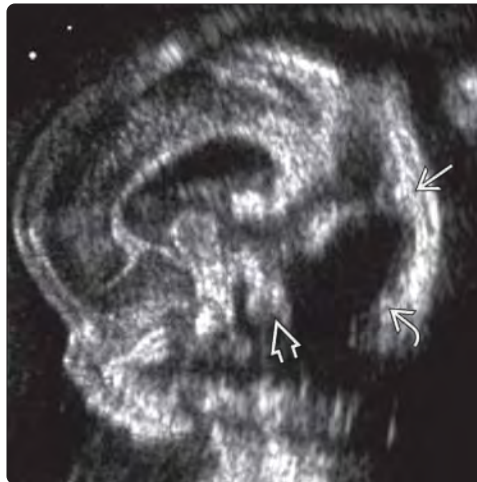SELECTED REFERENCES

1. Chapman T et al: Diagnostic imaging of posterior fossa anomalies in the fetus and neonate: part 2, posterior fossa disorders. *Clin Imaging.* 39(2):167-175, 2015
2. Chapman T et al: Diagnostic imaging of posterior fossa anomalies in the fetus and neonate: part 1, normal anatomy and classification of anomalies. *Clin Imaging.* 39(1):1-8, 2015
3. Paladini D et al: Abnormal or delayed development of the posterior membranous area of the brain: anatomy, ultrasound diagnosis, natural history and outcome of Blake's pouch cyst in the fetus. *Ultrasound Obstet Gynecol.* 39(3):279-87, 2012
4. Adamsbaum C et al: MRI of the fetal posterior fossa. *Pediatr Radiol.* 35(2):124-40, 2005

Dandy-Walker Malformation

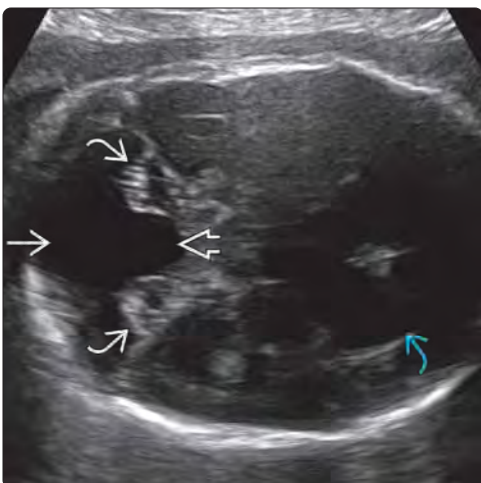


Dandy-Walker Malformation

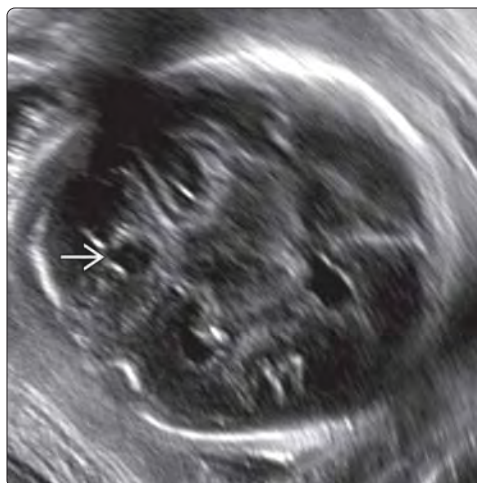

(Left) Graphic shows a superiorly rotated vermian remnant [blue arrow], an uncovered 4th ventricle communicating with a posterior fossa cyst [blue arrow], and elevation of the torcular [white arrow]. These are the requisite findings of a Dandy-Walker malformation. (Right) The routine brain views of this fetus showed a cystic fluid collection in the posterior fossa. Dandy-Walker malformation was confirmed on a sagittal US, which shows a vermian remnant [blue arrow], posterior fossa cyst [blue arrow], and elevation of the torcular [white arrow].

Dandy-Walker Malformation



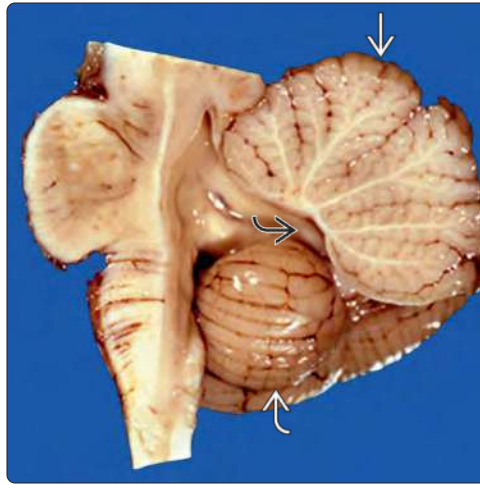
Vermian Dysgenesis



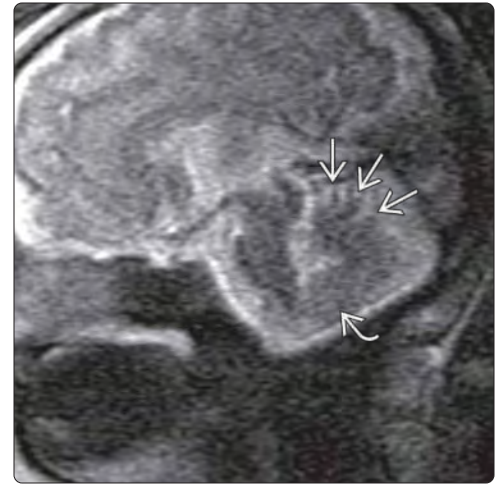(Left) Axial US at 29-week gestation shows small dysplastic cerebellar hemispheres [white arrow], with the uncovered 4th ventricle [white arrow] and posterior fossa cyst [white arrow]. In this case, the Dandy-Walker malformation is associated with hydrocephalus [blue arrow]. (Right) Contrast this axial oblique US with a posterior fossa "keyhole" [white arrow] due to vermian dysgenesis with the prior image. There is neither a large posterior fossa cyst nor torcular elevation with vermian dysgenesis.

Vermian Dysgenesis

(Left) Autopsy image shows a potential pitfall with vermian dysgenesis. When the vermis is abnormally small and rotated, the medial part of the cerebellar hemisphere moves toward the midline. Note the lack of a normal fastigial point. (Right) Sagittal T2WI MR is the correlate of the autopsy image. At 1st glance, the vermis looks normal. However, the fastigial point is not sharp and the vermis (identified by the folia) is small and elevated. The medial part of the cerebellar hemisphere mimics the inferior vermis.

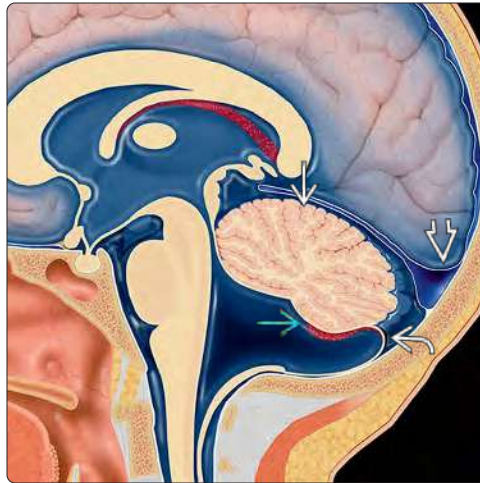


Vermian Dysgenesis

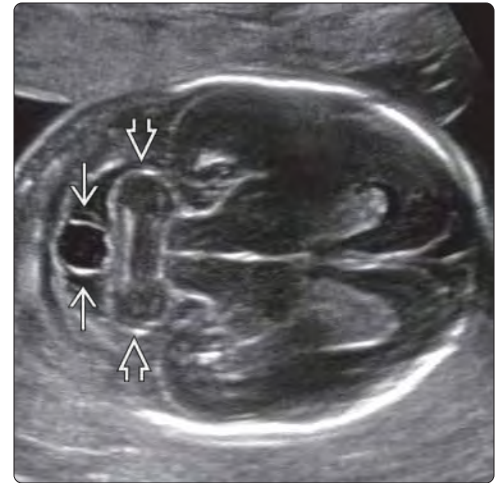

Blake Pouch Cyst

(Left) Graphic illustrates a Blake pouch cyst causing upward rotation of the vermis and displacement of the 4th ventricle choroid plexus to its superolateral margin. Torcular location is normal. The cyst communicates with the 4th ventricle but not with the cisterna magna. (Right) Axial US at 17 weeks shows the walls of the Blake pouch, which are convex outward. The cerebellum and supratentorial brain were normal. This resolved in follow-up, consistent with interval fenestration of the foramen of Magendie.

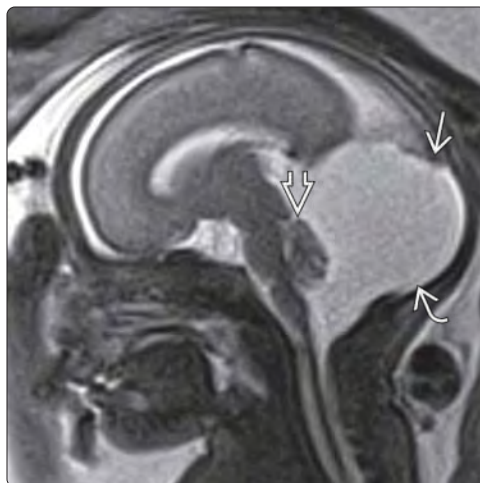


Blake Pouch Cyst

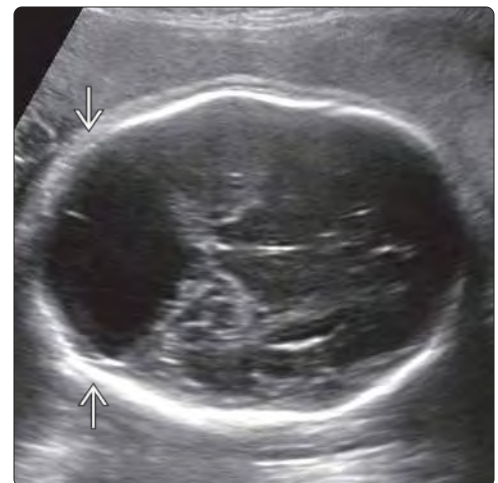


Arachnoid Cyst

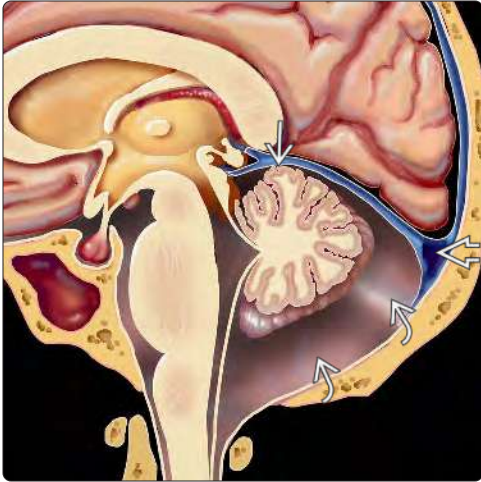
(Left) Sagittal T2WI MR in a fetus referred for a possible porencephalic cyst shows a simple cyst compressing the vermis and elevating the torcular. The mass effect and lack of brain destruction exclude porencephaly, and the normal tegmentovermian angle excludes Dandy-Walker malformation. (Right) Axial US in the same case shows the cyst expanding the posterior fossa. The supratentorial brain is normal. Sagittal views were crucial for making the correct diagnosis in this case.



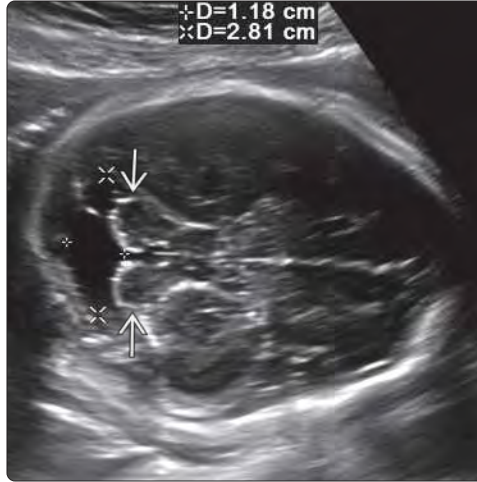
Arachnoid Cyst



Cerebellar Hypoplasia

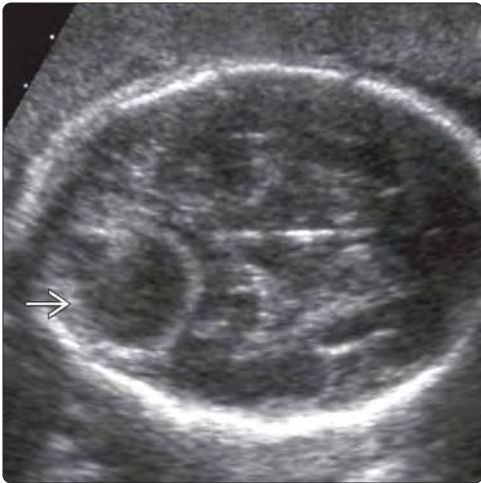


Cerebellar Hypoplasia

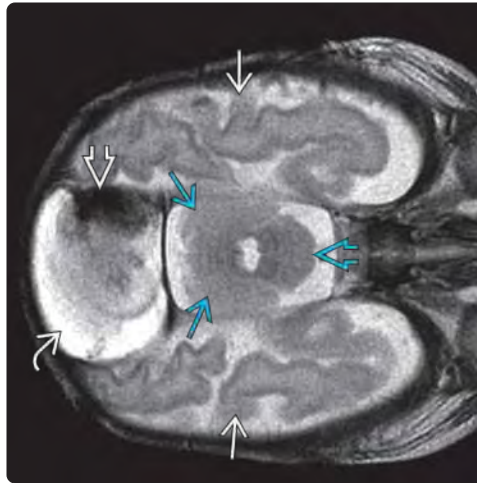


(Left) Sagittal graphic shows cerebellar hypoplasia. The vermian is structurally normal but small. This makes the posterior fossa space seem large. Note the normal torcular position . (Right) Cursors were placed on the cisterna magna to demonstrate anatomy to a student; this is not a standard measurement. The transverse cerebellar diameter at 26 wk should be ~ 30 mm. When the posterior fossa looks "roomy," remember to check if the cerebellum is too small or the cisterna magna is too large.

Dural Sinus Malformation

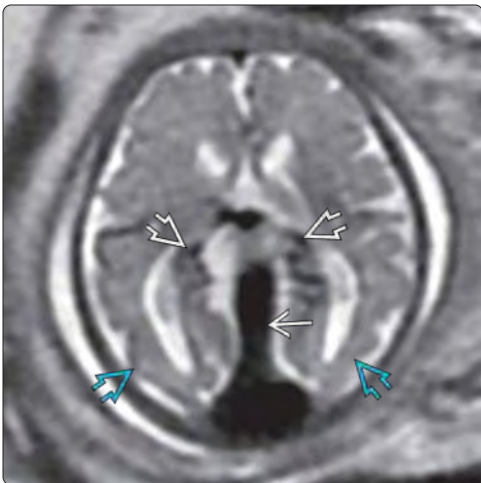


Dural Sinus Malformation

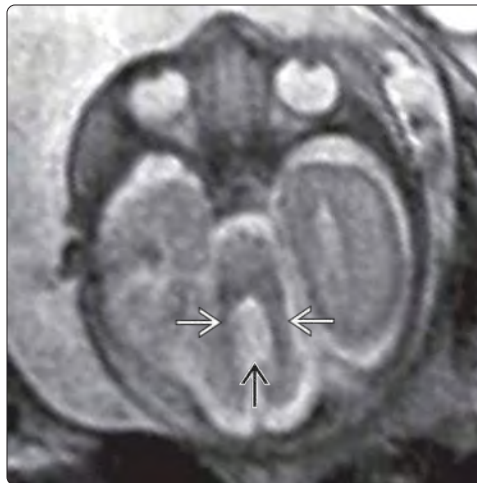


(Left) Third-trimester ultrasound shows the typical appearance of a thrombosed DSM in the conventional ultrasound axial plane. It is a well-circumscribed, extraaxial mass. The brain looked normal in this case, and the infant was developmentally normal on follow-up. (Right) Axial postnatal T2WI in another case with a good outcome shows normal cerebrum , cerebellum , and brainstem with a small retracted clot in a DSM . At 20 weeks, this mass occupied almost 1/2 of the skull volume; it shrank as the brain grew.

Vein of Galen Malformation



Joubert Syndrome

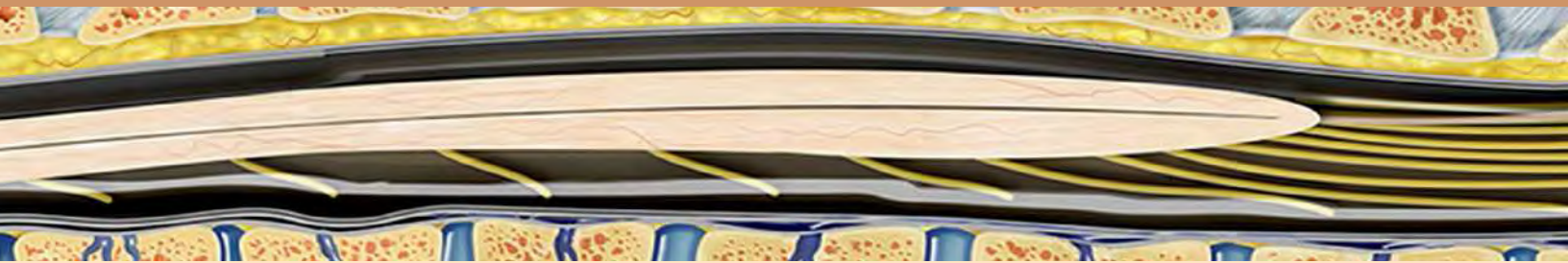

(Left) Axial fetal T2WI MR shows flow voids in the choroidal arteries with an enlarged midline flow void typical of a vein of Galen malformation. The cortex appears abnormal and thinned, particularly in the occipital lobes . (Right) Axial oblique T2WI MR shows the "molar tooth" described in Joubert syndrome, created by the elongated superior cerebellar peduncles on either side of a cleft between the cerebellar hemispheres .

This page intentionally left blank

SECTION 3

Spine



Embryology and Anatomy of the Spine	228
Approach to the Fetal Spine	234
Spina Bifida	236
Iniencephaly	242
Caudal Regression Sequence	244
Kyphosis, Scoliosis	248
Tethered Cord	250
Diastematomyelia	252
Sacroccygeal Teratoma	254

SPINAL CORD DEVELOPMENT

Early Embryologic Events

- 3rd week: Bilaminar germ disc evolves into trilaminar germ disc
- **Trilaminar germ disc**
 - **Ectoderm:** Part of amniotic cavity
 - **Mesoderm: Forms midline hollow central tube (notochordal process)**
 - Extends along long axis of embryonic disc
 - **Endoderm:** Part of yolk sac cavity
- Day 18: Notochord and remainder of intraembryonic mesoderm induce development of neural plate
 - Neural plate grows in length and width until day 21, when neurulation begins
 - Neural plate gives rise to most of central nervous system
- Day 21: **Hollow tube (notochordal process) evolves into solid cord (notochord)**

Neurulation

- **Primary:** Formation of cephalic spine to level of conus
- **Secondary:** Formation of spine caudal to level of conus

Primary Neurulation

- Occurs between days 18-28
 - **Formation of neural tube**
 - **Neural plate** folds and elevates, forming trough (**neural groove**)
 - Fusion of resultant neural folds
 - Before complete fusion, neuroectoderm cells give rise to neural crest cells
 - **Neural crest cells** will later migrate to various parts of body and contribute to variety of tissues
 - Autonomic nervous system, adrenal medulla, tissues of head and neck
 - Neural tube open at both ends temporarily
 - Communicates freely with amniotic fluid
 - Cranial and caudal openings of neural tube are called **neuropores**
- Simultaneously, somites paramedian to notochord differentiate to form sclerotome cells
 - Precursors to vertebral column
- Day 22-23 (4 weeks): **Neural tube closure** begins at occipitocervical level
 - Closure extends bidirectionally
 - **Neural canal:** Hollow center of neural tube later becomes
 - Ventricular system of brain
 - Central canal of spinal cord
- Day 24: Complete **cranial neuropore** closure is achieved
 - Cranial end of neural tube will become brain
- Day 26: **Caudal neuropore** closure
 - Caudal end of neural tube will become spinal cord
- Closed neural tube is required for normal development of neural arch

Dysjunction

- Final phase of primary neurulation
- Neural tube separates from overlying ectoderm
- **Premature dysjunction**

- Perineural mesenchyme can access neural groove and ependymal lining → differentiates into fat
- Prevents complete neural tube closure
- May result in lipomatous malformation spectrum
 - **Intradural lipoma**
 - **Lipomyelomeningocele:** Subcutaneous fatty mass contiguous with neural placode/lipoma through posterior dysraphism
 - Lipomyelomeningocele accounts for 20-56% of occult spinal dysraphism
 - Tethered cord may result
 - Lipomatous malformation prevents normal ascent of cord as vertebral column elongates
- **Nondysjunction**
 - Failure of dysjunction to occur
 - Ectodermal-neuroectodermal tract forms → prevents mesenchymal migration
 - Results in focal or widespread spinal dysraphism and open neural tube defects
 - **Myelomeningocele:** Open neural tube defect with meningocele and neural elements
 - **Myelocystocele:** Enlarged central spinal cord canal (inner cyst) protrudes through osseous dysraphic defect into dilated subarachnoid space (outer cyst)
 - **Dorsal dermal sinus:** Midline/paramedian stratified squamous epithelial-lined sinus tract
- At end of primary neurulation, spine is formed from cephalic end of embryo through level of conus

Secondary Neurulation

- Formation of spine caudal to level of conus
- Days 28-48: Caudal neural tube forms via process referred to as secondary neurulation or canalization
 - Below or distal to posterior neuropore, undifferentiated cells form **primitive streak or caudal cell mass**
 - Once caudal neuropore closes, neural tissue is laid down as neural cord
 - Rostral neural tube extends into caudal eminence
 - **Caudal cell mass** forms vacuoles that fuse to form distal neural tube
 - Day 48: Transient ventriculus terminalis appears in future conus
 - These cells eventually form **conus medullaris, cauda equina, and filum terminale**
- Terminal cord undergoes retrogressive differentiation
 - Occurs over ensuing gestational period and into early postnatal period
- **Secondary neurulation is less precise and leads to wide range of malformations**
 - **Tethered cord**
 - Most common lesion in caudal cell mass dysplasia spectrum
 - Low-lying cord with thickened filum terminale
 - **Caudal regression**
 - **Type 1:** Foreshortened terminal vertebral column with high conus termination; severe associated anomalies
 - **Type 2:** Low-lying tethered cord with milder associated anomalies
 - Associated anomalies: Renal hypoplasia, pulmonary hypoplasia, anorectal malformations

- Associated spinal anomalies: Open dysraphism, segmentation and fusion anomalies, split cord malformations
- **Terminal myelocystocele**
 - Hydromyelic cord terminating in skin-covered myelocystocele
 - Anorectal and visceral anomalies result in high morbidity
- **Anterior sacral meningocele**
 - Large meningocele traversing enlarged sacral foramen produces presacral cystic mass
- **Sacroccoccygeal teratoma**
 - Primitive streak incompletely regresses and leaves caudal remnant
 - Occurs due to residual totipotent cell rests (Hensen node) → 3 cell layers with varying proportions of mature and immature elements
- **Spinal cord ascent**
 - At 12-weeks gestational age, spinal cord extends entire length of developing spinal column
 - **Vertebral column and dura** elongate disproportionately compared to spinal cord
 - **Conus medullaris ascends** relative to vertebrae; filum terminale elongates
 - **Nerve roots** exit at levels of their respective foramen
 - Nerve roots then grow longer to accommodate this relative ascension of spinal cord
 - Forms **cauda equina** (sheath of nerve roots inferior to conus)
- Conus should be at or above L3-L4 after 18-weeks gestation
 - This process extends into postnatal period
 - By 2 months of age, conus is located at adult level
 - Final position is near L1-L2 interspace
 - Conus below L2 after 1st month of life, in term infant, is probably abnormal
 - Needs evaluation for tethered cord

VERTEBRAL BODY DEVELOPMENT

Cartilaginous Stage

- Week 4: **Notochord** induces surrounding paraxial mesoderm derived from primitive streak
 - Forms paired somite blocks: Myotomes and sclerotomes
 - **Myotomes** form paraspinal muscles and skin covering
 - **Sclerotomes** divide into medial and lateral formations
 - **Form vertebral body, intervertebral disc, meninges, spinal ligaments (medial), and posterior spinal elements (lateral)**
 - Migrate from somites and surround adjacent neural tube and notochord
 - Ventral portion of sclerotome surrounds notochord and forms rudiment of vertebral body
 - Dorsal portion of sclerotome surrounds neural tube, forms precursors to neural arch, and condenses to produce spinous processes
 - Notochord will degenerate and involute where it is surrounded by vertebral body
 - **Notochordal remnant** between vertebra expands to form **nucleus pulposus** of intervertebral discs

- **Failure of notochord induction** leads to incomplete division of neural plate → **neurenteric cyst or diastematomyelia**
- Week 6: Cartilaginous stage of vertebral development occurs when chondrification centers appear
 - **Chondrification centers** appear in each mesenchymal vertebral body
 - 2 centers in each mesenchymal vertebral body fuse at end of embryonic period
 - Forms cartilaginous **centrum**
 - At the same time, centers of **vertebral arches fuse** with each other and with centrum of vertebral body
 - Spinous and transverse processes develop from extensions of chondrification centers of vertebral arch

Ossification Stage

- Vertebral ossification begins during embryonic period and ends by age 25
- Vertebral body centrum forms from fusion of ventral and dorsal primary ossification center
- At end of embryonic period, there are **3 primary ossification centers** for each vertebrae including
 - **Centrum**
 - **Each 1/2 of vertebral arch**
- Week 8: Ossification is visible
 - **Ossification begins in lower thoracic and upper lumbar regions**
 - Ossification progresses both cranial and caudal
- Week 13: Three ossification centers present in vertebrae C1-L3
- At birth, each vertebra consists of 3 bony parts connected by cartilage

Anomalies of Vertebral Formation and Segmentation

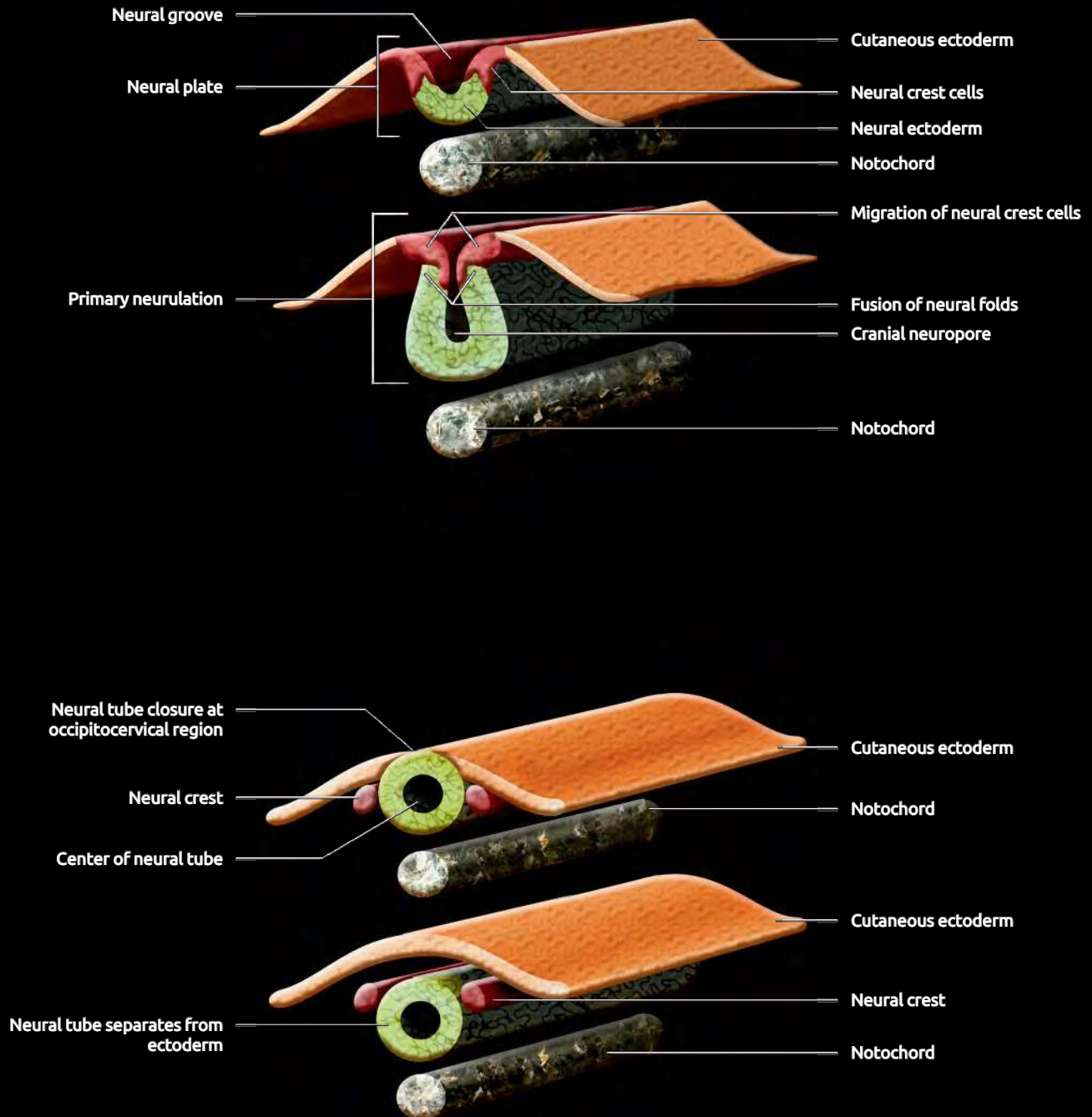
- Abnormal vertebrae may replace normal vertebrae or be supernumerary
- **Failure of vertebral formation** (total or partial)
 - Degree and location of vertebral formation failure predicts morphology
 - Unilateral chondral center defect and failure of ossification → **hemivertebrae**
- **Failure of vertebral segmentation**
 - **Block vertebrae** with posterior elements fusion
- More severe segmentation and fusion defect → increased incidence of concurrent malformations
 - Neuraxis anomalies: Tethered cord, abnormal alignment (kyphosis, scoliosis), dysraphism
 - Visceral organ anomalies

FAILURE OF NEURAL TUBE CLOSURE

Clinical Implications

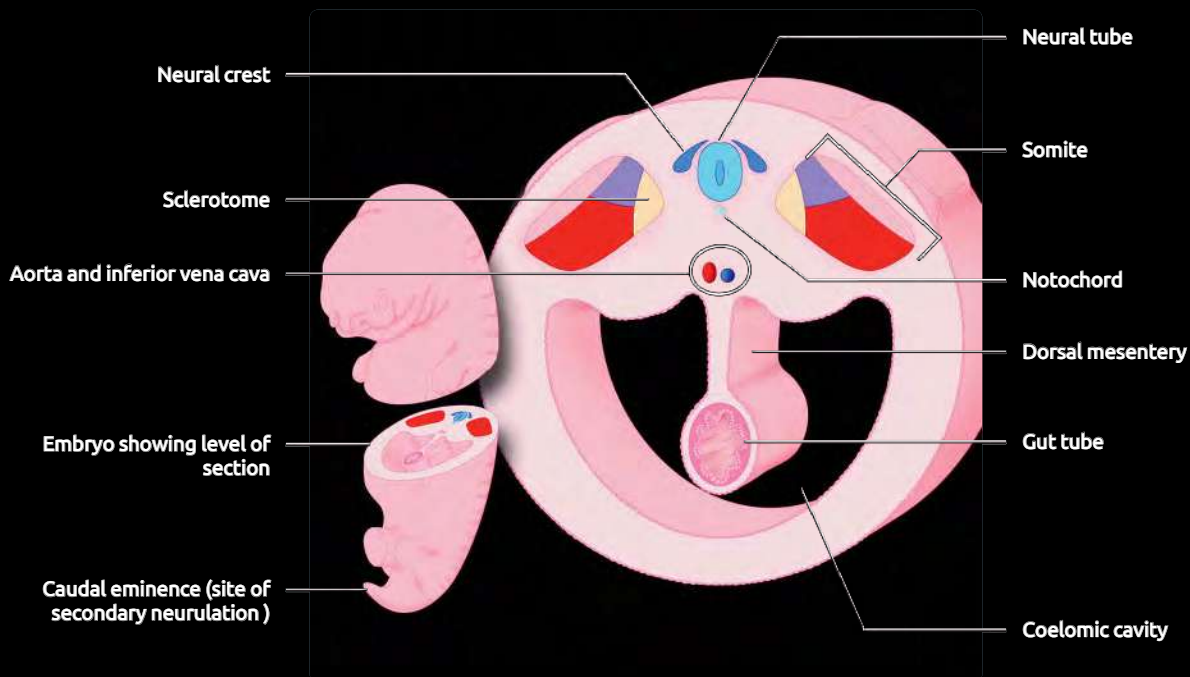
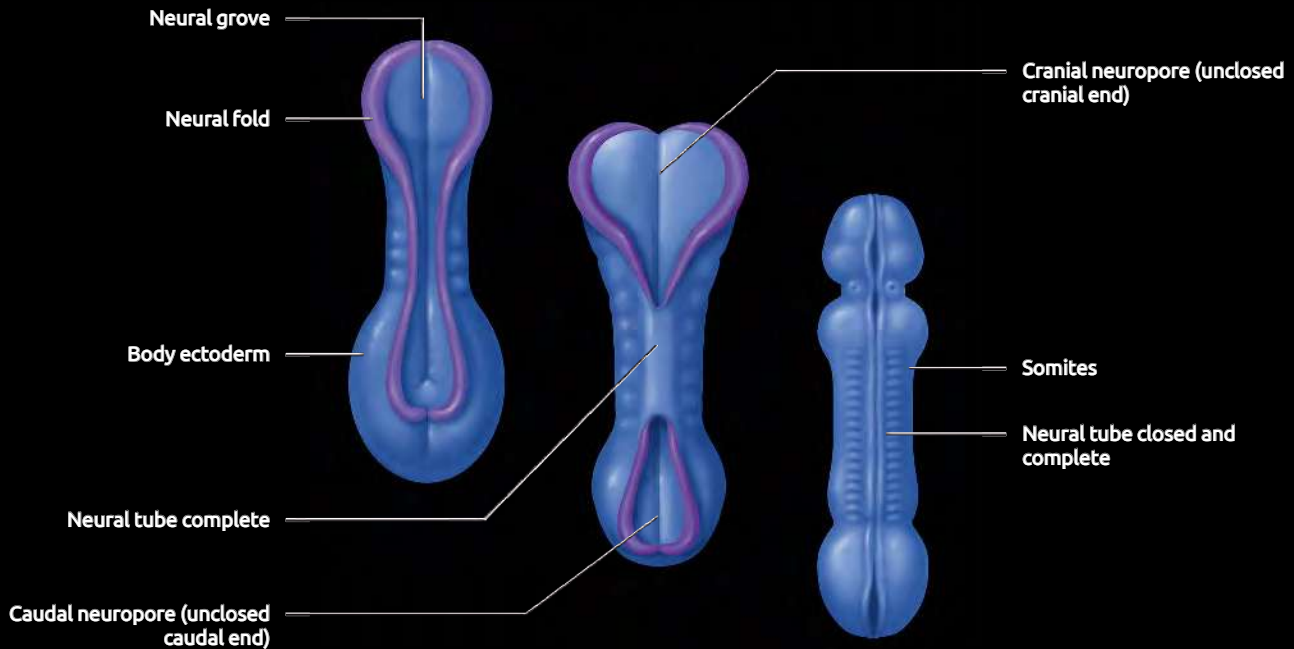
- Failure of any part of neural tube to close disrupts development of nervous system and disrupts induction of overlying vertebral arches
- Timing of event is such that other systems are also impacted
 - Look for associated visceral and anorectal malformations
- Look for consequences of abnormal innervation
 - Abnormal lower extremity positioning

NEURAL TUBE EMBRYOLOGY



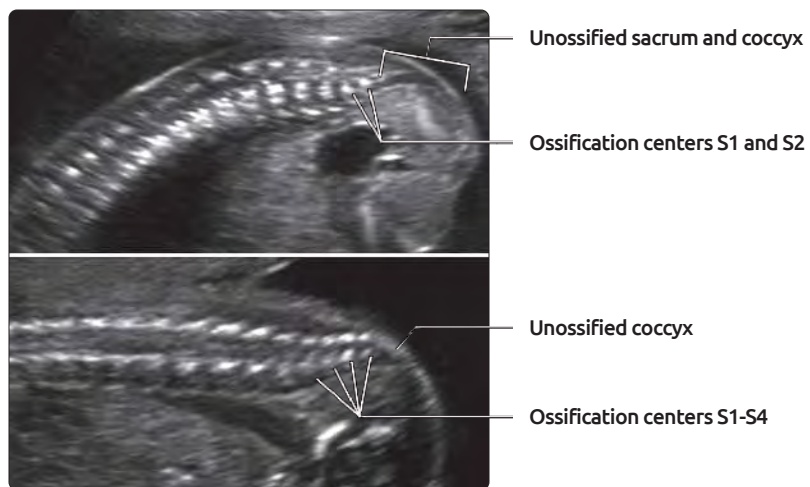
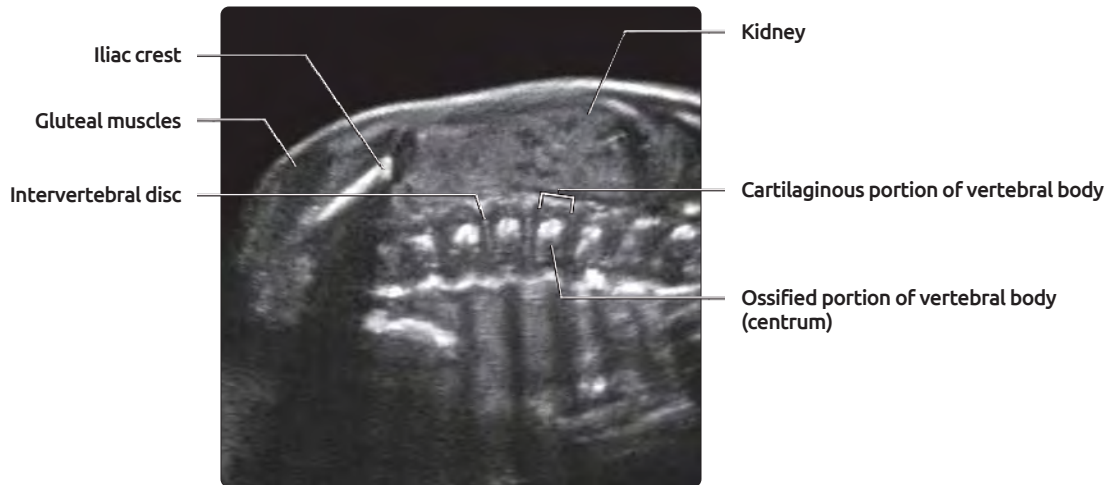
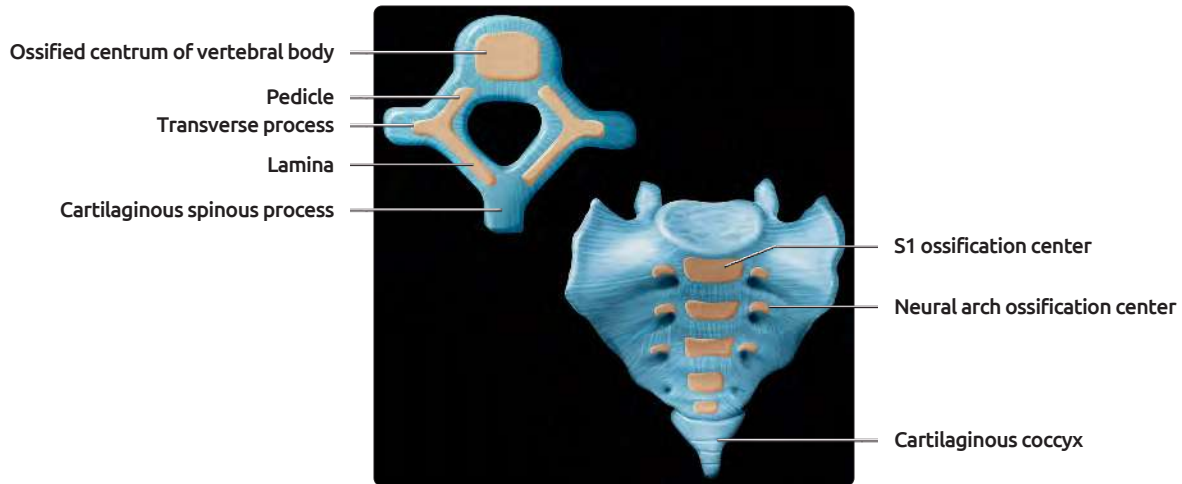
(Top) On day 18, the notochord and intraembryonic mesoderm induce development of the neural plate. The neural plate will grow in length and width until day 21, when primary neurulation begins. The neural plate folds and resultant neural folds fuse. **(Bottom)** Neural tube closure begins at 4 weeks at the occipitocervical region. The hollow center of the neural tube will become the central canal of the spinal cord and ventricular system of the brain. During primary neurulation, the neural tube separates from the overlying ectoderm in a process called dysjunction. Early dysjunction results in perineural mesenchyme access to the neural groove, which differentiates into fat (intradural lipoma); it may also prevent closure of the neural tube (lipomyelomeningocele). If dysjunction fails to occur, a spectrum of open neural defects results.

NEURAL TUBE EMBRYOLOGY



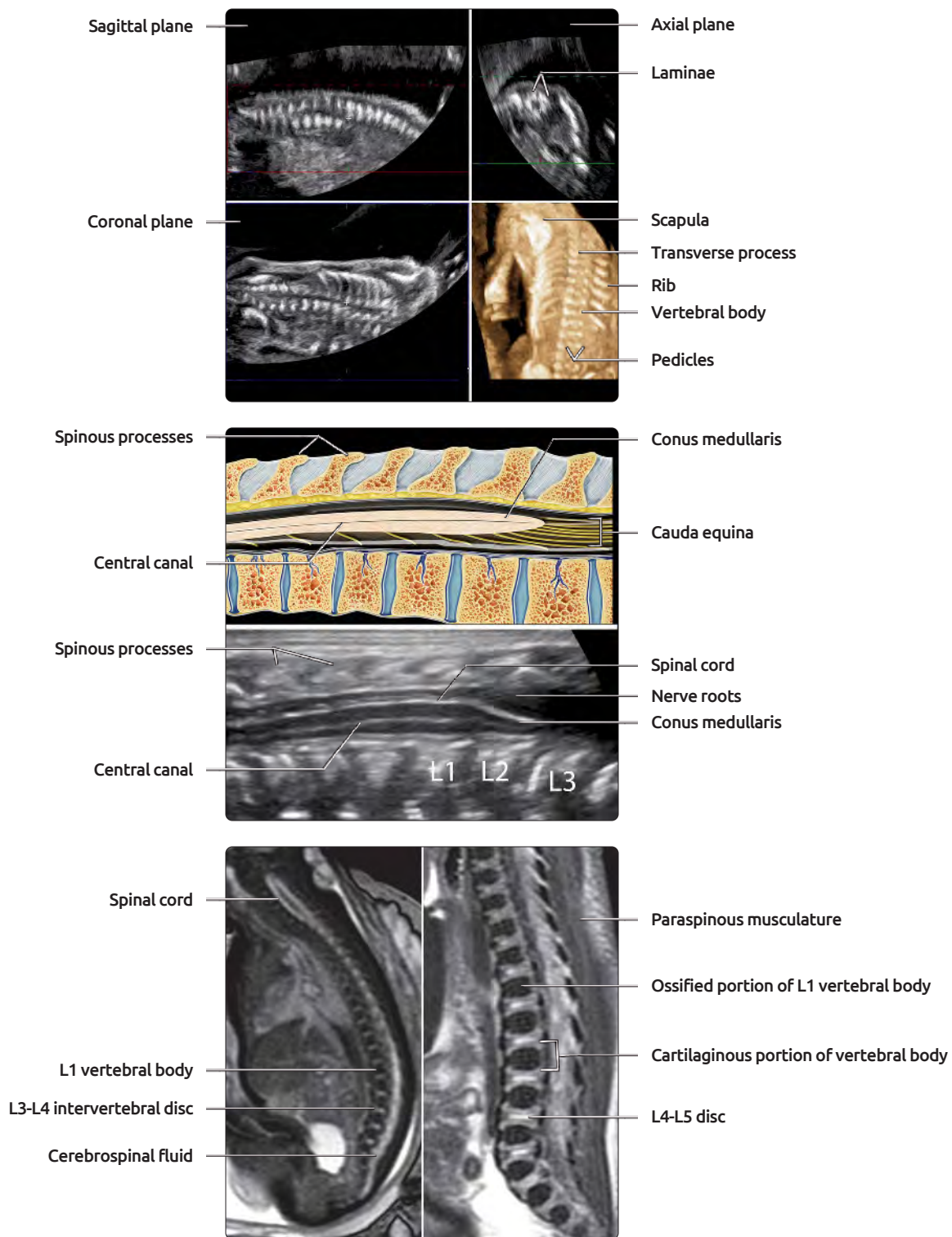
(Top) Graphic of neural tube closure as viewed from above is shown. At either end, there is an opening, the cranial and caudal neuropore, which are open to the amniotic fluid at this stage. The cranial neuropore closes by day 24 and will become the brain. The caudal end closes by day 26. **(Bottom)** Cross section of an embryo shows the neural tube, which has formed dorsal to the notochord. The neural tube will form the spinal cord, while the notochord largely degenerates with remnants contributing to the intervertebral discs. Neural crest cells migrate throughout the body and give rise to diverse tissues, including ganglia of the autonomic nervous system, adrenal medulla, and tissues of the head and neck. Somites form from the mesoderm and form multiple tissues. The medial somite is the sclerotome, which will form the vertebral column. Secondary neurulation begins at the caudal eminence and forms the conus medullaris, cauda equina, and filum terminale of the spinal cord.

FETAL SPINE



(Top) Axial graphic shows the normal ossification centers within the developing vertebrae. The vertebral body and neural arch primary ossification centers (beige) are forming within the cartilaginous (blue) vertebral axis. Coronal graphic illustrates the normal appearance of the sacral ossification centers and cartilage. The sacrum and coccyx are the last portions of the vertebral column to ossify. **(Middle)** Coronal ultrasound of the lumbar spine at 22 weeks shows the ossification center (centrum) within the vertebral body; the remainder of the vertebral body is cartilaginous. **(Bottom)** Sagittal transabdominal ultrasound at 19.5 weeks (top) shows normal ossification and alignment of the lumbar spine. The coccyx and sacrum are unossified, which is an expected finding. At 22 weeks (bottom), there has been more complete ossification. Ossification should be complete by 25 weeks.

FETAL SPINE



(Top) 3D ultrasound is ideal for evaluating the spine as all 3 planes can be evaluated with 1 acquisition. A 3D bone algorithm renders a skeletal view. **(Middle)** Sagittal graphic shows the normal appearance of the lumbar spinal column, conus medullaris, cauda equina, and central spinal canal. A correlative sagittal ultrasound of a fetal spine shows the normal hypoechoic appearance of the cord with a hyperechoic central canal. The lumbar portion of the spinal cord widens slightly compared to the thoracic portion. The normal cord ascends during gestation and should be at or above L3-L4 after 18 weeks and L1-L2 by 2 months of age. **(Bottom)** Sagittal T2 fetal MR (left) and newborn (right) shows the neural axis. The ossified portion of the vertebral bodies is hypointense with hyperintense intervertebral discs. The spinal cord is surrounded by high signal CSF. MR is an excellent tool for evaluating spinal dysraphism or cord abnormalities suspected on ultrasound.

Imaging Techniques and Normal Anatomy

Ultrasound

The American Institute of Ultrasound in Medicine requires documentation of the fetal cervical, thoracic, and lumbar spine. This should be done in both axial and longitudinal planes (coronal &/or sagittal depending on fetal position). Due to fetal movement and position, it is often difficult to image the entire spine in a single image. Therefore, multiple images are often required for complete documentation, and the importance of real-time evaluation of each vertebral body cannot be overemphasized.

At 16 weeks, vertebral ossification is first visualized. Prior to 19 weeks, distal ossification is incomplete and may falsely suggest a neural tube defect. At 20-24 weeks, the entire bony spine can be imaged on standard views. In the third trimester, more detailed bony anatomy of the spine can be visualized, including the pedicles, laminae, transverse processes, and spinous processes.

On the **axial** view in the second trimester, three ossification centers can be seen: Two lateral masses and a central vertebral body. The lateral mass is composed of the transverse process, spinous process, and articular process. The three ossification centers form a triangle, with the lateral masses forming a V-shaped "tent" over the spinal canal. The entire length of the spine should be scanned in the transverse plane ensuring the spinal cord is completely enclosed by this triangle. Splaying or divergence of the posterior elements is an important finding in the diagnosis of neural tube defects.

When imaging in the **sagittal** plane, the spine is seen as two parallel curvilinear echogenic lines (vertebral body and posterior elements). Although there is variation with position, there should be three gentle curves: Cervical lordosis, thoracic kyphosis, and lumbar lordosis. Variations of these normal curves warrant further evaluation for an underlying abnormality.

Coronal imaging is useful for evaluation of vertebral body anomalies and scoliosis. The normal ultrasound appearance of the posterior elements in the coronal plane is paired echogenic lines, which are flared in the cervical spine at the craniocervical junction and widen slightly in the lumbar spine.

MR

The strength of MR is in evaluating the spinal cord, and it is now part of the standard evaluation if fetal surgery is being considered for a neural tube defect. MR should also be performed whenever there is a concern regarding spinal cord position (e.g., tethered cord), appearance (e.g., diastematomyelia), or possible mass (e.g., lipoma).

Approach to Abnormal Fetal Spine

Complete evaluation of the spine is an essential part of every second and third-trimester fetal scan. Fetal movement, positioning, and shadowing of the vertebral bodies can make imaging challenging. Establishing a search pattern and checklist for evaluation of the spine will ensure accurate diagnosis. Real-time evaluation of the entire length of the spine in both the longitudinal and axial planes will complete the evaluation.

Is Spinal Alignment Normal?

Ideally, alignment should be evaluated in both the coronal and sagittal planes, but this is often not possible. Abnormalities of spinal alignment may be transient or fixed; therefore, it is

important to evaluate the spinal position over time. If fixed, search should begin for a spinal abnormality.

The coronal plane is the best to evaluate for scoliosis. The sagittal plane is best for kyphosis. Both scoliosis and kyphosis can occur due to vertebral body anomalies. When alignment is abnormal, careful investigation for hemivertebrae, block vertebrae, and butterfly vertebrae, as well as spinal dysraphism, should be performed. The relative size of the vertebral bodies should also be assessed to look for conditions such as platyspondyly.

Are Appropriate Number of Vertebral Bodies Present?

Counting the number of vertebral bodies, particularly in the lumbar region, is essential to ensure the distal spine is properly formed. In caudal regression syndrome, there is variable absence of the lower lumbar spine. Additionally, imaging in the axial plane is essential to ensure that all the vertebral bodies are properly formed, including the presence of the posterior elements.

Are Overlying Soft Tissues Intact?

It is important to visualize the soft tissues covering the entire spine. Amniotic fluid should be visualized between the spine and the uterine wall to ensure the overlying skin is intact. Although an open spinal defect is more common in the lumbar spine, it may affect both the cervical and thoracic spine.

Is There Paraspinous Mass?

When a paraspinous mass is present, it is important to determine the origin. Cystic posterior masses may indicate a meningocele (meninges and cerebrospinal fluid only), myelomeningocele (also contains neural elements), or terminal myelocystocele (dilation of the spinal cord central canal, which herniates through a spinal defect). Solid masses include a cord lipoma or a sacrococcygeal teratoma, which can invade into the spinal canal.

Are Brain and Posterior Fossa Normal?

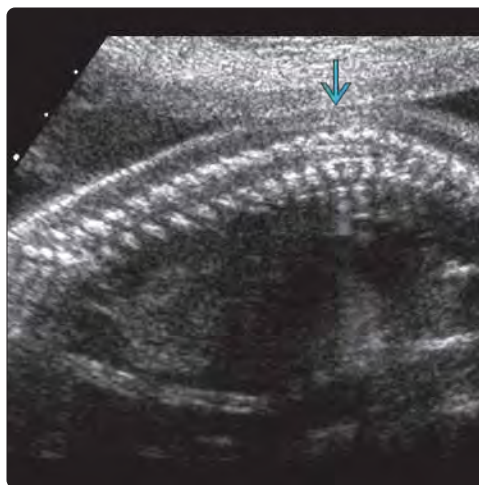
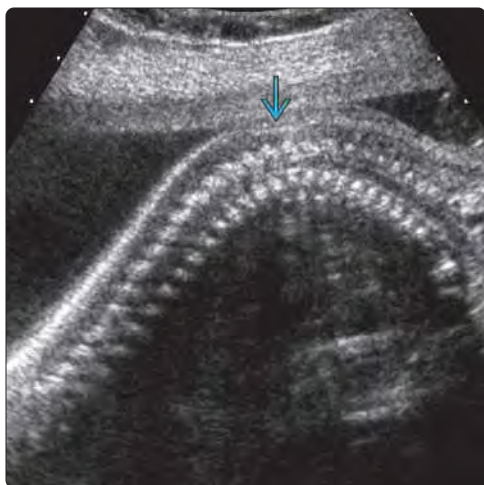
If the brain or posterior fossa is abnormal, it is imperative to evaluate the spine for associated abnormality. Nearly 100% of Chiari 2 malformations of the brain are in association with spina bifida. While most will have a protruding sac, myeloschisis is an open defect without a covering and can be easily missed if a thorough evaluation of the distal spine is not performed. If evaluation of the distal spine is difficult in a patient with Chiari 2, an MR is indicated.

Are Other Anomalies Present?

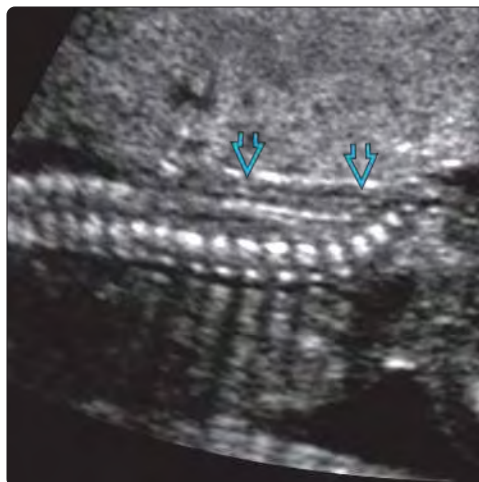
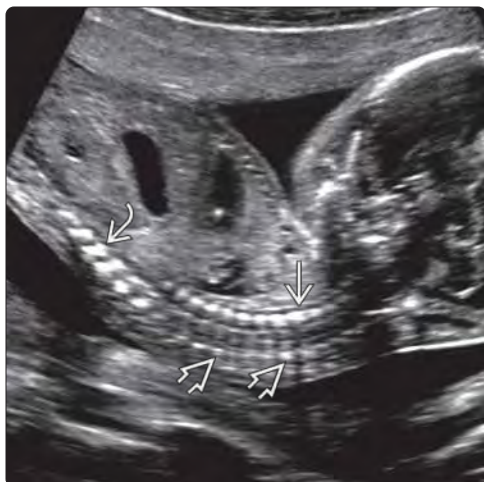Vertebral body anomalies are a feature of the VACTERL (vertebral anomalies, **a**nal atresia, **c**ardiac anomalies, **t**racheoesophageal fistula, **e**sophageal atresia, **r**enal anomalies, **l**imb defects) association. Therefore, when there is abnormal alignment or a vertebral body anomaly, it is necessary to have a high index of suspicion for additional abnormalities.

Where Is Conus Medullaris Located?

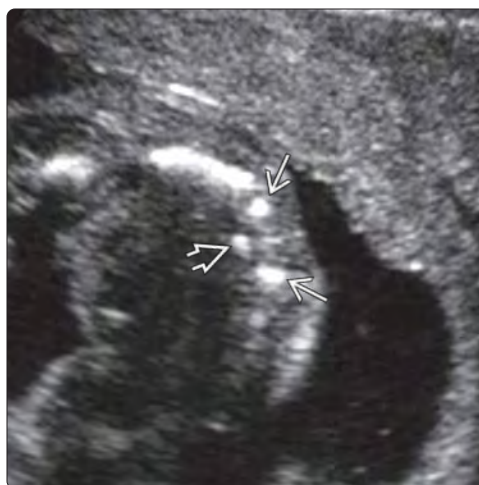
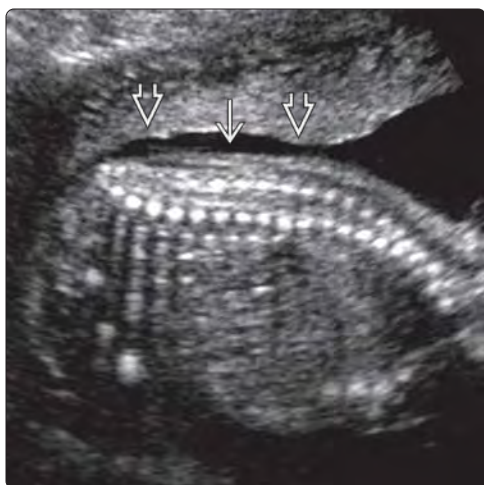
The position of the conus varies with gestational age. By 18 weeks, the conus should be superior to L3-L4, with progressive ascent to above L2-L3 by term. A tethered cord is seen with neural tube defects (both open and closed), VACTERL association, and kyphosis/scoliosis.



(Left) Sagittal transabdominal ultrasound shows dramatic kyphosis of the cervicothoracic spine. No definite vertebral anomalies were identified. Additional imaging of the spine is indicated to determine if this curvature is fixed in position. **(Right)** The same fetus a few minutes later shows normal alignment of the spine. Transient abnormal positional curvature can be a pitfall in fetal spine imaging.



(Left) This longitudinal ultrasound illustrates the difficulty of imaging the entire spine in a single plane. Vertebral bodies and posterior elements are seen in the cervical/thoracic spine, but the alignment is "twisted" with lateral masses seen in the lumbar spine. **(Right)** Sagittal ultrasound shows a normal-appearing lumbar and sacral spine. However, due to juxtaposition of the spine to the uterine wall, the distal spine and overlying skin cannot be cleared. Subtle dysraphism may be missed.



(Left) Sagittal ultrasound shows the apparently normal appearance of the spine. Amniotic fluid is seen between the myometrium and the spine. Imaging in 1 plane is not sufficient, and the entire spine should be assessed in the axial plane to rule out spinal dysraphism. **(Right)** An axial ultrasound in the same patient shows splaying, or divergence, of the posterior elements relative to the vertebral body. This fetus has myeloschisis, confirming the importance of imaging the spine in 2 planes.

KEY FACTS

TERMINOLOGY

- Open spina bifida: Without skin coverage (most common)
- Closed spina bifida: With skin coverage

IMAGING

- Myelomeningocele sac + Chiari 2
 - Most common presentation
 - Look carefully at spine if cisterna magna compressed
- Lumbar > sacral > thoracic > cervical
- Transverse view best for seeing bony defect
- Sagittal view best for seeing sac
 - Meningocele: Anechoic cystic mass
 - Myelomeningocele: Complex cystic mass
 - Lipomeningomyelocele: Spine defect + lipoma
- Coronal view best for evaluating extent of defect
- 20% of open spina bifida without sac
 - Myeloschisis: Spinal cord is part of defect
- Tethered spinal cord almost always present

TOP DIFFERENTIAL DIAGNOSES






- Sacrococcygeal teratoma
- Isolated scoliosis/kyphosis
- Body stalk anomaly (limb-body-wall)

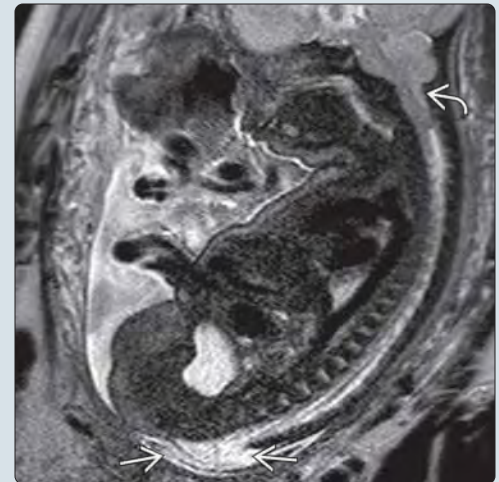
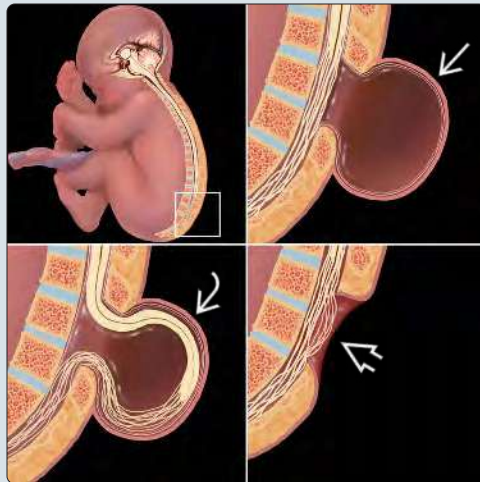
PATHOLOGY






- Mostly sporadic and multifactorial
- 4% aneuploidy rate when isolated

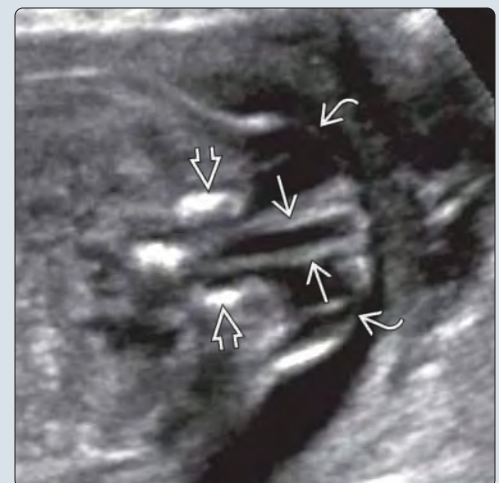
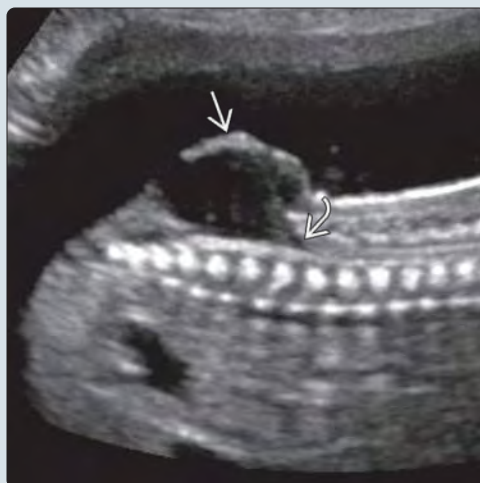
CLINICAL ISSUES

- Maternal issues
 - ↑ maternal serum α-fetoprotein
 - Most deliver by cesarean section
 - Clinical trials for fetal surgery ongoing
- Prognosis for child
 - 80% require ventricular shunting
 - Musculoskeletal dysfunction common
 - Gastrointestinal/genitourinary dysfunction
 - Only 17% with normal continence

(Left) Graphic shows spina bifida classification. Meningocele  contain only cerebrospinal fluid, while myelomeningocele  also contain neural elements. The neural tube defect is uncovered (no sac) in myeloschisis  and contains the spinal cord or nerve roots. **(Right)** In this fetus with a lumbosacral myelomeningocele , the cerebellar vermis has herniated through the foramen magnum . Classic Chiari 2 hindbrain compression findings are almost always present with open spina bifida.



(Left) In this fetus, at the time of midgestation anatomy scan, the sagittal view of the lumbosacral spine shows a cystic mass , which communicates with the spinal canal . **(Right)** Axial view of the lumbar spine in the same fetus shows neural elements  extending through splayed dorsal spine ossification centers (arches)  and into the myelomeningocele sac .



TERMINOLOGY**Synonyms**

- Spinal dysraphism
- Neural tube defect (open or closed)

Definitions

- Bony vertebral defect + neural content exposure
 - Open spina bifida: Without skin coverage (most common)
 - Closed spina bifida: With skin coverage

IMAGING**General Features**

- Best diagnostic clue
 - Myelomeningocele sac + Chiari 2 findings in brain
 - Almost all with tethered spinal cord
- Location
 - 73% lumbar > 17% sacral > 9% thoracic > 1% cervical

Ultrasonographic Findings

- **Vertebral findings**
 - Splayed dorsal ossification centers
 - Transverse view best for seeing bony defect
 - V-shaped vertebrae on axial view ± skin defect
 - Coronal view best for evaluating extent of defect
 - Multiple levels usually involved
 - Use ribs to identify 12th thoracic level
 - Sagittal view best for seeing sac
- **Defect findings**
 - 80% with overlying sac
 - Meningocele (anechoic sac)
 - ◻ Sac contains meninges only
 - ◻ Rarely covered by intact skin
 - Myelomeningocele (complex cystic sac)
 - ◻ Sac contains meninges + neural elements
 - 20% with no overlying sac
 - Myeloschisis (sometimes referred to as myelocele/myeloschisis)
 - ◻ Open spinal cord is part of defect
 - Closed spina bifida (often without Chiari 2)
 - Lipomyelomeningocele and lipomeningocele
 - ◻ Spine defect + canal lipoma
 - ◻ Associated tethered cord
 - Spina bifida occulta rarely seen in utero
 - ◻ Small bony defect covered by skin
 - ◻ Overlying subcutaneous lipoma, tuft of hair, skin dimple
 - ◻ ± tethered cord
- **Brain findings**
 - 99% of open spina bifida with Chiari 2 malformation
 - Cisterna magna effacement (most common finding)
 - Cerebellar compression
 - ◻ Banana sign: Cerebellum curved around midbrain
 - Progressive ventriculomegaly
 - ◻ Atrial width ≥ 10 mm
 - ◻ 55% at time of diagnosis
 - ◻ 90% at birth
 - Frontal bone concavity (lemon-shaped skull)
 - ◻ Transient nonspecific finding

- ◻ Seen in 1% of normal fetuses
- Other midline brain defects
 - ◻ Dysgenesis of corpus callosum most common
- Common associated anomalies
 - Scoliosis/kyphosis at level of defect
 - Lower extremity anomalies
 - 24% have clubfoot/feet
 - Rocker-bottom foot
 - Hip dislocation
 - 40% with additional anomalies
 - 67% of those with aneuploidy have other anomalies
- Ventral spina bifida is extremely rare
 - Splitting of vertebral body
 - Typically lower cervical or upper thoracic
 - Associated neurenteric cyst

MR Findings

- Identify additional brain anomalies associated with Chiari 2
- Often shows tethered spinal cord best
- Helpful if ultrasound visualization poor
 - Not for primary diagnosis
- Required before fetal surgery consideration

Imaging Recommendations

- Best imaging tool
 - Anatomy scan detects almost 100% of open spina bifida
 - Cranial Chiari 2 findings are most obvious
- Protocol advice
 - Look carefully at spine when cisterna magna is small or compressed
 - Serial surveillance scans important
 - Ventriculomegaly often progressive
 - Clubfoot may develop later
 - Look for tethered spinal cord
 - Conus above L3 in normal fetuses
 - 3D US for multiplanar imaging helps identify level of defect
 - Offer genetic amniocentesis for all cases

DIFFERENTIAL DIAGNOSIS**Sacroccygeal Teratoma**

- Complex exophytic mass from sacrum
 - Internal extension common
- No associated Chiari 2 malformation

Isolated Scoliosis/Kyphosis

- Abnormal curvature of spine
- Usually from anterior vertebral body anomaly
 - Hemivertebrae, fused vertebrae

Body Stalk Anomaly (Limb-Body-Wall)

- Entrapment of fetal parts by disrupted amnion
- Associated severe scoliosis almost always seen

PATHOLOGY**General Features**

- Etiology
 - Primary failure of neural tube or mesenchymal closure
 - Secondary destruction of exposed neural tissue
 - ◻ In utero trauma and amniotic fluid exposure

- Genetic and micronutrient etiologies suggested
- Folate deficiency
 - Folate metabolic pathway gene defect
- Teratogens
 - Anticonvulsants: Carbamazepine, valproic acid
 - 1% risk
- Arrhaphia theory
 - Primary failure of neuropore closure
 - Absent skin/muscle from failed induction
- Hydromyelic theory
 - Cerebrospinal fluid (CSF) imbalance
 - Excess CSF accumulates in closed neural tube
 - Secondary separation of dorsal wall
- Genetics
 - 4% aneuploidy rate when isolated
 - 14% aneuploidy rate when other findings also present
 - Trisomy 18, trisomy 13, triploidy

CLINICAL ISSUES

Presentation

- Most common signs/symptoms
 - ↑ maternal serum α-fetoprotein
 - > 2.5 multiples of median detects 80%
 - Incidentally seen at time of anatomy scan

Demographics

- Age
 - Advanced maternal age at slightly higher risk
- Ethnicity
 - United States data
 - Hispanic > Caucasian > African American > Asian
 - Difference persists after immigration
 - Highest rates in United Kingdom
 - Lowest rates in Japan
- Epidemiology
 - 1:3000 live births
 - Stabilized prevalence since folate supplementation impact
 - 25-40% termination rate when diagnosed in utero
 - 3% of all spontaneous abortions
 - 1-2% recurrence risk

Natural History & Prognosis

- Depends on level and severity of defect
 - 14-35% liveborn die in 1st 5 years
 - 70% with IQ > 80
 - 50% able to live independently as adults
 - Incidence of seizures, bladder dysfunction, and inability to walk increase with hindbrain herniation
 - Nearly 100% for C4 level hindbrain herniation
 - MR findings of worsening hindbrain herniation correlate with clinical outcomes
- Obstructive hydrocephalus from Chiari 2 hindbrain compression
 - 80% require ventricular shunting
 - 46% have shunt complication in 1st year of placement
 - Shunts associated with independent morbidity (e.g., blockage, infection)
- Musculoskeletal dysfunction
 - 25% complete lower limb dysfunction

- Gastrointestinal/genitourinary dysfunction
 - Only 17% with normal continence

Treatment

- Delivery at term or near term
 - Mostly by cesarean delivery
 - ↓ trauma to neural elements
 - ↓ sac rupture/infection rates reported
 - Better neurologic outcomes > 2 years of age reported
 - Delivery route controversial due to lack of prospective blinded trials
- Immediate postnatal surgery
 - Cover exposed spinal cord
 - Treat obstructive ventriculomegaly
- In utero surgery in clinical trials
 - Only fetal surgery currently offered for nonlethal anomaly
 - Justification for surgery based on "2-hit" hypothesis
 - 1st "hit" is original defect
 - 2nd "hit" is additional injury of exposed neural element during gestation
 - Surgery aimed at reducing 2nd "hit" and improving function
 - Currently paralysis and incontinence rates unchanged
 - May reverse hindbrain herniation and ↓ shunt dependence (54% vs. 80%)
- Preventive treatment with folic acid
 - Preconceptual therapy best
 - 4 mg/d reduces risk of recurrent neural tube defect by 70%
 - 0.4 mg/d for all women

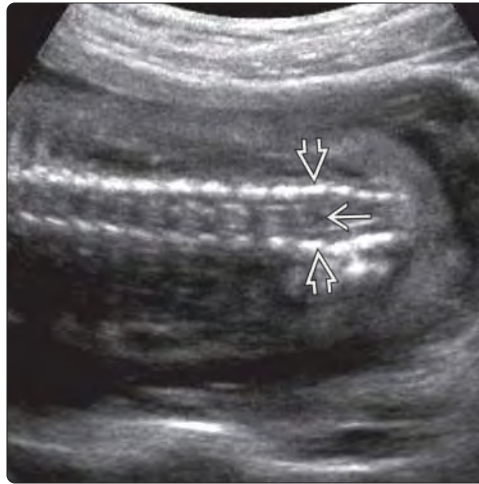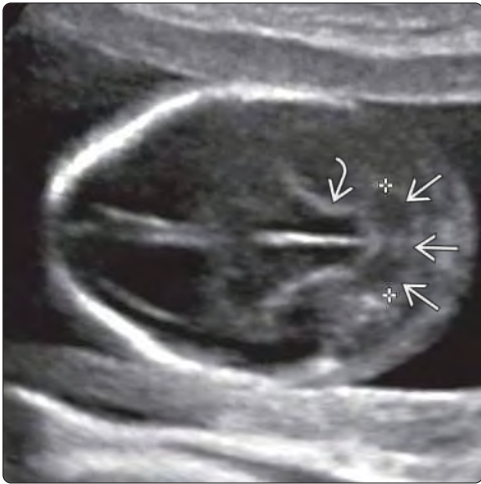
DIAGNOSTIC CHECKLIST





Image Interpretation Pearls

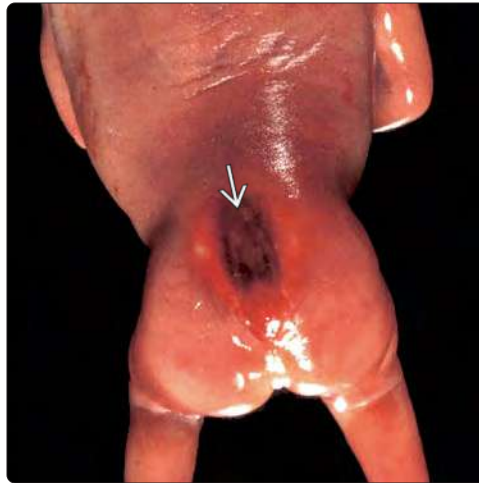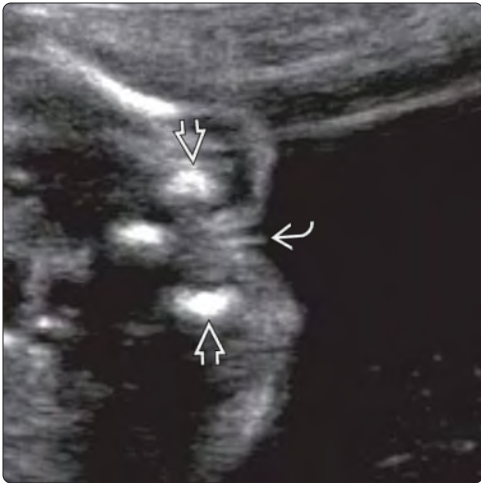
- Presence of normal cisterna magna nearly eliminates diagnosis of open spina bifida
 - Not closed spina bifida
- Chiari 2 malformation often easier to see than spine defect
- Attempt to identify most superior level of defect
 - Look for T12 by identifying lowest rib
 - Look for angled vertebral body of S1 on sagittal view
 - 3D ultrasound helpful
- Consider MR to look for additional brain anomalies




SELECTED REFERENCES

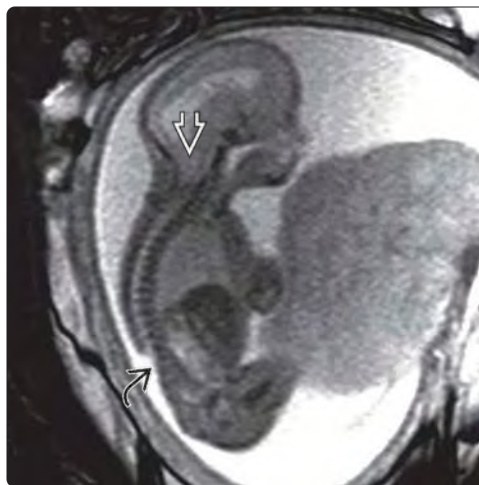
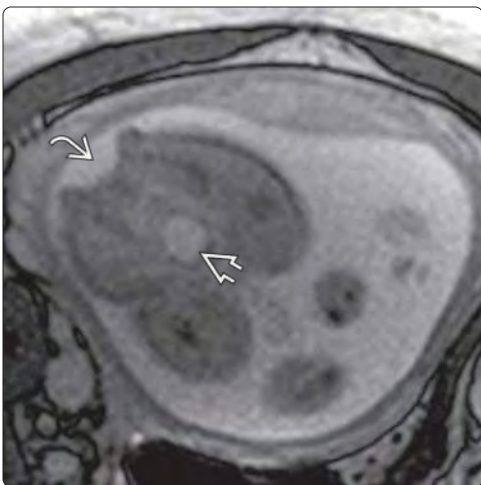
1. Khalil A et al: Prenatal prediction of need for ventriculoperitoneal shunt in open spina bifida. *Ultrasound Obstet Gynecol.* 43(2):159-64, 2014
2. Adzick NS: Fetal surgery for spina bifida: past, present, future. *Semin Pediatr Surg.* 22(1):10-7, 2013
3. Mangione R et al: Screening for fetal spina bifida at the 11-13-week scan using three anatomical features of the posterior brain. *Ultrasound Obstet Gynecol.* 42(4):416-20, 2013
4. Agopian AJ et al: Spina bifida subtypes and sub-phenotypes by maternal race/ethnicity in the National Birth Defects Prevention Study. *Am J Med Genet A.* 158A(1):109-15, 2012
5. Adzick NS: Fetal myelomeningocele: natural history, pathophysiology, and in-utero intervention. *Semin Fetal Neonatal Med.* 15(1):9-14, 2010
6. Bulas D: Fetal evaluation of spine dysraphism. *Pediatr Radiol.* 40(6):1029-37, 2010
7. Chao TT et al: Central nervous system findings on fetal magnetic resonance imaging and outcomes in children with spina bifida. *Obstet Gynecol.* 116(2 Pt 1):323-9, 2010







(Left) In this 18-week fetus, an axial view through the posterior fossa shows hindbrain compression. The cerebellum (calipers and ) wraps around the midbrain , taking on the typical banana shape described with Chiari 2 malformation. (Right) Coronal view through the spine, in the same patient, shows subtle divergence of the lower lumbar spine  and the tethered spinal cord extending into the sacrum . In this case, there was no sac and the spine findings are subtle. The cerebellar compression is the best clue for spina bifida.

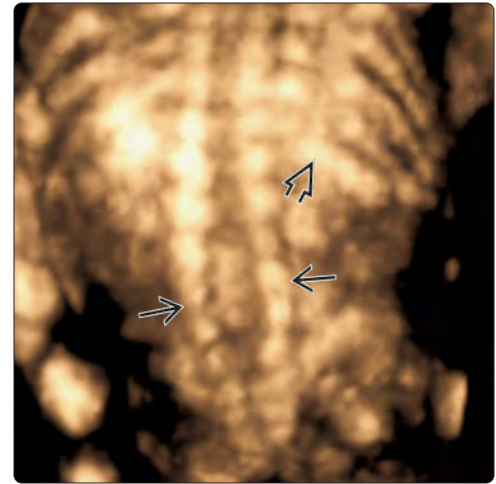
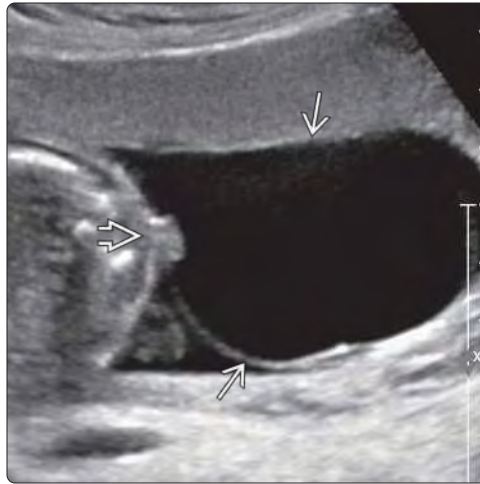


(Left) Axial view through the spine in the same fetus at 18 weeks shows divergent dorsal spine ossification centers  and a skin defect with linear echoes  extending from the spinal canal. The spinal cord itself is part of the neural elements in myeloschisis (open spina bifida without a sac). (Right) A clinical photograph of myeloschisis shows the skin defect and exposure of neural elements , with no overlying sac.

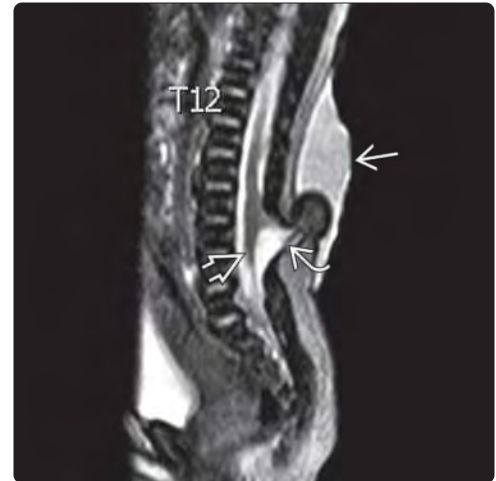
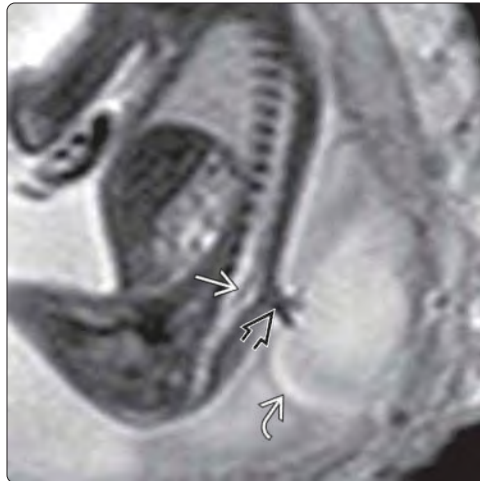

(Left) Midtrimester fetal MR in an obese patient with Chiari 2 findings and suspected large spinal defect without a sac shows a large open defect  at the level of the fetal bladder . (Right) Sagittal T2WI MR in the same fetus shows the extent of the large open spine defect without a sac  to better advantage. Also, there is cerebellar tonsil herniation  indicating Chiari 2 malformation. Fetal MR is often the best modality to image the suspected spine defect in obese patients.

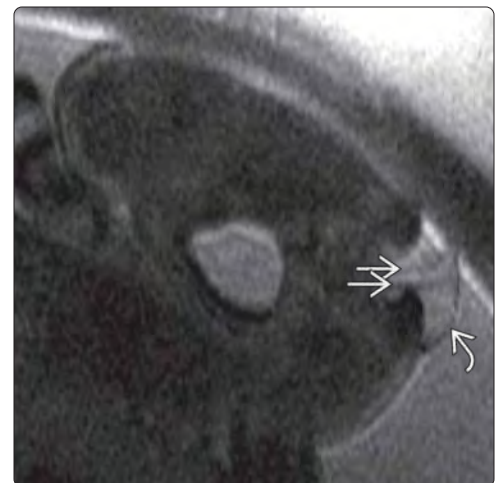
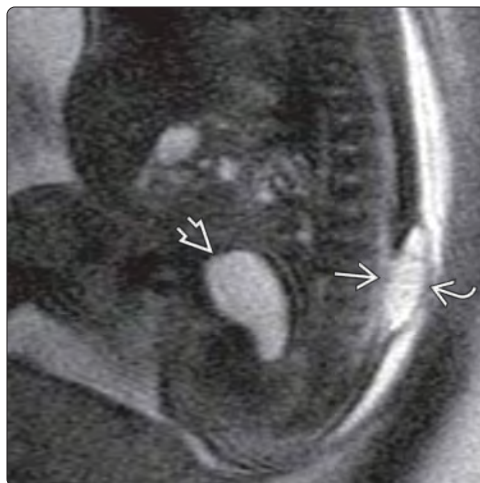
(Left) Axial view of the spine in this midgestation fetus shows an atypical, large, anechoic fluid-filled back mass with a suggestion of communication with the spinal canal. Suspicion was for a large meningocele on a stalk. **(Right)** 3D coronal reconstruction, in the same case, shows splayed midlumbar dorsal elements. The identification of the 12th rib helped localize the bony defect. Fetal MR was also performed.

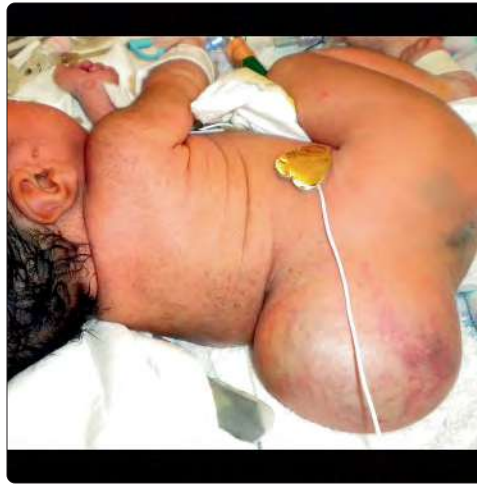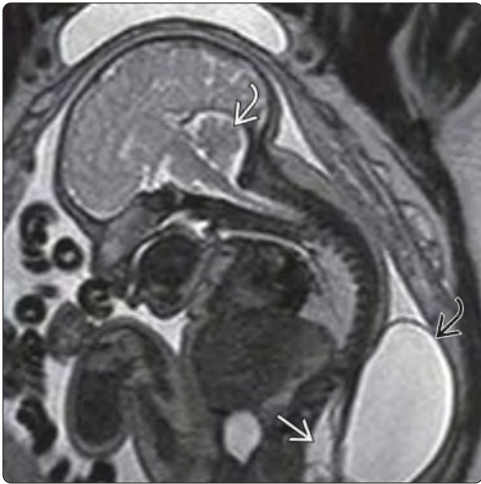


(Left) Fetal MR in same case shows a tethered spinal cord at the level of the meningocele. The pedicle is once again seen, but clear communication with spinal canal is not identified. The presence of Chiari 2 malformation (not shown) led to the correct diagnosis of meningocele. **(Right)** Neonatal MR performed after baby was born shows the decompressed meningocele sac, localized midlumbar bony defect, and the tethered spinal cord. 3D ultrasound and fetal MR helped clarify the anatomy in this case.

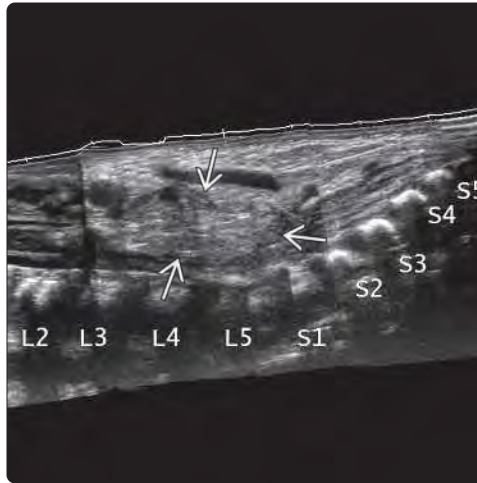
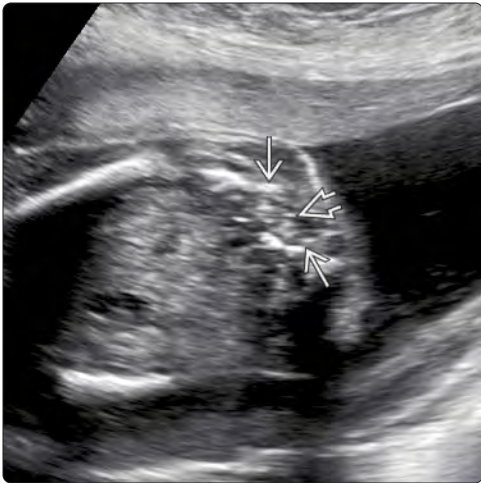


(Left) In this 3rd-trimester fetus with Chiari 2 and difficult spine visualization by ultrasound, the sagittal MR view shows a midlumbar spine sac. The communication with the spinal canal is seen at the level of the bladder dome. **(Right)** On the axial view, in the same fetus, nerve roots are clearly seen extending into the myelomeningocele sac through the dorsal bony defect. In difficult cases (obese patient, late presentation), MR visualization of the fetal spine and brain may be superior to ultrasound.

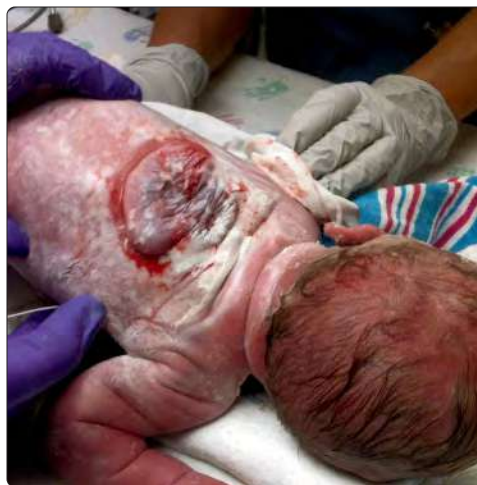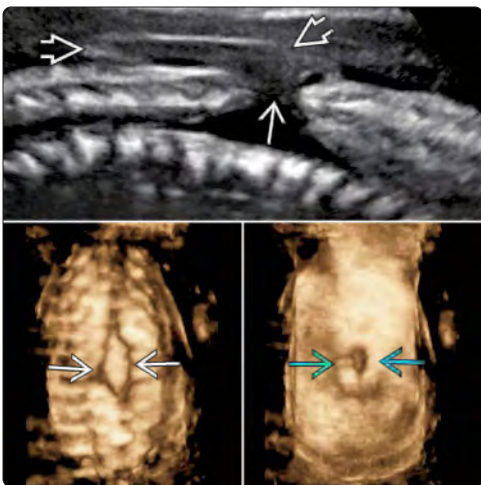




(Left) Sagittal MR in this fetus with a large spinal mass with extension into the spinal canal shows a normal posterior fossa. The cerebellar vermis is not compressed and is not herniated inferiorly. The lack of Chiari 2 findings is concordant with the ultrasound diagnosis of a large, skin-covered spina bifida. (Right) Clinical photograph of the child after delivery confirms the diagnosis of a skin covered spinal defect.



(Left) Axial ultrasound of the lower lumbar spine shows dorsal element divergence and an echogenic "mass" in the spinal canal. There were no Chiari 2 findings in the brain and any skin defect or sac. (Right) Spine ultrasound of the newborn in the same patient shows a spinal lipoma, which was associated with a skin-covered spinal defect. This is a lipomeningocele, which can be subtle. They are often not associated with Chiari 2 malformation, and, therefore, small ones are often missed at the time of the anatomy scan.



(Left) 3D multiplanar and soft tissue rendered view show a midthoracic spinal defect with a compressed sac. The skin-rendered 3D view (bottom right) shows the skin defect. The fetus had typical Chiari 2 findings in the brain. (Right) The postnatal clinical photograph after cesarean delivery shows the thoracic myelomeningocele sac. The most common location for spina bifida is lumbar, followed by sacrum. More rare locations are thoracic and cervical.

KEY FACTS

IMAGING

- 1st trimester
 - Crown-rump length less than expected
 - Head disproportionately large
- CNS
 - Extreme, fixed retroflexion of neck
 - Inion and cervical spine always involved
 - Cervical vertebrae are missing or fused
 - Spinal dysraphism common and extensive, often extending into thoracic and even lumbar area
 - Other brain anomalies frequently present
- Face
 - Orbits directed upward, stargazer appearance
 - Mandibular skin contiguous with chest
- Abdomen
 - Omphalocele and diaphragmatic hernia most common associated abnormalities
- Routine views in midtrimester should detect all cases

TOP DIFFERENTIAL DIAGNOSES



- Cervical hyperextension
 - May be transient
 - Follow-up to document resolution
- Klippel-Feil syndrome
 - Failure of segmentation of cervical vertebrae
 - Neck usually not retroflexed
- Cervical myelomeningocele
- Occipital cephalocele

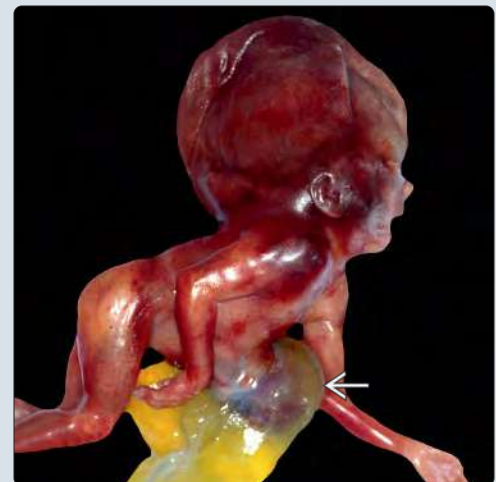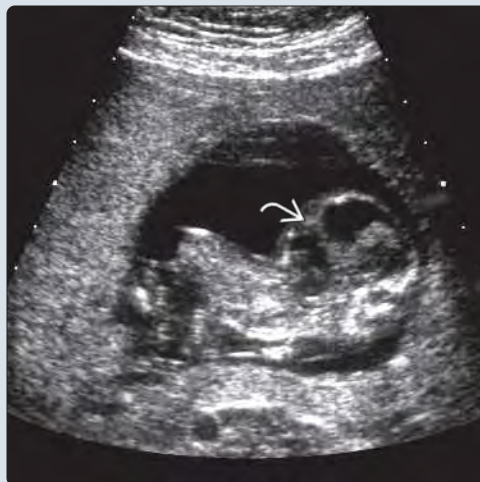PATHOLOGY






- Associated anomalies in up to 85%
- Iniencephaly apertus most common type
 - Encephalocele present
- Iniencephaly clausus has no encephalocele

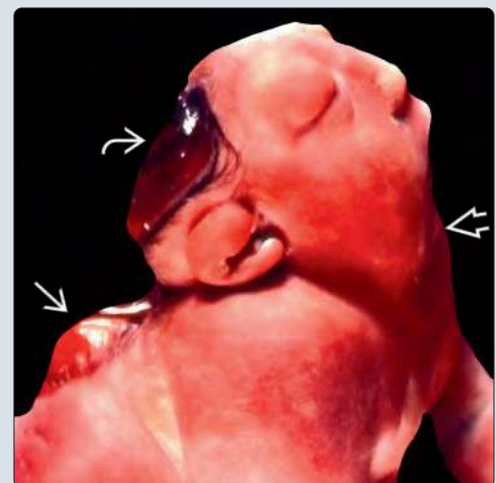
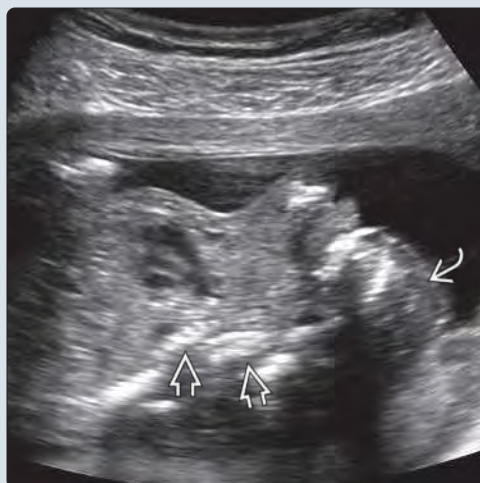CLINICAL ISSUES

- No treatment; lethal malformation
- Recurrence risk 1-4%

(Left) Transabdominal ultrasound of a 12-week gestation shows marked retroflexion of the head . Note the large size of the head relative to the body (a result of absent cervical and upper thoracic vertebrae). These are typical 1st-trimester features of iniencephaly. **(Right)** A similar appearance is shown on an autopsy at 17 weeks. The head is retroflexed and appears large in comparison to the body. There is also an omphalocele , a common associated finding. This is iniencephaly clausus (no associated encephalocele).



(Left) There is marked retroflexion of the head in this 2nd-trimester fetus with iniencephaly. The upper torso is short and the vertebrae  appear discontinuous and jumbled. The cranium is absent  and there was rachischisis of the spine. **(Right)** Clinical photograph shows iniencephaly associated with anencephaly . The neck is retroflexed and the chin is contiguous with the chest . There is also a large thoracic spine defect . Note the eyes are directed upward in what has been called a stargazer position.



IMAGING

General Features

- Best diagnostic clue
 - Combination of findings is diagnostic
 - Fixed retroflexion of neck
 - Occipital encephalocele
 - Spinal dysraphism

Ultrasonographic Findings

- **1st trimester**
 - Retroflexion of head
 - Head appears large in relation to body
 - Body shortened from absent vertebral bodies
 - Crown-rump length (CRL) less than expected
- **Cervical spine**
 - Fixed exaggerated lordosis (> 150°)
 - Large neural tube defect that may extend to involve thoracic and lumbar spine (rachischisis)
 - Short neck: Vertebrae are missing or fused
- **Face**
 - Orbits directed upward, stargazer appearance
 - Flattened profile
 - Mandibular skin contiguous with chest
- Other brain anomalies common: Anencephaly, holoprosencephaly, microcephaly, Dandy-Walker malformation
- Body malformations common: Omphalocele, diaphragmatic hernia, cardiac defects, renal anomalies, single umbilical artery, clubfeet
- Polyhydramnios common

Imaging Recommendations

- Midline sagittal plane best to evaluate
 - Head position
 - Relative size of head to body

DIFFERENTIAL DIAGNOSIS

Isolated Cervical Hyperextension

- Head held in extension throughout exam
- No structural abnormalities detected
 - Resolves on follow-up exam → normal outcome
 - Persistent finding
 - 73% normal
 - 27% unsuspected anomalies at delivery

Klippel-Feil Syndrome

- Failure of segmentation of cervical vertebrae
- Short, webbed neck
- Neck usually not retroflexed
- No open neural tube defect

Jarcho-Levin Syndrome

- Rib and widespread vertebral segmentation anomalies related to mutation in *DLL3* gene
- Small thorax

Isolated Open Neural Tube Defect

- Occipital encephalocele
- Cervical myelomeningocele

PATHOLOGY

General Features

- Etiology
 - Unknown
 - Drugs have been implicated including clomiphene, sulfonamide, tetracycline, and antitumor agents including vinblastine
- Genetics
 - Usually sporadic, autosomal recessive case reported
 - Has been reported with aneuploidy
 - Trisomy 13, monosomy X, trisomy 18
- Associated abnormalities in up to 85%
 - Virtually every organ system may be involved

Gross Pathologic & Surgical Features

- 2 types described
 - Iniencephaly apertus most common type
 - Encephalocele present
 - Iniencephaly clausus
 - No associated encephalocele
- Defect always involvesinion and foramen magnum

CLINICAL ISSUES

Presentation

- Most common signs/symptoms
 - 1st trimester
 - Retroflexed, large head
 - 2nd trimester
 - Obvious neural tube defect, spinal dysraphism
- Other signs/symptoms
 - Elevated maternal serum α -fetoprotein

Demographics

- Epidemiology
 - 0.1-10:10,000 births
 - M:F = 1:9

Natural History & Prognosis

- Lethal malformation
- Recurrence risk 1-4%

Treatment

- Fixed retroflexion may cause dystocia
 - Consider early induction
 - Cesarean section to be avoided
- Preconceptual folic acid for all future pregnancies
 - 4 mg/d decreases risk of all open neural tube defects by ~70%

DIAGNOSTIC CHECKLIST

Image Interpretation Pearls

- Hyperextension may be transient finding but should prompt careful evaluation for structural abnormalities
 - Follow-up to document resolution

SELECTED REFERENCES

1. Toru HS et al: Associated anomalies with neural tube defects in fetal autopsies. *J Matern Fetal Neonatal Med.* 1-5, 2015
2. Chikkannaiah P et al: Iniencephaly: Radiological and pathological features of a series of three cases. *J Neurosci Rural Pract.* 5(4):389-93, 2014

KEY FACTS

TERMINOLOGY

- Malformation complex characterized by varying degrees of developmental failure involving sacral and lumbar vertebrae and corresponding segments of spinal cord
 - Abnormal innervation affects lower extremity development

IMAGING

- 1st-trimester US findings: Short crown-rump length
- 2nd- and 3rd-trimester US findings
 - Abrupt termination of spine on longitudinal views spine
 - Looks as if spine has been rubbed out
 - Because of absent sacrum, iliac wings approximated or fused (shield appearance)
 - Lower extremity contractures and muscle wasting
 - Crossed-legged tailor or Buddha pose
- GI and GU anomalies common and often severe
- Congenital heart disease in 24%

- MR best modality to evaluate spinal cord and conus position

TOP DIFFERENTIAL DIAGNOSES





- Myelomeningocele
- VACTERL association
- Sirenomelia

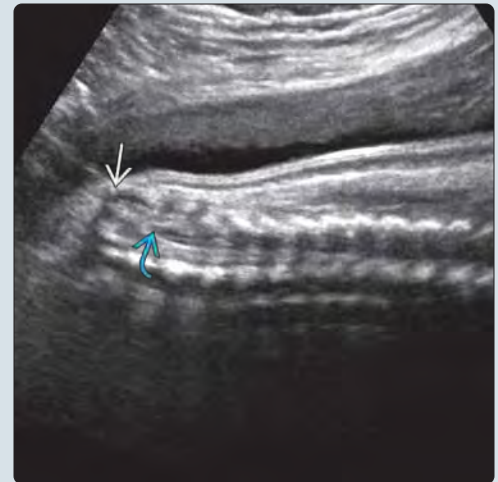
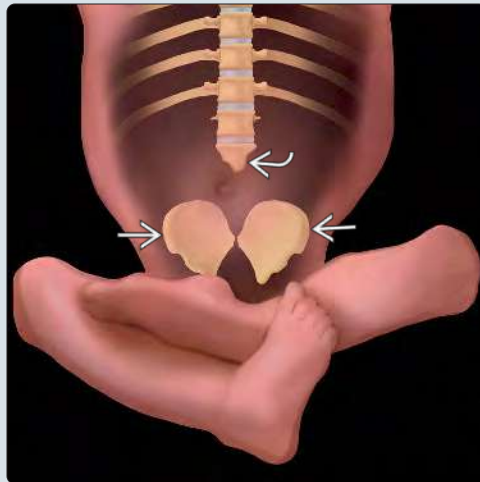
CLINICAL ISSUES






- 1% of infants born to diabetic mothers have caudal regression sequence (CRS)
- 12-16% of infants with CRS have diabetic mothers
- Clinical outcome determined by level of defect
 - Neurogenic bladder, motor deficits common in survivors

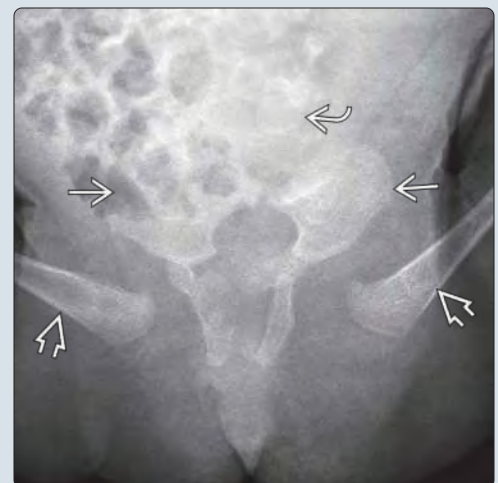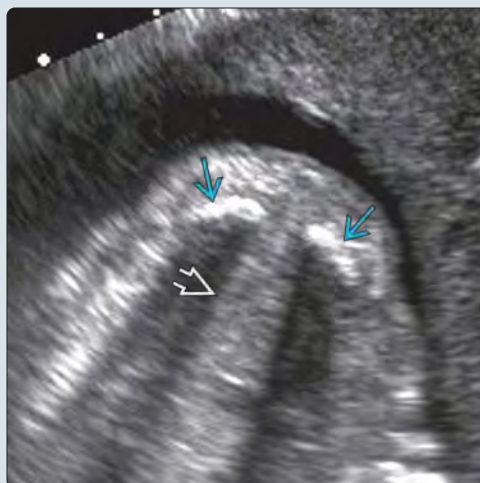
DIAGNOSTIC CHECKLIST

- Always check for spine ossification centers in axial scan plane at level of iliac wings
- Can be seen at time of nuchal translucency exam
 - Should specifically target in any diabetic mother

(Left) This graphic illustrates several features of caudal regression sequence (CRS), including abrupt termination of the spine , absence of the sacrum, and medial positioning of the iliac wings . The pelvis is foreshortened, and there is abnormal lower extremity positioning (crossed-legged tailor or Buddha pose) with muscle wasting. **(Right)** Coronal view of the spine at 32 weeks shows abrupt termination at L2 . The conus  is seen ending above that point.



(Left) Axial transvaginal ultrasound of the fetal pelvis shows absence of the sacrum; note the lack of shadowing  as there is no bone to reflect the ultrasound beam. This creates a shield appearance of the iliac wings . **(Right)** Pelvis radiograph shows the postnatal appearance of CRS. The sacrum is missing, causing the iliac wings to touch medially, thus creating the classic shield appearance . There is abrupt termination of the lumbar spine  and the femurs  are held in an abducted position.



TERMINOLOGY

Abbreviations

- Caudal regression sequence (CRS)

Synonyms

- Caudal dysplasia
- Sacral agenesis
- Axial mesodermal dysplasia spectrum
 - Additional midline craniofacial anomalies

Definitions

- Malformation complex characterized by varying degrees of developmental failure involving sacral and lumbar vertebrae and corresponding segments of spinal cord
 - Abnormal innervation affects lower extremity development

IMAGING

General Features

- Best diagnostic clue
 - Absent sacrum with hypoplastic lower extremities is diagnostic

Ultrasonographic Findings

- 1st-trimester findings
 - Short crown-rump length
 - Protuberance of lower spine
 - Increased nuchal translucency (NT)
- 2nd- and 3rd-trimester findings
 - Abrupt termination of spine
 - Looks as if spine has been rubbed out
 - S1-S2 ossification centers should be visualized at 16-17 weeks
 - Seen best on sagittal images
 - No spine visible on axial views of abdomen
 - Iliac wings approximated or fused
 - Shield appearance
 - Decreased interspace between femoral heads
 - Short trunk
 - Clubfeet
 - Lower extremity contractures
 - Crossed-legged tailor or Buddha pose
 - Normal to increased amniotic fluid
 - GI and genitourinary GU anomalies common and often severe
 - GI
 - Anorectal atresia most common GI finding
 - Duodenal atresia, malrotation
 - GU
 - Cystic renal dysplasia
 - Dilated bladder, hydronephrosis
 - Penoscrotal inversion
 - Penile agenesis
 - Cryptorchidism
 - Congenital heart disease (CHD) (24%)
 - Associated CNS anomalies
 - Chiari 2 malformation

MR Findings

- Best modality for evaluating spinal cord

- Level of conus correlates with prognosis
 - Higher termination → worse prognosis
- High-ending wedge-shaped or tapered cord termination is classic feature
 - Dorsal edge of taper longer than ventral
- May demonstrate additional spine/cord anomalies
 - Myelomeningocele (35-50%)
 - Myelocystocele (15%)
 - Tethered cord
 - Syringomyelia
 - Intraspinal arachnoid cyst

Imaging Recommendations

- Protocol advice
 - 1st-trimester endovaginal scan in diabetic mothers
 - Particularly important if poor perigestational glycemic control
 - Look for abnormal contour of lower spine area
 - Increased NT
 - Beware of tapering distal spine in fetus at risk for CRS
 - May taper where it terminates even if not at sacrum
 - Normal sagittal spine tapers to point at level of fetal buttock
 - Coronal section shows ribs; count down lumbar segments to show 5 vertebrae present
 - Axial view at level of iliac crests best to show sacrum
 - Sacrum not well ossified until mid 2nd trimester
 - Cannot confidently rule out if fetus < 18 weeks
 - Mild cases easily missed
 - Fetal echocardiography
 - Should be routine with maternal diabetes
 - Strong association with cardiovascular anomalies

DIFFERENTIAL DIAGNOSIS

Myelomeningocele

- Ossification centers present with posterior elements splayed
- Look for meningocele sac
- Associated with Chiari 2 malformation of brain
 - Obliteration of cisterna magna
 - Banana cerebellum
 - Lemon sign: Bifrontal concavity

VACTERL Association

- Combination of abnormalities: **V**ertebral, **a**norectal, **c**ardiac, **t**racheo-**e**sophageal fistula, **r**enal, **l**imbs
- Spine is more often abnormal (fused, butterfly, or hemivertebra) rather than absent
- Not associated with maternal diabetes

Sirenomelia

- Previously considered part of same spectrum but now felt to be vascular in origin
- Single fused lower extremity
- Renal agenesis

Segmental Spinal Dysgenesis

- Probably part of same spectrum as CRS
- Acute kyphosis or kyphoscoliosis
- Thin or indiscernible cord at dysgenetic level
 - Cord below dysgenetic level thickened, low lying

Arthrogryposis, Akinesia Sequence

- Contracture may cause similar appearance in legs
- Spine normal
- Not associated with maternal diabetes

PATHOLOGY

General Features

- Genetics
 - Most cases sporadic
 - Currarino syndrome is autosomal dominant; mutation in *MX1* (HLXB9) homeobox gene
 - Sacral defect (often sickle shape), anal atresia, anterior meningocele
- Embryology
 - Insult prior to 4th gestational week with multiple proposed etiologies
 - Metabolic (hyperglycemia)
 - Toxins
 - Solvents and drug exposure including minoxidil, sulfamides, retinoic acid
 - Ischemia, radiation, temperature extremes
 - Interrupted/abnormal secondary neurulation at caudal eminence
 - Also affects caudal mesodermal structures explaining high association with GI and GU anomalies

Staging, Grading, & Classification

- CRS Type 1: Conus ends at or above L1
 - Vertebral defect often extensive
 - Most common type to see in fetus
- CRS Type 2: Low-lying, tethered, thickened cord
 - Sacrum better preserved
 - Uncommon fetal diagnosis; generally presents in childhood

Gross Pathologic & Surgical Features

- Spectrum of spinal malformation
 - Abnormal sacrum with normal lower extremities
 - Absent sacrum
 - Abnormal/absent lower lumbar spine
 - Occasional thoracic spine involvement
- Extremities
 - Flexion deformities of hips/knees
 - Clubfeet

CLINICAL ISSUES

Presentation

- Most common signs/symptoms
 - Unable to clear distal spine on 2nd-trimester exam
 - Abnormal positioning of extremities
- Other signs/symptoms
 - May be seen in 1st trimester at time of NT exam
 - Should specifically target in any diabetic mother

Demographics

- Epidemiology
 - M:F = 1:1
 - 1-5/100,000
 - 200x more common in infants of diabetic mothers
 - 12-16% of infants with CRS are born to diabetic mothers

- Poor glycemic control thought to be etiologic factor
 - 1% of infants born to diabetic mothers have CRS

Natural History & Prognosis

- High mortality due to associated anomalies
- Spectrum of mild to severe impairment in survivors depending on level of defect
 - Mild foot disorders → complete lower extremity paralysis and distal leg atrophy
- Motor > sensory deficits
 - Motor level usually higher than sensory level
- Neurogenic urinary bladder dysfunction in nearly all patients
- Normal intellectual function

Treatment

- Known maternal diabetes
 - Strict diabetic control prior to conception and during pregnancy
- Fetal diagnosis
 - Maternal diabetes testing
 - No fetal intervention
- Have parents meet with pediatric surgeons to discuss postnatal care
 - Urologic consultation
 - Sacral anomaly determines bladder dysfunction
 - Neurogenic bladder
 - Reflux nephropathy
 - Aim to prevent progressive renal dysplasia
 - Orthopedic surgery
 - Spine instability
 - Hip dislocation
 - Joint contractures, clubfeet
 - Aim for proper sitting and standing without amputation, if possible

DIAGNOSTIC CHECKLIST

Consider

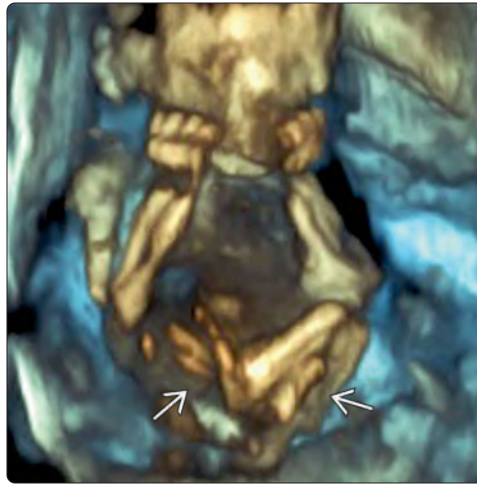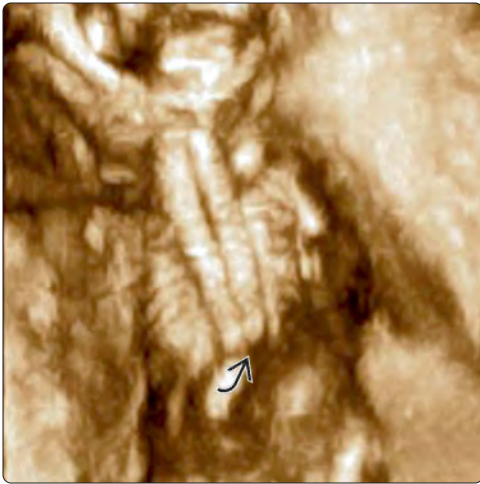- Fetal MR more precisely shows spinal cord, level of conus, and associated abnormalities
 - Allows more accurate prenatal counseling

Image Interpretation Pearls

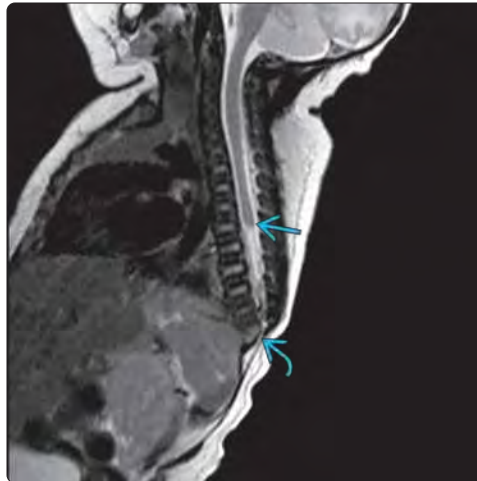
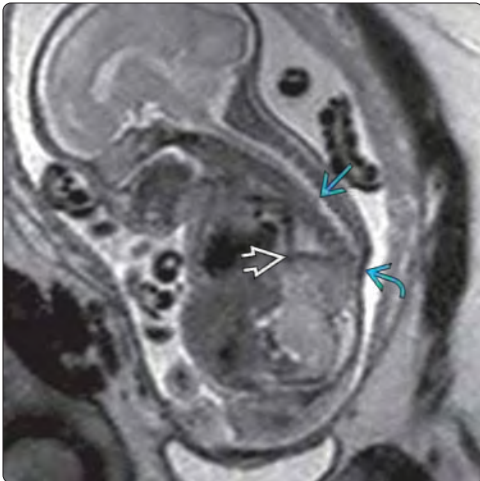
- Always check for spine ossification centers in axial scan plane at level of iliac wings
- In diabetics, perform endovaginal ultrasound for accurate dating and early anatomic assessment, especially if poor periconceptional glycemic control
 - Short crown-rump length should suggest CRS if dates are accurate

SELECTED REFERENCES

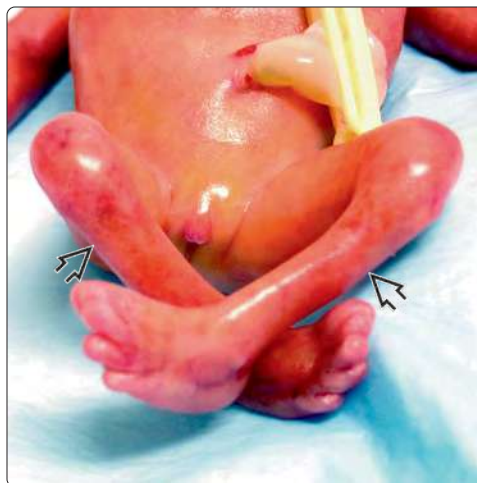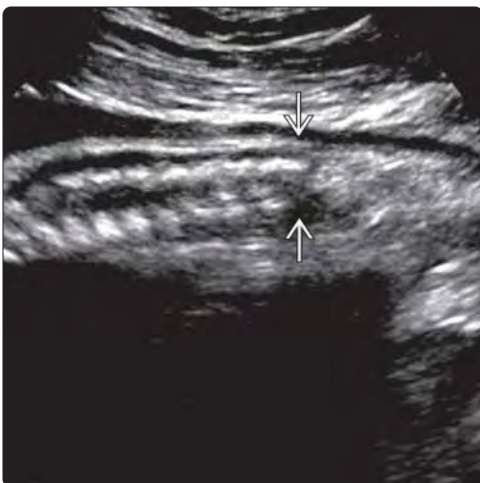
1. Demir MK et al: Caudal regression syndrome with diplomyelia (type 2 split cord malformation), tethered cord, syringomyelia, and horse-shoe kidney. *Spine J.* ePub, 2015
2. Puneeth KT et al: High abrupt cord termination: a hallmark of caudal regression syndrome. *BMJ Case Rep.* 2014, 2014
3. Beaumont C et al: Prenatal imaging of caudal regression syndrome with postnatal correlation: novel insights. *Fetal Diagn Ther.* 34(2):131-2, 2013
4. Kokrdova Z: Caudal regression syndrome. *J Obstet Gynaecol.* 33(2):202-3, 2013
5. Sharma P et al: Clinico-radiologic findings in group II caudal regression syndrome. *J Clin Imaging Sci.* 3:26, 2013



(Left) 3D ultrasound of the fetal spine at 20 weeks shows abrupt termination at the 12th thoracic vertebra. **(Right)** Surface-rendered image, in the same case, shows the lower extremities being held in a typical crossed-leg position. The mother was a poorly controlled diabetic, an important risk factor for CRS. It is important to realize, however, that only 12-16% of cases occur in the setting of maternal diabetes, so the distal spine must be carefully checked in all fetuses.



(Left) A fetal MR was performed for further evaluation in the same case. It confirms termination of the spine at the level of the diaphragm. MR adds additional information about the spinal cord, with the conus ending high above the vertebral defect. **(Right)** Postnatal MR confirms the prenatal findings with no spinal elements below T12. The conus has a wedge-shaped configuration and is ending well above the last vertebra, which is typical of severe CRS.



(Left) Sagittal ultrasound in the 3rd trimester shows the classic rubbed out appearance where the distal spine terminates abruptly. Only 3 lumbar vertebral ossification centers were visualized in this fetus of a diabetic mother. **(Right)** Clinical photograph shows a small pelvis with muscle wasting of the lower extremities, which is due to abnormal innervation. The legs are crossed in the classic Buddha pose.

KEY FACTS

TERMINOLOGY

- Scoliosis
 - Abnormal lateral spine angulation
- Kyphosis
 - Abnormal anterior spine angulation

IMAGING

- Longitudinal views best
 - Coronal for scoliosis
 - Sagittal for kyphosis
- Isolated vertebral body anomaly (5%)
 - Hemivertebra, butterfly, or block vertebra
- Associated anomalies (95%)
 - Spina bifida
 - VACTERL association
- Rib deformities common with thoracic scoliosis
- Beware of positional curvature
 - Resolves with time

TOP DIFFERENTIAL DIAGNOSES

- Caudal regression sequence
- Iniencephaly

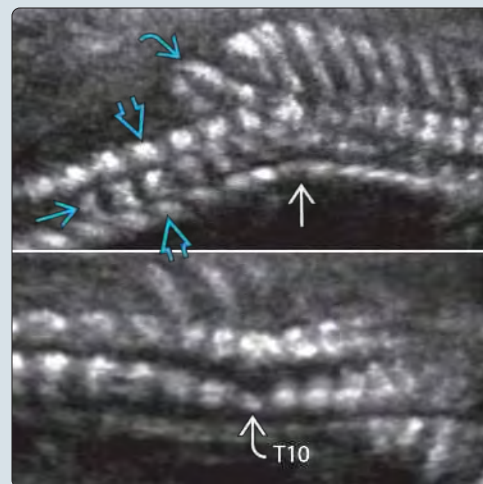
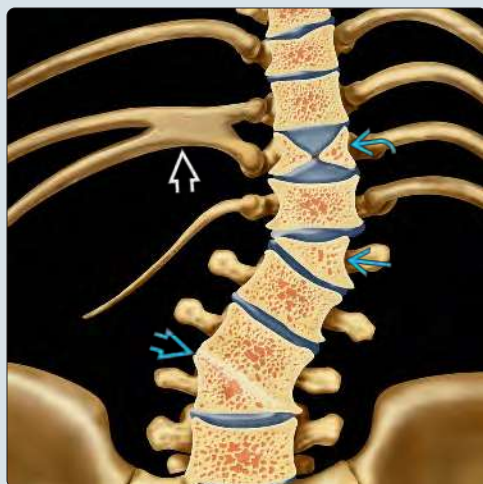
CLINICAL ISSUES

- Isolated has no increased risk for aneuploidy
- Curve progression of isolated scoliosis ($> 10^\circ$ at diagnosis)
 - 25% have no further curve progression
 - 50% have slow curve progression
 - 25% have rapid curve progression
- 20-30% with additional intraspinal anomaly
 - Requires postnatal evaluation

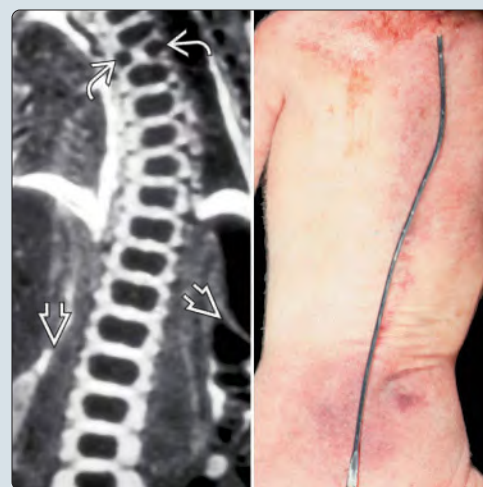
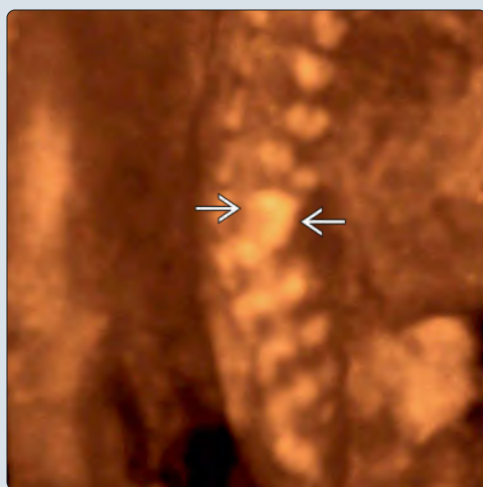
DIAGNOSTIC CHECKLIST

- Spina bifida most common cause of congenital scoliosis (60% of cases)
 - Spinal defect located at apex of curve
 - Look for Chiari 2 findings in brain
- Probably isolated if no Chiari 2 or other obvious anomalies

(Left) Coronal graphic shows the various vertebral body anomalies seen in scoliosis, including a butterfly vertebra [E], hemivertebra [E], and block vertebra [E]. Malformed ribs, especially fusion [E], are a common association. (Right) Coronal view of the spine (upper) shows normal lumbar vertebral bodies [E] and lateral processes [E], with abrupt scoliosis in the lower thoracic spine [E]. There is also an abnormal rib [E]. A more oblique plane (bottom) shows a hemivertebra at T10 [E]. Count the ribs to determine the level.



(Left) 3D ultrasound shows block vertebrae of the upper lumbar spine [E]. Fused vertebrae are large and rectangular. Mild kyphoscoliosis drew the sonographer's attention to this area. (Right) Coronal postmortem MR of a fetus with VACTERL association shows a butterfly vertebra [E]. There is bilateral renal agenesis (empty renal fossae [E]). The rod is shown on the back of the stillborn following the scoliosis curve.



TERMINOLOGY**Definitions**

- Scoliosis: Abnormal lateral spine angulation
- Kyphosis: Abnormal anterior spine angulation

IMAGING**Ultrasonographic Findings**

- Abnormal spine angulation
 - Longitudinal views best
 - Coronal for scoliosis
 - Sagittal for kyphosis
 - Identify level of defect
 - Use ribs to identify 12th thoracic level
 - Rib deformities common with thoracic scoliosis
- **Isolated vertebral body anomaly (5%)**
 - Hemivertebra
 - Only 1/2 of vertebral body develops
 - Triangular bone acts as wedge
 - Prenatal diagnosis is often associated with additional anomalies, often syndromic
 - Butterfly vertebra
 - Central nonfusion
 - "Balanced" so degree of scoliosis < for hemivertebrae
 - Block vertebra
 - Fusion of 1 or more vertebral bodies
 - Body or dorsal elements or both
 - Hemivertebrae may fuse
 - Rectangular large vertebra
 - Vertebral anomaly without scoliosis
 - May develop with time; requires follow-up
 - Multiple levels indicates more severe malformation
 - Multiple dysmorphic vertebrae ("jumbled spine")
- **Associated anomalies (95%)**
 - Spina bifida
 - Most common cause of congenital scoliosis (60%)
 - Abnormal curvature is at level of defect
 - VACTERL association (vertebral anomalies, anal atresia, cardiovascular anomalies, tracheoesophageal fistula, esophageal atresia, renal anomalies, limb anomalies)
 - Amniotic band syndrome
 - Scoliosis + amputation

Imaging Recommendations

- Beware of positional curvature
 - No bony defect, resolves with time
 - Often seen in 3rd trimester
- Persistent scoliosis/kyphosis should elicit carefully search for vertebral anomalies
 - Detailed orthogonal views of spine
 - 3D ultrasound best shows level and degree of vertebral dysmorphism

DIFFERENTIAL DIAGNOSIS**Caudal Regression Sequence**

- Absent sacrum with variable absence of lumbar spine
- Lower vertebral bodies may be dysmorphic
- Lower limb contractures; "Buddha pose"

Arthrogryposis

- Multiple congenital joint contractures
 - Extremities more involved than spine
 - Usually without bony abnormality

PATHOLOGY**General Features**

- Etiology
 - Failure of vertebral formation, segmentation, or abnormal fusion
- Genetics
 - Isolated has no increased risk for aneuploidy
- Associated abnormalities
 - Alagille syndrome has vertebral (most commonly butterfly vertebra), liver, heart, and eye abnormalities

CLINICAL ISSUES**Presentation**

- Most common signs/symptoms
 - Isolated scoliosis seen during routine exam
 - Congenital scoliosis + multiple other anomalies
 - ↑ maternal serum α-fetoprotein
 - Spina bifida, amniotic band syndrome

Natural History & Prognosis

- Prognosis depends on presence of other anomalies
- Isolated congenital scoliosis
 - Curve progression of isolated scoliosis (> 10° at diagnosis)
 - 25% have no further curve progression
 - 50% have slow curve progression
 - 25% have rapid curve progression
 - 20-30% with additional intraspinal anomaly
 - Often diagnosed only on postnatal MR
- Thoracic insufficiency syndrome
 - Rib anomalies + concave hemithorax

Treatment

- If isolated and not severe, may be watched
- Corrective surgery for significant or progressive curvature
 - Spinal fusion ± vertebral body resection
- Expansion thoracoplasty for thoracic insufficiency

DIAGNOSTIC CHECKLIST**Image Interpretation Pearls**

- Congenital scoliosis + Chiari 2
 - Look for spina bifida
 - Spinal defect located at apex of curve
- Look at limbs
 - VACTERL association: Radial ray anomalies
 - Amniotic band syndrome: Amputations
 - Spina bifida: Clubbed feet
- Congenital scoliosis, no Chiari 2 or obvious anomalies
 - Probable isolated vertebral anomaly

SELECTED REFERENCES

1. Wei Q et al: Value of 3-dimensional sonography for prenatal diagnosis of vertebral formation failure. J Ultrasound Med. 32(4):595-607, 2013

KEY FACTS

TERMINOLOGY

- Low-lying conus medullaris (CM)
 - Often with associated back anomaly
 - Short thick filum terminale in classic cases

IMAGING

- CM position varies with gestational age
 - CM should not be inferior to L3-L4 after 18 weeks
 - 19-24 weeks: CM between L2 and L3
 - 24 weeks-term: Progressive relative ascent with CM above L2-L3 at term
- Longitudinal views best for determining level
 - Identify T12 or S1 and count lumbar levels
- Associations
 - Neural tube defects (open and closed)
 - VACTERL association
 - Congenital scoliosis and kyphosis
- MR is additive and may show cord level best

TOP DIFFERENTIAL DIAGNOSES

- Cyst of filum terminale (may mimic low CM on ultrasound)
- Ventriculus terminalis (dilation of CM central canal)

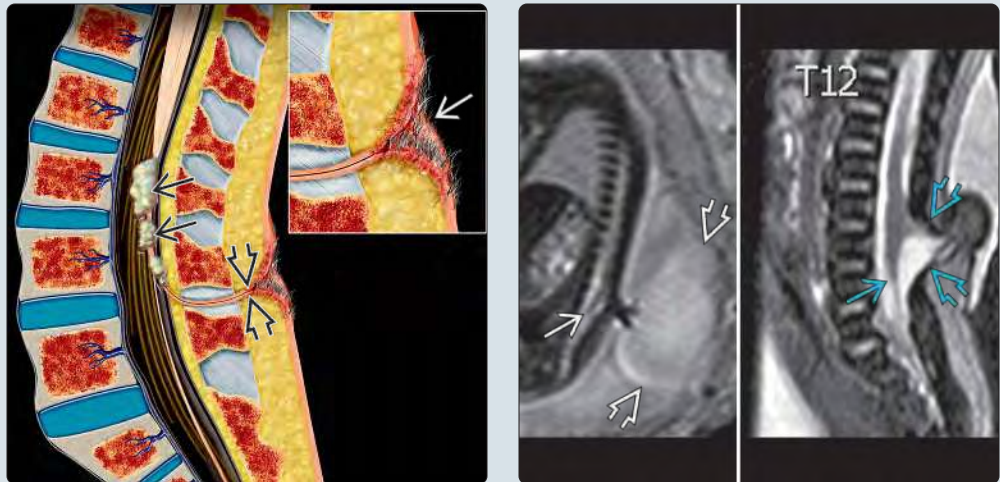
PATHOLOGY

- Thickened fibrotic filum
- Associated fibroma/lipoma
- Associated spine anomaly

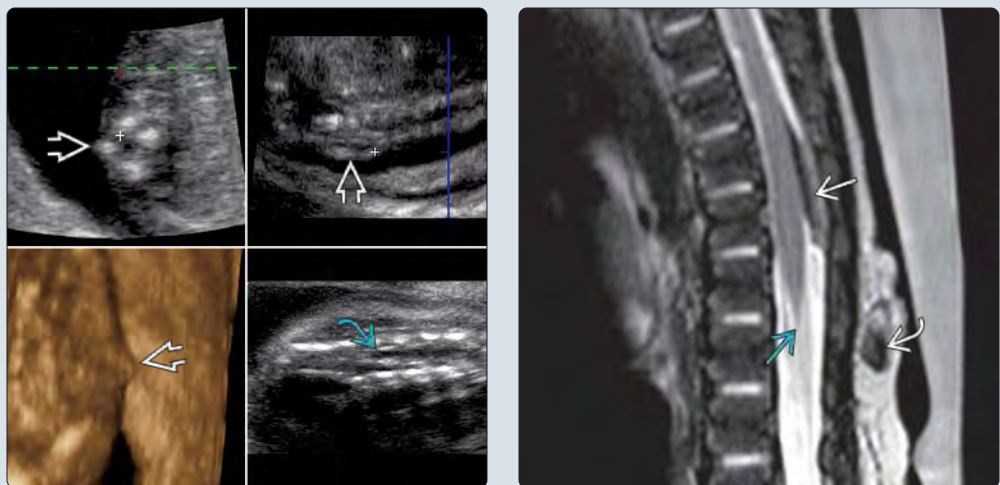
CLINICAL ISSUES

- Midline cutaneous stigmata seen on physical exam
 - Nevi, lipoma, hair tuft, hemangioma, dermal sinus
- Chronic fixed tension on cord may result in severe and permanent damage
- Treatment: Resect tethering mass → stabilizes neurological function
 - Improves bowel/bladder function
 - May prevent progression of scoliotic curvature

(Left) Sagittal graphic shows a tethered cord due to a filum terminale lipoma. There is an associated dorsal dermal sinus, extending to the skin surface. The inset shows the tuft of hair and sacral dimple, 2 skin stigmata associated with tethered cord. **(Right)** Sagittal fetal MR shows a pedunculated meningocele and tethered cord terminating in the lower lumbar spine. Postnatal imaging confirms the tethered cord at the L5 level and the small bony defect associated with the meningocele sac.



(Left) In this 20-week fetus, a small echogenic skin mass is seen on the axial, sagittal, and surface-rendered views. On the same 3D sweep, the coronal image shows a low-lying conus medullaris in the lower lumbar spine. **(Right)** Sagittal T2 fat-suppressed postnatal image in the same patient shows a tethered cord at the L3/L4 level. A small subcutaneous lipoma and an intraspinal lipoma were connected by a fistulous tract (not shown).



TERMINOLOGY**Abbreviations**

- Tethered spinal cord (TSC)

Definitions

- Low-lying conus medullaris (CM)
 - Short, thick filum terminale in classic isolated cases
 - Often seen with associated back anomaly

IMAGING**General Features**

- Best diagnostic clue
 - Low-lying CM for gestational age ± associated back mass/anomaly

Imaging Recommendations

- Best imaging tool
 - High-resolution probe if fetal spine is anterior and near uterine wall

Ultrasonographic Findings

- CM position varies with gestational age, because spine develops faster than cord
 - 13-18 weeks: CM at L4 vertebral level
 - 19-24 weeks: CM between L2 and L3
 - 24 weeks-term: Progressive relative ascent
 - Above L2-L3 at term
 - TSC diagnosed if CM is inferior to L3-L4 after 18 weeks
- Determining CM level
 - Longitudinal views best
 - Identify 12th rib (T12) and count inferiorly
 - Identify S1 and count superiorly
 - S1 angled compared to L5 on sagittal view
 - S1 at level of iliac crest on coronal view
 - 3D ultrasound helps identify vertebral body levels
- Neural tube defects are highly associated with TSC
 - Open spinal dysraphism (near 100% with TSC)
 - Myelomeningocele, myelocele, myeloschisis
 - Look for Chiari 2 changes in brain
 - Closed spinal dysraphism or intradural process (highly associated)
 - Associated lipoma (soft tissue, filum, intradural)
 - Fibrous adhesions and tracks
 - Short, thickened filum terminale
- Other associations
 - Congenital scoliosis and kyphosis
 - VACTERL association (39% with TSC)
 - Anal atresia (8% with TSC)

MR Findings

- Often shows spinal cord better than US
 - May show associated thick filum, lipoma, or adhesions

DIFFERENTIAL DIAGNOSIS**Normal Variant Conus**

- Cyst of filum terminale (may mimic low CM on ultrasound)
- Ventriculus terminalis (dilation of CM central canal without TSC)
- CM inferior to L3 but otherwise normal

- Needs postnatal surveillance

PATHOLOGY**General Features**

- Etiology
 - Associations with spine anomalies
 - Cases with minimal skin stigmata rarely diagnosed in utero

Gross Pathologic & Surgical Features

- Thickened fibrotic filum (55%)
- Associated fibroma/lipoma (23%)

CLINICAL ISSUES**Presentation**

- Most common signs/symptoms
 - Spinal anomaly on prenatal scan
 - TSC doesn't affect prognosis for fetuses with open neural tube defect
 - Midline cutaneous stigmata
 - Nevi, lipoma, tufts of hair, hemangioma, or dermal sinus
- Other signs/symptoms
 - Urodynamic disturbance: Presents as urinary dribbling after birth
 - Orthopedic lower extremity deformity: Clubfoot, leg length discrepancy, muscular atrophy

Natural History & Prognosis

- Chronic fixed tension on cord may result in severe and permanent damage
- Urinary bladder dysfunction
- Orthopedic foot problems

Treatment

- Prenatal diagnosis is important for family counseling and early treatment
 - Early surgery improves outcomes
- Resect tethering mass → stabilizes neurological function

DIAGNOSTIC CHECKLIST**Consider**

- TSC in cases with fetal back mass (may be subtle)
- TSC in all cases of open or closed spinal dysraphism
 - Level of defect is more indicative of function than TSC

SELECTED REFERENCES

1. Blondiaux E et al: Prenatal US evaluation of the spinal cord using high-frequency linear transducers. *Pediatr Radiol.* 41(3):374-83, 2011
2. Duczkowska A et al: Magnetic resonance imaging in the evaluation of the fetal spinal canal contents. *Brain Dev.* 33(1):10-20, 2010
3. Hertzler DA 2nd et al: Tethered cord syndrome: a review of the literature from embryology to adult presentation. *Neurosurg Focus.* 29(1):E1, 2010
4. Sohaey R et al: Prenatal diagnosis of tethered spinal cord. *Ultrasound Q.* 25(2):83-7; quiz 93-5, 2009
5. Lowe LH et al: Sonography of the neonatal spine: part 1, Normal anatomy, imaging pitfalls, and variations that may simulate disorders. *AJR Am J Roentgenol.* 188(3):733-8, 2007
6. Lowe LH et al: Sonography of the neonatal spine: part 2, Spinal disorders. *AJR Am J Roentgenol.* 188(3):739-44, 2007

KEY FACTS

TERMINOLOGY

- Rare form of spinal dysraphism
- Sagittally oriented spinal canal spur that splits spinal cord into 2 hemicords

IMAGING

- US diagnosis difficult secondary to shadowing from vertebrae
 - Axial plane best for seeing spur (echogenic focus in posterior spinal canal)
 - Coronal plane shows widening of spinal canal
 - Sagittal plane best to evaluate for associated vertebral body anomalies
- Associated CNS abnormalities
 - Scoliosis (80%)
 - Tethered cord (75%)
 - Myeloschisis, myelomeningocele (15-25%)
- MR superior to US for looking at cord

TOP DIFFERENTIAL DIAGNOSES

- Duplicated spinal cord (diplomyelia)

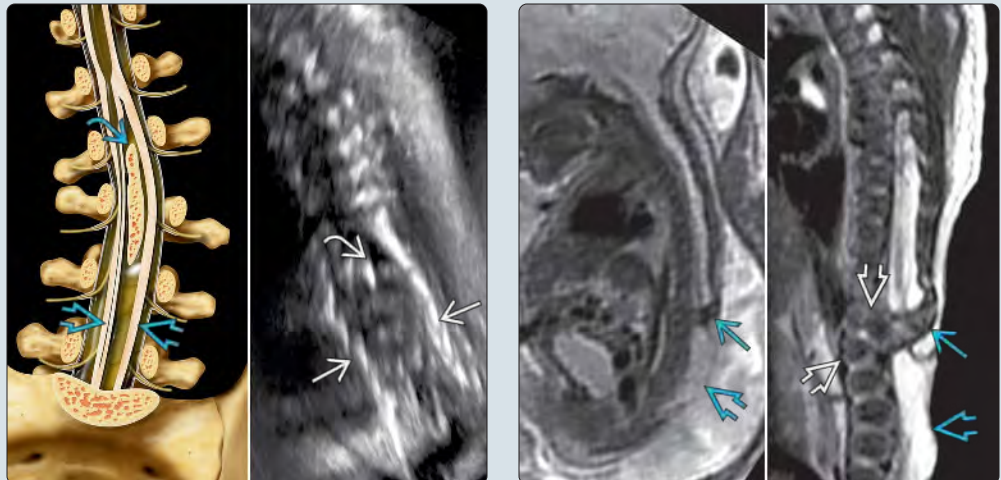
CLINICAL ISSUES

- Represents 5% of congenital scoliosis
- Symptoms related to degree of spinal cord tethering
 - Orthopedic foot problems (50%)
 - Urologic dysfunction
- Prognosis favorable when not associated with other spinal anomalies
- Treatment: Tethered cord release, spur resection, and dural repair
 - Decreases symptom progression

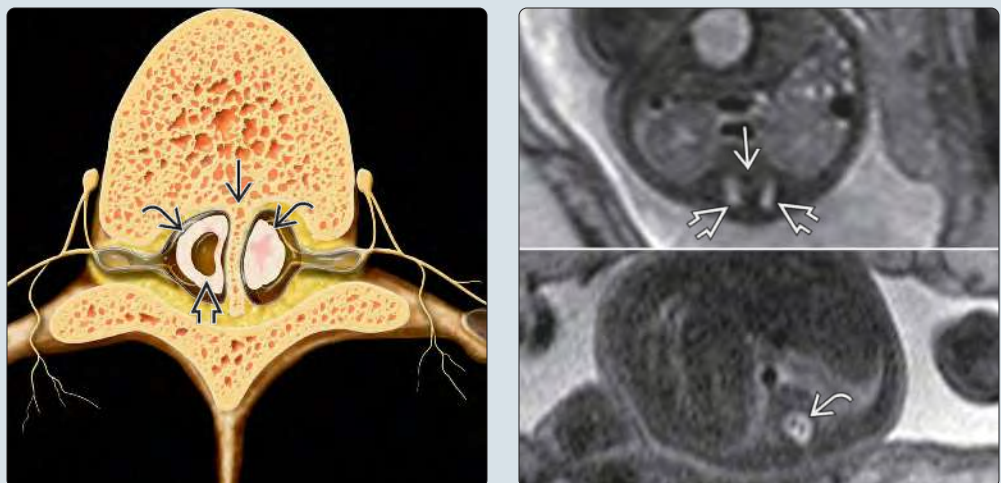
DIAGNOSTIC CHECKLIST

- When vertebral anomaly is present, evaluate spinal cord
- Consider MR for further evaluation

(Left) Coronal graphic shows scoliosis of the lumbar spine with a bony spur splitting the cord into 2 hemicords. On the right, a coronal image shows splaying of the posterior element of the lumbar spine in a fetus with a myelomeningocele. Note the bony spur at the upper end of the defect. **(Right)** Fetal (left) and postnatal (right) sagittal MR images in the same case show the bony spur as well as the myelomeningocele. Also note the abnormal vertebral bodies at the same level.



(Left) Axial graphic shows a bony spur dividing the central spinal canal, typical of diastematomyelia. The cord is split into 2 hemicords. The right hemicord also has syringohydromyelia, which can be seen in 1 or both cords in 50% of cases. Unless severe, syringohydromyelia may not be seen on US. **(Right)** Diastematomyelia is shown in 2 different cases. On the top, there is a bony spur separating the 2 canals. On the bottom, 2 distinct hemicords can be seen within the central spinal canal.



TERMINOLOGY

Synonyms

- Split cord malformation (SCM)

Definitions

- Sagittally oriented spinal canal spur that splits spinal cord into 2 hemicords
 - Rare form of spinal dysraphism

IMAGING

General Features

- Best diagnostic clue
 - Complete or incomplete sagittal division of cord into 2 hemicords in 1 central spinal canal
 - Additional echogenic focus in posterior spinal canal in axial plane
- Location
 - 85% thoracolumbar cleft (T9-S1)
 - Single or multilevel cleft

Ultrasonographic Findings

- Difficult to diagnose when isolated secondary to shadowing from vertebrae
 - Axial best plane for seeing spur
 - Echogenic focus in posterior spinal canal
 - Located between spinal laminae
 - May be osseous or fibroosseous cleft/spur
 - Intersegmental vertebral fusion is common
 - Echogenic cleft divides central spinal canal
 - Coronal: Widening of spinal canal
 - Evaluate for associated scoliosis
 - Sagittal: Evaluate for associated vertebral body anomalies
 - Butterfly vertebra, block vertebra, hemivertebra
 - Overlying skin intact
- Associated CNS abnormalities
 - Scoliosis (80%)
 - Tethered cord (75%)
 - Syringohydromyelia in 1 or both cords (50%)
 - Myeloschisis, myelomeningocele (15-25%)
 - Chiari 2 (15-20%)
- Associated visceral abnormalities
 - Horseshoe kidney, ectopic kidney
 - Uteroovarian malformation
 - Rectal malformation

MR Findings

- Spinal cord better evaluated
 - 2 hemicords may unite above and below cleft
 - Evaluate filum terminale (tethered cord, fibrolipoma)
- Useful for evaluation for associated spine or CNS abnormalities

DIFFERENTIAL DIAGNOSIS

Duplicated Spinal Cord (Diplomyelia)

- 2 complete spinal cords, each with 2 anterior and 2 posterior horns and roots

PATHOLOGY

Staging, Grading, & Classification

- Pang type 1 SCM
 - Separate dural sac; arachnoid space surrounds each hemicord
 - Osseous or fibroosseous spur
 - More commonly symptomatic
- Pang type 2 SCM
 - Single dural sac and arachnoid space
 - No osseous spur; ± adherent fibrous bands tether cord
 - Symptoms rare unless cord tethered or hydromyelia

Gross Pathologic & Surgical Features

- Symmetric: Each hemicord contains 1 central canal, 1 dorsal horn/root, 1 ventral horn/root with surrounding pial layer
- Asymmetric: Variable division of anterior and posterior hemicord
- Filum fibrolipoma common in all types

CLINICAL ISSUES

Presentation

- Most common signs/symptoms
 - Usually detected in conjunction with spinal defect
 - Represents 5% of congenital scoliosis

Natural History & Prognosis

- Symptoms related to degree of spinal cord tethering
 - Orthopedic foot problems (50%)
 - Urologic dysfunction
- Prognosis favorable when not associated with other spinal anomalies
- Dividing cleft inhibits normal movement with activity

Treatment

- Tethered cord release, spur resection and dural repair → decreased symptom progression
- Surgery recommended before deterioration of function

DIAGNOSTIC CHECKLIST

Image Interpretation Pearls

- When vertebral anomaly is present, evaluate spinal cord
- Consider MR for further evaluation

SELECTED REFERENCES

1. Bixenmann BJ et al: Prenatal and postnatal evaluation for syringomyelia in patients with spinal dysraphism. *J Neurosurg Pediatr.* 14(3):316-21, 2014
2. Gavrilu S et al: Diastematomyelia in congenital scoliosis: a report of two cases. *Eur Spine J.* 23 Suppl 2:262-6, 2014
3. Guo A et al: Fetal syringomyelia. *Acta Neuropathol Commun.* 2:91, 2014
4. Turgal M et al: Prenatal diagnosis and clinicopathologic examination of a case with diastematomyelia. *Congenit Anom (Kyoto).* 53(4):163-5, 2013
5. Cheng B et al: Diastematomyelia: a retrospective review of 138 patients. *J Bone Joint Surg Br.* 94(3):365-72, 2012
6. Li SL et al: Prenatal diagnosis of diastematomyelia: a case report and review of the literature. *J Clin Ultrasound.* 40(5):301-5, 2012
7. Passoglou V et al: Diastematomyelia: pre- and postnatal multimodal diagnostic approach. *JBR-BTR.* 94(6):333-5, 2011
8. Kulkarni M et al: Fetal diastematomyelia: MR imaging: A case report. *Indian J Radiol Imaging.* 19(1):78-80, 2009
9. Has R et al: Prenatal diagnosis of diastematomyelia: presentation of eight cases and review of the literature. *Ultrasound Obstet Gynecol.* 30(6):845-9, 2007

KEY FACTS

IMAGING

- Exophytic mixed cystic/solid mass extending from sacrum
 - Variable size but often large, with potential for extremely rapid growth
 - Commonly extend into pelvis and abdomen
- Solid tumors may have significant arteriovenous shunting, which may lead to hydrops
 - Color Doppler essential to evaluate vascularity
 - Scan every 1-3 weeks depending on size, vascularity, etc.
 - Evaluate for signs of impending cardiovascular compromise or internal hemorrhage
- Associated malformations in 11-38%, mostly secondary to mass effect from local tumor growth
- MR superior to ultrasound for evaluation of intraabdominal extent of tumor
- Calculate tumor volume:fetal weight ratio (TFR)
 - TFR > 0.12 prior to 24 weeks gestation is predictive of poor prognosis

TOP DIFFERENTIAL DIAGNOSES

- Myelomeningocele

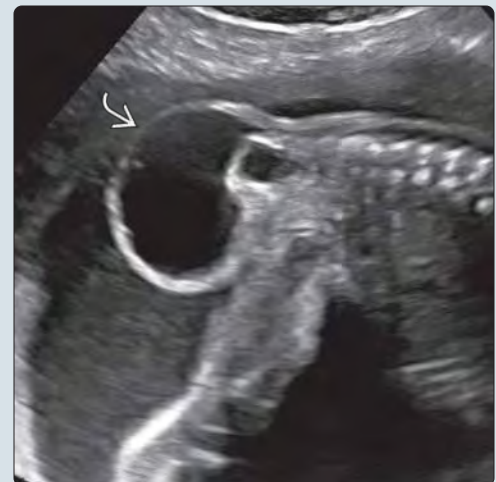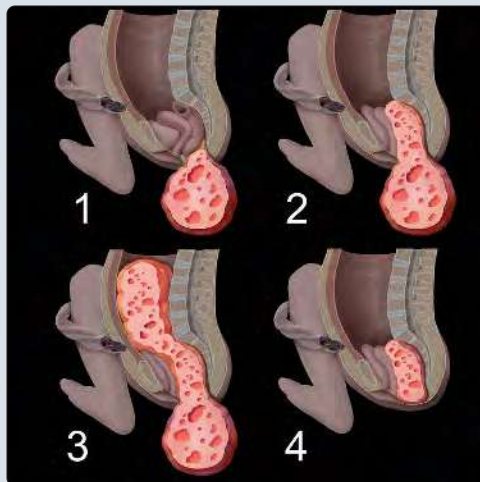
CLINICAL ISSUES

- Often presents as size > dates secondary to polyhydramnios and large tumor size
 - May require therapeutic amnioreduction for symptomatic relief
- Large, solid, vascular tumors have high mortality and morbidity
- Prognosis significantly worse for fetus than neonate
 - Fetal diagnosis: 30-50% mortality
 - Hydrops almost universally fatal
 - Better outcome for cystic tumors

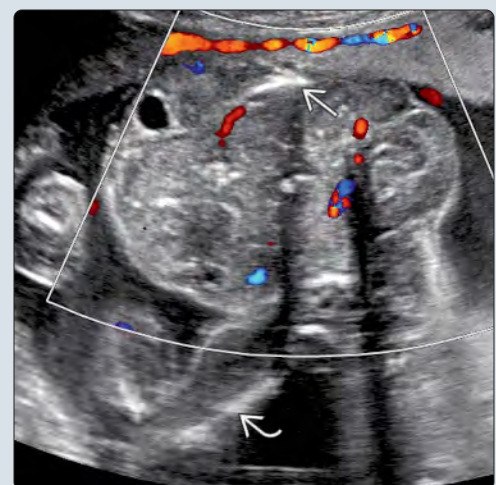
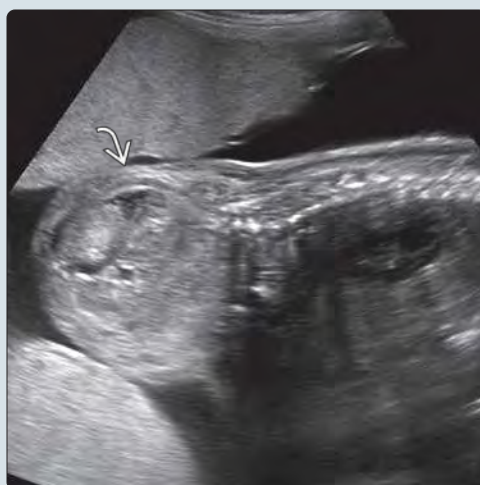DIAGNOSTIC CHECKLIST

- Aggressively follow at-risk fetuses
 - Consider early delivery or referral for fetal surgery if signs of cardiovascular compromise

(Left) Graphic shows the surgical classification of sacroccygeal teratoma (SCGT). Type 1 is predominately external with minimal presacral component; type 2 extends into the presacral space; type 3 extends up into the abdomen; and type 4 is completely internal. (Right) This sagittal US of the distal spine at 18 weeks shows a predominately cystic SCGT. This remained stable throughout gestation and the prenatal course was uncomplicated. A cystic SCGT generally has a good prognosis.



(Left) As a comparison, here is an example of a solid SCGT of similar size in a 19.5-week fetus. (Right) In 4 weeks time, there was dramatic growth (note the size of the leg for comparison). This mass shows several classic features of a teratoma, including internal vascularity and calcifications. Solid tumors may show very rapid growth and have a much more guarded prognosis. This fetus developed hydrops with intrauterine fetal death (IUFD) at 26 weeks.



TERMINOLOGY

Abbreviations

- Sacrococcygeal teratoma (SCGT)

Definitions

- Neoplasm derived from all 3 germ cell layers
- 70-80% of all teratomas are located in sacrococcygeal area

IMAGING

General Features

- Best diagnostic clue
 - Exophytic, mixed cystic/solid mass extending from sacrum
- Size
 - Variable but often large
 - Size alone is not independent factor for prognosis
 - Amount of solid component is far more important
 - Has potential for extremely rapid growth

Ultrasonographic Findings

- Grayscale ultrasound
 - Heterogeneous, mixed solid/cystic mass
 - Purely cystic in 15%
 - May contain calcifications
 - Commonly extends into pelvis or abdomen
 - Important in staging and surgical planning
 - Hydrops indicates very poor prognosis
 - Placentomegaly also indicator of high output failure
 - Polyhydramnios commonly present
 - Oligohydramnios occurs infrequently
 - Secondary to intrapelvic portion of mass obstructing urinary tract
 - May exhibit rapid growth in short period of time
 - Intratumoral hemorrhage
 - Common in large solid tumors
 - Very poor prognostic sign
 - Associated malformations in 11-38%; predominately local effects secondary to tumor mass effect
 - Hydronephrosis, renal dysplasia
 - Lower urinary tract obstruction
 - Hydrocolpos, undescended testes
 - Anorectal malformations
 - Hip dislocation, clubbed feet
- Color Doppler
 - Color Doppler essential to evaluate vascularity
 - Solid tumors may have significant arteriovenous shunting
 - At risk for hydrops
 - Shearing forces can cause red cell destruction and fetal anemia

MR Findings

- Superior for evaluation for intraabdominal extension of tumor and effect on other organs
 - More accurate classification and postnatal planning
 - More accurate diagnosis of intratumoral hemorrhage
 - Always evaluate for possible involvement of spinal canal

Imaging Recommendations

- Protocol advice

- Calculate tumor volume:fetal weight ratio (TFR)
 - Tumor volume: Tumor length x width x depth x 0.523
 - Divide by estimated fetal weight
 - TFR > 0.12 prior to 24 weeks gestation is predictive of poor prognosis
 - ◻ Follow this group close for possible fetal intervention
- Large, solid tumors at risk for developing hydrops
 - Scan every 1-3 weeks depending on size, vascularity, composition etc.
- Evaluate for signs of impending cardiovascular compromise
 - Tumor growth
 - Amniotic fluid index
 - Placental thickness
 - Cardiothoracic ratio (normal ~ 50%)
 - Early signs of high-out state
 - ◻ Inferior cava diameter > 1 cm
 - ◻ Increase descending aortic velocity (> 120 cm/sec)
 - ◻ Increased combined ventricular output (>500 ml/kg/min)

DIFFERENTIAL DIAGNOSIS

Myelomeningocele

- Sac contains meninges + neural elements
- Splayed dorsal ossification centers
- Sac extends posteriorly in most cases
- Anterior myelomeningocele may be more difficult to differentiate from SCGT
 - Always look at brain for Chiari 2 findings
- Caution: Myelomeningocele and SCGT may occur together

Terminal Myelocystocele

- Closed spinal dysraphism with large, skin-covered back mass
- Hydromyelic, low-lying, tethered spinal cord traverses dorsal meningocele and terminates in dilated terminal cyst (myelocystocele)
- Frequent associated anorectal and visceral anomalies

Other Solid Tumors

- Isolated case reports of sarcomas
- Generally intrapelvic with no exophytic component
- All extremely rare

PATHOLOGY

General Features

- Etiology
 - Embryology
 - In weeks 4-6, primordial germ cells migrate from yolk sac to genital ridges where they are then incorporated into primitive sex cords to form gonad
 - Unincorporated cells normally involute
 - Continued division of unincorporated pluripotential cells gives rise to teratoma
- Genetics
 - Most are sporadic
 - Rare familial SCGT thought to be autosomal dominant involving *MX1* (HLXB9) at chromosome region 7q36

Staging, Grading, & Classification

- American Academy of Pediatrics Surgery Section
 - Type 1: Predominately external with minimal presacral component
 - Type 2: External and internal component extending into presacral space
 - Type 3: External and internal component extending into abdomen
 - Type 4: Completely internal, no external component
 - Most likely to undergo malignant degeneration (postnatal)
 - Malignancy more likely in solid than cystic tumors
- Staging system less important prognostically in fetus
 - Amount of solid component and degree of arteriovenous shunting far more important for fetal survival
- Preeclampsia
- Mirror syndrome
 - Maternal fluid retention and hemodilution
 - Progressive maternal edema "mirroring" sick fetus
 - Necessitates immediate delivery
- Preterm labor
- HELLP (hemolysis, elevated liver enzymes, low platelets) syndrome
- Long-term functional results generally excellent
 - Urinary and fecal incontinence, lower extremity weakness reported when spine involved
 - Constipation is common

CLINICAL ISSUES

Presentation

- Most common signs/symptoms
 - Described in late 1st trimester but most often diagnosed in 2nd trimester with obvious mass
 - Often presents as size > dates
 - Polyhydramnios and large mass size
 - Presentation at delivery
 - Dystocia 6-13%
 - Tumor avulsion
 - Fetal exsanguination

Demographics

- Epidemiology
 - Most common neonatal tumor
 - 1:35,000-40,000 live births
 - Fetal incidence higher given large number of in utero deaths and terminations
 - M:F = 1:4
 - Malignant transformation (M > F)

Natural History & Prognosis

- Failure to diagnose has potentially catastrophic consequences for fetus and mother
- Significant obstetric complications in 81%
- Prognosis significantly worse for fetus than neonate
 - Fetal diagnosis 30-50% mortality
 - Hydrops from high-output state
 - Intratumoral hemorrhage, tumor rupture
 - Newborn diagnosis: ≤ 5% mortality
 - If undiagnosed internal component (type 4) may develop malignancy in adulthood
- **Poor prognostic factors**
 - Large solid component
 - TFR > 0.12 prior to 24 weeks gestation is predictive of poor prognosis
 - Early diagnosis
 - Significant vascularity
 - Hydrops almost universally fatal
- Better outcome if cystic
 - Less vascular → decreased risk for hemorrhage, hydrops
- Maternal complications
 - Hyperemesis

Treatment

- Therapeutic amnioreduction for symptomatic polyhydramnios
- Cesarean section preferred if tumor > 5 cm
 - Aspiration of cystic lesions may allow vaginal delivery
- Early delivery for signs of impending cardiovascular compromise
 - One large center showed better than expected survival in aggressively followed, high-risk patients delivered 27-32 weeks
- Consider referral to fetal surgery for poor prognosis cases
 - External component removed with complete surgery after delivery
 - Radiofrequency ablation has been used but has risk of significant collateral tissue damage
- Postnatal surgery must include complete resection of internal component
 - Incomplete resection may have local recurrence or malignant transformation
 - Alpha fetoprotein is elevated but should decrease to normal levels by 1 year of age
 - Useful marker for recurrence

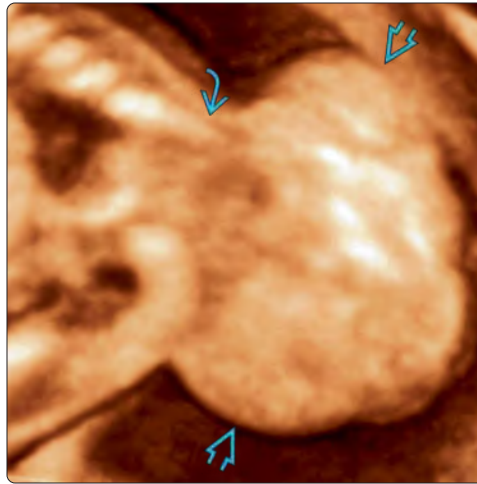
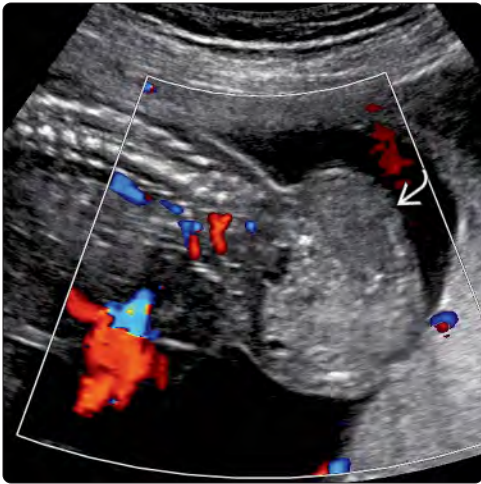
DIAGNOSTIC CHECKLIST

Image Interpretation Pearls

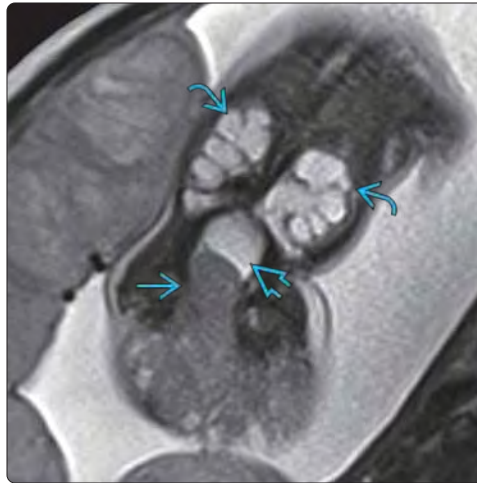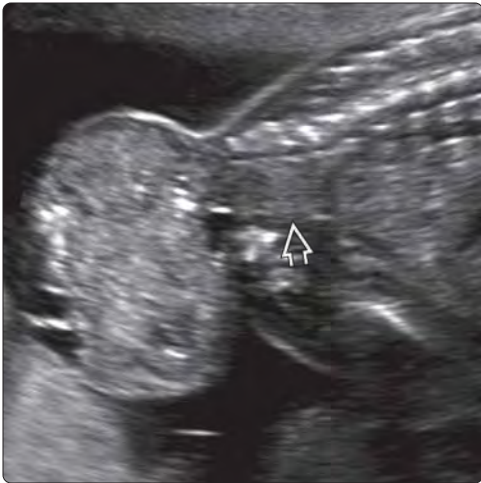- Most compelling issues for fetal/neonatal survival
 - Composition: Solid much worse prognosis than cystic
 - Vascularity: Vascular masses have significant arteriovenous shunting → high-output failure → hydrops
 - Associated abnormalities
 - Complicating factors: Hydrops, polyhydramnios, tumor hemorrhage or rupture
- Aggressively follow at-risk fetuses

SELECTED REFERENCES

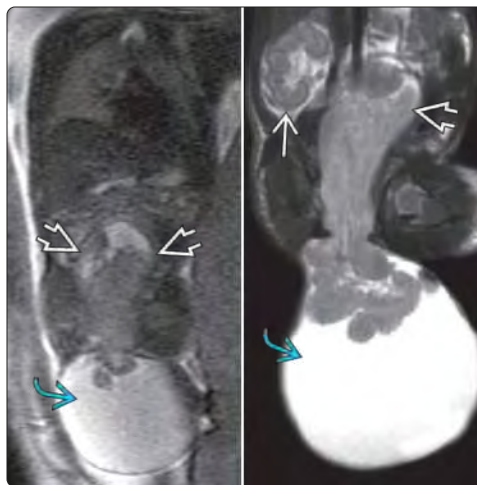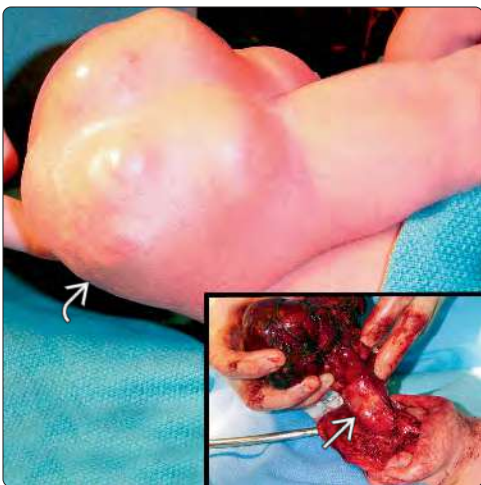1. Akinkuotu AC et al: Predictors of poor prognosis in prenatally diagnosed sacrococcygeal teratoma: A multiinstitutional review. *J Pediatr Surg.* 50(5):771-4, 2015
2. Arisoy R et al: Prenatal diagnosis and outcomes of fetal teratomas. *J Clin Ultrasound.* 44(2):118-25, 2015
3. Coleman A et al: Sacrococcygeal teratoma growth rate predicts adverse outcomes. *J Pediatr Surg.* 49(6):985-9, 2014
4. Partridge EA et al: Urologic and anorectal complications of sacrococcygeal teratomas: prenatal and postnatal predictors. *J Pediatr Surg.* 49(1):139-42; discussion 142-3, 2014
5. Coleman A et al: Prenatal solid tumor volume index: novel prenatal predictor of adverse outcome in sacrococcygeal teratoma. *J Surg Res.* 184(1):330-6, 2013



(Left) Although this SCGT is solid [redacted], there is very little internal vascularity. Although it did increase in size during gestation, the growth was not rapid and the fetus never showed signs of compromise. (Right) This 3D image of the same patient shows the smoothly encapsulated mass [redacted] below the tip of the spine [redacted]. 3D images are very helpful for prenatal counseling and are better understood by parents than 2D images.

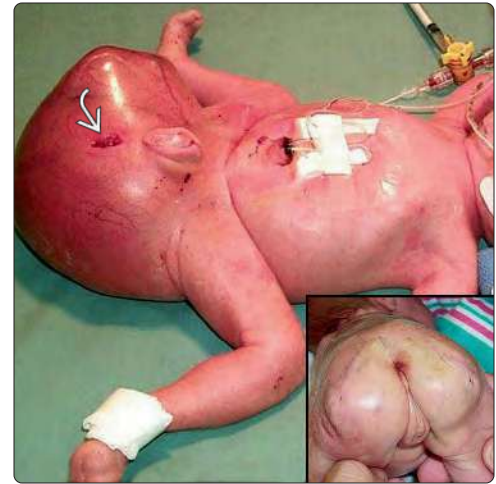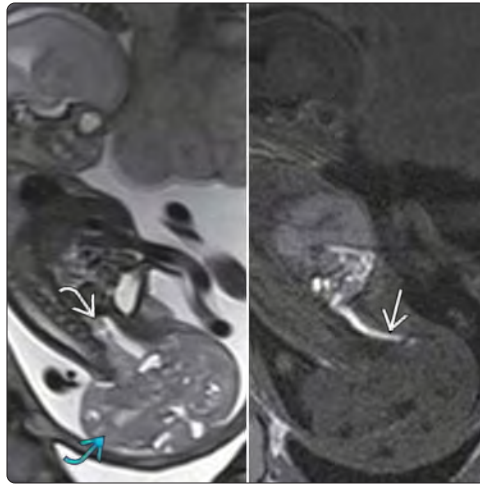


(Left) It is important to evaluate the intraabdominal extent of the mass for both appropriate classification and assessment of effect on other organs. In this case, the ultrasound was suspicious for intrapelvic extension [redacted]. MR is recommended in these cases as it has superior soft tissue contrast and can more precisely define the anatomic extent. (Right) T2 MR in the same patient shows definite intrapelvic extension [redacted] (type 2 SCGT) with compression of the bladder [redacted] and hydronephrosis [redacted].

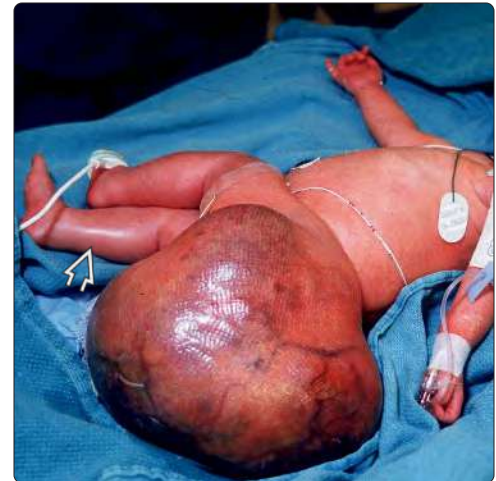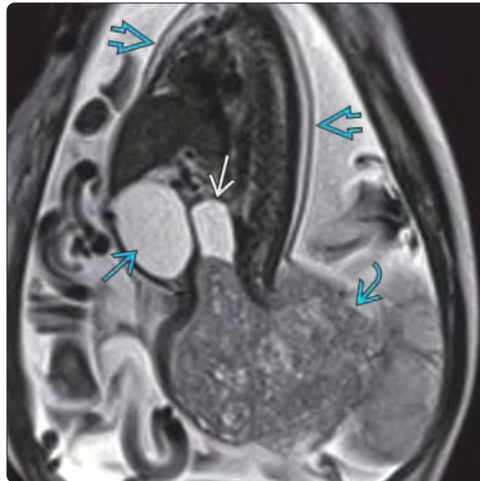


(Left) Clinical photograph shows an obvious exophytic mass [redacted] located at the sacrococcygeal area. An intraoperative photograph (inset) shows the internal component [redacted] being removed. This is important, as there is a risk of malignant transformation. (Right) Coronal fetal (left) and postnatal (right) MR images of a SCGT show a predominately cystic external component [redacted] with an extensive internal soft tissue component [redacted] extending up the level of the kidneys [redacted] (type 3).

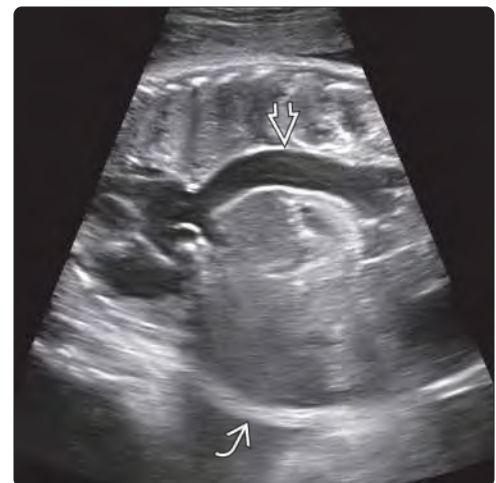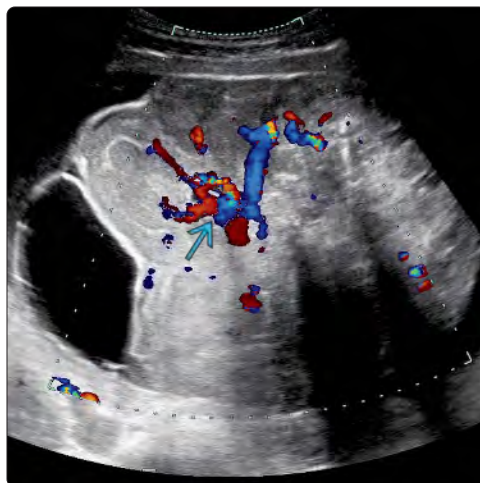
(Left) Sagittal T2 MR (left) nicely shows the intrapelvic extension of an SCGT. Most fetal imaging is performed using T2-weighted sequences, but T1 (right) has great benefit for evaluating bowel, with meconium being high in signal. In this case the rectum is being anteriorly displaced but is intact. (Right) Postnatal photograph shows the anterior displacement of the patent anal orifice. The postsurgical photograph (inset) shows the excellent result that can be achieved even with very large masses.

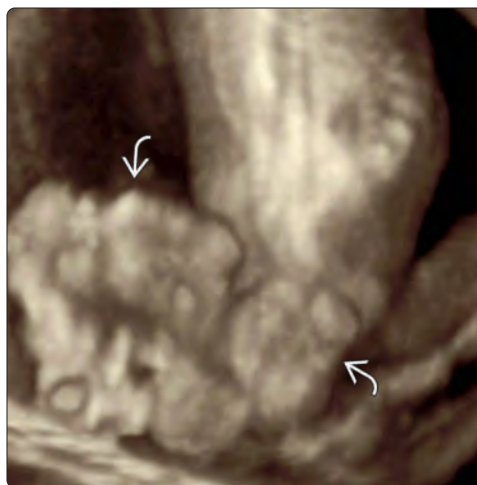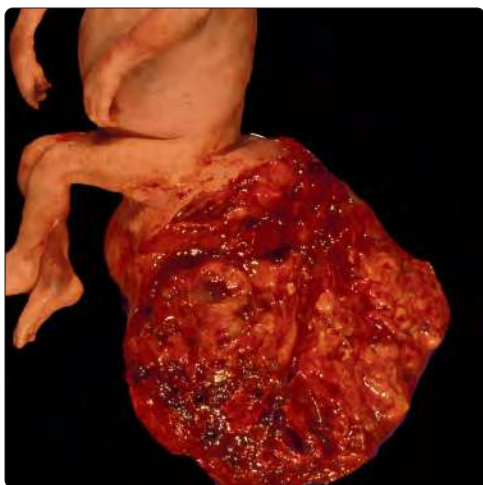


(Left) Sagittal MR shows a SCGT with a large solid external component and a cystic portion extending into the midabdomen. The bladder is being pushed anteriorly and cephalad. Most importantly, there is soft tissue edema concerning for developing hydrops, a poor prognostic sign. (Right) Clinical photograph after delivery shows edema around the trunk and particularly around the legs. Lower extremity edema can be part of generalized anasarca or from obstructed lymphatic and vascular return.

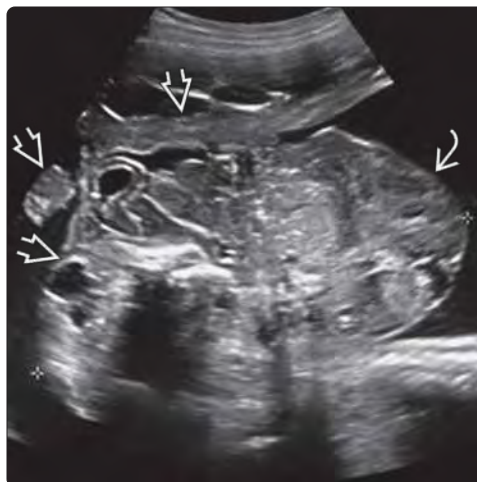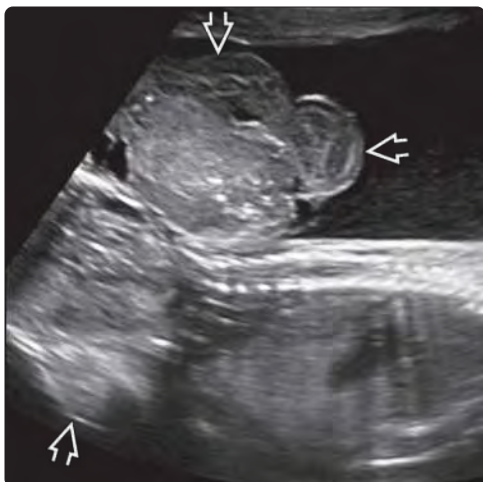


(Left) This cross section through a large SCGT shows turbulent flow within an arteriovenous fistula (AVF). (Right) An oblique axial image through the abdomen in the same patient shows dramatic enlargement of the inferior vena cava and protuberant abdomen from hepatomegaly. An AVF can cause hydrops, not only from high-output failure but also from fetal anemia caused by shearing forces in the fistula.

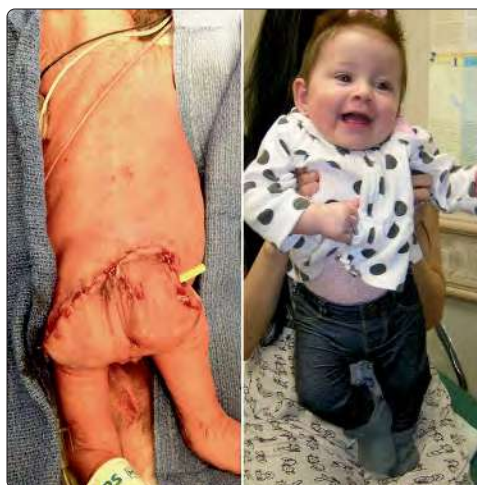
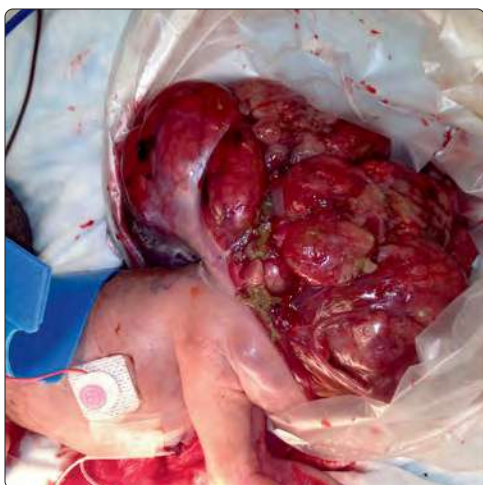


(Left) Autopsy case shows the cut surface of a SCGT with obvious intratumoral hemorrhage. This is one of the potential complications of these very vascular tumors. (Right) Another potential complication is tumor rupture. This 3D ultrasound at 17.5 weeks shows a 6-cm, irregular, frond-like, unencapsulated, solid mass. There was floating debris in the amniotic fluid and fetal anemia by the middle cerebral artery Dopplers. IUFD occurred at 22 weeks. Capsular disruption was confirmed at delivery.



(Left) Sagittal ultrasound at 24 weeks shows a very large, lobular, well-defined, solid mass. (Right) At 26 weeks, the largest dimension had increased from 7 cm to 14 cm. While remaining partially contained, there were large floating fragments concerning for capsular rupture. Severe polyhydramnios, fetal tachycardia, and decreased fetal movement quickly ensued. The fetus was emergently delivered by cesarean section.

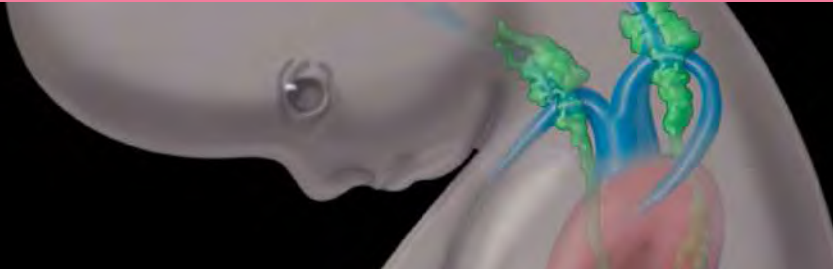

(Left) This is an immediate postdelivery photograph in the same patient showing the obvious capsular rupture. (Right) After stabilization, the infant was taken for surgical resection of the mass. The postoperative photograph is shown on the left. A follow-up photograph taken on a postoperative visit at 11 months shows a remarkably happy and healthy little girl. She had some mild lower extremity spasticity but was otherwise developmentally normal.

This page intentionally left blank

SECTION 4

Face and Neck



Embryology and Anatomy of the Face and Neck	262
Approach to the Fetal Face and Neck	274
Cleft Lip, Palate	278
Dacryocystocele	284
Coloboma	286
Epignathus	288
Epulis	292
Goiter	294
Cystic Hygroma	298
Cervical Teratoma	302

Pertinent Differential Diagnoses

Abnormal Orbits/Eyes	304
Abnormal Ears	310
Micrognathia	314
Macroglossia	318

GENERAL CONCEPTS**Branchial Arches**

- Form during 4th and 5th weeks of embryonic development
- 4 branchial arches (BA) appear as bars of mesenchymal tissue
- BA are separated by clefts
 - Branchial grooves
- BA and groove composition
 - External ectoderm
 - Internal endoderm
 - Central mesoderm
 - Migratory neural crest cells

Swellings Form on Branchial Arches

- Prominences
- Placodes
 - Migrate and fuse to form face
- Failed migration and fusion leads to common facial anomalies

Lymphatics

- Initial separate paired lymphatics
- Fuse with venous system
- Drain head, neck, upper limbs
- Failure to form or fuse leads to lymphatic disorders

NOSE, LIPS, AND PALATE**Frontonasal Prominence**

- Anterior cranial bulge of tissue
- Contains forebrain

Nasal Placodes

- Develop on frontonasal prominence (FNP)
 - 5th week of embryonic life
- Bilateral, oval-shaped thickenings
- Eventually evaginate
 - Form nasal pits

Medial + Lateral Nasal Prominences

- Develop on FNP
 - 6th week of embryonic life
- Mesenchyme proliferation of nasal margins
 - Horseshoe-shaped elevations
- Deepening of nasal pit forms nasal sacs
 - Nasal sacs grow dorsal and superior
 - Initial separation between oral and nasal cavity
 - Primitive choanae forms posterior to primary palate
 - Rupture of oronasal membrane
- Medial nasal prominences merge
 - Fusion of midline medial prominence
 - Form intermaxillary segment
 - Becomes philtrum of lip

Maxillary Prominences

- 5th-8th week of embryonic life
- Start as paired swellings lateral to primitive mouth
 - Enlarge and grow rapidly toward midline
- Fuse with lateral nasal prominences
 - Lateral margins of philtrum
 - Just below nostrils

Palate

- 6th-12th week of embryonic life
- Forms from 2 primordia
- **Primary palate**
 - Innermost part of intermaxillary segment
 - From medial nasal prominence
 - Wedge-shaped segment
 - Eventual small section of adult hard palate
 - Anterior maxilla to incisor foramen
 - Includes incisor teeth
- **Secondary palate**
 - Primordia of most of hard palate and soft palate
 - Develops from maxillary prominences
 - Lateral palatine shelves
 - Palatine shelves grow toward midline and superiorly
 - Over developing tongue
 - Lateral palate shelves fuse
 - Medially with each other
 - Anteriorly with primary palate
 - Superiorly with nasal septum
 - Neural crest cells concurrently ossify palate
 - Posterior portion is without bone (soft palate)

MANDIBLE AND EARS**Mandible**

- 4th-8th week of embryonic life
- Jaw is 1st part of face to form
- Paired mandibular prominences
 - Caudal boundary of primitive mouth
 - Fuse medially by end of 4th week
- Part of Meckel cartilage migrates
 - Forms incus and malleus of middle ear

Ears

- 4th-8th week of embryonic life
- Inner ear arises from hindbrain
- Middle ear arises from 1st pharyngeal pouch
- External ear from 1st branchial groove
 - Inferior and dorsal to mandibular prominence
 - Early ears are located in upper part of future neck
 - Migrate lateral and superior as mandible develops
 - Auricle from 6 swellings (hillocks)

EYES**Lens Placode**

- Forms on FNP during 3rd week
- Induced by optic vesicles
 - From forebrain
 - Becomes lens vesicle and final lens of eye
- Form optic cups
 - Large at 1st, then invaginate

Orbits

- From mesenchyme that encircles optic vesicle
 - Neural crest cells
- Walls of orbit from 7 skull bones
 - Superiorly: Frontal bone
 - Inferiorly: Maxilla, zygomatic
 - Medially: Frontal, lacrimal, maxilla

- Lateral: Zygomatic, frontal

LYMPHATICS

Lymph Sacs

- Begin to develop at end of 5th week
 - 2 weeks after cardiovascular system
- Develop alongside vessels
- Lymph sacs form from fusion/dilatation of adjacent mesenchymal spaces
- **6 primary lymph sacs**
 - **Paired jugular lymph sacs**
 - Subclavian and internal jugular vein junction
 - Drain head, neck, thorax, upper extremities
 - **Cisterna chyli**
 - Lymph sac below diaphragm
 - Along posterior abdominal wall
 - **Retroperitoneal (mesenteric) lymph sac**
 - Root of mesentery
 - Posterior abdominal wall, anterior to cisterna chyli
 - **Paired iliac lymph sacs**
 - Junction of iliac and posterior cardinal veins
 - Drain abdominal wall, pelvis, lower extremity
 - Joins cisterna chyli
- Lymph sacs eventually become groups of lymph nodes
 - Exception is superior cisternal chyli
- Lymphatic vessels grow out from lymph sacs and make connections with venous system

Thoracic Duct

- 2 channels connect jugular sacs with cisterna chyli
 - Right and left thoracic ducts
- Anastomosis and attrition occurs between paired ducts
- Final thoracic duct anatomy
 - Superior part from left duct
 - Central part from anastomosis
 - Caudal part from right duct
- Variations of thoracic duct anatomy common

EMBRYOLOGY OF COMMON ANOMALIES

Cleft Lip and Palate

- **Isolated cleft lip**
 - Involves lip ± primary palate
 - Incisive foramen is boundary of 1° and 2° palate
 - Secondary palate intact
 - Maxillary prominence fails to unite with nasal prominence
 - Results in persistent labial groove
 - Rare cases
 - Median isolated cleft lip
 - Bilateral isolated cleft lip
- **Cleft palate ± cleft lip**
 - Failure of lateral palatine processes fusion
 - Nonunion with each other
 - Nonunion with nasal septum
 - Most often involves lip and 1° and 2° palate
 - Isolated cleft palate (intact lip and 1° palate)
 - Posterior to incisive foramen
- **Rare facial clefts**
 - Median cleft of mandible

- Lateral or transverse facial cleft
 - From mouth toward ear
- Oblique facial cleft
 - Upper lip to medial margin of orbit

Eye Anomalies

- Hypertelorism and hypotelorism
 - Optic migration follows forebrain migration
 - Holoprosencephaly: Hypotelorism, cyclopia
 - Associated with craniofacial dysostosis
 - Hypertelorism
- Absent or small eye/orbit
 - Failure of optic vesicle or lens placode to form

Hypognathia

- Insufficient 1st branchial arch
 - From poor neural crest cell migration
- Syndromes
 - Pierre Robin syndrome
 - Hypoplasia of mandible
 - Cleft palate + ear anomalies
 - Treacher Collins syndrome
 - Mandibulofacial dysostosis
 - Eye and ear anomalies

Ear Anomalies

- Low-set ears
 - Ear migration follows mandible development
 - Small chin associated with low-set ears
- Abnormal hillock development
 - Auricular appendages (tags)
 - Ear duplication
 - Anotia (absent ear), microtia (small ear)

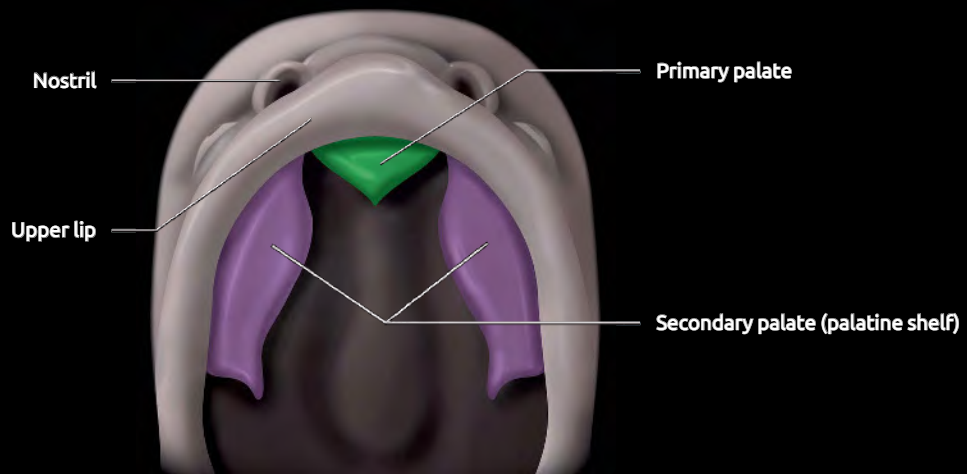
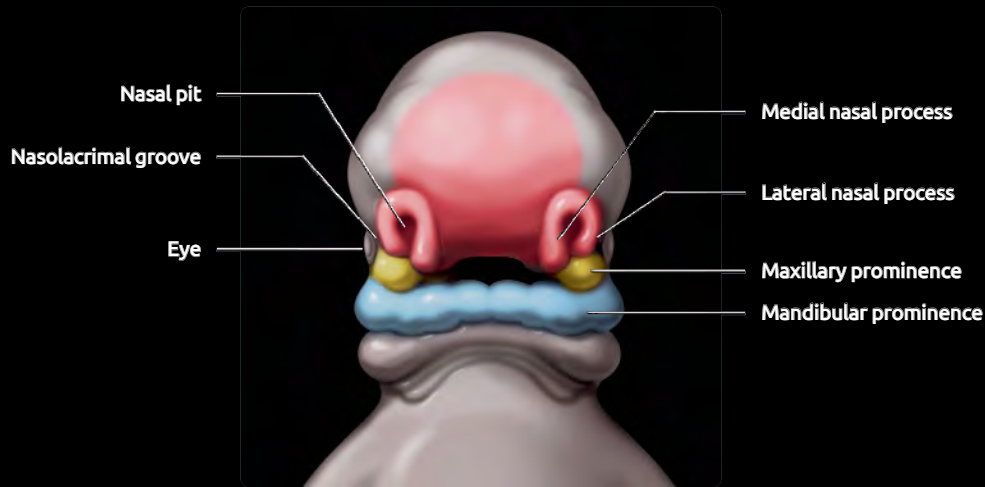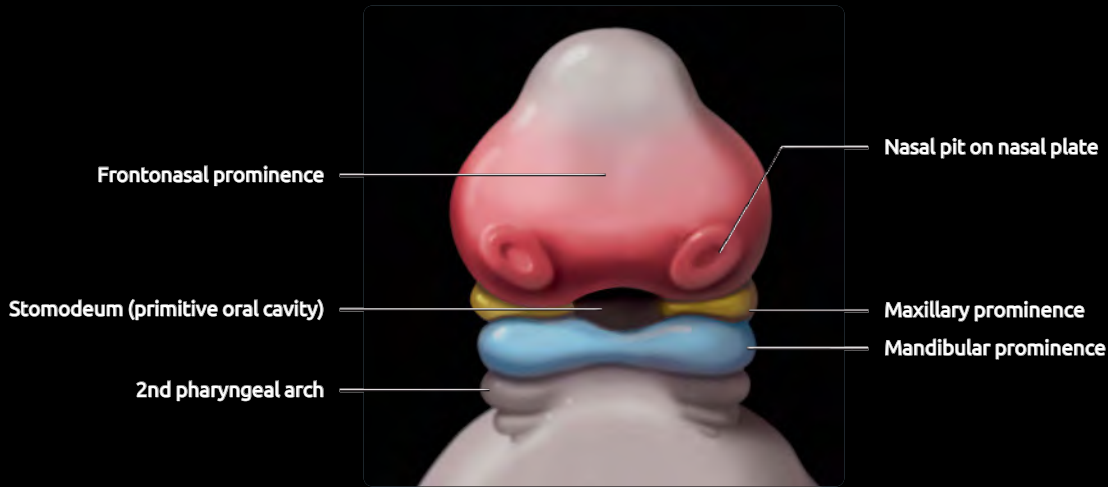
Nose and Mouth Anomalies

- Congenital microstomia (small mouth)
 - Excessive merging of mesenchymal masses
- Absent nose
 - Paired nasal placodes do not form
- Single nostril
 - Only 1 nasal placode forms
- Bifid nose
 - Medial nasal prominences do not merge completely

Lymphangioma

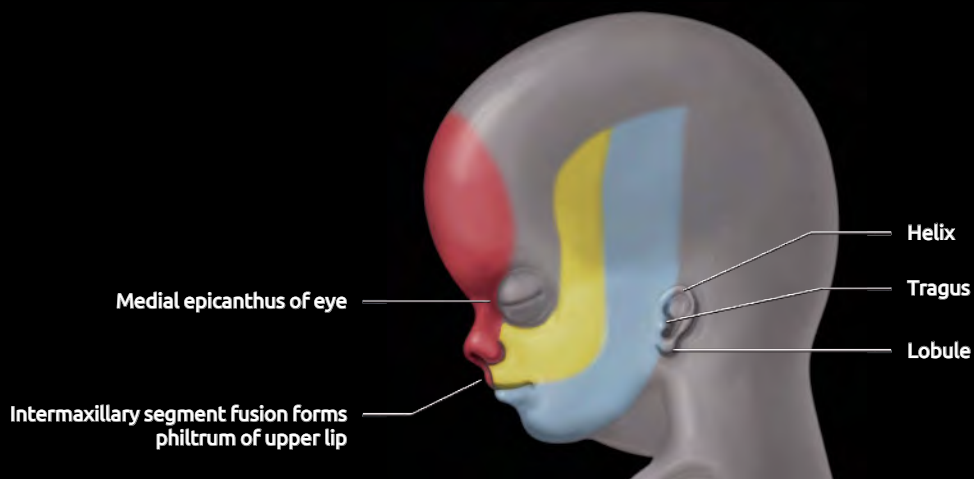
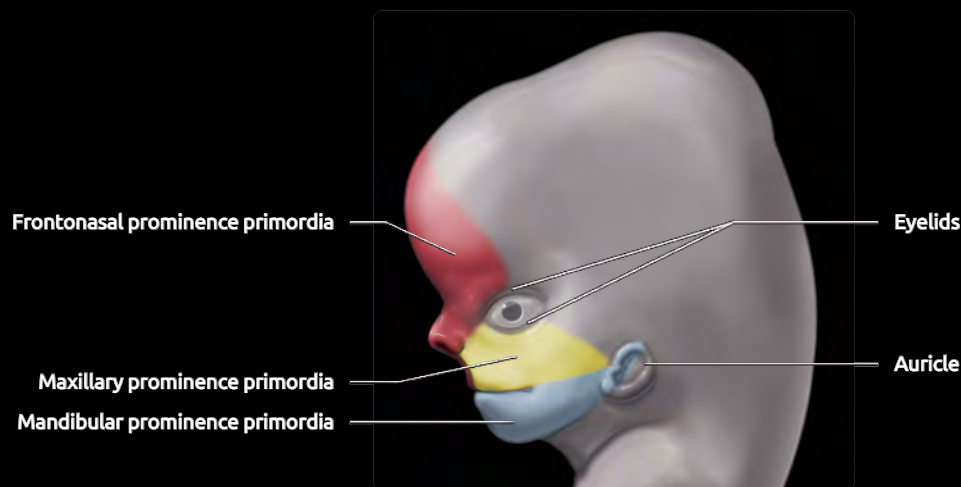
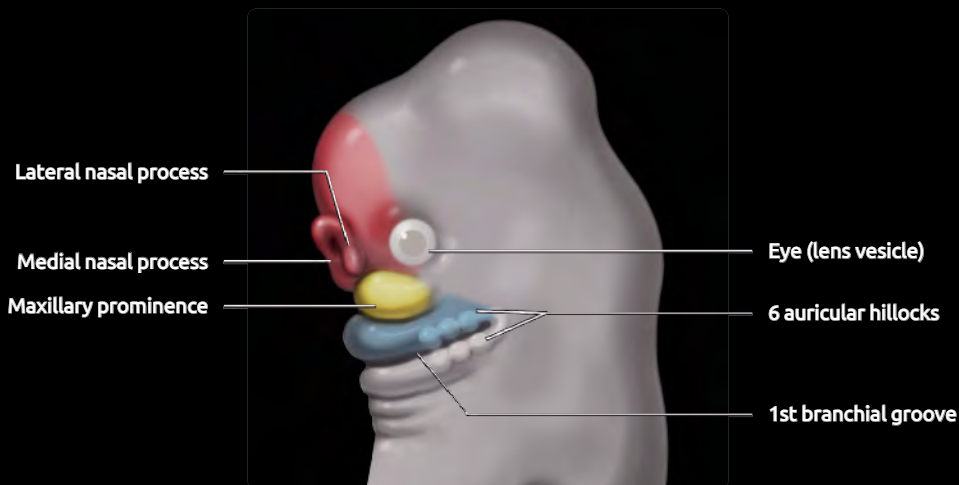
- Dilated primitive lymphatic channels
 - Diffuse congenital lymphedema
 - Focal cystic mass
- Cystic hygroma
 - Failed jugular sac → venous connection
 - Primary fluid collection in dorsal and lateral neck
 - Multiseptated fluid
 - Associated with hydrops fetalis and aneuploidy
 - Turner syndrome most common
 - Trisomy 21 is 2nd most common
- Body lymphangioma
 - Sites
 - Axillary (most common)
 - Intraperitoneal, retroperitoneal
 - Extremities
 - Often large, infiltrative cystic mass

EMBRYOLOGY OF FACE AND PALATE



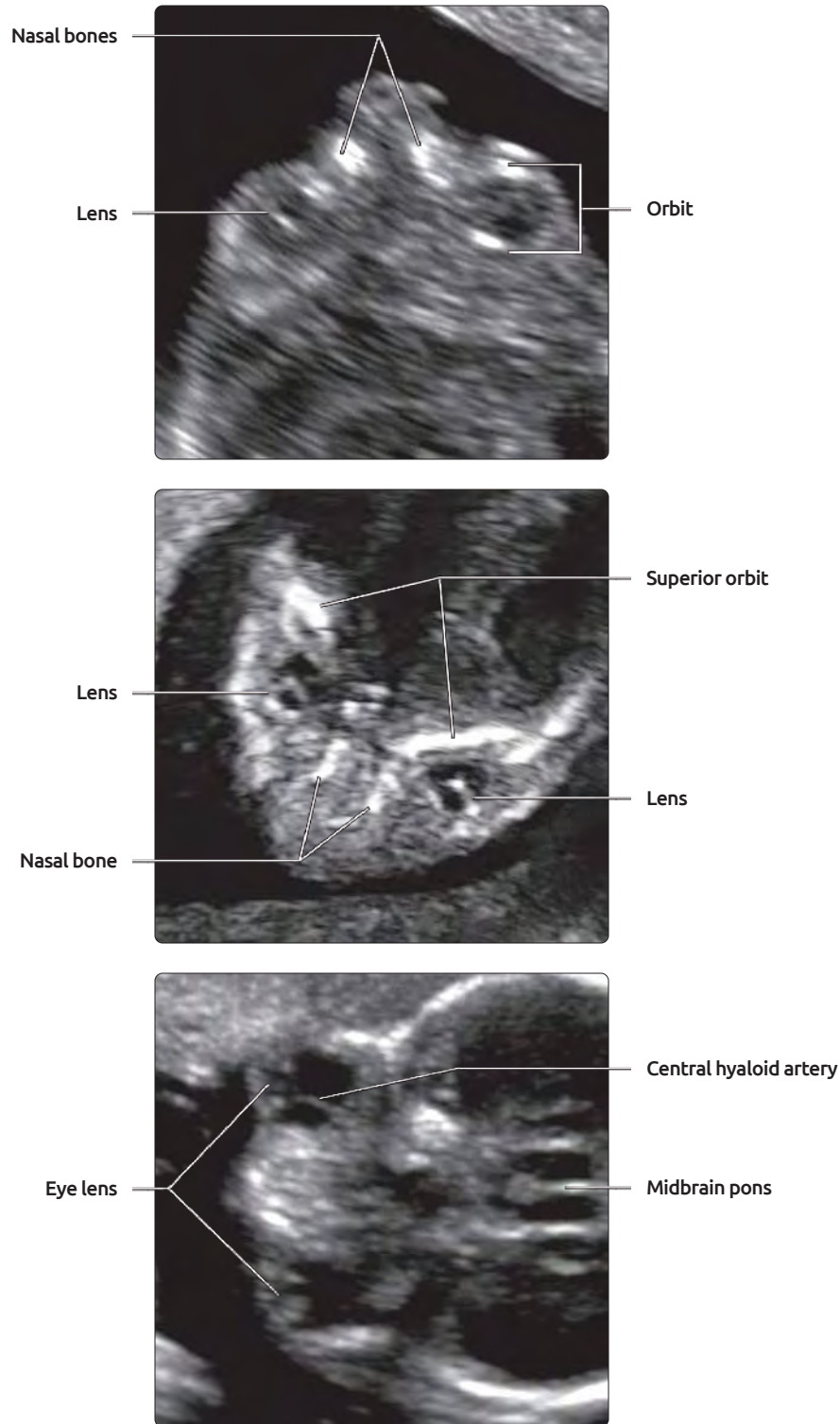
(Top) Graphic shows a coronal view of a 5-week embryo. The face forms from 5 primordia that appear in the 4th week (frontonasal prominence, 2 maxillary prominences, and 2 mandibular prominences). By the 5th week, the mandibular prominences have fused. Nasal pits form on a pair of ectodermal thickenings, the nasal plates. **(Middle)** Graphic shows a coronal view of a 6-week embryo. Invagination of the nasal pits has occurred. Medial nasal processes will fuse to form an intermaxillary process and, subsequently, the upper lip philtrum. In addition, the maxillary prominences will fuse with the intermaxillary process to form an intact upper lip. **(Bottom)** Graphic shows an axial view of the palate at 7-8 weeks. The primary palate arises dorsally from the intermaxillary process, and the secondary palate originates from the maxillary prominence. Complete fusion occurs by the 10th week.

EMBRYOLOGY OF FACE AND EAR



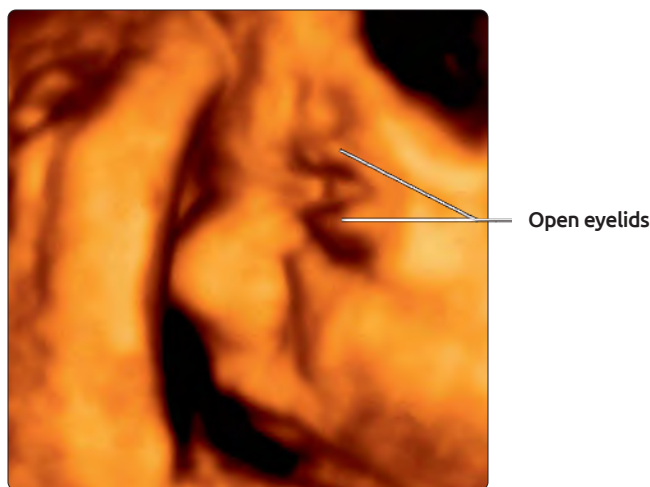
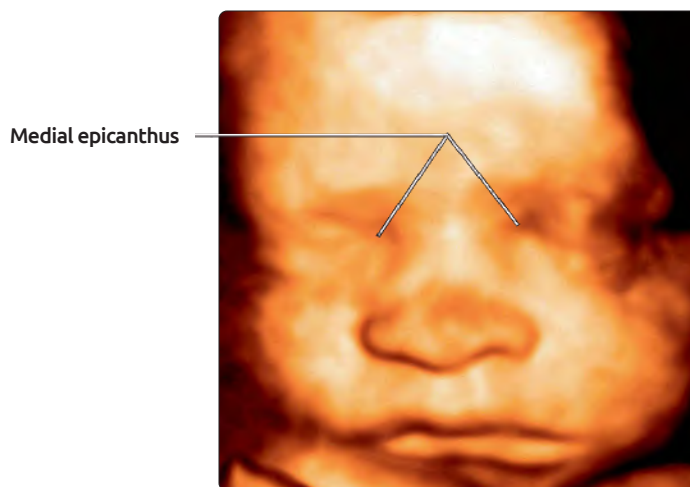
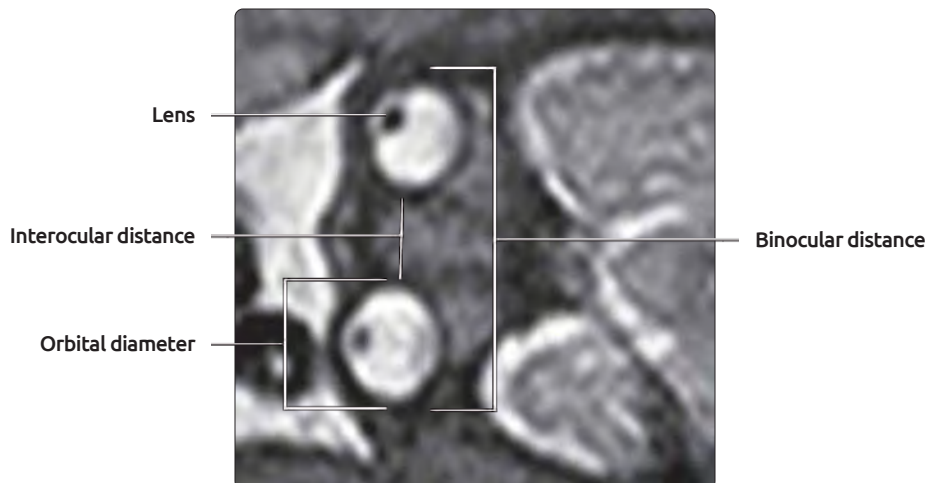
(Top) Graphic of a 5-week embryo profile shows the lateral and medial nasal processes, not yet fused with the maxillary prominence. Arising from the 1st and 2nd pharyngeal arches, the auricular hillocks of the external ear flank the 1st branchial groove. **(Middle)** Graphic of a 10-week embryo profile shows the development of eyelids and the external ear. The ear position is medial and low at this time. As the mandible grows, the ear migrates superiorly. **(Bottom)** Graphic of a 14-week fetus profile shows that the philtrum of the lip has formed from fusion between the paired medial nasal processes. The philtrum and maxillary prominences have also fused. The ear is now at its final location with the top of the helix at the same level as the medial epicanthus of the eye.

EYES



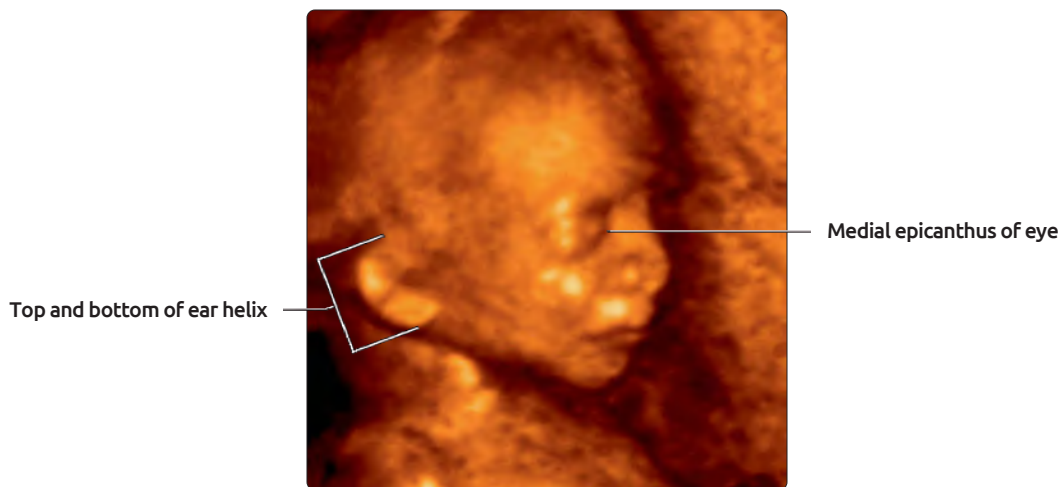
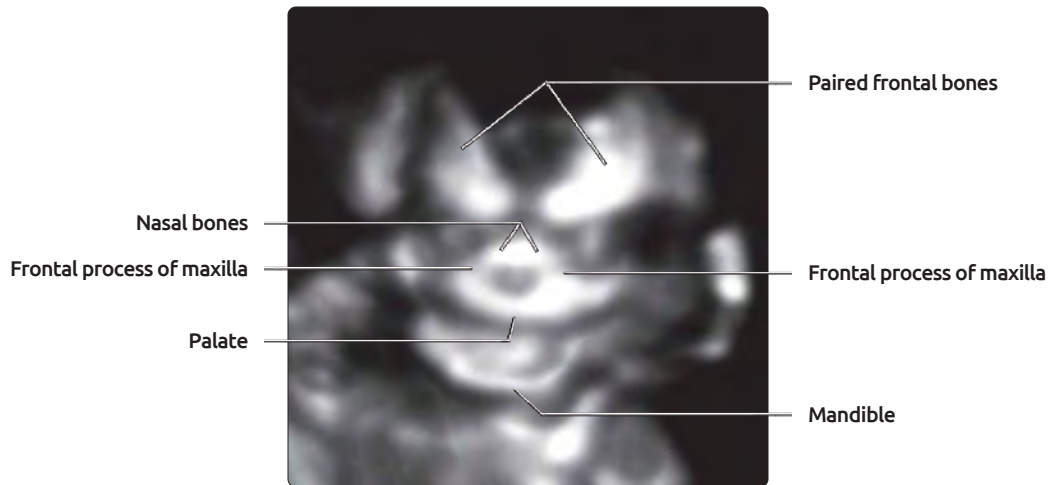
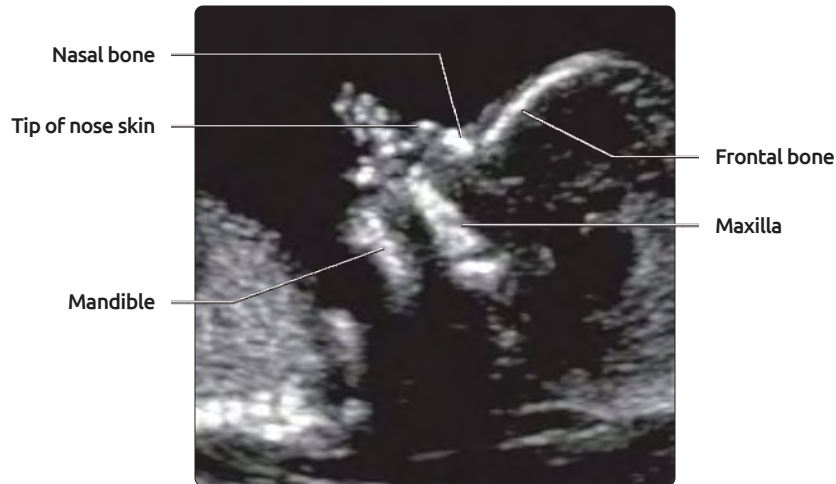
(Top) Transvaginal axial ultrasound through the orbits of a 12-week fetus shows paired nasal bones and normal-sized orbits. The lens of the eye can be seen even at this early gestational age. **(Middle)** Coronal transvaginal ultrasound of a 13-week fetus shows the frontal bones and nasal bones contributing to the superior and medial borders of the bony orbit. The eyes and lens are once again seen very well. **(Bottom)** Axial ultrasound through the eyes in an early 2nd-trimester fetus shows the normal central hyaloid artery, which is located within the hyaloid canal. This artery supplies nutrients to the developing lens and is a normal finding at this time, usually regressing during the 3rd trimester.

EYES



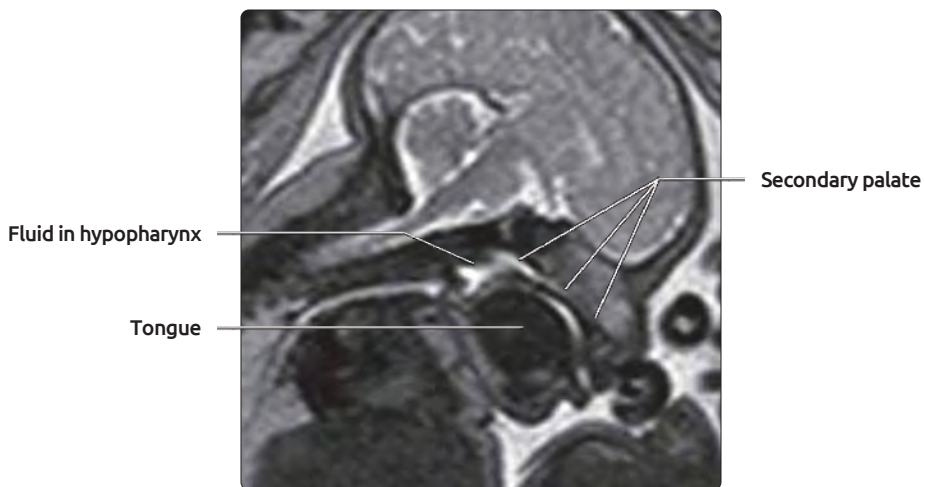
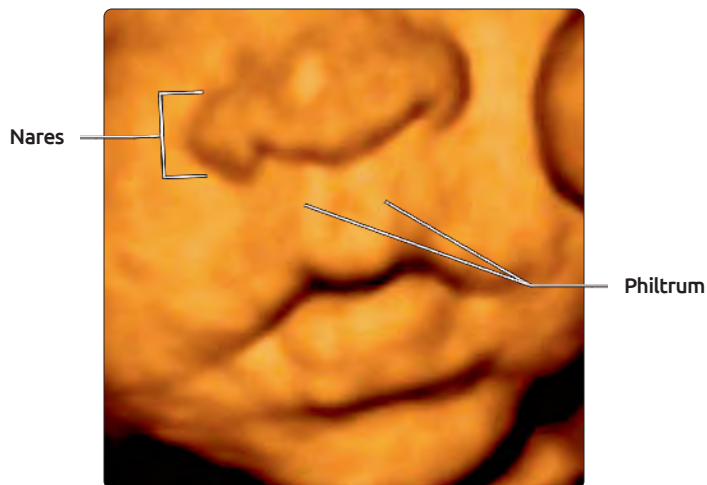
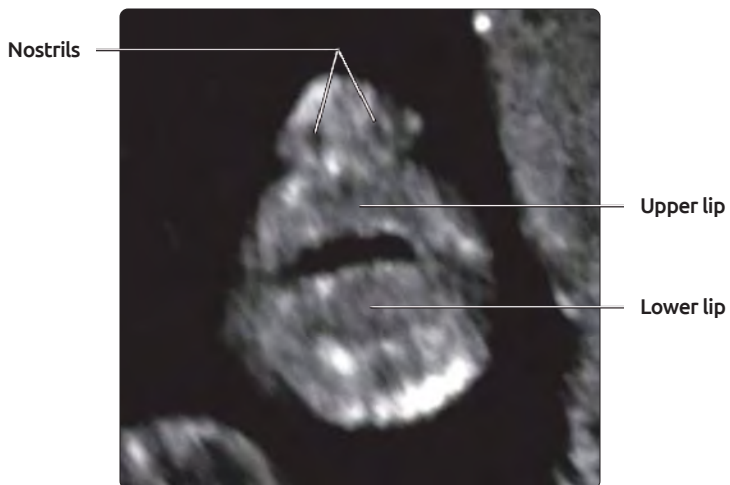
(Top) Axial T2WI MR of a late 2nd-trimester fetus shows the orbits. MR or ultrasound can be used to measure the globe diameter, interocular distance, and binocular distance. The lens of the eye is low signal on MR. **(Middle)** 3D ultrasound of a 3rd-trimester fetal face shows the eyes, nose, and lips. The interocular distance and the medial epicanthus of the eyes are seen well. **(Bottom)** 3D ultrasound of a fetal profile shows open eyes. In the 3rd trimester, it is common to see the eyes open and close. In addition, globe movement is also commonly seen with real-time imaging.

NOSE



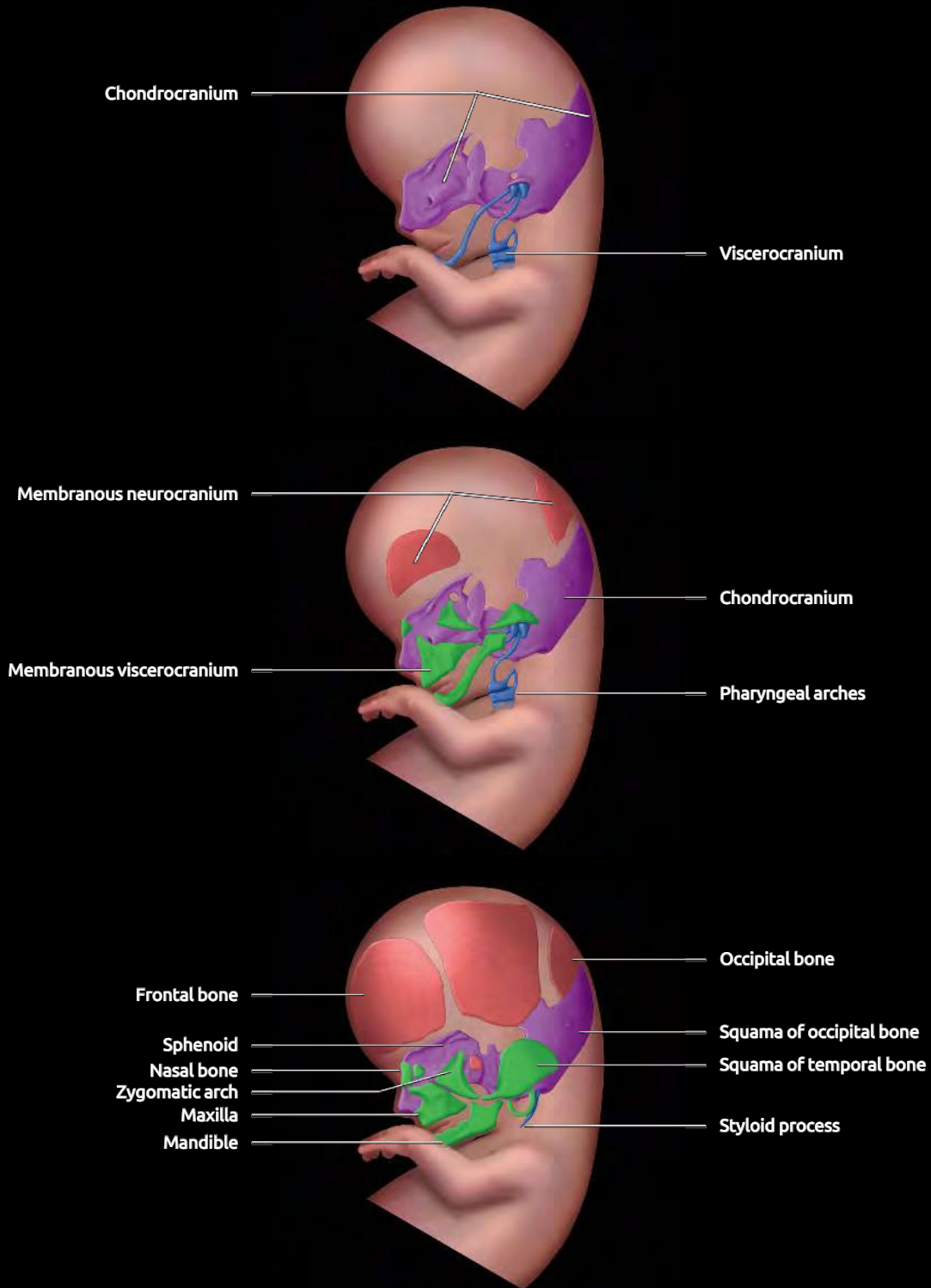
(Top) Sagittal ultrasound of a 12-week fetus shows a normal nasal bone. The echogenic nasal bone is as bright as the frontal bone, and it is seen separately from the nasal skin. **(Middle)** 3D ultrasound with skeletal reconstruction of a 13-week fetus shows the retranasal triangle view comprised of the paired nasal bones superiorly, the frontal process of the maxilla laterally, and the inferior primary palate. **(Bottom)** 3D ultrasound profile view that includes the nose, eye, and ear shows normal relationships. The top of the helix should be at the same height as the medial epicanthus of the eye.

LIPS AND PALATE



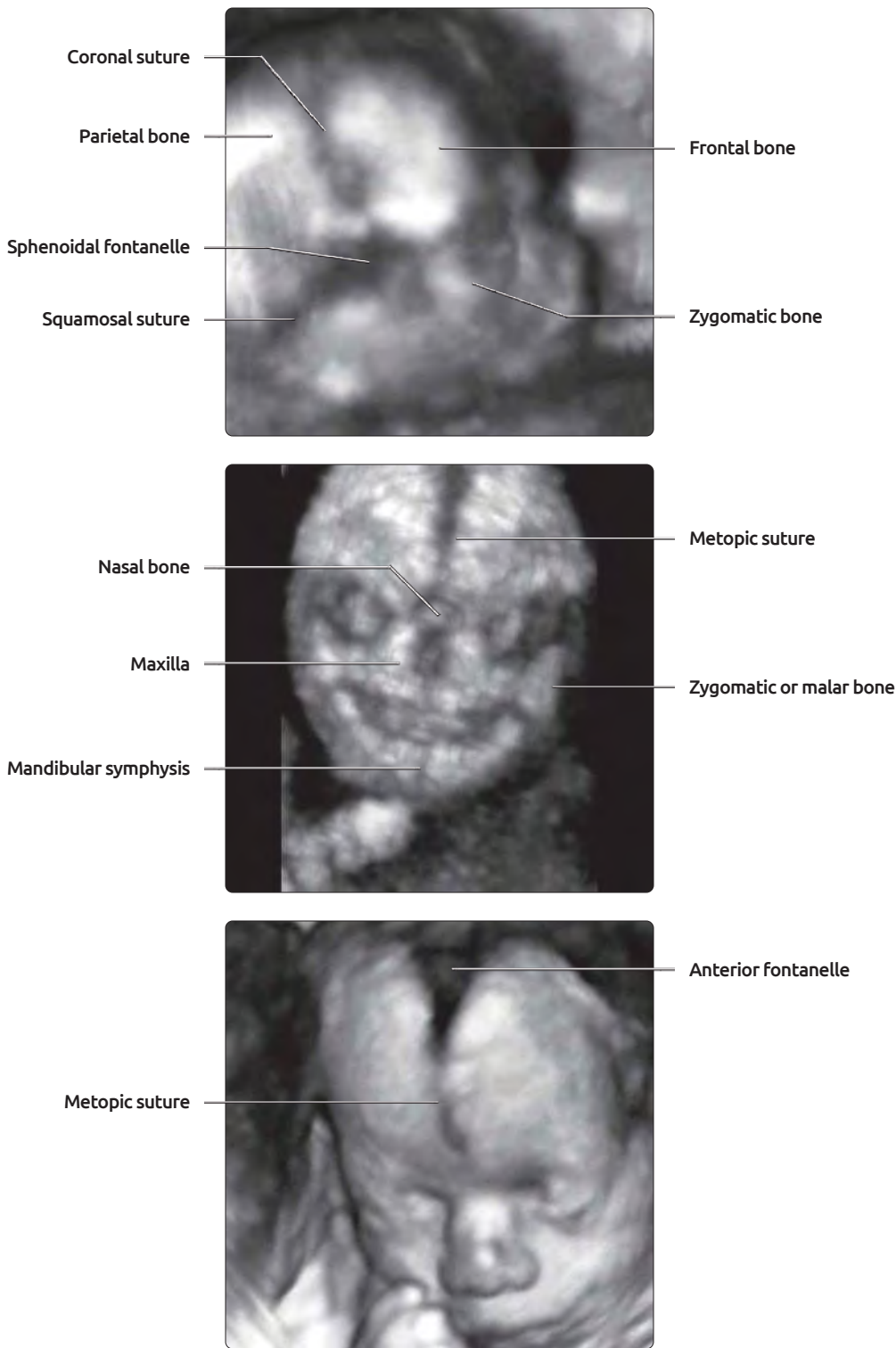
(Top) Coronal ultrasound through the nose and lips shows the nostrils and intact upper lip. This view is considered standard for anatomy scans. **(Middle)** 3D ultrasound with soft tissue reconstruction shows the normal rounded nares of the nose and the intact philtrum of the upper lip. **(Bottom)** T2WI MR of a 30-week fetus shows an intact secondary palate. A sliver of high-signal fluid in the mouth, superior to the tongue, provides excellent contrast, allowing for visualization of the palate. The fluid-filled hypopharynx is also seen extending down to the upper trachea.

SKULL AND FACIAL BONES



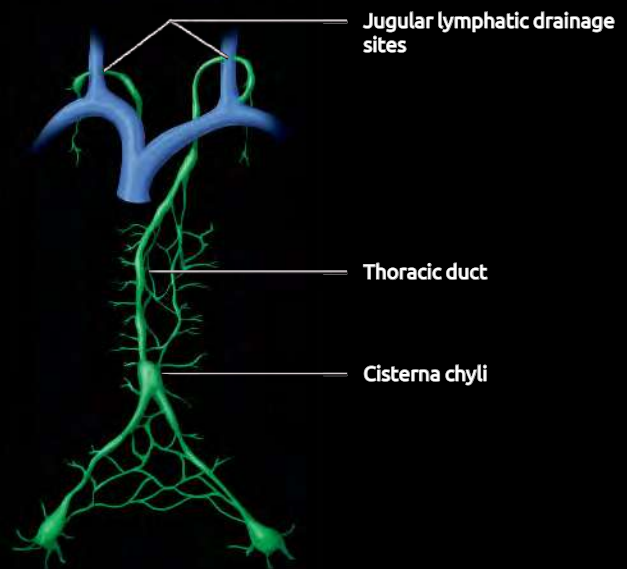
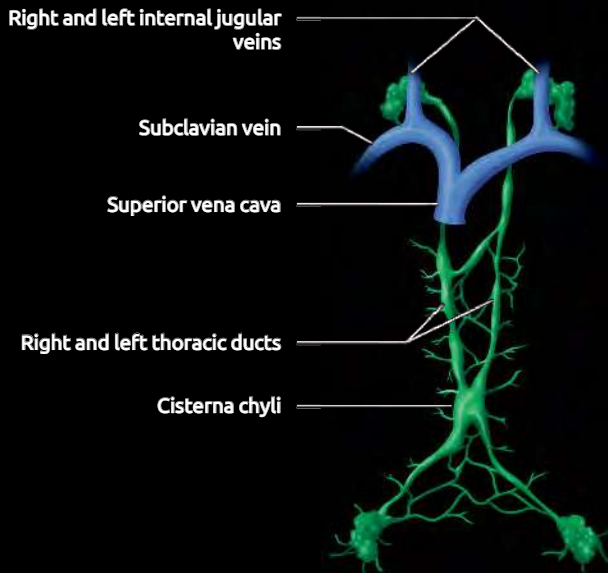
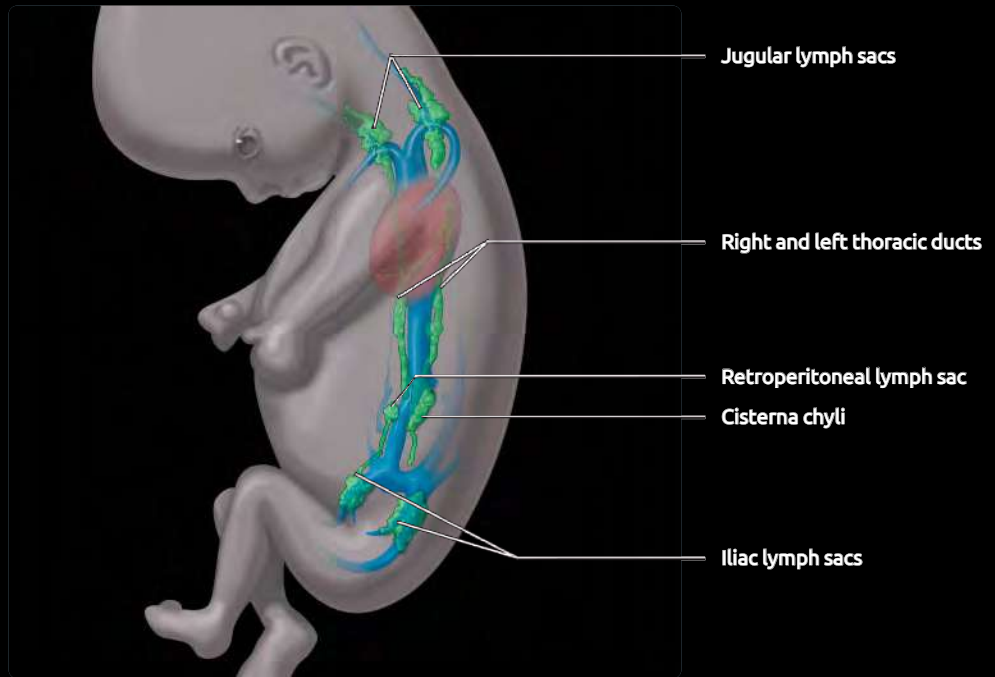
(Top) Graphic shows the cartilaginous skeleton of the embryonic head. Purple represents the developing chondrocranium; blue represents the developing viscerocranium of the pharyngeal arches. The chondrocranium arises from the notochord and is the forerunner of the skull base. The viscerocranium, derived from the pharyngeal arches, gives rise to the facial bones. **(Middle)** The chondrocranium and portions of pharyngeal arches ossify as the membranous neurocranium (protective case around the brain) and the membranous viscerocranium develop. **(Bottom)** Final development of cranial bones from chondrocranium, pharyngeal arches, membranous viscerocranium, and membranous neurocranium is shown.

SKULL AND SUTURES



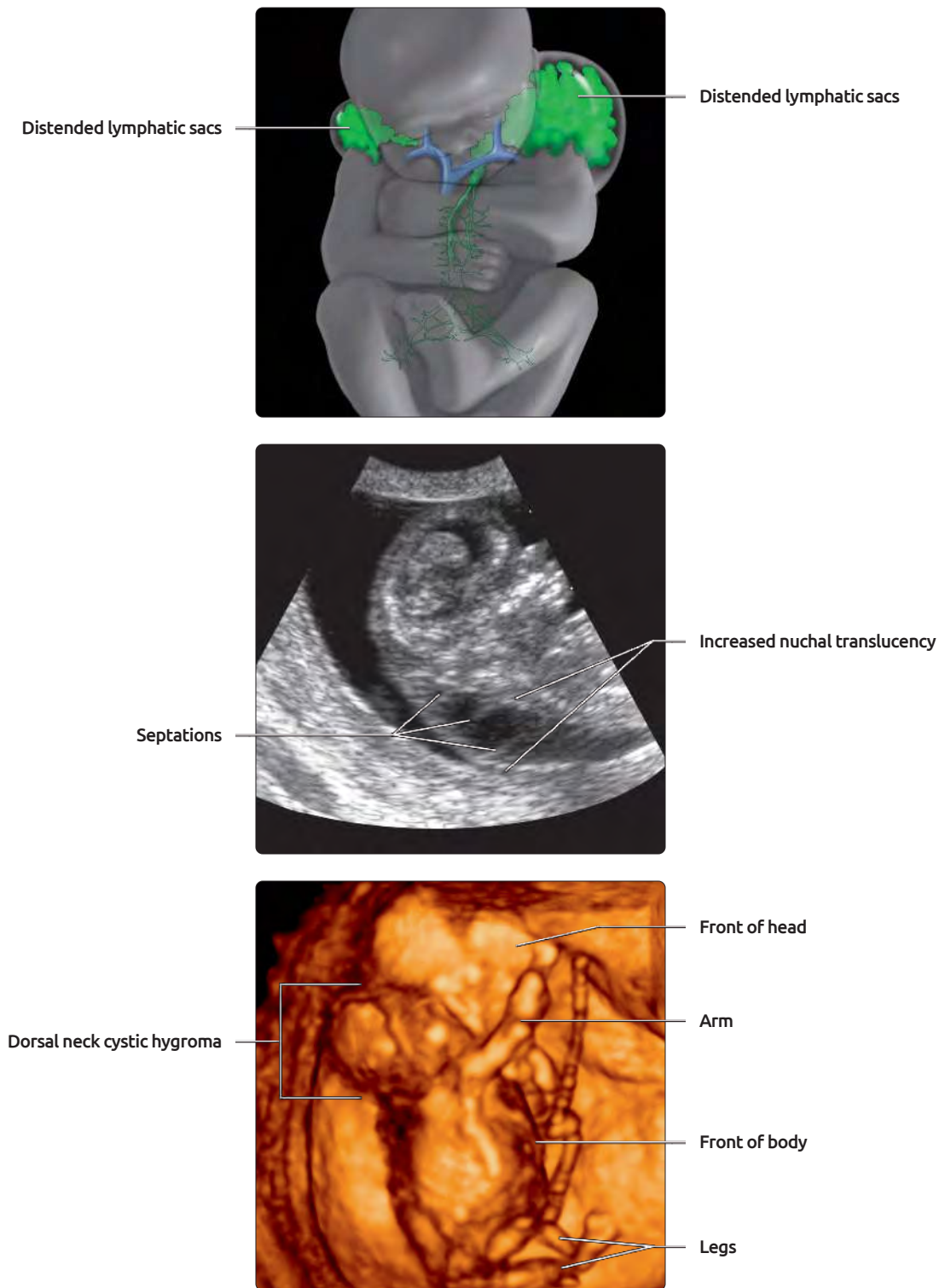
(Top) 3D ultrasound of an 18-week fetus profile shows normal skull and suture anatomy. **(Middle)** Coronal 3D ultrasound with skeletal reconstruction of a 20-week fetus shows normal skull bones and sutures. **(Bottom)** 3D ultrasound of an early 3rd-trimester fetus shows the anterior fontanelle and metopic suture.

LYMPHATIC SYSTEM EMBRYOLOGY



(Top) Graphic of a 6- to 7-week embryo shows lymph sacs that collect lymph fluid before venous connections are established. Lower extremity and body lymph fluid drain into external and internal iliac veins. **(Bottom)** Graphic of the lymphatic system at 7 weeks (left) and 17 weeks (right) shows that, originally, there are paired thoracic ducts. In most embryos, the caudal left and cranial right ducts atrophy, resulting in a thoracic duct that crosses the midline. Upper body lymphatic drainage occurs mostly at the venous connection near the jugular-subclavian vein junction.

CYSTIC HYGROMA



(Top) Graphic of cystic hygroma shows massively distended jugular lymph sacs secondary to failure of establishment of venous connections at the jugular drainage site. **(Middle)** Sagittal ultrasound of a 12-week fetus shows cystic hygroma. The nuchal translucency is markedly increased and contains septations. **(Bottom)** 3D ultrasound of a 13-week fetus shows posterior neck cystic hygroma. This fetus was found to have Turner syndrome.

Introduction

For the patient, imaging of the fetal face is one of the most anticipated parts of the ultrasound exam. Indeed, viewing the face has been shown to improve bonding with the fetus. With 3D ultrasounds, a single image of the complete fetal face, like a photograph, instantly shows everyone in the ultrasound suite that the fetus has a normal face. However, in order to adequately evaluate the fetal face and neck, standard views and normative data of facial and neck structures have been developed. Recent publication of an executive summary of fetal imaging with buy-in from most US imaging societies only includes documentation of the fetal upper lip as part of the fetal face survey. However, many ultrasound centers also obtain standard views of the fetal profile, nasal bone, and orbits. Additional views of the ears, neck, and jaw are recommended when fetuses are at risk for anomalies of these structures or if abnormalities are otherwise noted during scanning. More recent publications also have demonstrated that some anomalies of the fetal face can be seen at the time of nuchal translucency (NT) assessment in the late first trimester.

Imaging Techniques and Normal Anatomy

Nose and Lips

The standard view for imaging the upper lip is the **angled coronal nose-mouth view** ("snout view"). The transducer is angled so that the nostrils, tip of nose, and soft tissue of the upper lip are seen well. A normal image will show rounded nares and an intact upper lip. If a cleft lip is present, additional views of the maxilla are necessary to see if there is an associated cleft palate.

The nose is also evaluated with a standard facial **profile view**. A nasal bone should be present in the first trimester and measurable in the second and third trimesters. Normative data tables for nasal bone length have been published. A short nasal bone, midface anomalies, and small mandible are all anomalies that may be detectable with this view.

Mandible, Maxilla, and Midface

Most midface and mandible anomalies are clearly identifiable on the facial **profile view**, but if the finding is mild or the operator is not sure if the midsagittal view is normal, objective measurements can be made. The **maxilla-nasion-mandible (MNM) angle** is measured between a line from the nasal bone attachment to the skull → anterior maxilla and a line from the same nasal bone attachment → anterior mandible. Between 16-36 weeks, this angle is 13.5° (95% confidence interval of 13.3-13.8°; range 9-19.6°). ↑ MNM angle is associated with retrognathia, hypognathia, or maxillary protrusion. ↓ MNM angle is associated with midface hypoplasia (as seen with trisomy 21, Apert syndrome, thanatophoric dysplasia, and other syndromes).

Direct **mandible measurements** can also be compared to nomograms. On an axial view of the mandible at the level of the temporomandibular joint, a symmetric triangle is formed by the mandibular arms. The transverse and anterior-posterior diameter is measured (inner point to inner point) on this view.

An intact **maxilla** can be seen on the profile view even at the time of NT screening (any defect > 1.5 mm is suspicious for a palate defect). Cleft palate is highly associated with cleft lip and further imaging in axial and coronal planes is indicated. Soft tissue palate defects as isolated findings are often missed

but are suspected if the fetal jaw is small. MR and 3D ultrasound are additive.

Eyes

The standard view to evaluate the eyes is the **axial orbital view**, and for many labs, it is routinely obtained for anatomy surveys. If hypotelorism or hypertelorism is suspected, the binocular distance and interocular distance can be measured from this view. In addition, attention should be paid to the eye itself. The eye can be measured and the lens is easily identifiable. The central hyaloid artery is normally seen in the second trimester and usually regresses during the third trimester. Fetuses routinely open and close their eyes in the third trimester and, of course, 3D ultrasound shows the eyes very well.

Ears

Ear growth is linear through gestation. **Ear length** can be measured in the sagittal or coronal planes and compared with published normative data. Normal ear length is approximately 1/3 the biparietal diameter. The position of the ear can also be assessed with 2D or 3D ultrasound; the top of the helix should be at the level of the medial inner canthi line of the eyes. Low-set ears are most often associated with hypognathia. Abnormal ear morphology is seen best with 3D ultrasound.

Neck

The neck is not routinely evaluated during the anatomy scan, but since neck masses tend to be large, they are noticed by the sonographer during routine scanning of the face and chest. Orthogonal views of the neck and mass should be obtained and the mass measured in this scenario. In addition, some fetuses are at risk for goiter and it may be helpful to identify and measure the fetal thyroid gland. The **axial thyroid gland view** is at the level of the maximum diameter of the gland. The central airway and peripheral neck vessels can be identified on this view. A thyroid circumference can be measured and compared to normative data. Additional coronal and sagittal views are helpful if a goiter is present.

Approach to Face and Neck Anomalies

When Is 3D Ultrasound Helpful?

3D ultrasound is helpful for better visualization of normal anatomy. For example, if a profile view is inaccessible but a coronal face view can be obtained, the 3D sweep on the coronal face will result in orthogonal multiplanar views. The midsagittal view, in that case, can serve as the standard profile view. An axial reconstruction can be used to look at the eyes.

3D ultrasound is also a powerful tool for better visualizing facial anomalies. The sonologist can look at the anomaly from several different angles and better assess depth of cleft defects, such as palate involvement with cleft lip. The patient can better understand the anomaly by seeing the surface-rendered face view, and many maxillofacial surgeons appreciate the 3D views if the patient seeks prenatal consultation.

When Is Fetal MR Helpful?

The superior soft tissue differentiation of MR and absence of artifact from bone allows for better evaluation of the deep structures of the mouth and neck. Fetuses at risk for **isolated cleft palate** may benefit from fetal MR. In addition, fetuses with **neck masses**, such as teratoma, lymphangioma or large goiter, may benefit from MR in order to better assess fetal airway patency.

Ocular and Orbit Diameters (mm)

GA (wk)	BOD, Mean (5th-95th Percentile)	IOD, Mean (5th-95th Percentile)	Orbit, Mean (10th-90th Percentile)
18	28 (22-37)	11 (7-16)	7.3 (6.2-9.0)
20	33 (26-41)	12 (8-17)	9.8 (8.6-11.3)
22	37 (30-44)	14 (9-18)	10.4 (9.5-11.3)
24	41 (33-48)	15 (10-19)	11.6 (10.7-12.5)
25	43 (35-50)	16 (10-19)	11.2 (10.3-12.6)
26	44 (36-51)	16 (11-20)	12.7 (11-14.5)
27	46 (38-53)	17 (11-20)	13.0 (11.9-14.8)
28	47 (39-54)	17 (12-21)	13.0 (12.1-14.1)
29	48 (41-56)	18 (12-21)	13.9 (12.6-15.7)
30	50 (42-57)	18 (13-22)	14.2 (13.3-15.4)
31	51 (43-58)	18 (13-22)	14.2 (13.3-15.4)
32	52 (45-60)	18 (14-23)	14.4 (12.2-17.5)
34	54 (47-62)	19 (15-24)	15.8 (14.6-16.9)
36	56 (49-64)	20 (16-25)	15.8 (14.6-16.9)

BOD = binocular diameter; IOD = interocular diameter; orbit = orbit diameter. Modified from Mayden KL et al: *Orbital diameters: a new parameter for prenatal diagnosis and dating. Am J Obstet Gynecol. 144:289, 1982, and from Goldstein I et al: Growth of the fetal orbit and lens in normal pregnancies. Ultrasound Obstet Gynecol. 12:175-179, 1998.*

Mandible Measurements (mm)






GA (wk)	Transverse Diameter, Mean (2 S.D. Range)	AP Diameter, Mean (2 S.D. Range)
11-13	9.4 (5.9-12.9)	6.0 (4.0-8.0)
14	13.4 (10.5-16.2)	8.7 (6.3-11.1)
16	17.3 (13.7-30.0)	10.5 (8.5-12.6)
17-18	18.5 (15.1-21.8)	11.3 (9.4-13.2)
19-20	20.9 (15.8-26.1)	13.4 (9.1-17.6)
22	26.7 (20.3-33.1)	17.6 (13.5-21.8)
24	29.5 (22.9-36.0)	19.5 (15.4-23.6)
26-28	33.1 (29.5-36.7)	23.2 (17.5-28.8)
29-31	36.1 (27.2-44.9)	26.3 (22.2-30.4)

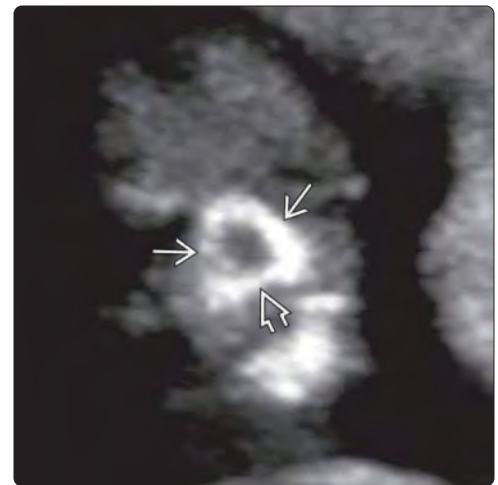
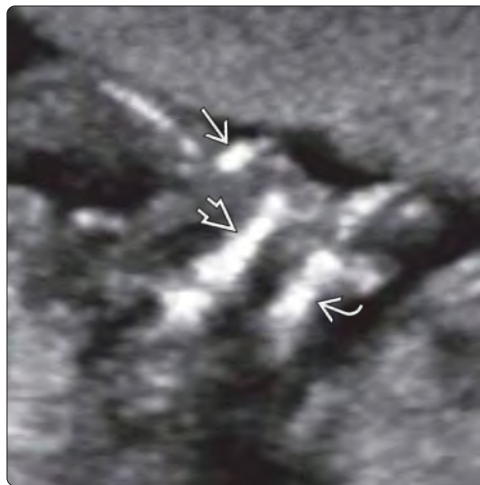
Modified from Zalel Y et al: *The fetal mandible: an in utero sonographic evaluation between 11 and 31 weeks' gestation. Prenat Diagn. 26:163-167, 2006.*



Thyroid Circumference (cm)

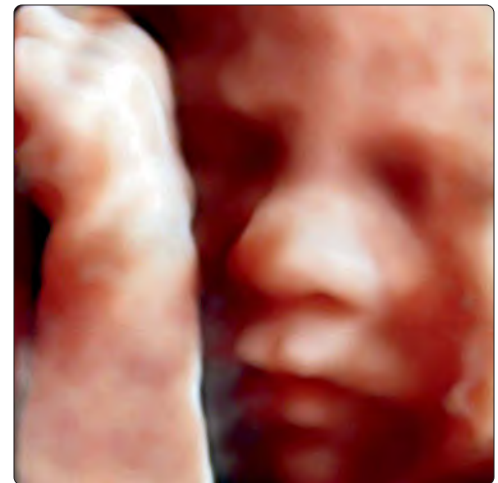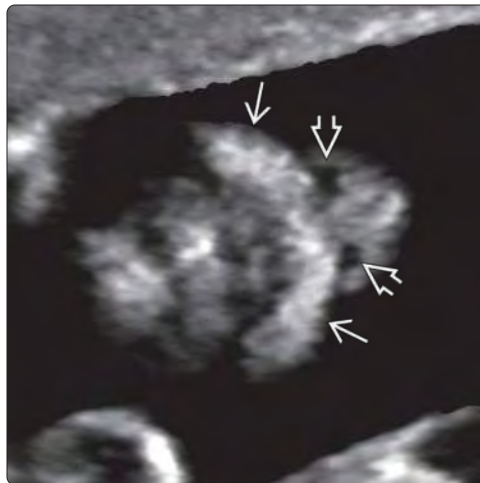GA (wk)	TC, Mean (10th-90th Percentile)	GA (wk)	TC, Mean (10th-90th Percentile)
18	2.4 (1.8-3.0)	28	3.6 (2.8-4.4)
20	2.5 (1.9-3.2)	30	4.0 (3.1-4.8)
22	2.8 (2.1-3.4)	32	4.4 (3.5-5.2)
23	2.9 (2.2-3.6)	33	4.6 (3.7-5.5)
24	3.0 (2.3-3.7)	34	4.8 (3.9-5.7)
25	3.1 (2.4-3.9)	35	4.8 (3.9-5.7)
26	3.3 (2.5-4.0)	36	5.3 (4.3-6.2)
27	3.4 (2.7-4.2)	37	5.5 (4.6-6.5)






Modified from Ranzini AC et al: *Ultrasonography of the fetal thyroid: normograms based on biparietal diameter and gestational age. J Ultrasound Med. 20:613-617, 2001.*

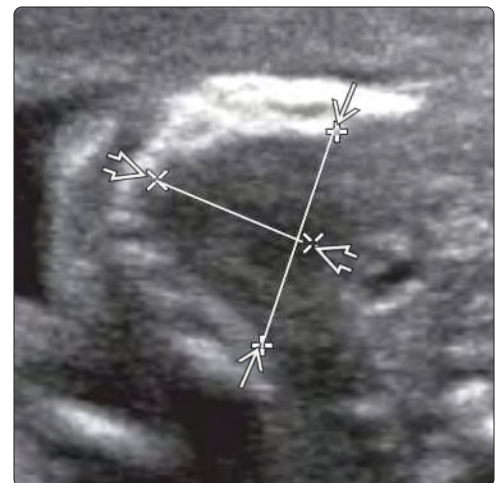
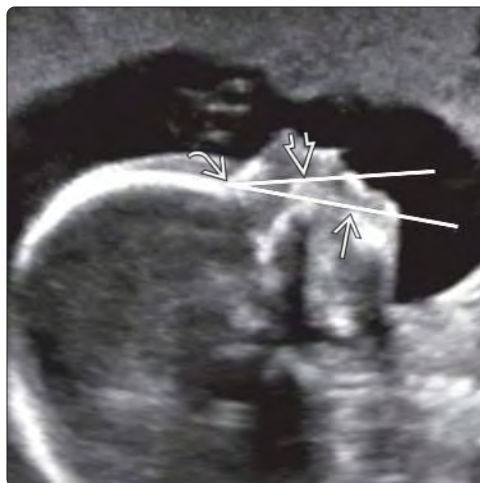
(Left) At the time of nuchal translucency (NT) screening, a normal profile view of a 13-week fetus shows a nasal bone , intact palate , and normal mandible . Facial bones are seen well on the routine sagittal image obtained for measuring the NT. **(Right)** An additional coronal view, in the same fetus, demonstrates 2 nasal bones  and confirms an intact maxilla . The "retronasal triangle" view can be used to screen for cleft palate.

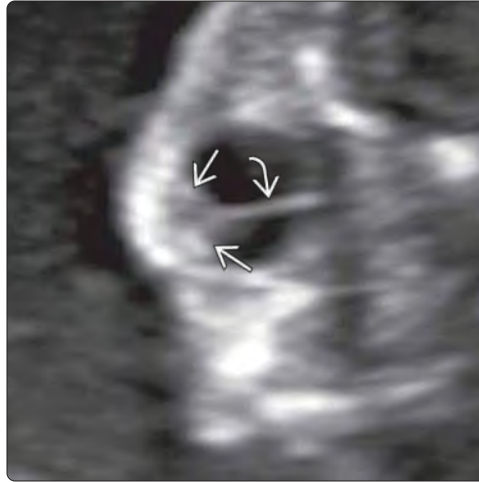
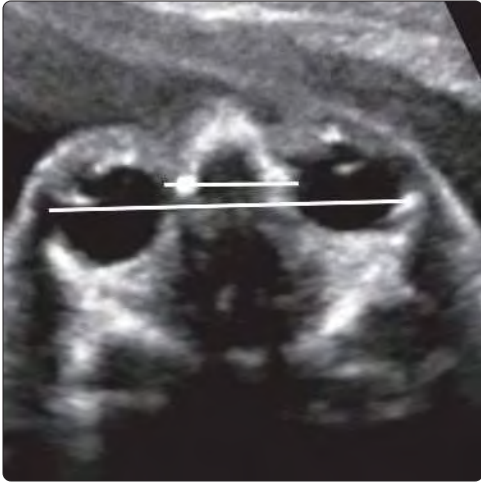

(Left) The standard nose and lip view in the 2nd and 3rd trimesters is a coronal "snout" view showing the rounded nares , tip of the nose (above the nares), and the intact upper lip . Cleft lip almost always occurs at the nares/upper lip junction or midline, between the nares. **(Right)** 3D ultrasound is also used to evaluate the nose and lips. When there is adequate fluid in front of the face and no overlying fetal parts, diagnostic and aesthetically pleasing images of the face are obtained.

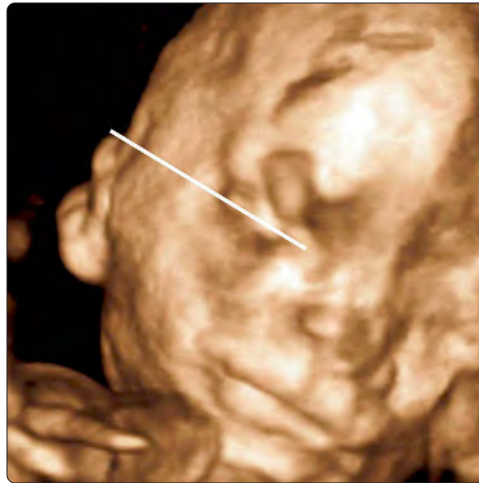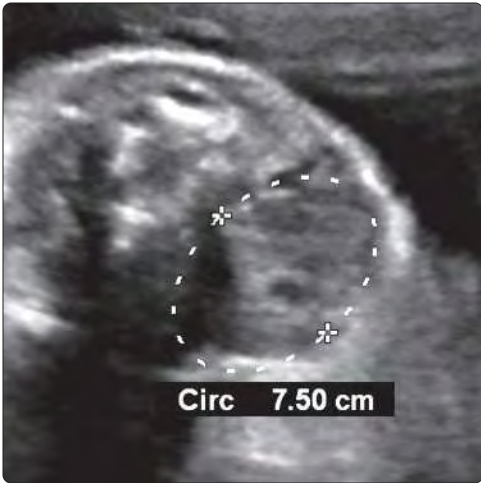


(Left) The maxilla-nasion-mandible (MNM) angle is the angle formed between a line from the nasal bone attachment to the skull  to the anterior maxilla  and a line from the same nasal point to the anterior tip of the mandible . Normal MNM angle is consistently near 13.5° (range: 9.0-19.6°). **(Right)** If hypognathia is suspected on the profile view, the axial view through the body of the mandible can be used to measure the transverse  and anterior-posterior  diameter of the mandible.

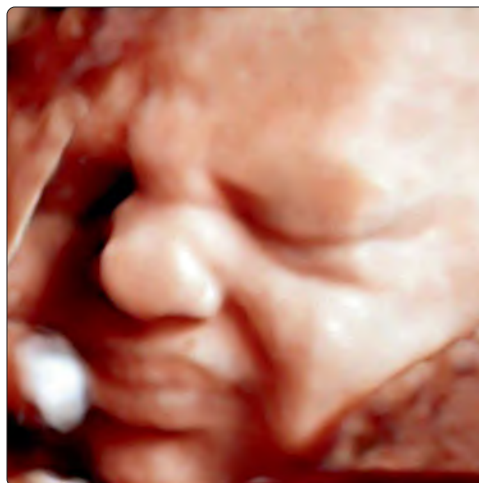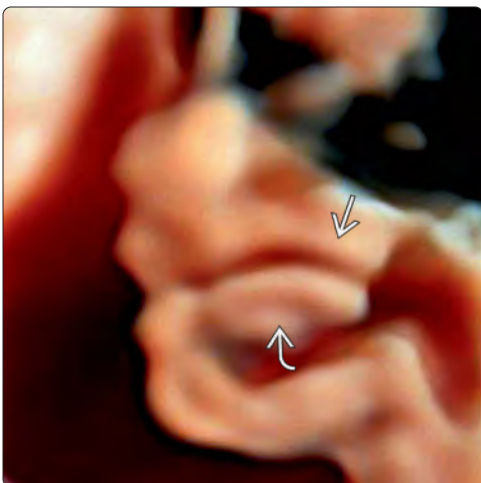




(Left) An axial US through the orbits is often routinely obtained during the anatomy scan. The binocular diameter (long line) and the interocular diameter (short line) can be measured if there is suspicion for hypotelorism or hypertelorism. By "eyeballing" it, a 3rd eye should fit between the 2 normal eyes. (Right) Axial view through the eye shows the lens [arrow]. The central hyaloid canal [arrow], carrying the central artery of the retina, is a normal finding in the 2nd trimester and usually regresses during the 3rd trimester.



(Left) In fetuses at high risk for thyroid disorders (from maternal hypothyroidism or hyperthyroidism), the fetal thyroid circumference is measured and compared to a nomogram. In this case, the thyroid circumference is 7.5 cm, too large for any gestational age. (Right) 3D ultrasound is superior to 2D for demonstrating ear morphology and position. The top of the ear should be at the level of the medial inner canthi of the eyes. Low-lying ears are associated with many syndromes and mandible anomalies.



(Left) A normal profile, tongue [arrow], & soft tissue palate [arrow] is seen in this 19-week fetus with a family history of micrognathia & cleft palate. When these structures are surrounded by fluid, 3D & multiplanar views can be diagnostic. Otherwise, fetal MR is superior to US for soft tissue palate defects. (Right) Seeing fetal facial features and expressions with 3D & 4D US increases parental-fetal bonding. Positive changes observed include reduced anxiety and increased awareness of the importance for self-care during pregnancy.

KEY FACTS

TERMINOLOGY

- Cleft lip with or without cleft palate (CL ± CP)
 - > 80% of CL have CP
- Primary palate: Alveolar ridge (anterior medial)
- Secondary palate: Dorsal to alveolar ridge (soft + hard)

IMAGING

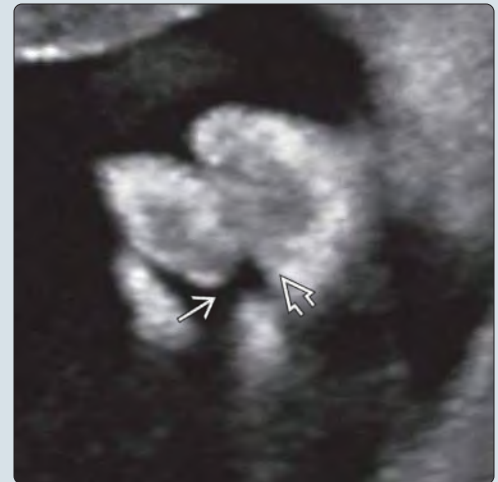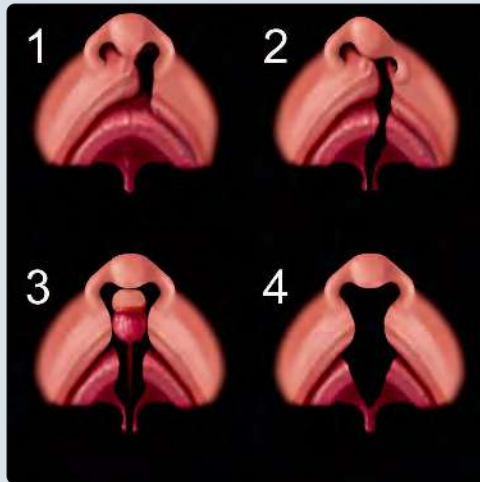
- Best to be descriptive when making prenatal diagnosis
 - Complete CL: Cleft extends to naris
 - Incomplete CL: Cleft does not extend to naris
 - CP seen with both complete and incomplete CL
 - Involves alveolar ridge (primary palate)
 - Isolated CP (only secondary palate involved)
 - Intact lip and alveolar ridge
- Unilateral CL + CP (most common)
 - CL + alveolar ridge defect
- Unilateral CL without CP
 - CL with intact alveolar ridge

- Bilateral CL/CP
 - Premaxillary protrusion on profile view
- Midline CL/CP
- Isolated CP (secondary palate)
 - Highly associated with hypognathia
- Associations
 - Trisomy 13, trisomy 18 > 200 syndromes
 - Midline and bilateral CL/CP more likely to have aneuploidy
 - Brain and cardiac anomalies

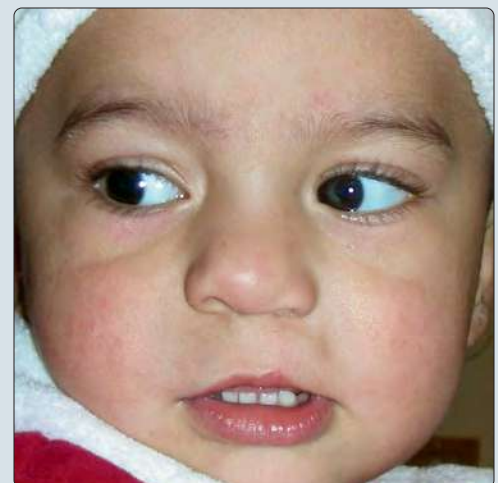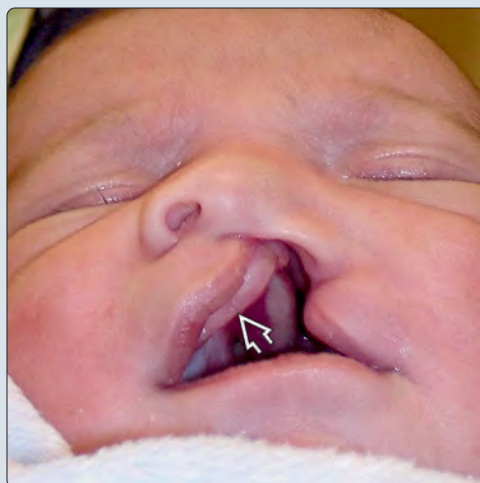CLINICAL ISSUES

- Multidisciplinary care
- Presurgical nasal alveolar molding
- Surgical treatment
 - CL often repaired at 2-3 months
 - CP often repaired at 9-12 months
 - 2 operations in 71%

(Left) Graphic shows a US classification system of cleft lip (CL) and cleft palate (CP). Type 1 is CL without CP, type 2 is unilateral CL + CP, type 3 is bilateral CL + CP, and type 4 is midline CL/CP. Type 2 is the most common. Most practitioners now feel that it is best to be descriptive of the anatomy with CL/CP diagnoses instead of using a classification system. (Right) Typical snout view appearance of unilateral complete CL shows the lip defect extending to the flat naris on the affected side.



(Left) Clinical photograph of a child with unilateral complete CL and CP demonstrates the flat naris, CL extending to the naris, and CP involving the alveolar ridge (and beyond). Dorsal extension of the CP is difficult to demonstrate prenatally. (Right) Clinical photograph of the same child after lip and palate repair demonstrates minimal deformity. Further lip or nasal revisions in adolescence may be performed. Modern surgical techniques yield excellent results.



TERMINOLOGY**Abbreviations**

- Cleft lip (CL)
- Cleft palate (CP)
- Cleft lip with or without cleft palate: CL ± CP

Definitions

- Primary palate: Alveolar ridge
- Secondary palate: Hard + soft palate dorsal to alveolar ridge

IMAGING**General Features**

- Best diagnostic clue
 - Variable classifications, best to be descriptive
 - Complete CL: Cleft extends to naris
 - Incomplete CL: Cleft does not extend to naris
 - CP associated with CL (complete and incomplete)
 - > 80% of all CLs have CP
 - Involves alveolar ridge (primary palate)
 - Isolated CP (involves only secondary palate)
 - Intact lip and alveolar ridge; cleft is dorsal
 - Unilateral CL + CP is most common type
- Location
 - Unilateral vs. bilateral vs. midline
 - Left > right

Ultrasonographic Findings

- Imaging of fetal nose, lip, and palate
 - Angled coronal soft tissue nose-mouth view: "Snout view"
 - Shows normal rounded nares and intact upper lip
 - Midsagittal profile view
 - Shows intact palate and normal nasal bone
 - Axial alveolar ridge view (not routine): For bony palate
 - 3D US is additive
 - Multiplanar advantages for showing palate defect
 - Surface-rendered views show overall morphology best
 - MR helpful for isolated CP
- **Unilateral CL + CP (most common)**
 - Complete or incomplete CL + alveolar ridge defect
 - Flattened naris almost always present
 - Variable dorsal involvement of CP
 - Fluid extends from oral to nasal cavity
 - Seen best on coronal and profile views
- **Unilateral CL without CP**
 - Complete or incomplete CL only
 - No alveolar defect
 - Normal or minimally flat naris
- **Bilateral CL/CP**
 - Premaxillary protrusion on profile view
 - Mass-like area just below nose
 - Dysplastic and anteriorly displaced medial anterior palate (primary palate)
 - Lip clefts seen best on axial and coronal views
 - Finding not subtle, but may be confusing
 - Severe nares deformity almost always present
- **Midline CL/CP**
 - Anterior mid lip/palate defect

- Large gap common
- Associated midface hypoplasia
 - Flat midface on profile view
 - Flattened dysplastic nose "collapsed"
 - Posteriorly displaced maxilla
- **Isolated CP**
 - Involves dorsal palate only (hard and soft)
 - Axial and sagittal views best
 - Fluid in nasal cavity via palate defect is biggest clue
 - Shadowing from hard palate may hinder diagnosis
 - 3D imaging and fetal MR helpful
 - Highly associated with hypognathia
 - Polyhydramnios in severe cases
 - Tongue migrates up via CP (obstructs swallowing)
- **1st-trimester diagnosis at nuchal translucency scan**
 - Maxillary gap on routine sagittal view of face and neck
 - > 1.5 mm lucency in maxilla considered abnormal
 - > 90% detection rate of CL/CP in recent retrospective study
 - Premaxillary protrusion can be seen at this time
 - Abnormal profile with maxillary protrusion + gap
 - Suggests bilateral CP
 - Disruption of coronal retrorhinal triangle
 - Not routinely assessed by most labs: Shows 2 nasal bones and intact maxilla
- **Associations and aneuploidy**
 - Midline and bilateral CL/CP
 - Trisomy 13 (T13) > trisomy 18 (T18)
 - Holoprosencephaly
 - Many syndromes with CL/CP
 - Rarely is CL/CP isolated in syndromic fetus
 - Many syndromes with hypognathia and CP
 - Robin sequence (Pierre-Robin syndrome)
 - Treacher Collins syndrome

Imaging Recommendations

- Best imaging tool
 - 3D US for more precise diagnosis
- Protocol advice
 - Genetic counseling
 - ↑ risk for aneuploidy
 - ↑ risk for syndromic child
 - Bilateral and midline CL/CP with higher associations
- Look carefully for other anomalies
 - 5% with brain anomalies (might be subtle)
 - Consider formal echocardiography
- Consider specialized 3D methods for difficult cases
 - Reverse-face technique
 - View volume from inside to outside face
 - Less shadowing of palate
 - Flipped-face technique
 - Rotate face 90° from midsagittal
 - Curved view bar around palate
 - Best axial plane of secondary plate

MR Findings

- Best modality for soft palate visualization
- Assess airway for delivery plan

DIFFERENTIAL DIAGNOSIS**Amniotic Band Syndrome**

- Disruption of amnion with fetal entrapment
- Slash-type facial defects
 - Asymmetric, random clefts without embryologic pattern
- Other body wall/extremity defects
 - Bizarre abdominal wall defects
 - Amputations

Facial Mass

- Teratoma (epignathus)
 - Nasal/oral origin
 - Can mimic premaxillary protuberance
- Frontal encephalocele
 - Bone defect + herniated brain/meninges
- Vascular or lymphatic malformation
 - Lymphangioma, hemangioma
 - Superficial, intact palate

PATHOLOGY**General Features**

- Etiology
 - Embryology
 - CL ± CP (6th-week embryogenesis)
 - Medial nasal processes fail to merge with each other ± with maxillary processes
 - Isolated CP (7th-10th-week embryogenesis)
 - Failure of 2° palate to fuse with 1° palate
 - Central CL/CP (4th-week embryogenesis)
 - Failure of frontonasal prominence to form
 - Maternal exposures associated with CL/CP
 - Smoking, alcohol
 - Organic solvents, agricultural chemicals
 - Nutritional deficiencies: Folate, zinc
 - Retinoid and anticonvulsant drugs
 - Diazepam, phenytoin, phenobarbital
- Genetics
 - CL ± CP is feature of > 200 genetic syndromes
 - Isolated CP is feature of > 400 genetic syndromes
 - Other anomalies almost always seen if T13 or T18
- Associated abnormalities
 - CL ± CP (live-birth data)
 - 70% isolated, 30% with other defects
 - Isolated CP (live-birth data)
 - 27% with recognizable syndromes

CLINICAL ISSUES**Presentation**

- Most common signs/symptoms
 - Incidentally noted at routine scan
 - CL/CP + associated anomalies
- Other signs/symptoms
 - Polyhydramnios from swallowing difficulties

Demographics

- Gender
 - M > F for CL ± CP
 - ≥ 2:1 in Caucasian and Japanese populations

- M < F for isolated CP
- Ethnicity
 - CL ± CP
 - 1:600 Asian
 - 1:1,000 Caucasian
 - 1:2,500 African American
 - Isolated CP ↑ rates: Canada, Northern Europe
- Epidemiology
 - 1:700 liveborn babies worldwide
 - 80% of babies with CL have CP

Natural History & Prognosis

- Excellent prognosis when isolated (with surgical repair)
- Associated craniofacial problems
 - Feeding difficulties
 - Hearing and speech impairment

Treatment

- Multidisciplinary care
 - Plastic, maxillofacial, orthodontic, dentistry
 - Otolaryngology, speech therapy, audiology
 - Counseling, psychologic support
- Presurgical nasal alveolar molding (PNAM) devices
 - Lip taping ± intraoral appliances
 - Nasal stent, elastic bands, maxillary arch device
- Surgical treatment
 - CL often repaired at 2-3 months
 - CP often repaired at 9-12 months
 - Wide defects require delayed repair (more PNAM)
 - Number of operations
 - 1 operation in 5%, 2 in 71%, 3 in 22%, ≥ 4 in 2%
- Fetoscopic surgery in future?
 - Fetal skin/bone heals with minimal scar/callus
 - Currently reserved for life-threatening conditions

DIAGNOSTIC CHECKLIST**Consider**

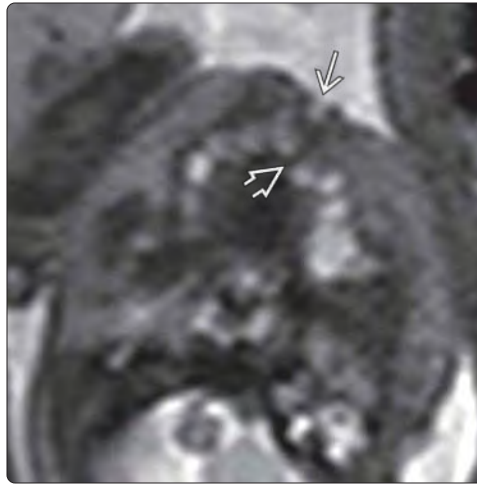
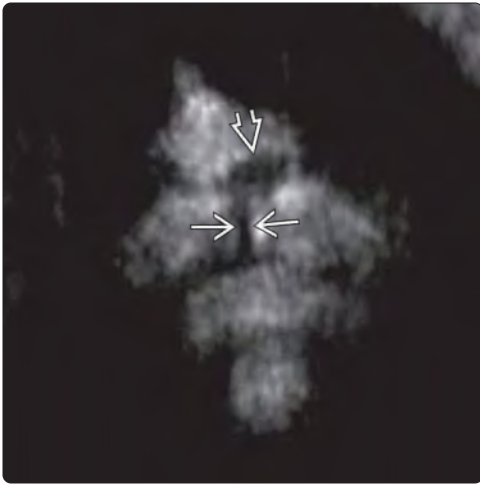
- Referral to CL/CP clinic during pregnancy
 - Parents learn PNAM techniques before baby arrives

Image Interpretation Pearls

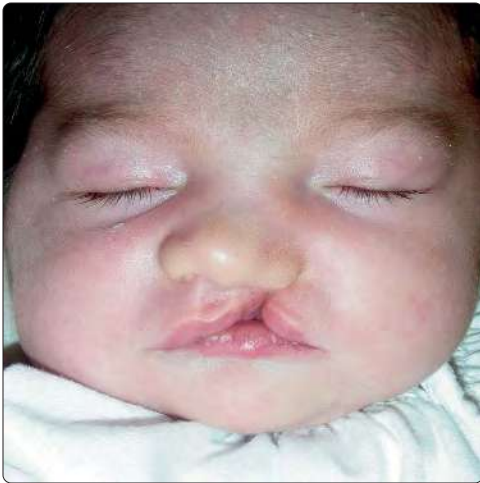- > 80% CL have associated CP
 - Repeat scan if CP not initially seen
- Variable accuracy for predicting CP extension
 - 3D US and MR often helpful
- Look carefully for CP if fetus has hypognathia
 - Consider MR if palate not seen well

SELECTED REFERENCES

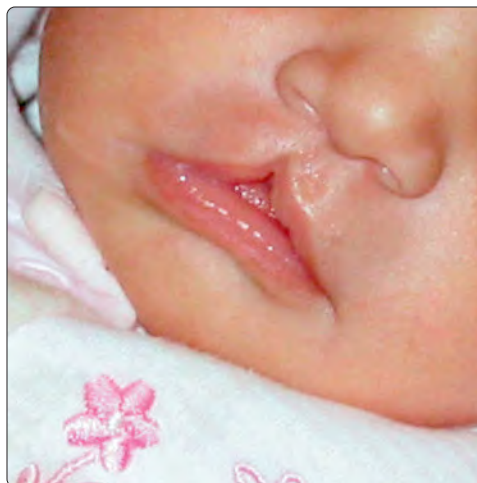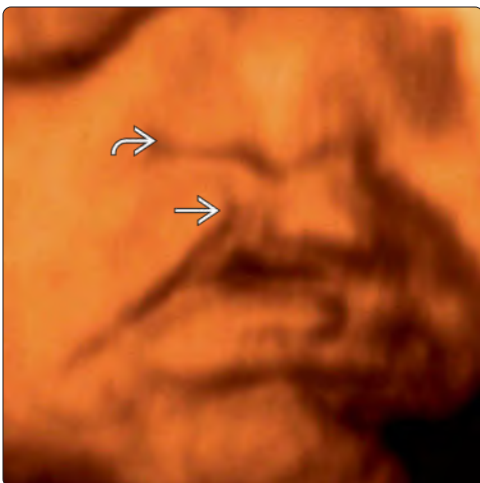1. Abramson ZR et al: Radiology of cleft lip and palate: imaging for the prenatal period and throughout life. *Radiographics*. 35(7):2053-63, 2015
2. Chaoui R et al: Maxillary gap at 11-13 weeks' gestation: marker of cleft lip and palate. *Ultrasound Obstet Gynecol*. 46(6):665-9, 2015
3. Kim DW et al: Prenatal ultrasonographic diagnosis of cleft lip with or without cleft palate; pitfalls and considerations. *Maxillofac Plast Reconstr Surg*. 37(1):24, 2015
4. Sepulveda W et al: Retronasal triangle: a sonographic landmark for the screening of cleft palate in the first trimester. *Ultrasound Obstet Gynecol*. 35(1):7-13, 2010
5. Gillham JC et al: Antenatal detection of cleft lip with or without cleft palate: incidence of associated chromosomal and structural anomalies. *Ultrasound Obstet Gynecol*. 34(4):410-5, 2009
6. Mossey PA et al: Cleft lip and palate. *Lancet*. 374(9703):1773-85, 2009



(Left) In this 22-week fetus with multiple other anomalies (normal chromosomes), a thin, complete CL is seen extending to the minimally flattened naris. **(Right)** Axial view through the palate on fetal MR, in the same case, shows the small lip defect and an associated CP. The alveolar ridge disruption was seen to better advantage on the MR in this case, although it was suspected on US.

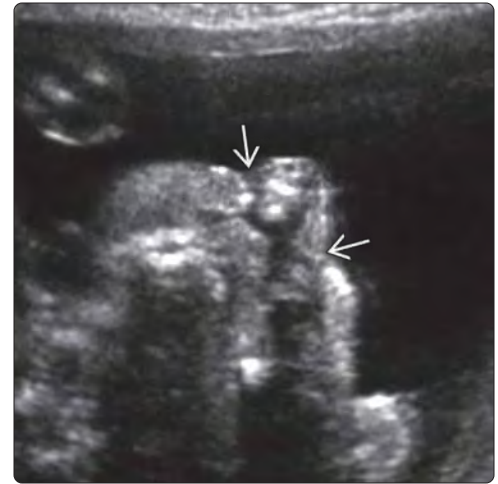
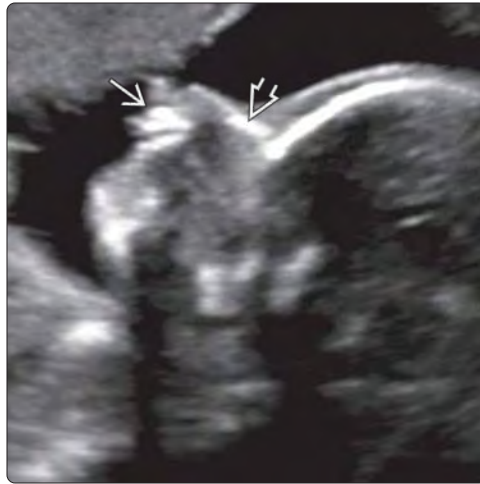

(Left) In this newborn, the cleft lip was called incomplete because it did not fully extend to the naris. An alveolar ridge CP was present, and the left naris is flattened. Both complete and incomplete CLs are highly associated with CP. The CP may be difficult to diagnose in utero. **(Right)** Post repair clinical photograph is shown in the same child.

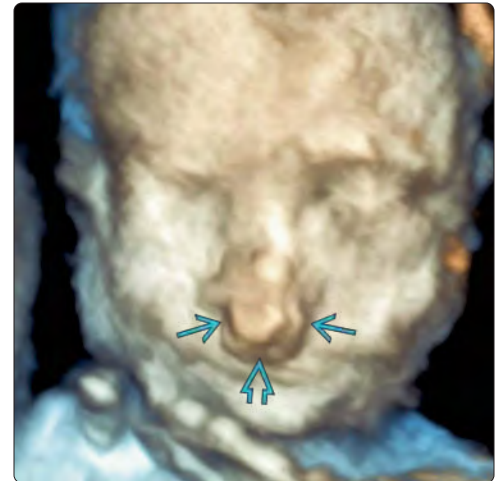
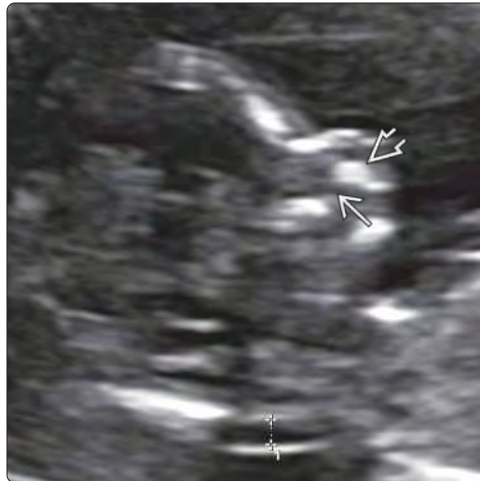


(Left) 3D US of incomplete CL shows a subtle unilateral CL, which does not extend to the naris. The alveolar ridge appeared intact. **(Right)** Postnatal photograph of the same baby confirms the prenatal diagnosis of incomplete CL without CP. Less than 20% of cases with CL (complete or incomplete) have an intact alveolar ridge.

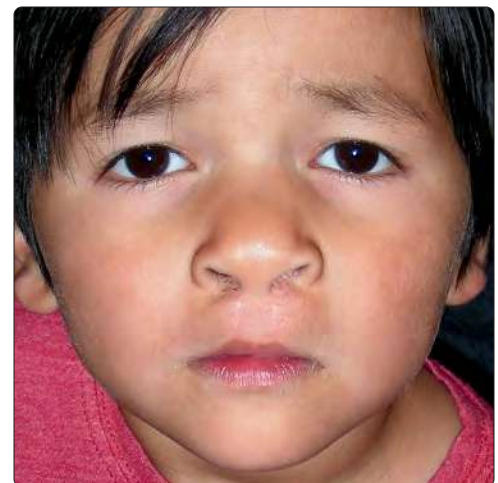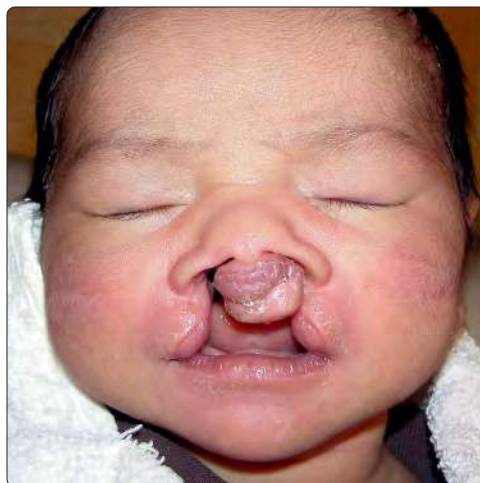(Left) Profile view of a 2nd-trimester fetus shows a premaxillary protuberance located beneath the nose (nasal bone). Premaxillary "mass" is a hallmark finding of bilateral CL with CP. Protrusion of the dysplastic primary palate causes this appearance. **(Right)** Axial view of the palate, in the same fetus, shows the bilateral lip and palate defects. Bilateral CL is almost always associated with CP and more highly associated with aneuploidy and other anomalies than unilateral CL.

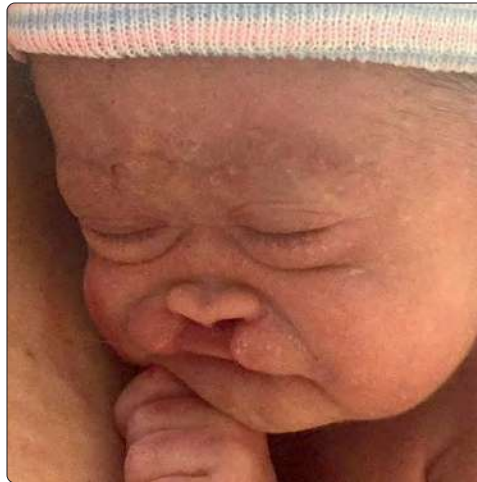
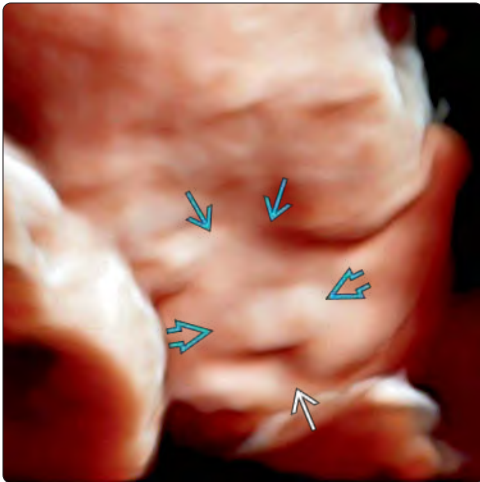
(Left) In this 13-week fetus, at the time of nuchal translucency measurement (calipers), a defect was seen in the maxilla, and the maxilla was displaced anteriorly (early premaxillary protrusion). The family opted for chorionic villus sampling instead of maternal serum screening. **(Right)** 3D surface-rendered images, in the same fetus at 20 weeks, confirms bilateral CL and mass-like premaxillary protrusion. The karyotype results were normal.

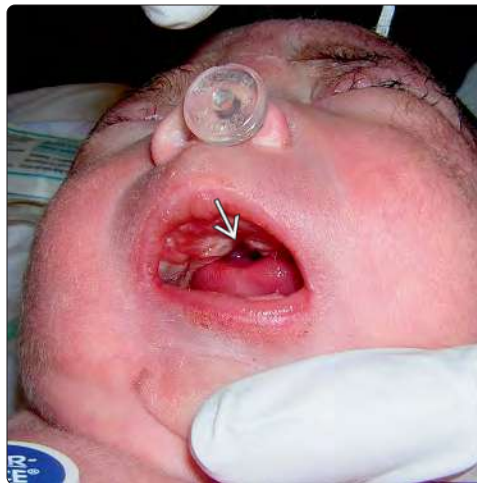
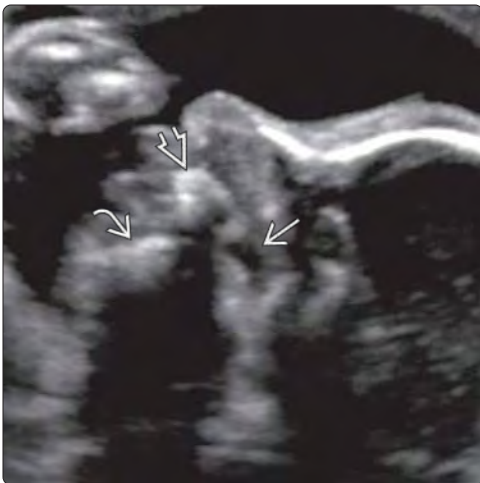
(Left) Clinical photograph of a child with bilateral complete CL and CP shows the anterior protruding premaxilla. **(Right)** The postsurgical repair photograph, shown here, exemplifies the importance of referral to the maxillofacial team when these diagnoses are made in the fetus. Families have a chance to learn how to use presurgical appliances before giving birth. Also, they can see "before and after" pictures before meeting their baby for the 1st time.

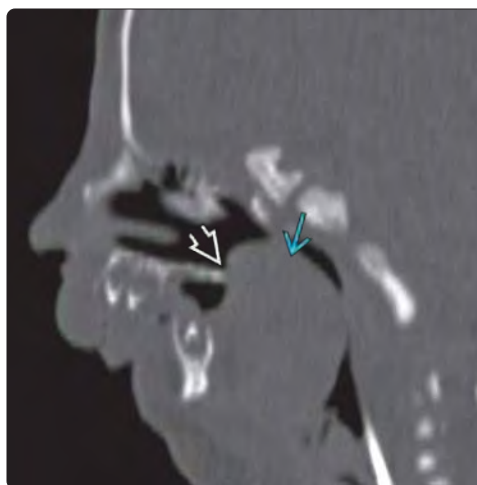
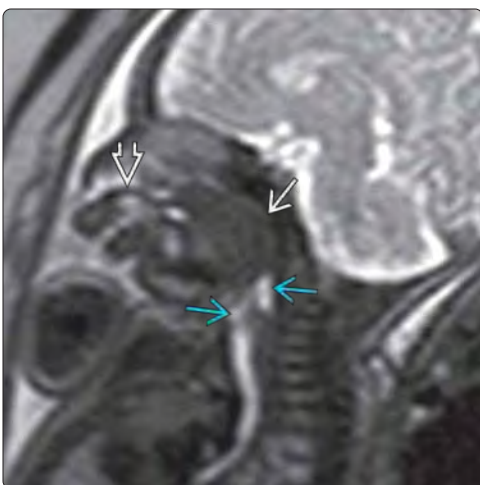




(Left) 3D surface-rendered image of the fetal face shows a midline CL, flat deficient nose, and close set eyes (hypotelorism). The fetus also had alobar holoprosencephaly. Karyotype results, however, were normal. **(Right)** Photograph of the child after delivery confirms the prenatal diagnosis. The family opted for comfort care, and the child died at 2 weeks of life. Midline CL/CP is highly associated with midline brain anomalies, usually on the holoprosencephaly spectrum. Both defects are associated with trisomy 13.



(Left) The profile view in this fetus with a small chin shows a fluid-filled palate defect in the dorsal palate, posterior to the intact alveolar ridge. Isolated CP is highly associated with hypognathia. **(Right)** Postnatal photograph from the same case shows the dorsal soft palate defect and small chin. A nasal airway is placed because of the resultant airway obstruction.



(Left) MR in a fetus with hypognathia and suspicion for associated CP shows tongue deviation through a posterior palate defect and an intact anterior alveolar ridge. Fluid was seen extending into the airway inferior to the tongue, suggesting a lower likelihood that the newborn would have severe airway compromise. **(Right)** Sagittal CT reconstruction correlates with the prenatal MR. The tongue deviates superiorly through the palate defect. The hard palate is seen to the point of the palate defect.

KEY FACTS

TERMINOLOGY

- Variant of nasolacrimal duct obstruction (NLDO)
- Synonyms include mucocele, amniotocele, lacrimal duct cyst

IMAGING

- Thin-walled round cyst located medial to globe
- 25% bilateral ± intranasal extension
- 3D best to show swelling on face
- Consider MR if dacryocystocele is large and bilateral
 - Best for evaluation of nasal extension

TOP DIFFERENTIAL DIAGNOSES

- Frontal/nasal encephalocele
 - Look for skull defect
 - Hypertelorism
- Lymphangioma
 - Multicystic mass with infiltration
- Hemangioma and dermoid (rare in fetal life)

PATHOLOGY

- Proximal (valve of Rosenmüller) + distal (valve of Hasner) NLDO leads to pooling of mucus/amniotic fluid in enclosed space

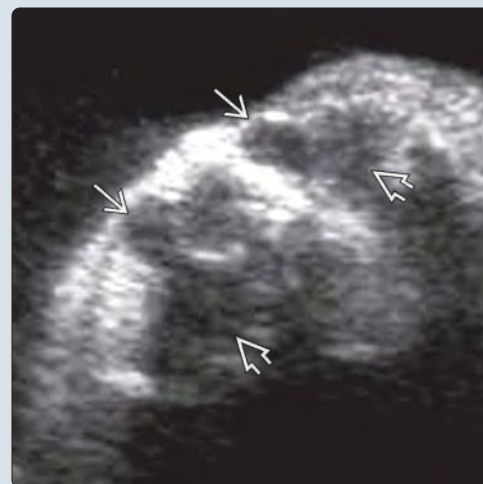
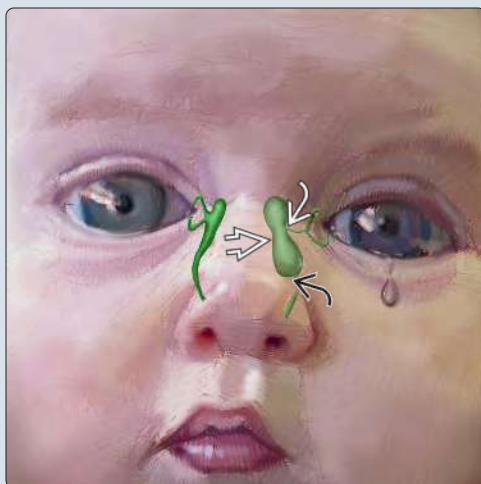CLINICAL ISSUES

- 76-85% resolve in utero or during 1st yr of life
- Conservative treatment
 - Massage, manual decompression, local heat
- Surgical treatment if conservative approach fails
 - Endoscopic cyst marsupialization

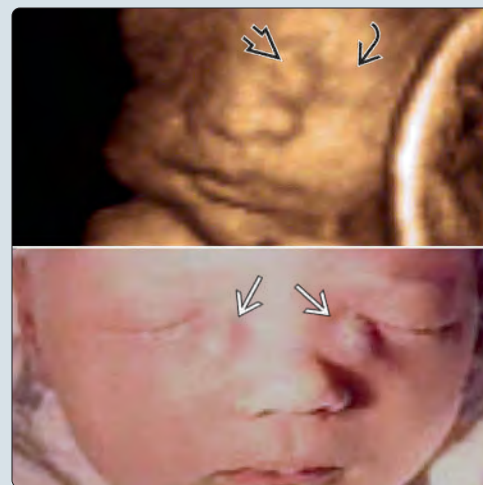
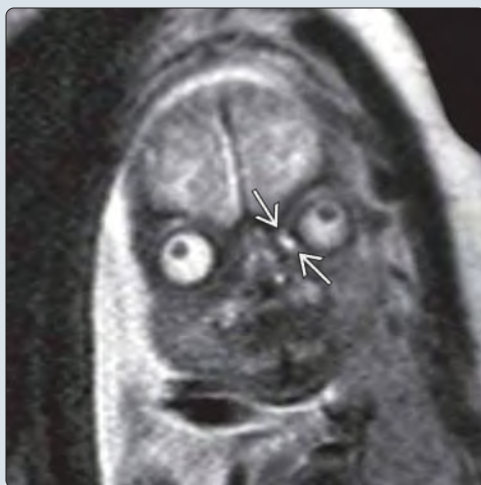DIAGNOSTIC CHECKLIST

- MR for bilateral large cyst to look for nasal extension
 - May be associated with respiratory difficulty at delivery (rare)
- Dacryocystocele is 3rd-trimester diagnosis, consider other diagnosis if orbital mass seen in 2nd trimester

(Left) This drawing shows left dacryocystocele due to obstruction of the proximal valve of Rosenmüller and the distal valve of Hasner. The normal lacrimal drainage system is seen on the right. Obstruction may be partial with variable amounts of nasolacrimal sac distention. **(Right)** Transverse US of the orbits shows bilateral dacryocystoceles. Bilateral well-circumscribed cysts are seen medial to the globes. These cysts decreased in size as the pregnancy progressed and were asymptomatic at birth.



(Left) Unilateral dacryocystocele was incidentally seen on this fetal MR. A small orbital cyst is seen medial to the left globe. **(Right)** 3D US surface-rendered view shows a focal swelling between the upper nose and left eye in this 28-week fetus with bilateral dacryocystoceles. Clinical photograph of a child with bilateral dacryocystoceles shows the focal facial swelling. Dacryocystoceles typically have a bluish tinge (seen best here with the left cyst).



TERMINOLOGY**Abbreviations**

- Nasolacrimal duct obstruction (NLDO)

Synonyms

- Mucocele, amniotocele, lacrimal duct cyst

Definitions

- Variant of NLDO leading to cyst formation

IMAGING**General Features**

- Best diagnostic clue
 - Orbital cyst medial and inferior to globe
- Location
 - 25% bilateral ± intranasal extension
- Size
 - Variable; > 5 mm for diagnosis

Ultrasonographic Findings

- Thin-walled round cyst located medial to globe
 - Anechoic or hypoechoic
 - Resembles extra globe when large

Imaging Recommendations

- Best imaging tool
 - Routine axial view of orbits
 - Confirm with coronal views and 3D
 - 3D best to show swelling on face (show family)
- Protocol advice
 - Consider MR if dacryocystocele is large and bilateral
 - Nasal extension may lead to respiratory distress (rare)

DIFFERENTIAL DIAGNOSIS**Frontal/Nasal Encephalocele**

- Associated skull defect
 - May be purely cystic (meningocele)
- Associated hypertelorism
- Fetal MR helps with differential diagnosis

Lymphangioma

- Rarely isolated in orbit
- Large and multicystic mass with infiltration

Hemangioma and Dermoid

- Both are rare in fetal life
- Hemangioma
 - Mostly involves skin
 - Eyelid involvement
 - More lateral than dacryocystocele
- Dermoid
 - Deeper than hemangioma
 - 85% with bone changes

PATHOLOGY**General Features**

- Etiology
 - Both proximal and distal NLDO lead to pooling of mucus or amniotic fluid in enclosed space

- Lower obstruction of valve of Hasner
 - Valve of Hasner may not canalize until after birth
- Upper obstruction of valve of Rosenmüller

- Genetics
 - Not associated with aneuploidy as isolated finding
- Associated abnormalities
 - Most often an isolated finding in 3rd trimester
 - Primary nasal mass may cause secondary NLDO

Microscopic Features

- Mucocele in obstructed duct

CLINICAL ISSUES**Presentation**

- Most common signs/symptoms
 - Incidental finding in 3rd trimester

Demographics

- Epidemiology
 - Incidence of 0.43% on prenatal scan
 - Dacryocystocele in 0.1-2% of infants with NLDO
 - NLDO (without dacryocystocele) is common
 - 20-30% of normal newborns

Natural History & Prognosis

- Newborn with focal bluish swelling inferomedial to medial canthus
- Often resolve without need for surgery
 - 76-85% resolve in utero or during 1st yr of life
 - Larger lesions require surgical drainage
- Complications
 - Neonatal nasal obstruction
 - Bilateral cases with nasal extension
 - May become airway emergency at delivery
 - Dacryocystitis
 - Considered ophthalmological emergency

Treatment

- Conservative approach 1st
 - Massage, manual decompression, local heat
- Surgical treatment if conservative approach fails
 - Endoscopic cyst marsupialization

DIAGNOSTIC CHECKLIST**Consider**

- Dacryocystocele is 3rd-trimester diagnosis, consider other diagnosis if orbital mass seen at time of anatomy scan

Reporting Tips

- Alert clinician that bilateral cysts may be associated with respiratory difficulty at delivery

SELECTED REFERENCES

1. Kim YH et al: Dacryocystocele on prenatal ultrasonography: diagnosis and postnatal outcomes. *Ultrasonography*. 34(1):51-7, 2015
2. Pediatric Eye Disease Investigator Group: Resolution of congenital nasolacrimal duct obstruction with nonsurgical management. *Arch Ophthalmol*. 130(6):730-4, 2012
3. Sotiriou S et al: Sonographic antenatal diagnosis of congenital dacryocystoceles. *J Clin Ultrasound*. 40(6):375-7, 2012
4. Brown K et al: Prenatal diagnosis of bilateral dacryocystocele using 3-D/4-D ultrasound technology: a case report. *J Reprod Med*. 56(1-2):78-80, 2011

KEY FACTS

TERMINOLOGY

- Gap or defect of ocular tissue

IMAGING

- Seen only on fetal MR as orbital apex shadowed out on US
- High signal protrusion from globe on T2WI
 - Focal bulge in globe contour at optic nerve insertion
- May be unilateral or bilateral
 - If bilateral more likely syndromic

PATHOLOGY

- Defect of fetal fissure closure and retinal ganglion cell development





CLINICAL ISSUES

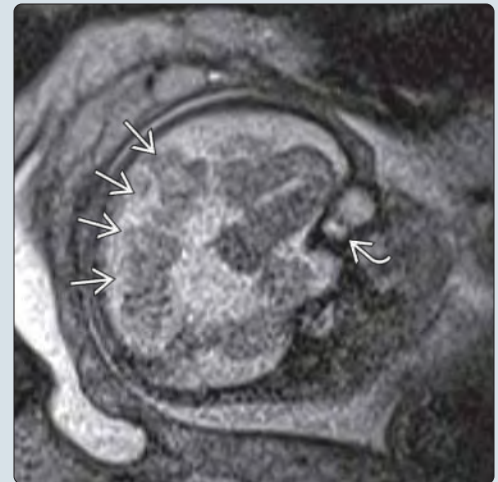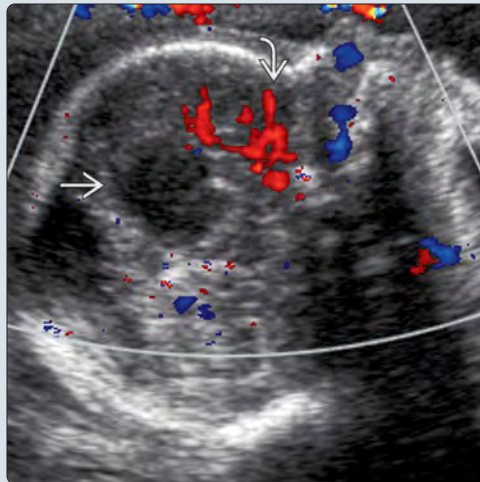
- Prevalence of 1.4:10,000
 - Most common in India
- Prognosis depends on underlying diagnosis
- Associated with numerous syndromes







- Aicardi syndrome
- CHARGE syndrome
- COACH syndrome
- PHACES syndrome
- Renal coloboma syndrome
- Walker-Warburg syndrome
- Goldenhar (oculo-auriculo-vertebral) syndrome
- Fetal alcohol syndrome
- May be associated with retinal detachment and microphthalmia
- Important cause of childhood visual impairment and blindness

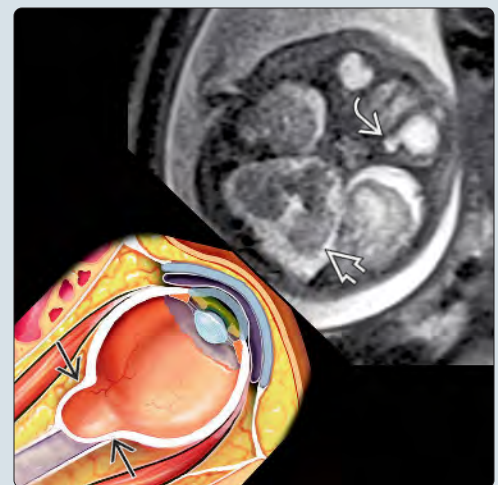
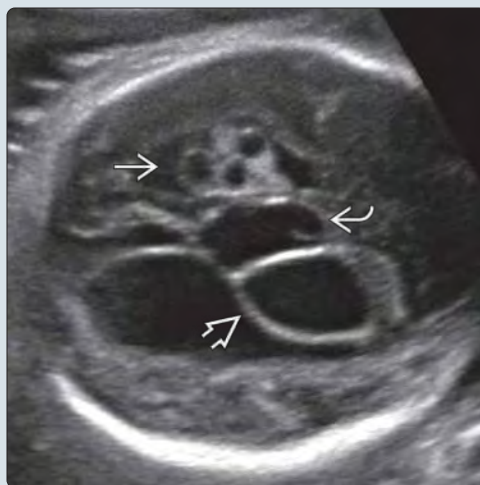
DIAGNOSTIC CHECKLIST

- May suggest specific syndromic diagnosis if noted during MR for other anomalies
- Always check orbit contents and globe contour on fetal cerebral MR

(Left) Midline US shows abnormal branching of the anterior cerebral artery  in a fetus with agenesis of the corpus callosum and an intracranial cyst . Remember to check the eyes in fetuses with brain structural abnormalities. (Right) Sagittal T2WI MR in the 3rd trimester confirmed callosal agenesis (note the radially arranged gyri ) but also showed an unsuspected coloboma , which led to suggesting the diagnosis of Aicardi syndrome in this female fetus. Diagnosis was confirmed by neonatal ophthalmic exam.



(Left) Axial US in the 3rd trimester shows a complex brain malformation with choroid plexus , intraventricular  and interhemispheric  cysts in a female fetus with agenesis of the corpus callosum, and an abnormal cerebellum. (Right) Axial T2WI MR in same fetus shows a small left cerebellar hemisphere  and an optic disc coloboma . The graphic shows a focal defect in the posterior globe  at the site of the optic nerve head insertion, a classic optic disc coloboma. Aicardi syndrome was confirmed at birth.



TERMINOLOGY

Definitions

- Gap or defect of ocular tissue
 - Optic disc coloboma is confined to optic disc
 - Choroidoretinal coloboma is separate from or extends beyond optic disc

IMAGING

General Features

- Seen only on fetal MR as orbital apex shadowed out on US

MR Findings

- High signal protrusion from globe on T2WI
 - Focal bulge in globe contour at optic nerve insertion
- May be unilateral when sporadic
- If bilateral more likely syndromic

Ultrasonographic Findings

- May be multiple anomalies in fetuses with syndromes

DIFFERENTIAL DIAGNOSIS

Microphthalmia, Anophthalmia

- Small malformed eye = microphthalmia
 - Associated with syndromes; look for multiple anomalies
- Absent eye = anophthalmia
 - Look for cyclopia (single central orbit) in holoprosencephaly
- Ocular anomalies are common in fetus with brain malformation; often overlooked but very important to parents
 - Check eye size, symmetry, and position in all fetuses with brain or facial anomalies

PATHOLOGY

General Features

- Etiology
 - Defect of fetal fissure closure and retinal ganglion cell development
 - Embryonic fissure extends along inferonasal aspect of optic cup and stalk
 - Fusion normally occurs between 5th-7th weeks
 - Required for normal globe and nerve formation
 - Described as complication of maternal carbamazepine use (controversial)
- Genetics
 - Renal-coloboma syndrome: Autosomal dominant
 - Aicardi syndrome: X-linked
 - Male lethal, most are spontaneous mutations
 - Trisomies

CLINICAL ISSUES

Presentation

- Usually seen as part of syndrome
 - **Aicardi syndrome:** Infantile spasms, agenesis of corpus callosum, and chorioretinal lacunae
 - **CHARGE syndrome:** Coloboma, heart defects, choanal atresia, growth restriction, genital anomalies, ear anomalies

- **COACH syndrome:** Cerebellar vermis hypoplasia/aplasia, oligophrenia (intellectual impairment), ataxia, coloboma, hepatic fibrosis
- **PHACES syndrome:** Posterior fossa malformations, hemangiomas, arterial anomalies, cardiac defects, eye abnormalities, sternal or ventral defects
- **Renal coloboma syndrome:** Hypo/dysplastic kidneys and optic nerve abnormalities
- **Walker-Warburg syndrome:** Congenital muscular dystrophy associated with brain and eye abnormalities
- **Goldenhar (oculo-auriculo-vertebral) syndrome:** Autopsy demonstration of coloboma in microphthalmic eye
- **Fetal alcohol syndrome:** Eye is primary target of ethanol; optic nerve hypoplasia, microphthalmia, and coloboma frequently observed in affected children
- May be associated with retinal detachment
 - Look for linear echoes within normally anechoic globe
- May be associated with microphthalmia
 - Biometric tables are available, use other eye as internal control

Demographics

- Prevalence of 1.4:10,000
 - Most common in India
 - Series of 83 cases in India: 43% consanguineous parents, 19% positive family history, 13% exposure to agricultural chemicals

Natural History & Prognosis

- Prognosis depends on underlying diagnosis as associated with numerous syndromes
 - Aicardi: Poor; high childhood mortality, severe intellectual impairment
 - PHACES: Vascular malformations determine outcome
 - Renal coloboma syndrome: Autosomal dominant, variable phenotype
- Many case reports of sublethal association with severe growth restriction and developmental delay
- Important cause of childhood visual impairment and blindness
 - Prognosis worst when associated with microphthalmos

DIAGNOSTIC CHECKLIST

Consider

- Only visible on MR
- May suggest specific syndromic diagnosis

Image Interpretation Pearls

- Always check orbit contents and globe contour on fetal cerebral MR

SELECTED REFERENCES

1. Dar SA et al: Prenatal diagnosis of colobomatous microphthalmos. J Pediatr Ophthalmol Strabismus. 52 Online:e22-5, 2015
2. Brennan D et al: Ocular involvement in fetal alcohol spectrum disorder: a review. Curr Pharm Des. 20(34):5377-87, 2014
3. Herwig MC et al: Preterm diagnosis of choristoma and choroidal coloboma in Goldenhar's syndrome. Pediatr Dev Pathol. 14(4):322-6, 2011

KEY FACTS

TERMINOLOGY

- Teratoma arising from naso- or oropharynx

IMAGING

- Fills oral cavity and emanates from mouth &/or nose
- Predominately solid or mixed cystic/solid
- Usually large at time of diagnosis
 - May grow rapidly to massive size
- Transsphenoidal intracranial extension can occur
 - Presence of intracranial extension negatively impacts prognosis
- Polyhydramnios secondary to pharyngeal obstruction
 - Often severe and may cause preterm labor
- MR recommended to better delineate anatomy and evaluate for intracranial extension

TOP DIFFERENTIAL DIAGNOSES

- Bilateral cleft lip and palate
 - Premaxillary protrusion may appear as soft tissue mass

PATHOLOGY



- Often better differentiated than teratomas in other locations; may have well-developed structures

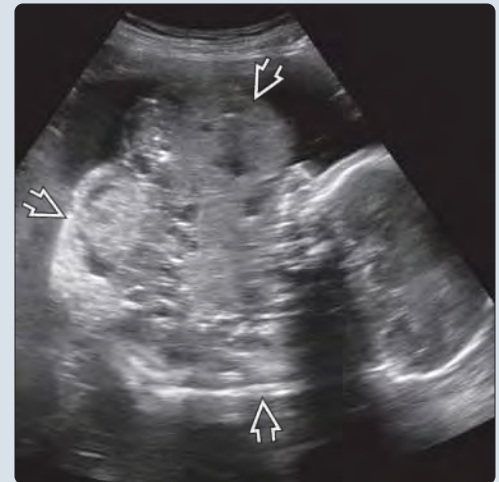
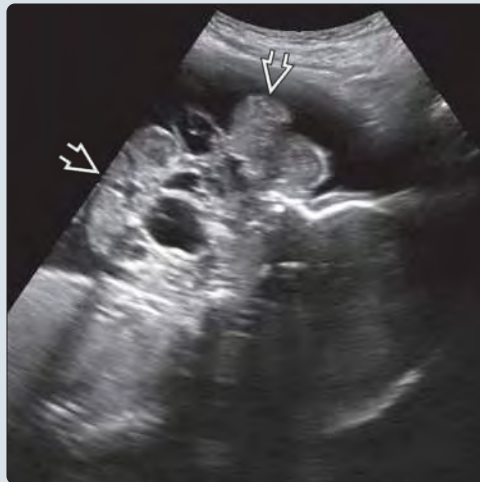
CLINICAL ISSUES




- Lethal if unable to establish airway
- Substantial improvement in survival achieved with ex utero intrapartum treatment (EXIT) procedure
 - Mortality rate 23% for head and neck teratomas (naso/oropharyngeal + cervical)
- Unlike other neck masses, teratomas often require immediate resection (EXIT to resection)
- Important to remember most infants are critically ill despite successful EXIT and often require long-term hospitalization

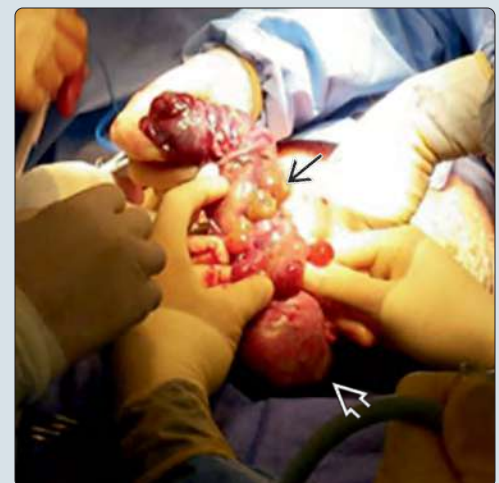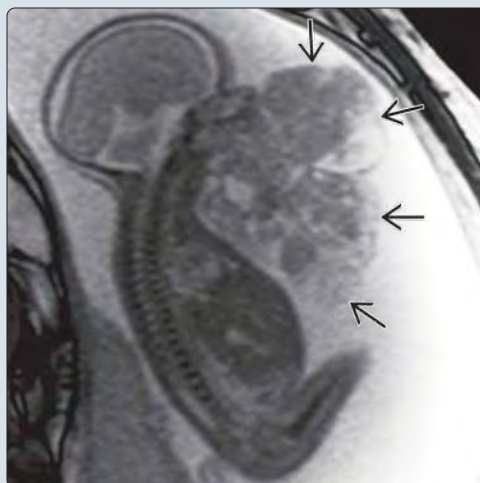
DIAGNOSTIC CHECKLIST

- Any large, fungating oral mass is virtually diagnostic of teratoma

(Left) Sagittal US of the face of a 24-week fetus shows a large, predominately solid, complex mass  fungating from the fetal mouth. (Right) Two weeks later, the mass  has nearly doubled in size, obscuring normal anatomic landmarks. Teratomas can grow at an extremely rapid rate and require close follow-up. The oropharynx was obstructed and polyhydramnios developed.



(Left) Sagittal large field of view MR of the same fetus gives a better perspective of the size of the mass , which is ~ 2/3 that of the fetal body. (Right) The patient went into preterm labor, and an EXIT was done at 27 weeks. This intraoperative photo shows the fungating mass  (compare to the size of the head ). It was resected during the EXIT procedure, and an airway was established, but support was withdrawn several weeks later after bilateral grade 4 intracranial hemorrhages.



TERMINOLOGY**Synonyms**

- Nasopharyngeal teratoma
- Oropharyngeal teratoma

Definitions

- Teratoma arising in oral/nasal cavity or pharynx

IMAGING**General Features**

- Best diagnostic clue
 - Large, fungating oral mass
 - Calcifications are virtually pathognomonic of teratoma but are present in less than 1/2 of cases and may not be visible with US
- Location
 - Most commonly arise from hard or soft palate
 - Fills oral cavity and emanates from mouth &/or nose
 - Transsphenoidal intracranial extension can occur
 - Produces extraaxial mass
 - Can cause marked distortion of intracranial structures
- Size
 - Usually large at time of diagnosis
 - Can be massive, often larger than fetal head

Ultrasonographic Findings

- Predominately solid or mixed cystic/solid
- Commonly distorts surrounding anatomy
 - Jaw is held in fixed, open position
 - Splayed mandible
 - Hypertelorism
 - Exophthalmos
 - Cervical hyperextension
- Polyhydramnios secondary to pharyngeal obstruction
 - Often severe
- Color Doppler
 - Solid portions of mass often very vascular
 - Arteriovenous shunting may be present
- Hydrops may develop with large masses

MR Findings

- Helpful in determining anatomic extent
 - Important for intracranial involvement
 - Better defines airway

CT Findings

- In utero CT with 3D reformation has been done
 - Better evaluation of bone, specifically looking for invasion by tumor
 - Calcifications better seen

Imaging Recommendations

- Routine head and face views should detect virtually all cases
- Color Doppler to evaluate vascularity
- MR recommended to better delineate anatomy
- Close interval scanning
 - Rapid growth rates with tumor-doubling times as short as 1-2 weeks
 - Evaluate brain carefully for intracranial extension

- Compresses and displaces normal brain parenchyma
- Head enlargement
- Hydrocephalus
- Monitor for worsening polyhydramnios and hydrops

DIFFERENTIAL DIAGNOSIS**Bilateral Cleft Lip and Palate**

- Premaxillary protrusion may appear as soft tissue mass
- Coronal/axial views show bilateral clefts
 - Clefts extend posteriorly through alveolar ridge

Cervical Teratoma

- Neck often held in hyperextension
- May extend into mediastinum
- Look carefully at mouth and brain
 - No intraoral or intracranial extension

Amniotic Band Syndrome

- May cause facial mass from "slash" defects
 - Large, obliquely oriented facial clefts
- Other body parts often affected

Frontal Cephalocele

- Frontoethmoidal skull defect with herniation of brain
- Usually small and may be missed prenatally
- Hypertelorism
- MR confirms diagnosis

Epulis

- Congenital gingival granular cell tumor
- Smooth, round, soft tissue mass
- Homogeneous echogenicity
- Most < 2 cm
- Female predominance (F:M = 8:1)

Rare Tumors

- **Nasal glioma**
 - Glioma is misnomer as this is nonneoplastic tissue
 - Collection of dysplastic brain tissue
 - Most occur at bridge of nose or in and around nasal cavity
 - Well-circumscribed round, ovoid, or polypoid mass
- **Dermoid cyst**
 - Persistent dural projection through foramen cecum
 - Dermoid or epidermoid develops along tract
 - Can have connection with intracranial contents
- **Myoblastoma**
 - Reported in oral cavity
 - Found exclusively in females
- **Soft tissue tumors** (both benign and malignant) may cause facial mass
 - Hemangioma
 - Fibromatosis, myofibromatosis
 - Fibrosarcoma, rhabdomyosarcoma

Macroglossia

- Mouth open with persistent protrusion of fetal tongue
- Seen with multiple syndromes

PATHOLOGY**General Features**

- Etiology
 - Postulated developmental field defect of cephalic pole
 - Abnormal sonic hedgehog signaling may play factor
- Genetics
 - Sporadic
 - No recurrence risk
- Associated abnormalities
 - Cleft palate
 - Mechanical obstruction by mass, impedes midline fusion of the 2 palatine processes
 - Other craniofacial clefts and duplications have been described
 - Cleft nose, bifid tongue, and even facial duplication (diprosopus)
 - Increased incidence of cardiac anomalies reported

Staging, Grading, & Classification

- Teratomas classified as mature or immature
 - Immature teratomas do not have same poor prognosis as those presenting later in life
 - Immaturity of tumor may reflect immaturity of fetus rather than biologic behavior of tumor
 - Size and vascularity are much more important than histology in fetus

Gross Pathologic & Surgical Features

- Complex, mixed cystic and solid components
- Often better differentiated than teratomas in other locations; may have fetus-like features

Microscopic Features

- Unique histologic features compared to teratomas presenting later in life
 - Ectodermal tissues are main histologic component of fetal teratomas
 - Often contain neural tissue (brain-like) as dominant component
 - Mesoderm
 - Fat, cartilage, smooth muscle, bone
 - Endoderm least common component
 - Respiratory and gastrointestinal tissues

CLINICAL ISSUES**Presentation**

- Most common signs/symptoms
 - Obvious fungating oral mass
 - Reported in 1st trimester
- Other signs/symptoms
 - Elevated α -fetoprotein
 - Polyhydramnios

Demographics

- Epidemiology
 - Rare: 1:35,000-200,000 live births
 - Head and neck 2nd most common site for teratomas after sacrococcygeal
 - Oropharynx less common than cervical
 - More common in females

Natural History & Prognosis

- May show rapid in utero growth
- Polyhydramnios may cause preterm labor
- Routine resuscitation techniques
 - Lethal if unable to establish airway
 - Even with maximal emergency procedures, hypoxia, acidosis, and anoxic brain injuries occur
 - Mortality 80-100%
- Substantial improvement in survival achieved with ex utero intrapartum treatment (EXIT) procedure
 - In large series, airway established in 79%, with overall survival of 69% for head and neck masses
 - In another study looking specifically at head and teratomas (naso-/oropharyngeal and cervical), mortality rate was 23%
 - Most deaths from complications of pulmonary hypoplasia
 - Important to remember most infants are critically ill despite successful EXIT and often require long-term hospitalization

Treatment

- Termination offered
- If pregnancy continued, deliver at tertiary care facility with capability of performing EXIT procedure
- EXIT procedure provides controlled environment to establish airway
 - Deep plane anesthesia
 - Unlike C-section, want enough time (typically 1 hr) for adequate uteroplacental transfer of inhaled anesthetic to fetus
 - Fetus is partially delivered by C-section while placenta and umbilical cord remain intact
 - Uteroplacental gas exchange maintained until airway achieved
 - Unlike other neck masses, teratomas often require immediate resection (EXIT to resection)

DIAGNOSTIC CHECKLIST**Consider**

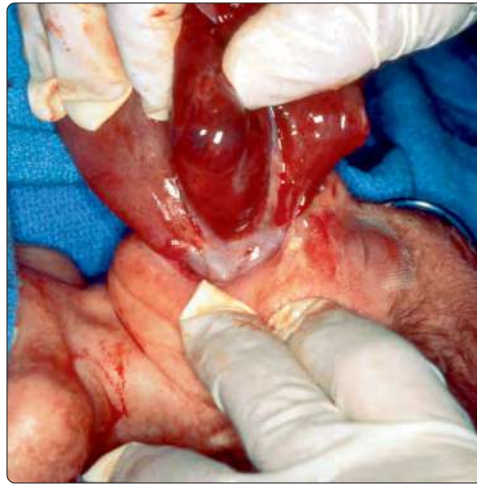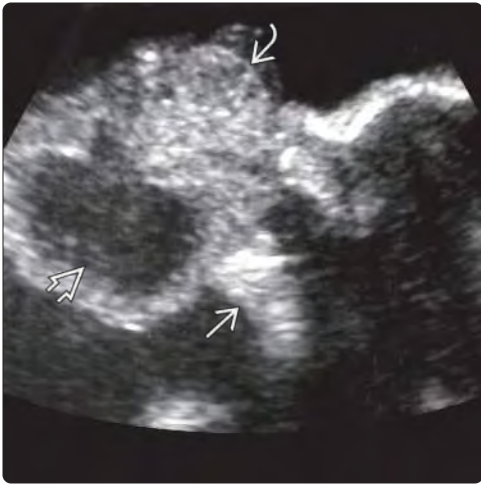
- MR to better delineate anatomy and evaluate for intracranial extension
- If pregnancy is continued, refer patient to tertiary care facility with capability of performing EXIT procedure

Image Interpretation Pearls

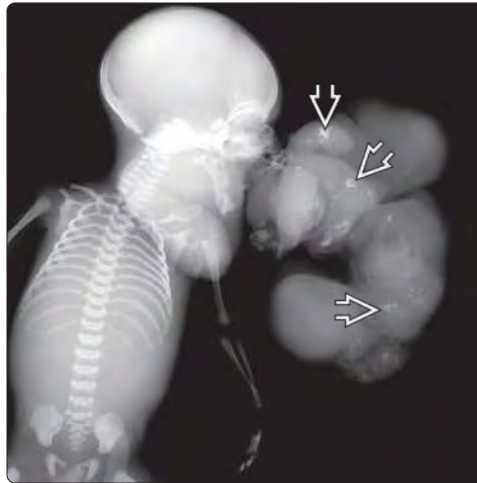
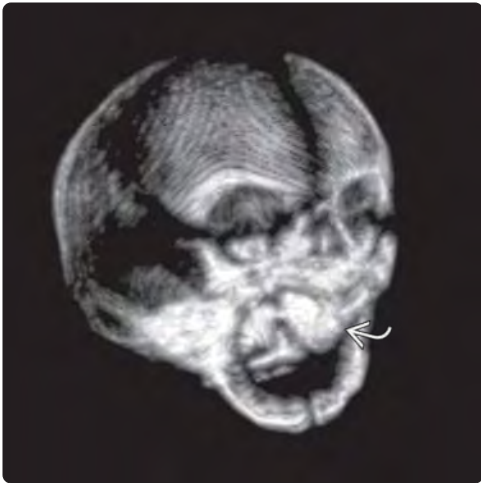- Any large, fungating oral mass is virtually diagnostic of teratoma

SELECTED REFERENCES

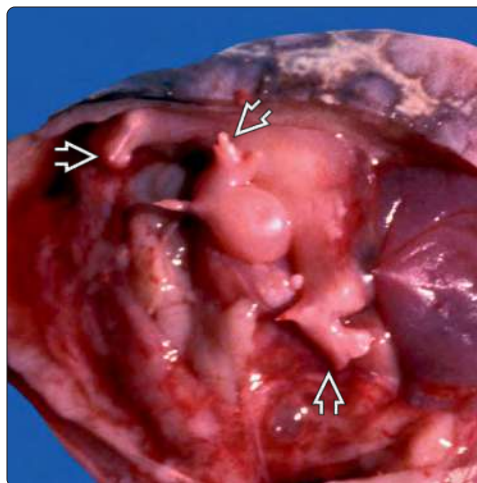
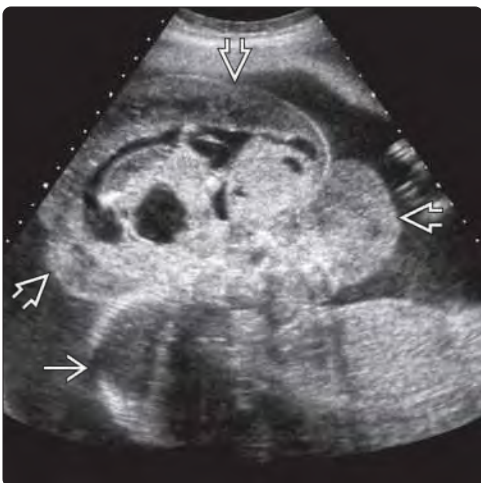1. Morlino S et al: Oropharyngeal teratoma, oral duplication, cervical diplomyelia and anencephaly in a 22-week fetus: A review of the craniofacial teratoma syndrome. *Birth Defects Res A Clin Mol Teratol.* 103(6):554-66, 2015
2. Walz PC et al: Prenatal diagnosis of obstructive head and neck masses and perinatal airway management: the ex utero intrapartum treatment procedure. *Otolaryngol Clin North Am.* 48(1):191-207, 2015
3. Laje P et al: Perinatal management of congenital oropharyngeal tumors: the ex utero intrapartum treatment (EXIT) approach. *J Pediatr Surg.* 48(10):2005-10, 2013
4. Allen LM: Prenatal 3-dimensional imaging techniques in the sonographic evaluation of an oral mass: comparison with postnatal imaging modalities. *J Ultrasound Med.* 30(4):561-8, 2011



(Left) Sagittal US of the fetal profile shows a large mass with both cystic and solid components protruding from the mouth. The jaw was held in a fixed, open position (mandible). (Right) Intraoperative photograph taken during the EXIT procedure is shown. The head and shoulders are partially delivered via C-section. The placenta and umbilical cord remain intact, and uteroplacental gas exchange is maintained. The mass is controlled while the intubation is performed.



(Left) 3D CT reconstruction of the face of a 29-week fetus shows the mouth held in an open position by a partially calcified mass. Fetal CT is not usually performed but can be additive if there is a question regarding bone invasion (none present in this case). (Right) Postmortem radiograph of a large, fungating epignathus shows internal calcifications.



(Left) Longitudinal US of a 2nd-trimester fetus shows an enormous epignathus (compare to the size of the fetal head). It is predominately solid with scattered cystic areas. Solid areas may be quite vascular and result in high-output cardiac failure and hydrops. (Right) Gross pathology of a portion of the specimen at autopsy shows areas of differentiation resembling extremities. Oropharyngeal teratomas often have fetus-like features.

KEY FACTS

TERMINOLOGY

- Benign soft tissue tumor arising from alveolar ridge

IMAGING

- Round, circumscribed mass in oral cavity
 - Homogeneous echogenicity
 - Usually solitary
 - Sessile or pedunculated
 - Vascular, may see feeding vessel in pedicle with color Doppler
- Use color Doppler to watch breathing/swallowing to prove patent nasopharynx/oropharynx
- MR may be used to confirm intact palate and prove no invasion of adjacent spaces

TOP DIFFERENTIAL DIAGNOSES

- Bilateral cleft lip, palate
 - Premaxillary protrusion may be mistaken for oral cavity mass




- Epignathus
 - Teratoma arising in oral/nasal cavity
 - Large, irregular shape, mixed echogenicity
- Macroglossia
 - Enlarged tongue; cannot fit in oral cavity

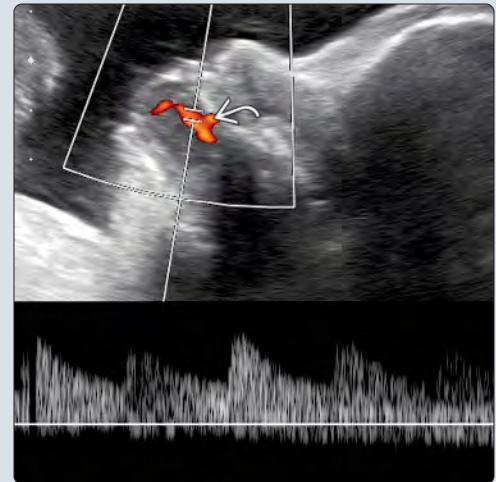
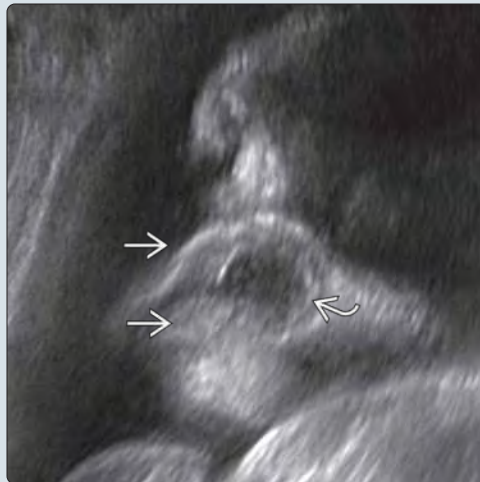
CLINICAL ISSUES



- Presents in 3rd trimester; F >> M
- May grow rapidly in utero
 - Potential for airway obstruction, mechanical feeding difficulties if large
 - May require EXIT procedure for delivery
- Conservative surgical resection important to avoid disruption of future dentition
- Some case reports of spontaneous regression

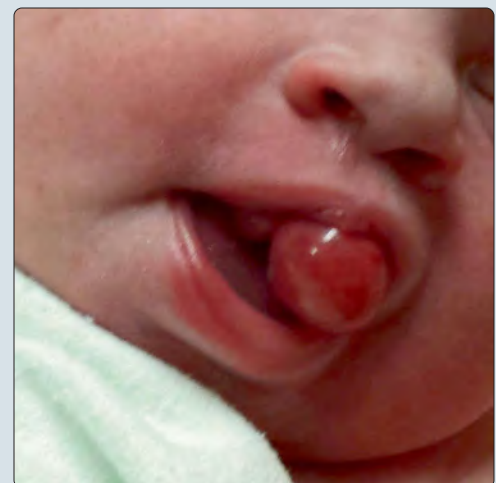
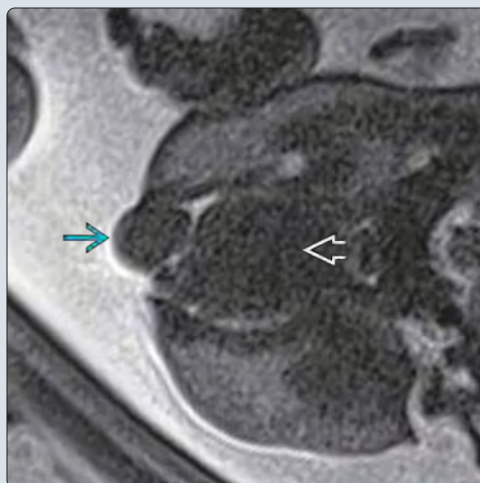
DIAGNOSTIC CHECKLIST

- Smooth contour and smaller size differentiates this tumor from epignathus

(Left) Coronal US in the late 3rd trimester shows a well-circumscribed mass  holding the fetal lips  apart. Amniotic fluid volume was generous but not enough for a diagnosis of polyhydramnios, and fetal breathing and swallowing were documented on real-time evaluation. **(Right)** Sagittal color Doppler US in the same case with color and spectral Doppler shows a vascular pedicle  in this mass, which was arising from the maxillary alveolar ridge. Maxillary origin is more frequent than mandibular.



(Left) Axial T2WI MR shows the mass  surrounded by amniotic fluid and separate from the tongue . Additional images showed that the palate was intact and confirmed that the mass was anterior in location. **(Right)** Clinical photograph confirms a round circumscribed mass arising from the maxillary alveolar ridge. The patient had a normal spontaneous vaginal delivery. The infant was able to breathe and nurse without difficulty, and the mass was resected without complication. Histology confirmed an epulis.



TERMINOLOGY**Synonyms**

- Myoblastic myoma
- Neumann tumor
- Gingival granular cell tumor of newborn

Definitions

- Benign soft tissue tumor arising from alveolar ridge

IMAGING**Ultrasonographic Findings**

- Round, circumscribed mass in oral cavity
 - Presents in 3rd trimester
 - All reported fetal cases had normal 2nd-trimester scan even in retrospect
- Homogeneous echogenicity
- Vascular, may see feeding vessel in pedicle with color Doppler
 - Spectral Doppler confirms arterial and venous flow
- Usually solitary
 - Multiple in 10% of cases
- Sessile or pedunculated
- Size varies from few mm to several cm; most < 2 cm
 - Prenatal diagnosis only possible if mass large enough to part lips or obstruct swallowing

MR Findings

- Not necessary for diagnosis
- Helpful for confirmation if sonographic access is limited by maternal habitus or fetal position
- May be used to confirm intact palate and prove no invasion of adjacent spaces
 - Epignathus is much more aggressive; can spread transsphenoidal
- Intermediate signal on T2WI

Imaging Recommendations

- Protocol advice
 - Use color Doppler to prove patent nasopharynx/oropharynx
 - Fetal breathing and swallowing cause fluid movement
 - Movement detected with color
 - Should see bidirectional movement to make sure no ball valve obstruction
 - 3D slices may show origin
 - 3D surface reconstructions easier for parents to understand

DIFFERENTIAL DIAGNOSIS**Bilateral Cleft Lip, Palate**

- Premaxillary protrusion may be mistaken for oral cavity mass

Epignathus

- Teratoma arising in oral/nasal cavity
- Large, rapidly growing
- Irregular shape, mixed echogenicity
- Frequently obstructs swallowing → polyhydramnios

Macroglossia

- Enlarged tongue; cannot fit in oral cavity
- Associated with Beckwith-Wiedemann syndrome
- Associated with trisomy 21

PATHOLOGY**General Features**

- Etiology
 - Unknown; maternal hormonal stimulation proposed
- Benign mesenchymal tumor
- Maxillary origin 3x as frequent as mandibular

Gross Pathologic & Surgical Features

- Covered in stratified squamous epithelium
- Stroma composed of fibrous connective tissue

CLINICAL ISSUES**Presentation**

- Other signs/symptoms
 - Polyhydramnios if swallowing obstructed
 - No known associated anomalies

Demographics

- Epidemiology
 - F:M = 10:1
 - Caucasians

Natural History & Prognosis

- May grow rapidly in utero
 - Monitor size, airway, and swallowing to plan delivery
 - Large, obstructing lesions may require EXIT procedure for delivery
- No further growth after delivery
- Potential for airway obstruction, mechanical feeding difficulties if large

Treatment

- Conservative surgical resection important to avoid disruption of future dentition
 - No reported recurrence
 - No risk of malignant degeneration
- Some case reports of spontaneous regression

DIAGNOSTIC CHECKLIST**Image Interpretation Pearls**

- Rare entity but has typical appearance
- Smooth contour and smaller size differentiates this tumor from epignathus

SELECTED REFERENCES

1. Gnassingbe K et al: Congenital giant epulis obstructing oral cavity: newborn emergency. *Pan Afr Med J.* 17:195, 2014
2. Yee J: Congenital epulis in a newborn. *Minn Med.* 97(5):39, 2014
3. Bhatia SK et al: Spontaneous regression of a congenital epulis in a newborn. *J Clin Pediatr Dent.* 37(3):297-9, 2013
4. Frisova V et al: Prenatal diagnosis of congenital epulis by 2D/3D ultrasound and magnetic resonance. *Fetal Diagn Ther.* 33(4):272-6, 2013
5. Laje P et al: Perinatal management of congenital oropharyngeal tumors: the ex utero intrapartum treatment (EXIT) approach. *J Pediatr Surg.* 48(10):2005-10, 2013

KEY FACTS

TERMINOLOGY

- Fetal thyroid enlargement due to hyper- or hypothyroidism

IMAGING

- Anterior neck mass of homogeneous echogenicity
 - Maintains thyroid contour and morphology
 - Axial view shows gland best
 - Normative data available
- Mass effect from goiter
 - May obstruct swallowing → polyhydramnios
 - Tracheal compression → airway compromise at birth
 - Extended neck → obstructed labor (dystocia)
- Fetal hyperthyroidism
 - Tachycardia
 - Advanced bone maturity
 - Fetal growth restriction
- Fetal hypothyroidism
 - Delayed bone maturation

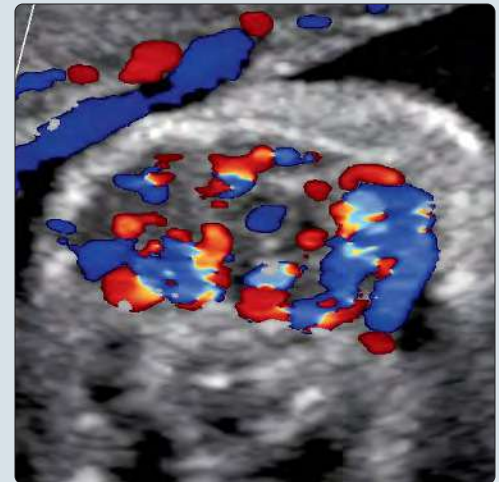
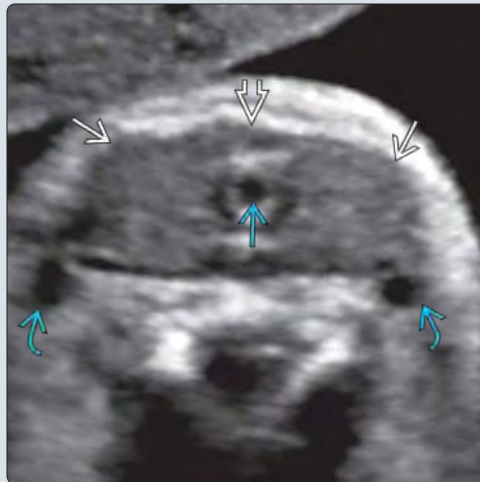
CLINICAL ISSUES

- Goiter most commonly from maternal thyroid dysfunction, but may be due to primary fetal problem
- Fetal hyperthyroid state due to transplacental passage of maternal thyroid-stimulating antibodies
 - Maternal Graves disease most common cause
 - 40% have fetal thyroid dysfunction if maternal antibodies > 3x normal
- Fetal hypothyroid state most commonly due to maternal antithyroid medication or endemic iodine deficiency
- Fetus generally responds rapidly to treatment

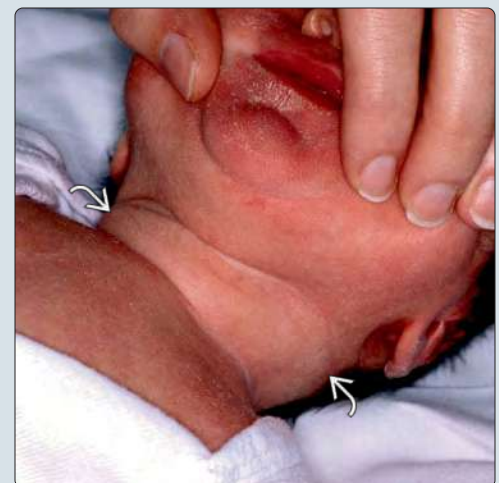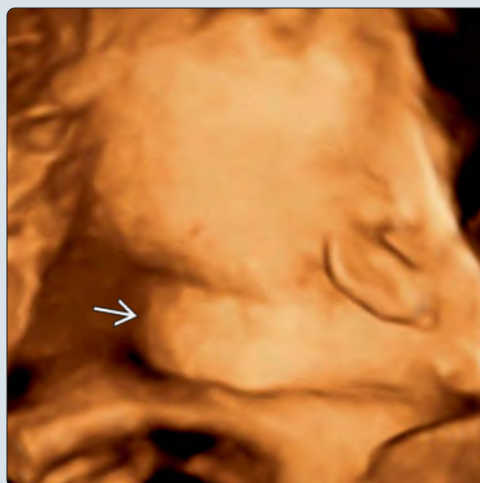DIAGNOSTIC CHECKLIST

- Always assess fetal neck in cases of unexplained polyhydramnios
 - Fetal goiter can occur even in maternal euthyroid state
- 2 crucial points when goiter present
 - Evaluation of fetal thyroid function
 - Evaluation for airway obstruction

(Left) Axial US of a fetal goiter shows enlarged right and left thyroid lobes connected anteriorly by the isthmus. The fluid-filled trachea is seen centrally, and the carotid arteries are displaced posteriorly. **(Right)** Color Doppler shows the gland is hypervascular. The fetus also had tachycardia. This case exemplifies goiter from fetal hyperthyroidism in a pregnancy complicated by maternal Graves disease and increased maternal thyroid antibody titers.



(Left) 3D US of a 3rd-trimester fetus with a goiter shows an anterior neck "bulge". The head was persistently extended. **(Right)** Clinical photograph shows a neonate who was successfully treated with intraamniotic injections of levothyroxine (Synthroid) for hypothyroidism and goiter. Redundant skin and mild goiter remain, but the infant was euthyroid.



TERMINOLOGY**Definitions**

- Fetal thyroid enlargement due to hyper- or hypothyroidism
 - Rarely, goiter may be present in euthyroid fetus

IMAGING**General Features**

- Best diagnostic clue
 - Homogeneous echogenic anterior cervical neck mass

Ultrasonographic Findings

- Enlarged thyroid gland
 - Maintains contour and morphology
 - Axial view shows gland best
 - Thyroid gland anterior and lateral to fluid-filled trachea
 - Carotid and jugular vessels seen lateral to lobes
 - Coronal view shows longitudinal view of neck vessels
 - May be splayed by large gland
 - Seen best with color Doppler
 - Normative size data available
 - Goiter is most often 3rd-trimester finding
- Mass effect from goiter
 - Polyhydramnios from obstruction to swallowing
 - Fetal neck extension
 - May cause obstructed labor and dystocia
 - Tracheal compression → airway compromise at birth
- **Fetal hyperthyroidism findings**
 - Fetal tachycardia and pulmonary hypertension
 - Can lead to hydrops, high-output cardiac failure, intrauterine fetal demise (IUFD)
 - ↑ central flow to gland seen with color Doppler
 - Accelerated bone maturation, including craniosynostosis
 - Most specific finding differentiating hyperthyroidism from hypothyroidism
 - Growth restriction
- **Hypothyroidism findings**
 - ↑ peripheral flow to gland seen with color Doppler
 - Delayed bone maturation

MR Findings

- T1WI: Homogeneous and slight ↑ signal
 - ↑ signal postulated to be from ↑ iodine or ↑ colloid
 - Helps differentiate goiter from other neck masses
- T2WI: Intermediate signal intensity
 - Best evaluation of tracheal/esophageal compression
 - Trachea normally seen as fluid-filled column
 - If not visible → ↑ risk of airway compromise at birth

Imaging Recommendations

- Monitor
 - Fetal growth
 - Heart rate and rhythm
 - Amniotic fluid volume
- Watch for signs of hydrops
- Serial thyroid measurements in at-risk patient or to follow therapy (both maternal and fetal therapy might be administered)
 - Axial section midthyroid level

- Measure maximum transverse diameter and circumference
- Monthly, starting at 22 weeks
- Use color Doppler to assess thyroid vascularity

DIFFERENTIAL DIAGNOSIS**Cervical Teratoma**

- Often large, irregular shape
- Mixed echogenicity ± irregular calcifications
- May extend into mediastinum
- Most exhibit rapid growth

Cervical Neuroblastoma

- Heterogeneous, solid, posterior mass ± microcalcifications
- Very rare

PATHOLOGY**General Features**

- Etiology
 - Hyperthyroid
 - Transplacental passage of maternal thyroid-stimulating antibodies
 - Maternal Graves most common cause
 - Hypothyroid
 - Transplacental passage of maternal antithyroid drugs
 - Both iodine insufficiency and intoxication
 - Inborn errors of thyroid metabolism
 - Fetal goiter most commonly associated with maternal thyroid dysfunction but may also be due to primary fetal problem
- Genetics
 - No association with aneuploidy
 - Pendred syndrome
 - Sensorineural deafness and goiter
 - Autosomal recessive condition with deficient thyroid hormone synthesis

CLINICAL ISSUES**Presentation**

- Noted during surveillance in patient with Graves disease
- Fetus may develop goiter despite maternal euthyroid state
- Incidentally noted anterior neck mass

Demographics

- Epidemiology
 - Fetal goiter incidence 1:40,000 deliveries
 - 1:3,500 newborns with hypothyroidism
 - ↑ incidence in iodine-deficient areas
 - Maternal antithyroid therapy → 10-15% newborns with hypothyroidism
 - Mothers with Graves disease
 - < 5% fetal thyroid dysfunction if treated or recently diagnosed maternal Graves
 - 40% fetal thyroid dysfunction if maternal antibodies > 3x normal
 - Enlargement of fetal thyroid in mothers with Graves disease may be earliest sign of gland dysfunction
 - US surveillance is important

Thyroid Circumference (cm)

GA (wk)	TC, Mean (10th-90th Percentile)	GA (wk)	TC, Mean (10th-90th Percentile)
18	2.4 (1.8-3.0)	28	3.6 (2.8-4.4)
19	2.5 (1.8-3.1)	29	3.8 (3.0-4.6)
20	2.5 (1.9-3.2)	30	4.0 (3.1-4.8)
21	2.6 (2.0-3.3)	31	4.2 (3.3-5.0)
22	2.8 (2.1-3.4)	32	4.4 (3.5-5.2)
23	2.9 (2.2-3.6)	33	4.6 (3.7-5.5)
24	3.0 (2.3-3.7)	34	4.8 (3.9-5.7)
25	3.1 (2.4-3.9)	35	4.8 (3.9-5.7)
26	3.3 (2.5-4.0)	36	5.3 (4.3-6.2)
27	3.4 (2.7-4.2)	37	5.5 (4.6-6.5)

GA = gestational age; TC = thyroid circumference. Modified from Ranzini AC et al: Ultrasonography of the fetal thyroid: nomograms based on biparietal diameter and gestational age. *J Ultrasound Med.* 20:613-617, 2001.

Natural History & Prognosis

- Prognosis depends on basic cause of goiter
- Maternal hyperthyroidism (Graves disease patients with persistent hyperthyroidism in pregnancy)
 - Increased incidence of spontaneous abortion
 - 5.6% IUFD or stillbirth
 - 72 pregnant women with history of Graves disease
 - 57% antibody positive or on antithyroid medication
 - 27% (11 fetuses) had goiter by 32-weeks gestation
 - 1 IUFD due to hyperthyroidism/heart failure
 - 10 treated successfully
 - 43% antibody negative, no medication
 - No fetal goiter, 1 neonate mildly hypothyroid
- Maternal hypothyroidism
 - Impaired fertility
 - Higher incidence of spontaneous abortion
 - Associated findings with fetal hypothyroidism
 - Deficient myelination → learning difficulties
 - Unlikely to result in cretinism, as neonatal treatment alone is generally effective in prevention
 - Some suggest that in utero therapy may obviate adverse neurological events
- If no response, or progressive increase in size, fetus likely hyperthyroid
 - Consider cordocentesis for direct measurement of fetal thyroid hormones
- Measure fetal free T3, free T4, and TSH levels in cord blood
 - Serum levels more reliable than amniotic fluid levels
- If fetal hyperthyroidism confirmed
 - Increase maternal medication until fetal response
 - Thyroxine replacement to keep mother euthyroid
 - May need intraamniotic administration of L-thyroxine
- Fetus generally responds rapidly to treatment
 - Reduction in size of goiter, resolution of polyhydramnios
- Refer to tertiary center for delivery
 - May require C-section for persistent head extension
 - If persistent goiter, consider EXIT procedure (ex utero intrapartum treatment) for delivery

Treatment

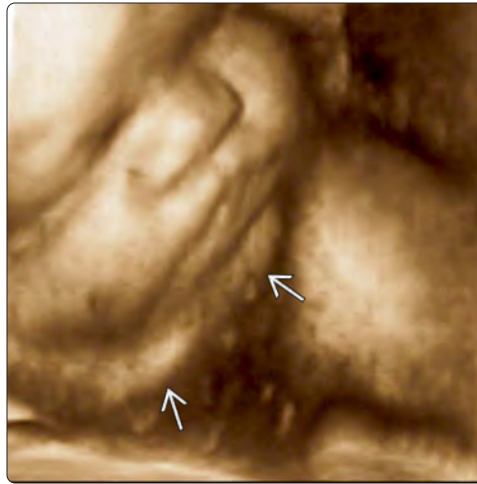
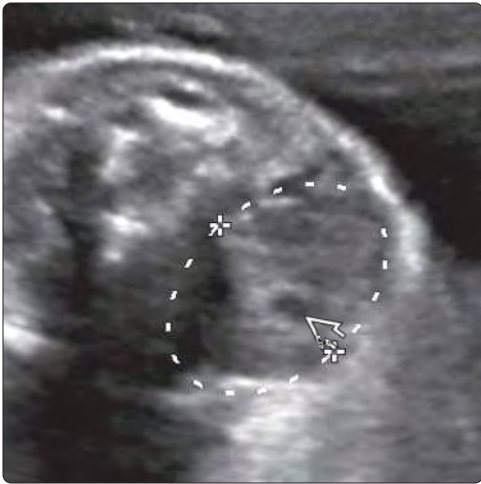
- Maternal thyroid function testing when fetal thyroid disease suspected
 - TSH, free T3, free T4
 - Antithyroid antibodies
 - Antithyroid peroxidase
 - Antithyroglobulin
 - TSH receptor-blocking antibodies
- Monitor fetal thyroid size if pregnancy at risk 2° to maternal hyperthyroidism treatment
 - If thyroid is large, assume fetus hypothyroid due to maternal drugs crossing placenta
 - Decrease maternal antithyroid drugs and monitor fetal thyroid size
 - If thyroid size returns to normal, no fetal intervention required

DIAGNOSTIC CHECKLIST**Consider**

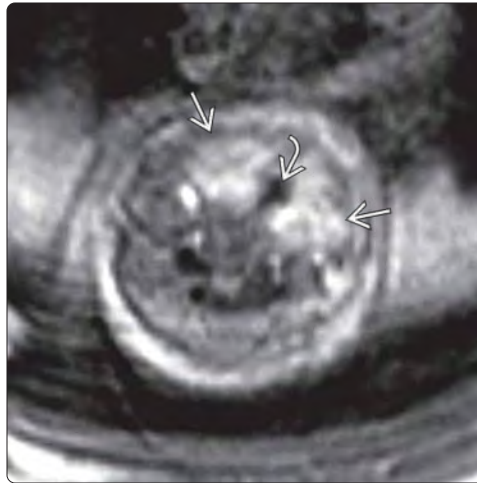
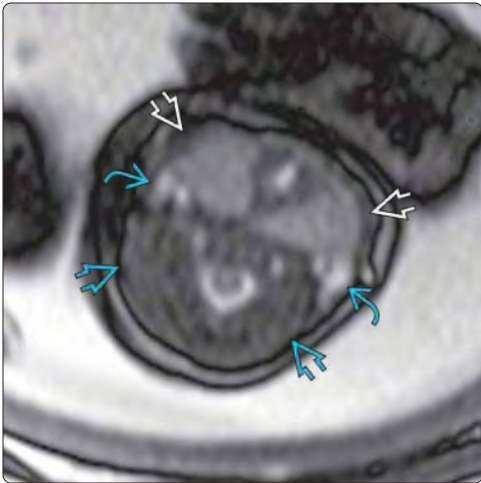
- 2 crucial points when goiter present
 - Evaluation of fetal thyroid function
 - May necessitate intervention for diagnosis and treatment
 - Evaluation for airway obstruction
 - Set appropriate delivery plan

SELECTED REFERENCES

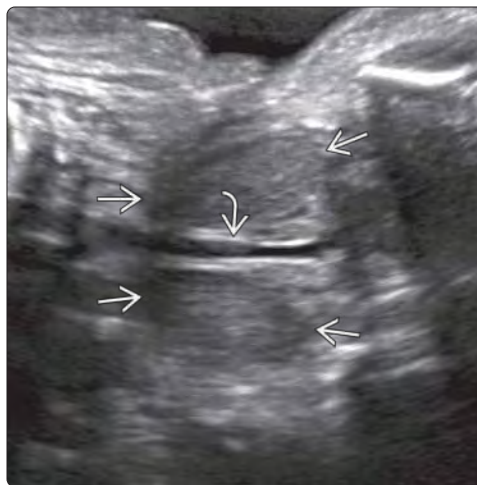
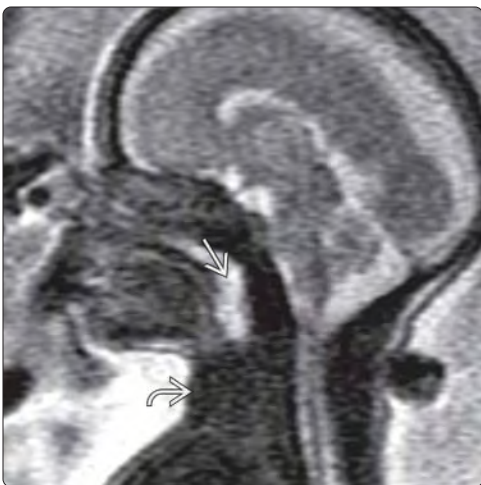1. Donnelly MA et al: Early severe fetal Graves disease in a mother after thyroid ablation and thyroidectomy. *Obstet Gynecol.* 125(5):1059-62, 2015
2. Mastrolia SA et al: Antenatal diagnosis and treatment of hypothyroid fetal goiter in an euthyroid mother: a case report and review of literature. *J Matern Fetal Neonatal Med.* 1-7, 2014
3. Polak M et al: Fetal thyroidology. *Best Pract Res Clin Endocrinol Metab.* 28(2):161-73, 2014
4. Patil-Sisodia K et al: Graves hyperthyroidism and pregnancy: a clinical update. *Endocr Pract.* 16(1):118-29, 2010
5. Raymond J et al: Fetal and neonatal thyroid function: review and summary of significant new findings. *Curr Opin Endocrinol Diabetes Obes.* 17(1):1-7, 2010



(Left) The thyroid circumference is measured in this fetus with a goiter. The measurement is performed along the periphery of the gland and includes the trachea . This can be compared to normative data to determine if the thyroid is enlarged and to follow thyroid size when maternal or fetal therapy is administered. (Right) 3D US in the same fetus shows the goiter . Though there was mild polyhydramnios, the airway and esophagus were patent.



(Left) Axial T2-weighted MR of a fetal goiter shows that the thyroid gland is mildly increased in signal, when compared with the neck muscles . The neck vessels are also seen well. (Right) With T1-weighted MR in the same fetus, the goiter signal intensity is greater than seen on the T2 image. This is characteristic of a fetal goiter and helps to differentiate it from other neck masses. On this sequence, fluid within the trachea is now hypointense.



(Left) Sagittal T2 MR shows a fetal goiter secondary to stimulation by maternal antibodies. The oropharynx is distended due to esophageal and tracheal compression. Large goiters are associated with polyhydramnios and airway compromise. (Right) While MR is the best modality to evaluate the fetal airway, on this coronal US in a fetus with goiter, the fluid-filled trachea is seen well between the enlarged thyroid lobes .

KEY FACTS

TERMINOLOGY

- Definition: Nuchal lymphangioma

IMAGING

- Large nuchal multiseptated fluid-filled mass
 - Posterior/lateral location
 - Multiple internal linear septations key to diagnosis
- Cystic hygroma (CH) is often associated with hydrops
 - Hydrops defined as fluid in 2 anatomic areas
 - CH counts as 1 area
- Aneuploidy in 2/3 fetuses with 2nd-trimester CH
 - Turner syndrome (monosomy X): Most common
 - Trisomy 21: 2nd most common
- 1st-trimester CH: ↑ nuchal translucency + septations
 - Aneuploidy in 55%
 - Trisomy 21: Most common
 - Turner syndrome: 2nd most common

TOP DIFFERENTIAL DIAGNOSES

- Body/trunk lymphangioma
- Occipital encephalocele
- Cervical teratoma

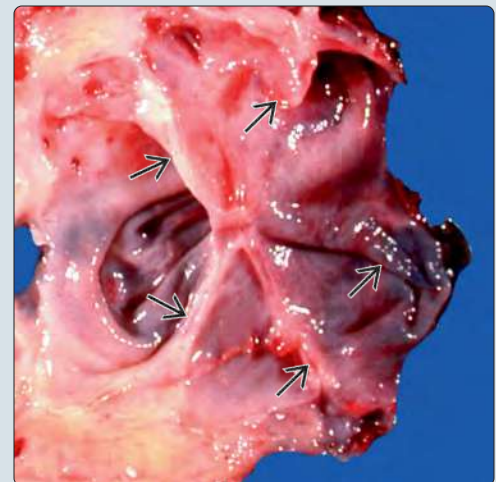
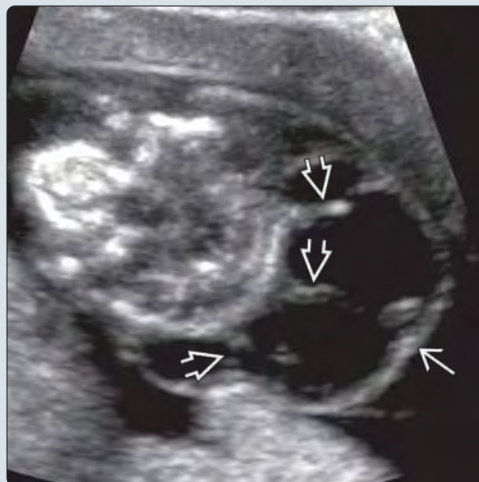
CLINICAL ISSUES

- Monosomy X is not associated with advanced maternal age
- CH also associated with other genetic syndromes
 - Noonan syndrome most common
- Markedly increased morbidity and mortality if hydrops or other anomalies seen
- Small percentage resolve in utero
 - More likely if small CH in euploid fetuses

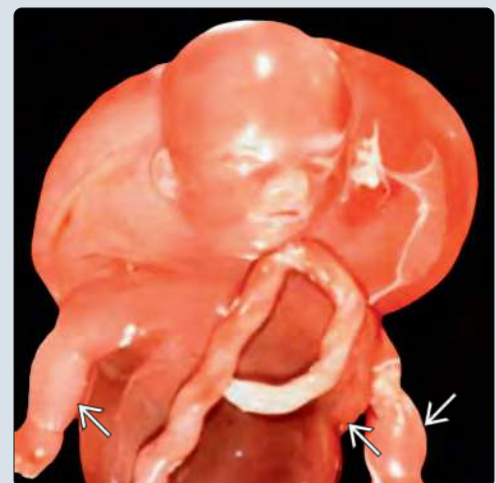
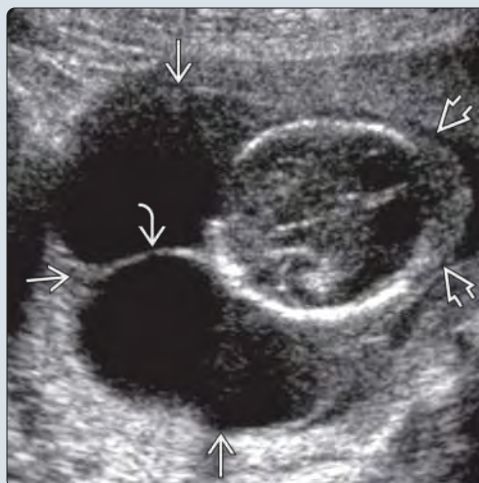
DIAGNOSTIC CHECKLIST

- Offer genetic testing in all cases
- Look carefully for other anomalies
- Recommend fetal echocardiography

(Left) Ultrasound shows an early 2nd-trimester cystic hygroma (CH). Axial view through the posterior neck shows a large cystic mass with septations. This fetus had multiple other anomalies. Chorionic villus sampling (CVS) results were normal, but the fetus died in utero. **(Right)** Gross pathology of a CH shows multiple internal septations. CHs are smooth cystic masses of dilated lymphatic sacs lined by a single layer of flattened endothelium.



(Left) Axial ultrasound shows a large CH, which contains a central septation, the nuchal ligament. In addition, there is skin thickening involving the scalp. This fetus also had a hypoplastic left heart. Left-sided heart defects and CH are hallmark findings of Turner syndrome (monosomy X). **(Right)** Postmortem photograph of a fetus with Turner syndrome shows a large CH as well as body wall and extremity edema. CH, hydrops, and Turner syndrome are common associations.



TERMINOLOGY

Abbreviations

- Cystic hygroma (CH)

Synonyms

- Nuchal lymphangioma

Definitions

- Dilated lymphatics from venous-lymphatic malformation

IMAGING

General Features

- Best diagnostic clue
 - Large nuchal multiseptated fluid-filled mass

Ultrasonographic Findings

- Posterior/lateral nuchal cystic mass
 - Best seen on axial posterior fossa view
 - Sagittal and coronal views show extent
- Multiple internal linear septations key to diagnosis
 - Thick midline septation is nuchal ligament
- Although variable in size, most often CH is large
 - Can mimic amniotic fluid
 - Sometimes CH is only fluid source for amniocentesis
 - Small CH can evolve into thick nuchal fold
- CH is often associated with hydrops
 - Lymphatic disorder → excess fetal fluid accumulation
 - Hydrops defined as fluid in 2 anatomic areas
 - CH counts as 1 area
 - Skin edema (anasarca)
 - Ascites, pleural effusion, pericardial effusion
 - Other findings: Polyhydramnios, thick placenta
- **2nd-trimester CH**
 - Aneuploidy in 2/3 fetuses with 2nd-trimester CH
 - Turner syndrome (monosomy X): Most common
 - CH is hallmark finding
 - Cardiovascular anomalies (60%)
 - Hypoplastic left heart
 - Coarctation of aorta
 - Horseshoe kidney: Kidneys fused inferiorly
 - Look for fused renal tissue anterior to aorta
 - Mild short stature: Short femur/humerus
 - Disorder of sexual differentiation (ambiguous genitalia)
 - Mixed gonadal dysgenesis, Turner mosaic (45X/46XY)
 - Trisomy 21 (T21): 2nd most common
 - Small CH more often than large
 - ↑ nuchal fold more common than CH
 - Look for associated markers of T21
 - Look for other associated anomalies of T21
 - Atrioventricular canal, duodenal atresia
 - Trisomy 18 (T18)
 - Other major anomalies often seen
 - Fetal growth restriction
 - Trisomy 13 (T13)
 - Other major anomalies
 - Holoprosencephaly is hallmark finding
 - FGR

- **1st-trimester CH:** ↑ nuchal translucency (NT) + septations
 - Typically very large NT (> 5 mm is typical)
 - Hydrops more subtle
 - 1st-trimester CH and aneuploidy (55%)
 - T21 most common (21%)
 - Turner syndrome (12%)
 - T18 (11%)
 - T13 (4%)
 - Triploidy (1%)
 - Mosaicism (1%)
 - Other (5%)
 - Look for other markers for aneuploidy
 - Absent nasal bone
 - Reversal of ductus venosus flow
 - Other major anomalies
 - CH in euploid fetuses
 - 15% with cardiac defects

Imaging Recommendations

- Best imaging tool
 - 11- to 14-week NT screening
 - 2nd-trimester anatomy scan
- Protocol advice
 - Offer genetic testing
 - Chorionic villus sampling in 1st trimester
 - Amniocentesis in 2nd trimester
 - Remember that noninvasive prenatal testing (cell-free DNA) is screening test
 - Look carefully for other anomalies, even in 1st trimester
 - Perform fetal echocardiography in all cases
 - Even if normal chromosomes
 - Follow-up ultrasound important
 - High rates of in utero demise
 - May see other anomalies as fetus grows

DIFFERENTIAL DIAGNOSIS

Body/Trunk Lymphangioma

- Nonnuchal cystic mass
 - Often large and septated
- Axilla is most common site but occurs anywhere
- Infiltrative mass
 - Fetal MR helps show extent
 - Prognosis related to structures affected
- Not associated with aneuploidy

Occipital Encephalocele

- Posterior neck mass from open neural tube defect
- Look for calvarial bony defect
 - Variable amounts of brain/meninges involved
 - Abnormal intracranial anatomy
 - Posterior fossa contents exposed to amniotic fluid
- Associations
 - Meckel-Gruber syndrome
 - Aneuploidy

Cervical Teratoma

- Germ cell tumor
 - Aggressive growth common
 - May be malignant
- Most often anterior neck

- Fetal neck often hyperextended
- Associated with airway obstruction
- Solid or mixed solid-cystic mass
 - ± calcification

PATHOLOGY

General Features

- Etiology
 - Anomaly of vascular-lymphatic system formation
 - Failed venous → lymphatic connection
 - Leads to distended fluid-filled spaces
 - Hydrops from fluid overload
 - Normal embryology
 - Lymphatics from outgrowth of venous system
 - Paired jugular venous buds → lymphatic sacs
 - Communication established by 40 days
- Genetics
 - Aneuploidy (55-70%)
 - Turner syndrome (monosomy X)
 - Most common with 2nd-trimester CH
 - Trisomy 21
 - Most common with 1st-trimester CH
 - Trisomy 18/trisomy 13
 - More common with 1st-trimester CH
 - Triploidy
 - Other: Mosaicism, unbalanced translocations, duplications, deletions, inversions, sex chromosome abnormalities
 - Genetic syndromes
 - Noonan syndrome most common
 - Angelman syndrome
 - Skeletal dysplasias
 - Cornelia de Lange syndrome
 - Multiple other rare syndromes
 - Associated abnormalities
 - Cardiovascular anomalies
 - Large variety of other anomalies
 - Mostly associated with aneuploidy/syndromes

Microscopic Features

- Cavernous lymphatic spaces
- Flattened endothelial lining

CLINICAL ISSUES

Presentation

- Most common signs/symptoms
 - Incidental finding on ultrasound
 - Abnormal maternal serum screen results
 - Noninvasive prenatal testing (cell-free fetal DNA): 89% detection rate for Turner
 - Quad screen: 53% detection rate for Turner syndrome
- Other signs/symptoms
 - Nonimmune hydrops
 - Fetal anomalies
 - Fetal demise

Demographics

- Age

- Turner syndrome not associated with advanced maternal age (AMA)
- T21/T13/T18 are associated with AMA
- Gender
 - F > M
 - Secondary to Turner syndrome association
- Epidemiology
 - 1:200 spontaneous abortions
 - 1:600 low-risk pregnancies
 - 1:1,750 live births

Natural History & Prognosis

- 75% mortality if CH + other anomaly
- 37% mortality if CH isolated (normal chromosomes)
- Outcome in fetuses with CH at time of NT screening (recent large study of 944 fetuses)
 - Overall abnormal outcome in 87% (including terminations)
 - 55% with aneuploidy
 - 29% of fetuses with normal chromosomes had major anomalies
 - Cardiac anomaly most common
 - 61% live birth rate when termination not pursued
 - Larger NTs associated with worse outcomes
- Hydrops associated with grim prognosis
 - 80-90% demise
- 10-20% resolve in utero
 - More likely if small CH in euploid fetuses

Treatment

- Complete surgical resection often difficult 2° to infiltrative nature of CH
 - Postsurgical recurrence (15%)
- Sclerosing agents injected directly into CH

DIAGNOSTIC CHECKLIST

Consider

- Genetic testing in all cases of CH

Image Interpretation Pearls

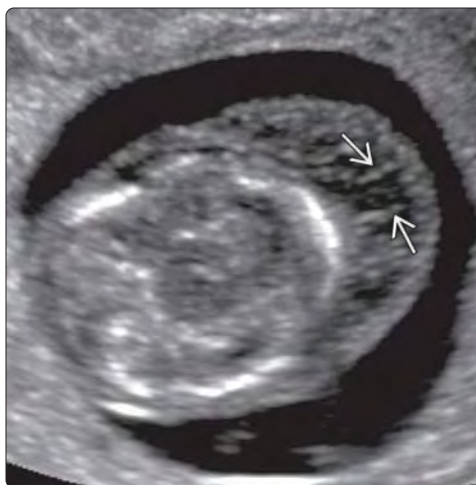
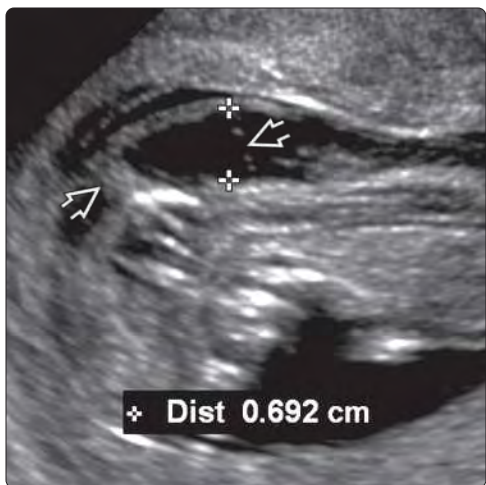
- T21 > Turner with 1st-trimester CH
- Turner > T21 with 2nd-trimester CH
- CH + hydrops with grim prognosis



Reporting Tips

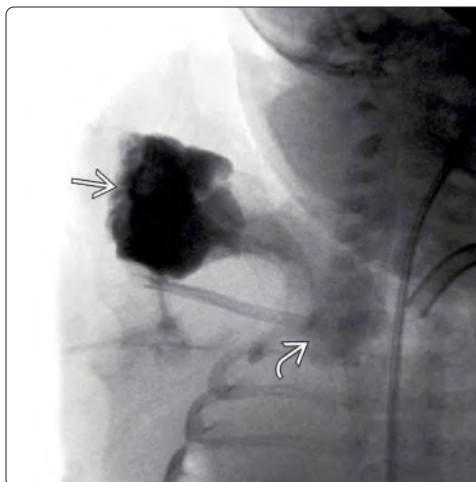
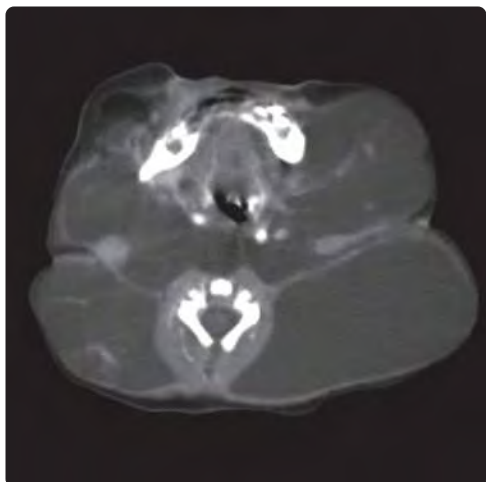
- Recommend fetal echocardiography in cases with 1st-trimester CH and normal chromosomes



SELECTED REFERENCES

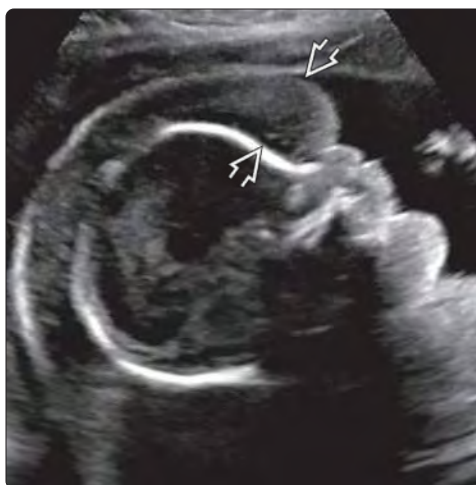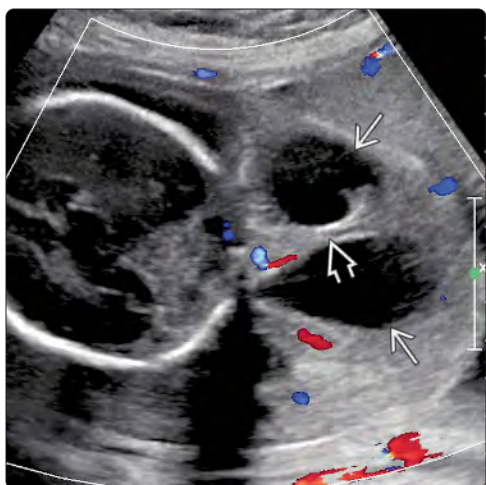
1. Malone LJ et al: Pediatric lymphangiectasia: an imaging spectrum. *Pediatr Radiol.* 45(4):562-9, 2015
2. Chen M et al: Cystic hygroma detected in the first trimester scan in Hong Kong. *J Matern Fetal Neonatal Med.* 27(4):342-5, 2014
3. Noia G et al: Fetal cystic hygroma: the importance of natural history. *Eur J Obstet Gynecol Reprod Biol.* 170(2):407-13, 2013
4. Scholl J et al: First-trimester cystic hygroma: relationship of nuchal translucency thickness and outcomes. *Obstet Gynecol.* 120(3):551-9, 2012
5. Sananes N et al: Nuchal translucency and cystic hygroma colli in screening for fetal major congenital heart defects in a series of 12,910 euploid pregnancies. *Ultrasound Obstet Gynecol.* 35(3):273-9, 2010
6. Gedikbasi A et al: Multidisciplinary approach in cystic hygroma: prenatal diagnosis, outcome, and postnatal follow up. *Pediatr Int.* 51(5):670-7, 2009






(Left) A large nuchal translucency (NT) of 6.9 mm is seen in this 12-week fetus. Note the presence of thick and thin septations , allowing for a more accurate diagnosis of CH, rather than simply increased NT. **(Right)** Axial view through the posterior neck in the same fetus shows more thin septations  in the associated anasarca. The patient chose to have CVS instead of maternal serum screening. The results were positive for an unbalanced translocation.



(Left) Axial contrast enhanced CT in a child with a CH shows the infiltrative nature of the mass as it dissects between all muscle planes. **(Right)** A fluoroscopic image of contrast injection into a CH during a sclerosis procedure shows contrast filling the cystic structures , which extends towards the chest . In a CH, dilated lymphatic channels fail to communicate with appropriate venous channels.



(Left) In this fetus with 2nd-trimester CH and normal chromosomes, cysts  and septations  are seen in the posterior neck. **(Right)** A profile view in the same patient shows marked scalp and facial anasarca . The fetus developed worsening hydrops at 30 weeks, and the newborn died shortly after delivery.

KEY FACTS

IMAGING

- Anterior neck mass
 - Predominately solid or mixed cystic/solid
 - Frequently extends to involve surrounding structures
 - Often large and can be massive
- Polyhydramnios is common and often severe
- 3D US to better evaluate extent of mass
 - Helpful visual aid for counseling parents
- Color Doppler to evaluate vascularity
 - Mass may cause high output cardiac failure and hydrops
- Perform detailed assessment of normal neck structures looking for invasion or compression
- MR recommended to better delineate anatomic extent and patency of airway

TOP DIFFERENTIAL DIAGNOSES

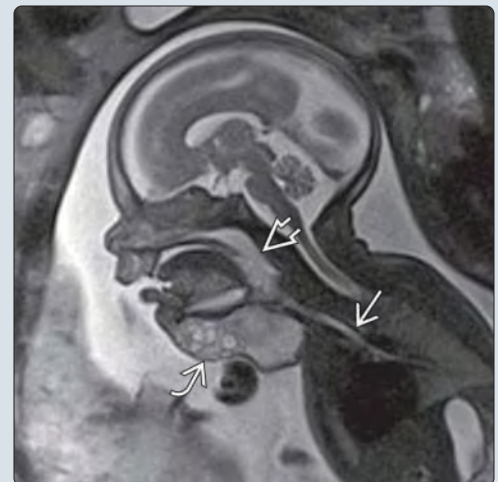
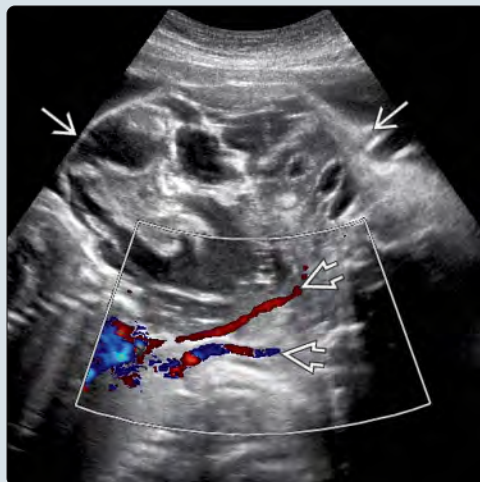
- Cystic hygroma
 - Septated fluid collection in posterior/lateral neck
- Goiter

- Homogeneously echogenic neck mass
- Maintains normal thyroid contour
- Soft tissue tumors rare

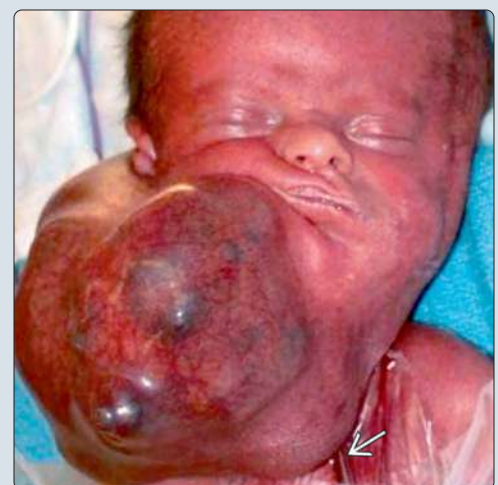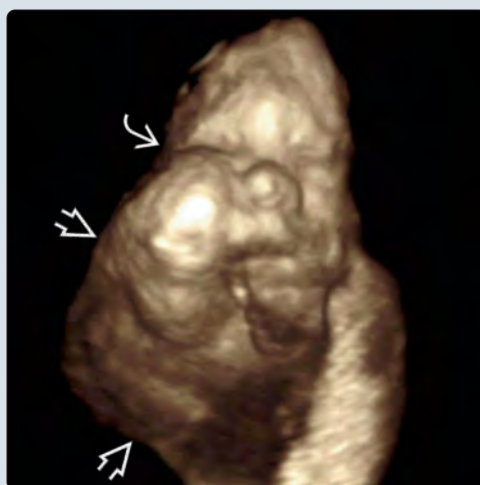CLINICAL ISSUES

- Head often held in hyperextension or deviated to side
 - May be dramatic, resulting in malpresentation and dystocia, precluding vaginal delivery
- May show rapid in utero growth
- If pregnancy continued, deliver at tertiary care facility with capability of performing EXIT procedure if needed
 - Provides controlled environment to establish airway
 - Substantial improvement in survival (mortality rate 23%)
- Quality of life study on neck masses showed children with resected teratoma had better quality of life than those with lymphatic malformations
 - Surgery for teratoma is usually curative, while lymphatic malformations recur

(Left) Coronal US through the neck shows a large cervical teratoma. Color Doppler shows both carotid arteries are patent. Try to assess the airway and watch for movement of fluid through the pharynx during fetal swallowing and breathing. **(Right)** MR provides superior resolution of pharyngeal anatomy. The oropharynx and trachea are well seen in this fetus with a neck teratoma (the bulk of the mass was to the right). Assessing the airway is critical for delivery planning.



(Left) 3D surfaced-rendered image shows a bulky cervical teratoma extending from the neck into the face, distorting the eye, and on other views, also the ear. These types of images are valuable for counseling the patient. **(Right)** The fetus was delivered via an EXIT procedure and was unable to be intubated so a tracheostomy tube was placed. The mass was resected day 3 of life and was an immature teratoma.



IMAGING**Ultrasonographic Findings**

- Mixed cystic and solid mass involving anterior neck
 - May be nearly circumferential but bulk of mass is anterior
- Commonly extends to involve surrounding structures
 - Superior extension frequently up to mastoid
 - May displace ear and distort jaw
 - Inferior extension to clavicle or even into mediastinum
- Calcifications are virtually pathognomonic of teratoma but are present in < 20% of cases
- Often large and can be massive
- Head held hyperextension when large
 - May be dramatic
 - Head may be deviated to 1 side
- Polyhydramnios from upper esophageal obstruction
- Hydrops may develop with large masses
- Solid portions often very vascular on color Doppler
- 3D US
 - Better evaluation of extent of mass
 - Helpful visual aid for counseling parents

MR Findings

- Best modality for determining anatomic extent and patency of airway
 - Look for fluid-filled trachea

Imaging Recommendations

- Routine views of chest, head, and face should detect virtually all cases
- Assess normal neck structures looking for invasion or compression
 - Color Doppler for carotid arteries
 - Detailed assessment of naso- and oropharynx
 - Watch swallowing and breathing, looking for obstruction
- Close interval follow-up
 - May grow rapidly to massive size
 - Monitor for worsening polyhydramnios and hydrops

DIFFERENTIAL DIAGNOSIS**Cystic Hygroma**

- Cystic mass in posterior and lateral neck
- Internal septations
 - Multiple thin septations common
 - Midline thick septation is nuchal ligament
- Should not have solid components

Goiter

- Homogeneously echogenic neck mass
- Maintains normal thyroid contour

Soft Tissue Tumors

- All rare: Hemangioma, fibromatosis, myofibromatosis, fibrosarcoma, rhabdomyosarcoma, neuroblastoma

PATHOLOGY**Staging, Grading, & Classification**

- Teratomas classified as mature or immature

- Size, vascularity, and location are much more important than histology in fetus

CLINICAL ISSUES**Presentation**

- Most common signs/symptoms
 - Obvious soft tissue mass involving neck
 - Head often held in hyperextension or deviated to side
 - Polyhydramnios

Demographics

- Epidemiology
 - Head and neck 2nd most common site for teratomas after sacrococcygeal area
 - Equal distribution between males and females
 - Different from most teratomas, which are more common in females

Natural History & Prognosis

- Polyhydramnios may cause preterm labor
- Hyperextension of neck results in malpresentation and dystocia, precluding vaginal delivery
- Lethal if unable to establish airway
- Substantial improvement in survival achieved with ex utero intrapartum treatment (EXIT) procedure
 - Mortality rate for head and neck teratomas is 23% (nasal/oropharyngeal + cervical)
- Quality of life study on neck masses showed children with resected teratoma had better quality of life than those with lymphatic malformations
 - Lymphatic malformations recur and cause disfigurement, while surgery for teratoma is usually curative

Treatment

- Termination may be offered
- If pregnancy continued, deliver at tertiary care facility with capability of performing EXIT procedure
- EXIT procedure provides controlled environment to establish airway
 - Fetus is partially delivered by cesarean section while placenta and umbilical cord remain intact
 - Uteroplacental gas exchange maintained
- Depending on size and location, may require immediate resection (EXIT to resection)

DIAGNOSTIC CHECKLIST**Consider**

- Delivery planning crucial, especially for large masses
 - Referral to tertiary care facility with capability of performing EXIT procedure

SELECTED REFERENCES

1. Sheikh F et al: Prenatally diagnosed neck masses: long-term outcomes and quality of life. *J Pediatr Surg.* 50(7):1210-3, 2015
2. Walz PC et al: Prenatal diagnosis of obstructive head and neck masses and perinatal airway management: the ex utero intrapartum treatment procedure. *Otolaryngol Clin North Am.* 48(1):191-207, 2015
3. Laje P et al: Ex utero intrapartum treatment in the management of giant cervical teratomas. *J Pediatr Surg.* 47(6):1208-16, 2012
4. Taghavi K et al: Perinatal airway management of neonatal cervical teratomas. *Int J Pediatr Otorhinolaryngol.* 76(7):1057-60, 2012

DIFFERENTIAL DIAGNOSIS**Common**

- Hypotelorism
- Hypertelorism

Less Common

- Proptosis
- Dacryocystocele
- Orbital Mass and Mass-Like Lesions
 - Lymphovascular Malformation
 - Coloboma
 - Tumor
 - Frontal Encephalocele
- Anophthalmia/Microphthalmia

ESSENTIAL INFORMATION**Key Differential Diagnosis Issues**

- General concepts
 - Orbit: Bony space containing globe, extraocular muscles, lacrimal gland, and neurovascular structures
 - Pyramidal shape: Apex is posterior, base is anterior
 - Lateral wall is thickest and most exposed
 - Medial wall is thin and prone to processes involving ethmoid sinus
 - Etiology of most orbit abnormalities
 - Part of genetic syndrome
 - Related to fetal skull developmental abnormality
- Evaluation of fetal orbits is routine part of anatomy scan
 - Axial view at level of eyes
 - Evaluate bony orbit and globes
 - Can see lens of globes as early as 14 weeks
 - Thin-walled echogenic ring in anterior globe
 - 3D ultrasound and fetal MR additive
- Orbital biometry
 - Interocular diameter (IOD)
 - Inner-to-inner margin between orbits
 - Binocular diameter (BOD)
 - Outer-to-outer margin of both orbits
 - Ocular diameter (OD)
 - Single bony orbit diameter
- Rule of 1/3s for normal biometry
 - Normal IOD = OD
 - A 3rd eye should fit between orbits
- Orbital normative data charts available
 - Gestational age vs. OD, IOD, BOD values
 - IOD/BOD percentiles
- Face predicts brain
 - Look carefully for brain anomalies
 - Look for other face anomalies

Helpful Clues for Common Diagnoses

- **Hypotelorism**
 - Eyes too close together
 - Definition: IOD < 5th percentile
 - Often with ↓ BOD as well
 - Hypotelorism is rarely isolated finding
 - Holoprosencephaly is major association
 - 2° hypotelorism from abnormal skull formation

- Metopic suture synostosis
- Microcephaly from any cause
- Cyclopia is most severe type
 - Single bony orbit with variable globe doubling
 - Dysplastic tissue may cover orbit
- Associated nose anomalies
 - Proboscis (tube-like nose)
 - Proboscis often above orbits
 - Ethmocephaly
 - Proboscis separates close set eyes
 - Cebocephaly
 - Infraorbital flat nose with single nostril
- Associated cleft lip and palate
 - Most common is median cleft lip/palate
- **Hypertelorism**
 - Eyes too far apart
 - Definition: IOD > 95th percentile
 - Associations
 - Aneuploidy
 - Midline brain anomalies and associated syndromes
 - Dysgenesis of corpus callosum + associations
 - Findings might be subtle on ultrasound
 - Associated craniofacial defects
 - Bilateral or large unilateral cleft lip and palate
 - Craniosynostosis
 - Frontonasal dysplasia

Helpful Clues for Less Common Diagnoses

- **Proptosis**
 - Exophytic eyes (anterior displaced globes)
 - Associations: Craniosynostosis; orbital mass and mass-like lesions
- **Dacryocystocele**
 - Dilation of lacrimal drainage system
 - From nasolacrimal duct obstruction
 - Can be large and cause nasal obstruction
 - Cyst medial to orbit (unilateral or bilateral)
 - Most resolve in utero or during 1st yr of life
- **Orbital Mass and Mass-Like lesions**
 - **Cystic mass**
 - **Lymphovascular malformation**
 - Lymphangioma, hemangioma
 - **Coloboma**
 - Defect in posterior globe → herniation of vitreous fluid
 - Associated with microphthalmia
 - Better seen with MR than US
 - **Solid mass in orbit**
 - **Tumors**
 - Teratoma most common in fetus
 - Less common tumors: Retinoblastoma, rhabdomyosarcoma, lymphoma, and leukemia
 - Often large and vascular
 - Globe may be displaced or destroyed
 - Unilateral proptosis most common finding
 - Bony orbit distorted or destroyed
 - **Frontal encephalocele**
 - Medial ± superior orbital wall defect with herniated intracranial contents displacing globe
 - May present as hypertelorism

- **Anophthalmia/Micropthalmia**
 - Absent or small globe
 - Optic vesicle fails to form appropriately
 - Eyelids, conjunctiva, and lacrimal apparatus present
 - Unilateral or bilateral
 - Associated chromosome abnormalities
 - Trisomy 13
 - SOX2-related eye disorders
 - Walker-Warburg syndrome
 - CHARGE syndrome
 - Coloboma, heart anomaly, choanal atresia, retardation, genital, and ear anomalies
 - Secondary anophthalmia
 - Infection
 - Toxic or metabolic insult
 - Abnormally low or high vitamin A
 - Vascular insult

Other Essential Information

- 3D ultrasound extremely helpful
 - Soft tissue detailed anatomy
 - Best for cleft lip
 - Bone-rendered images
 - Facial cleft bony defects
 - Fused sutures (craniosynostosis)
 - Helps nonimagers see anomalies better
 - Parents, genetic counselors, surgeons
- Fetal MR
 - Helps identify subtle and additional brain anomalies
 - Better delineate extent of tumors
- Signs of holoprosencephaly in cases of hypotelorism
 - Alobar holoprosencephaly
 - Severe midline facial anomalies
 - Single ventricle, no falx, dorsal sac
 - Fused thalami, fused brain mantle
 - Semilobar holoprosencephaly
 - Less severe than alobar
 - Face with less severe anomalies or normal
 - Incomplete falx with separate occipital horns

- Partially cleaved thalamus
- Lobar holoprosencephaly
 - Least severe form
 - Normal face or hypotelorism
 - Absent cavum septi pellucidum
 - Fused fornices

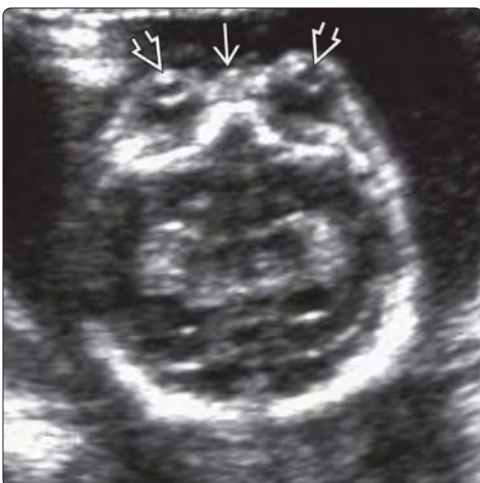Alternative Differential Approaches

- **Hypotelorism associations**
 - Trisomy 13
 - Trisomy 18
 - Microcephaly
 - Craniosynostosis
 - Trigonocephaly
 - Smith-Lemli-Opitz syndrome
 - Meckel-Gruber syndrome
 - Myotonic dystrophy
- **Hypertelorism associations**
 - Agenesis of corpus callosum
 - Associated anomalies include interhemispheric cyst + macrocephaly
 - Craniosynostosis
 - Carpenter syndrome
 - Apert syndrome
 - Crouzon syndrome
 - Thanatophoric dysplasia
 - Anterior encephalocele
 - Midline facial mass or cleft
 - Turner syndrome
 - Trisomy 13
 - Antiepileptic drug use
- **Proptosis associations**
 - Craniosynostosis
 - Treacher-Collins syndrome
 - Neu-Laxova syndrome
 - Anencephaly

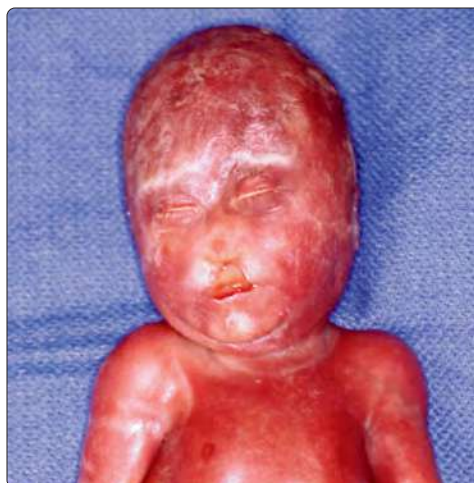SELECTED REFERENCES

1. Burns NS et al: Diagnostic imaging of fetal and pediatric orbital abnormalities. AJR Am J Roentgenol. 201(6):W797-808, 2013

Hypotelorism





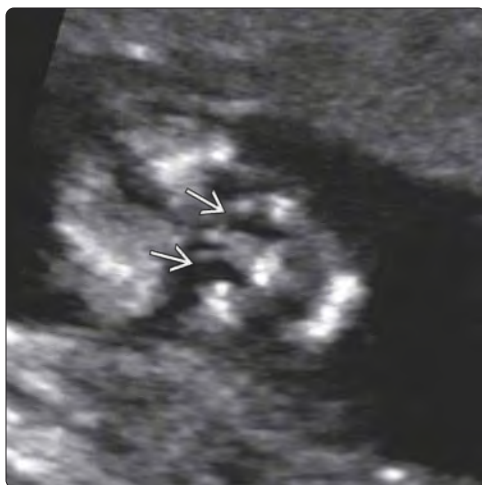
Hypotelorism



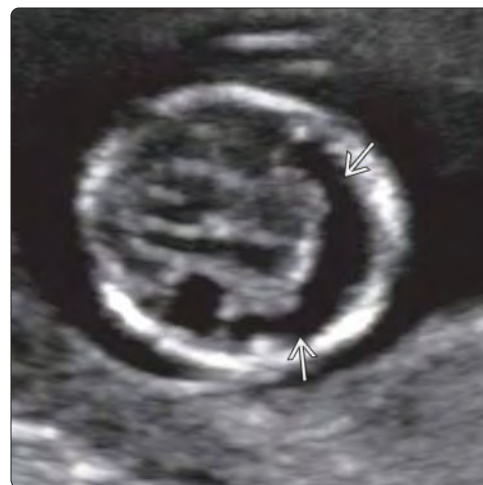(Left) In this fetus with holoprosencephaly and trisomy 13, the interocular distance (IOD) is decreased. Note that the globes and lenses of the eyes are seen well at the time of the anatomy scan. **(Right)** This fetus with trisomy 13 demonstrates classic facial features of hypotelorism, flat deficient nose, and midline cleft lip and palate.

Hypotelorism



(Left) Two small orbits , in close proximity, are seen at the time of nuchal translucency anatomy scan. (Right) Axial ultrasound through the fetal calvarium, in the same case, shows a fused monoventricle  and absent falx. Findings are diagnostic of holoprosencephaly, with hypotelorism. Chorionic villus sampling results showed trisomy 13.

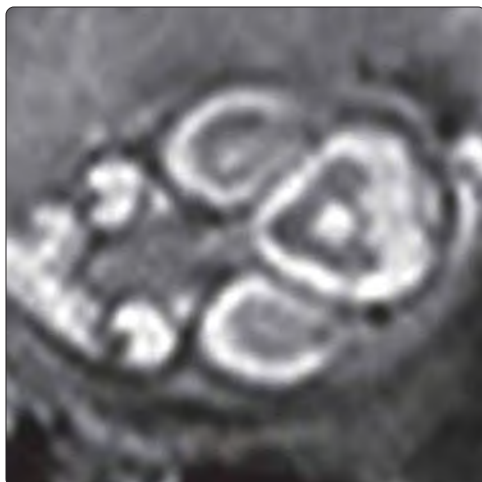

Hypotelorism

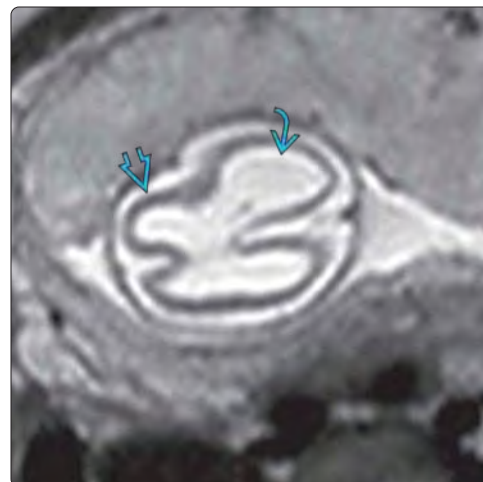


Hypotelorism



(Left) The orbits are close-set in this fetus with microcephaly and ascites. MR was performed to look for additional anomalies. (Right) Additional axial view through the brain, in the same fetus, shows ventriculomegaly  and cerebral atrophy . Amniocentesis results were positive for cytomegalovirus infection as the cause of microcephaly, and on follow-up ultrasound, brain calcifications were seen.

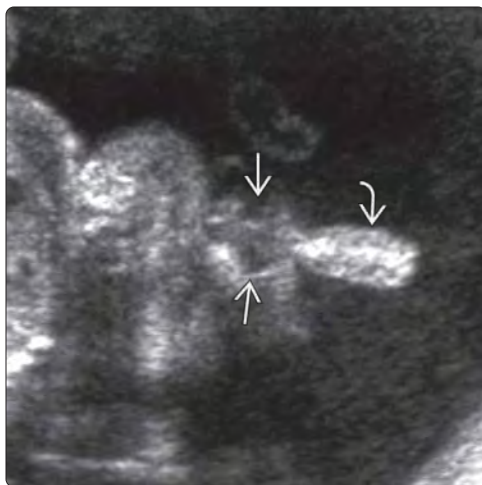

Hypotelorism

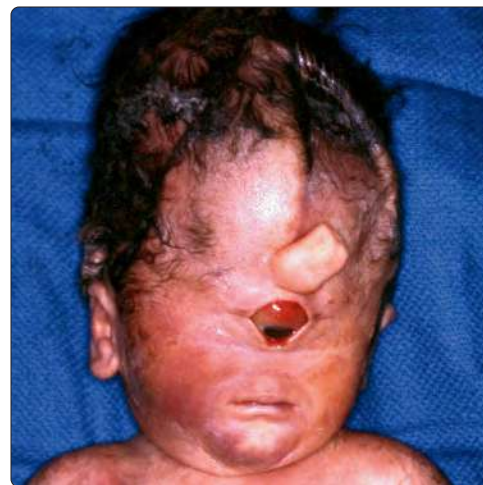

Hypotelorism

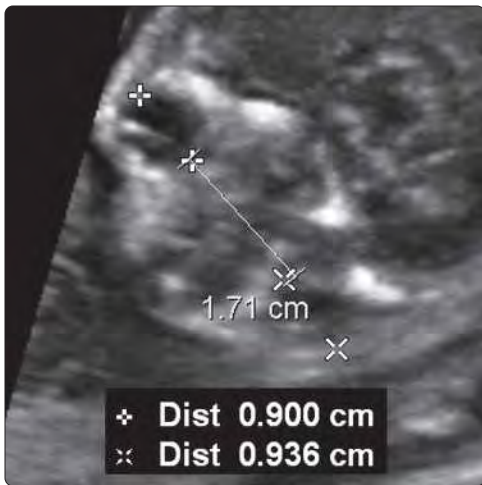(Left) Frontal face view shows a proboscis  superior to a single orbit  containing dysmorphic globe tissue. Cyclopia is the most severe form of hypotelorism and almost always associated with alobar holoprosencephaly. (Right) Clinical photograph of a fetus with trisomy 13, cyclopia, and proboscis shows typical features. In this case, a single globe, with no covering eyelid, is seen. The proboscis is most often located above the orbit.



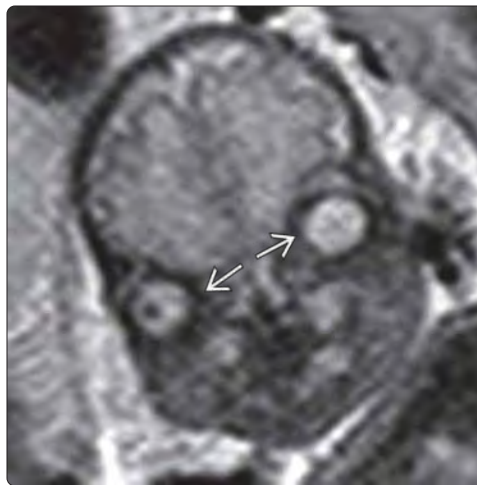
Hypotelorism



Hypertelorism

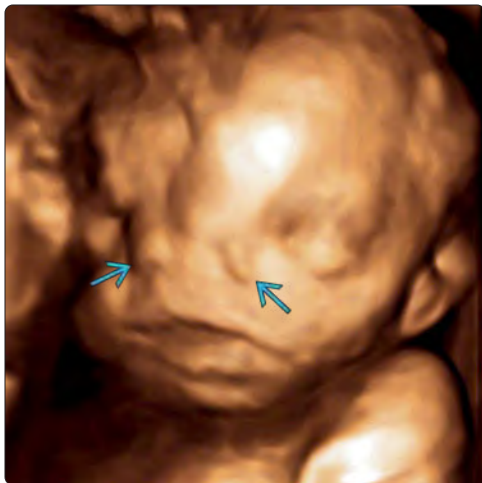

Hypertelorism

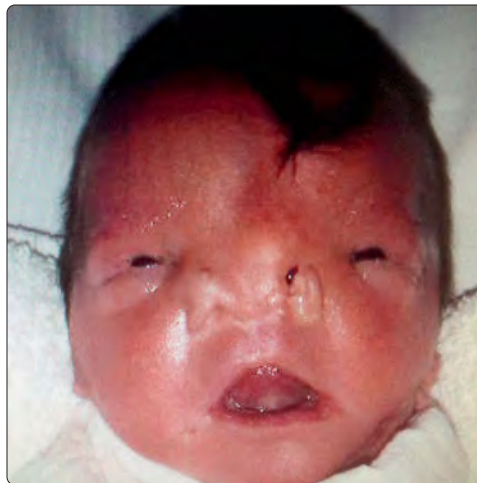

(Left) The IOD measures 17 mm, and the orbits are normal in size, measuring 9 mm. In a normal fetus, the IOD measures ~ the same as the orbital diameter. These orbits are laterally displaced from the midline. (Right) Coronal MR, in the same fetus, confirms the diagnosis of hypertelorism. The increased IOD can be seen on coronal or axial views. Other brain and facial anomalies were also present in this case.

Hypertelorism

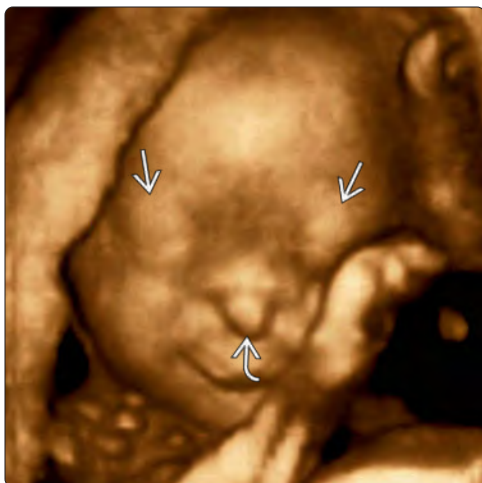

Hypertelorism

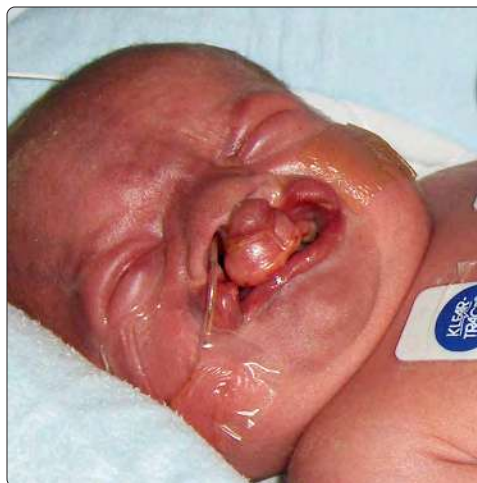

(Left) 3D surface-rendered image of the face in this fetus shows hypertelorism and a wide, dysmorphic nose with a vertical cleft laterally displacing the nostrils. (Right) Clinical photograph of the same child, after delivery, shows typical facial features of frontonasal dysplasia. Other findings associated with frontonasal dysplasia include cleft palate, anterior encephalocele, and midline brain anomalies.

Hypertelorism



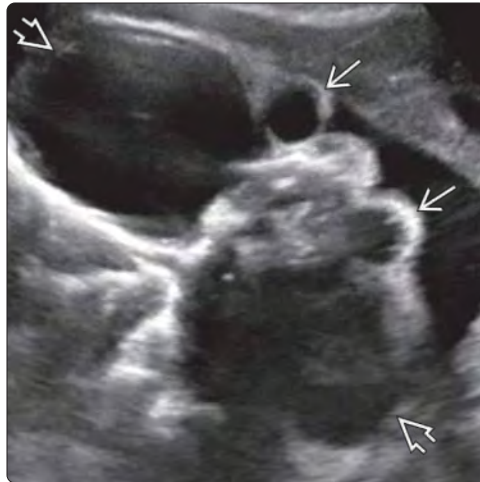
Hypertelorism



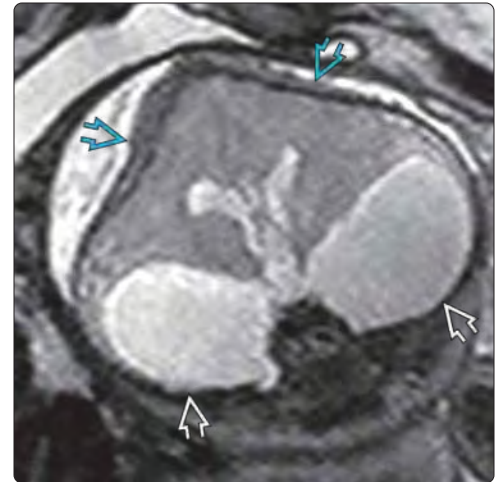(Left) Hypertelorism is seen in this fetus with bilateral cleft lip and palate and secondary premaxillary mass from dysplastic anterior palate. (Right) In a newborn with bilateral cleft lip and palate, the flattened wide nose and hypertelorism is seen to better advantage. Large unilateral cleft lip and palate is also associated with hypertelorism, usually milder than seen in bilateral cases.

Proptosis

(Left) In this fetus with severe brachycephaly from craniosynostosis, the orbits are shallow, and there is protrusion of both eyeballs. (Right) Fetal MR, in the same case, shows the classic tower-shaped skull from bicoronal craniosynostosis, associated with shallow orbits and proptosis. There is also severe dilation of the temporal horns. This fetus had Carpenter syndrome.

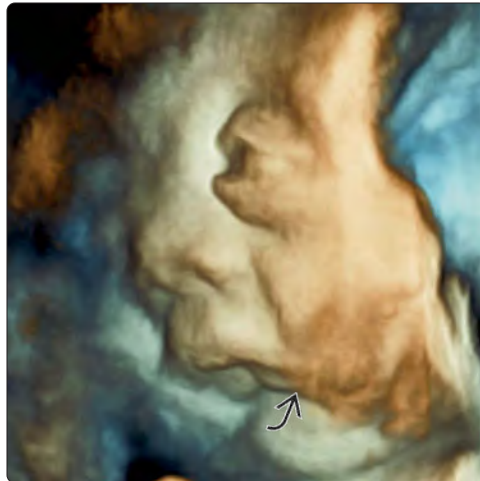

Proptosis

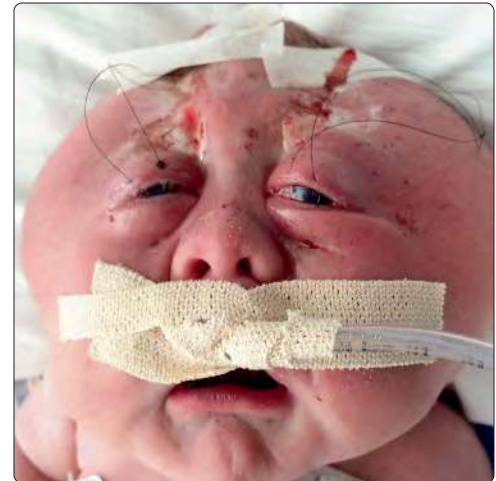

Proptosis

(Left) 3D ultrasound of the face in a fetus with severe craniosynostosis from Carpenter syndrome shows proptosis. The face is flat, there is micrognathia, and the eyes did not close throughout the exam. (Right) Clinical photograph of the same child shows the severe proptosis necessitating orbital ointment and lid sutures placed in order to help keep the eyes closed and minimize corneal damage. Because of the prenatal imaging and consultation, the family was prepared for the appearance and care of this child.

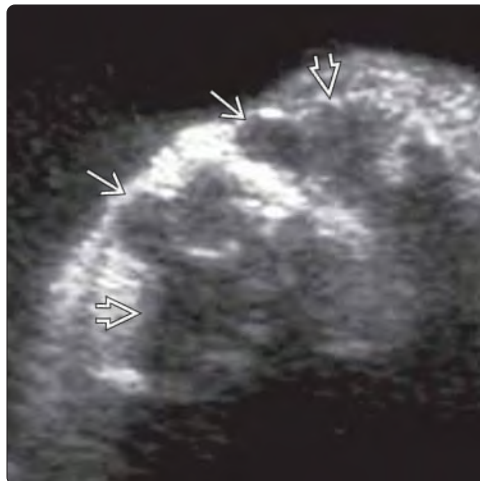


Proptosis

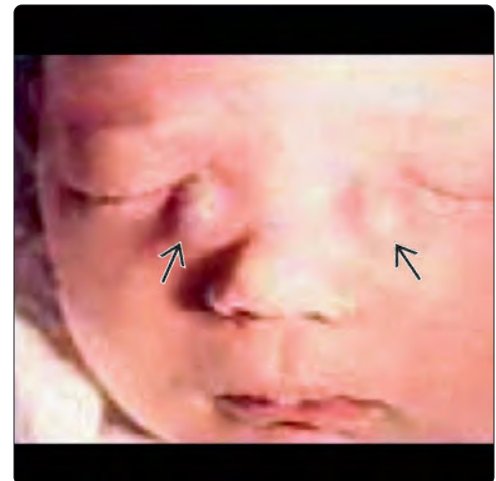

Dacryocystocele

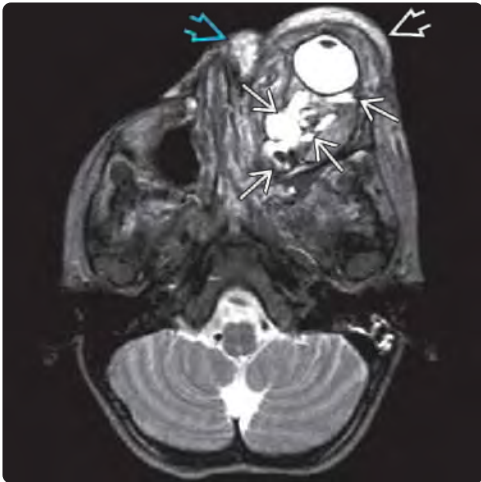
(Left) Axial ultrasound shows 2 small cysts located medial to the globes, adjacent to the nose. These cysts are in the expected region of the lacrimal drainage ducts. (Right) Clinical photograph of a child with bilateral dacryocystoceles shows the typical finding of medial orbital masses. Most often, dacryocystoceles resolve in the 1st year of life, but some need surgical drainage for treatment.



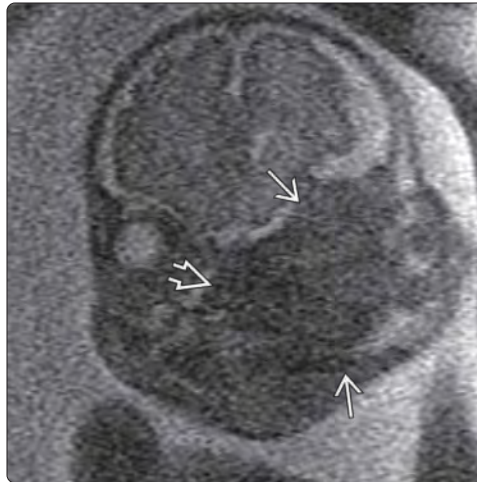
Dacryocystocele



Lymphovascular Malformation

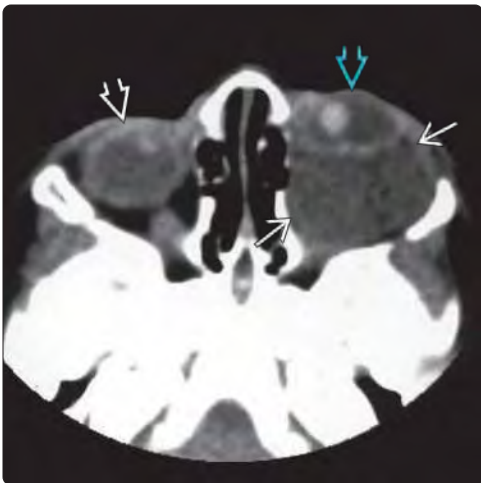


Tumor

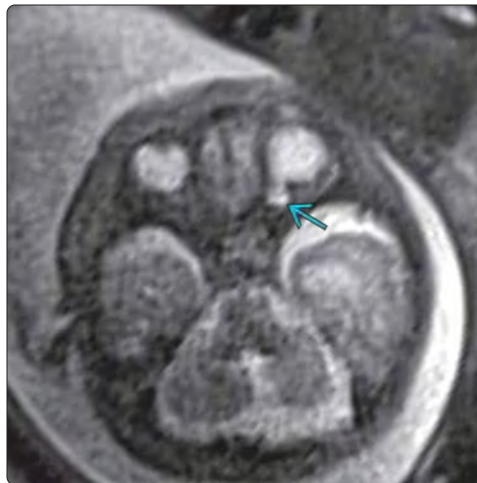

(Left) A multiloculated infiltrative cystic orbital mass [red box] in a child causes proptosis of the globe. Diagnosis is lymphangioma in this case. Note the associated skin thickening involving the eyelid [red box], from lymphedema. A smaller lymphangioma is seen between the eye and nose [red box]. (Right) Coronal fetal MR of a solid mass, an orbital rhabdomyosarcoma, shows the mass centered in the left orbit [red box] with invasion into surrounding structures, including the nasal cavity [red box].

Coloboma

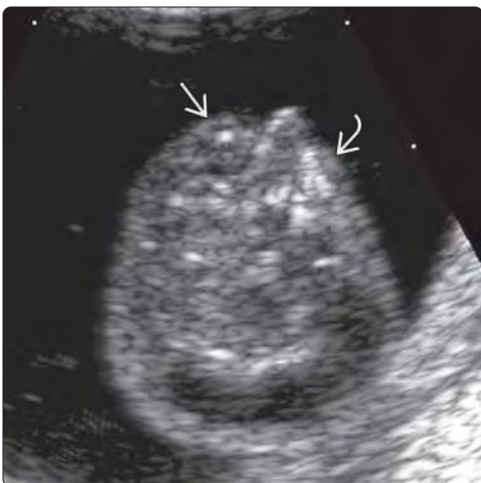


Coloboma

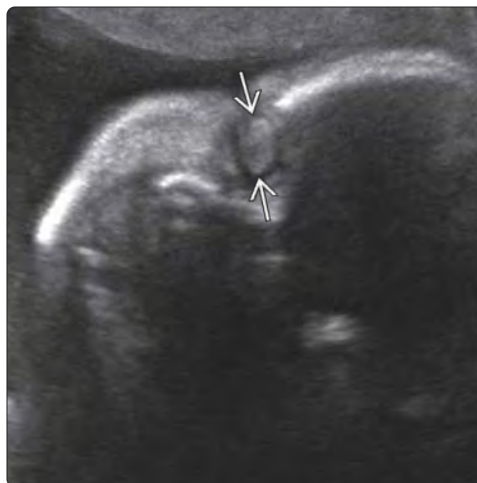

(Left) This CT shows the left globe [red box] is displaced and smaller than the right globe [red box] secondary to the presence of a retrobulbar cystic mass, which is a coloboma [red box]. Microphthalmia is associated with coloboma. (Right) T2 MR through the level of the orbits shows a focal bulge in globe contour [red box] at optic nerve insertion. When seen in fetal life, colobomas are often associated with a syndrome including Aicardi, CHARGE, and PHACES.

Anophthalmia/Microphthalmia



Anophthalmia/Microphthalmia



(Left) Facial asymmetry with absent left globe [red box] and normal right globe [red box] was noted at the time of nuchal translucency screening. A cystic hygroma was also present, and karyotype was shown to be trisomy 21 and trisomy 9. (Right) A small left orbit without recognizable globe [red box] is seen in this 3rd-trimester fetus with severe brain anomalies. The other eye was normal. Families are very sensitive to the cosmetic affect of an absent eye, and prenatal diagnosis helps prepare them for delivery.

DIFFERENTIAL DIAGNOSIS**Common**

- Congenital Syndromes Associated With Ear Anomalies
 - Treacher Collins Syndrome
 - Goldenhar Syndrome
 - Pierre Robin Sequence

Less Common

- Isolated Ear Anomalies
 - Preauricular Skin Lesions
 - Deficient Ear
 - Low-Set Ear
- Atypical Ear Morphology
 - Lop Ear
 - Protruding Ear

ESSENTIAL INFORMATION**Key Differential Diagnosis Issues**

- Look for ear anomalies when mandible is small
 - Ear and mandible embryology is related
 - Small chin seen best on profile view
 - Hypognathia and micrognathia are associated with cleft palate (most often posterior soft tissue defect)
 - 3D ultrasound and reverse-face views additive
 - Look for fluid extending into nasal cavity from back of oral cavity on sagittal view
 - MR best to show palate defect and tongue position
 - Glossoptosis may cause airway obstruction
 - Tongue superiorly displaced into palate defect
 - Associated polyhydramnios in severe cases
 - From obstruction to swallowing
 - Mostly in 3rd trimester
 - May require ex utero intrapartum treatment (EXIT) procedure
 - Fetal head delivered via cesarean section with intubation of airway before rest of body delivered
 - Micrognathia associated with many syndromes and aneuploidy
- Look for other facial features
 - Helps make possible diagnosis of specific syndrome
 - Eye, nose, and mouth appearance
 - Head shape
 - 3D is best to get complete picture of fetal face
- Isolated ear anomalies are more common but often missed in utero
 - Ear views are not routinely performed as part of anatomy scan
- Normal ear position
 - Top of helix is at inner canthi eye level
 - Ear lies flat against skull
 - Variable and hereditary patterns apply
- Ear size evaluation
 - Ear length = 1/3 biparietal diameter
 - Normative data tables available
 - Ear width is variable
- Use 3D ultrasound to evaluate auricular morphology
 - Helix is most external curve of auricle
 - Antihelix is Y-shaped internal auricle

- Tragus lies over external meatus
- Antitragus faces tragus
- Fetal MR is best for internal ear anomalies
 - Better diagnostic value later in pregnancy
 - > 25-28 weeks
 - External auditory canal (EAC)
 - Seen best on axial view
 - Normally patent after 28 weeks
 - After involution of ectodermal plug
 - Remnant of plug becomes tympanic membrane
 - Look for bilateral fluid-filled EAC
 - In 1 study, EAC only seen in 59% of normal fetuses, therefore, anomaly diagnosis is limited
 - Middle ear
 - Ossicles seen as signal void structures on T2
 - Difficult to discriminate each ossicle
 - Seen typically after 25 weeks
 - Vestibule and semicircular canal
 - Axial view is best
 - Formed before 11 weeks
 - Lateral semicircular canals form last
 - Seeing lateral canals is reassuring that rest is formed normally
 - Look for vestibule separate from semicircular canal
 - Cochlea
 - Coronal view best
 - Cochlea turns seen better with ↑ gestational age
 - Anomalies of cochlea range in severity
 - Complete aplasia
 - Cochlear hypoplasia
 - Absence of turns (cystic cavity)

Helpful Clues for Common Diagnoses

- **Treacher Collins**
 - Inheritance is most often autosomal dominant
 - Classic facial features (variable severity)
 - Small chin
 - Downward slope of eyelids
 - Deficient ears
 - Protruding eyes from shallow orbits
 - Inner ear often best developed
 - Variable middle ear and EAC development
 - Almost all have hearing impairment
 - Cleft palate common
 - Secondary to associated small chin
- **Goldenhar Syndrome**
 - Part of oculo-auriculo-vertebral spectrum
 - Complex developmental disorder of 1st and 2nd branchial arches + intervening structures
 - Hemifacial microsomia is hallmark finding
 - 1/2 of jaw is small
 - 1 ear affected or asymmetry of ear anomalies
 - Mild cases with unilateral ear anomaly only
 - Up to 2/3 with other anomalies
 - Congenital heart anomalies
 - Most common
 - Genitourinary anomalies
 - 2nd most common
 - Central nervous system anomalies
 - Musculoskeletal anomalies

- Most cases are sporadic
 - Small percentage are familial
- **Pierre Robin Sequence**
 - Hallmark findings
 - Micrognathia
 - U-shaped cleft palate
 - Glossoptosis
 - Ears are low set
 - Auricles are often well developed
 - Middle ear and internal ear anomalies common
 - Most children have hearing impairment
 - MR shows cleft palate and internal ear anomalies best
 - Think of another syndrome if other anomalies seen

Helpful Clues for Less Common Diagnoses

- **Preauricular Skin Lesions**
 - Skin tag or tags along jaw line
 - Might present as cheek mass
 - Associated segmentation anomalies of auricle
 - Most often occur in isolation
 - Prevalence is around 1%
 - Sporadic incidence although some regions of world with higher prevalence
 - Isolated cases often missed in fetal life
 - Associate hearing impairment in up to 20%
 - Associated with syndromes (not isolated)
 - Treacher Collins
 - Oculo-auricular-vertebral spectrum
 - Bracheo-oto-renal syndrome
- **Deficient Ear**
 - Microtia
 - Small ears
 - ± absent auricular components
 - Anotia
 - No external ears
 - Rarely isolated finding
- **Low-Set Ear**
 - Top of helix is lower than inner canthi line
 - Associated with micrognathia

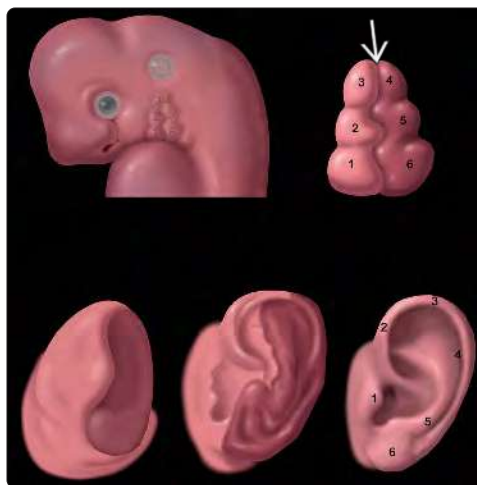
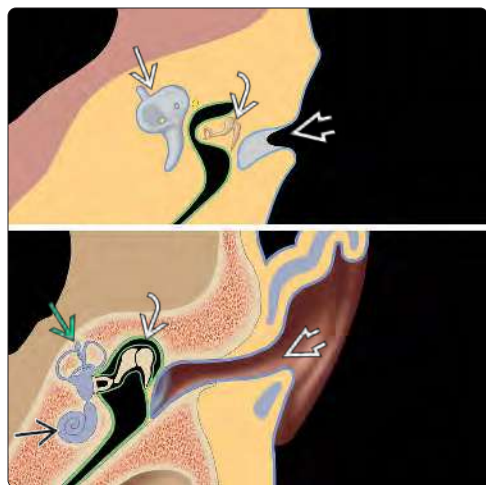
- Treacher Collins syndrome
- Nager syndrome
- Pierre Robin sequence
- Aneuploidy
- Rarely isolated finding when severe
- **Lop Ear**
 - Deformed upper ear cartilage
 - Top of ear curls downward
 - Often isolated
 - Autosomal dominant inheritance described
 - Might be associated with other anomalies
 - Anencephaly
 - Other syndromes with cartilage defects

Protruding Ear

- Ear protrudes > 25° from head
- Most often idiopathic
 - Show ears are not low set

Other Essential Information

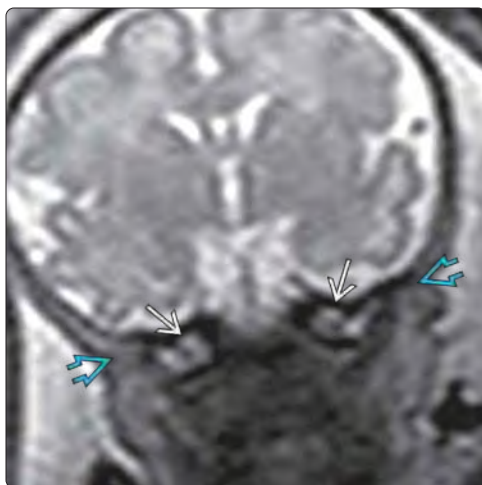
- Low-set and deficient ears can be complication of severe oligohydramnios
- Association with aneuploidy
 - Trisomy 21
 - Lop ears, low-set ears
 - Other facial features
 - Hypoplastic nasal bone, flattened midface
 - Trisomy 18
 - Low-set ears, deficient ears
 - Other facial features
 - Hypertelorism, upturned nose, small chin
 - Trisomy 13
 - Low-set ears, deficient ears
 - Other facial features
 - Cyclopia/hypotelorism, proboscis/single nares/deficient nose, small mouth
- Turner syndrome
 - Up to 1/4 with auricular anomalies
 - Middle ear anomalies common
 - 1/2 with hearing impairment



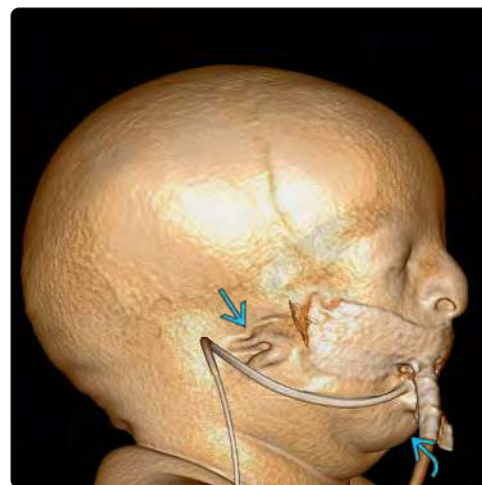
(Left) The inner ear develops from the otic placode and gives rise to the cochlea and semicircular canal. The ossicles reside in middle ear and mature at 15-20 weeks. The external auditory canal elongates in fetal life and reaches its final shape in late childhood. (Right) The auricle develops from 6 hillocks (1, 2, 3 from 1st brachial arch and 4, 5, 6 from 2nd brachial arch). The hillocks border the 1st pharyngeal groove, and the diagram shows the final destination of the hillocks as they form the normal external ear.

Treacher Collins Syndrome

(Left) Fetal MR performed in a fetus with Treacher Collins syndrome and mild features on fetal ultrasound shows fairly well-developed cochlea with underdeveloped middle ear and external auditory canals. These findings were confirmed with CT after delivery. (Right) 3D CT in the same child after delivery shows a deficient ear and small chin. Similar findings were seen with ultrasound. Treacher Collins syndrome inheritance pattern is autosomal dominant, and the father of the child also had the disorder.

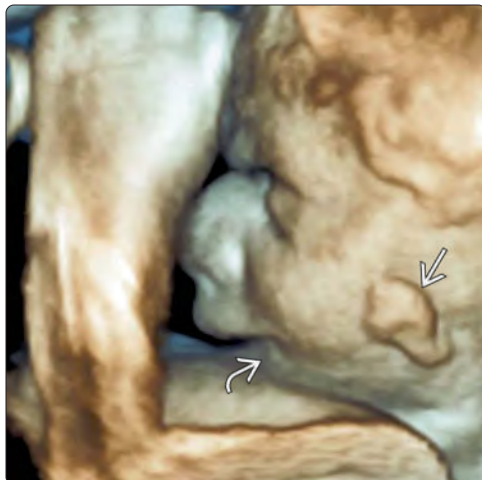

Treacher Collins Syndrome

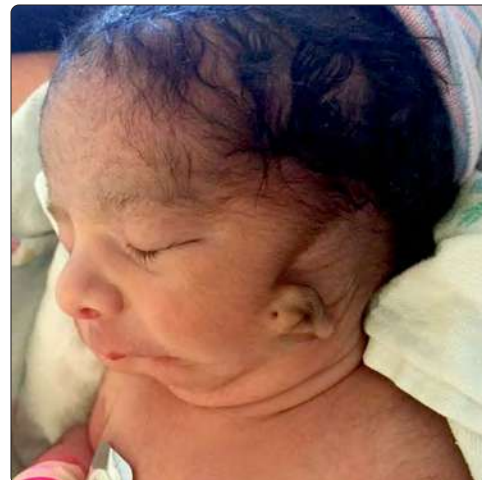

Goldenhar Syndrome

(Left) A small chin and malformed, small, low-set left ear is seen. Notice the ear is markedly lower than the eye, and the auricle is not fully formed. The right ear was normal. (Right) Clinical photograph of the same child shows microtia with a deformed, deficient, low-set left ear.

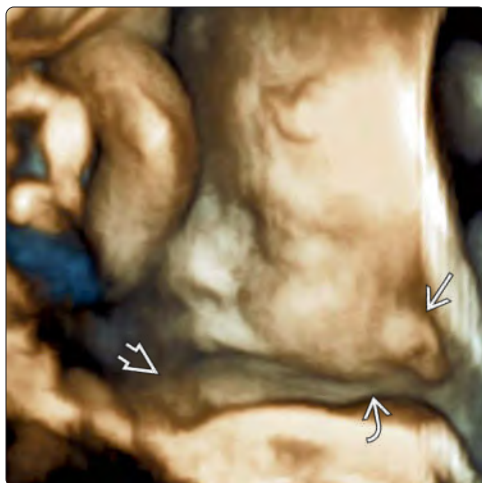


Goldenhar Syndrome

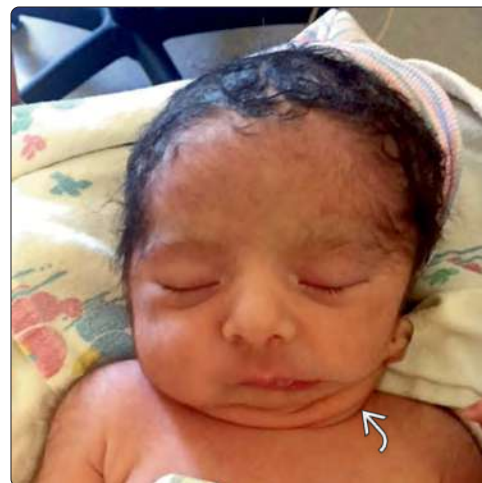

Goldenhar Syndrome

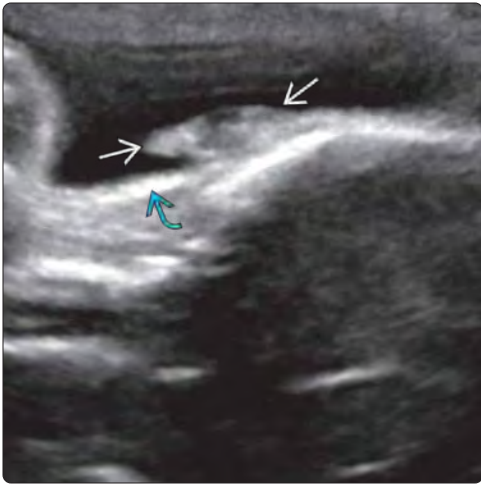
(Left) A different angle in the same case shows hemifacial microsomia. The left part of the mandible is very small, while the right is more normal in appearance. Both eyes were normal and only the left ear was deficient. (Right) Clinical photograph of the same child shows the hemifacial microsomia, affecting the left jaw and ear. Note the redundant skin over the deficient mandible. The term Goldenhar syndrome is felt to be imprecise. The findings are best referred to as oculo-auricular-vertebral spectrum disorder.



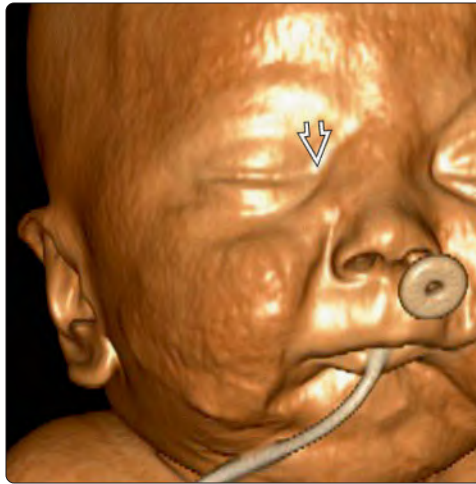Goldenhar Syndrome



Pierre Robin Sequence

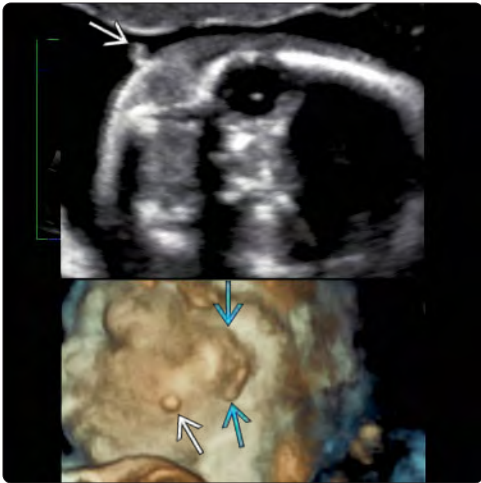


Pierre Robin Sequence

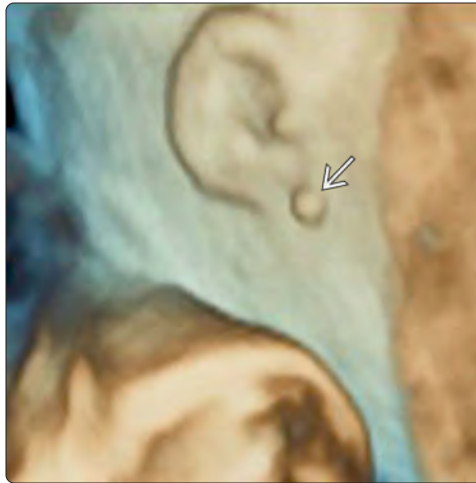

(Left) In this fetus with hypognathia, the ear is well developed and normal in length but low-lying (ear lobe is seen extending into the upper neck). Fetal MR also showed a cleft palate. No other anomalies were seen. (Right) 3D surface-rendered image, in the same case, shows a well-formed low-lying ear and small chin. The top of the ear should be at the same level as the inner canthus of the eye. Children with Pierre Robin have a higher risk for hearing impairment, mostly from middle ear problems.

Preauricular Skin Lesions

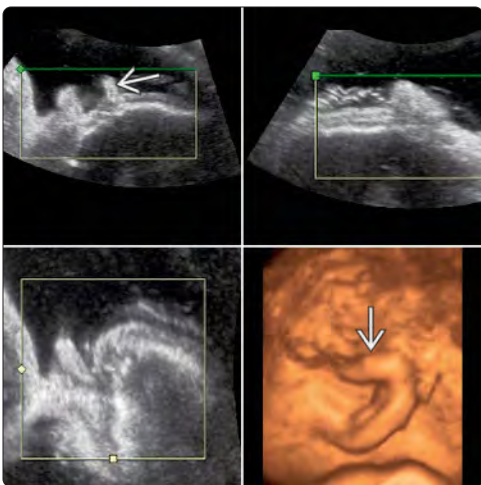


Preauricular Skin Lesions

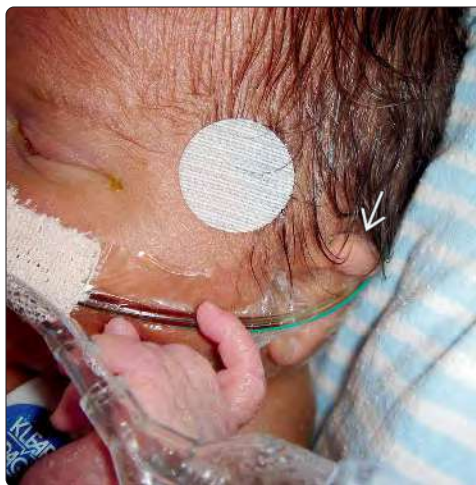

(Left) This 22-week fetus was referred for a small cheek mass. No other anomalies were noted on anatomy scan. 3D ultrasound of the ipsilateral ear was pursued because skin lesions along the jaw line are often preauricular skin tags, associated with ear anomalies. A deficient low-set ear was seen. (Right) In the same case, the contralateral ear is well-formed, but a 2nd preauricular skin tag is seen, not originally seen with 2D imaging. The mandible was normal in this case.

Lop Ear



Lop Ear



(Left) This fetus was noted to have an atypical appearance of the ear on 2D ultrasound. 3D ultrasound shows the top of the ear bent away from the head and curled downward. (Right) Clinical photograph of the same newborn confirms the diagnosis. The baby had multiple other anomalies as well. Lop ear results from abnormal upper ear cartilage and can be an isolated finding with no significant clinical sequelae.

DIFFERENTIAL DIAGNOSIS**Common**

- Technical
- Idiopathic
- Oligohydramnios
- Trisomy 18

Less Common

- Amniotic Band Syndrome

Rare but Important

- Pierre Robin Syndrome
- Diabetic Embryopathy
- Treacher Collins Syndrome
- Cornelia de Lange Syndrome
- Otocephaly
- Other Named Syndromes/Conditions

ESSENTIAL INFORMATION**Key Differential Diagnosis Issues**

- Is micrognathia real or technical due to incorrect scan plane?
 - Reproducible finding if real
- Use 3D ultrasound if available
 - Helpful to assess additional dysmorphic features (e.g., ear malposition, ear malformation, eye orientation)
 - Volume acquisition increases likelihood that true midline sagittal view of profile is being analyzed
 - Surface rendering → way to qualitatively evaluate chin from different perspectives
 - Help parents understand appearance and consulting services plan treatment
- Mandibular measurements
 - Plethora of measurement described with some nomograms available
 - Jaw index
 - Mandibular area
 - Inferior facial angle, mandibular angle
 - Mandible width/maxilla width ratio
 - Most are technically challenging & not widely used

Helpful Clues for Common Diagnoses

- **Technical**
 - Incorrect scan plane
- **Idiopathic**
 - True isolated small jaw in otherwise normal fetus
 - May be familial; look at both parents
 - Micrognathia and other findings for which no unifying diagnosis is apparent with current technology
 - Likely that many of these cases are due to, as yet unidentified, genetic variants
- **Oligohydramnios**
 - Part of Potter sequence
 - Beaked nose, low set ears, redundant skin
 - Club feet, joint contractures
- **Trisomy 18**
 - Facial features include micrognathia and clefting
 - Usually associated with growth restriction and multiple anomalies

- Omphalocele, congenital heart disease, abnormal finger positioning, arthrogryposis/radial ray malformation, central nervous system anomalies, congenital diaphragmatic hernia

Helpful Clues for Less Common Diagnoses

- **Amniotic Band Syndrome**
 - Random constriction/amputation defects; slash defects
 - Mandibular hypoplasia is associated with transverse facial clefting in setting of amniotic bands
 - Careful search for bands mandatory, as no significant recurrence risk
 - Linear echoes in amniotic fluid
 - Extend from fetal parts to uterine wall
 - Fetus appears tethered or in fixed position
 - Occasionally, inspection of placenta after delivery may be only way to confirm diagnosis

Helpful Clues for Rare Diagnoses

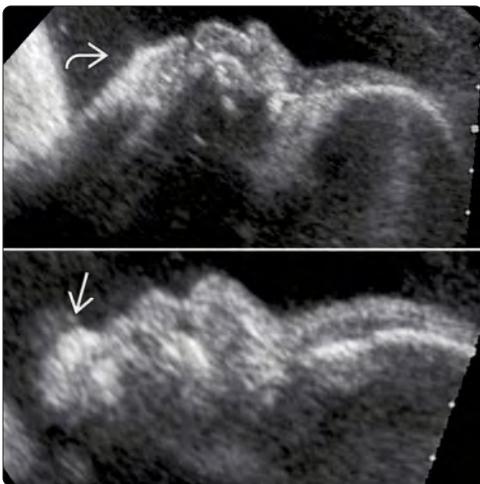
- **Pierre Robin Syndrome**
 - Micrognathia often severe
 - U-shaped palatal cleft hard to see sonographically as lip intact but may be evident on MR
 - Glossoptosis (posterior displacement of tongue), also easier to see on MR
- **Diabetic Embryopathy**
 - Caudal regression sequence ± extremity malformations
 - Brain malformations including holoprosencephaly
 - Congenital heart disease, especially transposition and double-outlet right ventricle
 - Long-standing diabetes → fetal growth restriction, oligohydramnios
 - Gastrointestinal malformations (e.g., anorectal atresia)
 - Genitourinary malformations (e.g., renal agenesis)
- **Treacher Collins Syndrome**
 - Genetic disorder characterized by craniofacial deformities
 - Malar hypoplasia
 - Downslowing palpebral fissures
 - Microtia
- **Cornelia de Lange Syndrome**
 - Typical facies: Prominent upper lip, crescent-shaped mouth, micrognathia, fine arched eyebrows, long eyelashes
 - Upper extremity limb reduction defects
 - Congenital diaphragmatic hernia, occasionally bilateral
 - Fetal growth restriction
- **Otocephaly**
 - Extremely rare but lethal anomaly
 - Microstomia
 - Aglossia or oroglossal hypoplasia
 - Agnathia or mandibular hypoplasia
 - Synotia: Low-set medially rotated ears
 - Fetus cannot swallow → marked polyhydramnios
- **Other Named Syndromes/Conditions**
 - Online Mendelian Inheritance in Man (OMIM) database includes 510 named conditions featuring micrognathia
 - Presence of micrognathia mandates careful search for other anomalies and consideration of formal fetal echocardiography

- **22q11 deletion** associated with micrognathia and conotruncal malformations
 - Thymic hypoplasia
 - Broad nasal bridge with bulbous nose
 - Long slender fingers and toes
- Heart defects common in **Wold Hirschhorn syndrome** (hemizygous deletion of 4p16.3)
 - **Micrognathia is rarely isolated**
- Important to recognize autosomal recessive conditions as 25% recurrence risk
 - **Neu-Laxová syndrome**
 - Lethal syndrome with growth restriction
 - Microcephaly
 - Exophthalmos, absent eyelids
 - **Nager syndrome**
 - Severe micrognathia and malar hypoplasia
 - Spectrum of radial ray malformations
 - 28% survival reported
 - Some dispute as to nature of inheritance; some cases appear dominant

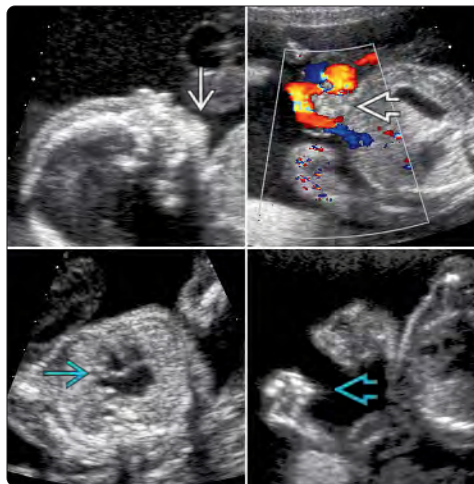
Other Essential Information

- Micrognathia may be associated with **skeletal dysplasias**
 - Assess bone density
 - Measure long bone lengths
 - Look at vertebral contours
 - Use 3D ultrasound
- If associated with ear anomalies, may also be associated with renal malformations
 - Neonatal renal ultrasound worthwhile
- Other potential complications
 - Polyhydramnios → increased risk of preterm labor
 - Respiratory distress ± feeding difficulties
 - Typically 1 or more surgical procedures required for repair
- Families should be evaluated by clinical genetics service
 - Increased risk of genetic/syndromic condition
 - Obtain detailed family history
 - Consider microarray testing on affected infant unless truly isolated or mild

Technical

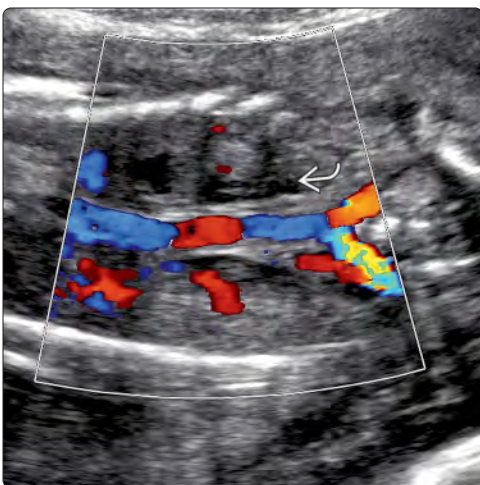


Idiopathic

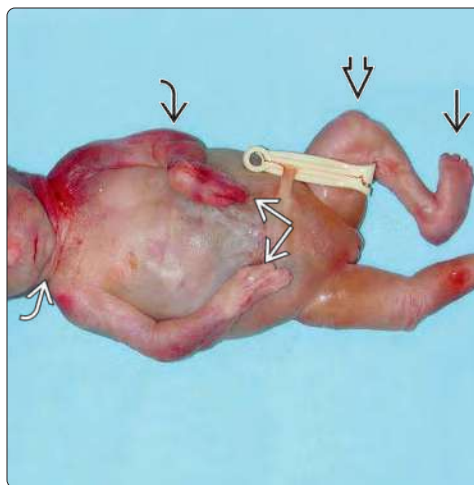


(Left) Images obtained within minutes of each other show how scan planes can create spurious micrognathia when the chin is actually normal. 3D volume acquisition can be helpful to ensure that the profile is assessed in a true sagittal plane. (Right) This fetus has micrognathia, omphalocele, atrioventricular septal defect, and radial club hand. Surprisingly, chromosomes were normal; we had assumed this was trisomy 18. Without a unifying diagnosis, this case is characterized as idiopathic.

Oligohydramnios



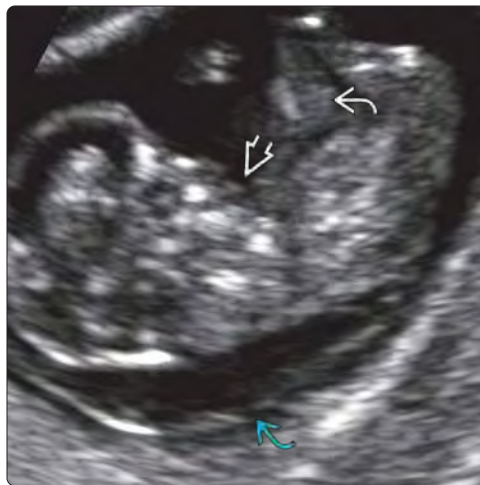Oligohydramnios



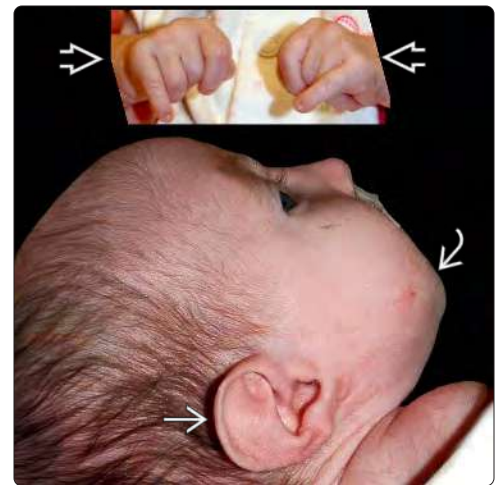(Left) Coronal image through the abdomen shows a lying-down adrenal gland and anhydramnios in a fetus with bilateral renal agenesis. The lack of amniotic fluid results in a typical appearance with multiple contractures, micrognathia, and redundant skin. (Right) Autopsy image in a case of renal agenesis shows clubfoot, knee and elbow contractures, bilateral camptodactyly, and micrognathia.

Trisomy 18

(Left) Sagittal image shows increased nuchal translucency [red arrow], bowel-containing omphalocele [green arrow], and suspicion for micrognathia [blue arrow]. Chorionic villus sampling revealed trisomy 18. (Right) Clinical photograph shows micrognathia [red arrow], abnormal ears [green arrow], and clenched fingers [blue arrow] in an infant with trisomy 18. Surgery was performed for congenital heart disease, but she died at 1 year of age.

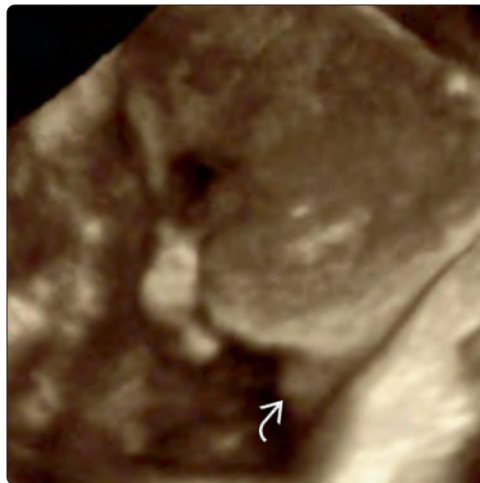

Trisomy 18

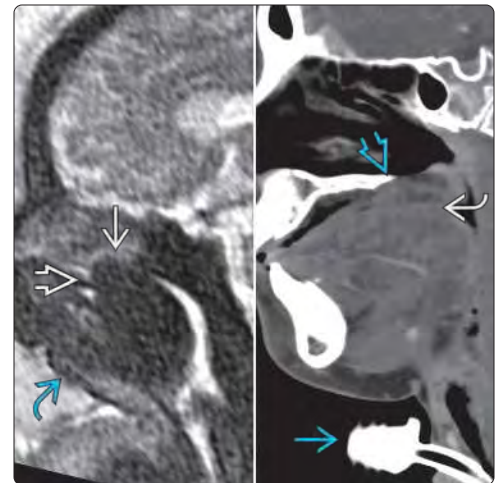


Pierre Robin Syndrome

(Left) Profile view of a fetus of a diabetic mother was misconstrued as a laughing baby with fat cheeks. In fact, there is severe retrognathia [red arrow], and the infant had Pierre Robin syndrome at birth. (Right) Sagittal HASTE MR shows glossoptosis with the tip of the tongue [red arrow] stuck in the cleft in the palate [green arrow] and severe micrognathia [blue arrow]. CT scan shows the defect in the hard palate [red arrow] and the abnormal tongue position [green arrow]. This infant had to have a tracheostomy [blue arrow] due to airway obstruction.

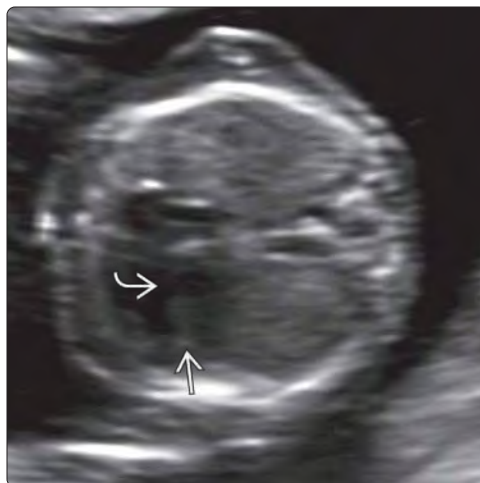

Pierre Robin Syndrome

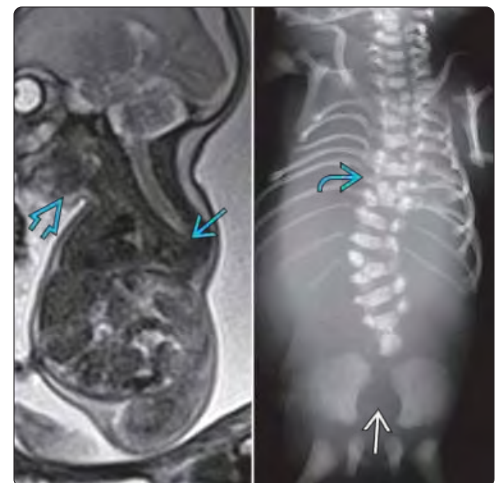


Diabetic Embryopathy

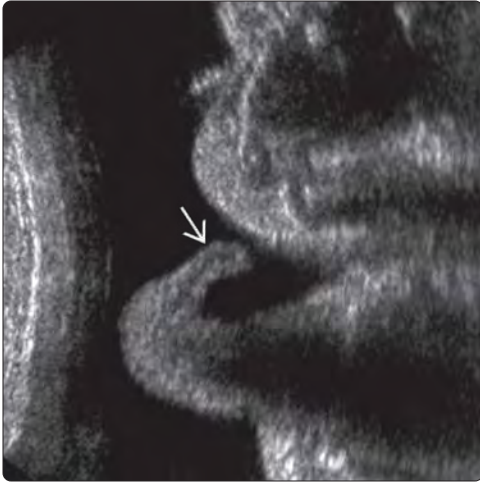(Left) Four-chamber view in a diabetic mother was limited by maternal habitus and 17-week fetal size, but the axis was abnormal [red arrow]. There was a ventricular septal defect [green arrow]. Follow-up echocardiography showed a truncus arteriosus. (Right) Sagittal T2WI shows severe caudal regression with vertebral agenesis beginning at the midthoracic spine [red arrow]. There is also a small chin [blue arrow]. Coronal radiograph shows multiple segmentation anomalies [red arrow] and caudal regression with absent sacrum [green arrow], all features of diabetic embryopathy.



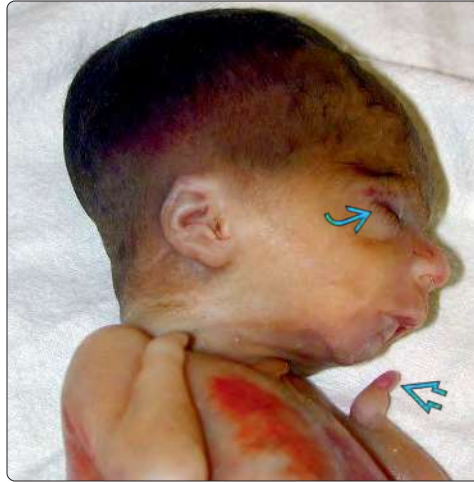Diabetic Embryopathy



Cornelia de Lange Syndrome

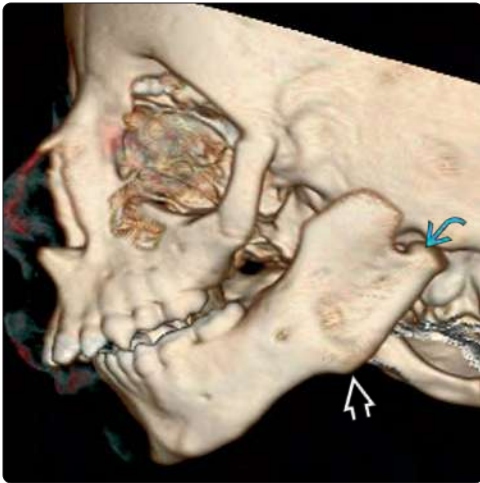


Cornelia de Lange Syndrome

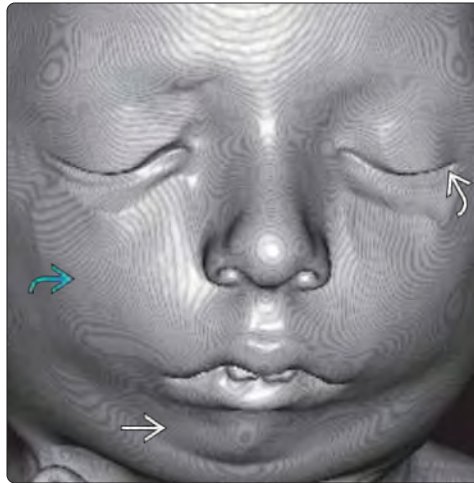

(Left) A view of the upper extremity in a fetus with a right-side diaphragmatic hernia shows a limb reduction defect ending in a point. (Right) This gross photograph shows the monodactyly and micrognathia typical of Cornelia de Lange syndrome. Also note the long eyelashes, another common feature. The diagnosis was confirmed by molecular analysis of the NIPBL gene.

Other Named Syndromes/Conditions

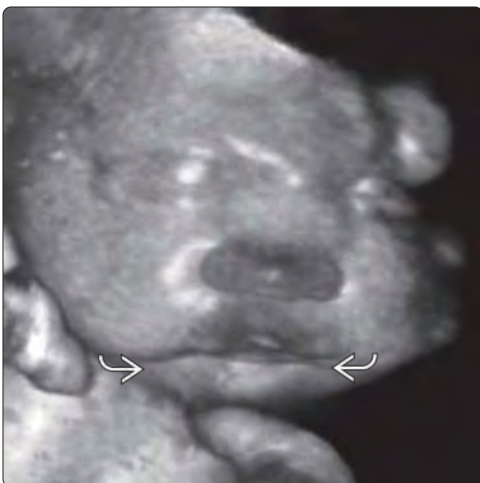

Other Named Syndromes/Conditions

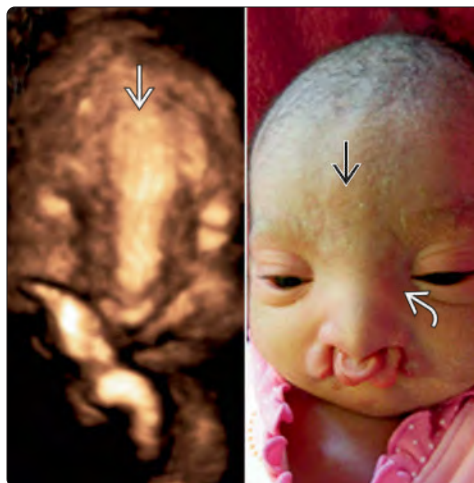

(Left) Sagittal 3D image shows an obtuse angle of the mandible and severe hypoplasia of the mandibular neck and condyle. Micrognathia causes posterior and superior displacement of the tongue or glossoptosis with effacement of the oropharynx. Radioulnar synostosis in this case (not shown) led to a diagnosis of Nager syndrome. (Right) 3D surface rendering in the same case of Nager syndrome shows symmetric micrognathia, malar flattening, and downslanting of the palpebral fissures.

Other Named Syndromes/Conditions



Other Named Syndromes/Conditions



(Left) This fetus with micrognathia had a final diagnosis of atelosteogenesis, a very rare skeletal dysplasia that is perinatal lethal due to respiratory compromise. (Right) 3D US in a fetus with micrognathia and bilateral cleft lip and palate shows an unusual appearance to the nose akin to a Greek warrior helmet. Amniocentesis confirmed Wolf Hirschhorn syndrome. The infant has the typical facial findings of prominent glabella, broad nasal root, hypertelorism, and upward slant of the palpebral fissures.

DIFFERENTIAL DIAGNOSIS

Common

- Idiopathic
- Trisomy 21

Less Common

- Beckwith-Wiedemann Syndrome
- Oral Mass (Mimic)
 - Epulis
 - Epignathus
 - Tongue Lymphangioma

ESSENTIAL INFORMATION

Key Differential Diagnosis Issues

- Normal fetal movements include swallowing, thumb sucking, and tongue motion
- Macroglossia implies that tongue is too large to fit in oral cavity
- Down syndrome fetuses may exhibit tongue thrusting movements in 3rd trimester
 - Tongue protrudes intermittently due to lax muscle tone
- If tongue seems "too easy to see," look carefully for facial cleft
 - Coronal view of nose/lips
 - Axial view of tooth buds
 - 3D ultrasound with multiplanar reconstructions
- Oral masses can be confusing
 - Sometimes hard to tell if mass originates in tongue or palate
- Lymphangioma may cause tongue enlargement
 - Rare amongst head and neck lymphangiomas
 - More likely to present in childhood than in fetus

Helpful Clues for Common Diagnoses

- **Idiopathic**
 - Structurally normal fetus
 - No signs of aneuploidy, particularly trisomy 21
 - Size appropriate for dates
- **Trisomy 21**

- Correlate with a priori risk and look for sonographic markers
 - Absent nasal bone
 - Thick nuchal fold
 - Mild ventriculomegaly
 - Congenital heart disease, particularly atrioventricular septal defect
 - Duodenal atresia
 - Echogenic bowel
 - Urinary tract dilation
 - Short humerus/femur
 - Clinodactyly/sandal gap toe

Helpful Clues for Less Common Diagnoses

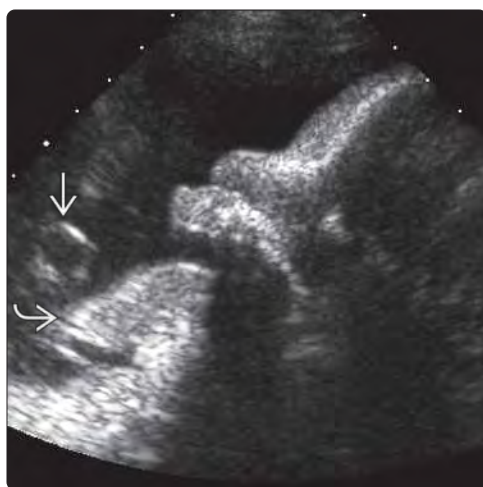- **Beckwith-Wiedemann Syndrome**
 - Macroglossia in 97%
 - Fetal overgrowth in 88%
 - Omphalocele/umbilical hernia in 80%
 - Organomegaly
 - Ear lobe pits or creases
 - Specific childhood risks associated with Beckwith-Wiedemann syndrome include
 - Severe neonatal hypoglycemia sufficient to cause brain injury
 - Childhood tumors develop in up to 10% of cases
 - ◻ Wilms tumor most common
- **Epulis**
 - Epulis arises from alveolar ridge
 - Separate from tongue
 - Centered to 1 side of oral cavity
- **Epignathus**
 - Typically very large mass
 - Cystic/solid/calcified components
 - Polyhydramnios common due to impaired swallowing

SELECTED REFERENCES

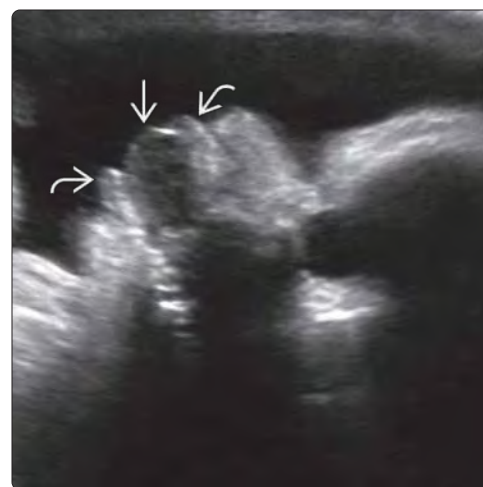
1. Achiron R et al: Development of the fetal tongue between 14 and 26 weeks of gestation: in utero ultrasonographic measurements. *Ultrasound Obstet Gynecol.* 9(1):39-41, 1997
2. Weissman A et al: Macroglossia: prenatal ultrasonographic diagnosis and proposed management. *Prenat Diagn.* 15(1):66-9, 1995

Idiopathic

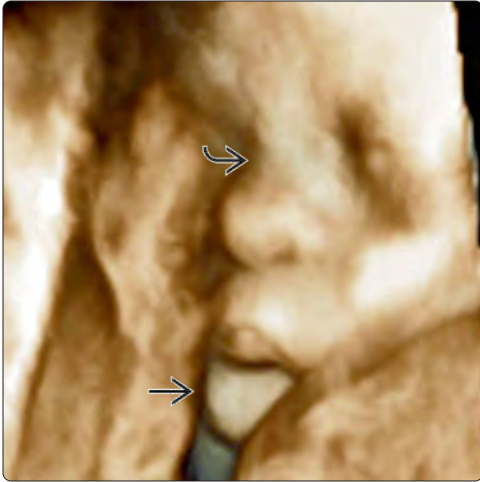(Left) Sagittal transabdominal ultrasound in the 3rd trimester to assess "size less than dates" shows a quite spectacular view of the fetal tongue flicking the umbilical cord. As the tongue was able to fit back in the mouth, this is not actually macroglossia. The infant was normal at birth. **(Right)** Contrast the previous ultrasound with this fetus with epulis. The mass is anchored at the alveolar ridge. Although it protrudes between the lips, it cannot, unlike the tongue, move in and out of the oral cavity.



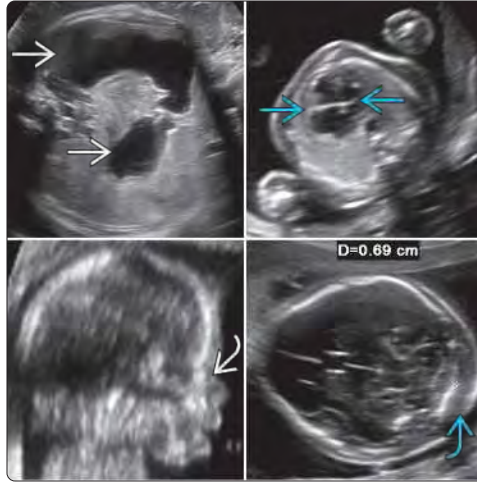Epulis



Trisomy 21

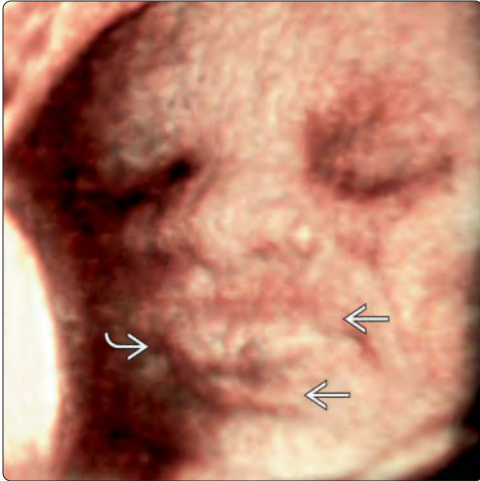

Trisomy 21

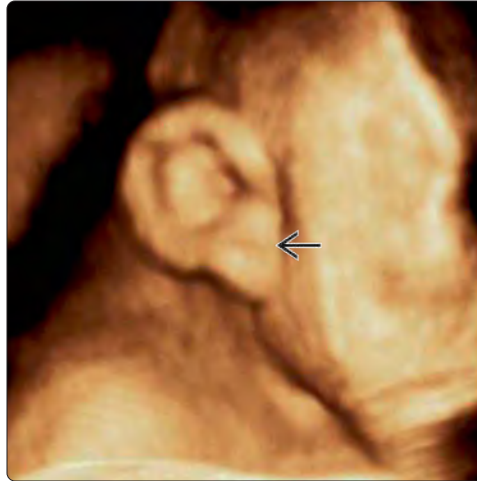

(Left) 3D surface reconstruction in a fetus with trisomy 21 shows macroglossia [arrow] as well as a flattened nasal bridge [arrow]. Tongue thrusting may be seen during the exam. (Right) Findings that may be seen in Down syndrome include duodenal atresia (double bubble created by fluid-filled stomach and duodenum) [arrow], atrioventricular septal defect (flat atrioventricular valves instead of normal offset on septum) [arrow], absent nasal bone [arrow], and increased nuchal fold thickness [arrow].

Beckwith-Wiedemann Syndrome

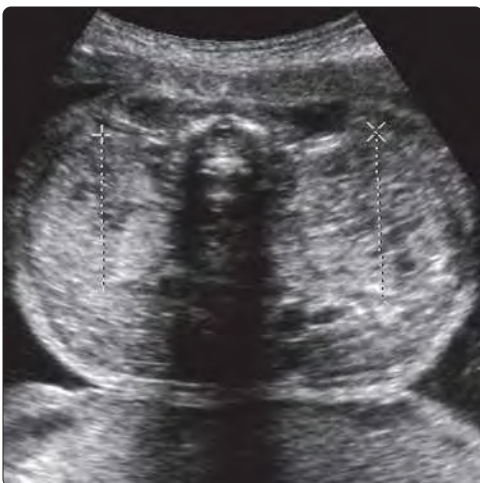

Beckwith-Wiedemann Syndrome

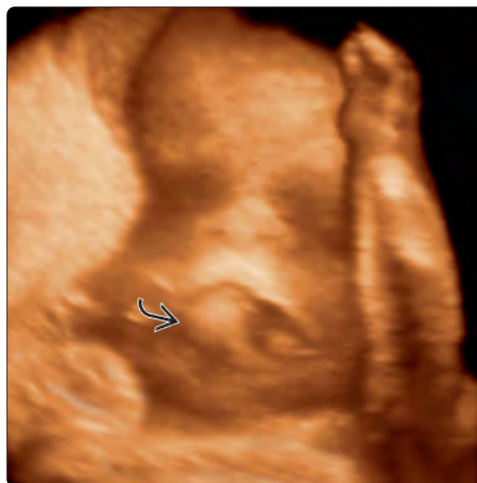

(Left) 3D surface-rendered view of the face in a fetus with Beckwith-Wiedemann syndrome shows the tongue [arrow] protruding between the lips [arrow]. This persisted throughout the scan, indicating that the tongue did not fit in the mouth, i.e., the fetus has macroglossia. (Right) 3D surface-rendered view shows a transverse crease [arrow] in the lobule of the ear. The same techniques apply to creating 3D surface-rendered images of the ears as to the face. Ear findings can be helpful in characterization of syndromes.

Beckwith-Wiedemann Syndrome



Epignathus

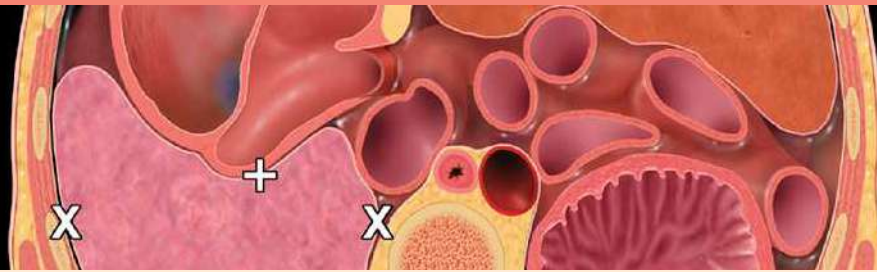


(Left) Axial ultrasound through the abdomen at the level of the kidneys shows marked nephromegaly; calipers mark the AP diameters of both kidneys. As a rule of thumb, the renal AP diameter should be no more than 1/3 of the abdominal AP diameter. (Right) An epignathus usually forms a large, fungating mass but on occasion can be small [arrow] and potentially confused with macroglossia.

This page intentionally left blank

SECTION 5

Chest



Embryology and Anatomy of the Chest	322
Approach to the Fetal Chest	330
Congenital Diaphragmatic Hernia	332
Congenital Pulmonary Airway Malformation	336
Bronchopulmonary Sequestration	340
Bronchogenic Cyst	344
Congenital High Airway Obstruction Sequence (CHAOS)	346
Pulmonary Agenesis	348
Lymphangioma	350
Mediastinal Teratoma	354
Pertinent Differential Diagnoses	
Solid/Echogenic Chest Mass	356
Cystic Chest Mass	360

GENERAL CONCEPTS

Overview of Lung Development

- Larynx and trachea
 - Origin of primitive larynx from laryngotracheal groove
 - Separation of primitive trachea from foregut and developing esophagus
- Bronchi
 - Tracheal bud branches into 2 primitive bronchial buds
 - Bronchial buds are precursors of bilateral main bronchi
- Lungs
 - Sequential branching of primitive bronchi
 - Formation of distinct pulmonary lobes
 - Formation of distinct pulmonary segments
- Distal airways and lung parenchyma
 - Interaction of endodermal and mesodermal elements allow normal lung development
 - Continued branching of primitive airways
 - Progressive vascularization of surrounding mesenchyme
 - Development of alveolar-capillary interface
 - Postnatal airway development and maturation
- Pleural development
 - Developing lungs protrude into coelomic cavity
 - Separation of pleural and pericardial cavities
 - Pleural investment of lungs within bilateral hemithoraces
- 5 developmental stages
 - Embryonic stage
 - Pseudoglandular stage
 - Canalicular stage
 - Saccular stage
 - Alveolar stage

EMBRYONIC STAGE (26 DAYS TO 6 WEEKS)

Laryngotracheal Groove

- Develops 26-28 days after fertilization
- Arises caudal to primitive pharynx and 4th pair of pharyngeal pouches
- Longitudinal growth

Respiratory Diverticulum or Lung Bud

- Develops 4 weeks after fertilization
- Pouch-like outgrowth from caudal aspect of laryngotracheal groove
- Caudal growth
- Invested in mesodermal-derived splanchnic mesenchyme

Tracheal Bud

- Globular enlargement of distal lung bud
- Caudal growth from primordial pharynx
- Proximal communication with foregut through primordial laryngeal inlet

Tracheoesophageal Septum

- Longitudinal tracheoesophageal folds form on either side of developing tracheal bud
- Medial growth of bilateral tracheoesophageal folds
- Formation of tracheoesophageal septum from midline fusion of tracheoesophageal folds
- Separation of primitive trachea from developing esophagus

Primary Bronchial Buds and Branches

- Branching of primitive tracheal bud into right and left branches (5th week after fertilization)
 - Right bronchial bud: Larger and vertically oriented
 - Left bronchial bud: Smaller and horizontally oriented
- Branching of primary bronchial buds into 2 primitive lobar bronchi
 - Right superior lobar bronchus → right upper lobe bronchus
 - Right inferior lobar bronchus → primitive bronchus intermedius
 - Right middle lobe bronchus
 - Right lower lobe bronchus
 - Left superior lobar bronchus → left upper lobe bronchus
 - Left inferior lobar bronchus → left lower lobe bronchus
- Branching of primitive lobar bronchi into primitive segmental bronchi

PSEUDOGLANDULAR STAGE (6-16 WEEKS)

Important Events

- Formation of all major airway elements
 - Bronchial development complete to level of terminal bronchioles
- All bronchopulmonary segments formed by 7 weeks after fertilization

Microscopic Morphology

- Gland-like appearance of lung
- Formation of tracheobronchial cartilages, mucus glands, and cilia by 13 weeks after fertilization
- Primitive airways lined by endodermal-derived columnar epithelium
- Primitive airways surrounded by mesodermal-derived mesenchymal tissue
- Absent alveolar-capillary interface

Physiologic Implications

- Respiration not possible
- No possibility of extrauterine survival

CANALICULAR STAGE (16-28 WEEKS)

Important Events

- Continued vascularization of lung
- Continued development of primitive airways
 - Terminal bronchioles give rise to 2 or more respiratory bronchioles
 - Respiratory bronchioles give rise to 3-6 alveolar ducts
 - Development of small number of terminal saccules
- Lamellar inclusions within type 2 pneumocytes in terminal saccules with potential for surfactant production

Microscopic Morphology

- Continued enlargement of primitive airway lumens
- Continued thinning of airway epithelium
- Epithelial differentiation into type 1 and type 2 cells
- Airways separated by reduced but significant mesenchymal tissue

Physiologic Implications

- Limited surfactant production

- Respiration is possible in late canalicular stage
- Possibility of neonatal survival with intensive care and appropriate life support

SACCULAR STAGE (28-36 WEEKS)

Important Events

- Development of increasing numbers of terminal sacculles
- Establishment of primitive alveolar-capillary interface
- Increased potential for surfactant production

Microscopic Morphology

- Continued airway differentiation
- Continued thinning of airway epithelium
- Some capillaries abut and bulge into developing alveoli
- Terminal sacs begin to approach morphology of adult alveoli

Physiologic Implications

- Respiration with adequate gas exchange is possible
- Survival of premature neonates with appropriate life support

ALVEOLAR STAGE (36 WEEKS TO 8 YEARS)

Important Events

- Continued development of distal airways with primordial alveoli forming along respiratory bronchioles and terminal sacculles
- Development of thin alveolar-capillary membrane
- Postnatal lung development
 - 24 million terminal sacs and alveoli present at birth compared to 300 million in adult lungs
 - 5x increase of alveolar numbers within 1st year of life
 - Formation of 95% of adult alveoli by 8 years of age

Microscopic Morphology

- Continued thinning of epithelial lining of terminal sacs
- Formation of primordial alveoli
- Adjacent capillaries bulge into terminal sacculles

Physiologic Implications

- Presence of nearly mature alveolar-capillary interface
- Adequate surfactant production
- Respiration possible without external support

OTHER DEVELOPMENTAL REQUIREMENTS

Volume Requirements

- Adequate intrathoracic volume required for normal pulmonary development
- Intrathoracic masses (especially diaphragmatic hernia) and chest wall abnormalities (e.g., skeletal dysplasias) restrict space for lung growth

Amniotic Fluid Requirements

- Amniotic fluid and fetal breathing required for normal lung development
- Oligohydramnios has severe adverse effect on lung development
 - Fetal compression causes decreased space for lung growth
 - Restriction of breathing movements with efflux of lung fluid into amniotic space

Circulatory Requirements

- Circulation affects pulmonary development
 - Pulmonary arterial development along developing airways
 - Vasculogenesis within primitive mesenchyme to form capillary network
 - Pulmonary vein and lymphatic development along segmental boundaries
- Right-sided obstructive lesions decrease pulmonary blood flow with subsequent poor lung development

Diaphragm Development

- Complex embryonic origin with 4 embryologic structures
 - Septum transversum: Forms most of central tendon
 - Pleuroperitoneal membranes: Bulk of diaphragm muscle, innervated by phrenic nerve
 - Paraxial mesoderm of body wall: Outer rim of diaphragmatic muscle
 - Esophageal mesenchyme: Condenses to form diaphragmatic crura

Thymus

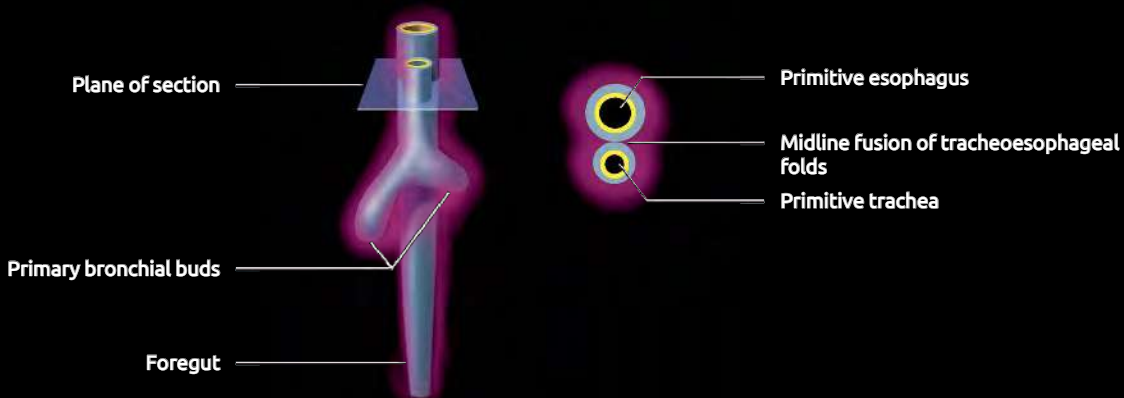
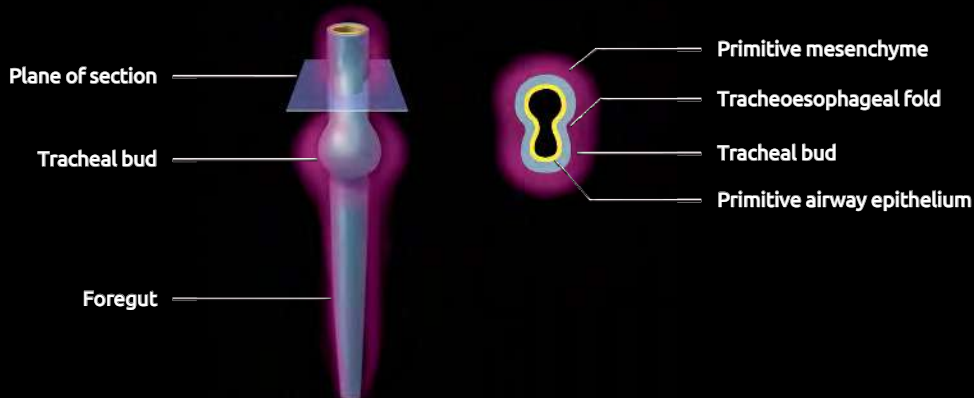
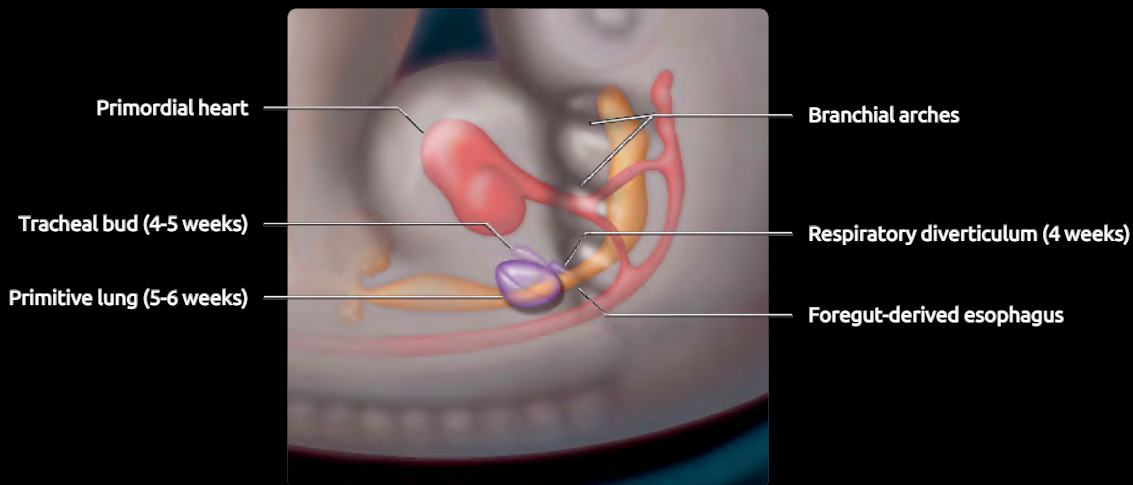
- Arises from 3rd pharyngeal pouch
- Between 4th-7th, week thymic primordia migrate to chest
 - Posterior to sternum in superior mediastinum
 - Fuse to form bilobed gland
- Once formed, lymphocytes infiltrate gland
- Large and highly active in perinatal period
 - Continues to grow until puberty and then involutes in adulthood
- May be confused with chest mass
 - Look for thy-box to confirm it is thymus
 - Thymus is flanked by internal mammary arteries, branches of subclavian arteries
 - Color Doppler of superior mediastinum, at level of 3-vessel view, shows thymus between internal mammary arteries creating box appearance

NEONATAL LUNG

1st Breath

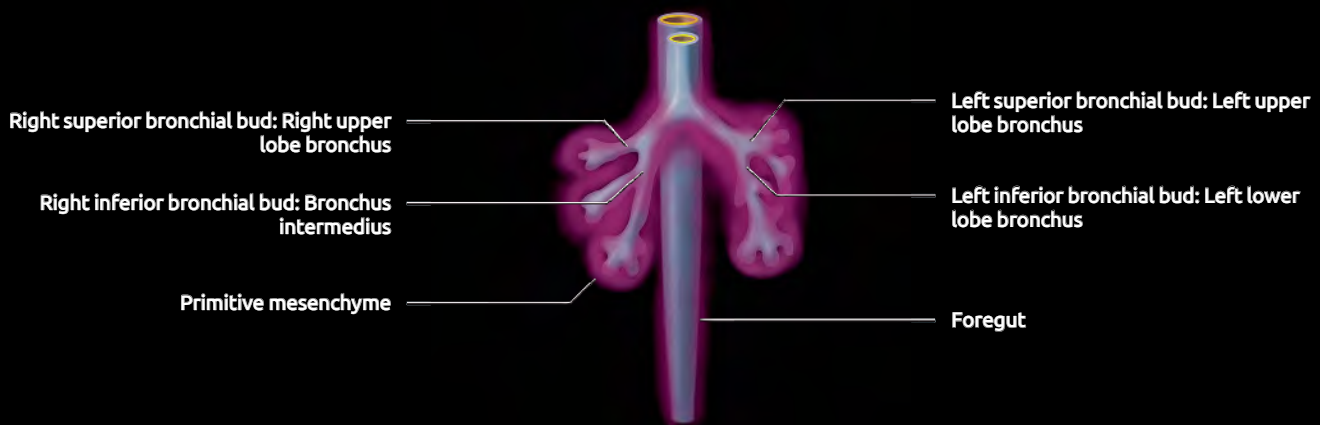
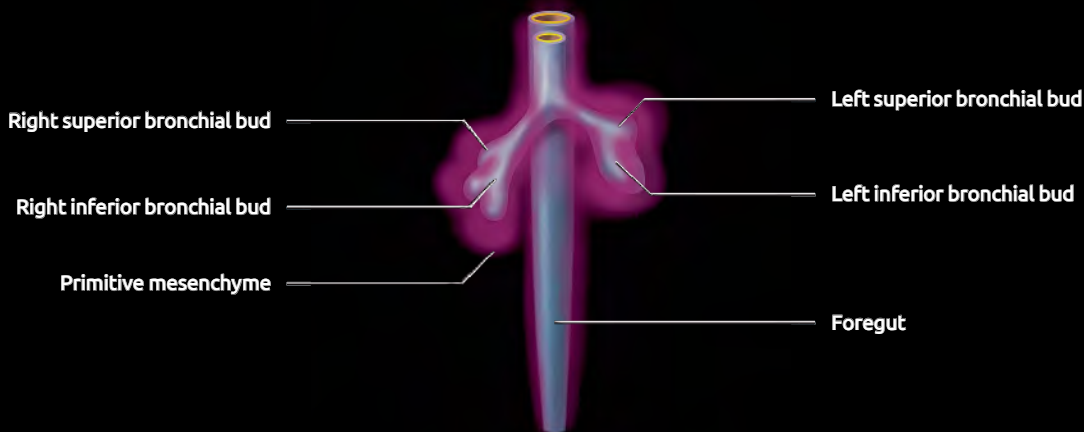
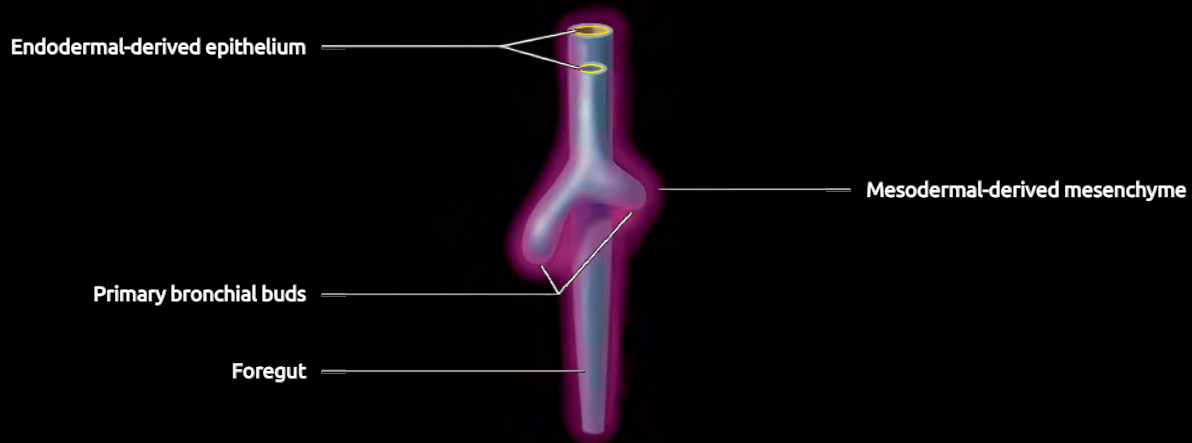
- Diaphragmatic contraction
- Pulmonary vascular changes
 - Fluid-filled lungs result in high-resistance pulmonary circulation
 - Small portion of cardiac output goes to lungs prior to birth
 - Pulmonary expansion with 1st breath
 - Vasodilatation
 - Increased pulmonary blood flow
 - Clearance of fetal lung fluid via lymphatics and capillaries
- Role of surfactant
 - Alveolar expansion results in surfactant discharge by type 2 pneumocytes
 - Decreased surface tension of remaining intraalveolar fluid
 - Increased surfactant activity with decreased surface area
 - Prevention of alveolar collapse during expiration

LUNG DEVELOPMENT



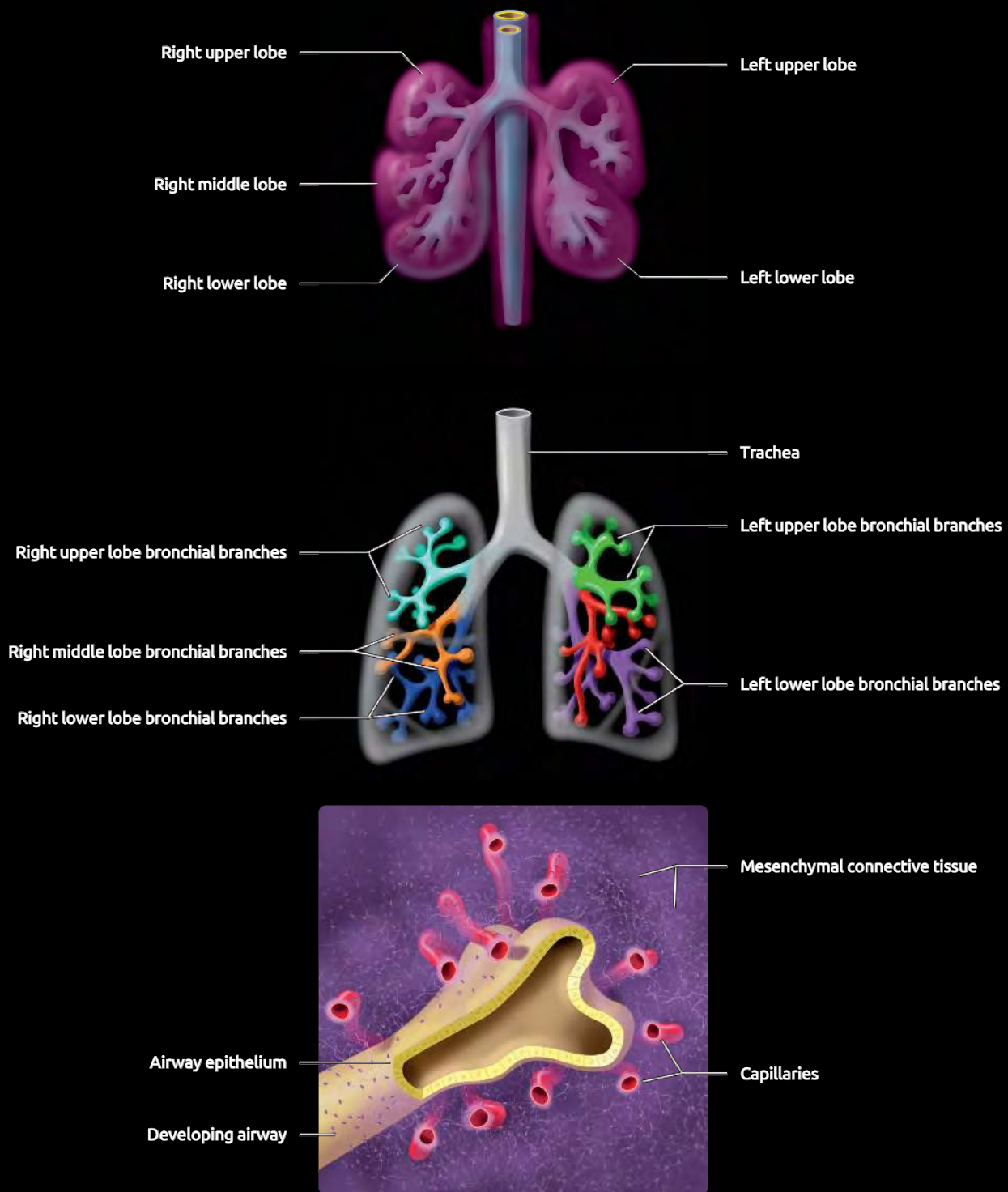
(Top) Graphic shows the development of the primitive lung. The respiratory diverticulum arises from the laryngotracheal groove near the primordial esophagus caudal to the 4th pharyngeal pouches. The sequential evolution of the respiratory diverticulum to the tracheal bud and the primitive lung is shown. Note the close relationship of the developing tracheobronchial tree and lungs to the primitive esophagus. **(Middle)** Graphic shows the tracheal bud, a ventral outpouching of the foregut surrounded by mesodermal-derived mesenchyme and lined by endodermal-derived epithelium. The axial plane of section (right) shows communication between the tracheal bud and the foregut. The formation of bilateral longitudinal tracheoesophageal folds is shown. **(Bottom)** Graphic shows vertical development of the primary bronchial buds. The tracheoesophageal folds fuse in the midline to separate the trachea from the esophagus.

LUNG DEVELOPMENT



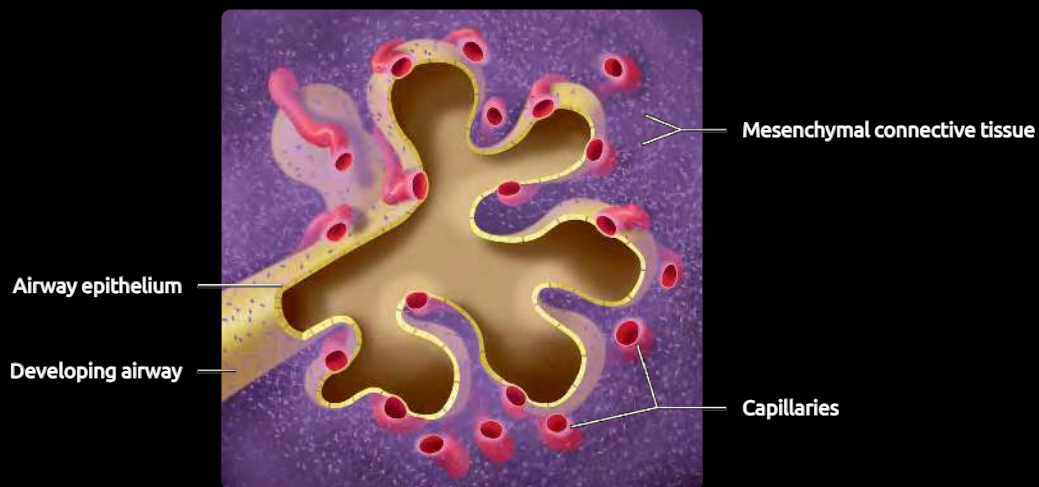
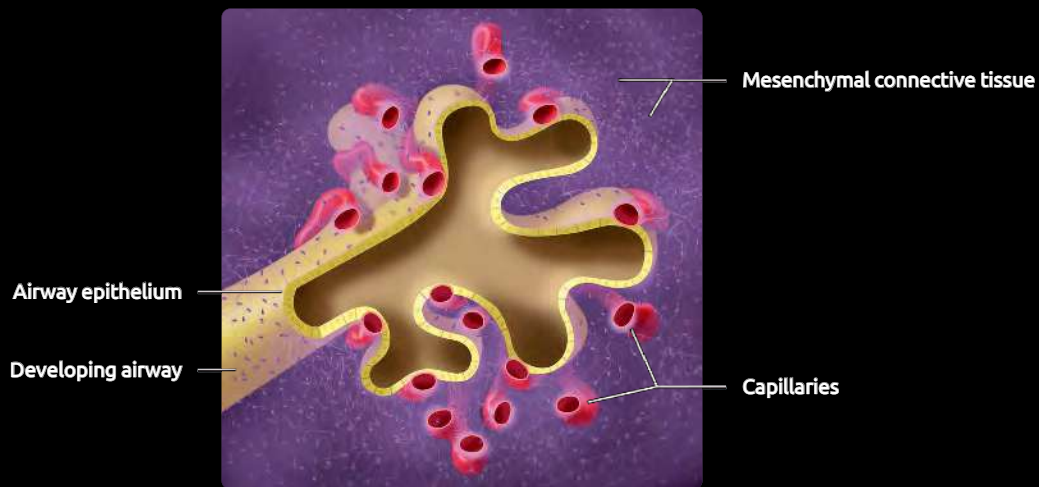
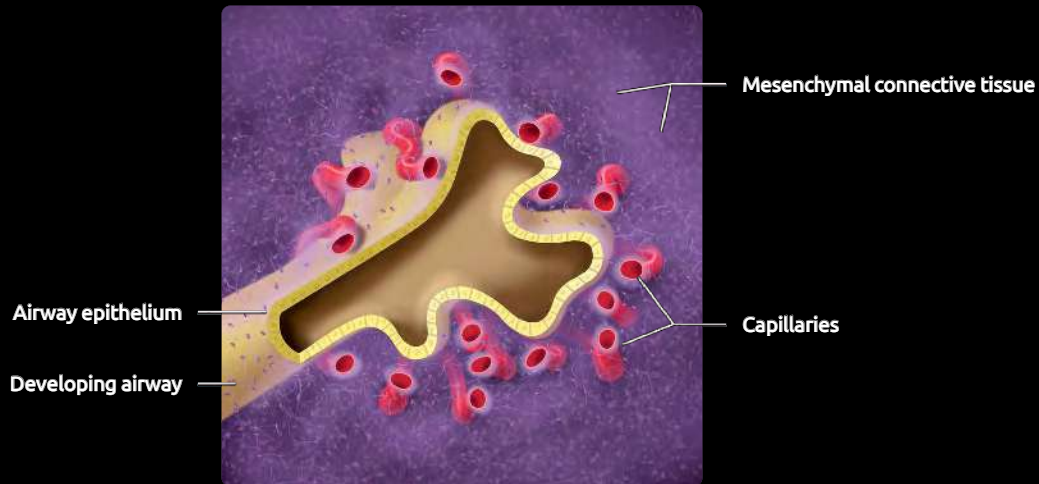
(Top) Graphic shows the development and morphology of the bronchial buds as they invaginate into the primitive mesenchyme. The bronchial buds are the precursors of the main bronchi. Note that the right bronchial bud is vertically oriented and the left follows a more horizontal course. **(Middle)** Graphic shows the tracheobronchial tree at 28 days of gestation as the right and left bronchial buds begin to divide. The developing tracheobronchial tree is surrounded by primitive mesenchyme. **(Bottom)** Graphic shows the developing tracheobronchial tree at 42 days of gestation with continued elongation and branching of the bronchial buds to form rudimentary lobar bronchi. Further growth and branching of the distal primitive airway forms rudimentary segmental bronchi. The rudimentary bronchus intermedium gives rise to primitive right middle and right lower lobe bronchi.

LUNG DEVELOPMENT



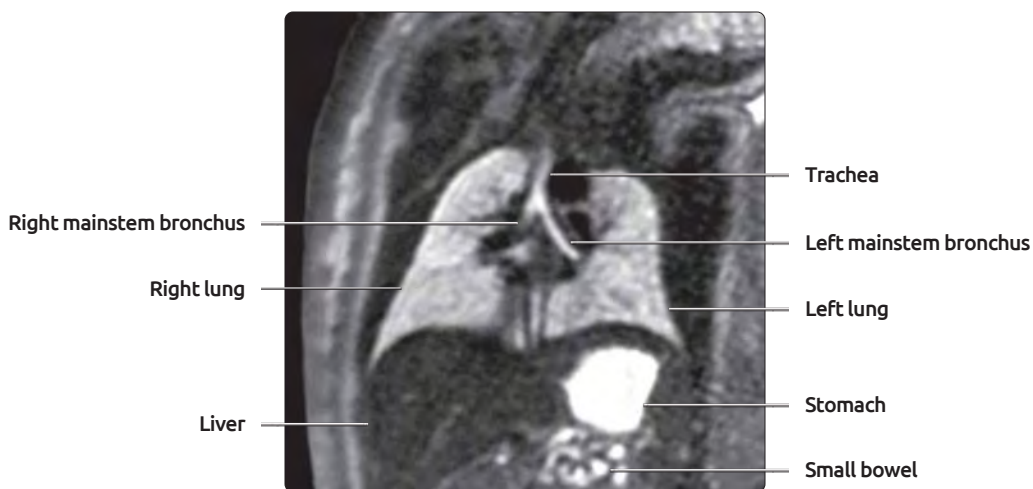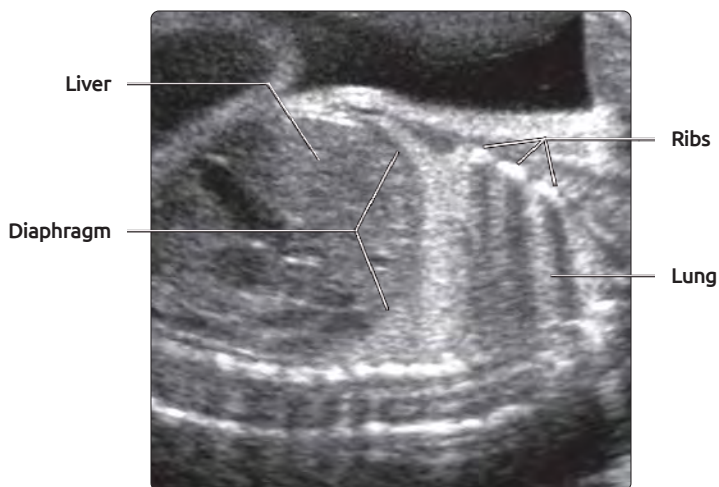
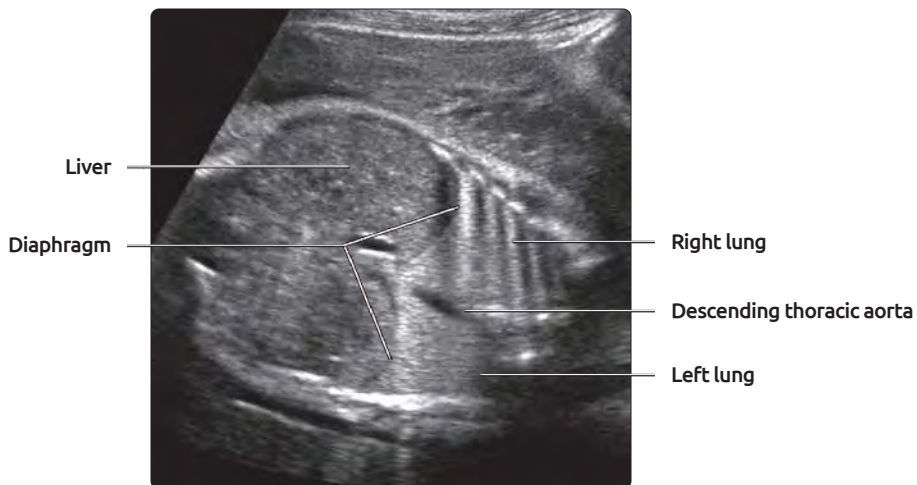
(Top) Graphic shows tracheobronchial development at 56 days of gestation with continued branching of the primitive airways and rudimentary lung lobes. **(Middle)** Graphic shows tracheobronchial development at ~ 10 weeks of gestation. Note the airway differentiation into the rudimentary lobar bronchial branches (shown in different colors) and segmental bronchial branches. Note that the green and red bronchial branches represent different portions of the primitive left upper lobe. Recognizable lung lobes are present. The interaction between the primitive tracheobronchial tree and the surrounding primitive mesenchyme induces the development of lung parenchyma. **(Bottom)** Graphic shows the primitive airway in the pseudoglandular stage of development (6-16 weeks). The airways are blind-ending tubules. There is no alveolar-capillary interface as connective tissue separates the thick-walled primitive airway from the pulmonary capillaries. Respiration is not possible.

LUNG DEVELOPMENT



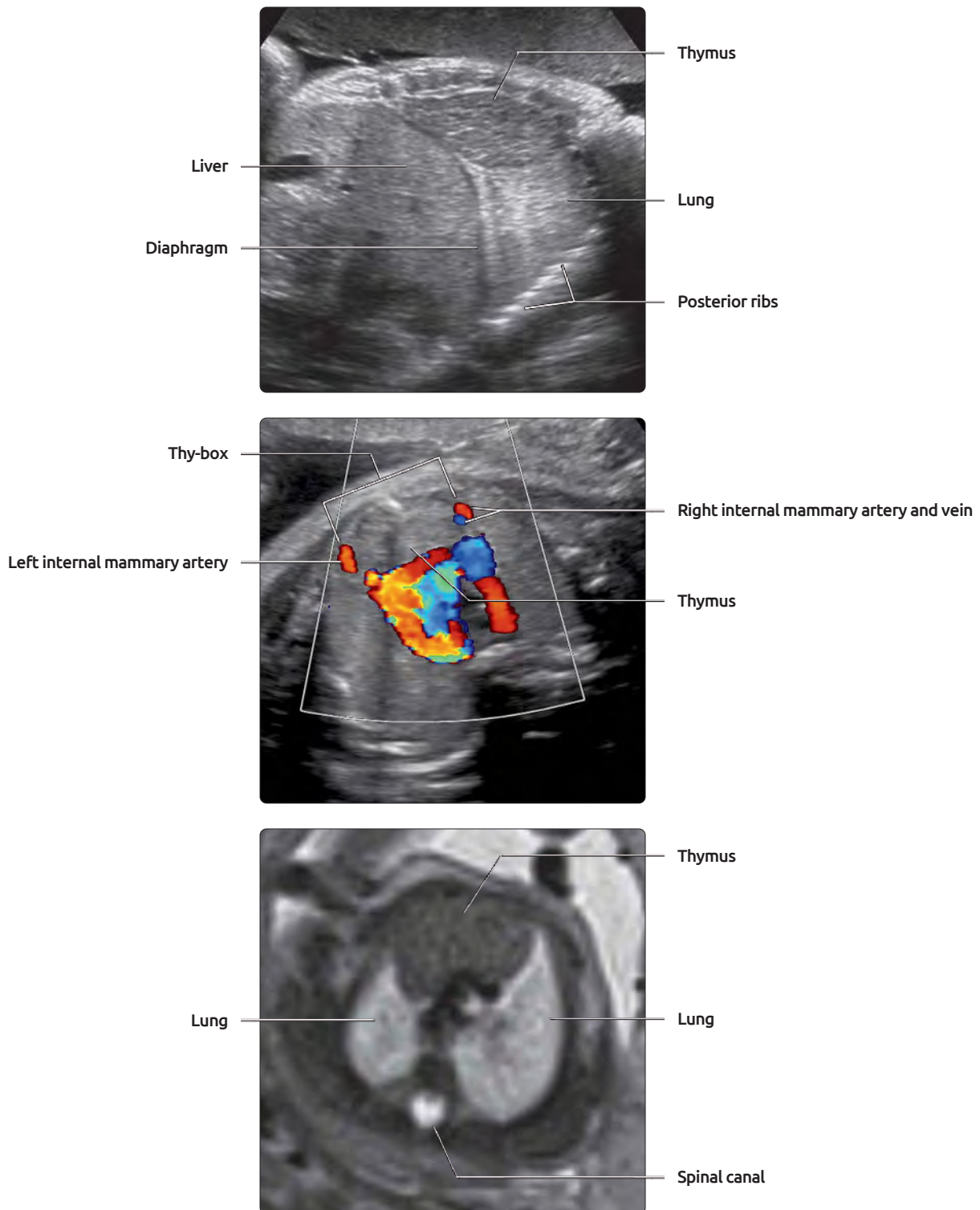
(Top) Graphic of the canicular stage of development (16-28 weeks) shows the airway lumen has enlarged and the epithelium has thinned. There is an increased number of vessels within the primitive mesenchyme, some of which abut the airway wall. Respiration is possible at the end of this stage of lung development, but these infants require intensive care for survival. **(Middle)** Graphic of the sacular stage of lung development (28-36 weeks) shows the airway lumen continuing to enlarge. More numerous capillaries abut the wall, and some bulge into the lumen. Respiration is possible, and many infants born at this stage of pulmonary development survive with proper medical management and support. **(Bottom)** Graphic of the alveolar stage of pulmonary development (36 weeks to 8 years) shows continued airway enlargement with less surrounding connective tissue. The airway epithelium is thin, and many capillaries bulge into the airway lumen establishing mature alveolar-capillary interfaces. Airway development continues after birth and into childhood.

FETAL LUNGS



(Top) Coronal ultrasound of a 3rd-trimester fetus shows the lungs are homogeneous in echotexture and hyperechoic when compared to the liver. In the 1st trimester, the lungs and liver are similar in echogenicity, but the lungs become more hyperechoic as alveolar development progresses, creating more acoustic interfaces. **(Middle)** Sagittal ultrasound of the fetal chest shows the diaphragm, which is a thin, hypoechoic, muscular band. The diaphragm is best evaluated in this projection to ensure it has been seen in its entirety. **(Bottom)** Coronal T2WI of the chest shows the relatively high signal intensity lungs compared to the low signal intensity liver. Fluid-filled structures, including the trachea, bronchi, stomach, and small bowel, are all very high signal and easily distinguished on T2-weighted sequences.

FETAL THYMUS



(Top) Sagittal ultrasound of the fetal chest in the 3rd trimester shows the fetal thymus. It is hypoechoic when compared to the lungs and has a slightly reticular appearance. The thymus is often quite prominent in a fetus and should not be confused with a lung or mediastinal mass. **(Middle)** Axial color Doppler of the superior mediastinum at the top of the outflow tracts shows the thy-box. The internal mammary arteries, branches of the subclavian arteries, flank the thymus, creating a box appearance. Thymic measurements can be taken if there is a suspicion for hypoplasia, as in 22q11 deletion syndrome. **(Bottom)** Axial T2-weighted MR at ~ the same level shows the thymus is hypointense when compared to the lungs.

Imaging Techniques and Normal Anatomy

Ultrasound

In regards to the fetal chest, the American Institute of Ultrasound in Medicine requires a four-chamber view of the fetal heart and outflow tracts. Evaluation of the lungs is not specified; however, the cardiac views, along with images of the diaphragm, can adequately evaluate the lungs, and significant chest masses can be excluded.

The heart occupies ~ 1/3 of the intrathoracic area on the four-chamber view. The cardiothoracic ratio can be calculated by dividing the cardiac circumference by the thoracic circumference (TC), with normal being ~ 50%. An increased ratio usually indicates that the heart is dilated (cardiomegaly), but it may also occur when the chest is small.

The fetal heart has a horizontal lie and should be imaged in a true axial plane. The plane is correct if one continuous rib is seen. If the transducer is angled, it may give the erroneous impression of a diaphragmatic hernia. If multiple ribs are seen, the view is oblique and, therefore, incorrect.

When evaluating the four-chamber view, picture an imaginary line drawn from the midvertebral body through the sternum, dividing the chest in half. Only the right atrium and a portion of the right ventricle should project to the right of this line. A second imaginary line can be drawn along the interventricular septum; the angle between these lines indicates the cardiac axis. The axis should be ~ 45°.

Early in gestation, the lungs can be similar in echogenicity to the liver but become more echogenic with advancing gestational age. Unfortunately this increase in echogenicity does not correlate with lung maturity and cannot be used to predict pulmonary hypoplasia. Any aberration in this homogeneous echotexture indicates the presence of a mass.

The diaphragm appears as a thin, arched, hypoechoic band. It is imperative that it be completely imaged from front to back, which is best done in the sagittal plane. If only viewed in the anterior coronal plane, a congenital diaphragmatic hernia (CDH) may potentially be missed.

Fetal breathing movements can be observed during real-time scanning and are essential for normal lung development. Fetal lung fluid is necessary for lung growth and maturation, and there is a complex interchange of lung fluid with amniotic fluid during breathing. In addition to growth factors, fetal lung fluid functions as a stent, keeping developing airways distended. Decreased fetal lung fluid, which is often the result of oligohydramnios, leads to hypoplasia, while increased fetal lung fluid (e.g., with tracheal atresia) leads to overgrowth and advanced maturation. Breathing is also an indicator of overall fetal well being and is a component of the biophysical profile.

MR

MR can be a helpful adjunct in the evaluation of fetal chest masses, particularly CDH. Its superior soft tissue contrast easily differentiates liver, lung, and bowel.

On T1-weighted images, the lungs are intermediate signal intensity, not significantly different from surrounding soft tissues; most lung masses are not well evaluated with this sequence. The value of T1-weighted imaging is primarily in the evaluation of CDH. The liver is higher in signal intensity than lung, fluid-filled small bowel is low in signal intensity, but meconium-filled large bowel will be high in signal intensity.

On T2-weighted imaging, the lungs are higher in signal intensity than the surrounding musculature. The signal intensity of the lungs increases throughout gestation reflecting the fluid within the enlarging alveoli. The liver, by comparison, is significantly lower in signal intensity making this sequence ideal for determining liver herniation in a CDH. A compressed lung will have decreased signal (i.e., contains less fluid) compared to a normal lung and may be difficult to visualize.

The thymus is often seen and should not be confused with a chest mass. It has an intermediate signal intensity on T2-weighted images and is located in the superior portion of the mediastinum, often displaying angular borders.

Approach to Fetal Chest Mass

It is important to have a systematic approach when viewing the fetal chest and developing an appropriate differential for a chest mass. The following questions form a framework for evaluation. Each of the diagnostic entities will be discussed in detail in the subsequent chapters.

Is the Chest Normal in Size?

A TC is not generally performed unless there is concern that the chest is small (e.g., skeletal dysplasias or oligohydramnios). The TC is performed at the level of the four-chamber view with the soft tissues excluded. This can be compared to the expected value based on gestational age or as a ratio with the abdominal circumference (AC). The TC:AC ratio is stable throughout gestation with normal being > 0.8. Enlarged chest size is unusual but is a prominent feature of congenital high airway obstruction sequence (CHAOS).

Is the Axis of the Heart Deviated?

Any shift in the cardiac axis is highly suspicious for a thoracic mass or, alternatively, a cardiac defect. While a normal axis rules out most significant chest masses, small masses may not necessarily deviate the axis and may be missed.

Where Is the Stomach?

Absence of the normal abdominal stomach bubble is a cardinal sign of a left-sided CDH. It is important to note, however, that a left-sided hernia may contain only bowel &/or liver, with the stomach remaining below the diaphragm. With a right-sided CDH, the stomach remains in the abdomen but is often more midline than normally seen.

Is the Mass Cystic or Solid?

This is the first and most important question once it has been determined that a chest mass is present. Although there is overlap in the two differentials [congenital pulmonary airway malformation (CPAM) and CDH may look either cystic or solid], this is the starting point for forming a differential diagnosis.

If Cystic, Is it a Simple Cyst or a Complex Cystic Mass?

A simple cyst within the chest is more likely to be a foregut duplication cyst, while a complex cystic mass is more likely to be a CDH, macrocystic CPAM, or lymphangioma. An effusion should not be confused with a cystic mass. The lung will float within an effusion and have a wing-like appearance, while a cystic mass will displace and compress the lung.

If Solid, What Does the Doppler Show?

A CPAM has its vascular supply (both arterial and venous) from the pulmonary circulation. A sequestration has a prominent feeding vessel from the aorta. A CDH containing liver will show hepatic and portal veins.

Where Is the Mass?

Sequestrations are almost always at the left lung base (or below the diaphragm), while CPAMs are more variable in location, occurring equally on both sides. Congenital lobar obstruction occurs more commonly in the upper lobes (L > R). Bilateral chest masses are less common but include bilateral CPAMs, bilateral CDHs, or CHAOS.

Does the Mass Extend Beyond the Chest Wall?

Lymphangiomas have the bulk of the mass in the subcutaneous tissues, with secondary intrathoracic involvement. Teratomas can be locally aggressive and erode through the chest wall.

Is There Hydrops?

While uncommon, any chest mass has the potential to cause hydrops. The development of hydrops is a poor prognostic sign and may warrant clinical intervention (e.g., cyst drainage, in utero resection, early delivery). All chest masses should be monitored carefully for developing hydrops.

CDH is an interesting exception in that hydrops is rare. The reasons are not entirely clear, but it may be that an open

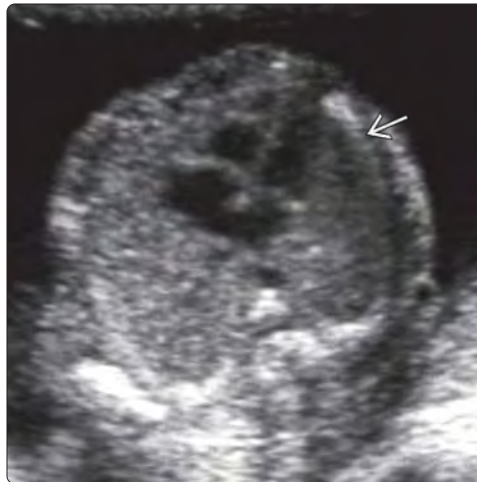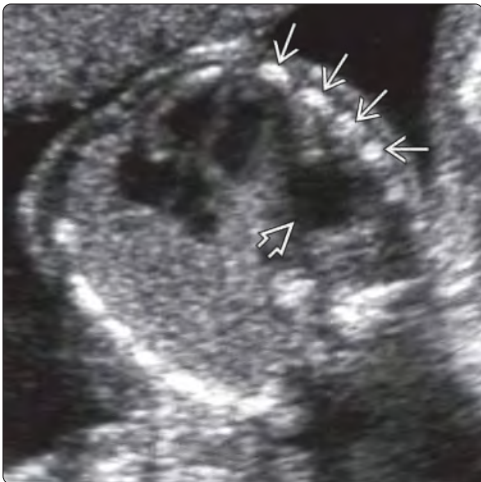diaphragmatic defect decreases the compressive forces on mediastinal structures.




Are There Other Anomalies?

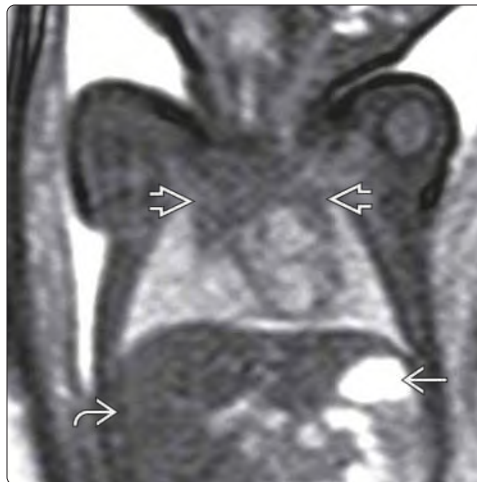
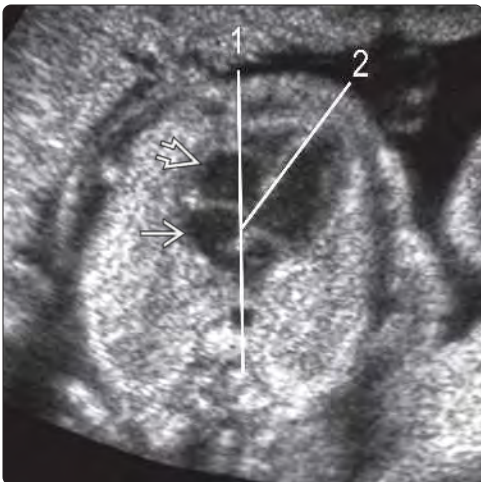
Many chest masses are isolated findings. CDH is the exception, having a high association with chromosomal anomalies, other structural anomalies, and syndromes. It is especially important to carefully evaluate the heart. Because the cardiac axis is often distorted, it may be more difficult to adequately evaluate, and a dedicated fetal echo may be warranted.






What Is the Likelihood of Pulmonary Hypoplasia?

This is ultimately the most important question in evaluating any fetus with a chest mass. Unfortunately, it is not a question that can be easily answered. There are no universally accepted criteria for predicting hypoplasia, and a plethora of measurements and ratios exist. In addition, not all chest masses are created equal. A CDH is far more likely to cause pulmonary hypoplasia, and therefore has a worse prognosis, than a similarly sized lung mass. This is likely the result of disruption of normal fetal breathing as well as mass effect. The lung:head ratio is the most widely used predictive measurement for hypoplasia in CDH.



(Left) Axial oblique ultrasound through the fetal chest gives the erroneous appearance of a congenital diaphragmatic hernia. The stomach  appears to be adjacent to the heart. Note that multiple ribs  are seen, indicating that this is not a true axial plane. **(Right)** When the scan plane is corrected, a single continuous rib  is seen along with a normal 4-chamber view of the heart. It is imperative to scan in the correct axis to avoid misinterpretation.



(Left) Axial ultrasound at the level of the 4-chamber view shows that only the right atrium  and a portion of the right ventricle  extend to the right of midline (line 1). The interventricular septum (line 2) indicates the cardiac axis, which should be ~ 45°. **(Right)** Coronal T2WI MR shows a normal thymus , which should not be confused with a lung mass. The lungs are higher in signal intensity than the liver . The fluid-filled stomach  has the highest signal intensity.

KEY FACTS

TERMINOLOGY

- Foramen of Bochdalek hernia (posterior defect in diaphragm) most common type in fetuses

IMAGING

- Imperative to view entire diaphragm in sagittal plane
 - Coronal view of anterior diaphragm may be normal
- Left-sided hernia (80-90% of cases)
 - Stomach usually in chest
 - More posterior position suggests liver also herniated
 - Deviation of heart toward right
 - Polyhydramnios often develops in 3rd trimester
- Be suspicious of bilateral hernias when stomach is in chest but little mediastinal shift
- Up to 85% contain herniated liver (liver up)
 - Use color Doppler to look for portal and hepatic veins
- Calculate lung:head ratio (LHR)
- MR excellent for identifying contents of hernia and performing volumetric lung measurements

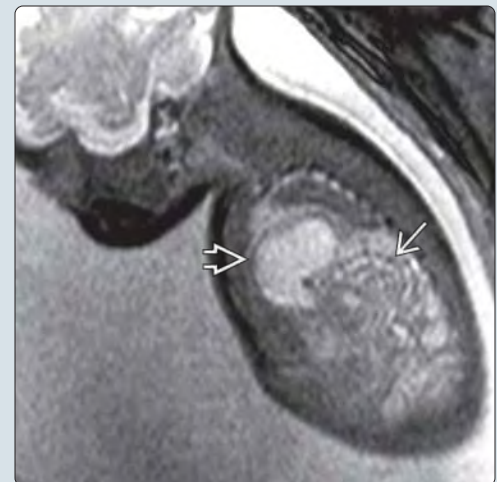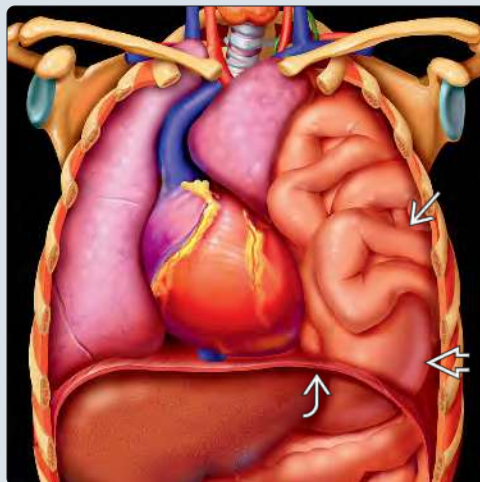
PATHOLOGY

- Associated abnormalities in up to 50% of cases
 - Structural anomalies (especially cardiac), abnormal chromosomes, and syndromes all reported
 - All fetuses should be karyotyped
- Pulmonary hypoplasia worse than from other chest masses of comparable size
 - Hypoplasia always present to varying degrees

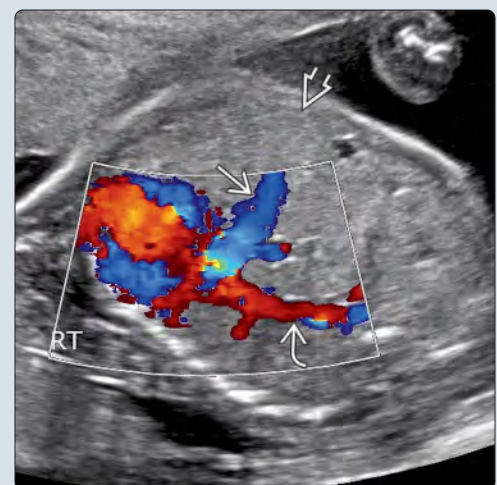
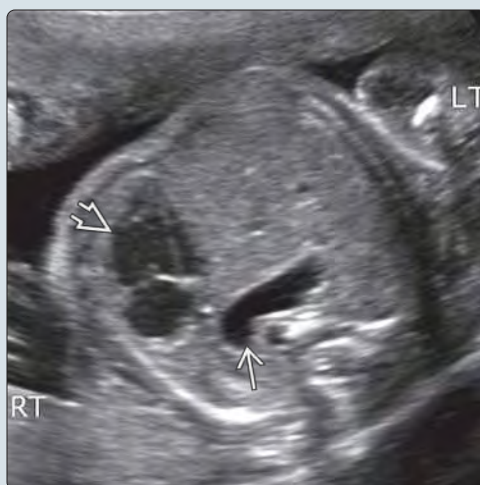CLINICAL ISSUES

- 1st step is determining if CDH is isolated or other anomalies present; if present, very poor prognosis
- If isolated, other prognostic indicators become important
 - Liver up is independent risk factor with poor prognosis
 - LHR < 1.0 has ↑ mortality and morbidity in survivors
 - Consider fetal therapy for this group
- Delivery at tertiary care facility essential for all cases
- All ultrasound ratios can be calculated by entering data in calculators at: Perinatology.com/calculators

(Left) Graphic shows a Bochdalek hernia, the most common CDH in fetuses. The defect is posterior with herniation of the stomach and small bowel into the left hemithorax. Note that the anterior diaphragm remains intact, stressing the importance of the sagittal plane when evaluating the diaphragm. If viewed only in the coronal plane, a diaphragmatic defect could be missed. (Right) Sagittal T2WI MR through the left hemithorax of a fetus shows herniation of the stomach and small bowel.



(Left) Axial US through the chest shows the heart abutting the right chest wall. The stomach is posterior, crosses the midline, and has a retrocardiac portion. The posterior location indicates liver herniation. (Right) This oblique coronal color Doppler US confirms a large amount of liver within the chest, with the inferior vena cava and middle hepatic vein converging toward the heart.



TERMINOLOGY

Definitions

- Herniation of abdominal contents into chest cavity
 - Foramen of Bochdalek (most common type in fetuses)
 - Posterior defect in diaphragm
 - Foramen of Morgagni: Anterior, right sided

IMAGING

General Features

- Abdominal circumference will measure < expected

Ultrasonographic Findings

- **Left-sided hernia** (80-90%)
 - Stomach usually in chest
 - Deviation of heart toward right
 - Small congenital diaphragmatic hernias (CDH) may be missed, especially if stomach is not herniated
 - Abnormal cardiac axis may be only clue
 - Polyhydramnios often develops in 3rd trimester
 - Up to 85% contain herniated liver (liver up)
 - Typically, left lobe herniates adjacent to heart
 - Stomach is displaced posteriorly
 - Always use Doppler to follow portal and hepatic veins
- **Right-sided hernia** (10-15%)
 - Contains liver ± gallbladder ± bowel
 - Stomach below diaphragm but often midline in location
- **Bilateral hernia** (< 5%)
 - Be suspicious when stomach is in chest but little mediastinal shift

MR Findings

- Excellent for identifying contents of hernia and performing volumetric lung measurements
 - Small bowel: Low-signal T1WI, high-signal T2WI
 - Meconium-filled colon: High-signal T1WI, low-signal T2WI
 - Liver: High-signal T1WI, low-signal T2WI
 - Compare signal of liver above and below diaphragm
 - Higher signal above diaphragm suggests some degree of vascular compromise (liver lock)
 - Lung: Signal increases on T2WI with gestational age but not adequate to predict hypoplasia

Imaging Recommendations

- Imperative to view entire diaphragm in sagittal plane
 - Most CDHs are posterior so coronal view of anterior diaphragm may be normal
- Higher frequency transducers helpful for differentiating herniated bowel vs. liver
- Look for surrounding membrane (hernia sac)
 - Present in 10-15% of cases and has better prognosis
- All fetuses with CDH need dedicated fetal echo
- Document stomach position
 - From least to most aberrant: Anterior left chest, midposterior left chest, retrocardiac right chest
 - Reflection of degree of liver herniation

Calculations

- All ultrasound ratios can be calculated by entering data in calculators at: Perinatology.com/calculators
- **Lung:head ratio (LHR)**

- Area of lung contralateral to CDH divided by head circumference (all measurements done in mm)
 - Lung area measured at level of 4-chamber view using 1 of 2 methods
 - Tracing method along periphery of visible lung shown to be more accurate and is now preferred method in many protocols
 - Longest diameter method: Calculated by multiplying 2 longest orthogonal cross-sectional lung measurements (overestimates area)
- < 1.0 high mortality and significant morbidity in survivors
- 1.0-1.4 extracorporeal membrane oxygenation (ECMO) usually required
- > 1.4 better outcomes
- LHR has limitations: Not gestational age independent as previously assumed

• Observed/expected LHR

- Corrects for gestational age
- In one study, few survivors if < 25%; 100% survivors if > 45%

• Qualitative lung index (QLI)

- Mathematical equation describing right lung growth; therefore, valid for only left CDH
- 50th percentile for QLI is constant at ~ 1 at 16-32 weeks
- Small lung (< 1st percentile) QLI < 0.6

• MR total fetal lung volume (TFLV)

- **TFLVo (observed)** calculated by summing all traced lung areas (ipsilateral, as well as contralateral) and multiplying by slice thickness
 - In 1 study of 44 patients, 32-34 weeks 90% survival if TFLVo > 40 cc; 35% survival if < 20 cc
 - Mean lung volume for requiring ECMO: 18 cc
 - Mean lung volume for not requiring ECMO: 25 cc
- **TFLVe (expected)** can be calculated by several methods
 - TFLVe: $0.0033 \times \text{gestational age (GA)}^{2.86}$ most commonly used; where GA is in weeks
 - Some studies recommend using fetal body volume to calculate TFLVe
- **Calculate TFLV observed:expected ratio**
 - TFLVo/TFLVe < 0.25 higher mortality
 - Also correlates with need for ECMO and chronic lung disease (CLD)
 - CLD in 74% of children with TFLVo/TFLVe ≤ 25%; 35.8% for ratio of 35%; 9.7% for ratio > 45%

• Percent predicted lung volume

- Thoracic volume and mediastinal volumes calculated using tracing technique
- TFLVe: Thoracic volume - mediastinal volume
- TFLVo/TFLVe < 15% poor prognosis
 - Mean of those who died: 23%; mean of survivors: 36%

• Modified McGoon index

- Used to predict pulmonary hypertension
- Diameters of right + left pulmonary arteries/diameter of descending aorta at level of diaphragm
- < 1.0 correlates with severe pulmonary hypertension at 3 weeks of age

DIFFERENTIAL DIAGNOSIS

Congenital Pulmonary Airway Malformation

- Macrocytic type may imitate stomach and bowel

Prognostic Indicators

Finding	Poor Prognosis	Better Prognosis
Liver position	Liver up	Liver below diaphragm
Lung:head ratio (LHR)	< 1	> 1.4
Observed/expected LHR	< 25%	> 45%
Stomach position	More aberrant (posterior or retrocardiac)	Normal position or anterior chest
Associated anomalies	< 10-15% survival	Isolated defect, normal chromosomes

Syndromes Associated With Congenital Diaphragmatic Hernia

Syndrome	Major Features
Fryns	Congenital diaphragmatic hernia (CDH), coarse facial features, micrognathia, hypertelorism, distal digital hypoplasia, renal and brain anomalies
Cornelia de Lange	Upper limb reduction defects (often severe), micrognathia with protruding upper lip/philtrum, early-onset growth restriction, CDH and other gastrointestinal abnormalities, intellectual impairment, hypertrichosis
Pallister-Killian (Tetrasomy 12p)	CDH, rhizomelic limb shortening, cardiac anomalies, polydactyly, intellectual impairment, abnormal pigmentation
Donnai-Barrow	CDH, omphalocele, hypertelorism, callosal agenesis, inner ear malformation

Associated syndromes reported in 5-10% of cases; always look for additional findings when CDH is present.

PATHOLOGY

General Features

- Genetics
 - < 2% of cases are familial with autosomal dominant, recessive, and X-linked inheritance all described
- Associated abnormalities
 - Present in 40-50% of cases; most commonly cardiac
- Chromosomal abnormalities are common
 - Trisomies 18, 13, 21, tetrasomy 12p
 - All fetuses should be karyotyped

CLINICAL ISSUES

Presentation

- Most common signs/symptoms
 - Cystic chest mass, abnormal cardiac axis

Natural History & Prognosis

- Pulmonary hypoplasia worse than from other chest masses of comparable size
 - Hypoplasia always present to varying degrees
 - Muscular hypertrophy of arterial walls results in pulmonary hypertension and persistent fetal circulation
- In isolated hernia without liver herniation, overall survival is ~ 80%
- Factors that worsen prognosis
 - Presence of other abnormalities
 - With liver herniation survival decreases to ~ 50%
 - Mortality increases as LHR decreases
 - 0-25% reported survival for LHR < 0.8
 - 75% require ECMO for LHR < 1.0
 - Large size, bilateral, diagnosis before 24 weeks
 - Polyhydramnios
- Even CDH infants with good outcomes do not resolve pulmonary hypertension until 1-3 weeks

- Persistence of pulmonary hypertension > 2-3 weeks of life associated with chronic lung disease
 - Significant cause of morbidity among survivors
 - Correlates with liver up, more aberrant stomach position, LHR < 1

Treatment

- Delivery at tertiary care facility essential for all cases
 - Antenatal steroids, surfactant, high-frequency oscillatory ventilation, inhaled nitric oxide, permissive hypercapnia
 - ECMO may be required
- Ex utero intrapartum treatment to ECMO best strategy in poor prognosis group
- Fetoscopic endoluminal tracheal occlusion
 - May be considered before 28 weeks GA in fetuses with poor prognosis
 - Inclusion criteria include liver up, LHR < 1.0, normal karyotype, no other anomalies
 - Balloon inflated between carina and vocal cords
 - Causes retention of fetal lung fluid, which accelerates lung maturation
 - Reverse occlusion at 34 weeks by fetoscopy or ultrasound-guided balloon puncture
 - Potentially deleterious if in place too long
 - Reduces number of type 2 cells and surfactant production

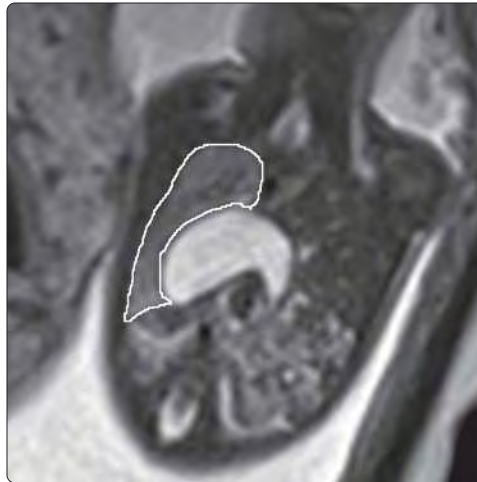
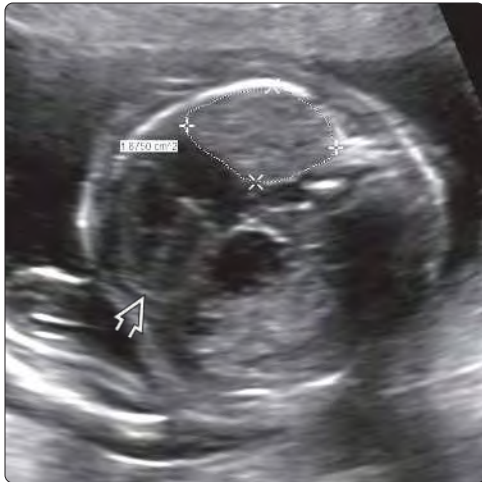DIAGNOSTIC CHECKLIST


Image Interpretation Pearls

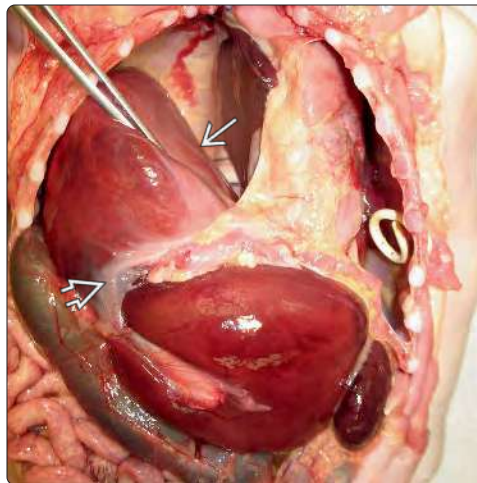
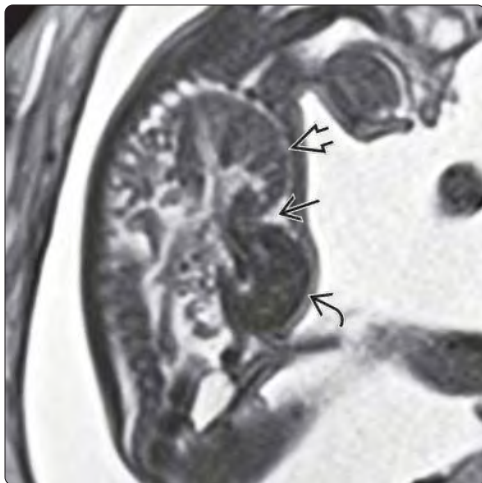- Always use Doppler to evaluate liver position
- Oblique scan plane may result in erroneous diagnosis






SELECTED REFERENCES

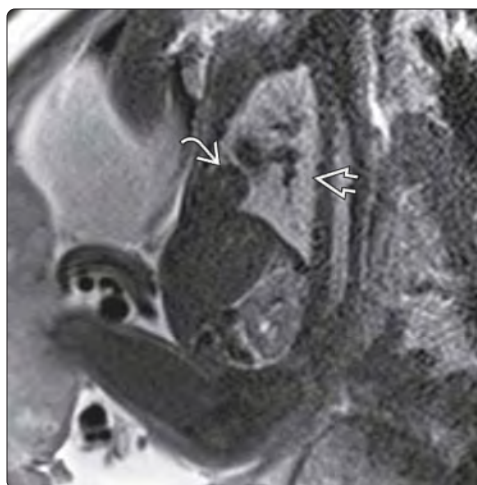
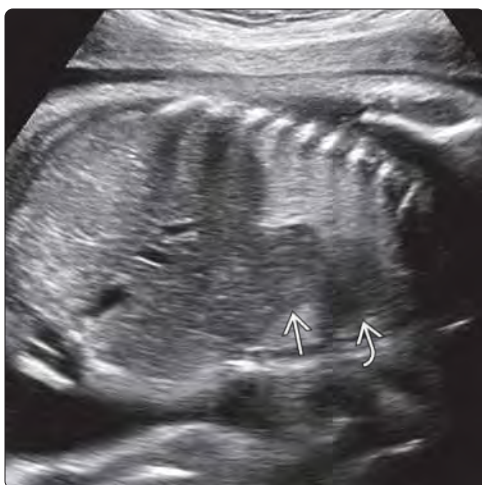1. Lusk LA et al: Fetal ultrasound markers of severity predict resolution of pulmonary hypertension in congenital diaphragmatic hernia. Am J Obstet Gynecol. 213(2):216.e1-8, 2015







(Left) The lung area for the lung:head ratio (LHR) calculation should be taken at the level of the 4-chamber view . It can be calculated by either tracing the area or multiplying the longest diameters (calipers). The tracing method is preferred as the area can be overestimated by as much as 45% using the longest diameters. This would erroneously make the LHR better than it truly is. (Right) A total lung volume can be calculated on MR by summing the areas on consecutive images and multiplying by the slice thickness.



(Left) Sagittal MR of a right-sided CDH shows a waist  created by a small portion of the intact diaphragm. The herniated portion continues to grow in a confined space, which can constrict blood supply and make it more difficult to reduce at surgery (liver lock). Note the herniated liver  is slightly higher in signal compared to the abdominal portion  suggesting edema. (Right) Autopsy shows the band of the remaining diaphragm . Note the somewhat paler appearance to the herniated portion of the liver .



(Left) Coronal oblique US through the anterior portion of the diaphragm shows a focal bulge of liver . The heart  is displaced slightly superiorly, but the axis was normal on the standard 4-chamber view. (Right) MR confirms the US findings and shows a herniated liver  through a small anterior foramen of Morgagni. These are rare in fetuses and are an exception to the "liver up is bad" rule. Note that the herniated liver is having little effect on the lung .

KEY FACTS

TERMINOLOGY

- CPAM newer terminology for congenital cystic adenomatoid malformation (CCAM)

IMAGING

- Variable appearance from solid-appearing (microcystic) to complex cystic mass (macrocytic)
 - Macrocytic: 1 or more cysts \geq 5 mm
 - Microcystic: Cysts $<$ 5 mm
- No side predilection, more common at lung bases
- Vascular supply from pulmonary artery
- Calculate CPAM volume ratio (CVR)
 - CPAM volume/head circumference
 - CVR $>$ 1.6 indicates increased risk of developing hydrops and fetal demise
- Monitor frequently until growth stabilizes

TOP DIFFERENTIAL DIAGNOSES

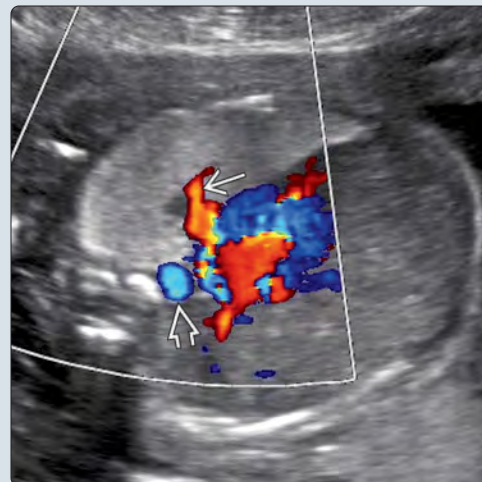
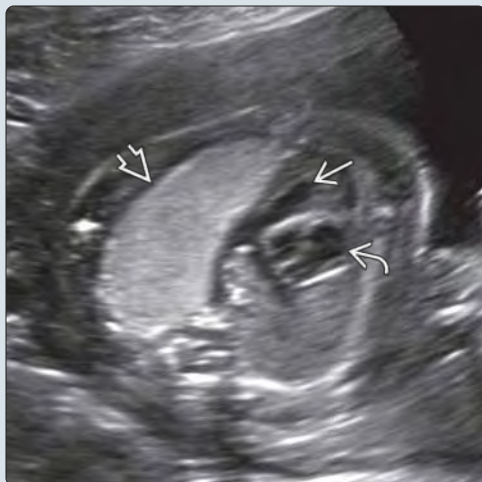
- Bronchopulmonary sequestration (BPS)

- Hybrid lesion (CPAM + BPS)
- Congenital diaphragmatic hernia

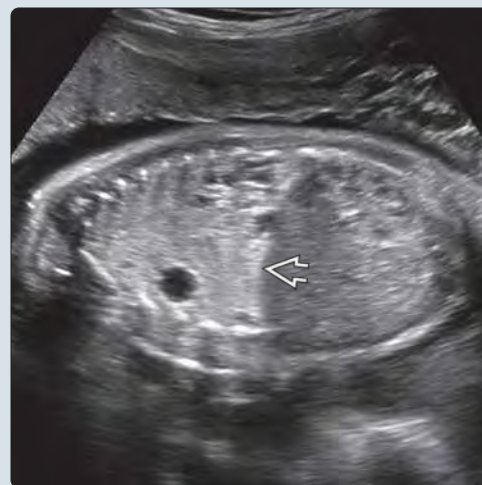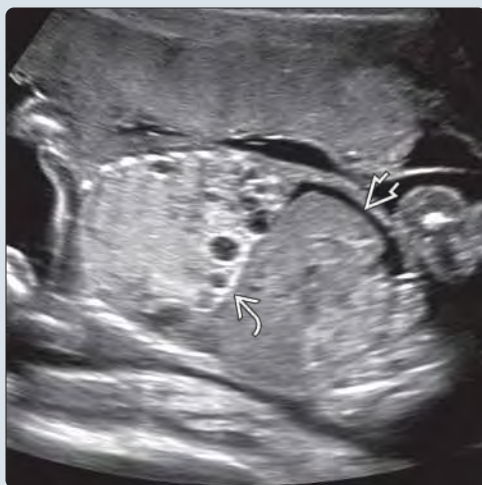CLINICAL ISSUES

- Stable lesions may be watched without intervention
 - Often decrease in size or completely regress ("disappearing" CPAM)
- Microcystic CPAMs often stabilize and begin regressing at 26-28 weeks but are more prone to cause hydrops
- Macrocytic CPAM may grow throughout pregnancy
- Betamethasone administration for high-risk lesions (CVR $>$ 1.6 &/or hydrops)
- Hydrops significantly impacts prognosis
 - Near 100% mortality with hydrops if untreated
 - Mortality has declined to 20-47% with betamethasone administration
- Postnatal work-up of all lesions even if regressed in utero
 - Postnatal resection generally felt warranted even in asymptomatic individuals

(Left) Axial US of the fetal chest at the level of the right ventricular outflow tract shows a large, uniformly echogenic lung mass having mass effect with shift of the heart to the right. The primary differential is a congenital pulmonary airway malformation (CPAM) vs. a sequestration, so next is evaluation of the blood supply. (Right) Color Doppler US just below the prior image in the same patient shows a feeding vessel from the pulmonary artery, not the aorta, confirming that this is a CPAM.



(Left) Sagittal US of a CPAM at 20 weeks shows a mixed cystic and solid mass filling the right hemithorax. The diaphragm is flattened and partially everted. More importantly, there is ascites. Developing hydrops portends a very poor prognosis, so the patient was treated with betamethasone. (Right) The same fetus 4 weeks later shows improvement with resolution of the ascites and a normal domed contour of the diaphragm. If hydrops is progressive despite treatment, consider referral to a fetal surgery center.



TERMINOLOGY

Abbreviations

- Congenital pulmonary airway malformation (CPAM)
 - Newer terminology reflects developmental disorder of pulmonary airway morphogenesis

Synonyms

- Congenital cystic adenomatoid malformation
 - Older name that reflects cystic and adenomatous histologic components in many, but not all, of these masses

IMAGING

General Features

- Best diagnostic clue
 - Solid or cystic lung mass with arterial supply from pulmonary artery
- Size
 - Variable
 - Usually contained within single lobe
 - Can be massive
 - Heart is often displaced to opposite chest wall
- Morphology
 - Varies from solid-appearing (microcystic) to complex cystic mass (macrocytic)
 - 95% are unilateral and affect only 1 lobe
 - No side predilection
 - More common at lung bases
- May spontaneously regress
 - "Disappearing" CPAM

Ultrasonographic Findings

- **Macrocytic CPAM**
 - 1 or more cysts > 5 mm
 - Often multiple cysts of varying sizes
 - May have single large cyst
 - Borders poorly defined
- **Microcystic CPAM**
 - Cysts < 5 mm
 - Uniformly echogenic
 - Well-defined masses
- **Color Doppler**
 - Vascular supply from pulmonary artery
 - Venous drainage to pulmonary vein
 - More difficult to see
- **Hydrops**
 - Most important predictor of outcome
 - Occurs in < 10%
 - Dismal prognosis if untreated
- **Polyhydramnios**
 - May result from compression of esophagus
 - Associated with hydrops

MR Findings

- T2WI
 - Microcystic: High signal intensity mass
 - Macrocytic: Discrete cysts discernible
- Vascular supply better seen with Doppler

Imaging Recommendations

- Use color Doppler to identify feeding vessel
- Calculate CPAM volume ratio (CVR)
 - CPAM volume calculated by measuring all 3 dimensions
 - Length x width x height x 0.52
 - CPAM volume is then divided by head circumference
 - CVR can be calculated for you by entering data at perinatology.com/calculators
 - CVR > 1.6 indicates increased risk of developing hydrops and fetal demise
 - Occurs in 80% of cases
- Monitor weekly until growth stabilizes
 - More often if signs of developing hydrops
 - Greatest growth 20-26 weeks for microcystic CPAM
- If regression or no change, can increase time interval between scans

DIFFERENTIAL DIAGNOSIS

Bronchopulmonary Sequestration (BPS)

- Grayscale appearance indistinguishable from microcystic CPAM
- Feeding vessel from aorta
- 90% left-sided
- Ipsilateral pleural effusion highly suggestive

Hybrid Lesion (CPAM + BPS)

- Consider when systemic vessel supplies cystic lung mass
- Histology shows both lesions
- Dual histology has been reported in as many as 50% of echogenic lung mass cases

Congenital Diaphragmatic Hernia

- Absent normal, fluid-filled stomach
- Abdominal circumference small
- Peristalsis is pathognomonic

Bronchial Obstruction

- Uniformly echogenic
- More commonly upper lobes
 - Left upper lobe > right middle lobe > right upper lobe > lower lobes
- May be either primary bronchial abnormality or plugging with viscous secretions
 - Can spontaneously resolve
- Manifests as congenital lobar overinflation postnatally

Congenital High Airway Obstruction Sequence

- May be confused for bilateral CPAM
- Symmetric, bilateral lung enlargement
- Inversion of diaphragm
- Fluid-filled trachea and bronchi, massive ascites

Other Cystic Masses

- Bronchogenic cyst, esophageal duplication cyst, neurenteric cyst
 - Thoracic bony abnormality usually present with neurenteric cysts
- More often associated with mediastinum than lung

Teratoma

- Solid and cystic components

- Calcifications most specific finding
- Mediastinal or pericardial

PATHOLOGY

General Features

- Genetics
 - No genetic cause
 - No recurrence risk
- Associated abnormalities
 - Seen in 3-12%
 - Other lung malformations, including sequestrations, and renal anomalies most common

Staging, Grading, & Classification

- Pathologic staging system (types 0-4) based on cyst size, epithelial components, and presence of solid components
- In utero sonographic classification generally divides into macrocystic and microcystic
 - Much more practical for management decisions
 - Macrocystic: 1 or more cysts \geq 5 mm
 - Microcystic: Cysts < 5 mm
 - Solid-appearing echogenic mass

CLINICAL ISSUES

Presentation

- Usually incidental finding
 - Cystic or echogenic lung mass
- Patient may be large-for-dates if polyhydramnios is present

Demographics

- Epidemiology
 - Most common fetal lung mass
 - 75% of all lesions

Natural History & Prognosis

- **Prenatal**
 - Majority remain stable or regress in utero
 - Excellent prognosis without hydrops even if large at diagnosis
 - Hydrops significantly impacts prognosis
 - Near 100% mortality with hydrops if untreated
 - Mortality has now declined to 20-47% with betamethasone administration
 - Features increasing risk of hydrops
 - CVR > 1.6
 - Dominant large cyst
 - Microcystic CPAMs often stabilize and begin regressing at 26-28 weeks but are more prone to cause hydrops
 - Macrocystic CPAM may grow throughout pregnancy
- **Postnatal**
 - Risk for infection
 - Small risk for developing malignancy
 - Infants and young children: Pleuropulmonary blastoma, rhabdomyosarcoma, myxosarcoma
 - Older children and adults: Bronchoalveolar carcinoma

Treatment

- Stable lesions may be watched without intervention
- Betamethasone administration for high-risk lesions (CVR > 1.6 &/or hydrops)

- Has been shown to decrease growth of CPAM and reverse hydrops
- Microcystic lesions more responsive than macrocystic lesions
- Hydrops > 32 weeks
 - Early delivery
 - Immediate resection
 - May be resected during delivery using ex utero intrapartum treatment procedure
- Hydrops < 32 weeks
 - Macrocystic CPAM
 - Cyst drainage: Temporizing measure only, fluid will reaccumulate
 - Thoracoamniotic shunt
 - Microcystic CPAM
 - Betamethasone 1st-line therapy
 - ◻ Once daily intramuscular injection of 12.5 mg for 2 consecutive days
 - ◻ May require multiple courses
 - In utero resection being performed in specialized fetal surgery centers
 - ◻ Rigid criteria including normal karyotype and no other anomalies
 - ◻ Survival rates reported in 50-78%
- Delivery at tertiary care facility
 - At risk for neonatal complications, including air-trapping and pneumothorax
 - Large lesions may require extracorporeal membrane oxygenation
- Postnatal work-up of all lesions even if regressed in utero
 - Contrast-enhanced CT (CXR may not show lesion)
- Postnatal resection generally felt warranted even in asymptomatic individuals
 - Most feel risk of infection and malignancy warrants resection in all cases
 - Elective resection at 1 month or older
 - Risk of anesthesia decreases after 4 weeks of age
 - Early resection maximizes compensatory lung growth

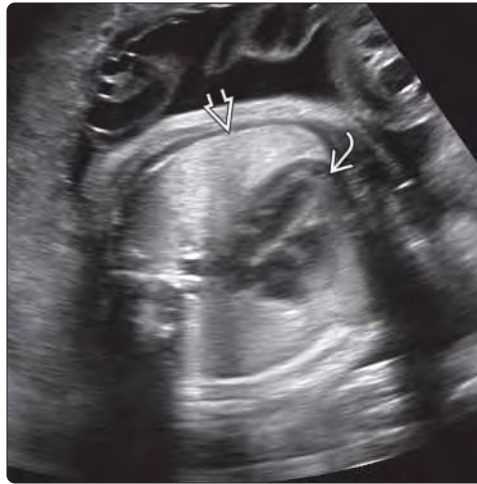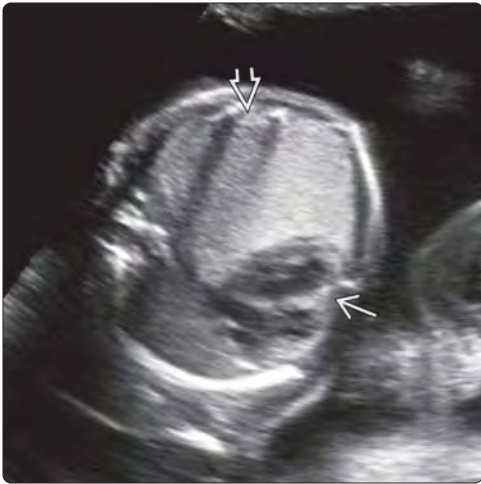
DIAGNOSTIC CHECKLIST

Image Interpretation Pearls

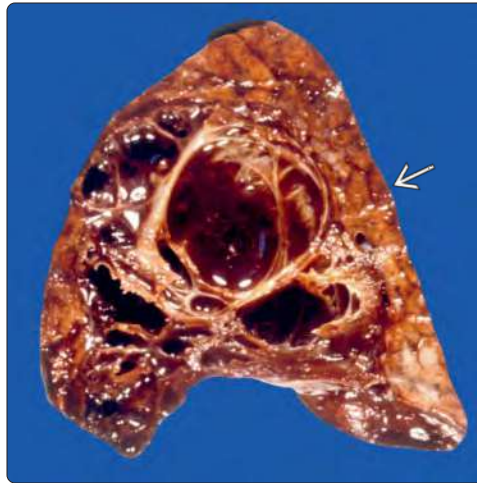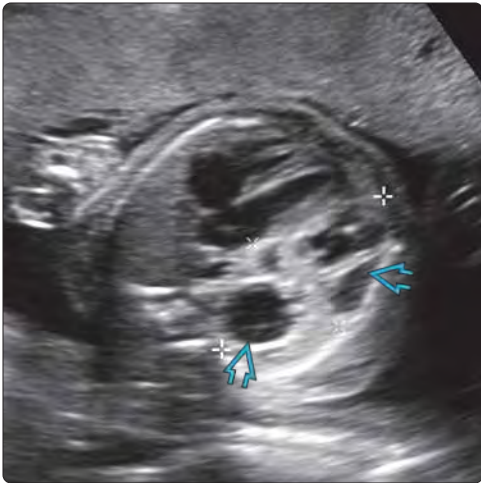- Development of hydrops is single most important predictor of outcome

SELECTED REFERENCES

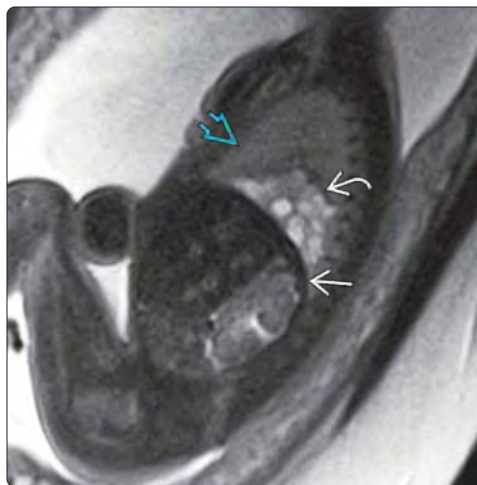
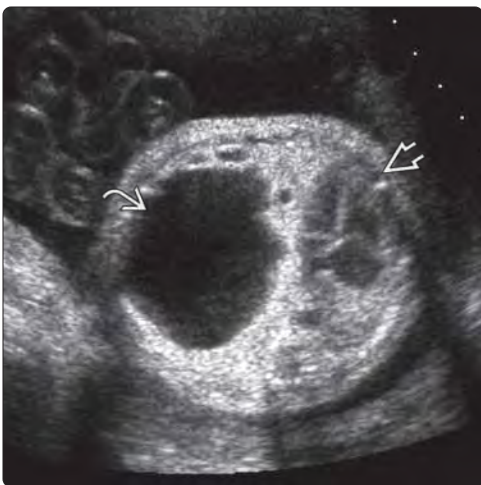
1. Derderian SC et al: Favorable outcomes in high-risk congenital pulmonary airway malformations treated with multiple courses of maternal betamethasone. *J Pediatr Surg.* 50(4):515-8, 2015
2. Fowler DJ et al: The pathology of congenital lung lesions. *Semin Pediatr Surg.* 24(4):176-82, 2015
3. Kunisaki SM et al: Vanishing fetal lung malformations: Prenatal sonographic characteristics and postnatal outcomes. *J Pediatr Surg.* 50(6):978-82, 2015
4. Pacharn P et al: Congenital lung lesions: prenatal MRI and postnatal findings. *Pediatr Radiol.* 43(9):1136-43, 2013
5. Gupta K et al: Extralobar sequestration associated with congenital pulmonary airway malformation (CPAM), type I: an autopsy report. *Fetal Pediatr Pathol.* 30(3):167-72, 2011
6. Adzick NS: Open fetal surgery for life-threatening fetal anomalies. *Semin Fetal Neonatal Med.* 15(1):1-8, 2010



(Left) Axial US through the chest at 24 weeks shows a large, echogenic, left lung mass pushing the heart against the right chest wall. This was monitored closely for development of hydrops, but on subsequent scans, it became less obvious. **(Right)** The same fetus at 32 weeks shows a much more normal cardiac axis with the CPAM being only slightly more echogenic than the normal lung. Regression in utero is common and has been termed "disappearing" CPAM.



(Left) This CPAM (cursors) has several macroscopic cysts. On occasion there can hybrid lesions (CPAM + sequestration), which should be considered if a cystic lung mass is supplied by the aorta. **(Right)** Gross pathology of a resected lower lobe in a different, but similar, case of macrocystic CPAM demonstrates multiple irregular cysts with only a small rim of normal remaining lung parenchyma.



(Left) Transverse US of a macrocystic CPAM shows a single large cyst displacing the heart. The primary differential for this appearance is a congenital diaphragmatic hernia. It is important to document an intact diaphragm and normal position of the stomach. If the fetus becomes hydropic, a thoracoamniotic shunt could be placed. **(Right)** Sagittal T2 MR of a CPAM shows a cystic mass at the left lung base. It is higher in signal intensity than the adjacent lung. The diaphragm is well seen.

KEY FACTS

TERMINOLOGY

- Bronchopulmonary tissue that does not connect to tracheobronchial tree or pulmonary arteries

IMAGING

- Extralobar sequestration is subtype of BPS found in fetus
 - 90% left-sided
 - 85-90% supradiaphragmatic
 - 10-15% subdiaphragmatic
- Prominent feeding vessel from aorta most important imaging finding
- Intrathoracic BPS
 - Homogeneously echogenic, triangular lesion adjacent to diaphragm
 - Unilateral pleural effusion in 6-10%
 - May cause tension hydrothorax
- Abdominal BPS
 - Stomach is displaced anteriorly by echogenic mass
 - Separate from adrenal gland

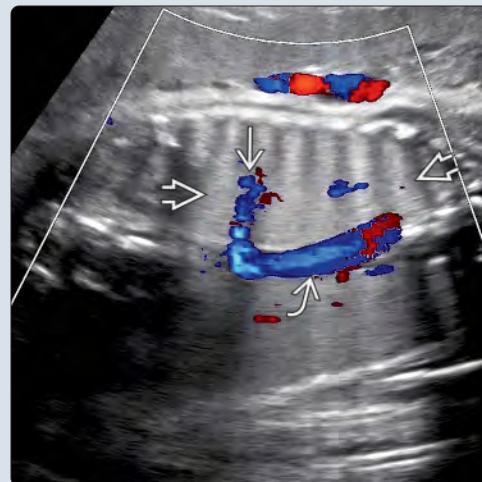
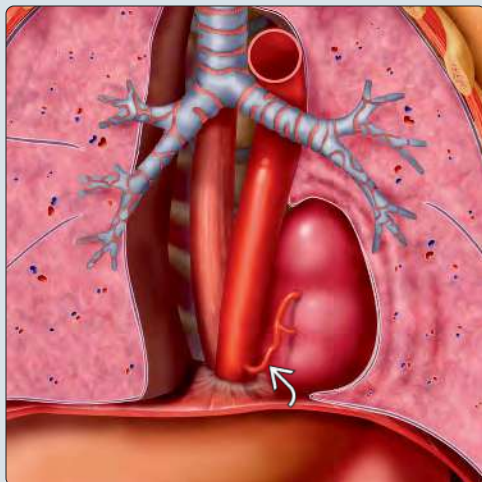
TOP DIFFERENTIAL DIAGNOSES

- Congenital pulmonary airway malformation (CPAM)
- Hybrid lesion (BPS + CPAM)
 - Consider when systemic vessel supplies cystic lung mass
- Neuroblastoma
 - Most common differential consideration for subdiaphragmatic BPS
 - More often on right
 - Often cystic with no feeding vessel

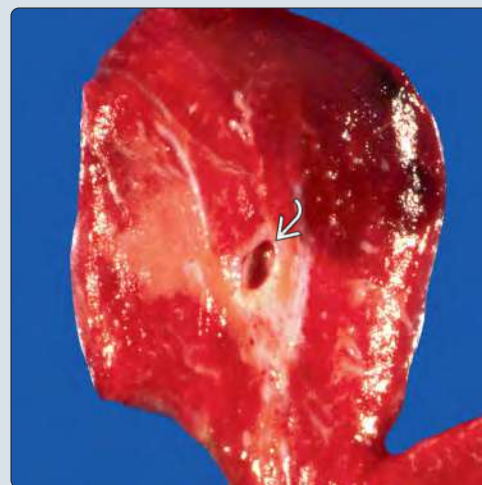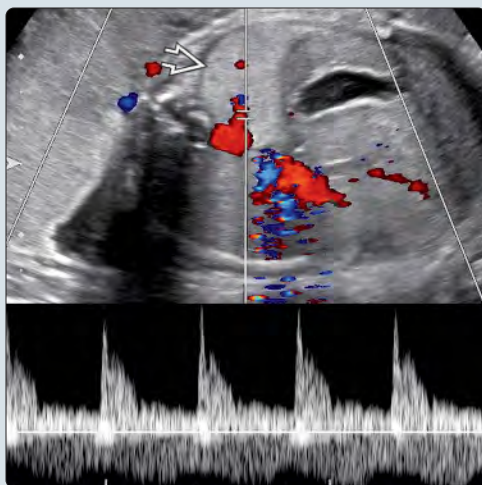
CLINICAL ISSUES

- 10-20% of fetal lung masses
- Associated anomalies reported in up to 50%
 - BPS is most commonly associated with congenital diaphragmatic hernia but is often missed
- Excellent prognosis when isolated finding
 - 50-75% regress in utero
- Hydrops serious complication with near 100% mortality

(Left) Graphic shows an extralobar sequestration at the left lung base. The vascular supply is from the aorta. It is covered with its own pleural investment, and there is no communication with the tracheobronchial tree. (Right) A coronal US of the chest shows a large, left-sided mass that was only slightly more echogenic than the lung. Color Doppler is extremely helpful in situations like this as the feeding vessel is usually easy to find. Note the aorta is being bowed to the right by the mass.



(Left) The same vessel is viewed in cross section as it enters the sequestration. The waveform tracing is identical to that of the aorta. (Right) Photograph of the cut surface of a resected sequestration demonstrates a solid mass with a smooth pleural covering. A dominant feeding vessel is seen. This arises from the aorta, or other systemic vessel, and is usually readily identifiable by color Doppler.



TERMINOLOGY

Abbreviations

- Bronchopulmonary sequestration (BPS)

Definitions

- Bronchopulmonary tissue that does not connect to tracheobronchial tree or pulmonary arteries
- Extralobar sequestration is subtype of BPS found in fetus
 - Fetal intralobar sequestration extremely rare

IMAGING

General Features

- Best diagnostic clue
 - Solid lung mass with arterial supply from aorta
- Location
 - 85-90% supradiaphragmatic
 - 10-15% subdiaphragmatic
 - 90% left-sided
- Size
 - Generally small to moderate size
 - Rarely can fill entire chest
- Morphology
 - Pleural investment results in well-marginated mass
 - Triangular or lobar shape

Ultrasonographic Findings

- **Intrathoracic BPS**
 - Homogeneously echogenic
 - Can appear similar to normal lung, especially when regressing
 - Typically left lung base
 - Between lower lobe and diaphragm
 - Unilateral pleural effusion in 6-10%
 - May cause tension hydrothorax
 - Cysts may be seen
 - More common in hybrid lesions
 - Hybrid lesions contain histologic elements of both BPS and congenital pulmonary airway malformation (CPAM)
 - Spontaneous regression common
- **Abdominal BPS**
 - Also typically left sided
 - Stomach is displaced anteriorly by echogenic mass
 - May communicate with stomach
 - Separate from adrenal gland
- Color Doppler
 - Prominent feeding vessel from aorta
 - May have more than 1
 - Occasionally arises from celiac axis
 - Venous drainage
 - Azygous or inferior vena cava
 - Some may partially drain into pulmonary veins
 - Often difficult to visualize
- Pulsed Doppler
 - Wave form of feeding vessel similar to aortic waveform
 - Peak systolic velocity decreases in regressing lesions

MR Findings

- T2WI

- Well-defined, high-signal mass
 - Higher signal than normal lung
- Feeding vessel not consistently visualized
- Helpful in selected cases
 - When coexistent abnormalities are present
 - Especially congenital diaphragmatic hernia
 - Subdiaphragmatic lesion
 - Uniform high signal suggestive of BPS rather than neuroblastoma

Imaging Recommendations

- Use color Doppler to identify feeding vessel
- Close follow-up of lesion
 - Watch for development of pleural effusion or hydrops
 - May spontaneously regress
- Careful evaluation for other anomalies
 - Present in up to 50%
 - Congenital diaphragmatic hernia (CDH) most common
 - BPS often missed when coexistent CDH present
 - Cardiac malformations
 - Other pulmonary anomalies
 - Bronchogenic cyst
 - Vascular malformations
 - CPAM
 - Gastrointestinal anomalies
 - Tracheoesophageal fistula
 - Duplication cysts
 - Neurenteric lesions
 - Skeletal anomalies
 - Vertebral anomalies
 - Pectus excavatum

DIFFERENTIAL DIAGNOSIS

Chest Mass

- **CPAM**
 - Newer terminology for congenital cystic adenomatoid malformation
 - Microcystic type has similar grayscale appearance
 - Feeding vessel from pulmonary artery
 - Pulmonary venous drainage
 - May occur on right or left
- **Hybrid lesion (BPS + CPAM)**
 - Consider when systemic vessel supplies cystic lung mass
 - Dual histology has been reported in as many as 50% of echogenic lung mass cases
- **Teratoma**
 - Mediastinal or pericardial
 - Calcifications most specific finding
 - Pleural or pericardial effusions
 - No aortic arterial feeder
- **Bronchial stenosis/atresia**
 - Localized lung overgrowth in atretic bronchial segment
 - Similar developmental physiology to congenital high airway obstruction
 - Uniformly echogenic
 - More commonly upper lobe
 - Normal vasculature

Suprarenal Mass

- **Neuroblastoma**

- More often on right
- Often cystic
- No feeding vessel
- Occurs in adrenal gland, therefore no normal adrenal gland visible
- Dose not present until 3rd trimester
- **Adrenal hemorrhage**
 - Uncommon in utero
 - Blood products evolve, becoming more hypoechoic and involuting over time

PATHOLOGY

General Features

- Etiology
 - Embryology
 - Hypothesized early insult when tracheobronchial tree splits from primitive foregut
 - Subsequent ectopic budding of tracheobronchial tree
 - Explains high association with enteric anomalies
- Genetics
 - Sporadic inheritance
 - No recurrence risk
- Associated abnormalities
 - Seen in up to 50%

Gross Pathologic & Surgical Features

- Pathologically 2 types
 - Extralobar sequestration
 - Type seen in fetus
 - Own pleural investment
 - Drains to systemic vessel
 - Histology: Dilated bronchioles, alveoli, and subpleural lymphatics
 - Intralobar sequestration
 - No pleural investment
 - Drains to pulmonary vein
 - May be acquired
 - Extremely rare in utero or infancy
 - > 50% present over 20 years of age
 - May result from recurrent infection
 - Normal blood supply may be compromised with parasitization of systemic vessels
 - Histology: Chronic inflammation and fibrosis

Microscopic Features

- Up to 50% of BPS have histologic features of type 2 CPAM

CLINICAL ISSUES

Presentation

- Usually incidental finding
 - Seen as early as 16 weeks
- Unilateral pleural effusion

Demographics

- Epidemiology
 - 10-20% of fetal lung masses
 - 2nd most common mass after CPAM
 - M:F = 3-4:1

Natural History & Prognosis

- Excellent prognosis when isolated finding
 - 50-75% regress in utero
- Poorer prognosis categories
 - Largely determined by severity of associated abnormalities
 - Development of hydrops
 - Mortality approaching 100% for large, echogenic lung mass (BPS and microcystic CPAM) with hydrops
- May be complicated by tension hydrothorax
 - Proposed mechanisms
 - Torsion of sequestered segment on narrow vascular pedicle
 - May be intermittent "rocking" back and forth on pedicle
 - Leakage from ectatic lymphatics
 - May progress to generalized hydrops from cardiovascular compromise
- Postnatal
 - Most are asymptomatic
 - May have respiratory distress or cyanosis
 - May present with associated abnormality

Treatment

- Prenatal
 - Usually none
 - Intervention for hydrops
 - Steroids and delivery
 - Drainage or thoracoamniotic shunt for tension hydrothorax
 - Fetal surgery and US-guided laser coagulation has been reported for cases complicated by hydrops, with variable results
- Postnatal
 - Contrast-enhanced CT or MR should be done in all cases
 - Chest radiograph may miss lesion
 - Embolization of feeding vessel
 - Surgical ligation and resection
 - Resection may not be necessary for regressed lesions in asymptomatic individuals

DIAGNOSTIC CHECKLIST

Consider

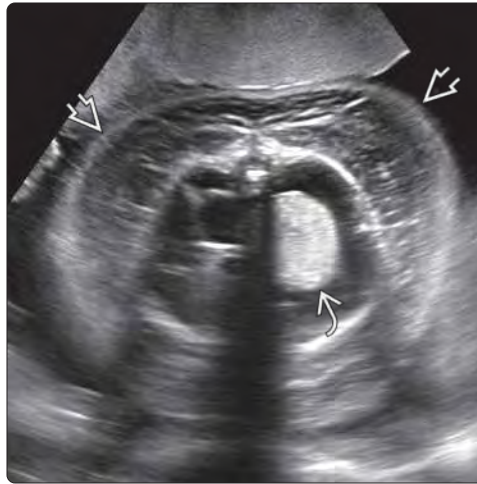
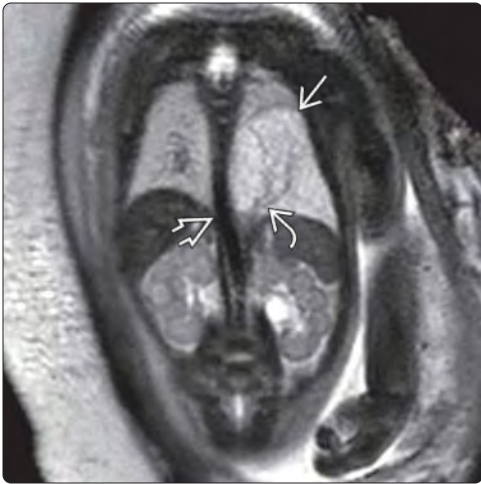
- When there is lung mass with unilateral pleural effusion
- Always look for BPS when evaluating CDH

Image Interpretation Pearls

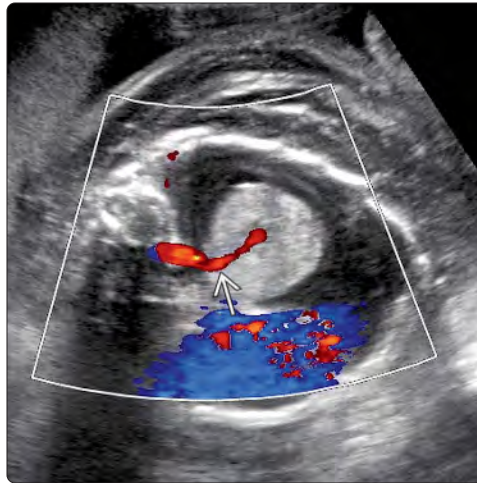
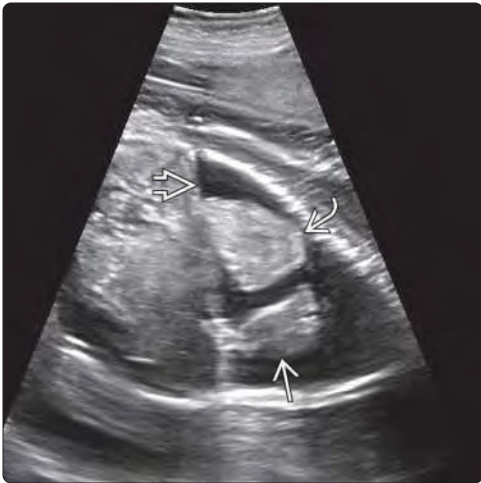- Doppler evaluation essential for making diagnosis
- May spontaneously regress

SELECTED REFERENCES

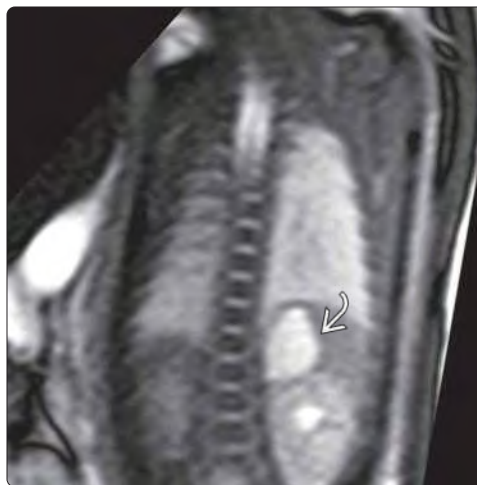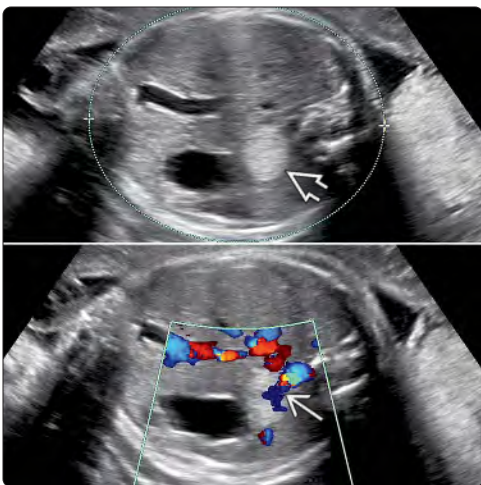
1. Macardle CA et al: Management of perinatal lung malformations. *Minerva Ginecol.* 67(1):81-94, 2015
2. Maki E et al: Imaging and differential diagnosis of suprarenal masses in the fetus. *J Ultrasound Med.* 33(5):895-904, 2014
3. Nunes C et al: Fetal bronchopulmonary malformations. *J Matern Fetal Neonatal Med.* 1-5, 2014
4. Zhang H et al: Retrospective study of prenatal diagnosed pulmonary sequestration. *Pediatr Surg Int.* 30(1):47-53, 2014



(Left) Coronal T2 MR of a 31-week fetus shows a large, left lower lobe hyperintense mass. It is exerting mass effect displacing the left upper lobe and aorta. Flow voids are seen extending into the mass from the aorta. MR is usually not necessary to make the diagnosis but can be helpful if there are associated abnormalities. (From *DI3:Pediatrics*.) (Right) Axial US through the chest of a 3rd-trimester fetus who presented with hydrops shows dramatic skin thickening. An echogenic mass is seen surrounded by pleural fluid.



(Left) A sagittal US in the same case shows a flattened diaphragm, indicating a tension hydrothorax. The mass is triangular and hyperechoic, with the normal lung floating posteriorly. (Right) An oblique axial color Doppler US shows a feeding vessel from the aorta consistent with a BPS. The mother was given steroids and the fetus delivered. The BPS was immediately resected with the surgeon describing it as twisting on a string. Always consider torsion in the setting of a developing tension hydrothorax.



(Left) Abdominal circumference plane shows a left-sided echogenic mass posterior to the stomach. Color Doppler shows a large feeding vessel off the aorta. In addition to looking for the feeding vessel, scan to make sure it's separate from adrenal gland. Both of these features help to differentiate a subdiaphragmatic BPS from a neuroblastoma. (Right) Coronal fetal MR shows a high-signal suprarenal mass, which proved to be a BPS. Approximately 10-15% of sequestrations are subdiaphragmatic.

KEY FACTS

TERMINOLOGY

- Bronchogenic cysts are part of family of foregut duplication cysts

IMAGING

- May be mediastinal or in lung parenchyma
 - Mediastinal more common
 - Pericarinal most common location
 - Majority in parenchyma occur in medial 1/3 of lungs
- Unilocular, simple cyst
- Almost always solitary
- May contain echogenic debris and be difficult to differentiate from surrounding tissues
- May exert mass effect and compress esophagus or adjacent bronchus, especially if large
 - Polyhydramnios or hydrops if significant compression of mediastinal structures
- No flow on color Doppler

TOP DIFFERENTIAL DIAGNOSES

- Congenital pulmonary airway malformation (CPAM)
 - Usually more complex and multilocular, but unilocular CPAM could have similar appearance
- Esophageal duplication cyst
 - Can be round or tubular
 - Always located in posterior mediastinum
- Neurenteric cyst
 - Associated with spinal anomalies

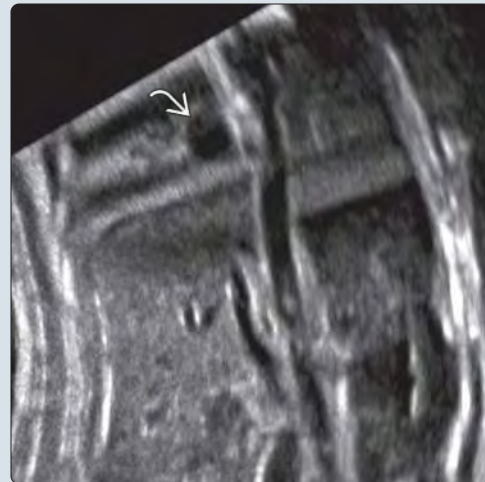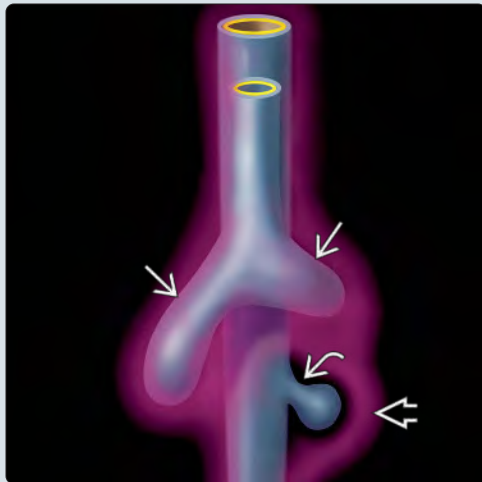
PATHOLOGY

- Supernumerary or anomalous foregut bud occurring between days 26-40 of gestation

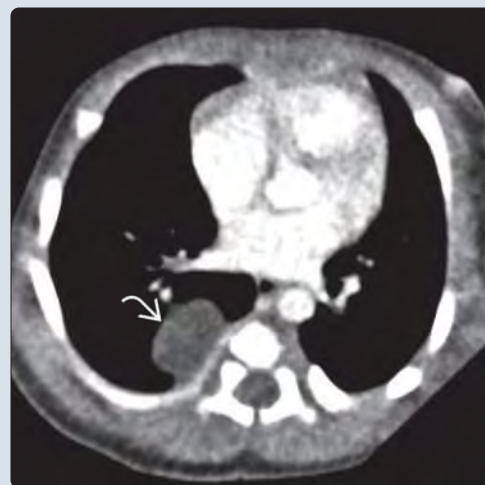
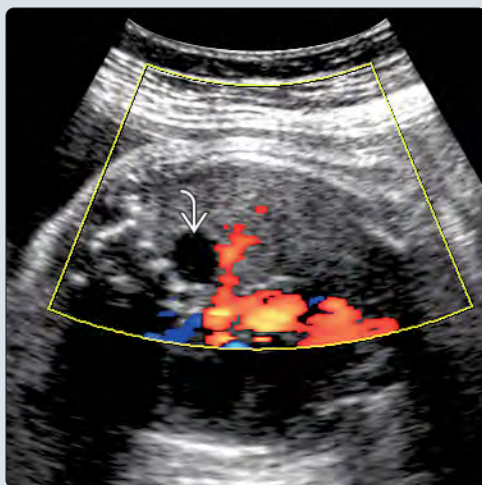
CLINICAL ISSUES

- Usually incidental finding in fetus
- Surgical resection recommended postnatally

(Left) Graphic shows the proposed pathogenesis of a bronchogenic cyst. An anomalous supernumerary bud from the primitive foregut does not come in contact with the surrounding primitive mesenchyme like the normally developing bronchi. The original communication with the foregut typically involutes, resulting in a blind-ending pouch or cyst. **(Right)** Coronal ultrasound shows a centrally located unilocular cystic lesion just above the diaphragm.



(Left) Transverse color Doppler ultrasound in the same case shows no flow within this cystic lesion. Because of the lesion's close proximity to the spine, a neurenteric cyst was also considered in the differential, but no spinal anomalies were identified. **(Right)** Axial contrast-enhanced CT after delivery shows a simple unilocular cyst. The adjacent vertebral body was normal. This was resected at 6 months of age and proved to be a bronchogenic cyst.



TERMINOLOGY

Definitions

- Bronchogenic cysts are part of family of foregut duplication cysts
 - Bronchogenic cysts, enteric cysts, neurenteric cysts

IMAGING

General Features

- Location
 - May be mediastinal or in lung parenchyma
 - Mediastinal more common
 - Majority in middle mediastinum
 - Typically paratracheal, carinal, or hilar
 - Pericarinal most common
 - Pulmonary location
 - Majority in medial 1/3 of lungs
 - More frequent in lower lobes
 - Rare occurrence in thymus, diaphragm, neck, pericardium, and retroperitoneum
- Size
 - Variable but usually small

Ultrasonographic Findings

- Unilocular, simple cyst
 - Only rarely multilocular
- Almost always solitary
- May contain echogenic debris and be difficult to differentiate from surrounding tissues
- May exert mass effect and compress esophagus or adjacent bronchus, especially if large
 - May develop polyhydramnios if significant esophageal obstruction
 - Bronchial obstruction causes distended, echogenic lung segment distal to point of obstruction secondary to retained fetal lung fluid
 - May mimic echogenic lung mass
- No flow on color Doppler

MR Findings

- T1WI low signal intensity
- T2WI high signal intensity

Imaging Recommendations

- Protocol advice
 - Look carefully for spinal abnormality
 - If present, more likely to be neurenteric cyst

DIFFERENTIAL DIAGNOSIS

Congenital Pulmonary Airway Malformation

- Usually more complex and multilocular, but unilocular congenital pulmonary airway malformation (CPAM) could have similar appearance
- Much more common

Esophageal Duplication Cyst

- Can be round or tubular
- Always located in posterior mediastinum
- May extend below diaphragm

Neurenteric Cyst

- Originate from incomplete separation of foregut from notochord
- Associated with spinal anomalies
 - Hemivertebrae, butterfly vertebrae, missing vertebrae, thoracic meningocele
- Cyst communicates with spinal canal
- Often has bilobed appearance

PATHOLOGY

General Features

- Etiology
 - Supernumerary or anomalous foregut bud occurring between days 26-40 of gestation
 - Anomalous bud does not come in contact with surrounding primitive mesenchyme; therefore, fails to induce formation of lung parenchyma
 - Early budding results in mediastinal cysts
 - Later budding results in lung parenchymal cysts
 - Original communication with foregut typically involutes, resulting in blind-ending pouch or cyst

Microscopic Features

- Because anomalous bud develops in same way as primitive central airways, its wall contains bronchial components; hence term bronchogenic
- Fluid is proteinaceous and often thick or gelatinous in consistency

CLINICAL ISSUES

Presentation

- Most common signs/symptoms
 - Usually incidental finding in fetus

Natural History & Prognosis

- Generally of no effect on pregnancy
- Rarely, large cysts may have significant mass effect, causing compression of mediastinal structures and resulting in hydrops
 - Ex utero intrapartum treatment (EXIT) procedure has been performed for airway compromise
- Infants may present with respiratory distress or feeding difficulties
- Older children may present with infection
- May remain asymptomatic and be discovered incidentally later in life

Treatment

- In utero aspiration reported for large cysts
- Surgical resection recommended postnatally

SELECTED REFERENCES

1. Chatterjee D et al: Ex utero intrapartum treatment to resection of a bronchogenic cyst causing airway compression. *Fetal Diagn Ther.* 35(2):137-40, 2014
2. Maurin S et al: Bronchogenic cyst: clinical course from antenatal diagnosis to postnatal thoracoscopic resection. *J Minim Access Surg.* 9(1):25-8, 2013
3. Rios LT et al: Prenatal diagnosis and postnatal findings of bronchogenic cyst. *Case Rep Pulmonol.* 2013:483864, 2013
4. Bayar UO et al: Management of fetal bronchogenic lung cysts: a case report and short review of literature. *Case Report Med.* 2010:751423, 2010

KEY FACTS

TERMINOLOGY

- High airway obstruction (tracheal or laryngeal) caused by atresia, stenosis, or web

IMAGING

- Bilaterally enlarged, echogenic lungs
- Heart appears small and midline in position
- Dilated, fluid-filled trachea and bronchi distal to point of obstruction
- Diaphragm flattened or everted
- Ascites common and may be massive
 - High intrathoracic pressures obstructs lymphatic and venous return
- Coronal color Doppler ultrasound of neck focused on larynx
 - Look for movement of fluid during breathing
 - Opening and closing of vocal cords suggests less severe obstruction
- Associated anomalies in 50% of cases

TOP DIFFERENTIAL DIAGNOSES

- Bilateral congenital pulmonary airway malformations

PATHOLOGY

- Obstruction causes retention of fetal lung fluid and subsequent overdevelopment
 - Lungs more mature than expected for gestational age

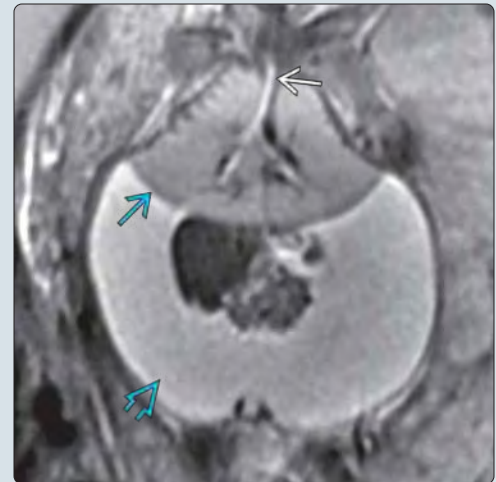
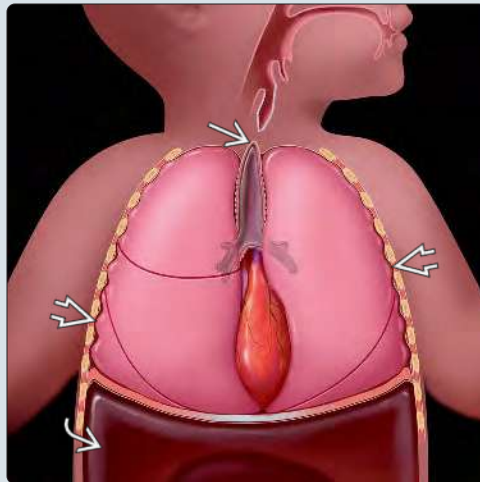
CLINICAL ISSUES

- Planning for delivery is essential
 - EXIT procedure (ex utero intrapartum treatment) to tracheostomy
- Long-term prognosis is poor even with appropriate planning

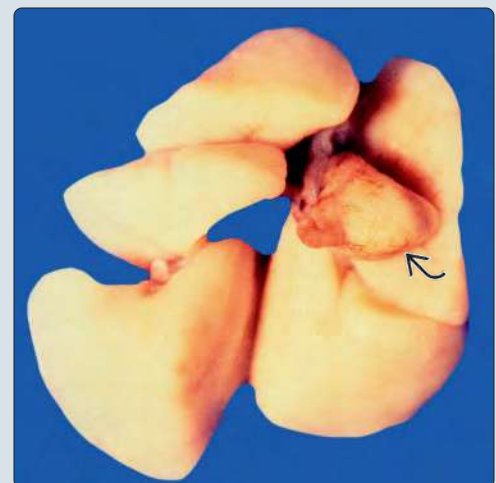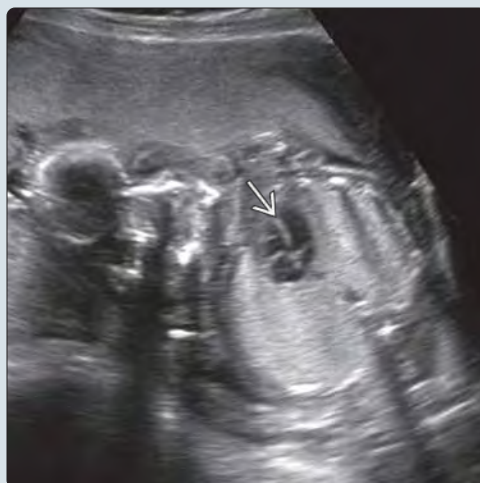DIAGNOSTIC CHECKLIST

- Symmetric, homogeneous lung enlargement is essentially pathognomonic
- Goal of imaging is to determine site and severity of obstruction to aid in counseling and treatment planning

(Left) Graphic shows a high tracheal atresia with distension of the distal trachea and bronchi. The diaphragm is everted, and there is ascites. The heart is shifted toward the midline and is compressed by the enlarged lungs. The lungs are bulging out between the ribs. **(Right)** Coronal MR in a fetus at 20 weeks gestation shows a dilated, fluid-filled trachea and bronchi. The lungs are massively enlarged with eversion of the diaphragm. There is a large volume of ascites, a classic feature of CHAOS. (From *D13: Pediatrics*.)



(Left) Transverse view of the chest shows hyperexpanded, hyperechoic lungs compressing the heart and subsequently obstructing venous and lymphatic return. There were coexistent renal anomalies in this fetus. Other anomalies are seen in ~ 50% of cases. **(Right)** Gross pathology from a fetus with CHAOS shows enlargement of all lobes of the lung. Note how small the heart is in comparison. High airway obstruction causes retention of fetal lung fluid and subsequent overdevelopment of the lungs.



TERMINOLOGY

Abbreviations

- Congenital high airway obstruction sequence (CHAOS)

Definitions

- High airway obstruction (tracheal or laryngeal) caused by atresia, stenosis, or web
- Term can be used more generically to describe lung findings secondary to any sort of obstructing mass, such as neck teratoma

IMAGING

General Features

- Best diagnostic clue
 - Bilaterally enlarged, echogenic lungs

Ultrasonographic Findings

- Dramatic lung findings
 - Symmetric bilateral enlargement
 - Homogeneously hyperechoic
- Heart shifted to midline and appears small
 - Compressed by enlarged lungs
 - Best appreciated on 4-chamber view
- Diaphragm flattened or everted
- Ascites common and may be massive
 - High intrathoracic pressures obstructs lymphatic and venous return
- Generalized hydrops may develop, but ascites is dominant feature
- Both polyhydramnios and oligohydramnios reported
 - Polyhydramnios more common
- Other anomalies in 50% of cases
 - 1 or more features of VACTERL association (vertebral, anal atresia, cardiac, tracheoesophageal fistula, renal, and limb anomalies)
 - Renal and cardiac most common
 - If esophageal fistula present may decompress lungs
 - Diagnosis of tracheal atresia may be missed until after delivery

MR Findings

- T2WI: Lungs have increased signal
- Often better than ultrasound for finding point of airway obstruction
 - Dilated trachea and bronchi distal to point of obstruction

Imaging Recommendations

- Protocol advice
 - Coronal color Doppler ultrasound of neck focused on larynx
 - Look for movement of fluid during breathing and opening and closing of vocal cords that would suggest less severe obstruction, such as web
 - Consider dedicated fetal echo
 - Heart may be difficult to evaluate because of compression
 - Cardiac anomaly worsens prognosis
 - MR recommended for better anatomic definition

DIFFERENTIAL DIAGNOSIS

Bilateral Congenital Pulmonary Airway Malformations

- Trachea and bronchi would not be fluid-filled

PATHOLOGY

General Features

- Etiology
 - Midforegut forms esophagus only
 - No endoderm for trachea
 - Obstruction causes retention of fetal lung fluid and subsequent overdevelopment
 - Lungs more mature than expected for gestational age
 - Larger volumes
 - Greater number of alveoli
- Genetics
 - Generally considered sporadic
 - Autosomal dominant inheritance documented in some families
- Associated abnormalities
 - Fraser syndrome: Tracheal atresia, cryptophthalmus, syndactyly, genitourinary abnormalities, abnormal ears

CLINICAL ISSUES

Natural History & Prognosis

- Fatal if unrecognized and delivery plan not established
- Better outcome if atresia is not complete
 - Web or stenosis
- In utero improvement has been described
 - Likely from spontaneous perforation or fistulization of airway
- Long-term prognosis is poor
 - Live born neonates have diaphragmatic dysfunction, tracheomalacia, and capillary leak syndrome
 - Few survive outside of nursery

Treatment

- Planning for delivery is essential
 - EXIT procedure (ex utero intrapartum treatment) to tracheostomy
 - Uteroplacental circulation maintained while airway is established
- There are case reports of successful fetoscopy for web

DIAGNOSTIC CHECKLIST

Image Interpretation Pearls

- Symmetric homogeneous lung enlargement is essentially pathognomonic
- Goal of imaging is to determine site and severity of obstruction to aid in counseling and treatment planning

SELECTED REFERENCES

1. Aslan H et al: Prenatal diagnosis of congenital high airway obstruction syndrome (CHAOS). Five case report. *Med Ultrason.* 17(1):115-8, 2015
2. Martínez JM et al: Evaluation of fetal vocal cords to select candidates for successful fetoscopic treatment of congenital high airway obstruction syndrome: preliminary case series. *Fetal Diagn Ther.* 34(2):77-84, 2013
3. Saadai P et al: Long-term outcomes after fetal therapy for congenital high airway obstructive syndrome. *J Pediatr Surg.* 47(6):1095-100, 2012

KEY FACTS

IMAGING

- Abnormal heart position without chest mass or diaphragmatic hernia
- 2/3 on right
- Associated anomalies in 50-75%
- MR helpful in most cases

TOP DIFFERENTIAL DIAGNOSES

- Congenital diaphragmatic hernia (CDH)
 - Left CDH with right cardiac shift
 - Stomach, bowel in chest ± liver
 - Right CDH with left cardiac shift
 - Liver in chest
- Other causes of abnormal cardiac axis
 - Congenital pulmonary airway malformation
 - Bronchopulmonary sequestration
 - Congenital heart disease

PATHOLOGY

- Classification includes agenesis, aplasia, hypoplasia

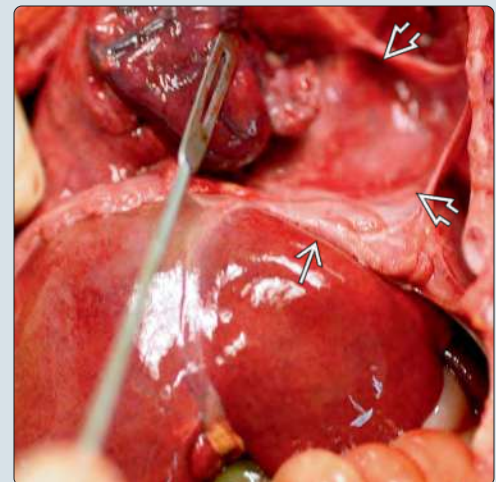
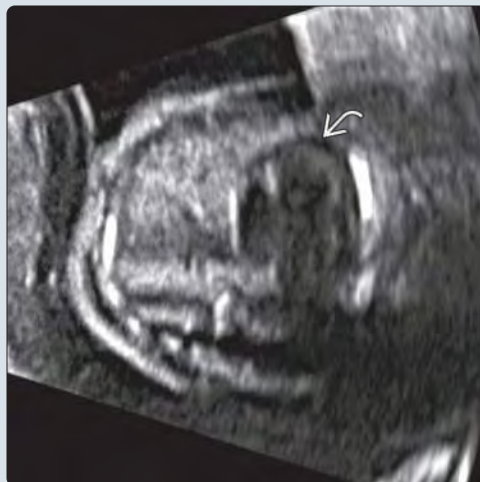CLINICAL ISSUES

- Consider genetic counseling and testing
 - 70% with genetic defect when not isolated
- Prognosis depends on associated anomalies
 - Isolated and partial cases with good prognosis
- Postnatal CT ± MR/MRA often necessary

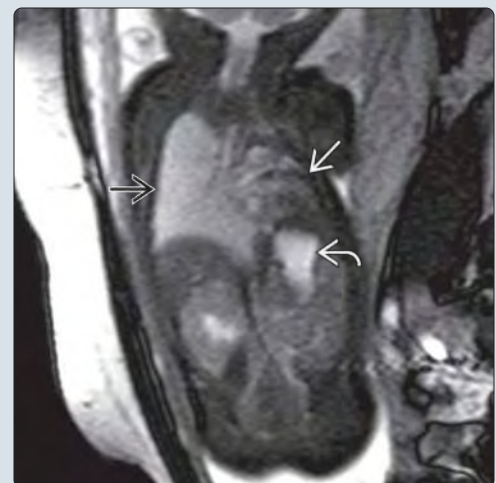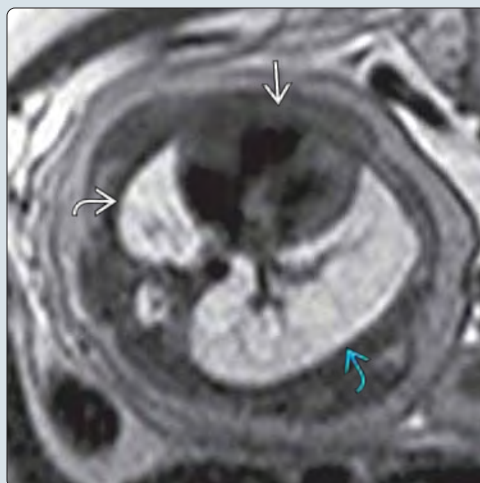
DIAGNOSTIC CHECKLIST

- Outcome variable depending on associated malformations
- Much of vascular anatomy cannot be elucidated prenatally
 - Especially associated great vessel anomalies
- Consider diagnosis with unexplained dextrocardia or levocardia
 - Echocardiogram for abnormal cardiac axis recommended
 - Partial agenesis findings often subtle

(Left) Axial view through the fetal chest shows displacement of the heart to the left chest wall. The right lung was normal and there was no evidence of a congenital diaphragmatic hernia. The fetus had several anomalies, including a large occipital encephalocele. **(Right)** Photograph from the autopsy in the same case with the heart retracted reveals an empty cavity, which should be occupied by the left lung. The diaphragm is intact.



(Left) Axial MR in a fetus with partial right pulmonary agenesis shows the heart displaced to the right with the volume of right lung much less than the left. The only other finding was a pelvic kidney. Amniocentesis showed a chromosome 10 deletion. **(Right)** Coronal MR of complete left pulmonary agenesis shows a single right lung and displacement of the heart to the left chest wall (stomach). This fetus survived but had unexpected coarctation of the aorta with a stormy postop course due to pulmonary hypertension.



TERMINOLOGY

Definitions

- Failure of lung tissue development
 - Unilateral > bilateral
 - Complete or partial

IMAGING

General Features

- Best diagnostic clue
 - Heart is displaced (mediastinal shift)
 - Dextrocardia > levocardia
- Location
 - 2/3 on right

Ultrasonographic Findings

- Cardiac axis displacement
 - Without chest mass or diaphragmatic hernia
 - Might be subtle if partial agenesis
- Color Doppler findings
 - Absent right or left pulmonary artery
- Associated anomalies in 50-75%
 - Vascular and cardiac most common
 - Genitourinary, spine > head, face, gastrointestinal
 - VACTERL association

MR Findings

- Complete or partial absent lung on side of cardiac shift
 - Fluid-filled airway seen to better advantage
- Allows more specific diagnosis
 - 98% specificity reported
 - Lung signal different than liver, thymus, bowel
 - No shadowing from bone

DIFFERENTIAL DIAGNOSIS

Congenital Diaphragmatic Hernia

- Cardiac axis abnormal due to mass affect
- Left congenital diaphragmatic hernia (CDH)
 - Stomach/small bowel/colon in chest ± liver
- Right CDH presents with liver in chest
 - Use color Doppler to assess portal vein branch position

Other Causes of Abnormal Cardiac Axis

- Congenital pulmonary airway malformation
 - Arterial flow to mass from pulmonary artery
- Bronchopulmonary sequestration
 - Systemic arterial flow to mass
- Congenital heart disease
 - Abnormal cardiac axis often 1st clue with outflow tract anomalies

PATHOLOGY

General Features

- Etiology
 - Vascular etiology proposed
 - Underdeveloped bronchial arteries disrupts lung bud development
- Genetics
 - Genetic defect in 70% when other anomalies present

- Deletions, syndromes, aneuploidy

Staging, Grading, & Classification

- Pulmonary agenesis
 - Complete absence of lung tissue, bronchi, and vasculature
- Pulmonary aplasia
 - Complete absence of lung tissue with rudimentary bronchus
- Pulmonary hypoplasia
 - Underdeveloped lung and bronchi
 - Often secondary to oligohydramnios/chest compression

CLINICAL ISSUES

Presentation

- Most common signs/symptoms
 - Abnormal cardiac axis on 4-chamber view

Demographics

- Epidemiology
 - 1:10,000-15,000

Natural History & Prognosis

- Prognosis depends on associated anomalies
- Isolated and partial cases with good prognosis
 - Reports of incidental diagnosis in childhood or later
- Postnatal CT ± MR/MRA often necessary
 - MRA excellent for display of associated vascular anomalies
 - Pulmonary artery sling, anomalous origin of great vessels from aortic arch
 - Persistent left superior vena cava compressing airway with right agenesis
 - Right pulmonary artery impingement → tracheomalacia with left agenesis
 - CT best for evaluation of airway anatomy

Treatment

- Reports of diaphragm surgery to stabilize mediastinum

DIAGNOSTIC CHECKLIST

Consider

- Consider diagnosis with unexplained dextrocardia or levocardia
 - e.g., normal echocardiogram, no chest mass, no diaphragmatic hernia
- Outcome depends on associated anomalies
- Refer for genetic counseling

SELECTED REFERENCES

1. Kayemba-Kay's S et al: Unilateral pulmonary agenesis: a report of four cases, two diagnosed antenatally and literature review. *Pediatr Pulmonol.* 49(3):E96-102, 2014
2. Russell BC et al: Isolated unilateral pulmonary agenesis and other fetal thoracic anomalies. *Obstet Gynecol Surv.* 69(6):335-45, 2014
3. Pacharn P et al: Congenital lung lesions: prenatal MRI and postnatal findings. *Pediatr Radiol.* 43(9):1136-43, 2013
4. Meller CH et al: Prenatal diagnosis of isolated right pulmonary agenesis using sonography alone: case study and systematic literature review. *J Ultrasound Med.* 31(12):2017-23, 2012
5. Backer CL et al: Tracheal reconstruction in children with unilateral lung agenesis or severe hypoplasia. *Ann Thorac Surg.* 88(2):624-30; discussion 630-1, 2009

KEY FACTS

IMAGING

- Nonnuchal, subcutaneous, complex cystic mass
 - Often large with septations
 - No solid component
- 20% of all lymphangiomas are nonnuchal
 - 70% occur in axilla
 - Often bilateral
- May extend through chest wall
 - Mediastinal involvement common
 - Assess for airway compression
- Prenatal MR accurately predicts extent of disease when compared with postnatal MR

TOP DIFFERENTIAL DIAGNOSES

- Nuchal cystic hygroma
 - More common than nonnuchal lymphangioma
 - 66% associated with chromosome abnormality
- Klippel-Trenaunay-Weber syndrome
 - Large cutaneous hemangiomas

- Doppler shows blood flow in mass

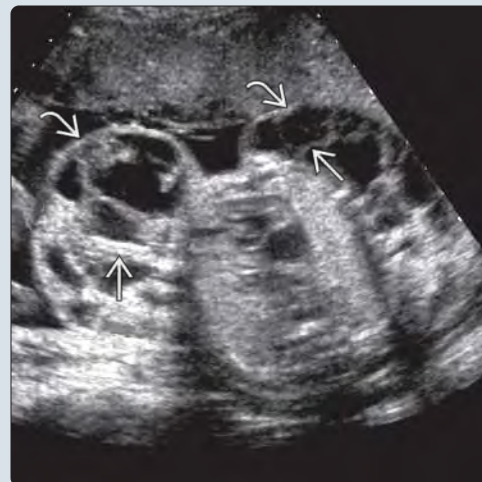
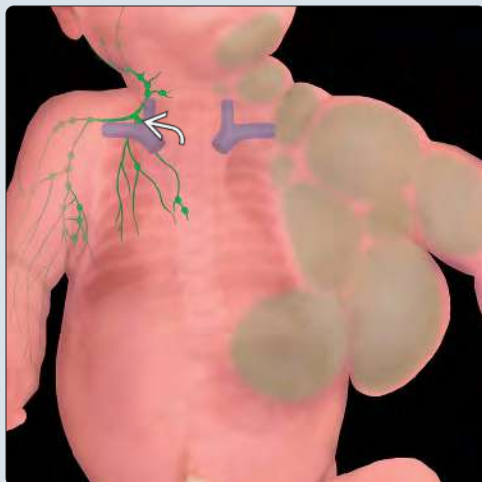
CLINICAL ISSUES

- 2nd-trimester nonnuchal lymphangioma not associated with chromosome abnormalities (in contrast to nuchal cystic hygroma)
- Prenatal needle aspiration considered for size control prior to delivery
 - Prenatal sclerosis of fetal mass reported
- Potential delivery complications due to size of mass
- Postnatal surgical excision is treatment of choice
 - Sclerosis with cyst injections can be done
- Survival rates near 100%
 - Much better than with nuchal cystic hygroma

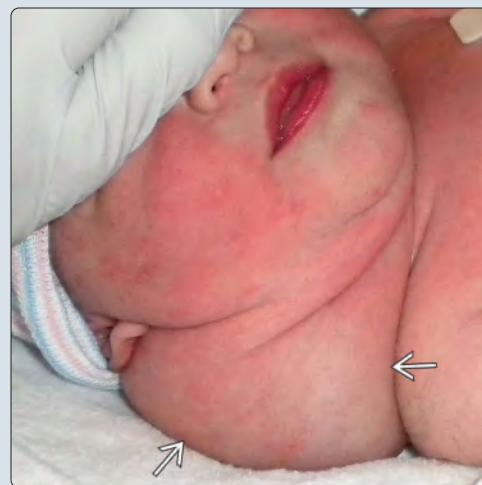
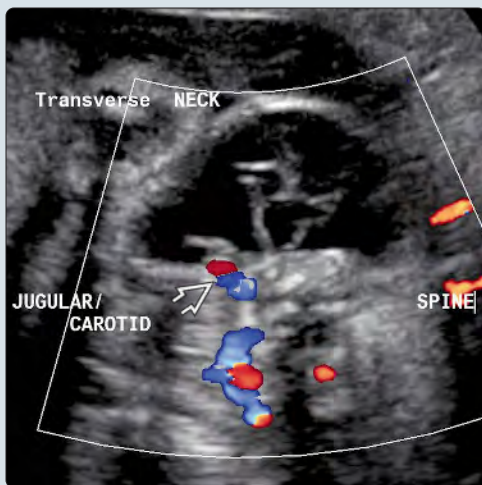
DIAGNOSTIC CHECKLIST

- Consider fetal MR
 - Extent of mass better shown than US alone
- Use Doppler to assess for blood flow in mass

(Left) Graphic shows a lymphangioma. Multiple cysts along the left chest, neck, and arm have formed because of congenital lymphatic obstruction. Normal lymphatic drainage anatomy with a patent jugular lymphatic connection is shown on the fetal right. **(Right)** Axial US shows bilateral, large, multiloculated, axillary cystic masses in a 2nd-trimester fetus. The masses contain thin and thick septations. Axillary lymphangiomas are frequently bilateral.



(Left) Transverse color Doppler ultrasound of a right anterolateral septated neck mass shows the mass is avascular, consistent with a lymphangioma. The mass abuts but does not appear to encase the jugular and carotid vessels. No deep invasion was seen. **(Right)** Photograph of the neonate shows the large lateral neck mass. The delivery was uncomplicated, and intubation was not required, as suggested by the prenatal imaging.



TERMINOLOGY

Synonyms

- Cystic lymphangioma (CL)
- Nonnuchal cystic hygroma
- Axillary lymphangioma
- Cutaneous lymphangioma

Definitions

- Benign, nonnuchal, cystic tumors of lymphatic system

IMAGING

General Features

- Best diagnostic clue
 - Nonnuchal, subcutaneous, large, complex cystic mass
- Location
 - 70% of nonnuchal CL are axillary
 - Often bilateral
 - May extend through chest wall
 - Mediastinal involvement common
 - 30% other sites
 - Trunk
 - Limbs
 - Anterior and lateral neck (nonnuchal)
 - 80% of all lymphangiomas are nuchal (cystic hygroma)
 - Different prognosis than nonnuchal CL
- Size
 - Variable; prenatal cases usually large
- Morphology
 - Complex cystic mass with septations
 - Septations usually thick
 - No solid component
 - Rarely unilocular

Ultrasonographic Findings

- Grayscale ultrasound
 - Complex cystic body wall mass
 - Sonolucent cysts
 - Septa of variable thickness
 - No solid components
 - May enlarge during pregnancy
 - Extent of mass difficult to estimate
 - Associated anomalies rare
 - **Axillary CL**
 - Cystic mass between arm and chest wall
 - May extend down arm
 - Secondary lymphedema common
 - Abnormal arm positioning
 - Arm held away from fetal trunk
 - Can grow into mediastinum
 - Rib deformity common
 - Associated pleural effusion rare
 - Associated hydrops rare
 - **Trunk CL**
 - Cystic mass involving fetal trunk
 - Usually asymmetric
 - May involve lower extremity
 - Secondary lymphedema common
 - Limb held in abnormal position

- **1st-trimester axillary CL**
 - Often transient
 - Nonoculated most common
 - Often with chromosome abnormality
- Color Doppler
 - No blood flow
- 3D
 - Extent of mass better seen
 - Mass volume can be calculated

MR Findings

- T1WI: Low signal
- T2WI: High signal
- Extent of mass better evaluated with MR
 - Mediastinum
 - Assess for airway compression
 - Less commonly seen than with solid masses
 - Chest wall
 - Neurovascular structures
 - Body wall musculature
- Excellent correlation of prenatal MR extent of disease with postnatal MR

Imaging Recommendations

- Protocol advice
 - Follow mass size with sequential exams
 - Consider 3D US or MR to assess volume
 - Consider aspiration of large cysts for delivery purposes

DIFFERENTIAL DIAGNOSIS

Nuchal Cystic Hygroma

- Posterior lateral neck location
- Usually septated
- More common than nonnuchal CL
- 66% associated with chromosome abnormality
 - Turner most common
 - Noonan syndrome
 - Trisomy 21
- Commonly seen in 1st trimester
 - Nonseptated more common
- Hydrops fetalis common

Klippel-Trenaunay-Weber Syndrome

- Large cutaneous hemangiomas
 - Doppler shows blood flow in mass
 - Less cystic than CL
- Hypertrophy of associated limb
 - Long bone asymmetry
 - Focal gigantism

Hemangioma

- Dilated vessels deep in skin
- Solid component present
 - Less cystic than lymphangioma
- Doppler shows blood flow in mass
- Scalp is common site
- Can be infiltrative
 - Chest wall involvement
 - Extremity involvement

PATHOLOGY**General Features**

- Etiology
 - Axillary
 - Obstruction of axillary lymph vessels at junction with jugular venous system
 - Abnormal lymphatic anlage
 - Insufficient anastomoses with larger lymph channels
- Genetics
 - 2nd-trimester nonnuchal CL not associated with chromosome abnormalities
 - 1st-trimester axillary CL
 - Associated with trisomy 21
 - Rare finding
- Associated abnormalities
 - Musculoskeletal dysmorphism
 - Secondary to mass effect
 - Hydrops fetalis

Gross Pathologic & Surgical Features

- Tumor with numerous cystic cavities
- Infiltrative features
 - Skin
 - Muscle
 - Neurovascular structures

Microscopic Features

- Tumor wall
 - Endothelium lining
 - Smooth muscle fascicles
- Small compressed capillaries
- Lymphatic spaces
 - Lymphocytes
 - Rare erythrocytes

CLINICAL ISSUES**Presentation**

- Most common signs/symptoms
 - Incidental on routine screening exam
 - Uncommonly associated with hydrops
 - More rare than with nuchal cystic hygroma

Demographics

- Gender
 - M = F
- Epidemiology
 - 20% of all lymphangiomas are nonnuchal

Natural History & Prognosis

- Short term
 - Obstructed labor
 - Dystocia
 - Cesarean section delivery preferred
 - Fetal respiratory compromise
 - Delivery at tertiary care center
 - Reports of EXIT (ex utero intrapartum treatment) procedure to deliver
 - In cases of significant airway compression due to mass

- Birth trauma to mass
 - Bleeding, infection, skin necrosis
- Long term
 - Outcome depends on size and location of mass
 - Functional impairment common
 - Lymphedema
 - Infection
 - Hemorrhage
 - Recurrence
 - Microcystic components recur most commonly
 - Treated with further surgery or sclerosis
- Spontaneous involution reported
 - 29% show partial involution
- Survival rates near 100%
 - Much better than with nuchal cystic hygroma

Treatment

- **Prenatal**
 - Often no treatment
 - US-guided fluid aspiration of large cysts
 - Reduce volume before delivery
 - Prenatal sclerosis of fetal mass reported
 - OK-432
 - Inactivated streptococcal organisms
- **Postnatal**
 - Surgical excision
 - Complete excision desired
 - Infiltration of vital structures common
 - Makes excision difficult
 - Postsurgical recurrence common
 - Sclerosis
 - Agents injected directly into cysts
 - Bleomycin, OK-432, doxycycline, ethanol
 - Use alone or in conjunction with surgical excision

DIAGNOSTIC CHECKLIST**Consider**

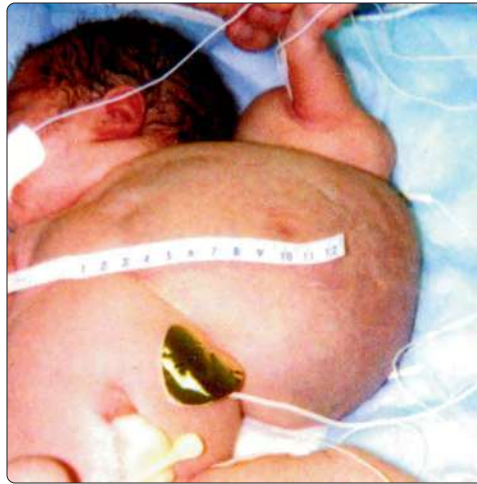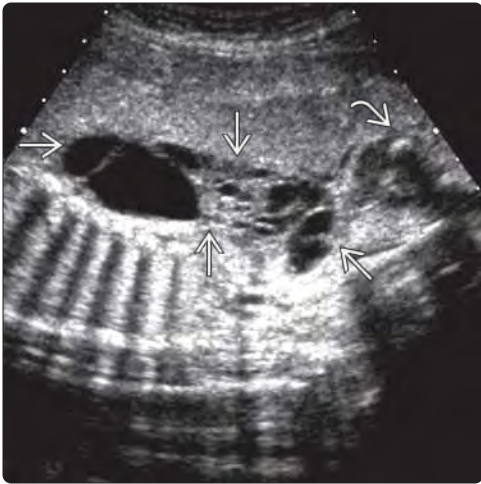
- Nonnuchal CL in cases of large superficial fetal mass
- Consider fetal MR
 - Better tissue characterization
 - Extent of mass better shown
 - Correlates well with postnatal MR appearance

Image Interpretation Pearls

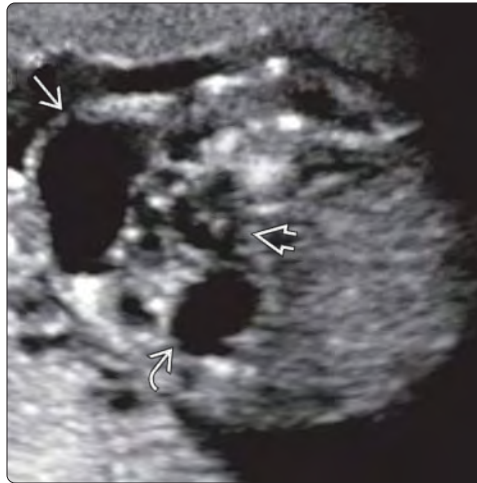
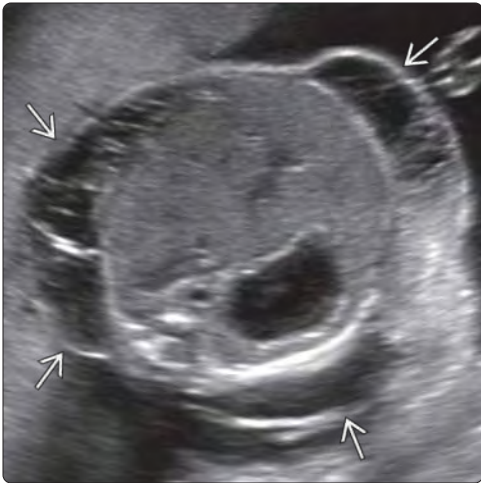
- Look for bilateral masses when 1 CL is seen
 - Long view of humerus identifies early axillary CL
- Use Doppler to assess for blood flow
 - Excludes vascular malformation

SELECTED REFERENCES

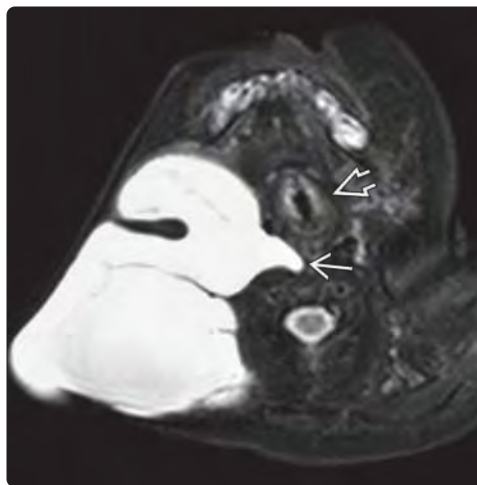
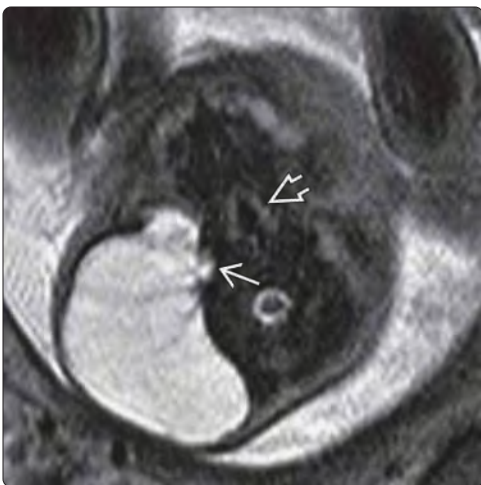1. Arisoy R et al: Prenatal diagnosis and outcome of lymphangiomas and its relationship with fetal chromosomal abnormalities. *J Matern Fetal Neonatal Med.* 1-7, 2015
2. Koelblinger C et al: Fetal magnetic resonance imaging of lymphangiomas. *J Perinat Med.* 41(4):437-43, 2013
3. Surico D et al: Antenatal diagnosis of fetal lymphangioma by ultrasonography. *Eur J Obstet Gynecol Reprod Biol.* 168(2):236, 2013
4. Chiappinelli A et al: Congenital abdominal cystic lymphangiomas: what is the correct management? *J Matern Fetal Neonatal Med.* 25(7):915-9, 2012
5. Wiegand S et al: Sclerotherapy of lymphangiomas of the head and neck. *Head Neck.* 33(11):1649-55, 2011



(Left) Coronal US shows a fetus with a lymphangioma arising from the axilla and extending down the chest wall **➤**. The fetal arm **➤** (cross section) was consistently held away from chest. **(Right)** Clinical photograph shows a neonate with a large lymphangioma, which involved the chest wall, axillae, and arm. As often seen prenatally, the arm is markedly abducted.



(Left) At 22 weeks gestation, this fetus has a diffuse body wall lymphangioma **➤**. Mass-like areas of anechoic septated cysts are present in the subcutaneous tissues, distinguishing lymphangioma from skin edema, which is usually diffuse and uniform. **(Right)** US of a retroperitoneal lymphangioma at 18 weeks shows a subcutaneous fluid collection **➤**, which has extended into the retroperitoneum **➤** and is surrounding the right kidney **➤**. The flank cyst was aspirated, yielding lymphocytes.



(Left) Fetal MR can help assess the infiltrative extent of the lymphangioma. The medial margin of the mass **➤** does not encase the airway **➤**, which is valuable information for delivery planning. **(Right)** Postnatal MR correlates well with the fetal MR findings. The medial portion of the mass **➤** abuts the airway **➤**, but the airway is widely patent, and intubation was not required.

KEY FACTS

IMAGING

- Complex heterogeneous mass
 - Contains both cystic and solid components
 - Calcifications most specific feature but not present in all cases
- Most originate from superior mediastinum and are midline in location
 - Lungs are pushed laterally
 - Heart compressed inferiorly
- Hydrops common and may be severe with large masses
- MR helpful in defining extent of mass and evaluating airway
 - Lack of airway visualization does not necessarily mean invasion; may still be patent but compressed by mass

TOP DIFFERENTIAL DIAGNOSES

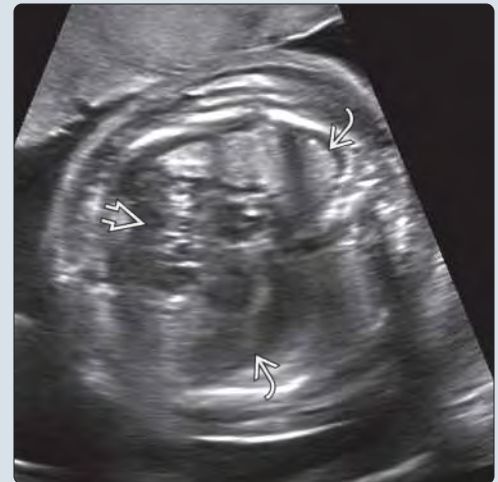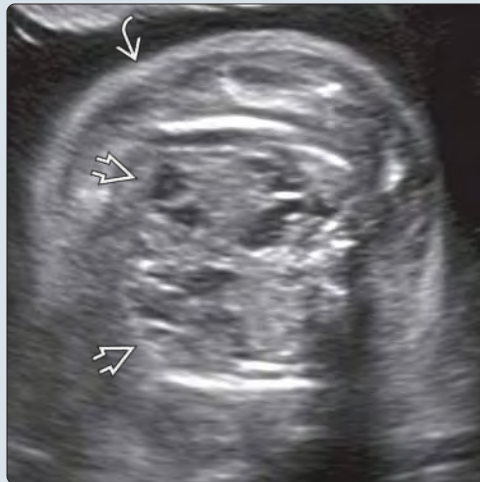
- Pericardial teratoma
 - Often has massive pericardial effusion
- Lymphangioma

- Septated cystic mass without significant solid components
- May invade into chest and mediastinum but largest component in neck or axillae
- Congenital pulmonary airway malformation and bronchopulmonary sequestration
 - Arise from lung, not mediastinum

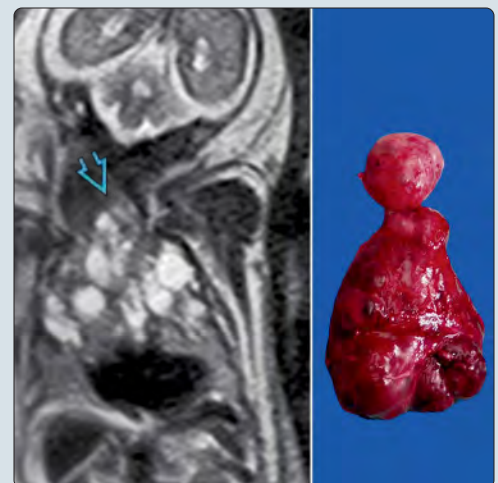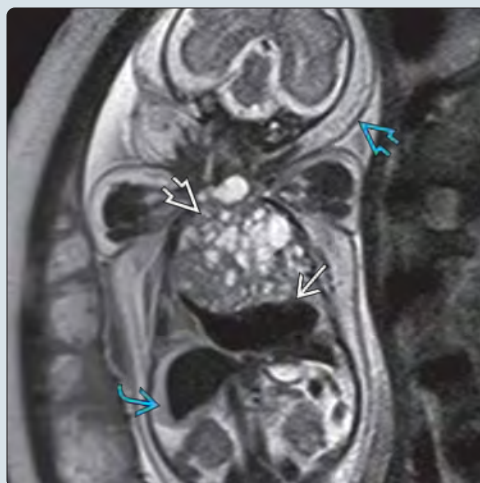CLINICAL ISSUES

- Most present in 3rd trimester
 - May have had normal 2nd-trimester scan
 - Reflects rapid growth of mass
- Large masses with hydrops often fatal
- For those resected in neonatal period, degree of pulmonary hypoplasia and status of trachea are key prognostic indicators
- Even if airway is not invaded, tracheomalacia is common secondary to external compression

(Left) Transverse US of the upper chest shows a complex mass with cystic and solid areas. It fills the thoracic cavity, extending from rib to rib. There is also hydrops with marked skin edema. (Right) On a more inferior image, the mass is shown to be in a midline location with the lungs pushed laterally and surrounded by small effusions. This identifies the mass as mediastinal in origin and not a lung mass.



(Left) Coronal T2 MR shows the complex nature of the mass. There is compression of the heart resulting in hydrops with skin edema and ascites. (Right) The mass extended through the thoracic inlet into the neck. No airway could be identified, and an EXIT procedure was planned. At delivery, an endotracheal tube was placed and the mass, a well-encapsulated teratoma, was immediately resected. Even when successfully resected, there can be long-term morbidity from tracheomalacia.



TERMINOLOGY

Definitions

- Neoplasm composed of all 3 germ cell layers

IMAGING

General Features

- Best diagnostic clue
 - Calcifications within centrally located chest mass
- Location
 - Most originate from mediastinum
 - Typically anteriorly within superior mediastinum
 - Intrapulmonary teratoma extremely rare
- Size
 - Variable but typically large
 - May grow rapidly over short period of time

Ultrasonographic Findings

- Complex heterogeneous mass
 - Contains both cystic and solid components
 - Calcifications most specific feature but not present in all cases
- Midline location within chest
 - Lungs are pushed laterally
 - Often outlined with pleural fluid aiding in visualization
 - Heart compressed inferiorly
- Pleural effusions
 - Isolated or with hydrops
- Hydrops common and may be severe with large masses
 - Compression of venous and lymphatic return
- Polyhydramnios from esophageal/tracheal compression
- Color Doppler
 - Variable vascularity
 - No dominate feeding vessel
 - Helps differentiate from other lung masses

MR Findings

- Best modality for evaluating extent of tumor and airway
 - Lack of airway visualization does not necessarily mean invasion
 - May still be patent but compressed by mass

DIFFERENTIAL DIAGNOSIS

Pericardial Teratoma

- More common than mediastinal or intrapulmonary teratoma
- Often has massive pericardial effusion
 - Compresses lungs posteriorly vs. pleural effusion in which lungs will be outlined by fluid (wing-like appearance)
- May be either intrapericardial (most common) or extrapericardial

Lymphangioma

- Septated cystic mass
 - No significant solid areas or calcifications
 - No flow on color Doppler
- May invade into chest and mediastinum
- Largest component will be external to chest in neck or axillae

Lung Masses

- These arise from lung parenchyma, not mediastinum
- Congenital pulmonary airway malformation may be cystic or solid
 - Vascular supply from pulmonary artery
- Bronchopulmonary sequestration homogeneously echogenic
 - Systemic vascular supply, typically aorta
- Neither have calcifications

Neuroblastoma

- More common in abdomen but can occur in chest
- Arises posteriorly from neural crest cells on either side of spine

CLINICAL ISSUES

Presentation

- Most present in 3rd trimester
 - Chest mass
 - Hydrops
 - Polyhydramnios
- May have had normal 2nd-trimester scan
 - Reflects rapid growth of mass

Demographics

- Epidemiology
 - < 10% of fetal teratomas occur in chest
 - Most of these are pericardial
 - Mediastinal teratomas are rare

Natural History & Prognosis

- Variable based on size of mass and extent of local involvement
- Large masses with hydrops often fatal
- For those resected in neonatal period, degree of pulmonary hypoplasia and status of trachea are key prognostic indicators
 - Even if airway is not invaded, tracheomalacia is common secondary to external compression
 - Often results in significant morbidity

Treatment

- In utero resection reported
- Ex utero intrapartum treatment (EXIT) treatment may be required to establish airway
- Immediate resection of mass
 - Requires planned multidisciplinary approach

DIAGNOSTIC CHECKLIST

Consider

- When chest mass in midline in location
- When calcifications present in chest mass

SELECTED REFERENCES

1. Simoncic M et al: Mediastinal teratoma with hydrops fetalis in a newborn and development of chronic respiratory insufficiency. *Radiol Oncol.* 48(4):397-402, 2014
2. Giancotti A et al: Mediastinal masses: a case of fetal teratoma and literature review. *Clin Exp Obstet Gynecol.* 39(3):384-7, 2012
3. Noreen S et al: Mediastinal teratoma as a rare cause of hydrops fetalis and death: report of 3 cases. *J Reprod Med.* 53(9):708-10, 2008

DIFFERENTIAL DIAGNOSIS**Common**

- Thymus (Pitfall)
- Microcystic Congenital Pulmonary Airway Malformation
- Bronchopulmonary Sequestration
- Congenital Diaphragmatic Hernia

Less Common

- Teratomas
 - Mediastinal Teratoma
 - Pericardial Teratoma
- Airway Obstruction
 - Congenital High Airway Obstruction Sequence
 - Bronchial Stenosis/Atresia

ESSENTIAL INFORMATION**Key Differential Diagnosis Issues**

- Doppler is key for diagnosing solid chest mass
 - Congenital pulmonary malformation (CPAM) has arterial supply from pulmonary circulation
 - Sequestration has prominent feeding vessel from aorta
 - Diaphragmatic hernia containing liver will show portal/hepatic veins
 - Other masses may show flow but usually no dominant feeding vessel
- Lesion location
 - Lower lobes for either CPAM or sequestration
 - Right side favors CPAM
 - Left side could be either CPAM or sequestration
 - Upper lobes favor bronchial stenosis/atresia
 - Bilateral
 - CHAOS: Look for massive chest enlargement, fluid-filled trachea/bronchi, ascites
 - Bilateral CPAM
 - Bilateral congenital diaphragmatic hernia
 - ◻ Stomach will appear as cystic mass on left side
- Is mass surrounded by fluid
 - Pericardial vs. pleural effusion
 - May be confusing if large
 - Pericardial effusion: Lungs compressed posteriorly
 - Pleural effusion: Lungs float in fluid, with winged appearance
 - Pericardial effusion common with pericardial teratomas
 - Unilateral pleural effusion suggests sequestration, especially if large
 - Bilateral effusions as part of generalized hydrops
 - Most common with CPAM
- Disappearing lung mass
 - Common in both CPAM and sequestration

Helpful Clues for Common Diagnoses

- **Thymus (Pitfall)**
 - Normal fetal thymus is quite large in 3rd trimester and can be mistaken for chest mass
 - Mildly hypoechoic compared to lungs with fine linear striations
 - Look for thy-box to confirm it is thymus
 - Thymus is flanked by internal mammary arteries, branches of subclavian arteries

- **Microcystic Congenital Pulmonary Airway Malformation**
 - Morphology varies from solid-appearing (microcystic) to complex cystic mass (macrocytic) or even unilocular
 - Microcystic CPAM appear as solid lesions
 - Cysts < 5 mm
 - Uniformly echogenic, well-defined masses
 - 95% are unilateral and affect only 1 lobe
 - No side predilection
 - More commonly lower lobe, near diaphragm
 - Color Doppler
 - Vascular supply from pulmonary artery
 - Venous drainage to pulmonary vein
 - ◻ Often not visualized
 - Greatest growth 20-26 weeks
 - May regress and even disappear later in pregnancy
 - May be complicated by hydrops (< 10%)
- **Bronchopulmonary Sequestration**
 - Uniformly echogenic, well-marginated, triangular shape
 - 90% left-sided by lung bases
 - 90% supradiaphragmatic, 10% subdiaphragmatic
 - Color Doppler
 - Prominent feeding vessel from aorta (may have more than 1)
 - Venous drainage to inferior vena cava or azygous
 - ◻ Often not visualized
 - Unilateral pleural effusion in 6-10%
 - May cause tension hydrothorax
- **Congenital Diaphragmatic Hernia**
 - Right-sided hernia more likely to present as solid mass because stomach remains below diaphragm
 - Stomach may be more medially located than usual
 - Contents of hernia vary in echogenicity
 - Liver more hypoechoic
 - Bowel more hyperechoic
 - Liver may be difficult to differentiate from lung
 - Use Doppler to look for hepatic/portal veins
 - Fetal MR best tool to evaluate contents of hernia
 - Bilateral hernias may be difficult to diagnose
 - Abnormal cardiac axis may be only clue
 - ◻ Apex will be more midline
 - Abdominal circumference < expected
 - Pulmonary hypoplasia worse for CDH than other chest masses of comparable size
 - Not only mass effect but also abnormal diaphragm effects lung development
 - Up to 50% have an associated abnormality, including chromosomal

Helpful Clues for Less Common Diagnoses

- **Mediastinal Teratoma**
 - Typically originate from anterior mediastinum and can cross midline
 - May extend through thoracic inlet into neck
 - Often exhibit rapid growth
 - Contain both solid and cystic components
 - Calcifications most specific feature but not always present
- **Pericardial Teratoma**
 - May be either intrapericardial or extrapericardial
 - Intrapericardial mass invariably has pericardial effusion

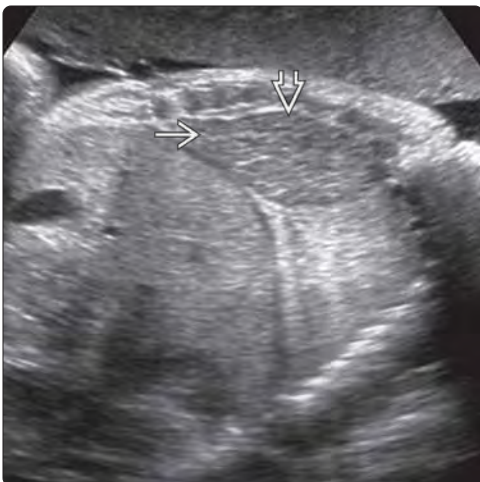- May be massive and mistaken for pleural effusion
- At risk for cardiac tamponade
- **Congenital High Airway Obstruction Sequence**
 - Tracheal or laryngeal obstruction caused by atresia, stenosis, or web
 - Retention of fetal lung fluid causes overdevelopment
 - Symmetric, often dramatic, bilateral lung enlargement
 - Chest circumference enlarged
 - Lungs are diffusely echogenic
 - Fluid-filled trachea and bronchi
 - Causes severe mass effect
 - Eversion of diaphragm
 - Heart appears midline and compressed
 - Ascites, often severe
- **Bronchial Stenosis/Atresia**
 - Disruption of bronchial development with luminal narrowing
 - Mild forms may not be detected on prenatal scan
 - May present in neonatal period with air trapping (congenital lobar overinflation)

- More severe stenosis/atresia presents as uniformly echogenic lung mass
 - Significant overlap in findings with CPAM but may be more extreme
 - As with CHAOS, trapped fetal lung fluid causes overdevelopment
 - May cause significant mass effect
- More commonly upper lobes
 - Left upper lobe > right middle lobe > left upper lobe
 - Lower lobes uncommon

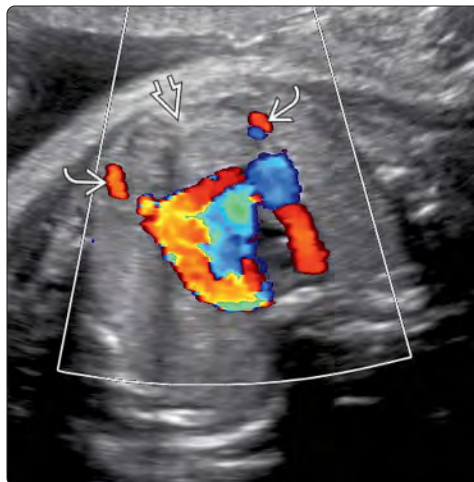
Other Essential Information

- Postnatal work-up should be done in all cases even if mass has disappeared in utero
 - Mass not truly gone, just regressed to point that it is not discernible by routine scanning
 - Postnatal resection somewhat controversial in asymptomatic individuals
 - Most feel risk of infection and malignancy warrants resection in all cases

Thymus (Pitfall)

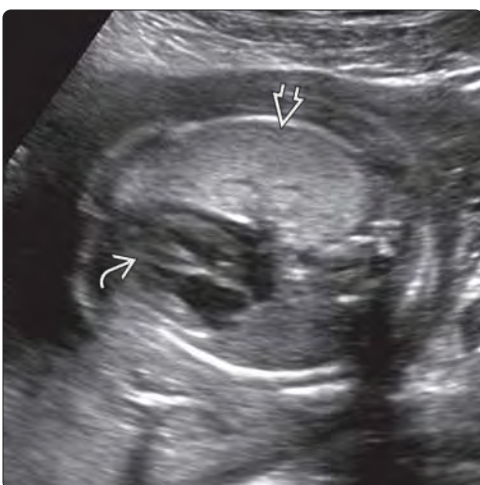

Thymus (Pitfall)

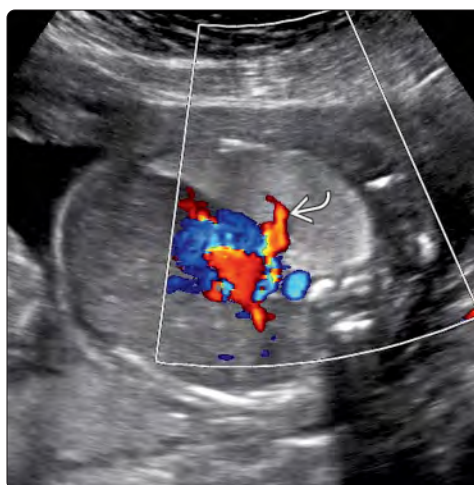


(Left) Sagittal view through the chest in a 3rd-trimester fetus shows a hypoechoic solid chest mass. The echogenicity is closer to liver than lung, and there are fine linear striations. The anterior location and imaging appearance are classic for a normal thymus, which can be quite prominent in a fetus. (Right) If there is any question look in the axial plane with color Doppler. The thymus will be flanked on either side by the internal mammary arteries creating what has been referred to as the thy-box.

Microcystic Congenital Pulmonary Airway Malformation



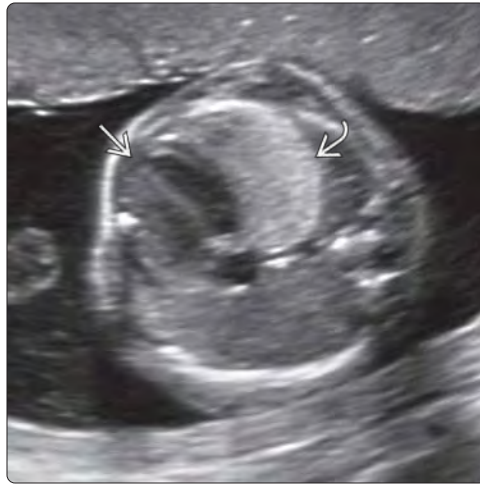Microcystic Congenital Pulmonary Airway Malformation



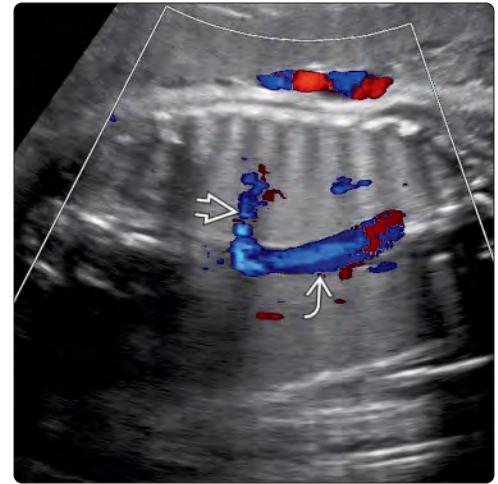
(Left) Axial US through the fetal chest shows a uniformly echogenic lung mass, which is shifting the axis of the heart. Bronchopulmonary sequestration and microcystic congenital pulmonary malformation (CPAM) can have an identical grayscale appearance and color Doppler must be used to differentiate these entities. (Right) Color Doppler ultrasound, in the same case, shows a feeding vessel from the pulmonary artery. This is a classic appearance of a CPAM.

Bronchopulmonary Sequestration

(Left) Axial ultrasound through the fetal chest shows a uniformly echogenic mass in the left hemithorax, which is pushing the heart to the right. (Right) A coronal ultrasound through the mass shows a large feeding vessel from the aorta. Pulsed Doppler will confirm an arterial waveform similar to the aorta. A CPAM has no side predilection, whereas a sequestration is almost exclusively left-sided with 10% occurring below the diaphragm.

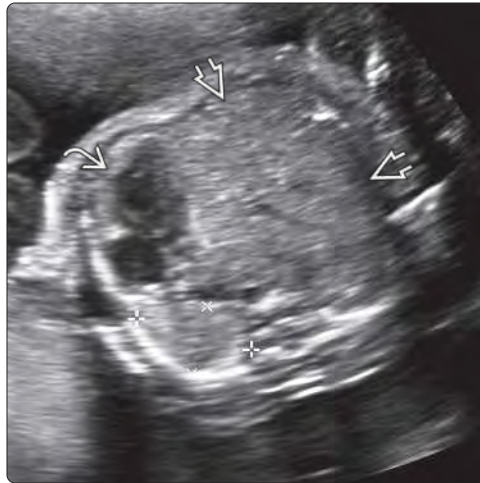


Bronchopulmonary Sequestration

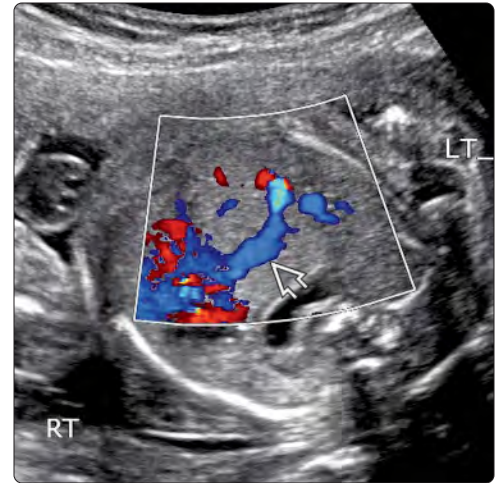


Congenital Diaphragmatic Hernia

(Left) Axial ultrasound through the chest in a fetus with a left-sided diaphragmatic hernia shows the liver appearing as a uniformly echogenic chest mass, which is compressing the heart against the right chest wall. The right lung is being measured by the calipers. (Right) Oblique axial color Doppler, in the same case, shows a prominent hepatic vein draining toward the heart. Color Doppler is essential when evaluating lung masses.

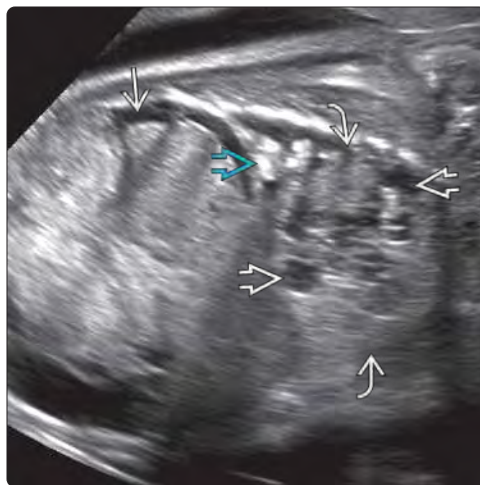


Congenital Diaphragmatic Hernia

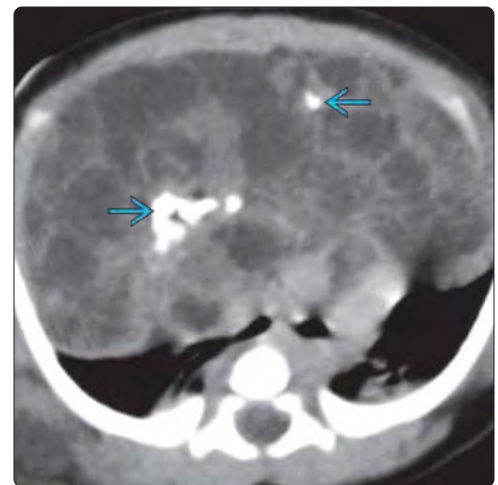

Mediastinal Teratoma

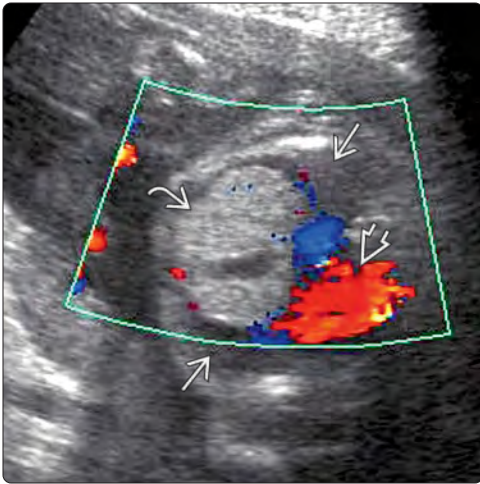
(Left) Coronal ultrasound through the anterior chest shows a large complex mass. The lungs (not shown) were compressed posteriorly. The mass contains some cystic areas and calcifications. Calcifications are the most specific finding of a teratoma but are not always present. Ascites is also present. A teratoma can grow at a very rapid rate and quickly lead to fetal decompensation. (Right) Postnatal CT shows a large complex mediastinal mass filling the chest. Note the areas of scattered calcifications.



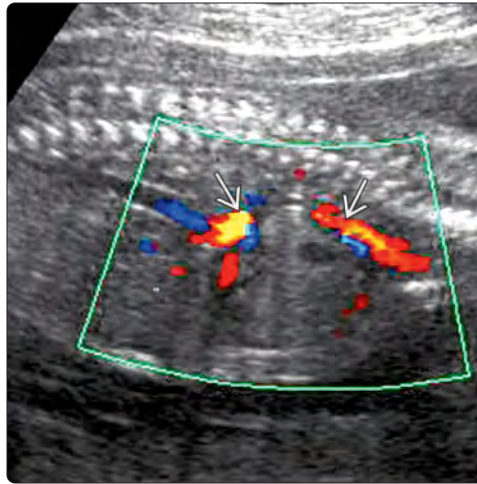
Mediastinal Teratoma



Pericardial Teratoma

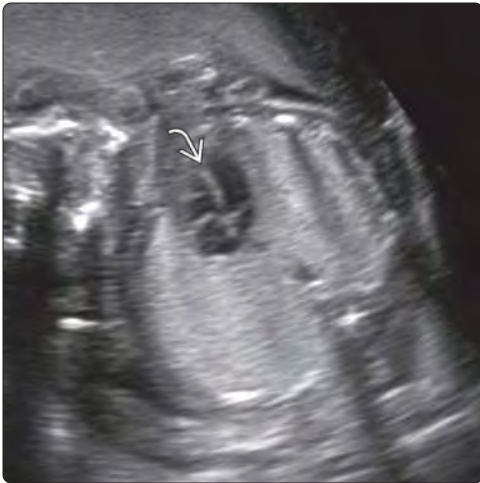

Pericardial Teratoma

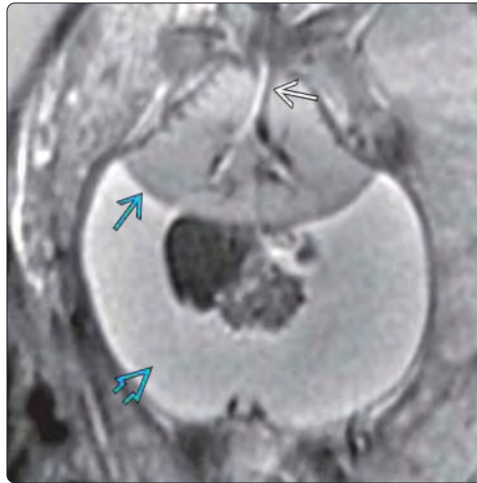


(Left) Axial color Doppler ultrasound shows a large intrapericardial teratoma adjacent to the heart. It is surrounded by a massive pericardial effusion. (Right) Sagittal color Doppler ultrasound in the same case shows deviation of the aorta, but the mass itself had little flow and no feeding vessel could be identified. This helps differentiate a teratoma from a sequestration or CPAM.

Congenital High Airway Obstruction Sequence

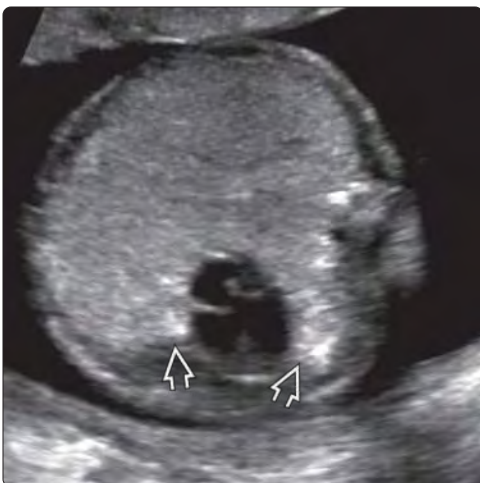


Congenital High Airway Obstruction Sequence

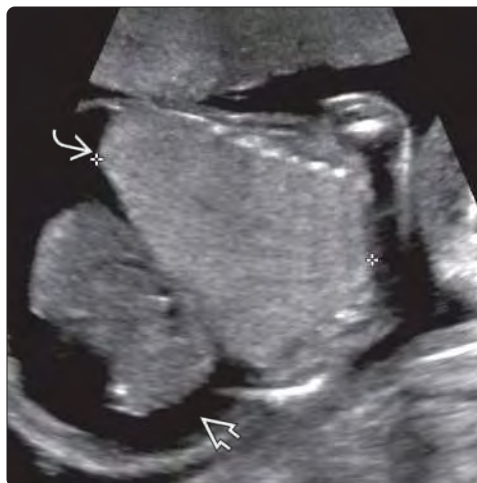

(Left) Axial ultrasound through the fetal chest shows hyperexpanded lungs with compression of the heart in the midline. This obstructs venous and lymphatic return, and there is often severe ascites. Tracheal obstruction causes retention of fetal lung fluid and subsequent overgrowth. (Right) Coronal MR in a 20-week fetus shows a dilated, fluid-filled trachea and bronchi. The lungs are massively enlarged with eversion of the diaphragm. There is a large volume of ascites, a classic feature of CHAOS. (From DI3: Pediatrics.)

Bronchial Stenosis/Atresia



Bronchial Stenosis/Atresia



(Left) Axial ultrasound of the fetal chest in a case of confirmed left upper lobe bronchial atresia shows a dramatically enlarged left lung. Note how it is growing around and encasing the heart on either side. (Right) Sagittal ultrasound through the left side of the chest in the same case shows eversion of the diaphragm and severe ascites. The findings are similar to CHAOS except only one lung is affected.

DIFFERENTIAL DIAGNOSIS**Common**

- Congenital Diaphragmatic Hernia
- Macrocystic Congenital Pulmonary Airway Malformation

Less Common

- Lymphangioma
- Bronchogenic Cyst
- Neurenteric Cyst

ESSENTIAL INFORMATION**Key Differential Diagnosis Issues**

- Where is stomach?
 - If it is below diaphragm, congenital diaphragmatic hernia (CDH) is less likely
 - CDH without gastric herniation (small bowel, liver) generally appears as solid or echogenic mass
- Simple cyst vs. complex cystic mass
 - Bronchogenic cyst and neurenteric cyst more likely to be unilocular simple cysts
 - CDH, macrocystic congenital pulmonary malformation (CPAM), and lymphangioma are generally large complex masses
- Does mass extend beyond chest wall?
 - Lymphangioma has bulk of mass in subcutaneous tissues, not in chest cavity
- Always evaluate spine
 - Neurenteric cysts often associated with thoracic bony abnormality

Helpful Clues for Common Diagnoses




- **Congenital Diaphragmatic Hernia**
 - Left-sided hernias most common (80-90%)
 - Stomach and dilated bowel causes cystic mass in chest
 - Stomach posteriorly located when liver is also herniated
 - Those with liver up have poorer prognosis
 - Abdominal circumference less than expected



- Look carefully for other anomalies including chromosomal
- **Macrocystic Congenital Pulmonary Airway Malformation**
 - Morphology varies from solid appearing (microcystic) to complex cystic mass (macrocystic) or even unilocular
 - Both arterial supply and venous drainage from pulmonary circulation
 - Stomach is below diaphragm
 - Abdominal circumference is normal
 - 95% unilateral and affect only 1 lobe
 - No predilection for side (R = L)

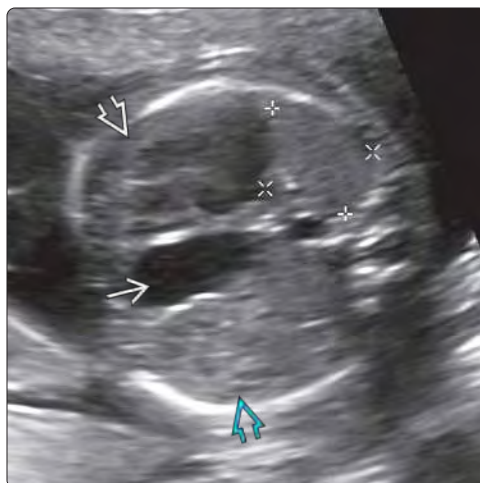
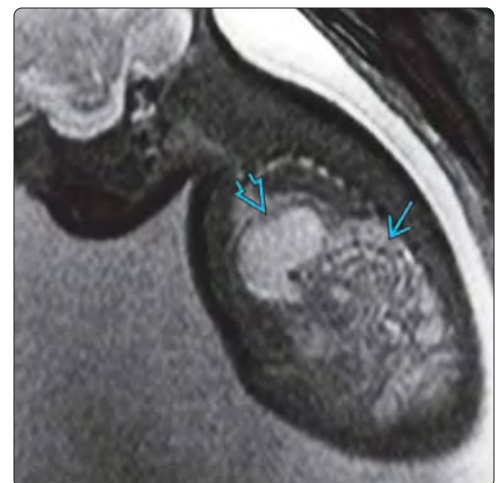Helpful Clues for Less Common Diagnoses

- **Lymphangioma**
 - Complex cystic body wall mass
 - Sonolucent cysts
 - Septa of variable thicknesses
 - No solid components
 - Mediastinal involvement common, but bulk of mass will be outside thoracic cavity
 - Can be located anywhere in soft tissues
 - 70% are axillary
 - Axillary masses typically between arm and chest wall
 - Rib deformity common
- **Bronchogenic Cyst**
 - Majority in middle mediastinum typically paratracheal, carinal, or hilar
 - Occasionally pulmonary, typically in medial 1/3 of lung
- **Neurenteric Cyst**
 - Located midline by spine
 - Thoracic spine most common site, followed by cervical spine
 - Dumbbell shape with extension into spinal canal highly suggestive
 - Vertebral anomalies (both segmentation and fusion) in up to 50%
 - Etiology thought to be incomplete separation of notochord layer from endoderm (primitive foregut)
 - Small piece of primitive gut becomes trapped in developing spinal canal

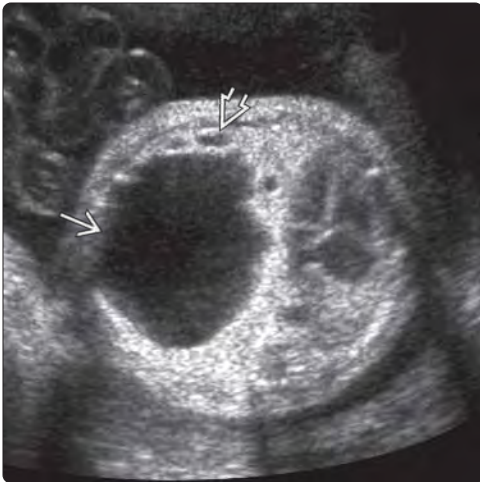Congenital Diaphragmatic Hernia

(Left) This left-sided CDH forms a complex chest mass. The stomach  is the most obvious fluid collection, but the small bowel  is also herniated with the multiple interfaces creating a complex appearance. The heart  is displaced to the right, and the compressed right lung is being measured by the calipers.

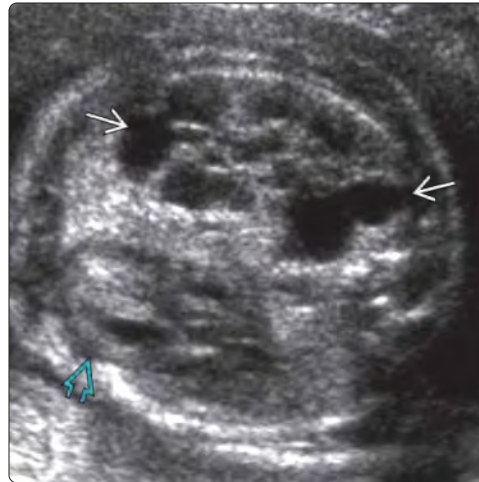
(Right) Sagittal T2WI through the left hemithorax in a fetus with a CDH shows high-signal fluid in the stomach  and small bowel . Colon is best identified on T1 sequences, with meconium being high in signal.

**Congenital Diaphragmatic Hernia**

Macrocytic Congenital Pulmonary Airway Malformation

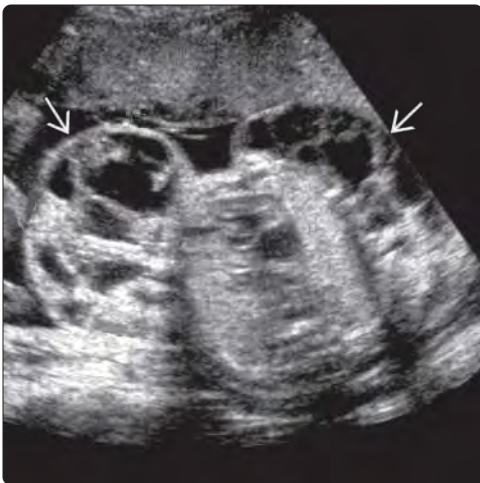

Macrocytic Congenital Pulmonary Airway Malformation

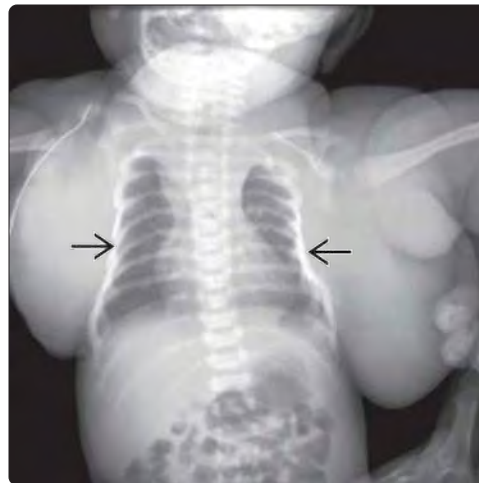

(Left) CPAMs can appear as either cystic or solid chest masses. In this case, there is a dominant cyst, with smaller peripheral cysts. When unilocular, the primary differential is the stomach in a CDH, so always look below the diaphragm for a normal stomach position. (Right) This CPAM has a far more complex appearance with multiple internal septations. The heart is displaced against the chest wall. Unlike a CDH, the abdominal circumference should be normal.

Lymphangioma

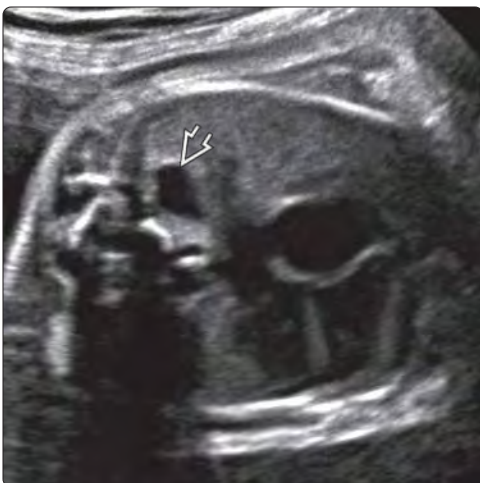

Lymphangioma

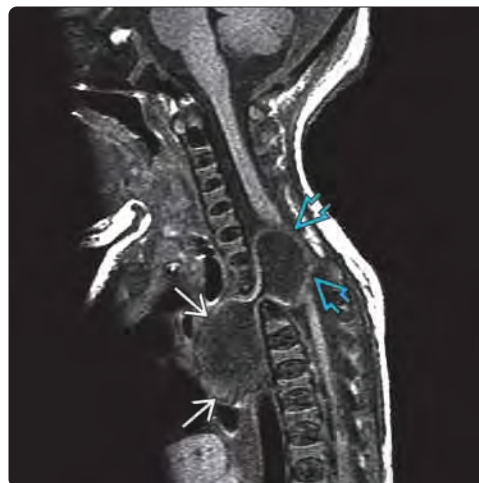


(Left) Axial ultrasound shows bilateral, large, complex, multiloculated chest wall masses. Thin and thick septations are seen throughout. There was no obvious invasion into the thoracic cavity. (Right) Postnatal chest radiograph shows the arms extending away from the trunk and lateral rib deformity secondary to in utero mass effect. Lymphangiomas are typically soft tissue masses but can extend into the mediastinum.

Bronchogenic Cyst



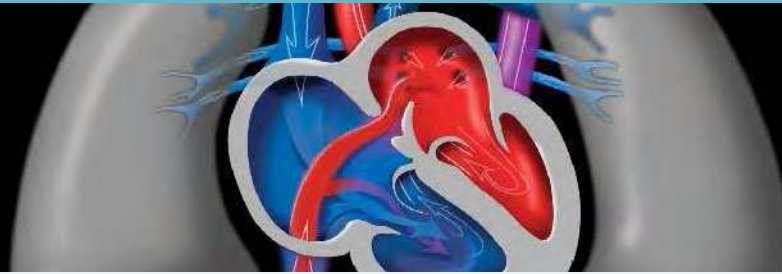Neurenteric Cyst



(Left) Axial ultrasound through the chest shows a centrally located, small, unilocular cyst, which remained stable throughout gestation. Bronchogenic cysts typically occur in the mediastinum or inner 1/3 of the lung. (Right) Sagittal MR of an infant with a neurenteric cyst shows a classic dumbbell shape with both spinal canal and posterior mediastinal components. Vertebral anomalies are common and can be a clue to the diagnosis. Fetal MR is recommended to better evaluate the intraspinal extent.

SECTION 6

Heart



Introduction and Overview

Embryology and Anatomy of the Cardiovascular System	364
Approach to the Fetal Heart	374

Abnormal Location

Heterotaxy, Cardiosplenic Syndromes	380
Ectopia Cordis	384

Septal Defects

Ventricular Septal Defect	388
Atrioventricular Septal Defect	390
Atrial Septal Aneurysm	394

Right Heart Malformations

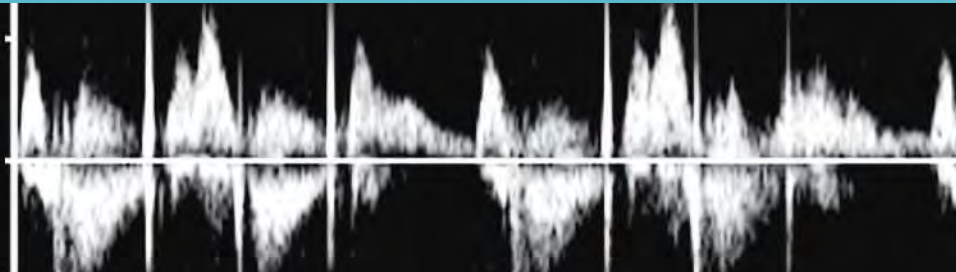
Ebstein Anomaly	396
Tricuspid Dysplasia	400
Tricuspid Atresia	402
Pulmonary Stenosis, Atresia	404

Left Heart Malformations

Hypoplastic Left Heart	408
Coarctation and Interrupted Aortic Arch	412
Aortic Stenosis	416
Total Anomalous Pulmonary Venous Return	420

Conotruncal Malformations

Tetralogy of Fallot	424
Transposition of the Great Arteries	428
Truncus Arteriosus	432
Double-Outlet Right Ventricle	436



Myocardial and Pericardial Abnormalities

Echogenic Cardiac Focus	438
Cardiomyopathy	440
Rhabdomyoma	444
Pericardial Effusion	448
Pericardial Teratoma	450

Abnormal Rhythm

Irregular Rhythm	452
Tachyarrhythmia	454
Bradyarrhythmia	458

Pertinent Differential Diagnoses

Abnormal Cardiac Axis	462
Chamber Asymmetry	468

EMBRYOLOGY OVERVIEW

Heart Fields

- Heart formed from 2 fields; primary and secondary heart fields
- Primary heart field (cardiac crescent)
 - Patterned at 16-18 days and is dependent on normal signals that establish laterality
 - Cardiac progenitor cells from **splanchnic mesoderm**
 - Angiogenic cell clusters create **endocardial tubes**
 - Body folding brings tubes ventral and midline
 - Tubes fuse in midline to create **primitive heart tube**
- Secondary heart field
 - Contributes to cardiac development at 22-28 days
 - Cardiac progenitor cells in **pharyngeal mesoderm** help develop arterial/venous poles of heart tube
 - Outflow tract, right ventricle (RV), atria
 - Contribute to myocardium, smooth muscle
 - Signaling critical in differentiation, elongation, and looping

Primitive Heart Tube

- Composed of endothelial cells surrounded by myoepicardial mantle, cardiac jelly
- From caudal → cranial (or venous → arterial) pole
 - Sinus venosus, primitive atria, primitive ventricle, bulbus cordis, truncus arteriosus
 - Aortic arch vessels sprout from arterial pole
 - Truncus arteriosus divides into ascending aorta, pulmonary artery (PA)
- Heart tube begins **contracting** around 4th week
- Effective circulation in 5th week

Looping

- Differential gene expression controlling sidedness detected as early as cardiogenic field stage
- **Differential growth** causes heart tube to fold into U shape
 - Creates typical heart shape by 28 days
- Venous pole remains anchored dorsally
- Atria migrate cephalad
- Arterial end **bends rightward** and ventral

Septation

- Occurs from 30- to 40-days gestation
- Atria
 - **Septum primum** grows down from above to meet endocardial cushions
 - Fusion with endocardial cushions closes **ostium primum**
 - Apoptosis in center of septum primum creates **ostium secundum**
 - **Septum secundum** grows to right of septum primum
 - Septum secundum fenestrates to create foramen ovale
- Atrioventricular canal
 - Initially directed toward primitive ventricle (developing left ventricle)
 - By 5th week, bulboventricular flange divides ventricles equally
 - Anterior, posterior, and lateral **endocardial cushions** grow inward
 - Cells derived from endocardium or neural crest

- Endocardial cushion fusion creates mitral/tricuspid valves (TVs), separates atria from ventricles
- Ventricles
 - Separated by muscular septum; grows as ventricles grow downward
 - Membranous septum extends from inferior endocardial cushions
 - Outflow septum extends from outflow tract cushions in bulbus cordis
- Great arteries
 - Swellings in conus and truncus create **endocardial ridges**
 - Endocardial ridges grow to separate great arteries in 7th week
 - Spiraling of great arteries results from
 - Inferior/superior orientation of truncal ridges
 - Left/right orientation of conal ridges
 - Secondary heart field directs neural crest cells through signaling pathways

ARTERIAL EMBRYOLOGY

Aortic Arches

- Paired dorsal aortae develop in mesenchyme on either side of notochord
 - Notochord is primitive axis of developing body
- Heart tube rotates into chest as cranial end of embryo bends
- Dorsal aortae follow in loop → 1st aortic arch
- Series of other arches develop and regress → adult arterial anatomy
 - 6 paired arches are blood supply for **pharyngeal arches**, connect to ipsilateral dorsal aorta
 - Right dorsal aorta, 1st, 2nd, and 5th arches regress
 - 3rd arches → internal carotid arteries
 - Left 4th arch → aortic arch
 - Right 4th arch → right subclavian artery
 - Left 6th arch → ductus arteriosus, left PA
 - Right 6th arch → right PA
- Paired dorsal aortae fuse from 4th thoracic to 4th lumbar vertebrae → single midline aorta

Conotruncus

- Conotruncus constitutes outflow tract of primitive heart tube
- Endocardial ridge growth separates truncus arteriosus into ascending aorta and PA
 - Same process creates **aortic and pulmonary valves**
- Aortic valve typically rightward of and posterior to pulmonary valve
- Initially 2 subarterial coni
 - Subpulmonary conus persists
 - Subaortic conus resorbs
 - Fibrous continuity between aortic and mitral valves (MVs)
 - Aorta "anchored" into left ventricle
 - Gooseneck deformity in atrioventricular canal due to lack of septal-aortic continuity

Pulmonary Artery

- Anterior and to left of aortic root

- In fetus, main pulmonary artery (MPA) trifurcates into ductus arteriosus and right and left pulmonary arteries
- In adults, MPA bifurcates into right and left branches as it leaves pericardium
 - Atrophic ductus arteriosus becomes ligamentum arteriosum

VENOUS EMBRYOLOGY

Sinus Venosus

- Has right and left horns
- Each horn receives **vitelline, umbilical, and cardinal** veins
- With differential growth, sinus entrance shifts rightward into developing right atrium (RA)

Systemic Vein Development

- Right anterior cardinal vein → superior vena cava (SVC)
- Left anterior cardinal vein involutes, left sinus venosus horn → coronary sinus
 - Persistent left anterior cardinal vein results in left SVC
- Vitelline veins drain yolk sac, develop into hepatic/portal venous system
- Left umbilical vein (UV) drains through **ductus venosus** to return **oxygenated** placental blood to fetal heart
- Right UV involutes
- UV also enters liver via portal sinus
 - Obliterated UV becomes ligamentum teres

CARDIAC ANATOMY

Segmental Nomenclature

- Each segment of heart is identified based on morphology
- Cardiac anatomic description is based on segments, relative locations, how connected

Normal Chamber/Vessel Morphology

- **RA** identified by limbic bands of fossa ovalis, large pyramidal appendage with pectinate muscles that extend outside appendage, and crista terminalis
 - Fetal marker for RA is systemic venous connection
- **Left atrium (LA)**: Identified by finger-like appendage, pectinate muscles confined to the appendage, no crista terminalis
 - Fetal marker for LA is pulmonary venous connection
- **RV** is heavily **trabeculated** with **moderator band**
 - TV belongs to RV
 - More apically placed than MV, has septal and free wall attachments
 - Fetal marker for RV is moderator band
- **Left ventricle (LV)** is **smooth walled** with fine apical trabeculations
 - MV belongs to LV, only has free wall attachment
 - Fetal marker for LV is smooth internal contour/absence of moderator band
- **PA** should come off RV, branches early into ductus arteriosus, left and right branches
- **Aorta** should come off LV, head and neck vessels come off apex of arch
 - Continues to descending aorta, which connects with ductus arteriosus right after isthmus

CIRCULATION

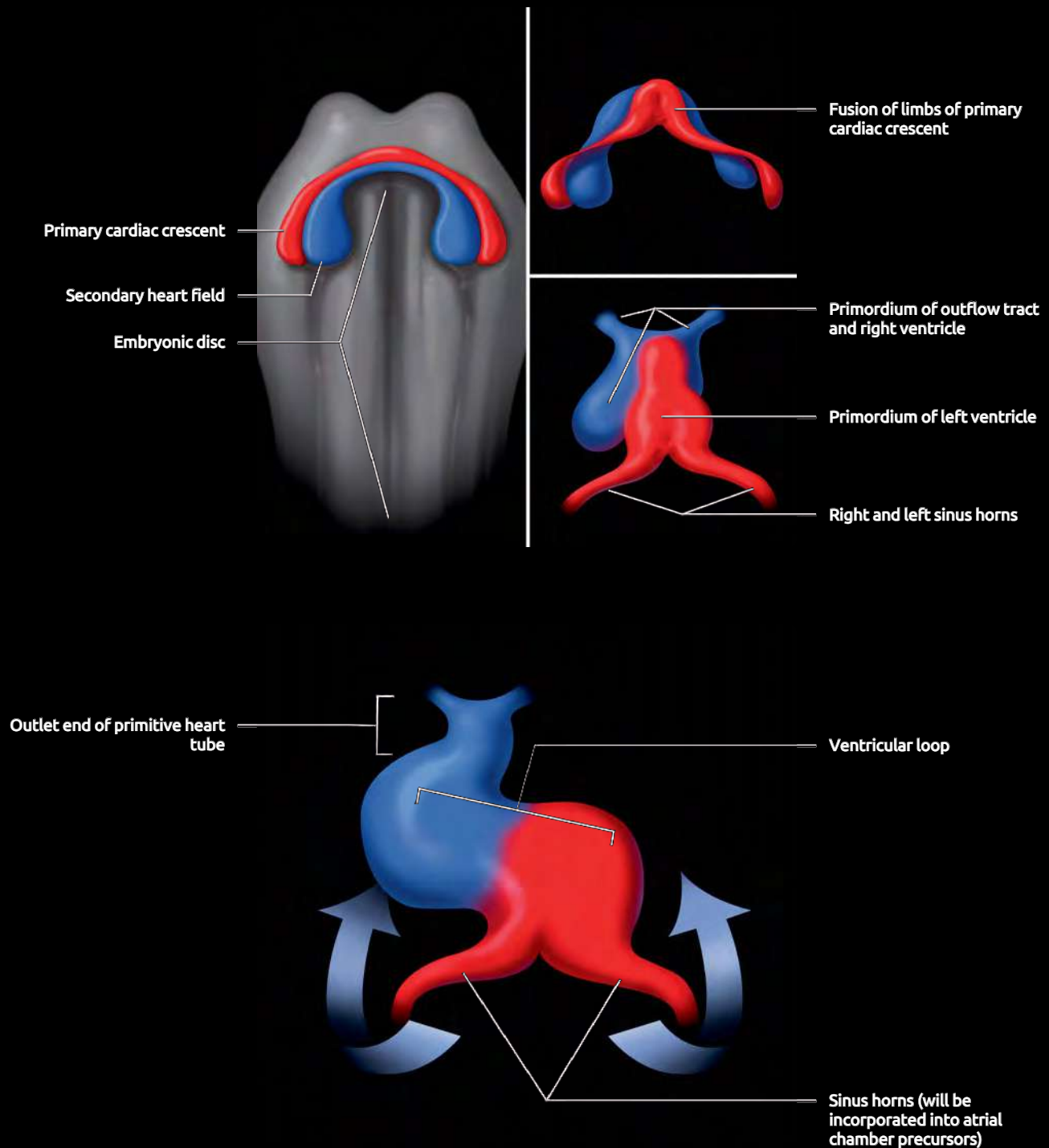
Fetoplacental

- Arteries move blood **away** from heart
 - Aorta takes blood to brain and body
 - **Umbilical arteries** (internal iliac branches) carry deoxygenated blood away from heart to placenta
 - Become medial umbilical ligaments in adults
 - MPA takes blood from RV to body via ductus arteriosus
 - Small volume to lungs in fetal life as not site of gas exchange
- Veins take blood to heart
 - **UV** brings oxygenated blood back to heart, from placenta
 - Oxygenated blood preferentially crosses foramen ovale to left heart to be directed to brain
 - Inferior vena cava (IVC) brings deoxygenated blood from body to RA
 - SVC brings deoxygenated blood from head to RA
- Distribution of cardiac output is very different in fetus compared to adult
 - **Ductus arteriosus** connects MPA to descending aorta
 - Allows oxygenated blood in RV to bypass lungs and be directed to body
 - ◻ Becomes **ligamentum arteriosum** in adults
 - Fetal combined cardiac output (CCO) is 55% RV, 45% LV
 - ~ 40% CCO → body via **ductus arteriosus**
 - ~ 15% CCO → lungs via branch pulmonary arteries
 - ~ 30% CCO → brain via ascending aorta
 - ~ 10% CCO → body via aortic arch/isthmus and descending aorta
 - ~ 3% CCO → heart via coronaries arteries
- Streaming optimizes delivery of oxygenated blood to head
 - Oxygenated UV blood enters RA via ductus venosus and IVC
 - Jet streams preferentially across foramen ovale to LA, LV
 - Blood with highest oxygen content perfuses brain, heart
 - Deoxygenated systemic venous blood drains to RA via SVC, IVC
 - Jet streams preferentially into right ventricle

Neonatal

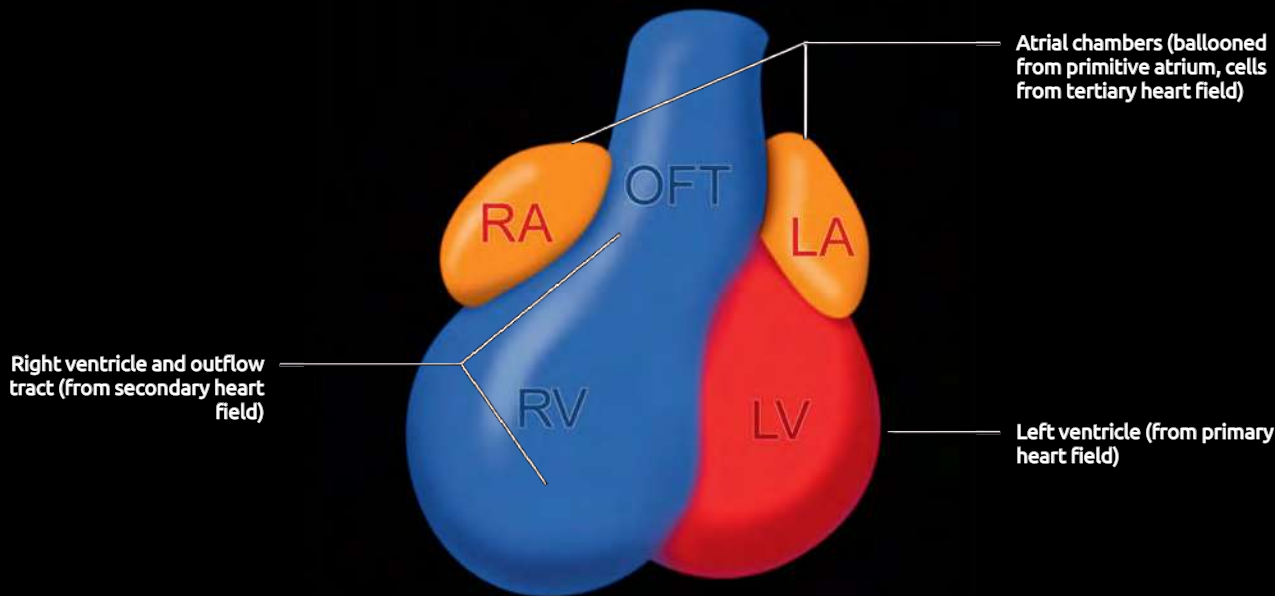
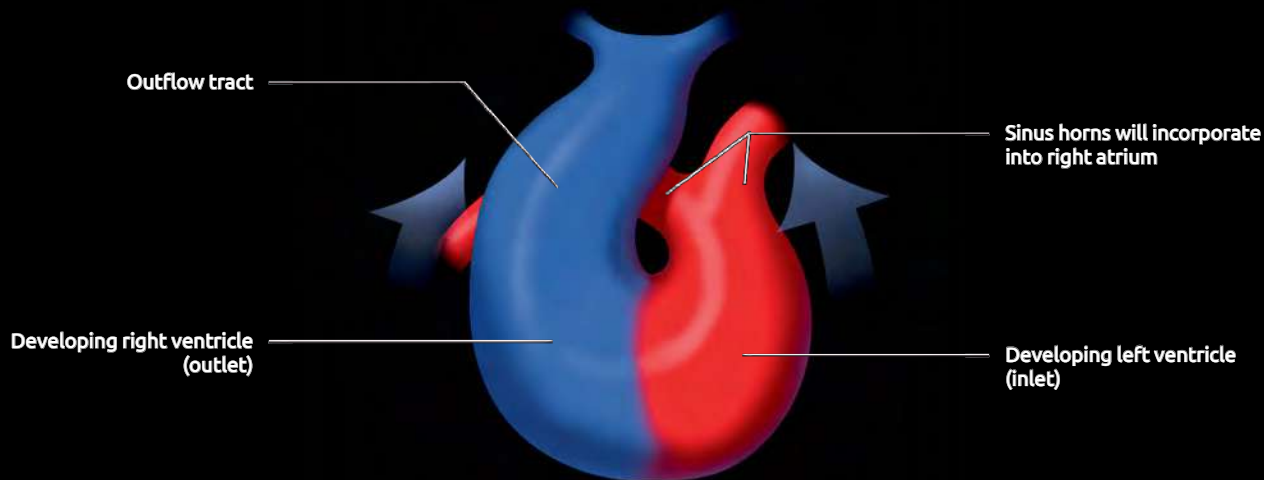
- Onset of breathing increased oxygen in lungs, PAs dilate in response
 - **Decreased pulmonary arterial resistance**
- Low-resistance arterial connection to placenta removed when cord clamped
 - **Increased systemic arterial resistance**
- End result is decreased flow across ductus arteriosus, increased flow in MPA
 - Ductus arteriosus closes
- Pulmonary veins bring oxygenated blood from lungs to LA
- Increases LA pressure closes foramen ovale flap

PRIMITIVE HEART TUBE



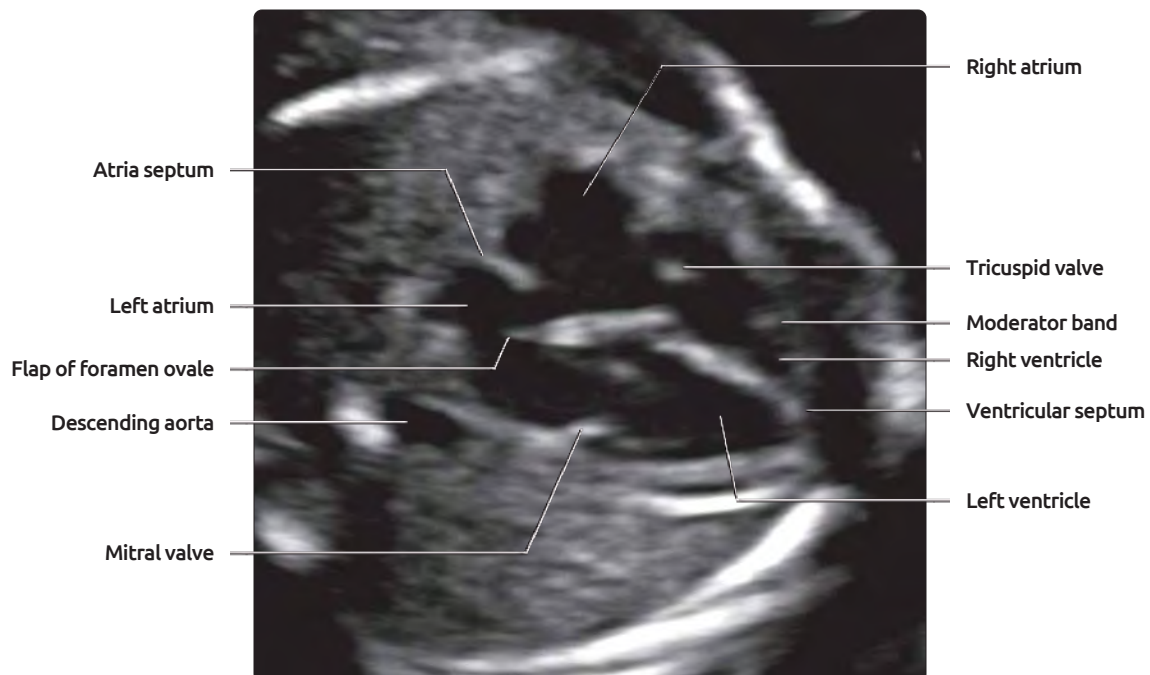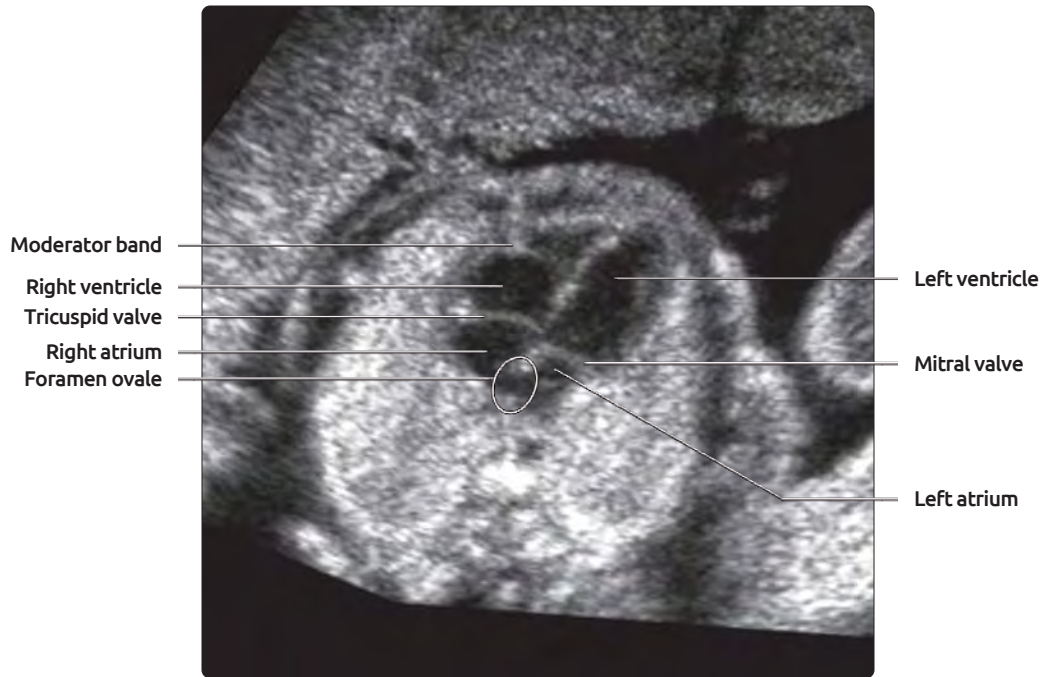(Top) Cells destined to form the heart derive from mesoderm, forming the primary cardiac crescent at the cranial border of the embryo. The secondary heart field lying contiguous with, but medial to, the primary cardiac crescent populates the outflow tract and primordium of the right ventricle. As the embryo elongates and folds, the limbs of the crescent come together in the midline and fuse, creating the heart tube (which moves into the thorax). **(Bottom)** As the straight heart tube elongates, it rotates and folds on itself due to differential growth in a standard D loop, moving the ventricles to the right and left sides. The proximal, venous pole remains anchored dorsal and will become part of the atria, while the arterial pole bends rightward and ventral and will become the outflow tract.

4-CHAMBER HEART



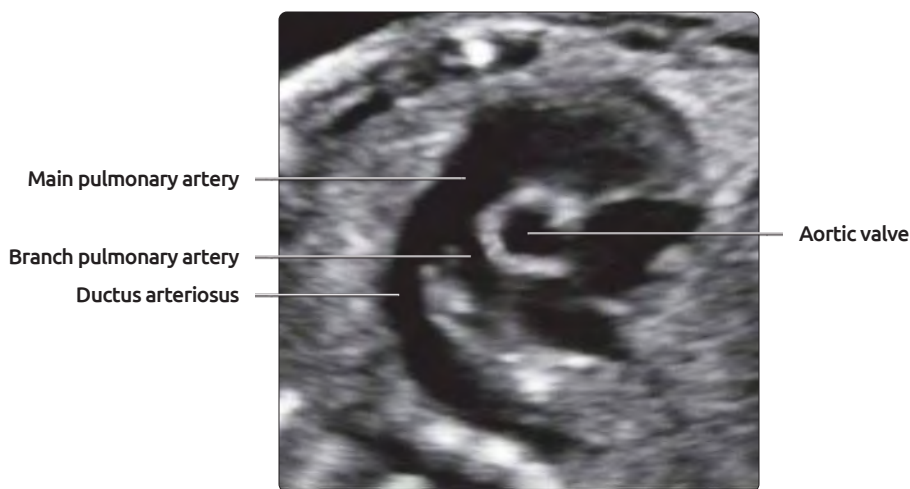
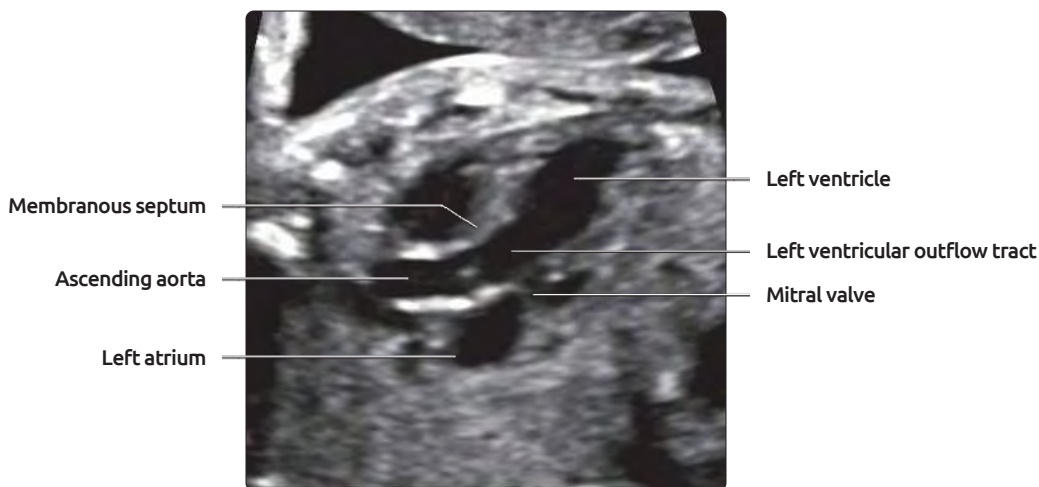
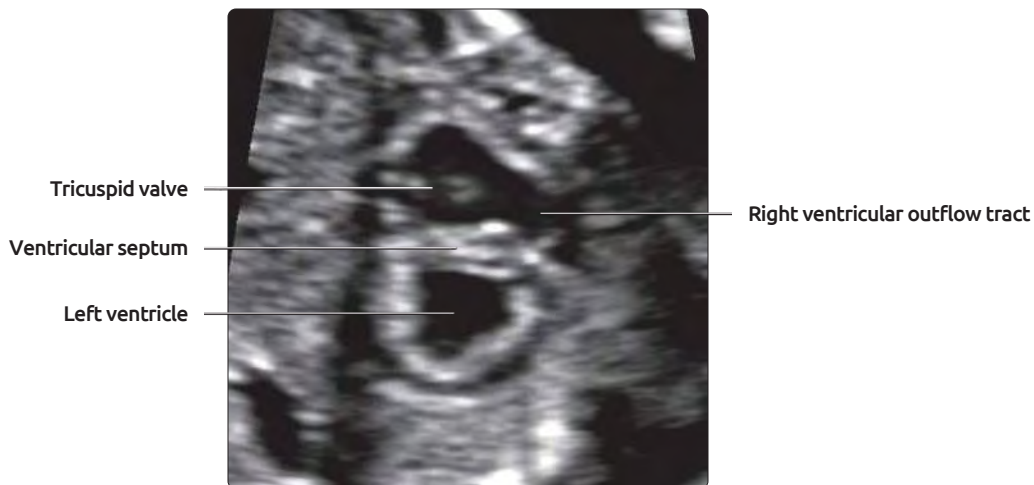
(Top) Cellular growth leads to both the looping and development of the definitive cardiac chambers. The right and left ventricles are shown as well as the eventual right atrium and great vessels. **(Bottom)** Graphic shows a schematic of the early 4-chamber heart. The left ventricle is derived from the primary heart field (red), the right ventricle, and outflows from the secondary heart field (blue). The tertiary field (orange) contributes to formation of the atria and provides cellular components to the ventricles.

VENTRICLES



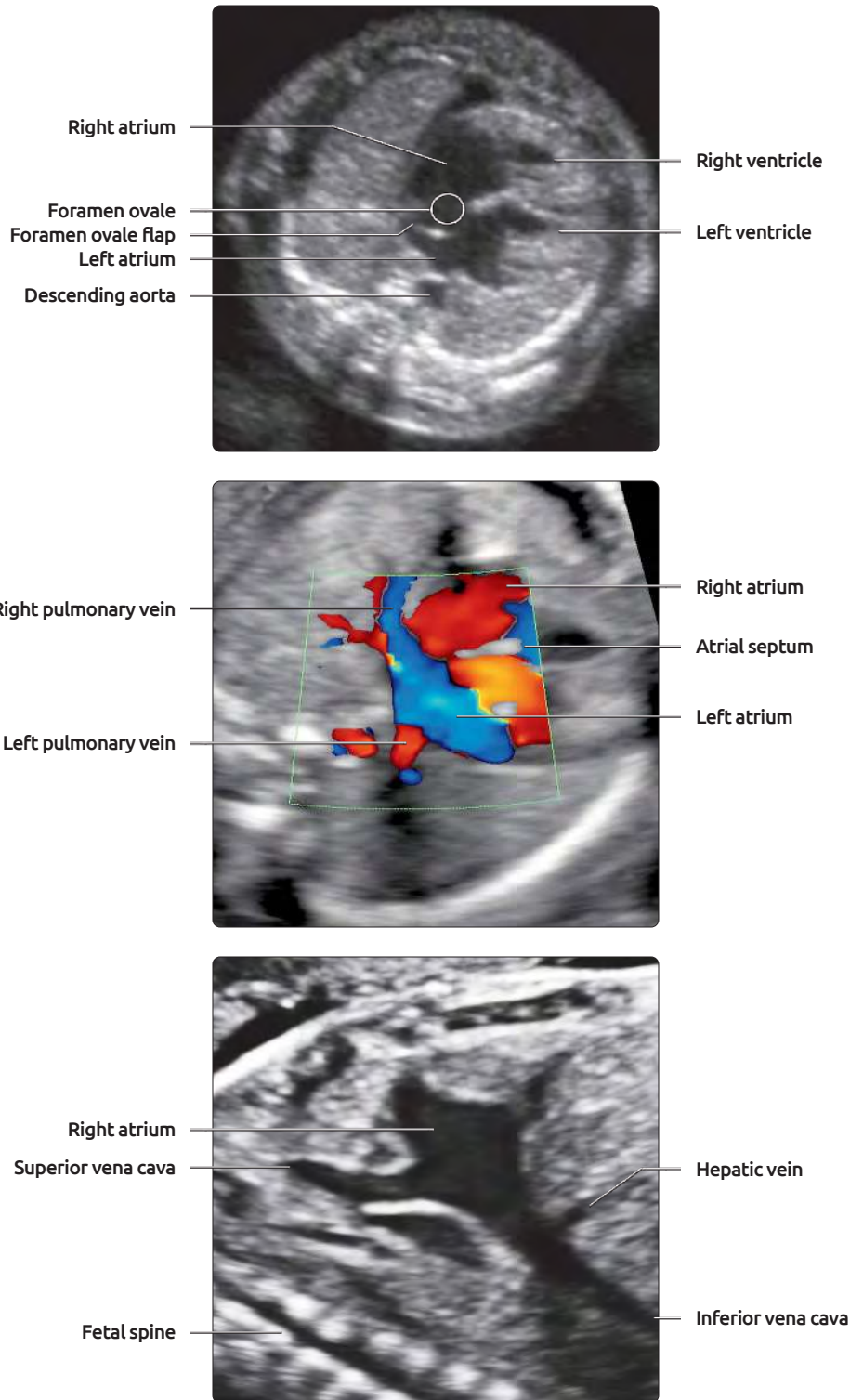
(Top) Four-chamber view in the 2nd trimester provides excellent anatomic detail given that the heart is about the size of a dime and is beating at 130-160 beats per minute. Note the moderator band in the trabeculated right ventricle; this can be used to identify the morphologic right ventricle, which should always be the anterior ventricle. **(Bottom)** This is a more zoomed 4-chamber view using the ultrasound machine's cardiac setting, which creates more contrast to bring out the fine details of the cardiac structures. Note that the flap of the foramen ovale is in the left atrium, which signifies right-to-left flow with the oxygenated stream of blood from the umbilical vein and ductus venosus crossing to the left to provide oxygenated blood to the brain.

VENTRICULOARTERIAL CONNECTIONS



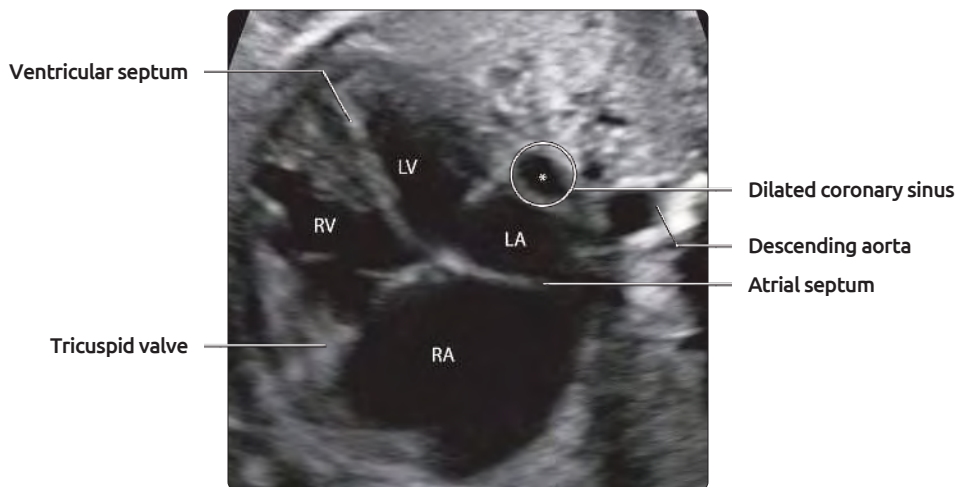
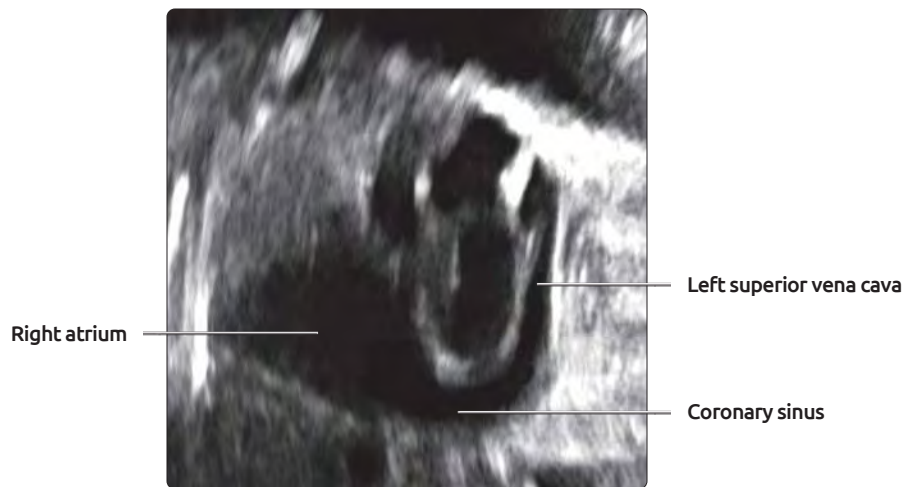
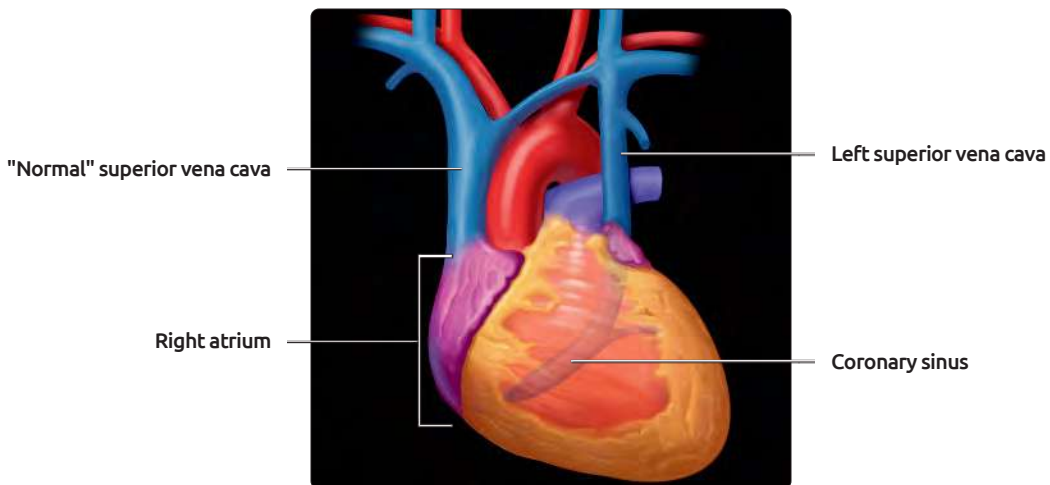
(Top) A short-axis view through the ventricles is not a standard view in OB ultrasound but is an important component of fetal echocardiography as it allows side-by-side assessment of ventricular size and function in real time. The tricuspid valve is seen in cross section in the center of the right ventricular cavity. **(Middle)** The LVOT view is the best view to evaluate the membranous ventricular septum. A defect in this area may simply be an isolated perimembranous ventricular septal defect but may also be found in association with right ventricular outflow tract or conotruncal lesions, such as tetralogy of Fallot or double outlet right ventricle. **(Bottom)** This is the standard RVOT view, which is a short-axis view at the level of the aortic valve. It allows one to lay out the main pulmonary artery and the ductus arteriosus as it runs posteriorly, toward the spine, to join the descending aorta. A parasagittal through the RVOT demonstrates the ductal arch, which is wider and flatter than the aortic arch and has no head and neck vessels arising from it.

VENOATRIAL CONNECTIONS



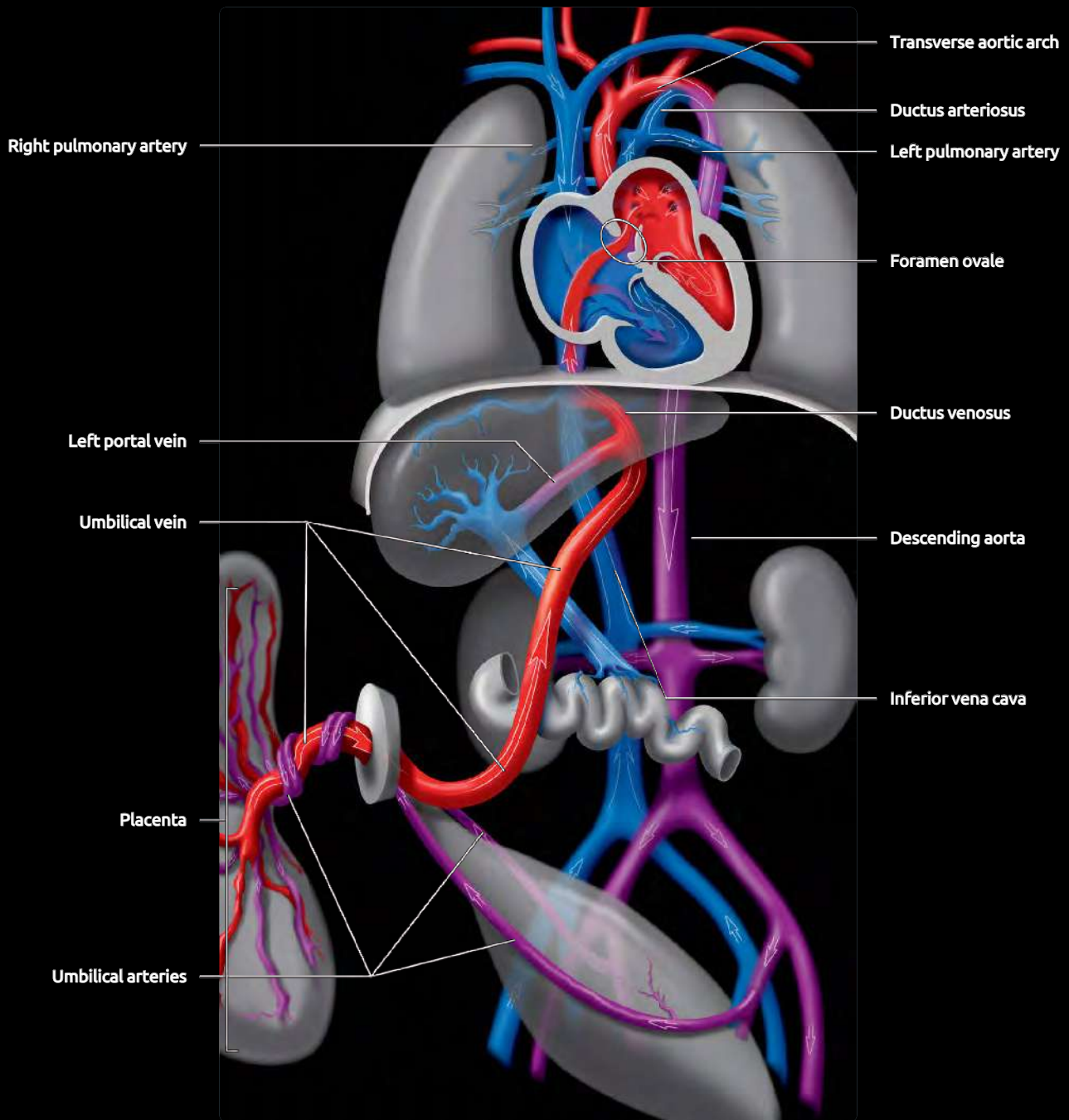
(Top) Abnormal 4-chamber view in a monozygotic twin with ischemic cardiomyopathy following the demise of the cotwin illustrates that the atria and ventricles may be symmetric even when abnormal. The atria are enlarged due to atrioventricular valve regurgitation. The regurgitation is secondary to myocardial ischemia and impaired ventricular contraction. **(Middle)** Image shows a right-sided pulmonary vein, which drains across the midline to the left atrium as well as a left-sided pulmonary vein draining into the left atrium. Note the right vein is blue, so the probe is anterior and to the right of the fetus. **(Bottom)** This is the bicaval view demonstrating systemic venous return to the right atrium. Note the hepatic vein confluence with the inferior vena cava (IVC). In azygous continuation of the IVC, the hepatic veins may drain directly to the right atrium, but they are small and should not be mistaken for the IVC. In azygous continuation of the IVC, the enlarged azygous vein is seen as 2nd vessels posterior to the heart on the 4-chamber view.

ANATOMIC VARIANT: LEFT SUPERIOR VENA CAVA



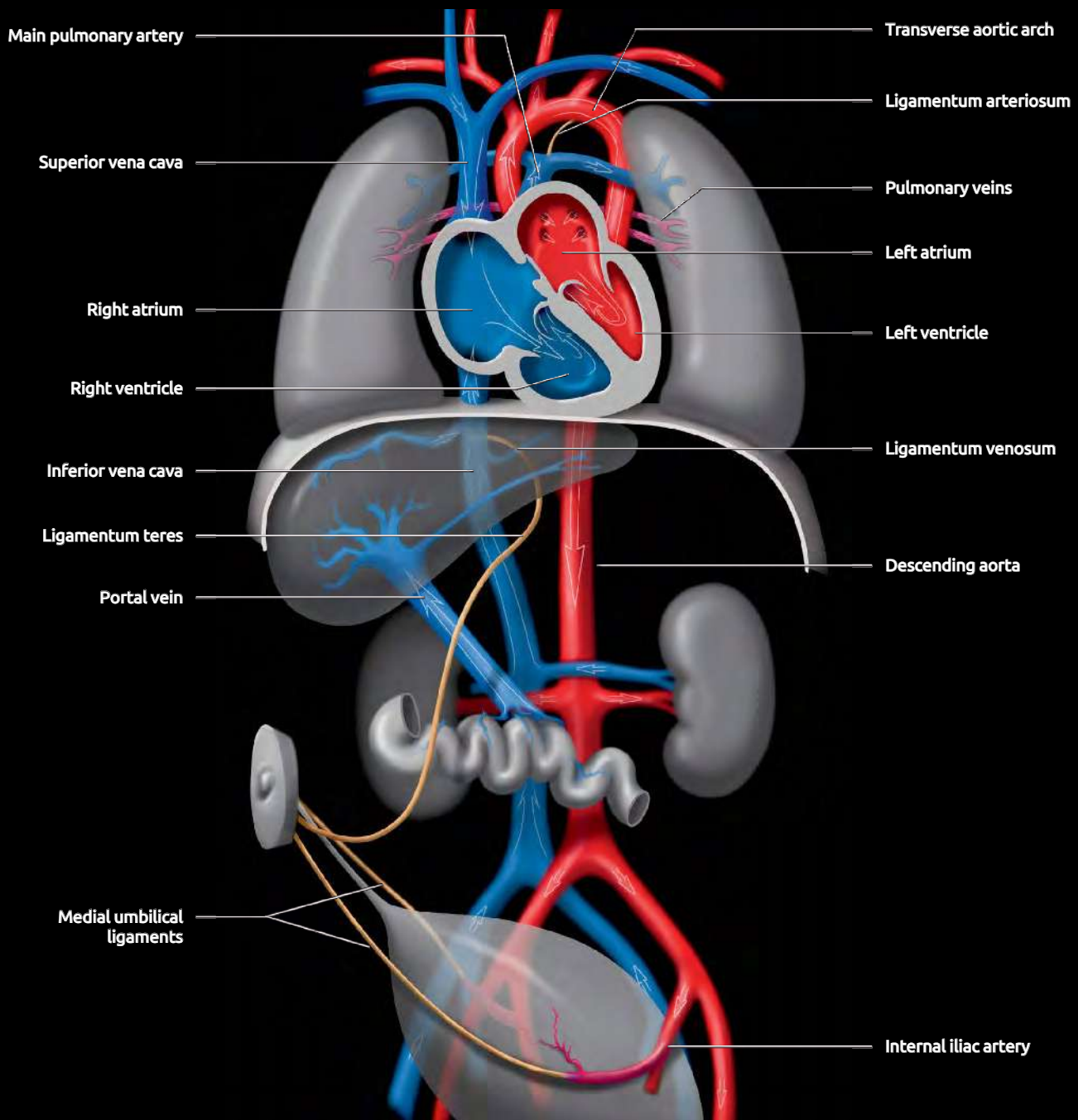
(Top) Graphic illustrates the anatomic variant of a persistent left superior vena cava. This occurs when the left anterior cardinal vein fails to involute. The left superior vena cava drains into the right atrium via the coronary sinus, which is enlarged due to the increased volume of blood entering it. Enlargement of the coronary sinus is visible on the 4-chamber heart view. **(Middle)** Sagittal view of left superior vena cava draining to a dilated coronary sinus and into the right atrium is shown. Be careful to check for anomalous pulmonary venous return to the coronary sinus, another important cause of dilation of this structure. **(Bottom)** 4-chamber view with a dilated coronary sinus (*) is shown. This finding is suspicious for a persistent left superior vena cava.

FETAL CIRCULATION



In the fetus, blood is oxygenated by the placenta and returns to the heart via the umbilical vein. This highly oxygenated blood (red) shunts through the ductus venosus and streams across the foramen ovale to the left side of the heart, supplying the head. Deoxygenated blood (blue) returns to the right atrium via the superior and inferior vena cavae. This blood preferentially flows to the right ventricle, which pumps a small amount to the pulmonary arteries but most across the ductus arteriosus.

POSTNATAL CIRCULATION



In adult circulation, blood is oxygenated in the lungs and returns to the left heart via the pulmonary veins. The left heart pumps to the body via the aorta and its branches. Deoxygenated blood returns via the superior and inferior vena cavae to the right side of the heart, which pumps deoxygenated blood to the lungs for gas exchange. The umbilical arteries become the medial umbilical ligaments, the umbilical vein becomes the ligamentum teres, and the ductus arteriosus becomes the ligamentum arteriosum.

Imaging Techniques and Normal Anatomy

Many professional societies have published specific recommendations for imaging the fetal heart. In particular, in the United States, the current procedural terminology (CPT) codes for standard and complex obstetric ultrasound include specific criteria for cardiac images. In the standard scan, the goal is to document the 4-chamber view and both outflow tracts. Additional cardiac images required for the complex scan are the 3-vessel view, the aortic arch, and the bicaval view.

Determination of the fetal position by establishing left and right, anterior and posterior, and superior and inferior aspects of the fetus is vital. One cannot rely on position of the organs, since their position may vary from normal, especially in cases of heterotaxy. Once left and right are established, the heart and stomach can be used as points of reference in addition to the fetal spine.

After the position in the maternal pelvis is determined, and there is correct identification of left and right, one should start with a transverse (axial) cut through the fetal chest. A sweep in this orientation in a normal fetus will show the stomach and heart on the left with the inferior vena cava draining into the right atrium. Sweeping cephalad, a **4-chamber view** of the heart can be obtained. To obtain a true cross section of the thorax, rotate the transducer until only one rib is seen on each side. The 4-chamber view should show the **crux** [point between the two atrioventricular (AV) valves and the atrial and ventricular septum] of the heart. Tipping caudad from this image shows the **coronary sinus** and tipping cephalad shows the **left ventricular outflow tract and aortic valve**.

Continuing to sweep cranially from the left ventricular outflow tract in the transverse plane, the **right ventricular outflow tract** and pulmonary valve are seen. In the normal heart, the pulmonary valve is leftward and anterior to the aortic valve and gives rise to the pulmonary artery that crosses over the aorta at a right angle. In the 3-vessel view, the **ductus arteriosus** will be directed straight posteriorly toward the descending aorta, the ascending aorta will be seen rightward of main pulmonary artery and the superior vena cava (SVC) will be seen to the right of the aorta in cross section as it enters the right atrium. Continuing the axial sweep, the transverse aortic arch will be seen cranial to the ductus arteriosus.

The **great arteries** are distinguished from each other by their morphological features rather than their connections to the heart. The **main pulmonary artery** branches shortly after the valve into the right and left pulmonary arteries as well as the ductus arteriosus, whereas the **aorta** gives rise to head and neck vessels (going superiorly toward the head) some distance from the valve apparatus. In addition, the aortic arch is located superior to the ductal arch.

Rotating 90° from the 4-chamber view to a sweep in the sagittal plane produces the short-axis view of the ventricles as well as the **bicaval, ductal arch, and aortic arch views** with slight adjustments in the transducer position.

The ability to obtain all of these views is the first step in the evaluation of the fetal heart. The second, and maybe more important, step is the ability to recognize the structures and to determine whether they are normal. The **normal findings in the fetal heart** are as follows.

- Heart is located on left in fetal chest at an axis of 45° (+/- 15°)

- There are 2 atria and 2 ventricles that are ~ equal in cavity size and wall thickness
- There are 2 atrioventricular valves (tricuspid opens into right ventricle and the mitral opens into left ventricle) that are similar in size, open freely, and are slightly offset from one another with tricuspid displaced apically
- Atrial and ventricular septum attach to "crux" and are intact except for foramen ovale, which allows oxygenated blood from placenta to be directed to left atrium
- 2 lower pulmonary veins can be seen draining into left atrium on 4-chamber view
- Morphologic right ventricle should be anterior ventricle, right of chest; it is identified by septal attachments of tricuspid valve as well as thickened moderator band
- Morphologic left ventricle should be posterior ventricle, more leftward in chest it is smooth-walled and associated mitral valve has attachments to free wall only
- Both ventricles reach apex and contract equally well
- Great vessels are seen crossing each other as they exit heart with pulmonary artery being located anterior to aorta
- Ductal and aortic arches are widely patent with antegrade flow

Approach to Fetal Heart

Determination of situs is required prior to the fetal cardiac evaluation. The axial views obtained from sweeps cranially and caudally from the 4-chamber view are sufficient to identify almost all normal features of the fetal heart, as well as many of the abnormalities.

Are the Heart and Stomach on the Same Side?

The stomach and cardiac apex are normally on the left. If both are on the right, one needs to consider complete situs inversus, which has a good prognosis. If, however, the heart and stomach are located on opposite sides, heterotaxy or situs ambiguous is present. Heterotaxy carries a very high likelihood of complex congenital heart disease.

Is the Cardiac Axis Normal?

The heart lies in the left chest with its axis at approximately 45° (the axis is identified by drawing a line from the spine to the sternum and a separate line along the axis of the interventricular septum). There is some variation in the normal fetus with ranges from 30-60°. If the axis is abnormal, one needs to determine if the heart is being "pushed" or "pulled" to one side. Very rarely the heart is located outside the thorax (ectopia cordis). Conditions that may "push" or displace the heart are congenital diaphragmatic hernia and congenital pulmonary airway malformations. The heart may be "pulled" to one side if a lung is hypoplastic.

Is the Heart Size Normal?

The heart occupies about 1/2 of the circumference of the chest with a normal range being 0.55 ± 0.05 . An increased ratio usually indicates that the heart is dilated (cardiomegaly), but it may also occur when the chest is small due to thoracic dysplasia. Causes of cardiomegaly can be both cardiac and noncardiac.

There are multiple cardiac causes of cardiomegaly.

Enlargement of multiple chambers is seen with intrinsic cardiomyopathy or secondary to arrhythmia. Isolated right atrial dilation secondary to leakage of the tricuspid valve from Ebstein anomaly can drastically increase the total cardiac

circumference. Left ventricular enlargement can be seen with critical aortic stenosis. Right ventricular enlargement is seen with coarctation of the aorta and premature ductal constriction.

Noncardiac causes of cardiomegaly are typically from volume overload and come in 2 main categories: Twin-related heart failure and vascular shunting. In a multiple pregnancy, one needs to evaluate chorionicity as twin-twin transfusion and twin reversed arterial perfusion only occur with monochorionic placentation. Heart dilation can also be seen with volume overload from an absent ductus venosus or sources of vascular shunting, including sacrococcygeal teratoma, chorioangioma, and vein of Galen malformation. Finally, anemia can cause cardiomegaly due to the creation of a high-output state.

Is There Chamber Asymmetry?

In general, the two **atria** are approximately equal in size. This is typically estimated visually, but they can be measured and compared to normative values. The left atrium can be small in total anomalous pulmonary venous drainage. The right atrium may be very large in the setting of severe tricuspid regurgitation, as noted above.

The two **ventricles** are also approximately equal in size in the normal fetus. In cases of asymmetry, you must determine if one is enlarged or the other is hypoplastic; surprisingly, such a distinction can often be challenging. Using normative values for AV valve diameter can be helpful along with any associated defects. Whether or not both ventricles are apex forming (i.e., both reach the apex of the heart) should be evaluated in multiple planes. There may be only a single ventricle. If so, morphology should be determined.

The two **AV valves** are comparable in size with the tricuspid slightly larger than the mitral in the normal heart. The tricuspid should also be apically displaced compared to the mitral. AV valves in the same plane should raise suspicion of an atrioventricular canal type defect. If there is only one AV valve, is it the tricuspid or mitral valve? This determination helps identify which ventricle did not form correctly.

A single ventricle with one AV valve raises concern for hypoplastic left heart syndrome or tricuspid atresia. Rarely, two atrioventricular valves may drain into a single left ventricle, a condition called double inlet left ventricle.

A single common AV valve draining into two ventricles is likely an **atrioventricular septal defect** also known as **AV canal**. This is a situation in which the single AV valve does not separate into two discrete valves during heart development. In the complete form, it coincides with atrial and ventricular septal defects. In the partial form, there is only a primum atrial septal defect. Common AV valves can be "balanced" or "unbalanced" over the ventricular septum. If AV valve commitment is equal to both ventricles, it is balanced, if flow is committed more to one ventricle, it is unbalanced. The degree to which they are unbalanced determines whether the heart will function as a single ventricle or the normal two ventricles after repair.

Is There Great Vessel Asymmetry?

Detailed assessment of the great arteries is critical as many complex cardiac diseases may have a normal 4-chamber view. First, determine if there are one or two great vessels and where they are located in relation to the ventricular septum. Only **one great vessel** suggests the fetus has either **truncus**

arteriosus or atresia of a semilunar valve (**pulmonary or aortic atresia**). Semilunar valve atresia with an intact ventricular septum should cause recognizable pathology to the respective ventricle, namely a small or hypoplastic chamber. With a ventricular septal defect (VSD), however, ventricular size may appear normal even with atresia or stenosis of the semilunar valve. The valve annulus may also appear normal in plate-like atresia or critical stenosis, so color Doppler is required to determine direction of and restriction to blood flow.

The great vessels normally cross as they exit the heart. If they exit in a side-by-side fashion, this is always abnormal and is most commonly due to **transposition**. In the sagittal plane, seeing the head and neck vessels come off the anterior great vessel is also abnormal and concerning for transposition.

If the aortic valve is patent but the ascending aorta seems small, look for **coarctation** or an **interrupted aortic arch**. An interrupted arch will have a ventricular septal defect and a small ascending aorta giving rise to one or more head and neck vessels. The descending aorta is wholly supplied by the ductus arteriosus with no flow connecting the ascending to descending aorta.

What About Doppler?

Color Doppler should be employed in all fetal cardiac evaluations. The physics of Doppler is such that the best images are obtained when the ultrasound beam is as close to parallel to the flow of blood as possible. If the beam is perpendicular to the direction of blood flow, there will be an inadequate Doppler signal despite normal flow. Ideally, color Doppler evaluation should take place in a **sequential fashion from venous to arterial flow**.

Start with flow in the umbilical vein, artery, and the ductus venosus. Flow in the inferior vena cava and SVC should be followed into the right atrium. Documentation of flow from right to left at the **foramen ovale** is very important because reversal of flow suggests left-sided outflow tract obstruction.

Laminar flow across both AV valves in diastole should be documented as well as the absence of valve regurgitation in systole. Interrogation of the ventricular septum by color Doppler also helps to identify ventricular septal defects, which may be too small to see by 2D imaging alone.

The pulmonary veins should be shown by color Doppler and be interrogated by pulsed Doppler to confirm entrance into the left atrium. Forward flow should be shown across the pulmonary and aortic valves and one should look for regurgitation. Normal flow in the ductus arteriosus is right to left; however, in the setting of **pulmonary atresia**, the flow will be retrograde from the aorta into the pulmonary artery. In the setting of **aortic atresia**, flow to the head and heart will be retrograde around the aortic arch from the ductus arteriosus.

Pulsed Doppler is helpful as an adjunct to color Doppler because it confirms direction of flow, pattern of flow (venous or arterial), and velocity of flow that varies according to the site being interrogated. Pulsed Doppler also allows you to obtain a **mean velocity across any valve**. This can be used to calculate the **volume of blood** crossing the valve ($Q = V_{\text{mean}} \times \pi \times D^2/4$). This can be helpful when an assessment of cardiac output is needed in the setting of poor ventricular function or when tracking cardiac function in twin-twin transfusion syndrome.

What About Heart Rate?

Rhythm disturbances are fairly frequent findings on routine scans but most are benign and self-limiting. The ability to identify a benign rhythm disturbance is critical to those who perform routine obstetric ultrasounds. Sometimes, arrhythmias are observed on grayscale evaluation of the 4-chamber view, but M-mode and pulsed Doppler techniques will help you identify the exact nature of the arrhythmia. Detailed analysis of the cardiac rhythm requires accurate measurement of the heart rate, the relationship between atrial and ventricular contractions, and measurement of the time intervals between specific events in the cardiac cycle.

In **M-mode**, a single static line is placed through the atrium and ventricle simultaneously; movement is plotted against time to allow measurement of the heart rate and comparison of timing. Using **pulsed Doppler**, the sample volume can be placed in the left ventricular inflow (flow across the mitral valve) adjacent to the outflow (across the aortic valve) such that both tracings can be obtained at the same time. This allows identification of the normal beats, but it also allows one to see an early atrial beat (and whether or not it is conducted) as well as early ventricular beats. Other areas may be used for

similar purposes, such as the SVC-aorta, which is excellent for measuring the PR interval.

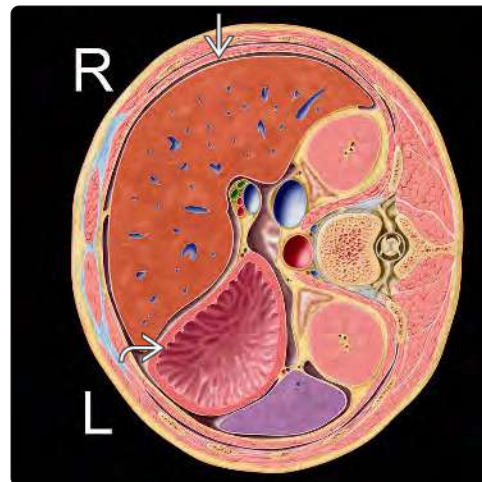
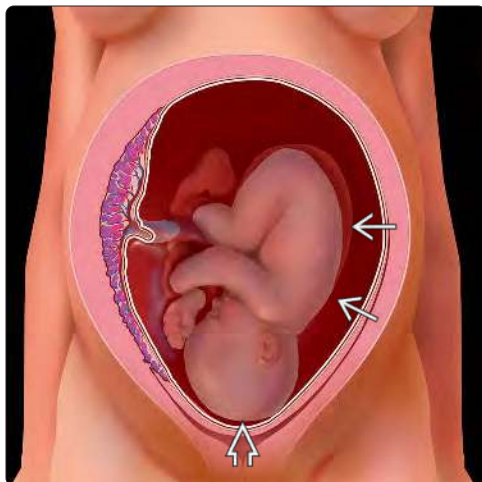
Clinical Implications

Congenital heart disease is strongly associated with aneuploidy, and even when chromosomes are normal, it may be the index finding leading to diagnosis of a specific syndrome. Prenatal diagnosis with planned delivery in a facility with appropriate expertise maximizes the potential for a good outcome in operable cases.

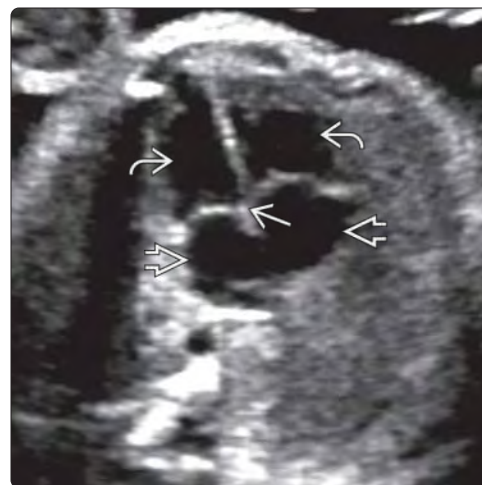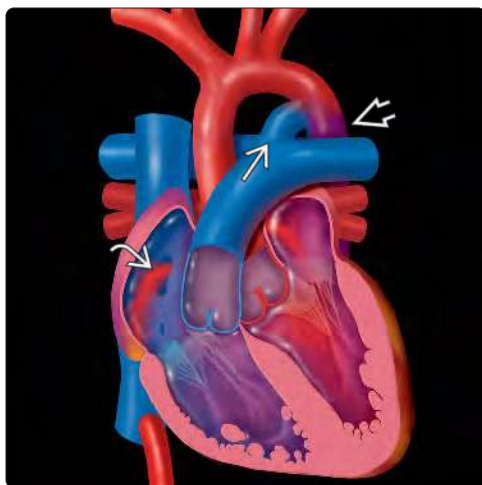
Selected References

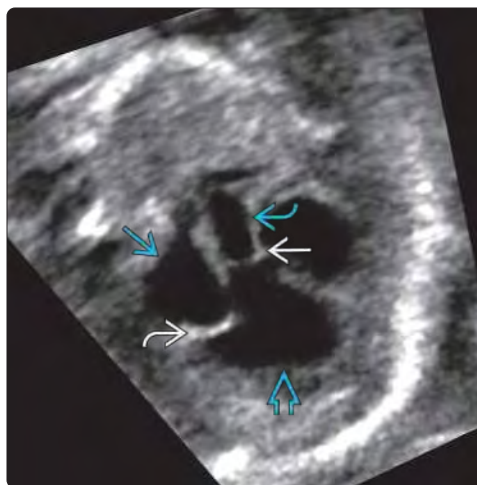
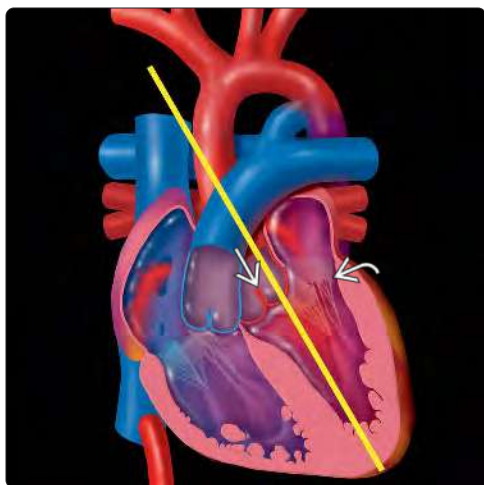
1. Donofrio MT et al: Diagnosis and treatment of fetal cardiac disease: a scientific statement from the American Heart Association. *Circulation*. 129(21):2183-242, 2014
2. Wacker-Gussmann A et al: Diagnosis and treatment of fetal arrhythmia. *Am J Perinatol*. 31(7):617-28, 2014
3. American Institute of Ultrasound in Medicine: AIUM practice guideline for the performance of fetal echocardiography. *J Ultrasound Med*. 32(6):1067-82, 2013

(Left) Graphic shows the steps needed to determine fetal situs. This fetus is in cephalic presentation with the spine to the maternal left. In this position, the fetal right side is closest to the maternal abdominal wall, while the fetal cardiac apex and stomach should be toward the maternal spine. (Right) An axial section through the same fetus' abdomen shows situs solitus with the liver on the right and the stomach on the left. The cardiac apex should be on the same side as the stomach.

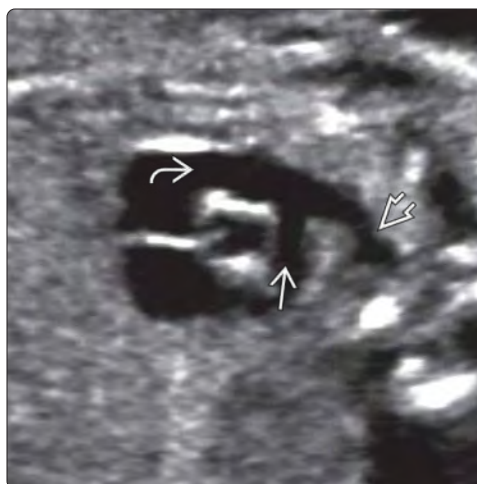
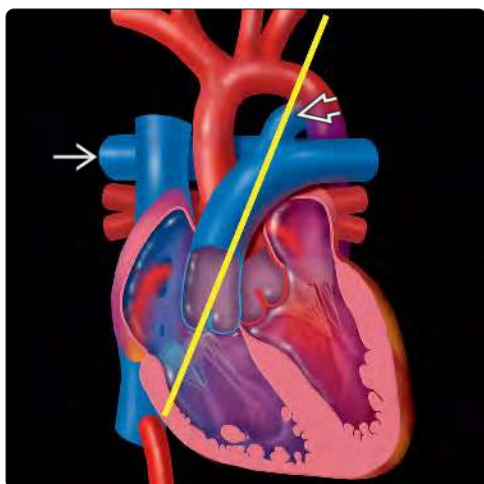


(Left) Graphic illustrates the normal fetal heart and circulation. Richly oxygenated blood from the UV is shunted across the foramen ovale to the left atrium and on to the aortic arch, selectively perfusing the brain and myocardium. Most of the RV output bypasses the lungs, entering the ductus arteriosus to join the descending aorta. (Right) Four-chamber view echocardiogram clearly displays the "crux" of the heart separating the 2 atrioventricular valves and the atria from the ventricles.

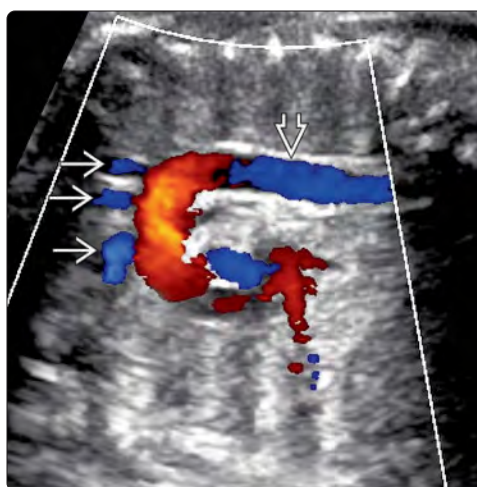
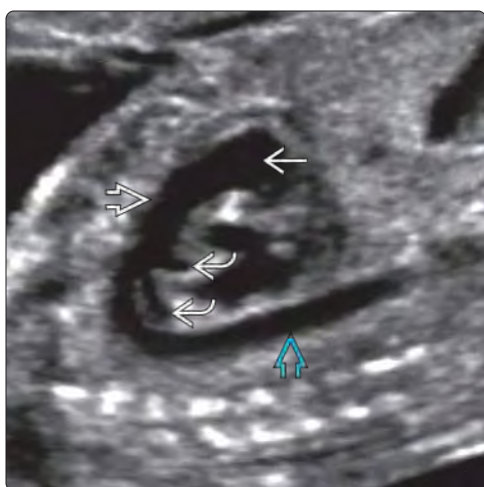




(Left) Graphic illustrates the scan plane for the left ventricular outflow tract (LVOT) view along the axis of the left ventricle and aortic root. The mitral valve separates the left atrium and left ventricle. (Right) LVOT echocardiogram shows the mitral valve, which is in fibrous continuity with the aortic valve. This view was obtained by tipping cranially from the 4-chamber view. The path of blood flow is from the left atrium to the left ventricle to the ascending aorta.

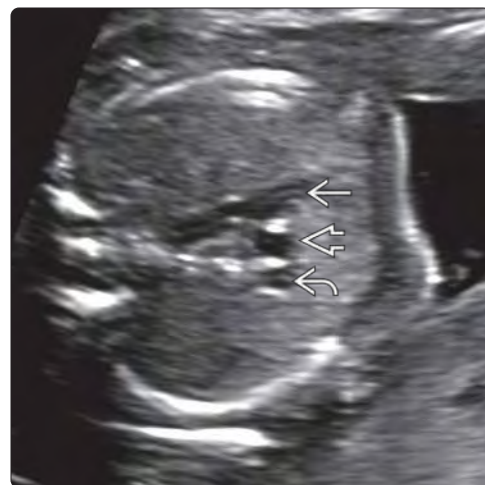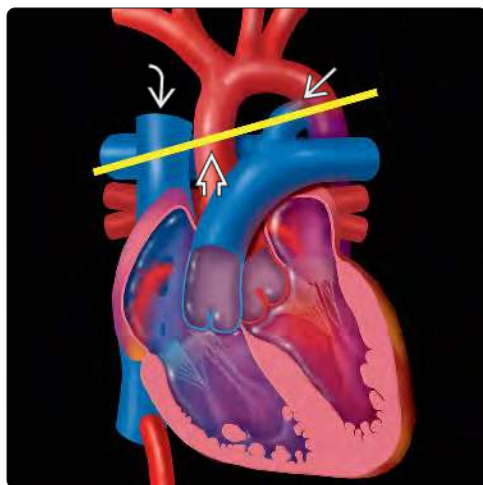


(Left) Graphic illustrates the scan plane for the right ventricular outflow tract (RVOT) view along the axis of the main pulmonary artery. In the fetus, the "bifurcation" seen around the aortic root is between the ductus arteriosus and the right pulmonary artery. (Right) Short-axis echocardiogram at the level of the aortic valve is shown. Note the main pulmonary artery with early branching into the ductus arteriosus and right pulmonary artery as well as a widely patent right ventricular outflow tract.

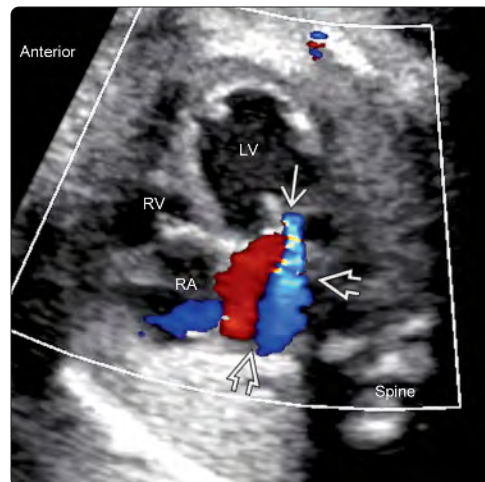
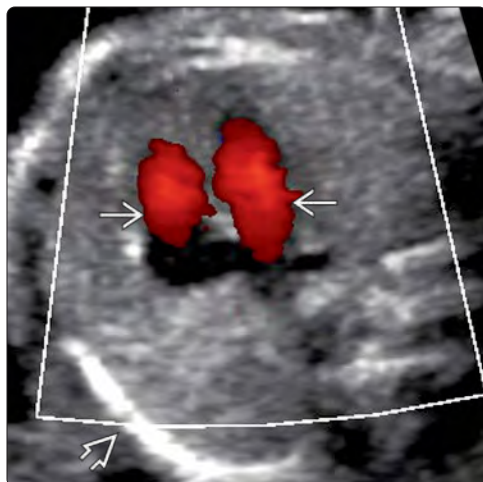


(Left) Ductal arch view of the RVOT shows the right ventricle extending through the main pulmonary artery and ductal arch and continuing on to the descending aorta. Note both branch pulmonary arteries arising off the main pulmonary artery. (Right) Color Doppler in the plane of the aortic arch shows the entire aorta almost to the diaphragm. One can see flow in all 3 head and neck vessels directed superiorly toward the head. Also note the color change as flow wraps around the transverse arch.

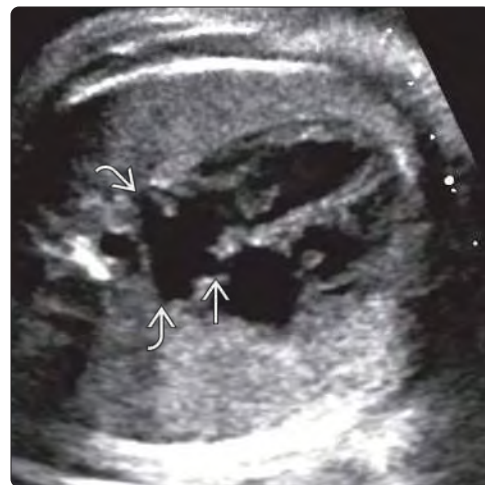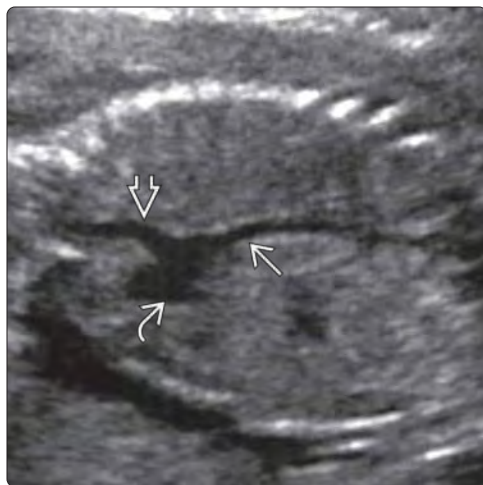
(Left) Graphic illustrates the scan plane to obtain the 3-vessel view, which is another way to look at the outflow tracts. This is part of the transverse sweep from the 4-chamber view showing the superior vena cava, aorta, and ductus arteriosus. (Right) The 3-vessel view shows the main pulmonary artery giving rise to the ductus arteriosus, which is directed straight posterior to the descending aorta, the aorta, and the superior vena cava.

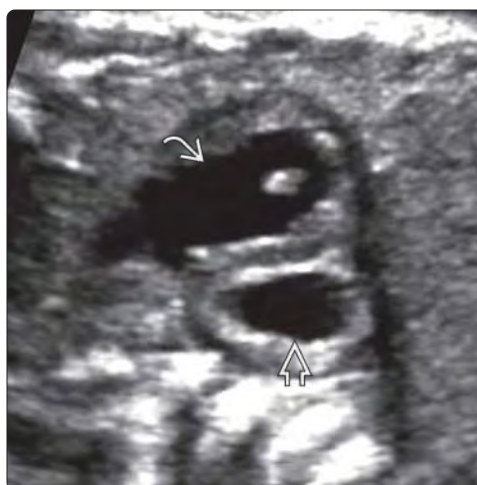
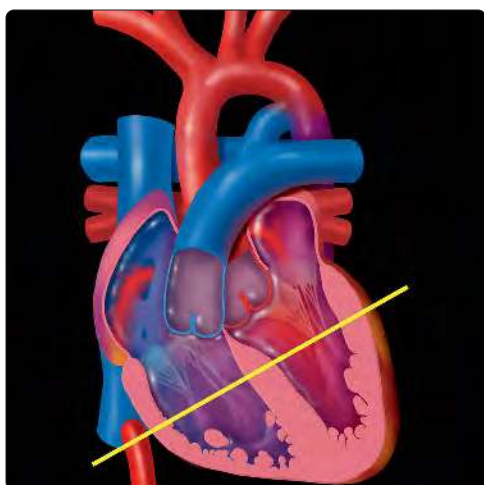


(Left) Color Doppler shows normal flow across the AV valves into both ventricles, without stenosis, regurgitation, or communication between the chambers to suggest a ventricular septal defect. Also note the full rib confirming correct scan plane. (Right) This 4-chamber view with color Doppler in critical aortic stenosis shows a dilated left ventricle (LV). Mitral regurgitation due to poor ventricular functions cause a jet of flow swirling back into the left atrium.

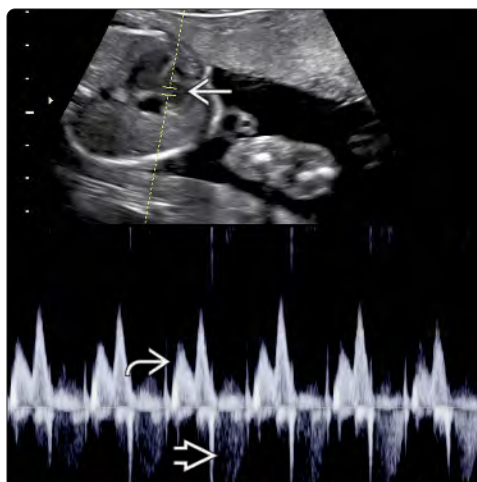
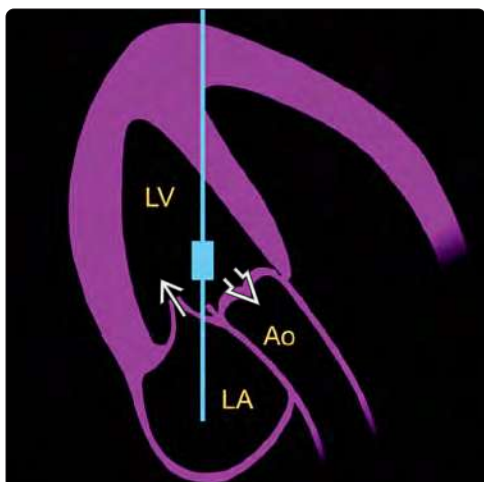


(Left) Sagittal echocardiogram angled rightward gives a nice bicaval view. One can see the inferior vena cava and superior vena cava as they drain into the right atrium. (Right) Four-chamber view highlights the foramen ovale, which allows the stream of oxygenated blood from the UV to flow from right to left. Two pulmonary veins are also seen draining into the left atrium.

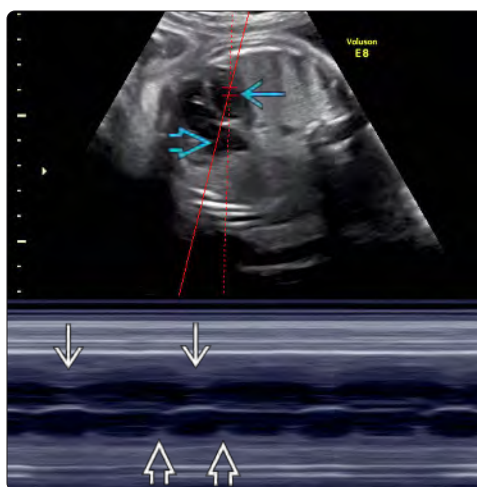
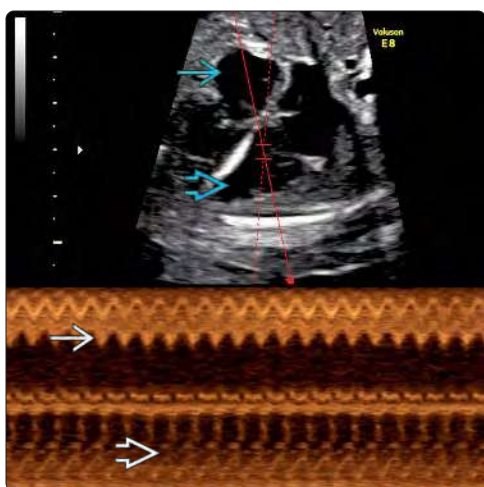




(Left) Graphic illustrates the scan plane for the short-axis view of both ventricles. This is a coronal section through the heart and allows for side by side comparison of ventricular size and "squeeze." (Right) Short-axis echocardiogram shows the 2 ventricles in cross section. The left ventricle is located posterior to the right ventricle. This is a good plane to evaluate ventricular function.



(Left) Graphic shows a sample volume placed for pulsed Doppler assessment of rhythm. Inflow into the LV, toward the transducer, reflects the atrial rate. Ventricular outflow, away from the transducer, reflects the ventricular rate. (Right) Image shows the pulsed Doppler gate in the mitral inflow (waveform noted above the baseline), which gives the atrial rate. The gate is also picking up ventricular outflow noted below the baseline, allowing assessment of normal AV conduction.



(Left) Image shows the static line through the atrium and ventricle with the atrial contractions on top and the ventricular contractions on the bottom with 1:1 conduction in a patient with supraventricular tachycardia. (Right) Image shows the static line through the ventricle and the atrium. The M-mode allows one to clearly see ventricular contractions and atrial contractions in a fetus with complete heart block and a ventricular rate of 63.

KEY FACTS

TERMINOLOGY

- Heterotaxy syndrome
 - Abnormality where internal thoraco-abdominal organs demonstrate abnormal arrangement across left-right axis of body
 - Implies that laterality of internal organs is neither situs solitus (normal) nor situs inversus (mirror image of situs solitus)

IMAGING

- Heart and stomach on opposite sides
- Abnormal relationship of abdominal aorta and inferior vena cava (IVC)
- Large midline liver
- Cardiac anomalies occur at every level: Atrial, atrioventricular, ventricular, ventriculoarterial
- Anomalies occur in any combination but have patterns
 - Left atrial appendage (LA) isomerism
 - Right atrial appendage (RA) isomerism

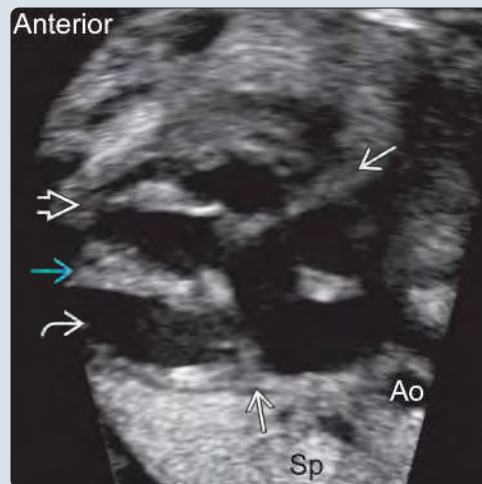
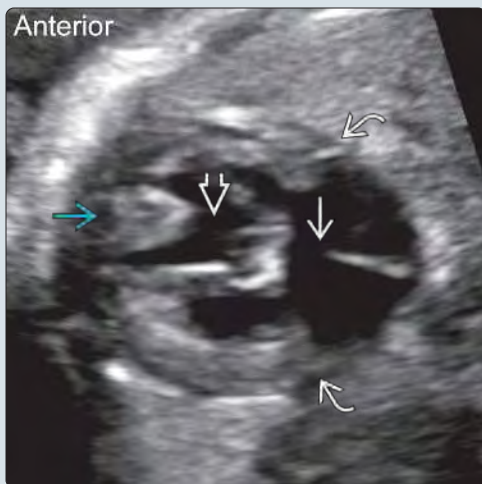
PATHOLOGY

- Heterotaxy is clinically and genetically heterogeneous
- Aneuploidy rarely coexists with heterotaxy syndromes

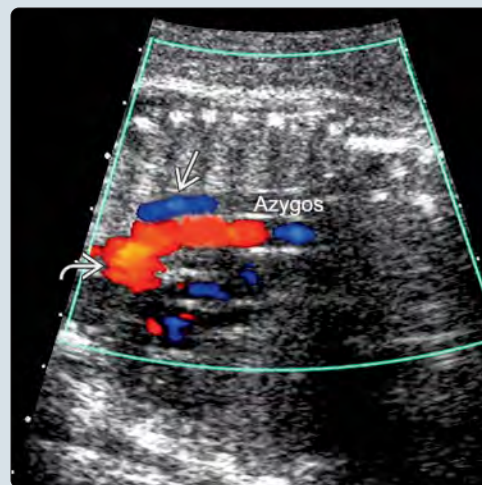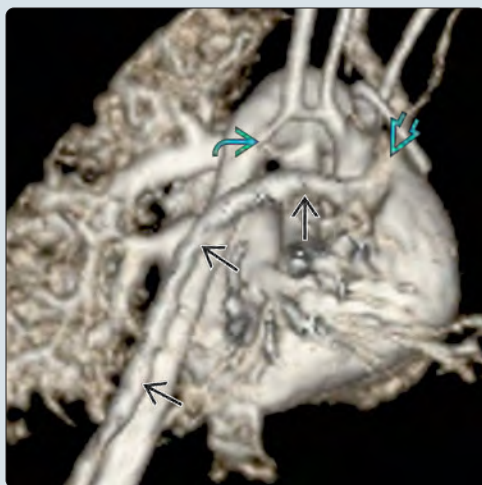
CLINICAL ISSUES

- LA isomerism more commonly diagnosed in utero
 - Associated complete heart block → hydrops → intrauterine fetal demise
- RA isomerism more common in postnatal series
 - Single ventricles with outflow tract abnormalities
- Outcomes depend on type and severity of associated cardiac malformation
 - Early survival has improved in current era but is still poor in single ventricles with total anomalous pulmonary venous return
 - Mortality and morbidity continue to be significant even after early neonatal period

(Left) Image shows a complete balanced atrioventricular canal with a large primum atrial septal defect and a large inlet ventricular septal defect. Note the common atrioventricular valve, which spans across the defects. The ventricular septum is noted. (Right) Four-chamber view shows unbalanced, right-dominant atrioventricular canal. Note ventricular septum. The common AV valve is more committed to the right ventricle than the left. (Note that Ao is descending aorta and Sp is spine.)



(Left) Image shows azygos continuation of the inferior vena cava to the right superior vena cava. Also note the severe coarctation with transverse arch hypoplasia. This patient had left atrial isomerism. (Right) Sagittal color Doppler echocardiogram shows normal antegrade flow within the aorta and cephalad flow in a very prominent azygos vein, which is seen posterior to the aorta. These findings are consistent with an interrupted inferior vena cava in a fetus with left atrial isomerism.



TERMINOLOGY

Synonyms

- Heterotaxy syndrome
- Visceral heterotaxy
- Situs ambiguus
- Terminology is confusing with multiple terms for similar anatomic combinations
 - Listed below are terms used for certain combinations of findings (not necessarily synonymous)
- Right atrial appendage (RA) isomerism
 - Asplenia
 - Bilateral right sidedness
- Left atrial appendage (LA) isomerism
 - Polysplenia
 - Bilateral left sidedness

Definitions

- Abnormality where internal thoraco-abdominal organs demonstrate abnormal arrangement across left-right axis of body
 - Implies that laterality of internal organs is neither situs solitus (normal) nor situs inversus (mirror image of situs solitus)

IMAGING

General Features

- Best diagnostic clue
 - Heart and stomach on opposite sides
 - Abnormal relationship of abdominal aorta and inferior vena cava (IVC)
 - Large midline liver
 - Complete heart block in presence of complex congenital heart disease (CHD)

Ultrasonographic Findings

- Grayscale ultrasound
 - Interrupted IVC in LA isomerism
 - Hepatic veins drain directly to atrium
 - Enlarged azygos vein (continuation of IVC) posterior to aorta
 - IVC anterior to aorta on same side of spine in RA isomerism
 - Bilateral superior vena cava (SVC)
 - Seen in both LA/RA isomerism
 - Abnormal stomach location
 - Right, left, or central depending on liver position
 - Midline liver
 - Gallbladder may be absent in LA isomerism
- Color Doppler
 - Look for splenic artery
 - Seen with polysplenia (LA isomerism)
 - Absent in asplenia (RA isomerism)
 - Identify and trace course of systemic and pulmonary veins

Echocardiographic Findings

- Dedicated fetal echo should be performed in all cases for more detailed cardiac evaluation
- Cardiac anomalies occur at every level
 - Atrial, atrioventricular (AV), ventricular, ventriculoarterial

- Anomalies occur in any combination but have patterns
 - Most common forms of CHD seen with each type of heterotaxy are listed below
- **Left atrial appendage (LA) isomerism**
 - Dextrocardia in 30-40%
 - Bilateral SVC in 40%
 - Interrupted IVC in > 70%
 - Anomalous pulmonary venous return, usually partial (PAPVR), in 20-40%
 - Common atrium/atrial septal defect (ASD) in 80%
 - Atrioventricular (AV) canal in 20-40%
 - Single ventricle in 10%
 - Left ventricular outflow tract obstruction in 40%
 - Conotruncal abnormalities in 15-30%
 - Pulmonary stenosis/atresia
 - Transposition of great arteries
- **Right atrial appendage (RA) isomerism**
 - Dextrocardia in 30-40%
 - Bilateral SVC in 50-70%
 - Total anomalous pulmonary venous return (TAPVR) in 50-70%
 - Common atrium/ASD in 90%
 - AV canal in 85%
 - Single ventricle in > 50%
 - Conotruncal abnormalities in 80%
 - Double outlet right ventricle (DORV)
 - Pulmonary stenosis/atresia
 - Transposition of great arteries

Imaging Recommendations

- Protocol advice
 - If heart and stomach are located on opposite sides of chest/abdomen
 - Look carefully for cardiac abnormalities
 - If you see 1 abnormality, look for 2
 - If you see 2 abnormalities, look for 8
 - Look for systemic and pulmonary venous abnormalities
 - Look for midline liver
 - Complete anatomic survey

DIFFERENTIAL DIAGNOSIS

Abnormal Cardiac Position

- Chest mass causing abnormal axis or dextroposition
 - Congenital diaphragmatic hernia (CDH)
 - Congenital pulmonary airway malformation
 - Bronchopulmonary sequestration
- Dextrocardia
- Complete situs inversus

Abnormal Stomach Position

- Malpositioned due to CDH or pulmonary agenesis

PATHOLOGY

General Features

- Genetics
 - Most cases are sporadic

- Genetically heterogeneous with at least 7 known heterotaxy genes (*NODAL*, *ZIC3*, *CFC1*, *FOXH1*, *LEFTY2*, *GDF1*, *ACVR2B*)
- Familial recurrences are seen with both dominant and X-linked recessive (*ZIC3*) inheritance
- Clinically heterogeneous, even within family members with same mutation
- Chromosome deletion/duplications or aneuploidy are uncommon causes
- Important to distinguish patients who have heterotaxy in context of primary ciliary dyskinesia (PCD), which has important additional respiratory treatment implications
- Associated abnormalities
 - **LA isomerism**
 - Bilateral left atrial appendages (finger-like)
 - Polysplenia in 96%
 - Both lungs bilobed with hyparterial bronchus
 - Malpositioned stomach
 - Malrotation of intestines ~ 70%
 - Centrally placed, abnormally shaped liver
 - Extrahepatic biliary atresia
 - Absent/hypoplastic or midline gallbladder
 - Absence of sinoatrial node
 - Often in junctional rhythm or heart block
 - **RA isomerism**
 - Bilateral right atrial appendages (pyramidal shape)
 - Asplenia in 74%
 - Both lungs trilobed with eparterial bronchus
 - Centrally placed globular liver
 - Stomach either midline or left in 60%
 - Malrotation of intestines ~ 70%
 - Presence of 2 sinoatrial nodes; often with supraventricular tachycardia
- Broad spectrum of abnormalities fit with heterotaxy category
 - Dextrocardia + abdominal situs solitus
 - Levocardia + abdominal situs inversus
 - Also documented cases of isomerism with normal spleen
- Embryology
 - Midline developmental field defect or laterality sequence
 - Embryonic insult between days 28-35
 - Sequence of cardiac development arrested in 5th-week gestation

CLINICAL ISSUES

Presentation

- Most common signs/symptoms
 - In fetus
 - Abnormal situs
 - Interrupted IVC with azygous continuation
 - Midline liver
 - 2 or more types of CHD
 - Heart block
 - At birth
 - Presentation is highly variable from acyanotic to cyanotic
 - Abnormal chest x-ray due to alteration in organ position

Demographics

- Epidemiology
 - M:F = 1:2 in LA isomerism
 - M:F = 2:1 in RA isomerism
 - ~ 4% of all infants with CHD
 - ~ 30% of cardiac malpositions in infants
 - LA isomerism more commonly diagnosed in utero
 - Associated complete heart block → hydrops → intrauterine fetal demise
 - RA isomerism more common in postnatal series

Natural History & Prognosis

- Depends on type and severity of associated cardiac malformation
 - Early survival has improved in current era
- Biventricular repair has better long-term outcome than single ventricle
- Associations with increased mortality
 - Obstructed pulmonary veins
 - Moderate or greater AV valve regurgitation
 - Single ventricles
- Survival in liveborn infants
 - 64% 5-yr survival
 - 57% 10-yr survival
 - 53% 15-yr survival
 - 57% survival to hospital discharge if TAPVR with single ventricle
- Morbidity continues to be factor
 - Arrhythmias, thromboembolic events, bowel obstruction, infection

Treatment

- Consider karyotype if multiple anomalies in addition to CHD
- Detailed genetic history
- Prenatal consultation with neonatology/pediatric cardiology
- Delivery in tertiary care facility
 - Prostaglandins may be necessary for survival with duct-dependent lesions
 - Emergent surgery required for obstructed TAPVR
- Surgery for outflow tract obstruction necessary in 1st week of life
- Additional surgery for single ventricle palliation within 6 months
- Additional surgery for complex systemic venous abnormalities may also be necessary

DIAGNOSTIC CHECKLIST

Consider

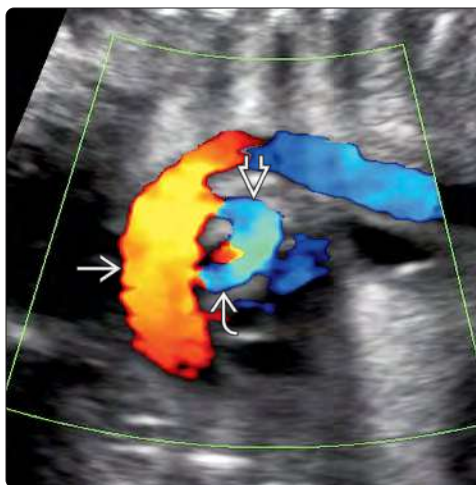
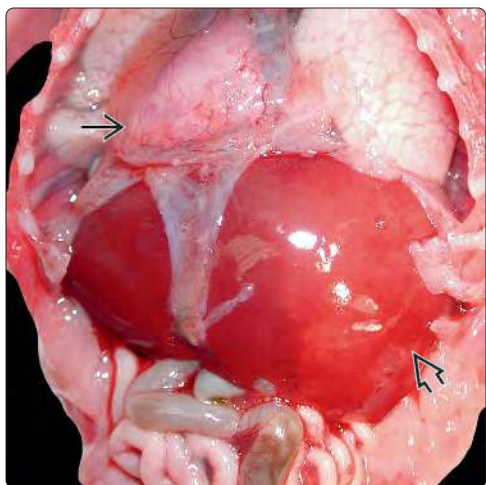
- Check situs in all fetal ultrasound scans

Image Interpretation Pearls

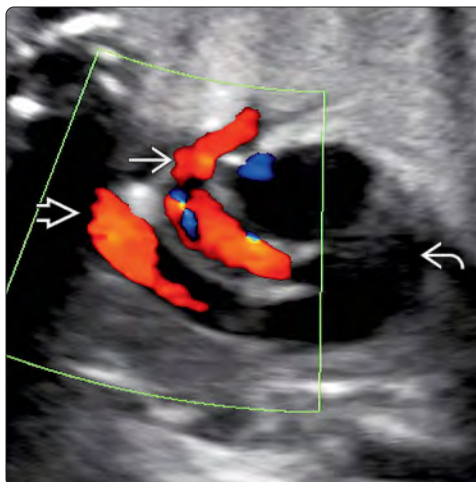
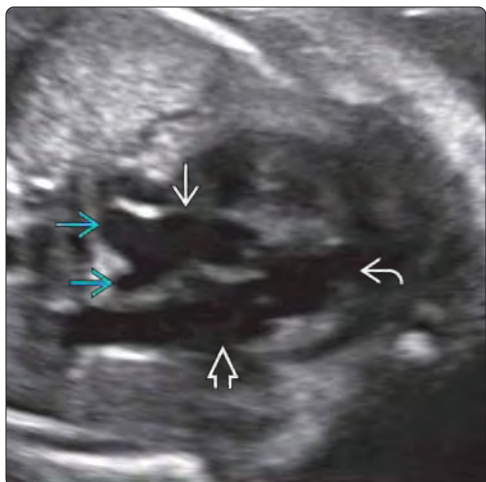
- ≥ 2 cardiac defects strongly suggests heterotaxy
- Interrupted IVC strongly suggests LA isomerism
- Single ventricle + AV canal + right outflow obstruction = RA isomerism

SELECTED REFERENCES

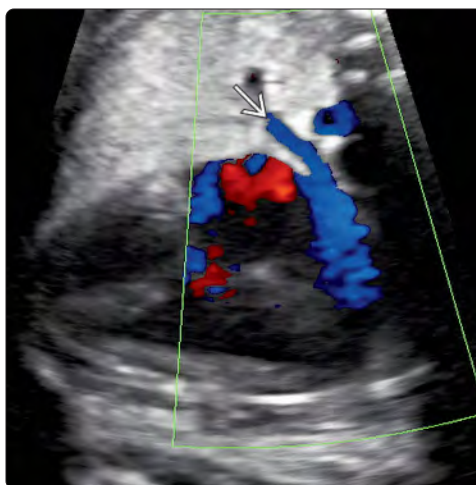
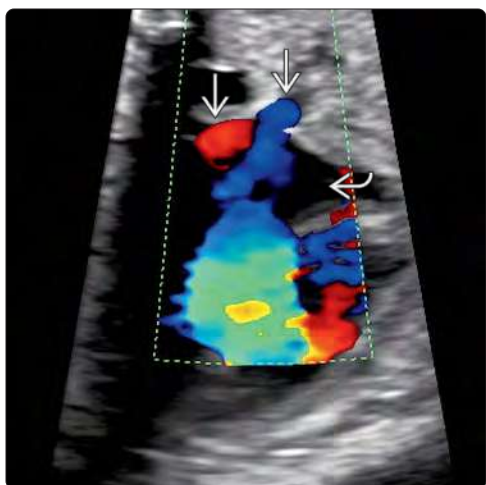
1. Gottschalk I et al: Extracardiac anomalies in prenatally diagnosed heterotaxy syndromes. *Ultrasound Obstet Gynecol*. ePub, 2015



(Left) Photograph from a fetal autopsy shows dextrocardia [arrow], a large midline liver with the bulk of the liver to the left [arrow]. The bowel was also malrotated. These findings are classic for right atrial isomerism. (Right) This image shows antegrade flow in the aortic arch [arrow] with retrograde flow to the pulmonary artery [arrow] via a reverse oriented ductus arteriosus [arrowhead] in a case of pulmonary atresia. Normally, the direction of flow in the ductal and aortic arches should be the same.



(Left) Outflow tract view (tipped anteriorly from the 4-chamber view) shows parallel great vessels arising from the right ventricle [arrow]. The pulmonary artery [arrow] (recognized by early branching) is posterior to the aorta [arrow] as in transposition. (Right) Color Doppler view in the same image plane shows flow out both the aorta [arrow] and the pulmonary artery [arrow] from the right ventricle [arrow]. This is a double outlet right ventricle, which is a common finding in right atrial isomerism.



(Left) Zoomed 4-chamber view shows pulmonary veins from the left [arrow] entering the left-sided atrium [arrow]. This finding does not mean that all pulmonary veins drain normally, so the right-sided veins must be looked for as well to exclude partial anomalous venous return. (Right) In the same patient, the pulmonary vein [arrow] (PV) from the right lung enters the right-sided atrium. The right lung PVs go to right-sided atrium and left lung to left-side atrium in left atrial isomerism because both are morphologically left atria.

KEY FACTS

TERMINOLOGY

- Anomaly in which fetal heart lies completely or partially outside thoracic cavity

IMAGING

- 1st-trimester diagnosis described at time of nuchal translucency screen
- Distinguish abnormal axis from abnormal location
- Look for specific features of
 - Body stalk anomaly
 - Fixed fetal/placental relationship essential for diagnosis
 - Amniotic band syndrome
 - Fine linear echoes of bands tethering fetus to uterine wall
 - Pentalogy of Cantrell
- Look carefully for additional abnormalities
 - Omphalocele increases suspicion for trisomy 18
- Refer for formal fetal echocardiography

- Prognosis at least partly determined by complexity of associated congenital heart disease (CHD)

TOP DIFFERENTIAL DIAGNOSES

- Sternal cleft
 - Prognosis dependent on coexisting congenital heart disease but good if isolated

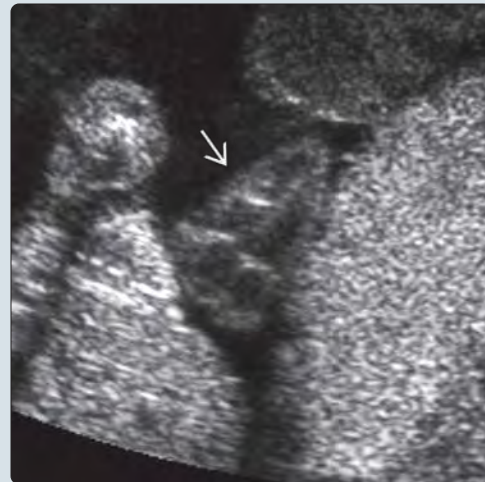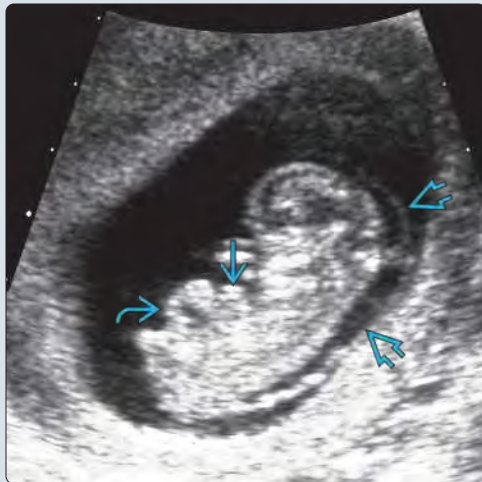
PATHOLOGY

- Subtypes based on location
 - Cervical (3-5%)
 - Thoracic (60-65%)
 - Thoracoabdominal (7-20%)
 - Abdominal (10-30%)
- 83% incidence of associated CHD
- Reported association with trisomy 18, triploidy, 45 X0

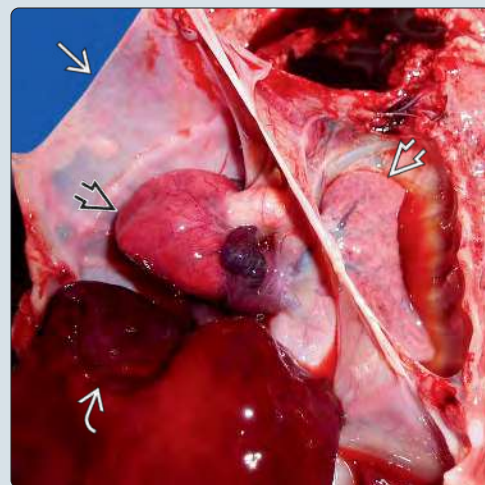
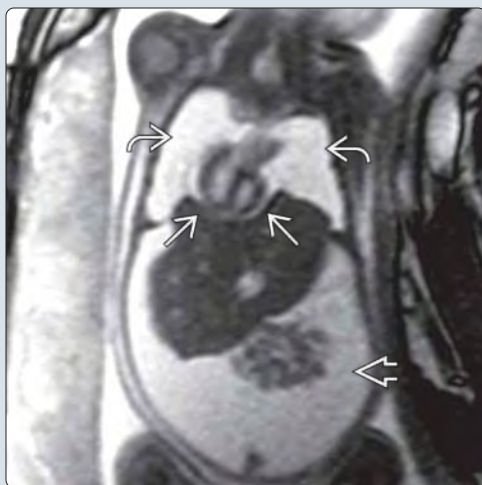
CLINICAL ISSUES

- Extremely poor prognosis
- Significant postoperative loss rate in surviving infants

(Left) Sagittal US in the 1st trimester shows a cystic hygroma, omphalocele, and ectopia cordis. Intrauterine demise occurred prior to planned CVS. **(Right)** This 4-chamber view is perfect apart from the fact that the heart is completely outside of the thorax, appearing to float in the amniotic fluid. On further inspection, an amniotic band stretched from the chest wall defect across the fetal face and anchored the heart in its external location. The infant died within hours of delivery.



(Left) Coronal T2WI MR shows a 3rd-trimester hydropic fetus. Note massive pleural effusions and ascites as well as the excavated contour of the liver. This fetus had abdominal ectopia cordis with the heart "nesting" into the liver. **(Right)** Gross pathology in the same case with the diaphragm elevated shows the intraabdominal heart, creating a defect in the liver dome. The hypoplastic left lung lies in a pool of pleural effusion fluid.



TERMINOLOGY**Definitions**

- Anomaly in which fetal heart lies completely or partially outside thoracic cavity

IMAGING**General Features**

- Best diagnostic clue
 - Heart seen in abnormal location

Ultrasonographic Findings

- 1st-trimester diagnosis described
 - Most with increased nuchal translucency
 - Associated with major malformations
 - Pentalogy of Cantrell
 - Body stalk anomaly
- Heart seen outside of thoracic cavity
- Lungs may be hypoplastic
- Doppler
 - Useful to confirm abnormal location of heart, particularly in 1st-trimester diagnosis
- 3D
 - Gives global perspective
 - Useful for parental counseling
 - Surface rendered images look more realistic than 2D "slices"

MR Findings

- MR may be helpful to look for other anomalies
- Assess extent of thoracoabdominal wall defect for surgical planning
- Lung area can be measured on T2WI
 - Summation of slices allows calculation of lung volumes
 - Normative data available
 - Technique important: Measure only lung not hilar vessels, mediastinal structures

Imaging Recommendations

- Protocol advice
 - Must distinguish abnormal axis from abnormal location
 - Abnormal axis usually due to mass effect
 - Heart is always intrathoracic, just displaced
 - ◻ Intrathoracic mass, such as diaphragmatic hernia, will "push" heart to opposite side of thorax
 - ◻ Lung agenesis/hypoplasia "pulls" heart toward side of abnormality
 - Careful search for additional findings to make specific diagnosis
 - **Amniotic band syndrome**
 - Unusual distribution of defects, not in recognizable pattern
 - Often severe craniofacial defects (usually lethal if cranium involved)
 - Limb or digit amputations
 - Limb constriction with distal edema
 - Band is in contact with deformity
 - Bands in amniotic fluid appear as thin membranes but may be difficult to discern
 - Change maternal position and look for areas of fetal tethering

Body stalk anomaly

- Complex lethal condition with multiple abnormal findings
- Umbilical cord short or absent
- Peritoneum open and in continuity with amnion, which reflects onto placenta surface
 - ◻ Scoliosis prominent feature
 - ◻ Fixed fetal/placental relationship essential for diagnosis
 - ◻ Usually fetus with ectopia cordis is mobile within amniotic sac

Pentalogy of Cantrell

- Specific syndrome with ectopia cordis described by Cantrell in 1958
 - ◻ Midline supraumbilical abdominal wall defect
 - ◻ Defect in diaphragmatic pericardium
 - ◻ Deficient anterior diaphragm
 - ◻ Defect in lower sternum
 - ◻ Congenital heart disease (CHD)

Additional anomalies increase suspicion for aneuploidy when present

- Omphalocele increases suspicion for trisomy 18
- Trisomy 18 associated with ectopia cordis even in absence of full spectrum of pentalogy of Cantrell

Refer for formal fetal echocardiography

- Structural malformations common
- Prognosis at least partly determined by complexity of associated CHD
- Great vessel anatomy important for planned surgical repair
- Measure chest circumference and track chest growth
 - Lung hypoplasia is bad prognostic indicator

DIFFERENTIAL DIAGNOSIS**Sternal Cleft**

- Clue to diagnosis is thinned, depressed midline anterior chest wall transmitting cardiac pulsation
- Heart is appropriately located within thorax
 - Skin covered
 - Pericardium intact
- Prognosis dependent on coexisting CHD
 - Isolated cleft has good prognosis

PATHOLOGY**General Features**

- Etiology
 - Many theories
 - Defective fusion of anterior chest wall
 - ◻ Failed fusion of paired cartilaginous bars of embryonic sternum
 - Abnormal fetal folding
 - Vascular disruption
 - Field defect
- Genetics
 - Usually sporadic
 - Reported association with
 - Trisomy 18
 - Turner syndrome (45, XO)
 - Triploidy

- 46XX 17q+
- Associated abnormalities
 - 83% incidence of CHD with ectopia cordis
 - Ventricular septal defect (100%)
 - Atrial septal defect (53%)
 - Tetralogy of Fallot (20%)
 - Left ventricular diverticulum (20%)
 - Variable incidence of conotruncal malformations
 - Kinked great vessels
 - Associated noncardiac malformations
 - Omphalocele (60%)
 - Facial clefting (10%)
 - Nonspecific dysmorphic appearance
 - Small thoracic cavity with hypoplastic lungs

Staging, Grading, & Classification

- Classified by location
 - Cervical (3-5%)
 - Thoracic (60-65%)
 - Most common subtype with heart displaced outside thoracic cavity through sternal defect
 - Partial: Heart is seen to pulsate through skin
 - Complete: Naked heart displaced outside thorax without pericardial coverage
 - Thoracoabdominal (7-20%)
 - Essentially same as pentalogy of Cantrell
 - Abdominal (10-30%)

CLINICAL ISSUES

Presentation

- Most common signs/symptoms
 - Sonographic detection of abnormal cardiac location
- Other signs/symptoms
 - Several reported cases of diagnosis at birth

Demographics

- Epidemiology
 - Ectopia cordis 5.5-7.9 per million live births in USA
 - Prenatal incidence higher due to termination/intrauterine fetal demise
 - 0.05% incidence in 15 yr of 1st-trimester screening exams
 - Pentalogy of Cantrell 1:65,000-200,000 births

Natural History & Prognosis

- Pentalogy of Cantrell
 - Depends on severity of intracardiac anomalies and associated malformations
 - Usually fatal if detected in fetus
- Sternal cleft
 - Can be surgically repaired
 - Excellent prognosis if heart structurally normal
- Long-term outcome of ectopia cordis hard to predict
 - Uniformly fatal outcome in series of 10 seen in 1 institution
 - 3 terminations
 - 1 intrauterine fetal demise
 - 1 died at birth
 - 5 died from days 4-37
 - Cardiac failure, cardiac arrest, sepsis

- 38.5% survival in series of 13 at another institution
 - Oldest survivor age 9 at time of report
 - All long-term survivors had staged repair
 - Provide soft tissue coverage of heart
 - Complete reduction of heart into thorax cavity
 - Repair of structural heart disease (may require several surgeries)
 - Chest wall reconstruction
 - Series of 7 with 1st-trimester diagnosis
 - 2 live births, longest survivor 3 months of age
- Significant postoperative loss rate
 - Overwhelming sepsis
 - Respiratory failure
 - Circulatory collapse
 - Inflow and outflow problems due to abnormal course of great vessels
 - Ventricular insufficiency secondary to CHD or resection of diverticulum
- Case reports in twins with good outcome for unaffected fetus

Treatment

- Formal fetal echocardiogram
- Offer karyotype
- Offer termination
 - If dichorionic twins, selective reduction with potassium chloride injection may be offered
- If pregnancy continues, options include
 - Comfort care with no intervention in labor
 - Planned delivery in tertiary care facility
 - C-section to avoid trauma to externalized heart
 - Attempted surgical repair

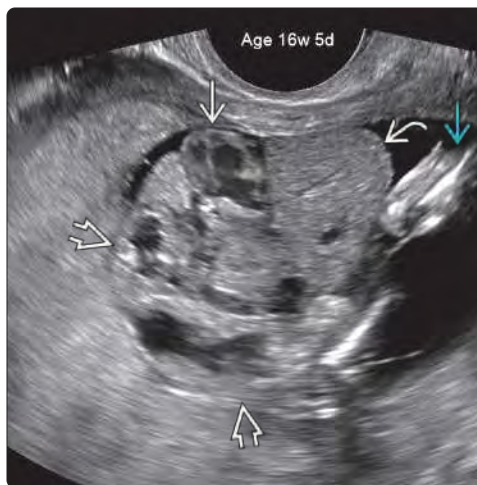
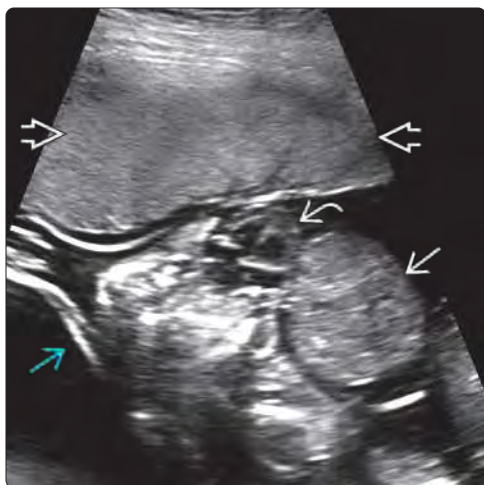
DIAGNOSTIC CHECKLIST

Consider

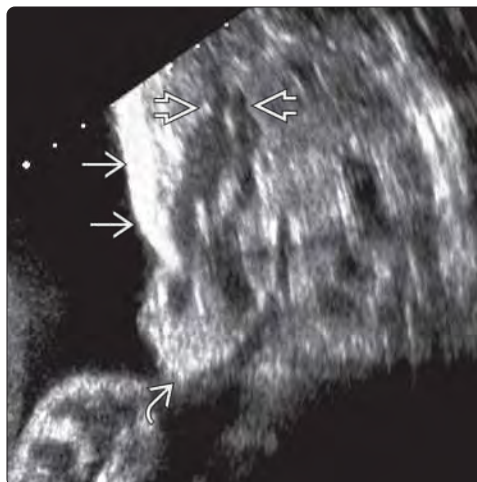
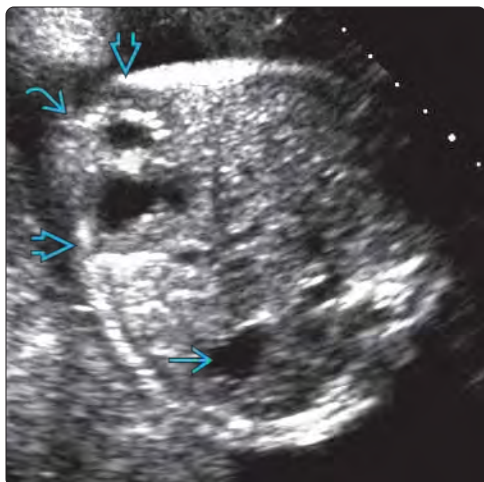
- Extremely poor prognosis
- Families need extensive counseling and support
- 3D reformatted images may be easier for families to understand

SELECTED REFERENCES

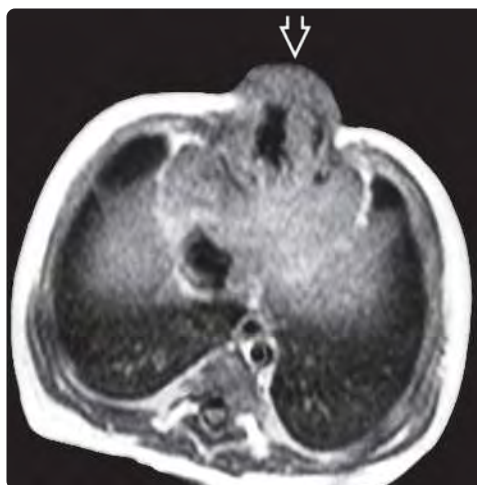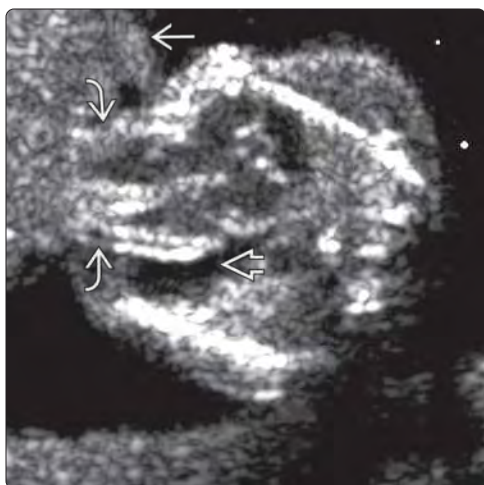
1. Zeidler S et al: Early prenatal disruption; a foetus with features of severe limb body wall sequence, body stalk anomaly and amniotic bands. *Genet Couns.* 25(3):315-20, 2014
2. Pepper MA et al: Thoracoabdominal wall defect with complete ectopia cordis and gastroschisis: a case report and review of the literature. *Pediatr Dev Pathol.* 16(5):348-52, 2013
3. Sepulveda W et al: Ectopia cordis in a first-trimester sonographic screening program for aneuploidy. *J Ultrasound Med.* 32(5):865-71, 2013
4. Sadlecki P et al: Prenatally evolving ectopia cordis with successful surgical treatment. *Fetal Diagn Ther.* 30(1):70-2, 2011
5. Balakumar K et al: Ectopia cordis with endocardial cushion defect: Prenatal ultrasonographic diagnosis with autopsy correlation. *Ann Pediatr Cardiol.* 3(2):166-8, 2010
6. Barbee K et al: First-trimester prenatal sonographic diagnosis of ectopia cordis in a twin gestation. *J Clin Ultrasound.* 37(9):539-40, 2009
7. Twomey EL et al: Prenatal ultrasonography and neonatal imaging of complete cleft sternum: a case report. *Ultrasound Obstet Gynecol.* 25(6):599-601, 2005
8. Ley EJ et al: Successful repair of ectopia cordis using alloplastic materials: 10-year follow-up. *Plast Reconstr Surg.* 114(6):1519-22, 2004
9. Humpl T et al: Presentation and outcomes of ectopia cordis. *Can J Cardiol.* 15(12):1353-7, 1999



(Left) The heart and liver in this twin (note intertwined membrane) are outside the body cavity but not adherent to the placenta. A normal cord made body stalk anomaly unlikely. Amniotic bands may not be immediately apparent but can be demonstrated (as in this case) by rolling the patient to float the fetus away from the uterine wall. (Right) TVUS shows exteriorized heart and liver with viscera adherent to the placenta. There was no normal cord (note lower extremity). This is an example of body stalk anomaly.



(Left) Transverse image through the upper abdomen shows the heart protruding from the body wall at the same transverse level as the gastric fundus. (Right) The same case viewed in a midline longitudinal plane shows an intact sternum with the heart protruding through the upper abdominal wall. This is an example of abdominal ectopia cordis. The distortion of the great vessels was such that repair failed and the infant died.



(Left) Axial US in a typical example of pentalogy of Cantrell shows the cardiac apex protruding from the chest into the top of an upper abdominal omphalocele. A small pericardial effusion is also seen. (Right) Axial T1WI MR in a liveborn infant with ectopia cordis shows a "naked" heart protruding through the chest wall skin and subcutaneous fat. Surgical repair is often staged and has to address not only the ectopia cordis but also any associated structural anomalies, which are common and often complex.

KEY FACTS

TERMINOLOGY

- Ventricular septal defects classified according to location
 - Membranous: Defect in outflow tract of left ventricle, immediately below aortic valve
 - Muscular: Defect in muscular portion of septum, anywhere from apex to base
 - Outlet: Defect in outflow tract of right ventricle, below pulmonary valve
 - Inlet: Located posterior and inferior to membranous septum, beneath septal leaflet of tricuspid valve

IMAGING

- Signal dropout in septum is potential pitfall
 - Try to image perpendicular to ventricular septum
 - Confirm on long-axis view if seen on apical 4-chamber view and vice versa
- Small muscular ventricular septal defects may not be visible on grayscale or color Doppler
- Color Doppler useful to confirm blood flow across defect

- Needs dedicated fetal echo, as associated cardiac abnormalities are present in 50%

PATHOLOGY

- Membranous (75%): Tetralogy of Fallot, double-outlet right ventricle (DORV)
- Muscular (10-15%): May be multiple
- Outlet (5%): Truncus arteriosus
- Inlet (5-8%): Component of atrioventricular septal defect (AVSD)

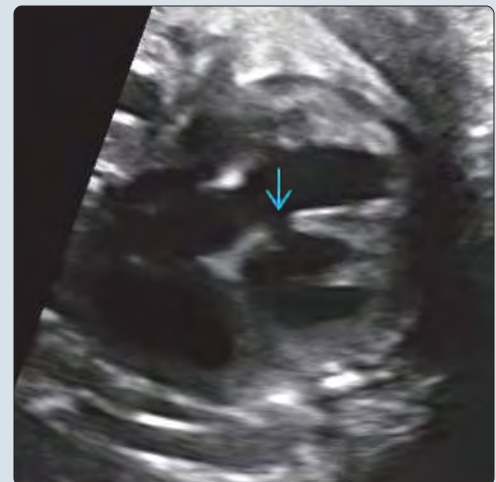
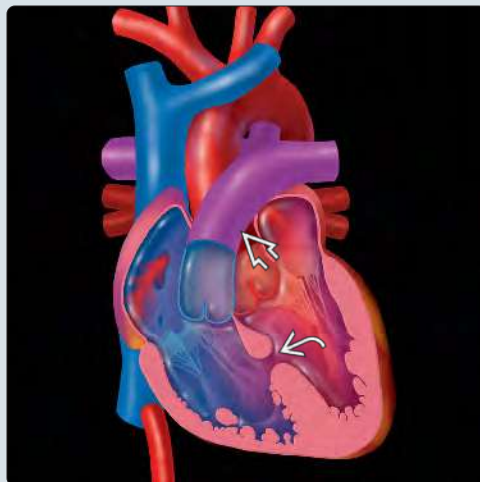
CLINICAL ISSUES

- Accounts for 20% of all congenital heart disease as solitary lesion
- Excellent short- and long-term outcomes
 - Operative mortality 0.5%

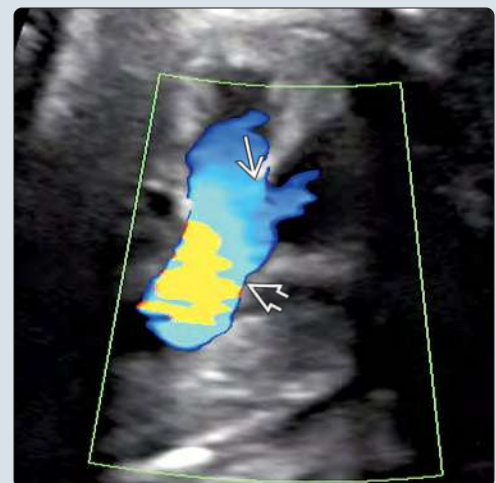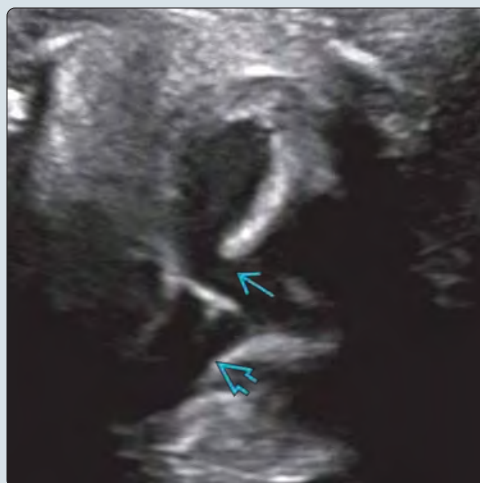
DIAGNOSTIC CHECKLIST

- Hemodynamically significant lesions are larger → more likely to be detected

(Left) Graphic shows a mid-muscular ventricular septal defect (VSD) allowing oxygenated blood to flow from the left ventricle (LV) to the right ventricle (RV), increasing the oxygen saturation in the main pulmonary artery. (Right) A large muscular VSD is noted in the mid-ventricular septum. Always try to scan perpendicular to the septum. There is often signal dropout if scanning parallel to the septum, and a VSD can be erroneously diagnosed.



(Left) Ultrasound shows a membranous VSD with aortic override in a fetus with tetralogy of Fallot. (Right) Color Doppler ultrasound in the same plane shows flow across the VSD from the RV and LV exiting the aorta. Approximately 1/2 of all VSDs are associated with other cardiac malformations.



TERMINOLOGY

Abbreviations

- Ventricular septal defect (VSD)

Definitions

- **Membranous:** Defect in outflow tract of left ventricle (LV), immediately below aortic valve
- **Muscular:** Defect in muscular portion of septum, anywhere from apex to base
- **Outlet:** Defect in outflow tract of right ventricle (RV), below pulmonary valve
- **Inlet:** Located posterior and inferior to membranous septum, beneath septal leaflet of tricuspid valve

IMAGING

General Features

- Best diagnostic clue
 - Defect in ventricular septum

Echocardiographic Findings

- Echocardiogram
 - Signal dropout in septum is potential pitfall
 - Try to image perpendicular to ventricular septum
 - Septal continuity with aortic annulus excludes VSD in that location
 - Confirm on long-axis view if seen on apical 4-chamber view and vice versa
 - Small muscular VSDs may not be visible on grayscale or color Doppler
- Color Doppler
 - Useful to confirm blood flow across defect
 - If unidirectional shunt, look for other anomalies altering balance of ventricular pressures (e.g., outflow tract obstruction)
- Additional cardiac malformations very common

Imaging Recommendations

- Protocol advice
 - If defect is noted in ventricular septum
 - Decide on its location (membranous, muscular, outlet, inlet)
 - Perform complete sequential analysis of heart (associated cardiac malformations in 50%)
 - Full anatomic survey for other extracardiac anomalies

DIFFERENTIAL DIAGNOSIS

Atrioventricular Septal Defect (AVSD)

- Defect involves atrial and ventricular septa
- Common AV valve straddling septal defects

Double-Outlet Right Ventricle (DORV)

- Discontinuity between mitral and aortic valves
- Aorta arises more (> 50%) from RV than LV

PATHOLOGY

General Features

- Genetics
 - Chromosomal anomaly found in > 40%

Staging, Grading, & Classification

- Membranous (75%): Tetralogy of Fallot, DORV
- Muscular (10-15%): May be multiple
- Outlet (5%): Truncus arteriosus
- Inlet (5-8%): Component of AVSD

CLINICAL ISSUES

Demographics

- Epidemiology
 - Accounts for 20% of all congenital heart disease (CHD) as solitary lesion
 - 2-3/1,000 live births

Natural History & Prognosis

- Variable, depends on
 - Location
 - Outlet and inlet VSDs are likely to need surgical closure
 - Perimembranous and muscular VSDs have high rate of spontaneous closure (1/3 and 2/3, respectively)
 - Size of defect and degree of left-to-right shunt
 - Tiny muscular VSDs close spontaneously in 1st year of life
 - Small VSDs, typically perimembranous, often close later in childhood or remain asymptomatic
 - Large (> 50% of aortic annulus) hemodynamically significant VSDs develop congestive heart failure and often require surgery
 - Associated cardiac abnormalities present in 50%
- Surgical repair if
 - Part of other complex congenital heart disease
 - Maximal medical therapy fails
- Excellent short- and long-term outcomes
 - Operative mortality: 0.5%
- Recurrence risk
 - 1 child: 3%; 2 children: 10%
 - Maternal VSD: 6-10%; paternal: 2%

Treatment

- Offer karyotype if complex congenital heart disease or extracardiac abnormalities
- Prenatal consultation with pediatric cardiology
- Refer to tertiary care center if defect is large or part of complex CHD
- Definitive treatment
 - Pericardial or Dacron patch repair

DIAGNOSTIC CHECKLIST

Image Interpretation Pearls

- Look for septal continuity with aortic annulus in left ventricular outflow tract (LVOT) view to exclude membranous VSD
- Keep sound beam perpendicular to septum
 - Avoids VSD mimic of dropout at membranous-muscular junction

SELECTED REFERENCES

1. Brown KL et al: Trends in 30-day mortality rate and case mix for paediatric cardiac surgery in the UK between 2000 and 2010. *Open Heart*. 2(1):e000157, 2015

KEY FACTS

TERMINOLOGY

- Central cardiac defect involving atrial and ventricular septum, atrioventricular (AV) valves, and conducting system
- Atrioventricular septal defect can be balanced or unbalanced
 - Balanced defect: Right and left ventricles are equal in size with equal commitment of AV valves
 - Unbalanced defect: 1 ventricle gets majority of inflow and is equivalent to single ventricle
- Defect can be complete or partial
 - Partial: Primum atrial septal defect (ASD), distinct mitral and tricuspid valve annuli, cleft in mitral valve
 - Complete: Primum ASD, contiguous inlet ventricular septal defect, & common AV valve has single annulus

IMAGING

- Missing crux of heart on 4-chamber view
 - Normally atrial & ventricular septa meet at crux of heart and AV valves are separated into 2 distinct valve annuli

- Single AV valve makes straight line across heart in systole
 - Identify commitment of AV valve to ventricles
 - Small ventricle suggestive of unbalanced defect
- Defect in primum atrial septum and inlet ventricular septum
- Gooseneck deformity of left ventricular outflow tract

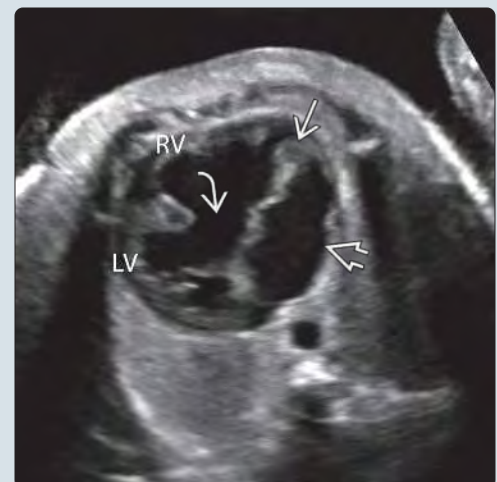
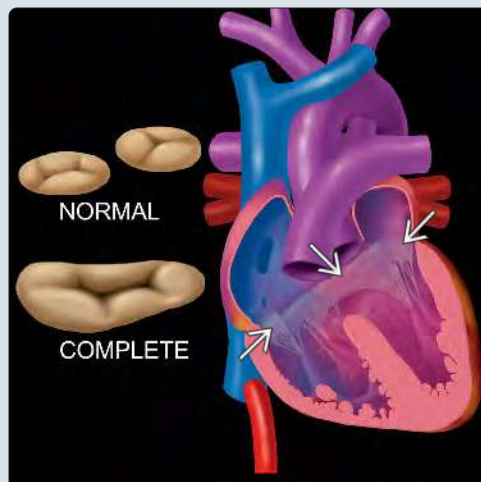
PATHOLOGY

- Trisomy 21 in up to 50% of fetal cases
- Other chromosomal anomalies or syndromes in 20-30%
- Heterotaxy found in 15-20%
- Additional cardiac malformations common

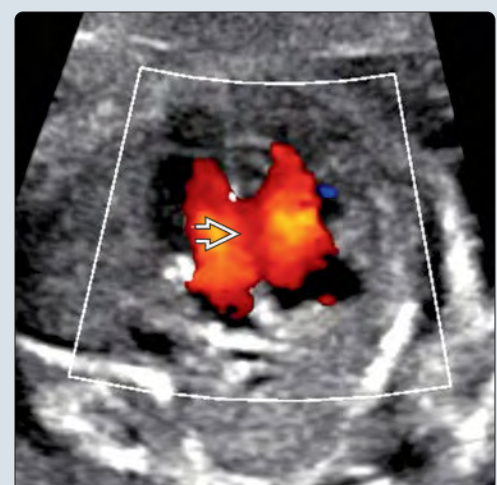
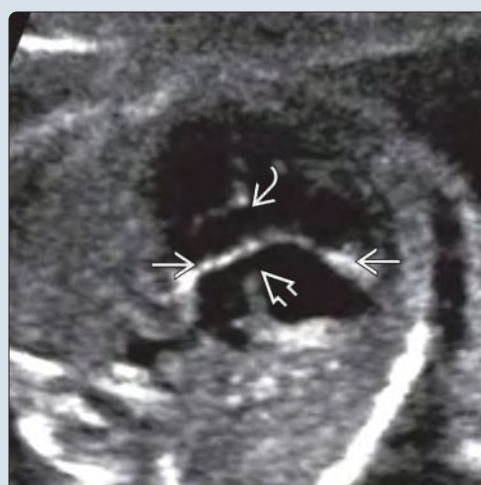
CLINICAL ISSUES

- Trisomy 21 not independent risk factor for adverse surgical outcome
- Excellent short- and long-term surgical outcomes in liveborns (95% 20-yr survival rate)

(Left) Graphic shows a common atrioventricular (AV) valve straddling a central defect in the heart, involving the atrial and ventricular septa. Mixing of blood in the heart results in similar saturations in the aorta and main pulmonary artery. (Right) This image shows a very large ventricular septal defect, virtually no atrial septum, and a single valve which spans both ventricular chambers. This appears to be a balanced defect as the ventricles are similar in size.



(Left) Four-chamber view fetal echocardiogram shows a balanced atrioventricular septal defect (AVSD) with a single common AV valve in systole and contiguous atrial and ventricular septal defects. The usual offset of the valves is absent. (Right) Color Doppler image in diastole shows blood filling the entire atrioventricular septal defect. The crux of the heart is missing and there is complete mixing of oxygenated and deoxygenated blood.



TERMINOLOGY

Abbreviations

- Atrioventricular septal defect (AVSD)

Synonyms

- Atrioventricular canal
- Endocardial cushion defect

Definitions

- Central cardiac defect involving
 - Atrial septum [atrial septal defect (ASD)]
 - Ventricular septum [ventricular septal defect (VSD)]
 - Atrioventricular (AV) valves
 - Abnormal course of conducting system
- Defect can be balanced or unbalanced
 - **Balanced:** Right and left ventricles are equal in size with equal commitment of AV valves
 - **Unbalanced:** 1 ventricle gets majority of inflow and is equivalent to single ventricle
- Defect can be complete or partial
 - Partial: Primum ASD, distinct mitral and tricuspid valve annuli, cleft in mitral valve
 - Transitional: Partial AVSD that also has small inlet VSD which is partially occluded by dense chordal attachments
 - Complete: Primum ASD, contiguous inlet VSD, and common AV valve has single annulus
 - Intermediate: Complete AVSD that has distinct right and left AV valve orifice despite having only 1 common annulus

IMAGING

General Features

- Best diagnostic clue
 - Missing crux of heart on 4-chamber view
 - Normally atrial and ventricular septa meet at crux of heart and AV valves are separated into 2 distinct valve annuli
 - Presence of atrial and ventricular septal defects
 - Usual offset of the AV valves is absent (i.e., valve is in same plane)

Echocardiographic Findings

- Single AV valve makes straight line across heart in systole
 - Tricuspid insertion normally 1-2 mm offset (toward apex) from mitral insertion
 - This is not present because single AV valve has superior and inferior bridging leaflet
 - AV valve regurgitation is common
 - It is important to identify commitment of AV valve to ventricles
 - Small ventricle suggestive of unbalanced defect
- Defect in primum atrial septum and there is typically normal foramen ovale as well
- Defect in inlet ventricular septum
- Gooseneck deformity of left ventricular outflow tract (LVOT)
 - Elongated, narrowed, somewhat horizontally inclined LVOT

- Aortic root is sprung due to lack of aortic-mitral continuity
- Color Doppler
 - Assess stenosis or flow turbulence across AV valves
 - Assess valve regurgitation
 - Assess flow through VSD and ASD
- Pulsed Doppler
 - Used to evaluate presence or absence of valve stenosis or obstruction
- Additional cardiac malformations common
 - Tetralogy of Fallot
 - Double outlet right ventricle
 - Left heart obstruction
 - Heterotaxy syndrome

Imaging Recommendations

- Protocol advice
 - If AV valves are noted to be at same level
 - Look for primum ASD
 - Look for inlet VSD
 - Assess for AV valve regurgitation
 - Evaluate for associated cardiac defects
 - Look for features of heterotaxy syndromes, especially interrupted inferior vena cava
 - Determine ventricular dominance (balanced or unbalanced)
 - Determine complete vs. partial form
 - Check rate and rhythm
 - Conduction system involvement → bradycardia or heart block may suggest association with heterotaxy
 - Monitor for signs of hydrops
 - Pericardial effusion, pleural effusion, ascites, skin edema
 - Cardiomegaly
 - Track ratio of heart to chest circumference
 - Full anatomic survey for other anomalies
 - Strong association with trisomy 21
 - Thickened nuchal fold, rhizomelic limb shortening, duodenal atresia, echogenic bowel, pelviectasis, clinodactyly

DIFFERENTIAL DIAGNOSIS

Large Ventricular Septal Defect

- AV valves normal
- Primum atrial septum intact

Large Atrial Septal Defect

- AV valves normal
- Ventricular septum intact

Heterotaxy Syndromes

- Multiple additional cardiac defects
- Right atrial isomerism
- Left atrial isomerism

PATHOLOGY

General Features

- Etiology
 - Embryology

- Endocardial cushions fail to form, grow or fuse normally
- Proper AV septation requires early epithelial-to-mesenchymal transformation and later requirement of myocardialization to complete this process
- Primitive AV canal persists after 6-weeks gestational age
- Genetics
 - Trisomy 21 in up to 50% of fetal cases
 - Other chromosomal anomalies or syndromes in 20-30%
 - Trisomy 18, 13, heterotaxy syndromes
- Associated abnormalities
 - Heterotaxy found in 15-20%
 - Additional cardiac malformations, such as tetralogy of Fallot, double outlet right ventricle, left heart obstruction
 - Found in 10% with trisomy 21
 - Found in 33% in non-Down syndrome group
- **Unbalanced AVSD** typically need intervention or surgery in 1st week of life
 - Outcomes similar to single ventricle pathology
 - Inherent limited life expectancy due to single ventricular pump
 - Even higher risk with trisomy 21
- **Partial AVSD** may do well for years prior to need for surgical intervention
- Excellent short- and long-term surgical outcomes
 - < 2% operative mortality
 - 95% 20-yr survival rate
 - 10-20% of patients need reoperation for AV valve regurgitation or LVOT obstruction
- Trisomy 21 not independent risk factor for adverse surgical outcome
 - Outcome is often better due to redundant AV valve tissue
 - Natural history affected by high incidence of upper airway obstruction and resultant pulmonary hypertension

Staging, Grading, & Classification

- Rastelli classification of AVSD
 - Type A (most common)
 - Superior bridging leaflet attached to crest of ventricular septum
 - Type B (least common)
 - Superior bridging leaflet attached to right side of ventricular septum
 - Type C
 - Superior bridging leaflet is free floating from LV free wall to RV free wall
- Additional classification of right or left dominance in unbalanced defects

CLINICAL ISSUES

Presentation

- Abnormal 4-chamber view detected on routine sonography
 - Common AV valve with single annulus contiguous with ASD and VSD
- Complete AV canal detected as early as 12-14 weeks with endovaginal scanning

Demographics

- Epidemiology
 - Accounts for 4-5% of congenital heart disease
 - 0.34/1,000 live births
 - Partial AVSD is more common than complete in liveborn

Natural History & Prognosis

- Prenatal
 - Fetal incidence > liveborn
 - Loss rate reflects high association with aneuploidy/heterotaxy/additional cardiac malformations
 - If isolated, pregnancy often uncomplicated
- Postnatal
 - **Complete (balanced) AVSD** stable after birth but with lower oxygen content due to mixing at septal defects
 - Most will grow and have elective repair at 4-6 months
 - Delay in surgical repair raises likelihood of pulmonary hypertension and worse outcomes

- Recurrence risk
 - 1 child: 2-3%
 - 2 children: 10%
 - Parent with AVSD and normal chromosomes: 2-6%
 - Higher for affected mother than father

Treatment

- Encourage amniocentesis
 - Strong association with aneuploidy/trisomy 21
 - May offer termination in severe cases
- Prenatal consultation with pediatric cardiology/neonatology
- If pregnancy continues, referral to tertiary center for delivery in more complex cases
 - Not indication for early delivery or cesarean section
 - Management at birth is minimal unless there are additional abnormalities or unbalanced defect
- Definitive treatment
 - Complete repair for balanced defects
 - Single ventricle palliation for unbalanced defects
 - Clinical observation and management for partial defects
 - Surgery unusual in neonate, common in childhood

DIAGNOSTIC CHECKLIST

Consider

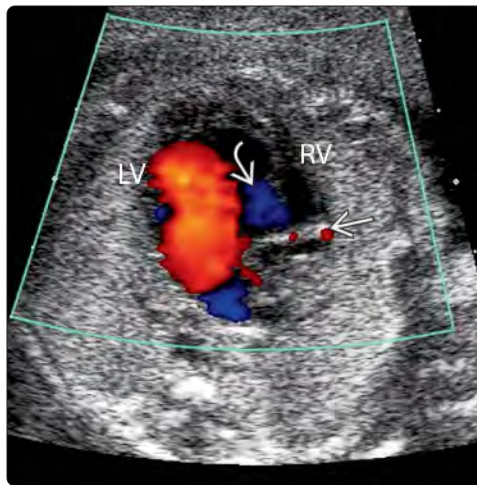
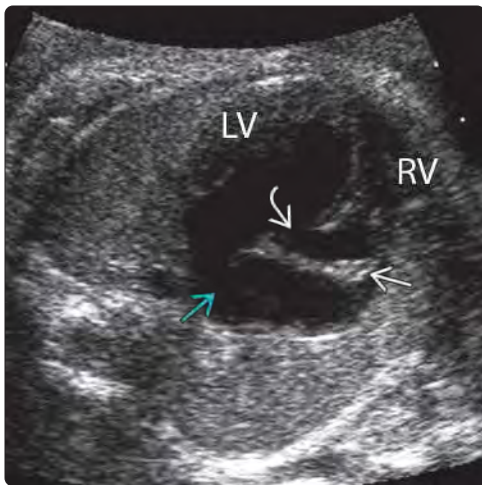
- Formal fetal echocardiography in all cases
 - Management, prognosis, and treatment are very different for each AVSD type
 - Differentiation requires assessment of ventricular size and valve commitments

Image Interpretation Pearls

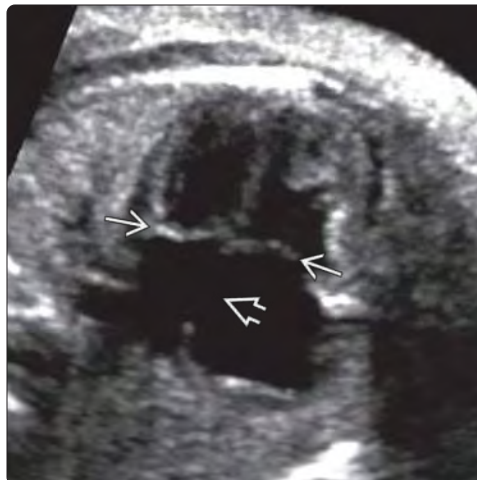
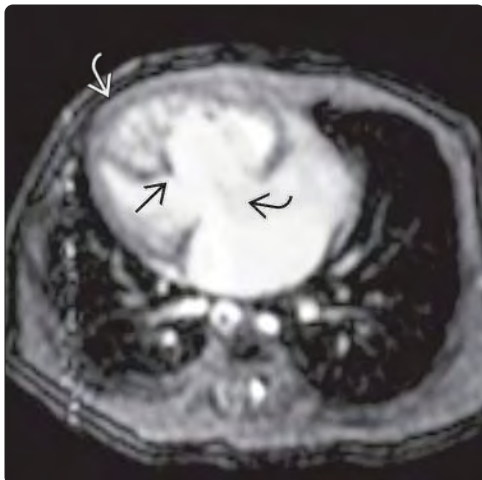
- Trisomy 21 in ~ 50% of isolated AVSD

SELECTED REFERENCES

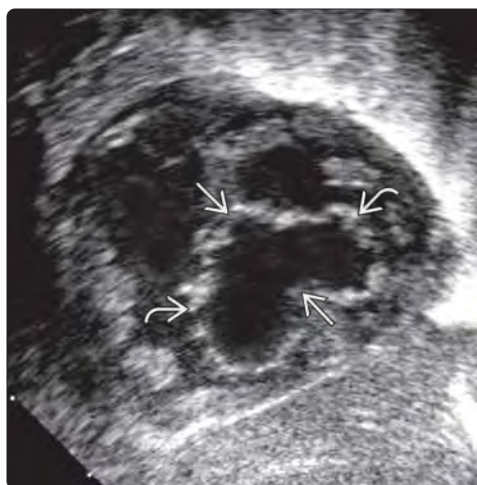
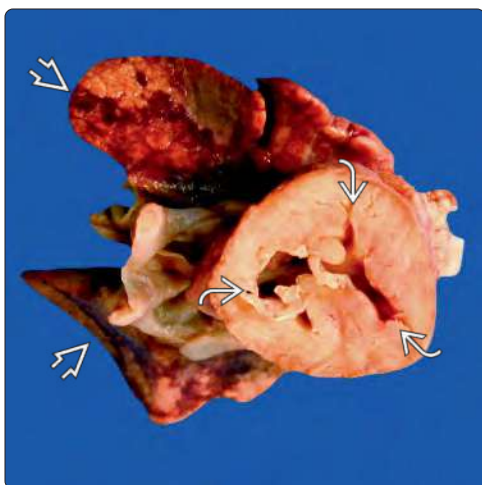
1. Ginde S et al: Long-term outcomes after surgical repair of complete atrioventricular septal defect. *J Thorac Cardiovasc Surg.* 150(2):369-74, 2015
2. Gittenberger-de Groot AC et al: Morphogenesis and molecular considerations on congenital cardiac septal defects. *Ann Med.* 46(8):640-52, 2014
3. Shuhaiber JH et al: Current options and outcomes for the management of atrioventricular septal defect. *Eur J Cardiothorac Surg.* 35(5):891-900, 2009



(Left) This is an example of an unbalanced AVSD with the right ventricle smaller than the left. There is a ventricular septal defect (VSD) and no visible atrial septum. The AV valves were shown in a single plane with the tricuspid valve being thick and nonmobile. AVSD is often associated with other cardiac defects as in this case with tricuspid atresia. (Right) Color flow Doppler during diastole only shows flow into the left ventricle as the right AV valve is atretic. Some blood does enter the small right ventricle via the VSD.



(Left) Axial neonatal cardiac MR shows a large atrioventricular septal defect. There is absence of the atrial septum and a large inlet VSD (crest of the ventricular septum). Also note the abnormal axis, with the cardiac apex to the right. (Right) Four-chamber view echocardiogram of a partial AVSD shows a single AV valve and a large primum atrial septal defect but no ventricular septal defect. This patient also had a cleft in the mitral valve.



(Left) Gross pathology from a fetus with an AVSD is shown. The plane of section mimics a short-axis view and shows a single common atrioventricular valve. There was also pulmonary hypoplasia, hence the small size of the lungs. (Right) Subcostal short-axis echocardiogram shows the identical view of a single, balanced common atrioventricular valve matching that shown in the gross anatomy specimen. Note the plane of the associated ventricular septal defect.

KEY FACTS

TERMINOLOGY

- Redundant foramen ovale flap

IMAGING

- Balloon appearance of foramen ovale flap
 - Extends at least halfway across left atrium
- May make cyclical contact with left atrial wall or mitral valve
- Very redundant flap may even herniate through mitral valve
 - Can cause left ventricular inflow obstruction
- Movement during cardiac cycle creates fluttering appearance
 - Described as appearing like jellyfish
- Check rhythm
 - Up to 36% will have premature atrial contractions (PACs)

TOP DIFFERENTIAL DIAGNOSES

- Normal foramen ovale
 - Flap projects into left atrium but shows little mobility

- Linear appearance; not enough tissue to balloon

PATHOLOGY



- No association with aneuploidy
- PACs may be due to cyclical contact of redundant flap with left atrial wall or irritation of sinoatrial node

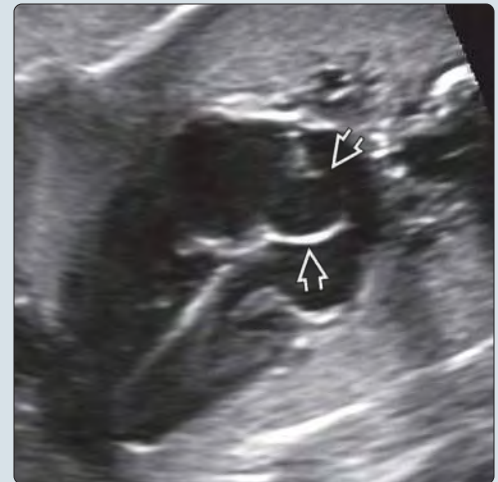
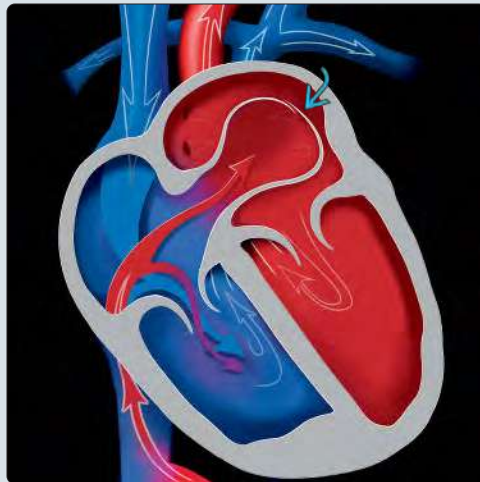
CLINICAL ISSUES



- True population incidence unknown
- 1.2% of fetuses undergoing fetal echo for any reason
- 5.4% of fetuses referred for arrhythmia
- No fetuses in large series (> 1,000 patients) developed significant arrhythmia

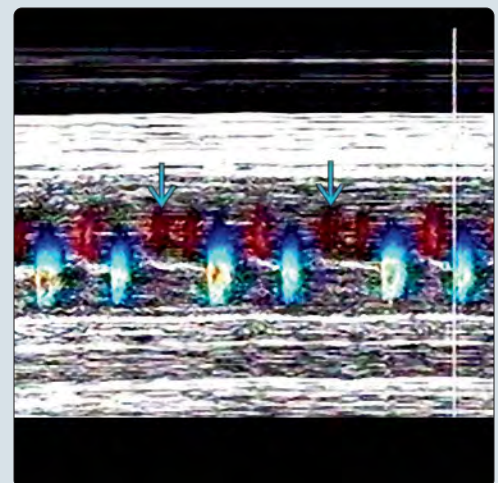
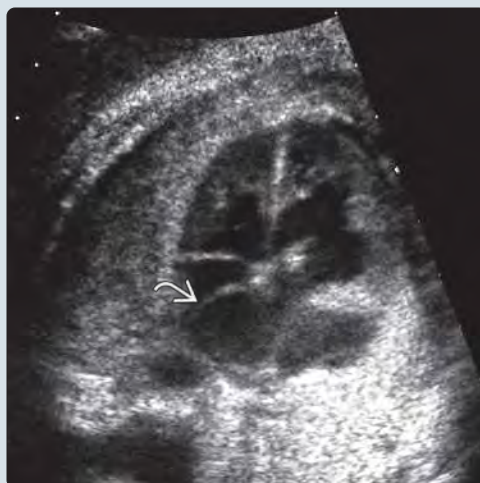DIAGNOSTIC CHECKLIST

- Isolated atrial septal aneurysm is a benign entity
- Monitor for rhythm disturbance by regular auscultation
- If associated with PACs, very small risk of progression to tachyarrhythmia

(Left) In a fetus, blood normally moves right to left across the foramen ovale. On occasion the covering flap can be redundant and balloon into the left atrium , creating an atrial septal aneurysm. **(Right)** Four-chamber view of the fetal heart shows an atrial septal aneurysm , bulging into the left atrium. Although definitions vary, an abnormally redundant flap is considered to extend at least halfway across the left atrium.



(Left) The redundant flap moves during the cardiac cycle and in this case makes contact with the left atrial wall . This contact is a suspected etiology for premature atrial contractions (PACs). A very redundant flap may even herniate through the mitral valve and cause obstruction of left ventricular inflow. **(Right)** Color M-mode tracing shows the typical appearance of blocked PACs . Red reflects atrial contraction, and blue reflects ventricular contraction. PACs can be seen in up to 36% of fetuses with atrial septal aneurysms.



TERMINOLOGY**Synonyms**

- Foramen ovale aneurysm
- Aneurysm of septum primum
- Redundant septum primum flap

Definitions

- Redundant foramen ovale flap
- Definition of redundancy varies between series
 - Flap extends at least halfway across left atrium
 - Flap excursion > 5 mm beyond plane of atrial septum
 - Flap demonstrates abnormal mobility

IMAGING**General Features**

- Balloon appearance of foramen ovale flap
 - May make cyclical contact with left atrial wall or mitral valve
 - Very redundant flap may even herniate through mitral valve
 - Can cause left ventricular inflow obstruction
 - If longstanding, at risk for developing left heart hypoplasia
- Movement during cardiac cycle creates fluttering appearance
 - Described as appearing like jellyfish

Imaging Recommendations

- Check rhythm
 - Up to 36% will have premature atrial contractions (PACs)
 - Rare case with intermittent or sustained supraventricular tachycardia
- Look for additional structural abnormality

DIFFERENTIAL DIAGNOSIS**Normal Foramen Ovale**

- Normal flap shows little mobility during cardiac cycle
- Seen projecting into left atrium on 4-chamber view
 - Linear flap; not enough tissue to balloon
- With reversed atrial shunting flap projects into right atrium
 - Seen in left heart obstruction

PATHOLOGY**General Features**

- Etiology
 - Unclear
 - Possibly abnormally weak septum primum tissue
- Genetics
 - No association with aneuploidy
- Associated abnormalities
 - PACs may be due to
 - Cyclical contact of redundant flap with left atrial wall
 - Base of flap may irritate sinoatrial (SA) node
 - Intermittent blocking of SA node transmission
- Embryology
 - Septum primum: Thin flap grows from top of common atrium toward ventricular septum
 - Continues until attachment to endocardial cushion

- Leaves foramen between atria: Ostium primum and ostium secundum
- Septum secundum: Thicker muscular flap develops as true atrial septum growing posteroinferiorly
 - Leaves opening (foramen ovale) near floor of right atrium
- Septum primum flap (foraminal flap) normally covers foramen ovale
 - Flap seen in left atrium as blood flows R → L in fetus

CLINICAL ISSUES**Presentation**

- Most common signs/symptoms
 - Observed on 4-chamber view at routine obstetric sonography
 - May be found in fetus being evaluated for PACs or arrhythmia

Demographics

- Epidemiology
 - Fetus
 - True population incidence unknown
 - 1.2% of fetuses undergoing fetal echo for any reason
 - 5.4% of fetuses referred for arrhythmia
 - Young adults
 - Higher prevalence of atrial aneurysm if born preterm
 - Risk factor for stroke

Natural History & Prognosis

- Associated with PACs
- No fetuses in large series (> 1,000 patients) developed significant arrhythmia
- All infants had normal sinus rhythm by 3 months age

Treatment

- Monitor for rhythm disturbance by regular auscultation
- Maternal hyperoxygenation has been used if there is significant obstruction of left ventricular inflow
 - Increases fetal pulmonary venous return
 - Alters left ventricular geometry
 - Promotes antegrade flow in aortic isthmus

DIAGNOSTIC CHECKLIST**Image Interpretation Pearls**

- Isolated atrial septal aneurysm is benign entity
- If associated with PACs, very small risk of progression to tachyarrhythmia

SELECTED REFERENCES

1. Channing A et al: Maternal hyperoxygenation improves left heart filling in fetuses with atrial septal aneurysm causing impediment to left ventricular inflow. *Ultrasound Obstet Gynecol.* 45(6):664-9, 2015
2. Sun HY et al: Unusual consequence of a fetal atrial septal aneurysm. *Clin Case Rep.* 3(6):368-9, 2015
3. Bassareo PP et al: High prevalence of interatrial septal aneurysm in young adults who were born preterm. *J Matern Fetal Neonatal Med.* 27(11):1123-8, 2014
4. Yozgat Y et al: Importance of close follow-up in the fetus with premature atrial contractions accompanied by atrial septal aneurysm: a case report. *Case Rep Obstet Gynecol.* 2013:391085, 2013
5. Hung JH et al: Prenatal diagnosis of atrial septal aneurysm. *J Clin Ultrasound.* 36(1):51-2, 2008

KEY FACTS

TERMINOLOGY

- Apical displacement of septal and posterior tricuspid valve (TV) leaflets
- Coaptation point of tricuspid valve is lowered into right ventricle (RV), not at atrioventricular junction
 - Results in "atrialization" of RV

IMAGING








- Cardiomegaly due primarily to right atrial enlargement
 - Dilation often massive; wall-to-wall heart
- Adherence of septal and posterior leaflet to underlying myocardium results in apical displacement of functional annulus into RV
- Long, sail-like or redundant anterior tricuspid leaflet
- Valve dysplasia + leaflet malposition → tricuspid regurgitation
- Functional RV small
- Pulmonary artery often small or atretic

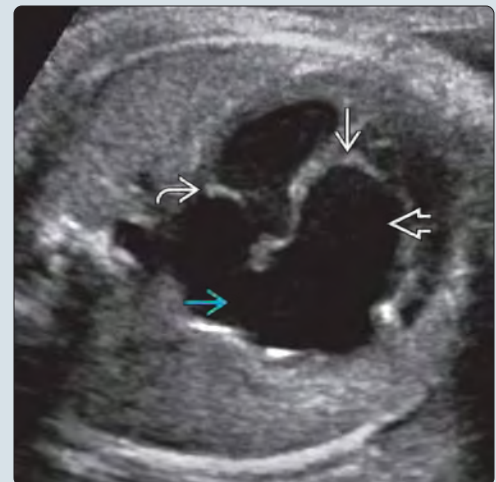
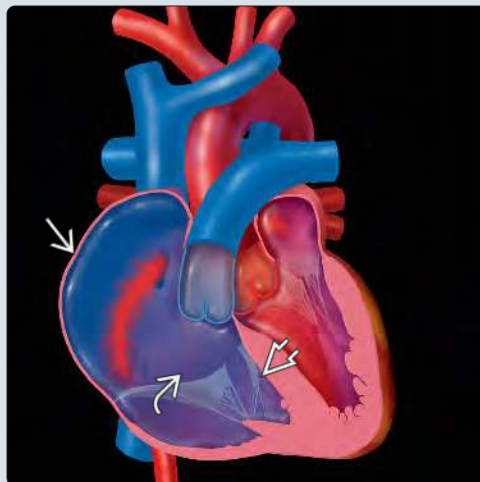
CLINICAL ISSUES





- Degree of anatomic deformity and clinical outcome varies greatly
 - GOSE score (ratio of combined RA and atrialized RV to functional RV and left heart) helps determine prognosis based on 4 grades
 - Grade 1 ratio < 0.5; > 90% survival
 - Grade 4 ratio > 1.5; 100% mortality is expected
- Absence of antegrade flow across pulmonary valve is lethal without patency of ductus arteriosus
- In utero mortality rate is 45%
- In cases of mild valve displacement patients do well and may not require surgery for long time, if at all

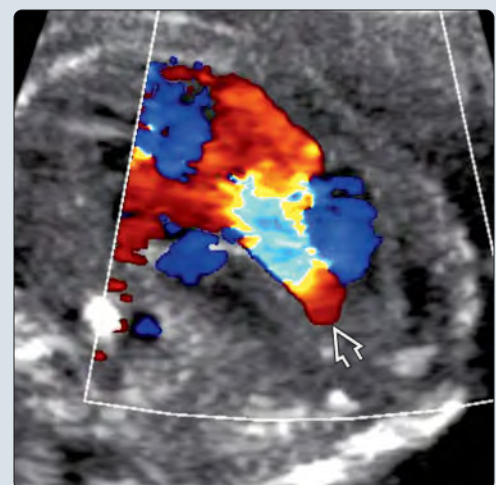
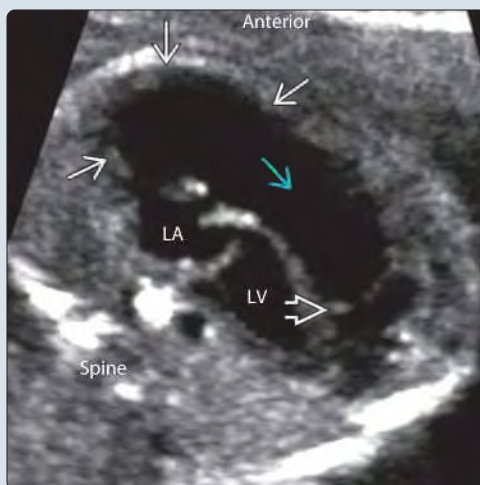
DIAGNOSTIC CHECKLIST

- Abnormal offset of TV is key to making diagnosis of Ebstein anomaly

(Left) Graphic of Ebstein anomaly of the tricuspid valve shows a large right atrium , which includes the "atrialized" inlet portion of the right ventricle . Note the downwardly displaced and attached septal leaflet . **(Right)** Four-chamber view shows an apically displaced septal leaflet  of the tricuspid valve resulting in "atrialized" right ventricle.  The plane of the mitral valve is shown . There is also a large atrial septal defect evident .



(Left) Four-chamber view echocardiogram shows a massively dilated heart. The septal leaflet  of the tricuspid valve is downwardly displaced almost to the apex of the heart, resulting in a large atrialized portion of the RV  in continuity with the RA . **(Right)** Color Doppler echocardiogram in the same plane shows severe tricuspid regurgitation , which starts near the apex of the right ventricle, confirming the downward displacement of the valve.



TERMINOLOGY**Definitions**

- Apical displacement of septal and posterior tricuspid valve (TV) leaflets
 - Coaptation point of tricuspid valve is lowered into right ventricle (RV), not at atrioventricular junction
 - Results in "atrialization" of RV

IMAGING**General Features**

- Best diagnostic clue
 - Right atrial enlargement + apical displacement of TV
 - Normally lower on septum than mitral valve by only 1-2 mm

Echocardiographic Findings

- Cardiomegaly often severe (wall-to-wall heart)
 - Due primarily to right atrial (RA) enlargement
- Adherence of septal and posterior leaflet to underlying myocardium (failure of delamination)
 - Results in apical displacement of functional annulus into RV
- Dilation of "atrialized" portion of RV
 - Functional RV is small; often only muscular and outlet portion are present
- Long, sail-like or redundant anterior tricuspid leaflet
- Dilation of right AV junction or true tricuspid annulus
- Valve dysplasia + leaflet malposition → tricuspid regurgitation
- Pulmonary artery often small or atretic due to decreased antegrade flow
- Color Doppler
 - Helpful to demonstrate tricuspid regurgitation
 - Assess if there is flow across pulmonary valve

Imaging Recommendations

- Protocol advice
 - If significant cardiomegaly
 - Look at right atrial size
 - Assess level of TV
 - Assess degree of tricuspid regurgitation
 - If severe, increased risk of hydrops
 - Look for associated structural abnormalities (30%)
 - Atrial or ventricular septal defects
 - Pulmonary stenosis or atresia
 - Assess for arrhythmia
 - Supraventricular tachycardia or atrial flutter → worse prognosis

DIFFERENTIAL DIAGNOSIS**Tricuspid Dysplasia**

- Tricuspid valve normally located
- Both valve leaflets thick & dysplastic but move freely
- Tricuspid regurgitation can be severe with right atrial dilation
- RV typically normal in size

PATHOLOGY**General Features**

- Etiology
 - Unknown; studies suggest genetic, reproductive, and environmental risk factors
 - Questionable association with lithium; current recommendation is to avoid during pregnancy
- Embryology
 - Myopathy of RV that results in variable degrees of failure of delamination of TV leaflets from underlying endocardium

CLINICAL ISSUES**Presentation**

- Cardiomegaly noted on routine obstetric scan, often massive

Natural History & Prognosis

- Degree of anatomic deformity and clinical outcome varies greatly
- In utero mortality rate is 45%
- Great Ormond Street score (GOSE score)
 - Ratio of combined RA and atrialized RV to functional RV and left heart
 - Grade 1 ratio < 0.5; > 90% survival
 - Grade 2 ratio 0.5-0.99; > 90% survival
 - Grade 3 ratio 1-1.49; mortality up to 45% by childhood
 - Grade 4 ratio > 1.5; 100% mortality expected
- Absence of antegrade flow across pulmonary valve is lethal without patency of ductus arteriosus
- Adults with Ebstein anomaly have good medium-term survival of 100% at 40 years, 95% at 50 years, and 81% at 60 years
- Recurrence risk: 1 child (1%), 2 affected siblings (3%)

Treatment

- Offer karyotype: Ebstein anomaly has been described in trisomy 21, 18
- Offer termination in severe cases
- Prenatal consultation with pediatric cardiology/neonatology
- Planned delivery at tertiary center; early delivery does not improve prognosis
- Surgery is necessary for patients in heart failure or who are profoundly cyanotic
- In cases of mild valve displacement, patients do well and may not require surgery for long time, if at all

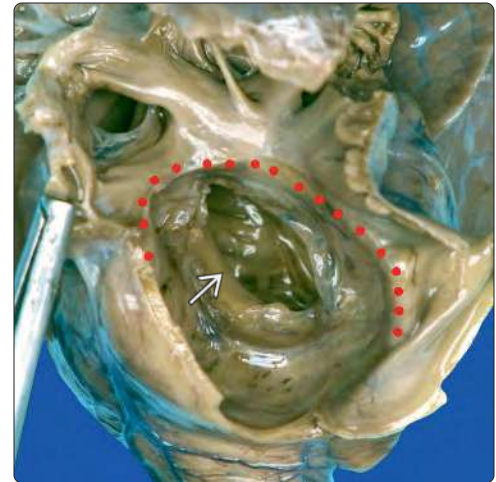
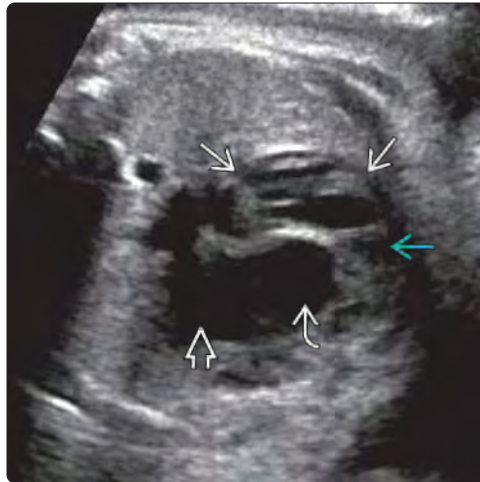
DIAGNOSTIC CHECKLIST**Image Interpretation Pearls**

- Abnormal offset of TV is key to making diagnosis of Ebstein anomaly

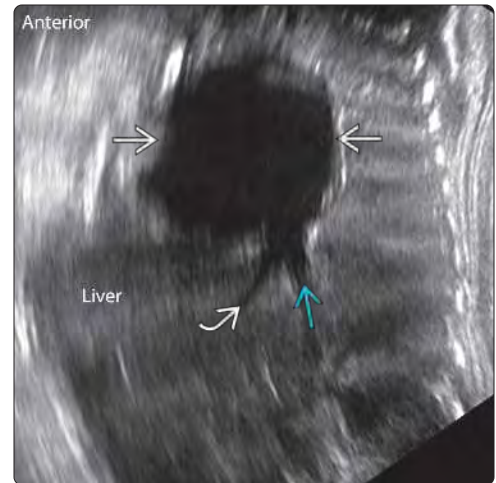
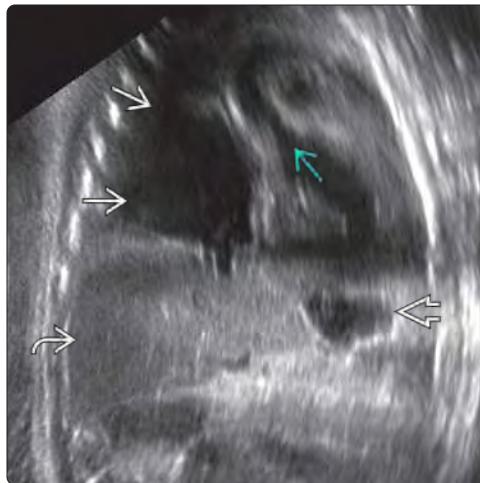
SELECTED REFERENCES

1. Freud LR et al: Outcomes and predictors of perinatal mortality in fetuses with Ebstein anomaly or tricuspid valve dysplasia in the current era: a multicenter study. *Circulation*. 132(6):481-9, 2015

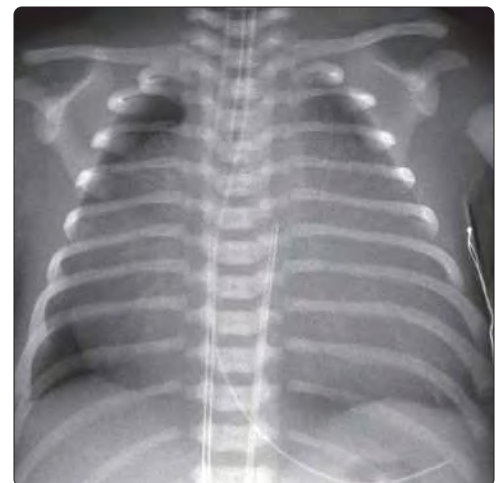
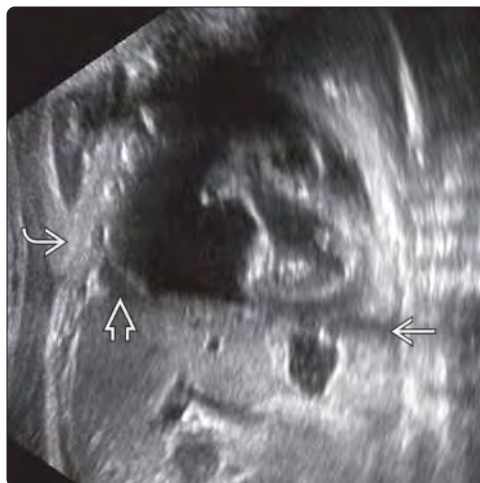(Left) Four-chamber view shows a normal-sized LV cavity; it is smaller than the combined right atrium and "atrialized" RV. The functional RV is the small cavity at the apex. This case would have a GOSE score of grade 3 (mortality up to 45%). **(Right)** Autopsy image shows the right atrium has been opened with the view looking down at the tricuspid valve annulus, outlined by red dots. The attachment of the septal leaflet is well below the annulus.

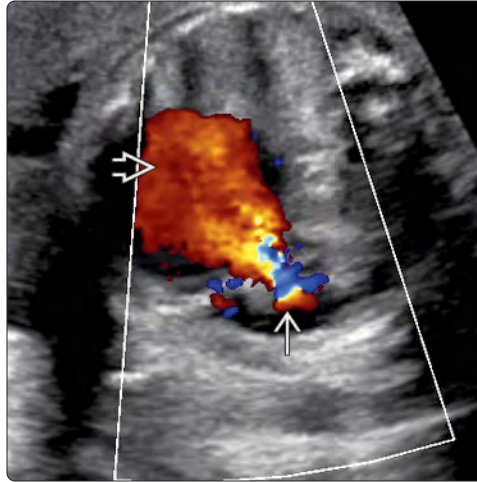
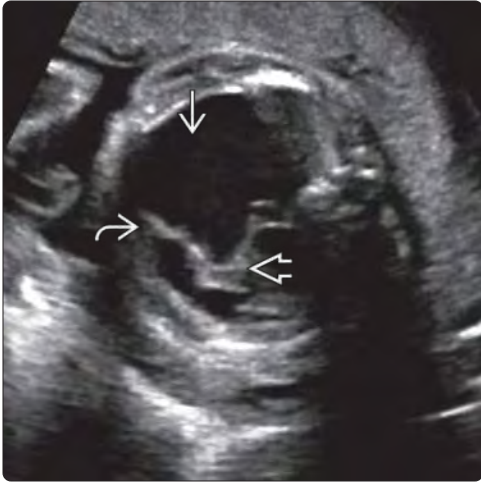


(Left) Coronal ultrasound of the fetal chest shows how the massive RA enlargement distorts normal anatomy. The left ventricular outflow tract is visible in this plane because the heart is rotated. Note liver and stomach. **(Right)** An attempted bicaval view shows the inferior vena cava entering the massive right atrium. Note the prominent hepatic vein; abnormal right atrial pressure causes back pressure into the liver. The atrium is so large, it is not possible to image the superior and inferior vena cava in the same plane.

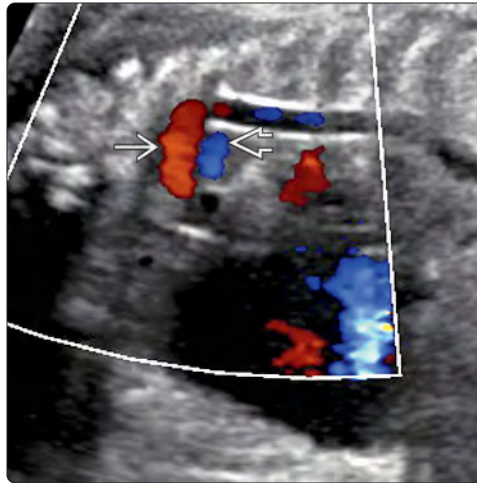
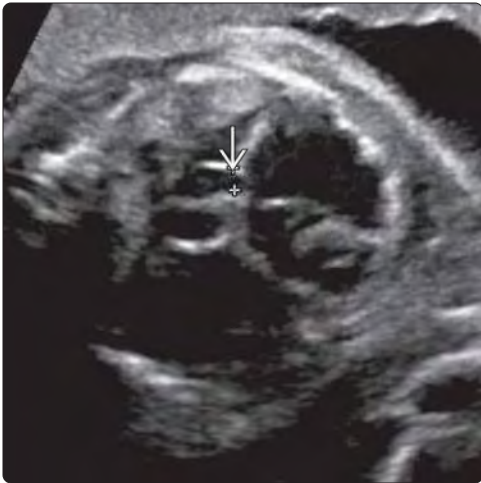

(Left) Follow-up in the same case shows that hydrops has developed, as evidenced by pericardial and pleural effusions and skin thickening. As a result, labor was induced, and the infant delivered at 38 weeks and 2 days. **(Right)** Chest radiograph in the same case shows the "wall-to-wall" heart. She was placed on prostaglandins for known retrograde filling of the pulmonary artery via the ductus but failed to oxygenate even with high-flow nasal cannula. Urgent intubation was required but she survived to surgical repair.

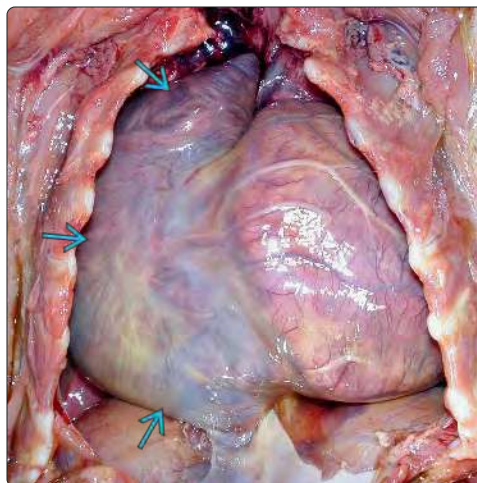
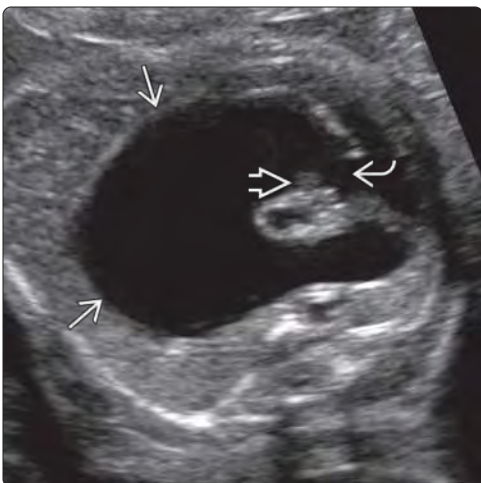




(Left) Axial image through the chest at the level of the 4-chamber view shows a dilated right atrium with thickened leaflet tips, and only mild displacement of the septal leaflet below the true annulus, but given the overall heart size, it is clear there must be significant regurgitation. **(Right)** Color Doppler of the same image shows that severe regurgitation starting down in the RV is consistent with Ebstein anomaly. Note how the regurgitant flow fills the right atrium.



(Left) Image of the right ventricular outflow tract in this patient with Ebstein anomaly shows a very small pulmonary valve in which we could not document antegrade flow into the main pulmonary artery. **(Right)** Image in the same patient shows antegrade flow in the aorta and retrograde flow in the ductus arteriosus. This is what you see when there is functional pulmonary atresia in the setting of severe tricuspid regurgitation, as the RV cannot generate enough forward pressure to open the pulmonary valve.



(Left) Axial image through the fetal chest shows a massively dilated heart, most of which is the right atrium. There is only a remnant of the septal leaflet of the tricuspid valve, resulting in a large coaptation defect causing severe regurgitation. **(Right)** Autopsy of an Ebstein anomaly shows wall-to-wall heart. The pericardium has been removed, revealing a massively enlarged right atrium, which fills the majority of the thoracic cavity. [Courtesy L. Erickson, PA (ASCP).]

KEY FACTS

TERMINOLOGY

- Thick and dysplastic tricuspid valve (TV)

IMAGING

- Tricuspid valve is in normal position
- Thick, nodular, or irregular valve leaflets
 - Leads to incompetence or tricuspid regurgitation → large right atrium and increased risk of developing hydrops
- Often associated with pulmonary stenosis/atresia
- Assess for arrhythmias

TOP DIFFERENTIAL DIAGNOSES





- Ebstein anomaly
 - Also has dysplastic TV and tricuspid regurgitation, but key difference is apical displacement of septal and posterior TV leaflets
 - Results in atrialization of right ventricle (RV)
 - Functional RV small

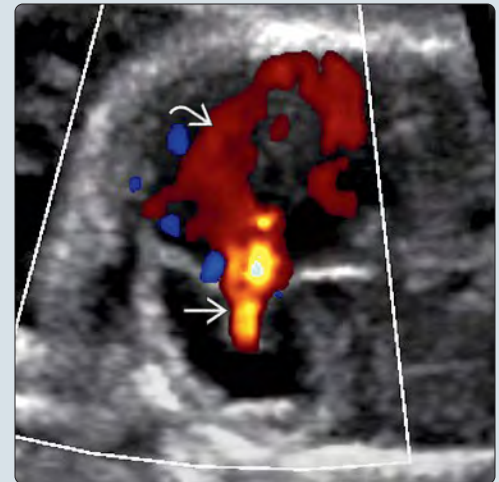
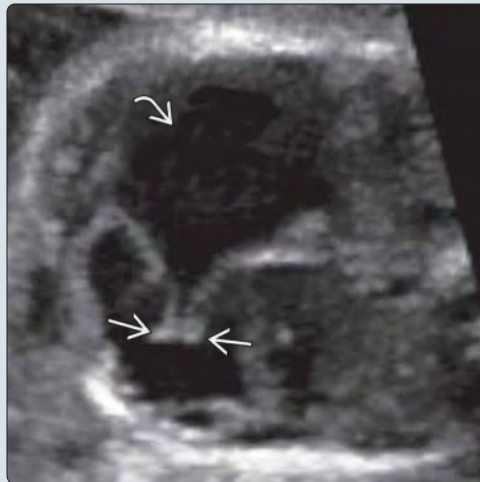
PATHOLOGY




- Ebstein and TV dysplasia have similar pathophysiology

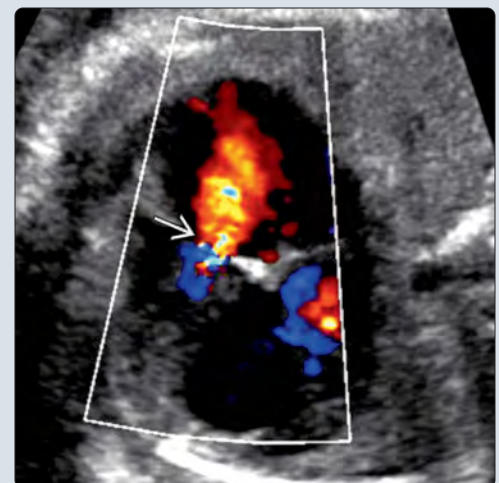
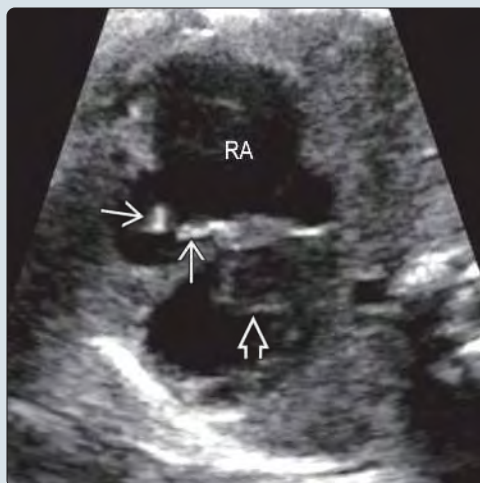
CLINICAL ISSUES

- After delivery, may present with cyanosis due to right to left shunting at atrial level
 - Loud regurgitant systolic murmur at auscultation
- May improve significantly without any intervention
 - Due to rapid fall in pulmonary vascular resistance (PVR) after birth
- Presentation in utero or after birth with severe regurgitation has worse prognosis
 - Fetal demise is common
 - Outcomes in liveborns very poor with survival past 1 month of 20%
- Surgery is necessary for patients in heart failure with profound cyanosis who are not improving with time and decreased PVR

(Left) Axial image of the chest, at the level of the 4-chamber view, shows cardiomegaly with an enlarged right atrium . The tricuspid valve is in the normal position but the leaflet tips are thick and dysplastic . The normal position of the leaflets distinguishes it from Ebstein anomaly where there is apical displacement and a small right ventricle. (Right) The correlative color Doppler image shows severe regurgitation  of the tricuspid valve. The right atrium  is very dilated with the blood swirling around the cavity.



(Left) Four-chamber fetal echocardiogram shows a thickened tricuspid valve with both leaflets  at the same level. The right atrium (RA) is very dilated. Note the normal mitral valve leaflets  for comparison. (Right) Color Doppler image of the same patient shows severe tricuspid regurgitation  due to poor leaflet coaptation. Severe regurgitation leading to right atrial enlargement and hydrops has a poor prognosis.



TERMINOLOGY**Abbreviations**

- Tricuspid valve (TV) dysplasia

Definitions

- Thick and dysplastic tricuspid valve
- Valve located at normal annulus position

IMAGING**General Features**

- Best diagnostic clue
 - Cardiomegaly
 - Right atrial (RA) enlargement
 - Thick and dysplastic TV
 - Severe regurgitation
- Morphology
 - Tricuspid valve is in normal position
 - Thick, nodular, or irregular valve leaflets
 - Leads to incompetence or tricuspid regurgitation → large right atrium and increased risk of developing hydrops
 - Often associated with pulmonary stenosis/atresia

Imaging Recommendations

- Protocol advice
 - If there is significant cardiomegaly
 - Look at RA for size
 - Assess level of TV
 - Assess degree of tricuspid regurgitation
 - If severe, increased risk of hydrops
 - Look for associated structural abnormalities
 - Pulmonary stenosis, atresia
 - Retrograde flow through pulmonary valve risk factor for fetal or neonatal death
 - Assess for arrhythmias

DIFFERENTIAL DIAGNOSIS**Ebstein Anomaly**

- Also has dysplastic TV and tricuspid regurgitation but with additional findings as well
- Apical displacement of septal and posterior TV leaflets
- Coaptation point of valve is lowered into right ventricle (RV), not at atrioventricular junction
 - Results in atrialization of RV
 - Functional RV small, often only muscular and outlet portion
- Long, sail-like anterior tricuspid leaflet
- Cardiomegaly primarily due to RA enlargement
 - Often massive (wall-to-wall heart)
- Pulmonary artery often small or atretic due to decreased flow

PATHOLOGY**General Features**

- Ebstein and TV dysplasia have similar pathophysiology

CLINICAL ISSUES**Presentation**

- In utero
 - Cardiomegaly noted on routine obstetric scan
 - May present with hydrops if severe tricuspid regurgitation
- After delivery
 - May present with cyanosis due to right to left shunting at atrial level
 - Loud regurgitant systolic murmur at auscultation
 - May present later in infancy, childhood, or adulthood depending of degree of tricuspid valve dysfunction

Demographics

- Epidemiology
 - Rare condition

Natural History & Prognosis

- May improve significantly without any intervention
 - Due to rapid fall in pulmonary vascular resistance (PVR) after birth
 - Liberal use of oxygen helps lower PVR
 - As size of RV decreases
 - Valve leaflets coapt better
 - Resulting in less regurgitation
 - Less cyanosis
- Presentation in utero or after birth with severe regurgitation has worse prognosis
 - Fetal demise is common
 - Outcomes in liveborns very poor with survival past 1 month of 20%
 - Outcomes have not changed over past decade

Treatment

- Prenatal consultation with pediatric cardiology/neonatology
- Deliver at tertiary care center
 - Allows for accurate diagnosis and treatment
 - Liberal use of oxygen to lower PVR
- Surgery is necessary for patients in heart failure with profound cyanosis who are not improving with time and decreased PVR
 - Annuloplasty is typically done with improved success rates in older patients
 - Rarely tricuspid valve replacement is necessary

DIAGNOSTIC CHECKLIST**Image Interpretation Pearls**

- Valve leaflet tips are thick and dysplastic causing severe tricuspid regurgitation, but annulus is in normal position

SELECTED REFERENCES

1. Freud LR et al: Outcomes and predictors of perinatal mortality in fetuses with Ebstein anomaly or tricuspid valve dysplasia in the current era: a multicenter study. *Circulation*. 132(6):481-9, 2015
2. Ishii T et al: Left ventricular function and geometry in fetuses with severe tricuspid regurgitation. *Ultrasound Obstet Gynecol*. 40(1):55-61, 2012
3. Lasa JJ et al: Perinatal course of Ebstein's anomaly and tricuspid valve dysplasia in the fetus. *Prenat Diagn*. 32(3):245-51, 2012

KEY FACTS

TERMINOLOGY

- Absent functional tricuspid valve (TV)
 - No communication from right atrium to right ventricle (RV)

IMAGING

- Small RV and plate-like TV on 4-chamber view
- Results in obligatory right to left shunt at atrial level
- Ventricular septal defect (VSD) also usually present
 - Only way for blood to go from left ventricle (LV) to pulmonary circulation when the great vessels are normally related
- Additional cardiac anomalies reported in up to 20%
 - Pulmonary stenosis/atresia common

PATHOLOGY

- Type 1: Great artery relationship normal (72%)
- Type 2: D-transposition (25%)
- Type 3: L-transposition (3%)

- Type 4: Persistent truncus arteriosus (rare)

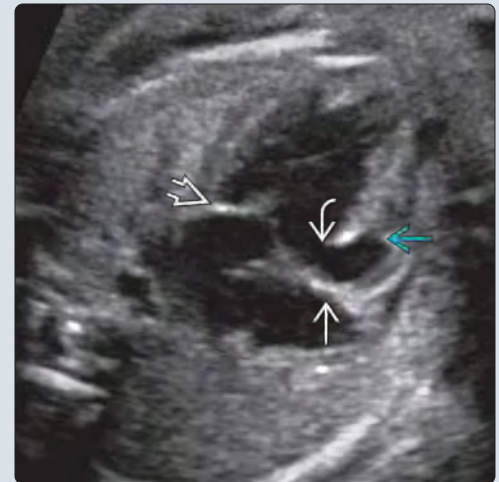
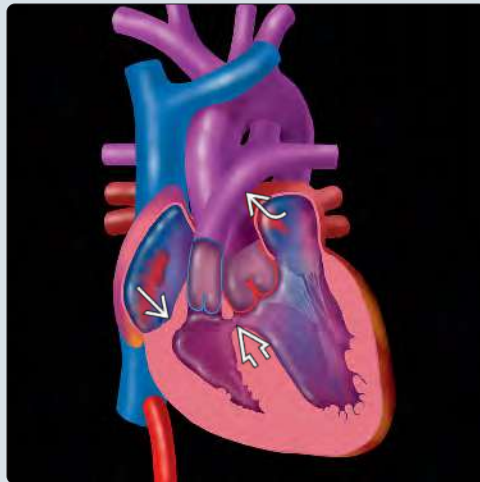
CLINICAL ISSUES

- Untreated, 90% mortality by 1 year
- Current surgical experience from prenatally diagnosed patients
 - 91% survival at 1 month, 83% at 1 year
 - 83% at 10 years
- Poor prognostic indicators
 - Presence of chromosomal anomaly or syndrome
 - Use of extracorporeal membrane oxygenation

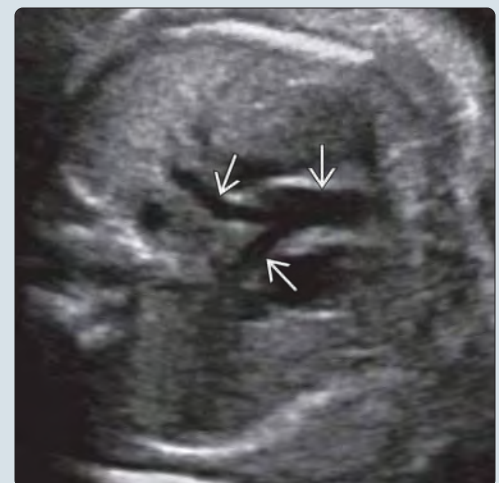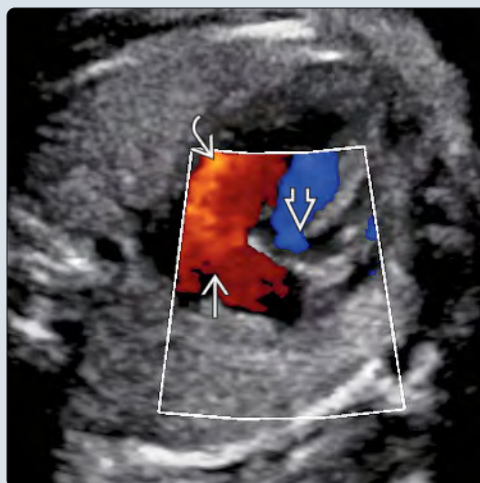
DIAGNOSTIC CHECKLIST

- If plate-like TV and hypoplastic RV are seen
 - Assess ventriculoarterial relationship
 - Look for presence and size of VSD/outflow obstruction
 - With D-transposition, look for additional aortic/arch obstruction

(Left) Graphic shows an absent tricuspid valve, a hypoplastic right ventricle, and a ventricular septal defect that allows blood to enter a hypoplastic pulmonary artery. Blood admixture occurs in the left atrium and left ventricle. (Right) Image shows a classic picture of tricuspid atresia. The mitral valve is normal in appearance. There is a ventricular septal defect, which allows blood to enter the hypoplastic right ventricle.



(Left) Color Doppler image of the same patient shows right-to-left flow across the atrial septal defect and into the left ventricle. One can also see some blood crossing the ventricular septal defect (VSD) into the right ventricle. (Right) Evaluation of the outflow tracts shows the main and branch pulmonary arteries arising from the right ventricle. This documents that the great vessels are normally related and not transposed, which is very important to determine before birth, if possible.



TERMINOLOGY

Abbreviations

- Tricuspid atresia (TA)

Definitions

- Absent functional tricuspid valve (TV)
 - No communication from right atrium to right ventricle (RV)

IMAGING

General Features

- Best diagnostic clue
 - 4-chamber view shows small RV and plate-like TV

Echocardiographic Findings

- TV appears plate-like with no movement
 - Results in obligatory right to left shunt at atrial level through atrial septal defect (ASD) or foramen ovale
- RV: Small, nonapex-forming, function typically decreased
- Ventricular septal defect (VSD) usually present
 - Only way for blood to go from left ventricle (LV) to pulmonary circulation when great vessels are normally related
- Additional cardiac anomalies reported in up to 20%
 - Pulmonary stenosis/atresia
 - Mitral valve abnormalities
 - D-transposition of great arteries
 - Aorta comes off the small RV
 - Coarctation of the aorta is often present, especially if the VSD is small
- Color Doppler
 - Confirms no flow across TV
 - Shows right to left shunt at atrial level
 - Helps identify presence of VSD
 - Assesses outflow obstruction or reverse flow in the ductus arteriosus in the setting of pulmonary atresia

Imaging Recommendations

- Protocol advice
 - If plate-like TV and hypoplastic RV are seen
 - Assess ventriculoarterial relationship
 - Look for presence and size of VSD/outflow obstruction
 - With D-transposition, look for additional aortic/arch obstruction

DIFFERENTIAL DIAGNOSIS

Pulmonary Atresia-Intact Ventricular Septum

- TV patent but usually abnormal
- RV small and hypertrophied, coronary sinusoids

Double Inlet Left Ventricle

- L-looping of heart
- Usually 2 normal atrioventricular (AV) valves, but 1 can be atretic

Unbalanced Left Dominant Atrioventricular Septal Defect

- RV is small, nonapex-forming
- Common AV valve with inlet VSD and primum ASD

PATHOLOGY

General Features

- Genetics
 - 22q11 deletion in up to 8% TA

Staging, Grading, & Classification

- Type 1: Great artery relationship normal (72%)
- Type 2: D-transposition (25%)
- Type 3: L-transposition (3%)
- Type 4: Persistent truncus arteriosus (rare)

CLINICAL ISSUES

Demographics

- Epidemiology
 - 0.05/1,000 live births; M = F

Natural History & Prognosis

- Untreated, 90% mortality by 1 year
- Current surgical experience
 - 91% survival at 1 month, 83% at 1 year
 - < 2% operative mortality for children who survive to Fontan repair
 - 83% survival at 10 years
- Poor prognostic indicators
 - Low birth weight
 - Severe RV hypoplasia
 - Associated arch anomalies
 - Use of extracorporeal membrane oxygenation
 - Presence of chromosomal anomaly or syndrome

Treatment

- Prenatal consultation with pediatric cardiology/neonatology
- Planned delivery in tertiary center
- Medical management
 - Prostaglandin infusion to maintain ductal patency
 - Evaluate adequacy of pulmonary blood flow to determine need for surgery
- Surgical management
 - Blalock-Taussig shunt if pulmonary flow is insufficient in 1st week
 - Bidirectional Glenn at 4-6 months: Superior vena cava to right pulmonary artery connection
 - Fontan at 2-4 years of age: Inferior vena cava to right pulmonary artery conduit
 - Arch reconstruction and coarctation repair with PA band in setting of D-Transposition of great vessels
- Cardiac transplantation in rare cases

DIAGNOSTIC CHECKLIST

Image Interpretation Pearls

- Hypoplastic RV with plate-like TV is key to making diagnosis of TA

SELECTED REFERENCES

1. Berg C et al: Prenatal diagnosis of tricuspid atresia: intrauterine course and outcome. *Ultrasound Obstet Gynecol.* 35(2):183-90, 2010
2. Wald RM et al: Outcome after prenatal diagnosis of tricuspid atresia: a multicenter experience. *Am Heart J.* 153(5):772-8, 2007

KEY FACTS

TERMINOLOGY

- Obstruction to right ventricular outflow at level of pulmonary valve
 - Pulmonary atresia (PA): No antegrade flow across pulmonary valve
 - Pulmonary stenosis (PS): Turbulent, high-velocity flow across pulmonary valve

IMAGING

- **PA with intact ventricular septum (IVS) subtype**
 - Severe hypertrophy of RV with $RV \ll LV$
 - Coronary cameral fistula often present
- **PA with ventricular septal defect (VSD) subtype**
 - Right ventricular outflow tract (RVOT) small or nonexistent
 - Large aorta overrides VSD
 - Pulmonary arteries typically very hypoplastic
 - Often associated with major aortopulmonary collateral arteries (MAPCAs)

• Pulmonary stenosis

- Pulmonary annulus small with thickened valve

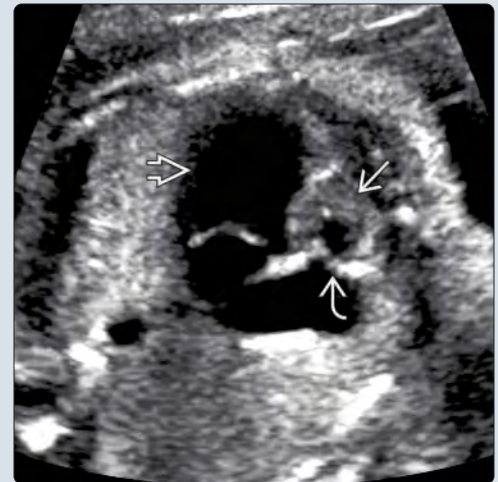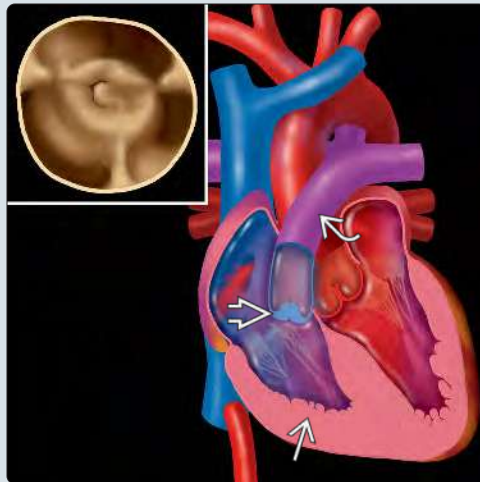
PATHOLOGY

- Maternal diabetes: 20x increased risk
- 8-23% of PA-VSD have 22q11 deletion syndrome

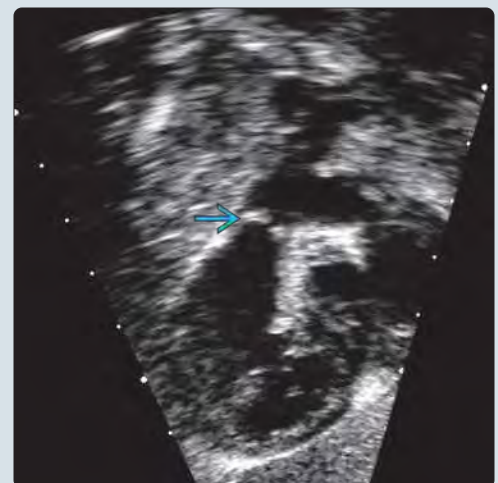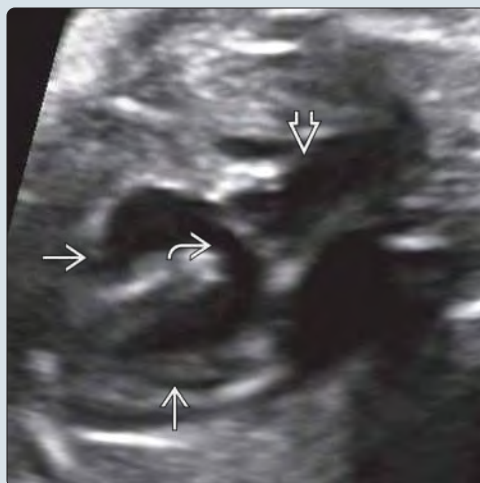
CLINICAL ISSUES

- Pulmonary circulation is ductus dependent in severe forms of PS and PA
- PA-IVS require surgery within 1st week of life
 - 67% survival at 5 years
 - Few patients achieve biventricular repair
- PS-VSD > 50% require surgery within 1 month
 - Overall survival 71% at 10 years
 - Complete repair with VSD closure and RV to pulmonary artery conduit is goal if possible
- PS in isolation ~ 1/3 improve, 1/3 remain unchanged, and 1/3 increase in severity

(Left) Graphic shows a thickened pulmonary valve. The right ventricle is hypertrophied, and the pulmonary artery is hypoplastic. Inset shows an abnormal, thickened pulmonary valve. (Right) Hypoplastic and hypertrophied right ventricle and normal-sized left ventricle are shown. The tricuspid valve was severely hypoplastic but did open and close normally with no regurgitation. Therefore, there should be a high index of suspicion for presence of coronary sinusoids.



(Left) Equal-sized ventricular chambers are shown with a large ventricular septal defect (VSD) and aorta overriding the ventricular septum. This patient had pulmonary atresia with a VSD but this picture can also be seen in truncus arteriosus or tetralogy of Fallot. (Right) Right ventricular outflow tract (RVOT) echocardiogram shows a thick and doming pulmonary valve consistent with diagnosis of pulmonary stenosis.



TERMINOLOGY

Abbreviations

- Pulmonary valve atresia (PA)
- Pulmonary valve stenosis (PS)

Definitions

- Obstruction to right ventricular outflow at level of pulmonary valve (PV)

IMAGING

General Features

- Best diagnostic clue
 - PA: No antegrade flow across PV
 - PS: Turbulent, high-velocity flow across PV

Echocardiographic Findings

- **PA with intact ventricular septum (IVS) subtype**
 - Abnormal 4-chamber view
 - Right ventricle (RV) small with decreased function
 - Severe hypertrophy of RV
 - RV << left ventricle (LV)
 - RV cavity almost nonexistent
 - Blood entering RV must get out
 - Does so either via tricuspid regurgitation (TR) or coronary cameral fistulas
 - In coronary cameral fistula (result of persistent sinusoids), coronary blood supply comes from RV, not aorta
 - High-pressure RV provides driving pressure for coronary blood flow
 - If tricuspid regurgitation is severe, RV pressure is low and coronary fistulas are typically not present
 - Right atrium (RA) may be enlarged when TR is present
 - Right ventricular outflow tract (RVOT) is small or nonexistent
 - Pulmonary arteries are usually confluent but small and fed by reverse oriented ductus arteriosus
- **PA with ventricular septal defect (VSD) subtype**
 - 4-chamber view may be normal
 - Large VSD but in outlet
 - RV and LV are symmetric in size
 - Large aorta overrides VSD
 - RV function usually is preserved
 - RVOT is small or nonexistent
 - Pulmonary arteries typically very hypoplastic
 - Often associated with major aortopulmonary collateral arteries (MAPCAs)
 - MAPCAs may be present alone or in combination with true pulmonary arteries
- **Pulmonary stenosis**
 - Pulmonary annulus is small with thickened valve
 - May see poststenotic dilation of main pulmonary artery
 - RV may be hypertrophied and small if severe
- **Color Doppler**
 - Assess absent or turbulent flow across pulmonary valve
 - Assess presence of tricuspid regurgitation
 - Assess for retrograde flow in ductus arteriosus (seen in PA and sometimes severe PS)
 - Assess shunting at atrial level (typically R → L)

- Pulsed Doppler
 - Assess gradient across pulmonary valve in PS
 - Assess gradient across tricuspid valve to estimate RV pressure

Imaging Recommendations

- Protocol advice
 - **If PA is suspected**
 - Look for presence or absence of VSD
 - Look at size of RV
 - **If PA with IVS is suspected**
 - RV should be hypoplastic and hypertrophied
 - Look for RV to coronary cameral fistulas by lowering Nyquist limit
 - Course along outer wall of heart or within septum
 - Assess tricuspid valve for abnormalities, regurgitation
 - **If PA with VSD is suspected**
 - Look for antegrade flow across pulmonary valve
 - If no antegrade flow, look for source of pulmonary blood flow
 - Reverse oriented ductus arteriosus to hypoplastic pulmonary arteries
 - MAPCAs off descending aorta or head vessels
 - If turbulent flow across pulmonary valve (PS)
 - Assess direction of flow in ductus arteriosus
 - Look for other cardiac anomalies
 - Tricuspid atresia, Ebstein anomaly, transposition of great arteries, double outlet right ventricle
 - Look for features of right atrial isomerism

DIFFERENTIAL DIAGNOSIS

Tetralogy of Fallot (ToF)

- Pulmonary stenosis from anterior deviation of infundibulum
 - Pulmonary atresia can occur (ToF with PA may also be classified as PA with VSD)
- VSD must be present
- Aorta overrides the VSD

Tricuspid Atresia

- RV not apex-forming
- VSD usually present
- Pulmonary valve may be atretic

Truncus Arteriosus

- Pulmonary arteries come off truncus in majority
- VSD almost always present
- Ventricular chambers are normal in size

PATHOLOGY

General Features

- Etiology
 - During early gestation, there is dual blood supply to lungs
 - Branches from 6th aortic arch enlarge and become true pulmonary arteries
 - Branches off thoracic aorta become smaller and disappear

- If there is no connection from right ventricle to pulmonary arteries, these connections will persist and become collateral vessels
- These patients will have pulmonary atresia with ventricular septal defect and MAPCAs
 - Pulmonary atresia with IVS occurs later in gestation after ventricular septation is complete
- Genetics
 - Case reports of siblings → possible autosomal recessive inheritance with 25% recurrence risk
 - 8-23% of PA-VSD have 22q11 deletion syndrome
 - Previously called DiGeorge, velocardiofacial, Shprintzen syndromes or CATCH 22
 - PS can be seen with Noonan, Williams, Alagille, and LEOPARD syndromes

Staging, Grading, & Classification

- PA-IVS: Classified based on coronary artery connections
- PA-VSD: Classified on basis of pulmonary circulation

CLINICAL ISSUES

Presentation

- Turbulent or absent antegrade flow across pulmonary valve
- May have abnormal 4-chamber view on routine sonography

Demographics

- Epidemiology
 - PA accounts for 3% of congenital heart disease (CHD)
 - Incidence: 8 in 100,000 live births
 - Some cases may result from fetal progression of PS
 - PS accounts for 10% of all CHD
 - ~ 1% in fetus; more severe end of spectrum
 - 3-4% present in infancy
 - Mild cases present in childhood or later
 - M = F

Natural History & Prognosis

- PA-IVS
 - Some (severe tricuspid regurgitation) may be predisposed to fetal death
 - Severe hypoxia at birth
 - Cardiomegaly → pulmonary hypoplasia
 - Require institution of prostaglandins
 - Require surgery within 1st week of life
 - 75% survival at 1 year
 - 67% survival at 5 years
 - Increased risk with prematurity, Ebstein anomaly, or RV dependent coronaries
- PA-VSD
 - > 50% require surgery within 1 month
 - Additional 25% require surgery within 3 months
 - Survival 89% at 3 year with unifocalization (type of surgical repair)
 - Multiple catheter and surgical interventions necessary
 - Overall survival 71% at 10 years
 - Poor prognostic markers
 - Low birth weight, male gender, discontinuous or absent pulmonary arteries, MAPCAs
 - 22q11 deletion
 - 2.4x relative risk of surgical mortality for PA-VSD

- Deletion is independent risk factor for surgical mortality even after correction for presence of MAPCAs
 - MAPCAs much more common with deletion syndrome

- PS
 - Depends on associated condition
 - In isolation ~ 1/3 improve, 1/3 remain unchanged, and 1/3 increase in severity

Treatment

- Consider karyotype with fluorescent in situ hybridization (FISH) for 22q11 microdeletion
- Successful fetal pulmonary valvotomies have been performed although rare
 - Postprocedural growth of RV, TV, and PV
 - Some have achieved successful biventricular repair
- Deliver at tertiary care facility
- Pulmonary circulation is ductus dependent in severe forms of PS and PA
 - Prostaglandin infusion necessary
- PA-IVS treatment
 - Transcatheter balloon valvuloplasty or radiofrequency perforation becoming 1st-line intervention
 - Blalock Taussig shunt palliation ± RVOT reconstruction often necessary
 - Few patients achieve biventricular repair
 - RV dependent coronary circulation (coronary cameral fistula) precludes decompression of RV
 - May necessitate cardiac transplantation
- PA-VSD treatment
 - Depends on presence or absence of native pulmonary arteries
 - Central shunt to pulmonary arteries or early unifocalization of MAPCAs often necessary
 - Unifocalization entails sewing MAPCAs together with native pulmonary artery → new pulmonary arteries on each side
 - Complete repair with VSD closure and RV to pulmonary artery conduit is goal if possible
- PS treatment involves balloon valvuloplasty depending on gradient
 - < 40 mm Hg is mild; no intervention necessary
 - 40-70 mm Hg is moderate; intervention is discretionary
 - > 70 mm Hg is severe; intervention is necessary

DIAGNOSTIC CHECKLIST

Consider

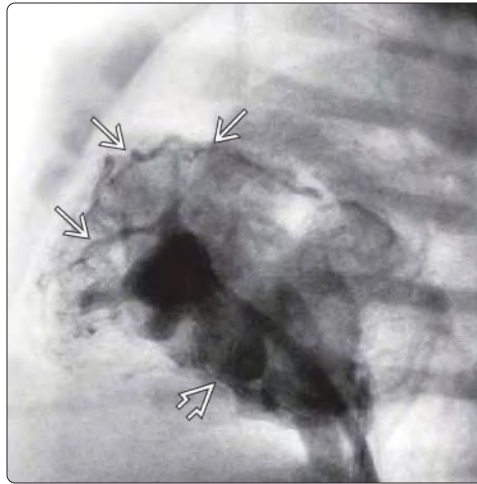
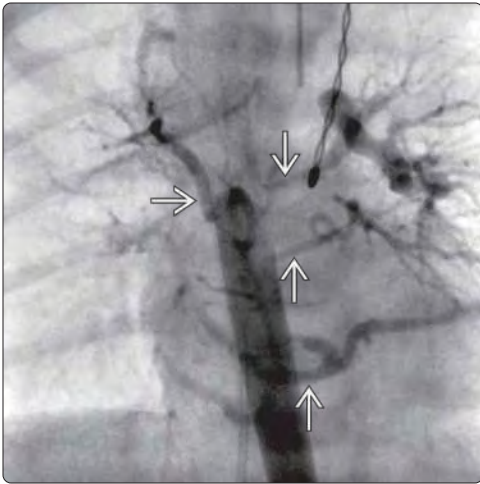
- Karyotype with FISH for 22q11 deletion
 - Independent risk factor for adverse outcome

Image Interpretation Pearls

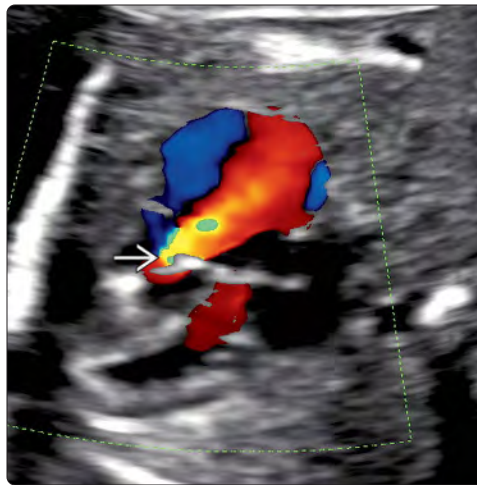
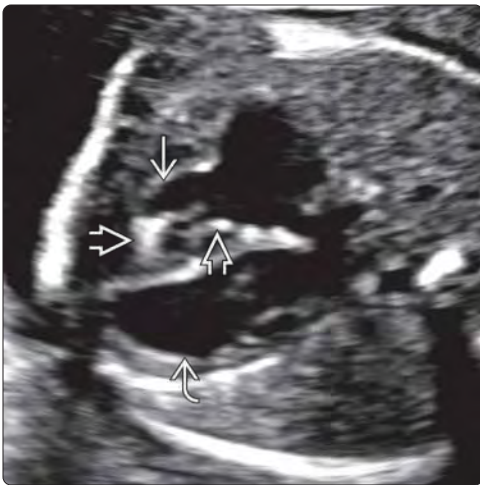
- Reverse flow in ductus arteriosus = duct dependent pulmonary circulation

SELECTED REFERENCES

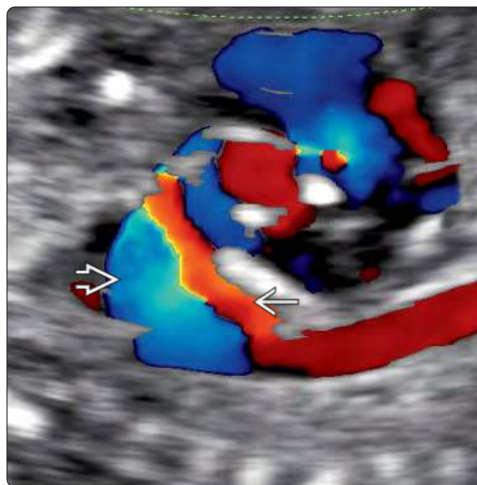
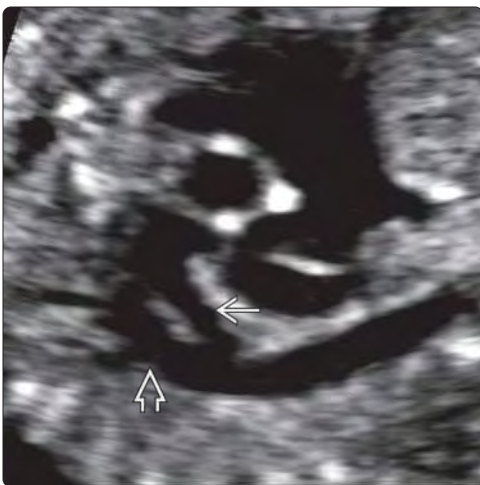
1. Schneider AW et al: More than 25 years of experience in managing pulmonary atresia with intact ventricular septum. *Ann Thorac Surg.* 98(5):1680-6, 2014



(Left) Descending aortic injection shows at least 4 collaterals coming off the descending aorta supplying blood to the lungs in this patient with pulmonary atresia with a VSD. **(Right)** Lateral oblique angiogram shows contrast injected into an extremely hypoplastic, muscle-bound right ventricle in a patient with pulmonary atresia with intact septum revealing multiple coronary sinusoids.



(Left) Four-chamber view shows a hypoplastic right ventricle with bright endocardium and chordae of the tricuspid valve and a normal-appearing left ventricle. **(Right)** The same view with color shows moderate to severe regurgitation of the tricuspid valve filling almost the entire right atrium. The degree of tricuspid regurgitation in this case suggests coronary sinusoids will not be present in this patient with PA/IVS.



(Left) Echocardiogram in a patient with pulmonary atresia shows a large ductus arteriosus filling the pulmonary arteries in a retrograde fashion. Note the clear view of the aortic arch, which is not seen in the same plane as the ductus arteriosus in normal patients. **(Right)** Image shows the same picture documenting the antegrade flow in the aorta and retrograde flow in the ductus arteriosus.

KEY FACTS

TERMINOLOGY

- Hypoplasia of left ventricle associated with
 - Mitral stenosis/atresia
 - Aortic stenosis/atresia
 - Hypoplastic ascending aorta and coarctation

IMAGING

- Left ventricle (LV) small or nonexistent
 - Hypocontractile and typically spherical, not bullet-shaped
 - May see bright echogenic LV endocardium signifying endocardial fibroelastosis
 - LV is not apex forming
- Right ventricle (RV) is dilated with good function
 - It wraps under LV apex as it enlarges to accommodate extra blood flow
- Interatrial septum bowed left to right signifying direction of blood flow
- Ascending aorta and transverse arch are very small
- Retrograde filling of aortic arch = ductal dependence

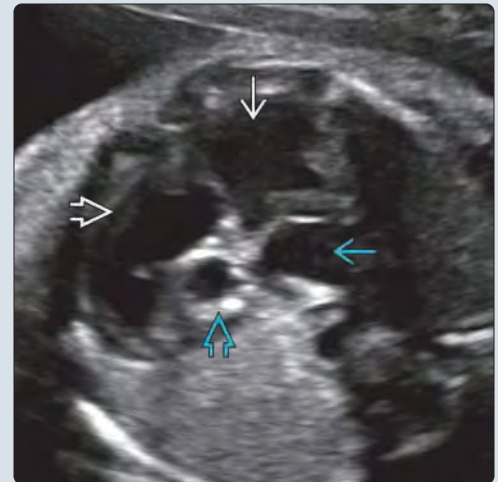
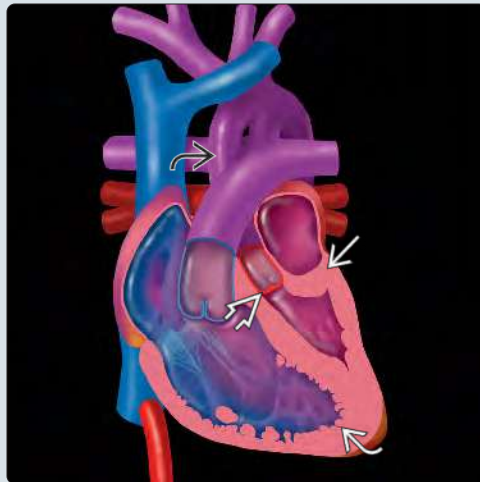
CLINICAL ISSUES

- Lethal in days/weeks if untreated
- If pregnancy continues, main choices are
 - Comfort care → no intrapartum monitoring, deliver at any institution
 - Surgical intervention → planned delivery at tertiary center specializing in cardiac surgery
 - Hybrid procedure → planned delivery at tertiary center with preference for catheter/surgery-based approach
- Improving surgical techniques → increased survival
 - > 85% success of 1st-stage Norwood in many centers
 - Near 100% for Glenn and Fontan (2nd and 3rd stage) surgeries
 - Long-term survival unknown but 6 yr survival with current techniques at 64%

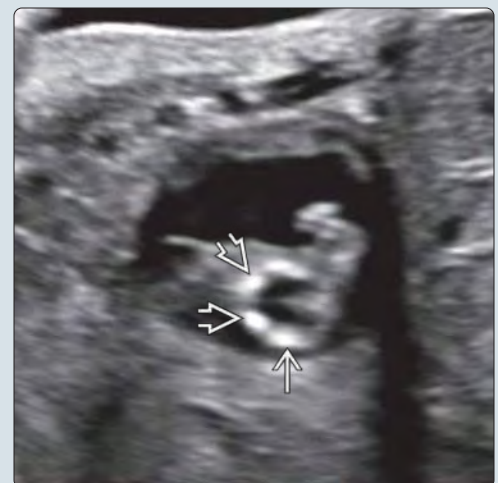
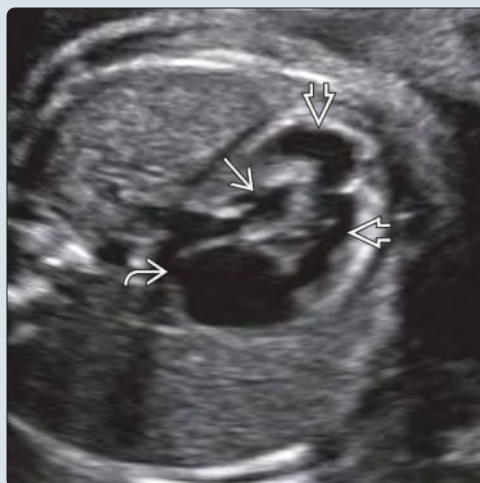
DIAGNOSTIC CHECKLIST

- Fetal echocardiography very specific for this entity

(Left) Graphic shows mitral and aortic atresia. There is asymmetry of ventricular size with the right ventricle (RV) being apex forming. The ascending aorta is hypoplastic. (Right) Four-chamber view shows a classic picture of hypoplastic left heart. The right atrium and right ventricle are large. The left atrium and left ventricle (LV) are small. The LV myocardium is much brighter than the rest of the myocardium, consistent with endocardial fibroelastosis (EFE).



(Left) Four-chamber view shows a small hypoplastic LV without significant EFE. The RV is dilated and wraps under the apex of the LV. A defect in the atrial septum is easily seen and flow was noted to be left to right as expected given the minimal flow across the mitral valve. (Right) Short-axis view of the LV shows it is almost a perfect circle. Note the hyperechoic patchy areas within the myocardium reflective of EFE.



TERMINOLOGY

Synonyms

- Hypoplastic left ventricle
- Hypoplastic left heart syndrome (HLHS)

Definitions

- Hypoplasia of left ventricle associated with
 - Mitral stenosis/atresia
 - Aortic stenosis/atresia
 - Hypoplastic ascending aorta and coarctation

IMAGING

General Features

- Best diagnostic clue
 - Abnormal 4-chamber view with small, nonapex-forming left ventricle

Echocardiographic Findings

- Echocardiogram
 - Atria
 - Interatrial septum bowed left to right
 - Only outlet for flow from left atrium (LA)
 - Occasionally restrictive septum
 - Pulmonary veins will be dilated with retrograde flow
 - LA is hypoplastic, right atrium is dilated
 - Tricuspid valve
 - Annulus is dilated, but valve is typically normal or mildly dysplastic
 - Right ventricle (RV)
 - Dilated and often wraps under LV apex
 - Hypertrophied with good function
 - Pulmonary artery is invariably dilated
 - Ductus arteriosus (DA) is large
 - Mitral valve
 - Either atretic or severely hypoplastic and stenotic
 - Left ventricle (LV)
 - Small or nonexistent
 - Hypocontractile and typically spherical, not bullet-shaped
 - May see bright echogenic LV endocardium signifying endocardial fibroelastosis
 - Aortic valve
 - Either atretic or severely hypoplastic and stenotic
 - Ascending and transverse arch very small
 - Typically associated with coarctation
- Color Doppler
 - Confirms absent or minimal flow across mitral and aortic valve
 - Left-to-right shunt across foramen ovale
 - Retrograde filling of arch from ductus arteriosus
 - May see ventriculocoronary connections in LV myocardium
 - Evaluate for presence of tricuspid regurgitation
- Pulsed Doppler
 - Confirms flow direction and degree of obstruction
 - May estimate ventricular pressures
 - May quantify degree of obstruction at atrial septum via evaluation of pulmonary vein flow pattern

Ultrasonographic Findings

- Noncardiac anomalies in 10% of autopsy cases
 - Diaphragmatic hernias
 - Major central nervous system anomalies, such as holoprosencephaly
 - Significant adverse impact on prognosis

Imaging Recommendations

- Protocol advice
 - If only 1 ventricle is seen
 - Identify morphology of remaining ventricle
 - Assess for presence of endocardial fibroelastosis (EFE)
 - Brightly echogenic LV endocardium
 - Look for ventriculocoronary connections
 - More common with mitral stenosis and aortic atresia
 - Assess for flow across AV valves
 - Mitral stenosis vs. atresia
 - Presence or absence of tricuspid regurgitation
 - Assess for flow across semilunar valves
 - Aortic stenosis vs. atresia
 - Assess flow in aortic arch
 - Coarctation is seen in majority
 - Arch fills retrograde from ductus arteriosus
 - Assess direction of shunting at atrial level
 - Left → right across foramen ovale
 - If atrial septum is restrictive or intact, Doppler pulmonary veins

DIFFERENTIAL DIAGNOSIS

Severe Aortic Stenosis (AS)

- Antegrade flow across aortic valve
- Mitral valve may be normal in size
- LV may be apex-forming

Coarctation of Aorta (CoA)

- Mitral and aortic valve may be normal or small in size
- LV typically apex forming
- Consider association with Turner and Shone syndromes

Shone Syndrome

- In complete form, includes supraaortic mitral membrane, parachute mitral valve, subaortic stenosis, and aortic coarctation
- Definition is often expanded to include mitral and aortic valve stenosis as well as supraaortic stenosis
- In other words, multiple left-sided obstructions occurring together

PATHOLOGY

General Features

- Etiology
 - Multiple theories with no single unifying explanation
 - Structural defect early in cardiac development, which may be progressive
 - Form follows function, embryology perspective
 - Aortic atresia → no flow out of LV → hypoplasia of LV and aorta
 - Mitral atresia → no flow into LV → hypoplasia of LV and aorta

- Genetics
 - Strong evidence for genetic factors and significant recurrence risk in families
 - Pedigree analyses have shown 12% prevalence of cardiac abnormalities (Bicuspid aortic valve, AS, CoA, HLHS) in 1st-degree relatives of HLHS patients
 - No common causative gene is specific to HLHS (due to high genetic heterogeneity), but there are genetic associations
 - *NOTCH1*, *dHAND*, *HRT1*, and *HRT2*, *NKX2-5*
 - Association of HLHS with some chromosomal anomalies:
 - Turner syndrome (45,XO) fetuses reported to be as high as 13%
 - Trisomy 18 and 13
 - 10% of Jacobsen syndrome (distal 11q deletion)

Gross Pathologic & Surgical Features

- Endocardial fibroelastosis
 - Thickening of endocardial layer by abundant collagen and elastic tissue presumably from ischemia
 - Usually associated with aortic atresia or severe AS

CLINICAL ISSUES

Presentation

- Most cases detected on routine 18-20 week scan
- Abnormal 4-chamber view

Demographics

- Epidemiology
 - 2.8% congenital heart disease
 - 0.16/1,000 live births
 - Male predominance of 55-67%

Natural History & Prognosis

- Prenatal diagnosis
 - 20% intrauterine fetal demise
- Most severe congenital heart lesion presenting in neonate
 - Lethal in days/weeks if untreated
- Improving surgical techniques → increased survival
 - > 85% success of 1st-stage Norwood in many centers
 - Near 100% for Glenn and Fontan (2nd and 3rd stage) surgeries
 - Long-term survival unknown
 - May be improving in current era due to many factors
 - Most recent large studies still show up to 45% mortality at 6 yr of age
 - Centers performing hybrid procedure are 15% of total cases and have higher mortality rates at 30%
- Recurrence risk
 - 2% with 1 sibling, 6% with 2

Treatment

- Offer karyotype
 - Chromosomal abnormality in 15%
 - Turner syndrome most common
- May offer termination given lethality and uncertain long-term outcomes
 - Termination depends on many factors but decreasing in frequency, at least in USA
 - USA (13%), Europe (44-71%)
- If pregnancy continues, several choices

- Comfort care → no intrapartum monitoring, deliver at any institution
- Surgical intervention → planned delivery at tertiary center specializing in cardiac surgery
- Hybrid approach → planned delivery at tertiary center with preference for catheter/surgery-based approach
- Heart transplantation → not offered at birth but option with surgical failure
- **3-stage surgical palliation most common**
 - **Stage 1 (Norwood):** 1st week of life
 - Construction of neo-aorta from pulmonary artery, aorta, and graft
 - Atrial septectomy
 - Pulmonary blood flow supplied by Blalock-Taussig shunt or RV-pulmonary conduit (Sano modification)
 - **Stage 2 (Glenn):** 3-6 months
 - Superior vena cava to right pulmonary artery connection
 - Hemi-Fontan also performed in some institutions
 - **Stage 3 (Fontan):** 2-5 yr
 - Inferior vena cava to right pulmonary artery conduit
 - May be lateral tunnel type or extracardiac conduit
 - Fenestration from conduit to right atrium often used as pop-off for systemic blood flow
- Hybrid palliation
 - Involves ductal stent and bilateral PA bands after birth
 - Complex 2nd-stage surgery with a Norwood and arch reconstruction with a Glenn at 4-6 months of age
- Heart transplant
 - Option now used mostly for surgical failures
 - Mortality while waiting not insignificant
- Fetal intervention has been reported to prevent development of HLHS
 - Balloon valvuloplasty in severe fetal aortic stenosis
 - Carries risk of fetal demise (19%)
 - Approximately 1/2 of patients make it to hospital discharge with 29% achieving biventricular circulation

DIAGNOSTIC CHECKLIST

Consider

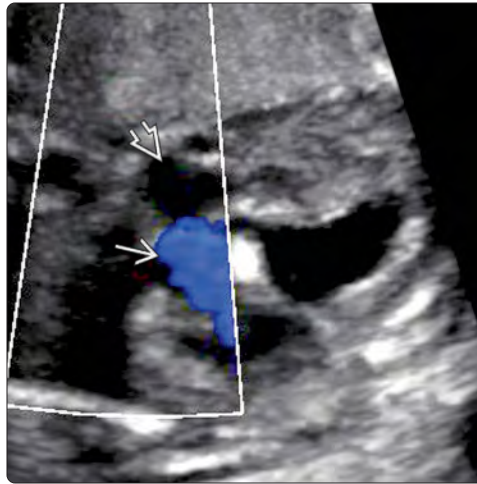
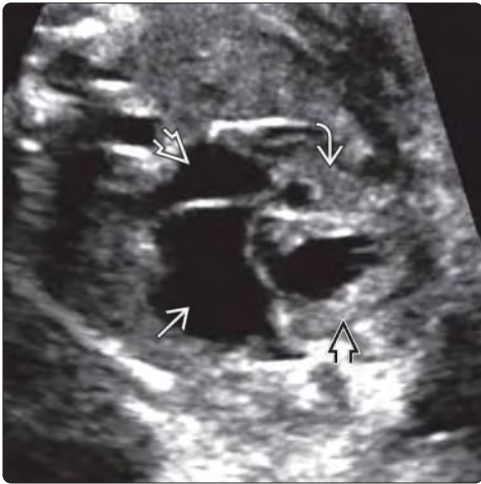
- Fetal echocardiography very specific for this entity
 - 95% prenatal diagnoses confirmed

Image Interpretation Pearls

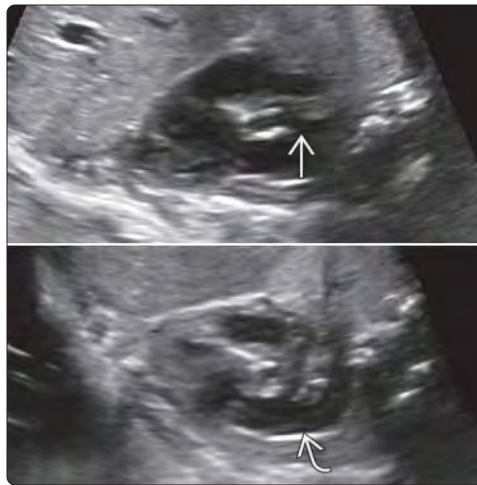
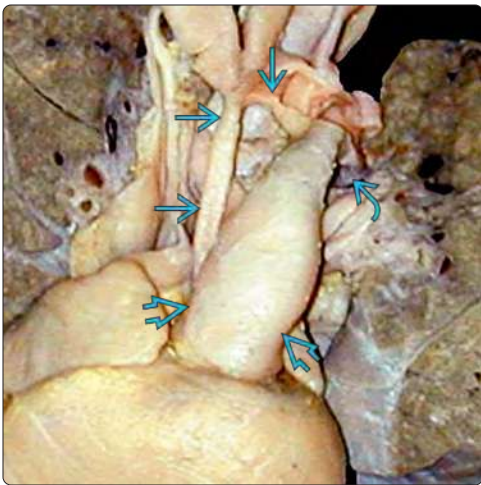
- Left ventricle small and nonapex-forming, hypocontractile
- Small to nonexistent mitral/aortic valves
- Ascending aorta hypoplastic with retrograde flow from ductus arteriosus

SELECTED REFERENCES

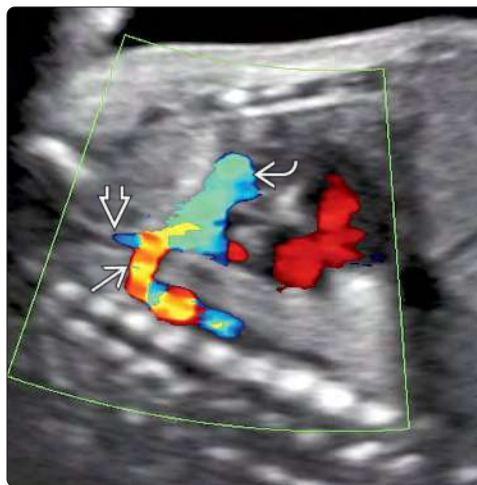
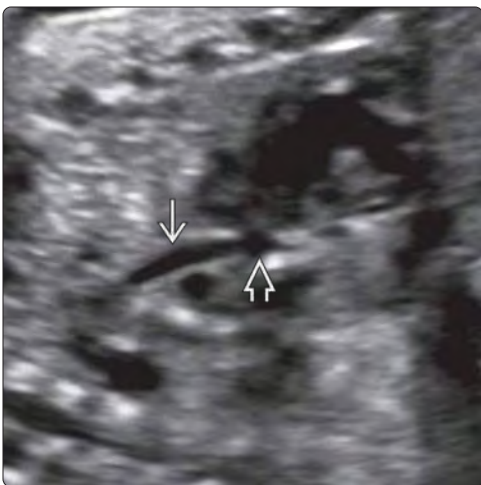
1. Karamlou T et al: Stage 1 hybrid palliation for hypoplastic left heart syndrome—assessment of contemporary patterns of use: an analysis of The Society of Thoracic Surgeons Congenital Heart Surgery Database. *J Thorac Cardiovasc Surg.* 149(1):195-201, 2022.e1, 2015
2. Wilder TJ et al: Survival and right ventricular performance for matched children after stage-1 Norwood: Modified Blalock-Taussig shunt versus right-ventricle-to-pulmonary-artery conduit. *J Thorac Cardiovasc Surg.* 150(6):1440-50, 2015
3. Barron DJ et al: Hypoplastic left heart syndrome. *Lancet.* 374(9689):551-64, 2009



(Left) Four-chamber view fetal echocardiogram shows a large right atrium in comparison to the small left atrium. The LV is hypoplastic and hypertrophied, and the RV is hypertrophied. (Right) Color Doppler echocardiogram in the same patient shows all L → R flow across the foramen ovale consistent with left heart obstruction (left atrium).



(Left) Gross pathology shows a hypoplastic ascending aorta and transverse arch, and a very large main pulmonary artery with continuation to the descending aorta via the ductus arteriosus. (Right) This comparison of the standard outflow tract views in a fetus with a hypoplastic left heart shows a very small left ventricular outflow tract compared to the large right ventricular outflow tract.



(Left) Aortic arch view shows a hypoplastic ascending aorta. The location of the aortic valve can be seen given the location of the aortic sinuses. (Right) Color Doppler in the same case shows reversal of blood flow in the transverse arch with some blood even supplying the head. This typically implies lack of antegrade blood flow across the aortic valve. Blood flow needs to get to the coronary arteries to perfuse the heart. Note normal antegrade flow in the main pulmonary artery.

KEY FACTS

TERMINOLOGY

- Coarctation: Narrowing of aortic arch
- Interrupted arch: Occlusion of aortic lumen

IMAGING

- Coarctation
 - Can be discrete or long segment
 - Asymmetry in ventricular size (RV > LV)
 - Aortic valve < pulmonary valve in diameter
 - Mitral valve smaller than tricuspid valve
 - Hypoplasia of transverse arch and isthmus suggests coarctation
 - Color Doppler may show
 - Focal turbulence at narrowed area
 - Left-to-right shunt across foramen ovale
 - Reverse or retrograde flow in transverse arch
- Interrupted aortic arch
 - Normal candy cane curve not seen

- Arch gives rise to 1 or more head and neck vessels, which extend straight into neck
- Descending aorta reconstituted by ductus arteriosus
- Interrupted aortic arch rarely occurs in isolation
 - Almost always ventricular septal defect with posterior deviation of infundibular septum

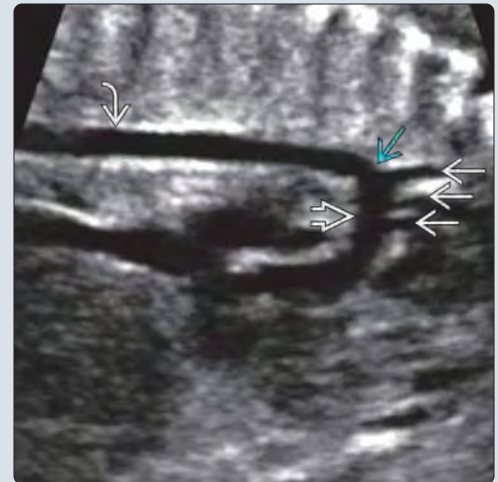
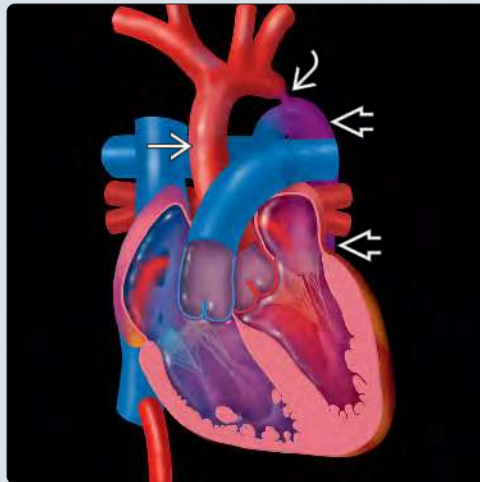
PATHOLOGY

- 35% of Turner syndrome patients have coarctation
- 22q11 deletion (DiGeorge syndrome)
 - Present in > 50% of interrupted aortic arch cases

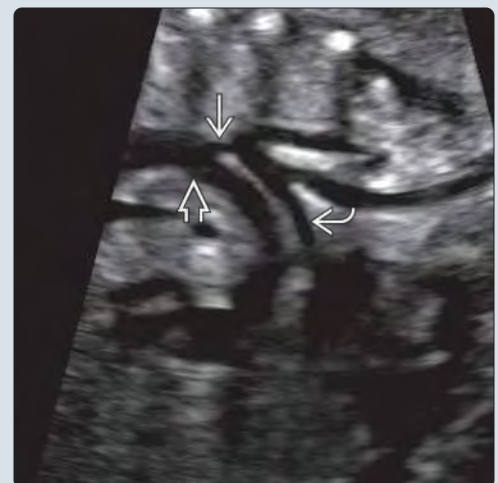
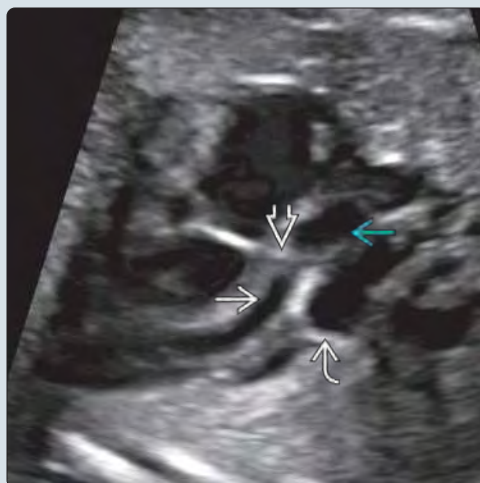
CLINICAL ISSUES

- Coarctation accounts for 6-8% of congenital heart disease
- Early arch repair straightforward with excellent outcomes
 - Normal life expectancy
 - Restenosis (10-15%)
- Recurrence risk for coarctation of aorta
 - 1 sibling (2%), 2 siblings (6%), mother (4%), father (2%)

(Left) Graphic shows aortic coarctation distal to the head and neck vessels, with hypoplasia of the ascending aorta. Blood flow in the descending aorta is mainly from the ductus. **(Right)** Sagittal echocardiogram shows the normal candy cane aortic arch with 3 normal head and neck vessels arising from it. The descending aorta is well visualized almost to the diaphragm, and the isthmus is only slightly narrower than the descending aorta.



(Left) Echocardiogram shows a narrowed left ventricular outflow tract with a suggestion of a thick aortic valve and mitral valve. The ascending aorta seems normal in size, but don't be fooled as this just suggests that there is still antegrade flow across the aortic valve. **(Right)** This image shows a discrete coarctation as the isthmus appears to almost enter the top of the ductus arteriosus. Note also the significant transverse arch hypoplasia.



TERMINOLOGY**Abbreviations**

- Coarctation of aorta (CoA)
- Interrupted aortic arch (IAA)

Definitions

- **Coarctation**
 - Narrowing of aortic arch
 - Can be discrete or long segment
 - Discrete typically has narrowing at aortic isthmus
 - Part of aorta distal to left subclavian take-off and proximal to insertion of ductus arteriosus
- **IAA**
 - Ascending aorta supplies one or all head vessels
 - Ductus arteriosus is patent, supplies lower body

IMAGING**General Features**

- Best diagnostic clue
 - Serial decrease in aortic isthmus size for coarctation
 - Progressive left/right size discrepancy, including valves and great vessels
 - Inability to see candy cane aortic arch when interrupted

Echocardiographic Findings

- **Coarctation**
 - Asymmetry in ventricular size
 - Mean right:left ventricular diameter ratio 1.69 ± 0.16 in affected fetuses
 - 1.19 ± 0.08 in normal fetuses
 - Aortic valve (AV) < pulmonary valve (PV) in diameter
 - AV/PV ratio < 0.6 suggests coarctation
 - Mitral valve (MV) smaller than tricuspid valve (TV)
 - MV:TV ratio < 0.6 suggests coarctation
 - Transverse arch/isthmus hypoplasia suggests coarctation
 - Isthmus diameter Z-score < 2
 - Transverse arch measurement < 3 mm
 - Isthmus to ductal ratio < 0.74
 - Color Doppler
 - May show focal turbulence at narrowed area
 - Left-to-right shunt across foramen ovale with left ventricle (LV) outflow obstruction
 - \uparrow LLV pressure \rightarrow \uparrow left atrial (LA) pressure \rightarrow flow direction at foramen ovale changes, becomes left to right
 - Retrograde flow in transverse arch
 - Pulsed Doppler
 - May show increased velocity distal to coarctation
- **IAA**
 - Ascending aorta gives rise to 1 or more head and neck vessels, which extend straight into neck
 - Descending aorta is supplied by ductus arteriosus like normal fetus
 - Typically associated with malalignment-type ventricular septal defect (VSD)
 - Left ventricular outflow tract (LVOT), aortic valve, and ascending aorta are usually small given that they only supply head

Imaging Recommendations

- Protocol advice
 - Serial measurements and later gestational age improve diagnostic accuracy
 - If ventricular asymmetry (RV > LV) is seen
 - Measure transverse arch, isthmus, and ductus serially
 - Measure AV valves and semilunar valves serially
 - Use color and pulsed Doppler to assess arch turbulence, increased velocity
 - Look for associated malformations
 - Aortic stenosis (possible bicuspid valve; difficult fetal diagnosis)
 - Conotruncal malformations
 - Ventricular septal defects in 50%
 - Mitral valve disease in conjunction with Shone syndrome
 - Supravalvar mitral ring
 - Parachute mitral valve
 - Careful survey for additional extracardiac malformations
 - Turner syndrome
 - Cystic hygroma
 - Characteristic finding is "domed" pedal edema

DIFFERENTIAL DIAGNOSIS**Other Causes of Left Heart Outflow Obstruction**

- Isolated aortic stenosis
 - Small ascending and transverse arch due to decreased flow
 - Retrograde flow around arch in severe cases
- Hypoplastic left heart syndrome
 - Left ventricle is not apex-forming
 - Severe mitral stenosis/atresia
 - Severe aortic stenosis/atresia

Other Causes of Ventricular Asymmetry

- Right heart enlargement
 - Shunt lesions with increased venous return

PATHOLOGY**General Features**

- Etiology
 - Coarctation due to abnormal development of left 4th, 6th aortic arches
 - 2 main theories for development
 - Hemodynamic theory
 - Diminished blood flow from LV across aortic arch results in hypoplasia
 - Ductal tissue theory (postnatal process)
 - Upon closing, ductal tissue pulls aortic wall toward ductal orifice, causing narrowing
- Genetics
 - Turner syndrome (45, XO)
 - 35% of Turner syndrome patients have CoA
 - 22q11 deletion (DiGeorge syndrome)
 - Present in > 50% of interrupted aortic arch cases
 - Right-sided aortic arch with aberrant left subclavian more common
 - *NOTCH1* mutations have been linked to patients with left-sided obstructive lesions

- Associated abnormalities
 - Cardiac malformations are common
 - Bicuspid aortic valve in 85%
 - Ventricular septal defect in 35%
 - Mitral valve abnormality, especially in conjunction with Shone syndrome
 - Noncardiac abnormalities in 25%

Staging, Grading, & Classification

- Coarctation
 - Isolated or simple coarctation
 - Complex coarctation
 - Coarctation + complex intracardiac anomalies including ventricular septal defects
- Interrupted aortic arch
 - Type A: Distal to left subclavian artery
 - Type B: Between left common carotid and subclavian arteries (most common)
 - Type C: Between innominate and left common carotid arteries (rarest)

CLINICAL ISSUES

Presentation

- Abnormal nuchal thickness in 1st trimester
 - Marker for aneuploidy, also associated with congenital heart disease (CHD)
- Ventricular asymmetry $RV > LV$
- Transverse arch hypoplasia or absent arch view is more specific

Demographics

- Epidemiology
 - Coarctation accounts for 6-8% of CHD
 - 0.2-0.6:1,000 live births
 - M:F = 1.3-1.7:1
 - Interrupted aortic arch accounts for < 1.5% CHD

Natural History & Prognosis

- Arch hypoplasia may progress over course of gestation
- Prognosis in CoA depends on associated anomalies and timing of diagnosis
 - Early arch repair straightforward with excellent outcomes
 - Normal life expectancy
 - Restenosis (10-15%)
 - Delayed diagnosis in severe cases
 - Cardiovascular collapse at presentation
 - Longer hospital stay is rule but still excellent long-term outcome
 - Delayed diagnosis in mild cases
 - Develop systemic hypertension in upper extremities
 - Progressive left ventricular hypertrophy
 - Outcomes less favorable due primarily to added secondary morbidity
- CoA + left heart hypoplasia defined as mitral or aortic valve with Z-score < -2
 - 51 neonates followed-up long-term to mean of 15 years (range: 11-18 years)
 - All were alive and well with 90% having recent echo
 - Both aortic and mitral valves were normal in size for body surface area

- 24% had required reintervention
 - 18% for recoarctation
- Turner syndrome has less favorable outcomes due to intrinsic aortic wall abnormalities
- Interrupted aortic arch
 - Rarely occurs in isolation
 - Almost always with VSD and posterior deviation of infundibular septum
- Recurrence risk for CoA
 - 1 affected sibling (2%), 2 affected siblings (6%), affected mother (4%), affected father (2%)

Treatment

- Offer karyotype
 - In females with coarctation for Turner syndrome
 - In patients with interrupted aortic arch, fluorescent in situ hybridization (FISH) for 22q11 deletion
- Prenatal consultation with pediatric cardiology/neonatology
- Deliver at tertiary center
- Goal at delivery is to maintain ductal patency as systemic perfusion is duct dependent
 - Prostaglandin infusion
 - Avoid supplemental oxygen
- Definitive treatment for coarctation is primary surgical repair
 - Resection with extended end-to-end anastomosis is most common type of repair
 - Isolated arch repair < 1% mortality in experienced hands
 - Repair when associated with VSD increases mortality to 2.5%
 - Repair when associated with other major cardiac diagnoses increases to almost 5%
 - Subclavian flap aortoplasty and patch aortoplasty are rare
- Balloon angioplasty
 - Associated with restenosis
 - Now mostly reserved for recoarctation and late diagnoses with stent implantation
- Definitive treatment for interrupted aortic arch is primary surgical repair
 - Mortality is up to 20% at 1 year and 28% at 5 years
 - Likely due in part to increased rate of genetic syndromes

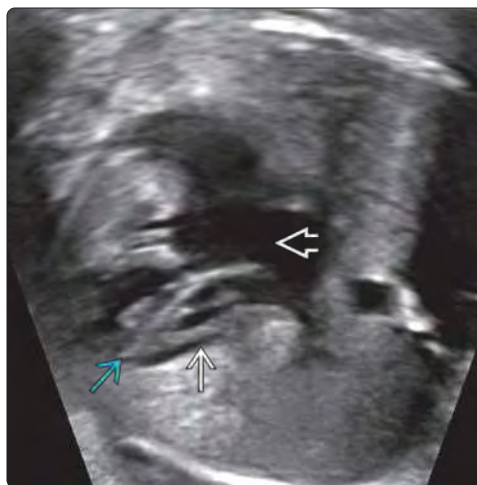
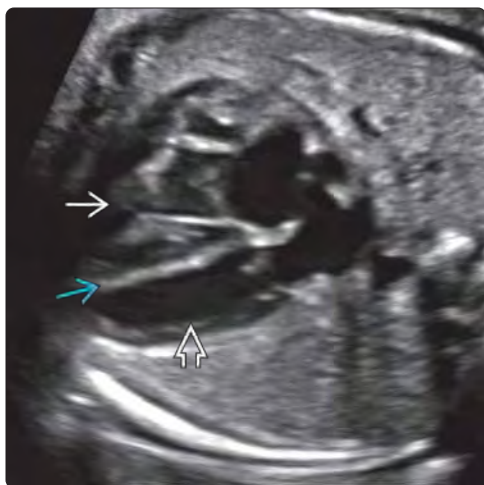DIAGNOSTIC CHECKLIST

Consider

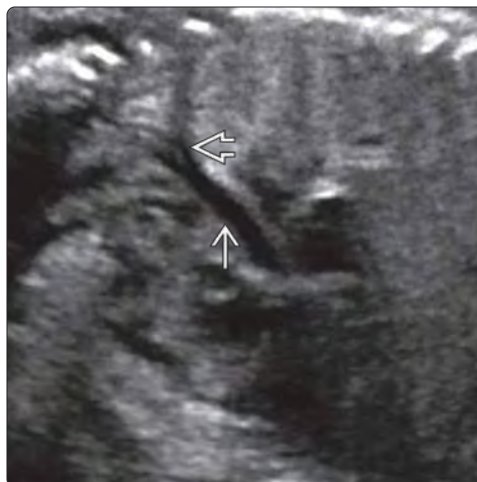
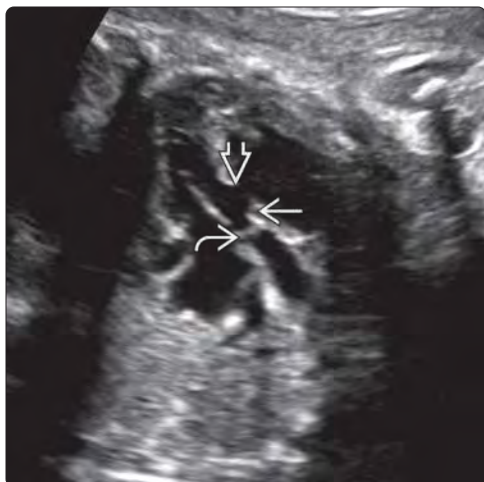- Formal fetal echocardiography
 - Coarctation, especially discrete narrowing, is difficult diagnosis in utero
 - Primarily due to presence of ductus arteriosus
 - At-risk fetus with normal study still needs postnatal evaluation

SELECTED REFERENCES

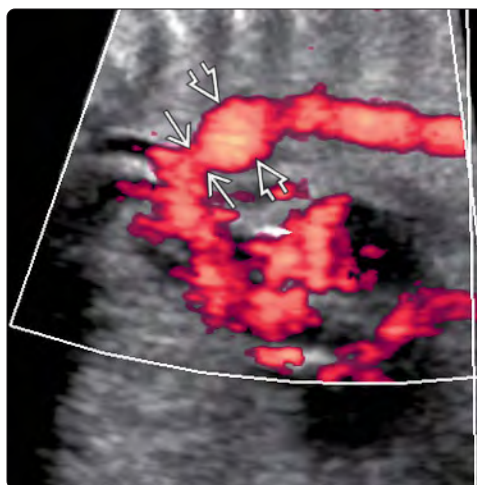
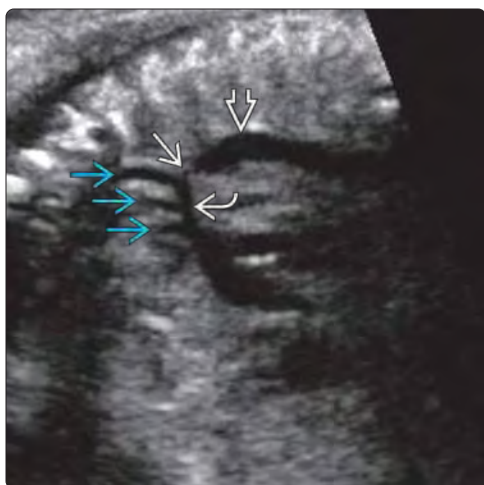
1. Gómez-Montes E et al: Gestational age-specific scoring systems for the prediction of coarctation of the aorta. *Prenat Diagn.* 34(12):1198-206, 2014
2. Jowett V et al: Sonographic predictors of surgery in fetal coarctation of the aorta. *Ultrasound Obstet Gynecol.* 40(1):47-54, 2012



(Left) Suspicion for an arch abnormality increases when the right ventricle is dilated compared to the left even when still apex-forming. Good valve measurements and arch assessment are essential to confirm the diagnosis. Ventricular septum is noted. (Right) Another 4-chamber view shows a much smaller left ventricle. It is important to note here that this did up end being a 2-ventricle repair and not a hypoplastic left heart. Note also the large atrial septal defect and ventricular septum.



(Left) This is an excellent image of posterior deviation of the infundibulum in the setting of a ventricular septal defect and small aortic valve. This is a classic set-up for an interrupted aortic arch. (Right) Image shows a hypoplastic ascending aorta without an arch, consistent with interruption of the aorta. One can see a branch as it extends into the neck, likely the innominate artery. This patient had the most common type of interruption, type B, between the left common carotid and subclavian arteries.



(Left) Image shows progressive tapering of the transverse arch. All 3 head and neck vessels are seen and the isthmus becomes very narrow before entering the descending aorta. (Right) Color Doppler in the same patient shows how one can be fooled by the color encoding making a structure (in this case, the isthmus) appear larger than it is. What does stand out, and may help with the diagnosis of coarctation, is the very large segment of descending aorta where the ductus arteriosus inserts.

KEY FACTS

TERMINOLOGY







- Obstruction to flow across aortic valve
 - Valvar
 - Subvalvar: Fixed or dynamic
 - Supravalvar: Narrowing in proximal aorta

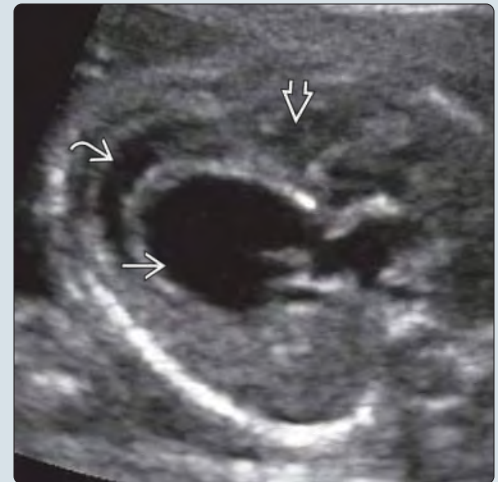
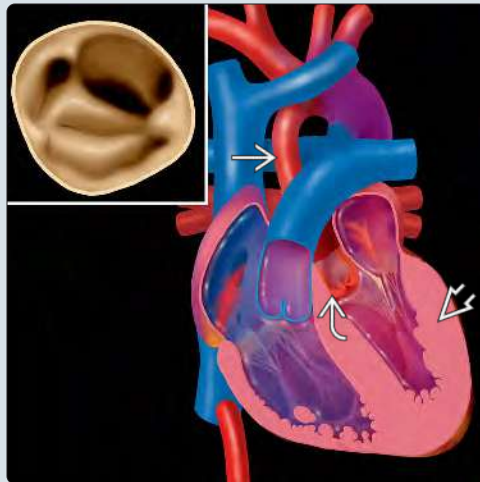
IMAGING





- Aortic stenosis (AS)
 - Valve often bicuspid (difficult to see in fetus)
- Critical AS → minimal flow in aorta
 - Retrograde filling of arch via ductus arteriosus
 - Reverse flow in transverse arch indicates ductal dependency
- Subvalvar aortic (subaortic) stenosis
 - Muscular: Look for asymmetric septal hypertrophy
 - Fibrous: Membrane from septum to mitral valve
- Supravalvar aortic stenosis
 - Typical ridge at sinotubular junction

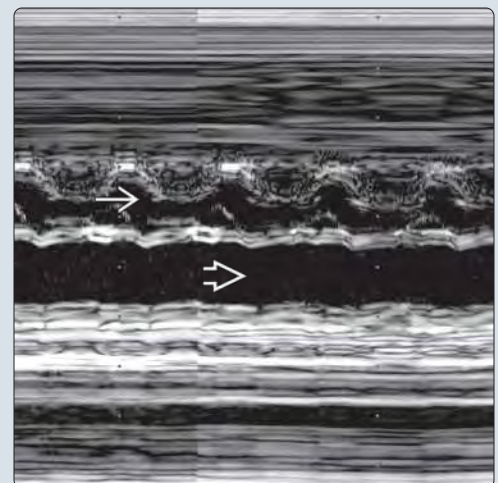
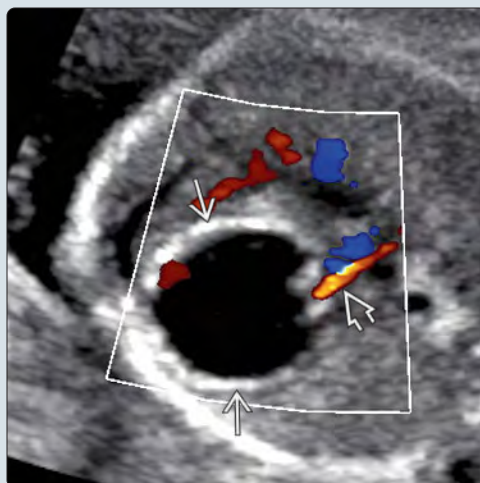
CLINICAL ISSUES

- Accounts for 3-8% of all congenital heart disease
 - 60-75% valvar
 - 10-20% subvalvar
- Prognosis of valvar AS varies with severity of obstruction and associated anomalies
 - Balloon valvuloplasty for severe fetal AS in hopes of preventing progression to hypoplastic left heart is possible but carries high risk
 - Approximately 1/2 (53%) who undergo valvuloplasty survive to hospital discharge
 - Only 29% of survivors have biventricular circulation
 - Severe valvar stenosis (mean gradient > 40 mm Hg) requires intervention
 - Balloon aortic valvuloplasty has generally supplanted open surgical valvotomy as initial treatment
 - Mortality is 13% at 15 years, 19% at 20 years
 - Mild valvar stenosis (mean gradient < 25 mm Hg) progresses slowly, intervention by 4th-6th decade

(Left) Graphic of valvar aortic stenosis shows a small aortic annulus with a thickened valve , hypoplastic ascending aorta , and thickened left ventricle (LV) myocardium . The insert shows a bicuspid valve end-on. This is the most common type of aortic stenosis. (Right) Four-chamber view of the heart shows a very dilated left ventricle , which is compromising the right ventricle so much so that it is not well seen . A pericardial effusion is also noted at the apex of the heart .



(Left) Color Doppler US in the same patient shows the left ventricle with echogenic areas reflective of endocardial fibrosis/fibroelastosis in the septum and free wall . There is mitral regurgitation , suggesting that there is at least some flow in the LV even though almost no color is seen in the cavity itself. (Right) M-mode shows a right ventricle  with normal function and a left ventricle  with minimal contractility. The LV is unable to contract against severe fixed obstruction in critical aortic stenosis (AS).



TERMINOLOGY**Abbreviations**

- Aortic stenosis (AS)

Definitions

- Obstruction to flow across aortic valve
 - Valvar
 - Subvalvar: Fixed or dynamic
 - Supravalvar: Narrowing in proximal aorta

IMAGING**General Features**

- Best diagnostic clue
 - Turbulent, high-velocity flow across aortic valve

Echocardiographic Findings

- Left ventricle (LV) may be large, small, or normal in size
 - May see concentric hypertrophy
 - May see bright walls (i.e., endocardial fibroelastosis)
 - LV function may be decreased
 - Right ventricle (RV) may be large to compensate cardiac output
- **Valvar aortic stenosis**
 - Thickened aortic valve leaflets
 - Valve often bicuspid (difficult to see in fetus)
- **Subvalvar aortic (subaortic) stenosis**
 - Muscular: Look for asymmetric septal hypertrophy
 - Fibrous: Membrane present from ventricular septum to mitral valve leaflet (more common)
- **Supravalvar aortic stenosis**
 - Typical ridge at sinotubular junction
 - Gives hourglass appearance to proximal ascending aorta
- Color Doppler
 - Turbulent flow in left ventricular outflow
 - May be at valve, or start below or above valve
 - Critical AS → minimal flow in aorta
 - Retrograde filling of arch via ductus arteriosus due to lack of antegrade flow
 - Mitral regurgitation from increased LV pressure
 - Left-to-right shunt across foramen ovale
 - ◻ Left atrial pressure ↑ so flow direction at foramen ovale changes, becomes left to right
- Pulsed Doppler
 - Used to measure gradient across, above, and below aortic valve
 - Pressure difference may not reflect severity of stenosis
 - ◻ Due to presence of ductus arteriosus
 - ◻ Due to degree of ventricular dysfunction
 - Assess for restriction at atrial level
 - Assess for obstruction across mitral valve

Imaging Recommendations

- Protocol advice
 - If LV is small/large and hyperechoic with decreased function
 - Evaluate flow across aortic valve
 - Assess direction of flow across ascending and transverse aortic arch

- Look for mitral regurgitation
- Assess direction of flow across atrial septum
- If turbulent flow across aortic valve
 - Assess size of aortic valve
 - Look for narrowing above or below aortic valve
 - Assess where turbulence begins by color Doppler
- Look for associated cardiac malformations (30% of fetuses)
 - Coarctation/interrupted aortic arch
 - Consider Shone syndrome
- Monitor for growth restriction
 - ↑ risk due to poor placental perfusion
- Monitor for progression to hypoplastic left heart syndrome
 - Postnatal management more complex than isolated AS
- Careful survey for additional extracardiac malformations
 - Williams syndrome (supravalvar AS)
 - ◻ Abnormal facies and kidney abnormalities

DIFFERENTIAL DIAGNOSIS**Spectrum of Left Heart Outflow Obstruction**

- **Hypoplastic left heart**
 - LV not apex-forming
 - Typically associated with aortic and mitral atresia
 - May occur as end result of critical AS in utero
- **Coarctation and interrupted aortic arch**
 - Look for isthmus hypoplasia or absence
 - RV > LV size
 - Main pulmonary artery > aorta and tricuspid valve > mitral valve
- **Shone syndrome**
 - In complete form, includes supravalvular mitral membrane, parachute mitral valve, subaortic stenosis, and aortic coarctation
 - Definition is often expanded to include mitral and aortic valve stenosis as well as supravalvular aortic stenosis
 - In other words, multiple left-sided obstructions occurring together

PATHOLOGY**General Features**

- Etiology
 - Complex interaction of environmental and genetic factors not well understood
 - Compelling evidence for genetic link
 - Mechanical factors, such as abnormal fluid dynamics, have been implicated as well
 - Bicuspid aortic valve
 - Results from partial or complete fusion of 2 aortic valve cusps
 - Large variation in types of bicuspid valves exist
 - Some patients have associated cystic medial necrosis
 - ◻ Results in dilation of ascending aorta with risk of dissection or rupture
 - Subaortic stenosis
 - Collar or ridge of fibromuscular tissue encircling LV outflow tract
 - May also be diffuse and tunnel-like

- Tissue is closely related or "tethered" to mitral valve
- Supravalvar aortic stenosis
 - Reduced elastin in arterial media
 - Decreased elasticity, smooth muscle hypertrophy, increased collagen
 - Commonly localized to sinotubular junction but can involve other arteries
- Genetics
 - AS is known to occur in genetic syndromes
 - Turner syndrome (45, XO), Jacobsen syndrome
 - Single-gene autosomal dominant inheritance has also been reported
 - Family members with hypoplastic left heart syndrome and bicuspid aortic valve
 - Role of *NOTCH-1* gene mutations associated with bicuspid aortic valves
 - **Recurrence risk**
 - **Valvar AS**
 - 1 sibling (2%); 2 siblings (6%)
 - Affected mother (13-18%); affected father (3%)
 - **Subvalvar AS**
 - Most cases are sporadic and develop postnatally
 - Many believe this is an acquired condition and not congenital
 - **Supravalvar AS**
 - 30-50% have Williams syndrome; autosomal dominant, gene deletion for elastin ELN on 7q11.23
- Freedom from repeat valvuloplasty and aortic valve replacement is 65% and 61% at 15 years respectively
- Subvalvar AS diagnosed in childhood usually progresses
 - Associated cardiac defects are present in > 50%
 - Often causes aortic regurgitation prompting earlier treatment
- Supravalvar AS rarely requires intervention in infancy but progresses
 - Aortic valve is abnormal in 50%
 - Coronary artery stenoses is common cause of sudden death
- Bicuspid aortic valve patients are often asymptomatic
 - Eventual significant AS development later in life, ~ 50 years of age
 - May develop dilation of aortic root or ascending aorta earlier

Treatment

- Balloon valvuloplasty in severe fetal AS in hopes of preventing progression to hypoplastic left heart
 - Selection criteria
 - Unequivocal AS vs. aortic atresia
 - LV long and short axis Z-score > 0
 - Aortic annulus Z-score > -3.5
 - Mitral valve annulus Z-score > -2.0
 - Mitral or aortic max systolic gradient \geq 20 mm Hg
 - One point given for each dimension; score \geq 4 suggests fetus may benefit from prenatal intervention
 - Prenatal intervention carries risk of fetal demise (19%)
 - 53% survive to hospital discharge
 - Only 29% of survivors achieve biventricular circulation
- Prostaglandins are required at birth if ductal dependent critical AS
- Balloon valvuloplasty is 1st-line therapy for valvar AS if LV is adequate in size
- Surgical aortic valve repair/replacement is common over lifetime
 - Aortic root replacement often necessary at same time if dimension > 40 mm
- Subvalvar and supravalvar stenosis that progresses requires surgical intervention
- Survivors need lifetime follow-up

CLINICAL ISSUES

Presentation

- Most common fetal presentation is abnormal 4-chamber view detected on routine antenatal screening

Demographics

- Epidemiology
 - Bicuspid aortic valve occurs in 1.3% population
 - One of most common congenital heart malformations
 - AS accounts for 3-8% all congenital heart disease
 - 60-75% valvar
 - M:F = 3-5:1
 - 10-20% subvalvar
 - M:F = 2-3:1
 - Supravalvar stenosis is rare
 - M:F = 1:1.2

Natural History & Prognosis

- Prognosis varies with severity of obstruction and associated anomalies
 - Mild valvar stenosis (mean gradient: < 25 mm Hg) progresses slowly, intervention common by 4th-6th decade
 - Moderate valvar stenosis (mean gradient: 25-40 mm Hg) may require surgical or nonsurgical intervention
 - Severe valvar stenosis (mean gradient: > 40 mm Hg) requires surgical or nonsurgical (catheter based) intervention
 - Fetal cases tend to be more severe with frequent progression to hypoplastic left heart
- Balloon aortic valvuloplasty has generally supplanted open surgical valvotomy as initial treatment
 - Mortality is 13% at 15 years, 19% at 20 years

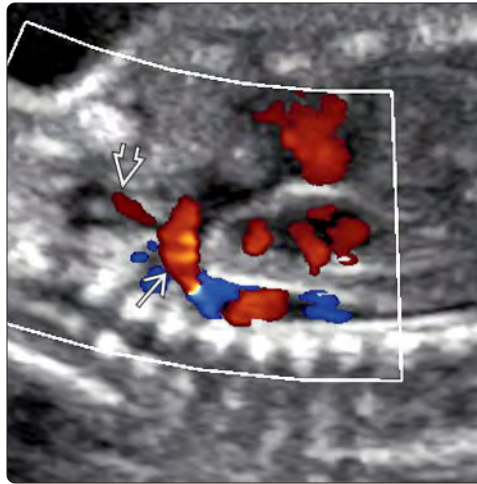
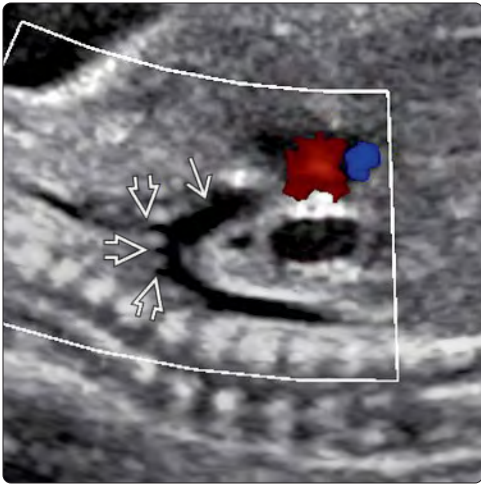
DIAGNOSTIC CHECKLIST

Image Interpretation Pearls

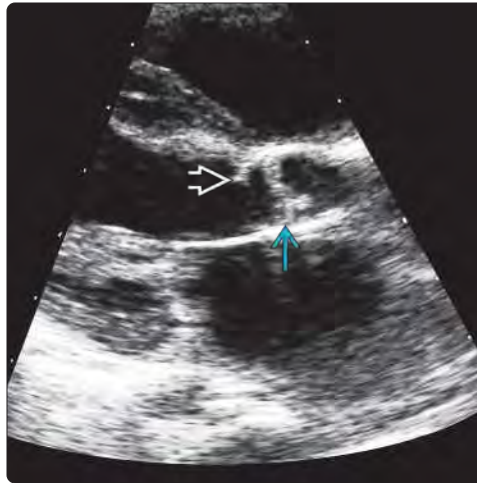
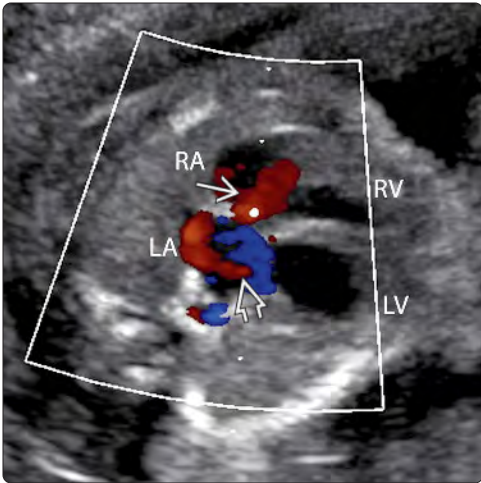
- Use color Doppler to determine origin of turbulent flow
 - Assess whether at level of valve, above or below
- Reverse flow in transverse arch indicates ductal dependency

SELECTED REFERENCES

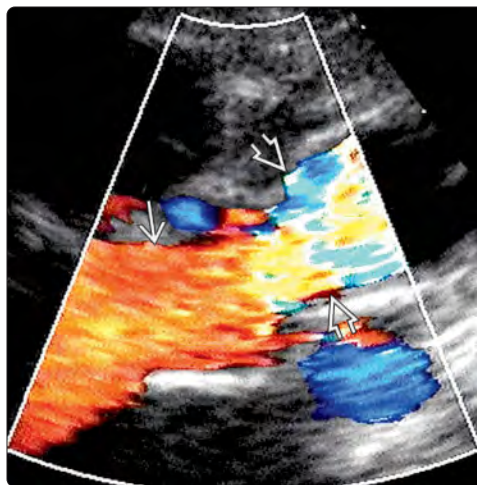
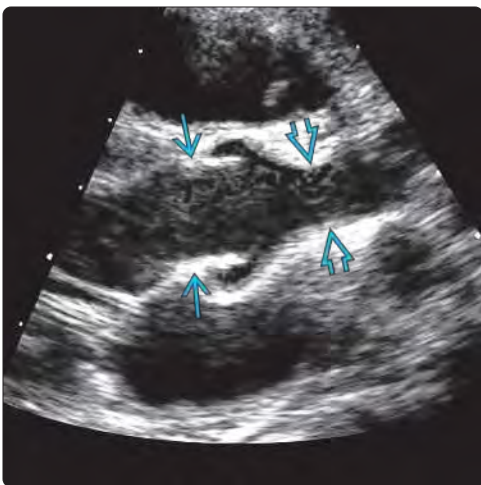
1. Moon-Grady AJ et al: International fetal cardiac intervention registry: a worldwide collaborative description and preliminary outcomes. *J Am Coll Cardiol.* 66(4):388-99, 2015
2. Soulatges C et al: Long-term results of balloon valvuloplasty as primary treatment for congenital aortic valve stenosis: a 20-year review. *Pediatr Cardiol.* 36(6):1145-52, 2015
3. Maskatia SA et al: Twenty-five year experience with balloon aortic valvuloplasty for congenital aortic stenosis. *Am J Cardiol.* 108(7):1024-8, 2011



(Left) This image shows a normal-appearing aortic arch and 3 major arch vessels arising from it. (Right) The same image with color Doppler (red is toward the transducer) shows the "normal" arch actually has retrograde flow, suggesting that there is not enough antegrade flow coming out of the LV across the aortic valve. Reversed flow in the transverse indicates ductal dependency to perfuse the vessels to the head.



(Left) Color Doppler echocardiogram shows left-to-right shunting at the atrial level, which implies fixed obstruction on the left (in this case at the aortic valve). Note that there is significant mitral regurgitation as well. (Right) Long-axis postnatal echocardiogram in a case of subvalvar stenosis shows a subaortic fibrous membrane just below the level of the aortic valve.



(Left) Left ventricular outflow tract (LVOT) postnatal echocardiogram demonstrates significant narrowing above the aortic valve (supralvalvar aortic stenosis). The aortic valve and annulus size are normal. (Right) LVOT color Doppler echocardiogram in the same patient shows laminar flow across the aortic valve but turbulent flow starting at the level of narrowing in the supralvalvar region. Supralvalvar AS has a strong association with Williams syndrome.

Total Anomalous Pulmonary Venous Return

KEY FACTS

TERMINOLOGY

- TAPVR means that all pulmonary veins (PV) connect to systemic veins, right atrium (RA) or both
 - Supracardiac TAPVR
 - Drainage is cephalad, typically via vertical vein to innominate vein
 - Cardiac TAPVR
 - Drainage is directly to heart, typically via coronary sinus
 - Infracardiac TAPVR
 - Drainage is caudad coursing below diaphragm
 - Mixed TAPVR
 - Drainage of each vein may be to a different location or groups of veins may drain to different locations

IMAGING

- Increased distance between descending aorta (DAo) and left atrium (LA) on 4-chamber view

- Twig sign: Tubular vascular confluence posterior to atria, anterior to descending aorta
- TAPVR to innominate vein causes abnormal 3-vessel trachea view

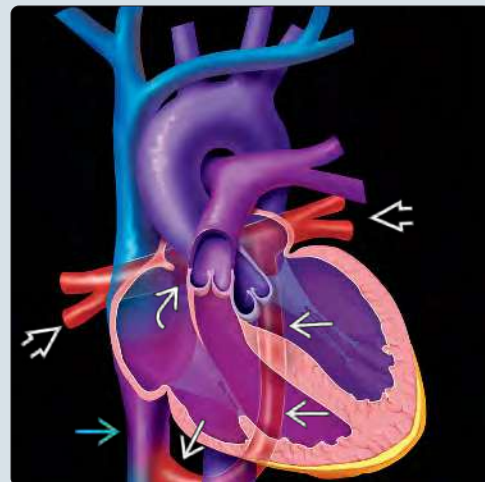
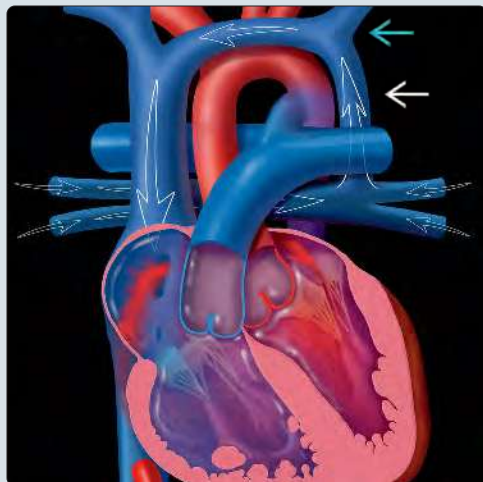
PATHOLOGY

- Infracardiac TAPVR egress is almost always obstructed, creating surgical emergency at birth
 - Obstructed pulmonary venous return → no oxygenated blood gets back to heart → circulatory collapse

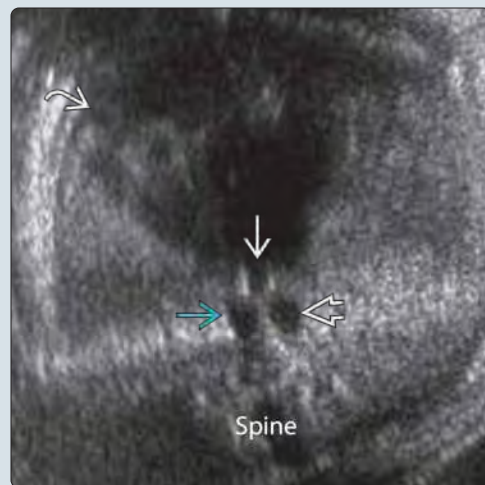
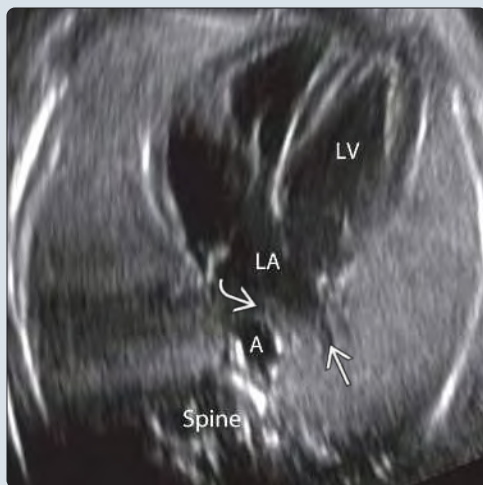
CLINICAL ISSUES

- Obstructed TAPVR is surgical emergency
- Unobstructed TAPVR can be repaired electively but typically still done in 1st few weeks of life
- Surgical repair connects all veins back to LA
- Surgical mortality < 5% with elective repair in relatively healthy infants

(Left) Graphic of fetal circulation with supracardiac TAPVR shows pulmonary veins draining to the innominate vein via an ascending vertical vein. (Right) Postnatal circulation with infracardiac TAPVR shows venous confluence behind the left atrium draining to the IVC via a descending vertical vein. An atrial septal defect is critical for survival as it is the only avenue for oxygenated blood to reach the left heart. These are almost all obstructed at birth and are a surgical emergency. (From *DI: Cardiovascular, 2e.*)



(Left) Normal 4-chamber view shows a pulmonary vein entering the left atrium (LA). Note that there is very little space between the LA and the descending aorta (A). LV = left ventricle. (Right) 4-chamber view in a fetus with heterotaxy shows dextrocardia and 3 vessels behind the heart. These are the aorta, azygos continuation of the IVC, and a vertical vein draining TAPVR below the diaphragm. There was also a double outlet right ventricle with mitral atresia. The infant did not survive.



TERMINOLOGY

Abbreviations

- Total anomalous pulmonary venous return (TAPVR)
- Partial anomalous pulmonary venous return (PAPVR)
- Total (TAPVC) and partial pulmonary venous connection (PAPVC)
 - Semantic difference for more complex heart disease differentiating between how veins are connected and where they ultimately return

Synonyms

- Total anomalous pulmonary venous drainage (TAPVD)
- "Total veins"

Definitions

- TAPVR means that all pulmonary veins (PV) connect to systemic veins, right atrium (RA) or both
 - **Supracardiac TAPVR**
 - Drainage is cephalad, typically via vertical vein to innominate vein
 - **Cardiac TAPVR**
 - Drainage is directly to heart, typically via coronary sinus
 - **Infracardiac TAPVR**
 - Drainage is caudad coursing below diaphragm
 - Draining vein passes through liver (portal venous system) before returning to heart
 - Confluence frequently vertical, long, and thin; can be particularly difficult to identify in fetus
 - **Mixed TAPVR**
 - Drainage of each vein may be to different location or groups of veins may drain to different locations
 - For example, 2 right veins may drain to supracardiac location and 2 left veins may drain below diaphragm
- PAPVR
 - 1 or 2 PVs with anomalous drainage, others drain normally to LA

IMAGING

General Features

- Best diagnostic clue
 - Increased distance between descending aorta (DAo) and left atrium (LA) on 4-chamber view
 - Can measure post-LA space index: LA to DAo/DAo diameter
 - Measure on 4C view at end-systole
 - Posterior wall LA to anterior wall DAo measured on line from crux of heart to center DAo
 - DAo diameter inner edge to inner edge
 - Post-LA space index cut-off of 1.0 has high sensitivity for prenatal detection TAPVR
 - TAPVR cases with large shunt have common PV chamber between LA and DAo
 - Specificity: 89%
 - Twig sign: Tubular vascular confluence posterior to atria, anterior to descending aorta
 - Seen in 96% of cases in retrospective series published 2013

Ultrasonographic Findings

- Fetal echocardiography
 - Smooth back wall of left atrium without vein ostia
 - Vein draining blood away from heart behind left atrium either to head or below diaphragm
 - Must use color Doppler for direction of flow
 - Markedly dilated coronary sinus
 - Seen with intracardiac type
 - Unexpected venous structure anterior to aorta on axial view of upper abdomen/liver
 - Suggests vein draining below diaphragm in infracardiac type
 - TAPVR to innominate vein causes abnormal 3-vessel trachea view
 - 4th vessel (i.e., ascending vein) seen on left
- Postnatal echocardiography
 - Obligate right to left shunt at atrial septum
 - Small left atrium (diminished or no venous return from lungs)
 - Vein draining blood away from heart (toward head or below diaphragm)
 - Infracardiac TAPVR egress is almost always obstructed in liver creating surgical emergency at birth
 - Obstructed PV return → no oxygenated blood gets back to heart → circulatory collapse
 - Supracardiac TAPVR
 - Obstructs between left bronchus/left pulmonary artery when vertical vein drains up to innominate
 - Actually occurs more frequent than obstruction below diaphragm due to more common occurrence

Imaging Recommendations

- Protocol advice
 - Difficult to recognize isolated TAPVR on screening OB ultrasound
 - Prenatal detection rate ~ 6%
 - Interrogate pulmonary veins with any complex heart disease
 - Use color Doppler
 - Decrease Nyquist limit in order to see venous flow

DIFFERENTIAL DIAGNOSIS

Partial Anomalous Pulmonary Venous Return

- Scimitar syndrome
 - Hypoplastic right lung
 - Right pulmonary veins drain to inferior vena cava instead of LA
- Superior sinus venosus ASD
 - Right upper vein commonly drains into right atrium via superior vena cava instead of left atrium
- Isolated anomalous pulmonary vein
 - Left upper vein may drain to innominate vein
 - Often left alone as clinically not significant

PATHOLOGY

General Features

- Etiology
 - Failure of common pulmonary vein to absorb into back of left atrium

- Results in retention of connections to primitive cardinal and umbilicovitteline drainage systems

Staging, Grading, & Classification

- Anatomic
 - Supracardiac: 49%
 - Cardiac: 16%
 - Infracardiac: 26%
 - Mixed: 9%

Gross Pathologic & Surgical Features

- Infracardiac are almost always obstructed
- Supracardiac may obstruct between left bronchus/left pulmonary artery when vertical vein drains up to innominate

CLINICAL ISSUES

Presentation

- **Prenatal**
 - Detected as part of assessment for complex CHD or heterotaxy
 - Prognosis depends on underlying cardiac structure
 - Addition of TAPVR increases mortality significantly and may make correction prohibitive
 - Isolated TAPVR is very hard diagnosis
 - Check for increased space behind LA/
 - Twig sign on 4-chamber view
- **Postnatal**
 - Increased pulmonary blood flow at birth drastically alters volume pulmonary veins are required to handle
 - **Unobstructed**
 - Mildly desaturated
 - Cardiovascularly stable as neonate
 - **Obstructed**
 - Respiratory distress and cardiac failure
 - Clinically very unstable in neonatal period

Demographics

- Epidemiology
 - 66% case isolated, 33% associated with complex CHD
 - 2010 series reviewed 422 liveborn infants with TAPVR excluding univentricular hearts and atrial appendage isomerism
 - Only 2.4% with prenatal suspicion of cardiac lesion, **but**
 - International study with variable views required
 - Some countries did not even have fetal anomaly screening during timespan from which cases were collected
 - 2/8 of cases with prenatal diagnosis died in utero
 - Family history is important
 - 4% of cases in one cohort had 1st-degree relative with significant CHD
 - Baltimore-Washington Infant Study: 5% of neonates with TAPVR had family history of CHD
 - ~ 50% of cases with family history had infradiaphragmatic type TAPVR

Natural History & Prognosis

- Only ~ 8% of fetal cardiac output goes to lungs so fetal PVs are small

- With adult circulation, PVs convey oxygenated blood to heart
 - Anomalous PV drainage: Oxygenated blood → systemic veins/RA → hypoxia
 - Only way for oxygenated blood to get to left circulation is through admixture via patent foramen ovale, ductus arteriosus
- Surgical repair connects all veins back to LA
 - **Unobstructed** TAPVR can be repaired electively but typically still done in 1st few weeks of life
 - **Obstructed** TAPVR is surgical emergency
 - Prostaglandin may make neonate worse
 - Divert blood back to lungs where its egress is blocked causing more lung congestion
 - May even require extracorporeal membrane oxygenation (ECMO) support
 - Postoperative intensive care typically prolonged when infants critically ill prior to surgery
- Cardiac structural malformation determines prognosis in complex cases
 - Single ventricle physiology, atrial appendage isomerism confer particularly poor prognosis
- **Isolated TAPVR**
 - Surgical mortality < 5% with elective repair in relatively healthy infants
 - Long-term outcome is excellent
 - Repair results in normal circulation: Anticipate normal growth and development
- Some have intrinsically abnormal pulmonary vein structure
 - Progressive pulmonary vein stenosis is very hard to treat
 - Very poor prognosis

DIAGNOSTIC CHECKLIST

Consider

- Very difficult prenatal diagnosis especially when isolated

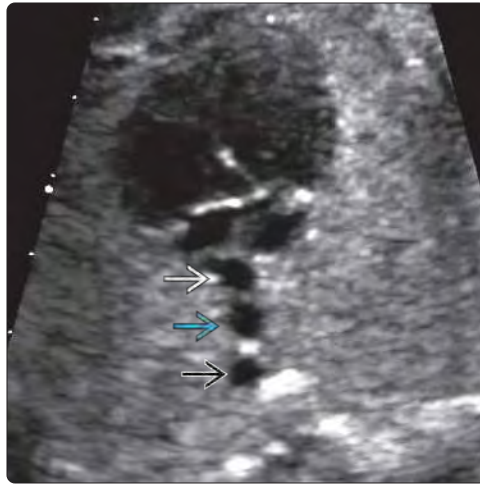
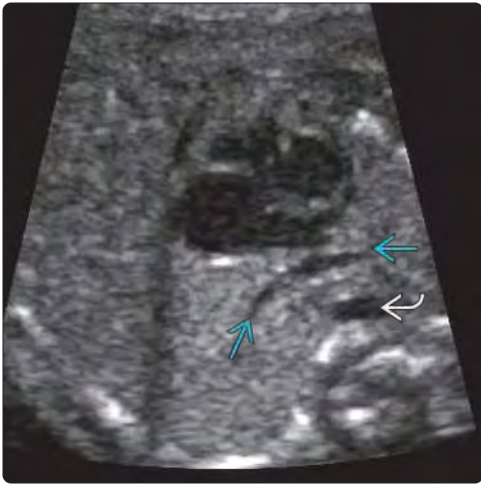Image Interpretation Pearls

- Be systematic in evaluation of 4-chamber view
 - Beware dilated coronary sinus, increased space behind LA, "extra" vessels anywhere
- Have low threshold for referral for dedicated fetal echocardiography
 - TAPVR is associated with wide variety of cardiac malformations
 - Especially common with atrial appendage isomerism (heterotaxy)
 - Documentation of TAPVR impacts surgical planning
 - Obstructed TAPVR is surgical emergency

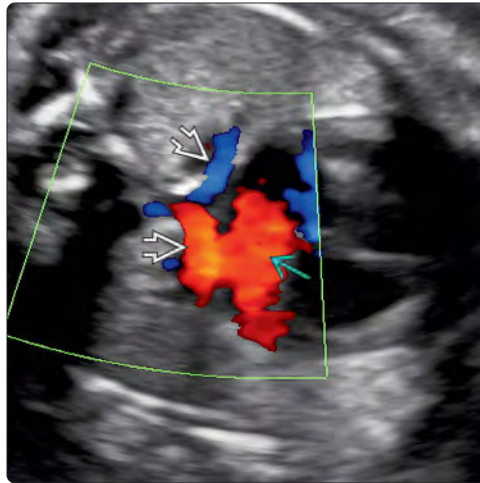
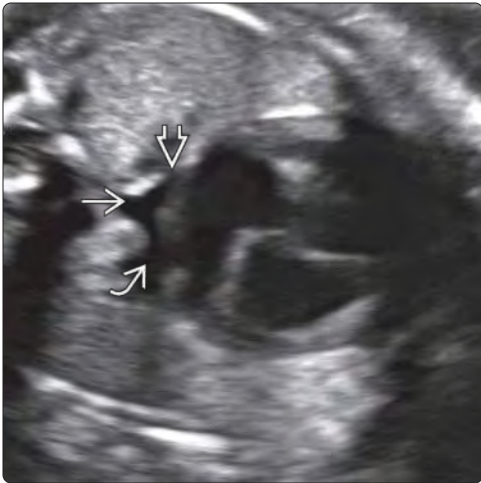
SELECTED REFERENCES

1. Koneti NR et al: Surgical correction of obstructed total anomalous pulmonary venous return soon after birth. *Ann Pediatr Cardiol.* 8(3):255-6, 2015
2. Ganesan S et al: Prenatal findings in total anomalous pulmonary venous return: a diagnostic road map starts with obstetric screening views. *J Ultrasound Med.* 33(7):1193-207, 2014

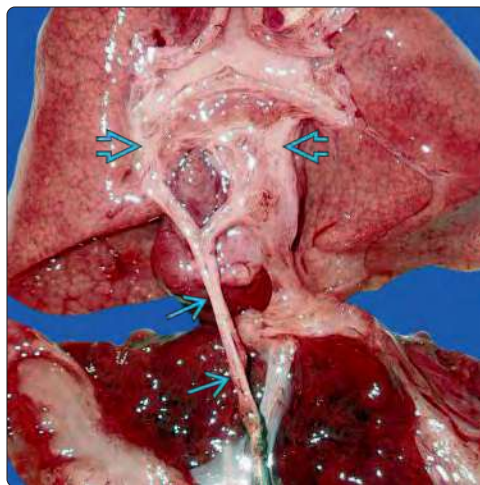
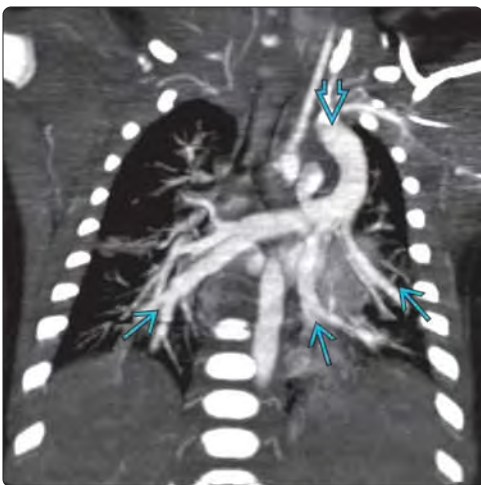
Total Anomalous Pulmonary Venous Return



(Left) Axial oblique US tipped slightly from the plane of the 4-chamber view shows the twig sign of anomalous PV confluence between the heart and the descending aorta. (Courtesy C. Rossi Palmieri, MD.) **(Right)** Axial US in right atrial appendage isomerism shows the aorta located on the same side as the IVC. Note a 3rd vessel just posterior to the atrium; this is a pulmonary venous confluence receiving all 4 pulmonary veins in TAPVR.



(Left) Four-chamber echocardiogram shows a confluence forming behind the atrium, which is receiving blood from the right and left side pulmonary veins. This patient had total anomalous pulmonary venous drainage above via a vertical vein to the innominate vein, which is the most common form of TAPVR. **(Right)** Same image with color shows flow in the pulmonary veins behind the atrium draining to the confluence.



(Left) Coronal MIP CECT shows all pulmonary veins draining into a vertical vein along the left superior mediastinum in supracardiac TAPVR. **(Right)** Posterior view from an autopsy shows an infracardiac TAPVR with pulmonary veins draining inferiorly to the portal system via a vertical vein. This pregnancy was terminated due to multiple anomalies.

KEY FACTS

TERMINOLOGY

- Congenital heart disease with 4 components
 - Right ventricular outflow tract (RVOT) obstruction
 - RV hypertrophy
 - Ventricular septal defect (VSD)
 - Overriding aorta

IMAGING

- Aorta overrides a large perimembranous VSD
- RVOT obstruction
 - Anterior deviation of infundibulum
 - Pulmonary valve (PV) usually abnormal
 - Pulmonary annulus usually small
 - Stenosis may be combination of subvalvar, valvar, or supravalvar
- Tetralogy of Fallot with absent pulmonary valve (APV)
 - Back and forth flow across PV seen with color Doppler
 - Markedly enlarged pulmonary artery and branches

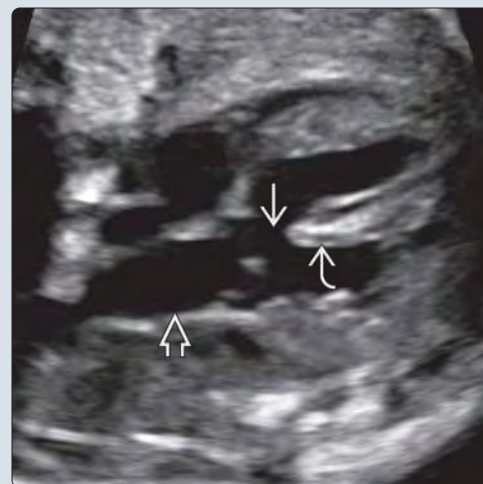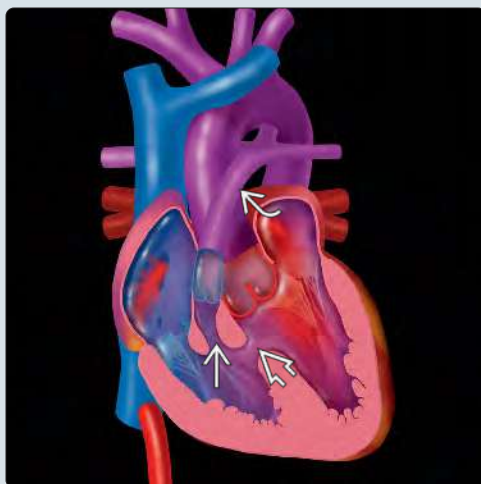
CLINICAL ISSUES

- Most common cyanotic congenital heart disease
 - 7-10% of congenital heart disease in liveborn
- Chromosomal abnormality in up to 45% of fetal cases, 25% of live births
 - Prognosis will be determined by aneuploidy/syndrome
 - Trisomy 21 (may have ToF with AVSD)
 - Trisomy 18, 13
 - 22q11 deletion syndrome
- If isolated, excellent short and long-term outcome with definitive repair
 - Greater than 98% survival in liveborn
- ToF with APV has worse prognosis

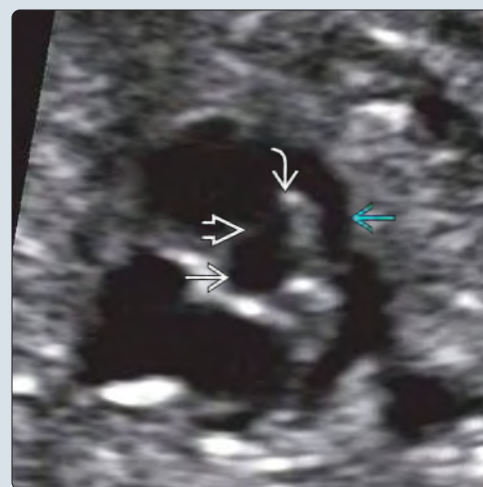
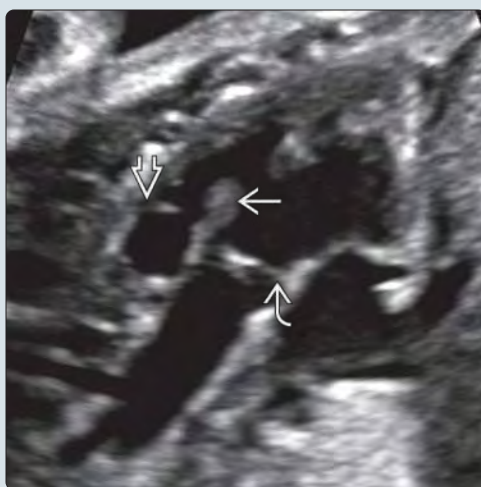
DIAGNOSTIC CHECKLIST

- 95% of fetuses have normal 4-chamber view
- Outflow tract assessment is key to making diagnosis

(Left) Graphic shows pulmonary artery (PA) hypoplasia secondary to anterior deviation of infundibulum, which causes narrowing of pulmonary outflow tract. The presence of ventricular septal defect (VSD) allows for mixing of blood at baseline, but during tetralogy "spell," shunts all blood from right to left, resulting in hypoxemia. (Right) Image shows outlet VSD with aorta, which is overriding the ventricular septum. This is a classic finding in tetralogy of Fallot (ToF), but is not diagnostic.



(Left) Image shows anterior deviation of the infundibulum into the right ventricular outflow tract (RVOT). The PA at the level of the valve appears smaller than the aorta, (note aortic valve), a typical finding in this condition. (Right) Image shows the aorta in cross section. A large VSD and anterior/superior deviation of the infundibulum result in a small RVOT. This is the picture you want to get to confirm ToF in the setting of a VSD with an overriding aorta.



TERMINOLOGY

Abbreviations

- Tetralogy of Fallot (ToF)
- ToF with absent pulmonary valve (ToF-APV)

Definitions

- Congenital heart disease with 4 components
 - Right ventricular outflow tract (RVOT) obstruction
 - Right ventricle (RV) hypertrophy
 - Ventricular septal defect (VSD)
 - Overriding aorta

IMAGING

General Features

- Best diagnostic clue
 - Dilated aorta overriding a VSD

Echocardiographic Findings

- 4-chamber view normal in > 95% of prenatal cases
- Outflow tract assessment key to making this diagnosis
 - Aorta overrides large perimembranous VSD by variable extent
 - RVOT obstruction
 - Anterior deviation of infundibulum
 - PV usually abnormal
 - Pulmonary annulus usually small
 - Stenosis may be combination of subvalvar, valvar, or supralvalvar
 - Large aortic outflow
 - RVOT obstruction + VSD = ↑ flow through aorta
- ToF-APV characterized by markedly enlarged pulmonary artery (PA) and branches
 - May cause bronchial compression and affect lung development
 - Back and forth flow across PV seen with color Doppler
 - Abnormal ductus arteriosus
 - Small in 70%, not visualized in 30%
 - Autopsy confirmation of absent ductus in 50% of cases where not visualized
 - Increased risk of hydrops
 - ToF-APV + hydrops = 80% intrauterine fetal demise in 1 series
- Pulsed Doppler
 - Can determine level of RVOT obstruction
- Color Doppler
 - Assess antegrade and regurgitant flow through outflow tracts
 - Evaluate flow across VSD

Imaging Recommendations

- If aorta is seen overriding a VSD
 - Look for presence and level of RVOT obstruction
 - Assess size and continuity of branch PAs
 - Look for PV regurgitation
 - Look for features predicting need for early intervention/surgery
 - Reversal of flow in ductus arteriosus
 - Failure of growth in PV and artery
 - Size of PV (Z-score)

- Look for associated cardiac findings
 - Right aortic arch (25%)
 - Atrioventricular septal defect (Tet-canal)
 - Left superior vena cava to coronary sinus
 - Discontinuous or "absent" branch PA
 - Right or left PA may be supplied by ductus
- Detailed anatomic survey for extracardiac anomalies
 - ↑ risk of aneuploidy/syndrome if other anomalies

DIFFERENTIAL DIAGNOSIS

Pulmonary Atresia With Ventricular Septal Defect

- No antegrade flow across PV
- Retrograde flow in ductus arteriosus
- Pulmonary collaterals come off descending aorta

Double Outlet Right Ventricle

- Outflow tracts parallel as they exit heart
- Both great arteries arise from RV
- Discontinuity between mitral and aortic valves

Isolated Perimembranous Ventricular Septal Defect

- Septal defect without significant override of aorta
- Absence of pulmonary or subpulmonary stenosis

PATHOLOGY

General Features

- Etiology
 - Multifactorial: Interaction of environment and genetic factors
 - Diabetic mothers (relative risk 3:1)
 - Also ↑ with maternal phenylketonuria, use of retinoic acids and trimethadione
- Traditional division into syndromic and nonsyndromic ToF
 - Commonest definition of syndromic is when multiple abnormalities exist in same individual
 - Some authors use specific combinations of defects for "syndromic"
 - Include both chromosomal and genetic causes
 - Trisomy 21 (may have Tet-canal)
 - Trisomy 18, 13
 - 22q11 deletion syndrome (20% of patients with ToF, up to 75% in TOF-APV)
 - Mutations in *JAG1*, *NOTCH2* associated with Alagille syndrome
 - 10-15% have ToF
 - CHARGE syndrome
 - Coloboma
 - Heart disease
 - Atresia (choanal)
 - Restricted growth/development
 - Genitourinary anomalies
 - Ear anomalies
 - VACTERL association
 - Vertebral defects
 - Anorectal atresia
 - Cardiac disease
 - Tracheoesophageal fistula
 - Renal anomalies
 - Limb dysplasia

- Nonsyndromic used when congenital heart defect isolated
 - May be due to gene mutations or copy number variants (CNV)
 - CNV: Small de novo deletions or duplications
 - 3 commonest associated with ToF are *CHL1*, *NKX2-1*, *GSTT1*
 - Mutations in single genes
 - *NKX2.5*, *ZFPM2*, *GATA4*, *GATA6*, *NOTCH1*
- Embryology
 - Complex process, mechanism remains uncertain
 - Primary pathology may be underdevelopment of subpulmonary infundibulum
 - Cardinal feature is anterior-cephalad deviation of outlet (infundibular) septum
 - Partitioning unequal → aorta larger than PA
 - Aortopulmonary septum does not line up with interventricular septum → VSD
 - Larger vessel (aorta) straddles VSD

Staging, Grading, & Classification

- 3 major categories
 - ToF with pulmonary stenosis
 - This category can be subdivided into 2 based on degree of stenosis
 - Mild or no stenosis = "pink" ToF
 - Moderate to severe stenosis = "blue" ToF
 - ToF with pulmonary atresia
 - Cases with pulmonary atresia may also be categorized as pulmonary atresia with VSD
 - ToF with APV

Gross Pathologic & Surgical Features

- Infundibular stenosis
 - Anterior and cephalad deviation of infundibular septum
 - Hypertrophy of septum, free wall and septomarginal trabeculations
- PV
 - Unicuspid/bicuspid/tricuspid
 - Valve thickened with poor mobility
- PAs
 - May have focal or diffuse obstruction or hypoplasia
- VSD
 - Typically membranous

CLINICAL ISSUES

Demographics

- Epidemiology
 - Most common cyanotic congenital heart disease
 - 7-10% of congenital heart disease in liveborn
 - 0.2-0.5:1,000 live births

Natural History & Prognosis

- Chromosomal abnormality in up to 45% of fetal cases
 - Prognosis will be determined by aneuploidy/syndrome
 - Extremely poor in trisomy 13/18
- Excellent short and long-term outcome with definitive repair if normal chromosomes and no other anomaly
 - Greater than 98% survival in liveborn
 - Reintervention rate 32% or greater primarily due to PV regurgitation/stenosis

- Palliation required prior to definitive repair in all patients with pulmonary atresia and some of those categorized as blue ToF
 - Balloon dilation of PV
 - Blalock Taussig shunt
- ToF with APV has worse prognosis
 - 32% mortality at 4 years
 - Primarily result of severe respiratory problems
 - Due to bronchial compression from dilated branch PAs
 - Associated with hydrops in fetus → poor prognosis
- Recurrence risk
 - 1 child: 2.5%, 2 children: 8%, parent 3-4%

Treatment

- Encourage karyotype
 - Abnormal in 45% of prenatal cases
 - Abnormal in 10% of liveborn (most often 22q deletion in this group)
- Offer termination if associated aneuploidy/multiple anomalies
- Prenatal consultation with neonatology/pediatric cardiology
- Plan delivery at tertiary center
- Follow for progressive RVOT obstruction
 - 2/25 fetuses in 1 series progressed to pulmonary atresia
 - Determines need for prostaglandins after birth
 - Early intervention may be required if significant RVOT obstruction/PA hypoplasia
- Surgical repair
 - VSD closure
 - RVOT reconstruction
 - Valve-sparing with infundibular resection
 - Transannular patch
 - RV-PA conduit
 - Anterior descending coronary artery may arise from right coronary artery
 - Surgeon needs to be aware

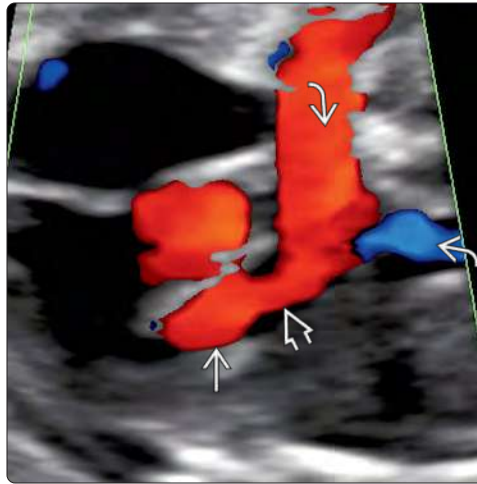
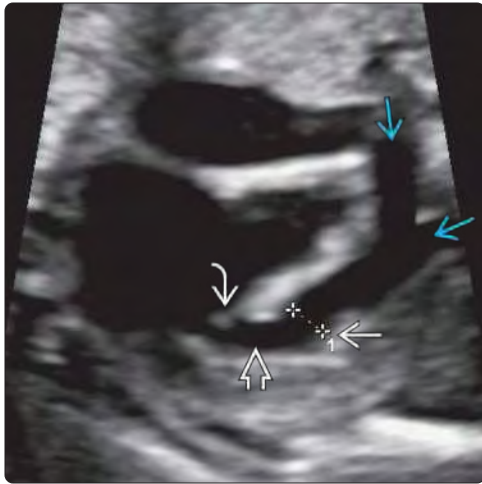
DIAGNOSTIC CHECKLIST

Image Interpretation Pearls

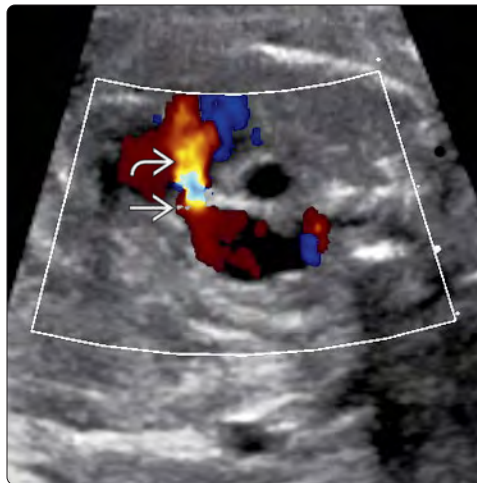
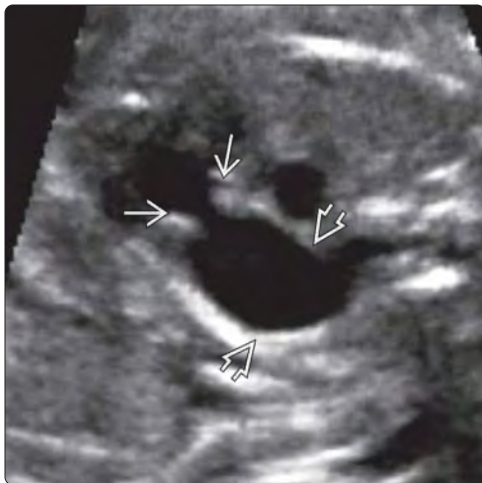- 95% of fetuses have normal 4-chamber view
- Outflow tract assessment is key to making diagnosis

SELECTED REFERENCES

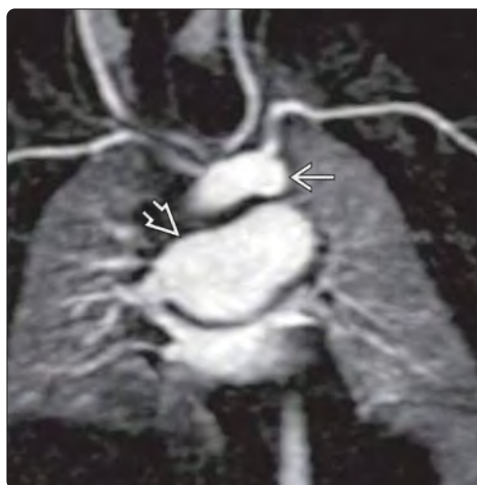
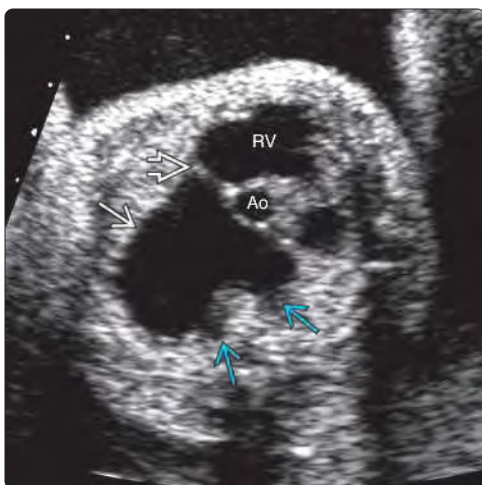
1. Devendran V et al: Tetralogy of Fallot with subarterial ventricular septal defect: Surgical outcome in the current era. *Ann Pediatr Cardiol*. 8(1):4-9, 2015
2. Smith T et al: MicroRNAs in congenital heart disease. *Ann Transl Med*. 3(21):333, 2015
3. Arya B et al: Fetal echocardiographic measurements and the need for neonatal surgical intervention in Tetralogy of Fallot. *Pediatr Cardiol*. 35(5):810-6, 2014
4. Qureshi MY et al: Importance of absent ductus arteriosus in tetralogy of Fallot with absent pulmonary valve syndrome. *Tex Heart Inst J*. 41(6):664-7, 2014



(Left) Image shows the pulmonary valve (PV) being measured. Note the narrowed RVOT caused by anterior superior deviation of the infundibulum. The branch PAs are also clearly seen. (Right) Similar image with color shows flow in the outflow tract, across the PV, and into the branch PAs, which is laminar, suggesting no stenosis. If the valve and main PA grow normally, one can be optimistic that this child will be a "pink tet."



(Left) Image shows a thick and dysplastic PV with a very dilated main PA. This should raise the suspicion of an absent pulmonary valve (APV) complex in the setting of ToF. (Right) Similar image shows that there is poor coaptation of the PV in diastole resulting in severe regurgitation, consistent with the APV complex.



(Left) A dilated RV outflow is seen with the aortic valve in cross section. There is massive dilation of the main and branch PAs, typical of ToF with APV. Rudimentary PV tissue is seen; it can actually look normal, but it does not function properly. (Right) Contrast-enhanced MR shows massive dilation of the right PA, which appears about 3x the size of the aorta in this child with ToF and APV.

KEY FACTS

TERMINOLOGY

- Transposition of great arteries (TGA)
 - Ventriculoarterial (VA) discordance
 - Aorta arises from right ventricle (RV)
 - Pulmonary artery (PA) arises from left ventricle (LV)
- Congenitally corrected TGA (CTGA)
 - Atrioventricular (AV) and VA discordance
 - Right atrium → LV → pulmonary artery
 - Left atrium → RV → aorta

IMAGING

- TGA has normal 4-chamber view
 - Outflow tracts parallel as they exit heart
 - Ventricular septal defect (VSD) (40-45%)
 - Left ventricular outflow tract obstruction (25%)
- In CTGA, ventricles loop to left not right, bringing morphologic LV to the right and morphologic RV to left
 - Outflow tracts parallel as they exit heart
 - VSD (60-80%)

- Right ventricular outflow tract obstruction (30-50%)

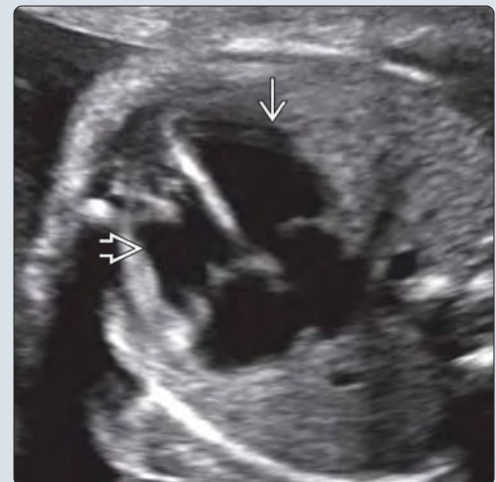
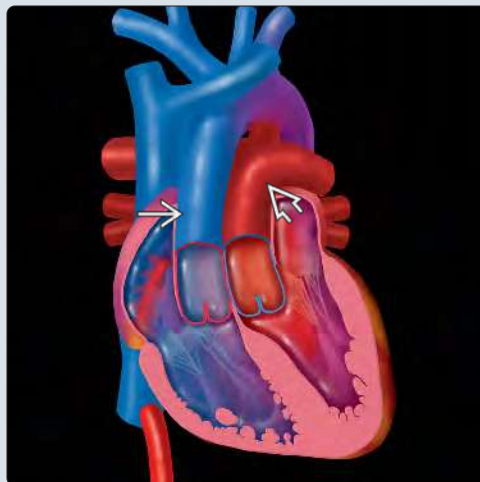
CLINICAL ISSUES

- Fetal loss is uncommon but postnatal TGA is **lethal** without treatment
- TGA postnatal circulation
 - Fetal connections are necessary to allow mixing of blood and delivery of oxygenated blood to tissues
 - Arterial switch recommended in 1st week of life
- CTGA postnatal circulation
 - Oxygenated blood from lungs reaches systemic circulation like normal
 - Survivors possible into 50 without surgery but surgical repair now more common

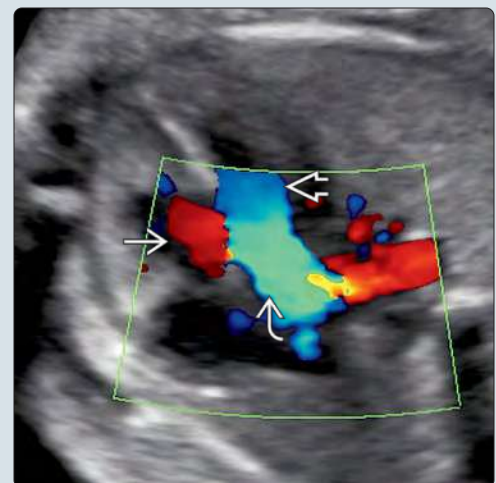
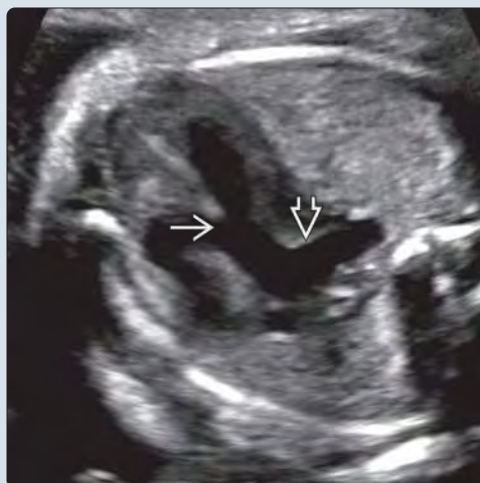
DIAGNOSTIC CHECKLIST

- Parallel outflow tracts → significant congenital heart disease

(Left) Graphic shows the aorta arising from the RV and the pulmonary artery arising from the LV in simple transposition without a ventricular septal defect. The great arteries are parallel rather than crossing as they should do. (Right) This 4-chamber view is in a fetus with TGA and a ventricular septal defect. It looks normal with the RV anterior and the LV posterior. This view highlights how important it is to sweep from the 4-chamber view up to the great vessels to pick up some congenital heart diseases.



(Left) Tipping the probe anterior reveals a large ventricular septal defect in the same patient. The great vessel above this branches early, consistent with a pulmonary artery; this confirms a diagnosis of transposition of great arteries (TGA). (Right) Same image with color Doppler shows flow from the RV and LV entering the pulmonary artery. One needs to pay close attention to the size of the aorta and the possibility of a coarctation if it is smaller than the pulmonary artery.



TERMINOLOGY

Synonyms

- **Transposition of great arteries (TGA)**
 - D-transposition
 - Dextrotransposition
- **Congenitally corrected transposition of great arteries (CTGA)**
 - L-transposition
 - Ventricular inversion
 - Levotransposition

Definitions

- **TGA:** Ventriculoarterial (VA) discordance
 - Aorta arises from right ventricle (RV)
 - Pulmonary artery (PA) arises from left ventricle (LV)
 - Further distinguished by presence/absence of ventricular septal defect (VSD)
- **CTGA:** Atrioventricular (AV) and VA discordance
 - Right atrium → LV → PA
 - Left atrium → RV → aorta

IMAGING

General Features

- Best diagnostic clue
 - Outflow tracts parallel as they exit heart
 - In dextrotransposition of great arteries, posterior great artery branches early (i.e., is PA)

Echocardiographic Findings

- **TGA**
 - Normal 4-chamber view
 - Outflow tracts parallel as they exit heart
 - Posterior artery (pulmonary) bifurcates
 - Arises from LV
 - Anterior artery (aorta) gives rise to arch/head and neck vessels
 - Arises from RV
 - Associated lesions
 - VSD (40-45%)
 - Left ventricular outflow tract obstruction (25%)
 - Coarctation of aorta (5%)
 - AV valve abnormalities (5%)
 - Abnormal coronary artery course is common
- **CTGA**
 - Ventricles loop to left not right, bringing morphologic LV to right and morphologic RV to left
 - Outflow tracts parallel as they exit heart
 - Anterior ventricle is LV, smooth walled with no chordal attachments to septum
 - Posterior ventricle is RV, trabeculated, moderator band present, chordal attachments to septum
 - PA arises from anterior, LV
 - Aorta arises from posterior, RV
 - Associated lesions
 - VSD (60-80%)
 - Right ventricular outflow tract obstruction (30-50%)
 - Systemic AV valve abnormalities (90%) (often without functional significance)

- Color Doppler
 - Assess stenosis, flow turbulence, regurgitation across valves
 - Assess flow across VSD
 - Document flow in coronary arteries
- Pulsed Doppler
 - Used to assess gradients across aortic/pulmonary valves and aortic arch
 - High velocity or turbulence seen in obstructive lesions

Imaging Recommendations

- Protocol advice
 - If parallel outflow tracts are seen
 - Assess ventricular morphology to identify LV/RV, look for VSD
 - Assess VA connections
 - Differentiate aorta from PA, look for outflow tract obstruction
 - Differentiate TGA from CTGA by accurate identification of AV and VA connections
 - Check situs
 - 80% of right atrial isomerism/asplenia have conotruncal malformations including TGA

DIFFERENTIAL DIAGNOSIS

Double-Outlet Right Ventricle

- VSD is always present
- Normal AV connections
- Outflow tracts are parallel but both wholly or predominantly arise from RV
- Great arteries may be normally related or transposed

Tetralogy of Fallot

- VSD is always present
- Normal AV connections
- Outflow tracts not parallel, aorta overrides VSD
- PA arises from RV with pulmonary or subpulmonary stenosis
- Higher association with aneuploidy and extracardiac anomalies

PATHOLOGY

General Features

- Etiology
 - TGA thought to result from abnormal growth of subaortic infundibulum
 - Aortic valve pushed superior and anterior, placing it above RV
 - Simultaneous failed development of subpulmonary infundibulum prevents anterior movement of pulmonary valve
 - CTGA is caused by abnormal cardiac looping
 - Heart tube loops left, not right as it should
 - Morphologic LV to right, morphologic RV to left
- Genetics
 - Rarely associated with aneuploidy

Staging, Grading, & Classification

- **TGA**

- TGA with intact ventricular septum or small VSD (60%) (so-called simple TGA)
- TGA with large VSD (25%)
- TGA with VSD and LV outflow tract obstruction (10%)
- TGA with intact ventricular septum and LV outflow tract obstruction (5%)

CLINICAL ISSUES

Presentation

- Parallel outflow tracts noted on routine sonography
- Morphologic LV located on right side in CTGA

Demographics

- Epidemiology
 - TGA accounts for 5-7% of congenital heart disease (CHD)
 - 0.21-0.31/1,000 live births
 - Males account for 60-70% of incidence
 - CTGA accounts for 0.05% of CHD

Natural History & Prognosis

- Fetal loss is uncommon but postnatal TGA is **lethal** without treatment
 - **TGA postnatal circulation**
 - Only communication between pulmonary and systemic circulations via ductus arteriosus (DA) and foramen ovale (FO)
 - Blood flows in parallel instead of in series, which is very inefficient and problematic
 - Blue blood delivered to body, pink blood is delivered to lungs
 - Fetal connections necessary for mixing of blood, delivery of oxygenated blood to tissues
 - At birth, DA/FO closure → complete dissociation of circulations → death from hypoxia
 - Some admixture of blood if VSD but typically also need patent FO or DA
 - Rashkind procedure to open atrial septum often required to improve mixing of blood and higher oxygen saturations to body
 - Surgery required within 1st 2 weeks of life, preferably 1st few days
 - Before development of pulmonary hypertension
 - Before LV adapts to low pressure pulmonary circulation
 - **CTGA postnatal circulation**
 - Oxygenated blood from lungs reaches systemic circulation like normal
 - Problem is that RV not meant to pump to systemic circulation for lifetime
 - Associated lesions determine early prognosis and surgical options
 - At risk for conduction defect before and following repair
 - 10% may present with congenital heart block with continued risk ~ 2% per year
 - **Excellent short- and long-term outcomes with treatment**
 - TGA long-term (20 year plus) survival approaching 97%
 - Arterial switch has early mortality of < 3%
 - 1-2% late mortality due primarily to coronary artery complications
 - Branch pulmonary stenosis is common residual problem (5-30%)

- **CTGA patients** survive into 50s without surgery
 - Physiologic-type repairs maintain RV as systemic ventricle
 - Early mortality: Up to 10%, 10-year survival: 68%
 - Anatomic repair or double-switch makes LV systemic ventricle
 - Early mortality: 6%, 7-year survival: 85%
- Recurrence risk
 - 1 sibling: 1.5%; 2 siblings: 5%

Treatment

- **TGA**
 - Not typically associated with aneuploidy, karyotype not necessary
 - Refer to tertiary center for delivery
 - 1st line of treatment is prostaglandin infusion to prevent DA closure
 - Balloon atrial septostomy (Rashkind) allows L → R atrial shunt
 - May be necessary to improve oxygenation
 - Definitive treatment is arterial switch in 1st week
 - Great vessels transected and reconnected to appropriate ventricles
 - Coronary arteries reimplemented on transposed aorta
- **CTGA**
 - Refer to tertiary center for delivery
 - No intervention necessary immediately after birth in majority
 - Without VSD: Consider no intervention
 - With VSD ± pulmonary stenosis: Surgical options vary
 - Atrial switch with Rastelli
 - Double-switch (atrial and arterial)
 - Patients with significant tricuspid regurgitation are more likely to have poor outcome

DIAGNOSTIC CHECKLIST

Consider

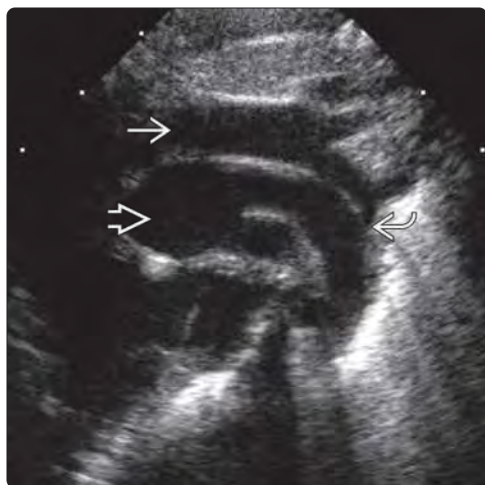
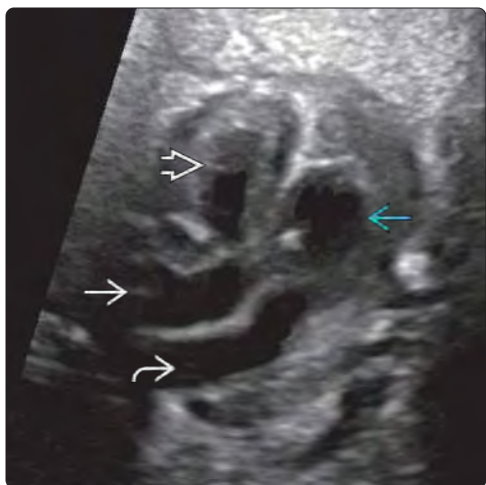
- Formal fetal echocardiography
 - TGA and CTGA have different prognosis and treatment
 - Differentiation requires identification of ventricles/VA connections
- Normal 4-chamber view does not exclude significant conotruncal malformations

Image Interpretation Pearls

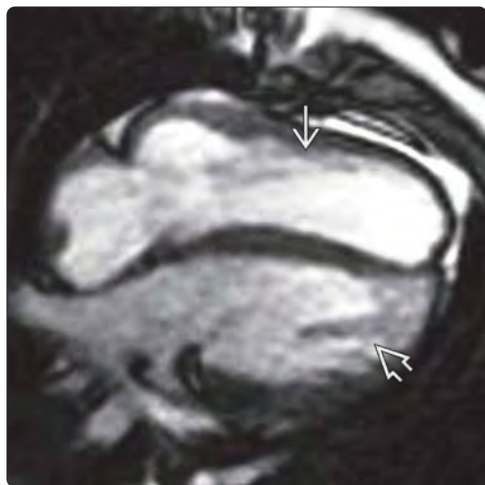
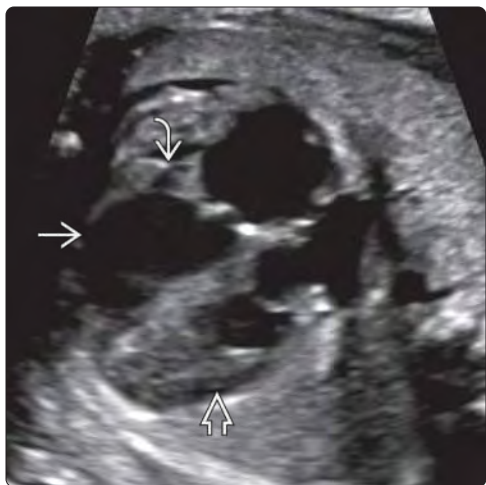
- Parallel outflow tracts → significant CHD

SELECTED REFERENCES

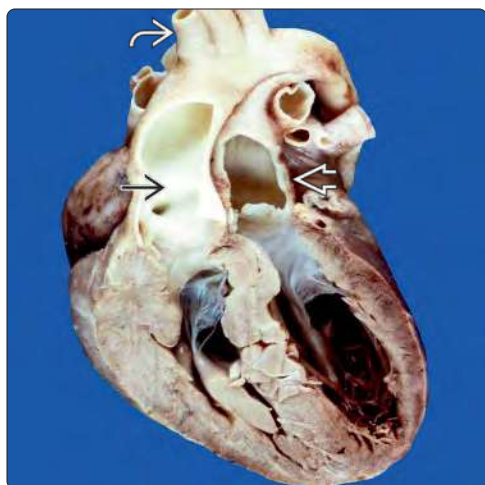
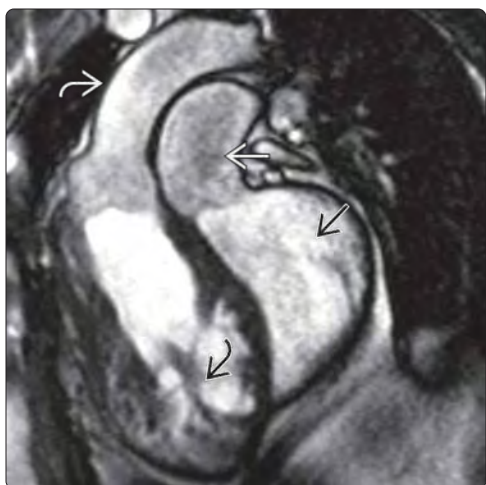
1. Brandt JS et al: Utility of a single 3-vessel view in the evaluation of the ventricular outflow tracts. *J Ultrasound Med.* 34(8):1415-21, 2015
2. Debost-Légrand A et al: Impact of prenatal diagnosis on the outcome of patients with a transposition of great arteries: A 24-year population-based study. *Birth Defects Res A Clin Mol Teratol.* 106(3):178-84, 2015
3. Escobar-Díaz MC et al: Prenatal diagnosis of transposition of the great arteries over a 20-year period: improved but imperfect. *Ultrasound Obstet Gynecol.* 45(6):678-82, 2015
4. Palatnik A et al: Is the "I-sign" in the 3-vessel and trachea view a valid tool for prenatal diagnosis of D-transposition of the great arteries? *J Ultrasound Med.* 34(7):1329-35, 2015
5. Wolter A et al: Fetal cardiac axis in fetuses with conotruncal anomalies. *Ultraschall Med.* ePub, 2015
6. Villafañe J et al: D-transposition of the great arteries: the current era of the arterial switch operation. *J Am Coll Cardiol.* 64(5):498-511, 2014



(Left) Image shows the branching pulmonary artery coming off the posterior LV and the aorta coming off the anterior RV. (Right) This image shows the aorta anterior to the pulmonary artery. Notice the caliber difference between the 2 vessels. If you see this in a patient with TGA and a VSD, make sure to look for an arch obstruction. This patient has a coarctation clearly shown here with a hypoplastic transverse arch and isthmus.



(Left) Image shows a morphologic LV (smooth walled) anterior to the morphologic RV (more trabeculated) in a patient with corrected transposition of the great arteries or CTGA. Note the AV valve attachments from the mitral valve go to the free wall only, which identifies this as the LV. (Right) Four-chamber view postnatal MR shows a very similar picture of CTGA with the anterior ventricle being a smooth-walled LV and the posterior ventricle being a more trabeculated RV.



(Left) RVOT postnatal MR shows TGA with the aorta arising from the trabeculated RV and the main pulmonary artery arising from the smooth left ventricle. There is no ventricular septal defect. (Right) Gross pathology shows transposition of the great arteries. The aorta is arising from the normally positioned right ventricle. Note the head and neck vessels clearly identifying this vessel as the aorta. The pulmonary artery is arising from the left ventricle and again there is no VSD.

KEY FACTS

TERMINOLOGY

- Single vessel (truncus) arises from heart
 - Gives rise to aorta and pulmonary arteries

IMAGING

- Single truncal valve with 1-5 cusps
 - May cause stenosis ± regurgitation
- Ventricular septal defect (VSD)
- Right-sided aortic arch in 21-36%
- Interrupted aortic arch in 10-19%
- Full anatomic survey for other extracardiac anomalies (21-30%)

PATHOLOGY

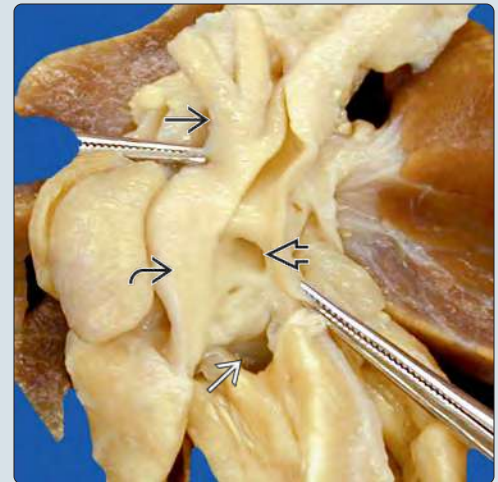
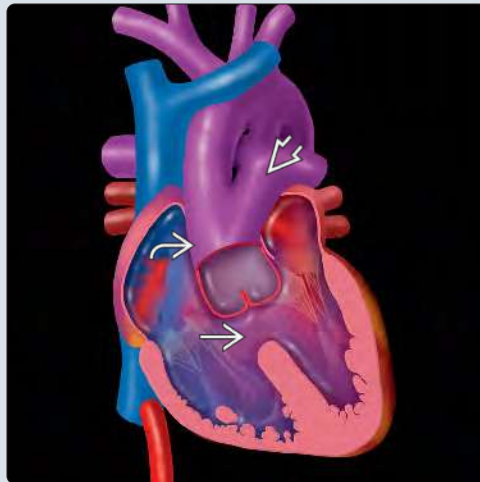
- Embryonic truncus lies between conus cordis proximally and aortic arch distally
 - Truncal swellings divide truncal lumen into 2 channels: Ascending aorta and pulmonary trunk

- As truncal septum fuses with developing conal septum, right and left ventricular origin of pulmonary trunk and aorta respectively are established
- If truncal swellings do not divide lumen → single vessel leaving heart
- Spiral course of truncus produces anterior/posterior and orthogonal relationship of great arteries
- Deficiency or absence of conal septum produces large VSD
- 40% of liveborns with truncus have 22q11 deletion

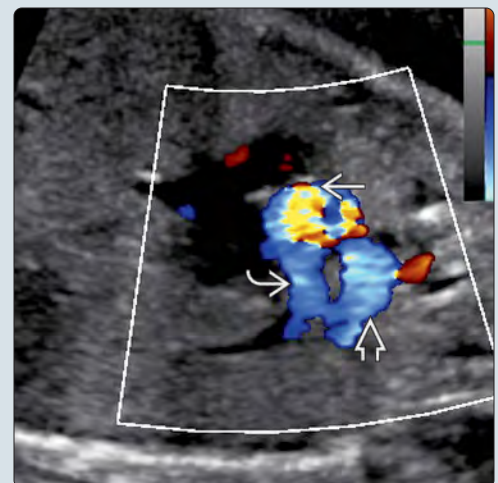
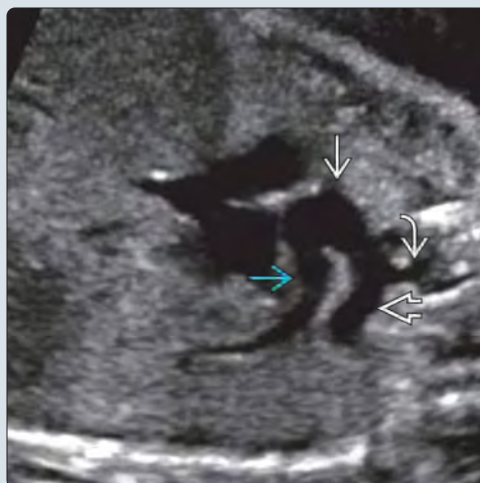CLINICAL ISSUES

- Prognosis dependent on associated abnormalities
- Definitive treatment is early, complete surgical repair
 - Excellent outcomes with 90% survival
 - Outcomes may be worse if associated with interrupted aortic arch

(Left) Graphic shows the truncal vessel arising over a ventricular septal defect (VSD). The pulmonary artery (PA) branches from the truncus shortly after it exits the heart, consistent with type 1 truncus arteriosus. **(Right)** Gross pathology of the same lesion shows the outlet VSD with a single common trunk leaving the heart. A left-sided branch gives rise to a PA. Note the head and neck vessels come off the common truncus.



(Left) Outlet view shows a single great vessel exiting the heart. It gives rise to the PA, and the aorta, which is identified by the presence of a head and neck vessel (probably the innominate artery). The branching of the PA is not seen in this view, so the type of truncus cannot be commented on. **(Right)** Same image with color shows mild flow turbulence at the truncal valve with laminar flow into the aortic arch and PA.



TERMINOLOGY

Synonyms

- Truncus arteriosus communis
- Persistent truncus arteriosus
- Common arterial trunk

Definitions

- Single vessel (truncus) arises from heart
 - Gives origin to coronary, pulmonary artery (PA) and systemic arteries
 - PA origin from this single artery differentiates truncus from pulmonary valve atresia

IMAGING

Echocardiographic Findings

- Truncus exits heart and gives rise to
 - Ascending aorta and, typically, aortic arch
 - Main ± branch PAs
 - Coronary arteries
- Truncal origin is biventricular in 68-83% of patients; remainder are entirely from right or left ventricle
- Single truncal valve with 1-5 cusps
 - Truncal valve dysplasia common
 - Stenosis, regurgitation, or both may be present
- Ventricular septal defect (VSD), outlet type most common
- Right-sided aortic arch in 21-36%
- Interrupted aortic arch in 10-19%
- Ductus arteriosus
 - Agenesis ~ 50%
 - May be very large if arch interrupted
- Coronary artery anomalies are common
- Color Doppler
 - Allows visualization of truncal stenosis and regurgitation
 - Helps with detection of VSDs
 - Shows flow pattern in aortic arch to aid in diagnosing interrupted arch
- Pulsed Doppler
 - Useful to assess degree of truncal stenosis if present
 - Persistent forward flow in truncal vessel → run-off into low pressure system
 - Pulmonary circulation is lower resistance than systemic circulation

Imaging Recommendations

- Protocol advice
 - If great vessel is noted overriding VSD
 - Look to see if that vessel gives rise to head and neck vessels
 - Look to see if PA comes off this vessel
 - Carefully look at valve for stenosis and regurgitation
 - Look for associated findings
 - Right-sided aortic arch
 - Interrupted aortic arch
 - Abnormal take off of PAs
 - Full anatomic survey for other extracardiac anomalies (21-30%)

DIFFERENTIAL DIAGNOSIS

Pulmonary Atresia With Ventricular Septal Defect

- Aorta straddles VSD
- 2nd semilunar valve is present but atretic
- Pulmonary blood flow is via
 - Retrograde flow in ductus arteriosus or
 - Collateral vessels arising from descending aorta

Tetralogy of Fallot

- PA arises from right ventricle, often with small annulus
- Aorta straddles VSD
- Anterior deviation of infundibular septum → outflow obstruction

Double-Outlet Right Ventricle

- VSD always present
- Outflow tracts are parallel, but both wholly or predominantly arise from right ventricle
 - Can be side-by-side or anterior/posterior to one another
- Great vessels may be normally related or transposed

PATHOLOGY

General Features

- Etiology
 - Maternal diabetes, including gestational, has been implicated as risk factor
 - Has occurred in dizygotic twins, siblings
 - Developmental field defect
 - Malformations of ears/jaws/lips and palate
 - Aplasia/hypoplasia thymus/parathyroid glands
 - Cardiovascular malformations, especially conotruncal defects
- Genetics
 - 40% of liveborns with truncus have 22q11 deletion syndrome
 - Microdeletion of chromosome 22
 - ◻ 10% of patients have truncus arteriosus
 - ◻ Right-sided aortic arch and abnormal branching are more common
 - Can also occur in trisomy 13, 18, 21, recombinant 8 syndrome, and single gene syndromes like CHARGE
- Embryology
 - Embryonic truncus is normal structure between conus cordis proximally and aortic arch system distally
 - Truncal swellings divide truncal lumen into 2 channels
 - Ascending aorta and pulmonary trunk
 - As truncal septum fuses with developing conal septum, right ventricular origin of pulmonary trunk and left ventricular origin of aorta are established
 - If truncal swellings do not divide lumen → single vessel leaving heart
 - ◻ Embryologically, this form of congenital heart disease should be called persistent truncus arteriosus
 - ◻ Single vessel then gives rise to pulmonary/systemic/coronary circulation
 - Spiral course of truncus produces anterior/posterior and orthogonal relationship of great arteries
 - Deficiency or absence of conal septum → large VSD

Gross Pathologic & Surgical Features

- Truncal valve usually has 3 cusps (69%)
 - Can be anywhere from 1-5 cusps
- Classification systems
 - Collett and Edwards 1949, revised in 1976 by Calder and Van Pragh
 - Type A: VSD present
 - Type B: Ventricular septum intact (very rare)
- Type A further divided
 - Subgroup or type 1
 - Short main pulmonary trunk arising from truncus, usually left-sided
 - Most common form; 48-68% of all cases
 - Subgroup or type 2
 - PAs arise separately from truncus
 - 29-48% of all cases
 - Subgroup or type 3
 - One PA arises from ascending aorta
 - Other PA arises from ductus (common) or major aortopulmonary collateral
 - 6-10% of all cases
 - Subgroup or type 4
 - Underdevelopment of aortic arch
 - Includes interrupted aortic arch, preductal coarctation, or severe arch hypoplasia/atresia
 - 10-19% of all cases
- Parent may have microdeletion, but not have cardiac disease
- At birth, large L → R shunt as blood preferentially flows into PAs
 - Untreated → pulmonary hypertension/cyanosis/heart failure/death
 - Truncal regurgitation exacerbates volume overload
- 85% mortality by end of 1st year if untreated
 - Rarely, if ever, left untreated
- Prognosis depends on
 - Pulmonary circulation
 - Discontinuous PAs or only collateral vessels = worse prognosis
 - Truncal valve function
 - Stenosis or insufficiency affects morbidity and mortality

Treatment

- Offer karyotype and FISH for 22q11 deletion
- Prenatal parental consultation with neonatology/pediatric cardiology
- Planned delivery in tertiary center with multidisciplinary team
- Definitive treatment is early, complete surgical repair
 - VSD closed off to truncal valve
 - PA/PAs removed from truncus and attached to right ventricle with homograft conduit
 - Truncal valve repaired if necessary
- Need for reintervention is common, especially to replace right ventricle-PA conduit

CLINICAL ISSUES**Presentation**

- Most common signs/symptoms
 - Fetus
 - Single great artery (truncus) exits heart, overrides VSD
 - Truncal vessel gives rise to coronary arteries, aorta, and PAs
 - Infant or child
 - Pulmonary overcirculation early in life
 - 22q11 deletion syndrome
 - Dysmorphic facies
 - Developmental delay
 - Hypocalcemia
 - Immune deficiencies due to T-cell malfunction

Demographics

- Epidemiology
 - Truncus arteriosus accounts for 1.2% (0.7-2.5%) of congenital heart disease
 - 0.006/1,000 live births
 - M = F

Natural History & Prognosis

- Series of 141 cases
 - Fetal diagnosis in 30%
 - 40% terminated pregnancy
 - Preoperative death 3%
 - Early survival 90%
- Recurrence risk
 - 1 sibling affected = 1%
 - 2 siblings affected = 3%
 - Parental karyotype required for accurate recurrence risk if child has 22q11 deletion

DIAGNOSTIC CHECKLIST**Consider**

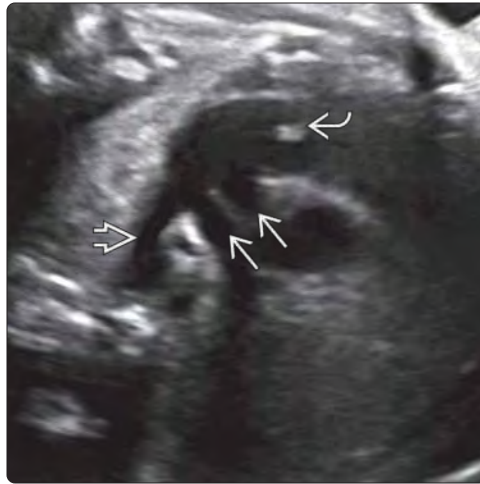
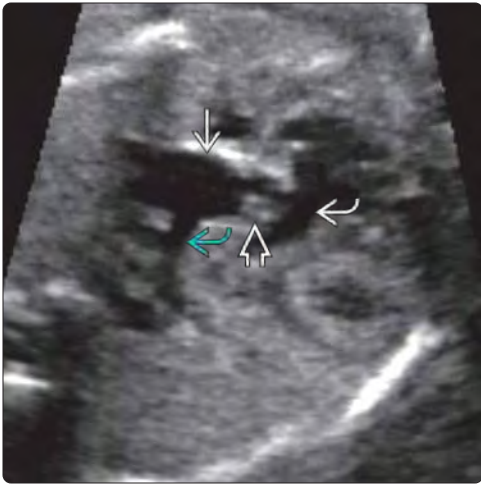
- Formal fetal echocardiogram
- Evaluate for anomalies associated with 22q11 deletion

Image Interpretation Pearls

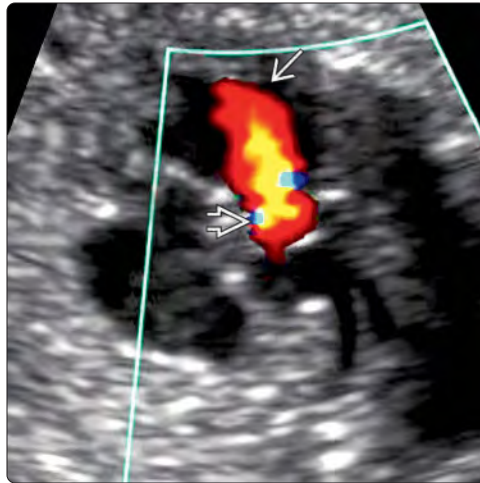
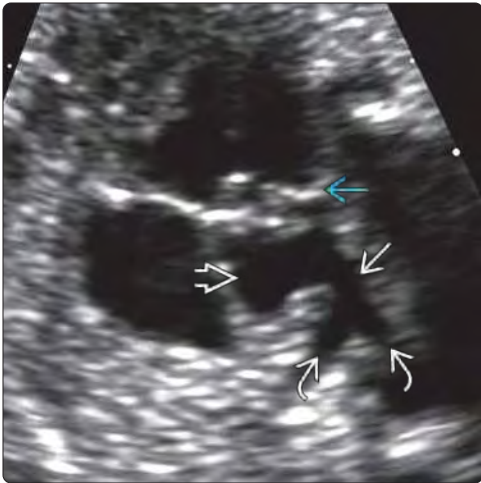
- Truncus is difficult diagnosis to make in utero
 - Look for single great vessel arising from heart
 - Proximal branch → PA is diagnostic
 - Look for truncal stenosis/regurgitation

SELECTED REFERENCES

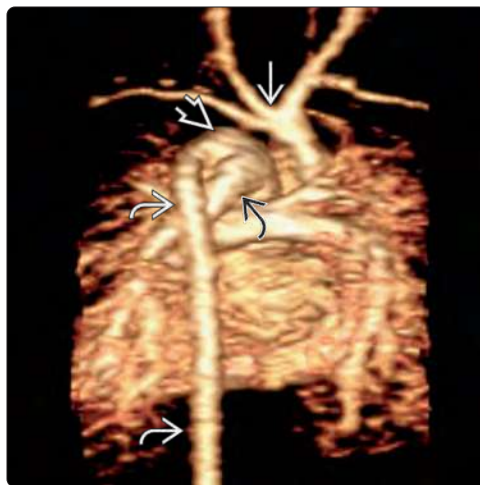
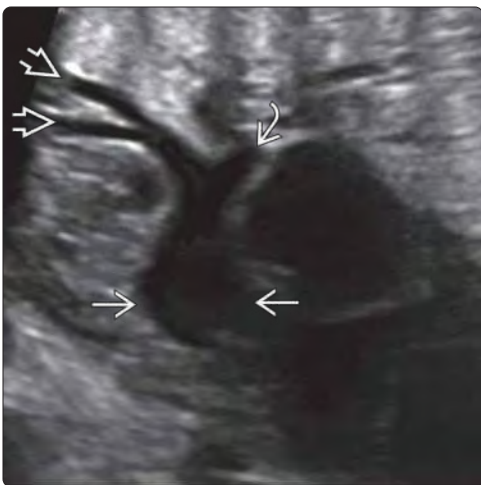
1. Gómez O et al: Accuracy of fetal echocardiography in the differential diagnosis between truncus arteriosus and pulmonary atresia with ventricular septal defect. *Fetal Diagn Ther.* 39(2):90-9, 2015
2. Traisisilp K et al: Prenatal differentiation between truncus arteriosus (Types II and III) and pulmonary atresia with ventricular septal defect. *Ultrasound Obstet Gynecol.* 46(5):564-70, 2015
3. Lee MY et al: Variety of prenatally diagnosed congenital heart disease in 22q11.2 deletion syndrome. *Obstet Gynecol Sci.* 57(1):11-6, 2014
4. O'Byrne ML et al: 22q11.2 Deletion syndrome is associated with increased perioperative events and more complicated postoperative course in infants undergoing infant operative correction of truncus arteriosus communis or interrupted aortic arch. *J Thorac Cardiovasc Surg.* 148(4):1597-605, 2014
5. Galindo A et al: Conotruncal anomalies in fetal life: accuracy of diagnosis, associated defects and outcome. *Eur J Obstet Gynecol Reprod Biol.* 146(1):55-60, 2009
6. Swanson TM et al: Truncus arteriosus: diagnostic accuracy, outcomes, and impact of prenatal diagnosis. *Pediatr Cardiol.* 30(3):256-61, 2009



(Left) Image shows a single great vessel straddling a large VSD. The valve is thickened and the vessel itself gives off an early branch, which is the main PA, consistent with truncus arteriosus. (Right) Image shows a single great vessel which has 2 vessels coming off early. These turned out to be separate PAs, making this a type 2 truncus arteriosus. One also sees the ductus arteriosus as it runs posterior to join the descending aorta.



(Left) This image shows the main and branch PAs coming off the truncal root. Note the truncal valve is very thick and dysplastic. (Right) Color Doppler in the same view shows severe insufficiency of the truncal valve with the flow going all the way to the apex of the ventricles. This confirms that the valve is dysplastic; this usually portends a worse prognosis.



(Left) Image shows a dilated truncal root, which gives rise to head vessels and the ductus arteriosus, which supplies the descending aorta in this patient with type 4 truncus arteriosus and an interrupted aortic arch. (Right) 3D MR of a type 4 truncus arteriosus viewed from the back shows an interrupted arch, patent ductus arteriosus to the descending aorta, and the branch PA coming off the truncal root.

KEY FACTS

TERMINOLOGY

- Both great arteries arise predominantly from right ventricle (RV) with variable patterns

IMAGING

- Double-outlet RV described in terms of relative position of great arteries and relative position of ventricular septal defect (VSD)
 - 40% tetralogy of Fallot type: Subaortic VSD, with pulmonary stenosis (PS) (most common)
 - Aorta located right of and posterior to pulmonary artery (PA)
 - 20% transposition of great arteries type: Subpulmonary VSD (Taussig-Bing anomaly)
 - Aorta located right of and anterior to PA
 - 15% VSD type: Subaortic VSD without PS
 - 10% doubly committed VSD
 - < 10% noncommitted or remote VSD
- PS present in 50% of patients

- Aortic/mitral or pulmonary/mitral discontinuity
 - Neither semilunar valve is in fibrous continuity with atrioventricular valve

PATHOLOGY

- Trisomy 18, 13, or 21 may be associated
- It can be manifestation of CHARGE or heterotaxy syndromes
- Associated with maternal diabetes

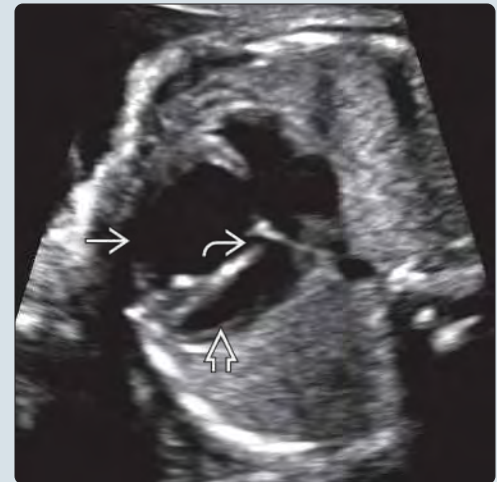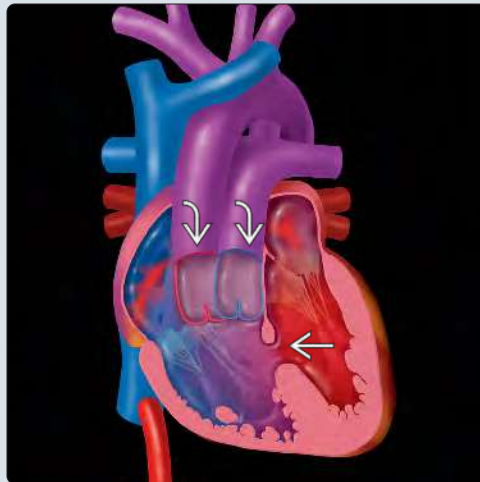
CLINICAL ISSUES

- Offer karyotype
 - 40% aneuploidy with fetal diagnosis
- Excellent early and long-term outcomes if normal chromosomes/no heterotaxy
- 26-42% of children will need reoperation at some point after primary repair

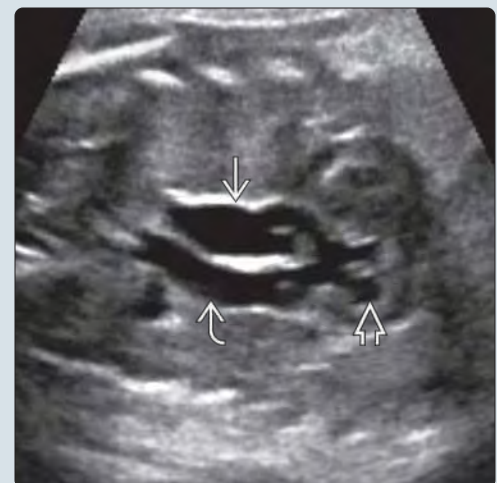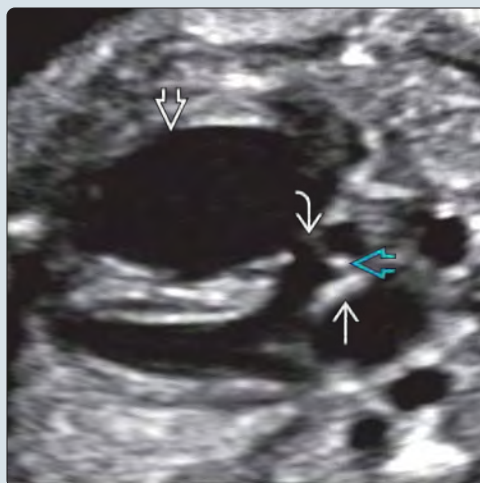
DIAGNOSTIC CHECKLIST

- Parallel outflow tracts are never normal

(Left) Graphic shows both great arteries arising from the right ventricle (RV). The presence of a ventricular septal defect (VSD) allows shunting of oxygenated blood to the RV for similar saturations in the aorta and main pulmonary artery. (Right) Image shows a dilated RV with a smaller but apex-forming left ventricle. One gets a small hint of a VSD here, but this picture is not diagnostic for double-outlet RV (DORV). Additional imaging of the great vessels is necessary.



(Left) Another image in the same patient shows mitral/aortic valve discontinuity with the aortic valve > 50% over the RV. The VSD is subaortic, making this a tetralogy of Fallot type of DORV. (Right) Image shows 2 great vessels arising from the RV. The aorta is anterior to the pulmonary artery. This is consistent with the transposition type of DORV (Taussig-Bing anomaly). The aorta is smaller than the pulmonary artery, which is concerning for associated aortic coarctation.



TERMINOLOGY

Abbreviations

- Double-outlet right ventricle (DORV)

Definitions

- Both great arteries arise predominantly from right ventricle (RV)
 - Neither semilunar valve is in fibrous continuity with atrioventricular (AV) valve
 - Ventricular septal defect (VSD) usually present

IMAGING

Echocardiographic Findings

- Both great arteries arise 50% or more from RV with variable patterns
 - Tetralogy of Fallot (TOF) type: Aorta located right of and posterior to pulmonary artery (PA)
 - Transposition of great arteries (TGA) type: Aorta located right of and anterior to PA
 - Multiple variants in between with side-by-side aorta, PA
- Aortic/mitral or pulmonary/mitral discontinuity
 - Caused by variable distribution of conal septum
- DORV described in terms of relative position of great arteries and VSD
 - VSD relationship to great vessels determined by conal development
 - 40% TOF type: Subaortic VSD, with pulmonary stenosis (PS) (most common)
 - 20% TGA type: Subpulmonary VSD (Taussig-Bing anomaly)
 - 15% VSD type: Subaortic VSD without PS
 - 10% doubly committed VSD
 - <10% noncommitted or remote VSD
- PS in 50% of patients
 - May be valvar or subvalvar

Imaging Recommendations

- If outflows parallel
 - Assess if both arise from RV
 - Assess relative positions
 - Look for location of VSD
- Look for associated cardiac findings
 - Outflow tract obstruction
 - Mitral valve abnormalities (atresia, stenosis, straddling) and AV septal defects
 - Aortic coarctation or interruption of aorta
 - Coronary artery abnormalities
- Look for features of heterotaxy syndrome

DIFFERENTIAL DIAGNOSIS

D-Transposition of Great Arteries

- Outflow tracts are parallel
- Aorta arises from morphologic RV; PA arises from morphologic LV

Tetralogy of Fallot

- Outflow tracts relate normally (i.e., not parallel)
- Aorta overrides VSD, and there is mitral to aortic continuity

PATHOLOGY

General Features

- Trisomy 18, 13, or 21 may be associated
- It can be manifestation of CHARGE or heterotaxy syndromes
- Associated with maternal diabetes
- Embryology
 - Failure of leftward shift of aortic/pulmonary conus → great vessels remaining connected to RV

CLINICAL ISSUES

Demographics

- Epidemiology
 - < 1% of all congenital heart disease

Natural History & Prognosis

- Excellent early and long-term outcomes if normal chromosomes, no heterotaxy
 - 73-88% survival at 5-8 years
- 26-42% of children will need reoperation at some point after primary repair

Treatment

- Offer karyotype as 40% aneuploidy with fetal diagnosis
- Immediate management depends on associated lesions
 - If significant PS infants are duct dependent
 - May need prostaglandins at birth to keep ductus arteriosus open
- Timing and type of corrective surgery depends on
 - Great artery relationship, presence and location of VSD
 - VSD closure with or without addressing pulmonary outflow
 - Arterial switch in TGA type (Taussig-Bing anomaly)
 - Associated lesions
 - Single-ventricle palliation for mitral atresia
 - Arch repair with coarctation or arch interruption
- Goal of correction is to reestablish LV as systemic ventricle and repair all associated lesions

DIAGNOSTIC CHECKLIST

Image Interpretation Pearls

- Parallel outflow tracts are never normal

SELECTED REFERENCES

1. Li S et al: Surgical outcomes of 380 patients with double outlet right ventricle who underwent biventricular repair. *J Thorac Cardiovasc Surg.* 148(3):817-24, 2014
2. Hartge DR et al: Prenatal detection and postnatal management of double outlet right ventricle (DORV) in 21 singleton pregnancies. *J Matern Fetal Neonatal Med.* 25(1):58-63, 2012
3. Lagopoulos ME et al: Impact of prenatal diagnosis and anatomical subtype on outcome in double outlet right ventricle. *Am Heart J.* 160(4):692-700, 2010
4. Obler D et al: Double outlet right ventricle: aetiologies and associations. *J Med Genet.* 45(8):481-97, 2008
5. Gelehrter S et al: Accuracy of the fetal echocardiogram in double-outlet right ventricle. *Congenit Heart Dis.* 2(1):32-7, 2007
6. Kim N et al: Diagnosis and prognosis of fetuses with double outlet right ventricle. *Prenat Diagn.* 26(8):740-5, 2006

KEY FACTS

IMAGING

- Small bright dot (< 3 mm) in ventricle of heart
 - Should be bright as bone to be true finding
 - Left >> right > bilateral
 - Beware of pitfalls
- Echogenic cardiac focus (ECF) is most often isolated finding in low-risk patient
 - Not cardiac defect (no associated dysfunction)
 - Weak association with trisomy 21 (T21) when isolated
 - Likelihood ratio of 1.4-1.8
 - Seek other markers for T21
 - Association with trisomy 13 (T13) if severe anomalies
 - Multiple ECF with higher aneuploidy association

TOP DIFFERENTIAL DIAGNOSES

- Rhabdomyoma
 - Homogenously echogenic myocardial mass
- Atrioventricular (AV) septal defect
 - Valve remnants can mimic ECF

PATHOLOGY




- Probably from microcalcification within papillary muscle

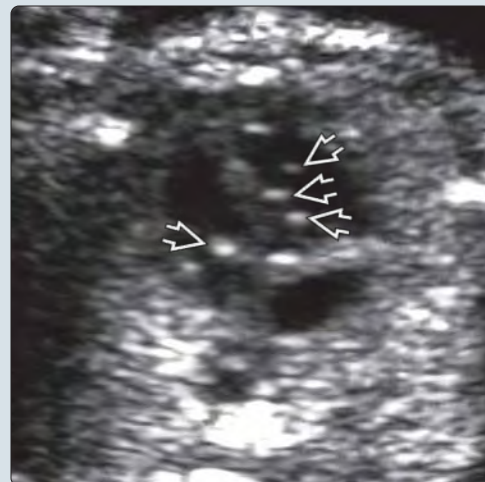
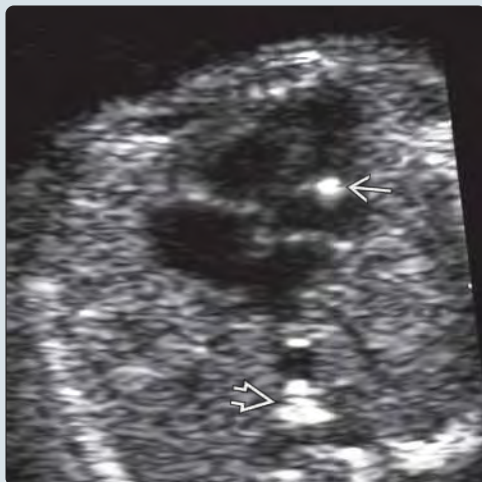
CLINICAL ISSUES





- 4-7% of euploid fetuses have ECF
- Aneuploidy association
 - 15-30% of T21 fetuses have ECF
 - 30-40% of T13 fetuses have ECF
- Ethnic variability is controversial
 - 20% Asian fetuses with ECF
 - More likely from lower maternal BMI leading to diagnosis than true ethnic variability

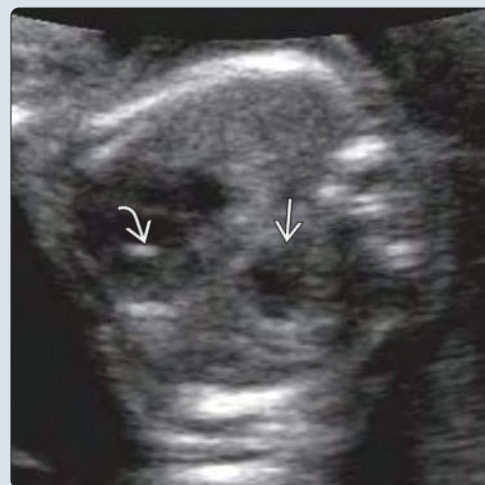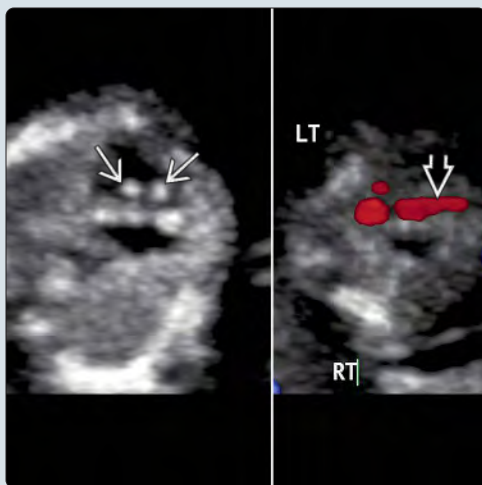
DIAGNOSTIC CHECKLIST

- Isolated ECF in low-risk patient is considered normal finding
- Do not diagnose ECF if echogenicity is less than bone
- Low-risk patients need no follow up for ECF

(Left) The 4-chamber view at 20 weeks shows the typical appearance of an incidental, isolated echogenic cardiac focus (ECF) in a low-risk patient. A bright dot , as bright as bone , is seen in the left ventricle. Targeted US revealed no other anomalies or markers. **(Right)** In this fetal heart, there are multiple bilateral ECF . Multiple ECF are associated with a higher risk for aneuploidy than isolated single ECF. Most, however, are seen in low-risk euploid fetuses.



(Left) Early anatomic survey at 15 weeks in a fetus with increased nuchal translucency reveals bilateral ECF  and a single umbilical artery . The presence of 2 markers led to invasive genetic testing, leading to the diagnosis of trisomy 13. **(Right)** Axial view through the fetal chest shows an ECF  as well as shift of the cardiac axis, secondary to an intrathoracic stomach  in this fetus with a diaphragmatic hernia and trisomy 13. The presence of an anomaly, in addition to the ECF, should raise the suspicion of aneuploidy.



TERMINOLOGY**Abbreviations**

- Echogenic cardiac focus (ECF)

Synonyms

- Intracardiac echogenic focus (IEF)
- Echogenic intracardiac focus (EIF)

Definitions

- Focal echogenicity of papillary muscle

IMAGING**General Features**

- Best diagnostic clue
 - Small bright dot (< 3 mm) in ventricle of heart
- Location
 - 78% left, 18% right, 4% bilateral

Ultrasonographic Findings

- Bright echogenic focus in ventricle, bright as bone
 - Seen best when cardiac apex points toward transducer
 - Becomes linear on orthogonal views
 - ECF is most often incidental isolated finding
 - Not associated with cardiac anomalies or dysfunction
 - Most often only single ECF seen
 - Multiple and bilateral ECF have ↑ risk for aneuploidy
- **ECF association with trisomy 21 (T21)**
 - 1.4-1.8 likelihood ratio (LR) when isolated
 - Rarely turns low-risk patient into high-risk patient
 - Increased risk if other markers for T21 seen
- **ECF association with trisomy 13 (T13)**
 - Associated cardiac anomaly common
 - Other severe hallmark anomalies almost always present

Imaging Recommendations

- Protocol advice
 - Look for other anomalies and markers
 - Beware of pitfalls
 - Normal papillary muscle (not as bright as bone)
 - Moderator band (at apex of right ventricle)
 - False tendon (normal left ventricular band)
 - From septum to ventricular wall
 - Assess maternal a priori risk for aneuploidy
 - Maternal age and genetic testing serum results
 - Amniocentesis not indicated in low risk patients
 - Follow-up US and echocardiography not indicated in low-risk patients with normal anatomy scan

DIFFERENTIAL DIAGNOSIS**Rhabdomyoma**

- Homogeneous echogenic cardiac tumor
 - Originates from septum, ventricular wall, or atria
 - Multiple tumors common
- 50-85% have tuberous sclerosis

Atrioventricular Septal Defect

- Lack of central cardiac structures
- Mitral and tricuspid valve lateral remnants can mimic ECF
- Highly associated with aneuploidy (mostly T21)

PATHOLOGY**General Features**

- Etiology
 - Probably from microcalcification within papillary muscle
- Genetics
 - Most often euploid fetus
 - Associated with T21 and T13

CLINICAL ISSUES**Presentation**

- Most common signs/symptoms
 - Incidental finding in low-risk patient at anatomy scan
 - Seen with other markers or anomalies of T21
 - Seen with severe anomalies of T13

Demographics

- Epidemiology
 - 4-7% of euploid fetuses have ECF
 - 15-30% of T21 fetuses have ECF
 - 30-40% of T13 fetuses have ECF
 - Prevalence of ECF seen relates to maternal body mass index (BMI) rather than ethnicity
 - 20% of Asian fetuses have ECF
 - Multiple ECF associated with ↑ risk for aneuploidy
 - 8.5% with T21 in 1 large study

Natural History & Prognosis

- Excellent prognosis when isolated finding in low-risk patient
 - Not associated with cardiac dysfunction

DIAGNOSTIC CHECKLIST**Consider**

- Isolated ECF in low-risk patient is considered normal finding
- Controversial about disclosing finding to low-risk patient
 - Disclosure leads to increased testing

Image Interpretation Pearls

- Do not diagnose ECF if echogenicity is less than bone
 - Turn down gain until all that is seen is ECF and bone to confirm true finding
- Review chart to assess patient's a priori risk
- Low-risk patients need no follow-up

SELECTED REFERENCES

1. Yozgat Y et al: Modified myocardial performance index is not affected in fetuses with an isolated echogenic focus in the left ventricle. *J Matern Fetal Neonatal Med.* 28(3):333-7, 2015
2. Reddy UM et al: Fetal imaging: executive summary of a joint Eunice Kennedy Shriver National Institute of Child Health and Human Development, Society for Maternal-Fetal Medicine, American Institute of Ultrasound in Medicine, American College of Obstetricians and Gynecologists, American College of Radiology, Society for Pediatric Radiology, and Society of Radiologists in Ultrasound Fetal Imaging Workshop. *J Ultrasound Med.* 33(5):745-57, 2014
3. Altug N et al: Echogenic focus in the fetal left ventricular cavity: is it a false tendon? *Early Hum Dev.* 89(7):479-82, 2013
4. Chasen ST et al: Echogenic intracardiac foci: disclosure and the rate of amniocentesis in low-risk patients. *Am J Obstet Gynecol.* 209(4):377.e1-3, 2013
5. Rodriguez R et al: The continuing enigma of the fetal echogenic intracardiac focus in prenatal ultrasound. *Curr Opin Obstet Gynecol.* 25(2):145-51, 2013
6. Gupta G et al: Intracardiac echogenic focus and fetal outcome. *J Clin Ultrasound.* 38(9):466-9, 2010

KEY FACTS

TERMINOLOGY

- Hypertrophic cardiomyopathy (HCM)
 - Primary disorder of cardiac muscle
 - Thickened but nondilated left ventricle
 - Absence of another cardiac or systemic disease capable of producing hypertrophy
- Dilated cardiomyopathy (DCM)
 - Dilated heart with decreased systolic function
 - Final common pathway for diverse disease processes that lead to heart failure

IMAGING

- HCM
 - Myocardial thickening characteristically asymmetric
 - Septum most often involved
 - May be confined to apex or free wall
 - May be symmetric (concentric hypertrophy)
 - Normal or hyperdynamic function
 - Increased gradient in left ventricular outflow tract

- Diastolic dysfunction
- DCM
 - Cardiomegaly
 - Poor myocardial contractility
 - May involve right ventricle, left ventricle, or both
 - Anatomically normal with no valvar obstruction

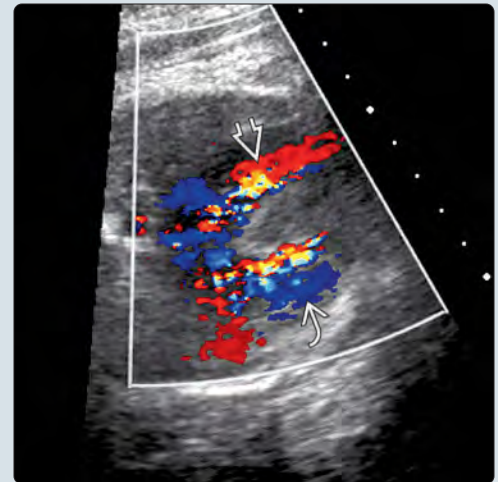
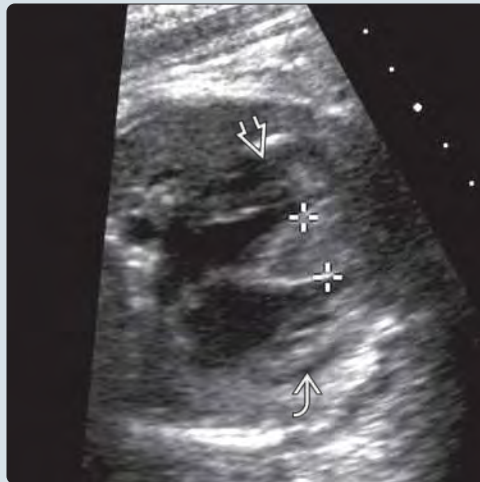
PATHOLOGY

- May be end result of numerous disease processes
 - Idiopathic, genetic, metabolic, inflammatory, familial, renal disease, twin-twin transfusion syndrome, high-output states

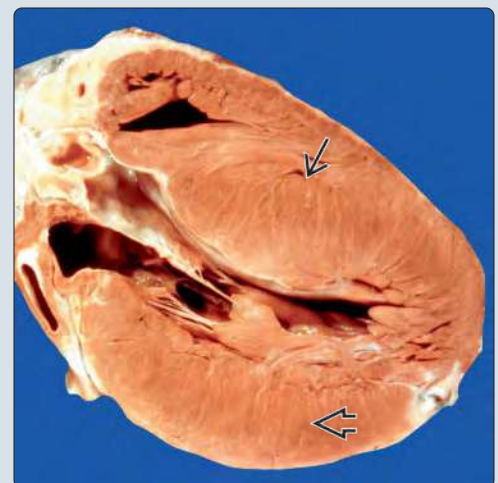
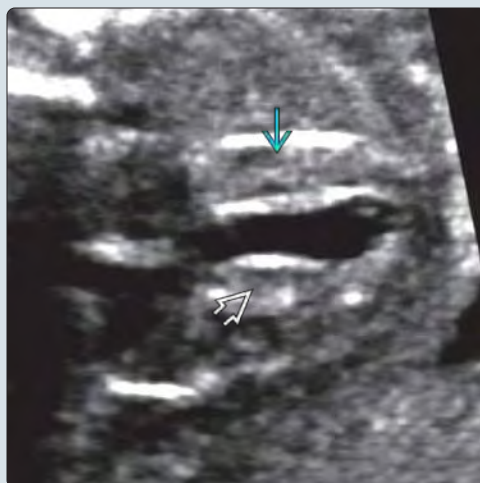
CLINICAL ISSUES

- Presence of hydrops is poor prognostic sign
- CM (all types) accounts for 2% of neonatal heart disease
 - Annual risk of death with primary/familial forms is 1%
 - Barth syndrome is often lethal early in infancy
 - HCM: 18% 1-year survival

(Left) Four-chamber view of a fetus of a diabetic mother shows marked thickening of the ventricular septum (calipers). The ventricular free walls are also hypertrophied, with the left ventricle (LV) being more severely involved than the right ventricle (RV). **(Right)** Color Doppler in the same case shows marked turbulence and obstruction to flow. Note that the LV cavity is smaller than that of the RV.



(Left) Long axis of the LV shows a thick septum and LV free wall. The etiology was unknown. Genetic counseling should be considered in cases such as these; numerous genetic disorders cause hypertrophic cardiomyopathy (HCM). Recurrence risk is important for future pregnancy management. **(Right)** Cross section of the LV in a different case shows severe, asymmetric hypertrophy, with the septum more involved than the free wall. HCM has a poor prognosis.



TERMINOLOGY

Abbreviations

- **Hypertrophic cardiomyopathy (HCM)**
- **Dilated cardiomyopathy (DCM)**

Synonyms

- HCM: Idiopathic hypertrophic subaortic stenosis (IHSS)
- HCM: Hypertrophic obstructive cardiomyopathy (HOCM)

Definitions

- **HCM**
 - Primary disorder of cardiac muscle
 - Thickened but nondilated left ventricle (LV)
 - Absence of another cardiac or systemic disease capable of producing hypertrophy
- **DCM**
 - Dilated heart with decreased systolic function
 - Final common pathway for diverse disease processes that lead to heart failure

IMAGING

General Features

- Best diagnostic clue
 - HCM: Thickened myocardium
 - DCM: Dilated LV with poor function

Echocardiographic Findings

- **HCM**
 - Myocardial thickening characteristically asymmetric
 - Septum most often involved
 - May be confined to apex or free wall
 - May be symmetric (i.e., concentric hypertrophy)
 - Normal or hyperdynamic function
 - Pulsed Doppler
 - Increased gradient in left ventricular outflow tract
 - Delayed upstroke suggesting dynamic obstruction
 - Due to systolic anterior motion (SAM) of mitral valve
 - Signs of cardiac decompensation
 - Reversed flow in inferior vena cava and ductus venosus
 - Pulsatile flow in umbilical vein
 - Signs of diastolic dysfunction
 - Abnormal mitral E and A wave
 - Abnormal tissue Doppler of ventricular walls
 - Color Doppler
 - Signs of midcavitary obstruction
 - Turbulent flow in left ventricular outflow from subaortic stenosis or SAM of mitral valve
 - Atrioventricular regurgitation
 - Color regurgitant "jet" back into atrium during systole
- **DCM**
 - Cardiomegaly
 - Poor myocardial contractility
 - May involve right ventricle, LV, or both
 - Myocardium often thin, not thick
 - Anatomically normal with no valvar obstruction

Imaging Recommendations

- Protocol advice
 - Measure ventricular wall thickness
 - Measure at level of papillary muscles
 - Epicardial to endocardial surface at end-diastole
 - Measure chamber dimensions in 4-chamber view
 - End-diastolic diameter (EDD) is longest measurement at end-diastole
 - End-systolic diameter (ESD) is shortest measurement at end-systole
 - Measure function by ventricular shortening fraction (VSF) or by ejection fraction
 - Measure cardiac output
 - Distinguish between high output and low output
 - Use cardiovascular profile score to evaluate fetal well-being, which takes into account following factors
 - Hydrops, umbilical venous and arterial Doppler, heart size, and cardiac function
 - **HCM**
 - Assess for involvement of both ventricles
 - Assess symmetric or asymmetric LV involvement
 - Exclude mechanical causes
 - Valvar stenoses
 - Ductal constriction
 - Coarctation (difficult to exclude in fetus)
 - **DCM**
 - Assess for involvement of both ventricles
 - Exclude mechanical causes
 - Critical aortic stenosis
 - Exclude arrhythmia-induced cardiomyopathy
 - Fetal supraventricular tachycardia or heart block
 - Exclude causes of high-output failure
 - Anemia, twin-twin transfusion syndrome (TTTS), twin reversed arterial perfusion (TRAP), arteriovenous malformations, fetal tumors
 - Look for signs of intrauterine infection
 - Intracranial or intrahepatic calcifications
 - Hepatosplenomegaly

DIFFERENTIAL DIAGNOSIS

Outflow Tract Obstruction

- Left or right ventricular outflow tract obstruction
 - May cause hypertrophy, which will mimic HCM

Rhabdomyoma

- Mimics HCM if it involves ventricular septum
- Usually multiple masses, more echogenic than surrounding myocardium

Pseudocardiomegaly

- Heart size normal, chest is small
 - Pulmonary hypoplasia
 - Skeletal dysplasia

PATHOLOGY

General Features

- Etiology
 - 44% idiopathic
 - 41% genetic, metabolic causes

- Maternal diabetes: Type 1, type 2, rare with gestational diabetes
- Noonan syndrome: Only single gene disorder likely to be diagnosed in utero
 - LEOPARD syndrome: Related but caused by different missense mutation of same gene
- X-linked: Barth, Duchenne, and Becker muscular dystrophy
 - 50% have mutation of chromosomes 1, 14, or 15
 - 30% missense mutation in cardiac β myosin heavy chain gene on chromosome 14q11
 - 15% mutation in cardiac troponin T gene on chromosome 1q3
 - 3% mutation in a tropomyosin gene on chromosome 15q2
- Pompe disease
 - Muscle fibers infiltrate with glycogen and become massively hypertrophied
- 15% inflammatory
 - Postinfectious
 - Anti-Sjögren's-syndrome-related antigen A (Anti-SSA, also called anti-Ro) antibody
- Fetal renal disease
 - May be related in part to fetal hypertension
- TTTS
 - Increased work for pump twin heart, recipient has volume overload
- Other high-output states
 - Anemia, vascular malformation, vascular tumor (e.g., sacrococcygeal teratoma)
- Physiology
 - Ventricular walls and septum are thick
 - Thick myocardium is stiff
 - \downarrow compliance \rightarrow \downarrow filling \rightarrow \downarrow cardiac output
- HCM may cause diastolic dysfunction
 - Myocardial perfusion occurs in diastole
 - Diastolic dysfunction \rightarrow myocardial ischemia/myopathy
- Fetus of diabetic mother
 - Disproportionate thickening of septum or free wall
 - Progressive but tends to occur after 30 weeks
 - Usually resolves spontaneously after birth with few patients being symptomatic
- Primary/familial forms
 - Annual risk of death: 1%
 - Barth syndrome is often lethal early in infancy
 - Normal fetal echocardiogram does not imply disease-free lifetime
 - Familial forms may not have clinical impact until adolescence or later
 - Duchenne, Becker muscular dystrophy develop progressive cardiomyopathy as teenagers

Treatment

- Maternal infection screen
- Identify and correct underlying conditions when possible
 - Laser/radiofrequency ablation for TTTS or TRAP
 - Early delivery or fetal surgery for masses
 - Intrauterine transfusion for fetal anemia
- Detailed family history, genetic counseling
 - Consider echocardiography of parents if mother not diabetic
 - Genetic testing possible for some types
 - Ethical dilemma as presence of mutation does not = presence of disease
 - Inborn errors of metabolism often autosomal recessive
 - May require specific treatment/dietary measures
- Monitor for progression of HCM \rightarrow outflow obstruction
- Check for associated arrhythmia
- Refer to tertiary center for coordinated delivery plan

DIAGNOSTIC CHECKLIST

Consider

- Formal fetal echocardiography essential in all cases
 - Exclude structural malformation
 - Characterize arrhythmia
 - Assess baseline function and cardiac output
 - Obtain cardiovascular profile score

Image Interpretation Pearls

- Always check for mechanical obstruction
- In at-risk fetus, measure ventricular function
- Always check for shunt lesions in fetus with apparent isolated cardiomegaly

SELECTED REFERENCES

1. Weber R et al: Spectrum and outcome of primary cardiomyopathies diagnosed during fetal life. *JACC Heart Fail.* 2(4):403-11, 2014
2. Mongiovi M et al: Diagnosis and prognosis of fetal cardiomyopathies: a review. *Curr Pharm Des.* 16(26):2929-34, 2010
3. Yinon Y et al: Fetal cardiomyopathy—in utero evaluation and clinical significance. *Prenat Diagn.* 27(1):23-8, 2007
4. Huhta JC: Guidelines for the evaluation of heart failure in the fetus with or without hydrops. *Pediatr Cardiol.* 25(3):274-86, 2004

CLINICAL ISSUES

Presentation

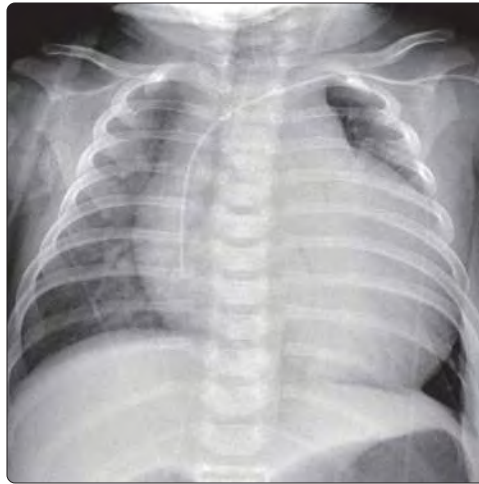
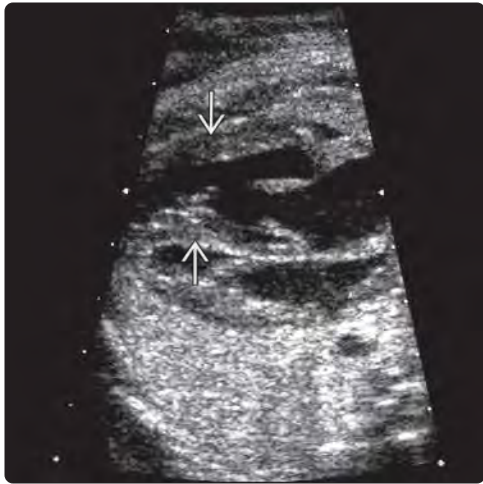- Cardiomegaly observed on routine obstetric sonogram
- Fetuses of diabetic mothers may show progressive increase in heart size/myocardial thickness from 2nd trimester onward
- Most primary/familial cases present in 3rd trimester

Demographics

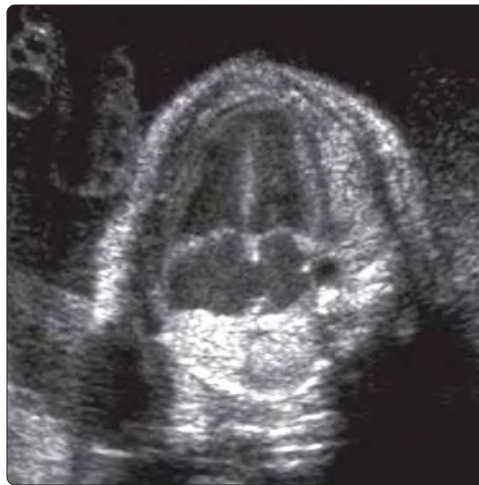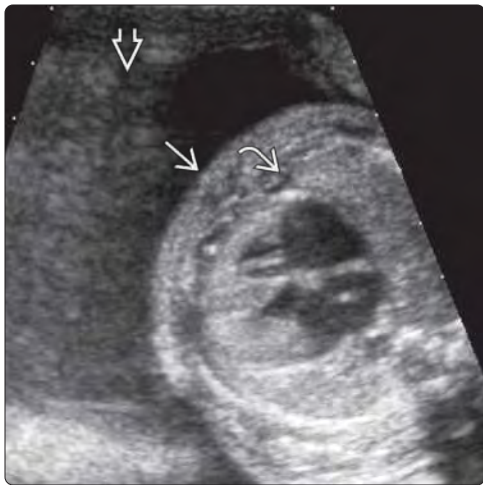
- Epidemiology
 - CM (all types) accounts for 2% of neonatal heart disease
 - HCM: 1:500 live births, or 0.2% in general population
 - DCM: Detected in < 1% fetal echocardiograms
 - Likely underrepresented in cardiology series as underlying condition takes precedence

Natural History & Prognosis

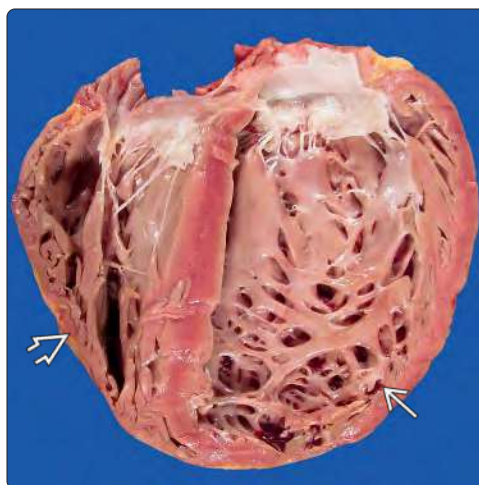
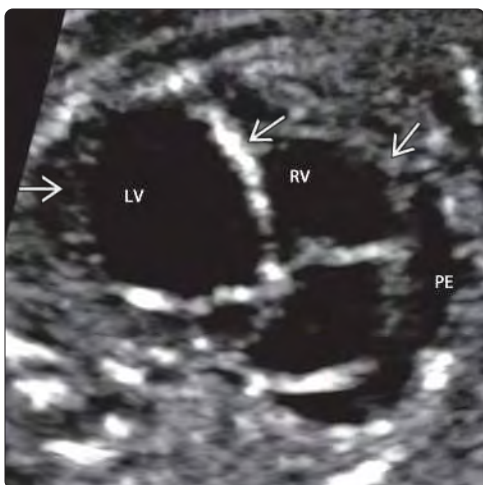
- Hydrops is poor prognostic sign regardless of underlying cause
- Depends on etiology
 - HCM: 18% 1-year survival
 - Some HCM cases progress to DCM if underlying condition not treated



(Left) Echocardiogram shows a large, hypertrophied, and dilated RV in a fetus with Barth syndrome (abnormal mitochondrial function). This typically progresses to dilated cardiomyopathy (DCM), which is often lethal in early infancy. **(Right)** Radiograph shows cardiomegaly in an infant with Pompe disease, a lysosomal storage disorder resulting in accumulation of glycogen in skeletal and cardiac muscles, hepatomegaly, and macroglossia. Always test for lysosomal storage disorders in apparently "idiopathic" hydrops fetalis.



(Left) Four-chamber view of the recipient twin in twin-twin transfusion syndrome shows markedly thickened ventricular walls and septum as well as skin edema and small pleural effusion. **(Right)** Two weeks after donor twin demise, the 4-chamber view shows thin myocardium and a "baggy," poorly functioning heart, indicating DCM. Autopsy confirmed myocardial ischemia, which was attributed to severe hypotension at the time of twin demise.



(Left) Fetal echocardiogram demonstrates marked dilation of both ventricles with predominant dilation of the LV. Both the LV and RV have notable thinning of the myocardium. Poor cardiac function has resulted in hydrops with a pericardial effusion (PE). **(Right)** This gross specimen from a different but similar case of DCM shows dilation of both the LV and RV without increase in wall thickness. (From DP: Nonneoplastic Pediatrics.)

KEY FACTS

TERMINOLOGY

- Congenital, cardiac hamartoma composed of abnormal myocytes

IMAGING

- Well-defined, homogeneous, hyperechoic, intracardiac mass
- Typically multiple masses, most common in ventricles but can be anywhere

PATHOLOGY

- Well-circumscribed, unencapsulated, white or gray-white, intramural or intracavitary nodule
- 75-80% of infants with cardiac rhabdomyomas have tuberous sclerosis (TS)
 - Almost 100% with multiple masses
- TS is autosomal dominant with variable expressivity
 - ~ 30% of cases inherited
 - Other cases due to new mutation

- Caused by mutations in *TSC1* or *TSC2* genes

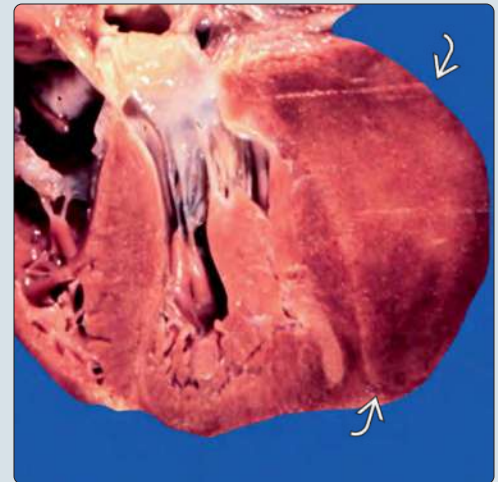
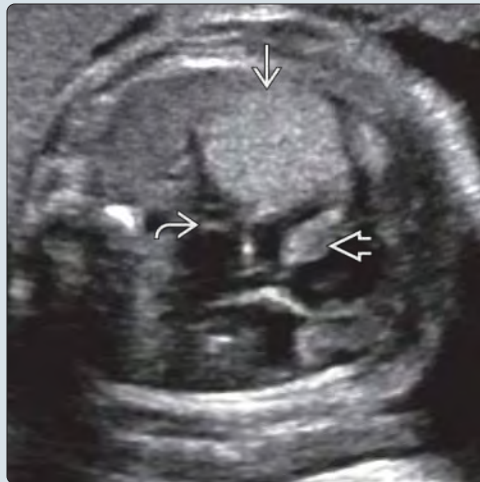
CLINICAL ISSUES

- Good cardiac outcome if no complications in utero or in 1st 6 months of life
 - Usually spontaneously regress
- Poor outcome if associated with cardiac dysfunction
 - Inflow or outflow obstruction or regurgitation due to mass effect
- Clinical triad of findings in TS: Seizures, intellectual disability, cutaneous angiofibromas
 - Overall prognosis is poor due to multiple factors (primarily CNS)
 - Survival 21% at 9 years

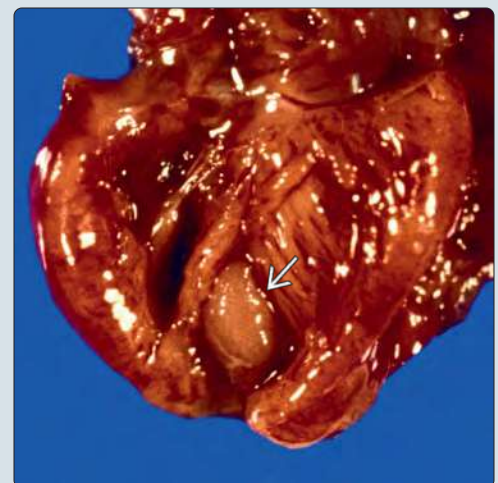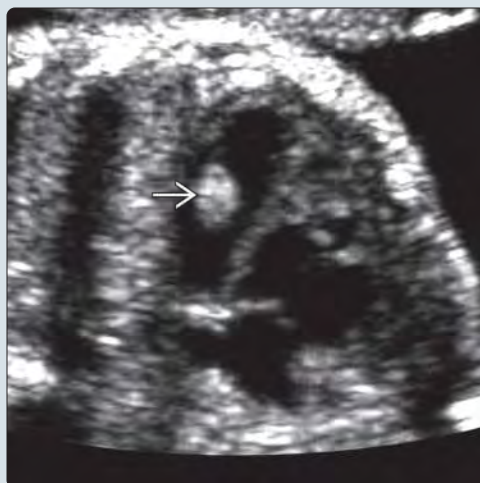DIAGNOSTIC CHECKLIST

- Consider fetal MR to evaluate for other signs of TS

(Left) Four-chamber view of the fetal heart shows a very large mass at the apex of the left ventricle (LV), which almost completely obliterates the cavity. The mitral valve almost seems to be attached to it. There is an additional mass in the septum. These are consistent with rhabdomyomas. **(Right)** Gross pathology from a different, but similar, case shows a rhabdomyoma causing dramatic LV wall thickening.



(Left) Fetal echocardiogram shows a small, hyperechoic, well-defined mass involving the papillary muscle of the LV. This was a solitary lesion, and the fetus was otherwise normal. **(Right)** Gross pathology of the heart in a similar case shows a well-defined mass arising from the wall of the LV. Histology confirmed a rhabdomyoma. This small mass would not have caused obstruction, but it could have triggered an arrhythmia as a cause of death.



TERMINOLOGY

Definitions

- Congenital, cardiac hamartoma composed of abnormal myocytes

IMAGING

General Features

- Best diagnostic clue
 - Well-defined, homogeneous, hyperechoic, intracardiac mass
 - Typically multiple masses
 - Most common in ventricles but can be anywhere in heart

Imaging Recommendations

- Best imaging tool
 - 2D echocardiogram for cardiac rhabdomyomas, evaluation of cardiac function
 - MR for evaluation of brain tubers
- If cardiac mass is identified
 - Look for additional masses
 - Assess location, characterize mass
 - Homogeneous, hyperechoic mass involving myocardium
 - More often in septum/ventricle but can be anywhere
 - Avascular
 - May appear as simple wall thickening, especially when small
 - Look for rhythm abnormalities
 - Premature atrial or ventricular beats
 - Supraventricular tachycardia
 - Sinus bradycardia
 - Look for signs of obstruction
 - May affect ventricular inflow or outflow
 - May manifest as valve regurgitation or stenosis
 - Increased cardiac work to overcome obstruction → wall hypertrophy
 - Monitor for signs of hydrops
 - Ascites, pleural effusion, pericardial effusion, skin thickening
- **Look for other findings of tuberous sclerosis (TS)**
 - High index of suspicion in setting of multiple cardiac masses
 - Subependymal nodules often difficult to discern by ultrasound
 - Look for subtle irregularity along lateral ventricular walls
 - Fetal brain MR recommended
 - Subependymal nodules and cortical/subcortical tubers
 - High signal intensity on T1WI
 - Low signal intensity on T2WI
 - Subependymal giant cell astrocytoma
 - Mass near foramen of Monro
 - May cause hydrocephalus
 - Uncommon to diagnose in utero
 - Postnatal brain MR should be done in all cases even if in utero scan is normal
 - Fetal findings may be difficult to discern
 - May use gadolinium

- Dedicated cardiac echo in all cases after birth

DIFFERENTIAL DIAGNOSIS

Pericardial Teratoma

- Rare tumor, usually benign
- Pericardial (not myocardial) tumor
 - Exophytic growth (will not be in cardiac chamber)
 - Frequently located at right anterior heart border
- Heterogeneous with calcification
- Solid and cystic components
- Pericardial effusion often present
- May cause heart failure due to pericardial effusion and cardiac compression
 - Symptoms more related to size and location than histology
 - Fetal pericardiocentesis can prevent cardiac tamponade

Fibroma

- Usually solitary
- Benign proliferation of connective tissue
 - May infiltrate normal myocardium
- Often arises from intraventricular septum or free wall of left ventricle
 - Right ventricle may be involved
- Intramural solid echogenic lesion
 - Occasionally can be inhomogeneous if associated cystic degeneration
- May be associated with pericardial effusion

Hemangioma

- Hyperechoic
- Variable vascularity with Doppler
- Can be associated with pericardium
- Presents with cardiac symptoms
 - Pericardial or pleural effusion
 - Arrhythmia
 - Heart failure
- Asymptomatic lesions may be observed
 - Can regress spontaneously

Myxoma

- Myxomas not typically seen in utero
 - Most arise from interatrial septum/region of foramen ovale
 - Left atrium > right atrium

Echogenic Cardiac Focus

- Associated with papillary muscle
 - Small (usually < 3 mm)
 - Very bright (similar to bone)
 - 78% in left ventricle
- Associated with both trisomy 21 and 13
 - Need to evaluate for other associated findings

PATHOLOGY

General Features

- Etiology
 - Unknown, but data suggests maternal hormones may play role in growth and development of fetal rhabdomyomas

- Genetics
 - 75-80% of infants with cardiac rhabdomyomas have TS
 - Almost 100% with multiple masses
 - ~ 50% with single mass, no family history
 - ~ 50% of patients with TS have cardiac rhabdomyomas
 - TS is autosomal dominant with variable expressivity
 - Offspring of affected individuals at 50% risk of inheriting mutation
 - ~ 1/3 of cases inherited
 - Other 2/3 of cases due to new mutation
 - Caused by mutations in *TSC1* or *TSC2* genes
 - *TSC1* has been mapped to chromosome 9q
 - *TSC2* has been mapped to chromosome 16p
 - TS involves multiple organ systems
- Majority of morbidity and mortality related to CNS tumors, which tend to progress in size and number
- TS-associated neuropsychiatric disorders describes brain dysfunction in TS
 - Aggressive behaviors, autism spectrum disorders, intellectual disability, psychiatric disorders, neuropsychological deficits, school/occupational difficulties
- Other manifestations of TS not seen in utero include
 - Kidney: Angiomyolipomas, cysts
 - Lung: Lymphangiomyomatosis, multifocal micronodular pneumocyte hyperplasia
 - Eye: Retinal hamartomas

Gross Pathologic & Surgical Features

- Benign tumor
- Well-circumscribed, unencapsulated, white or gray-white, intramural or intracavitary nodule

Microscopic Features

- Large, round, vacuolated cells filled with glycogen
 - Cytoplasmic extensions project from nuclei to cell membrane or so called spider cell appearance
- Classified as hamartomas with inability of cells to undergo mitotic division

CLINICAL ISSUES

Presentation

- Generally incidental finding
- May be noted on evaluation for fetal dysrhythmia or even hydrops
- Can detect early in gestation
 - May discover more masses as pregnancy progresses
 - Tend to increase in size prenatally and then regress after birth

Demographics

- Most common fetal cardiac tumor (90%)

Natural History & Prognosis

- Most often benign clinical course prenatally
- May grow or remain stable
 - Majority of growth in 2nd and 3rd trimesters
 - Growth slows after 32 weeks
 - Large or multiple lesions more likely to grow in utero
 - Smaller or single lesions may remain stable or demonstrate slow growth in utero
- Usually spontaneously regress postnatally
- Good cardiac outcome if no complications in utero or 1st 6 months of life
- Poor outcome if associated with cardiac dysfunction
 - Inflow or outflow obstruction or regurgitation due to mass effect
- Clinically significant arrhythmias occur in 16%
 - Wolff-Parkinson-White syndrome has been described in association
- Clinical triad of findings in TS: Seizures, intellectual disability, cutaneous angiofibromas
- TS prognosis is poor due to multiple factors; overall survival 21% at 9 years

Treatment

- Prenatal
 - Consider preterm delivery only if hemodynamic obstruction causing hydrops
 - May infrequently require prenatal therapy with antiarrhythmics
 - Genetic counseling
- Postnatal
 - Most regress without treatment
 - Neonatal medical management for heart failure may rarely be required
 - Surgical resection if adversely affecting cardiac function or causing ventricular tachycardia

DIAGNOSTIC CHECKLIST

Consider

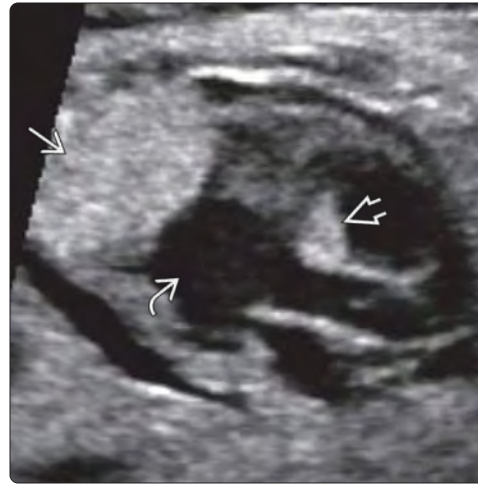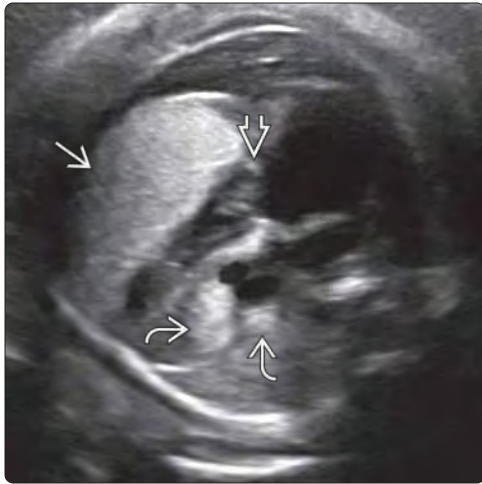
- Fetal echocardiography to monitor cardiac function and development of obstruction or regurgitation
- Fetal MR to evaluate for other signs of TS

Image Interpretation Pearls

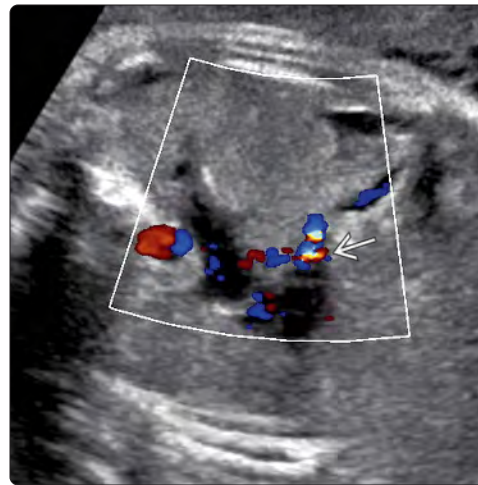
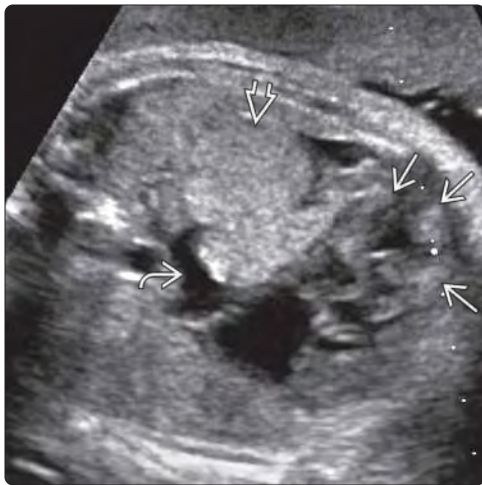
- Multiple rhabdomyomas strongly suggests TS
- Rhabdomyomas less likely to cause pericardial effusions than other cardiac tumors

SELECTED REFERENCES

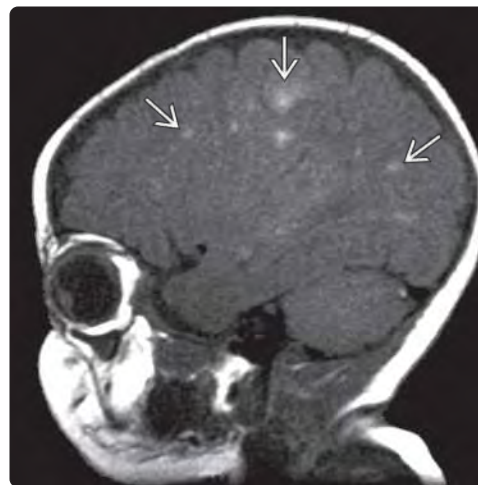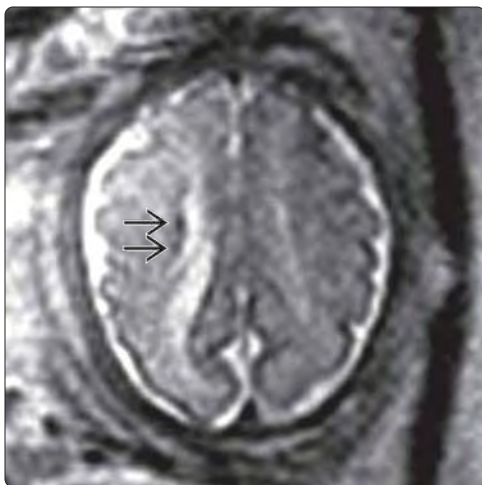
1. Lefort B et al: Unusual outcome of a right ventricular rhabdomyoma in an infant. *World J Pediatr Congenit Heart Surg.* ePub, 2016
2. Choudhry S et al: Rapid resolution of cardiac rhabdomyomas following everolimus therapy. *BMJ Case Rep.* 2015, 2015
3. Hoshal SG et al: Regression of massive cardiac rhabdomyoma on everolimus therapy. *Pediatr Int.* ePub, 2015
4. Wacker-Gussmann A et al: Fetal arrhythmias associated with cardiac rhabdomyomas. *Heart Rhythm.* 11(4):677-83, 2014
5. Lee KA et al: Molecular genetic, cardiac and neurodevelopmental findings in cases of prenatally diagnosed rhabdomyoma associated with tuberous sclerosis complex. *Ultrasound Obstet Gynecol.* 41(3):306-11, 2013
6. Miyake CY et al: Cardiac tumors and associated arrhythmias in pediatric patients, with observations on surgical therapy for ventricular tachycardia. *J Am Coll Cardiol.* 58(18):1903-9, 2011
7. Yinon Y et al: Fetal cardiac tumors: a single-center experience of 40 cases. *Prenat Diagn.* 30(10):941-9, 2010
8. Isaacs H: Perinatal (fetal and neonatal) tuberous sclerosis: a review. *Am J Perinatol.* 26(10):755-60, 2009



(Left) This 4-chamber view shows a very large mass involving the entire right ventricle free wall. This is not obstructing inflow as evidenced by the near normal appearing tricuspid valve. Additional masses are noted at the LV apex. (Right) Long-axis view shows a large mass at the LV apex and a small mass in the septum. There is a good-sized LV cavity with no obstruction to inflow or outflow. These rhabdomyomas regressed after birth, which is the typical clinical course.



(Left) A very large mass fills the LV cavity and appears to protrude into the left atrium, raising concern for obstruction to flow. Multiple small masses are also seen in the RV in this patient with tuberous sclerosis. (Right) The same image with color Doppler shows obstruction to both LV inflow and outflow. This patient was delivered and we attempted to bypass the LV surgically without success. This is a very unusual outcome of rhabdomyoma.



(Left) Axial T2 HASTE MR shows low-signal subependymal nodules in a fetus with suspected tuberous sclerosis. Postnatal MR confirmed these nodules and also showed others, which were not seen prenatally. (Right) Sagittal T1 MR at 2 months of life shows multiple high signal intensity cortical tubers typical of tuberous sclerosis. All fetuses with rhabdomyomas should be evaluated for tuberous sclerosis.

KEY FACTS

TERMINOLOGY

- Accumulation of excessive fluid in pericardial space

IMAGING

- Fluid collection surrounding all or part of heart
 - Must measure > 2 mm
 - Seen best on standard 4-chamber view
 - Significant if surrounding atria and ventricles
- Trace of fluid along 1 ventricular wall is normal
- If large, heart is seen beating in a "bag of water"

PATHOLOGY

- Etiology
 - Cardiac abnormality
 - Congenital infection
 - High-output states
 - Fetal endocrine abnormality

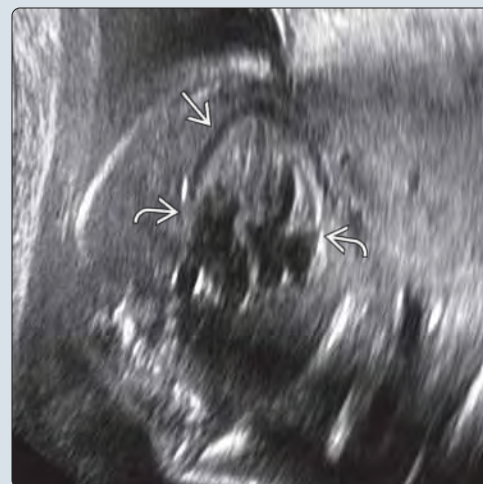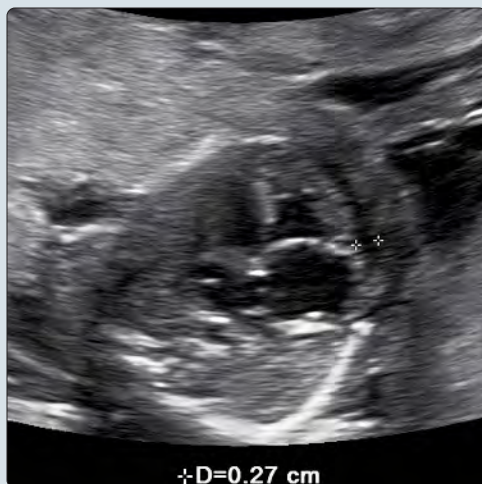CLINICAL ISSUES

- Typically incidental finding on screening exam
 - 0.02% of fetuses in series of 506 routine obstetric scans had isolated pericardial effusion
- Course is variable depending on cause
 - No treatment necessary if isolated and small
 - With hydrops fetalis, overall prognosis is poor
- Follow-up exams necessary when fluid is > 2 mm or in high-risk patients
- Treat underlying cause where possible
- Case reports of pericardiocentesis for massive effusion with risk of tamponade

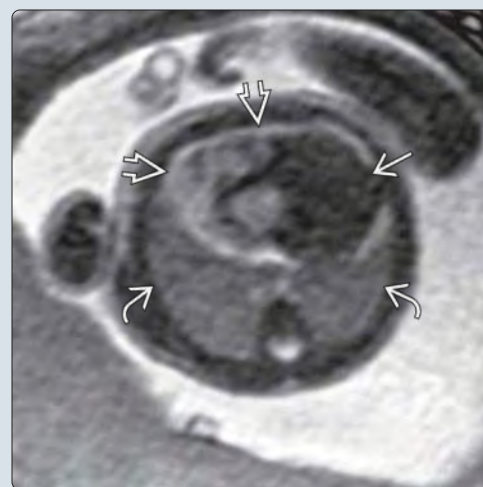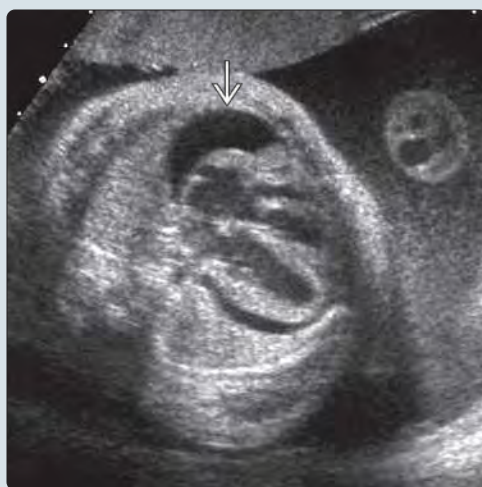DIAGNOSTIC CHECKLIST

- Assessment requires thorough anatomic survey
- May need formal fetal echocardiogram
- Pericardial effusion may be 1st sign of hydrops, especially if etiology is cardiac

(Left) Four-chamber view shows a sliver of pericardial fluid surrounding the heart in this 20-week fetus. Note that it extends beyond the plane of the atrioventricular (AV) valves (where the calipers are placed). It resolved on follow-up 1 week later. **(Right)** Axial US shows the appearance of the compacted outer myocardial layer of the ventricles. Note that this extends only to the level of the AV valves. In real time it contracts, distinguishing it from a pericardial effusion. Do not mistake normal peripheral myocardium for an effusion.



(Left) Four-chamber view shows a moderate effusion in a fetus with unexplained bradycardia. The heart was structurally normal, hydrops never developed, and the infant did well after delivery. **(Right)** Axial TRUFI obtained for evaluation of a chest mass with "pleural effusions" shows that the mass is cardiac in origin and the pleural effusion is, in fact, pericardial, surrounding the heart and displacing the lungs posteriorly. This was a large rhabdomyoma with an associated pericardial effusion.



TERMINOLOGY

Abbreviations

- Pericardial effusion (PE)

IMAGING

Ultrasonographic Findings

- Fluid collection surrounding all or part of heart
 - Must measure > 2 mm
- Seen best on standard 4-chamber view
 - Significant if surrounds atria and ventricles
 - Large effusion may be mistaken for pleural effusion
 - Lungs will be compressed posteriorly
 - Heart is seen beating in "bag of water"
- Trace fluid along 1 ventricular wall is normal
 - 50-80% of fetuses have trace fluid (< 2 mm) on careful search

Imaging Recommendations

- If fluid is noted around heart, complete fetal assessment required to exclude significant pathology
- Look for other signs of hydrops
- Look for signs of congenital infection
 - Liver &/or brain calcifications
 - Echogenic bowel
- Look for anemia
 - Measure middle cerebral artery peak systolic velocity
- Look for shunt lesions as cause of high-output state
- Monozygotic diamniotic pairs at risk for twin-twin transfusion syndrome (TTTS)
 - Risk cardiac compromise in both fetuses
 - High output in pump (donor) twin
 - Volume overload in recipient
- Careful search for features of aneuploidy
- Pericardial teratoma
 - Effusion often very large
 - May have tamponade physiology
- Cardiac diverticulum
 - Localized protrusion of ventricle with thin neck
 - Associated with PE, which may be significant
 - Color Doppler shows flow within diverticulum
- Formal fetal echocardiogram if significant effusion and none of above etiologies
 - Look for structural malformations
 - Assess baseline function
 - Evaluate rhythm

DIFFERENTIAL DIAGNOSIS

Normal Peripheral Myocardium

- Outer 1-6 mm of myocardium may be hypoechoic and mimic fluid
 - Circular outer muscle fibers cause this effect
- Seen encircling ventricles, does not surround atria
 - Look for contraction
 - Pericardial fluid creates immobile ring

Pleural Effusion

- Fluid tracks around lungs, not heart

- Large pleural effusion → circumferential pressure on lungs → lungs collapse centrally → angel wing appearance

PATHOLOGY

General Features

- Etiology
 - Cardiac abnormality
 - Arrhythmia, structural defect, cardiomyopathy
 - Congenital infection
 - Cytomegalovirus (CMV), rubella, toxoplasmosis, parvovirus B19, syphilis
 - High-output states
 - TTTS, AVM, tumors, anemia
 - Fetal endocrine abnormality
 - Fetal hypo- or hyperthyroidism may present as hydrops

CLINICAL ISSUES

Demographics

- Epidemiology
 - 0.02% of fetuses in series of 506 routine obstetric scans had isolated PE
 - Maximum measurement: 3 mm
 - All normal outcome

Natural History & Prognosis

- Variable depending on cause
- With hydrops fetalis, overall prognosis is poor
 - When PE seen early, hydrops more likely associated with cardiac abnormality
 - Some causes may be treatable (e.g., tachyarrhythmia)
 - When PE seen late, hydrops likely from other causes
 - Still potential to treat successfully (e.g., intrauterine transfusion for fetal anemia)
- Cardiac diverticulum
 - Large associated PE may cause tamponade and hydrops
 - Successful single pericardiocentesis reported
 - No recurrence of PE
 - Normal cardiac function at birth

Treatment

- No treatment necessary if isolated and small
- Follow-up exam necessary when fluid is > 2 mm or in high-risk patients
- Consider karyotype, especially if cardiac lesion is found
- Infection screen
- Treat underlying cause where possible
 - Medical treatment for arrhythmias
 - Treat TTTS
 - Laser ablation vs. serial amnioreduction
 - Intrauterine transfusion for fetal anemia
- Case reports of pericardiocentesis for massive effusion with risk of tamponade

SELECTED REFERENCES

1. Carrard C et al: Fetal right ventricular diverticulum with pericardial effusion: report of a new case treated by in utero pericardiocentesis. *Pediatr Cardiol.* 31(6):891-3, 2010
2. Slesnick TC et al: Characteristics and outcomes of fetuses with pericardial effusions. *Am J Cardiol.* 96(4):599-601, 2005

KEY FACTS

TERMINOLOGY

- Neoplasm arising from pericardium composed of all 3 germ cell layers

IMAGING

- May be intrapericardial (most common), extrapericardial, or very rarely intracardiac
- Often quite large with reported range of 2-15 cm
- Contains both solid and cystic components
 - Calcifications most specific finding for teratoma but not always present
- Pericardial effusion invariably present with intrapericardial teratoma
 - May be massive and mistaken for pleural effusion
 - Pericardial effusion compresses lungs posteriorly
 - Lungs will float in pleural effusion (wing-like appearance)
- Hydrops common associated finding from compression of heart and great vessels








- Extrapericardial teratomas may be indistinguishable from lung masses
 - Look for attachment to pericardium

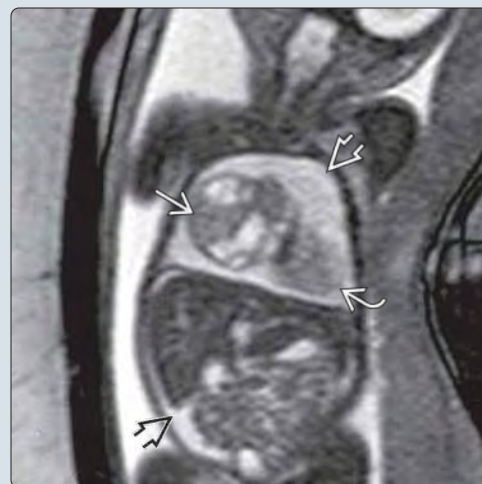
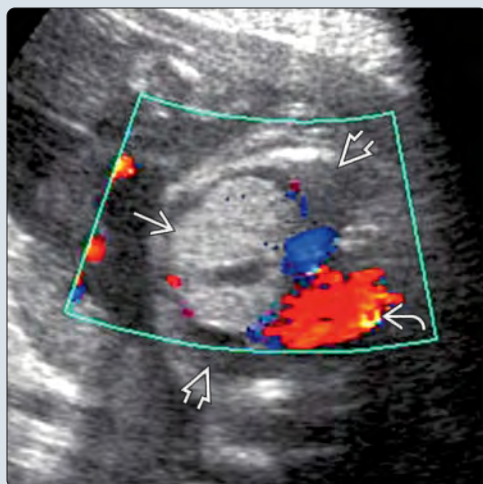
TOP DIFFERENTIAL DIAGNOSES





- Rhabdomyoma
 - Myocardial (not pericardial) mass
- Mediastinal teratoma
 - May have pleural (not pericardial) effusion
- Lung masses (congenital pulmonary airway malformation, bronchopulmonary sequestration) may potentially be confused with extrapericardial teratoma

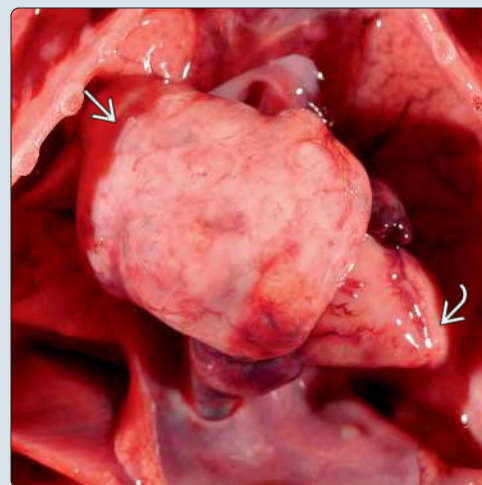
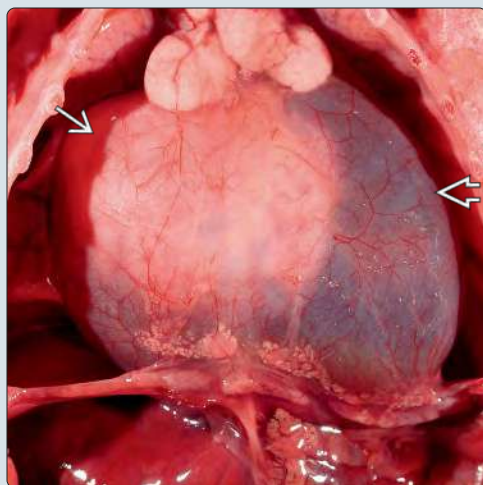
CLINICAL ISSUES

- < 10% of teratomas occur in chest but most of these are pericardial
- Case reports of survival with in utero intervention
- Often fatal, especially if hydrops is present

(Left) Transverse color Doppler US shows a large, echogenic, intrapericardial teratoma  adjacent to the heart . It is surrounded by a massive pericardial effusion . (Right) Coronal T2WI MR in the same case shows that the teratoma  is composed of high-signal cystic areas and intermediate-signal soft tissue. The heart  is dwarfed in size by the teratoma. The massive pericardial effusion  fills the chest, and a small amount of ascites  is also present.



(Left) A photograph from the autopsy shows the teratoma  within the markedly distended pericardial sac , which essentially fills the chest cavity. (Right) The teratoma  can be seen to better advantage with the pericardium removed (apex of the heart ). Most pericardial teratomas are intrapericardial, as in this case, and are invariably associated with a pericardial effusion, which may be massive.



TERMINOLOGY**Definitions**

- Neoplasm arising from pericardium composed of all 3 germ cell layers

IMAGING**General Features**

- Best diagnostic clue
 - Intrapericardial mass with massive pleural effusion
- Location
 - Pericardial in origin with exophytic growth
 - Frequently located at right anterior heart border
 - May be intrapericardial (most common), extrapericardial, or very rarely intracardiac
- Size
 - Often quite large with reported range of 2-15 cm

Ultrasonographic Findings

- Complex heterogeneous mass with both cystic and solid components
- Calcifications most specific finding for teratoma
 - Helps differentiate from other masses but not always present
- **Intrapericardial**
 - Most common location
 - Pericardial effusion invariably present
 - May be massive and mistaken for pleural effusion
 - Pericardial effusion compresses lungs posteriorly
 - Lungs will float in pleural effusion (wing-like appearance)
 - Hydrops common associated finding
 - Compression of heart and great vessels
- **Extrapericardial**
 - Look for attachment to pericardium
- Intracardiac very rare
- Color Doppler
 - Variable vascularity

DIFFERENTIAL DIAGNOSIS**Rhabdomyoma**

- Myocardial (not pericardial) mass
- Presents as echogenic intracardiac mass
- Most often in septum or ventricle

Lung Masses

- May potentially be confused with extrapericardial teratoma
 - Congenital pulmonary airway malformation
 - Bronchopulmonary sequestration
- May have pleural (not pericardial) effusion
- None have calcifications

Mediastinal Teratoma

- Usually in superior mediastinum, compressing heart inferiorly
- May have pleural (not pericardial) effusion
- Less common than pericardial teratoma

PATHOLOGY**Gross Pathologic & Surgical Features**

- Multilobulated mass with solid and cystic components

Microscopic Features

- Both immature and mature teratomas have been reported
- Predominate components include immature mesenchyme, epithelium, and neural tissue

CLINICAL ISSUES**Presentation**

- Most common signs/symptoms
 - Chest mass on 2nd- or 3rd-trimester scan
 - Massive pericardial effusion and hydrops
- Other signs/symptoms
 - May have elevated α -fetoprotein

Demographics

- < 10% of teratomas occur in chest but most of these are pericardial
- 2nd most common cardiac tumor in fetus, after rhabdomyoma

Natural History & Prognosis

- Case reports of survival with in utero intervention
- Often fatal, especially if hydrops is present

Treatment

- In utero treatment
 - Pericardiocentesis
 - Pericardio-amniotic shunting
 - In utero laser treatment reported
 - Steroid and early delivery for developing hydrops
- If liveborn, immediate resection required
 - Often resectable with good results if only pericardium is involved
 - Those with intracardiac extension do poorly

DIAGNOSTIC CHECKLIST**Image Interpretation Pearls**

- Do not confuse massive pericardial effusion with pleural effusion

SELECTED REFERENCES

1. Malay J et al: Intrapericardial immature teratoma with successful treatment in a neonate. *Indian J Pediatr.* 81(10):1099-101, 2014
2. Manoly I et al: Intrapericardial teratoma in neonates: a surgical emergency. *World J Pediatr Congenit Heart Surg.* 2(2):321-3, 2011
3. Fagiana AM et al: Management of a fetal intrapericardial teratoma: a case report and review of the literature. *Congenit Heart Dis.* 5(1):51-5, 2010
4. Niewiadomska-Jarosik K et al: Prenatal diagnosis and follow-up of 23 cases of cardiac tumors. *Prenat Diagn.* 30(9):882-7, 2010
5. Soor GS et al: Prenatal intrapericardial teratomas: diagnosis and management. *Cardiovasc Pathol.* 19(1):e1-4, 2010
6. Steffensen TS et al: Massive pericardial effusion treated with in utero pericardioamniotic shunt in a fetus with intrapericardial teratoma. *Fetal Pediatr Pathol.* 28(5):216-31, 2009
7. Liddle AD et al: Intrapericardial teratoma presenting in fetal life: intrauterine diagnosis and neonatal management. *Congenit Heart Dis.* 3(6):449-51, 2008
8. Pachy F et al: Intrapericardial teratoma with hydrops leading to in utero demise. *Prenat Diagn.* 27(10):970-2, 2007

KEY FACTS

TERMINOLOGY

- Ectopic beat is extra beat arising prematurely from site other than heart's natural pacemaker
 - Extra beat can arise from anywhere (atrium or ventricle) within myocardium to produce irregular rhythm
- Blocked beats: Atrial activity does not conduct to ventricles

IMAGING

- M-mode cursor needs to be placed in position to allow atrial and ventricular (AV) activity to be recorded at same time
 - Doppler sample volume placed in left ventricular inflow and adjacent outflow
 - Demonstrates atrial filling in 1 direction and ventricular ejection in opposite direction
 - Doppler sampling in ascending aorta and superior vena cava or pulmonary artery and vein
 - Normal flow reversal in vein (onset of atrial contraction) and onset of forward flow in artery (same direction)

– Allows assessment of interval between AV contraction

• **Premature atrial contraction (PAC)**

- Early atrial contraction in cardiac cycle followed by ventricular contraction (conducted) or not (blocked)

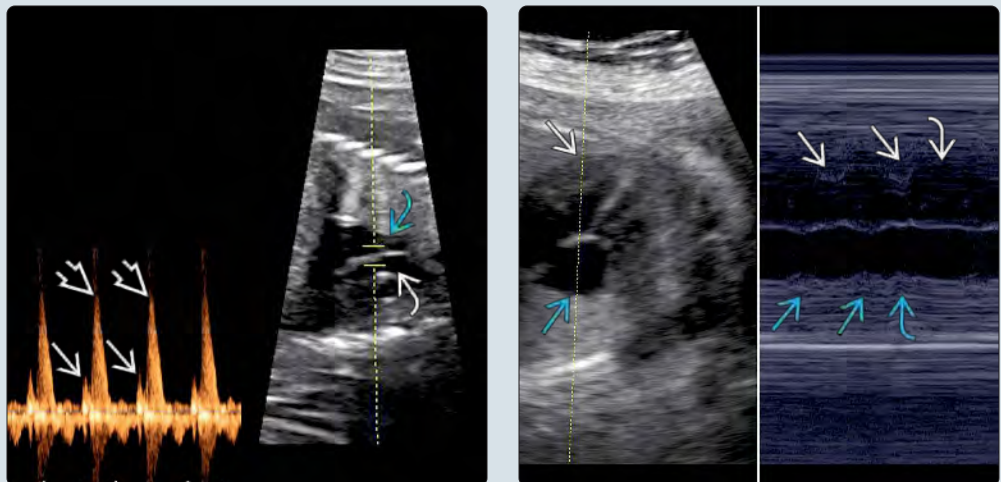
• **Premature ventricular contraction (PVC)**

- Early ventricular contraction in cardiac cycle occurring without prior atrial contraction

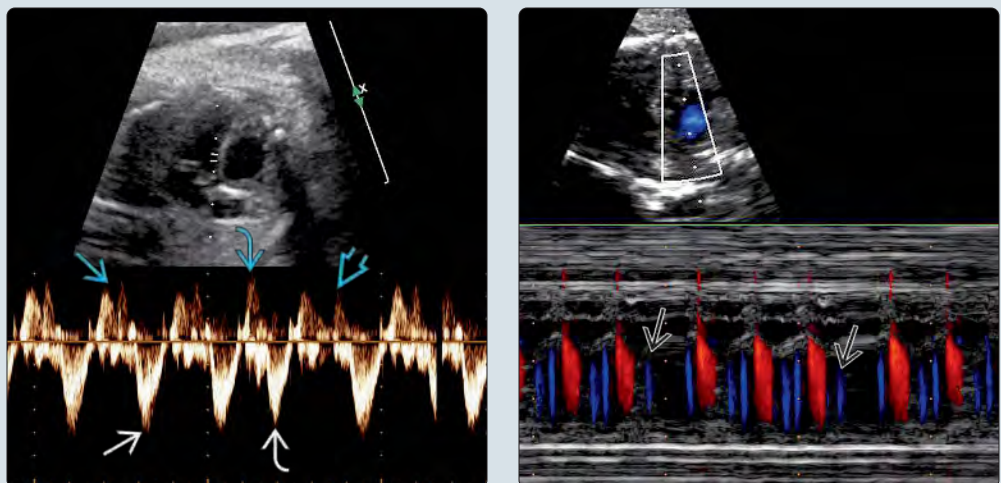
CLINICAL ISSUES

- 1-2% of pregnancies will have arrhythmia
 - < 10% are significant
 - PACs/PVCs account for 90%
 - Most common in 3rd trimester
 - Self-limited: Most resolve by time of delivery, extremely rare to cause problem in neonate
 - If frequent PACs, 2-5% risk of developing supraventricular tachycardia (higher if multiple beats are blocked)

(Left) The cursor is placed for simultaneous interrogation of the superior vena cava (SVC) and proximal ascending aorta. There is normal 1:1 conduction. With atrial contraction, there is a small amount of retrograde flow in the SVC followed by antegrade flow in the aorta representing ventricular contraction. (Right) M-mode interrogation of atrial followed by ventricular wall motion is shown. After 2 normal beats, there is a PAC that is blocked as evidenced by no ventricular contraction.



(Left) Pulse-wave Doppler shows left ventricular inflow and outflow. After 3 normal beats, there is a PAC that is conducted and leads to a smaller ventricular ejection. There is then a delay (compensatory pause) before the next atrial contraction. (Right) Color M-mode demonstrates left ventricular inflow (blue) followed by ventricular outflow (red). There are 2 PACs shown; conduction of both is blocked, evidenced by the lack of subsequent ventricular outflow. Note the delay before subsequent beat.



TERMINOLOGY

Definitions

- Ectopic beat is extra beat arising prematurely from site other than heart's natural pacemaker
 - Extra beat can arise from anywhere (atrium or ventricle) within myocardium to produce irregular rhythm
- Bigeminy: Every other beat is ectopic
- Trigeminy: Every 3rd beat is ectopic
- Couplets (and Triplets): 2 (and 3) ectopic beats in a row
- Blocked beats: When atrial activity does not conduct to ventricles
 - When normal sinus beats are blocked, there is typically problem with atrioventricular (AV) node
 - When early atrial beats are blocked, there is typically no problem with AV node; usually variant of normal

IMAGING

Echocardiographic Findings

- M-mode
 - Cursor needs to be placed in position to allow atrial and ventricular activity to be recorded at same time
 - Ventricular activity can also be recorded by onset of semilunar valve opening (ventricular ejection)
- Pulsed Doppler
 - Doppler sample volume placed in left ventricular inflow and adjacent outflow
 - Demonstrates passive and active atrial filling in 1 direction and ventricular ejection in opposite direction
 - Doppler sampling in ascending aorta and superior vena cava or pulmonary artery and pulmonary vein
 - Normal flow reversal in vein (onset of atrial contraction) and onset of forward flow in artery (same direction) corresponds to ventricular ejection
 - Allows assessment of interval between atrial and ventricular (AV) contraction
 - **Premature atrial contraction (PAC)**
 - Early atrial contraction in cardiac cycle followed by ventricular contraction (conducted) or not (blocked)
 - Compensatory pause with reset of sinus node before sinus rhythm resumes
 - **Premature ventricular contraction (PVC)**
 - Early ventricular contraction in cardiac cycle occurring without prior atrial contraction
 - Noncompensatory pause, sinus node beats as if nothing happened

Imaging Recommendations

- Best imaging tool
 - Imaging in multiple planes and using multiple techniques is required to compare AV contraction
- Protocol advice
 - Determine rate, rhythm, and AV relationship
 - Widen pulse wave gate in order to capture all flow in both areas
 - Evaluate heart size and function
 - Most arrhythmias occur in setting of structurally normal heart, but one needs to look for congenital heart disease

DIFFERENTIAL DIAGNOSIS

Supraventricular Tachycardia

- 1:1 AV relationship
- Characteristic rate 220-280, may be intermittent

Atrial Flutter

- Atrial rates typically 300-500 beats per minute
- Variable AV block leads to irregular ventricular rate
 - If 2:1 block, then ventricular rate is regular

2nd-Degree Heart Block

- Type 1: Progressive increase in interval from atrial to ventricular contraction with eventual dropped beat
- Type 2: Atrial to ventricular conduction time is prolonged and constant with intermittent nonconduction to ventricles

PATHOLOGY

General Features

- Normal cardiac conduction tissue and impulse generation
 - Sinoatrial (SA) node (heart's pacemaker) typically located at top of right atrium and dictates heart rate
 - AV node is located near crux of heart, also on right side
 - AV node slows impulse from SA node and passes it on to ventricles via His-Purkinje system
 - Impulse passes from His bundles onto ventricles and causes ventricular systole
- Extra beats can arise from anywhere in myocardium, as all cells conduct electrical activity

CLINICAL ISSUES

Presentation

- Most common signs/symptoms
 - Abnormal heart rhythm noted on screening ultrasound or fetal heart rate check

Demographics

- Epidemiology
 - 1-2% of pregnancies will have arrhythmia
 - < 10% are significant
 - PACs/PVCs account for 90%
 - ◻ Most common in 3rd trimester
 - In fetus with frequent PACs
 - ◻ Congenital heart defects reported in up to 2% of cases
 - ◻ 2-5% risk of developing supraventricular tachycardia; higher if multiple beats are blocked

Natural History & Prognosis

- PACs and PVCs
 - Self-limited: Most resolve by time of delivery, extremely rare to cause problems in neonate

Treatment

- PACs/PVCs usually do not require treatment

SELECTED REFERENCES

1. Donofrio MT et al: Diagnosis and treatment of fetal cardiac disease: a scientific statement from the American Heart Association. *Circulation*. 129(21):2183-242, 2014
2. Sekarski N et al: Perinatal arrhythmias. *Eur J Pediatr*. 173(8):983-96, 2014

KEY FACTS

TERMINOLOGY

- Supraventricular tachycardia (SVT): Any tachycardia with its origin above ventricles; rates typically > 200
- Ventricular tachycardia: Ventricular rate exceeds atrial rate

IMAGING

- 2D echo in 4-chamber view to compare atrial and ventricular contraction
- Pulsed Doppler ± M-mode ± color
 - Allows assessment of interval between atrial and ventricular contraction

PATHOLOGY

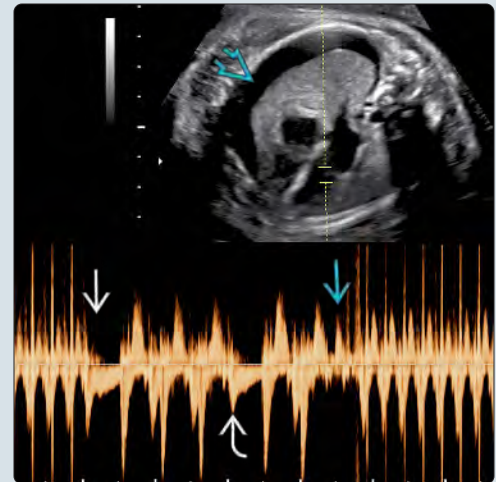
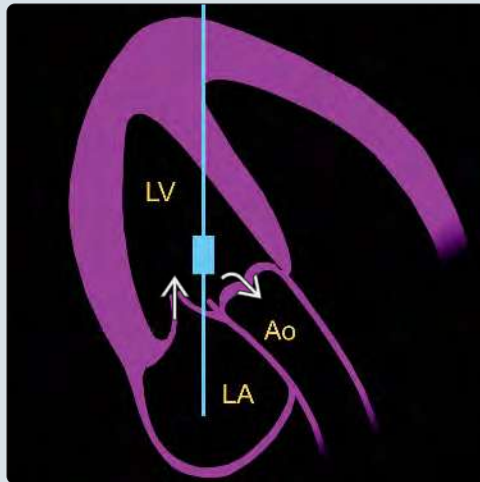
- AV reentry SVT (including Wolf-Parkinson-White)
 - Most common fetal tachyarrhythmia
 - Normal conduction through AV node from atria to ventricle
 - Accessory pathway conducts ventricular impulse back to atria

- AV node is recovered from refractory state and conducts impulse again, setting up circuit
- Atrial flutter
 - Single reentry circuit within atrium, which is very fast
 - Variable AV block but often 2:1

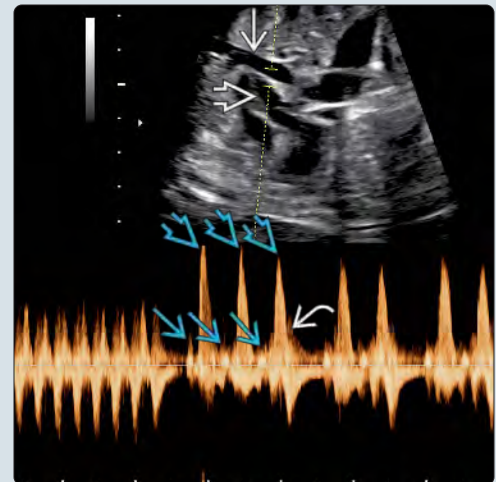
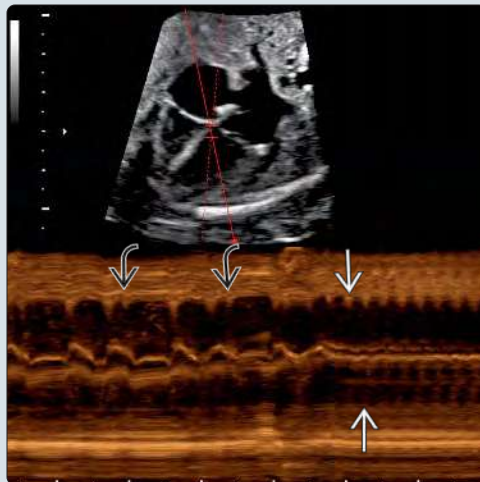
CLINICAL ISSUES

- Fetal arrhythmia seen in 1-2% of pregnancies have arrhythmia
 - Only ~ 10% clinically significant
- Prognosis generally good for intermittent SVT and SVT without hydrops
- Hydrops develops in 50-75% of fetuses with sustained tachyarrhythmia
 - When present, treatment is more complicated and urgent
 - Harder to achieve therapeutic levels of medication and therefore cardioversion

(Left) Graphic shows Doppler cursor position for evaluation of arrhythmias. Flow during an atrial contraction is toward the transducer, while flow during a ventricular contraction is away from the transducer. (Right) Doppler interrogation of left ventricle inflow and outflow shows both termination and restarting of the tachycardia with atrial ectopy in between. There is also a large pleural effusion in this fetus who has developed hydrops.



(Left) M-mode interrogation through the right atrium and left ventricle shows frequent premature atrial contractions (PACs), which eventually trigger supraventricular tachycardia (SVT) with 1:1 conduction. (Right) Doppler interrogation through the superior vena cava (SVC) and aorta shows SVT, which breaks and starts normal sinus rhythm (noted by atrial contraction in the SVC) and ventricular contraction in the aorta for 3 beats followed by a blocked PAC.



TERMINOLOGY**Definitions**

- Supraventricular tachycardia (SVT)
 - Any tachycardia with its origin above ventricles
 - Rates typically > 200
 - May have 1:1 atrioventricular (AV) conduction or variable degree of heart block (e.g., 2:1)
 - Types
 - Automatic rhythms
 - Sinus tachycardia
 - Atrial ectopic tachycardia
 - Reentrant rhythms
 - AV reentry
 - Atrial flutter
- Ventricular tachycardia
 - Ventricular rate exceeds atrial rate

IMAGING**General Features**

- Best diagnostic clue
 - Sustained fast heart rate > 200 BPM
 - No heart rate variability with reentrant forms except if AV block is present in flutter
 - M-mode tracing or pulsed Doppler must be performed to determine type of arrhythmia
 - Determine "mechanical intervals" in absence of ECG tracing

Echocardiographic Findings

- M-mode
 - Place M-mode cursor to include both atrium and ventricle
 - Evaluate atrial and ventricular rates
 - May also use color M-mode to assess ventricular inflow and outflow, similar to pulse Doppler
- Pulsed Doppler
 - Doppler sampling in left ventricle at junction of mitral valve and left ventricular outflow tract
 - Mitral inflow = atrial rate in one direction
 - Left ventricular outflow = ventricular rate in opposite direction
 - Doppler sampling in ascending aorta and superior vena cava (SVC) or pulmonary artery and pulmonary vein (PV)
 - Flow reversal in vein (SVC) or flow cessation (PV) = onset of atrial contraction
 - Antegrade flow in artery = ventricular ejection
 - Doppler flow will be in same direction
 - Allows assessment of interval between atrial and ventricular contraction
 - PR interval and VA time (time from ventricle back to atria)
- Color Doppler
 - Useful to document AV valve regurgitation

Imaging Recommendations

- Best imaging tool
 - 2D echo in 4-chamber view to compare atrial and ventricular contraction
 - Pulsed Doppler ± M-mode ± color

- If available, fetal magnetocardiography can be very helpful
- Most tachycardias occur in setting of normal heart, but check for congenital heart disease
- Evaluate heart size and function
 - Track size by measuring heart:chest circumference ratio
 - Track function subjectively or with ventricular ejection fraction, keeping in mind degree of AV valve regurgitation
- Assess fetal well being
 - Look for presence of hydrops
 - Look for signs of hemodynamic decompensation
 - Look for changes in inferior vena cava, ductus venosus, and umbilical vein flow
 - Perform biophysical profile

DIFFERENTIAL DIAGNOSIS**Sinus Tachycardia**

- 1:1 AV relationship
- Characteristic rate up to 180 but may be higher

Atrial Ectopic Tachycardia

- 1:1 AV relationship
- Persistent variable rates of 180-220

AV Reentry

- **Most common fetal tachyarrhythmia**
- Commonly just called SVT despite term not being specific
- 1:1 AV relationship
 - Characteristic rate 230-280 BPM, may be intermittent

Junctional Ectopic Tachycardia

- 1:1 AV relationship with rate typically 160-210 and nonsustained
- Commonly associated with SSA/Ro antibodies and reported with heart block
- Relatively rare with therapy directed at underlying cause

Atrial Flutter

- Atrial rate > ventricular rate
 - Atrial rate 300-500 BPM, regular
- Variable AV conduction (may be 2:1, 3:1, or vary during exam)

Ventricular Tachycardia

- Ventricular rate > atrial rate
 - No characteristic rate, AV dissociation
 - 170-400 BPM recorded
- Rare in fetus

PATHOLOGY**General Features**

- Etiology
 - **Sinus tachycardia**
 - Normal but fast rate due to maternal conditions like thyrotoxicosis, fever, sepsis, or drugs
 - **Atrial ectopic tachycardia**
 - Abnormal focus of cells distinct from sinus node in atria, which depolarize faster
 - Can be incessant with rate increasing or decreasing depending on sympathetic tone

- **AV reentry SVT (including Wolf-Parkinson-White)**
 - Normal conduction through AV node from atria to ventricle
 - Accessory pathway conducts ventricular impulse back to atria
 - AV node is recovered from refractory state and conducts impulse again, setting up circuit
- **Atrial flutter**
 - Single reentry circuit within atrium, which is very fast
 - Variable AV block but often 2:1
- **Ventricular tachycardia**
 - Focus present in ventricles causing tachycardia, which is usually paroxysmal
 - Observed in association with AV block, and when these coexist, long QT syndrome is likely
- **Genetics**
 - Sporadic
 - Few familial preexcitation syndromes
- **Physiology**
 - Ventricular rates > 230 BPM → ↑ fetal central venous pressure
 - ↑ venous pressure → flow reversal in inferior vena cava
 - Short diastole → ↓ myocardial perfusion
 - Ischemic ventricles dilate → AV valve regurgitation
 - AV regurgitation → further increase in venous pressures/hepatic congestion
 - End result is heart failure/hydrops
- Recent reports indicate concern for ischemic brain injury in association with hydrops

Treatment

- Multidisciplinary team approach most effective
- Delivery may be simplest treatment option if gestational age allows
- **Sinus tachycardia**
 - Does not require treatment; rather, careful observation and evaluation for etiology
- **Intermittent AV reentry SVT**
 - Careful conservative management
 - Patient follow-up is key, as persistent SVT with hydrops may develop within 24 hours
 - Spontaneous resolution possible
- **Persistent AV reentry SVT without hemodynamic decompensation**
 - Digoxin monotherapy, 60% successful conversion of SVT
 - Monitor maternal serum levels
 - Recommend flecainide as 2nd-line therapy
- **Persistent AV reentry SVT with hemodynamic decompensation (hydrops)**
 - Unlikely to convert with digoxin monotherapy due to lower blood levels
 - Requires additional medications or direct therapy to achieve success rate of 65%
 - Flecainide: Potential fast response, may cause maternal proarrhythmia
 - Amiodarone: May be successful 3rd line, but there are case reports of neonatal hypothyroidism
- **Atrial flutter**
 - Digoxin monotherapy is successful in 45-55% of nonhydropic fetuses
 - Recommend sotalol alone or in combination with digoxin in hydropic fetus
 - Fetal levels near 100% maternal levels
 - Concern for proarrhythmic effects in mother and fetus

CLINICAL ISSUES

Presentation

- Abnormal fetal heart rate noted on physical examination
- Most reported cases present in 3rd trimester
 - Range: 18-42 weeks

Demographics

- **Epidemiology**
 - Fetal arrhythmia seen in 1-2% of pregnancies have arrhythmia
 - Only ~ 10% clinically significant
 - Of fetuses with tachyarrhythmia
 - AV reentry SVT in 65-93%
 - Atrial flutter in 7-29%
 - Ventricular tachycardia in < 4%
 - 2-5% of fetuses with premature atrial contractions will develop SVT

Natural History & Prognosis

- Postnatal cardiac evaluation required for all
- Arrhythmias can recur/persist in neonatal period
 - 48% in 1 series of fetuses with atrial flutter/SVT
 - 8-10% of fetuses with SVT will be diagnosed with Wolf-Parkinson-White syndrome
- Prognosis generally good for intermittent SVT
- Hydrops present or develops in 50-75% of fetuses with sustained tachyarrhythmia
 - Complicates treatment
 - Harder to achieve therapeutic levels of medication
- Overall fetal demise ~ 10%
 - Worse with hydrops

DIAGNOSTIC CHECKLIST

Consider

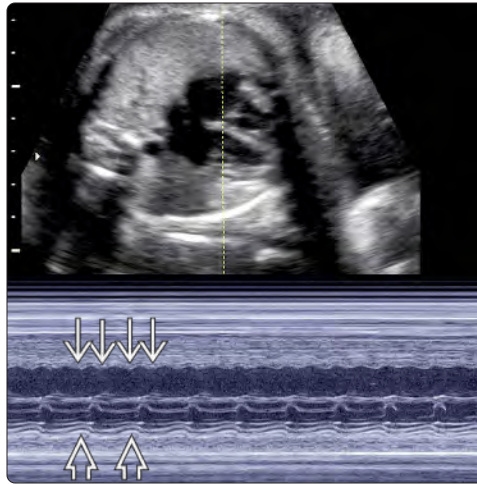
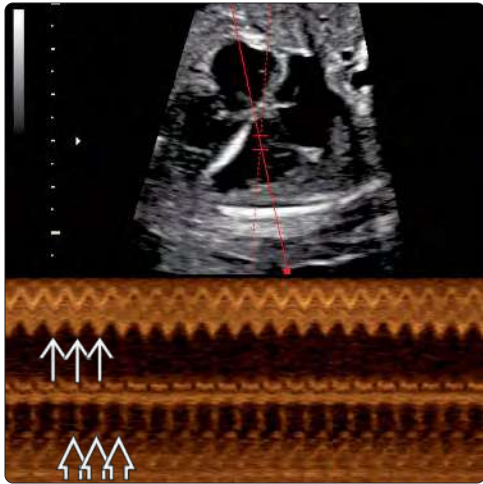
- Formal fetal echocardiogram
 - Look for associated structural disease
 - Assess baseline function
 - Look for signs of hydrops





Image Interpretation Pearls

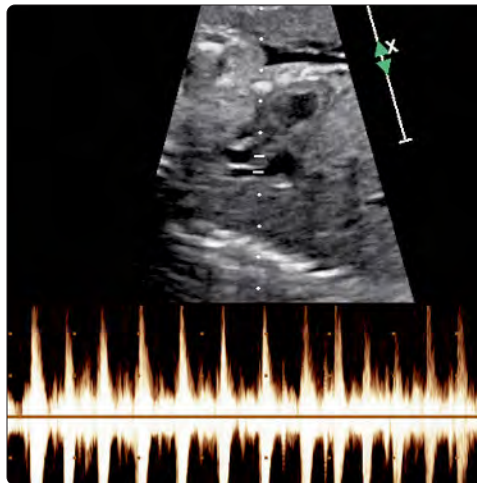
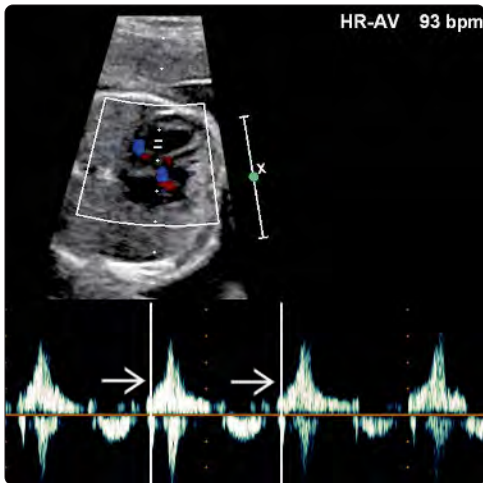
- Vital to differentiate types of tachyarrhythmia due to different therapies


SELECTED REFERENCES

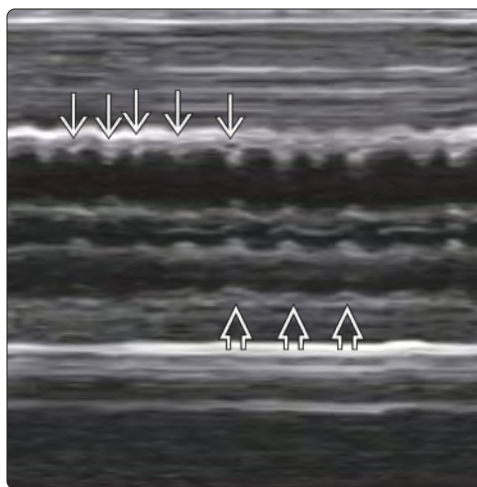
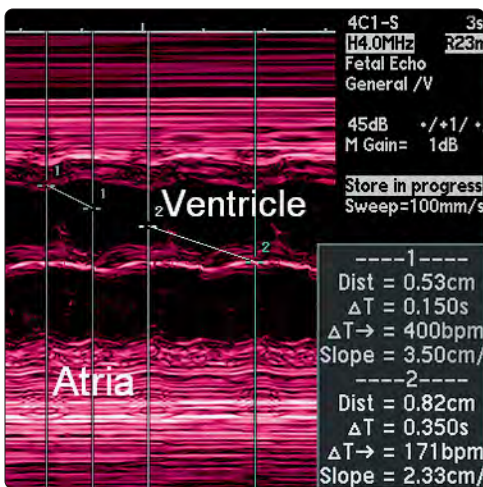
1. Jaeggi E et al: Fetal and neonatal arrhythmias. *Clin Perinatol.* 43(1):99-112, 2016
2. Donofrio MT et al: Diagnosis and treatment of fetal cardiac disease: a scientific statement from the American Heart Association. *Circulation.* 129(21):2183-242, 2014
3. Wacker-Gussmann A et al: Diagnosis and treatment of fetal arrhythmia. *Am J Perinatol.* 31(7):617-28, 2014
4. Jaeggi ET et al: Comparison of transplacental treatment of fetal supraventricular tachyarrhythmias with digoxin, flecainide, and sotalol: results of a nonrandomized multicenter study. *Circulation.* 124(16):1747-54, 2011





(Left) M-mode cursor is placed to bisect the right atrium and left ventricle. One can see atrial  and ventricular  contractions occurring in a 1:1 pattern. The rate was 250 and consistent with a reentry form of SVT. (Right) M-mode cursor again is placed to bisect the right atrium and left ventricle. The atrial  contractions here are at a rate of 450 with the ventricular  contractions at a rate of 225, consistent with atrial flutter with 2:1 atrioventricular (AV) block.



(Left) Image shows a patient who at the start of the study had what seemed like sinus bradycardia. Noted here is a mitral inflow  pattern with a heart rate of 93. (Right) Pulsed Doppler in the same patient later in the study showed SVT with 1:1 conduction at a rate of 215. Doppler was placed in the ascending aorta and SVC. Periods of 2:1 AV block were also seen. These findings are consistent with a fetus who has long QT syndrome. Unfortunately, this fetus died in utero.



(Left) M-mode echocardiogram shows an atrial rate (400 BPM) roughly 2x the ventricular rate (171 BPM). This patient had atrial flutter with 2:1 AV block. (Right) M-mode echocardiography shows a highly variable atrial rate , ranging from 150-390. Note the ventricular rate  does not seem to vary. This can be seen with atrial fibrillation or multifocal atrial tachycardia.

KEY FACTS

TERMINOLOGY

- Abnormally slow heart rate < 100 beats per minute (BPM)
- Benign transient bradycardia
 - Due to vagal stimulation; often from transducer pressure
 - Quickly returns to normal rate with release of pressure
- Complete heart block (CHB)
 - Due to failed conduction from atrium to ventricle
- Blocked premature atrial contractions (PAC)
 - Early atrial beat not followed by ventricular beat

IMAGING

- M-mode for AV correlation and rates
- Pulsed Doppler to assess mechanical PR interval
 - Doppler sampling placed in left ventricular inflow and outflow, ascending aorta and SVC or PA and PV

PATHOLOGY

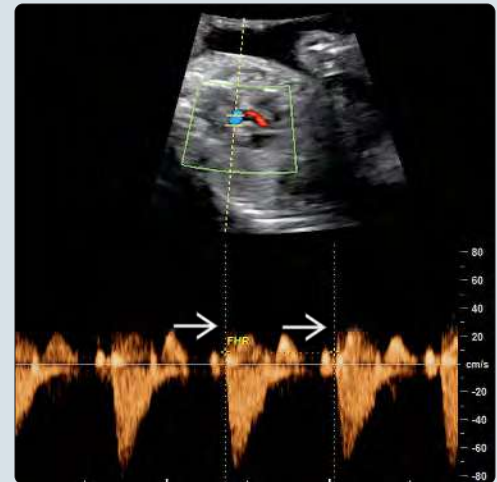
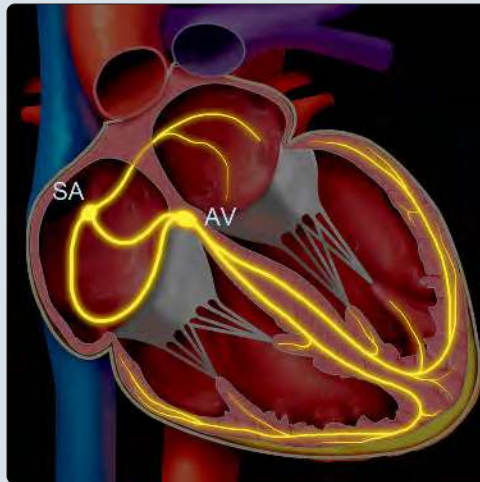
- 50% associated with cardiac malformation, particularly left atrial appendage isomerism (heterotaxy)

- CHB without heart disease
 - 50% of cases in mothers with connective tissue disease
 - Anti-SSA/Ro ± anti-SSB/La antibodies start crossing placenta at 16 weeks
 - Fetal/neonatal myocardium contains body's highest concentration of Ro antigen
 - Maternal antibody binds to fetal antigen causing inflammation/fibrosis of fetal heart conduction system

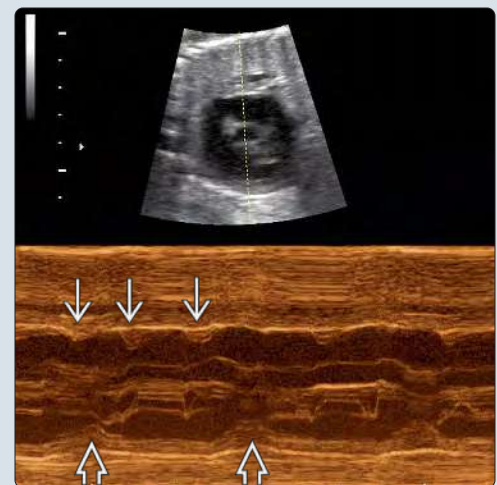
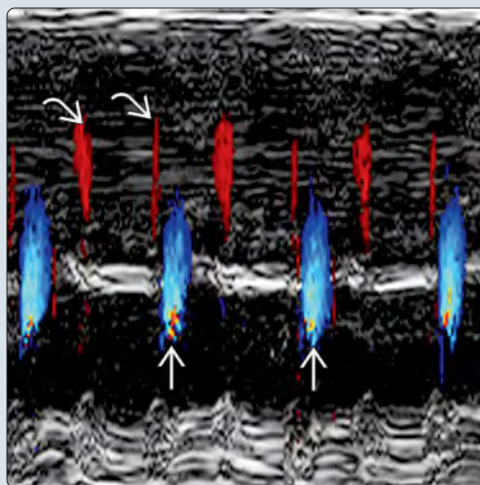
CLINICAL ISSUES

- 1st-trimester bradycardia associated with high pregnancy failure rate
- Risk of fetal CHB with maternal lupus up to 5%
- Recurrence risk up to 20% in mother with anti-Ro/La antibodies and previous child with CHB
- Normal structure/no hydrops → 90% survival
- Poor prognosis with structural abnormality
- Increased mortality with heart rate < 50 BPM

(Left) Graphic shows a representation of the conduction system. The sinoatrial (SA) node provides the sinus, or atrial beat. Conduction moves to the atrioventricular (AV) node, which allows conduction through the septum and to the ventricles. (Right) Image shows a patient with sinus bradycardia at a rate of 89 beats per minute. The markings are at the onset of aortic outflow giving the ventricular rate.



(Left) M-mode ultrasound with color enhancement (red = ventricular inflow and blue = outflow) shows 2nd-degree heart block. There is a 2:1 block with 2 atrial contractions for each ventricular contraction. (Right) Image shows the M-mode cursor through the atrium, aortic valve, and right ventricle. The tracing then shows multiple atrial contractions and infrequent ventricular contractions, which are dissociated with each other, consistent with complete heart block.



TERMINOLOGY

Definitions

- Abnormally slow heart rate < 100 beats per minute (BPM)
- **Benign transient bradycardia**
 - Slowing of fetal heart rate followed by rapid and progressive recovery
 - Due to vagal stimulation
- **Sinus or low atrial bradycardia**
 - Typical rates 90-130 BPM
 - Atrioventricular (AV) conduction intact
- **1st-degree AV block**
 - Long PR interval but maintained 1:1 AV conduction
- **2nd-degree AV block**
 - Long PR interval with intermittent AV conduction and AV block
- **Complete heart block (CHB)**
 - Atrial rate normal
 - Slow independent ventricular rate (40-90 BPM)
 - Due to failed conduction from atrium to ventricle
- **Blocked premature atrial contractions (PAC)**
 - Early atrial beat not followed by ventricular beat

IMAGING

General Features

- Cardiac anatomy normal in 50%
- Structural defects present in 50%

Echocardiographic Findings

- M-mode
 - Place M-mode line to include both atrium and ventricle
 - Evaluate atrial and ventricular rates
 - Ventricular activity can also be recorded by onset of semilunar valve opening (ventricular ejection)
 - If 2 M-mode lines are possible, 1 can be placed in atria and other in ventricle to establish rates in each
- Pulsed Doppler
 - Doppler sampling placed in left ventricular inflow and adjacent outflow
 - Mitral inflow = atrial rate in 1 direction
 - Left ventricular outflow = ventricular rate in opposite direction
 - Doppler sampling in ascending aorta and superior vena cava (SVC) or pulmonary artery (PA) and pulmonary vein (PV)
 - Flow reversal in SVC or cessation of flow in PV = onset of atrial contraction
 - Antegrade flow in aorta or PA = ventricular ejection
 - Allows assessment of interval between atrial and ventricular contraction (mechanical PR interval)

Imaging Recommendations

- Best imaging tool
 - 2D echo in 4-chamber view to compare atrial and ventricular contraction
 - M-mode showing AV correlation and rates
 - Pulsed Doppler to assess mechanical PR interval
- Protocol advice
 - Is heart rate < 100?
 - Assess if transient or persistent, regular, or irregular

- Check for signs of fetal distress
- If stable, determine rate, atrioventricular relationship, and PR interval
- Look for structural defects commonly seen in fetuses with CHB
 - Atrioventricular septal defect
 - Atrioventricular discordance
 - Heterotaxy syndromes
- Assess myocardial function
- Assess fetal well-being, monitor growth
- Assess heart size (cardiomegaly)
 - Track by measuring heart circumference:chest circumference
- Look for signs of hemodynamic decompensation
 - Significant atrioventricular valve regurgitation
 - Reversal of flow in vena cava
 - Reversal of flow in ductus venosus
 - Umbilical vein pulsation
- Look for signs of hydrops
- Use umbilical artery Doppler to monitor placental vascular resistance
 - ↑ risk of placental insufficiency
 - Increasing placental resistance may precipitate hydrops without further decrease in heart rate

DIFFERENTIAL DIAGNOSIS

Benign Transient Bradycardia

- May be caused by transducer pressure on fetus or cord
- Heart rate quickly returns to normal with release of transducer pressure

Sinus or Atrial Bradycardia

- Sinus node dysfunction
- Long QT syndrome
- Fetal distress

Partial Atrioventricular Block

- 1st-degree heart block
 - Unlikely to be picked up and considered a variant of normal but may be precursor to higher degrees of heart block
- 2nd-degree heart block
 - Type 1: Progressive increase in PR interval with eventual dropped beat
 - Type 2: PR interval is prolonged and constant with intermittent nonconducted beats
 - Can also be secondary to long QT syndrome

Complete Heart Block

- Independent, disassociated atrial and ventricular contractions
- Rhythm can be regular or irregular depending on presence of PVCs

Blocked Premature Atrial Contractions

- Intermittent, early atrial beat without conduction to ventricle
- Not indication of disease or abnormality of conduction tissue
- Rhythm can be regular or irregular depending on frequency of blocked beats

PATHOLOGY**General Features**

- Etiology
 - 50% CHB associated with cardiac malformation, particularly left atrial appendage isomerism (heterotaxy)
 - 50% CHB in mothers with autoimmune disease
 - Anti-SSA/Ro ± anti-SSB/La antibodies start crossing placenta at 16 weeks
 - Fetal/neonatal myocardium contains body's highest concentration of Ro antigen
 - Maternal antibody binds to fetal antigen
 - Inflammation/fibrosis of fetal heart conduction system and myocardium
 - Another, as yet unknown, cofactor may also be present
 - Majority of mothers with anti-SSA/Ro and anti-SSB/La antibodies have normal pregnancies
 - Trigger to fetal cardiac damage may be viral exposure
 - Mothers of fetuses with CHB have increased frequency of antibodies to cytomegalovirus
- Physiology
 - Heart rate < 100 BPM → may cause progressive ventricular dilation
 - Ventricular dilation → distortion of atrioventricular valve ring
 - Tricuspid regurgitation → increased right atrial pressure
 - Venous hypertension → hepatic congestion, ascites, effusions, and edema (hydrops)
- Usually resolves by 6 months as antibodies clear from infant circulation
- Syndrome resolves, but damage to conducting system is permanent
- Some series show significant incidence of progression to dilated cardiomyopathy in children with heart block
 - Survivors require close follow-up with cardiology
- Recurrence risk
 - Up to 20% in mother with anti-Ro/La antibodies and previous child with CHB
 - 25-64% if previous child with neonatal lupus manifesting CHB

Treatment

- Maternal evaluation by rheumatologist
 - Positive antibody screen in 90% of mothers with CHB fetuses and normal cardiac structure
- Treatment aim
 - Dampen fetal inflammatory response
 - Limited efficacy using steroids, plasmapheresis, and intravenous immunoglobulin
 - Increase fetal heart rate
 - β agonists (e.g., terbutaline)
 - Poor maternal tolerance at dose sufficient to increase fetal heart rate
 - Effect also seems to be transient
 - Fetal cardiac pacing has been achieved but does not prevent fetal demise
- Consider cesarean delivery
 - Stress of vaginal delivery may lead to acute decompensation
 - Intrapartum monitoring extremely difficult due to bradycardia
- Deliver at tertiary center with cardiology support
 - Temporary cardiac pacing may be urgent need for survival
 - Permanent cardiac pacing required for definitive treatment

CLINICAL ISSUES**Presentation**

- Bradycardia noted on routine exam
 - Transient suggests conduction tissue is normal
 - Persistent suggests conduction tissue is not normal

Demographics

- Epidemiology
 - CHB 1:20,000 live births
 - Fetal incidence likely higher due to loss rate in association with heterotaxy syndromes
 - CHB accounts for 9% of all fetal arrhythmias
 - Risk of fetal CHB with maternal lupus up to 5%
 - Risk of fetal CHB for antibody-positive mother ≤ 2%

Natural History & Prognosis

- 1st-trimester bradycardia associated with high pregnancy failure rate
 - Survivors likely to have structural disease, especially heterotaxy syndromes
- Increased mortality with heart rate < 50 BPM
 - 15-25% will develop hydrops
 - Intrauterine fetal demise ~ 75%
- Poor prognosis with structural abnormality
 - Survival < 15%
- Normal structure/no hydrops → 90% survival
- In at-risk pregnancy, monitor fetal PR interval
 - Prolongation may be 1st sign of immune-mediated disease
- If bradycardia due to maternal antibodies, significant risk for neonatal lupus syndrome

DIAGNOSTIC CHECKLIST**Consider**

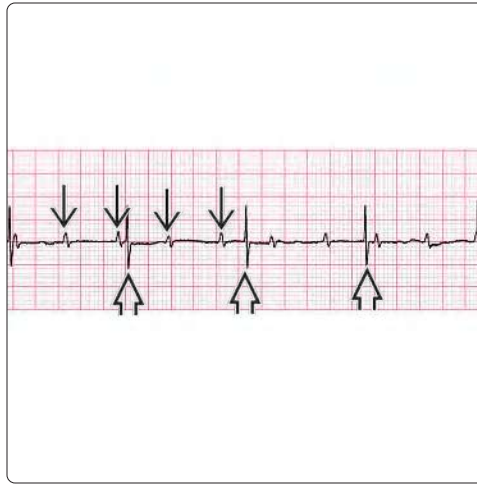
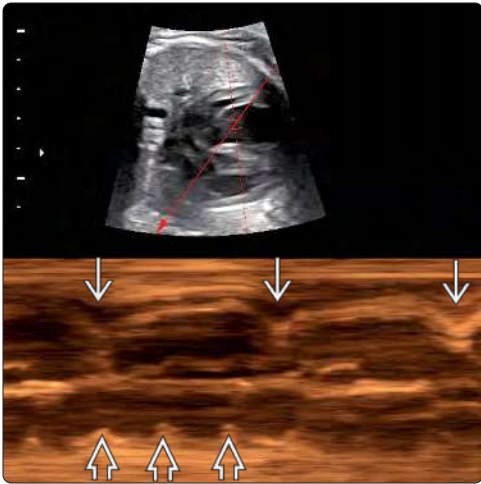
- Formal fetal echocardiography
 - Look for associated structural disease
 - Assess baseline function
 - Look for signs of hydrops
- Goal is to identify cause as that impacts therapy and prognosis

Image Interpretation Pearls

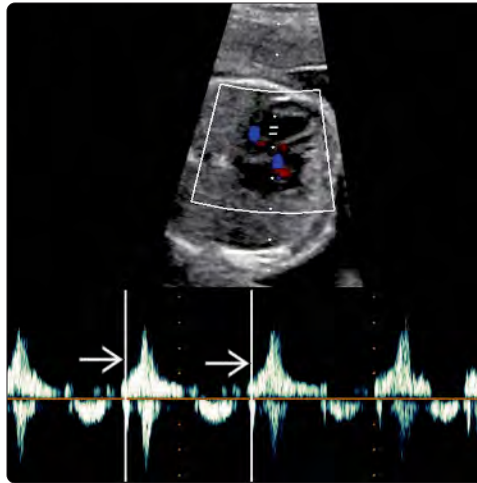

- Bradycardia with structural malformation confers poor prognosis
- Fetus with CHB may be 1st presentation of maternal autoimmune disease

SELECTED REFERENCES

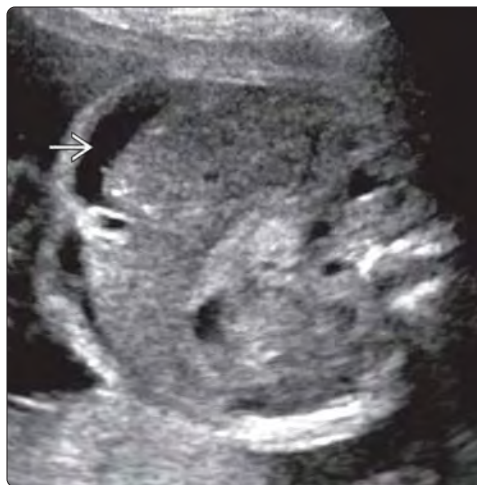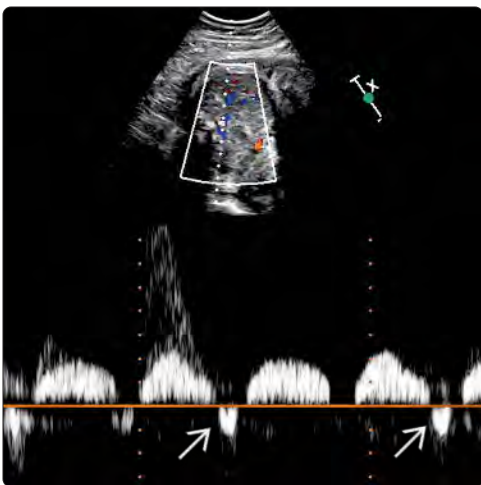
1. Hunter LE et al: Atrioventricular block during fetal life. *J Saudi Heart Assoc.* 27(3):164-78, 2015
2. Mitchell JL et al: Fetal heart rate predictors of long QT syndrome. *Circulation.* 126(23):2688-95, 2012
3. Friedman DM et al: Utility of cardiac monitoring in fetuses at risk for congenital heart block: the PR Interval and Dexamethasone Evaluation (PRIDE) prospective study. *Circulation.* 117(4):485-93, 2008



(Left) Image shows an M-mode line going through anterior ventricle and posterior atrium. The ventricular rate is slow and the atrial rate is more normal, but again, there is complete dissociation in this patient with complete heart block. (Right) Postnatal EKG shows complete heart block with P waves (atrial contraction) marching along with no variation at 140 bpm. There is complete dissociation from the QRS complex (ventricular contraction), which is marching along with no variation at 60 bpm.



(Left) M-mode echocardiography shows a patient with a 2nd-degree heart block type 2 with every other beat not being conducted. This could also be the appearance of blocked premature atrial contractions, but the pattern would eventually change during scanning back to sinus rhythm. (Right) Pulsed Doppler echocardiography shows left ventricular inflow above the baseline in a patient with sinus bradycardia. This was transient.



(Left) Pulsed Doppler ultrasound shows reversal of flow in the ductus venosus with flow below the baseline during atrial systole. This signifies significant elevation of right atrial pressure in this patient with heart block and hydrops. (Right) Ultrasound shows ascites in this fetus with complete heart block and hydrops. This combination typically has a poor prognosis with limited options for treatment.

DIFFERENTIAL DIAGNOSIS**Common**

- **Chest Mass**
 - Congenital Diaphragmatic Hernia
 - Congenital Pulmonary Airway Malformation
 - Bronchopulmonary Sequestration
 - Pleural Effusion
 - Teratoma
- **Cardiac Causes**
 - Chamber Asymmetry
 - Conotruncal Malformation
 - Heterotaxy, Cardiosplenic Syndromes

Less Common

- Pulmonary Agenesis

Rare but Important

- Ectopia Cordis

ESSENTIAL INFORMATION**Key Differential Diagnosis Issues**

- Important to have systematic approach
- In all OB scans, check fetal orientation
 - Which is fetal anatomic left and right?
- Check position of stomach
- Check position of cardiac apex
- Stomach and cardiac apex should both be on left
 - If both on right, likely complete situs inversus with good prognosis
 - If opposite sides, likely heterotaxy syndrome
 - Strong association with complex congenital heart disease (CHD)
 - Left atrial appendage isomerism
 - Common atrium/atrial septal defect in 80%
 - Interrupted inferior vena cava (IVC) in > 70%
 - Right atrial appendage isomerism
 - Total anomalous pulmonary venous return 50-70%
 - Conotruncal abnormalities in 80%
- 4-chamber view is axial image through chest
 - Ribs should be symmetric and C-shaped
- Normal cardiac axis is 35-45° in 2nd trimester
 - Draw line from spine to sternum
 - Draw line along axis of interventricular septum
- 1st-trimester cardiac axis measurement useful for early detection of CHD
 - Mean cardiac axis was $44.5 \pm 7.4^\circ$ between 11 weeks 0 days and 14 weeks 6 days in study published in 2015
 - Previous study found mean axis $47.6 \pm 5.6^\circ$ standard deviation
 - Noted axis higher from 11 weeks 0 days to 11 weeks 6 days than from 12 weeks 0 days to 14 weeks 6 days
 - Cardiac axis was abnormal in 2/3 of 197 fetuses with CHD
 - Abnormal axis defined as $> 97.5^{\text{th}}$ or $< 2.5^{\text{th}}$ percentile or nonidentifiable
 - Performed better than nuchal translucency, tricuspid regurgitation, or reversed ductus venosus A-wave used alone or in combination for detection of CHD
 - Consider checking cardiac axis at time of nuchal translucency screening
- If axis is abnormal
 - Does heart appear displaced within thorax?
 - May be "pushed" to one side by mass, large pleural effusion
 - May be "pulled" to one side if lung small or absent
 - May be pushed inferiorly if mediastinal mass
 - Ectopia cordis implies heart situated outside thorax
 - Intraabdominal
 - Extrathoracic
 - Is internal cardiac structure normal?
 - Normal right and left atria
 - Normal right and left ventricles
 - Normal outflow tracts crossing as they exit heart
 - Atrioventricular concordance
 - Ventriculoarterial concordance

Helpful Clues for Common Diagnoses

- **Congenital Diaphragmatic Hernia**
 - Stomach/intestine \pm liver in chest
 - Heart displaced away from side of hernia
 - In bilateral hernias, there may be minimal cardiac shift
 - Look for peristalsis within chest
 - Look for "bucket handle" motion of diaphragm on coronal view
 - Use color Doppler to look at liver vessels
 - Strong association with aneuploidy
 - Liver-up hernias have worse prognosis
- **Congenital Pulmonary Airway Malformation**
 - Chest mass with perfusion from pulmonary artery branches
 - May be uniformly echogenic to multicystic
 - Macrocystic: ≥ 1 cyst of > 5 mm in diameter
 - May have 1 large cyst
 - Microcystic: Looks like echogenic, solid mass as multiple tiny cysts
 - Heart displaced away from mass
 - Right side = left side
- **Bronchopulmonary Sequestration**
 - Echogenic mass with perfusion from aorta
 - Usually on left, with cardiac shift to right side
 - Rare association with tension hydrothorax
- **Pleural Effusion**
 - Large solitary effusion may displace heart
 - Look for floating lung
 - Differentiate from pericardial effusion
 - Surrounds heart, displaces lung posteriorly
- **Teratoma**
 - Complex cystic/solid mass \pm calcifications
 - Mediastinal teratoma may extend into neck
- **Chamber Asymmetry**
 - Which chamber is abnormal?
 - Is it single ventricle heart [e.g., unbalanced atrioventricular septal defect (AVSD)]?
 - **Right Heart Enlargement**
 - Shunt lesions with increased venous return
 - Check for vascular malformation, vascular tumor
 - Incipient hydrops
 - Severe placental insufficiency

- Left heart outflow obstruction
- o **Small Right Ventricle**
 - Pulmonary atresia (PA)/stenosis
 - Right ventricle can also be normal in size especially if ventricular septal defect (VSD) is present
 - Left-dominant, unbalanced AVSD
- o **Small Left Ventricle**
 - Hypoplastic left heart syndrome
 - May see dilated, poorly functioning echogenic left ventricle with endocardial fibroelastosis
 - Right dominant unbalanced AVSD
- o **Large Right Atrium**
 - Ebstein anomaly
 - Tricuspid dysplasia
 - Pulmonary stenosis/atresia
- **Conotruncal Malformation**
 - o 4-chamber view often shows normal chambers
 - o Look at outflow tracts in every case
 - Single outflow: Truncus most likely if normal sized ventricles and VSD present
 - Parallel outflow tracts: Transposition of great arteries or double outlet right ventricle
 - Large aorta overriding VSD with separate, small PA: Tetralogy of Fallot
- **Heterotaxy, Cardiosplenic Syndromes**
 - o Check situs in every OB scan: Cardiac apex and stomach should be on left side
 - o Look for interrupted IVC with azygous continuation to superior vena cava
 - Vessel located posterior to aorta at level of diaphragm
 - Will see 2 similarly sized vessels behind left atrium on 4-chamber view
 - o Look for transverse, midline liver
 - o Complex CHD
 - Often AV septal defect
 - Often single ventricle
 - Often abnormal outflow tracts
 - Systemic and pulmonary venous abnormalities
 - Look for twig sign of anomalous pulmonary veins behind left atrium

Helpful Clues for Less Common Diagnoses

- **Pulmonary Agenesis**
 - o Heart displaced to chest wall on side of missing lung
 - o Diaphragm elevated but present on side of missing lung
 - o No evidence of diaphragmatic hernia or lung mass "pushing" heart
 - o Look for associated vertebral anomalies or CHD
 - o Look for other features of VACTERL association

Helpful Clues for Rare Diagnoses

- **Ectopia Cordis**
 - o Heart in abnormal location: Extrathoracic or intraabdominal
 - o Look for amniotic bands if exterior to thorax
 - o Pentalogy of Cantrell
 - Anterior diaphragmatic hernia
 - Midline abdominal wall defect
 - Cardiac anomalies
 - Defect of diaphragmatic pericardium
 - Low sternal defect

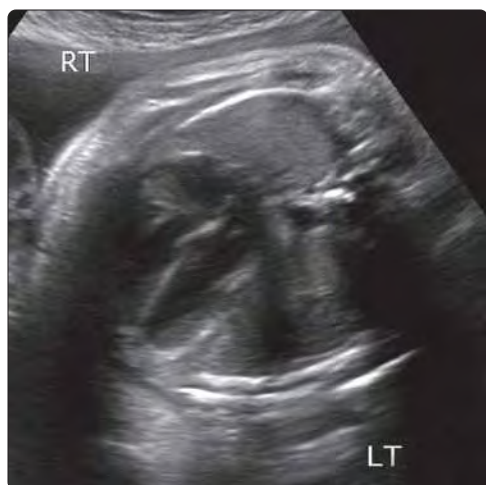Other Essential Information

- Prognosis in heterotaxy syndromes depends on complexity of cardiac disease
 - o Association with complete heart block almost uniformly fatal
- Prognosis in diaphragmatic hernia depends on liver position and presence of cardiac defects
 - o Liver-up or complex cardiac anomaly confers worse prognosis

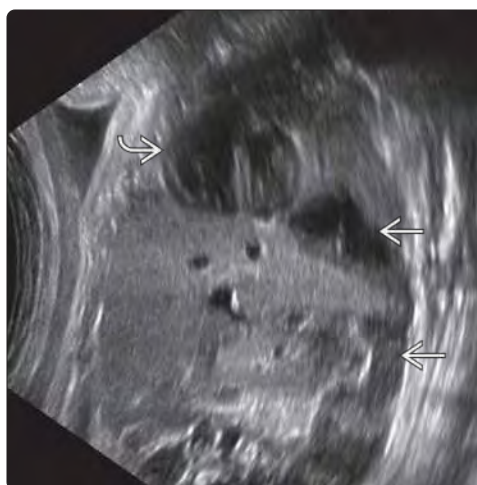
SELECTED REFERENCES

1. Sinkovskaya ES et al: Fetal cardiac axis and congenital heart defects in early gestation. *Obstet Gynecol.* 125(2):453-60, 2015
2. Sinkovskaya E et al: Defining the fetal cardiac axis between 11 + 0 and 14 + 6 weeks of gestation: experience with 100 consecutive pregnancies. *Ultrasound Obstet Gynecol.* 36(6):676-81, 2010

Congenital Diaphragmatic Hernia



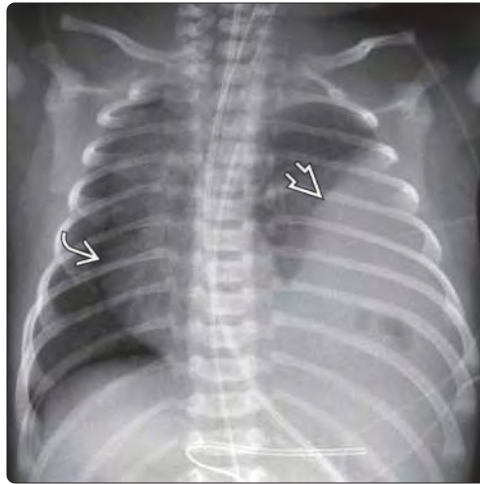
Congenital Diaphragmatic Hernia



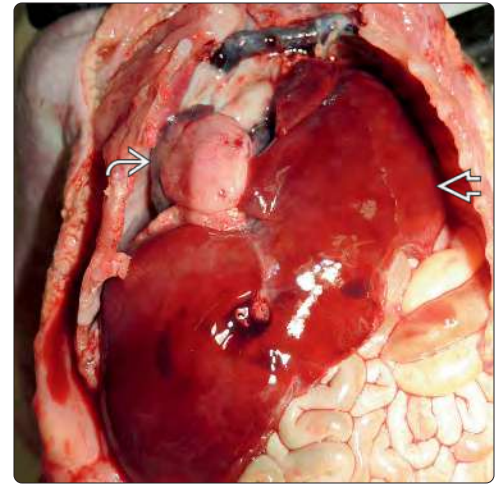
(Left) Axial US of the chest shows subtle cardiac displacement to the right. The patient had been sent for fetal echo, and as the heart was structurally normal, it was assumed that there was no significant problem. Remember, if the heart is not in the right place, it is either being pushed or pulled. (Right) Coronal US of the same patient shows the colon in the left hemithorax, indicating a left diaphragmatic hernia and explaining why the heart is pushed to the right. The hoped-for home delivery was changed to hospital based.

Congenital Diaphragmatic Hernia

(Left) Frontal chest radiograph in a newborn shows the heart displaced toward the right chest wall by a left, liver-up, diaphragmatic hernia. This delivery was planned with a multidisciplinary team and the infant did well after surgery. (Right) Autopsy photograph shows a left liver-up diaphragmatic hernia. Almost 1/2 of the liver was in the left hemithorax, the heart was displaced, and there was almost no measurable lung. Liver-up hernias have a worse prognosis than those where the liver remains in the abdomen.

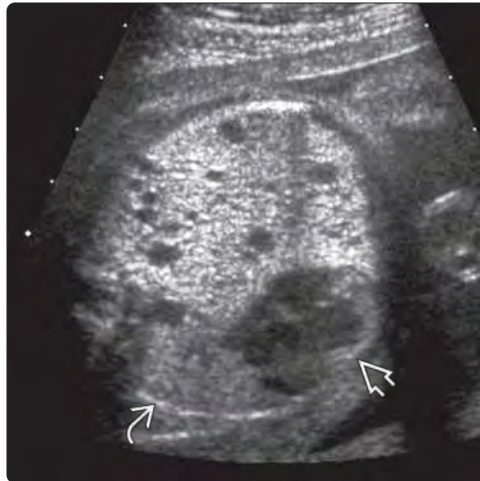

Congenital Diaphragmatic Hernia

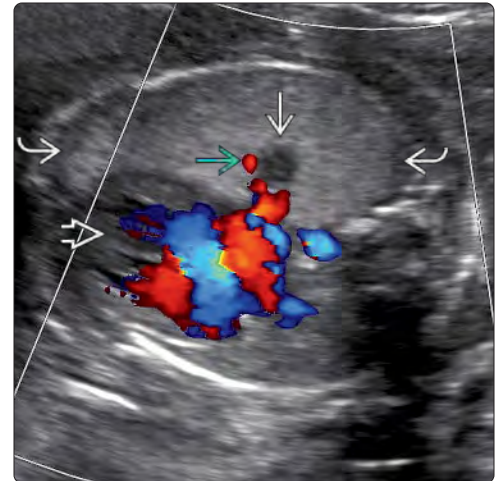


Congenital Pulmonary Airway Malformation

(Left) Axial US shows a large, echogenic mass with small, scattered cysts consistent with a congenital pulmonary airway malformation. There is marked displacement of the heart and compression of the contralateral lung. (Right) Axial color Doppler US of the chest shows an echogenic mass with a macroscopic cyst causing displacement of the heart. The mass is perfused by branches of the pulmonary artery; thus, it is a congenital pulmonary airway malformation.

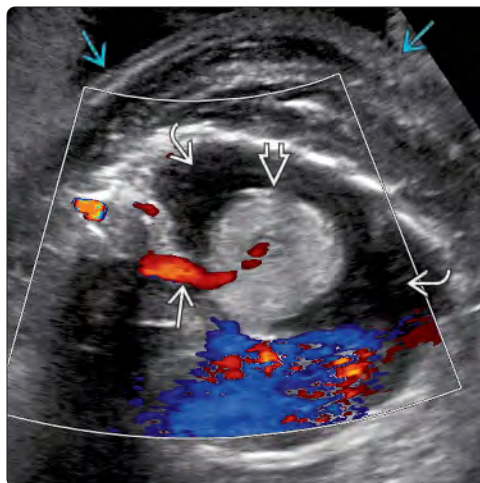


Congenital Pulmonary Airway Malformation

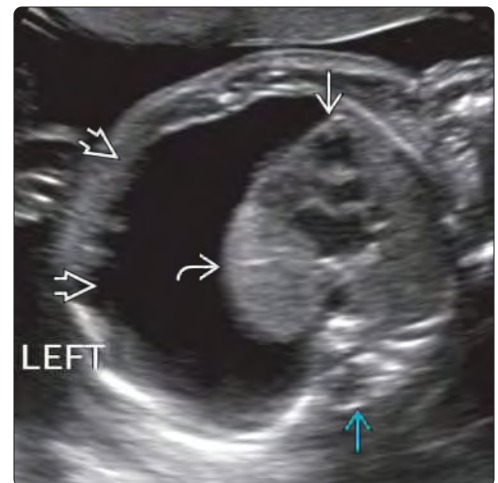


Bronchopulmonary Sequestration

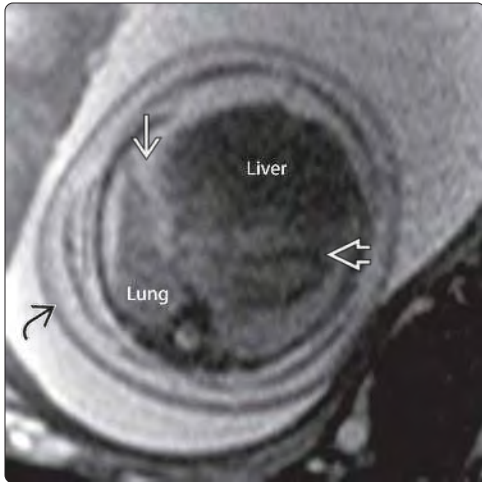
(Left) This echogenic mass is clearly perfused by a feeding vessel from the aorta. There was an associated tension hydrothorax and the fetus developed hydrops. Skin edema was severe. This is a well-recognized complication of a sequestration. (Right) Axial view of the chest shows marked cardiac displacement by the very large left pleural effusion. The lung floats in the fluid surrounding it. A pericardial effusion would compress and displace the lung toward the spine.



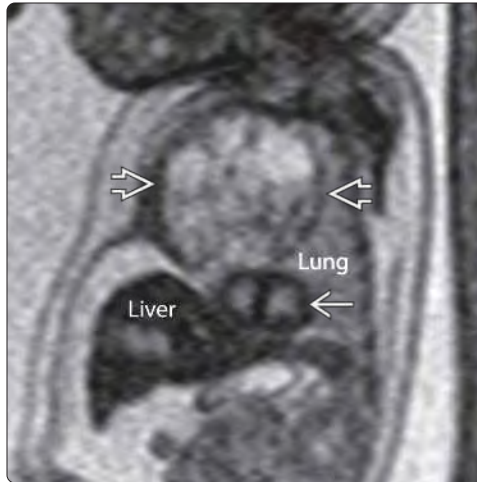Pleural Effusion



Teratoma

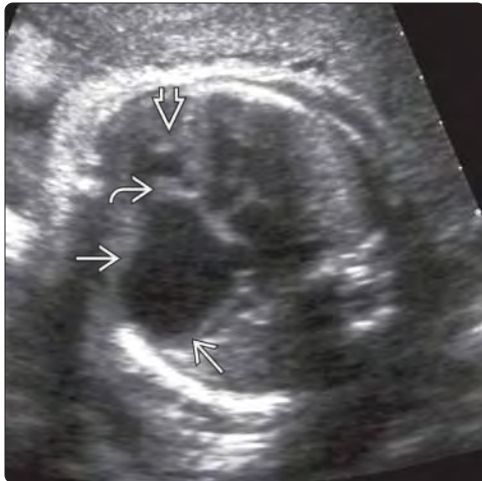


Teratoma

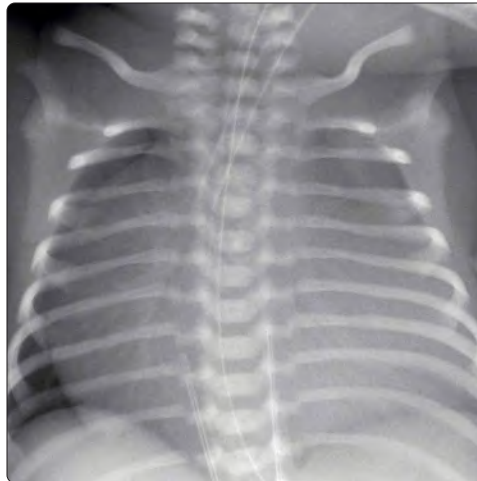


(Left) Axial T2 HASTE MR through the lower chest in a hydroptic fetus referred with suspected diaphragmatic hernia shows pleural effusion [arrow], skin edema [arrow], and cardiac displacement [arrow]. (Right) Sagittal T2WI to the right of midline shows the heart pushed inferiorly by a large mediastinal teratoma [arrow]. The fact that a short-axis view of the ventricles [arrow] is visible in this plane indicates that the heart is also rotated. The infant had prolonged cardiac dysfunction after resection of the teratoma but eventually recovered fully.

Chamber Asymmetry

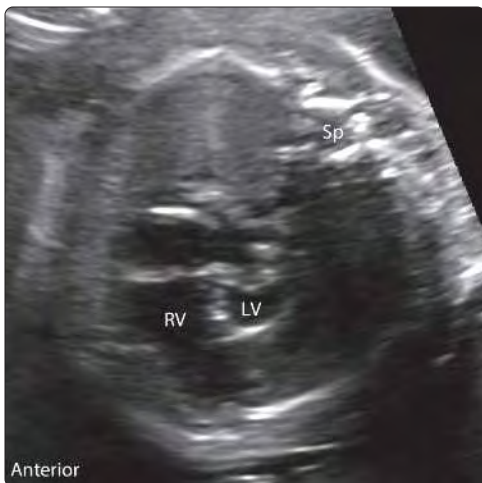

Chamber Asymmetry

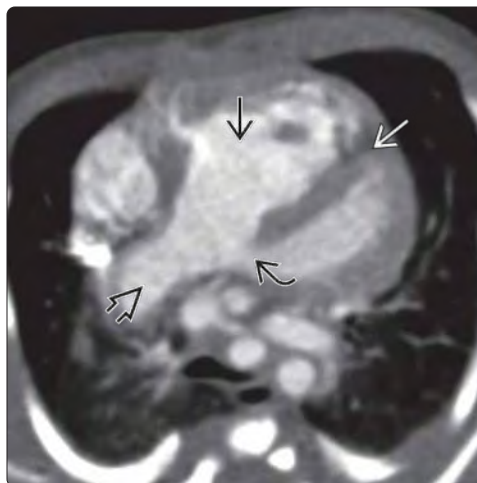


(Left) Four-chamber view shows an abnormal axis secondary to dramatic right atrial enlargement [arrow] in a fetus with Ebstein anomaly. Note the inferior displacement of the septal tricuspid leaflet [arrow], causing atrialization of the right ventricle (RV), the functional part of the RV [arrow] being very small. (Right) Frontal chest radiograph in an infant with Ebstein anomaly shows the "wall-to-wall" heart; this is due to the massive right atrial enlargement.

Chamber Asymmetry



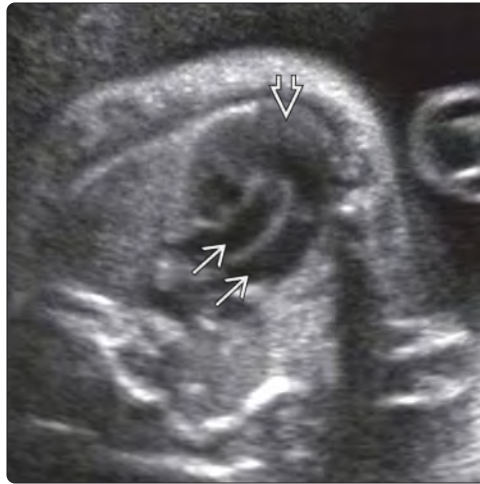
Conotruncal Malformation



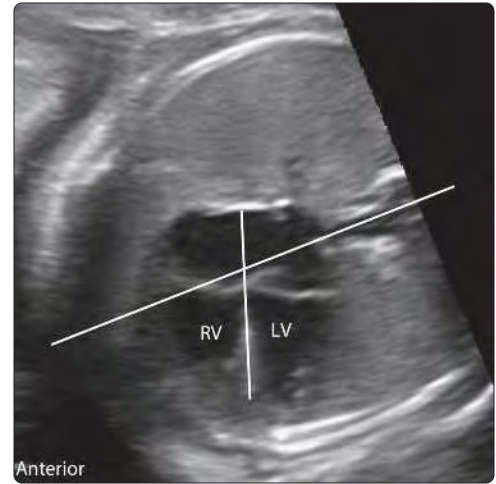
(Left) Four-chamber view shows an enlarged RV wrapping around the small, nonapex-forming left ventricle (LV) in this fetus with hypoplastic left heart syndrome. (Right) CECT demonstrates the aorta [arrow] predominantly overlying the RV [arrow] but communicating with the LV through a large ventricular septal defect [arrow]. Note the abnormal axis of ~60 degrees (plane of the ventricular septum [arrow]).

Conotruncal Malformation

(Left) Right ventricular outflow tract view shows parallel great arteries as both arise from the RV in this fetus with double outlet RV. (Right) The only abnormality in this 4-chamber view is the abnormal axis, but this is a fetus with tetralogy of Fallot. Outflow tract views are essential for detection of conotruncal malformations.

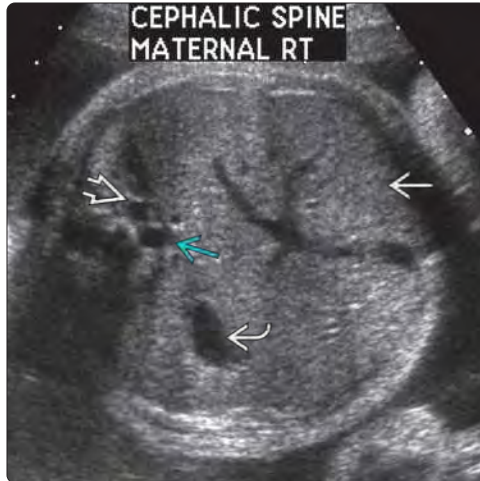


Conotruncal Malformation

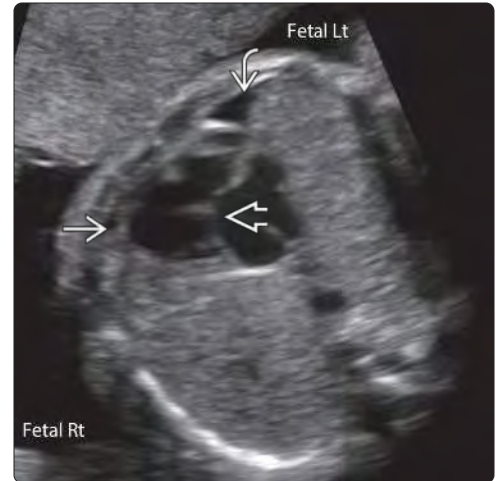


Heterotaxy, Cardiosplenic Syndromes

(Left) In a fetus in cephalic presentation with spine to the maternal right, the fetal left side is anterior. This transverse US through the abdomen shows the liver on the left and the stomach on the right. Azygos continuation of the IVC is visible as a vessel posterior to the aorta. (Right) Four-chamber view in a case of heterotaxy shows dextrocardia, an atrioventricular septal defect, and a left pleural effusion. This fetus also had transposition. Hydrops developed and the pregnancy ended in intrauterine demise.

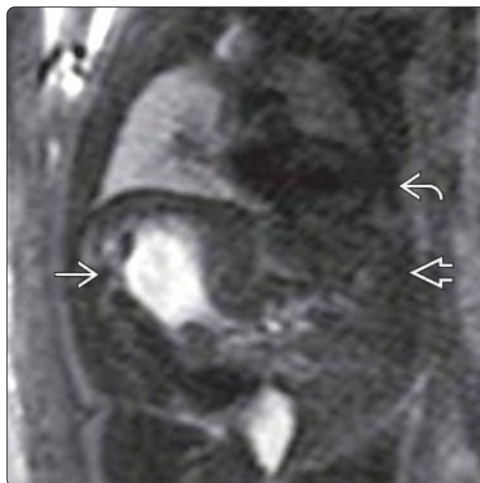

Heterotaxy, Cardiosplenic Syndromes

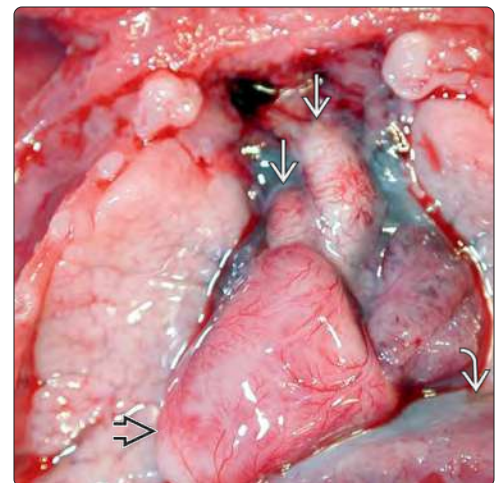


Heterotaxy, Cardiosplenic Syndromes

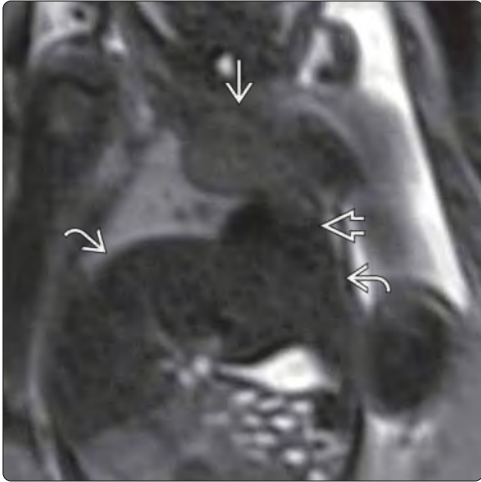
(Left) Coronal T2WI MR nicely demonstrates the right-sided stomach and left-sided liver in a fetus with heterotaxy. The cardiac apex is directed leftward. You can never assume that the stomach is on the left. Determine fetal left and right in every scan. (Right) Autopsy photograph in a case of heterotaxy shows dextrocardia, parallel outflow tracts (transposition in this case), and left-sided liver.



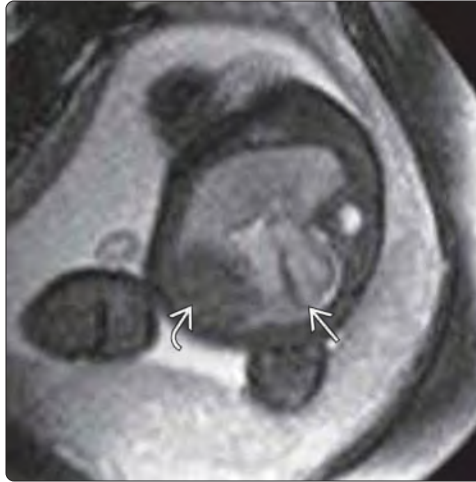Heterotaxy, Cardiosplenic Syndromes



Pulmonary Agenesis

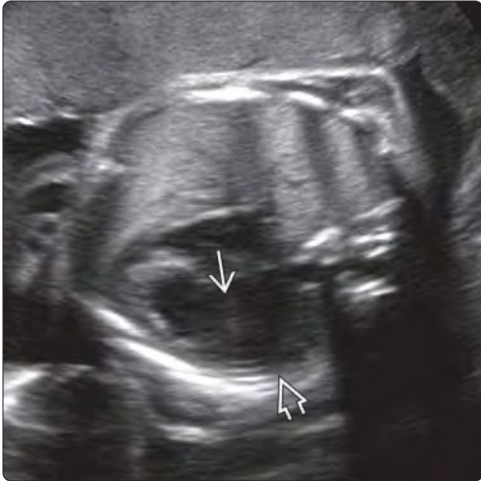

Pulmonary Agenesis

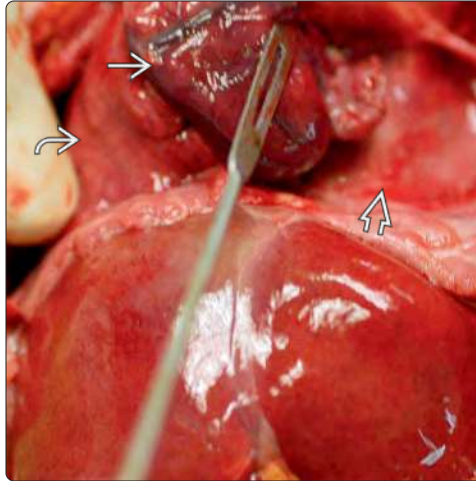


(Left) T2WI MR in a fetus referred for MR to measure lung volumes in a diaphragmatic hernia reveals that the diaphragm is intact. The heart is displaced to the left as there is left lung agenesis. Note the thymus. (Right) Axial TRUFI sequence in the same case shows the cardiac apex rotated posteriorly. The liver is anterior to the heart because of diaphragmatic elevation, not a diaphragmatic hernia.

Pulmonary Agenesis

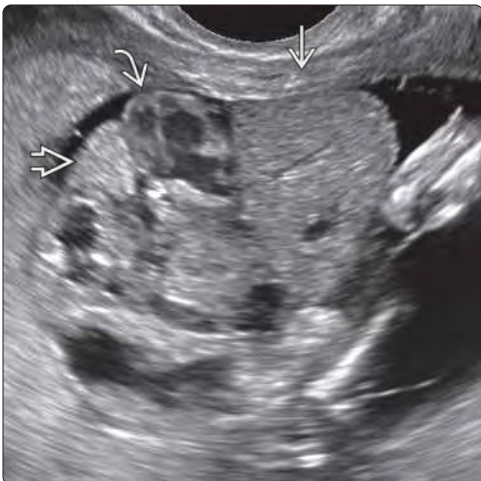


Pulmonary Agenesis

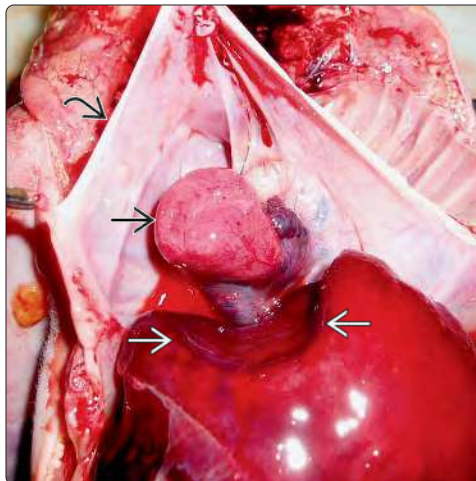


(Left) Axial view of the chest in the same case shows the cardiac apex directed posteriorly. Note the plane of the ventricular septum. The unilateral left lung agenesis was isolated in this case and the child is alive and well. (Right) Gross pathology, in which there were multiple other anomalies, including a large encephalocele, shows the right lung and the "empty" left hemithorax with the heart retracted. The newborn died within minutes of delivery.

Ectopia Cordis



Ectopia Cordis



(Left) Vaginal US at 16 weeks shows the heart, liver, and 1 lung outside the body in this case of amniotic bands with extensive thoraco-abdominoschisis and extrathoracic ectopia cordis. One cannot even draw the lines used to measure the cardiac axis. (Right) Gross pathology shows the heart beneath the elevated and retracted diaphragm. Note the mass effect on the dome of the liver. This is an example of abdominal ectopia cordis.

DIFFERENTIAL DIAGNOSIS

Common

- Hypoplastic Left Heart Syndrome
- Tricuspid Atresia
- Pulmonary Valve Atresia With Intact Ventricular Septum
- Coarctation of Aorta

Less Common

- Atrioventricular Septal Defect, Unbalanced
- Ebstein Anomaly
- Tricuspid Dysplasia

ESSENTIAL INFORMATION

Key Differential Diagnosis Issues

- Are there 1 or 2 ventricles?
 - If only 1, is it morphologically right or left ventricle (LV)?
 - If 2 ventricles, do they both reach cardiac apex?
- Are there 1 or 2 atrioventricular (AV) valves?
 - If only 1 AV valve, is it tricuspid, mitral, or common AV valve?
 - Are AV valves normal in size?
 - Are valves located in same plane or offset?
 - Normal tricuspid insertion is more apical than mitral
 - When valves appear to be in same plane, think AV septal defect (AVSD)
 - Is there AV valve regurgitation?
- Are there 1 or 2 great arteries?
 - Are they normal in size?
 - Does blood flow into both from heart?
 - Is perfusion to 1 artery from ductus arteriosus?
 - No forward flow from heart, vessel fills retrograde via ductus

Helpful Clues for Common Diagnoses

- **Hypoplastic Left Heart Syndrome**
 - Abnormal 4-chamber view with small, nonapex-forming LV
 - May see brightly echogenic LV endocardium with endocardial fibroelastosis
 - LV function is poor
 - Interatrial septum is bowed left to right as flow across foramen ovale is reversed
 - Little or no antegrade flow from LV so left atrial (LA) blood crosses into right atrium (RA)
 - Aortic valve often atretic &/or very small
 - Ascending aorta and transverse arch are very small
 - Right ventricle (RV) is large
 - Wraps around apex of LV
 - Function is typically very good, even hyperdynamic
- **Tricuspid Atresia**
 - Abnormal 4-chamber view
 - Small, nonapex-forming RV with poor function
 - Tricuspid valve appears plate-like with no movement
 - Interatrial septum is bowed right to left like normal
 - No antegrade flow into RV so all blood crosses into LA from RA
 - Ventricular septal defect (VSD) usually present to provide blood flow to great artery arising from RV

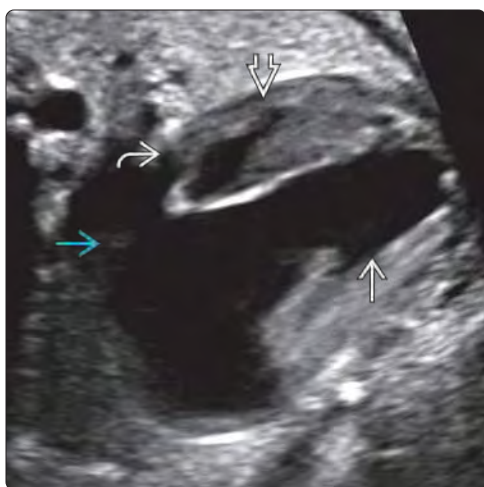
- Size of great artery arising from RV depends on size of VSD
 - Large VSD → bigger great vessel
 - Small VSD → could mean pulmonary stenosis or suggest presence of coarctation
- Great artery relationship
 - Normally related: Pulmonary artery arises from RV
 - Transposition: Aorta arises from RV
- LV is normal to large in size with good function
- **Pulmonary Valve Atresia With Intact Ventricular Septum**
 - 4-chamber view is abnormal
 - RV very hypertrophied and small
 - RV function is poor
 - Tricuspid valve is often hypoplastic
 - However, it can be normal in size with significant regurgitation
 - Look for abnormal coronary flow in RV walls
 - Indicates presence of coronary sinusoids
 - ◻ Flow is of low velocity in these small vessels
 - Coronary flow is typically normal in presence of tricuspid regurgitation (TR)
 - Reversed flow in ductus arteriosus
 - Pulmonary artery fills retrograde from aortic arch, not antegrade from RV
 - Ductus arteriosus is more vertically oriented than usual
 - Pulmonary arteries are typically normal in size
- **Coarctation of Aorta**
 - There is no 1 finding to diagnose coarctation reliably due to presence of ductus arteriosus, so multiple factors are looked at
 - RV usually mildly or significantly enlarged compared to LV
 - Size discrepancy between aorta (smaller) and pulmonary artery (larger)
 - Size discrepancy between mitral (smaller) and tricuspid (larger) valves
 - Transverse arch hypoplasia is common and there may be posterior shelf in proximal descending aorta
 - Aortic isthmus to ductal ratio may be small
 - Left-to-right shunt at atrial level with no mitral or aortic valve stenosis
 - Retrograde flow in transverse aortic arch
 - ◻ No forward flow past coarctation; transverse arch retrograde to ductus to descending aorta postcoarctation segment
 - VSD with posteriorly deviated infundibular septum also raises suspicion of coarctation
 - Serial follow-up is very helpful to track growth or lack thereof in heart structures noted above
 - If "candy cane" aortic arch is not seen, look for arch interruption

Helpful Clues for Less Common Diagnoses

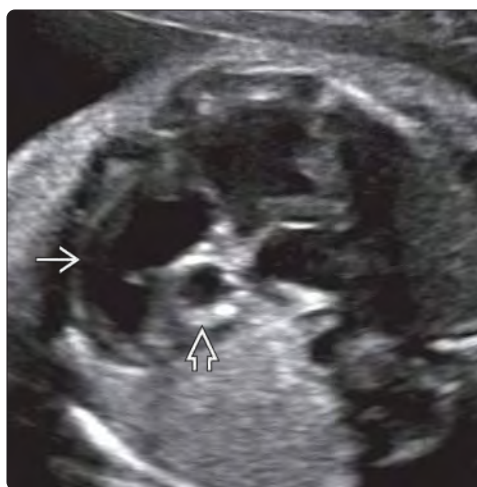
- **Atrioventricular Septal Defect, Unbalanced**
 - Missing "crux" of heart in 4-chamber view
 - Primum atrial septal defect present
 - Inlet VSD present
 - Single AV valve may be committed more to one ventricle than other
 - Ventricle lacking commitment will be hypoplastic

- Valves located in same plane in 4-chamber view is tip-off
 - Normally tricuspid and mitral valves offset on interventricular septum
 - Additional cardiac malformations are common
 - Look for features of heterotaxy syndromes
 - Situs abnormalities (e.g., dextrocardia, right-sided stomach)
 - Midline liver and splenic abnormalities
 - Anomalous venous drainage especially azygous continuation of inferior vena cava
 - Look for signs of trisomy 21
 - Thick nuchal fold, absent nasal bone
 - Duodenal atresia, echogenic bowel
 - Short humerus, femur
 - Sandal gap toes, clinodactyly
 - **Ebstein Anomaly**
 - Apical displacement of septal and mural tricuspid valve leaflets with attachments to ventricular septum
 - Anterior leaflet is often sail-like
 - "Atrialization" of RV
 - Significant right atrial enlargement
 - Functional RV is small
 - Variable degrees of TR
 - Pulmonary artery is often small or has functional atresia
 - Severe TR → lack of antegrade flow to RV
 - Cardiothoracic ratio is greater than normal and sometimes up to 80%, called "wall-to-wall" heart
 - **Tricuspid Dysplasia**
 - Valve leaflets are in normal position
 - Leaflets are thick, nodular, or irregular
 - Severe TR → RA enlargement
 - Often associated with pulmonary stenosis/atresia
 - LV normal in size with good function
- Other Essential Information**
- Hypoplastic left heart syndrome (HLHS), tricuspid atresia (TA), and unbalanced AVSD
 - All considered single ventricles and require 3-stage surgical palliation
 - Norwood followed by Glenn and Fontan operation
 - Outcomes for HLHS
 - Improved in terms of survival in short term but remain poor for long term
 - Survival into 20s or 30s is currently standard
 - Neurodevelopment is delayed and can be significant problem
 - Liver, gut, and lung issues are major concerns long term
 - Outcomes for TA are better than HLHS with survivors into their 40s and 50s
 - Outcomes for unbalanced AVSD are variable
 - Depend on which ventricle is dominant
 - Depend on associated anomalies like heterotaxy
 - Pulmonary atresia with intact ventricular septum can have very poor prognosis
 - Additional source of pulmonary blood is needed early either by antegrade flow from RV or Blalock-Taussig shunt
 - Presence of coronary sinusoids may prevent decompressing RV with catheter intervention
 - Increased risk of sudden death when present
 - May require heart transplant
 - Most patients have single ventricle repair, require Glenn and Fontan operations
 - Tricuspid valve dysplasia has good prognosis
 - Increased oxygen saturation + decreased pulmonary vascular resistance often decreases TR significantly
 - Surgery may not be necessary
 - Coarctation of aorta has high survival rates and excellent long-term outcome
 - Isolated arch repairs have < 1% mortality, repairs associated with VSD have 2.5% mortality
 - 85-90% of patients need no additional intervention in their lifetime and have normal life expectancy
 - Even in setting of hypoplastic left heart structures at birth if LV is apex forming

Hypoplastic Left Heart Syndrome



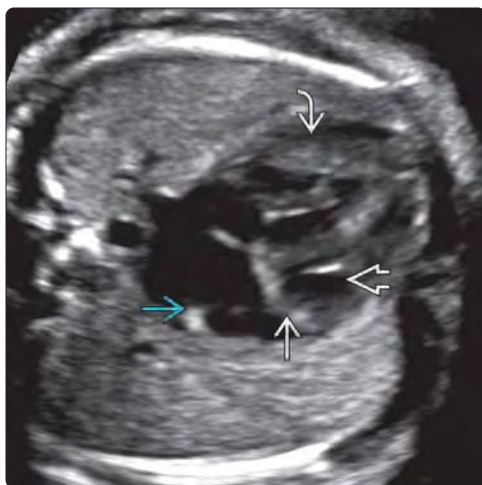
Hypoplastic Left Heart Syndrome



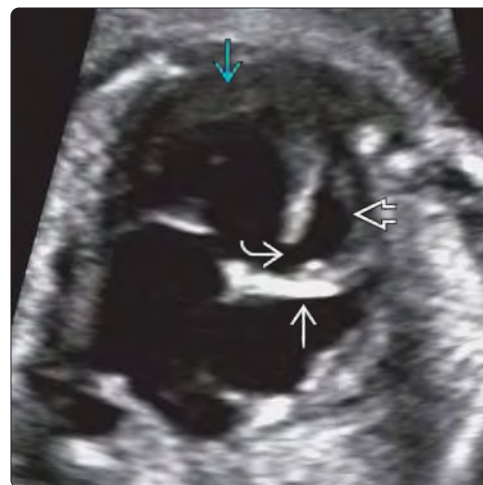
(Left) Image shows a large right ventricle (RV) and a small or hypoplastic left ventricle (LV). In this case, there was mitral atresia so all the blood flow from the lungs was going left to right at the atrial level. There was almost no atrial septum in this patient. (Right) Image shows a large RV, which is apex-forming, and a very small LV with echogenic lining consistent with hypoplastic left heart syndrome. This patient had mitral and aortic atresia. Note how the RV apex wraps around the nonapex-forming LV.

Tricuspid Atresia

(Left) Four-chamber echocardiogram shows plate-like atresia of the tricuspid valve with a very small RV cavity. Flow is all right to left at the atrial level; there is minimal atrial septal tissue. The LV is dilated and hypertrophied. (Right) Four-chamber echocardiogram shows an atretic tricuspid valve and a small RV, which receives blood flow from the ventricular septal defect. The LV is dilated. It is key to look at the relationship of the great vessels to avoid missing associated transposition.

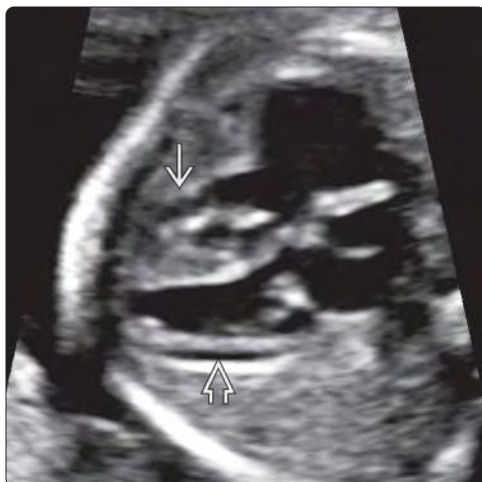

Tricuspid Atresia

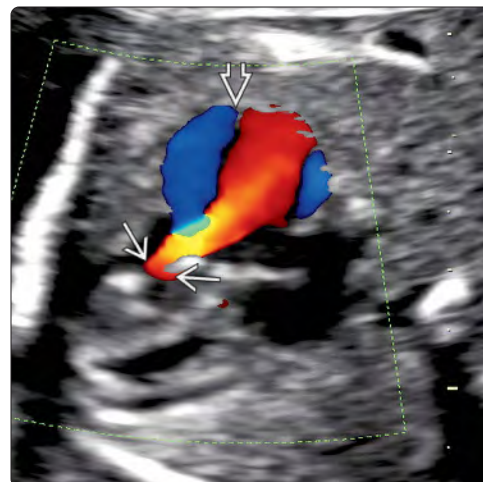


Pulmonary Valve Atresia With Intact Ventricular Septum

(Left) Four-chamber echocardiogram shows a hypertrophied and hypoplastic RV with a very normal appearing LV, which is apex forming. (Right) The same image with color in systole shows severe tricuspid regurgitation with the regurgitant jet filling the dilated right atrium. Patients with pulmonary atresia and significant tricuspid regurgitation have a lower pressure RV due to the "pop-off" into the atrium and therefore typically do not develop coronary sinusoids.

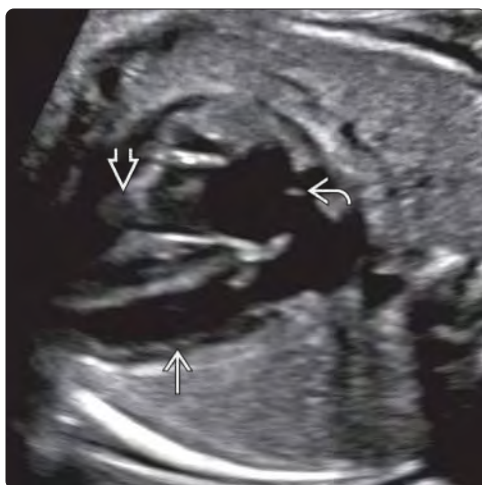


Pulmonary Valve Atresia With Intact Ventricular Septum

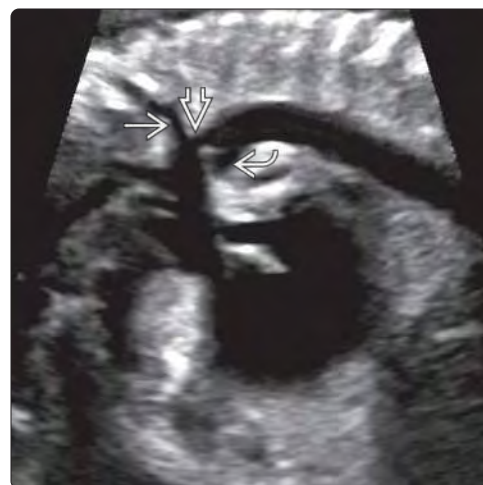

Pulmonary Valve Atresia With Intact Ventricular Septum

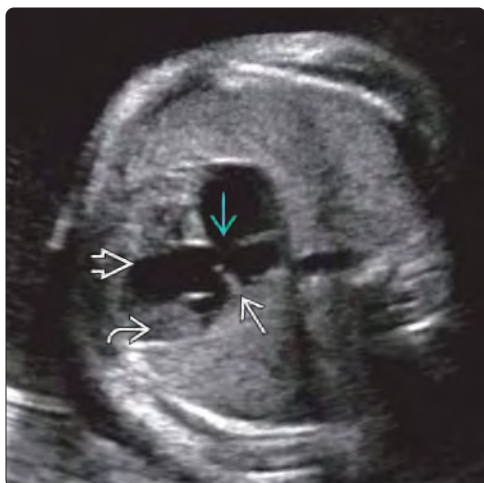
(Left) Four-chamber echocardiogram shows an apex-forming LV that is smaller than the RV. One also notes a portion of the foramen ovale flap bowing into the RA, suggesting left to right flow, which is the opposite of normal. (Right) Arch imaging in the same patient shows the left subclavian artery is displaced and there is significant isthmus hypoplasia consistent with coarctation. The ductus arteriosus can be seen entering the descending aorta.



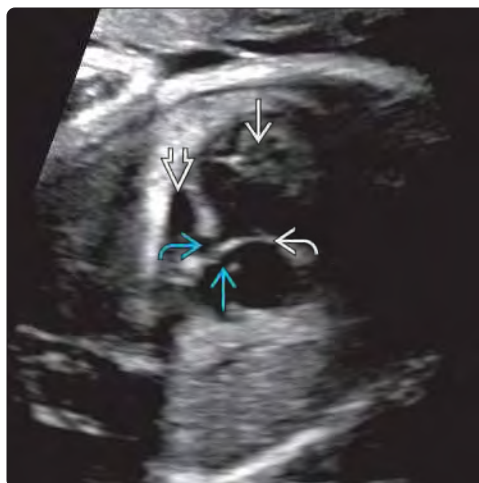
Coarctation of Aorta



Atrioventricular Septal Defect, Unbalanced

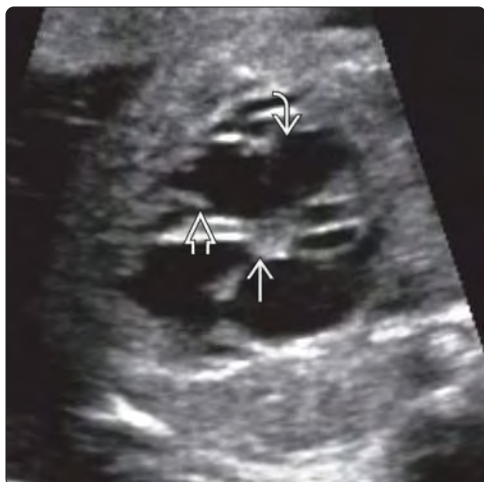


Atrioventricular Septal Defect, Unbalanced

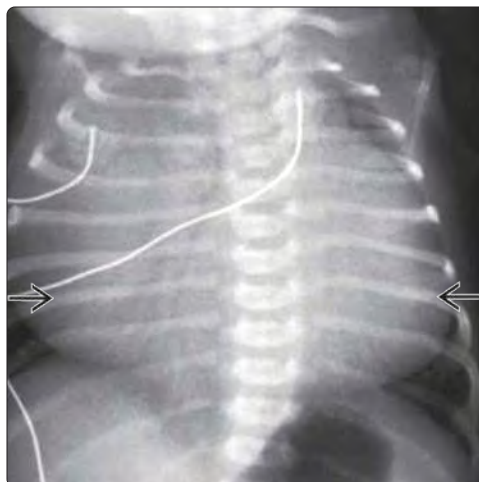


(Left) Four-chamber echocardiogram shows a single atrioventricular (AV) valve that is more committed to the RV. The LV is hypoplastic. One can also clearly see the primum atrial septal defect. (Right) Four-chamber echocardiogram shows another right dominant AV canal. The RV is very large in comparison to the LV. A single AV valve is present. Both the primum atrial septal defect and inlet ventricular septal defect are seen.

Ebstein Anomaly

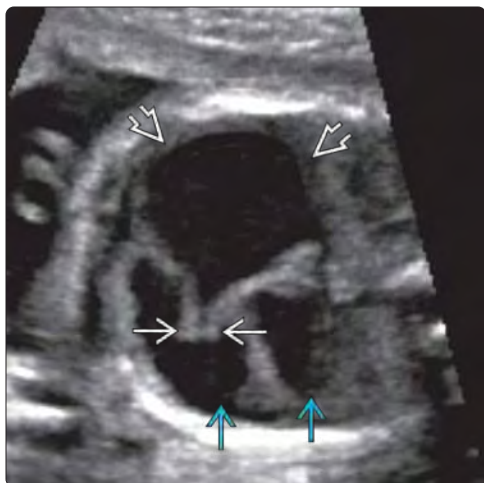


Ebstein Anomaly

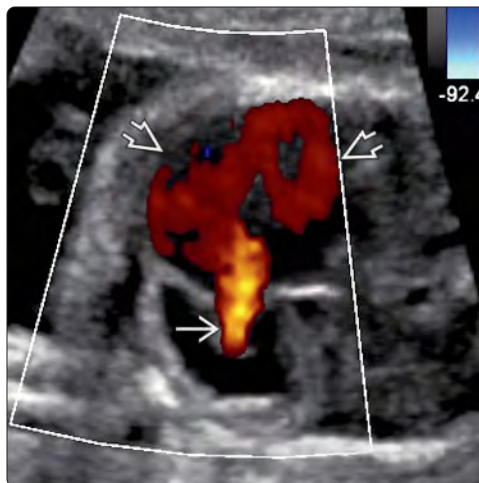


(Left) Four-chamber echocardiogram shows a mitral valve in the normal position with a normal left heart. The septal leaflet of the tricuspid valve is displaced inferiorly. This is noted by the difference in arrow locations, which mark the hinge point of each valve. In this patient, the RA is not as dilated as we often see. (Right) Radiograph shows the typical appearance of the chest x-ray in a child with Ebstein anomaly. This degree of cardiomegaly is called a "wall-to-wall" heart and is due to massive dilation of the RA.

Tricuspid Dysplasia



Tricuspid Dysplasia

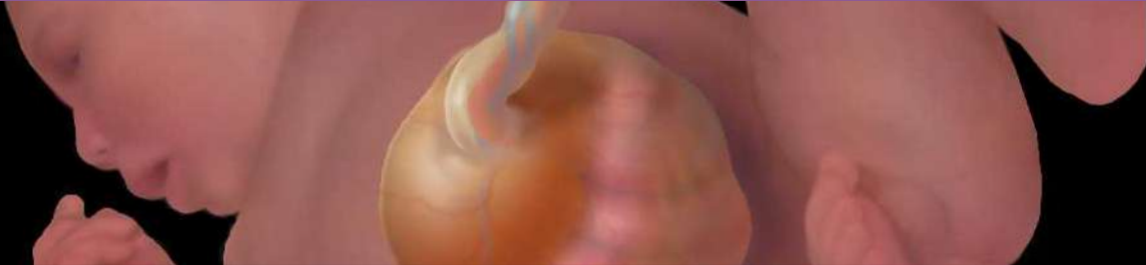

(Left) Four-chamber echocardiogram shows thick and dysplastic tricuspid valve leaflets that do not appear to coapt well. Also note how large the RA is; it appears to be equal to the size of both ventricles combined. (Right) Four-chamber echocardiogram in the same patient confirms that the leaflets do not coapt well as there is severe tricuspid regurgitation. Blood flow essentially fills the RA chamber in systole. These patients typically do well after birth when the pulmonary vascular resistance falls.

This page intentionally left blank

SECTION 7

Abdominal Wall and Gastrointestinal Tract



Introduction and Overview

Embryology and Anatomy of the Abdominal Wall and GI Tract	474
Approach to the Abdominal Wall and GI Tract	484

Abdominal Wall Defects

Gastroschisis	490
Omphalocele	496
Pentalogy of Cantrell	502
Body Stalk Anomaly	504
Bladder Exstrophy	508
Cloacal Exstrophy/OEIS Syndrome	512

Bowel Abnormalities

Esophageal Atresia	516
Duodenal Atresia	520
Jejunal, Ileal Atresia	524
Colonic Atresia	528
Anal Atresia	530
Cloacal Malformation/Urogenital Sinus	532
Volvulus	536
Enteric Duplication Cyst	538

Peritoneal Abnormalities

Meconium Peritonitis, Pseudocyst	540
Mesenteric Lymphangioma	544

Hepatobiliary Abnormalities

Gallstones	546
Choledochal Cyst	548
Congenital Hepatic Hemangioma	550
Mesenchymal Hamartoma	552
Malignant Liver Tumors	554

Pertinent Differential Diagnoses

Echogenic Bowel	558
Ascites	560
Cystic Abdominal Mass	562

EARLY EMBRYOLOGIC EVENTS**2nd Week: 8-14 Days Post Conception**

- **Rule of 2s**
 - Embryoblast splits into 2 layers: Epiblast and hypoblast
 - Trophoblast gives rise to 2 tissues: Cytotrophoblast and syncytiotrophoblast
 - Blastocyst cavity is remodeled twice: Primary and secondary **yolk sac**
 - 2 novel cavities appear: Amnion and chorion
 - Extraembryonic mesoderm splits into 2 layers lining chorionic cavity: **Somatic** and **splanchnic mesoderm**

3rd Week: 15-21 Days Post Conception

- Bilaminar disk → trilaminar disk (gastrulation begins)
- **Gastrulation:** Process of forming 3 primary germ layers
 - **Ectoderm** → epidermis, retina, central and peripheral nervous systems, other
 - **Mesoderm** → smooth muscle, connective tissue, vessels, most of cardiovascular system, blood cells, bone marrow, skeleton, striated muscles, reproductive and excretory organs
 - **Endoderm** → epithelial linings of respiratory passages and GI tract, including glands opening into GI tract and glandular cells of liver and pancreas
- Endoderm and ectoderm separated by mesoderm in all areas of gut with 2 exceptions
 - Areas of mesodermal deficiency: Oropharyngeal membrane (future oropharyngeal cavity) and cloacal membrane (future area of urethra and anus)
- **Allantois** appears as diverticulum from caudal yolk sac on day 16 and extends into connecting stalk
 - Involved in development of bladder in humans and early blood formation
 - Becomes urachus as bladder enlarges
 - Blood vessels of allantois become umbilical arteries and veins

4th Week: 22-28 Days Post Conception

- Rapid growth results in folding of embryo
 - 4 folds: Cranial, caudal, 2 lateral
- Folding causes yolk stalk to narrow, bringing it in close proximity to body stalk
- **Umbilical ring** surrounds both yolk and body stalks
- Allantois contained within body stalk
- Lateral edges of trilaminar disk fold ventrally to form **body wall**, moving toward yolk stalk and body stalk

5th Week: 29-35 Days Post Conception

- Viscera develop in mesentery of caudal part of foregut
- Fetal stomach is suspended by 2 mesogastria, and rotation of stomach begins
 - **Dorsal mesogastrium:** Site for developing spleen, body-tail of pancreas
 - **Ventral mesogastrium:** Site for developing liver, bile ducts, head of pancreas
 - Dorsal part of ventral mesogastrium becomes lesser omentum
 - Lesser omentum includes gastrohepatic ligament and hepatoduodenal ligament
- **Foregut:** Caudal to liver bud forms esophagus, stomach, and proximal duodenum

- **Midgut:** From liver bud to 2/3 of transverse colon; opens into yolk sac
 - Gut tube begins to lengthen → primary intestinal loop (attached to yolk sac via yolk/vitelline duct)
 - Axis of loop is superior mesenteric artery (SMA)
 - Yolk duct and connecting stalk begin to merge
- **Hindgut:** Gives rise to distal 1/3 of transverse colon, descending colon, sigmoid, rectum, and upper anal canal
 - Endoderm of hindgut also forms internal lining of bladder and urethra
 - Caudal end of hindgut terminates in endodermally lined **cloaca**
 - Cloaca includes base of allantois
 - Shelf of mesodermal tissue, **urorectal septum**, sits between hindgut and base of allantois

6th to 7th Weeks: 36-49 Days Post Conception

- Merging of yolk stalk and body stalk to form **umbilical cord** is complete
 - Yolk stalk atrophies: Failure to regress completely → **Meckel diverticulum**, blind outpouching from distal ileum
- **Physiologic herniation**
 - Length of midgut increases, volume of gut is greater than body can accommodate → herniation into base of umbilical cord
 - Rotates 90° counterclockwise around axis of SMA (as viewed from front of embryo)
 - Folds grow out from urorectal septum to partition cloacal membrane and divide cloaca into rectum and urogenital sinus
 - Cloacal membrane is divided into anal membrane and urogenital membrane

8th Week: 50-58 Days Post Conception

- Fusion of urorectal septum, lateral mesodermal folds, and cloacal membrane to form perineal body, partition between GI and urogenital systems
- Cloacal membrane ruptures by beginning of 8th week, creating anal opening for hindgut and ventral opening for urogenital sinus

9th Week

- Abdominal cavity has enlarged sufficiently to accommodate intestines, which begin to migrate back into abdomen

10th Week

- Upon return of intestines into abdominal cavity, rotation proceeds additional 180° for total of 270°

ABDOMINAL VESSELS**Arteries**

- Major fetal arteries course anteriorly through dorsal mesenteries from aorta to supply gut and intramesenteric viscera
- Omphalomesenteric arteries supply yolk sac, then gradually fuse to form arteries in dorsal mesentery of gut
 - **Celiac** artery supplies foregut, **superior mesenteric** artery supplies midgut, **inferior mesenteric** artery supplies hindgut

Veins

- **Umbilical vein**
 - Carries oxygenated blood from placenta to fetus (major source of blood flow to liver)
 - Enters liver through ventral part of ventral mesentery (**falciform ligament** in adults)
 - Obliterated umbilical vein → **ligamentum teres**
- **Vitelline veins**
 - Paired vessels that carry blood from yolk sac to fetus in 1st few weeks of gestation
 - Give rise to venous plexus within liver
 - Precursor to hepatic and portal veins and sinusoids
 - Proximal extrahepatic veins → **portal venous system**
 - Carries blood (and nutrients) from gut to liver
 - Proximal vitelline veins → **hepatic vein precursors**
 - Carry blood from liver to heart via inferior vena cava (IVC)
- **Ductus venosus**
 - Derived from left umbilical vein (after right vein has atrophied)
 - Bypasses liver to carry umbilical vein blood to IVC and heart
 - In neonate, atrophies to become **ligamentum venosum**
- **Portal sinus**
 - In fetus, diverts some oxygenated blood from umbilical vein to liver parenchyma

ABDOMINAL ORGANS

Abdominal Viscera

- Alimentary tube
 - Foregut (esophagus, stomach, duodenum)
 - Midgut (small intestine, colon up to splenic flexure)
 - Hindgut (descending and sigmoid colon, rectum)
- Intramesenteric viscera develop from diverticula of ventral or dorsal foregut
- Supporting mesentery

Small and Large Intestine

- **Duodenum**
 - In fetus, is intraperitoneal, has mesoduodenum
 - Ventral pancreas also lies in mesoduodenum
 - Becomes retroperitoneal organ when ascending mesocolon fuses to posterior abdominal wall, "trapping" duodenum and pancreas in retroperitoneum
- **Small intestine**
 - Develops within dorsal mesentery, which elongates and persists into adulthood as small bowel mesentery
- **Large intestine (colon)**
 - Develops as straight tube within dorsal mesentery
- **Ascending and descending colon** usually lose their mesentery and become retroperitoneal structures in adult
 - Common variant: Ascending colon that is mobile due to persistent mesocolon (predisposes to twist and obstruct, "cecal volvulus")

Liver

- Arises from ventral bud of foregut
- Rapid growth is main factor in distortion of peritoneal spaces and mesentery

- Rotates counterclockwise and attaches to right side of diaphragm at bare area
- Rotation of liver results in **right peritoneal space** extending leftward, posterior to stomach
 - Becomes **lesser sac (omental bursa)**

Spleen

- Develops within dorsal mesogastrium, which elongates to form **gastrosplenic ligament**
 - Carries **short gastric vessels** and forms left anterior wall of **lesser sac (omental bursa)**
 - Elongated caudal parts of gastrosplenic ligament hang down (drape-like) from stomach
 - Forms **greater omentum** and **gastrocolic ligament**
 - Greater omentum and gastrocolic ligament carry **gastro-omental vessels**

Pancreas

- Develops within dorsal part of **dorsal mesentery**
 - Leaves only short **splenohepatic ligament**
 - Carries **splenic vessels** and tail of pancreas
 - Forms left posterior wall of **lesser sac**
- Pancreas becomes retroperitoneal organ

Peritoneal Spaces

- **Ventral mesentery** resorbs to allow communication between right and left peritoneal cavity in adults
- Variations in complex rotation, fusion and growth of mesenteric viscera result in common variations in peritoneal and retroperitoneal spaces in adults

SELECTED DEFECTS IN DEVELOPMENT

Omphalocele

- Lack of continuous folding results in failure of closure of umbilical ring vs. failure of resolution of physiologic herniation of gut
- Pathogenetic mechanism may differ depending upon which organs are prolapsed

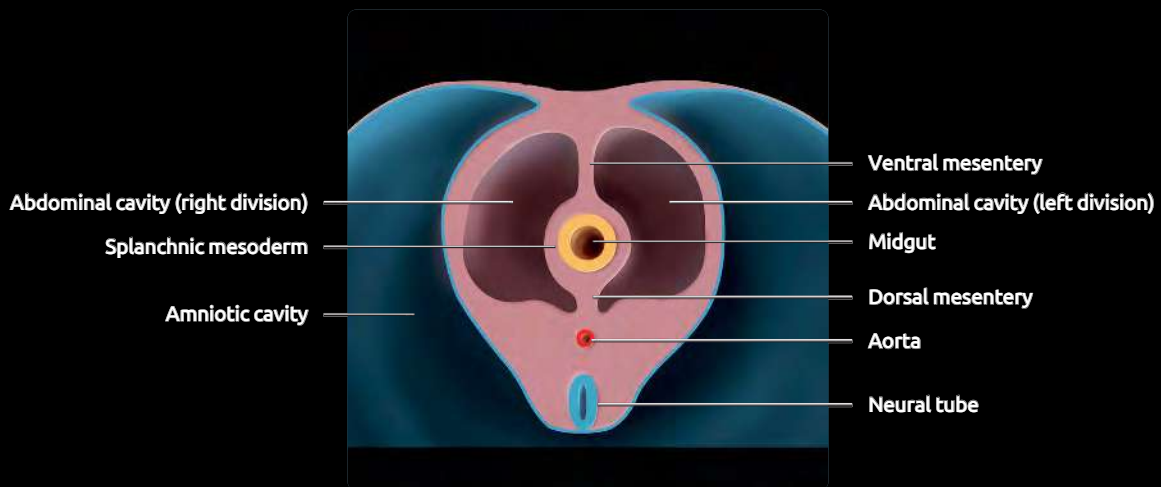
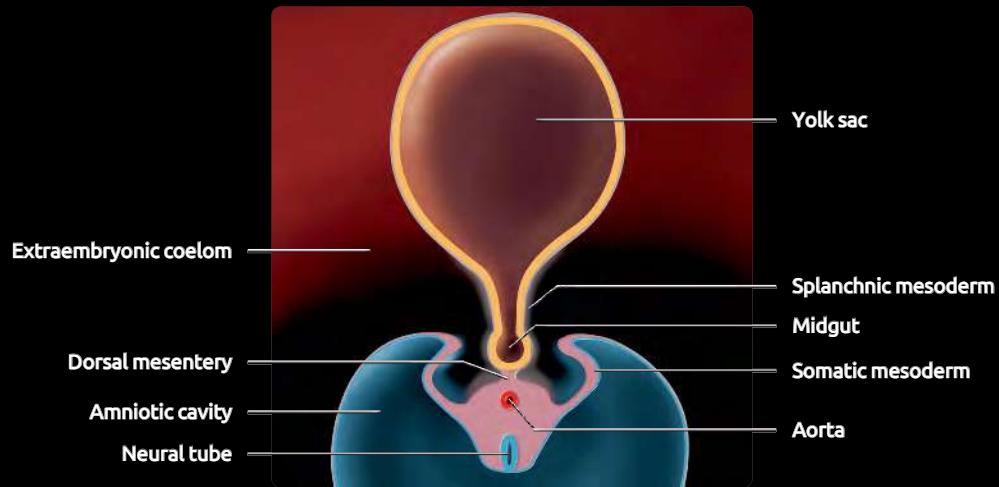
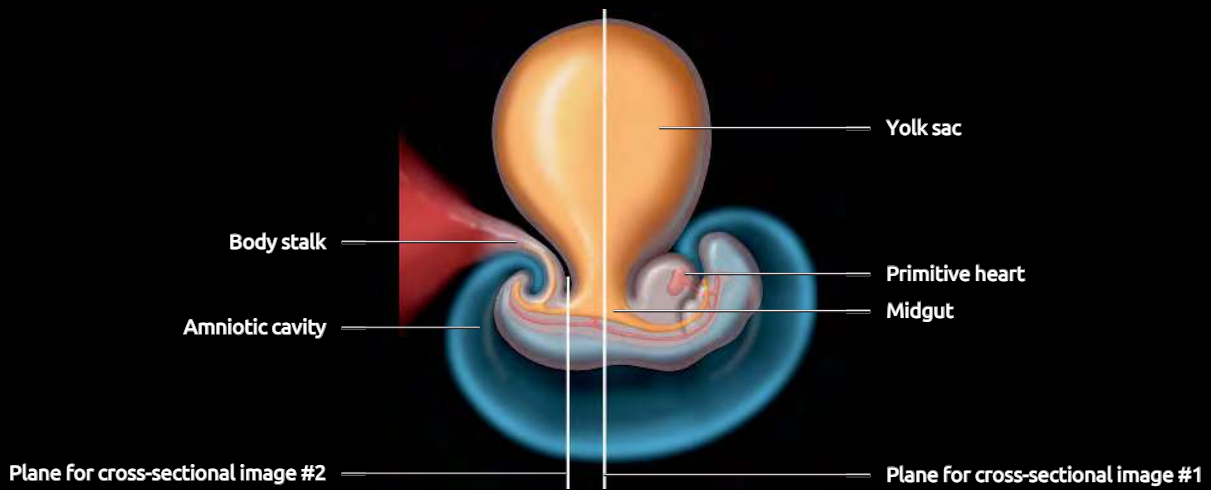
Gastroschisis

- Likely involves more than 1 pathogenetic mechanism
- Failure of right lateral abdominal fold, resulting in body stalk and yolk stalk not merging to form umbilical cord vs. focal weakness at juncture of right lateral fold and umbilical cord, permitting intestines to be extruded

Pentalogy of Cantrell

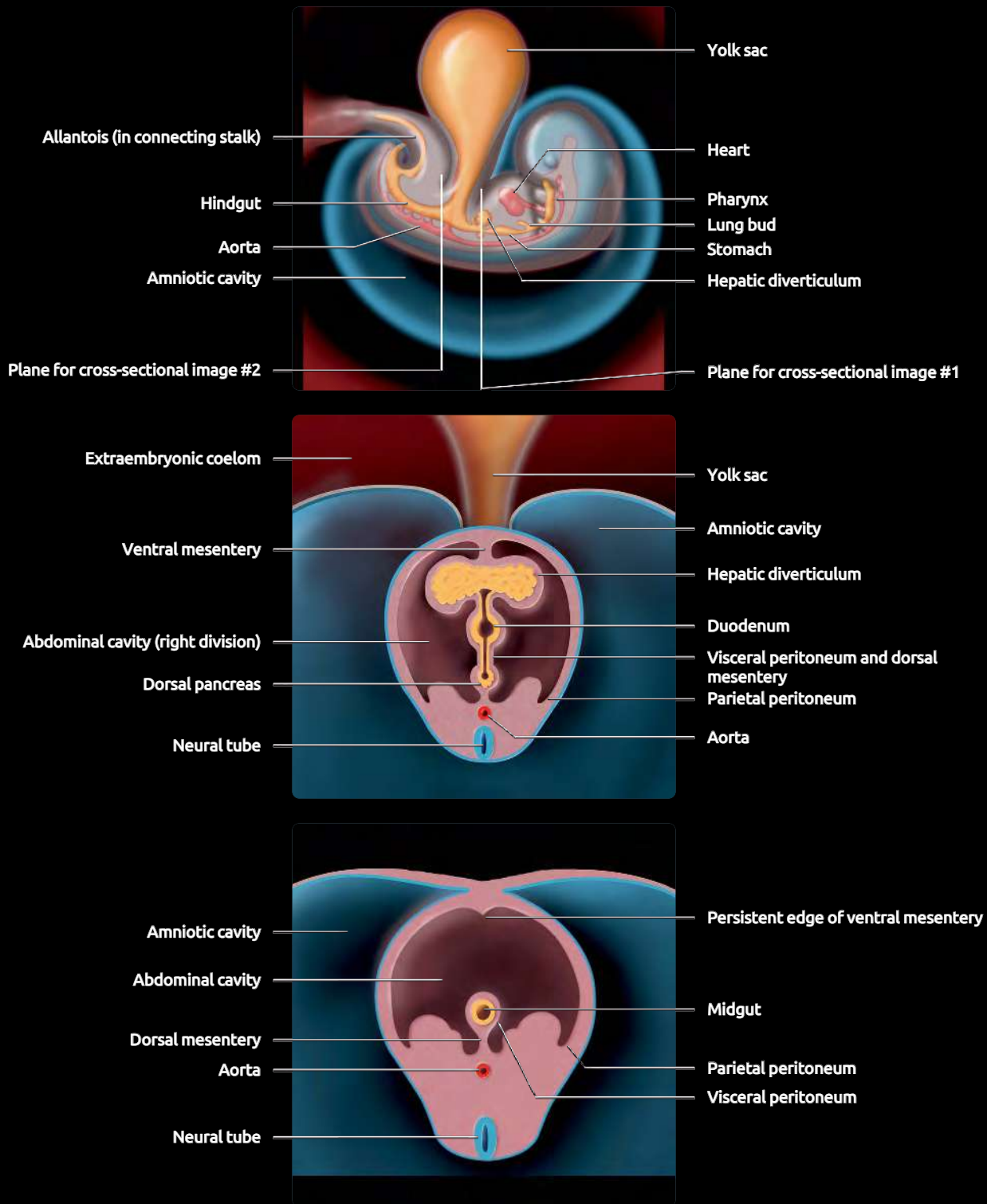
- Abnormality of mesodermal development of cephalic fold at ~ 14-18 days post conception

18-DAY EMBRYO



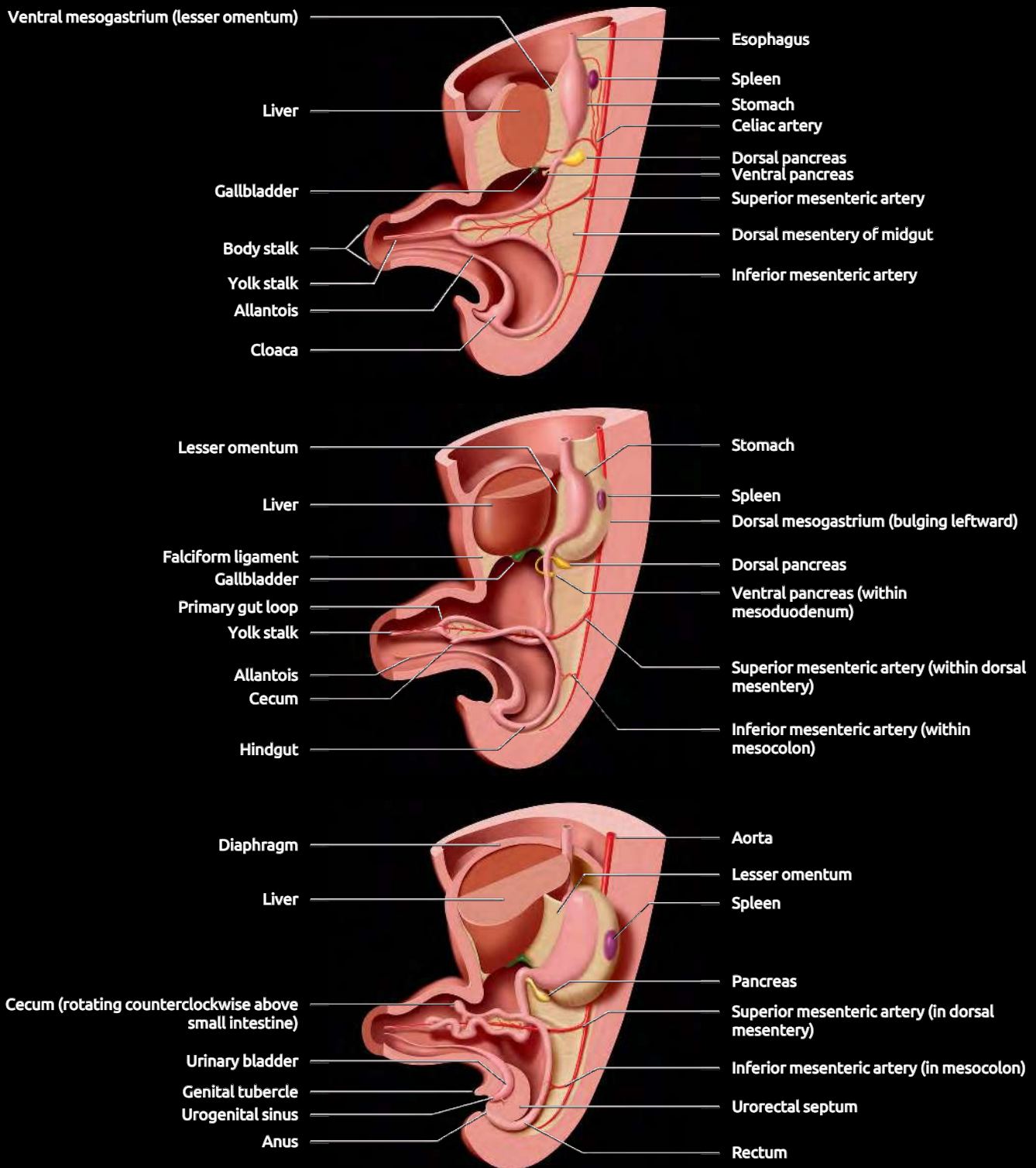
(Top) Lateral illustration shows an 18-day embryo. The roof of the yolk sac becomes incorporated in the form of a tube as part of the primitive gut. The cranial end of the tube becomes the foregut and the caudal end, the hindgut. **(Middle)** Cross-sectional illustration along plane #1 (indicated on the lateral image) shows that the midgut has a wide communication with the yolk sac at this phase. **(Bottom)** Cross-sectional illustration more distally along plane #2 (indicated on the lateral image) shows that the gut is suspended by the ventral and dorsal mesenteries.

4-WEEK EMBRYO



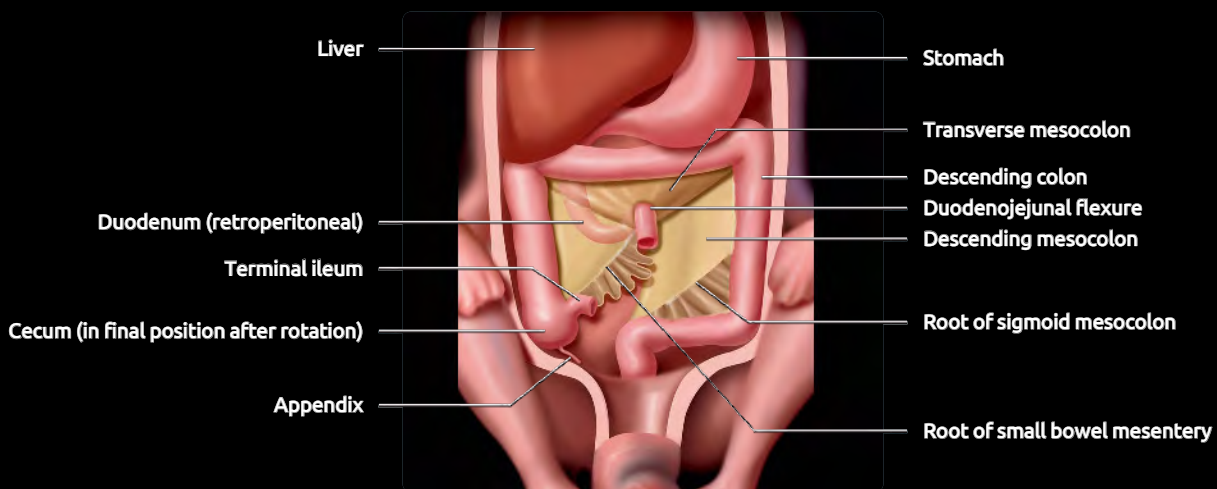
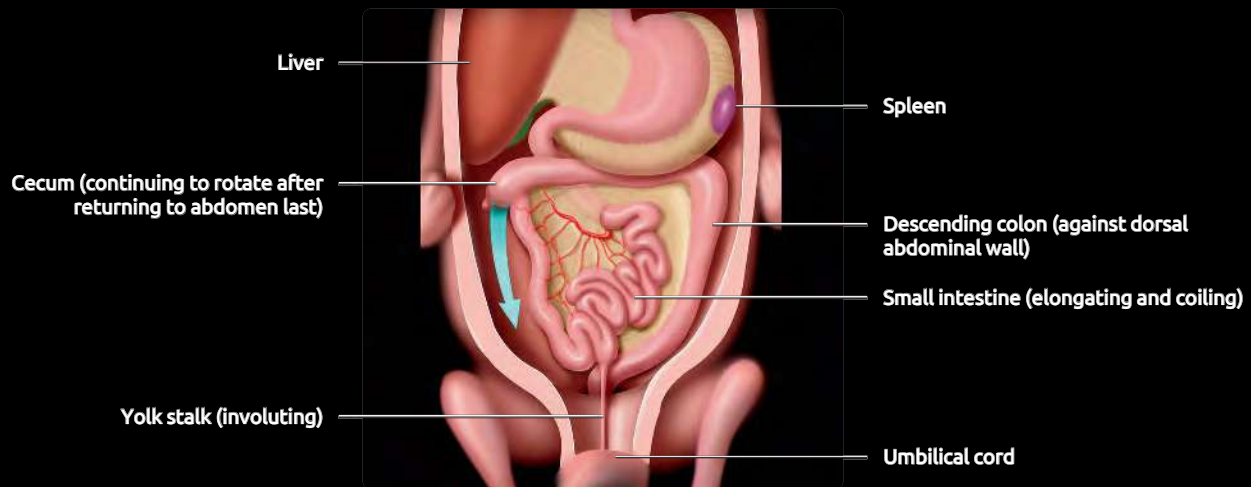
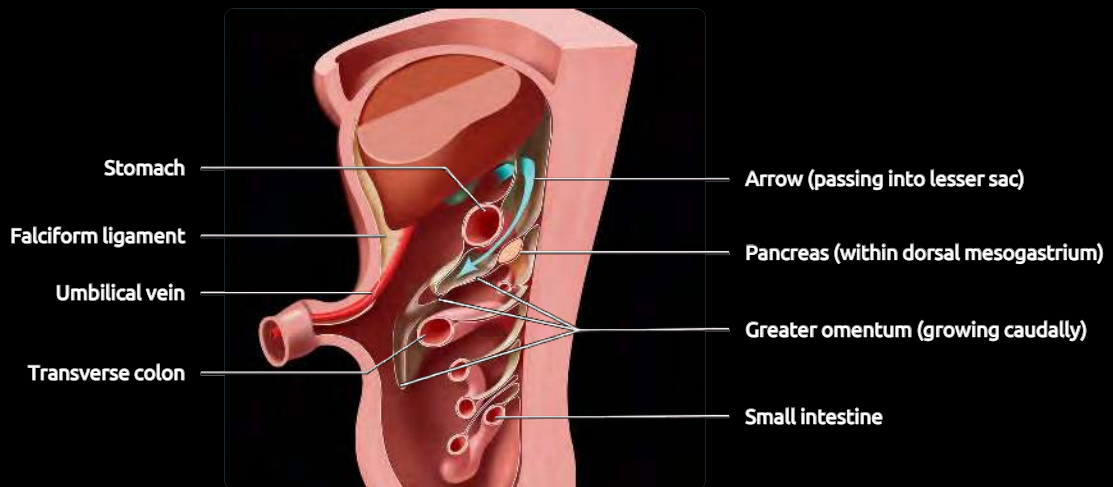
(Top) Lateral illustration shows a 4-week embryo. The pharynx and lung bud arise from the foregut, along with the stomach. The allantois connects the body stalk to the hindgut. The yolk sac communicates broadly with the primitive gut. Errors in development include communication between the foregut branches, such as a tracheoesophageal fistula. **(Middle)** Cross-sectional illustration along plane #1 (indicated on the lateral image) shows that the liver arises from a ventral bud of the foregut, while the pancreas arises from the dorsal mesentery. **(Bottom)** Cross-sectional illustration along plane #2 (indicated on the lateral image) shows that the ventral mesentery begins to disintegrate to allow communication between right and left sides of the abdominal cavity.

BOWEL ROTATION



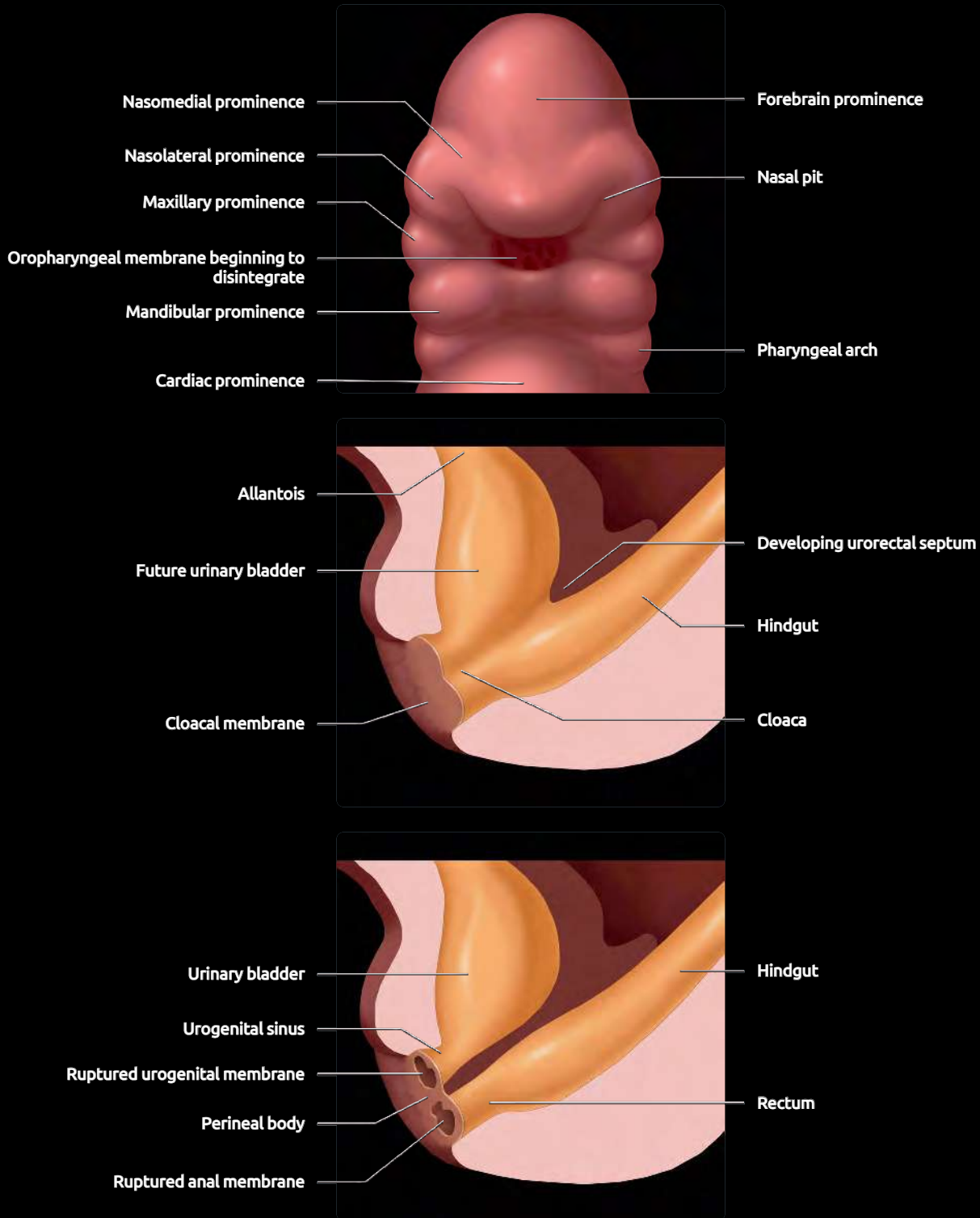
(Top) The primary gut begins to elongate along with its dorsal mesentery. The hepatic diverticulum gives rise to the biliary tree and ventral pancreas. The arterial supply to the gut is already defined: Celiac artery (foregut), superior mesenteric artery (midgut), and inferior mesenteric artery (hindgut). **(Middle)** The liver expands within the ventral mesentery, which later disintegrates, leaving only the falciform ligament and the lesser omentum. The primary gut elongates and herniates out into the umbilical cord. **(Bottom)** The liver continues its rapid enlargement. Only the caudal part of the ventral mesentery remains (falciform ligament). The dorsal mesogastrium elongates, forming the left and caudal portions of the lesser sac. The gut continues to elongate and rotates counterclockwise (as viewed from the front) around the superior mesenteric artery within the dorsal mesentery. The urogenital sinus has separated from the rectum and anus. Common developmental errors include midgut malrotation, omphalocele, and imperforate anus.

BOWEL ROTATION



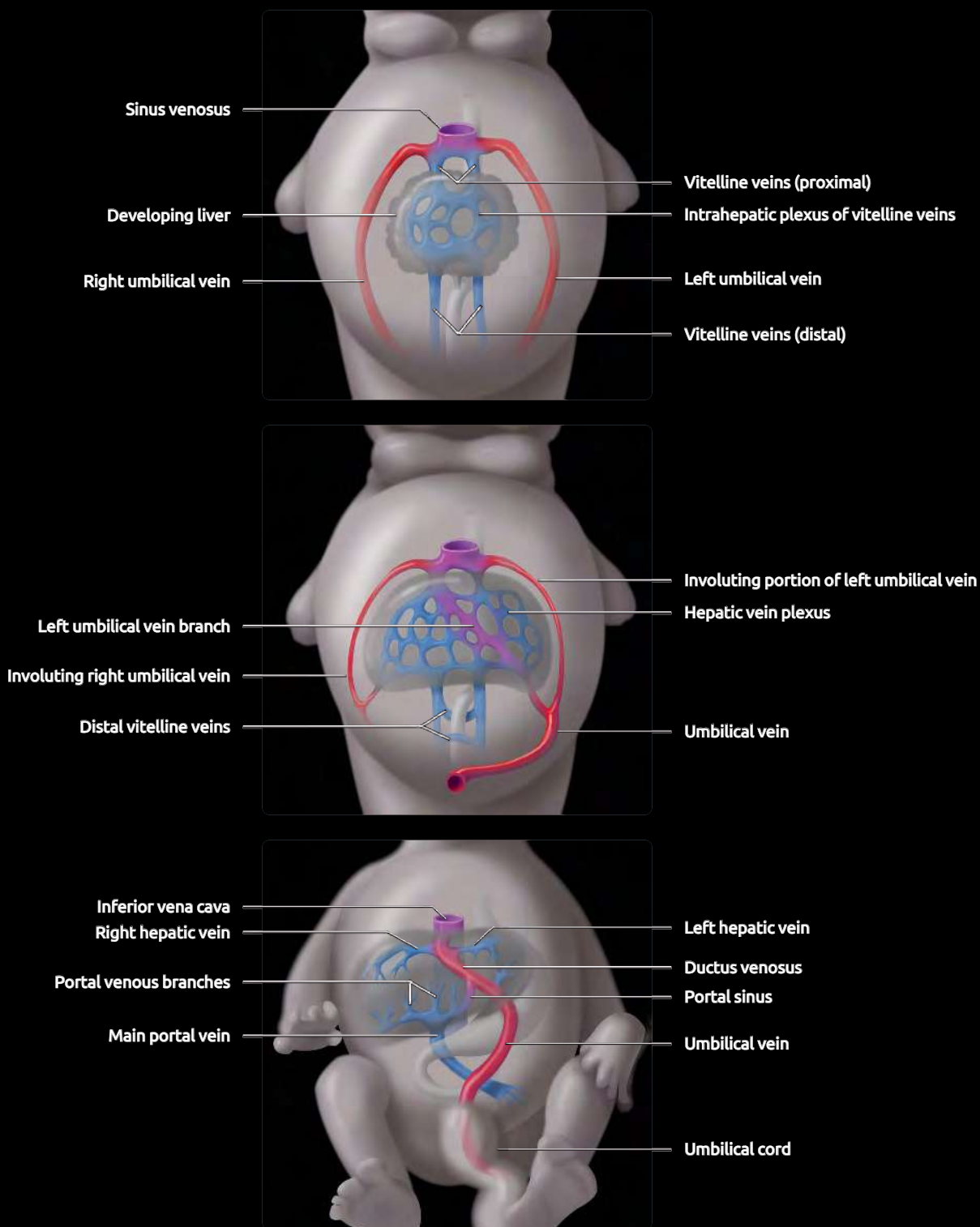
(Top) The umbilical vein enters the liver along the caudal (free) edge of the falciform ligament. The leaves of the greater omentum elongate to the left and caudally, expanding the lesser sac and covering the transverse colon and small intestine. **(Middle)** At 10 weeks post conception (12 weeks by LMP) the small intestine has returned to the abdomen. The yolk stalk, which connected the yolk sac to the primitive gut, is disintegrating. The cecum is the last part to return and continues to rotate in a counterclockwise direction until reaching the right lower quadrant. Errors in development include persistence of a part of the yolk stalk (Meckel diverticulum) and errors of bowel rotation. **(Bottom)** By 4- to 5-months gestation, the ascending and descending colon are fixed in a retroperitoneal location by fusion of their mesocolons to the posterior abdominal wall. The small bowel and transverse and sigmoid colon remain intraperitoneal, suspended by their respective mesenteries.

MOUTH AND ANUS FORMATION



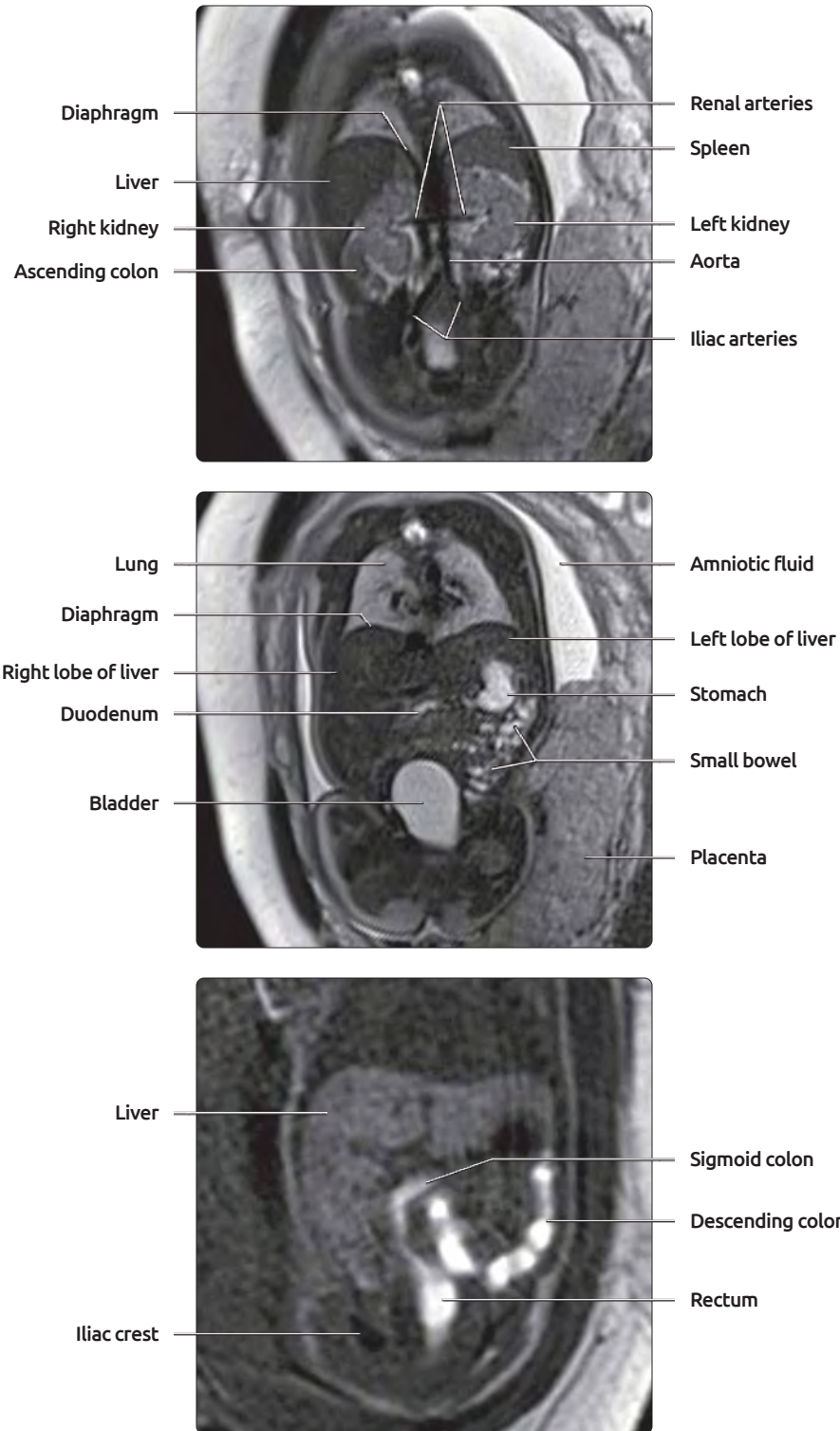
(Top) The endoderm and ectoderm are separated by mesoderm in all areas of the gut except for the oropharyngeal and cloacal membranes. These are areas of mesodermal deficiency, which upon disintegrating became the oropharyngeal cavity and area of the urethra and anus, respectively. This graphic shows the beginning of disintegration of the oropharyngeal membrane in the 4th week. The stomodeum, or primitive mouth, is the result. **(Middle)** During the 6th to 7th weeks, a mesodermal shelf called the urorectal septum begins to grow between the hindgut and allantois, toward the cloacal membrane. It fuses with the cloacal membrane, dividing it into the anal and urogenital membranes, and forms the perineal body. **(Bottom)** By the end of the 8th week the anal membrane ruptures, allowing access from the hindgut to the exterior of the body. The urethra forms within the urogenital sinus.

LIVER, PORTAL AND HEPATIC VEINS



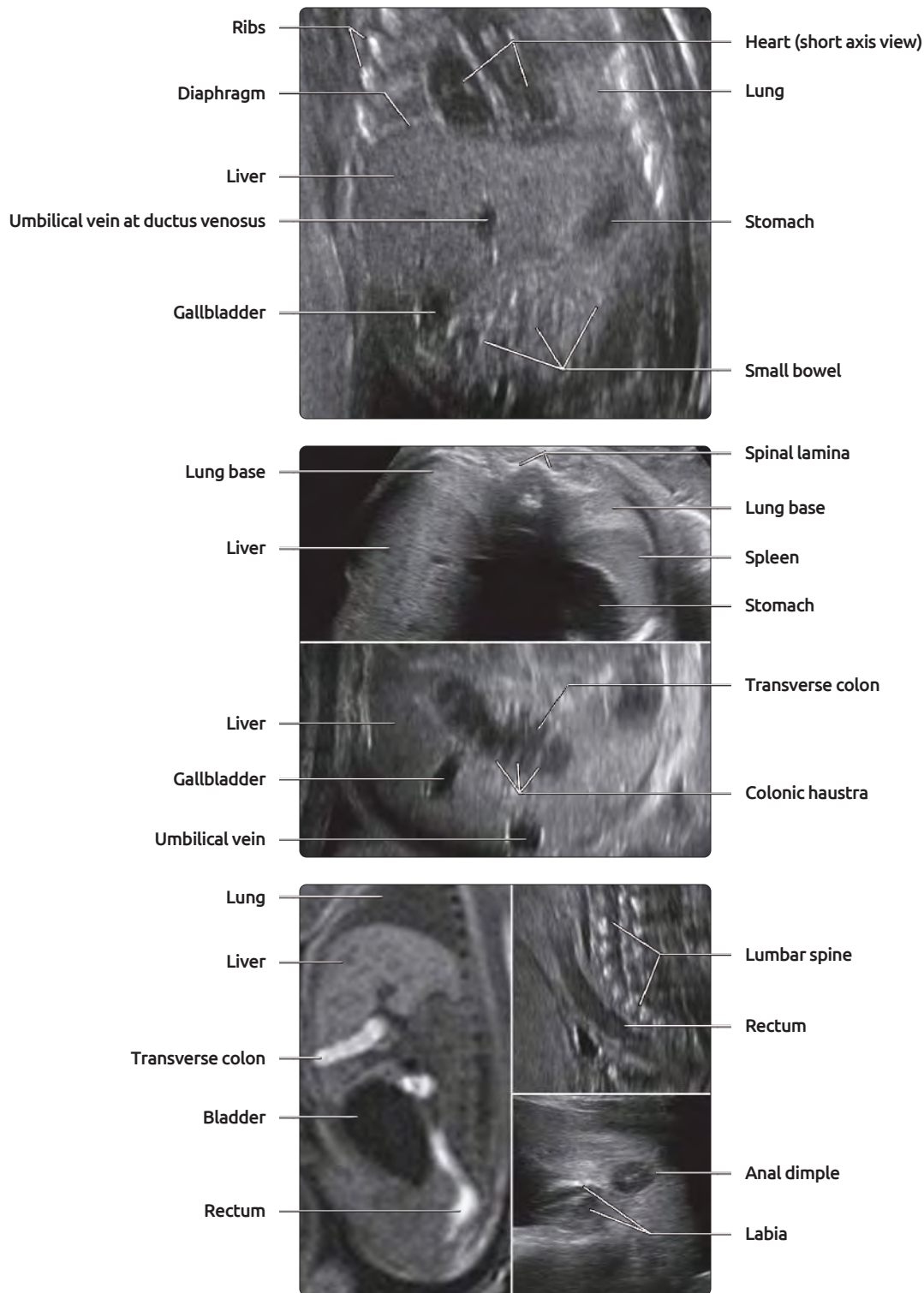
(Top) The vitelline veins return blood from the yolk sac and branch within the liver to form the hepatic sinusoids and venous system. They unite again to form the proximal vitelline veins, which join with the (initially) paired umbilical veins to enter the sinus venosus of the heart. **(Middle)** All of the right and much of the left umbilical veins atrophy. The left umbilical vein sends a large branch to the liver, which anastomoses with the plexus derived from the vitelline veins. The extrahepatic (distal) vitelline veins form the precursors to the portal venous system. **(Bottom)** The portal sinus diverts some oxygenated blood to the liver. The proximal parts of the vitelline veins have become the hepatic veins, returning blood from the liver to the heart. The distal parts have developed into the portal venous system, returning blood from the gut to the liver sinusoids.

FETAL ABDOMEN MR IMAGING



(Top) Coronal T2WI MR through the level of the kidneys shows a portion of the ascending colon, which has a low to intermediate signal intensity, blending into the surrounding soft tissues. Both the liver & spleen are very low in signal intensity & are easily identified. **(Middle)** More anteriorly, the liver crosses the midline & is the main contributor to the abdominal circumference measurement. The lungs are higher in signal intensity. Fluid-filled structures, including the bladder, stomach, & small bowel, are very high signal intensity. Because of its excellent contrast resolution, MR is ideally suited for evaluating the contents of a diaphragmatic hernia. **(Bottom)** While T2WI MR is the primary sequence in evaluating most fetal anatomy, T1WI is particularly helpful for evaluating the colon as meconium is high in signal intensity & is obvious on this sequence. Also note the higher signal of the liver parenchyma on T1WI compared to T2WI. In addition to evaluating the colon, T1WI is valuable for evaluating for blood products, which are often high in signal intensity.

FETAL ABDOMEN ULTRASOUND



(Top) Coronal ultrasound in a 20-week fetus shows the anatomy of the upper abdomen. **(Middle)** Subtle differences in echogenicity allow the identification of the various organs, as shown in this composite image of a 3rd-trimester fetus. The upper oblique axial image shows the lungs are mildly hyperechoic compared to the liver and spleen. Changes in echotexture often provide clues regarding any pathologic process in a given organ. The lower image is an oblique coronal US of the transverse colon. US can show detailed anatomy, such as the colonic haustra. **(Bottom)** Anorectal malformations are a complex group of anomalies that require a complete evaluation of the colon down to the anus. Sagittal T1WI MR (left) shows normal rectal tapering. Following the colon on ultrasound (top right) is somewhat more difficult, but the anal dimple image (bottom right) of the perineum should be performed in any case of suspected anorectal malformation. It has a classic doughnut or target appearance with a thick, hypoechoic sphincter and hyperechoic mucosa.

Imaging Techniques and Normal Anatomy

Transabdominal Ultrasound

Guidelines set forth by the American Institute of Ultrasound in Medicine (AIUM) outline the minimum number of images to be obtained during evaluation of the abdomen in the midtrimester and beyond. A more detailed assessment is required in a fetus with anomalies. Structures that should specifically be evaluated include **the stomach, kidneys, bladder, umbilical cord insertion site, and umbilical cord vessel number** (the normal appearance of the kidneys and bladder are reviewed in the approach to the genitourinary system). The diaphragm, esophagus, small intestine, colon, gallbladder, and liver should also be examined but is not required as part of the standard midtrimester scan.

The **stomach** is seen as a fluid-filled structure in the left upper quadrant. Document that the heart and stomach are on the same side and it is the anatomic left (normal situs). The stomach changes in size and shape during the exam; fluid may intermittently be seen to enter the duodenal bulb but should never persist.

Fluid must be visualized on both sides of the umbilical cord in a transverse section of the fetal abdomen in order to consider the **insertion site** intact. Stimulation of fetal movement may be necessary to create a more favorable acoustic window, especially in the third trimester when the fetal knees are often tucked up against the abdominal wall. The normal cord contains two arteries and one vein. These may be visible at the cord insertion site, but the easiest way to confirm a three-vessel cord is to use color Doppler to document the umbilical arteries as they run on either side of the bladder.

The **diaphragm** appears as a thin, arched, hypoechoic band. It is imperative that it be completely imaged from front to back, which is best done in the sagittal plane. If only viewed in the anterior coronal plane, a congenital diaphragmatic hernia may be missed.

The **esophagus** is not normally seen on fetal imaging. In the setting of esophageal atresia, a fluid-filled tubular structure may be seen in the fetal neck. Real-time evaluation will clarify whether or not this is persistent. Remember to use color Doppler to ensure that the fluid-filled structure is between the neck vessels. Also be aware that normal fetal swallowing may cause intermittent distension of the oropharynx.

In the early midtrimester, bowel loops may not resolve as distinct "tubes"; the **bowel** is seen as the intermediate echogenicity "filler" between the solid organs, bladder, and stomach. In the third trimester, it is normal for the **meconium-filled colon** to be seen as a hypoechoic tubular structure. The **anal dimple** can be seen on an axial view through the perineum; the anal mucosa is echogenic and is surrounded by the hypoechoic muscles of the anal sphincter.

The fetal **liver** is relatively large and extends across the upper abdomen with the left lobe anterior to the stomach. Both portal and hepatic veins can be seen as well as the confluence of the umbilical vein with the left portal vein. The **gallbladder** may be seen, especially in the third trimester, and should not be confused with an abdominal cyst.

Transvaginal Ultrasound

Transvaginal scanning provides higher resolution images than can be obtained transabdominally. This can be very helpful when the fetus is small and when a potentially lethal

malformation, such as body stalk anomaly, is being considered.

3D Ultrasound

3D ultrasound allows the acquisition of a volume set through the fetus, which then can be manipulated offline. Data can be displayed as serial "slices," similar to CT or MR; surface-rendered views are very useful to provide a "realistic" view of the fetus when counseling families regarding potential outcomes of large or unusual abdominal wall defects.

Doppler Ultrasound

Any apparent cyst should always be examined with Doppler to ensure that it is not a vascular structure. Evaluation of the ductus venosus waveform is used in first-trimester screening for aneuploidy and is an early indicator of a potential cardiac anomaly. In the midtrimester and beyond, ductus venosus Doppler is used to monitor cardiac strain in fetuses with growth restriction as well as in cases with high output (e.g., the pump twin in twin-twin transfusion syndrome or mass such as a sacrococcygeal teratoma).

Doppler evaluation helps with the differential diagnosis of intraabdominal masses. A suprarenal mass with a feeding vessel from the aorta is an extralobar sequestration, whereas a mass that has "speckled" flow and no feeding vessel is more likely to be a neuroblastoma. Serial Doppler assessment is used to monitor vascular lesions such as an umbilical vein varix.

Magnetic Resonance Imaging

Atypical abdominal wall defects, unusual abdominopelvic or abdominal wall masses, and complex laterality disturbances, such as heterotaxy syndromes, lend themselves well to evaluation by fetal MR. T2WI sequences provide excellent soft tissue contrast and are best for anatomic detail. Solid organs, particularly the liver, spleen, and kidneys, are very well demonstrated. The stomach and small bowel are fluid-filled and therefore of high signal intensity on T2WI.

T1WI sequences are excellent for looking at high-signal meconium and the presence of blood products. The course of the colon is easily followed, adding valuable information when an anorectal malformation is being considered.

Fetal tumors are rare but important to recognize. The prognosis varies with the type. The soft tissue contrast resolution afforded by MR often allows better evaluation of the organ of origin, as well as the extent of an intraabdominal mass, than does ultrasound alone.

Approach to Abdominal Wall

Is Cord Insertion Site Normal?

A normal cord insertion site excludes the majority of abdominal wall defects. Rarer schisis defects of the body wall away from the umbilical area may not be seen in this view alone.

Is Abdominal Wall Intact?

Extrusion of abdominal contents is seen in abdominal wall defects. **Gastroschisis**, the most common type, is generally located to the right of the umbilical cord insertion, and is not covered by membrane. The small bowel is the most commonly extruded organ, although the stomach, large bowel, and other structures may also be involved. Liver involvement is uncommon; when present it predicts a worse prognosis.

Omphalocele involves extrusion of the bowel into the base of the umbilical cord. The mass is covered by a membrane onto which the cord is inserted. The small bowel is usually involved,

and liver is also commonly seen. Some omphaloceles may be "giant," measuring larger than the fetal abdomen. Rarely, an omphalocele may rupture; in these cases it may be difficult to distinguish from gastroschisis. Remember there is normal physiologic herniation of bowel in the first trimester but any bowel seen outside the abdomen after 12 weeks is abnormal.

Chromosome abnormalities and other structural anomalies may be seen with gastroschisis, but they are much more common in omphalocele where they negatively impact the prognosis. An omphalocele containing only small bowel is at particular risk for aneuploidy. A careful search for other structural anomalies is essential in all cases of abdominal wall defects.

Abdominal wall defects may also be seen in unusual locations.

- Low, suprapubic mass may be associated with **bladder or cloacal exstrophy**; both will have absent bladder but cloacal exstrophy will also have extruded bowel appearing as elephant trunk sign
- Supraumbilical defect associated with diaphragmatic and cardiac abnormality is seen in **pentalogy of Cantrell**
- Other unusual or bizarre schisis defects may be seen in cases of **amniotic bands or body stalk anomaly**

Is Fetus Freely Mobile?

The diagnosis is almost certainly **body stalk anomaly** if the fetus is "stuck" to the placenta. The umbilical cord is absent or very short in this condition. A fetus entrapped within **amniotic bands** may also be tethered in one position.

Are There Linear Echoes in Amniotic Fluid?

Strands of membrane or associated defects, such as unusual facial or cranial clefts, add weight to the diagnosis of **amniotic band syndrome** in a fetus with abdominoschisis.

Approach to Gastrointestinal Tract

What is Abdominal Situs?

Part of the initial orientation is the ascertainment of left and right sides of the fetus. This should be reconfirmed upon the identification of any potential nonsymmetrical anomalies. The fetal stomach is normally located in the upper abdomen on the left. If in the midline (rare) or on the right, there may be an isolated **abdominal situs abnormality** or a more complex case of heterotaxy. Likewise, the position of the liver and gallbladder may be clues to disordered laterality. The larger lobe of the liver should be on the fetal right. A midline or predominantly left-sided liver may be seen in **heterotaxy**. The specific anatomy of the cardiac atria defines whether or not a laterality abnormality is associated with heterotaxy.

Is Abdomen Normal in Size?

Per AIUM guidelines, the **abdominal circumference (AC)** is measured at the skin line on a "true transverse view at the level of the junction of the umbilical vein, portal sinus, and fetal stomach when visible." The AC is utilized with other biometric parameters in the calculation of the fetal weight/average gestational age. It is also useful in the determination of fetal growth abnormalities.

By itself, the AC often provides information about fetal growth abnormalities. An AC below the normal range is often seen in fetuses with poor growth, including fetal growth restriction. Asymmetrical growth with preservation of head and long bone size can be seen in situations involving poor placental function. A small abdomen is often seen in cases where the normal abdominal contents are outside the

abdomen, such as in gastroschisis, or up in the chest, as in diaphragmatic hernia.

An AC above the normal range may be seen in cases of fetal overgrowth (e.g., macrosomic fetus of a diabetic mother). The AC is also often increased in fetuses with large abdominal masses, dilated bowel, or distended bladder. Overgrowth syndromes such as Beckwith-Wiedemann may also exhibit increased AC size, primarily due to enlarged kidneys and liver.

Is Stomach Seen?

The stomach can often be seen in the first trimester and should reliably be identified after about 14-weeks gestation. If not, short-term follow-up is required to confirm its presence or absence. True absence of the stomach is exceedingly rare. When the gastric fundus is not seen within the abdomen after more than one exam, it is most commonly due to a proximal GI obstruction (e.g., esophageal atresia). A neurologic abnormality that prevents normal swallowing may also result in a persistently small or "absent" stomach. Associated polyhydramnios is commonly seen in the third trimester.

When the stomach is not seen within the fetal abdomen, it is important to ensure that it is not in an abnormal location, such as within the chest in a diaphragmatic hernia. It is equally important to remember that seeing the stomach in the abdomen does not exclude the diagnosis of a diaphragmatic hernia.

Is Stomach Normal in Size and Shape?

A persistently **small stomach** may be seen in cases of decreased swallowing, or in esophageal atresia with a tracheoesophageal fistula in which some filling of the stomach is possible through the fistula.

A very **large stomach** may sometimes be a transient finding or may be seen in evolving, distal GI obstructions. The so-called double bubble sign is indicative of an obstructed duodenum, most commonly from **duodenal atresia**. Polyhydramnios, often severe, is a common association late in gestation.

Is There Mass in Abdomen?

Masses in the abdomen should be characterized as to their location and appearance (cystic, solid, or complex; vascular or nonvascular) as this information will help in the development of the differential diagnosis. **Cystic masses** in the abdomen are relatively common.

- Large midline cystic mass in lower abdomen in late first trimester may be enlarged bladder due to **lower urinary tract obstruction** such as posterior urethral valves or prune-belly syndrome; megacystis is also described as early sign of trisomy 18
- Unilateral simple or complex cystic mass in female fetus in third trimester is frequently benign **ovarian cyst** and often requires no treatment
- **Dilated loops of bowel** may appear cystic and may be associated with atresias; focal dilated loops may result from in utero **volvulus**; irregular cystic mass with echogenic "rind" is commonly seen in **meconium pseudocyst** secondary to bowel perforation
- Other cystic masses associated with bowel may be due to duplication or mesenteric cysts
- Anterior cystic mass in pelvis contiguous with upper bladder and umbilicus may be due to **patent urachus**; these may also have associated allantoic cyst of umbilical cord

- Persistent **cloaca** occurs when genitourinary tract and colon never separate; typically associated with septated vagina, which is markedly distended and has fluid-fluid level created by mixing of urine, vaginal secretions, and meconium; can be differentiated from bladder, which changes size and contour during scan and contains only anechoic urine

Solid masses are less common; the differential diagnosis starts with the organ of origin. The most common liver mass is a congenital hemangioma, which usually has prominent vascularity. Solid suprarenal masses may be due to neuroblastoma or extralobar sequestration. Fetus-in-fetu is a mixed solid/cystic mass and is often quite large. The bulk of a sacrococcygeal teratoma is exophytic but it is important to quantify the intraabdominal extent, as this is part of the staging criteria and influences prognosis.

Are There Calcifications in Abdomen?

The differential diagnosis for calcification in the abdomen also depends on the location. Focal calcifications **in the liver** may be in a mass, whereas diffuse calcifications are most often seen with intrauterine infection, most commonly cytomegalovirus.

Calcifications **on the surface of the liver** are actually in the peritoneum; these correlate strongly with intrauterine bowel perforation. Look for associated echogenic or dilated bowel loops, small amounts of ascites, &/or meconium cysts to add weight to this diagnosis.

Calcifications **in the bowel lumen** indicate admixture of meconium and urine in the setting of abnormal distal bowel and bladder development. These "meconium marbles" roll within the bowel lumen with peristalsis. Look carefully for the anal dimple to detect associated anal atresia.

Does Bowel Appear Echogenic?

A high-frequency transducer may give the false impression of echogenic bowel; confirm that the finding is persistent with a lower frequency transducer (< 5 MHz) prior to an extensive work-up. The bowel is not considered echogenic unless it is **as bright as bone**. There are several causes of echogenic bowel to consider. With a history of recent bleeding in pregnancy, it may be due to fetal **ingestion of blood**. This resolves without

intervention. Causes that require further investigation include **aneuploidy, intrauterine infection (viral), cystic fibrosis**, and early bowel abnormalities such as **atresia**, before the bowel becomes dilated. Echogenic bowel may indicate **ischemia** in association with severe growth and hemodynamic stress as in twin-twin transfusion.

Is There Ascites?

Care should be taken to differentiate true ascites from **pseudoascites**. Pseudoascites is a potential pitfall created by the abdominal wall musculature that is seen as a very hypoechoic line just under the skin; it does not outline the umbilical vessels at the cord insertion site.

Ascites may be the first sign of **impending hydrops** in a fetus at risk due to alloimmunization, sustained tachycardia, or other causes of cardiac decompensation. It is essential to search for other evidence of hydrops, as this may negatively impact long-term prognosis. A fetus with a known vascular tumor, such as teratoma, who develops ascites is at risk for in utero demise due to **high-output failure**. In these cases, the gestational age and type of tumor will determine what therapeutic options may be available.

Ascites may also result from **perforation of an abdominal viscus**, either bowel or bladder.

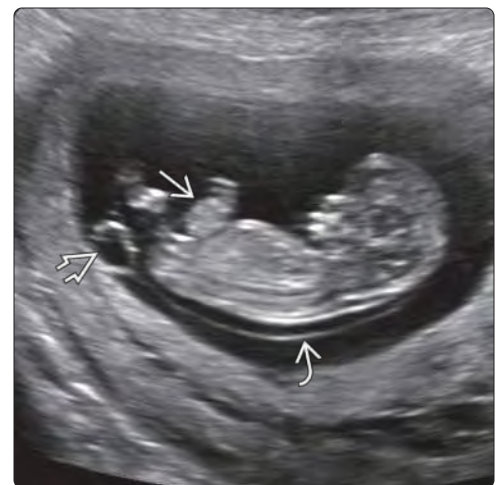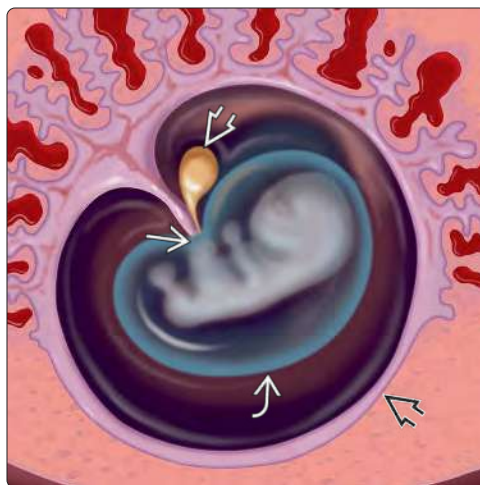
Clinical Implications

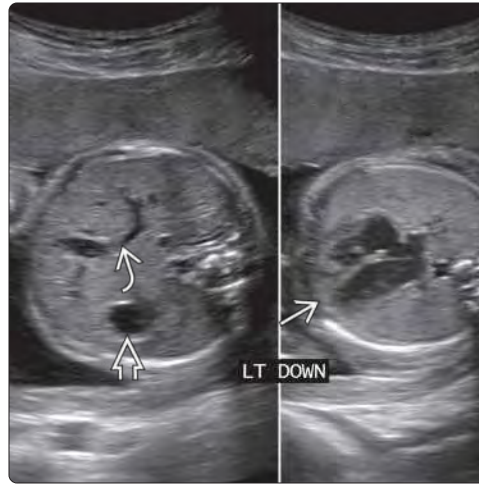
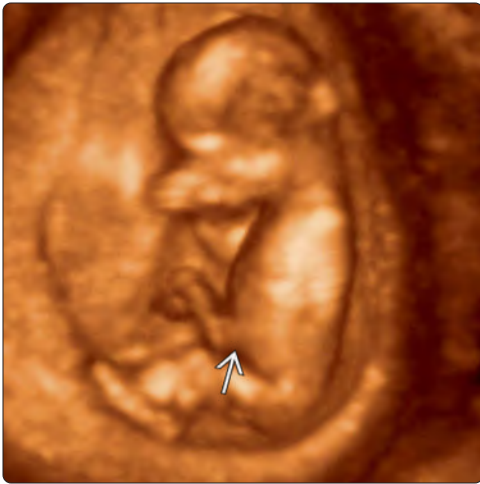Fetal GI malformations are common and it is imperative to make the correct the diagnosis to appropriately counsel parents. Some malformations described may be lethal (e.g., body stalk anomaly) to survivable with major morbidity (e.g., cloacal extrophy) to surgically correctable with good prognosis (e.g., uncomplicated gastroschisis).





Selected References

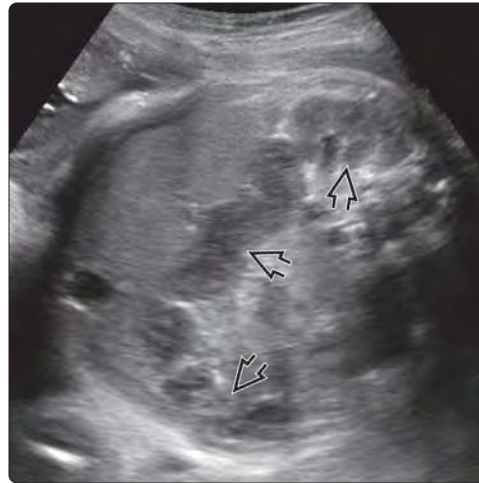
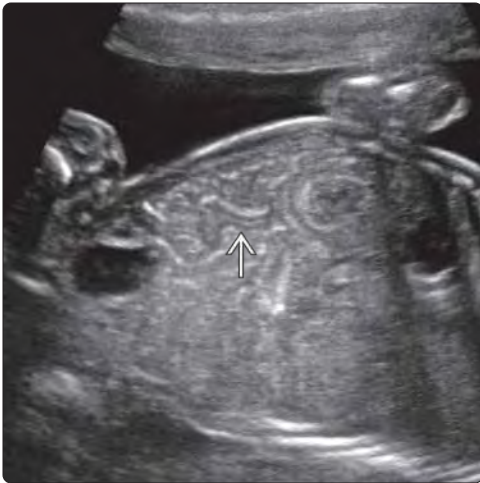1. American Institute of Ultrasound in Medicine: AIUM practice guideline for the performance of obstetric ultrasound examinations. *J Ultrasound Med.* 32(6):1083-101, 2013



(Left) Graphic shows physiologic bowel herniation into the base of the developing umbilical cord. The amnion and chorion are seen as distinct structures with the fetus in the amniotic cavity and the yolk sac within the chorionic cavity. **(Right)** Sagittal US of a 10-week fetus shows the same features, including prominent physiologic herniation of bowel, the amnion and yolk sac. You must be familiar with this normal appearance to avoid erroneously calling an abdominal wall defect.

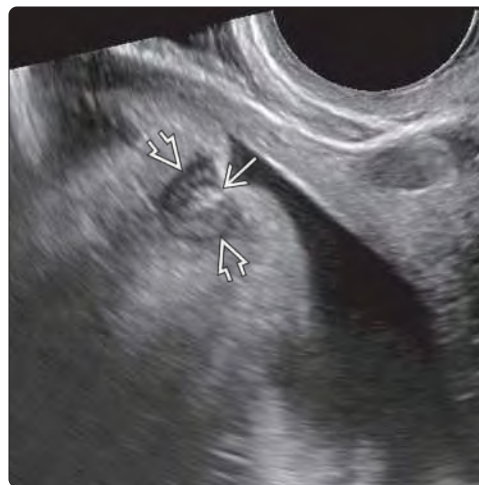
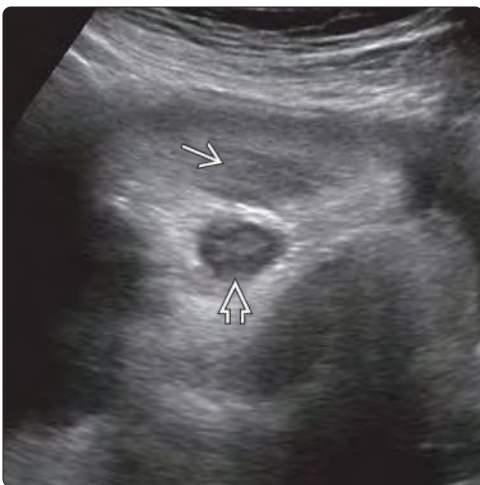







(Left) 3D US at 12 weeks shows a normal cord insertion site  with bowel having completely returned to the abdomen. (Right) The 1st step in fetal evaluation should be to determine which is the anatomic left and right of the fetus. This fetus is in cephalic presentation with the spine to the maternal left; therefore, the left side is down and both the cardiac apex  and stomach  are on the same side (situs solitus). This is also the correct level for the AC measurement with the C shape  of the umbilical vein and portal sinus.

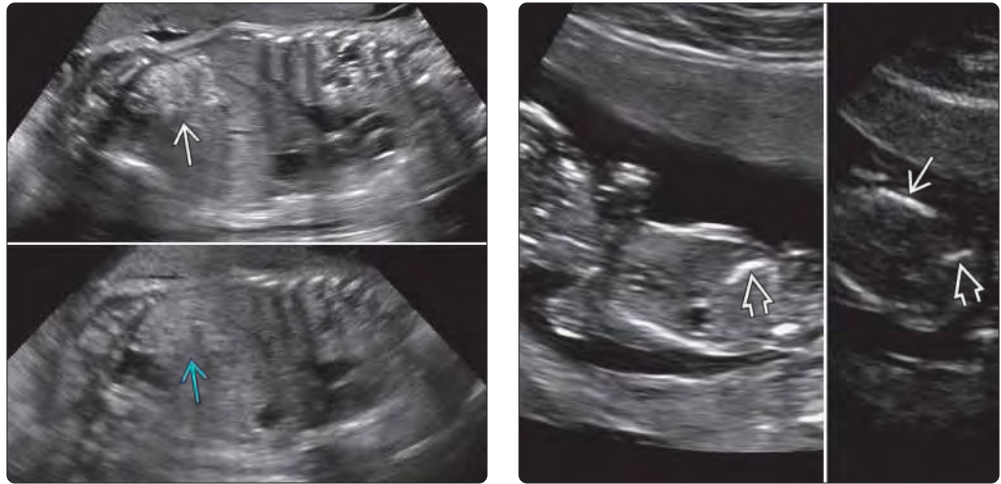


(Left) This high-resolution US of the bowel at 19 weeks shows the tubular morphology with the gut signature of hypoechoic muscular walls and hyperechoic mucosa . (Right) By the 3rd trimester, fluid can be seen peristalsing within the small bowel and meconium is seen within the colon. The colon can appear quite prominent , as shown in this 37-week fetus. If there is any question regarding anal atresia, it is important to document the anal dimple.

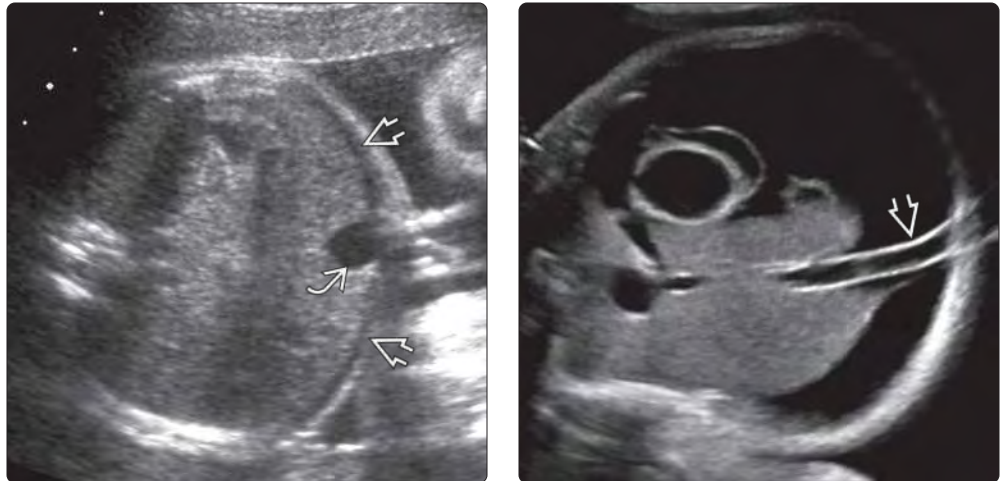


(Left) Axial US of the perineum shows the anal dimple  having a doughnut or target appearance with hyperechoic mucosa. The dimple is seen in the midline between the gluteal muscles; note the linear muscle fibers . (Right) Transvaginal US in a breech presentation fetus shows a coronal view of the anorectal complex in detail. There is a normal external indentation at the anal sphincter, with the muscular layered appearance of the rectal wall  and hyperechoic mucosa .

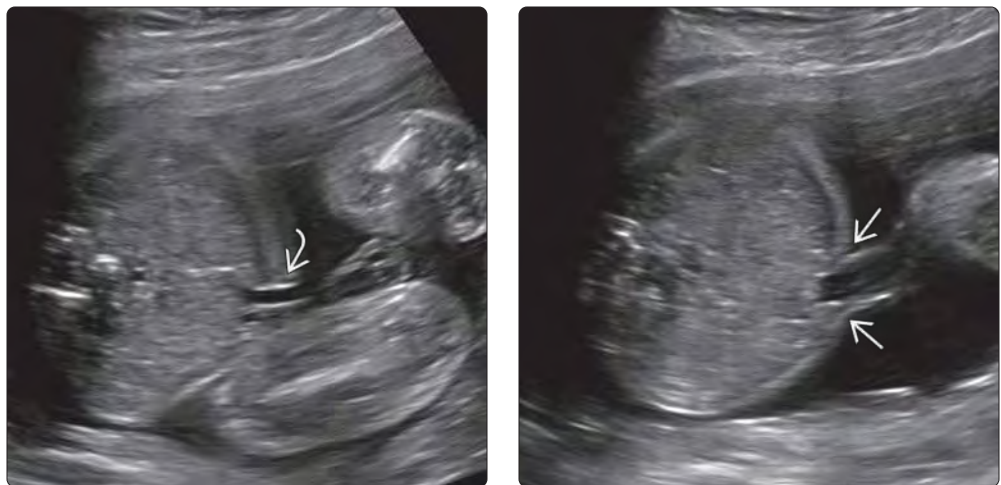
(Left) This composite shows the importance of transducer frequency. The bowel at 6 MHz (top) looks echogenic but at 4 MHz (bottom) does not. High frequencies provide much more detail (note you can see individual bowel loops) but be aware that the bowel may appear hyperechoic. **(Right)** For bowel to be considered abnormally echogenic, it should be as bright as bone. A good method of determining this is to turn the gain down as shown on the right. The soft tissues are suppressed but the bowel is as bright as the rib.

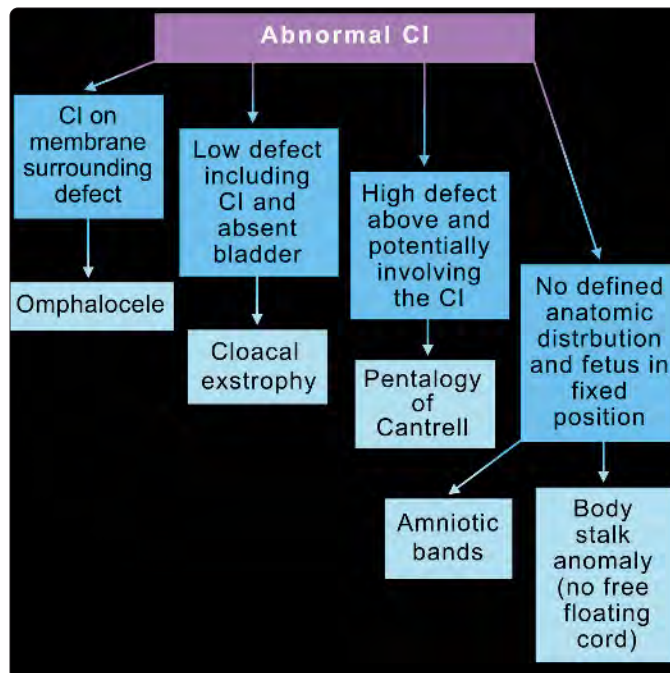
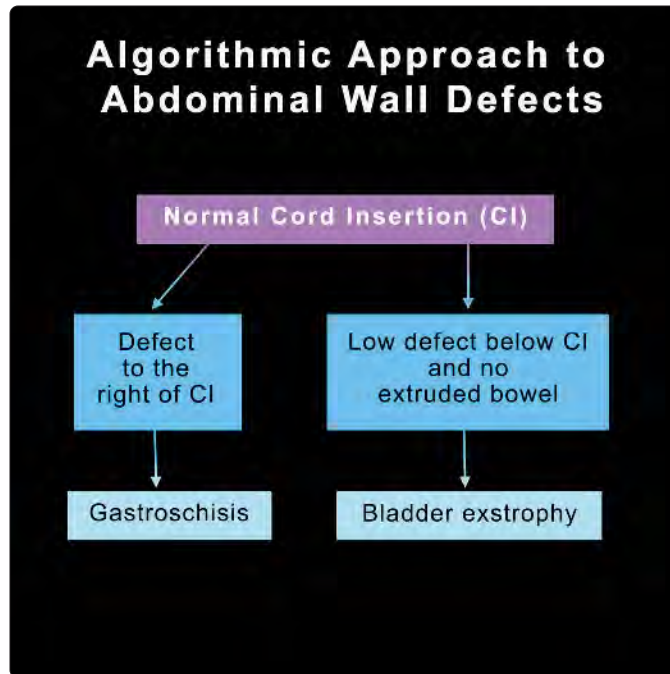


(Left) Axial US shows an example of pseudoascites created by the hypoechoic abdominal wall musculature. Note that the hypoechoic line stops abruptly at the cord insertion site and does not surround the intraabdominal portion of the umbilical vein. **(Right)** In this case of urinary tract ascites from a bladder rupture, fluid clearly outlines both sides of the umbilical vein.



(Left) The umbilical cord insertion is only seen on one side, with the fetal leg obscuring the down side. The cord insertion site cannot be cleared unless skin is seen on both sides. **(Right)** This image a few minutes later clearly shows both sides of the insertion site. Abdominal wall defects form a complex array of anomalies, and analysis of the cord insertion site in respect to the defect is important in making the correct diagnosis.





(Top) This flow chart gives an algorithmic approach to evaluating abdominal wall defects based on the location of the defect in regards to the umbilical cord insertion site. If the cord inserts normally on the abdominal wall and the defect is on the right, the diagnosis is gastroschisis. If the defect is below the cord insertion, no bladder is seen, and there is no extruded bowel, the diagnosis is bladder exstrophy. **(Bottom)** Cord insertion in an abnormal location is a more complicated grouping of diagnoses depending on where the cord inserts and additional findings. Omphalocele is the most common, with the cord inserted on the sac. Cloacal exstrophy is a complicated anomaly with not only an absent bladder but extruded bowel that has been described as appearing like an elephant's trunk. Pentalogy of Cantrell is a high defect, often involving the heart and diaphragm. Both amniotic bands and body stalk anomaly should be considered for nonanatomic "slash" defects.

KEY FACTS

TERMINOLOGY

- Bowel herniation through right paramedian abdominal wall defect
- Simple gastroschisis most common
- Complex gastroschisis (12-15%)
 - Dilated bowel, extruded liver, other anomalies

IMAGING

- Normal umbilical cord insertion (UCI) + extruded bowel
 - No covering membrane
 - Color Doppler best to show UCI
- Extracorporeal bowel dilation is common (88%)
- Intraabdominal bowel dilation more predictive of bowel pathology
 - > 14 mm associated with ↑ rates of atresia (29%)
- Note appearance of bowel wall
 - Thick, echogenic, matted, nodular
- Oligohydramnios more common than polyhydramnios
- Can make diagnosis in 1st trimester (> 12 weeks)

TOP DIFFERENTIAL DIAGNOSES

- Omphalocele
- Body stalk anomaly
- Amniotic band syndrome
- Cloacal exstrophy
- Physiologic gut herniation

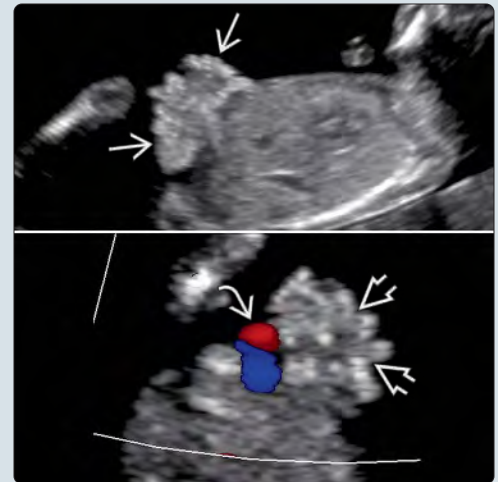
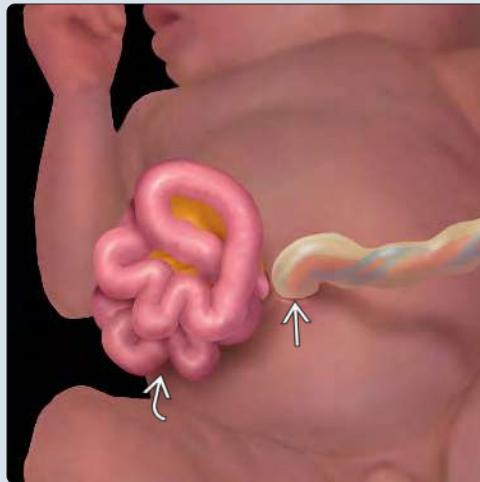
PATHOLOGY

- Most are sporadic, no specific genetic defect

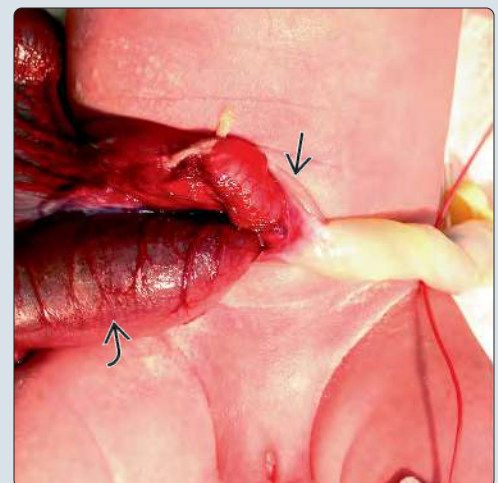
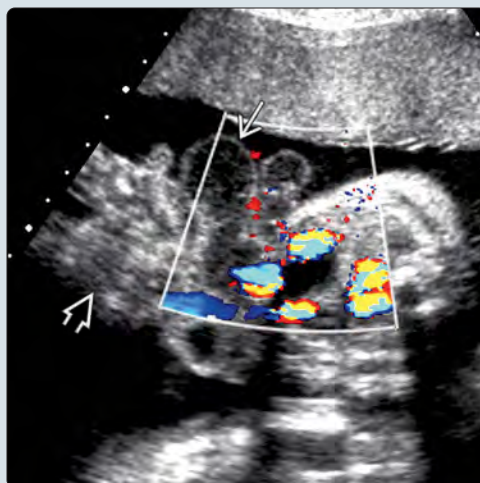
CLINICAL ISSUES

- Anomaly associated with young maternal age
- Survival for simple gastroschisis approaches 100%
- Complex gastroschisis mortality rates 28-50%
- Complications
 - Intrauterine fetal demise (4-5%)
 - Fetal growth restriction (25%)
 - Bowel atresia (15%)
 - Short gut syndrome, motility disorders (15%)

(Left) Graphic of gastroschisis shows an abdominal wall defect with herniation of small bowel. The defect is to the right of the normally inserted umbilical cord. (Right) Since physiological bowel herniation is reduced by 12 weeks, gastroschisis is detectable in the late 1st trimester. Extracorporeal bowel is seen well in this 13-week fetus. Amniotic fluid separates several loops of bowel, proving the lack of a covering membrane. In addition, the cord inserts on the abdominal wall, and the defect is paramedian.



(Left) Ultrasound of a midtrimester fetus with gastroschisis shows a large amount of extruded bowel. Some bowel is decompressed, while several loops are dilated. Extracorporeal bowel dilation is not predictive of bowel health. (Right) Clinical photograph of an infant with gastroschisis shows the typical appearance of the defect with the herniated bowel to the right of the umbilical cord insertion. Note the dilated bowel.



TERMINOLOGY**Definitions**

- Full-thickness paramedian abdominal wall defect
 - Almost always right-sided defect
- Simple gastroschisis most common
 - No additional anomalies, no significant bowel dilation
- Complex gastroschisis (12-15%)
 - Dilated bowel, extruded liver, other anomalies

IMAGING**General Features**

- Best diagnostic clue
 - Normal umbilical cord insertion (UCI) + extruded bowel
 - Large amount of bowel "out" is typical
 - Small bowel always involved
 - Large bowel often involved
 - Stomach and bladder may externalize
 - Rarely with extracorporeal liver
 - No covering membrane

Ultrasonographic Findings

- Grayscale ultrasound
 - Bowel dilation (> 7 mm considered dilated)
 - Extracorporeal bowel dilation is common (88%)
 - Not predictive of bowel atresia
 - Progressive as pregnancy advances
 - Intraabdominal bowel dilation (IABD) more predictive of bowel pathology
 - > 14 mm associated with ↑ rates of atresia (29%)
 - IABD < 14 mm with 91% negative predictive value for atresia
 - Bowel wall appearance
 - Thickened, echogenic, matted, nodular
 - 2° chemical peritonitis from amniotic fluid exposure
 - Fibrinous, serosal deposit "peel"
 - Associated with ileus, atresia, other bowel pathology
 - Stomach often malpositioned
 - Stomach "pulled" toward UCI
 - Stomach may externalize (intermittent or permanent)
 - Oligohydramnios more common than polyhydramnios
 - Polyhydramnios suggests atresia or obstruction
 - Fetal growth restriction (FGR) common
- Pulsed Doppler
 - Evaluation of superior mesenteric artery not predictive of bowel health and fetal outcome
 - Abnormal umbilical artery flow associated with FGR, bowel obstruction, fetal demise
- Color Doppler
 - Shows UCI best

MR Findings

- T2WI
 - High signal in exteriorized bowel loops
- Helpful when visualization compromised
 - Maternal obesity, oligohydramnios
- Helpful to evaluate suspected additional anomalies
 - Especially brain anomalies

Imaging Recommendations

- Can make diagnosis at time of nuchal translucency screening
 - Differentiate physiologic bowel herniation (at UCI base) from gastroschisis (right paramedian)
- Imperative to see abdominal wall on both sides of UCI at time of anatomy scan
- Close surveillance for fetal compromise in 3rd trimester
 - Developing FGR leads to early delivery
 - Biophysical profile and fetal monitoring
 - Progressive bowel dilatation is typically seen
 - Acute bowel complications rarely lead to early delivery
 - Volvulus with resulting bowel ischemia
 - Evidence for bowel rupture
 - Oligohydramnios more common than polyhydramnios

DIFFERENTIAL DIAGNOSIS**Omphalocele**

- Central abdominal wall defect + peritoneal cover
 - Most often, liver is "out" + some bowel
 - UCI is on omphalocele sac (sometimes eccentric)
- "Bowel only" omphalocele may mimic gastroschisis
 - Bowel is not "free-floating," UCI on sac
- Associated with aneuploidy
 - Other structural anomalies more common
- Ruptured omphalocele is rare
 - Difficult to differentiate from gastroschisis

Body Stalk Anomaly

- Bizarre abdominal wall defect
 - Extruded thoracic contents common
 - Scoliosis common + limb defects
- Fetus adherent to placenta
 - Short umbilical cord
- Almost always lethal

Amniotic Band Syndrome

- Variable in presentation and severity
- Multiple body parts affected
- Often involves head and neck
- "Schisis" defects do not follow normal embryologic lines

Cloacal Exstrophy

- Absent bladder + bowel only omphalocele
- Inferior abdominal wall defect
 - Low UCI + soft tissue mass inferior to UCI
 - Bladder mucosa or divided bladder
- Additional genital and renal anomalies common

Physiologic Gut Herniation

- Bowel returns to abdomen by 11-12 weeks
- Should not extend > 1 cm
- Always midline with UCI at base

PATHOLOGY**General Features**

- Etiology
 - Failed closure of ventral body wall at 5-7 weeks
 - Deficient mesoderm may be etiology of abnormal body wall folding

- Older vascular-related theories less likely
 - Possible exception is associated amyoplasia
- Genetics
 - Most are sporadic
 - ~ 1% recurrence risk
 - Familial cases reported
 - Less common aneuploidy association
 - No specific defect
- Associated abnormalities
 - Malrotated or nonrotated bowel in all cases
 - Nongastrointestinal abnormalities (10-20%)
 - Cardiac anomalies (most common)
 - Central nervous system anomalies
 - Septo-optic dysplasia, cerebral dysgenesis
 - Tethered spinal cord
 - Renal anomalies
 - Limb anomalies
 - Amyoplasia, arthrogryposis
 - Club feet
 - Other gastrointestinal anomalies
 - Hypoplastic gallbladder, Meckel diverticulum
- Intrauterine fetal demise (IUFD) (4-5%)
 - 7-fold ↑ from risk in general population (0.6%)
- FGR (25%)
- Bowel atresia (15%)
 - 29% if IABD is > 14 mm
 - Still 9% if no IABD seen (< 7 mm)
- Necrotizing enterocolitis (2%)
- Bowel perforation
- 10-15% persistent disability
 - Motility disorders
 - Short gut syndrome
 - Prolonged need for parenteral nutrition increases risk for liver disease

Treatment

- No consensus on best practice for time of delivery and time of surgical treatment
 - Wide variability in institutional practice patterns
- Primary closure versus silo
 - Silo < 5 days with similar outcomes as primary closure
 - No effect on age reaching full feedings
 - No effect on overall length of hospital stay
 - Silo > 5 days predictive of multiple poor outcomes
 - Silo use is associated with increased ventilator days
- Vaginal delivery recommended
 - Cesarean delivery for usual indications
 - In general, breech presentation is contraindication to vaginal delivery or external cephalic version due to concern for vascular compromise of bowel
- No consensus on timing of delivery
 - Recent study shows prevalence of IUFD does not ↑ at > 35 weeks
 - Benefit of monitoring at ≥ 36 weeks and delivery at 37 weeks suggested
 - Steroid administration for enhancement of pulmonary maturity considered
- Delivery at tertiary care center
 - Careful control of body fluids and heat loss
 - Increased risk of bowel injury due to improper handling during transport

Gross Pathologic & Surgical Features

- Abdominal defect relatively small (< 5 cm)
- Exposed loops inflamed and edematous
- Atresias
 - Often multiple or long-segment atresias
- Left-sided wall defects very rare

CLINICAL ISSUES

Presentation

- Fetal ultrasound highly sensitive in diagnosis
 - Most often diagnosed at midgestation anatomy scan
 - Can be diagnosed in 1st trimester (> 12 weeks)
- ↑ maternal serum α-fetoprotein in 2nd trimester (95%)
 - Exposed bowel results in greater elevations than omphalocele because of lack of covering membrane

Demographics

- Epidemiology
 - 4.5:10,000 births
 - ↑ incidence from 2.3:10,000 births in 1995
 - Incidence in teenage mothers is 6-10x greater than mothers ≥ 25 years
 - Mean age: 21-22 years old in most studies
 - Other risk factors
 - Tobacco (20-30% smoke)
 - Illicit drug use (6%)
 - Low socioeconomic status
 - Low body mass index

Natural History & Prognosis

- Survival for simple gastroschisis approaches 100%
- Complex gastroschisis mortality rates 28-50%
 - "Liver out" gastroschisis prognosis is grim
 - Most consider lethal if liver involved
- Complications
 - Preterm delivery (most elective)
 - Mean age: 36 3/7 weeks in recent large series
 - < 35-week delivery associated with adverse outcomes

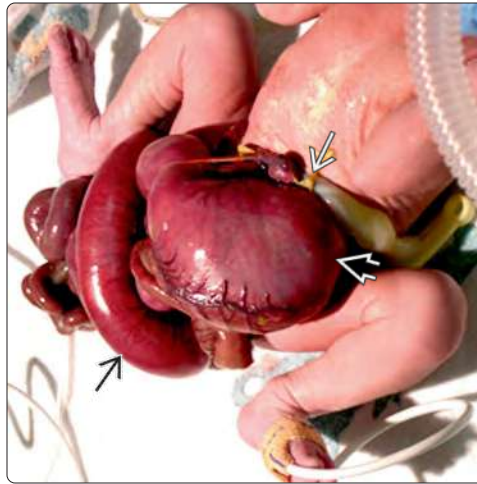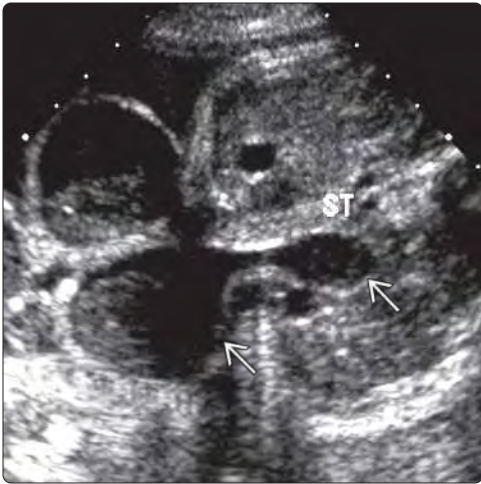
DIAGNOSTIC CHECKLIST





Image Interpretation Pearls

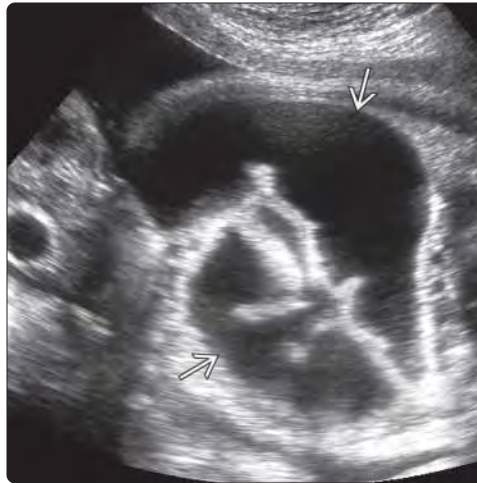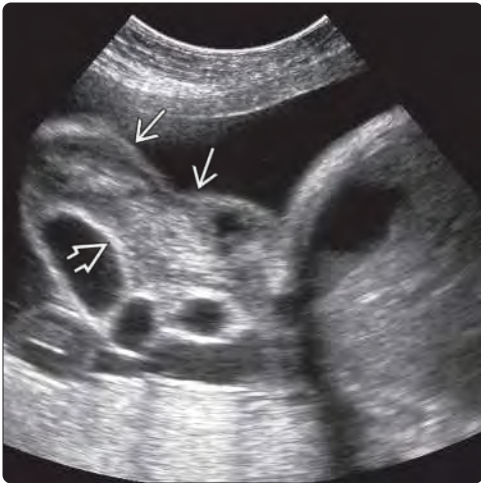
- Polyhydramnios often correlates with bowel complications
- Worsening bowel appearance rarely leads to early delivery
 - Preterm birth and gastroschisis with worse prognosis




SELECTED REFERENCES

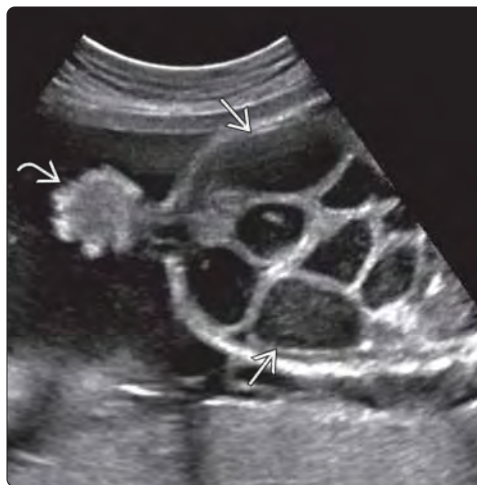
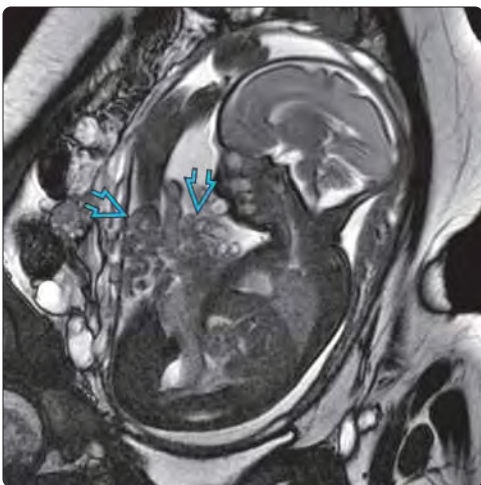
1. Goetzinger KR et al: Sonographic predictors of postnatal bowel atresia in fetal gastroschisis. *Ultrasound Obstet Gynecol.* 43(4):420-5, 2014
2. Lusk LA et al: Multi-institutional practice patterns and outcomes in uncomplicated gastroschisis: a report from the University of California Fetal Consortium (UCFC). *J Pediatr Surg.* 49(12):1782-6, 2014
3. Overcash RT et al: Factors associated with gastroschisis outcomes. *Obstet Gynecol.* 124(3):551-7, 2014
4. Grant NH et al: Elective preterm birth for fetal gastroschisis. *Cochrane Database Syst Rev.* 6:CD009394, 2013
5. South AP et al: Metaanalysis of the prevalence of intrauterine fetal death in gastroschisis. *Am J Obstet Gynecol.* 209(2):114.e1-13, 2013
6. Ajayi FA et al: Ultrasound prediction of growth abnormalities in fetuses with gastroschisis. *J Matern Fetal Neonatal Med.* 24(3):489-92, 2011






(Left) In this 3rd-trimester fetus with gastroschisis, the fetal stomach  herniates through the gastroschisis defect. Stomach herniation is more likely to be seen in the 3rd trimester and may be a transient finding. (Right) Photograph of preterm infant with gastroschisis shows a dilated extruded stomach  and small bowel  to the right of umbilical cord insertion . Stomach herniation is not associated with worse prognosis, but preterm delivery is associated with increased morbidity and mortality.

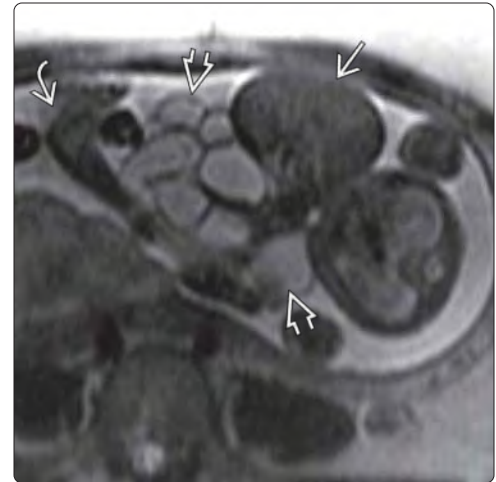
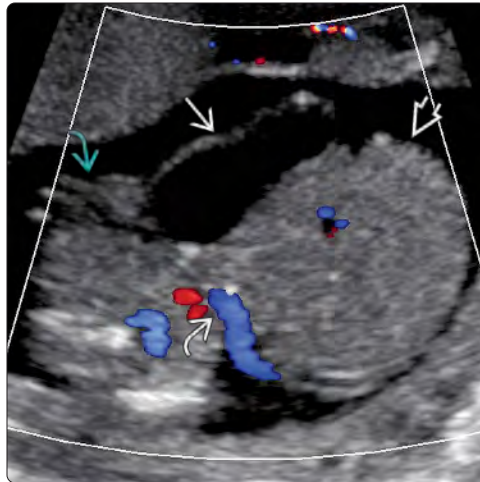


(Left) This extracorporeal bowel is not free-floating. The bowel wall thickness and echogenicity are increased , and a pseudomembrane fibrinous peel encases the extraabdominal bowel . Bowel exposure to amniotic fluid can cause this reaction. (Right) Multiple loops of markedly dilated intraabdominal bowel  were also seen in the same fetus. This US finding is most sensitive for predicting bowel atresias and obstruction. The newborn did have intestinal obstruction from jejunal atresia.

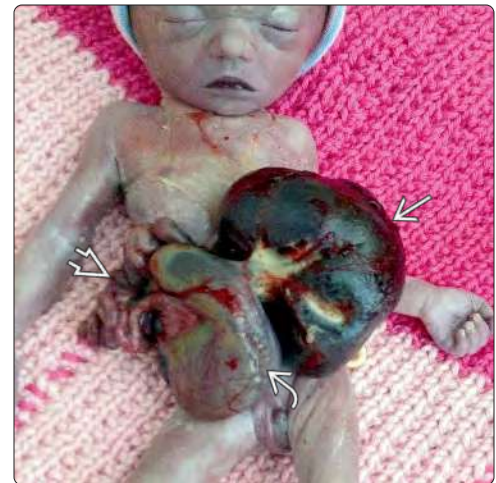
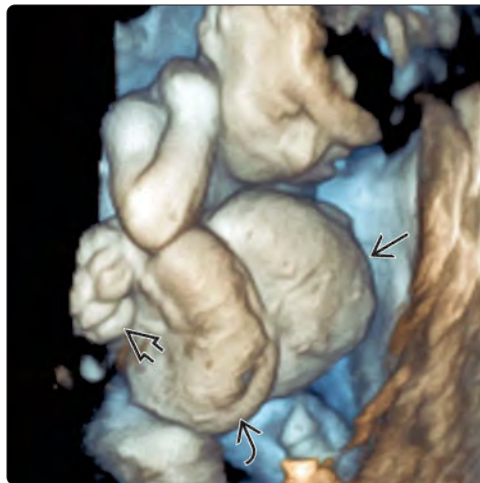
(Left) Sagittal T2WI MR of a fetus with simple gastroschisis shows herniated bowel  without significant dilation. The amniotic fluid was decreased, which is a common association. Polyhydramnios is more predictive of bowel compromise. (From DI: Pediatrics 3e.) (Right) In this fetus with complicated gastroschisis and polyhydramnios, the intracorporeal bowel is markedly dilated , and the extracorporeal bowel is markedly diminutive . This finding is suggestive of significant bowel compromise.

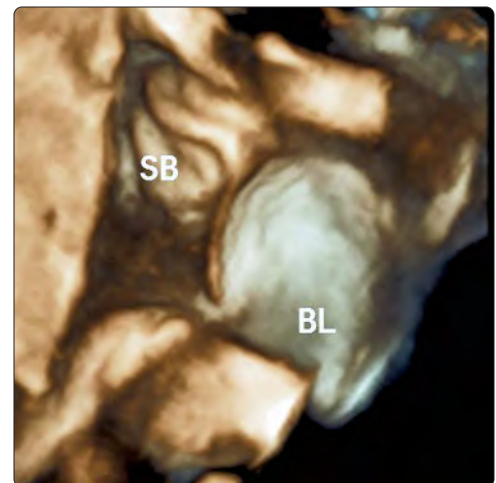
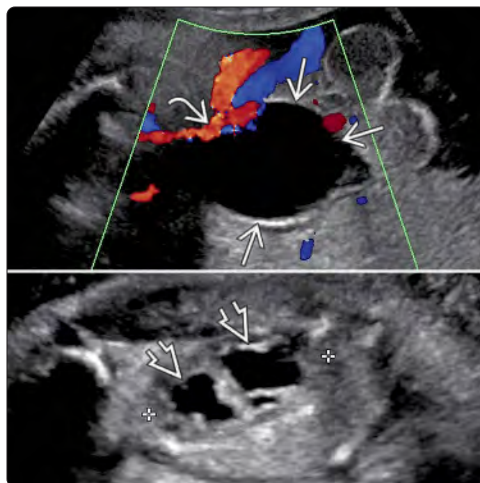
(Left) This fetus was originally diagnosed as having an omphalocele; however, color Doppler shows the cord inserts upon the abdominal wall. The extraabdominal liver, stomach, and small bowel are not covered by a membrane, so this fetus has complex gastroschisis involving the liver. **(Right)** T2WI MR in another fetus with "liver out" gastroschisis shows the additional finding of a club foot. Dilated high-signal, free-floating loops of bowel are seen well on MR. Additional anomalies are seen in a minority of cases.

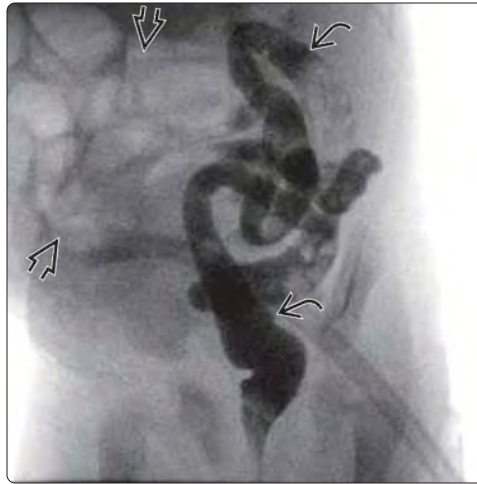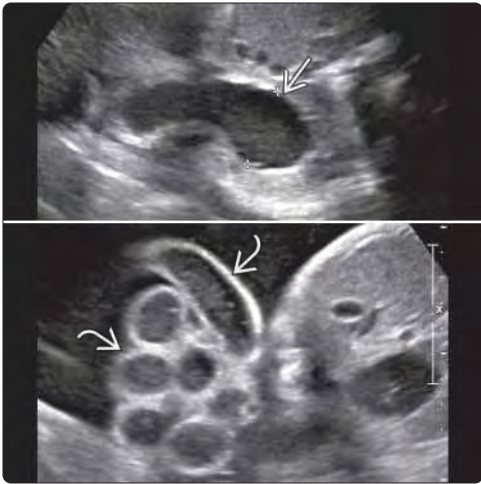


(Left) 3D ultrasound of this fetus with complicated gastroschisis shows most of the liver, stomach, and small bowel are extracorporeal. The prognosis is grim, and most consider this kind of defect a lethal anomaly. When defects are this severe, look carefully for possible amniotic bands. **(Right)** Postdelivery picture of the same fetus confirms findings suspected with ultrasound. The liver, stomach, and small bowel are extraabdominal, and the cord is inserted on the abdomen (not shown).

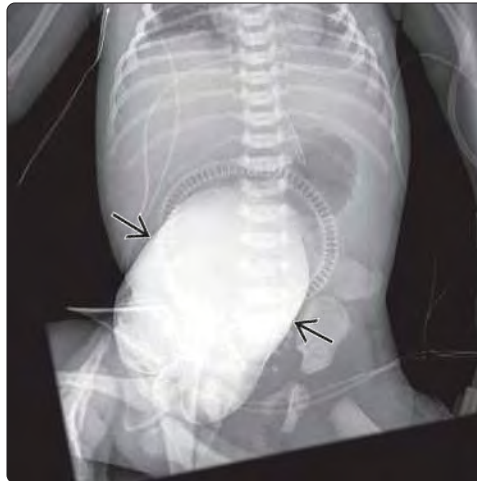
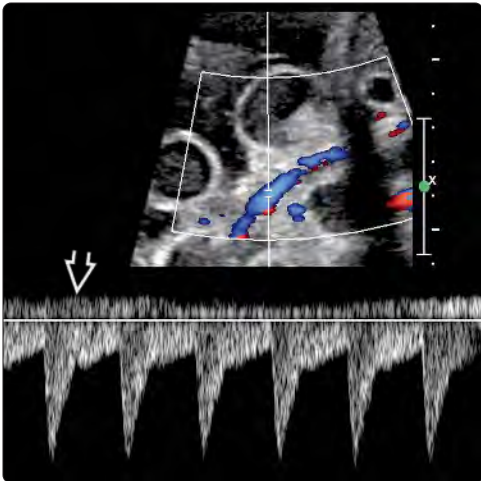


(Left) In this 3rd-trimester fetus, the fetal bladder herniates through the defect, paramedian to the umbilical cord insertion site. Also, there is a duplicated kidney with hydronephrosis. These findings were new for this fetus. After primary surgical reduction, the hydronephrosis resolved. **(Right)** 3D ultrasound of another fetus with extracorporeal bladder (BL) shows nondistended small bowel (SB). Extracorporeal bladder can be a transient finding and is not associated with worse outcomes.

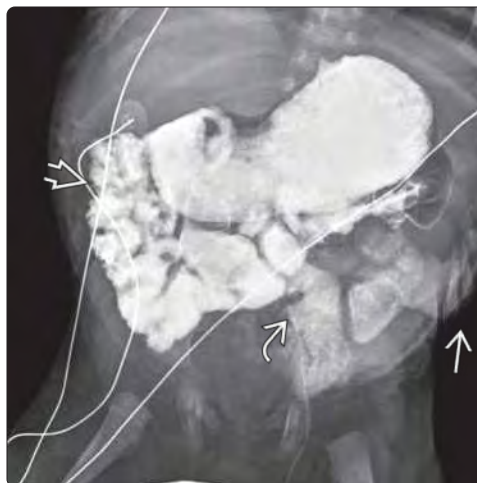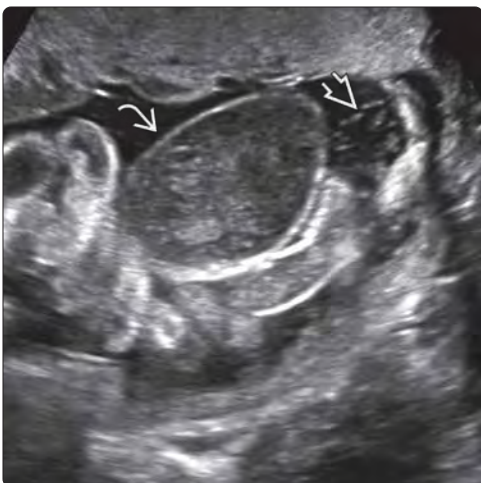




(Left) The fetal stomach is partially externalized in this fetus with dilated extraabdominal bowel. The intraabdominal bowel was otherwise normal. **(Right)** Contrast enema in a newborn with gastroschisis repair and small bowel obstruction shows all the colon in the left abdomen. All fetuses with gastroschisis have some degree of bowel malrotation. In this case, complete malrotation/nonrotation is present; the entire colon is on the left and dilated, gas-filled small bowel on the right.



(Left) Superior mesenteric artery (SMA) flow is seen well in this fetus with gastroschisis. In addition, venous flow is also demonstrated. While SMA flow can be measured, studies have not shown consistent predictive value for evaluating the SMA at this time. **(Right)** A radiopaque silo is seen on a plain film of the abdomen in this newborn with gastroschisis, which could not be immediately reduced. Short-interval use of a silo (< 5 days) has similar results to primary repair cases.



(Left) This 3rd-trimester fetus has a markedly dilated extracorporeal bowel, which resolved on follow-up. Also, progressively increasing echogenic debris in the amniotic fluid was seen, raising concern for bowel rupture. **(Right)** After delivery, the baby needed significant bowel resection, resulting in short gut syndrome. Upper GI shows malrotation (small bowel in right abdomen) and small amount of colon in the left abdomen, draining into a colostomy bag.

KEY FACTS

TERMINOLOGY

- Membrane-covered midline abdominal wall defect with herniation of abdominal contents into base of cord

IMAGING

- Liver + small bowel is most common type
- Bowel-only type with intracorporeal liver
- Omphalocele membrane is peritoneum + amnion
 - Mostly thin but can also be multicystic
- Umbilical cord inserts onto membrane (not always central)
 - Color Doppler best to show cord insertion site
- Ascites is common
- Membrane rupture is complication

TOP DIFFERENTIAL DIAGNOSES

- Physiologic herniation of bowel
- Gastroschisis
- Umbilical cord cysts
- Body stalk anomaly

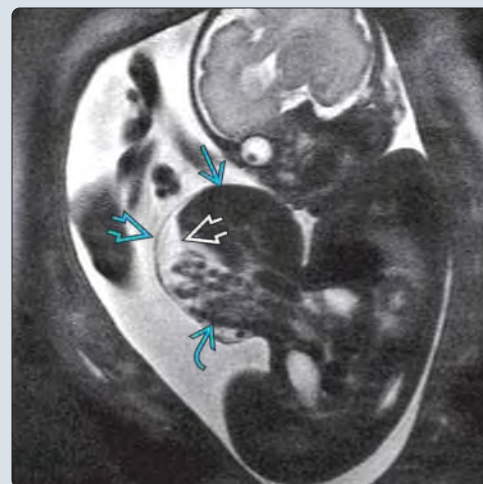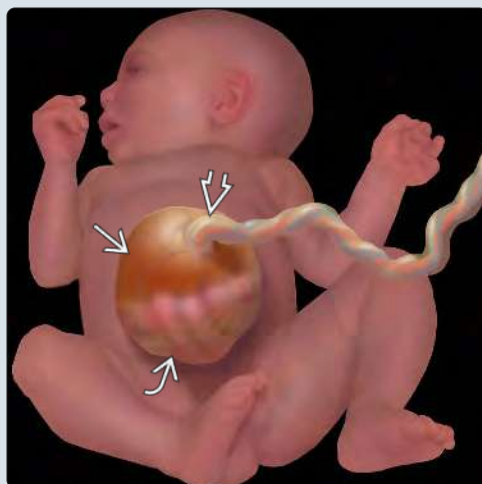
PATHOLOGY

- Associated structural abnormalities are common (25-30% of cases)
 - Chromosomal abnormalities in 30-40%
 - ↑ risk of chromosomal abnormality if defect contains only bowel
 - Cardiac defects: 50% of associated anomalies
 - Gastrointestinal: 40% of associated anomalies
- Syndromes with omphalocele
 - Beckwith-Wiedemann syndrome
 - Pentalogy of Cantrell
 - Cloacal exstrophy/OEIS complex

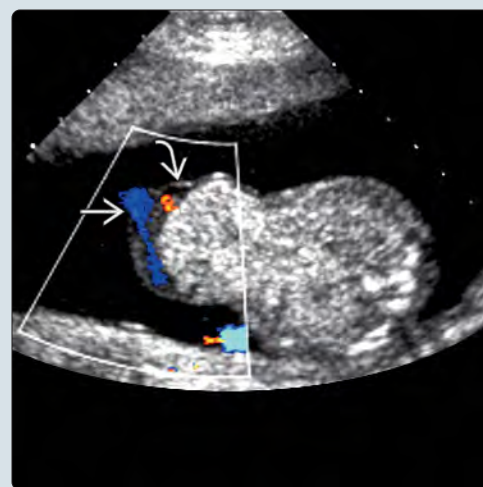
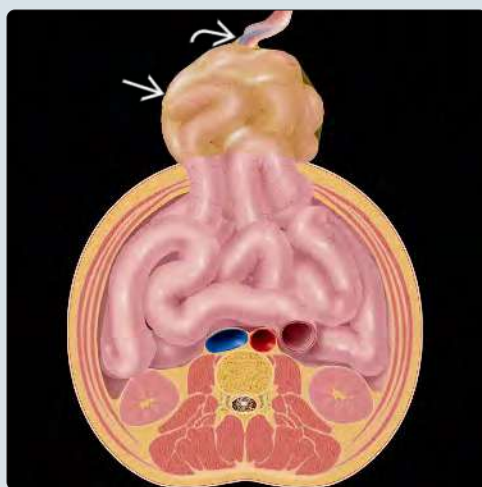
CLINICAL ISSUES

- ↑ premature birth rate
- Survival as high as 80-90% if normal chromosomes, no syndromes, and no other significant anomalies
- Stillbirth and neonatal death rates mostly determined by associated anomalies

(Left) Graphic shows the most common type of omphalocele. A smooth midline abdominal wall defect, with herniation of small bowel and liver, is covered by a membrane and the umbilical cord inserts directly onto the sac. **(Right)** T2WI MR shows typical features of an omphalocele containing liver and small bowel. The defect is covered by a thin membrane. A small amount of fluid within the sac is from ascites, typically present when the liver is extracorporeal.



(Left) The less common type of omphalocele contains only small bowel. This graphic shows the membrane-covered defect, eviscerated small bowel, and umbilical cord insertion upon the membrane. **(Right)** Axial ultrasound shows the typical appearance of an omphalocele containing only bowel (no liver). The cord inserts on the apex of the abdominal wall defect. Parts of the containing membrane are also seen. The bowel is contained, not free-floating as seen in gastroschisis.



TERMINOLOGY

Definitions

- Membrane-covered midline abdominal wall defect with herniation of abdominal contents into base of cord

IMAGING

General Features

- Best diagnostic clue
 - Smooth midline abdominal wall mass
 - Color Doppler shows cord inserts on omphalocele
- Location
 - Central abdominal wall, involving cord insertion site
- Size
 - Varies depending on content of omphalocele
 - Large if liver involved (> 6-8 cm called giant)
 - Small if liver not involved (bowel only)

Ultrasonographic Findings

- Grayscale ultrasound
 - Omphalocele contents seen well with ultrasound
 - Liver + small bowel is most common
 - Larger defects with spleen, bladder, stomach
 - Bowel-only omphalocele
 - Liver is intracorporeal
 - Echogenic content in sac is bowel
 - Look for peristalsis
 - Appearance of eviscerated bowel is generally good because of protection from membrane
 - Omphalocele membrane
 - Peritoneum on inside and amnion on outside
 - Wharton jelly is sandwiched between peritoneum and amnion
 - Mostly thin but can also be multicystic
 - Probably from cystic degeneration of Wharton jelly
 - Membrane rupture is complication
 - Can mimic gastroschisis
 - Contents no longer "protected" from amniotic fluid
 - Bowel wall may thicken and dilate if not protected
 - Umbilical cord inserts onto membrane
 - Usually centrally but can be eccentric
 - Ascites is common
 - Almost always present by 3rd trimester
 - Bowel floating in ascites might mimic floating bowel in amniotic fluid seen with gastroschisis
 - Polyhydramnios is common
- Color Doppler
 - Best to evaluate cord insertion site
 - Use to identify omphalocele contents
 - Hepatic vessels in sac confirm liver involvement
 - Look for ductus venosus in 1st trimester

MR Findings

- T1WI
 - Best for showing if colon is involved
 - Meconium has high signal
- T2WI
 - Liver dark
 - Fluid-filled bowel is bright

Imaging Recommendations

- Best imaging tool
 - Obtain adequate cord insertion site images
 - Show intact body wall in all directions
- Protocol advice
 - Look for fetal cord insertion site at time of nuchal translucency (NT) screening
 - Extracorporeal bowel should not be seen after 12 weeks
 - Liver is never extracorporeal
 - 3D ultrasound can be additive to explain findings to patients and referring providers
- Exclude omphalocele from abdominal circumference (AC) measurement
 - Exclude AC from biometry for dating
 - Inaccurate weight estimates are common
- Perform careful search for other abnormalities
 - Dedicated fetal echocardiography indicated
 - Evaluate for syndromes

DIFFERENTIAL DIAGNOSIS

Physiologic Gut Herniation

- Normal embryologic process prompted by rapid midgut growth in 1st trimester
- Bowel returns to abdomen by 11- to 12-weeks gestation
- Should not extend more than 1 cm
- Liver is never extracorporeal

Gastroschisis

- Paraumbilical abdominal wall defect (> 95% on right)
 - Cord inserts normally on abdominal wall
- No covering membrane: Free-floating loops of bowel
- Rarely involves liver (grave prognosis if liver is "out")

Umbilical Cord Cyst

- Omphalocele and cord cyst often coexist
- Cysts near abdominal wall insertion site can mimic bowel herniation
- 1st-trimester cysts tend to resolve
- **Omphalomesenteric duct cyst**
 - May be associated with omphalocele
 - From omphalomesenteric duct remnant, near fetal insertion site
- **Allantoic cyst**
 - Associated with patent urachus
 - Always near fetal insertion site
- **Wharton jelly cysts**
 - Mucoid degeneration of Wharton jelly
 - Associated with omphalocele (or seen in isolation)

Body Stalk Anomaly

- Fetus adherent to placenta with eviscerated organs
- Hallmark finding is atypical large abdominal wall defect + scoliosis and limb defects
- Short cord is typical: No free-floating loops of cord

Amniotic Band Syndrome

- Multiple body parts affected ("slash" defects)
 - Often involves head and neck
- Defects do not conform to normal embryologic processes

Syndromes With Omphalocele

Syndrome	Major Features
Beckwith-Wiedemann syndrome	Macroglossia, omphalocele, organomegaly, macrosomia,
Pentalogy of Cantrell	High omphalocele, ectopia cordis, intracardiac anomalies, sternal/pericardial/diaphragmatic defects
Cloacal exstrophy/OEIS complex	O mphalocele (often low), B ladder e xstrophy, I mperforate anus, S pine abnormalities

Always look for features of syndromes and chromosomal abnormalities when an omphalocele is seen.

Cloacal Exstrophy/OEIS Complex

- Infraumbilical body wall defect
- Small bowel containing omphalocele often present between bladder halves
- Absent bladder (bladder open to abdominal wall)
- Associated genitourinary and spine anomalies

Umbilical Hernia

- Hernia covered by skin and subcutaneous fat
- Small, bowel-containing omphalocele may be difficult to distinguish from umbilical hernia

PATHOLOGY

General Features

- Etiology
 - Liver containing omphalocele
 - Primary failure of body wall closure (5-8 weeks)
 - Bowel only omphalocele (intracorporeal liver)
 - Failed return of physiologic gut herniation (6-10 weeks)
- Genetics
 - Chromosomal abnormalities in 30-40% in utero
 - Trisomy 18 (most common)
 - Trisomy 13, 21
 - Triploidy
 - Chromosomal abnormalities less common at birth because of in utero demise or termination
 - Syndromes with an omphalocele include: Beckwith-Wiedemann syndrome, pentalogy of Cantrell, OEIS complex/cloacal exstrophy
- Associated abnormalities
 - Associated structural abnormalities are common (25-30% of cases)
 - Cardiac defects: 50% of associated anomalies
 - Gastrointestinal: 40% of associated anomalies
 - Malrotation always present
 - Congenital diaphragmatic hernia, bowel atresias
 - Others: Musculoskeletal, central nervous system, genitourinary

Staging, Grading, & Classification

- 2 general categories
 - Liver containing omphalocele
 - Extensive herniation of other abdominal contents can occur
 - Giant omphalocele if diameter is > 6-8 cm
 - Nonliver containing (bowel only)
 - ↑ association of both structural and chromosomal anomalies
 - Up to 60% aneuploidy rates reported

CLINICAL ISSUES

Presentation

- ↑ maternal serum α-fetoprotein (70%)

Natural History & Prognosis

- Survival as high as 80-90% if normal chromosomes, no syndromes, and no other significant anomalies
- Giant omphalocele with mortality of 25% reported
- ↑ premature birth rate
- Stillbirth and neonatal death rates correlate with associated anomalies
- In utero rupture rare

Treatment

- Delivery at tertiary care facility
- Benefits of cesarean section controversial
 - May be recommended in cases of very large omphaloceles
- Surgical treatment based on size
 - Primary closure if small
 - Delayed surgical closure if large
 - Complete reduction of large omphaloceles can cause harmful elevation of intraabdominal pressure
 - Skin graft and mesh techniques
 - Temporary silo chimney with gradual reduction
- Nonoperative techniques promote granulation and epithelization of sac prior to repair
 - Alcohol, Betadine, mercurochrome dressing changes
 - Silver impregnated hydrofiber dressing is new promising technique with less complications anticipated

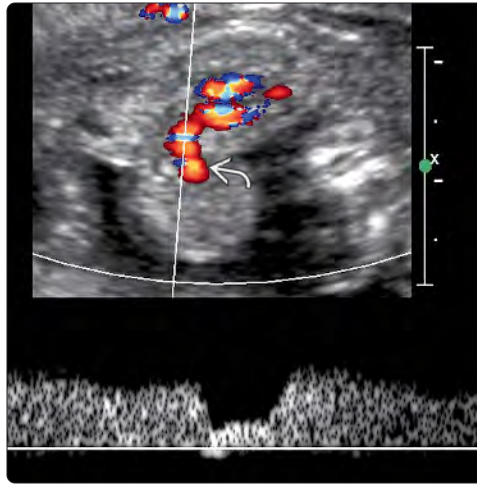
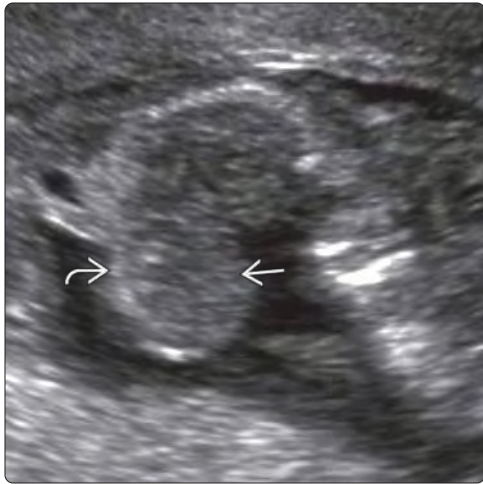
DIAGNOSTIC CHECKLIST

Image Interpretation Pearls

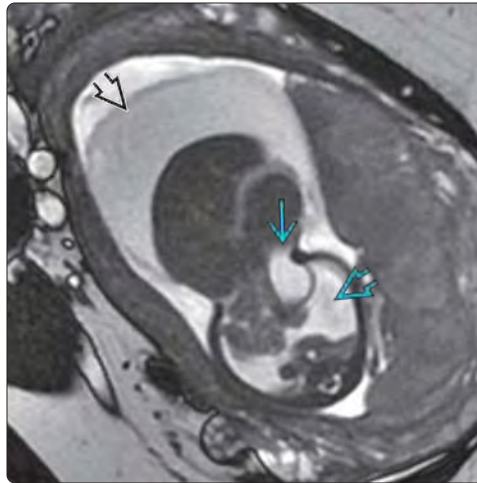
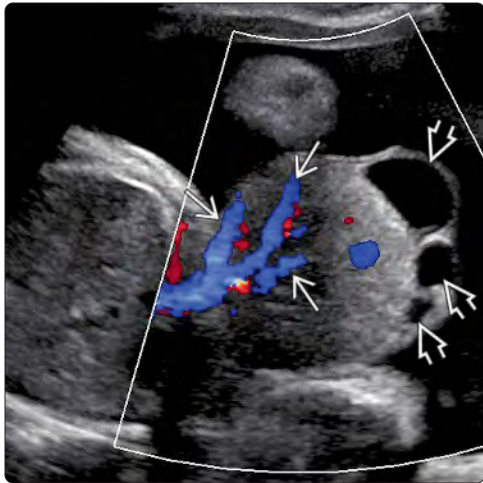
- Look for omphalocele at time of NT screening
- Genetic abnormality and syndrome more likely if liver is not involved
- Offer genetic testing in all cases
- Distinction from gastroschisis is essential in view of associated abnormalities and outcome

SELECTED REFERENCES

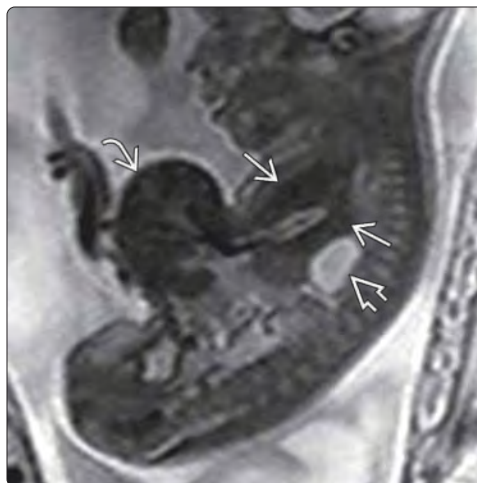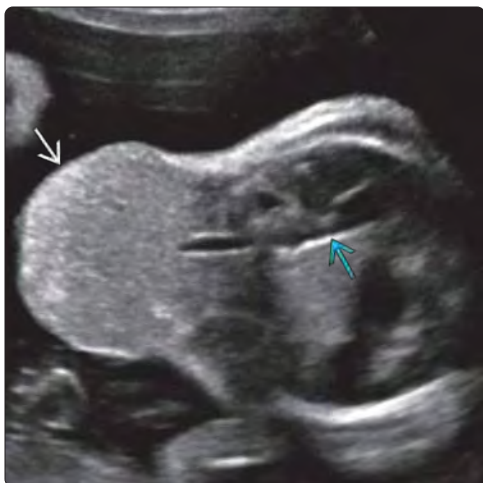1. Oquendo M et al: Silver-impregnated hydrofiber dressing followed by delayed surgical closure for management of infants born with giant omphaloceles. *J Pediatr Surg.* 50(10):1668-72, 2015
2. Pakdaman R et al: Complex abdominal wall defects: appearances at prenatal imaging. *Radiographics.* 35(2):636-49, 2015
3. Torres US et al: When closure fails: what the radiologist needs to know about the embryology, anatomy, and prenatal imaging of ventral body wall defects. *Semin Ultrasound CT MR.* 36(6):522-36, 2015







(Left) An omphalocele was diagnosed in this 11-week, 4-day fetus presenting for nuchal translucency (NT) assessment. The extracorporeal liver **➤** is more hypoechoic than the extracorporeal small bowel **➤**. (Right) Ductus venosus assessment in the same patient confirms that the liver is extracorporeal because the umbilical vein **➤** and ductus venosus (sample volume) are anteriorly displaced. The NT was normal and the patient opted for immediate chorionic villus sampling; the results were normal.

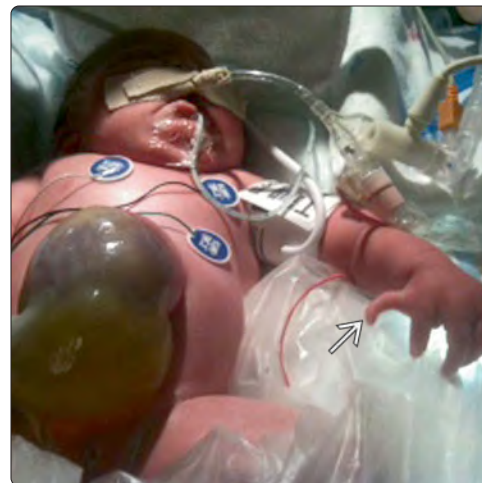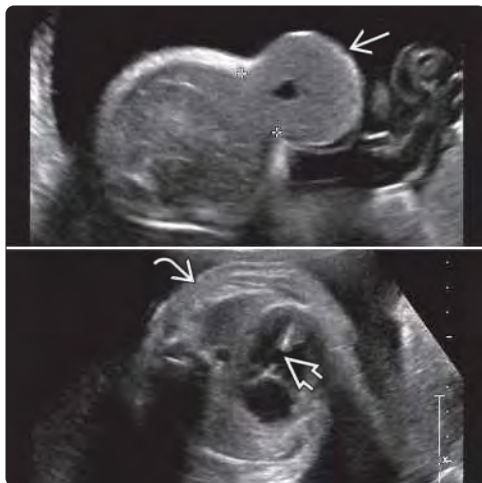




(Left) The hepatic veins **➤** extend into the eviscerated liver in this 34-week fetus with an omphalocele. Also, covering membrane cysts **➤** are seen, most likely from mucoid degeneration of the Wharton jelly located between the peritoneal and amnion layers of the membrane. (Right) In another fetus with a giant omphalocele, part of the stomach **➤** extends into the sac. There is also a large amount of ascites both within the abdomen **➤** and in the sac **➤**. Giant omphaloceles are at risk for rupture.

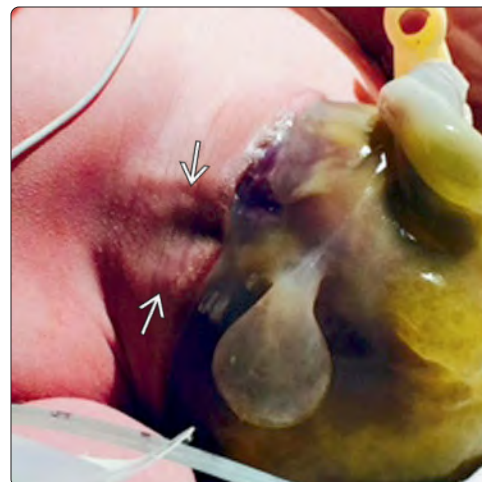
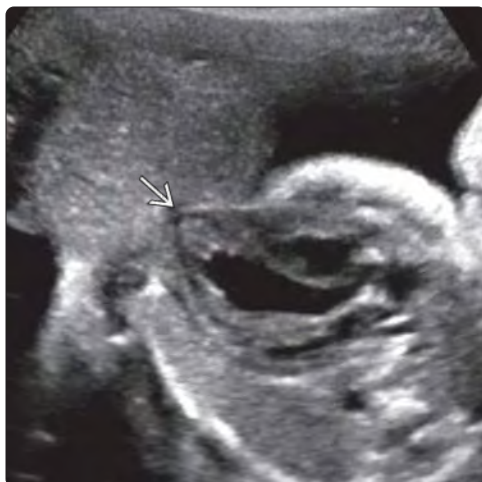





(Left) This fetus with extracorporeal liver **➤** also had shift of the heart into the left chest **➤**, and a concurrent diaphragmatic hernia was suspected. (Right) MR shows the left-sided diaphragmatic hernia to better advantage. The right lobe of the liver is extracorporeal **➤** and the left lobe is in the chest **➤** anterior to the intrathoracic fluid-filled stomach **➤**. Other anomalies, including diaphragmatic hernia, are commonly seen with an omphalocele and impact outcome.

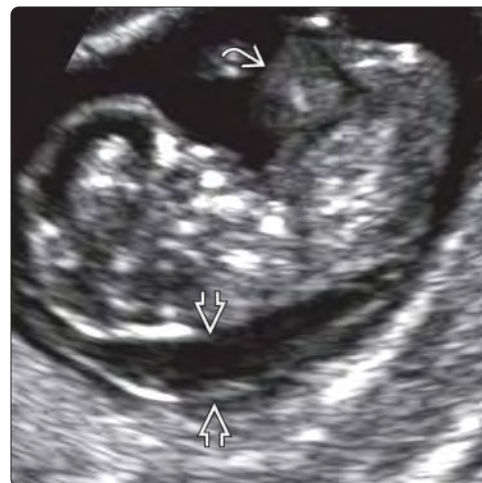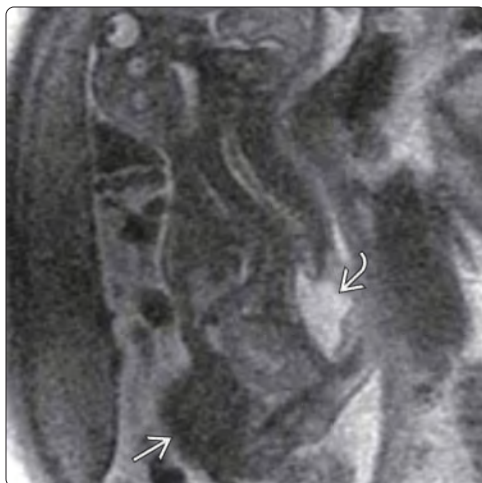
(Left) This fetus with an abdominal wall defect (calipers) and eviscerated liver  also had a cardiac defect (note the large ventricular septal defect ) and skin edema , suggesting early hydrops. (Right) Clinical photograph of the newborn in the same case shows the omphalocele, anasarca, and preaxial polydactyly  (also seen with ultrasound). Karyotype results showed deletion of part of chromosome 18. Chromosome abnormalities are seen in ~ 1/3 of fetuses with omphalocele.

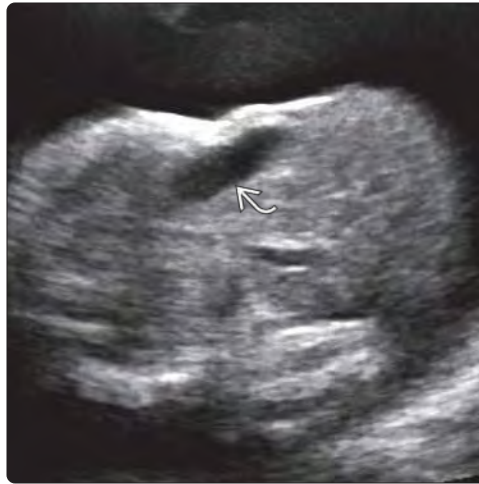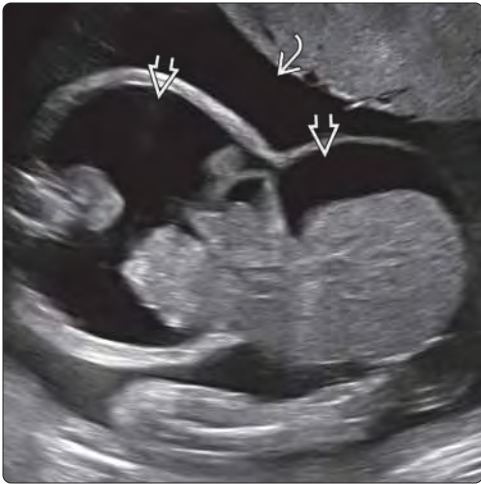


(Left) The apex of the heart  extended into the superior region of the omphalocele in this case. In addition, the omphalocele was more superiorly positioned than usual. These are typical findings of pentalogy of Cantrell, a known association with omphalocele. (Right) Clinical photograph after delivery in the same case shows a skin-covered sternal defect . The beating heart apex was seen in the sac intermittently, as the baby breathed and cried.

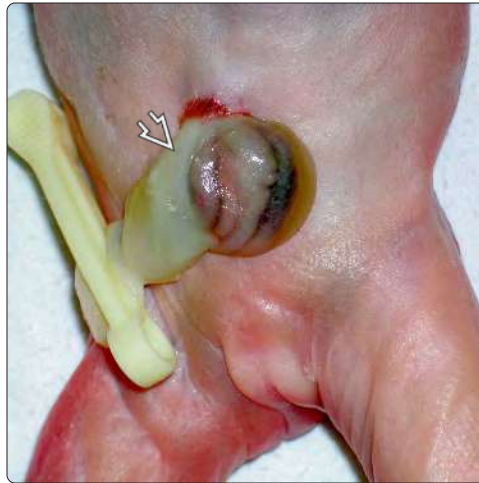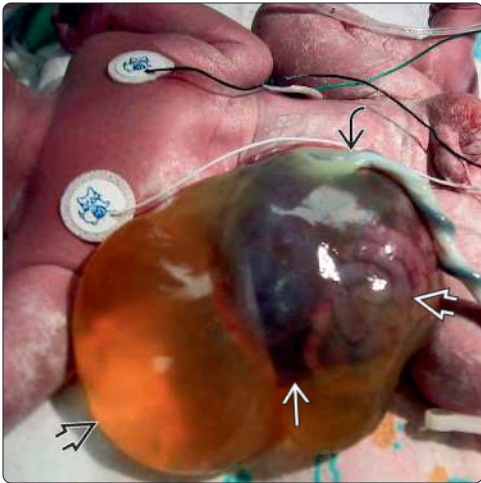


(Left) Fetal MR shows an omphalocele that is lower than usually seen . In addition, there is a large spinal defect . This fetus has OEIS, another known association with omphalocele. Atypical position of the omphalocele should prompt a search for a more complex abdominal wall defect. (Right) Sagittal ultrasound of a 1st-trimester fetus shows a thick NT  and a small omphalocele with hypoechoic liver . Unlike extracorporeal bowel, which can be normal prior to 11-12 weeks, extracorporeal liver is always abnormal.

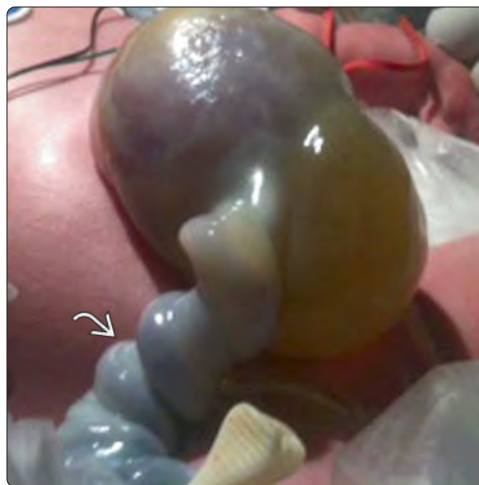
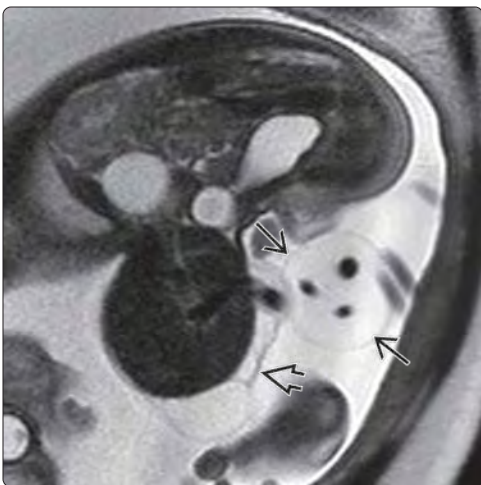



(Left) This fetus with a large omphalocele also has a large amount of ascites and polyhydramnios, features typical for giant omphalocele. **(Right)** Two weeks later in the same case, the ascites is no longer seen, though the polyhydramnios persisted. Also, note the fetal stomach extending into the large abdominal wall defect. The resolved ascites was because of rupture of the omphalocele membrane, confirmed after delivery.



(Left) This newborn with a giant omphalocele has a small bowel, liver, and a large amount of ascites in the sac. The cord inserts on the sac but is often to the side in giant omphaloceles. **(Right)** Clinical photograph shows an omphalocele containing only bowel (no liver) in a stillborn with trisomy 13. The umbilical cord inserts at the apex of the small defect. Bowel-only omphaloceles are more highly associated with aneuploidy.



(Left) Wharton jelly mucoid degeneration is commonly seen in association with omphalocele. A thick umbilical cord and complex, cystic, omphalocele-covering membrane are seen in this 34-week gestation. **(Right)** In the same case, the thick umbilical cord is evident at delivery. A large cystic cord, particularly near the fetal cord insertion site, is often seen with larger omphaloceles and does not change the prognosis.

Pentalogy of Cantrell

KEY FACTS

TERMINOLOGY

- Complex malformation with 5 classic components
 - Midline abdominal wall defect
 - Lower sternal defect/cleft
 - Anterior diaphragmatic defect
 - Defect of diaphragmatic pericardium
 - Intracardiac defect

IMAGING

- Supraumbilical abdominal wall defect
 - Omphalocele in 63%
 - Less commonly abdominal wall schisis
- Variable displacement of heart and mediastinum depending on severity of diaphragmatic/sternal defects
- Fetal echocardiography recommended to define intracardiac anomaly in potentially viable cases
 - Severity of cardiac malformation most important prognostic indicator in this group

TOP DIFFERENTIAL DIAGNOSES

- Isolated omphalocele
- Body stalk anomaly
- Amniotic band syndrome

PATHOLOGY






- Thought to result from abnormal formation and migration of ventral mesoderm during days 14-18 of embryonic life
 - Results in failure of fusion of transverse septum of diaphragm and lateral folds of thorax

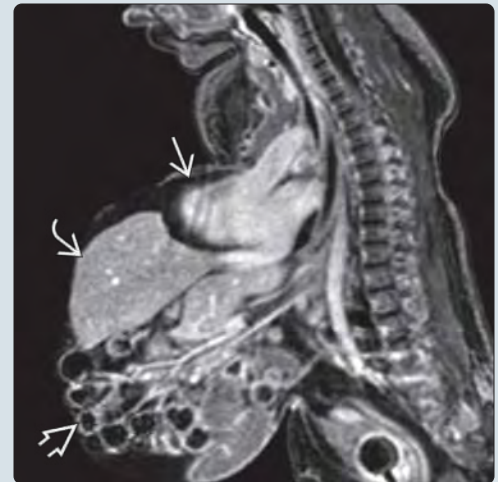
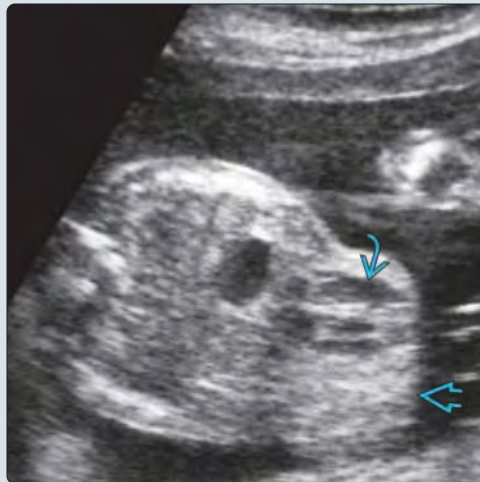
CLINICAL ISSUES






- All 5 anomalies are not always present
- Prognosis dependent on severity of anomalies but usually fatal when discovered prenatally

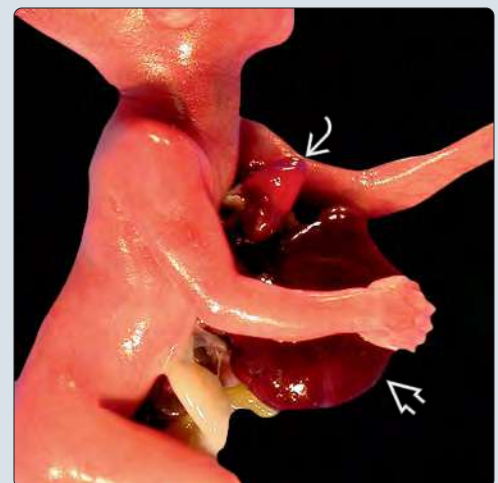
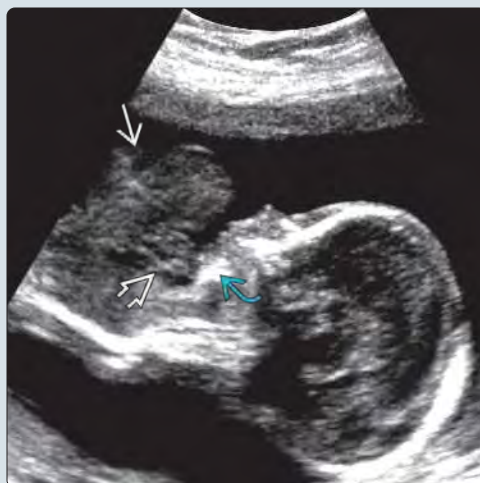DIAGNOSTIC CHECKLIST

- Coexisting ectopia cordis and omphalocele are specific
- Those with subtle defects or incomplete expression of the syndrome are difficult to diagnose prenatally

(Left) Transverse ultrasound through the upper abdomen shows a high omphalocele , which contains the heart . These 2 findings are essentially diagnostic of pentalogy of Cantrell. When the findings are more subtle, the diagnosis may be missed prenatally. **(Right)** Sagittal postnatal MR in a case of pentalogy of Cantrell shows a large omphalocele containing the heart , liver , and bowel . (From *DI: Pediatrics*.)



(Left) Sagittal ultrasound of a 2nd-trimester fetus with pentalogy of Cantrell shows both the liver  and heart  outside the chest. There is also micrognathia . Aneuploidy is a common association, and this fetus had trisomy 18. **(Right)** Gross pathology from a different case shows an upper abdominal wall schisis involving the liver  and heart . This defect is the result of failure of fusion of transverse septum of the diaphragm and lateral folds of the thorax occurring at 14-18 days of embryonic life.



TERMINOLOGY

Definitions

- Complex malformation with 5 classic components
 - Midline abdominal wall defect
 - Lower sternal defect/cleft
 - Anterior diaphragmatic defect
 - Defect of diaphragmatic pericardium
 - Intracardiac defect

IMAGING

General Features

- Best diagnostic clue
 - Ectopia cordis with omphalocele

Ultrasonographic Findings

- Supraumbilical abdominal wall defect
 - Omphalocele in 63%
 - May contain stomach, liver, bowel, and heart
 - Less commonly abdominal wall schisis
 - May be total evisceration of abdominal contents
- Variable displacement of heart and mediastinum depending on severity diaphragmatic/sternal defects
 - Completely external with large defects
 - Cardiac apex typically points toward fetal chin
 - Bulging of heart in small defects
- Cardiac anomalies
 - Septal defect most common
 - Atrial septal defects (50%)
 - Ventricular septal defects (20%)
 - Tetralogy of Fallot
 - Ebstein malformation
 - Left ventricular diverticulum
- Pleural or pericardial effusion

Imaging Recommendations

- Fetal echocardiography to define associated cardiac anomalies in potentially viable cases
 - Can be relevant for prognosis and delivery planning

DIFFERENTIAL DIAGNOSIS

Isolated Ectopia Cordis

- Heart protrudes through cleft sternum
 - May have intact chest wall
 - Prominent chest wall pulsations
- No other components of pentalogy

Isolated Omphalocele

- Lacks cardiac and diaphragmatic abnormalities

Body Stalk Anomaly

- Severely distorted fetus adherent to placenta
- No free-floating cord

Amniotic Band Syndrome

- Frequently involves head and neck
 - "Slash" defects
- Multiple limb defects
- Look for bands

PATHOLOGY

General Features

- Etiology
 - Thought to result from abnormal formation and migration of ventral mesoderm during days 14-18 of embryonic life
 - Results in failure of fusion of transverse septum of diaphragm and lateral folds of thorax
 - Midline developmental field defect believed to account for associated facial clefts and encephalocele
- Genetics
 - Most sporadic without recurrence risk
 - Familial and X-linked recessive cases have been reported
- Associated abnormalities
 - Craniofacial and vertebral anomalies
 - Cleft lip/palate
 - Exencephaly, encephalocele
 - Chromosomal abnormalities
 - Trisomies 13, 18
 - Turner syndrome (45,XO)

Staging, Grading, & Classification

- All 5 anomalies are not always present
 - Class 1: All 5 defects present
 - Class 2: 4 defects, including intracardiac and ventral wall abnormalities
 - Class 3: Sternal defect with various expression of other anomalies

CLINICAL ISSUES

Demographics

- Epidemiology
 - Estimated 1:65,000 live births

Natural History & Prognosis

- Prognosis dependent on severity of lesions but usually fatal when discovered prenatally
- Survival of up to 20% in live births
 - Severity of cardiac anomaly most important prognostic indicator in this group

Treatment

- Consider karyotype for aneuploidy
- Single or staged surgical repair depending on constellation of findings

DIAGNOSTIC CHECKLIST

Image Interpretation Pearls

- Coexisting ectopia cordis and omphalocele are specific
- Those with subtle defects or incomplete expression of syndrome are difficult to diagnose prenatally

SELECTED REFERENCES

1. Kaul B et al: 5, 4, 3, 2, 1: embryologic variants of pentalogy of Cantrell. *J Surg Res.* 199(1): 141-8, 2015
2. Pakdaman R et al: Complex abdominal wall defects: appearances at prenatal imaging. *Radiographics.* 35(2):636-49, 2015
3. Mallula KK et al: Spectrum of Cantrell's pentalogy: case series from a single tertiary care center and review of the literature. *Pediatr Cardiol.* 34(7):1703-10, 2013

KEY FACTS

TERMINOLOGY

- Lethal malformation characterized by attachment of visceral organs to placenta, with short or absent umbilical cord

IMAGING

- Abnormal fetus inseparable from placenta
 - Large thoracoabdominal wall defect
 - Absent/very short umbilical cord
 - Scoliosis prominent feature
 - Limb defects common
- Oligohydramnios in 2nd and 3rd trimesters
- Color Doppler often useful to clarify confusing anatomy and look for umbilical cord
- 3D US useful to define anatomic relationships, particularly in 1st trimester

TOP DIFFERENTIAL DIAGNOSES

- Amniotic band sequence

- Severe cases may be indistinguishable
- Usually normal umbilical cord seen
- Pentalogy of Cantrell

PATHOLOGY

- Persistence of extraembryonic coelomic cavity
- Umbilical vessels embedded in amniotic sheet connecting to skin margin of abdominal wall defect

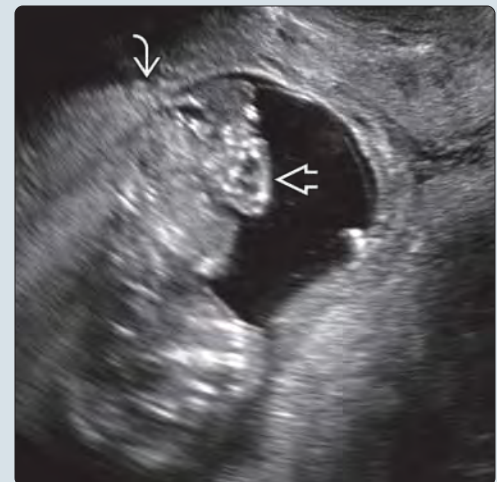
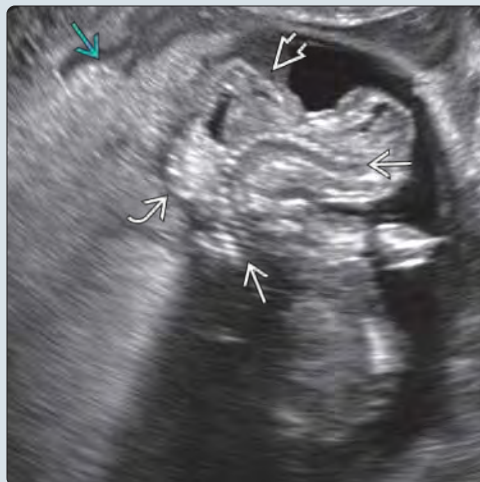
CLINICAL ISSUES

- Not associated with abnormal karyotype
- No known recurrence risk

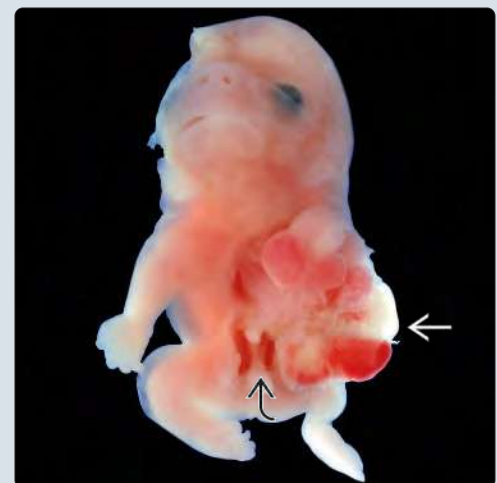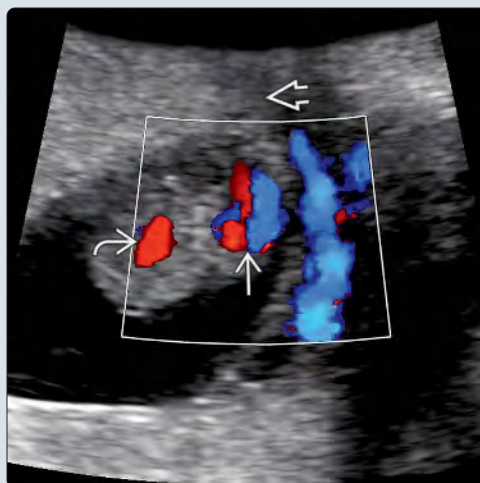
DIAGNOSTIC CHECKLIST

- Most likely diagnosis in setting of abdominal wall defect, scoliosis, and "stuck" fetal appearance
- Be vigilant at time of nuchal translucency screening
 - Early diagnosis allows earlier/safer termination of pregnancy

(Left) Transvaginal US (TVUS) at 13 weeks shows severe scoliosis with the spine bent into a U shape and evisceration of liver and bowel, which are adherent to the placenta. **(Right)** Another US from the same case confirms the close relationship of the fetus to the placenta. In this scan plane, it is apparent that the heart is also involved in the defect and is outside the fetal torso. This is a lethal malformation and should be routinely diagnosed at the time of the nuchal translucency screening.



(Left) Color Doppler can be helpful in evaluation of complex abdominal wall defects. In this case, no free-floating loops of normal cord were seen. The vessels from the extruded fetal liver ran directly to the placenta. The heart is also shown. **(Right)** This embryo has a severe thoracoabdominal wall defect with extrusion of the entire abdominal contents and exstrophy of the bladder. Asymmetry of the extremities is also present. These are the features of the limb-body wall malformation. (From DP: Placenta.)



TERMINOLOGY

Synonyms

- Limb-body wall complex (primary diagnosis if coexistent limb anomalies)

Definitions

- Lethal malformation characterized by attachment of visceral organs to placenta, with short or absent umbilical cord

IMAGING

General Features

- Best diagnostic clue
 - Abnormal fetus inseparable from placenta
 - Gross distortion, with complete loss of anatomic landmarks
 - Often large body wall defect with complete thoracoabdominal evisceration

Ultrasonographic Findings

- Complex array of multiple malformations
 - Large thoracoabdominal wall defect without covering membrane
 - Absent/very short umbilical cord
 - Vessels seen running from placental surface to fetal torso
 - Scoliosis is prominent feature
 - Often severe with multiple acute angulation points
 - Neck often extended (difficulty with vaginal delivery)
 - Limb defects, abnormal limb positioning common
 - Clubfoot
 - Arthrogryposis
 - Polydactyly
 - Syndactyly
 - Absent limbs or digits
 - Craniofacial defects less common than with amniotic band syndrome
 - Encephalocele or exencephaly
 - Facial defects
 - Oligohydramnios in 2nd and 3rd trimesters
- **1st-trimester diagnosis**
 - Entire fetus, or portion of fetus, outside of amniotic cavity
 - Normal fetus entirely within amniotic cavity, suspended by umbilical cord
 - Amniotic membrane can be normal or ruptured
 - Normal umbilical cord not seen
 - Cord can be identified as early as 8 weeks
 - Abnormal ratio of crown-rump length to cord length (normally 1:1)

Imaging Recommendations

- Scan mother in different positions to demonstrate fixed fetal/placental relationship
- Look for normal, free-floating loops of umbilical cord
- Use color Doppler to identify fetal/placental vascular connection
- Color Doppler often useful to clarify confusing anatomy
 - Identify liver location by morphology but also by course of umbilical vein

- Identify fetal vascular landmarks (e.g., iliac bifurcation, renal arteries)
- 3D US has been described and may be of value in defining anatomic relationships
 - Excellent in 1st trimester, may be limited by oligohydramnios/fetal crowding in later pregnancy

MR Findings

- Not necessary for diagnosis, which is usually obvious on US

DIFFERENTIAL DIAGNOSIS

Amniotic Band Syndrome

- Normal free-floating umbilical cord
 - Abdominal cord insertion site may be involved if abdominoschisis
- Look for bands extending from immobile fetal parts to uterine wall
- Limb amputations/constrictions more likely
- Scoliosis not major finding

Pentalogy of Cantrell

- Mobile fetus with normal umbilical cord
 - Ectopia cordis
 - Defect of diaphragmatic pericardium
 - Lower sternal defect
 - Diaphragmatic hernia
 - Omphalocele
- Cranial and limb defects not part of syndrome

Cloacal Exstrophy

- Mobile fetus with umbilical cord inserted at apex of defect
- Omphalocele, absent bladder
- Prolapsed bowel loops **not** adherent to placenta

Omphalocele

- Mobile fetus with normal umbilical cord
- Abdominal wall defect covered by membrane

Gastroschisis

- Mobile fetus with normal umbilical cord
- Defect is usually small, to right of cord insertion
- Bowel floats freely in amniotic fluid, **not** adherent to placenta

PATHOLOGY

General Features

- Etiology
 - Theory of primary ectodermal failure in early embryonic disc (ED)
 - Location/severity of defect determine area affected as well as severity of findings
 - Lateral margins of ED fold ventrally to form lateral abdominal wall
 - Process initiated by increased ectodermal cell division
 - Abnormal cell division → disruption of ventral apposition
 - Lower involvement more likely to alter body stalk embryology → fetal body wall/amnion/placental connections

- Involvement of extreme caudal portion of ED-amnion junction → anomalies limited to midline lower abdominal wall/cloacal area
- Theory of early amnion rupture before obliteration of extraembryonic coelom
 - Extreme form of amniotic band syndrome
- Theory of compromised early embryonic blood flow
 - Failed abdominal wall closure → persistent extraembryonic coelom
- Placenta-abdominal and placento-cranial phenotypes described
 - Placenta-abdominal (no craniofacial defects) in 60%
 - Explained by embryologic maldevelopment, abnormal embryonic folding process
 - Body stalk/yolk stalk fusion fails → short or absent umbilical cord
 - Amnion/chorion fusion fails, amnion does not cover cord
 - Amnion in continuity with fetal peritoneum at edge of defect
 - Placento-cranial (associated craniofacial defects) in 40%
 - Explained by early vascular disruption
- Genetics
 - Sporadic, no karyotypic abnormalities, no known recurrence risk
 - More common in monozygotic twins
 - May be discordant
 - Recent postulation that genes involved in laterality and caudal development may be abnormal
 - *HOX* genes, *FGF2*, transforming growth factor beta/activins/*BMP4*, *WNT 1-8*, and *SHH*
- Associated abnormalities
 - Multiple defects present in virtually all cases
 - Cardiac (ectopia cordis, structural defects)
 - Congenital diaphragmatic hernia or absent diaphragm
 - Renal anomalies (hydronephrosis, agenesis, cystic dysplasia)
 - Bowel atresia
 - Scoliosis
 - Facial clefts, cephaloceles
 - Limb anomalies

Gross Pathologic & Surgical Features

- Persistence of extraembryonic coelomic cavity
- Anterior body wall defect with evisceration of liver, bowel ± heart
 - All organs potentially involved
- Malformed umbilical cord incompletely covered in amnion
- Umbilical vessels embedded in amniotic sheet connecting to skin margin of abdominal wall defect

CLINICAL ISSUES

Presentation

- Abnormal anatomy at time of nuchal translucency (NT) screening
 - Often associated with ↑ NT
- Marked elevation of maternal serum α-fetoprotein
- Abnormal midtrimester anatomy scan

Demographics

- Epidemiology
 - Rare with reported incidence varying from 1:14,000 to 1:42,000
 - 0.12:10,000 total births in Denmark 1970-89 (16 cases total)
 - 9/16 stillbirths, 7/16 perinatal demise
 - 1:7,500 incidence in UK at time of 1st-trimester screening
 - Higher incidence reflects losses due to early spontaneous abortion
 - Risk factors
 - Alcohol, tobacco, marijuana use
 - History of prior child with any congenital anomaly in 40%
 - Reported after in vitro fertilization

Natural History & Prognosis

- Lethal
- Frequent spontaneous abortion

Treatment

- Amniocentesis not required as no abnormal karyotype reported
- Offer termination, but aim for delivery of intact fetus for autopsy
 - Late 1st-/early 2nd-trimester terminations safest for mother
- Psychological support to family
- Vaginal delivery if pregnancy not terminated
 - Cesarean section best avoided, but may be necessary for obstructed labor due to fetal deformity
 - At least 1 reported case of uterine rupture (patient with prior uterine scar)
 - No fetal monitoring during labor
 - No resuscitation of fetus

DIAGNOSTIC CHECKLIST

Consider

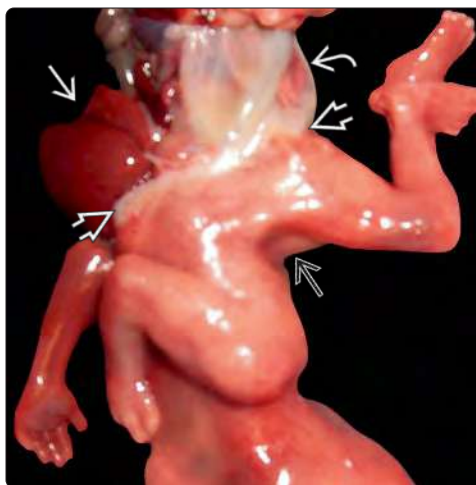
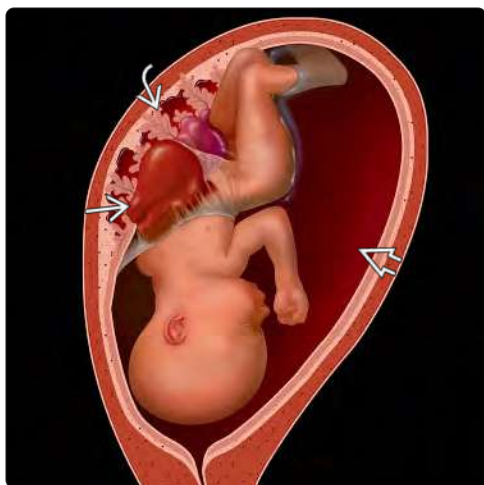- Most likely diagnosis in setting of abdominal wall defect and scoliosis

Image Interpretation Pearls

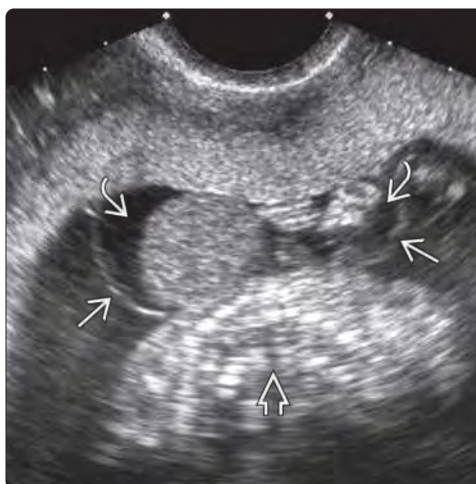
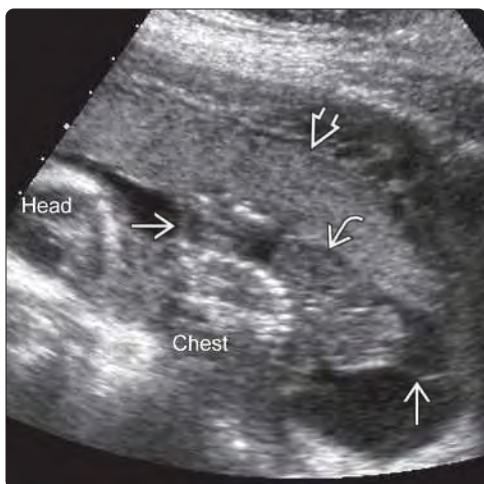- Fetus appears stuck to placenta with severe spinal and limb defects
- Part or all of fetus is located outside amniotic cavity

SELECTED REFERENCES

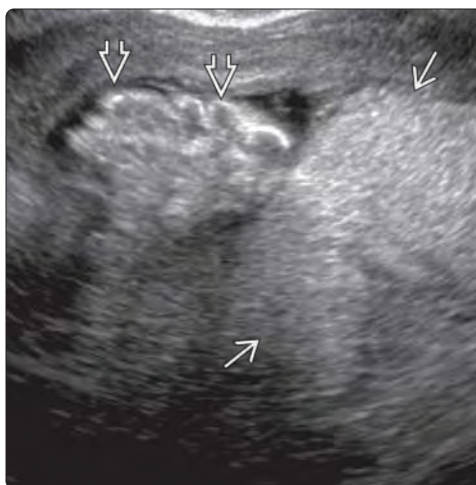
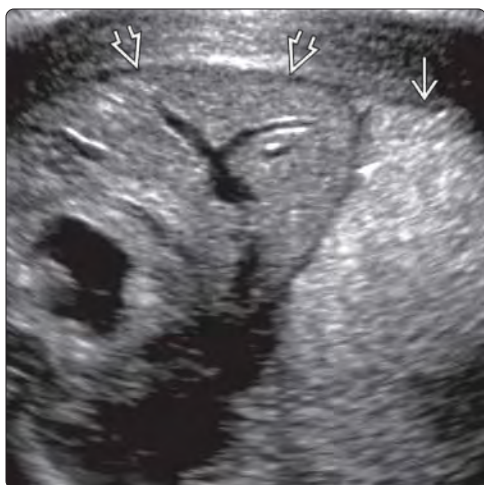
1. Gajzer DC et al: Possible genetic origin of limb-body wall complex. *Fetal Pediatr Pathol.* 34(4):257-70, 2015
2. Pakdaman R et al: Complex abdominal wall defects: appearances at prenatal imaging. *Radiographics.* 35(2):636-49, 2015
3. Aguirre-Pascual E et al: Prenatal MRI evaluation of limb-body wall complex. *Pediatr Radiol.* 44(11):1412-20, 2014
4. Bugge M: Body stalk anomaly in Denmark during 20 years (1970-1989). *Am J Med Genet A.* 158A(7):1702-8, 2012
5. Costa ML et al: Body stalk anomaly: adverse maternal outcomes in a series of 21 cases. *Prenat Diagn.* 32(3):264-7, 2012
6. Hunter AG et al: Limb-body wall defect. Is there a defensible hypothesis and can it explain all the associated anomalies? *Am J Med Genet A.* 155A(9):2045-59, 2011
7. Murphy A et al: First-trimester diagnosis of body stalk anomaly using 2- and 3-dimensional sonography. *J Ultrasound Med.* 30(12):1739-43, 2011



(Left) Graphic shows a large body wall defect with attachment of fetal viscera to the placenta. Scoliosis results from fetal tethering. The upper part of the fetus remains inside the amniotic cavity while the lower parts are in the extraembryonic coelomic cavity. There is no normal umbilical cord. (Right) Autopsy image presented in a similar orientation shows severe scoliosis, evisceration of liver and bowel, and reflection of the amnion at the edges of the large abdominal wall defect.



(Left) Transabdominal US shows extruded abdominal organs in contact with the placenta. The reflected amnion marks the boundary between the amniotic cavity and the extraembryonic coelomic space. (Right) TVUS in the same case shows the amnion more clearly. The main part of the torso is in the amniotic cavity but is anchored to the uterine wall, hence the scoliosis. The viscera are in the extraembryonic coelomic space.



(Left) Fetal anatomy can be very confusing in this body stalk anomaly as the scoliosis and fixed fetal position limit evaluation. TVUS can be very helpful as the higher resolution allows more confident identification of specific organs. In this case, the liver is confirmed to be external to the fetal body and closely associated with the placenta. (Right) Another US in the same case shows extracorporeal bowel loops, which remained in close proximity to the placenta.

KEY FACTS

TERMINOLOGY

- Bladder exstrophy (BE): Failure of closure of lower abdominal wall resulting in exposed bladder
- Exstrophy epispadias complex (EEC): Spectrum of malformations ranging from epispadias to BE to cloacal exstrophy

IMAGING

- Inability to demonstrate fluid-filled bladder
- Soft tissue mass on lower anterior abdominal wall created by exposed posterior bladder wall
- Lower than normal insertion of umbilical cord
- If bladder not seen, obtain midline sagittal image through torso for abdominal wall contour
- Evaluate for genital anomalies, which are common in both males and females

TOP DIFFERENTIAL DIAGNOSES

- Absent bladder





- Renal anomalies or other conditions resulting in anuria
- Cloacal exstrophy
 - Bowel herniation through abdominal wall defect → elephant trunk sign

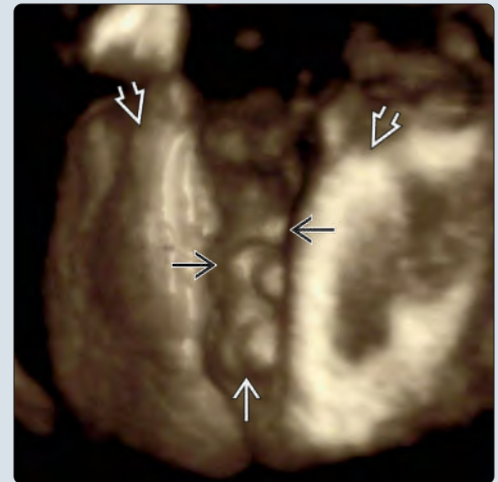
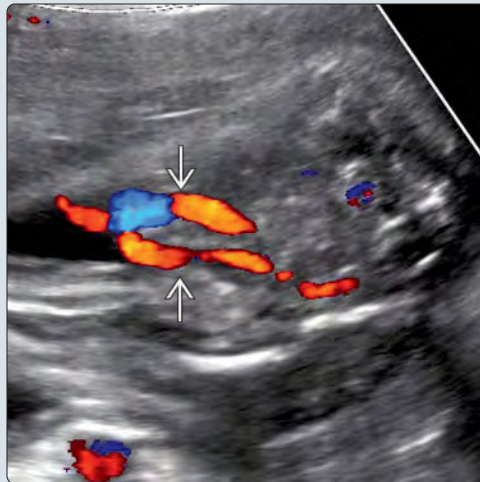
CLINICAL ISSUES









- Variable severity
 - Mild form associated with exstrophy of urethra and external sphincter
 - Severe form associated with wide diastasis of symphysis pubis and genital defects
- Goals of surgical repair
 - Secure abdominal wall closure
 - Urinary continence with preservation of renal function
 - Adequate cosmetic and functional genital reconstruction

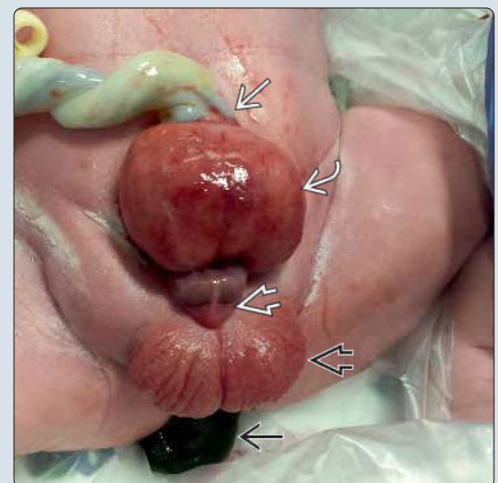
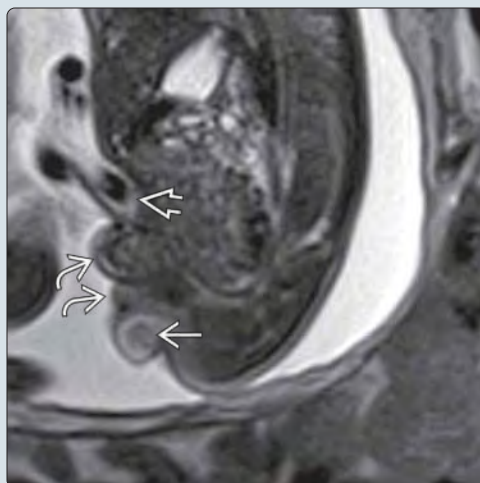
DIAGNOSTIC CHECKLIST

- Important to distinguish from cloacal exstrophy, which has worse prognosis

(Left) Axial oblique US shows the umbilical arteries . The bladder, normally seen as a fluid-filled structure between them, was never visible in this case. (Right) 3D surface-rendered image of the perineum in the same case shows the scrotum  between the lower extremities . 2D images showed descended testes. The lower abdominal wall contour  is abnormally "lumpy bumpy" due to inflammation of the everted bladder mucosa.



(Left) Sagittal T2WI MR in the same fetus shows a low abdominal cord insertion site , everted bladder mucosa , and a normal testis  in the scrotum. T1WI was used to confirm a normal rectum. US showed a normal anal dimple. (Right) Clinical photograph of the infant at birth confirms the low cord insertion site , everted bladder mucosa , and shows the small, abnormal penis , which contributed to the "lumpy bumpy" appearance on US. The scrotum  is normal and passage of meconium  proves a patent anus.



TERMINOLOGY

Definitions

- **Bladder exstrophy (BE)**
 - Failure of closure of lower abdominal wall resulting in exposed bladder
- **Exstrophy epispadias complex (EEC)**
 - Spectrum of malformations ranging from epispadias to BE to cloacal exstrophy
 - Defects involve genitourinary/musculoskeletal systems, pelvis, pelvic floor, abdominal wall, spine, and anus

IMAGING

Ultrasonographic Findings

- Inability to demonstrate fluid-filled bladder in fetal pelvis
 - Do not confuse cystic pelvic structures with bladder
 - Normal bladder fills and empties repeatedly during scan
 - Umbilical arteries encompass bladder as they course from internal iliac arteries to umbilicus
- Soft tissue mass on lower anterior abdominal wall created by posterior bladder wall
 - Inflammatory polyps creates "lumpy bumpy" surface
- Lower than normal insertion of umbilical cord
 - Inserts on abdominal wall at superior margin of exstrophic bladder

MR Findings

- MR useful to assess kidneys, genitalia, colon/anorectal anatomy, spine
 - T1WI particularly useful to demonstrate normal rectum and anus, which excludes cloacal exstrophy
 - Meconium is high-signal intensity on T1WI

Radiographic Findings

- Widely separated pubic bones
 - Mean pubic diastasis of 4.8 cm
- Everted innominate bones

CT Findings

- Performed in infant to plan repair of
 - Symphysis diastasis
 - Acetabular retroversion
 - Pelvic external rotation
 - Increased distance between triradiate cartilages
- Now known that pelvic reconstruction important for appropriate growth of pelvic muscles
 - Improved bladder neck orientation → better chance of long-term continence

Imaging Recommendations

- Protocol advice
 - If bladder not seen, obtain midline sagittal image through torso for abdominal wall contour
 - Lower than normal cord insertion and irregular lower abdominal wall
 - Acquire 3D surface-rendered ultrasound images
 - More difficult later in pregnancy when legs can largely obscure lower abdominal wall
 - Beware of misdiagnosis in fetuses with normal empty bladder

- Rescan after interval of 10-15 minutes
- Any cause of anuria will cause nonvisualization of bladder in utero
 - All will be associated with oligo-/anhydramnios
 - Amniotic fluid volume in bladder exstrophy is normal
- Carefully evaluate genitalia
 - Genital anomalies common in both males and females
- Look specifically for anal dimple
 - If not seen, increased suspicion for cloacal exstrophy

DIFFERENTIAL DIAGNOSIS

Absent Bladder

- Bladder is present but not filled with urine
- **Renal anomalies resulting in anuria**
 - Renal agenesis
 - Anhydramnios
 - No visible renal tissue
 - Lying down adrenal glands
 - Autosomal recessive polycystic kidney disease
 - Bilateral, large, echogenic kidneys
 - Bilateral multicystic dysplastic kidney
 - Bilateral multicystic masses in renal fossa
- **Severe placental insufficiency**
 - Fetal growth restriction
 - Oligohydramnios
 - Abnormal cord Doppler
- **Twin-twin transfusion syndrome** (donor twin with oligohydramnios)
 - Will be associated with polyhydramnios ± large bladder in recipient twin

Cloacal Exstrophy

- Bowel herniation through abdominal wall defect → elephant trunk sign
- Anal atresia
- Often multiple other anomalies such as myelomeningocele and omphalocele

PATHOLOGY

General Features

- Etiology
 - Unknown, controversial
 - Maternal smoking may be related
 - EEC spectrum hypothesis is very early defect in embryogenesis
- Genetics
 - EEC likely due to complex interplay of down-regulated and overexpressed genes
 - Many reports of involved genes
 - *p63* important in urogenital development (bladder epithelium, foreskin)
 - *FGF10* knockout mice have reproducible anorectal malformations, abnormal urethral plate fusion
 - Gene for EEC possibly harbored in critical regions on 4q31.21-22 and 19q13.31-41
 - Genome-wide association study identified significant locus for BE at 5q11.1 with hypothesis that *ISL1* is responsible gene
 - Reports of BE with trisomies 21,13

- Associated abnormalities
 - 7% have spine abnormalities at birth (dysraphism, scoliosis)
 - Inguinal hernia
 - Males
 - Epispadias
 - Short, split penis
 - Maldescended testes
 - Females
 - Cleft clitoris
 - Uterus didelphys
 - Duplicated vagina

CLINICAL ISSUES

Presentation

- Inability to demonstrate fluid-filled bladder
- Elevated maternal serum α -fetoprotein

Demographics

- Epidemiology
 - 1:10-50,000 births
 - M:F = 2.8:1

Natural History & Prognosis

- Not associated with increased pregnancy complications or perinatal mortality
- Variable severity
 - Mild form associated with exstrophy of urethra and external sphincter
 - Severe form associated with wide diastasis of symphysis pubis and genital defects
- QUALEX (quality of life of bladder exstrophy) study concluded that patients with reconstructed bladder exstrophy have impaired quality of life
 - Significantly impaired adolescent general health
 - Negative impact on family activity
 - Negative parental emotional impact
 - Males have erectile dysfunction
 - Decreased orgasmic function, particularly if multiple continence surgeries
- Functional results most likely predictive factor of health-related quality of life score
- Pelvic organ prolapse common
 - Levator hiatus 2x wider than normal
 - Posterior placement of levator ani
 - Occurs even without childbirth
 - Muscular anatomy improves with correct pelvic fixation techniques
- Infertility
- Increased risk of adenocarcinoma in extruded bladder
 - 4% if repair performed after infancy

Treatment

- Cell-free fetal DNA/amniocentesis may be considered if genitalia ambiguous
- Prenatal counseling with pediatric urologist
- Delivery in tertiary care center preferable
- Goals of surgical repair
 - Secure abdominal wall closure
 - Urinary continence with preservation of renal function

- Expect 80% continence rate during childhood
- Adequate cosmetic and functional genital reconstruction
 - Males
 - Delay of primary repair > 72 hr allows testosterone exposure to enhance penile development
 - hCG administration improves growth of available penile skin, promotes testicular descent
 - Females
 - Vaginal stenosis common
 - Vaginoplasty highly successful when performed in 2nd/3rd decade of life
- Surgical treatment can be staged or performed as single complete primary repair
 - Single primary repair preferred as correlates with better development of bladder capacity
 - Good primary repair is most important factor for long-term continence
- Psychosocial and emotional issues may require long-term multidisciplinary treatment
- Male-to-female gender reassignment surgery now almost never done
 - In utero exposure to androgens thought to determine sexual identity
- Ongoing bioengineering research into use of stem cells/cellular matrix to cell-seeded bioscaffolding for treatment
 - Tissue-engineered scaffolds serve as artificial extracellular matrix to replace functions of native tissues.
 - Scaffolds host new 3D spaces for formation, penetration, and proliferation of tissue cells
 - May help deliver transplanted cells (especially stem cells) and bioactive factors to specific sites

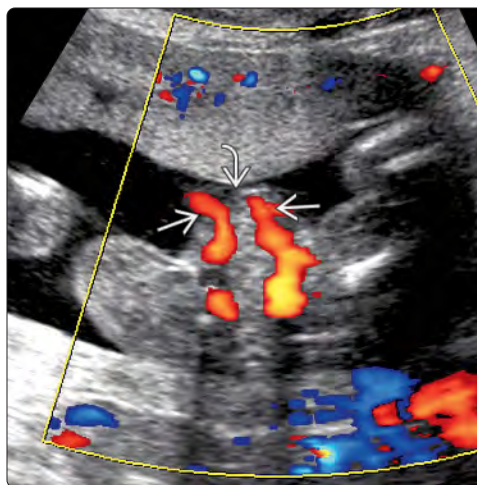
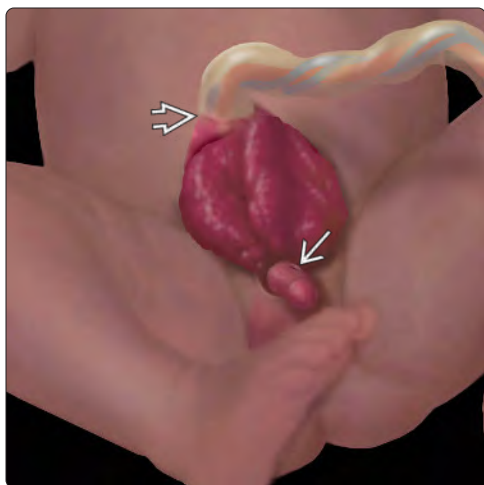
DIAGNOSTIC CHECKLIST

Image Interpretation Pearls

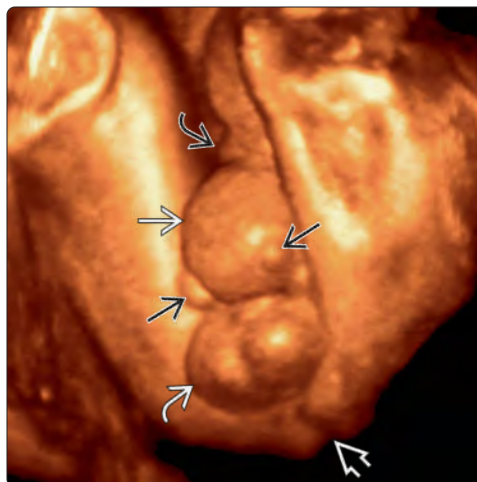
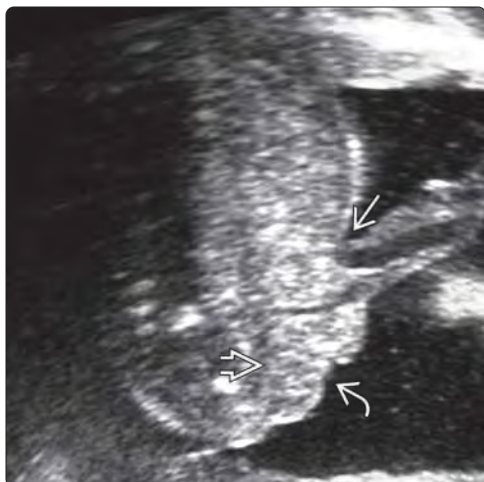
- Important to distinguish from cloacal exstrophy, which has worse prognosis

SELECTED REFERENCES

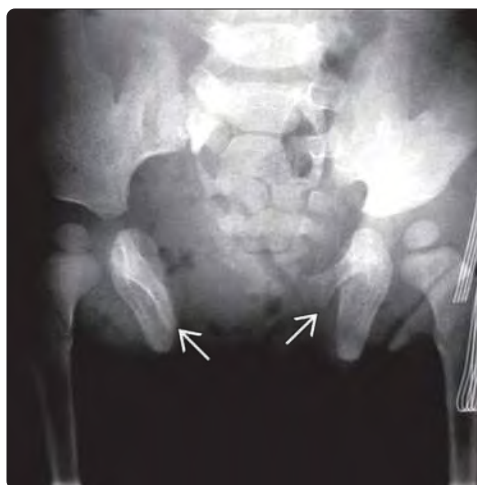
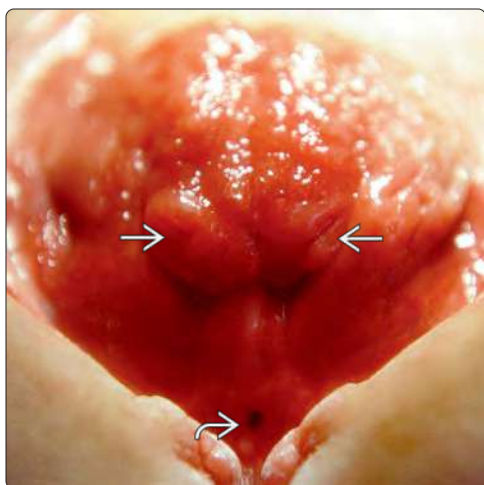
1. Draaken M et al: Genome-wide association study and meta-analysis identify ISL1 as genome-wide significant susceptibility gene for bladder exstrophy. *PLoS Genet.* 11(3):e1005024, 2015
2. Hurrell RA et al: Psychosocial screening at paediatric BEEC clinics: A pilot evaluation study. *J Pediatr Urol.* 11(2):79.e1-6, 2015
3. Park W et al: Sexual function in adult patients with classic bladder exstrophy: A multicenter study. *J Pediatr Urol.* 11(3):125 2015
4. Pierre K et al: Bladder exstrophy: current management and postoperative imaging. *Pediatr Radiol.* 44(7):768-86; quiz 765-7, 2014
5. Tekes A et al: 2D and 3D MRI features of classic bladder exstrophy. *Clin Radiol.* 69(5):e223-9, 2014
6. Castagnetti M et al: Issues with the external and internal genitalia in postpubertal females born with classic bladder exstrophy: a surgical series. *J Pediatr Adolesc Gynecol.* 24(1):48-52, 2010
7. Jochault-Ritz S et al: Short and long-term quality of life after reconstruction of bladder exstrophy in infancy: preliminary results of the QUALEX (QUALITY of Life of bladder EXstrophy) study. *J Pediatr Surg.* 45(8):1693-700, 2010
8. Wittmeyer V et al: Quality of life in adults with bladder exstrophy-epispadias complex. *J Urol.* 184(6):2389-94, 2010
9. Ebert AK et al: The exstrophy-epispadias complex. *Orphanet J Rare Dis.* 4:23, 2009
10. Gambhir L et al: Epidemiological survey of 214 families with bladder exstrophy-epispadias complex. *J Urol.* 179(4):1539-43, 2008



(Left) Graphic of bladder exstrophy shows an exteriorized bladder with exposed mucosa. There is also associated epispadias. Genital anomalies are commonly present with bladder exstrophy. The umbilical cord insertion site is above the abdominal wall defect. (Right) Axial color Doppler US shows the umbilical arteries on either side of a soft tissue protuberance from the anterior abdominal wall. The bladder is not seen as a fluid-filled structure between the umbilical arteries.



(Left) Sagittal US in the same case shows an irregular contour to the lower anterior abdominal wall inferior to the cord insertion site (which is lower than normal). Once again, the bladder is not seen as a fluid-filled structure in the expected location. Bladder exstrophy was confirmed at delivery. (Right) 3D US shows a normal scrotum and anus. The everted bladder mucosa creates a lower abdominal wall mass, and there is an associated bifid penis. The cord inserts low at the apex of the defect.



(Left) Clinical photograph shows the exposed, inflamed, posterior bladder mucosa, which creates the mass seen on imaging. The bladder trigone, including the ureteral and urethral orifices, is seen. Urine will drain directly into the amniotic cavity, which is why there is normal amniotic fluid despite an absent bladder. (Right) Radiograph of an infant born with bladder exstrophy shows wide diastasis of the symphysis pubis.

KEY FACTS

TERMINOLOGY

- Cardinal findings of cloacal exstrophy (CE) are hemibladder exstrophy, hindgut extrusion, and imperforate anus
- Exstrophy epispadias complex
 - Spectrum of malformations ranging from epispadias to bladder exstrophy to CE
 - Defects involve genitourinary/musculoskeletal systems, pelvis, pelvic floor, abdominal wall, spine, anus
- Term OEIS complex was proposed by Carey et al as way to recall all defects that may be present
 - Omphalocele
 - Exstrophy of bladder
 - Imperforate anus
 - Spinal deformities

IMAGING

- Absence of normal bladder
- Anal atresia (absent anal dimple)
- Low abdominal wall defect

- Appearance of prolapsed bowel described as elephant trunk sign

TOP DIFFERENTIAL DIAGNOSES

- Other unusual abdominal wall defects
 - Amniotic band syndrome
 - Body stalk anomaly

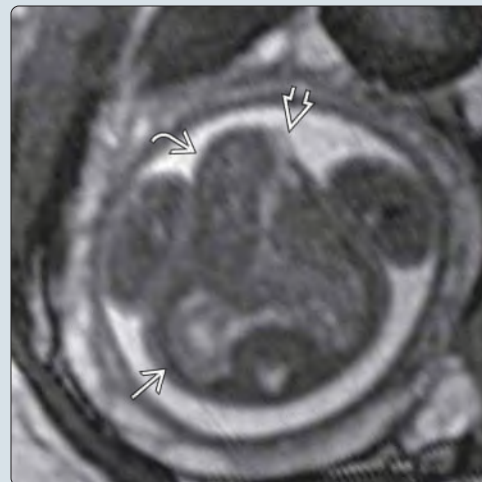
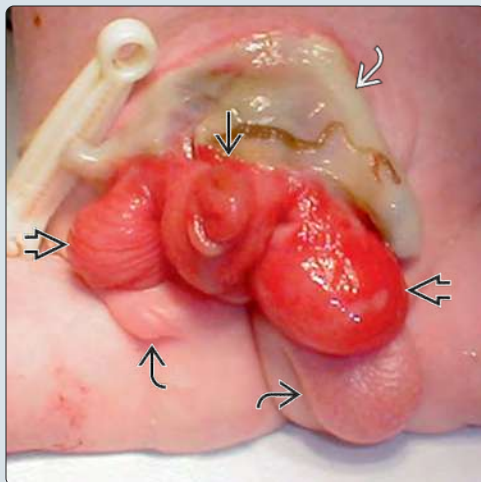
CLINICAL ISSUES

- Prognosis dependent on severity of defect and associated malformations
- Postnatal survival is good but associated with considerable morbidity and psychosocial consequences
- Most patients have poor prognosis for bowel control but can remain clean with bowel management

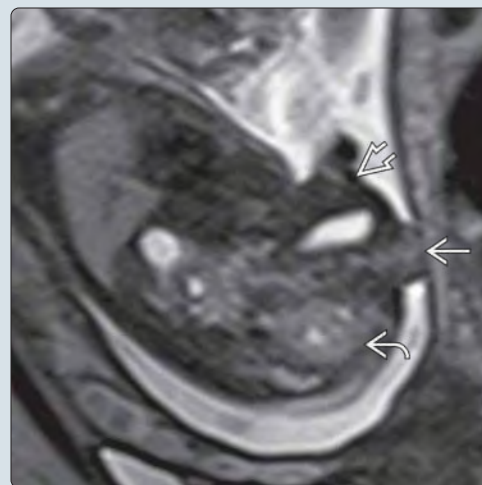
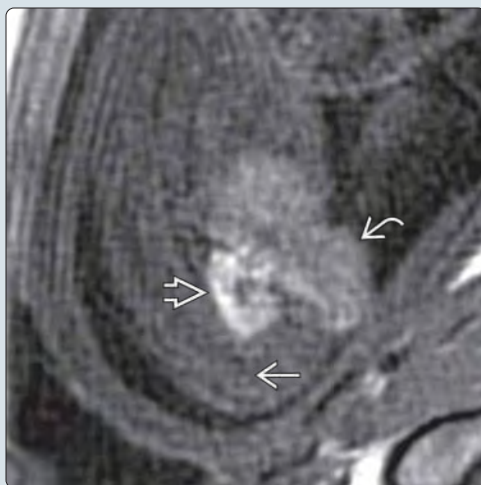
DIAGNOSTIC CHECKLIST

- Always look for multiple abnormalities in fetus with findings in "diaper distribution"

(Left) Clinical photograph shows typical features of cloacal exstrophy, including an omphalocele membrane and bowel herniating between 2 halves of the bladder. There is also a split scrotum with an undescended testis on the right. **(Right)** Axial MR in a fetus with a low abdominal wall defect and no bladder or anal dimple on US shows the cord insertion onto an omphalocele, which was forming the upper portion of the defect. Also note only a single kidney is visible.



(Left) Midline sagittal T1WI MR in the same case confirms there is a portion of extruded liver. High-signal meconium is easily visible in the colon, but the lack of signal in the presacral space indicates an absent rectum. **(Right)** Sagittal T2WI MR in the same case shows that bowel is also involved in the abdominal wall defect and confirms the cord insertion site on the omphalocele, which forms the upper portion of the defect. This constellation of findings is typical of CE. The "missing" kidney is visible in the pelvis.



TERMINOLOGY

Definitions

- Cardinal findings of cloacal exstrophy (CE) are hemibladder exstrophy, hindgut extrusion, imperforate anus
 - Hemiblasters contain ureter/vas deferens orifices in males, uterovaginal canal in females
 - Hemiblasters flank opening of small intestine/blind-ending large intestine
 - Omphalocele present in 64% (i.e., it is **not** essential for diagnosis)
- Exstrophy epispadias complex (EEC)
 - Spectrum of malformations ranging from epispadias to bladder exstrophy (BE) to CE
 - Defects involve genitourinary/musculoskeletal systems, pelvis, pelvic floor, abdominal wall, spine, anus
- Term OEIS complex was proposed by Carey et al in 1978 as way to recall all defects present
 - Omphalocele
 - Exstrophy of bladder
 - Imperforate anus
 - Spinal deformities (includes vertebral anomalies, dysraphism, sacral defects)
- Birth defects registries now use other terms to describe other combinations of findings with CE
 - OEI: Omphalocele, exstrophy, imperforate anus
 - EIS: Exstrophy, imperforate anus, spine abnormalities

IMAGING

General Features

- Best diagnostic clue
 - Low anterior abdominal wall defect with bowel involvement and absent bladder

Ultrasonographic Findings

- Absence of normal bladder
- Anal atresia (lack of normal anal dimple)
- Low abdominal wall defect
 - Herniation of bowel between 2 halves of bladder
 - Appearance of prolapsed bowel described as elephant trunk sign
 - Omphalocele (i.e., membrane bound) forms upper part of defect in majority of CE cases
- Urinary tract abnormalities in up to 60% (may lead to oligohydramnios)
- Spine abnormalities in full OEIS complex
 - Hemivertebra and segmentation defects
 - Myelomeningocele in 30-70%
- Club feet in 20-45%

MR Findings

- Absent bladder, protuberant abdominopelvic contour, absence of meconium-filled rectum and colon
 - T1WI excellent for evaluation of colon/rectum/anus
 - Meconium is high signal intensity
- Associated spine abnormalities
 - Tethered cord, cord lipoma, lipomyelomeningocele, terminal myelocystocele
- Associated genitourinary malformations
 - Dysplastic/pelvic kidney, hydrocolpos

Imaging Recommendations

- Protocol advice
 - Use color Doppler to localize umbilical arteries and cord insertion
 - Obtain dedicated views of perineum for anal dimple in any fetus with abnormal spine/genitalia/abdominal wall
 - 3D volume acquisition may be useful
 - Surface rendering of genitalia to show bifid scrotum/penis
 - Consider MR
 - Combination of T1 and T2WI allows differentiation of large/small bowel and other fluid-filled structures
 - Exquisite detail of brain, spinal cord
 - Consider fetal echocardiography
 - Congenital heart disease may impact ability to withstand multiple surgeries

DIFFERENTIAL DIAGNOSIS

Bladder Exstrophy

- Bladder opens into irregular low anterior abdominal wall defect
- Normal rectum/anus, no external bowel

Amniotic Band Syndrome

- Bizarre "slash" defects → abdominoschisis
- Linear bands seen extending from defects to uterine wall

Body Stalk Anomaly

- Large thoracoabdominal defect
- Fetus adherent to placenta with no identifiable abdominal cord insertion site
- Short or absent umbilical cord

Isolated Omphalocele

- All extruded abdominal contents contained within membranous sac
- Bladder normal

PATHOLOGY

General Features

- Etiology
 - Based on histopathological studies of human embryos, CE most likely due to very early defect involving embryonic caudal eminence
 - Recent animal/human studies suggest cloacal membrane **not** involved, etiology is subject of much discussion
 - Some authors believe BE and CE have different embryologic origin
 - Some believe CE is most severe form of continuum of disorders known as EEC
 - Some believe CE is part of continuum with limb-body wall and urorectal septum malformations
- Genetics
 - Features that suggest genetic component
 - 400x increase in incidence in children of affected individuals
 - Higher concordance rates in monozygotic twins (62%) than in dizygotic (11%)
 - Abnormal p63 expression (no mutations found as yet)

Differentiation of Exstrophies From Simple Abdominal Wall Defects

	Cloacal Exstrophy	Bladder Exstrophy	Omphalocele	Gastroschisis
Cord insertion	On membrane or low on abdominal wall	Low, on abdominal wall	On membrane	On abdominal wall
Membrane	In cases with omphalocele	No	Present	No
Free-floating bowel	Yes	No	No	Yes
Bladder visible	No	No	Yes	Yes
Anal dimple visible	No	Yes	Yes	Yes

Bladder and cloacal exstrophy are much more significant abdominal wall defects than gastroschisis and omphalocele due to the more complicated repairs and the ongoing physical and psychosocial consequences for patients and their families.

- Critical regions on 4q31.21-22 and 19q13.31-41 may harbor gene for EEC
- Associated abnormalities
 - Additional congenital anomalies in 14.5% of cases
 - Single umbilical artery, horseshoe kidney, renal agenesis, limb defects, bowel atresias
 - Rectovesical, rectovaginal, or complex fistulas involving rectum, vagina, and bladder
 - Hydrocephalus associated with spina bifida
 - Affected children have more surgeries, more likely to be wheelchair bound

CLINICAL ISSUES**Presentation**

- Abdominal wall defect with multiple additional findings

Demographics

- Epidemiology
 - 1:200,000-400,000 births (1:158,730 live births New York state reported in 2007)
 - 120 cases assessed by International Clearinghouse for Birth Defects Surveillance and Research
 - 22.6% full OEIS
 - 32.8% with OEI
 - 18% with EIS

Natural History & Prognosis

- 71.5% liveborn, 15.6% stillbirth, 12.9% termination of pregnancy
 - 51.1% delivered before 37 weeks
- Prognosis dependent on severity of defect and associated malformations
 - Prior to 1960 mortality was 100%; improved such that survival expected in 90% by 1980s
 - Multiple surgical procedures required
 - Psychological evaluation of survivors reveals considerable morbidity and psychosocial consequences
- Dutch series of 20 cases since 1974-2014
 - 6/20 died in first year of life
 - 11/14 survivors with end ileostomy or end colostomy, 3/14 with pull through (2 continent for feces)
 - 11/14 incontinent of urine
 - 6/9 XY patients with gender reassignment to female, all XX patients required vaginal/vulvar reconstruction
- Johns Hopkins series of 77 surgical patients

- 47/77 tubularization of cecal plate, end colostomy (thus potential for intestinal pull-through procedure)
- 30/77 patients had ileostomy (significant fluid and electrolyte derangements)
- 4/77 with short gut syndrome
- Johns Hopkins comparison of 34 successful initial bladder closures with 26 failed initial bladder closures
 - Those with larger symphysis diastasis more likely to fail
 - Delaying initial closure, pelvic osteotomy, external fixation improve success of initial closure
- Cincinnati Children's Hospital experience
 - To maximize potential for pull-through, all available hindgut must be used for initial colostomy, not for urogenital reconstruction
 - Most patients have poor prognosis for bowel control but can remain clean with bowel management (improved quality of life)

Treatment

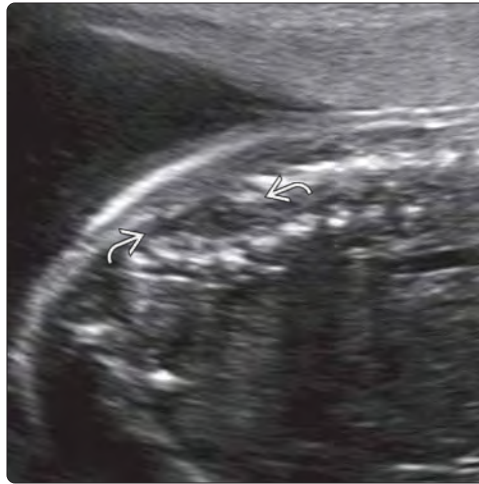
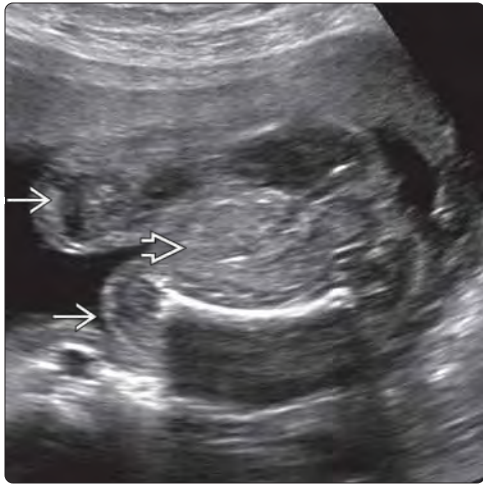
- Offer termination after appropriate counseling as to nature of disorder and long-term sequelae
- Cell-free fetal DNA/karyotype may be offered to determine genetic sex
- Extensive prenatal consultation with expert multidisciplinary team if pregnancy continues
- Stem cell therapy and tissue engineering have opened up a new avenue of research and significant promise in management of CE

DIAGNOSTIC CHECKLIST**Image Interpretation Pearls**

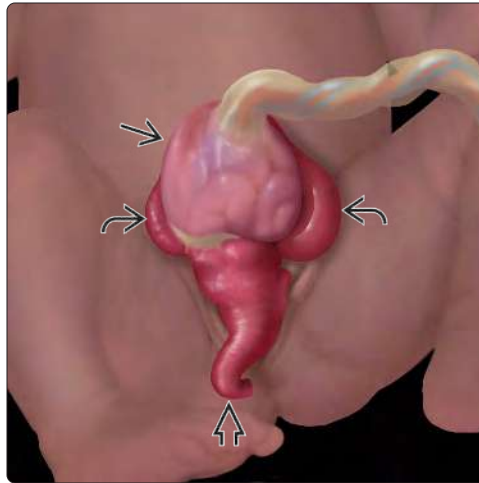
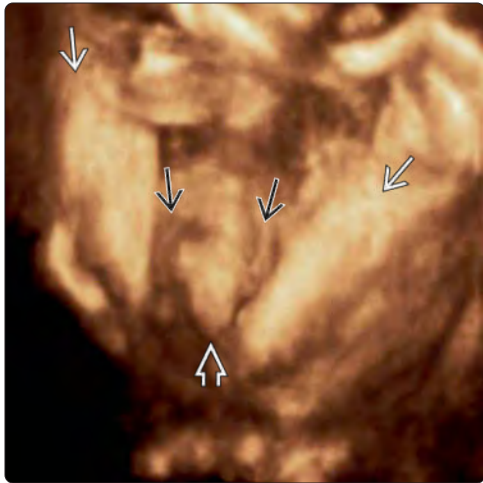
- Always look for multiple abnormalities in fetus with findings in "diaper distribution"

SELECTED REFERENCES

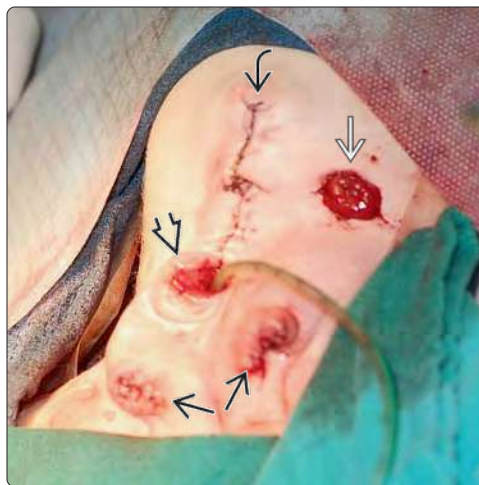
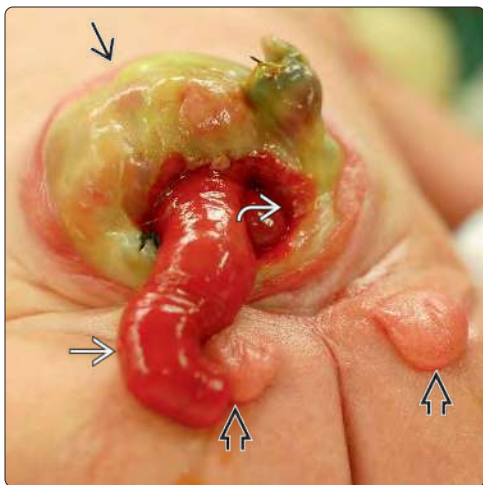
1. Pakdaman R et al: Complex abdominal wall defects: appearances at prenatal imaging. *Radiographics*. 35(2):636-49, 2015
2. Calvo-Garcia MA et al: Fetal MRI of cloacal exstrophy. *Pediatr Radiol*. 43(5):593-604, 2013
3. Feldkamp ML et al: Cloacal exstrophy: an epidemiologic study from the International Clearinghouse for Birth Defects Surveillance and Research. *Am J Med Genet C Semin Med Genet*. 157C(4):333-43, 2011
4. Sawaya D et al: Gastrointestinal ramifications of the cloacal exstrophy complex: a 44-year experience. *J Pediatr Surg*. 45(1):171-5; discussion 175-6, 2010



(Left) Axial US through the pelvis shows bowel between the legs. A fluid-filled bladder was never seen, nor were a normal anal dimple or normal external genitalia. Cell-free fetal DNA was consistent with normal female chromosomes in this case. It is often very hard to tell gender by US in CE cases. Genital reconstruction is more challenging in males. (Right) Sagittal US of the distal spine shows a closed (skin-covered) neural tube defect. Spine abnormalities of any sort are included by the letter S in the OEIS acronym.



(Left) 3D surface-rendered reconstruction, angled to show the abdominal wall defect framed by the fetal legs, shows the elephant trunk sign created by bowel prolapsed between the extrophied bladder halves. (Right) Graphic of cloacal exstrophy shows an omphalocele, with terminal ileum prolapsed between the 2 halves of the extrophic bladder. The appearance of the prolapsed bowel has been likened to an elephant trunk. Note that an omphalocele is not essential for this diagnosis.



(Left) Clinical photograph immediately prior to primary repair in a male infant with cloacal exstrophy shows prolapsed ileum, omphalocele, everted bladder mucosa, bilateral empty hemiscrotal sacs, and no identifiable penis. (Courtesy M. Molitor, MD.) (Right) Postoperative photo after primary repair shows omphalocele repair, colostomy, vesicostomy, and bilateral orchidopexy. This child will need many more surgeries. (Courtesy M. Molitor, MD.)

KEY FACTS

TERMINOLOGY

- Esophagus atresia (EA) often associated with tracheoesophageal fistula (TEF)
- Proximal atresia with distal TEF most common type

IMAGING

- Small or absent stomach bubble
 - Often difficult to define when stomach is "small"
 - Stomach size varies in same fetus over several hours
 - Follow-up scans should be performed on questionable cases
- Pouch sign
 - Transient filling of proximal esophagus with swallowing
- Fetal growth restriction seen in up to 40%
- Polyhydramnios
 - Rarely develops before 20 weeks
 - Fetal swallowing not important part of amniotic fluid dynamics until that time

- Fetal MR useful to look for esophageal pouch in setting of small stomach and polyhydramnios

PATHOLOGY

- > 50% have other anomalies
- VACTERL association in 30%
- Maternal diabetes is risk factor

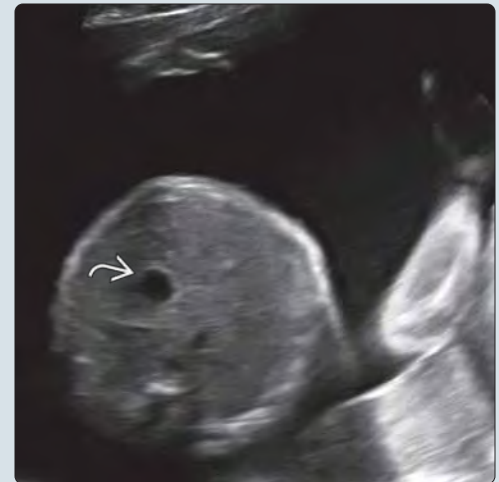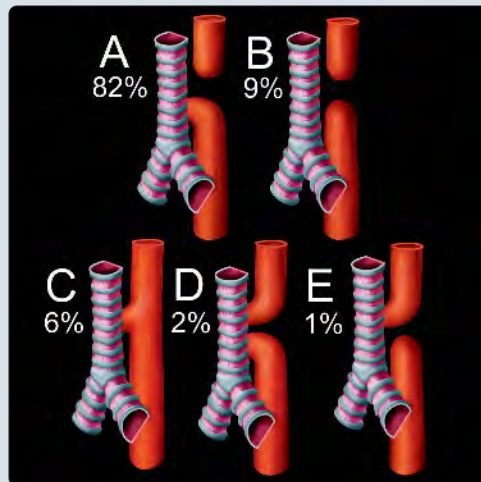
CLINICAL ISSUES

- All fetuses should be karyotyped
 - Aneuploidy reported in 5-44%, most commonly trisomy 18/21
- Deliver at tertiary care center with facilities for early surgical intervention after birth

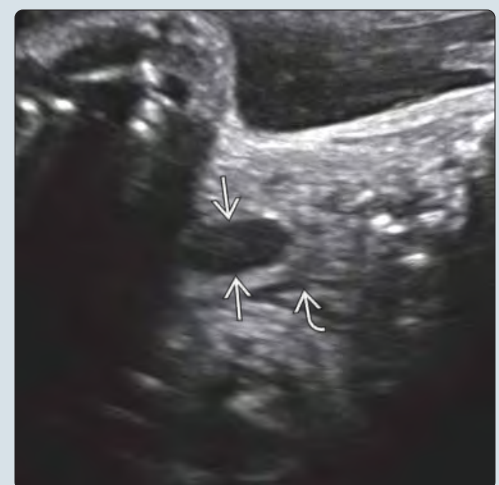
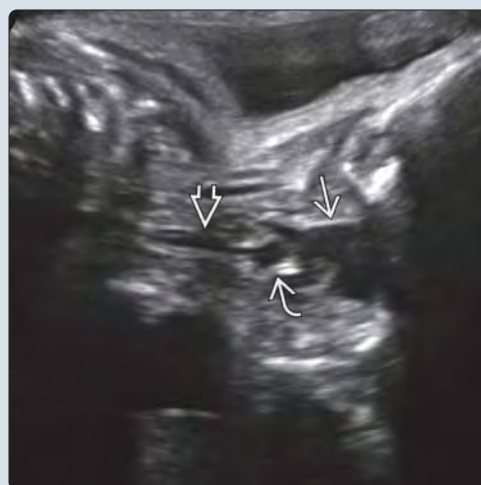DIAGNOSTIC CHECKLIST

- Ultrasound is poor in detecting EA before onset of polyhydramnios
 - Must have high degree of suspicion and perform follow-up scans in setting of small stomach

(Left) Graphic shows frequency and types of esophageal atresia (EA). EA with a distal tracheoesophageal fistula (TEF) (A) comprises the vast majority. Other types, in order of frequency, include EA with no fistula (B), "H" fistula with no EA (C), EA with proximal and distal fistulas (D), and EA with a proximal fistula (E). (Right) At 24 weeks, the stomach appears small and was persistently small over multiple scans. The additional finding of polyhydramnios led to a suspicion for EA.



(Left) Focused imaging of the neck at 32 weeks, in the same case, shows the normal fluid-filled hypopharynx, epiglottis, and proximal trachea. The esophagus will be just posterior to these structures. (Right) A plane just posterior to the prior image shows an anechoic pouch at the point of esophageal atresia. Real-time imaging showed this blind-ending pouch expanded and contracted with fetal swallowing. Note the adjacent carotid artery provides an anatomic landmark.



TERMINOLOGY

Definitions

- Esophagus atresia (EA) often associated with tracheoesophageal fistula (TEF)
 - > 90% have fistula
 - Proximal atresia with distal TEF most common type

IMAGING

General Features

- Best diagnostic clue
 - Combination of small stomach, polyhydramnios, and fetal growth restriction (FGR) in late 2nd and 3rd trimester
- Diagnosis often missed before polyhydramnios develops
- Reported sensitivity of ultrasound for detection of EA < 50%

Ultrasonographic Findings

- Small or absent stomach bubble
 - Complete absence suggests either no TEF or very small, stenotic connection
- Pouch sign
 - Transient filling of proximal esophagus with swallowing
 - Not pathognomonic: May be seen in normal fetuses and should not be used as sole criterion for diagnosis of atresia
 - Pouch ends above clavicles in normals; if seen lower, more likely EA
- Frequently associated with duodenal atresia (DA)
 - May not be able to diagnose combination of EA + DA prenatally if TEF present
 - Stomach secretions may decompress through fistula
 - If TEF not present, distal esophagus, stomach, and duodenum form closed "C loop"
 - Normal secretions accumulate in this isolated loop
 - May cause marked dilatation
 - Has been detected in 1st trimester
 - High risk for trisomy 21 (T21)
- FGR
 - Seen in up to 40%
 - Ingested amniotic fluid important for growth in latter 1/2 of gestation
 - Higher gastrointestinal obstructions cause greatest growth disturbances
 - Manifests in late 2nd or 3rd trimester
- Polyhydramnios
 - Rarely develops before 20 weeks
 - Fetal swallowing not important part of amniotic fluid dynamics until that time
- Part of VACTERL (vertebral anomalies, anal atresia, cardiac malformation, TEF/EA, renal anomalies, limb malformations) association

MR Findings

- Useful to look for esophageal pouch in setting of small stomach and polyhydramnios
 - Significant positive predictive value for EA when present on fetal MR
- Patency of esophagus difficult to determine

Imaging Recommendations

- Often difficult to define when stomach is "small"
 - Stomach size varies between patients
 - Stomach size varies in same fetus over several hours
 - Related to swallowing and peristalsis
 - Requires experience to assess size in many cases
- Follow-up scans should be performed on all fetuses with small stomach
 - Small stomach may be transient finding in normal fetus, especially in 1st and 2nd trimester
 - Persistence on multiple exams more likely pathologic
 - Very suspicious if polyhydramnios develops
- Perform focused exam
 - Look specifically at neck and upper chest for esophageal pouch
 - Pouch will expand with fetal swallowing
 - Distinguish from normal hypopharynx anatomy
 - ◻ Trachea should be easily identified as separate nondistensible structure, relatively thicker wall and connected to epiglottis
 - ◻ Esophagus located more posterior than trachea
 - Determine location of distal end of pouch
 - Termination in neck worse prognosis than termination in mediastinum
- Evaluate
 - Growth
 - Amniotic fluid
 - Combination of FGR and polyhydramnios highly suggestive of underlying abnormality
 - Always consider EA in this setting
- Search for other anomalies
 - > 50% have other anomalies
 - Specifically target malformations seen in VACTERL association
- Dedicated fetal echo for cardiac malformations

DIFFERENTIAL DIAGNOSIS

Causes of Small or Absent Stomach

- **Congenital diaphragmatic hernia**
 - Stomach in chest
 - May also have small bowel and liver in chest
 - Peristalsis within chest mass pathognomonic
 - Deviation of cardiac axis
 - Abdominal circumference small
 - Polyhydramnios
- **Abnormal swallowing**
 - Central nervous system malformations
 - Neuromuscular disorders
 - Arthrogryposis
 - Cleft lip, palate

PATHOLOGY

General Features

- Etiology
 - Embryology
 - Incomplete foregut division
 - Tracheoesophageal septum normally divides ventral (respiratory) from dorsal (digestive) segments

- Mechanism not completely understood
- Localized vascular compromise hypothesized for atretic segment without TEF
- Maternal diabetes is risk factor
- Genetics
 - Majority sporadic occurrence
 - Chromosomal
 - Aneuploidy reported in 5-44% of EA cases
 - Trisomy 18 (T18) most common, T21
 - EA without TEF more common in T21
 - Defined genetic syndrome in 10%
 - **Feingold syndrome**
 - Most frequent cause of familial syndromic gastrointestinal atresias
 - 30-40% will have EA with TEF
 - Microcephaly, syndactyly, clinodactyly
 - Mutation of *MYCN* gene
 - **CHARGE syndrome**
 - Coloboma, heart malformation, choanal atresia, retardation of growth &/or development, genital anomalies, ear anomalies
 - EA/TEF in 10%
 - 2/3 have mutation in *CHD7* gene
 - **AEG syndrome**
 - Anophthalmia, esophageal atresia, genital anomalies
 - Mutation of *SOX2* gene
 - **Pallister-Hall syndrome**
 - Postaxial polydactyly, anal atresia, hypothalamic hamartoma, renal anomalies, laryngotracheoesophageal cleft
 - Mutation of *GLI3* gene
 - Case reports in thrombocytopenia and absent radius (TAR) syndrome and Fanconi anemia
- > 50% have at least one associated anomaly
 - Congenital heart anomalies
 - Multiple bowel atresias often present
 - Bowel malrotation
 - VACTERL association in ~ 30% of cases
 - Any or all anomalies in syndrome may be present
 - Central nervous system anomalies
 - Case reports of biliary atresia

Staging, Grading, & Classification

- Types and percentages of EA
 - Proximal atresia with distal TEF (82%)
 - Proximal and distal atresia, no fistula (9%)
 - H-type fistula with no atresia (6%)
 - Atresia with both proximal and distal fistulas (2%)
 - Proximal TEF with distal atresia (1%)

CLINICAL ISSUES

Presentation

- Most common signs/symptoms
 - Polyhydramnios
 - Large-for-dates
 - Preterm labor
- Abnormal serum screen (T18, T21)
- Other more obvious findings in VACTERL association or T18, T21

- Postnatal
 - Coughing, drooling, choking
 - Recurrent pneumonia (H-type)

Demographics

- 1:2,000-3,000 live births
- Males slightly more common than females

Natural History & Prognosis

- 22-75% mortality for those detected in utero
- > 90% diagnosed within first day of life after delivery
- In liveborns, up to 24% mortality rate
 - Sepsis most common cause of death
 - Presence of cardiac defect greatest effect on survival in neonatal group
- Even if isolated, long-term sequelae common
 - Esophageal dysmotility in nearly 100%
 - Feeding difficulties, strictures, gastroesophageal reflux, aspiration, recurrent TEF, tracheomalacia

Treatment

- Genetic counseling for family history/syndromes
- All fetuses should be karyotyped
- Amnioreduction for severe polyhydramnios
 - Reduce uterine irritability
 - Maternal comfort
- Predelivery consult with pediatric surgeon
- Deliver at tertiary care center with facilities for early surgical intervention after birth
- Surgical repair, especially of long atretic segments, often requires staged procedures and prolonged hospitalizations
 - Various surgical techniques based on severity
 - Resection of atretic segment and reanastomosis
 - Staged gastric transposition
 - Suture approximation without anastomosis
 - Requires multiple luminal dilatations of approximated segment
 - Gastrostomy tube in some cases

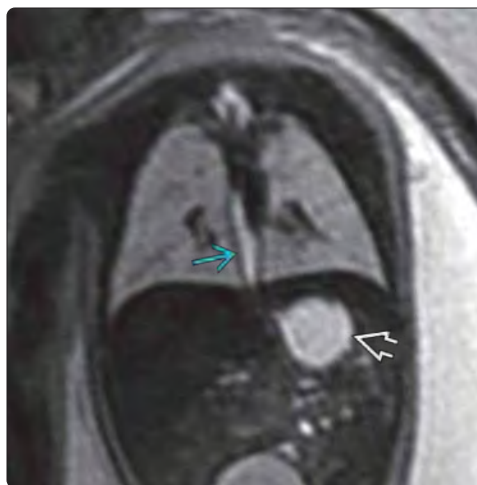
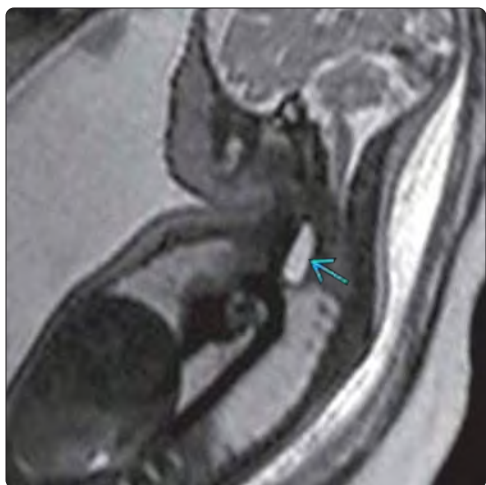DIAGNOSTIC CHECKLIST

Image Interpretation Pearls

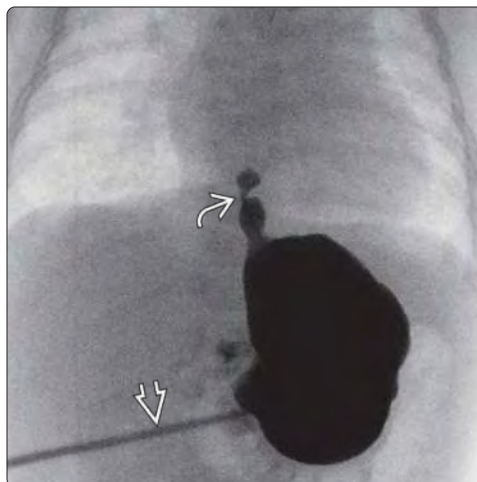
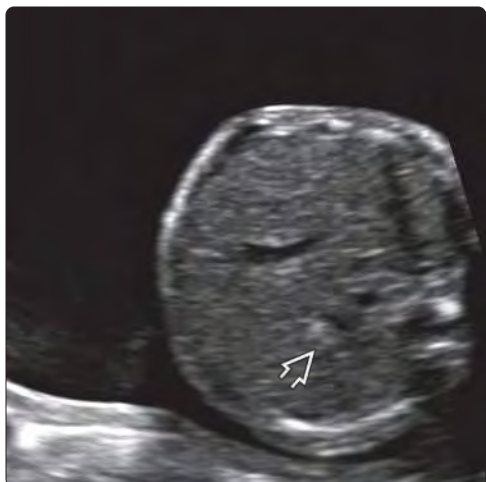- Ultrasound is poor in detecting EA before onset of polyhydramnios
 - Must have high degree of suspicion and perform follow-up scans in setting of small stomach
 - Pouch sign can be seen as transient finding in normal fetuses
- Fetal MR can be useful to identify esophageal pouch in setting of small stomach and polyhydramnios
- Combination of FGR and polyhydramnios should prompt careful search for anomalies, including EA

SELECTED REFERENCES

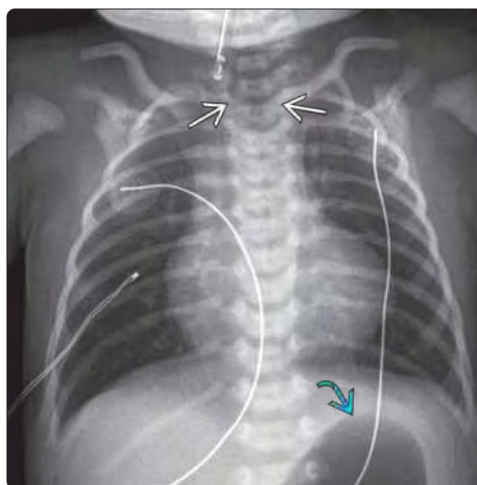
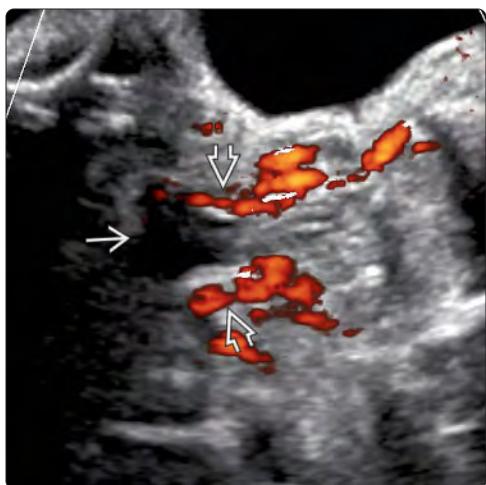1. Cartabuke RH et al: Long-term esophageal and respiratory outcomes in children with esophageal atresia and tracheoesophageal fistula. *Gastroenterol Rep (Oxf)*. ePub, 2015
2. Hochart V et al: The contribution of fetal MR imaging to the assessment of oesophageal atresia. *Eur Radiol*. 25(2):306-14, 2015
3. Ethun CG et al: Fetal MRI improves diagnostic accuracy in patients referred to a fetal center for suspected esophageal atresia. *J Pediatr Surg*. 49(5):712-5, 2014
4. Kunisaki SM et al: The diagnosis of fetal esophageal atresia and its implications on perinatal outcome. *Pediatr Surg Int*. 30(10):971-7, 2014



(Left) Sagittal oblique MR through the fetal chest shows a fluid-filled proximal esophageal pouch in this fetus with polyhydramnios and small stomach in the 3rd trimester. Fetal MR is a useful modality to confirm a suspicion of esophageal atresia. **(Right)** In this case, there is a visible distal esophagus and a fluid-filled stomach due to a TEF connecting the distal esophagus to the carina (confirmed at postnatal repair). EA with a distal TEF is the most common variant.



(Left) At 24 weeks, polyhydramnios is present and no stomach could be identified (shows the site of possible collapsed stomach). No fluid was identified in the stomach throughout gestation, which is suspicious for EA without TEF. **(Right)** Postnatal image of the same baby after administration of barium through the indwelling gastric tube shows reflux into the truncated distal esophagus. EA without a TEF was identified at surgery.



(Left) Coronal ultrasound of the neck shows an esophageal pouch. The carotid vessels are directly adjacent to the midline pouch, which can be traced to the hypopharynx to confirm esophageal origin and exclude a cystic neck mass. **(Right)** Postnatal radiograph of the same patient shows an orogastric tube within the air-distended proximal esophageal pouch. There is gas in the stomach, therefore a TEF must be present.

KEY FACTS

TERMINOLOGY

- Lack of normal duodenal canalization leading to partial (web/stenosis) or complete obstruction (atresia)

IMAGING

- Double bubble
 - Fluid-filled stomach and duodenum
- Persistent fluid in duodenum is always abnormal
- Hyperperistalsis of stomach on real-time imaging
- Fetal regurgitation may intermittently decompress stomach
- Polyhydramnios

TOP DIFFERENTIAL DIAGNOSES

- Distal atresias
 - Jejunal, ileal, colonic, anal
- Abdominal cysts
 - None will communicate with stomach
 - Polyhydramnios not feature

PATHOLOGY

- Duodenum most common site of intestinal obstruction
 - 2nd and 3rd portions most commonly involved
- 30% of duodenal atresia (DA) cases have trisomy 21
- 5-15% of trisomy 21 cases have DA
- 50-70% of DA cases have other anomalies
 - Cardiac and other GI malformations are most common

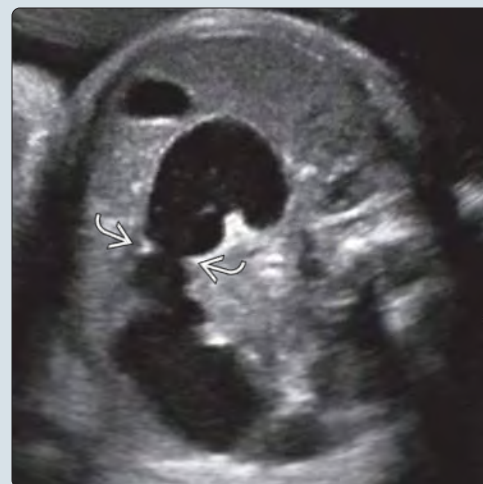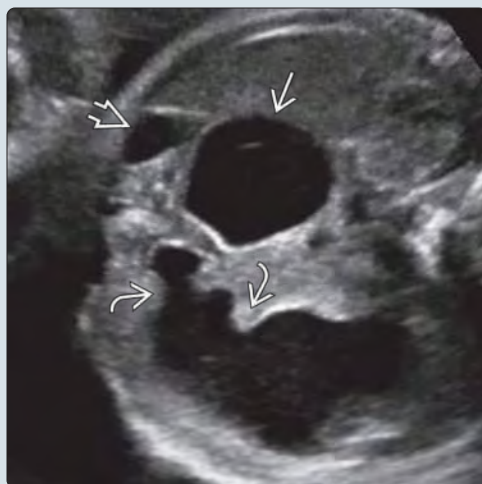
CLINICAL ISSUES

- All fetuses should be karyotyped
- Overall mortality is 15-40%
 - Dependent on associated abnormalities
- Isolated defect in liveborn; 95% survival with prompt surgical treatment
- Surgical correction is usually performed in immediate neonatal period

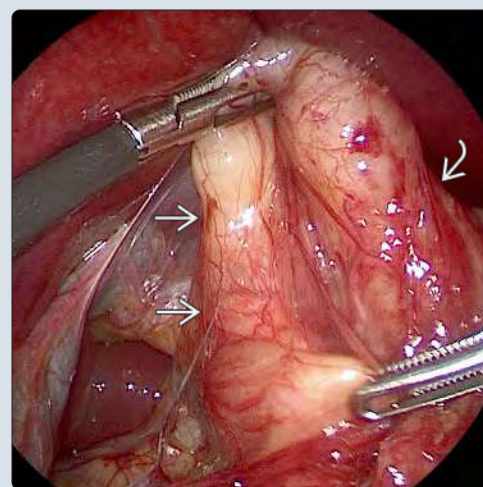
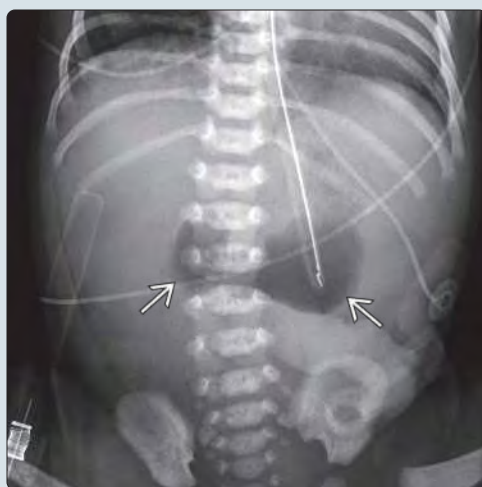DIAGNOSTIC CHECKLIST

- Continuity with stomach confirms diagnosis

(Left) Third trimester ultrasound shows a dilated stomach with prominent rugal folds. The duodenal bulb is markedly enlarged and polyhydramnios was present. The gallbladder is displaced by the duodenal bulb. Noninvasive prenatal testing showed trisomy 21. **(Right)** Use real-time imaging to connect the stomach with the dilated duodenum via an open pylorus, excluding an abdominal cystic mass. Hyperperistalsis and fluid motion through the pylorus can also be seen on real-time imaging.



(Left) Postnatal radiograph in the same patient confirms the typical appearance of the double bubble seen with duodenal atresia (DA). The remainder of the abdomen is gasless due to the proximal atresia. **(Right)** Within a few days of birth, neonates with DA typically undergo laparoscopic duodenoduodenostomy to bypass the area of atresia/obstruction. Note the stomach.



TERMINOLOGY

Synonyms

- Congenital duodenal obstruction more inclusive term
 - Includes duodenal atresia (DA), stenosis, web, or annular pancreas

Definitions

- Lack of normal duodenal canalization leading to partial (web/stenosis) or complete (atresia) obstruction

IMAGING

General Features

- Best diagnostic clue
 - Stomach and duodenum can be connected during real-time imaging
- Duodenum most common site of intestinal obstruction
- Normal gastric incisura may mimic appearance
- Persistent fluid in duodenum is always abnormal

Ultrasonographic Findings

- Double bubble
 - Fluid-filled stomach and duodenum
 - Generally seen after 20 weeks
 - Has been diagnosed in 1st trimester
 - May have worse prognosis
 - Hyperperistalsis of stomach may be seen on real-time imaging
- Polyhydramnios
 - Usually not detected before 24 weeks
 - Present in most cases by 3rd trimester
 - May become severe
 - Fluid is often echogenic
 - May be due, at least in part, to fetal regurgitation, which intermittently decompresses stomach
- Other GI malformations are common
 - Esophageal atresia (EA)
 - If tracheoesophageal fistula is not present, fluid may accumulate in distal esophagus, stomach, and duodenum forming C loop
 - Distal bowel atresia, malrotation
 - Biliary or gallbladder atresia
- Other associated findings
 - Cardiac malformations in 37%
 - Skeletal anomalies
 - Vertebral anomalies, caudal regression sequence
 - Radial ray malformation, clubfeet
 - Genitourinary
 - Hydronephrosis
 - Multicystic dysplastic kidney
- Fetal growth restriction
 - Ingested amniotic fluid important for growth in latter 1/2 of gestation
 - Higher GI obstructions cause greatest growth disturbance
- Chromosomal anomalies
 - 30% of DA fetuses have trisomy 21 (T21)
 - Combination of EA + DA → even greater risk of T21

- Other causes of duodenal obstruction, including duodenal web/stenosis, annular pancreas, or Ladd bands may not be seen until 3rd trimester, if at all
 - Consider when duodenal bulb is not as distended and has more normal elongated appearance
 - Polyhydramnios is not as severe

MR Findings

- Fluid-filled stomach and duodenum
 - Low-signal T1WI, high-signal T2WI
- MR adds information about distal bowel, specifically looking for other sites of atresia

Imaging Recommendations

- Must connect stomach with duodenum to confirm diagnosis
- Look for other findings of T21
 - Cardiac malformations
 - Atrioventricular septal defect + DA → greatest risk for T21
 - Ventricular septal defect, tetralogy of Fallot
 - GI
 - EA, omphalocele
 - Other markers
 - Nuchal thickening
 - Short femur and humerus
 - Absent or hypoplastic nasal bone
 - Mild ventriculomegaly
 - Echogenic bowel
 - Intracardiac echogenic focus
 - Renal pelviectasis
 - 5th finger clinodactyly, sandal gap foot
- Dedicated cardiac echo because of high association with cardiac anomalies
- Follow for worsening polyhydramnios

DIFFERENTIAL DIAGNOSIS

Distal Atresias

- Jejunal, ileal, colonic, anal
- Multiple dilated distal bowel loops

Antral Web/Atresia

- Single bubble
 - Dilated stomach
 - Duodenum not seen
- Much less common than DA

Abdominal Cysts

- None will communicate with stomach
- Polyhydramnios not feature
- **Choledochal cyst**
 - Right-sided, near gallbladder
 - Follow bile ducts into cyst
- **Ovarian cyst**
 - Female only
 - Not usually seen until 3rd trimester
- **Duplication cyst**
 - Duodenal duplication cyst can be difficult to differentiate from DA
 - Most duplications cysts are farther distal
 - Ileum most common location

- **Mesenteric cyst**
 - Unilocular or multilocular cystic mass
 - Often large, displacing bowel

PATHOLOGY

General Features

- Etiology
 - 2 theories of embryologic development
 - Failure of normal recanalization of duodenal lumen at 6-9 weeks (most widely accepted)
 - Vascular compromise to developing gut
- Genetics
 - Mostly sporadic
 - Chromosomal
 - 30% of DA cases have T21
 - 5-15% of T21 cases have DA
 - Feingold syndrome
 - Autosomal dominant
 - Most frequent cause of familial syndromic GI atresias
 - 16-31% with DA
 - Microcephaly, syndactyly, clinodactyly
 - Mutation of *MYCN* gene
- Associated abnormalities
 - 50-70% of DAs have other anomalies
 - Chromosomal
 - Cardiac
 - Other GI
 - Skeletal
 - Genitourinary

Staging, Grading, & Classification

- Type I (most common)
 - Intact intestinal wall and mesentery
 - Septal or membranous luminal obstruction
 - Diameter of proximal bowel segment >> distal segment
- Type II
 - Intestinal segments connected by fibrous cord
- Type III
 - 2 blind ends without intervening cord
 - Wedge-shaped mesenteric defect

Gross Pathologic & Surgical Features

- 2nd and 3rd portions most commonly involved
- Most near ampulla of Vater
- May be incomplete (web)
 - Same risk of T21
- Annular pancreas frequently present

CLINICAL ISSUES

Presentation

- Polyhydramnios
 - Large for dates
 - Preterm labor
- Abnormal serum screen (T21)
- Neonatal
 - Vomiting
 - 85% bilious
 - 15% nonbilious: Proximal to ampulla of Vater

Demographics

- 1-3:10,000 births
- Most common GI anomaly in fetuses with T21

Natural History & Prognosis

- Dependent on associated abnormalities
- Overall mortality is 15-40%
 - Mortality is greatest for those diagnosed in utero
 - At risk for 3rd-trimester in utero demise, even if isolated
- 95% survival with prompt surgical treatment if DA is isolated defect in liveborn infant
 - Trisomy 21 does not increase mortality risk if DA is isolated defect
- Recurrence risk is same as in general population

Treatment

- All fetuses should be karyotyped
- Genetic counseling
- Amnioreduction for severe polyhydramnios
 - Reduce uterine irritability
 - Maternal comfort
- Immediate orogastric suction after delivery
- Plain film after delivery
 - If gas-filled double bubble, no other GI work-up needed prior to surgery
 - If gas present distal to duodenum, perform upper GI exam to evaluate for web/stenosis
- Surgical correction is usually performed in immediate neonatal period
 - Classic transverse abdominal incision being replaced by more conservative techniques
 - Laparoscopic duodenoduodenostomy
 - Contraindications to immediate repair
 - Severe cardiac malformation may require repair 1st
 - Medically unstable (respiratory insufficiency, fluid or electrolyte imbalance)

DIAGNOSTIC CHECKLIST

Consider

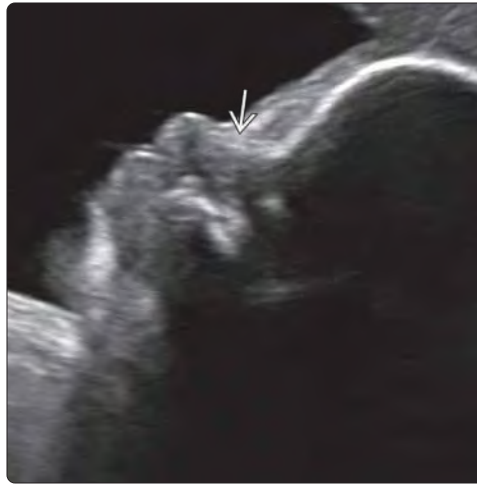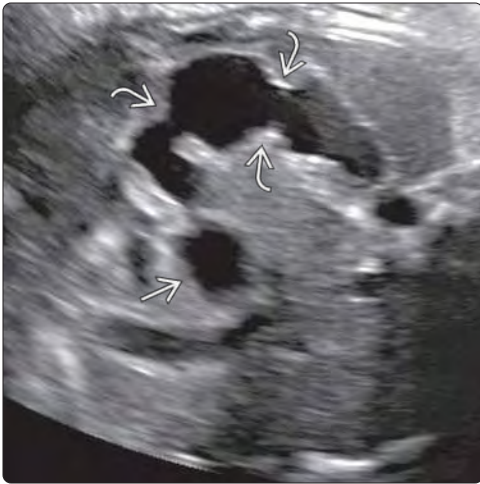
- Coexistent EA when DA presents early in gestation with marked dilatation (C loop) and polyhydramnios
 - High likelihood of T21




Image Interpretation Pearls

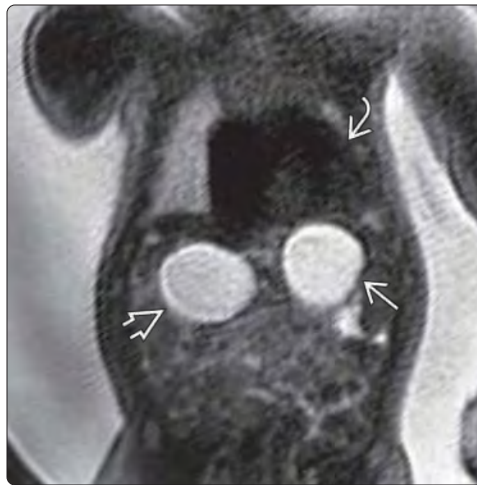
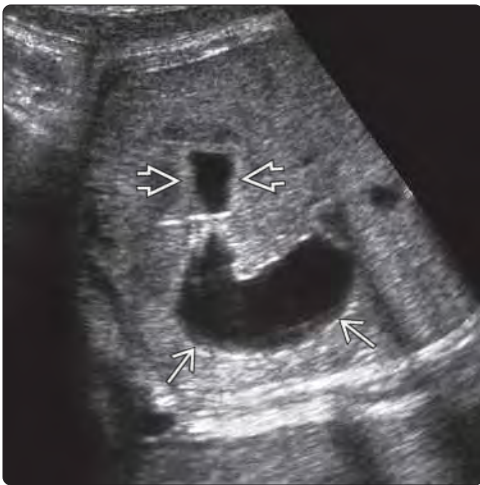
- Continuity with stomach confirms diagnosis
- Normal peristalsis with prominent gastric incisura can mimic appearance of DA
 - Look at location of 2nd bubble
 - Antrum will be anteriorly located
 - Duodenum medial to stomach






SELECTED REFERENCES

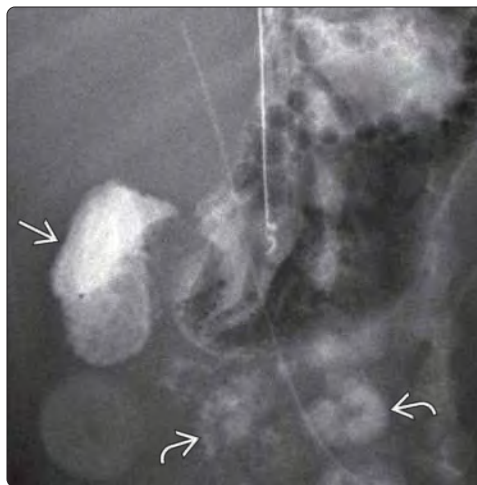
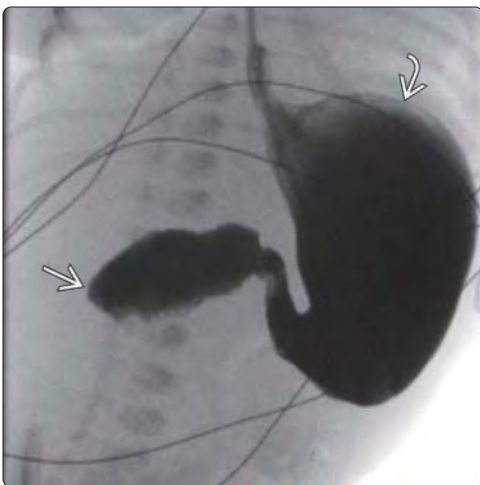
1. Parmentier B et al: Laparoscopic management of congenital duodenal atresia or stenosis: A single-center early experience. *J Pediatr Surg.* 50(11):1833-6, 2015
2. Stoll C et al: Associated congenital anomalies among cases with Down syndrome. *Eur J Med Genet.* 58(12):674-80, 2015
3. Adams SD et al: Malrotation and intestinal atresias. *Early Hum Dev.* 90(12):921-5, 2014
4. Chen QJ et al: Congenital duodenal obstruction in neonates: a decade's experience from one center. *World J Pediatr.* 10(3):238-44, 2014







(Left) In this case of DA, multiple focal gastric contractions  reflecting hyperperistalsis are demonstrated. The dilated duodenal bulb  is also shown. Severe associated polyhydramnios was present. **(Right)** Profile view of the same fetus at 34 weeks was easily obtained due to the polyhydramnios and shows an absent nasal bone . Postnatal exam confirmed trisomy 21.



(Left) Oblique axial US shows a prominent stomach , but the dilated proximal duodenum  is more elongated in appearance than usually seen with DA, and there was only mild polyhydramnios. This suggests an incomplete obstruction and an annular pancreas was identified postnatally. **(Right)** Coronal MR shows the typical appearance of DA, with a dilated stomach  and duodenal bulb . The heart is enlarged  in this fetus who also had a complex cardiac anomaly. About 50-70% of DA cases have other anomalies.



(Left) Postnatal upper GI confirms the presence of a distended stomach  and a distended, blind-ending duodenum  in the setting of DA. **(Right)** Postoperative upper GI in the same patient shows the duodenal bulb remains dilated ; however, contrast now passes into the normal distal small bowel  after the successful duodenoduodenostomy.

KEY FACTS

TERMINOLOGY

- 1 or more areas of stenosis or atresia involving small bowel

IMAGING

- Normal small bowel < 7-mm diameter
- Echogenic bowel in 2nd trimester may be 1st sign of atresia
- Dilated, fluid-filled loops of bowel progressively enlarge
 - Triple bubble for proximal jejunal atresia
 - Sausage-shaped bowel loops
- Hyperperistalsis of obstructed segments in real time
- Polyhydramnios more likely with proximal atresia
 - Usually develops after 26 weeks
- At risk for perforation and meconium peritonitis
 - More common with ileal obstruction
- Consider fetal MR to better delineate site of obstruction
 - Look for high-signal meconium in normal colon on T1WI

TOP DIFFERENTIAL DIAGNOSES

- Meconium ileus

- Anal atresia
- Ureterectasis

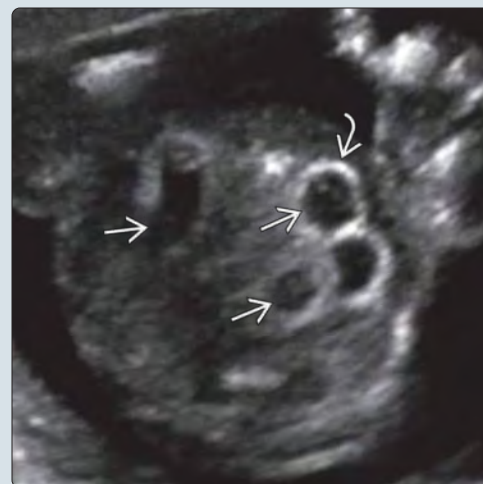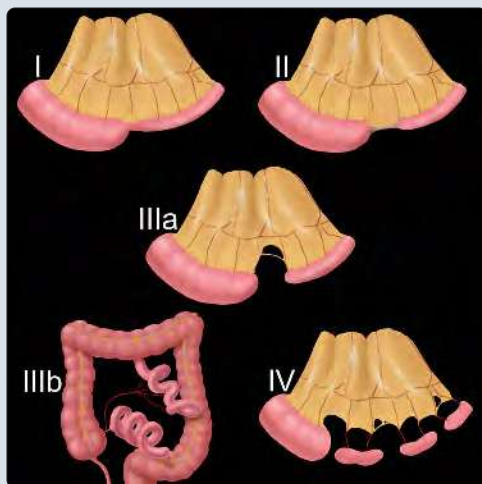
PATHOLOGY

- Vascular injury most accepted theory of development
- Frequently associated with other GI anomalies
 - Gastroschisis, volvulus, intussusception, malrotation
- Anomalies outside GI tract uncommon

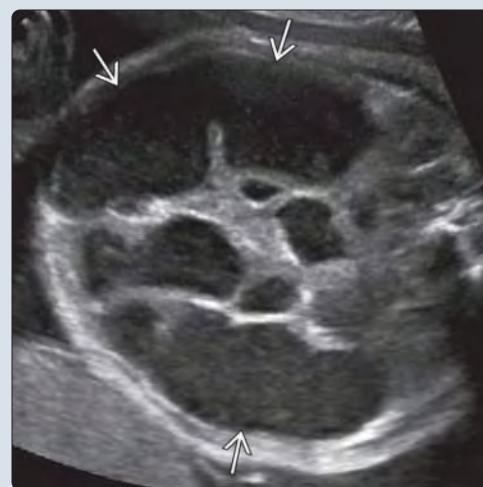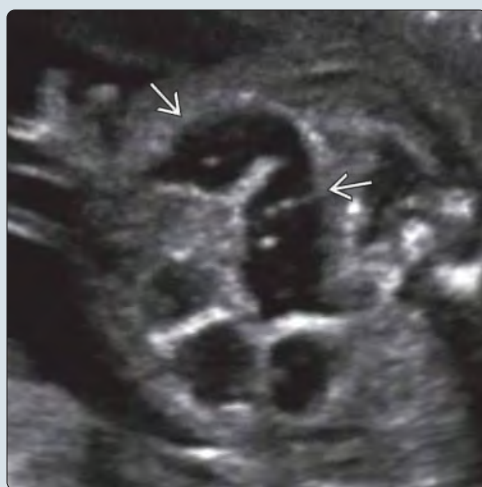CLINICAL ISSUES

- > 90% survival
- Long-term outcome dependent on length of resected bowel and associated malformations
 - Long-term sequelae include short gut syndrome, dysmotility, and functional obstruction
- Testing for cystic fibrosis is recommended in all cases of distal obstruction
 - Meconium ileus may have identical appearance to distal atresia

(Left) Surgical classification system of jejunoileal atresia: Type I is membranous; type II has a fibrous cord but no mesenteric defect; type IIIa shows a mesenteric gap; type IIIb is known as apple peel; and type IV represents multiple atresias. Type IIIb is more likely to be familial. **(Right)** At 20 weeks, there are a few mildly dilated loops of debris-filled bowel with an echogenic wall. Given the central location of the bowel, these loops are almost always small bowel, which should not be seen in the early 2nd trimester.



(Left) At 23 weeks in the same case, the bowel distention has increased, and there was peristalsis noted on real-time imaging. Polyhydramnios may not be seen before 26 weeks but frequently develops with more proximal atresias. **(Right)** At 33 weeks, there was marked continual bowel peristalsis on real-time imaging with distention up to 2.8 cm. Hypoechoic debris (succus entericus) fills the bowel lumen. Given the marked distention without perforation, jejunal atresia was correctly diagnosed.



TERMINOLOGY

Definitions

- 1 or more areas of stenosis or atresia involving small bowel

IMAGING

General Features

- Best diagnostic clue
 - Hyperperistalsis within dilated small bowel loops highly suggestive of obstruction
- Location
 - Roughly equal involvement between jejunum and ileum
 - 7% involve both jejunum and ileum
- Sensitivity for US detection reported as high as 100% for jejunal and 75% for ileal atresia

Ultrasonographic Findings

- Normal small bowel
 - < 7-mm diameter
 - Routinely seen in late 2nd and 3rd trimester
 - Peristalsis routinely demonstrated
- Atresias
 - Echogenic bowel in 2nd trimester may be 1st sign
 - Dilated, fluid-filled loops of bowel develop
 - Bowel contents (succus entericus) commonly echogenic
 - Triple bubble for proximal jejunal atresia
 - Sausage-shaped bowel loops
 - Hyperperistalsis of obstructed segments often seen in real time
 - Continued bowel dilation into 3rd trimester
 - Bowel diameter > 17 mm with polyhydramnios may increase specificity of diagnosis
 - Can rarely present as cyst-like mass
 - Peristalsis distinguishes atresia from other abdominal cysts
 - Dilated stomach also often seen
 - More common with jejunal atresia
 - May be seen before bowel dilatation
- Polyhydramnios
 - May not see before 26 weeks
 - Timing and severity dependent on site of atresia
 - Polyhydramnios seen earlier with more proximal atresias
 - Seen in < 50% of cases of jejunal obstruction
 - Even less frequently with ileal obstructions
- At risk for perforation and meconium peritonitis (~ 6%)
 - Ascites
 - Peritoneal calcifications
 - Pseudocysts
 - More common with distal atresias
- Fetal growth restriction (FGR)
 - Proximal atresias more likely to have FGR
 - Ingested amniotic fluid important for fetal growth in latter half of gestation

MR Findings

- May better delineate site of obstruction
- Obstructed fluid-filled loops
 - Low-signal T1WI, high-signal T2WI

- Signal intensity may vary among isolated segments
 - May allow diagnosis of multiple atresias
- Look for normal colon
 - Meconium high signal on T1WI

Imaging Recommendations

- Protocol advice
 - Frequent follow-up scans
 - Fetal growth
 - Polyhydramnios
 - Increasing bowel dilatation
 - Perforation
 - Obtain sonographic views of rectum/anus to evaluate for anal atresia
- Determining point of obstruction is difficult, especially when multiple loops are dilated
- Jejunal vs. ileal atresia
 - Jejunal
 - More frequently multiple
 - Greater bowel dilatation
 - ◻ More likely to have enlarged stomach
 - Less likely to perforate
 - Higher association with fetal growth restriction (FGR)
 - Ileal
 - Usually single
 - Less distensible, with earlier perforation
 - Usually not associated with polyhydramnios

DIFFERENTIAL DIAGNOSIS

Meconium Ileus

- Obstruction from meconium impaction in distal ileum
- Often indistinguishable from atresia
- High association with cystic fibrosis
 - Echogenic bowel on 2nd-trimester scan

Volvulus

- Ischemia leads to infarction
 - Dilated bowel segment shows no peristalsis
 - Heterogeneous lumen contents from hemorrhage and necrosis
- May be indistinguishable early

Anal Atresia

- Very difficult to distinguish large from small bowel in fetus
- Absent anal target sign: Hyperechoic mucosa with hypoechoic ring
- Associated with VACTERL syndrome

Ureterectasis

- Tubular appearance may be mistaken for bowel
- Often enlarged bladder
 - Posterior urethral valves, prune-belly syndrome

Normal Colon

- Can appear prominent in 3rd trimester
 - Normal caliber 18 mm

Duodenal Atresia

- Double bubble
- No bowel dilatation beyond duodenum

Abdominal Cysts

- Single cysts, not tubular
- No peristalsis

PATHOLOGY

General Features

- Etiology
 - Vascular injury most accepted theory of development; multiple possible mechanisms
 - Kinking of mesenteric artery during bowel rotation (6-12 weeks)
 - Fetal hypotension
 - Vascular malformation
 - In utero volvulus, intussusception, gastroschisis
 - Maternal cocaine use
- Genetics
 - Most sporadic
 - Familial cases reported
 - Apple-peel atresia
 - Feingold syndrome
 - Most frequent cause of familial syndromic gastrointestinal atresias
 - 3-16% have jejunal atresia, 12% have multiple atresias
 - Microcephaly, syndactyly, clinodactyly
- Associated abnormalities
 - Frequently associated with other GI anomalies
 - Gastroschisis
 - Malrotation
 - Look for superior mesenteric vein (SMV), which is normally right of superior mesenteric artery (SMA)
 - Reversed in malrotation: SMV left of SMA
 - Risk for volvulus
 - Anomalies outside GI tract uncommon

Staging, Grading, & Classification

- Type I: Membranous atresia
 - Web or diaphragm occluding bowel segment
 - No mesenteric defect
 - Normal bowel length
- Type II: Blind ends separated by fibrous cord
 - No mesenteric defect
 - Normal bowel length
- Type IIIa: Blind ends with complete separation
 - V-shaped mesenteric defect
 - Short bowel
- Type IIIb: Affects long contiguous segment of jejunum and ileum (rare familial form)
 - Remaining segments have spiraled apple-peel appearance
 - Large mesenteric defect
- Type IV: Multiple small bowel atresias

CLINICAL ISSUES

Presentation

- Prenatal
 - Dilated bowel and possible polyhydramnios in late 2nd and 3rd trimester
- Postnatal

- Abdominal distention, failure to pass meconium, bilious emesis

Demographics

- 1:3,000-5,000 live births
- Accounts for 39% of all intestinal atresias

Natural History & Prognosis

- Jejunal
 - Higher association with premature delivery
 - Likely secondary to polyhydramnios
 - FGR more often present
 - Amniotic fluid nutritional source for fetus
 - More likely to have multiple atresias
 - Not detectable prenatally because segments distal to obstruction are decompressed
- Ileal
 - More likely to perforate
- >90% survival
 - Factors negatively impacting prognosis
 - Increasing length of atretic segment
 - Multiple sites of atresia
 - Proximal worse than distal
 - Perforation
 - Volvulus
- Long-term outcome dependent on length of resected bowel and associated malformations
 - Short gut syndrome, dysmotility, and functional obstruction potential complications

Treatment

- Amniocentesis or parental screen for cystic fibrosis
- Amnioreduction for severe polyhydramnios
 - Reduce uterine irritability
 - Maternal comfort
- Surgical resection of affected bowel
 - May need staged procedure with diverting ostomy and later reanastomosis
 - Postoperative course dependent on complexity of procedure
 - Prolonged hospitalization and parenteral nutrition may be required

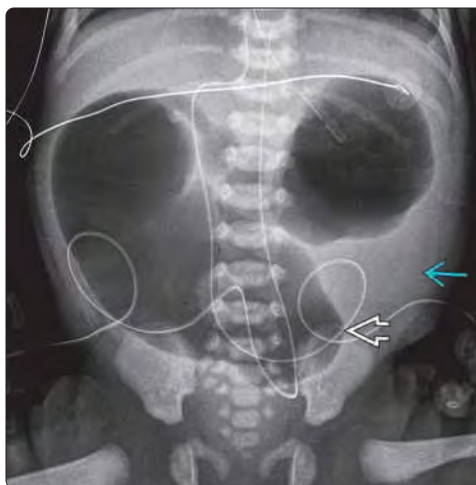
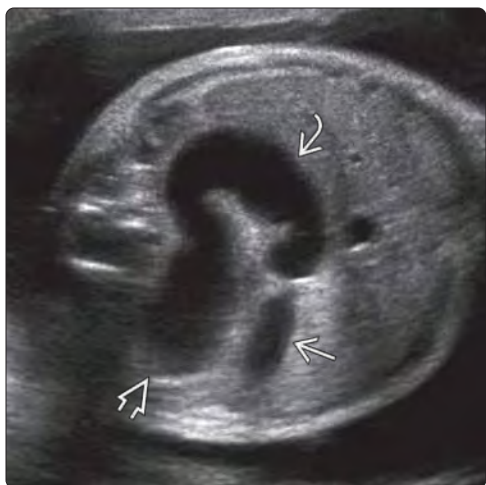DIAGNOSTIC CHECKLIST

Consider

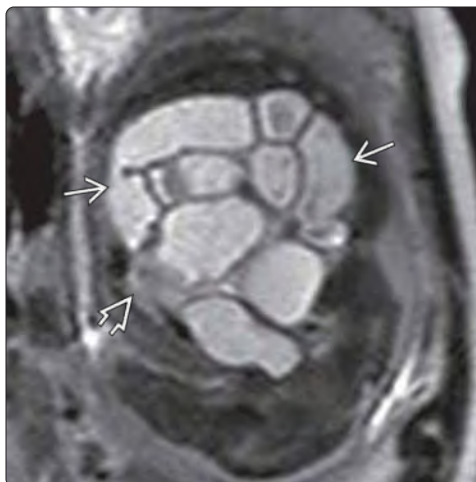
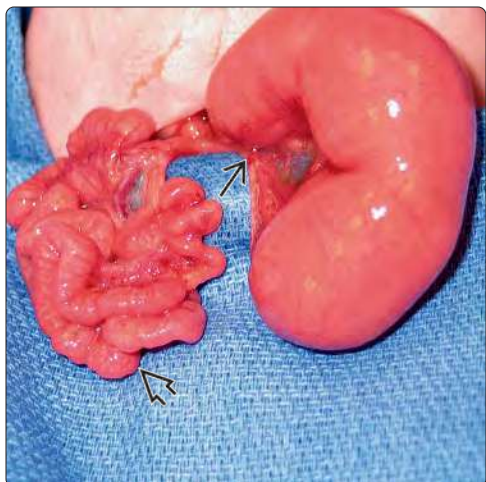
- Testing for cystic fibrosis is recommend in all cases of distal obstruction
 - Meconium ileus may have identical appearance to distal atresia

SELECTED REFERENCES

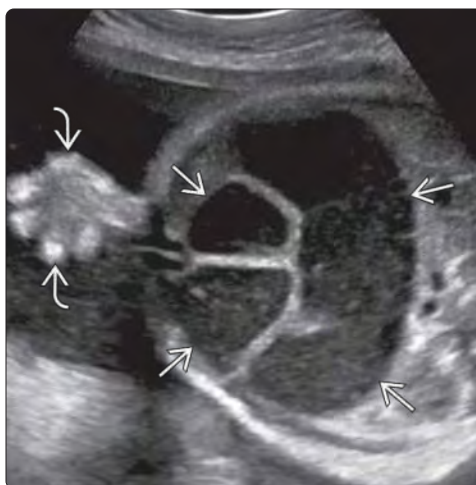
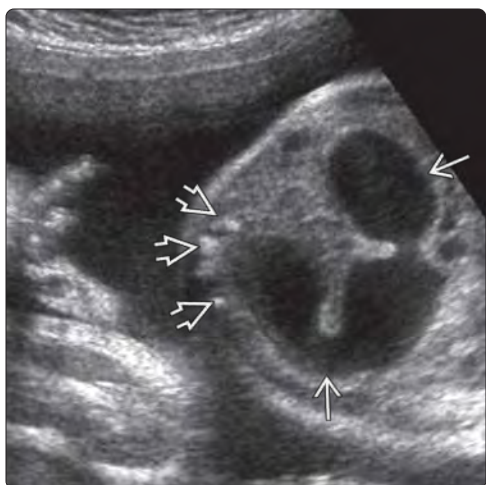
1. John R et al: Diagnostic accuracy of prenatal ultrasound in identifying jejunal and ileal atresia. *Fetal Diagn Ther.* 38(2):142-6, 2015
2. Virgone C et al: Accuracy of prenatal ultrasound in detecting jejunal and ileal atresia: systematic review and meta-analysis. *Ultrasound Obstet Gynecol.* 45(5):523-9, 2015
3. Takahashi D et al: Population-based study of esophageal and small intestinal atresia/stenosis. *Pediatr Int.* 56(6):838-44, 2014
4. Jo YS et al: Antenatal sonographic features of ileal atresia. *J Obstet Gynaecol Res.* 38(1):215-9, 2012
5. Rubesova E: Fetal bowel anomalies—US and MR assessment. *Pediatr Radiol.* 42 Suppl 1:S101-6, 2012



(Left) In this fetus with polyhydramnios at 31 weeks, dilated bowel can be traced from the stomach to the duodenum, terminating in a blind-ending loop of proximal jejunum. **(Right)** Postnatal radiograph after air injection into the NG tube shows the proximal jejunal blind-ending loop, with a gasless distal abdomen. Proximal jejunal atresia was confirmed surgically.



(Left) Intraoperative photograph shows a markedly dilated loop of jejunum with normal decompressed distal loops. Note the defect in the mesentery, making this a type IIIa atresia. **(Right)** Fetal MR can be helpful in delineating the site of bowel obstruction. In this 3rd-trimester fetus, there are multiple loops of fluid-filled bowel, which terminate at the distal jejunum/ileum where the lumen returns to normal caliber.



(Left) Sausage-like distended bowel was seen peristalsing in the midabdomen. Peritoneal calcifications are present, suggesting remote peritoneal spill of bowel contents with subsequent calcification (meconium peritonitis), which is more common with ileal atresia. **(Right)** In this fetus with gastroschisis, there are dilated intraabdominal small bowel loops. Bowel atresias are often associated with other GI abnormalities. Jejunojunctionostomy was performed to bypass a jejunal atresia.

KEY FACTS

TERMINOLOGY

- Atresia or stenosis involving colon
- Location: Anywhere along colon
 - Ascending colon (28%)
 - Splenic flexure (25%)
 - Transverse colon (23%)
 - Descending and sigmoid colon (20%)
 - Hepatic flexure (3%)
- Rare: 2-4% of all intestinal atresia

IMAGING

- Single dilated loop of bowel
 - In expected peripheral location of colon
 - Closed loop obstruction if competent ileocecal valve
 - Ascites from perforation
- Look for anal dimple to rule out anal atresia
- MR helpful to show dilation is colon
 - High-signal meconium with T1

TOP DIFFERENTIAL DIAGNOSES

- Anal atresia
- Jejunal atresia
- Cloacal malformation

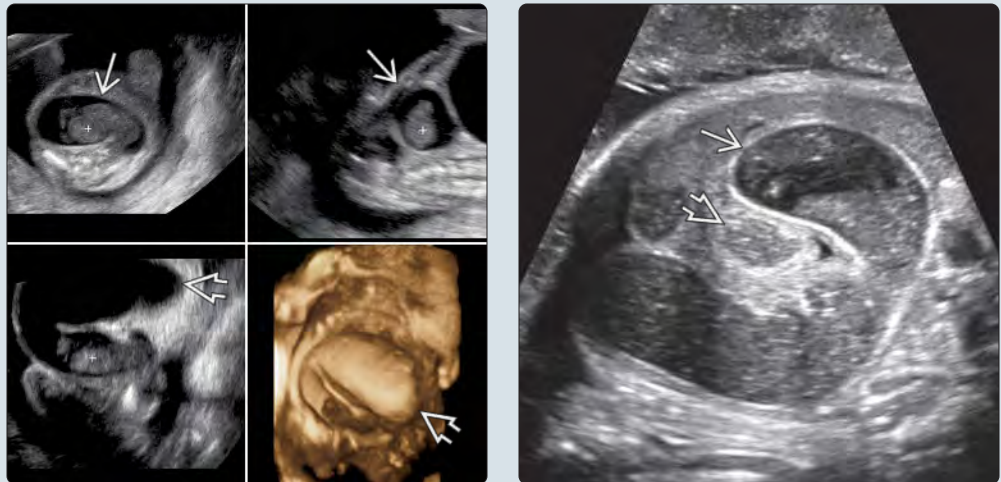
PATHOLOGY

- Etiology: Prenatal vascular interruption
 - Abnormal fibroblast growth factor 10 expression

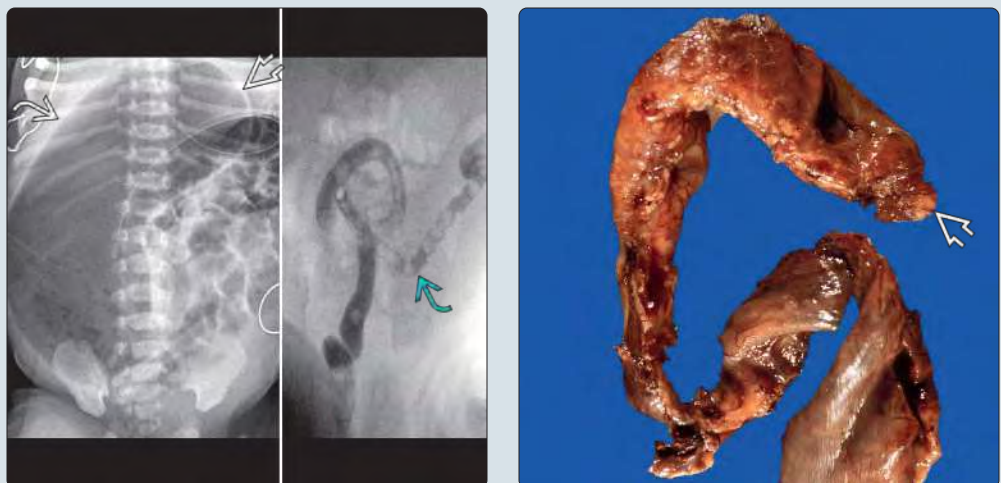
CLINICAL ISSUES

- Microcolon distal to atresia
- Associated with Hirschsprung
 - Worse prognosis
 - Consider rectal biopsy prior to definitive bowel continuity surgery
- Treatment
 - Primary resection with anastomosis
 - Colostomy diversion with subsequent anastomosis

(Left) Multiplanar and 3D images of a 22-week fetus show a dilated loop of bowel with internal echogenicity. The blind-ending loop and picture frame morphology are seen best on the coronal images. At 24 weeks, there was ascites, secondary to colonic perforation. **(Right)** At 34 weeks, the colon was once again distended, this time with meconium. The blind end of this closed loop colonic atresia case is once again seen. Note the minimal small bowel distention, which correlates with the degree of ileocecal valve competence.



(Left) In this newborn with colonic atresia, the ascending colon is massively dilated to the level of the transverse colon. Contrast enema, via the normal rectum, shows a micro colon. **(Right)** Gross pathology shows a resected blind-ending, dilated colon. The dilated portion of the colon proximal to the atresia is not functional and is most often resected prior to bowel continuity anastomosis.



TERMINOLOGY**Abbreviations**

- Colonic atresia (CA)

Definitions

- 1 or more areas of atresia or stenosis involving colon

IMAGING**General Features**

- Location
 - Ascending colon (28%)
 - Splenic flexure (25%)
 - Transverse colon (23%)
 - Descending and sigmoid colon (20%)
 - Hepatic flexure (3%)

Ultrasonographic Findings

- Single dilated loop of bowel
 - In expected peripheral location of colon
- ± associated small bowel distention
 - Depends on competence of ileocecal valve
 - Closed loop obstruction if competent valve
 - More prone to perforation
- Ascites from perforation
 - Anechoic early (no meconium)
 - Echogenic meconium peritonitis later

MR Findings

- MR may show haustra in distended colon
- Colon with meconium is bright on T1
 - Look for distal decompressed colon

Imaging Recommendations

- Best imaging tool
 - Routine US views of fetal abdomen
- Protocol advice
 - Look at perineum for anal dimple
 - Should see anal dimple ruling out anal atresia
 - Consider MR in complicated cases

DIFFERENTIAL DIAGNOSIS**Anal Atresia**

- High atresias more likely to have colonic distention in utero
- Associated with VACTERL syndrome

Jejunal Atresia

- Triple-bubble sign if proximal atresia
- Small bowel in different distribution than colon

Cloacal Malformation

- Female fetus only
- Fluid collection in pelvis is cloaca or vagina

PATHOLOGY**General Features**

- Etiology
 - Prenatal vascular interruption
 - Thrombosis, volvulus, strangulation → bowel necrosis
 - bowel reabsorption

- Abnormal fibroblast growth factor 10 expression
- Associated abnormalities
 - Hirschsprung disease
 - Abdominal wall defects
 - Riley-Day syndrome

Staging, Grading, & Classification

- Surgical classification system
 - Type 1: Lumen interrupted by membrane
 - Bowel and mesentery otherwise intact
 - Type 2: Colon blind end with fibrous cord
 - Intact mesentery
 - Type 3: Colon blind ends completely separate
 - Gap in mesentery

CLINICAL ISSUES**Presentation**

- Most common signs/symptoms
 - Large, echogenic, abdominal cyst if competent ileocecal valve
 - Dilated bowel if incompetent ileocecal valve
 - Newborn bowel obstruction
- Other signs/symptoms
 - Distal microcolon

Demographics

- Epidemiology
 - 1:20,000 live births
 - 2-4% of intestinal atresia
- Risk factors
 - Maternal use of vasoconstrictive medications
 - Cocaine, amphetamines, nicotine, decongestants

Natural History & Prognosis

- Atresia + Hirschsprung with worse prognosis
 - 10% mortality
 - More complicated course of treatment

Treatment

- Primary resection with anastomosis
 - Dilated proximal colon has poor function
 - Resect to level of normal caliber before hook up
- Colostomy diversion with subsequent anastomosis
- Consider rectal biopsy to rule out Hirschsprung prior to definitive bowel continuity surgery

DIAGNOSTIC CHECKLIST**Image Interpretation Pearls**

- Dilated colon follows classic picture frame morphology

SELECTED REFERENCES

1. Adams SD et al: Malrotation and intestinal atresias. *Early Hum Dev.* 90(12):921-5, 2014
2. Hsu CT et al: Congenital colonic atresia: report of one case. *Pediatr Neonatol.* 51(3):186-9, 2010
3. Dassinger M et al: Management of colonic atresia with primary resection and anastomosis. *Pediatr Surg Int.* 25(7):579-82, 2009
4. Draus JM Jr et al: Hirschsprung's disease in an infant with colonic atresia and normal fixation of the distal colon. *J Pediatr Surg.* 42(2):e5-8, 2007
5. Cox SG et al: Colonic atresia: spectrum of presentation and pitfalls in management. A review of 14 cases. *Pediatr Surg Int.* 21(10):813-8, 2005

KEY FACTS

TERMINOLOGY

- High (above levator sling) or low (below levator sling)

IMAGING

- Inability to demonstrate normal anal dimple or target sign
- Dilated, fluid-filled distal bowel
- Calcified meconium enteroliths within bowel lumen
 - Results from associated vesicocolic fistula

TOP DIFFERENTIAL DIAGNOSES

- Normal 3rd-trimester colon
- Small bowel atresias
- Anal displacement

PATHOLOGY

- Vast majority associated with other anomalies
 - Genitourinary anomalies most common
- Syndromic associations
 - VACTERL association

- OEIS complex
- Urorectal septum malformation sequence
- Most sporadic
 - Some associated with trisomy 18, 21

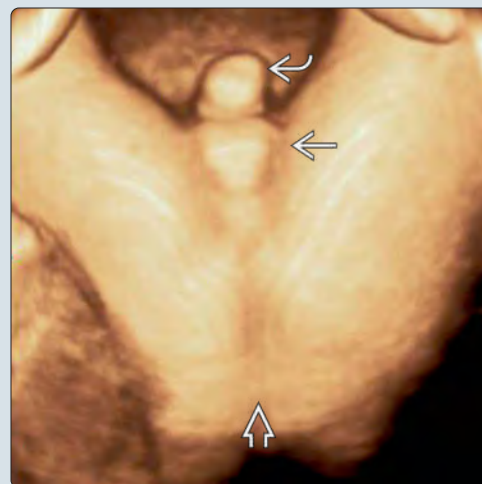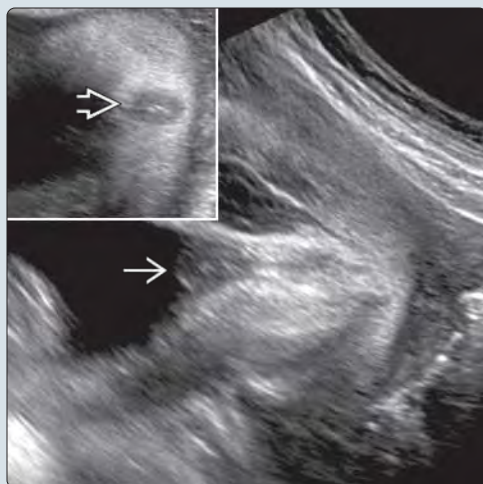
CLINICAL ISSUES

- May be missed when isolated, especially if 2nd-trimester scan is only study
- Offer karyotype, especially if multiple anomalies
 - Normal chromosomes do not exclude syndromic diagnosis
- Prognosis determined by associated malformations
- Isolated anal atresia has relatively good prognosis
- Decompressive surgery may be needed urgently
- 3-4% recurrence risk

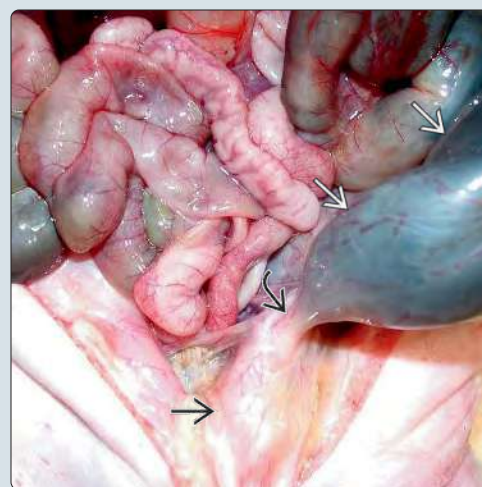
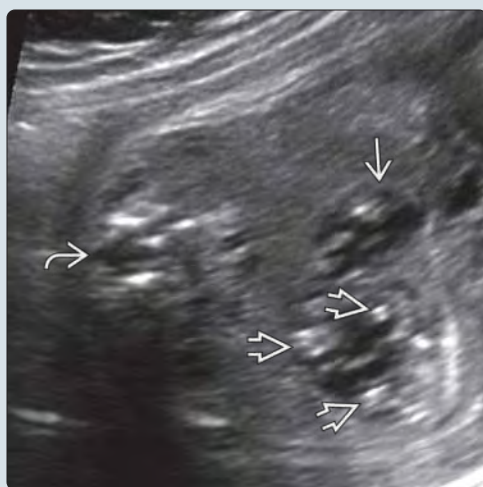
DIAGNOSTIC CHECKLIST

- Take dedicated views of rectum/anus when any bowel, spine, or genital abnormality is present

(Left) Axial view of the perineum of a fetus with multiple anomalies shows the labia majora [arrow], but no evidence of an anal dimple in the expected location. A normal anal dimple (target sign) [arrow] is shown in the inset. **(Right)** 3D US surface reconstruction shows undescended testes [arrow] (empty scrotum), short curved penis [arrow], and absence of an anal opening in the natal cleft [arrow]. Anal atresia is often associated with genital and distal spine abnormalities. Look for the anal dimple when evaluating fetal sex.



(Left) Axial abdominal US in the 3rd trimester shows echogenic enteroliths ("marbles") [arrow] of calcified meconium in the dilated transverse colon [arrow]. They were freely mobile during real-time scanning. This only occurs when meconium mixes with urine (e.g., vesicocolic fistula, persistent cloaca). Lumbar spine [arrow] is noted. **(Right)** Autopsy photograph in the same case shows the dilated distal colon [arrow] ending in a vesicocolic fistula [arrow]. Bladder [arrow] is noted.



TERMINOLOGY**Definitions**

- High anal atresia: Above levator sling
- Low anal atresia: Below levator sling

IMAGING**Ultrasonographic Findings**

- Inability to demonstrate normal appearance of anal dimple or target sign
 - Normal axial appearance: Hyperechoic mucosa within hypoechoic ring
 - Normal coronal appearance: Hyperechoic mucosal stripe between hypoechoic walls, extending to perineum
 - No other appearance is proof of normal anorectal development; should be demonstrable from 20 wks
- Dilated bowel
 - Difficult to distinguish large from small bowel
 - Late manifestation; not seen at time of 2nd-trimester survey
 - Meconium-filled loops of colon are normal in 3rd trimester
- U- or V-shaped bowel in presacral space, no extension to perineum
- High atresia often associated with urinary tract fistula and meconium calcification
 - Look for echogenic marbles moving within bowel

MR Findings

- T1WI excellent to demonstrate rectum extending to perineal opening
 - Meconium-filled rectum is high signal and easily identified (low signal on T2WI)
 - Closely apposed to bladder regardless of gender
 - Should extend ≥ 10 mm below bladder neck from 20 wks
 - Normal maximum colon diameter 8 mm at 24 wks, 16-18 mm by 35-38 wks
 - MR best performed at > 20 wks as prior to that meconium distribution not well defined
- 3rd structure (dilated vagina) separate from bladder and rectum in case of persistent cloaca
- May demonstrate dilated bowel not appreciated on sonography
- Increased T2 signal in rectum with urinary fistula (normal meconium is low signal)

Imaging Recommendations

- Protocol advice
 - Obtain dedicated anorectal views with any bowel/genital/distal spine abnormality
 - Dedicated fetal echocardiography in all cases
 - 3D data sets can be obtained to demonstrate rectum in sagittal and coronal planes

DIFFERENTIAL DIAGNOSIS**Normal 3rd-Trimester Colon**

- Often prominent, normal ≤ 18 mm

Proximal Bowel Atresias

- Presents earlier than more distal atresias

- More likely to cause polyhydramnios

Anal Displacement

- Reported in fetuses with perineal masses, persistent urogenital sinus, cloaca variant

PATHOLOGY**General Features**

- Associated abnormalities
 - Other anomalies present in 90% of cases diagnosed prenatally, 50% of those diagnosed at birth
 - Part of VACTERL association: Vertebral anomalies, anal atresia, cardiac anomalies, tracheoesophageal fistula, renal anomalies, limb malformations
 - Part of OEIS complex: Omphalocele, exstrophy of bladder, imperforate anus, spine anomalies
 - Part of urorectal septum malformation sequence

CLINICAL ISSUES**Presentation**

- May be missed when isolated, especially if 2nd-trimester scan is only study
- Generally not diagnosed until 3rd trimester as bowel dilation develops late, if at all
 - Other abnormalities may dominate, with associated anal atresia only noted after dedicated views obtained

Demographics

- Epidemiology
 - 1:1,500 to 1:5,000 live births
 - M:F = 3:2

Natural History & Prognosis

- Determined by associated malformations
- Isolated anal atresia has relatively good prognosis
- Timing and type of surgical repair depends on level
 - Low atresias repaired at birth
 - High atresias have diverting colostomy with repair at 1-3 months
- 80-90% continence rate
- 3-4% recurrence risk

Treatment

- Offer karyotype, especially if multiple anomalies

DIAGNOSTIC CHECKLIST**Image Interpretation Pearls**

- Take dedicated views of rectum/anus when any bowel, spine, or genital abnormality is present

SELECTED REFERENCES

1. Podberesky DJ et al: Magnetic resonance imaging of anorectal malformations. *Magn Reson Imaging Clin N Am.* 21(4):791-812, 2013
2. Gindes L et al: 3-Dimensional demonstration of fetal anal canal and sphincter. *Ultraschall Med.* 33(7):E25-30, 2012
3. Ochoa JH et al: Evaluation of the perianal muscular complex in the prenatal diagnosis of anorectal atresia in a high-risk population. *Ultrasound Obstet Gynecol.* 39(5):521-7, 2012
4. Zwink N et al: Parental risk factors and anorectal malformations: systematic review and meta-analysis. *Orphanet J Rare Dis.* 6:25, 2011
5. Khatib N et al: Fetal bowel calcifications: a sign of anal atresia with rectourethral fistula. *J Clin Ultrasound.* 38(6):332-4, 2010

KEY FACTS

TERMINOLOGY

- Complex malformation resulting from failure of cloacal division in early embryogenesis
- Spectrum of abnormal anatomy is related to timing of developmental arrest
 - Range from urogenital sinus (2 perineal openings) to cloacal dysgenesis (no perineal opening)
 - Classic cloaca defined as coalescence of urethra, vagina, and hindgut into common channel draining through single perineal orifice

IMAGING

- Septated cystic mass posterior to bladder with fluid-fluid level representing obstructed, duplicated vagina
 - Uterine and vaginal duplication is observed in ~ 80% of cases in which hydrocolpos is present
 - Vaginal duplication creates linear septation within conical fluid collection

- Absence of normal, meconium-filled, T1 hyperintense rectum on MR imaging
- High percentage have additional abnormalities; most commonly genitourinary, bowel, and lumbosacral
- Perform high-resolution images of perineum looking for abnormal genitalia and absent anal dimple

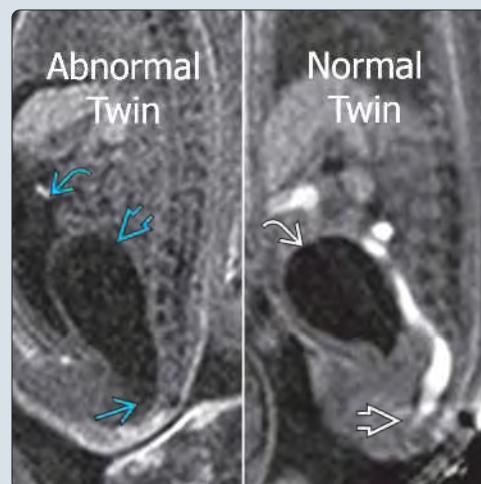
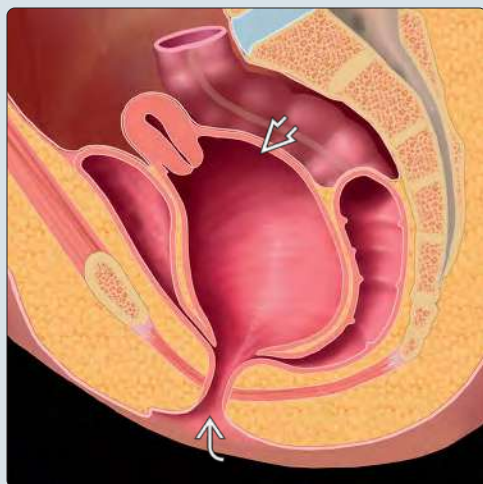
CLINICAL ISSUES

- Immediate drainage of hydrocolpos is important in neonatal period
- Goal of surgical repair is bowel and bladder continence and normal sexual function

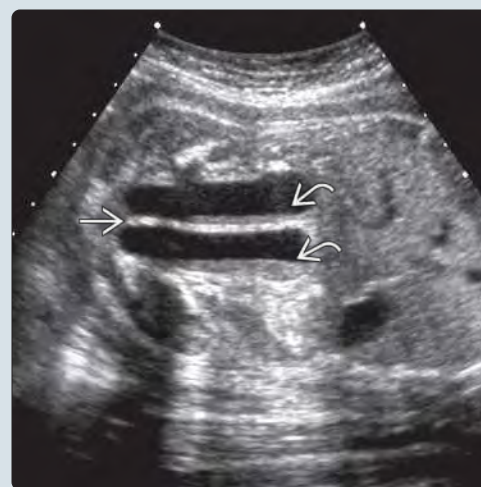
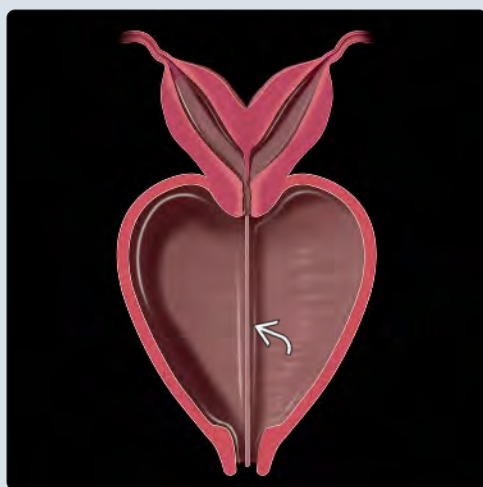
DIAGNOSTIC CHECKLIST

- > 50% will not have cystic mass due to absence of hydrocolpos
 - Constellation of genitourinary, lumbosacral, and bowel abnormalities in absence of hydrocolpos should also raise suspicion for cloacal anomaly

(Left) Sagittal graphic shows a common channel (cloaca) with hydrocolpos exerting mass effect on the rectum and bladder. (Right) Sagittal T1 MR images show twins, with the abnormal twin having a cloaca. The normal twin shows a hyperintense, meconium-filled rectum extending to the perineum and a low-signal, fluid-filled bladder. The twin with the cloacal malformation has no visible rectum. The obstructed vagina is seen taking up much of the pelvis with funneling to the perineum. The bladder is compressed anteriorly.



(Left) A vertical vaginal septum and uterine duplication anomaly occur in ~ 80% of cloacal malformation cases. The vaginal walls are far more distensible than the uterine walls and can become grossly distended. Retrograde flow can occur out the fallopian tubes, causing ascites. (Right) Coronal ultrasound shows fluid-fluid levels representing layering debris in obstructed, duplicated vaginas (note the linear septum). Debris results from the mixing of urine with vaginal secretions ± meconium.



TERMINOLOGY

Synonyms

- Urogenital sinus malformation
- Cloacal dysgenesis

Definitions

- Complex malformation encompassing spectrum of congenital hindgut and genitourinary anomalies resulting from failure of cloacal division early in embryogenesis
- Cloaca is Latin for sewer

IMAGING

General Features

- Best diagnostic clue
 - Septated retrovesicular cystic mass with fluid-fluid level representing hydrocolpos
 - Vertical vaginal septum creates bilobed appearance
 - May be asymmetric with 1 side much larger
- Size
 - May become large later in pregnancy as urine production increases
- Morphology
 - Conical-shaped, fluid-filled mass funneling to perineum, often with single straight septation

Ultrasonographic Findings

- Cystic pelvic mass posterior to bladder
 - Fluid-fluid level results from mixing of urine with vaginal secretions ± meconium
 - Vertical vaginal septum is observed in ~ 80% of cases in which hydrocolpos is present
 - Uterine duplication (müllerian) anomalies also common but often not seen prenatally
 - Wall of vagina very distensible, while uterus is not
- Genitourinary anomalies
 - Bilateral hydronephrosis
 - Extrinsic ureteral obstruction
 - Bladder outlet obstruction
 - Multicystic dysplastic kidney
 - Ureteropelvic obstruction
 - Renal ectopia or agenesis
 - Bladder abnormalities
 - Absent/decompressed bladder
 - Preferential decompression into compliant vagina
 - Dilated bladder
 - Urine initially decompresses through fallopian tubes
 - Chemical irritation may eventually obstruct fallopian tubes with progressive vaginal and bladder dilatation
- Ascites
 - Urinary ascites from backflow through fallopian tubes
- Bowel distention/obstruction
 - Extrinsic compression from hydrocolpos
 - Bowel atresia
 - Enterolithiasis
 - Results from mixing of urine with meconium
- Oligohydramnios
- Ambiguous genitalia

- Absent anal dimple
- Perform careful search for other commonly present anomalies
 - Spine anomalies
 - Sacral hypoplasia
 - Congenital heart anomalies
 - Limb defects

MR Findings

- T1WI
 - Absence of normal, high-signal, meconium-filled rectum
 - Normal rectum may be present in milder urogenital sinus type malformation
 - Colon may be dilated proximally
- T2WI
 - Hyperintense cystic mass arising from pelvis with local mass effect
 - Uterine and vaginal duplication
 - Renal anomalies
 - Lumbosacral abnormalities
 - Tethered cord

Imaging Recommendations

- Best imaging tool
 - Ultrasound to carefully follow structures and determine organ of origin
 - High-resolution ultrasound to evaluate fetal perineum
 - Fetal MR to look for presence of T1 hyperintense rectum and further evaluate genitourinary anatomy
- Protocol advice
 - Sagittal T2 thin section through fetal pelvis to evaluate relationship of vagina to perineum
 - Sagittal T1 GRE to look for meconium-filled rectum and relationship of rectum to perineum
 - Perform careful search for additional congenital anomalies that are often present
 - Dedicated fetal echocardiography

DIFFERENTIAL DIAGNOSIS

Isolated Hydrocolpos

- Unilocular without vaginal duplication
- Normal, meconium-filled rectum
- Normal anal dimple
- Usually developmentally normal kidneys and bladder, though may be obstructed due to mass effect

Ovarian Cyst

- Usually off midline
- Normal kidneys and bladder

Abdominal/Pelvic Lymphangioma

- Normal kidneys and bladder
- Thin-walled, multicystic structure
- Insinuates around organs

Obstructed Pelvic Kidney

- Look for dilated calyces
- Empty renal fossa with lying down adrenal gland

Enteric Duplication Cyst

- Wall has layered appearance suggesting gut signature separate from urinary tract

PATHOLOGY**General Features**

- Genetics
 - Normal chromosomes

Staging, Grading, & Classification

- Classification schemes have been devised for anorectal malformations and cloacal malformations published by pediatric surgeons
 - Pena and Levitt
 - Classification of nonsyndromic anorectal malformations in which cloaca is divided into 2 groups
 - Cloaca with short common channel < 3 cm
 - Cloaca with long common channel > 3 cm
 - Posterior cloaca is variant with posteriorly deviated urogenital sinus draining into rectum
 - Normally positioned anus

Gross Pathologic & Surgical Features

- Number of perineal orifices is key to diagnosis at birth
 - **No perineal orifice**
 - Diagnostic of cloacal dysgenesis
 - Complete lack of connection of genitourinary system and hindgut to perineum
 - **Single orifice**
 - Diagnostic of cloaca
 - Common channel draining bladder, vagina, and rectum
 - Location of orifice has important surgical and prognostic implications (i.e., posterior cloaca is less severe because anus is intact)
 - **2 orifices**
 - Urogenital sinus
 - Common channel draining urethra and vagina (urogenital sinus) with normal anus
 - Cloaca variant
 - Urogenital sinus with adjacent, anteriorly displaced anus

CLINICAL ISSUES**Presentation**

- Most common signs/symptoms
 - Cystic mass on routine prenatal screening
 - Correct diagnosis is commonly missed by prenatal imaging
 - Retrospective review found diagnosis suggested in only 6%

Demographics

- Gender
 - F >> M
- Epidemiology
 - Estimated to occur in 1:20,000 live births
 - Hydrocolpos present at birth in 22-50%
 - Lack of hydrocolpos significantly reduces sensitivity for prenatal diagnosis
 - Careful attention to combination of additional supportive findings can improve detection

Natural History & Prognosis

- Survival related to severity of malformation
 - Cloacal malformations are generally nonlethal
 - Exception is cloacal dysgenesis, which is rarely survivable beyond neonatal period
- Morbidity related to length of common channel and position of anus
 - Short cloacas have higher postsurgical continence rates
 - Urinary continence: 72%
 - Voluntary bowel movements: 68%
 - Long cloacas have poorer postsurgical continence rates, especially urinary
 - Urinary continence: 28%
 - Voluntary bowel movements: 44%
 - Normally positioned anus indicates intact pectinate line, innervation, and musculature
 - Good surgical outcomes with high rate of bowel continence

Treatment

- Immediate drainage of hydrocolpos important in neonatal period
- Surgery is undertaken early in neonatal period with goal to achieve urinary and bowel control and normal sexual function
- Surgical repair of short cloaca is more straightforward and can be performed at most pediatric hospitals
- Surgical repair of long cloaca is more complex and should be performed at specialized center by those with special training and experience

DIAGNOSTIC CHECKLIST**Image Interpretation Pearls**

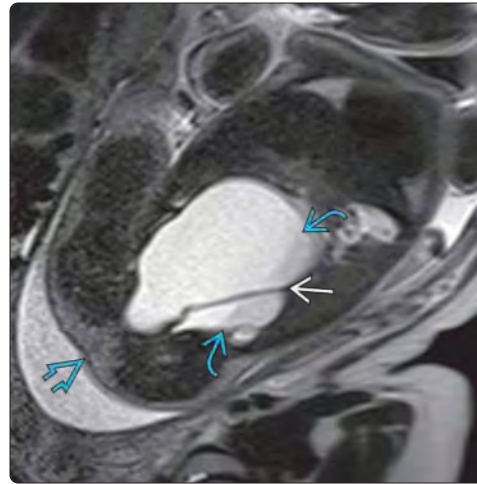
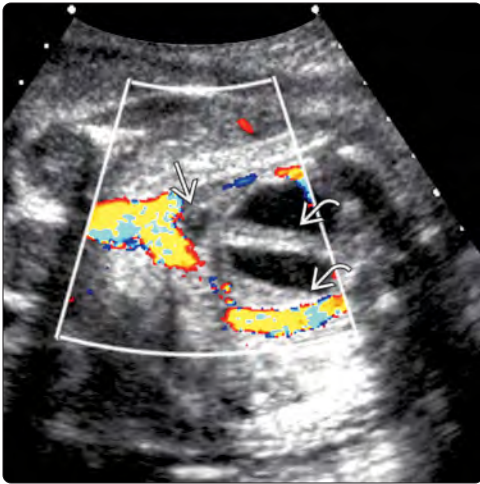
- Cystic pelvic mass with fluid-fluid level should raise suspicion of cloacal anomaly
- Prenatal diagnosis of cloaca is commonly overlooked
 - Hydrocolpos is present in only ~ 30-50% of cases
 - Constellation of genitourinary, lumbosacral, and bowel abnormalities should also raise suspicion
 - Always carefully evaluate perineum if these are present

Reporting Tips

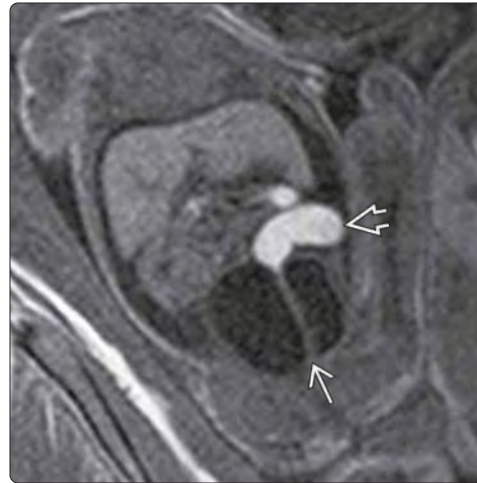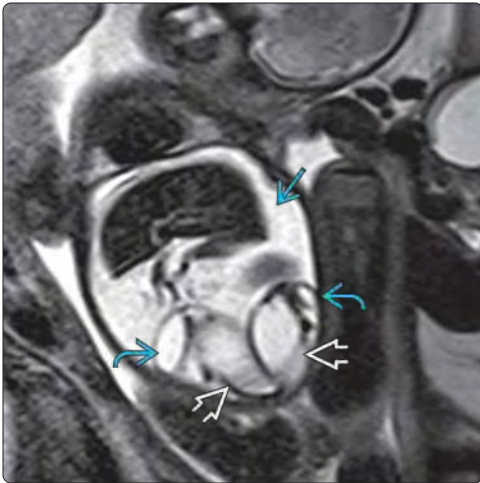
- Identify vaginal duplication
- Report presence or absence of T1 hyperintense, meconium-filled rectum
 - Evaluate position of anus if visible
- Perform careful survey of commonly present additional congenital anomalies

SELECTED REFERENCES

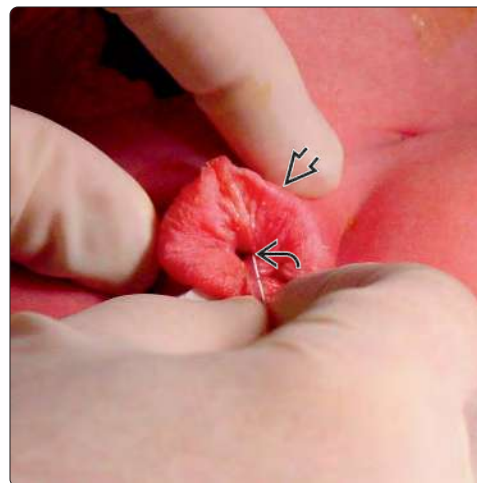
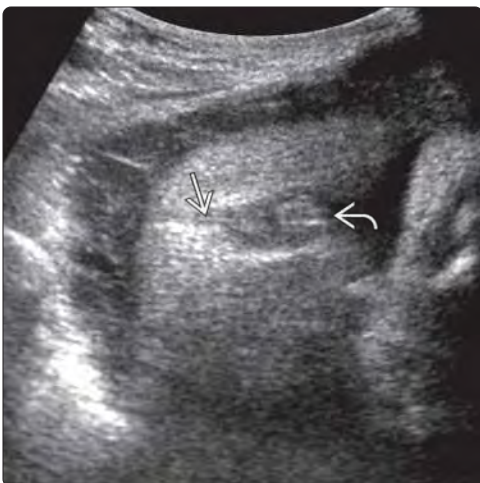1. Ación P et al: The presentation and management of complex female genital malformations. *Hum Reprod Update*. 22(1):48-69, 2016
2. Arlen AM et al: Disorders of the bladder and cloacal anomaly. *Clin Perinatol*. 41(3):695-707, 2014
3. Gupta A et al: The great divide: septation and malformation of the cloaca, and its implications for surgeons. *Pediatr Surg Int*. 30(11):1089-95, 2014
4. Livingston JC et al: Persistent cloaca: a 10-year review of prenatal diagnosis. *J Ultrasound Med*. 31(3):403-7, 2012
5. Winkler NS et al: Cloacal malformation: embryology, anatomy, and prenatal imaging features. *J Ultrasound Med*. 31(11):1843-55, 2012
6. Levitt MA et al: Cloacal malformations: lessons learned from 490 cases. *Semin Pediatr Surg*. 19(2):128-38, 2010



(Left) This fetus shows a septated cystic mass with fluid-fluid levels behind a decompressed bladder. As urine production increases, urine flows into the compliant vaginas, which will become progressively more distended. (Right) Coronal T2WI MR shows a vertically oriented vaginal septum. In this case, there is asymmetric distention with the right side being significantly larger. There are fluid-fluid levels on each side. Note the flattened perineum with absence of a normal rectum.



(Left) Coronal T2WI MR shows duplicated, fluid-filled uteri atop obstructed duplicated vaginas. Large-volume ascites is present, due to urine decompressing through the fallopian tubes. (Right) T1WI MR should always be performed to look for the high-signal, meconium-filled colon and rectum. This T1WI in the same patient shows mild dilation of the colon, which terminated abruptly near the rectosigmoid junction. There was no normal rectum. The vaginal septum is well seen on this more posterior image.



(Left) Transabdominal ultrasound of the fetal perineum shows no evidence of an anal dimple in the expected location. The labia are seen anteriorly. This was confirmed as a classic cloaca with 1 perineal orifice. (Right) Clinical photograph of the perineum shows a single orifice diagnostic of a cloaca with abnormal labia. This opening represents the common channel draining the bladder, vagina, and rectum.

KEY FACTS

TERMINOLOGY

- Closed-loop obstruction caused by bowel twisting on its mesentery
 - Causes high-grade obstruction and vascular compromise

IMAGING

- Dilated bowel, especially single kinked loop
 - Creates coffee bean sign
- Echogenic intraluminal contents from infarction, necrosis, and hemorrhage
- Ascites frequent
- Real-time evaluation important
 - Infarcted bowel loses ability for peristalsis
- Look for swirled mesenteric vessels (whirlpool sign)
- Hydrops may develop as overall fetal condition worsens

TOP DIFFERENTIAL DIAGNOSES

- Jejunal, ileal atresia
 - Hyperperistalsis often seen in obstructed loops

PATHOLOGY

- Most related to malrotation with short, mobile mesenteric attachment

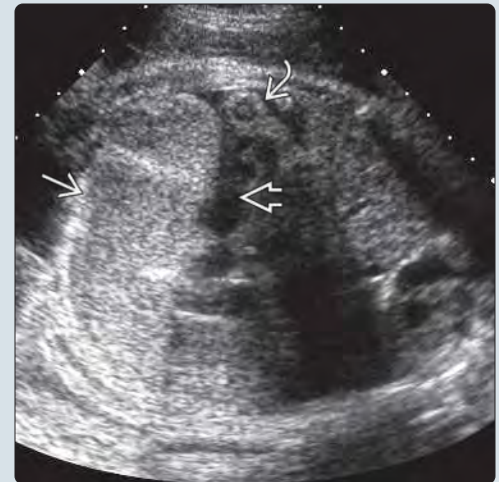
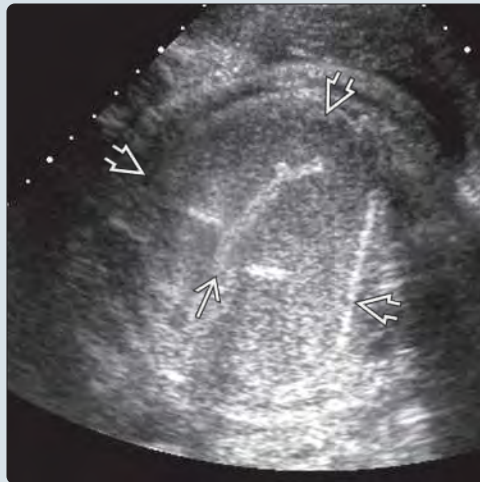
CLINICAL ISSUES

- "Sick" fetus with decreased fetal movement and nonreactive nonstress test
- May cause in utero demise
- Urgent delivery should be considered
- Variable outcome related to length of gangrenous segment and gestational age at time of volvulus

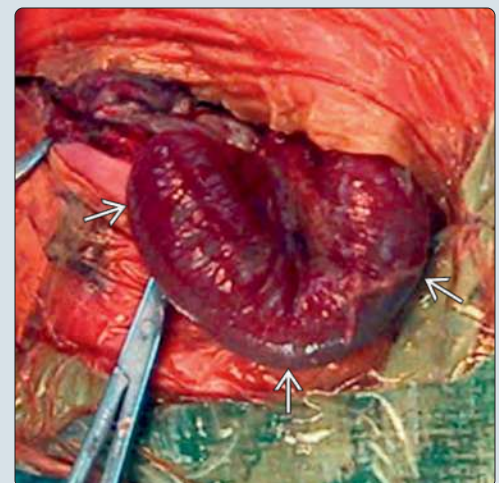
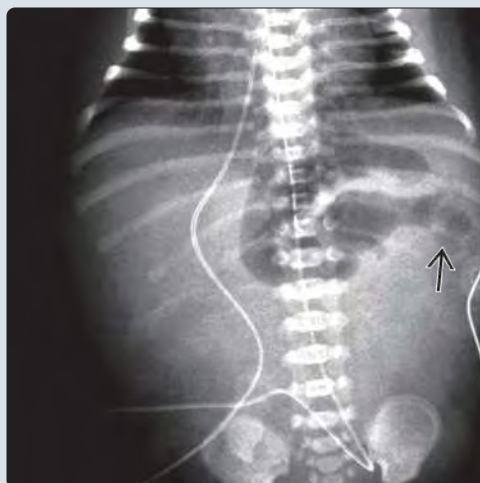
DIAGNOSTIC CHECKLIST

- Volvulus is abrupt event
 - Consider in setting of new dilated loop of bowel in previously normal gestation
- Ascites and lack of peristalsis in dilated, echogenic bowel loop are very suspicious

(Left) Axial ultrasound of the abdomen in a 36-week fetus shows a single, dilated segment of bowel. It is filled with echogenic debris, and no peristalsis was seen during real-time examination. Note the echogenic line down the middle, creating the coffee bean sign. (Right) In a slightly oblique view, normal decompressed distal bowel is seen, as well as the markedly enlarged loop. A small amount of ascites is also present. The findings were very suspicious for volvulus, so steroids were given and the fetus was delivered.



(Left) Anteroposterior radiograph taken before surgery shows a distended abdomen with abrupt termination of bowel gas at the site of obstruction. (Right) Intraoperative photograph shows the twisted loop of infarcted small bowel, confirming the prenatal diagnosis of volvulus. The infarcted bowel was resected, and the infant did well. Volvulus generally occurs in the setting of malrotation. It is an abrupt event with fetuses often having had a normal scan earlier in pregnancy.



TERMINOLOGY

Definitions

- Closed-loop obstruction caused by bowel twisting on its mesentery
 - Causes high-grade obstruction and vascular compromise

IMAGING

Ultrasonographic Findings

- Dilated bowel loops
 - Single kinked loop is very suggestive
 - Creates coffee bean sign
 - May see multiple dilated loops from proximal obstruction
- May have had normal scan earlier in gestation
 - Volvulus is abrupt event
- Echogenic intraluminal contents from infarction, necrosis, and hemorrhage
 - May have layering debris level
- Ascites
 - Frequently seen, ± bowel perforation
 - Perforation may lead to meconium peritonitis with pseudocyst formation and peritoneal calcifications
- Hydrops may develop as overall fetal condition worsens

MR Findings

- Dilated, low signal intensity bowel on T2WI from intraluminal hemorrhage

Imaging Recommendations

- Real-time evaluation important
 - Infarcted bowel loses ability for peristalsis
 - Obstructed, but viable, bowel loops often have hyperperistalsis
- Attempt to evaluate mesenteric vessels with Doppler
 - May have swirled whirlpool appearance
 - Often technically difficult
- Consider middle cerebral artery Doppler, as fetal anemia is described association

DIFFERENTIAL DIAGNOSIS

Jejunal, Ileal Atresia

- Hyperperistalsis often seen in obstructed loops
- Dilatation of loops may remain stable or progress over time
 - Differs from abrupt dilation in volvulus
- May also perforate and cause meconium peritonitis/pseudocyst formation

Duodenal Atresia

- "Double bubble"
- Able to connect stomach and duodenum during real-time examination

Intussusception

- Extremely rare and difficult to diagnose in utero
- Look for ringed, target appearance at site of intussusception
- Appearance may be indistinguishable from atresia

PATHOLOGY

General Features

- Etiology
 - Most related to malrotation with short, mobile mesenteric attachment
 - Fetal cases generally involve small bowel
- Associated abnormalities
 - Jejunal/ileal atresia may coexist with volvulus
 - Congenital diaphragmatic hernia, gastroschisis, omphalocele, and abdominal heterotaxy are described in neonatal series

CLINICAL ISSUES

Presentation

- Dilated bowel, typically in 3rd trimester
 - May have had prior normal scan
- "Sick" fetus with decreased fetal movement and nonreactive nonstress test

Demographics

- Epidemiology
 - Malrotation in 1:6,000 live births, which is predisposing factor
 - Actual in utero volvulus is rare
 - Incidence in neonatal series inversely related to maternal age

Natural History & Prognosis

- May cause in utero demise
- Variable outcome
 - Related to length of gangrenous segment and gestational age at time of volvulus
 - Those with late presentation and immediate resection have better prognosis

Treatment

- Urgent delivery should be considered
- Consult with pediatric surgeons for immediate surgery upon delivery

DIAGNOSTIC CHECKLIST

Consider

- In setting of new dilated loop of bowel in previously normal gestation

Image Interpretation Pearls

- Ascites and lack of peristalsis in dilated, echogenic bowel loop are very suspicious
 - Ultrasound findings reflect vascular compromise with bowel infarction

SELECTED REFERENCES

1. Sciarone A et al: Fetal midgut volvulus: report of eight cases. *J Matern Fetal Neonatal Med.* 29(8):1322-7, 2016
2. Keskin U et al: Prenatal diagnosis of the acute meconium peritonitis secondary to ileum volvulus perforation: a case report. *Fetal Pediatr Pathol.* 34(1):9-13, 2015
3. Nakagawa T et al: A case of fetal intestinal volvulus without malrotation causing severe anemia. *Jpn Clin Med.* 6:1-3, 2015
4. Jakhere SG et al: Fetal small bowel volvulus without malrotation: the whirlpool & coffee bean signs. *J Neonatal Perinatal Med.* 7(2):143-6, 2014

Enteric Duplication Cyst

KEY FACTS

TERMINOLOGY

- Duplication of gastrointestinal tract with enteric lining and muscular wall
 - Foregut 40%
 - Mid- and hindgut 60%
 - Ileum most common site
- May either be cystic (80%) or tubular (20%)
 - Tubular duplications may communicate with bowel and are usually not detected in utero

IMAGING

- Gut signature: Hypoechoic muscular wall between hyperechoic mucosa and serosa
- Obtain enlarged, high-frequency images focused on cyst to evaluate wall
- Rarely may cause bowel obstruction
- Variable appearance depending on location
 - Esophagus: Commonly associated with vertebral anomalies



- May cause oral mass and obstruct airway
- Stomach: Appears as cyst within gastric lumen
- Bowel: Solitary abdominal cyst

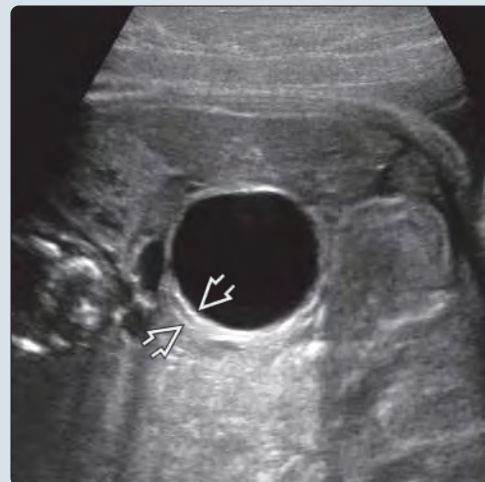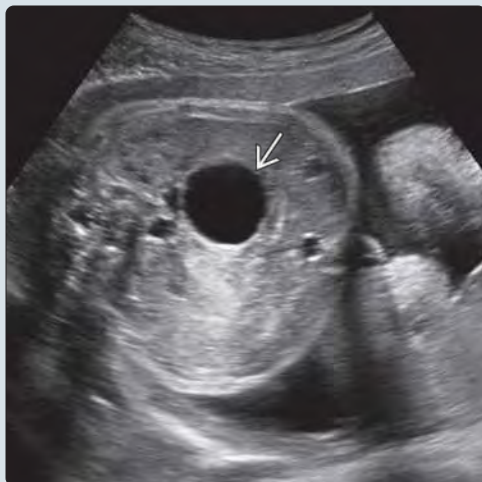TOP DIFFERENTIAL DIAGNOSES


- Mesenteric cyst
 - Usually multilocular
 - Unilocular cyst may look identical to enteric cyst
- Ovarian cyst
 - Most common abdominal cystic mass in female fetus
- Meconium pseudocyst
 - Thick, irregular wall
 - Other sequelae of meconium peritonitis
- Choledochal cyst
 - Look for bile ducts entering cyst

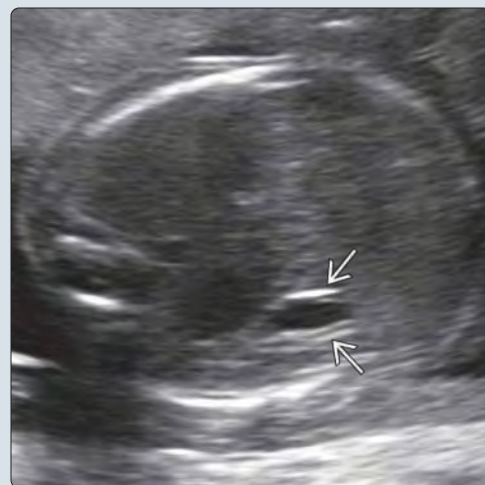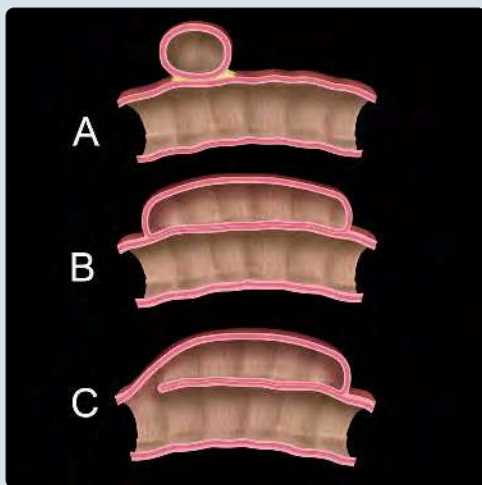
DIAGNOSTIC CHECKLIST

- Always look at wall for ringed appearance created by layers of bowel wall (gut signature)

(Left) Transverse US through the abdomen of a 2nd-trimester fetus shows an anechoic cyst . This is a very nonspecific appearance. **(Right)** To further characterize the cyst, a high-frequency linear transducer was used. Now a distinct trilaminar gut signature is seen , with a hyperechoic mucosa, hypoechoic muscular wall, and hyperechoic serosa. While there can be overlap with the appearance of other abdominal cysts, this makes an enteric duplication cyst the most likely diagnosis (confirmed at surgery).



(Left) Enteric duplication cysts can either be round (A) or tubular (B). The tubular type can communicate with the bowel lumen (C); these are difficult to detect in utero. Note that all of them have a thick muscular wall identical to the normal bowel wall. **(Right)** Transverse US through the fetal abdomen shows a tubular duplication cyst  with the typical gut signature. This one did not communicate with the bowel lumen.



TERMINOLOGY

Definitions

- Duplication of gastrointestinal tract with enteric lining and muscular wall
 - May either be cystic (80%) or tubular (20%)

IMAGING

General Features

- Best diagnostic clue
 - Thick-walled cyst with layered appearance (gut signature)
- Location
 - Foregut 40%
 - Mid- and hindgut 60%
 - Ileum most common site

Ultrasonographic Findings

- Fluid generally anechoic but can be echogenic
- Findings vary according to location
 - Bowel
 - Solitary abdominal cyst
 - Stomach
 - Appears as cyst within gastric lumen
 - Esophagus
 - Several case reports of lesions occurring at base of tongue, causing oral mass and airway obstruction
 - Mediastinal cyst
 - Commonly associated with vertebral anomalies, especially hemivertebrae
- May be multiple
- Rarely, bowel dilatation from obstruction
- Tubular duplications may communicate with bowel and therefore do not accumulate fluid
 - Usually not detected in utero
- High-frequency imaging may discern multiple layers of alternating echogenicity
 - Mucosa, muscularis mucosa, submucosa, muscularis propria, serosa
 - Typically only 3 layers seen in utero
 - Hypoechoic muscular wall between hyperechoic mucosa and serosa

Imaging Recommendations

- Confirm cyst is intraperitoneal and separate from urinary tract
 - Most cystic abdominal masses are related to urinary tract
- Obtain enlarged, high-resolution images looking at wall thickness and morphology
 - Posterior wall more easily evaluated
- Follow-up for bowel dilatation, polyhydramnios

DIFFERENTIAL DIAGNOSIS

Mesenteric Cyst

- Usually multilocular
- Unilocular mesenteric cyst may look identical to enteric cyst
- Less likely to cause obstruction

Ovarian Cyst

- Most common abdominal cystic mass in female fetus

- Presents in 3rd trimester

Meconium Pseudocyst

- Thick, irregular wall
- Other sequelae of meconium peritonitis
 - Peritoneal calcifications, dilated bowel

Choledochal Cyst

- Right upper quadrant
- Look for bile ducts entering cyst

Dilated Bowel

- Tubular appearance
- Contents echogenic (succus entericus)
- Peristalsis confirmatory

Urachal Cyst

- Midline, between bladder and cord insertion

PATHOLOGY

General Features

- Embryology: 2 primary theories
 - Abnormal recanalization
 - Alimentary tract begins as solid tube
 - Normal lumen forms from coalescence of developing vacuoles
 - Duplication occurs if vacuoles split into 2 groups with dividing septum
 - Abnormal separation from notochord
 - Explains association of esophageal duplication and vertebral abnormalities

CLINICAL ISSUES

Presentation

- In utero
 - Usually incidental finding
 - May cause bowel obstruction
- Most present in childhood
 - Intussusception, bleeding, abdominal pain
 - Most diagnosed before 2 yr of age

Treatment

- Work-up after delivery to confirm diagnosis
- Surgical resection

DIAGNOSTIC CHECKLIST

Image Interpretation Pearls

- Always look at wall for ringed appearance created by layers of bowel wall (gut signature)
 - While this appearance is highly suggestive of enteric duplication cyst, there is overlap in appearance with other abdominal cysts
 - Postnatal evaluation is required

SELECTED REFERENCES

1. Gantwerker EA et al: Management of a large antenatally recognized foregut duplication cyst of the tongue causing respiratory distress at birth. *JAMA Otolaryngol Head Neck Surg.* 140(11):1065-9, 2014
2. Ben-Ishay O et al: Multiple duplication cysts diagnosed prenatally: case report and review of the literature. *Pediatr Surg Int.* 29(4):397-400, 2013
3. Teunissen J et al: Prenatal detection of an enteric duplication cyst. *Acta Chir Belg.* 113(5):355-6, 2013

Meconium Peritonitis, Pseudocyst

KEY FACTS

TERMINOLOGY

- Chemical peritonitis due to intrauterine bowel perforation

IMAGING

- Intraperitoneal calcifications in 85%
- Implants on peritoneal surfaces
 - Best seen along liver capsule
 - May also be in scrotum (meconium periorchitis)
- Ascites secondary to both spilled contents and inflammatory response
- Meconium pseudocyst results from walled-off perforation
 - Irregular thick walls
- Dilated bowel seen when meconium peritonitis is secondary to obstruction
- No dilatation when perforation is secondary to ischemia

PATHOLOGY

- 2 proposed mechanisms leading to perforation
 - Primary ischemic event or bowel anomaly

- Bowel anomalies at risk for perforation: Atresias (distal at greater risk than proximal), meconium ileus, volvulus

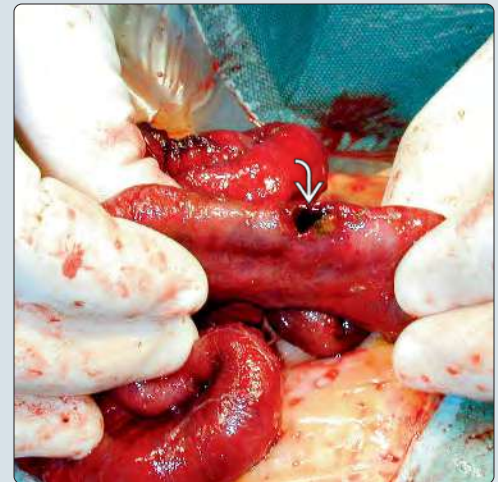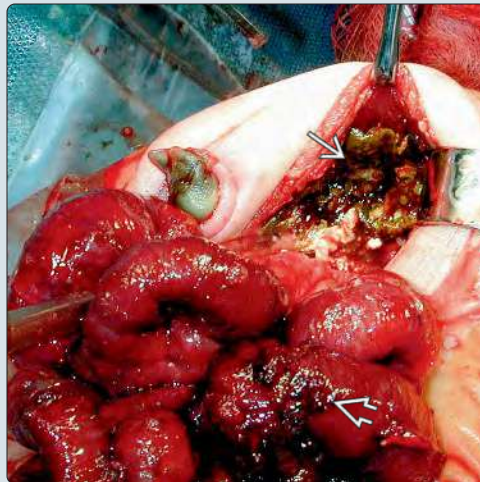
CLINICAL ISSUES

- Genetic counseling for cystic fibrosis
- Spontaneous in utero closure of perforation may occur with no long-term sequelae
- Those with bowel atresia, prematurity, and low birthweight with highest morbidity/mortality
 - Must deliver at tertiary care facility with plan for surgical intervention
 - Either resection with primary reanastomosis or staged procedure with initial enterostomy

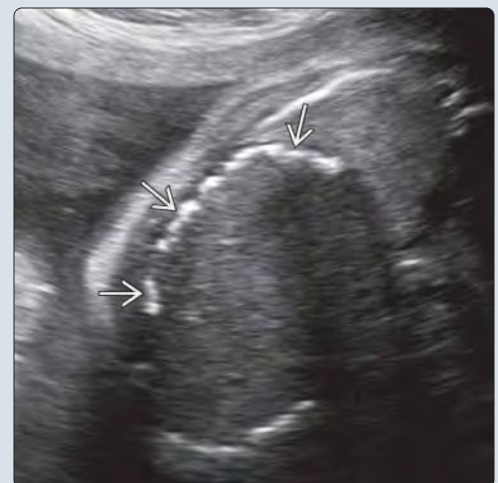
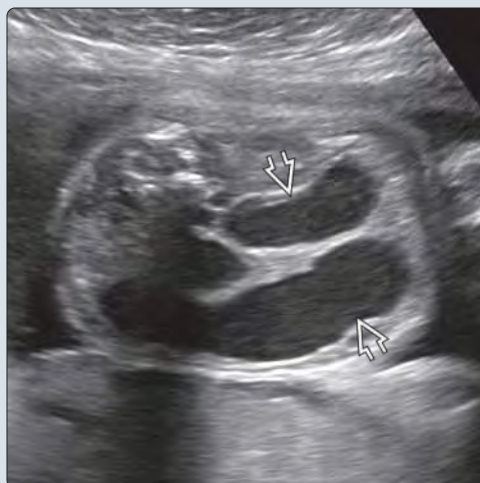DIAGNOSTIC CHECKLIST

- Liver calcifications are on capsular surface with meconium peritonitis, while infection causes intraparenchymal calcifications
 - Consider infection as cause of perforation when calcifications are seen in both locations

(Left) Intraoperative photograph shows a large amount of spilled meconium within the peritoneal cavity. The bowel loops are thickened and matted with meconium seen on the serosal surface. (Right) The site of perforation was found to be in the distal ileum. There was no bowel dilation or evidence of atresia, and the perforation was felt to be most likely due to an area of focal ischemia.



(Left) This 29-week fetus with ileal atresia shows multiple dilated loops of small bowel. (Right) There was no ascites, but a sagittal image through the liver in the same case shows calcifications along the capsule, indicating prior perforation with meconium peritonitis. Bowel atresia is a significant risk factor for perforation. It is very important to ensure that the calcifications are on the capsule and not in the parenchyma as would be seen with infection.



TERMINOLOGY

Definitions

- Chemical peritonitis due to intrauterine bowel perforation

IMAGING

General Features

- Best diagnostic clue
 - Combination of ascites, calcifications, and dilated bowel is pathognomonic

Ultrasonographic Findings

- Findings vary according to timing and severity of perforation
- Calcifications most specific finding
 - Intraperitoneal calcifications in 85%
 - Implants on peritoneal surfaces
 - Liver capsule often most obvious
 - Must differentiate from intraparenchymal hepatic calcifications
 - May also be in scrotum (meconium periorchitis)
 - Patent processus vaginalis in fetus
- Ascites secondary to both spilled contents and inflammatory response
 - Often 1st sign of meconium peritonitis
- Echogenic bowel may be combination of factors
 - Underlining bowel abnormality (e.g., cystic fibrosis) or meconium implantation on serosal surface
- Dilated bowel
 - Seen when meconium peritonitis is secondary to obstruction
 - Atresia
 - Volvulus
 - Meconium ileus
 - Intussusception
 - Not seen when perforation is secondary to ischemia
- Meconium pseudocyst
 - Walled-off area of perforation
 - Irregular thick walls, which may calcify
 - Contents variable in echogenicity
 - May be large and multiple
- Polyhydramnios
 - Usually secondary to bowel obstruction

Imaging Recommendations

- Frequent follow-up scans after initial diagnosis
 - Need to plan for delivery and postnatal work-up
 - May worsen with increasing bowel dilation and abdominal distention
 - May resolve completely with no sequelae
- Try to determine cause of perforation
 - Dilated bowel makes primary intestinal abnormality most likely
 - Look for bowel peristalsis
 - Nonperistalsing, dilated loops concerning for volvulus
 - Look for signs of infection
 - Infection may lead to vascular compromise and perforation
 - Intraparenchymal as well as capsular liver calcification
 - Intracranial calcifications

- Fetal growth restriction

DIFFERENTIAL DIAGNOSIS

Causes of Echogenic Bowel

- Increased echogenicity of bowel \geq bone
- Not calcified, so does not shadow
- Often appears mass-like
- Careful search for associated conditions
 - Aneuploidy (trisomy 21)
 - In utero infection
 - Fetal growth restriction
 - Cystic fibrosis
 - May progress to bowel obstruction from meconium ileus, which is at risk for perforation

Causes of Abdominal Calcifications

- **Infection**
 - Scattered punctate calcifications within liver parenchyma
 - Often do not shadow
 - May be caused by number of organisms
 - Toxoplasmosis
 - Cytomegalovirus
 - Parvovirus
 - Varicella
 - Infection may be etiologic agent for ischemia, so may have signs of both perforation and infection
- **Gallstones**
 - 1 or more echogenic foci within gallbladder
 - 3rd-trimester finding
 - Shadowing or comet tail reverberation artifact may be present
 - Usually resolve in 1st year of life
- **Enteroliths**
 - Calcified intraluminal meconium
 - May be seen moving within bowel lumen
 - Appear as small marbles
 - Described with vesicoenteric fistula
 - Most often in setting of anal atresia

Ascites

- Urinary
 - Fluid in abdomen only
 - Associated with obstructed urinary tract
 - Hydronephrosis
 - Bladder outlet obstruction
 - May have focal fluid collection (urinoma)
- Hydrops
 - Ascites + fluid in 1 other area
 - Numerous causes
 - Immune vs. nonimmune
 - Always check cardiac structure, rate, and rhythm

Abdominal Cysts

- Other cysts do not calcify and are usually more regular in appearance
 - **Choledochocyst**
 - Right upper quadrant cyst
 - Following bile ducts into cyst is pathognomonic
 - **Enteric duplication cyst**

- Hypochoic wall with hyperechoic mucosa (gut signature)
- **Mesenteric cyst**
 - Generally smooth, thin walls
 - May be multiseptated
- **Ovarian cyst**
 - Female fetus
 - Occurs in 3rd trimester
 - May have internal echoes with hemorrhage or torsion
- **Urachal cyst**
 - Midline between bladder and cord insertion

PATHOLOGY

General Features

- Etiology
 - 2 proposed mechanisms: Primary ischemic event or bowel anomaly leading to perforation
 - Bowel perforation → meconium spills into peritoneum
 - Intense inflammatory reaction
 - Adhesions → "cyst" formation
 - Bowel loops may be trapped within "cyst"
 - Calcifications secondary to inflammation
 - Bowel anomalies at risk for perforation
 - Atresias (distal at greater risk than proximal)
 - Meconium ileus
 - Volvulus
 - Intussusception
 - Maternal cocaine use may cause fetal bowel ischemia
 - In utero infection
- Genetics
 - Cystic fibrosis in 8% of fetal cases
 - 15-40% of postnatal cases
 - Autosomal recessive: 25% recurrence risk

Gross Pathologic & Surgical Features

- Variable, according to severity
- May see extensive fibrous adhesions with thick, matted bowel loops
- Pseudocyst formation around walled-off perforation
- Bowel atresias

CLINICAL ISSUES

Presentation

- Most common signs/symptoms
 - Incidental note of peritoneal calcifications or abdominal cyst
 - New ascites in patient being followed for dilated bowel
 - Calcification visible 1-2 weeks after perforation

Demographics

- 1:35,000 live births
- Fetal incidence greater than neonatal incidence
 - Reflects milder in utero cases, which resolve without clinical sequelae

Natural History & Prognosis

- May be incidental finding in fetus
 - Spontaneous in utero closure of perforation may occur
 - Often detected earlier in pregnancy
 - No postnatal sequelae

- Incidental note of calcification on abdominal film
- Later detection more often associated with significant bowel pathology
- Neonatal diagnosis carries worse prognosis
 - Higher proportion of cases have cystic fibrosis
 - May develop bacterial peritonitis
 - Mortality rates ~ 10%
 - Survival improving with advancement in neonatal intensive care and improved surgical techniques
 - Those with bowel atresia, prematurity, and low birthweight at greatest risk

Treatment

- Genetic counseling for cystic fibrosis
 - Consider testing parents for carrier status
 - If carriers, amniocentesis can test for direct detection of gene mutation in fetus
- **Simple peritonitis:** Calcifications only
 - Routine delivery plans
 - Postnatal evaluation
 - Abdominal examination
 - Abdominal ultrasound ± radiograph
 - If normal, child can feed
 - Very low likelihood of surgical intervention in simple peritonitis
- **Complex peritonitis:** Dilated bowel, persistent pseudocysts, ascites
 - Deliver at tertiary care facility
 - Evaluation by neonatologist/pediatric surgeon
 - Majority will require surgery
 - Either resection with primary reanastomosis or staged procedure with initial enterostomy
- In utero treatment has been performed for progressive ascites and polyhydramnios
 - Fetal paracentesis of ascites &/or drainage of pseudocyst
 - Case reports of injection with urinary trypsin inhibitor, an antiinflammatory agent, with resolution of ascites

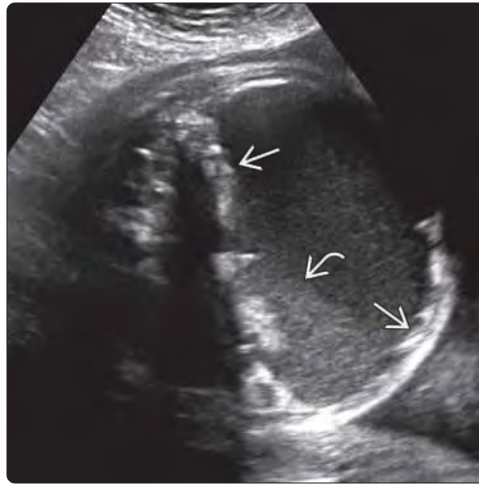
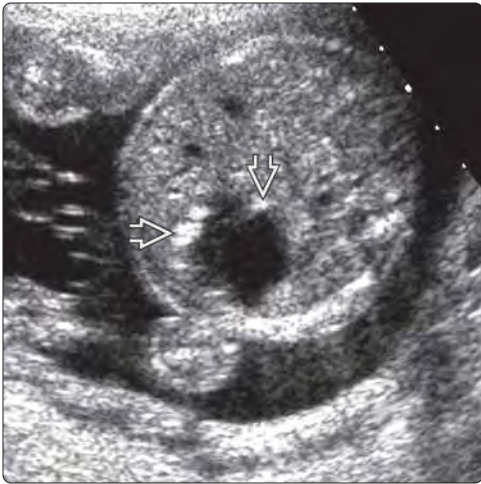
DIAGNOSTIC CHECKLIST

Image Interpretation Pearls

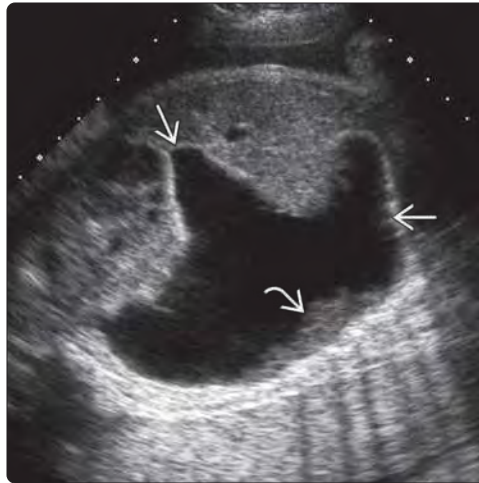
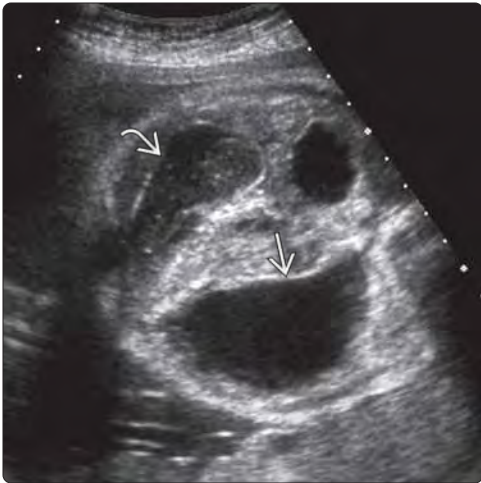
- Liver calcifications are on the capsular surface with meconium peritonitis, while infection causes intraparenchymal calcifications
 - Consider infection as cause of perforation when calcifications are seen in both locations

SELECTED REFERENCES

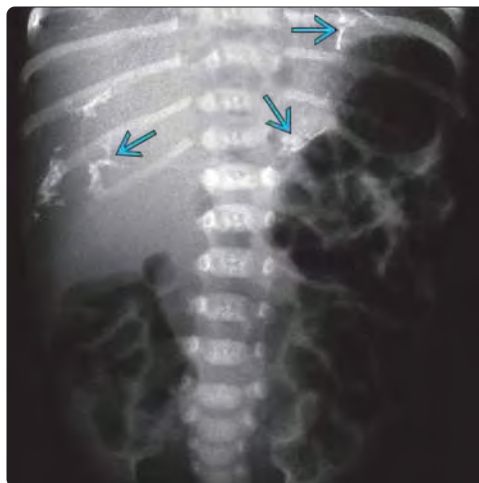
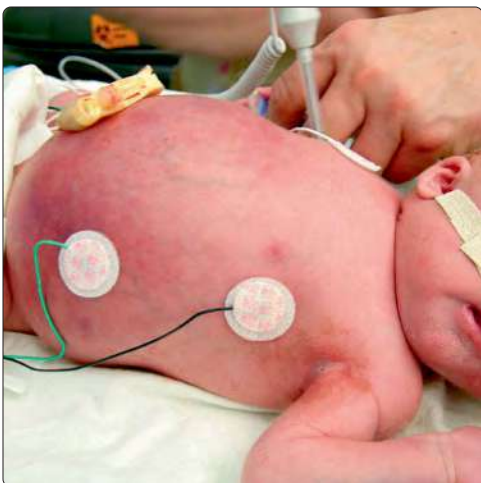1. Uchida K et al: Meconium peritonitis: Prenatal diagnosis of a rare entity and postnatal management. *Intractable Rare Dis Res.* 4(2):93-7, 2015
2. Alanbuki AH et al: Meconium periorchitis: A case report and literature review. *Can Urol Assoc J.* 7(7-8):E495-8, 2013
3. Zerhouni S et al: Can we select fetuses with intra-abdominal calcification for delivery in neonatal surgical centres? *J Pediatr Surg.* 48(5):946-50, 2013
4. Minato M et al: Meconium pseudocyst with particular pathologic findings: a case report and review of the literature. *J Pediatr Surg.* 47(4):e9-12, 2012
5. Miyake H et al: Primary anastomosis for meconium peritonitis: first choice of treatment. *J Pediatr Surg.* 46(12):2327-31, 2011
6. Regev RH et al: Meconium periorchitis: intrauterine diagnosis and neonatal outcome: case reports and review of the literature. *J Perinatol.* 29(8):585-7, 2009
7. Saleh N et al: Prenatal diagnosis and postnatal management of meconium peritonitis. *J Perinat Med.* 37(5):535-8, 2009
8. Tsai MH et al: Clinical manifestations in infants with symptomatic meconium peritonitis. *Pediatr Neonatol.* 50(2):59-64, 2009



(Left) Axial ultrasound of an 18-week fetus shows an irregular abdominal cyst with bright calcifications along the periphery. This resolved on follow-up scans. A postnatal radiograph showed right upper quadrant calcifications but was otherwise normal, as was the physical exam. **(Right)** In contrast, this is a very large pseudocyst in a 22-week fetus. Note the hyperechoic irregular walls and a layering debris level. Surgery showed a midjejunal perforation from an internal hernia with volvulus. (From *DI: Pediatrics*, 3e.)



(Left) Axial ultrasound of a 3rd-trimester fetus shows a dilated loop of bowel filled with echogenic material. There has been an in utero perforation with formation of a large, irregular, thick-walled meconium pseudocyst. **(Right)** The pseudocyst continued to increase in size, enlarging the abdominal circumference. The contours of the cyst are angular, helping to differentiate it from other types of abdominal cystic masses, which are more rounded in appearance. There is also internal layering debris.



(Left) Photograph after delivery in the same case shows that the infant has a distended, dusky abdomen. Surgery confirmed an ileal atresia with perforation, complicated by meconium peritonitis and pseudocyst formation. **(Right)** Radiograph of a different newborn with an in utero diagnosis of meconium peritonitis shows dense calcifications over the liver. The bowel gas pattern is normal and the infant began feeding without difficulty.

KEY FACTS

TERMINOLOGY

- Mesenteric cyst and lymphangioma often used synonymously

IMAGING

- Usually multilocular, with 1 to multiple septations
 - Septa are variable in thickness
- Less commonly unilocular
- Displaces bowel and may rarely cause obstruction
- Most often large, distending abdomen
 - May extend out of peritoneal cavity to involve retroperitoneum and lower extremities
- No flow on color Doppler

TOP DIFFERENTIAL DIAGNOSES



- Bowel atresia
- Meconium pseudocyst
- Enteric duplication cyst

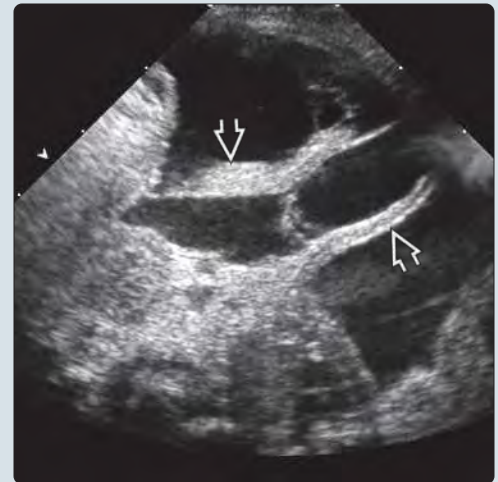
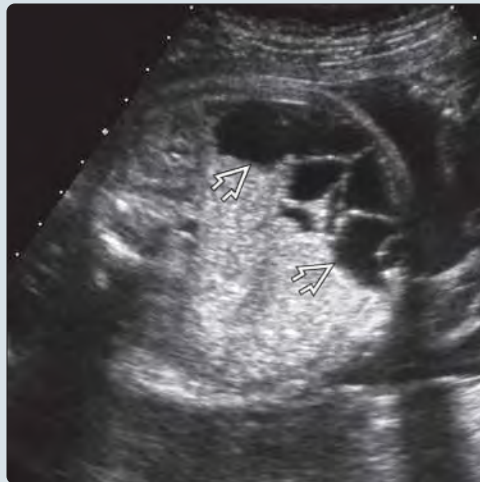
CLINICAL ISSUES




- Variable in utero course
 - May remain stable, regress, or expand and invade surrounding structures
- Postnatally may be asymptomatic or present with palpable mass or bowel obstruction
- Postnatal work-up usually requires CT or MR to see full extent of large masses
- Cyst drainage often unsuccessful as fluid reaccumulates
 - Ectopic lymphatic tissue lacks normal communication with lymphatic system
- Most require surgical excision ± bowel resection, depending on extent of involvement
- Excellent prognosis

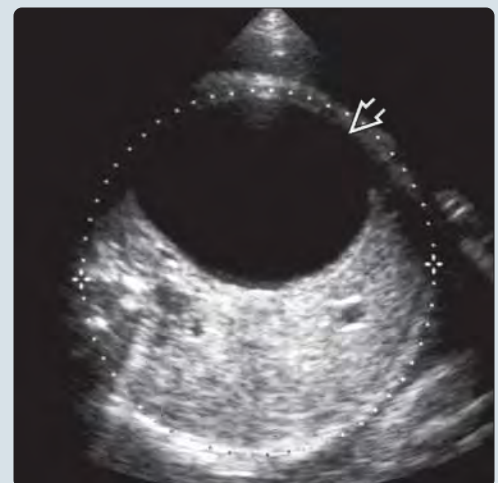
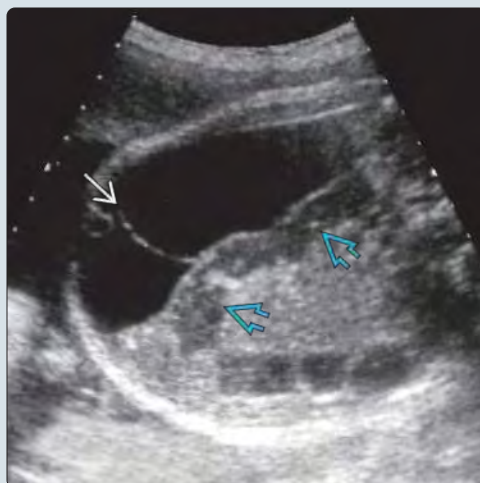
DIAGNOSTIC CHECKLIST

- Mesenteric lymphangioma is most likely diagnosis for large, multiloculated abdominal mass separate from urinary tract

(Left) Axial ultrasound of the fetal abdomen shows a multiloculated cyst  in the anterior abdomen. There was no flow seen on color Doppler. This remained stable throughout pregnancy. **(Right)** Ultrasound of the abdomen on day 1 of life in the same patient shows the cystic mass with multiple thick septations . The infant had no feeding difficulties, and resection was delayed to 6 months of age. Histology showed dilated lymphatic spaces with an endothelial lining typical of a mesenteric lymphangioma.



(Left) Axial oblique US of the fetal abdomen shows a relatively simple, anechoic mesenteric lymphangioma with a single internal septation . Note that the bowel  is being displaced by the mass. **(Right)** Axial ultrasound of a large mesenteric cyst shows a unilocular, thin-walled cyst  filling a large portion of the abdomen. This gallery of images shows the variable appearance of a mesenteric lymphangioma from complex (more common) to unilocular, as in this case.



TERMINOLOGY

Synonyms

- Mesenteric cyst, omental cyst, mesenteric or abdominal lymphovascular malformation

Definitions

- Proliferation of mesenteric lymphatic tissue that fails to communicate with central lymphatic system
- Mesenteric cyst used as generic descriptive term for cystic mass arising in mesentery or omentum

IMAGING

Ultrasonographic Findings

- Variable appearance
 - Most often multilocular, with 1 to multiple septations
 - Septa are variable in thickness
 - Can be very complex, insinuating around organs and extending out of abdomen
 - May be unilocular
 - Usually thin walled
 - Does not have muscular wall as seen with duplication cysts
 - Can be large enough to mimic ascites
 - Bowel is displaced, not floating in fluid
 - Variable echogenicity of fluid, but usually anechoic
 - Displaces bowel and may rarely cause obstruction
 - Often large, distending abdomen
 - No flow on color Doppler

Imaging Recommendations

- Confirm that it is not associated with urinary tract, which is most common source of cystic abdominal mass
- Follow-up scans for growth
 - May extend out of peritoneal cavity to involve retroperitoneum and lower extremities
- Consider fetal MR to evaluate extent of larger masses

DIFFERENTIAL DIAGNOSIS

Bowel Atresia

- Look for peristalsis
- "Cysts" can be connected into contiguous loop of bowel during real-time scanning

Meconium Pseudocyst

- Thick, irregular wall that can calcify
- Other sequelae of meconium peritonitis

Enteric Duplication Cyst

- Can appear identical to unilocular mesenteric cyst
- Often has thicker wall and no internal septations
 - Look for hyperechoic mucosa surrounded by hypoechoic muscular wall ("gut signature")
- More likely to cause obstruction and in utero bowel dilatation

Ovarian Cyst

- Female fetuses only; 3rd trimester
- Most common abdominal cystic mass in female fetus
- Ovarian ligament lax, so can be anywhere in abdomen

Urachal Cyst

- Midline, between bladder and cord insertion

Choledochal Cyst

- Look for bile ducts entering cyst

PATHOLOGY

General Features

- Etiology
 - Proliferation of ectopic lymphatics with lack of normal communication with lymphatic system
 - Lymph accumulates, forming cystic mass
 - *VEGFC*, *PROX1*, *FOXC2*, *SOX18* genes are involved in lymphangiogenesis

CLINICAL ISSUES

Presentation

- In utero
 - Incidental cyst seen on routine scan
- Childhood
 - Palpable mass
 - Abdominal distention and pain
 - May cause bowel obstruction
 - Less likely to do so than duplication cysts because they are of mesenteric origin, rather than bowel wall
 - Cyst rupture reported

Demographics

- Rare in fetal series
- 1/20,000 pediatric hospital admissions

Natural History & Prognosis

- Variable in utero course
 - May remain stable, regress, or expand and invade surrounding structures
- Excellent prognosis
 - May be completely asymptomatic
- Complications
 - Small bowel obstruction, hemorrhage, volvulus, rupture, infection, torsion
 - Rarely obstruct adjacent biliary tree or urinary system

Treatment

- Postnatal work-up usually requires CT or MR to see full extent of large masses
- Cyst drainage often unsuccessful as fluid reaccumulates
- Most require surgical excision ± bowel resection, depending on extent of involvement

DIAGNOSTIC CHECKLIST

Image Interpretation Pearls

- Most likely diagnosis for large, multiloculated abdominal mass separate from urinary tract

SELECTED REFERENCES

1. Chiappinelli A et al: Congenital abdominal cystic lymphangiomas: what is the correct management? *J Matern Fetal Neonatal Med.* 25(7):915-9, 2012
2. Chang TS et al: Mesenteric cystic masses: a series of 21 pediatric cases and review of the literature. *Fetal Pediatr Pathol.* 30(1):40-4, 2011
3. Cozzi DA et al: Fetal abdominal lymphangioma enhanced by ultrafast MRI. *Fetal Diagn Ther.* 27(1):46-50, 2010

KEY FACTS

TERMINOLOGY

- Echogenic material in gallbladder (GB)
 - Stones or sludge or both
 - Most often seen in 3rd trimester

IMAGING

- Spectrum of findings
 - Homogeneous echoes in GB
 - Focal echogenicities in GB
- Spectrum of artifacts
 - Shadowing is difficult to show in fetus
 - No shadowing if stone not in focal zone
 - > 3-mm stones more likely to shadow
 - Comet-tail artifact from cholesterol crystals
 - Twinkle artifact from stones' rough edges
- GB size variable
 - Enlarged or normal size common
 - Contracted GB with echoes can mimic liver calcification

TOP DIFFERENTIAL DIAGNOSES







- Liver echogenicities
 - Calcifications from infection
 - Tumor + calcification
 - Hemangioma
- Meconium peritonitis
 - Calcifications on peritoneal surfaces (liver capsule)
 - ± ascites
 - ± dilated bowel

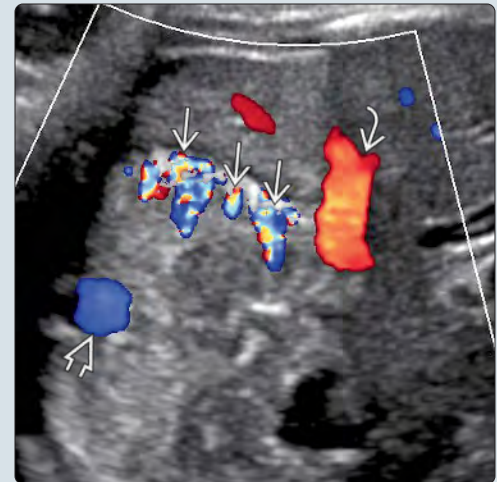
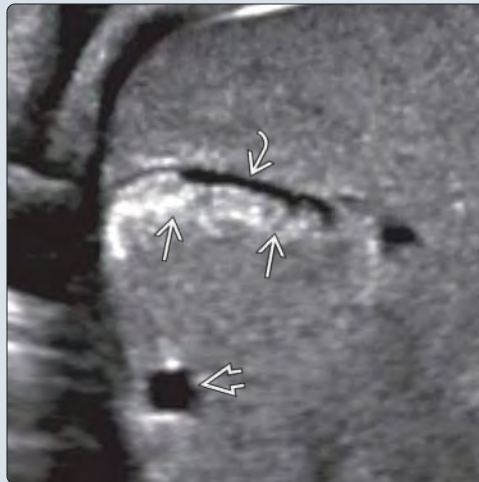
PATHOLOGY





- Abnormal production, composition, mode of bile transport
- Maternal causes include estrogen effect on fetal bile

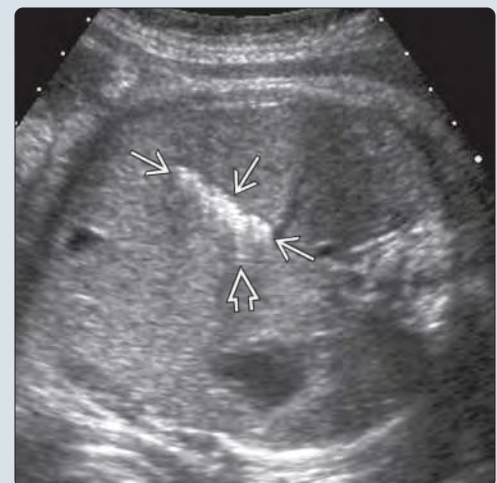
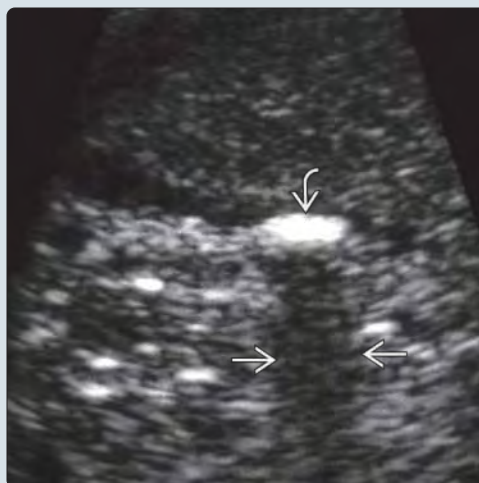
CLINICAL ISSUES

- Most often transient benign finding
 - Almost all resolve by 12 months
- Recommend postnatal confirmation and surveillance

(Left) The gallbladder (GB) , located to the right of the umbilical vein , contains echogenic material . This was an incidental finding in a 3rd-trimester fetus. **(Right)** Color Doppler in the same fetus shows twinkle artifact . The rough surface of small stones causes the false appearance of turbulent flow. Notice the otherwise normal Doppler signal in the right portal vein  and the umbilical vein . Twinkle artifact is used to find tiny stones, too small to shadow. Its presence proves this GB has stones, not sludge.



(Left) Long axis of the fetal GB shows shadowing  echogenic material  in the GB lumen. It is difficult to tell whether this is 1 stone or multiple small stones that are clumped together. **(Right)** This GB is contracted and filled with echogenic material . This appearance may mimic liver calcification. Notice the linear echoes that streak from the posterior border of the GB, into the liver parenchyma (note the long one ). These comet-tail artifacts are from cholesterol crystals.



TERMINOLOGY**Definitions**

- Echogenic material in gallbladder (GB)
 - Stones or sludge
 - Sludge is concentrated echogenic bile

IMAGING**General Features**

- Best diagnostic clue
 - 3rd-trimester GB with echogenic material ± shadowing

Ultrasonographic Findings

- Normal fetal GB
 - Anechoic ovoid or teardrop-shaped structure
 - Intrahepatic early, then becomes subhepatic
 - Thin echogenic wall
 - Seen after 20 weeks in 37-75% of cases
 - Can be seen as early as 14 weeks
- GB with echogenic material
 - GB with sludge, stones, or both
 - GB size variable
 - Enlarged, contracted, normal size
 - Spectrum of findings
 - Homogeneous echoes in GB
 - Focal echogenicities in GB
 - ± shadowing
 - Presence of shadowing suggests stones
 - May not see shadowing if GB not in focal zone or angle not optimized
 - Comet tail artifact from cholesterol crystals
 - Twinkle artifact with color Doppler
 - Looks like chaotic flow
 - Artifact created by rough surface of stones
 - Variable amount of material
 - Completely fills lumen vs. several small foci
- Contracted GB with stones/sludge can mimic liver calcification
 - Look for anterior crescent of bile in GB

Imaging Recommendations

- Protocol advice
 - Confirm foci are within GB lumen
 - 3D ultrasound may be helpful to accurately localize GB and rule out liver surface calcification
 - When looking for shadowing, put GB in small focal zone and insonate 90° to GB long axis

DIFFERENTIAL DIAGNOSIS**Liver Echogenicities**

- Calcifications from infection
 - Toxoplasmosis, cytomegalovirus, varicella
- Tumor + calcification
 - Hepatoblastoma, teratoma, neuroblastoma
- Hemangioma
 - Echogenic mass without calcification

Meconium Peritonitis

- Calcifications on peritoneal surfaces (liver capsule)
 - From fetal bowel perforation

- Often accompanied by other findings
 - Ascites, dilated bowel, echogenic bowel

PATHOLOGY**General Features**

- Etiology
 - Abnormal production, composition, or mode of transport of bile
 - No reported etiologies are conclusive
 - Suggested associations
 - Placental abruption: ↑ indirect bilirubin
 - Maternal estrogen effect on fetal bile
 - ↑ cholesterol, ↓ bile acids
 - Other potential causes
 - Maternal narcotic use
 - Maternal hemolytic anemia
 - Blood group incompatibility
 - Maternal malnutrition/dehydration
- Genetics
 - No clear associations with aneuploidy
- Associated abnormalities
 - Choledochal cyst (rare)

CLINICAL ISSUES**Presentation**

- Most common signs/symptoms
 - Incidental finding in 3rd-trimester fetus

Demographics

- Epidemiology
 - 0.42% in large cohort of 9,235 pregnancies

Natural History & Prognosis

- Most series report gallstones/sludge disappear spontaneously within 1st year of life
 - 87% resolve between 3-7 months
 - Almost all completely resolve by 12 months

Treatment

- Usually none needed
- Ursodeoxycholic acid use is controversial

DIAGNOSTIC CHECKLIST**Image Interpretation Pearls**

- Fetal gallstones do not always shadow
- Recommend follow-up exams after baby is born
 - Immediate post delivery for confirmation
 - 6-month and 1-year follow-up to ensure resolution

SELECTED REFERENCES

1. Troyano-Luque J et al: Short and long term outcomes associated with fetal cholelithiasis: a report of two cases with antenatal diagnosis and postnatal follow-up. *Case Rep Obstet Gynecol.* 2014;7:14271, 2014
2. Triunfo S et al: Fetal cholelithiasis: a diagnostic update and a literature review. *Clin Med Insights Case Rep.* 6:153-8, 2013
3. Tam PY et al: Perinatal detection of gallstones in siblings. *Am J Perinatol.* 27(10): 771-4, 2010
4. Sheiner E et al: Fetal gallstones detected by routine third trimester ultrasound. *Int J Gynaecol Obstet.* 92(3):255-6, 2006
5. Munjuluri N et al: Fetal gallstones. *Fetal Diagn Ther.* 20(4):241-3, 2005

Choledochal Cyst

KEY FACTS

TERMINOLOGY

- Congenital cystic dilatation of extrahepatic &/or intrahepatic bile ducts
- Type 1 (saccular or fusiform dilatation of common bile duct) represents 80-90% of fetal cases

IMAGING

- Right upper quadrant cyst
 - Separate from gallbladder
 - Connection to bile ducts
 - Look for short, tubular bile ducts entering cyst
 - Color Doppler shows relationship to porta hepatitis
 - Helps rule out umbilical vein varix
- Consider MR: Bile is high signal on T2WI, look for bile ducts entering cyst
- ↑ size during gestation is common

TOP DIFFERENTIAL DIAGNOSES

- Duodenal duplication cyst

- Umbilical vein varix
- Cystic biliary atresia
- Liver cyst (rare)
- Gallbladder duplication (rare)

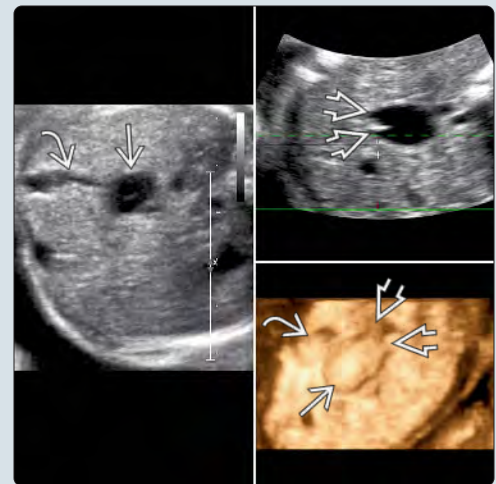
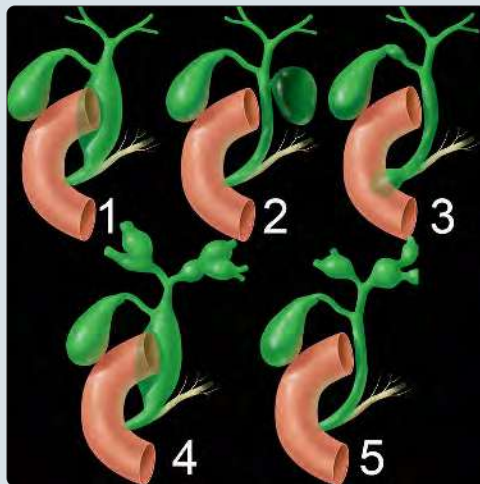
CLINICAL ISSUES

- More common in Asian population and female fetuses
- Most often incidental finding at time of anatomy scan
- Treatment and prognosis
 - Surgical resection with choledochojejunostomy or hepaticojejunostomy
 - Untreated leads to cholestasis, biliary cirrhosis, and eventual liver failure
 - Better outcome with early treatment before liver fibrosis

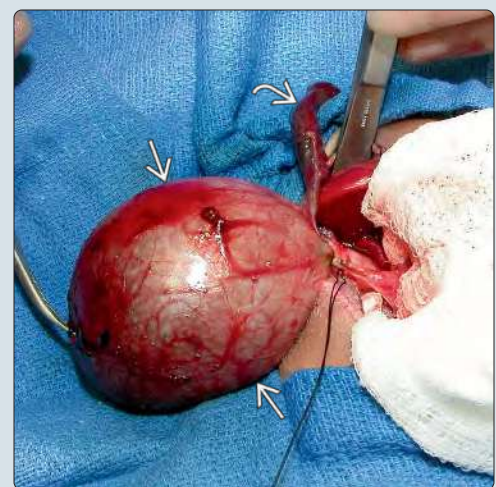
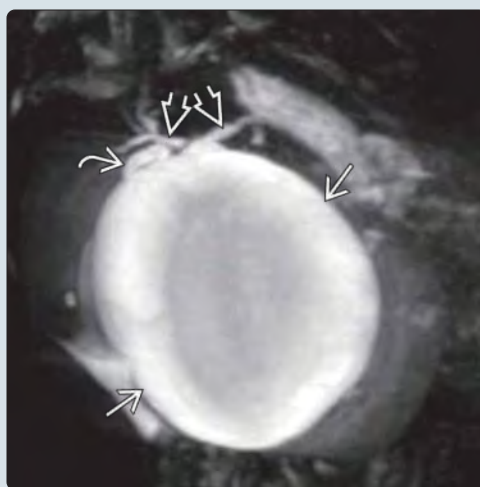
DIAGNOSTIC CHECKLIST

- Right upper quadrant cyst communicating with bile ducts is pathognomonic
- Presence of gallbladder rules out cystic biliary atresia

(Left) *Todani classification type 1, dilatation of the common bile duct, is the most common choledochal cyst and the one typically seen in utero; type 2 is choledochal diverticulum, type 3 is choledochoceles, type 4 is type 1 + intrahepatic involvement, and type 5 is Caroli disease.* (Right) *Multiplanar and 3D images in a 25-week fetus with a choledochal cyst show a unilocular cyst adjacent to the gallbladder. The cyst communicates with the dilated right and left hepatic ducts. These are key findings for the diagnosis.*



(Left) *Immediate postnatal MR in the same case shows a markedly dilated common bile duct, the adjacent gallbladder, and the dilated central right and left hepatic ducts. This choledochal cyst grew throughout the pregnancy and the newborn developed jaundice and needed surgery by day 12 of life.* (Right) *An intraoperative photograph in another child shows a large choledochal cyst next to the gallbladder. Definitive treatment for type 1 choledochal cyst is cyst resection and biliary diversion.*



TERMINOLOGY

Definitions

- Congenital cystic dilatation of extrahepatic &/or intrahepatic bile ducts

IMAGING

General Features

- Best diagnostic clue
 - Right upper quadrant cyst separate from gallbladder and with connection to bile ducts

Ultrasonographic Findings

- Unilocular, cystic right upper quadrant mass
- Look for short, tubular bile ducts entering cyst
- ↑ size during gestation is common

Imaging Recommendations

- Follow liver contour
 - Look for close relationship to gallbladder
 - Coronal view most helpful
- Color Doppler to show close proximity to porta hepatis
- Consider MR: Bile is high signal on T2WI, look for bile ducts entering cyst

DIFFERENTIAL DIAGNOSIS

Other Right Upper Quadrant Cysts

- **Enteric duplication cyst**
 - Duodenal most likely to mimic choledochal cyst
 - Layered wall (gut signature) difficult to see in utero
- **Ovarian cyst**
 - 3rd-trimester diagnosis in female fetuses
- **Liver cyst (within liver parenchyma)**
- **Gallbladder duplication**
- **Mesenteric cyst**
- **Meconium pseudocyst**

Cystic Biliary Atresia

- Key finding: No gallbladder will be seen

Umbilical Vein Varix

- Color Doppler confirms flow

PATHOLOGY

General Features

- Etiology
 - Pancreaticobiliary malfunction
 - Pancreatic enzymes reflux into bile duct with weakening of wall
 - Does not explain early cases (pancreas lacks mature secretory granules when < 20 weeks)
 - Abnormal recanalization during organogenesis
 - Abnormal epithelium resulting in wall weakness

Staging, Grading, & Classification

- Todani modification of Alonso-Lej classification
 - Type 1: Cystic, saccular, or fusiform extrahepatic biliary dilatation (80-90% of cases)
 - Type 2: Common bile duct diverticulum
 - Type 3: Choledochoceles

- Type 4: Intrahepatic and extrahepatic dilatation
- Type 5: Intrahepatic dilatation (Caroli disease)
- Recent Visser classification more clinically relevant
 - Choledochal cyst: Type 1 and 4
 - Considered spectrum
 - Same surgical treatment
 - Types 2, 3, and 5 considered distinct entities requiring different treatments
 - Choledochal diverticulum
 - Choledochoceles
 - Caroli disease

CLINICAL ISSUES

Presentation

- Incidental finding in utero
 - Most often seen at time of anatomy scan
 - Has been reported at time of nuchal translucency scan (11-14 weeks)
- Childhood presentation
 - Jaundice (most common), pain, mass

Demographics

- Incidence
 - 1:100,000-150,000 outside Asia; 1:1,000 in Asia
 - 1/3 of all cases from Japan
- F:M ratio is 3-4:1

Natural History & Prognosis

- Better outcome with early treatment before liver fibrosis
- Higher incidence of liver fibrosis in cases diagnosed in utero
 - Tend to be larger, more severe cases
- Untreated leads to cholestasis, biliary cirrhosis, eventual liver failure
- Risk factor for cholangiocarcinoma

Treatment

- Cyst excision with Roux-en-Y hepaticojejunostomy
 - May delay up to 6 months of age if asymptomatic

DIAGNOSTIC CHECKLIST

Image Interpretation Pearls

- Right upper quadrant cyst communicating with bile ducts is pathognomonic
- Look for separate gallbladder
 - Consider cystic biliary atresia as diagnosis if no gallbladder seen
 - MR may be helpful

SELECTED REFERENCES

1. Cong X et al: Evaluation and screening ultrasonic signs in the diagnosis of fetal biliary cystic malformation. *J Matern Fetal Neonatal Med.* 28(17):2100-5, 2015
2. Jensen KK et al: Antenatal sonographic diagnosis of choledochal cyst: Case report and imaging review. *J Clin Ultrasound.* 43(9):581-3, 2015
3. Khalil A et al: Outcome of first-trimester fetal abdominal cysts: cohort study and review of the literature. *Ultrasound Obstet Gynecol.* 43(4):413-9, 2014
4. Diao M et al: Timing of surgery for prenatally diagnosed asymptomatic choledochal cysts: a prospective randomized study. *J Pediatr Surg.* 47(3):506-12, 2012
5. Ruiz-Elizalde AR et al: A practical algorithm for accurate diagnosis and treatment of perinatally identified biliary ductal dilation: three cases that underscore the importance of an individualised approach. *J Matern Fetal Neonatal Med.* 22(7):622-8, 2009

KEY FACTS

TERMINOLOGY

- Confusing terminology in literature with various terms, which likely describe same lesion
- International Society for Study of Vascular Anomalies now classifies fetal lesion as congenital hemangioma
 - True benign, vascular neoplasm occurring in soft tissues or viscera, typically liver
 - Rapidly involuting congenital hemangioma (RICH) is most common subtype and describes biologic behavior
 - Noninvoluting congenital hemangioma occur rarely

IMAGING

- Well-defined, solid mass that may have central area of necrosis and fibrosis, especially when large
- Vascular on color Doppler with significant arteriovenous shunting
- Often peripheral flow around mass with less central vascularity

TOP DIFFERENTIAL DIAGNOSES

- Hepatoblastoma
- Mesenchymal hamartoma

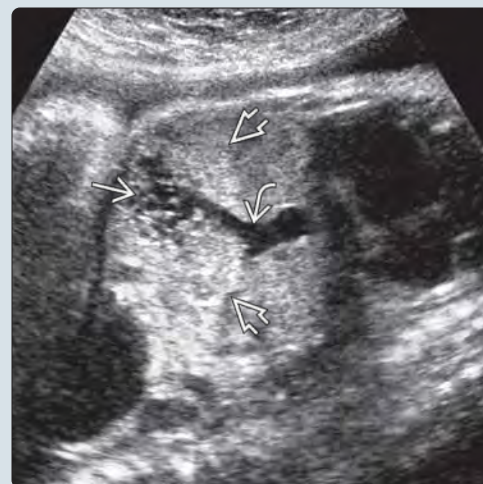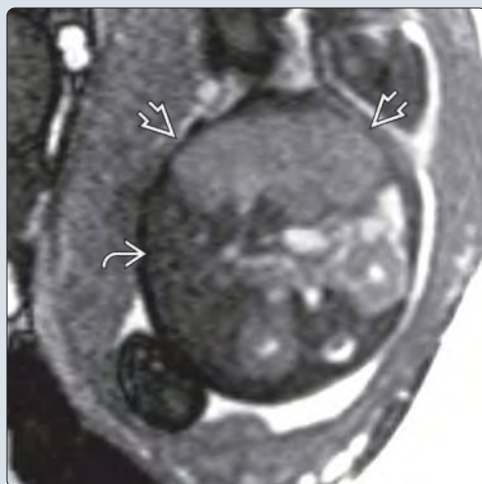PATHOLOGY

- Most common fetal liver tumor
- Immunohistochemical staining negative for GLUT-1 distinguishing it as histologically distinct from other lesions

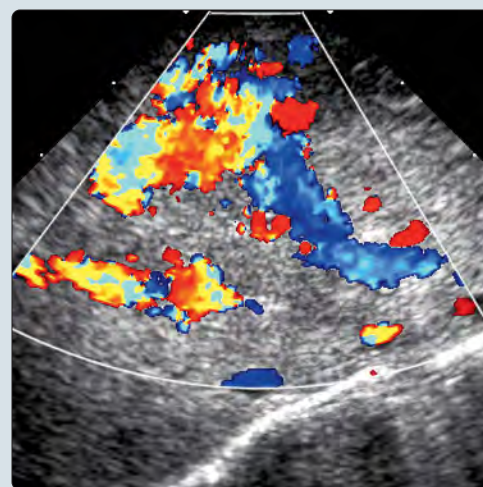
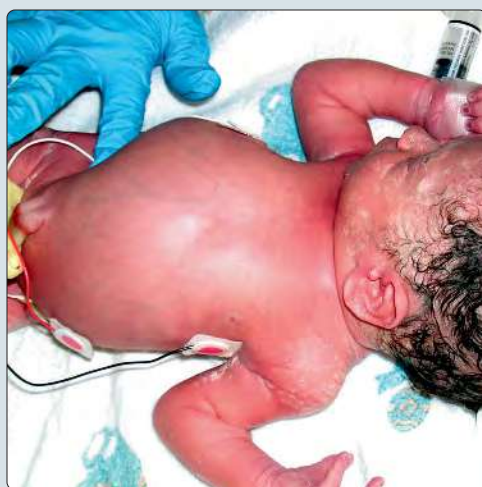CLINICAL ISSUES

- Hydrops can lead to fetal death
- Once delivered and stabilized, prognosis is excellent
- RICH will involute by 14 months of age
- 15% will have cutaneous hemangiomas, which may prompt search for liver lesion

(Left) Axial T2WI MR at 34 weeks shows a large, well-defined, mildly hyperintense mass within the normal low-signal fetal liver. **(Right)** Sagittal oblique ultrasound of the same fetus shows a hyperechoic mass with cystic areas within it. A clue to the vascular nature of the mass on this grayscale image is the large draining vein (Doppler confirmed flow). The fetus was followed carefully and began to show signs of hydrops at 38 weeks, which precipitated delivery.



(Left) Clinical photograph of the same patient immediately after delivery shows an obvious abdominal bulge from the large liver mass. **(Right)** Ultrasound of the liver was performed on day 1 of life and showed similar findings to the prenatal scan. There is dramatic arteriovenous shunting within the mass, typical of a congenital hepatic hemangioma. The infant stabilized and was treated conservatively. Congenital hepatic hemangiomas typically regress (RICH) by 14 months of life and usually do not require surgical resection.



TERMINOLOGY

Synonyms

- Pathogenesis of vascular liver lesion is not completely understood leading to confusing terminology
 - Multiple terms used for what is likely same lesion
 - Infantile hemangioendothelioma most common term seen in literature

Definitions

- International Society for Study of Vascular Anomalies now classifies fetal lesion as **congenital hemangioma**
 - True benign vascular neoplasm occurring in soft tissues or viscera, typically liver
 - Not to be confused with cavernous hemangiomas observed in adulthood (misnomer), which are actually venous malformations, not tumors
 - Further classified on biologic behavior
 - Rapidly involuting congenital hemangioma (RICH)
 - Most common type in fetus
 - Noninvoluting congenital hemangioma (NICH)
 - Infantile hemangioma is distinct histologic type, which occurs in infancy and is not present at birth

IMAGING

Ultrasonographic Findings

- Well-defined, solid mass that may have central area of necrosis and fibrosis, especially when large
 - Multifocal lesions usually only seen in infantile hepatic hemangioma, would be very unusual in fetus
- Vascular on color Doppler with significant arteriovenous shunting
 - Often peripheral flow around mass with less central vascularity
 - Enlarged draining vein and inferior vena cava
- Cardiomegaly, polyhydramnios, and hydrops may develop from high-output failure
- May develop thrombocytopenia, anemia

MR Findings

- T1WI: Low signal intensity mass; may see hyperintense areas related to hemorrhage
- T2WI: Higher signal compared to normal liver but variable centrally depending on blood products, necrosis, fibrosis
 - Central signal changes are more typical postnatally
 - Likely represents hemorrhage and thrombosis occurring with transition from fetal to postnatal circulation
 - Seen in hepatic RICH during involution

Imaging Recommendations

- Protocol advice
 - Close interval follow-up to look for growth and hydrops

DIFFERENTIAL DIAGNOSIS

Hepatoblastoma

- Solid, echogenic mass
- Less vascular with disorganized flow by color Doppler, no large vessels

Mesenchymal Hamartoma

- Predominately cystic or mixed cystic/solid mass

Metastatic Neuroblastoma

- Multiple or diffusely infiltrating liver masses
- Look for solid, suprarenal mass

PATHOLOGY

Microscopic Features

- Varying sized lobules of capillaries surrounded by dense myxoid stroma and large malformed vessels
- Foci of hemorrhage, necrosis, fibrosis, extramedullary hematopoiesis, calcification
- Immunohistochemical staining negative for glucose transporter-1 (GLUT-1) protein
 - Distinguishes it as separate entity from infantile hepatic hemangioma, which is GLUT-1 positive

CLINICAL ISSUES

Presentation

- Fetal presentation
 - Liver mass, polyhydramnios, hydrops
 - Most seen in 3rd trimester
- Postnatal presentation
 - Abdominal distention, palpable mass
 - High-output congestive heart failure, respiratory distress
 - Thrombocytopenia, anemia (usually transient)
 - 15% will have cutaneous hemangiomas, which may prompt search for liver lesion

Demographics

- Epidemiology
 - ~ 5% of fetal tumors occur in liver
 - 60% are congenital hepatic hemangiomas

Natural History & Prognosis

- Hydrops can lead to fetal death
- Once delivered and stabilized, prognosis is excellent
- RICH will involute by 14 months of age
- NICH will not resolve and may require resection

Treatment

- Monitor closely for hydrops and consider early delivery if signs of cardiovascular compromise
- Enlarged abdominal circumference may cause dystocia
- Corticosteroids have been successfully used in fetuses with rapidly growing masses
 - Both maternal administration and direct umbilical vein injection have been described
- Most do not require postnatal treatment
 - Follow monthly with ultrasound for complete involution
- Aggressive supportive treatment for those in congestive heart failure
 - Medical therapies, transarterial embolization, and surgical resection have all been performed with variable results

SELECTED REFERENCES

1. Dasgupta R et al: ISSVA classification. *Semin Pediatr Surg.* 23(4):158-61, 2014
2. Hsi Dickie B et al: Hepatic vascular tumors. *Semin Pediatr Surg.* 23(4):168-72, 2014

KEY FACTS

TERMINOLOGY

- Benign liver tumor composed of large, fluid-filled cysts surrounded by loose mesenchymal tissue containing small bile ducts

IMAGING

- Predominately cystic or mixed cystic/solid mass
- Multiple septations give Swiss cheese appearance
- No flow on color Doppler
- Polyhydramnios often develops
- Hydrops is poor prognostic sign

TOP DIFFERENTIAL DIAGNOSES

- Mesenteric lymphangioma
 - Usually in peritoneal cavity but may involve liver capsule or hepatic parenchyma
- Congenital hepatic hemangioma
 - Increased flow on color Doppler

PATHOLOGY


- Associated with placental mesenchymal dysplasia

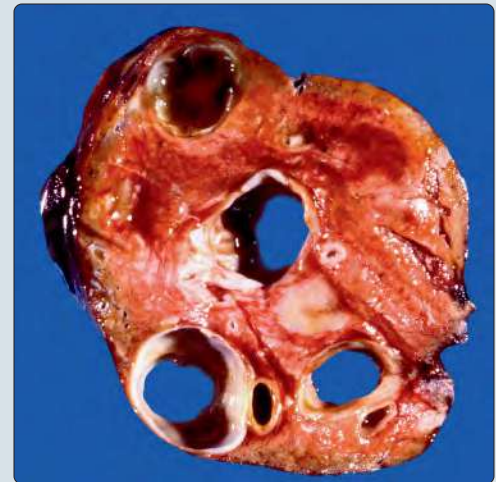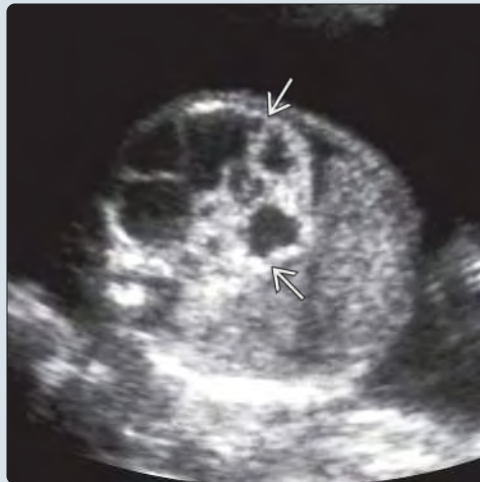
CLINICAL ISSUES


- May show rapid growth
- Prognosis is related to size and compression of surrounding organs
- Prenatal cyst drainage considered for large lesions
- Surgery is curative but not always possible if mass is extensive
- Those diagnosed in perinatal period have more guarded prognosis than those diagnosed later in childhood

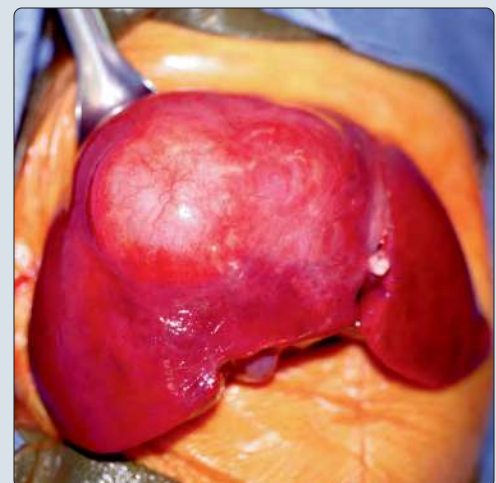
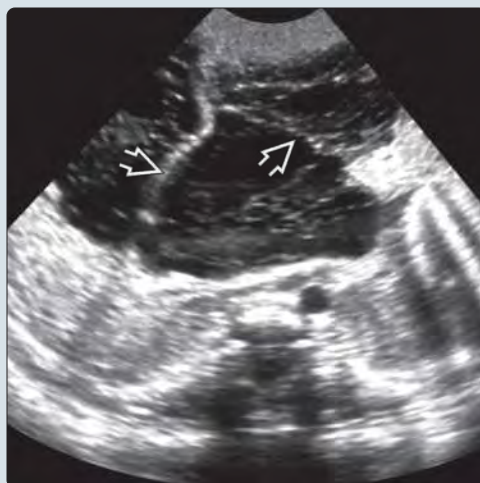
DIAGNOSTIC CHECKLIST

- Consider mesenchymal hamartoma for any cystic abdominal mass that is within or abuts liver
 - 20% are exophytic in pediatric series
- Follow any simple-appearing liver cyst carefully, as mesenchymal hamartomas may show rapid growth

(Left) Axial ultrasound shows a mixed cystic/solid exophytic liver mass . No flow was seen within the cystic spaces with color Doppler. The differential consideration was either a mesenchymal hamartoma or a lymphangioma that involved the liver capsule. **(Right)** The resected gross specimen shows the typical large cystic spaces in a background of disorganized mesenchymal tissue, typical features of a mesenchymal hamartoma.



(Left) Axial ultrasound shows a newborn who had a cystic abdominal mass noted on a 3rd-trimester scan. It is subcapsular and involves a large portion of the liver. Multiple septations  are present. **(Right)** Intraoperative photograph in the same patient shows the mass bulging under the capsule. Mesenchymal hamartomas are benign and surgery is curative but may not be possible if the tumor is extensive. Fetal cases often show rapid growth and have a more guarded prognosis than those diagnosed later in childhood.



TERMINOLOGY

Definitions

- Benign liver tumor composed of large, fluid-filled cysts surrounded by loose mesenchymal tissue

IMAGING

General Features

- Best diagnostic clue
 - Multiloculated, cystic liver mass
- Location (based on pediatric series)
 - Right lobe: 65%; left lobe: 20%; both: 10%
 - Pedunculated in up to 20%

Ultrasonographic Findings

- Grayscale ultrasound
 - Predominately cystic or mixed cystic/solid mass
 - Multiple septations give Swiss cheese appearance
 - Septations may be either thick or thin
 - Cysts may be anechoic or filled with echogenic material
 - Polyhydramnios often develops
 - Hydrops is poor prognostic sign
- No flow on color Doppler
 - Helps to distinguish from hemangioendothelioma

MR Findings

- T2WI
 - Hyperintense cysts surrounded by hypointense stroma

DIFFERENTIAL DIAGNOSIS

Mesenteric Lymphangioma

- Unilocular or multilocular cystic abdominal mass
- May have similar appearance
- Usually in peritoneal cavity but may involve liver capsule or parenchyma

Congenital Hepatic Hemangioma

- Variable sonographic appearance with overlap in imaging findings on grayscale ultrasound
 - Hypoechoic, hyperechoic, or mixed echogenicity
 - Sonolucencies may be seen within mass
- Increased flow on color Doppler

Hepatoblastoma

- Solid, echogenic masses
- Pseudocapsule around lesion creates well-defined borders
- Spoke wheel described with alternating hypo- and hyperechoic areas
- Moderate vascularity by color Doppler

PATHOLOGY

General Features

- Etiology
 - Presumed developmental malformation of primitive hepatic mesenchyme
 - Occurs late in embryogenesis
 - Cysts may form from ischemic degeneration of mesenchymal tissue
 - Association with androgenetic/biparental mosaicism (ABM) has been reported
 - ABM implies diploid chromosomal complement derived entirely from father in subset of cells
 - ABM also predisposes to placental mesenchymal dysplasia

- Associated abnormalities

- Placental mesenchymal dysplasia
 - May see multiple placental cysts
- Has been reported with Beckwith-Wiedemann syndrome

Gross Pathologic & Surgical Features

- Nonencapsulated mass with multiple cysts filled with clear or mucoid material

CLINICAL ISSUES

Presentation

- Most common signs/symptoms
 - Usually presents in 3rd trimester with cystic abdominal mass
 - Has been reported in 2nd trimester as small liver cyst that rapidly grew

Demographics

- Rare but comprised 23% of 194 hepatic tumors diagnosed in perinatal period

Natural History & Prognosis

- May show rapid growth
- Prognosis is related to size and compression of surrounding organs
 - Those diagnosed in perinatal period have more guarded prognosis than those diagnosed later in childhood
 - May have in utero demise
 - 79% survival rate for liveborns who have surgical resection

Treatment

- Prenatal cyst drainage considered for large lesions
- May need cesarean section if abdominal circumference is enlarged
- Surgery is curative but not always possible if mass is extensive

DIAGNOSTIC CHECKLIST

Consider

- Mesenchymal hamartoma for any cystic abdominal mass that is within or abuts liver
 - Remember they may be exophytic

Image Interpretation Pearls

- Follow any simple-appearing liver cyst carefully as mesenchymal hamartomas may show rapid growth

SELECTED REFERENCES

1. Harris K et al: Placental mesenchymal dysplasia with hepatic mesenchymal hamartoma: a case report and literature review. *Fetal Pediatr Pathol.* 32(6):448-53, 2013
2. Mack-Detlefsen B et al: Multiple hepatic mesenchymal hamartomas in a premature associated with placental mesenchymal dysplasia. *J Pediatr Surg.* 46(8):e23-5, 2011
3. Makin E et al: Fetal and neonatal liver tumours. *Early Hum Dev.* 86(10):637-42, 2010
4. Cornette J et al: Mesenchymal hamartoma of the liver: a benign tumor with deceptive prognosis in the perinatal period. Case report and review of the literature. *Fetal Diagn Ther.* 25(2):196-202, 2009

KEY FACTS



IMAGING

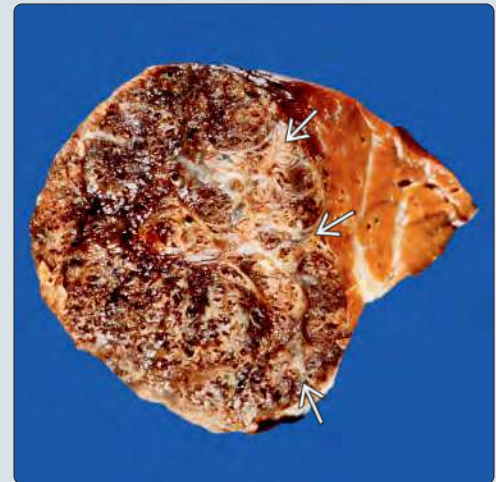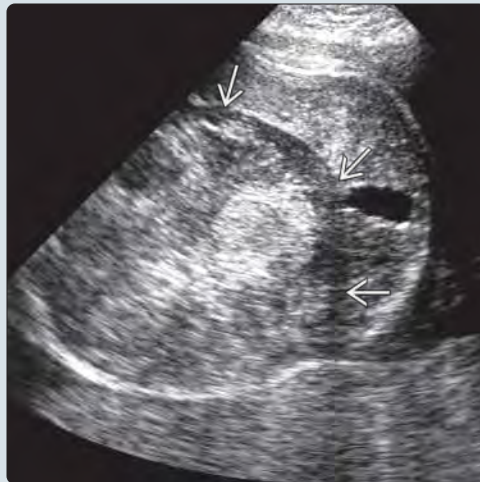
- **Hepatoblastoma**
 - Most common primary malignancy
 - Well-defined, solid mass
 - Fibrous septa create spoke-wheel appearance
 - Disorganized, mild to moderate vascularity
 - No large vessels as seen in congenital hepatic hemangioma
 - May have elevated maternal serum α -fetoprotein
 - Very poor prognosis if diagnosed in utero
- **Metastatic neuroblastoma**
 - Most common fetal malignancy to metastasize to liver
 - 25% of neuroblastoma cases have liver metastases
 - Look for primary tumor in suprarenal fossa
 - Liver metastases may either form discrete masses or be diffusely infiltrating
 - Infiltrating metastases may be missed, but be suspicious if hepatomegaly is present




- Stage 4S (unique grouping of metastases limited to skin, liver, and < 10% of bone marrow) has excellent prognosis
- **Leukemia**
 - 15-20x increased risk in trisomy 21
 - Hepatosplenomegaly most common finding
 - Hydrops common
 - Most subtypes in perinatal period have good prognosis

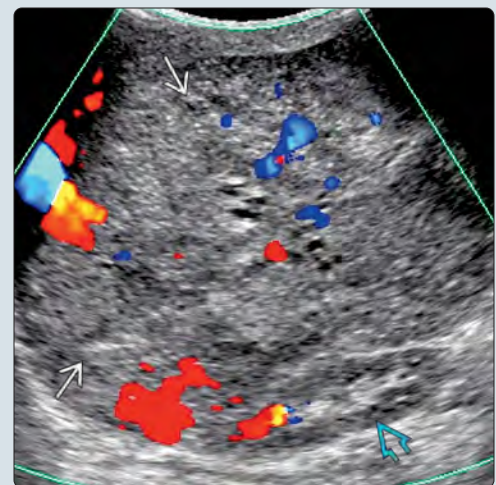
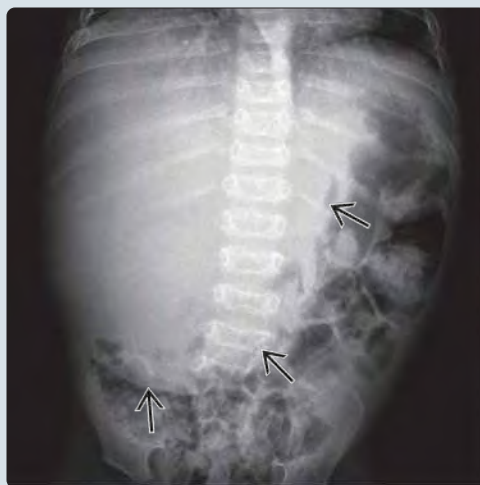CLINICAL ISSUES

- ~ 5% of fetal tumors occur in liver, and most are benign
 - Congenital hepatic hemangioma, mesenchymal hamartoma
- Malignant fetal liver tumors are rare
 - Consider hepatoblastoma for a large solitary mass
 - Consider leukemia in fetus with trisomy 21 and hepatosplenomegaly
 - Always carefully evaluate liver for metastases in cases of neuroblastoma

(Left) Axial ultrasound of a hepatoblastoma shows a large, well-defined, solid liver mass . A spoke-wheel appearance is used to describe the pattern of varying echogenicities within the mass. (Right) Autopsy photograph of the liver in the same patient shows the well-defined mass with prominent fibrous bands  extending to the pseudocapsule, correlating with the ultrasound appearance.



(Left) Abdominal radiograph of an infant with a palpable abdominal mass shows displacement of bowel gas by a markedly enlarged liver . (Right) Color Doppler ultrasound of the same patient shows a large, mildly heterogeneous, solid mass  replacing most of the right lobe of the liver (the normal right kidney  is noted for size reference). There is a mild amount of disorganized internal vascularity but no enlarged draining vessels as seen with a congenital hepatic hemangioma. (From *DI: Pediatrics*, 3e.)



TERMINOLOGY

Definitions

- 3 most common malignant fetal liver tumors
 - **Hepatoblastoma**
 - Malignant embryonic hepatic tumor composed of epithelial cells and occasionally mixture of epithelial and mesenchymal cells
 - Most common primary malignancy
 - **Metastases**
 - Typically neuroblastoma
 - All other metastases exceedingly rare
 - **Leukemic infiltration**
 - Most commonly transient abnormal myelopoiesis associated with trisomy 21

IMAGING

General Features

- **Hepatoblastoma**
 - Solid, echogenic mass
 - Pseudocapsule around lesion creates well-defined borders
 - Tends to displace rather than invade adjacent structures
 - Spoke-wheel appearance described with varying hypo- and hyperechoic areas
 - Appearance created by fibrous septa
 - Disorganized, mild to moderate vascularity by color Doppler
 - No large vessels as seen in congenital hepatic hemangioma
 - Calcifications occasionally seen
 - More common in postnatal cases
 - Can have spontaneous hemorrhage
 - Will appear more heterogeneous in echogenicity
 - If very large, organ of origin may be difficult to determine
 - Hydrops and polyhydramnios may be seen
- **Metastatic neuroblastoma**
 - Most common primary fetal tumor to metastasize to liver
 - 25% of neuroblastoma cases have liver metastases
 - Look for primary tumor in suprarenal fossa
 - Solid primary tumors are more likely to metastasize than cystic ones
 - Liver is most common site of metastases, but they may be seen anywhere, including placenta
 - Liver metastases may be diffusely infiltrating or form discrete lesions
 - Diffusely infiltrating liver metastases may be missed, especially with ultrasound
 - Consider MR for further evaluation
- **Leukemia**
 - Hepatosplenomegaly most common finding
 - Hydrops frequently develops
 - May develop from several potential causes
 - Fetal anemia
 - Leukemic infiltration of myocardium
 - Visceral fibrosis with increased vascular resistance

Imaging Recommendations

- Protocol advice
 - Confirm mass is within liver
 - Large renal, adrenal, and retroperitoneal masses may be mistaken for liver mass
 - Careful Doppler analysis
 - Significant vascularity with arteriovenous shunting favors congenital hepatic hemangioma, benign tumor
 - Follow-up scans
 - Monitor size of tumor
 - Look for development of hydrops
 - Early delivery may be considered if mass is rapidly growing &/or signs of impending cardiovascular compromise

DIFFERENTIAL DIAGNOSIS

Congenital Hepatic Hemangioma

- Most common liver mass in fetus
- Variable sonographic appearance
 - Hypoechoic, hyperechoic, or mixed echogenicity
- Usually hypervascular
 - Increased flow on color Doppler
 - Typically around periphery with large draining vein
 - Flow void described on fetal MR
- Hydrops may develop from arteriovenous shunting

Mesenchymal Hamartoma

- Predominately cystic or mixed, cystic/solid mass
- Does not have increased vascularity
- May develop hydrops
 - Secondary to rapid fluid shifts within expanding cysts

Conditions Causing Hepatomegaly

- **Nonimmune hydrops**
 - Multitude of causes, including cardiac anomalies, fetal masses, chromosomal anomalies, and placental chorioangiomas
- **Immune hydrops**
 - Rhesus (Rh) alloimmunization
 - Other alloimmune syndromes (Kell, Duffy, C, c, E, and others)
 - Check velocities in middle cerebral artery for anemia
- **Infection**
 - Cytomegalovirus (most common in utero infection), toxoplasmosis, parvovirus B19, varicella
 - Look for punctate, nonshadowing calcification within hepatic parenchyma
 - May see calcification elsewhere, particularly brain
 - Other findings include: Growth restriction, echogenic bowel, ventriculomegaly, polyhydramnios, hydrops
- **Beckwith-Wiedemann syndrome**
 - Organomegaly, primarily hepatosplenomegaly, and nephromegaly
 - Macroglossia
 - Macrosomia
 - Hemihypertrophy
 - Omphalocele
- **Gaucher disease (perinatal-lethal subtype)**
 - Hepatosplenomegaly
 - Hypokinesia/arthrogryposis

- Hydrops
- Ichthyosis, facial dysmorphism
- Prenatal testing available

PATHOLOGY

General Features

- Genetics
 - Hepatoblastoma
 - May be familial
 - Short arm chromosome 11
 - Similar to rhabdomyosarcoma and Wilms tumor
 - Leukemia
 - 15-20x increased risk of leukemia in trisomy 21

Microscopic Features

- Hepatoblastoma
 - Malignant tumor classified histologically as epithelial or mixed (epithelial + mesenchymal)
- Leukemia
 - Elevated peripheral leukocyte counts with circulating blasts

CLINICAL ISSUES

Presentation

- Most common signs/symptoms
 - Large right upper quadrant mass
 - Hepatomegaly
 - Hydrops
- Other signs/symptoms
 - Maternal serum α -fetoprotein may be elevated
 - Series are small but reported in 50% of fetal hepatoblastoma cases
 - Mirror syndrome described in both metastatic neuroblastoma and hepatoblastoma if fetus hydropic
- Postnatal
 - Palpable abdominal mass
 - Feeding difficulties

Demographics

- Epidemiology
 - ~ 5% of fetal tumors occur in liver, and most are benign (congenital hepatic hemangioma, mesenchymal hamartoma)
 - In series of 194 perinatal primary liver tumors, 16.5% were hepatoblastoma

Natural History & Prognosis

- **Hepatoblastoma**
 - Very poor prognosis if diagnosed in utero
 - Widespread systemic metastases often present in patients presenting in perinatal period
 - Most commonly brain, bone, and placenta
 - Lungs are generally spared, presumably due to fetal circulation pattern
 - Those able to undergo surgery have 75% mortality rate
- **Metastatic neuroblastoma**
 - 2 distinct groups
 - **Stage 4:** Distant metastases, including liver
 - Poor prognosis

- **Stage 4S:** Unique grouping of metastases with excellent prognosis
 - Metastases limited to skin, liver, and < 10% of bone marrow (not bone)

- **Leukemia** has 2 primary subtypes
 - **Transient abnormal myelopoiesis** type most often seen in fetus/newborn
 - Unusual myeloid proliferation resembling acute myeloid leukemia
 - Can be seen in up to 10% of newborns with trisomy 21 on peripheral smear
 - Only small percentage have hepatosplenomegaly
 - Resolves spontaneously; however, 20-30% will subsequently develop myeloid leukemia
 - **Myeloid leukemia associated with Down syndrome**
 - Good prognosis for those with *GATA1* mutations
 - Requires chemotherapy protocol
 - Acute lymphoblastic leukemia has worse prognosis in Down syndrome patients than in general population but is unusual in perinatal period

Treatment

- If diffuse hepatosplenomegaly, rule out more common causes 1st
 - Consider karyotype, especially if any markers for trisomy 21
- Pediatric surgery consult prior to delivery to discuss resectability and treatment options
- Delivery at tertiary care facility
 - Consider cesarean section
 - Intrapartum tumor rupture has been reported

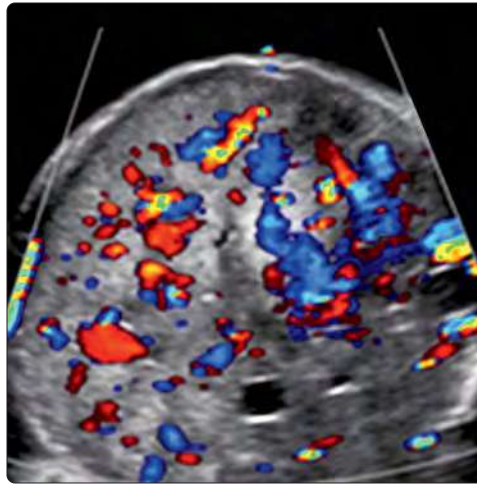
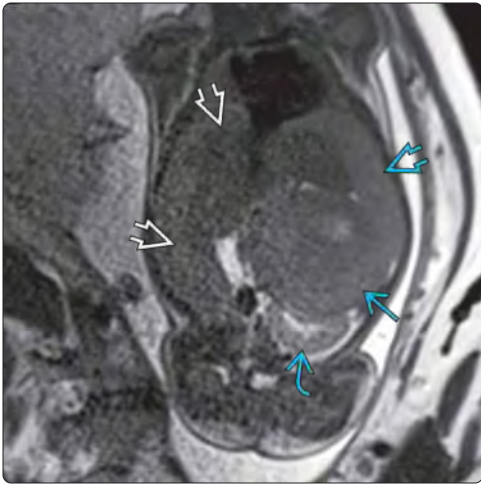
DIAGNOSTIC CHECKLIST

Image Interpretation Pearls

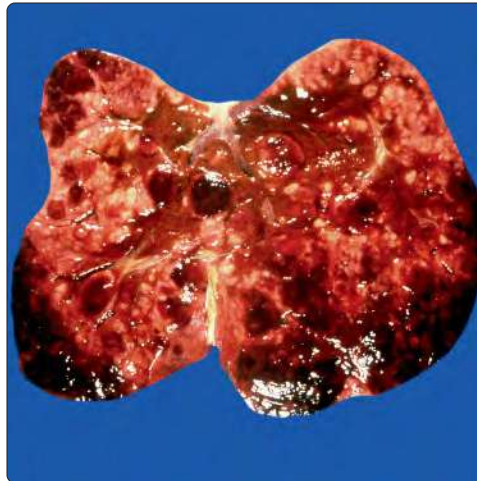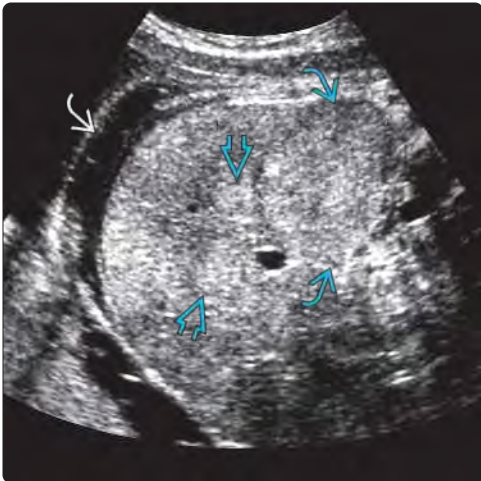
- Hepatoblastomas are well-defined, solid masses, which may exhibit spoke-wheel pattern of echogenicity
- Metastatic neuroblastoma may cause either focal liver mass or diffuse infiltration
 - Look for suprarenal primary tumor
- Consider leukemia in setting of diffuse hepatosplenomegaly, especially if fetus has Down syndrome

SELECTED REFERENCES

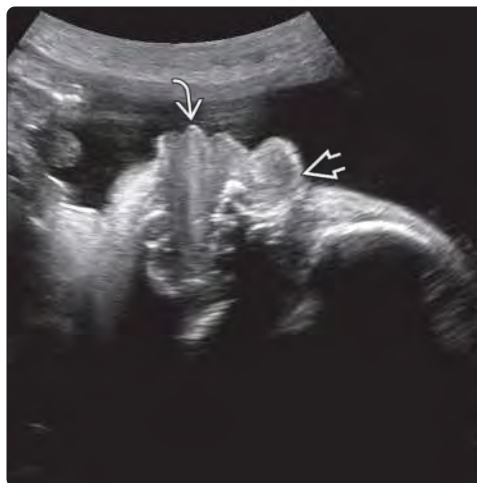
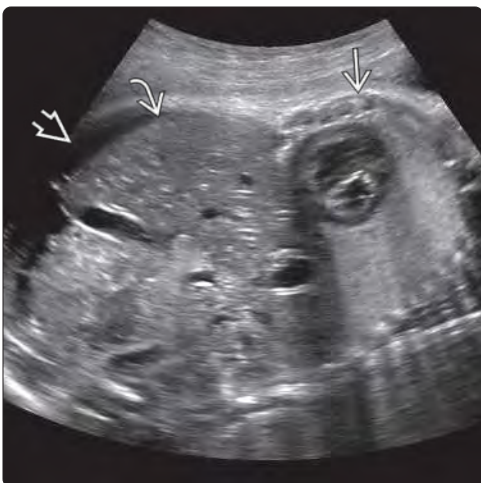
1. Miura Y et al: Diagnosis and treatment of a preterm infant with inoperable congenital hepatoblastoma—a case report. *J Pediatr Hematol Oncol.* 37(3):e188-90, 2015
2. Nagaraj UD et al: Diagnostic imaging of fetal and neonatal abdominal and soft tissue tumors. *Curr Pediatr Rev.* 11(3):143-50, 2015
3. Fisher JP et al: Neonatal neuroblastoma. *Semin Fetal Neonatal Med.* 17(4):207-15, 2012
4. Fouché C et al: [Fetal hepatosplenomegaly in the third trimester: A sign of leukemia in fetuses with Down syndrome.] *J Gynecol Obstet Biol Reprod (Paris).* 39(8):667-71, 2010
5. Makin E et al: Fetal and neonatal liver tumours. *Early Hum Dev.* 86(10):637-42, 2010
6. Desai G et al: Prenatal detection of an extra-adrenal neuroblastoma with hepatic metastases. *J Ultrasound Med.* 28(8):1085-90, 2009
7. Isaacs H Jr: Fetal and neonatal leukemia. *J Pediatr Hematol Oncol.* 25(5):348-61, 2003



(Left) Coronal T2 MR of a fetus with metastatic neuroblastoma shows the tumor displacing the kidney inferiorly. There was marked hepatomegaly with the left lobe having a normal homogeneous appearance, while the right has large areas of abnormal, heterogeneous, low signal intensity. (Right) Axial color Doppler ultrasound in the same patient shows diffuse increased abnormal flow. Metastases may either be diffusely infiltrating, as shown here, or form discrete masses.



(Left) Transverse ultrasound of the abdomen in a fetus with metastatic neuroblastoma shows a large, solid, supracardiac mass. The liver is heterogeneous with the suggestion of a few discrete nodules. Ascites is also seen. (Right) Autopsy specimen from the same patient shows the liver is riddled with metastases. Small or infiltrating hepatic metastases can be difficult to discern prenatally, but the liver should always be given careful scrutiny as 25% of neuroblastoma cases have liver involvement.



(Left) This was a routine scan on a 3rd-trimester fetus. The abdomen was large with hepatomegaly and a small amount of ascites (compare the protuberant abdomen to the normal-sized chest). (Right) A profile view in the same patient showed an absent nasal bone and macroglossia. A presumptive diagnosis of trisomy 21 with leukemia was made, which was confirmed at delivery. The white blood cell count was > 300,000 with 93% blasts. Fetal leukemia has a strong association with Down syndrome.

DIFFERENTIAL DIAGNOSIS

Common

- Idiopathic (Normal Variant)
- Trisomy 21
- Infection
 - Cytomegalovirus
 - Parvovirus
 - Toxoplasmosis
- Cystic Fibrosis
- Meconium Peritonitis (Mimic)

Less Common

- Fetal Growth Restriction
- Ingested Blood

Rare but Important

- Bowel Ischemia

ESSENTIAL INFORMATION

Key Differential Diagnosis Issues

- Echogenic bowel (EB) definition: Fetal bowel echogenicity \geq than surrounding bone
 - Focal EB is more likely pathologic than diffuse EB
- Prevalence: 0.4-2%
- Avoid false-positive diagnoses
 - Make diagnosis with 3.5-5.0 MHz transducer
 - High frequency probe may cause false EB
 - Turn down gain as low as possible when suspect EB
 - Does bone "disappear" before bowel?
- Etiology differs by cause for EB
 - Trisomy 21 and cystic fibrosis: Thick viscus secretions
 - FGR: Bowel hypoperfusion/ischemia

Helpful Clues for Common Diagnoses

- **Idiopathic**
 - 82.5% of cases of EB are considered normal variant
- **Trisomy 21**
 - 6.7x \uparrow maternal a priori risk when isolated
 - Look for other markers, anomalies

- **Infection**
 - 4-6% cases of EB from infection
 - Cytomegalovirus most common
 - Microcephaly, FGR, hydrops
- **Cystic Fibrosis**
 - 4-5% cases of EB with cystic fibrosis
 - \uparrow in northern European Caucasians
 - \pm bowel obstruction (meconium ileus)
- **Meconium Peritonitis, (Mimic)**
 - Bowel perforation \rightarrow peritonitis
 - Linear and punctate echoes/calcifications
 - Outline liver and bowel
 - Pseudocyst = walled-off fluid
 - Dilated bowel from associated atresia

Helpful Clues for Less Common Diagnoses

- **Fetal growth restriction (FGR)**
 - 10% of 2nd-trimester fetuses with EB develop FGR
 - EB probably from hypoperfusion to bowel
 - Other markers with EB suggestive of impending placental insufficiency
 - EB + \uparrow maternal serum alpha fetoprotein
 - EB + abnormal uterine artery Doppler
- **Ingested Blood**
 - Dependent layering in stomach is clue
 - Often transient
 - Look for evidence of prior perigestational hemorrhage as source for blood
 - Associated with \uparrow maternal serum alpha fetoprotein

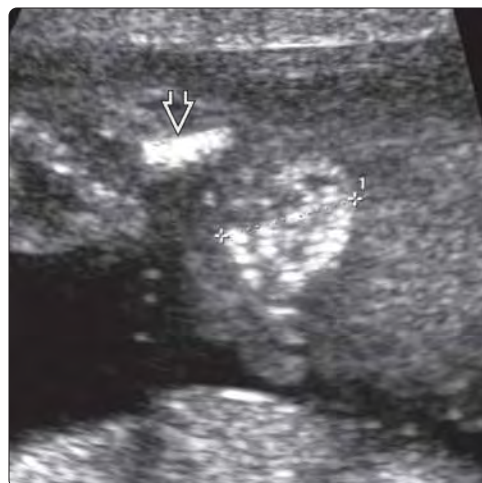Helpful Clues for Rare Diagnoses




- **Bowel Ischemia**
 - From any fetal hypotensive event
 - Associated with twin-twin transfusion

Other Essential Information

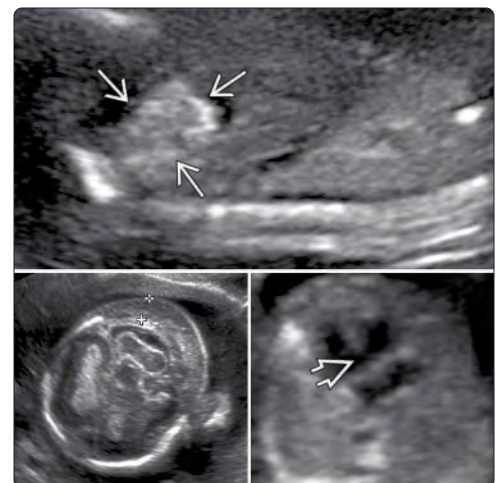
- 6-15% adverse outcome when EB is isolated
- 50% adverse outcome when EB not isolated
- Other aneuploidy associations include trisomy 18, trisomy 13, Turner syndrome + others

Idiopathic (Normal Variant)

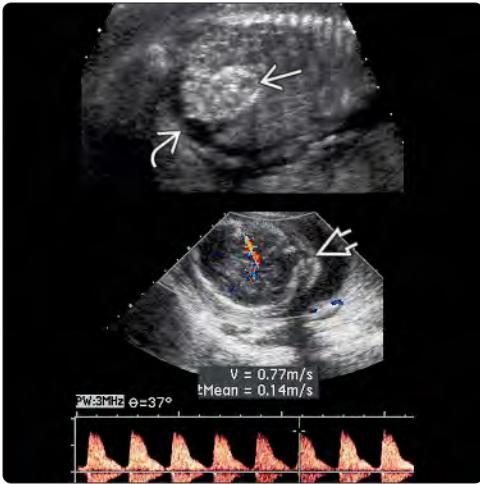


(Left) Coronal oblique ultrasound shows a 2nd-trimester fetus with isolated focal echogenic bowel (EB). The bowel (calipers) is as echogenic as the iliac crest . This fetus had normal karyotype results and normal outcome. (Right) Images through the fetal abdomen, head, and heart in this 2nd-trimester fetus with trisomy 21 show EB , thickened nuchal fold (calipers), and a subtle cardiac ventricular septal defect . The presence of 2 markers and an anomaly led to genetic testing.

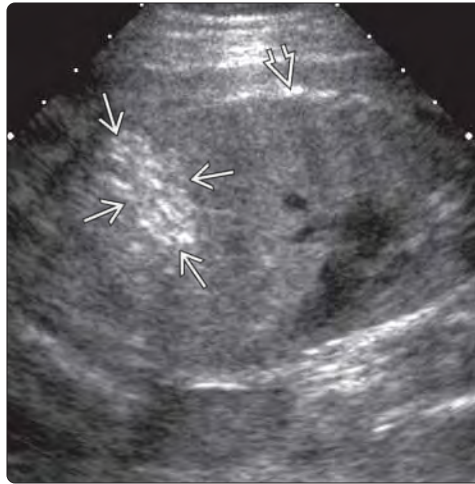
Trisomy 21



Parvovirus

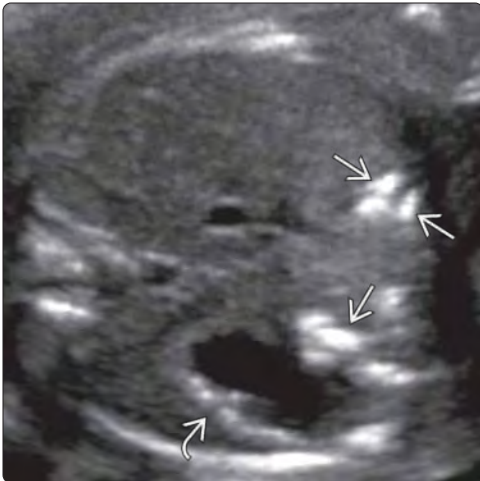

Cystic Fibrosis

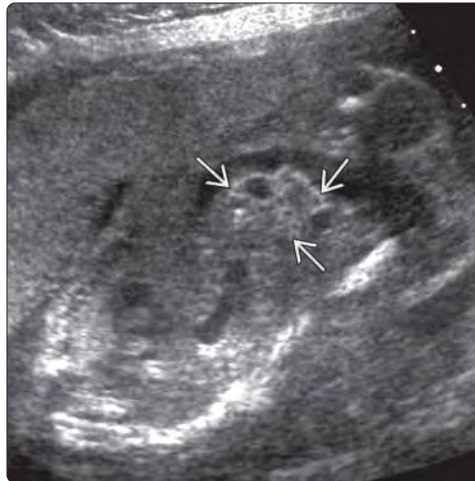

(Left) This fetus with complications of parvovirus infection has EB in addition to anasarca and ascites . The middle cerebral artery peak systolic velocity is elevated at 0.77 m/sec, suggesting anemia. Severe fetal anemia from infection can result in hydrops. Fetal transfusion can be considered for treatment. (Right) Coronal ultrasound shows EB as bright as bone . The parents were subsequently found to be cystic fibrosis carriers, and the fetus was diagnosed with cystic fibrosis at birth.

Meconium Peritonitis (Mimic)

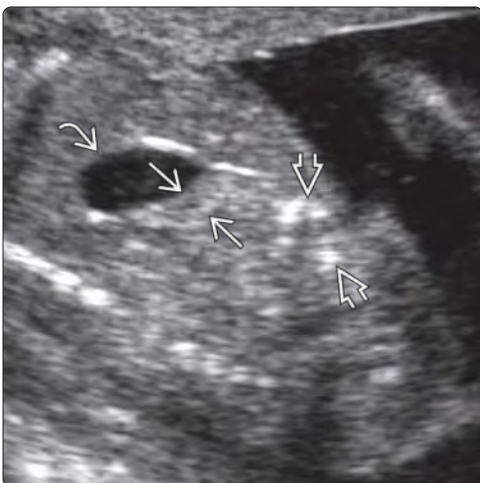

Fetal Growth Restriction

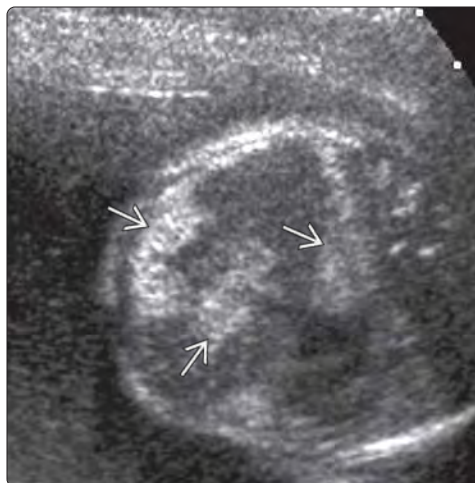


(Left) Plaque-like calcifications scattered in the abdomen and outlining the serosal surface of the fetal stomach are classic features of meconium peritonitis. This may mimic echogenic bowel. Additional calcifications along the liver surface were seen in this case. (Right) Sagittal oblique ultrasound shows EB in a pregnancy complicated by oligohydramnios and fetal growth restriction (FGR). The cause for the FGR in this case was severe placental insufficiency.

Ingested Blood



Bowel Ischemia



(Left) Sagittal oblique ultrasound shows EB and an echogenic fluid level in the fetal stomach . The pregnancy was complicated by chronic abruption. The EB was caused from ingested intraamniotic blood/proteinaceous material. (Right) Axial oblique ultrasound shows diffusely echogenic bowel in a twin pregnancy complicated by twin-twin transfusion. This donor twin had both bowel and brain ischemia.

DIFFERENTIAL DIAGNOSIS**Common**

- Pseudoascites (Mimic)
- Hydrops
- Bowel Perforation

Less Common

- Urinary Ascites
- Infection
- Arrhythmia

ESSENTIAL INFORMATION**Key Differential Diagnosis Issues**

- Intraabdominal fluid surrounding bowel and solid organs
- May also outline falciform ligament and umbilical vein
- Isolated ascites may be 1st sign of impending failure/hydrops
 - In absence of impending failure, isolated more likely to be perforated viscus (bladder or bowel)

Helpful Clues for Common Diagnoses






- **Pseudoascites (Mimic)**
 - Abdominal wall musculature can mimic ascites
 - More prominent with slightly oblique scan angle
 - Perpendicular high-frequency insonation can frequently discern 3 distinct muscle layers
 - Stops at midline at cord insertion and posteriorly at attachment to ribs
- **Hydrops**
 - Fluid in 2 body spaces: Skin edema, pleural effusion, ascites, pericardial effusion
 - Polyhydramnios and placentomegaly common
 - Immune or nonimmune (multiple causes)
 - Any fetal mass may cause increased cardiac output and nonimmune hydrops
 - Chest masses may also obstruct vascular and lymphatic return making ascites prominent feature
- **Bowel Perforation**
 - Initial ultrasound may show mildly dilated bowel

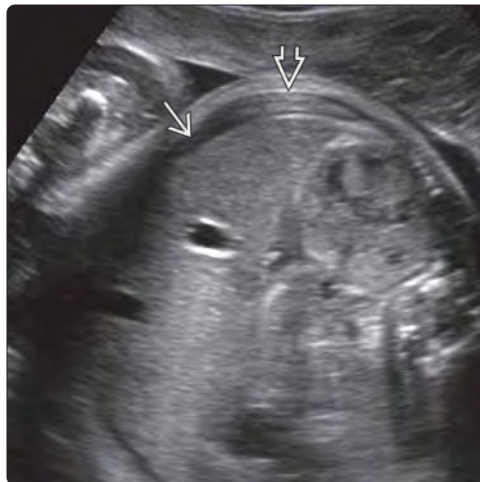
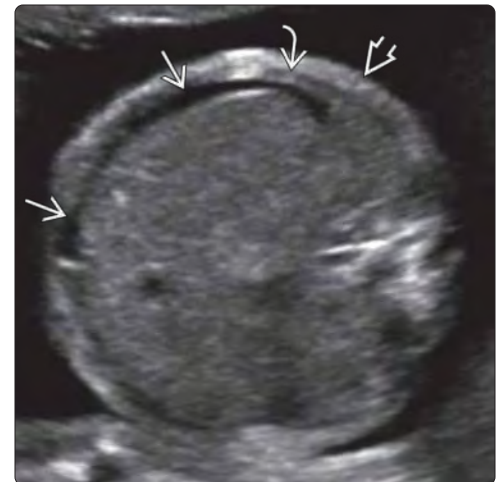
- Underlying atresia(s), volvulus, intussusception, meconium ileus
- Progressive dilation during pregnancy
- Often perforation event is occult, with ascites being only finding
- Look for signs of meconium peritonitis
 - Intraperitoneal calcifications
 - Meconium pseudocyst

Helpful Clues for Less Common Diagnoses

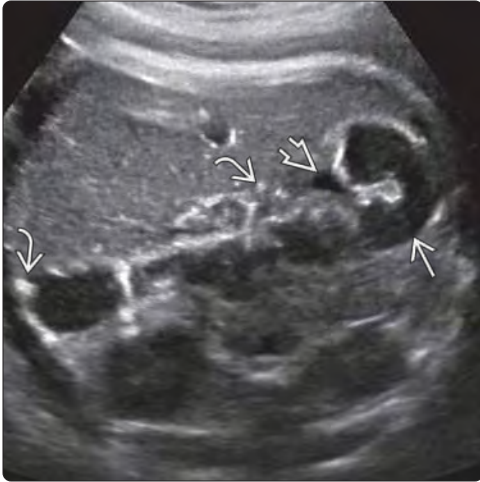
- **Urinary Ascites**
 - Initial ultrasound may show markedly enlarged bladder
 - Look for evidence of posterior urethral valves or urethral atresia
 - Less commonly due to prune belly or megacystis-microcolon
 - Bladder rupture results in urinary ascites
 - Thick-appearing bladder wall after decompression
 - Follow all fetuses with large bladder; likely transient finding if otherwise normal urinary tract
 - Upper tract obstruction (e.g., ureteral pelvic junction obstruction) can also less commonly lead to urinary ascites
 - Perforation of upper tract usually causes contained retroperitoneal urinoma
- **Infection**
 - Ascites may be isolated, but more commonly, is part of generalized hydrops
 - Look for intrahepatic or cerebral calcifications
 - Correlate with clinical history for maternal signs of infection or exposures
- **Arrhythmia**
 - Tachyarrhythmia
 - Sustained heart rate > 180-200 BPM
 - Bradyarrhythmia
 - Fetal heart rate < 100 beats per minute
 - Monitor to assess if transient (benign)
 - Often associated with structural anomaly (~ 50%)
 - Ascites often 1st sign of cardiac decompensation from any cause

Pseudoascites (Mimic)

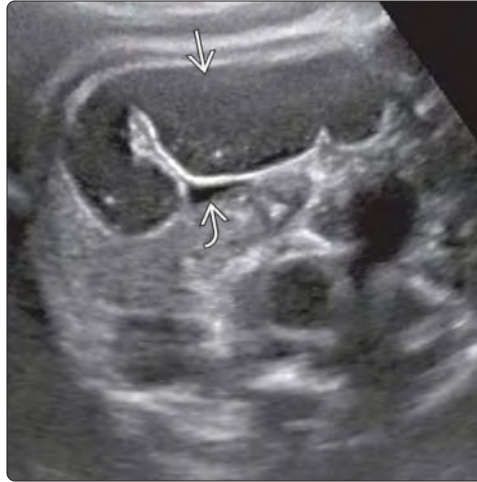(Left) Hypoechoic abdominal wall musculature is a potential pitfall for ascites. In an oblique plane it looks like fluid  but where the beam is perpendicular  the muscle layers can be seen. (Right) Trace ascites, while sometimes subtle, can be confidently diagnosed when anechoic fluid is present along the margin of the liver capsule . This may be the 1st sign of impending failure and hydrops. Note the hypoechoic abdominal wall musculature  located outside the peritoneal cavity. There is also subtle skin thickening .

**Hydrops**

Bowel Perforation

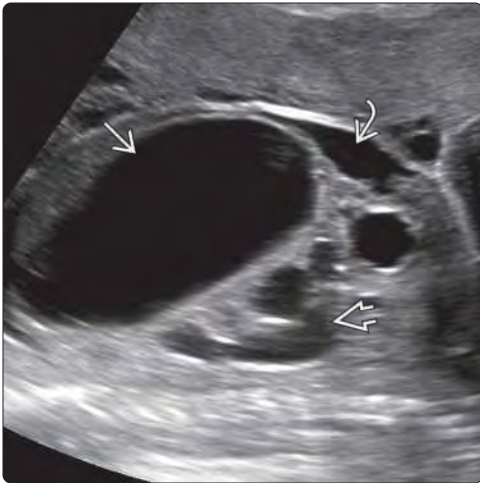


Bowel Perforation

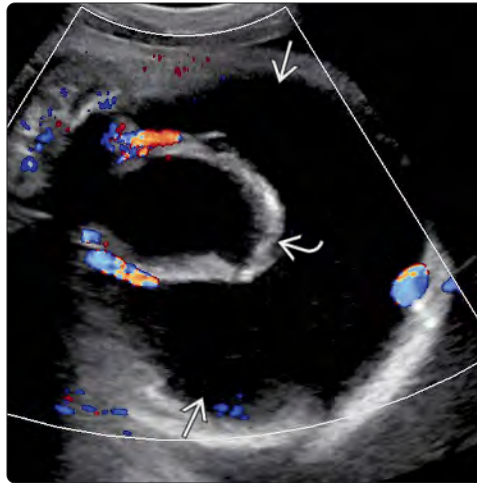


(Left) This oblique image through the abdomen shows bowel dilation from jejunal atresia. There are perihepatic calcifications and a small triangular fluid collection. **(Right)** A more detailed view in the same case shows definite free fluid next to the dilated loop of bowel. The ascites is from bowel perforation and this constellation of findings is pathognomonic for meconium peritonitis.

Urinary Ascites

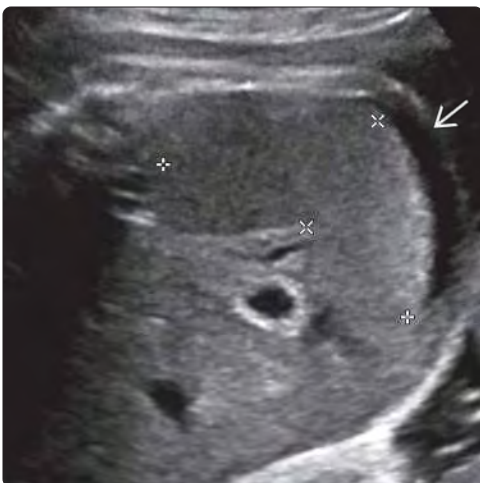

Urinary Ascites

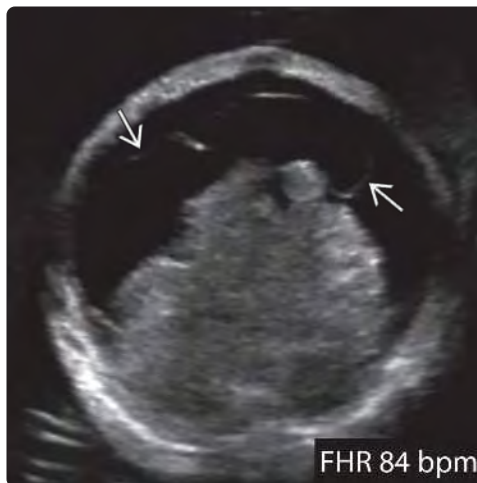


(Left) This midline sagittal image in a case of posterior urethral valves shows a massively dilated bladder and tortuous ureter. A small amount of urinary ascites is seen, the result of bladder perforation. **(Right)** This is a more severe case of urinary ascites from bladder perforation. The bladder is thick-walled from chronic obstruction and partially decompressed following rupture.

Infection



Arrhythmia



(Left) Hepatosplenomegaly is a prominent feature of fetal infection. In this case of syphilis, ascites is seen surrounding the markedly enlarged spleen (calipers). When considering infection, also look for intrahepatic and intracerebral calcifications. **(Right)** In this fetus with bradycardia, congenital cardiac anomaly and azygous continuation of the inferior vena cava, there is predominant ascites without overt hydrops. The ascites outlines the bowel and omentum.

DIFFERENTIAL DIAGNOSIS

Common

- **Urinary Tract**
 - Multicystic Dysplastic Kidney
 - Ureteropelvic Junction Obstruction
 - Lower Urinary Tract Obstruction
 - Urinoma
- **Gastrointestinal Tract**
 - Bowel Atresia
 - Meconium Pseudocyst

Less Common

- Ovarian Cyst
- Lymphangioma, Mesenteric Cyst
- Enteric Duplication Cyst

Rare but Important

- Choledochal Cyst
- Urachal Anomaly
- Neuroblastoma
- Splenic Cyst
- Fetus-in-Fetu, Teratoma
- Hydrocolpos
- Cloacal Malformation

ESSENTIAL INFORMATION

Key Differential Diagnosis Issues

- Can cystic mass be localized to normal structure?
 - Most abdominal cystic masses are from urinary tract
 - Gastrointestinal tract next most common
- Is it simple cyst or complex cystic mass?
 - Septations, internal echogenic debris
- What are wall characteristics?
 - Thin-walled, thick-walled, calcified, gut signature
- Is it constant or does it change appearance during exam, between exams?

Helpful Clues for Common Diagnoses

- **Multicystic Dysplastic Kidney**
 - Multiple cysts of varying sizes with no discernible renal parenchyma
 - Reniform shape is lost
 - Variable in utero course: May involute, remain stable, or grow
 - May be massive and cross midline
- **Ureteropelvic Junction Obstruction**
 - Look for communication with dilated calyces
 - Ends abruptly at ureteropelvic junction, no ureteral or bladder dilation
 - May present as large cyst with no remaining normal parenchyma if severe obstruction
- **Lower Urinary Tract Obstruction**
 - Posterior urethral valves most common cause
 - Look for keyhole appearance created by dilated posterior urethra
 - Prune-belly syndrome and urethral atresia less common
 - Ureteral dilation and hydronephrosis also commonly seen

- Megacystis is feature of trisomy 18; look for other anomalies

- **Urinoma**
 - Spontaneous rupture of renal collecting system into retroperitoneum
 - Look for contained fluid collection adjacent to obstructed kidney
- **Bowel Atresia**
 - Can occur anywhere along gastrointestinal tract
 - Has tubular, sausage-shaped appearance
 - Peristalsis within cystic mass is pathognomonic
- **Meconium Pseudocyst**
 - Wall-off bowel perforation
 - Irregular, thick walls
 - Look for other signs of meconium peritonitis
 - Intraperitoneal calcifications, dilated bowel, ascites

Helpful Clues for Less Common Diagnoses

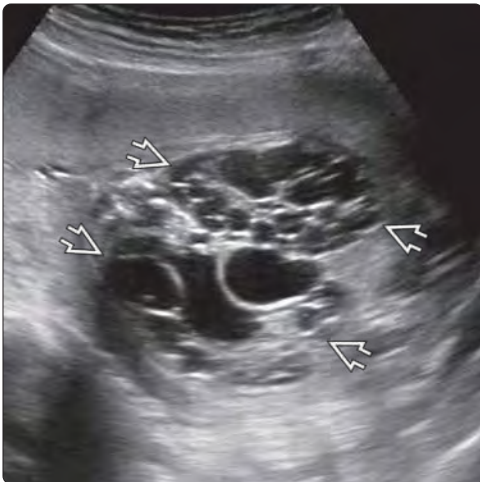- **Ovarian Cyst**
 - Top consideration for unilocular cyst in 3rd-trimester female fetus
 - Daughter cyst sign
 - Small cyst along wall of dominant cyst
 - Highly specific (up to 100%) sign for ovarian origin (82% sensitive)
 - May have occasional septations
 - If appearance becomes complex, with internal echoes, then there is concern for torsion
 - Occasionally found in upper abdomen
 - Supporting ligaments are lax, allowing for displacement
 - May occasionally be bilateral
- **Lymphangioma, Mesenteric Cyst**
 - Thin-walled cystic mass
 - May be unilocular or multilocular, with 1 or multiple septations
 - Can be very complex, insinuating around organs and extending out of abdomen
 - Variable echogenicity of fluid, but usually anechoic
- **Enteric Duplication Cyst**
 - Solitary, thick-walled cyst
 - Look for gut signature
 - Layered appearance with echogenic mucosa, hypoechoic muscular layer, echogenic serosa
 - Often difficult to see in utero
 - Rarely may cause bowel obstruction

Helpful Clues for Rare Diagnoses

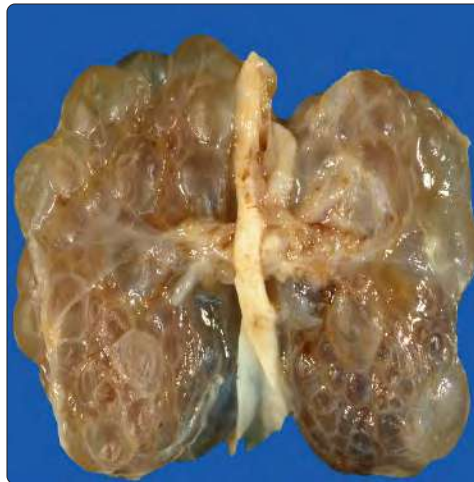
- **Choledochal Cyst**
 - Cystic dilatation of extrahepatic &/or intrahepatic bile ducts
 - Unilocular, simple, right upper quadrant cyst is most common presentation in fetus
 - Round in axial plane and fusiform in longitudinal plane
 - Following bile ducts into cyst confirms diagnosis
- **Urachal Anomaly**
 - Includes isolated cysts and patent urachus
 - Communication with bladder confirms patent urachus
 - Bladder may appear elongated with figure 8 or waisted configuration
 - May extend into base of umbilical cord

- Associated with allantoic cord cysts
- o May resolve as gestation progresses
- **Neuroblastoma**
 - o Arises from adrenal gland
 - o ~ 50% are cystic
 - o Complex appearance with thick septations
 - o Cystic neuroblastoma has excellent prognosis
- **Splenic Cyst**
 - o Incidental finding of no clinical significance
 - o If posterior to stomach may appear as cystic suprarenal mass and be confused with cystic neuroblastoma
 - o Use high-frequency transducer to confirm location in splenic parenchyma
- **Fetus-in-Fetu, Teratoma**
 - o Overlapping features between these 2 entities
 - Fetus-in-fetu more developed and must have spinal elements
 - o Complex, with large solid component encapsulated within cyst
 - o Calcifications, including well-formed bones, most specific finding
- o Majority reported in upper retroperitoneum
- o Fetus-in-fetu thought to result from inclusion of monochorionic diamniotic twin within host twin
- **Hydrocolpos**
 - o Cystic mass (distended vagina) posterior to bladder
 - o Vagina not septated as in cloacal malformation
 - o Normal external genitalia
- **Cloacal Malformation**
 - o In classic cloaca the bladder, vagina, and rectum all communicate with single perineal opening
 - o Vagina duplicated in percentage creating longitudinally septated mass
 - o Fluid-fluid levels from mixing of meconium, vaginal secretions, and urine
 - o Abnormal genitalia with lack of normal labial/clitoral formation; absent anal dimple
 - o Hydronephrosis and lumbosacral anomalies may also be present
 - o Ascites reported in some cases from retrograde flow through fallopian tubes

Multicystic Dysplastic Kidney

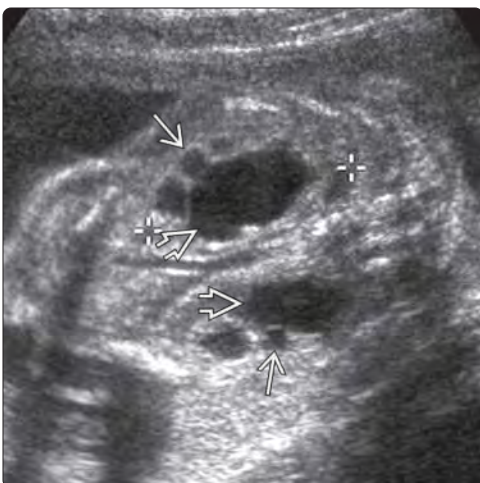


Multicystic Dysplastic Kidney

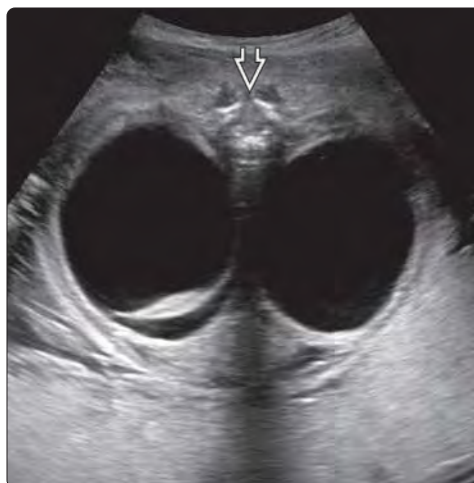

(Left) Multicystic dysplastic kidneys are often very large and filled with cysts of varying size. When bilateral, as in this case, there is anhydramnios. Note the kidneys fill the abdomen and can enlarge the abdominal circumference. (Right) This gross specimen shows the kidneys are completely replaced by cysts, with no normal remaining parenchyma. (From DP: Kidney, 2e.)

Ureteropelvic Junction Obstruction



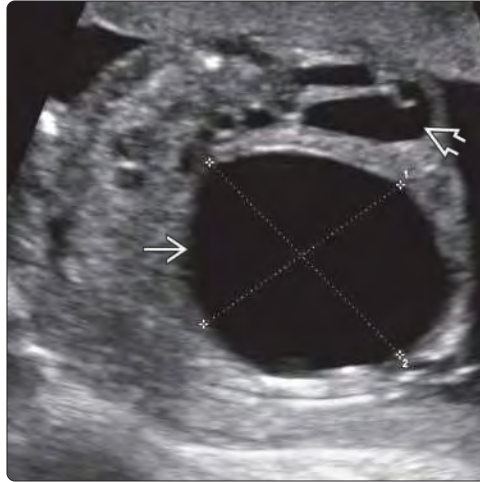
Ureteropelvic Junction Obstruction



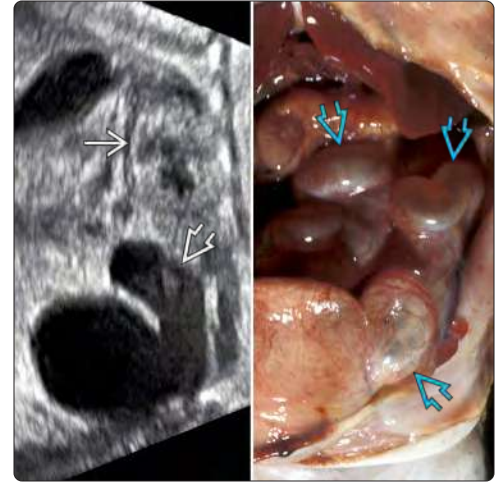
(Left) Coronal US shows classic bilateral ureteropelvic junction (UPJ) obstruction in a 2nd-trimester fetus. The dilated calyces are in communication with the renal pelvises. (Right) This case is also of bilateral UPJ obstructions. When the obstruction is complete, the normal anatomy is lost. A clue that these large "cysts" are actually related to the kidneys is their posterior location adjacent to the spine.

Lower Urinary Tract Obstruction

(Left) This US through the abdomen of a fetus with prune-belly syndrome shows a dramatically enlarged bladder and ureterectasis. (Right) Oblique sagittal US shows a portion of the massively dilated ureter (note the small echogenic kidney). This is also shown on the autopsy image where the ureter is seen "snaking" through the abdomen. This can be confused with dilated bowel on US, but urine should be anechoic and there should be no peristalsis.

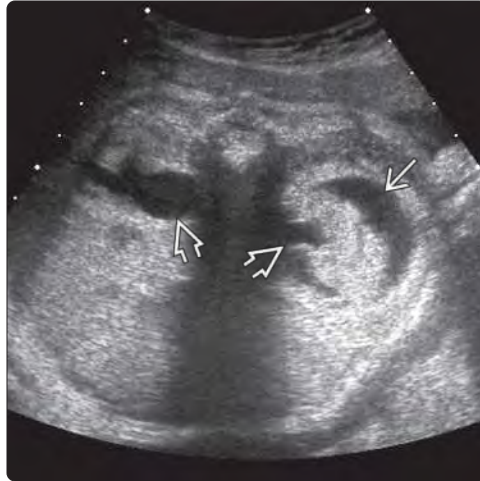

Lower Urinary Tract Obstruction

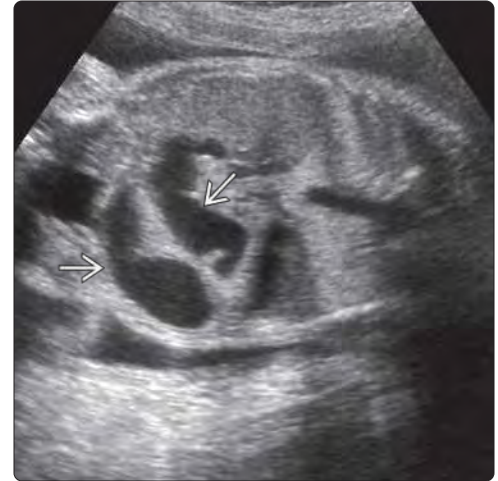

Urinoma

(Left) Axial US shows a fetus with bilateral UPJ obstruction. There was a unilateral collecting system rupture, partially decompressing the left collecting system. Urine is collecting in the perirenal space. Note how the fluid is surrounding and compressing the kidney, classic features of a urinoma. (Right) Coronal US shows a tubular, cystic mass in a fetus with jejunal atresia. Seeing peristalsis confirms that a cystic mass is actually dilated bowel.

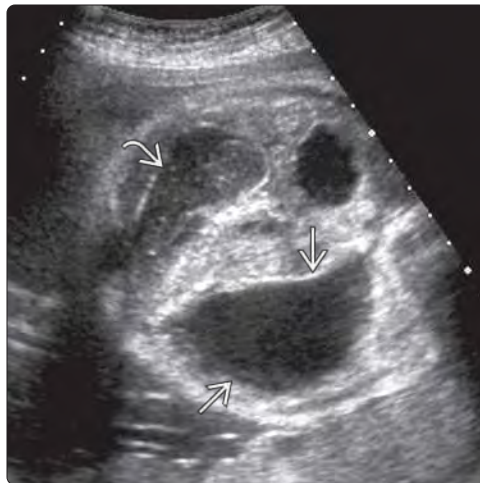


Bowel Atresia

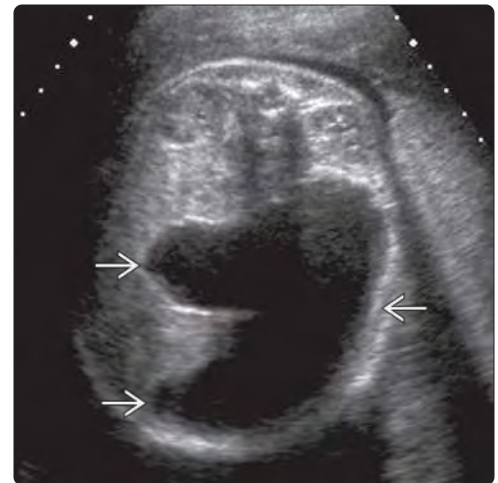

Meconium Pseudocyst

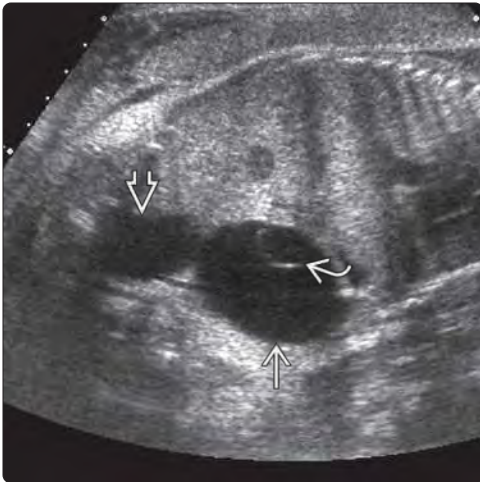
(Left) Axial US shows a dilated loop of bowel filled with echogenic material. There has been an in utero perforation with formation of a large, irregular, thick-walled meconium pseudocyst. (Right) Axial US shows a large, irregular cystic mass distending the abdomen. Note the thick, echogenic walls. Surgery confirmed an ileal atresia with perforation, complicated by meconium peritonitis and pseudocyst formation. Pseudocysts will often have an irregular, angular contour.



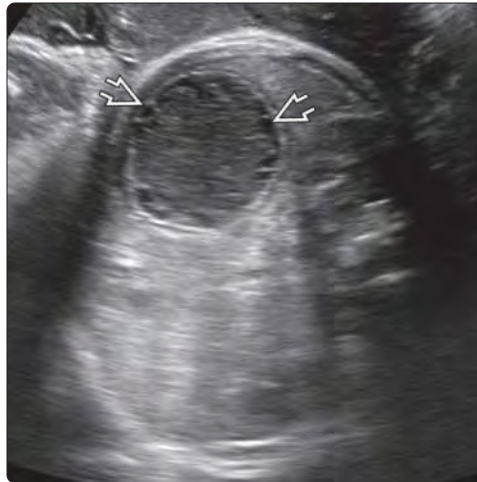
Meconium Pseudocyst



Ovarian Cyst

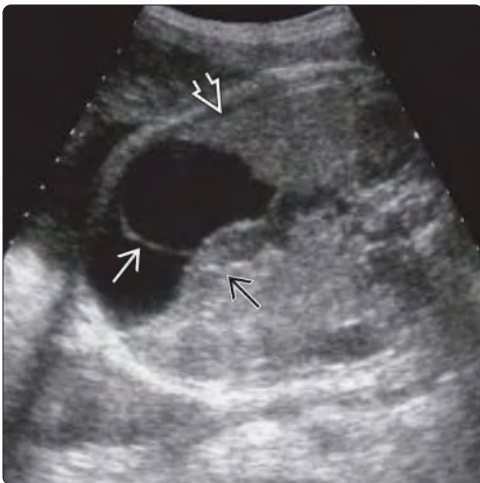


Ovarian Cyst

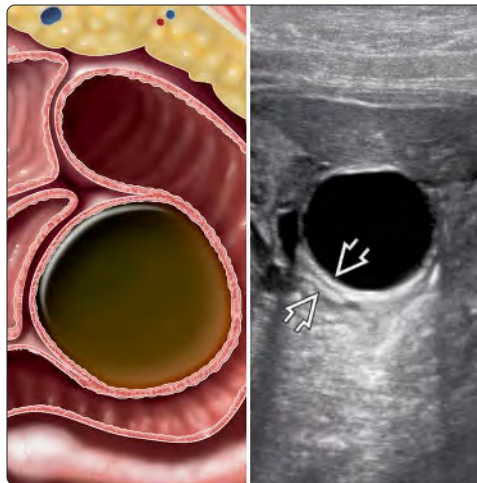


(Left) Coronal US in a female fetus shows a large cyst above the bladder. Note the small daughter cyst along the wall. This sign is highly specific for an ovarian cyst. (Right) When an ovarian cyst becomes complicated in appearance, there is a concern for either hemorrhage or torsion. In this case, there are small peripheral cysts with an echogenic central stroma, a feature seen with torsion.

Lymphangioma, Mesenteric Cyst

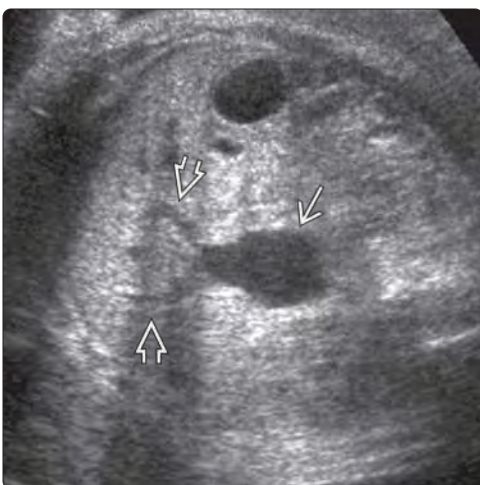


Enteric Duplication Cyst

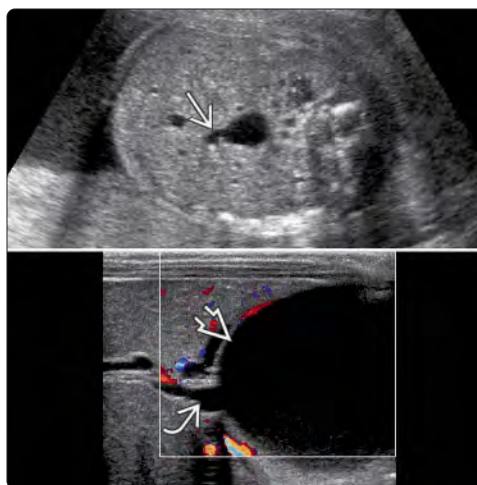


(Left) Axial oblique US shows a septation within a thin-walled abdominal cyst. The cyst is insinuated between the liver and colon. The appearance of mesenteric lymphangiomas is quite variable, ranging from a unilocular cyst to a large complex mass. (Right) An enteric duplication cyst is either round or oval and has a thick, well-defined wall. Use a high-frequency transducer to look for a trilaminar gut signature with a hyperechoic mucosa, hypoechoic muscular wall, and hyperechoic serosa.

Choledochal Cyst









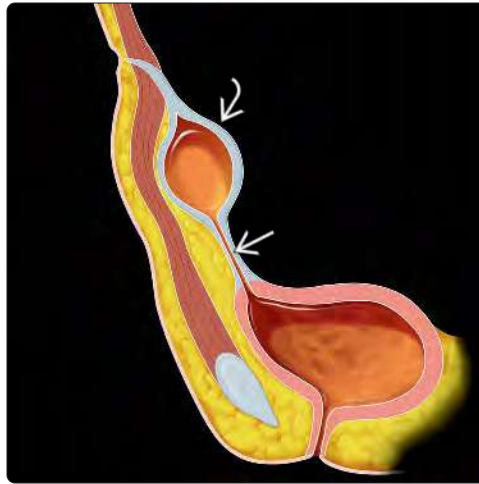Choledochal Cyst



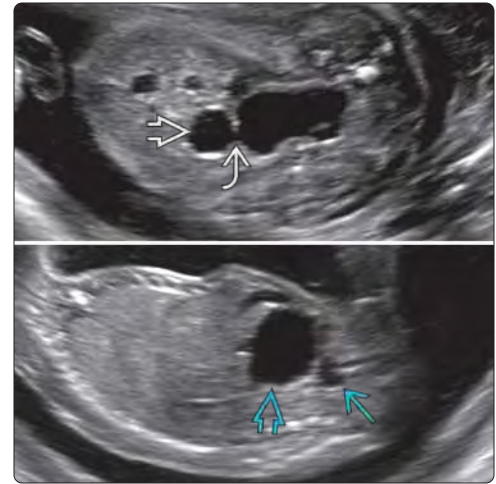
(Left) Coronal oblique US shows the bile ducts exiting the liver and entering the dilated common bile duct. Fusiform dilation is the most common fetal presentation of a choledochal cyst. Bile ducts entering a right upper quadrant cyst confirms the diagnosis. (Right) On the prenatal exam (upper), a cyst was noted in the upper abdomen. A small tubular structure, felt to be a bile duct, could be seen contiguous with it. The postnatal exam confirms the dilated bile duct and choledochal cyst.

Urachal Anomaly




(Left) If the midportion of the urachus involutes, a cyst can form . If a connection remains , urine can pass between the bladder and cyst. During real-time evaluation, the cyst may increase in size when the bladder contracts during voiding, sending urine into the cyst. **(Right)** Oblique coronal US (top) shows a midline cyst  with an apparent connection  to the bladder. A sagittal US later in the exam (bottom) shows the bladder is decompressed  and the cyst  has gotten larger, confirming the suspicion of a patent urachus.

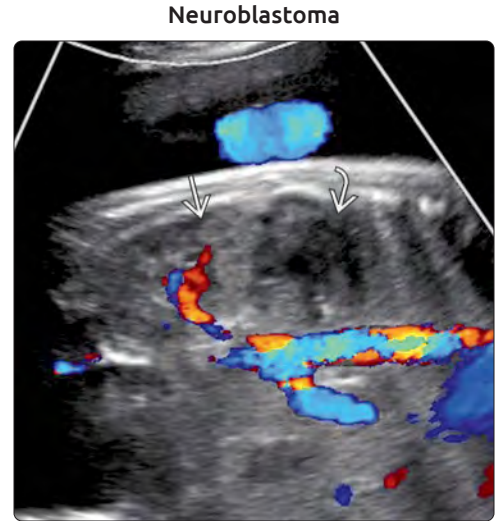
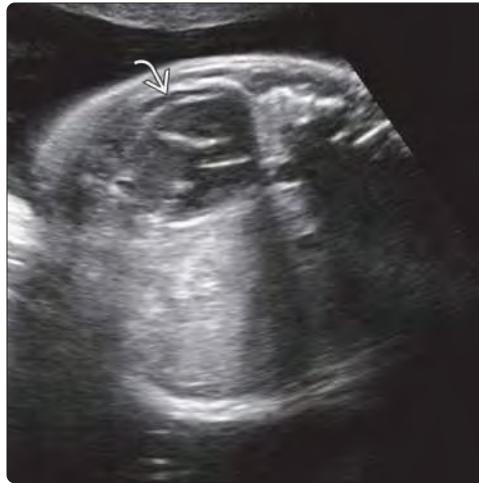

Urachal Anomaly





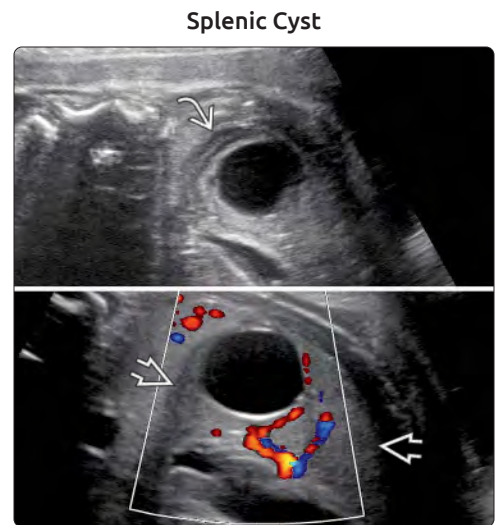
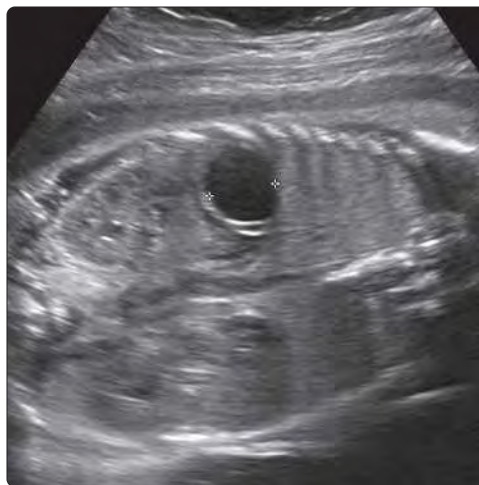
Neuroblastoma

(Left) Axial scan through the upper abdomen shows a complex cystic mass . **(Right)** Scanning in a coronal plane shows that the mass  is suprarenal, pushing the kidney  inferiorly. Given this cyst was suprarenal, an adrenal hemorrhage was also considered in the differential, but it remained unchanged. Adrenal hemorrhage should change appearance and decrease in size with involution. Neuroblastoma was confirmed postnatally.

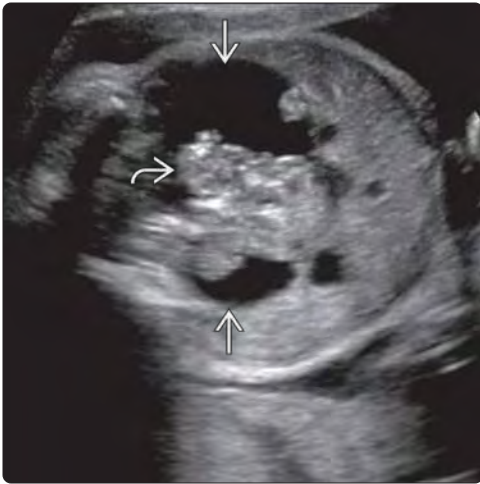

Splenic Cyst

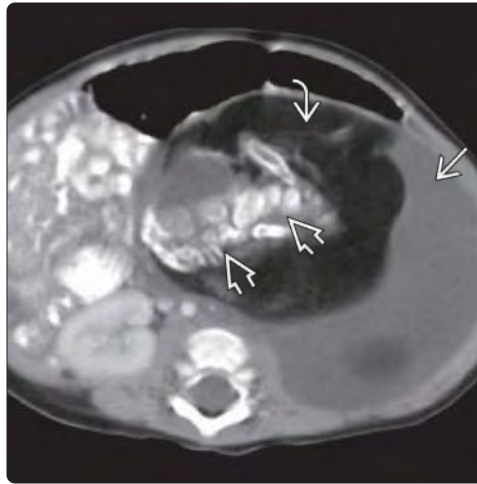
(Left) This fetus presented at 22 weeks with a left-sided suprarenal cyst that was simple in appearance. A cystic neuroblastoma was initially considered in the differential. **(Right)** A follow-up scan 1 month later, using a high-frequency transducer, clearly shows the cyst is separate from the normal adrenal gland  and is located within the spleen . Splenic cysts are benign and of no clinical significance.



Fetus-in-Fetu, Teratoma

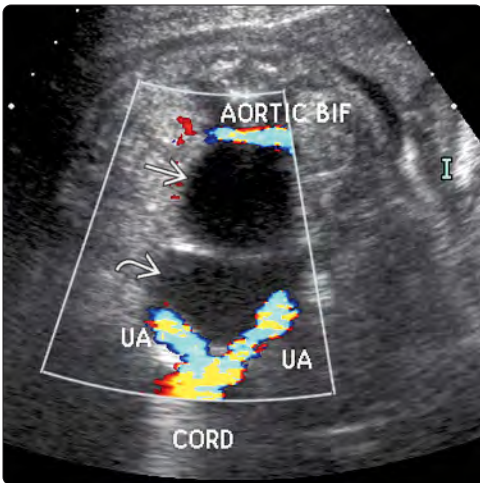


Fetus-in-Fetu, Teratoma

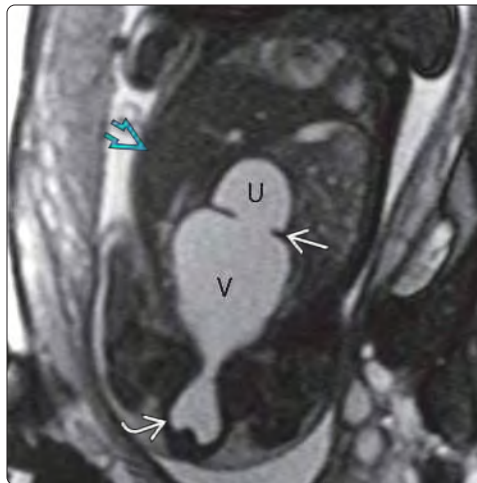


(Left) Axial US shows a cystic mass with a large, central, solid component. Calcifications were also present. Resection after delivery showed a teratoma. (Right) CECT in a newborn shows a complex mass within the left upper quadrant containing fluid, fat, and a well-differentiated spine. This meets the strict criteria for a fetus-in-fetu, which is felt to result from an aberration in monozygotic twinning.

Hydrocolpos

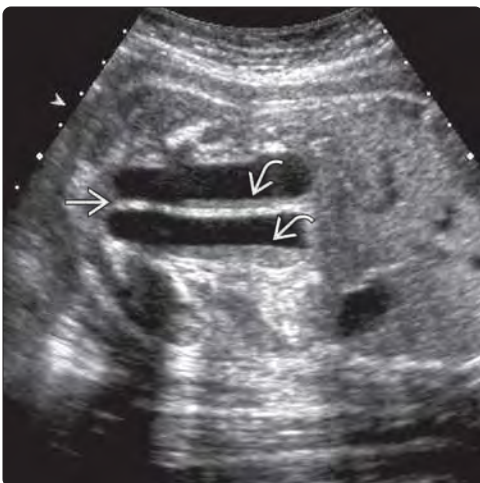


Hydrocolpos

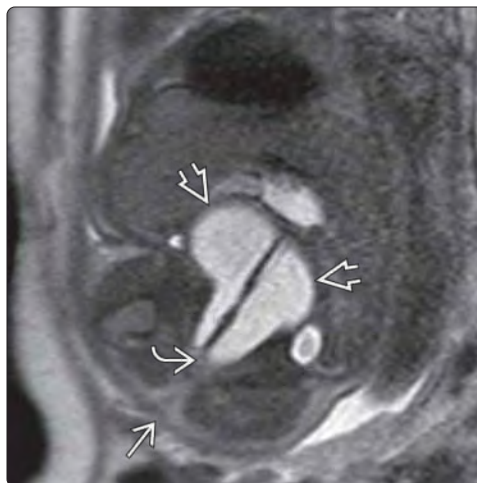


(Left) Axial US shows a unilocular, anechoic cystic mass posterior to the normal bladder representing an obstructed vagina filled with uterine and vaginal secretions. (Right) Coronal T2 MR in the same patient shows the markedly distended vagina (V) and uterus (U) extending up the level of the liver. The cervix is open and the distal vagina bulges at the perineum. This was shown to be hydrocolpos secondary to an imperforate hymen discovered at delivery.

Cloacal Malformation



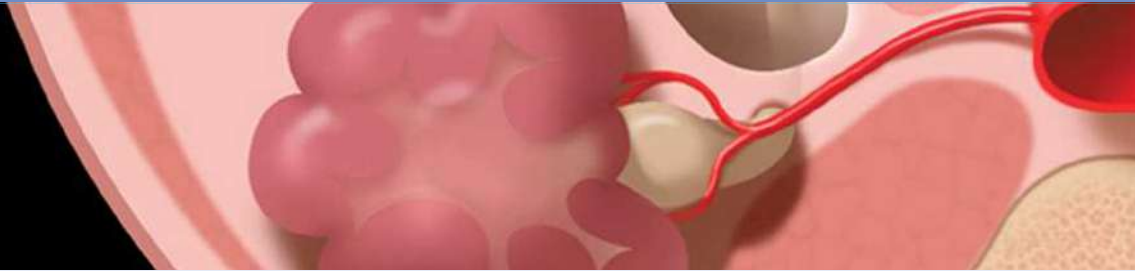
Cloacal Malformation



(Left) Coronal US shows fluid-fluid levels representing layering debris in obstructed, duplicated vaginas (note the linear septum). Debris results from the mixing of urine with vaginal secretions ± meconium. (Right) Coronal T2 MR shows duplicated vaginas with tapering to an obstruction within the pelvis. Note the relationship to the perineum, suggesting a relatively high obstruction. Oligohydramnios, a common associated finding, is present.

SECTION 8

Genitourinary Tract



Introduction and Overview

Embryology and Anatomy of the Genitourinary Tract	570
Approach to the Fetal Genitourinary Tract	580
Urinary Tract Dilation	584

Renal Developmental Variants

Unilateral Renal Agenesis	588
Duplicated Collecting System	590
Pelvic Kidney	594
Horseshoe Kidney	596
Crossed Fused Ectopia	598

Renal Malformations

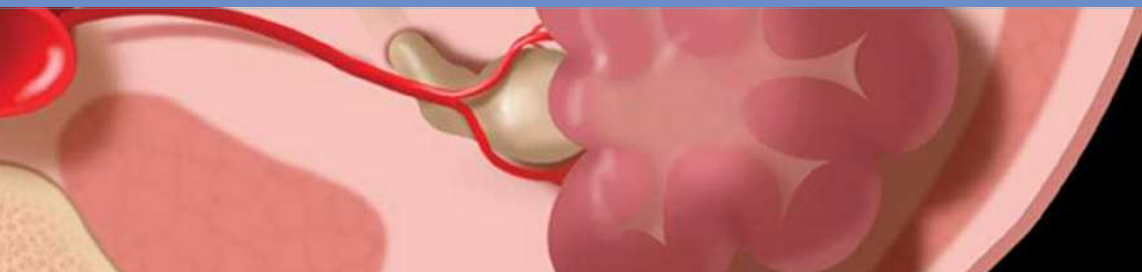Bilateral Renal Agenesis	600
Ureteropelvic Junction Obstruction	604
Urinoma	608
Obstructive Renal Dysplasia	610
Multicystic Dysplastic Kidney	614
Autosomal Recessive Polycystic Kidney Disease	618
Mesoblastic Nephroma	622

Adrenal Abnormalities

Adrenal Hemorrhage	626
Neuroblastoma	628
Congenital Adrenal Hyperplasia	632

Bladder Malformations

Posterior Urethral Valves	634
Prune-Belly Syndrome	638
Ureterocele	642
Urachal Anomalies	646



Genital Abnormalities

Disorders of Sexual Development	650
Hypospadias	656
Ovarian Cyst	658
Hydrocolpos	662

Pertinent Differential Diagnoses

Hydronephrosis	664
Echogenic Kidneys	668
Unilateral Enlarged Kidney	670
Suprarenal Mass	674
Scrotal Mass	676

DEVELOPMENT OF URINARY TRACT**Kidney Formation**

- Stages of development similar to those found in more primitive animals (e.g., invertebrates, amphibians)
 - Reflects evolutionary history
- **3 successive nephric structures** of increasing advanced design: **Pronephroi, mesonephroi, metanephroi** (pronephros, mesonephros, metanephros singular form)
 - **Structures develop and regress in craniocaudal sequence**
- Nonfunctional, primitive **nephrotomes** develop in cervical region
 - Vestige of **pronephroi**, which form primitive kidney in lower vertebrates
 - Regress by 4th week and are replaced by mesonephroi
- **Mesonephroi** are elongated functional primitive kidneys, which develop from upper thoracic to 3rd lumbar level
- **Mesonephric (wolffian) ducts** 1st appear at 24 days dorsolateral to mesonephroi in thoracic region
 - Grow caudally and fuse with ventrolateral wall of bladder
 - Mesonephric ducts connect to, and drain urine from, mesonephric tubules
- After 10 weeks, mesonephric tubules cease to function and regress
 - Mesonephric ducts also regress in females but persist in males to form part of genital tract
- **Ureteric bud** (also called metanephric diverticulum) sprouts from distal mesonephric duct
 - Induces sacral mesoderm (**metanephric blastema**) to develop into **metanephroi**, definitive kidneys
 - Ureteric bud and metanephric blastema exert reciprocal inductive effects on each other
 - Ureteric bud induces metanephric blastema to form nephrons
 - In turn, metanephric blastema induces ureteric bud to bifurcate into developing calyces
- Anomalies resulting in failure of ureteric bud to interact appropriately with metanephric blastema
 - **Renal agenesis**
 - Failure of ureteric bud to come into contact with metanephric blastema
 - **Multicystic dysplastic kidney** (proposed mechanisms)
 - Ureteric bud does not appropriately signal metanephros, leading to abnormal collecting duct development with loss of nephrons, stromal expansion, and cyst formation
 - Very early ureter obstruction leads to dysplasia (metanephric tissue does not form nephrons)

Renal Ascent

- Initially, kidneys (metanephroi) lie close together low in pelvis, with renal hila facing anteriorly
- Mechanism for "ascent" to final retroperitoneal flank position is not completely understood, but caudal embryonic growth is likely major contributing factor
- Blood supply changes as kidneys successively "recruit" arterial blood supply from iliac arteries and aorta
 - New, more superior arterial branches form as inferior branches involute
- With ascent, renal pelves rotate medially ~ 90°

- Ascent complete by 9 weeks when kidneys come into contact with adrenal glands
- Anomalies related to abnormal "ascent"
 - **Renal ectopia**
 - Kidney usually low in position with abnormal rotation
 - **Crossed fused ectopia and other fusion abnormalities**
 - Fusion of metanephroi prior to ascent leads to various appearances
 - **Horseshoe kidney**
 - Inferior poles of 2 metanephroi fuse
 - Become "stuck" under inferior mesenteric artery
 - **Accessory renal arteries**
 - Persistence of normally transient renal arteries during ascent

Bladder

- **Cloaca** (Latin for sewer) is common chamber with early communication between urinary, gastrointestinal, and reproductive tracts
 - Divided by **urorectal septum** into **urogenital sinus** anteriorly and **anorectum** posteriorly
 - Both structures open through perineum upon rupture of cloacal membrane
- **Urogenital sinus has 3 major components**
 - **Allantois** is cephalad portion
 - Extends from bladder to connecting stalk of yolk sac
 - Intraabdominal portion involutes to become **urachus**; in adult, this is **median umbilical ligament**
 - Middle vesicular portion becomes **urinary bladder**
 - Caudal portion forms **lower vagina** in females and **penile urethra** in males
- Distal portions of mesonephric ducts and attached ureteric ducts become incorporated into posterior bladder
 - During this process, **ureters are incorporated superiorly** in trigone
 - Orifices of **mesonephric ducts move inferomedially** and enter prostatic urethra, forming ejaculatory ducts

DEVELOPMENT OF ADRENAL GLANDS**Cortex and Medulla**

- Cortex and medulla derive from 2 different tissues
 - **Cortex**
 - Forms from mesoderm
 - 3 zones: **Glomerulosa, fasciculata, and reticularis**
 - Only glomerulosa and fasciculata present at birth
 - Reticularis not recognizable until 3rd year of life
 - **Medulla**
 - Forms from neural crest cells derived from sympathetic ganglion
- **Fetal adrenal glands 10-20x larger** than adult adrenal glands relative to body size
 - May be mistaken for fetal kidneys, especially early in pregnancy
 - May potentially miss renal agenesis before oligohydramnios has developed
 - Large size is from adrenal cortex
 - Rapidly become smaller as cortex regresses in 1st year of life

DEVELOPMENT OF MALE GENITAL TRACT

Mesonephric (Wolffian) Ducts

- Persist in males to form part of genital tract
 - Epididymis
 - Vas deferens
 - Seminal vesicles
 - Ejaculatory ducts

Testes

- Form from genital ridges, which extend from T6-S2 in embryo
- **Composed of 3 cell lines**, which form primitive sex cord
 - Germ cells
 - Sertoli cells
 - Leydig cells
- **Germ cells**
 - Form in wall of yolk sac and migrate along hindgut to genital ridges
 - Form spermatogenic cells in mature testes
- **Sertoli cells**
 - **Secrete müllerian inhibiting factor**
 - Causes paramesonephric (müllerian) ducts to regress
 - In adult, form supporting network for developing spermatozoa
 - Form tight junctions (blood-testis barrier)
- **Leydig cells**
 - **Principal source of testosterone production**
 - Lie within interstitium
 - Causes differentiation of mesonephric (wolffian) ducts into male genital tract

Scrotum

- Derived from **labioscrotal folds**
 - Folds swell under influence of testosterone to form twin scrotal sacs
 - Point of fusion is **median raphe**
 - Extends from anus, along perineum to ventral surface of penis
 - **Processus vaginalis**, sock-like evagination of peritoneum, elongates through abdominal wall into twin sacs
 - Forms anterior to developing testes
 - Aids in descent of testes, along with **gubernaculum** (ligamentous cord extending from testis to labioscrotal fold)

Testicular Descent

- Between 7th-12th week of gestation, testes descend into pelvis
 - Testes are retroperitoneal throughout their descent and are intimately associated with posterior wall of processus vaginalis
 - Remain near internal inguinal ring until 7th month, when they begin descent through inguinal canal into twin scrotal sacs
- **Component layers of spermatic cord and scrotum** formed during descent through abdominal wall
 - Transversalis fascia → internal spermatic fascia
 - Internal oblique muscle → cremasteric muscle and fascia
 - External oblique muscle → external spermatic fascia

- Dartos muscle and fascia embedded in loose areolar tissue below skin
- Processus vaginalis closes and forms tunica vaginalis
- **Cryptorchidism** results from incomplete descent

Prostate

- In 10th week, endodermal evaginations bud from prostatic portion of urethra and develop into prostatic cords
- Under increasing levels of testosterone, these cords develop into glandular acini
- Rest of gland forms from surrounding mesenchyme, which differentiates into stroma and smooth muscle

DEVELOPMENT OF FEMALE GENITAL TRACT

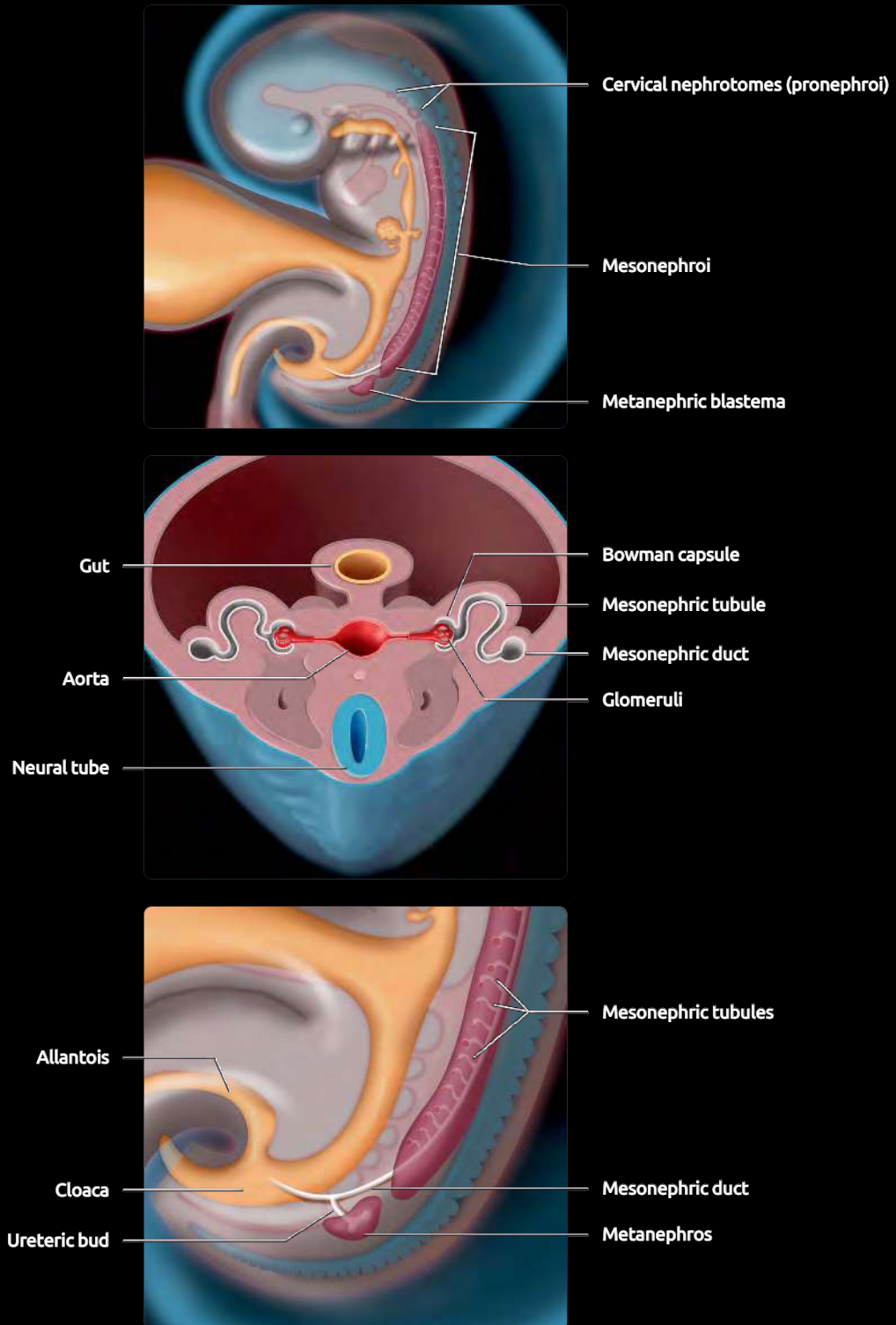
Ovaries

- Male and female gonadal development identical through 7th week
- In **absence of testis determining factor** from Y chromosome, ovaries will develop
- Primitive sex cords degenerate and mesothelium of genital ridges form secondary sex cords
- **Secondary sex cords** invest primordial germ cells to form follicle cells
 - **Germ cells undergo 1st meiotic division** but further development arrested until puberty
- Like testis, ovaries also descend with help from gubernaculum

Uterus

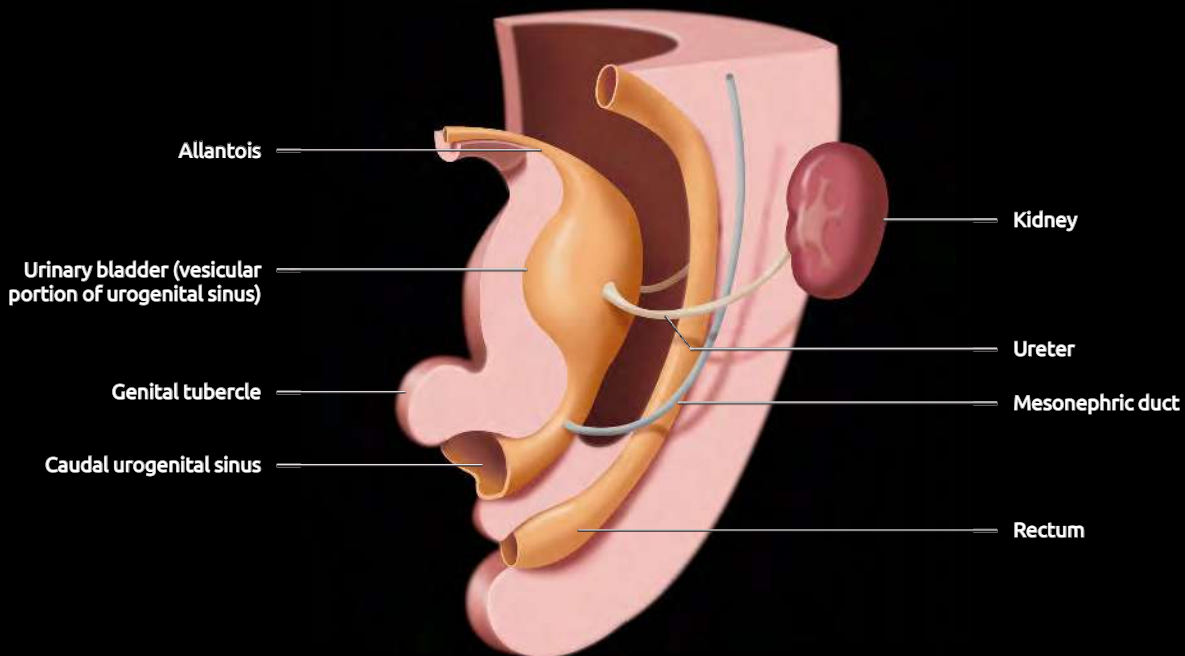
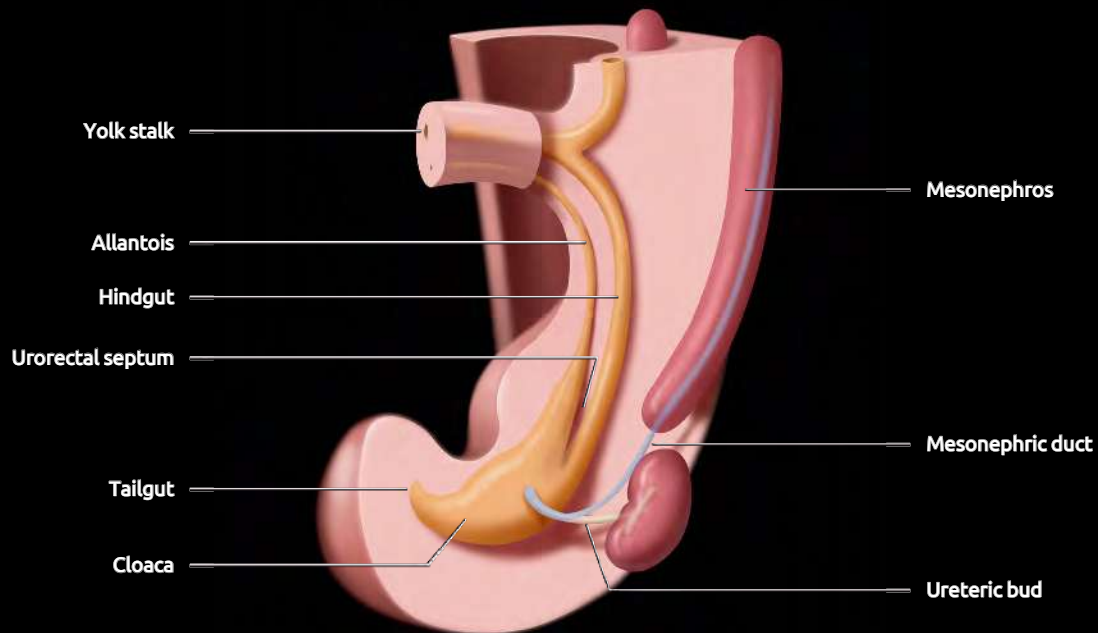
- Formed from paired **paramesonephric (müllerian) ducts**
- Paramesonephric ducts form lateral to mesonephric ducts
 - Join with urogenital sinus medial to mesonephric ducts
 - In absence of Y chromosome, paramesonephric ducts will continue to develop and form uterus
- These paired paramesonephric ducts fuse in midline
 - Fusion forms **uterovaginal canal**, becoming uterus and upper vagina
 - Unfused portions remain as **fallopian tubes**
- **Lower vagina formed from urogenital sinus**
- Failure of müllerian duct development &/or fusion leads to spectrum of **congenital uterine anomalies**
 - Class I: Agenesis or hypoplasia
 - Class II: Unicornuate uterus
 - Single uterine horn, may have accessory rudimentary horn
 - Class III: Uterus didelphys
 - 2 separate, noncommunicating horns
 - Class IV: Bicornuate uterus
 - Concave or heart-shaped external uterine contour
 - Class V: Septate uterus
 - Normal external contour
- Müllerian duct anomalies and renal anomalies are commonly associated
 - If fetal renal anomaly is seen, consider performing postnatal pelvic ultrasound
 - Uterus is often well seen in immediate neonatal period

KIDNEY DEVELOPMENT



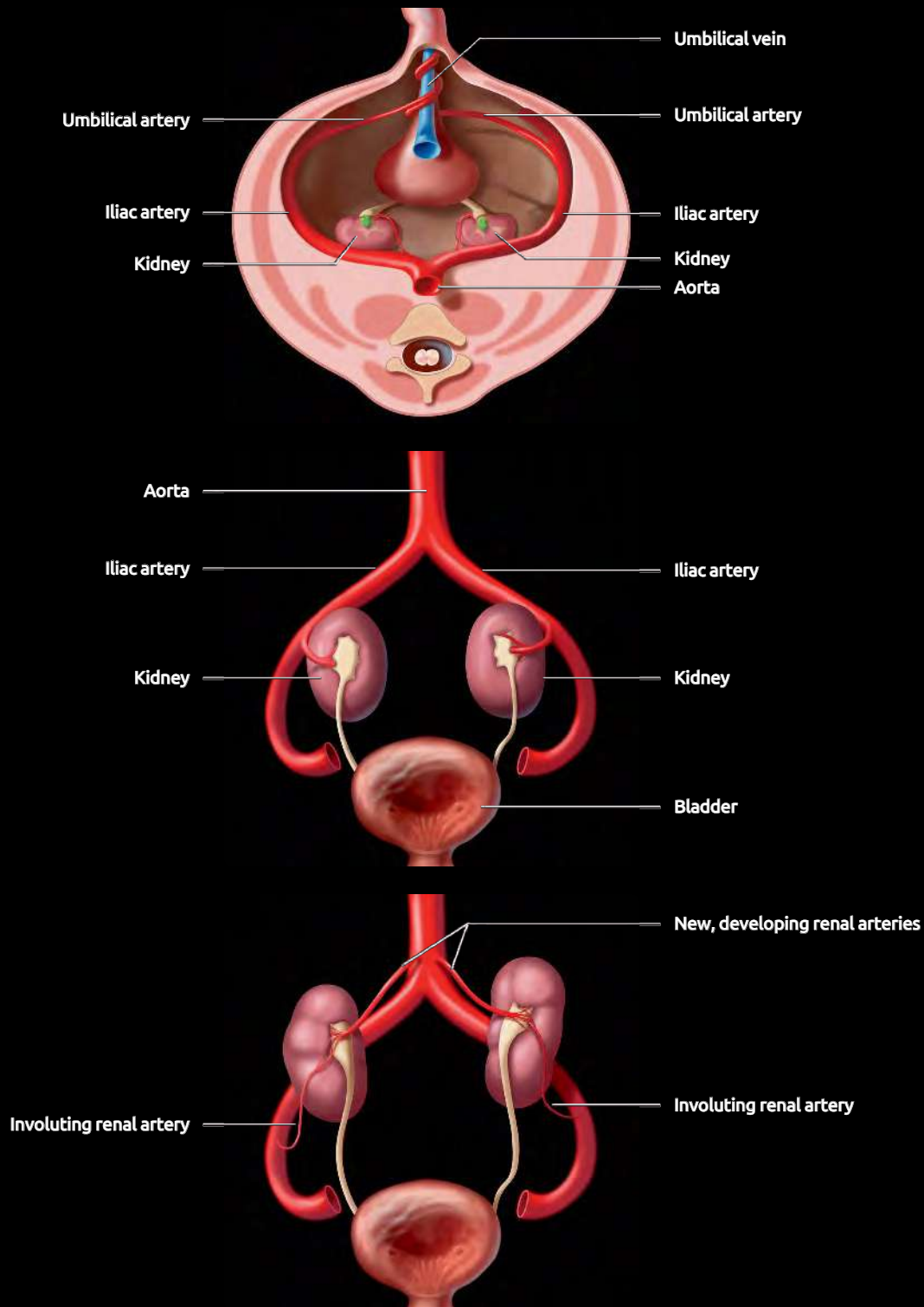
(Top) Three sets of nephric structures develop in human embryos. They form and regress in a craniocaudal progression. The pronephroi are transitory and nonfunctional. The mesonephroi also degenerate, although the distal mesonephric duct will persist in males and form part of the genital tract. **(Middle)** Cross section of the embryo shows the mesonephroi. By the 4th fetal week, the mesonephric tubules and duct are formed. Branched vessels from the aorta reach the blind ends of the tubules to form glomeruli. Although these achieve an excretory function in the human embryo, they degenerate as the metanephroi form. **(Bottom)** The 3rd, and definitive, kidney is formed when the ureteric bud induces the metanephric blastema to form the metanephros.

BLADDER DEVELOPMENT



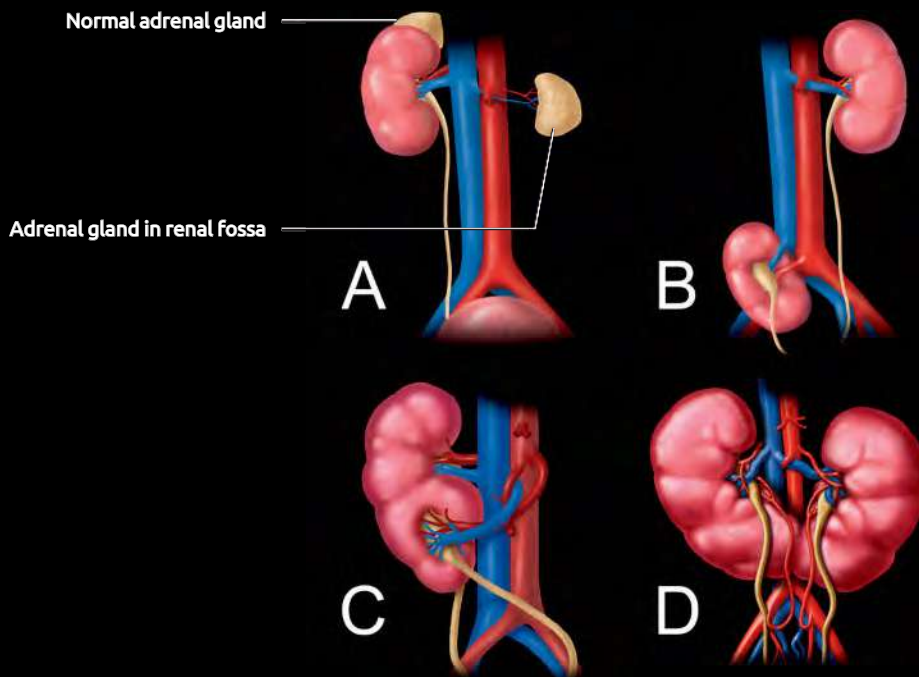
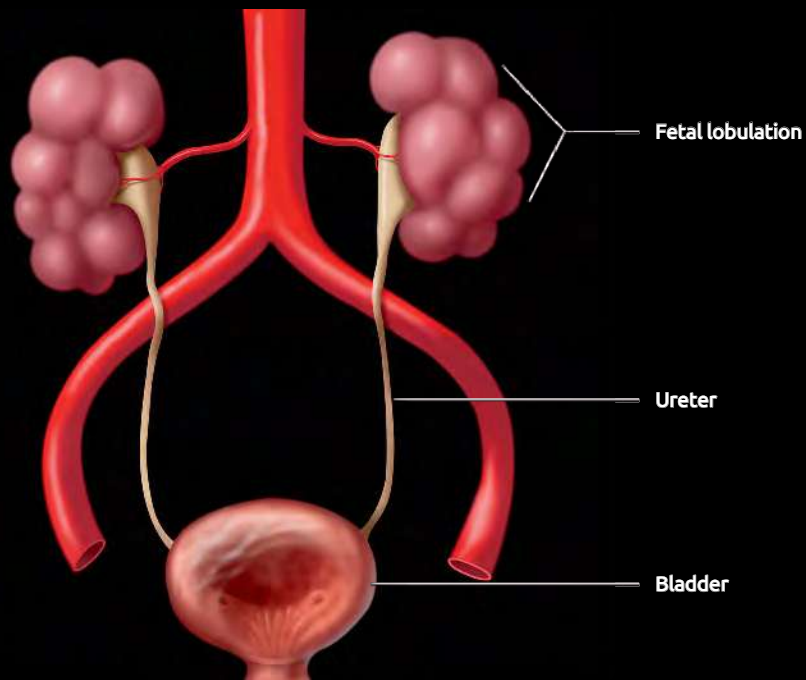
(Top) The cloaca is a common chamber with early communication between the urinary, gastrointestinal, and reproductive tracts. Between 4-6 weeks, the urorectal septum will separate the urogenital sinus anteriorly from the rectum posteriorly. **(Bottom)** The largest vesicular portion of the urogenital sinus forms the bladder. It is in direct continuity with the allantois superiorly. The allantois will eventually involute to form the urachus. The caudal portion of the urogenital sinus will form the lower portion of the vagina in females and the penile urethra in males. The ureteric buds are incorporated into the posterior bladder forming the upper portion of the trigone, while the mesonephric ducts migrate inferomedially and will ultimately insert into the prostatic urethra as the ejaculatory ducts.

RENAL ASCENT



(Top) Graphic looking down from above shows the kidneys low in the fetal pelvis. The definitive kidneys form from specialized sacral mesoderm called the metanephric blastema. Please note that while the umbilical vein carries oxygenated blood, for this set of graphics, veins will be depicted in blue and arteries in red. **(Middle)** The kidneys are located close together and may even be in direct continuity, leading to various anomalies of fusion. The kidneys face forward with the renal pelvis directed anteriorly. When initially formed, the arterial supply is from the iliac arteries. **(Bottom)** With ascent, the more inferior renal arteries regress, while more superior ones are recruited.

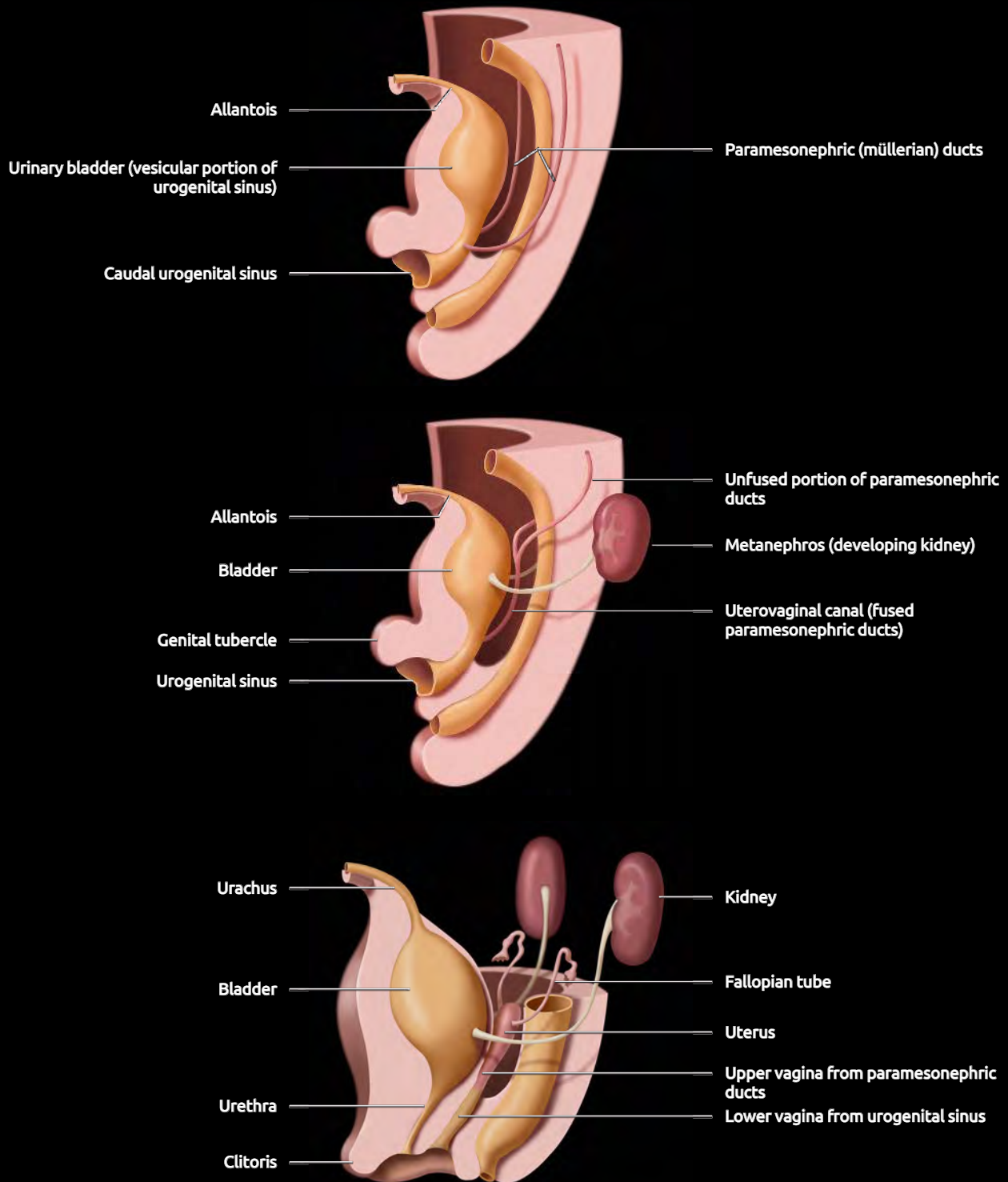
RENAL ASCENT



(Top) Normally, each kidney will be left with a single main renal artery. Accessory renal arteries, a common anatomic variant, are from failure of involution of transient arteries during ascent. The fetal kidneys have a distinct lobular contour (fetal lobulation), reflecting the developmental process between the ureteric bud forming the calyces and the metanephric blastema forming the nephrons.

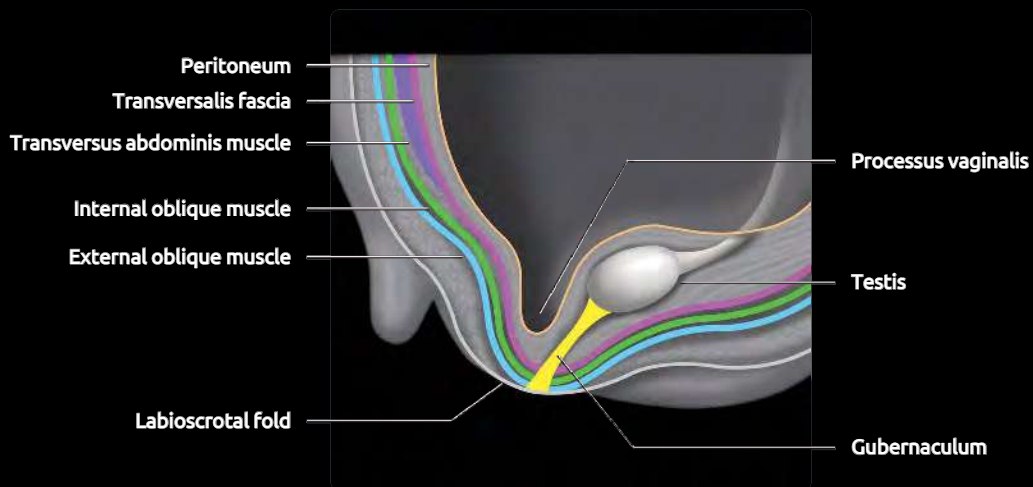
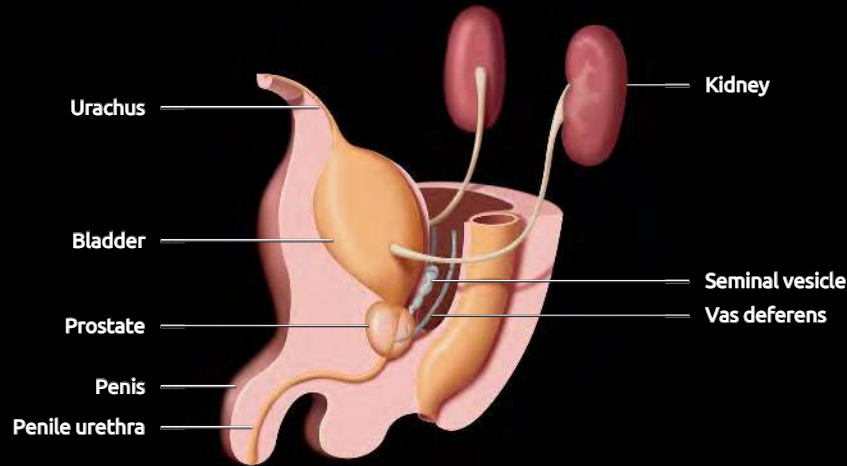
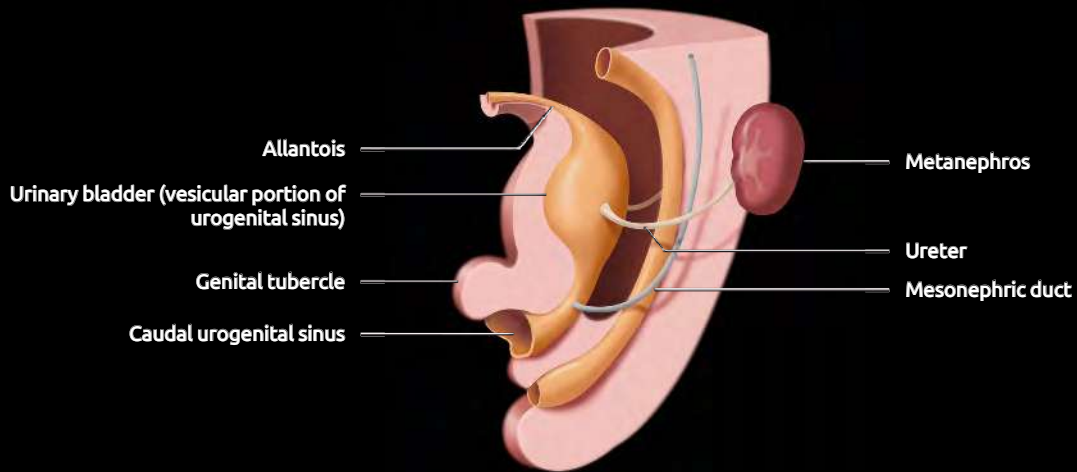
(Bottom) Aberration in the development and ascent of the kidneys causes an array of anomalies. Renal developmental variants include unilateral renal agenesis (A), pelvic kidney (B), crossed fused renal ectopia (C), and horseshoe kidney (D). Errors of formation, fusion, and ascent lead to these anomalies.

FEMALE GENITAL TRACT



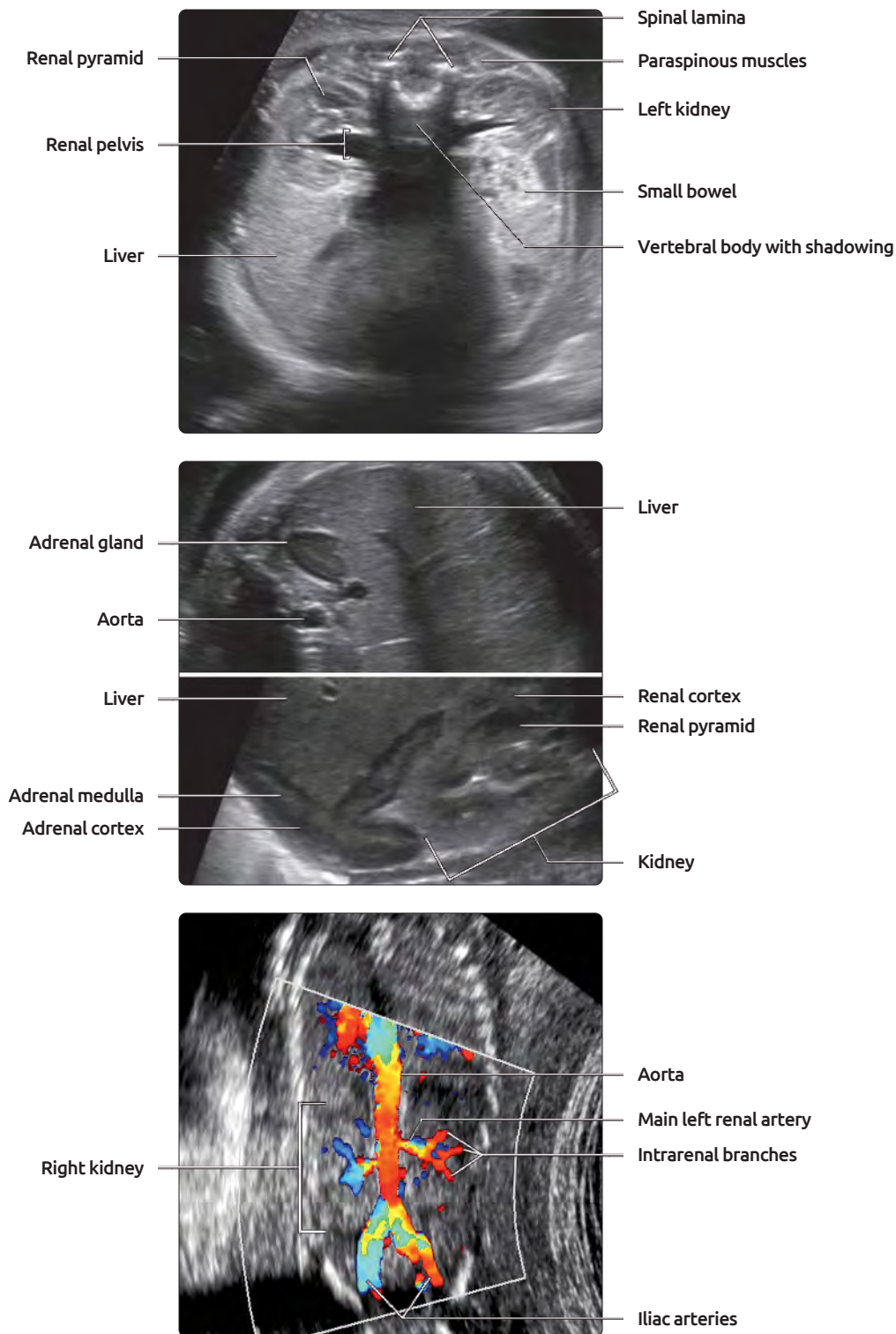
(Top) The fallopian tubes, uterus, and upper vagina form from the paired paramesonephric (müllerian) ducts, which develop on either side of the midline lateral to the mesonephric ducts (the mesonephric ducts regress in a female fetus). **(Middle)** The paramesonephric ducts must meet in the midline and fuse to form the uterus and upper portion of the vagina (uterovaginal canal). The unfused portions will form the fallopian tubes. The development of the kidney (metanephros) is closely related to uterine development, and coexistent renal and müllerian duct anomalies are common. **(Bottom)** The distal portion of the vagina (shown in yellow) is formed from the caudal urogenital sinus, which splits to form the urethra anteriorly and the vagina posteriorly. The allantois involutes to form the urachus.

MALE GENITAL TRACT



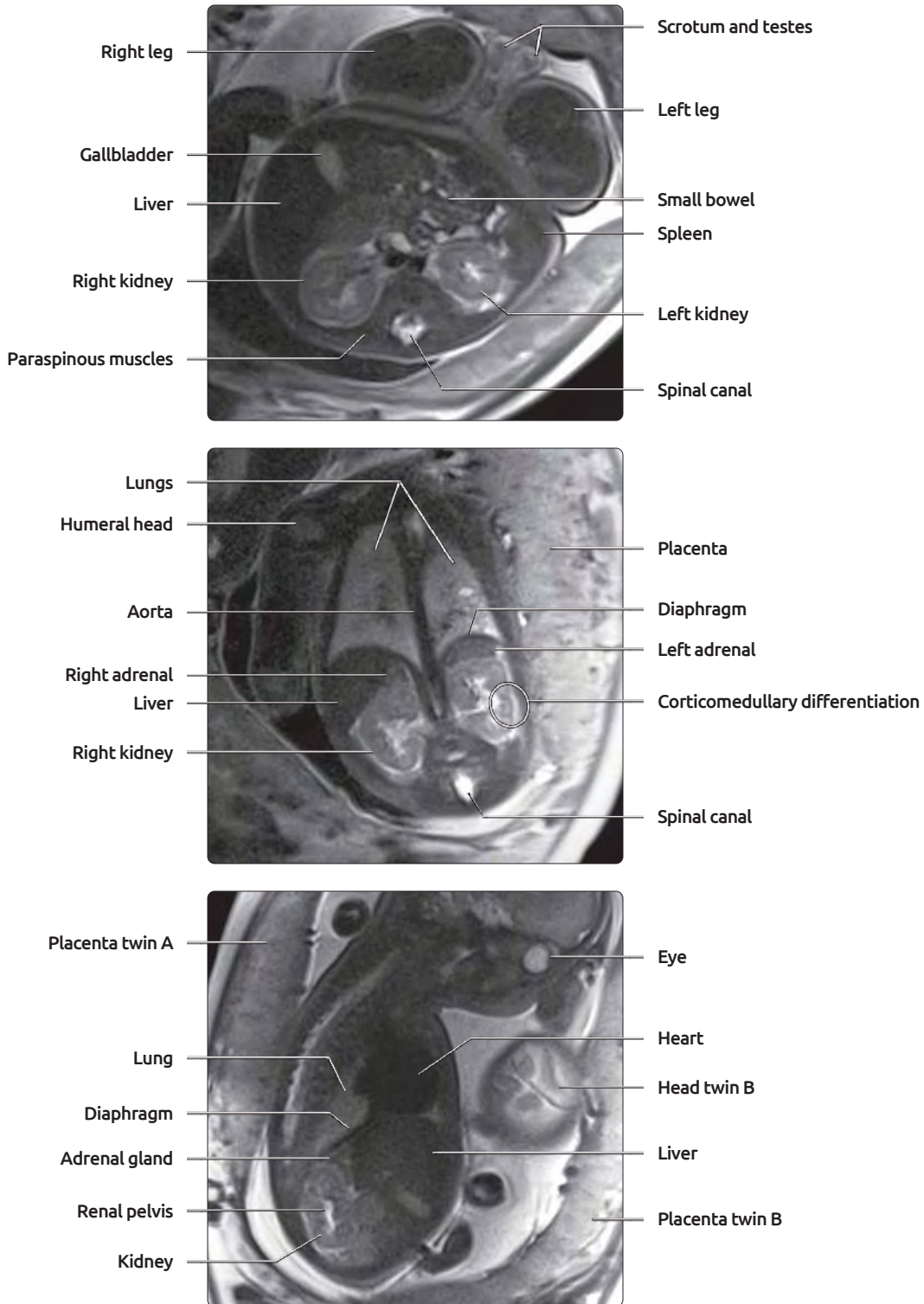
(Top) The mesonephric ducts (only 1 shown) persist in a male and will form the epididymides, vas deferens, seminal vesicles, and ejaculatory ducts. **(Middle)** The caudal urogenital sinus forms the penile urethra. The allantois involutes and forms the urachus. The prostate forms from endodermal evaginations of the prostatic portion of the urethra and surrounding mesenchyme. **(Bottom)** The processus vaginalis is a sock-like evagination of the peritoneum, which elongates caudally through the abdominal wall. It forms just anterior to the developing testes and, along with the gubernaculum (a ligamentous cord extending from the testis to the labioscrotal fold), aids in their descent. As the processus vaginalis evaginates, it becomes ensheathed by fascial extensions of the abdominal wall, which ultimately form the layers of the scrotum and spermatic cord.

URINARY TRACT, ULTRASOUND



(Top) This axial image is through the renal fossa with the spine at the 12 o'clock position. This is the best position to measure the renal pelvis diameter. **(Middle)** This is a composite image of an axial US of the right fetal adrenal gland (top) and sagittal ultrasound of the adrenal gland of a newborn (bottom). The fetal adrenal gland is 10-20x larger than the adult adrenal gland relative to body size. It is often quite prominent on fetal imaging and is recognized by its ice cream sandwich appearance, with a hyperechoic medulla and hypoechoic cortex. It typically is folded and angular in shape with a Y or tricorn hat configuration. **(Bottom)** Color Doppler ultrasound shows normal renal vasculature.

URINARY TRACT, MR



(Top) Axial image through the abdomen, at the level of the kidneys, in a 30-week fetus shows normal anatomy. The kidneys are well seen and are higher in signal than the liver, spleen, or muscles. **(Middle)** Coronal MR through the renal fossa shows the fetal adrenals, which are lower in signal compared to the kidneys. Normal corticomedullary differentiation is particularly well seen on the left kidney; also note the slightly "bumpy" contour (fetal lobulations). **(Bottom)** This image is a sagittal MR of twin A of a dichorionic twin gestation (note 2 placentas). The renal pelvis contains urine and is high signal intensity on T2-weighted imaging. Note the folded, tricorn shape of the adrenal gland.

Imaging Techniques and Normal Anatomy

Ultrasound

The American Institute of Ultrasound in Medicine requires documentation of the kidneys and bladder in all second and third-trimester fetuses. Evaluation of fetal sex is only required for the determination of zygosity in multiple gestations and when medically indicated. A qualitative or semiquantitative estimate of amniotic fluid volume should also be performed. These are considered the minimum requirements; if any anomaly is suspected, a detailed examination should ensue.

The components of the genitourinary tract include the **kidneys, ureters, bladder, urethra, adrenal glands, and the internal and external genitalia**. Knowledge of the normal developmental appearance of each of these structures is needed in order to recognize pathologic processes.

Kidneys can be identified by 12- to 14-weeks gestation using endovaginal sonography; internal architecture can be resolved as early as 16-18 weeks. The external renal contour is lobular (fetal lobulation), a finding that may persist into adulthood. The cortex is intermediate in echogenicity, and the hypochoic medullary pyramids are arranged symmetrically around the renal pelvis. Normative data is available for all renal dimension, but a rule of thumb for length is the length in mm approximates the fetal gestational age in weeks. The ratio of renal circumference to abdominal circumference is stable throughout pregnancy with values from 0.27-0.30.

The **anterior-posterior renal pelvis diameter (APRPD)** should measure < 4 mm at gestational age \leq 27 weeks and < 7 mm from 28 weeks to term. Larger measurements are concerning for a pathologic process, including obstruction and reflux. An APRPD of 4 to < 7 mm at 16-27 weeks or 7 to < 10 mm at \geq 28 weeks without calyceal dilation or renal parenchymal abnormality is considered low risk but should have an additional scan at \geq 32 weeks. If the APRPD measures larger than the above, or there is calyceal dilation or parenchymal changes, then closer follow-up is required.

Color Doppler ultrasound is helpful in the assessment of fetal vessels. When questioning **renal agenesis, the identification of renal arteries is crucial**. Be aware that the lumbar and adrenal arteries can appear quite prominent and may be mistaken for renal arteries. Color Doppler can also be used to identify the bladder between the umbilical arteries. This view also documents 2 umbilical arteries; renal anomalies are associated with a single umbilical artery.

The **normal adrenal gland has a characteristic ice cream sandwich** appearance with hyperechoic medulla (the ice cream filling) surrounded by hypochoic cortex. The normal adrenal is triangular or Y-shaped and relatively large, when compared with the kidney, in fetal life.

Although assessment of **fetal sex** is not required in low-risk pregnancies, it is often the most pressing question for the parents. The first-trimester phallus has a similar appearance in males and females. Although it points caudally in females and cranially in males, it is wise to avoid committing to gender before it can be clearly identified. If sex identification remains indeterminate (i.e., possible disorder of sexual development), a careful search should begin for various syndromes and aneuploidy.

Gender assessment is essential when diagnosing anomalies that affect only one sex or in evaluating disorders that only

affect monozygotic twins (e.g., twin-twin transfusion syndrome) in which the twins must have the same sex.

Amniotic fluid volume (AFV) is evaluated in every second and third-trimester study. AFV can be assessed subjectively or semiquantitatively by measuring fluid pockets. The **maximum (or deepest) vertical pocket (MVP)** measurement is the anterior to posterior distance of the largest fluid pocket within the uterus, void of fetal parts and umbilical cord. The "vertical" in the name implies that the measurement is obtained with the transducer perpendicular to the maternal abdomen. Oblique measurements are not reproducible and may lead to errors in assessment of fluid volume. Normal is 2-8 cm with < 2 cm indicating oligohydramnios and > 8-cm polyhydramnios. The **amniotic fluid index (AFI)** measurement is the sum of the MVPs in four quadrants of the uterus. In the third trimester especially, it may be hard to tell if a pocket is fluid-filled or contains loops of umbilical cord. Color Doppler is very useful to make this distinction. The AFI varies with gestational age but values of 5-20 cm are considered normal.

MR

MR is very helpful when US visualization is limited. T2WI is essential for the evaluation of renal anatomy. The renal parenchyma is intermediate in signal (i.e., < fluid, > liver or muscle), while the collecting system and the bladder should contain high-signal urine. The adrenal glands are seen best later in gestation; they are low signal, similar to liver, on T2WI with the medulla being somewhat higher in signal.

T1WI may allow differentiation of adrenal hemorrhage (high-signal blood products) from fetal neuroblastoma (intermediate-signal mass). Meconium-filled bowel is high signal, which can be helpful in differentiating bowel from urine-filled structures, which are low signal. It also helps to look at the course of the colon and rectum and to determine the location and patency of the anus if there is concern for cloacal or bowel anomalies.

Approach to Abnormal Urinary Tract

The first step in evaluation of any abdominal abnormality is to decide if it involves the urinary tract or the gastrointestinal tract. Peritoneal boundaries are not clear in the fetus, so care needs to be taken in deciding what organ system is involved. A dilated tubular structure may be either ureterectasis or obstructed bowel. A solid mass may be coming from the kidney (e.g., mesoblastic nephroma), the adrenal (e.g., neuroblastoma), or the liver (e.g., hepatoblastoma). Once the urinary tract is established as the site of origin, it is important to have a systematic approach to form an appropriate differential diagnosis.

Are There Two Kidneys? If So, Where Are They?

If both kidneys are absent, there will be anhydramnios in the second trimester. The **kidneys are not a major contributor to amniotic fluid until 16-weeks gestation**. The adrenal glands are very prominent early in gestation, and the diagnosis of renal agenesis could potentially be missed unless careful evaluation is performed. If there is normal fluid after this time, at least one kidney must be present. Evaluate the renal fossa carefully, and if there is only one kidney, begin a careful search to see if the other is absent (i.e., unilateral renal agenesis) or in an aberrant location (e.g., pelvic kidney, crossed fused ectopia).

Is the Renal Size and Echogenicity Normal?

Increased renal echogenicity may be seen in autosomal recessive polycystic kidney disease and Meckel-Gruber syndrome or in association with aneuploidy, typically trisomy 13. In these conditions, the kidneys are usually enlarged, sometimes massively so. The kidneys may also be echogenic in obstructive cystic dysplasia but are often small, and there should be obvious signs of an underlying urinary tract obstruction. Beckwith-Wiedemann syndrome may also present as renal enlargement, but the normal corticomedullary differentiation is usually preserved.

The differential diagnosis for **unilateral renal enlargement** includes: Unilateral renal agenesis with compensatory hypertrophy, cross-fused ectopia, duplicated renal collecting system, mesoblastic nephroma, and renal vein thrombosis.

Are Anechoic Structures Renal Cysts or Hydronephrosis?

Before you ask this question, make sure that the finding is real, not just hypoechoic renal pyramids, which can be quite prominent in the third trimester. If there are truly cystic areas within the kidney, real-time evaluation is essential. If they **connect centrally with the renal pelvis**, explore causes of hydronephrosis (e.g., ureteropelvic junction obstruction, ureterovesical obstruction, and bladder outlet obstruction). If they do not connect with each other or the renal pelvis, then the differential diagnosis is that for **multiple discrete cysts** (e.g., multicystic dysplastic kidney, cystic dysplasia).

Are the Ureters Visible?

Normal ureters are never seen sonographically. If dilated, consider obstruction, reflux, or primary megaureter.

Is the Bladder Normal in Size?

The bladder should fill and empty during the course of a scan. Always check the bladder at the beginning and end of the exam to make sure that the observation of a too big or too small bladder is persistent.

An **absent bladder** is most commonly due to failure of urine production; in which case, look for bilateral renal anomalies. This can also occur with decreased renal perfusion (e.g., fetal growth restriction, donor twin in twin-twin transfusion). Some structural malformations prevent normal bladder development, including cloaca and bladder extrophy.

If the bladder is distended and fails to empty, posterior urethral valves (PUV) and prune-belly syndrome should be considered. Demonstration of a dilated penile urethra in a male fetus with a large bladder differentiates prune-belly syndrome from PUV, in which the dilated posterior urethra creates the classic keyhole shape to the bladder. Amniotic fluid is usually decreased in these conditions.

In a female fetus, consider a cloacal malformation if there is a persistent fluid-filled structure in the pelvis. This should be a primary consideration if there is a fluid-debris level or a vertical septum. Ovarian cysts may be seen in the third trimester, beside or above the bladder.

Are the Adrenal Glands Normal in Size and Morphology?

In renal agenesis, the adrenal gland loses its triangular shape and flattens out into the renal fossa where it may be mistaken for the kidney. This is the **lying down adrenal sign**. Enlarged adrenals are unusual but may be seen in congenital adrenal hyperplasia (look for virilization of female fetus).

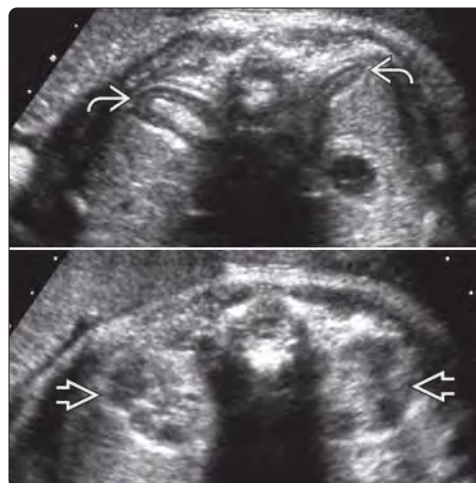
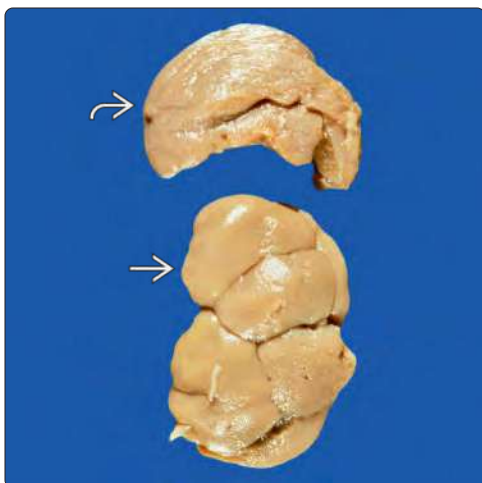
The differential for a **unilateral suprarenal mass** is neuroblastoma, adrenal hemorrhage, or extralobar sequestration. The latter is a pulmonary malformation and does not actually arise from the adrenal. To make this diagnosis, look for the normal adrenal gland displaced by the mass. Color Doppler will show a prominent feeding vessel arising from aorta.





Are the Genitalia Normal?



Anomalous/ambiguous genitalia can be seen in disorders of sexual development (e.g., congenital adrenal hyperplasia), structural malformation sequences that affect bladder development (e.g., bladder extrophy), aneuploidy (e.g., trisomy 13, trisomy 18, triploidy), and syndromes (e.g., Smith-Lemli-Opitz, Prader-Willi).

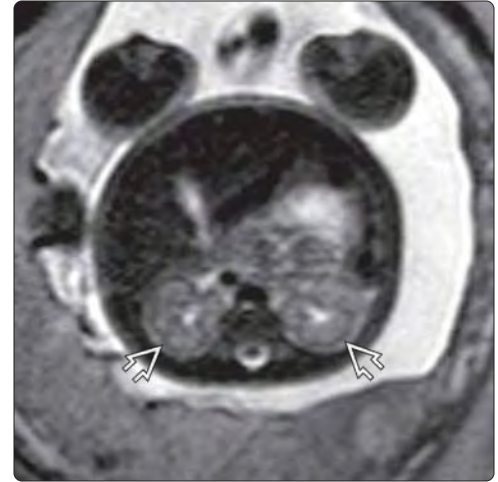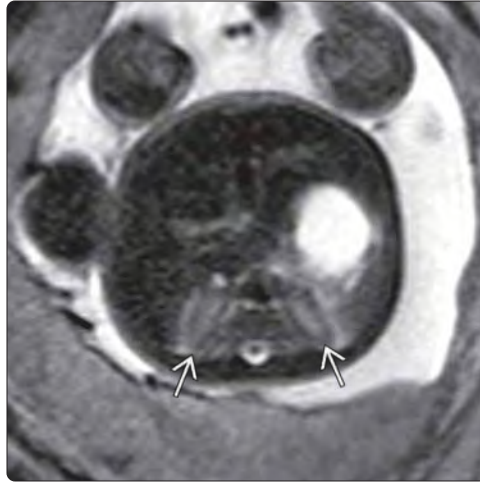
Clinical Implications




Abnormalities of the genitourinary tract can be lethal (e.g., bilateral renal agenesis) or of minor importance (e.g., ovarian cyst). A systematic approach to evaluation will help you to reach the correct diagnosis, which is essential for patient counseling, proper pregnancy management, and postnatal evaluation.

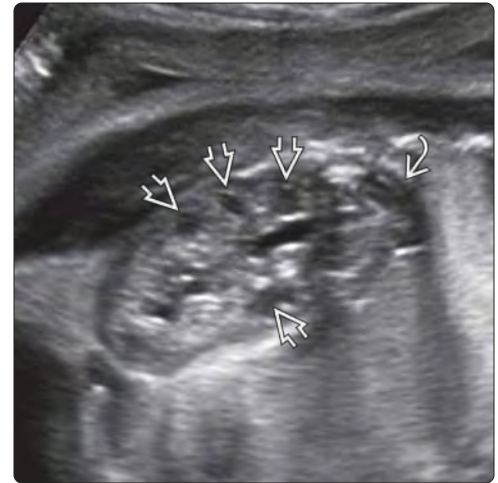
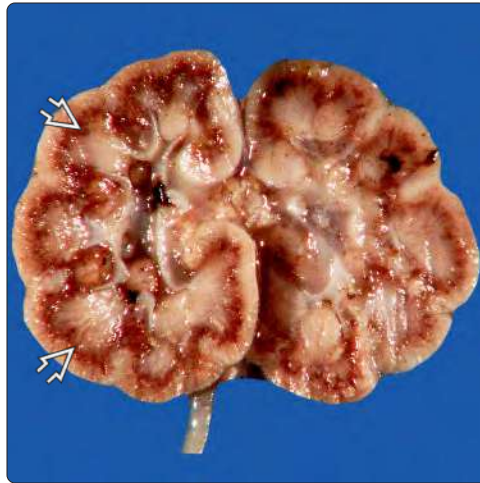






(Left) Gross pathology example from a 2nd-trimester fetus shows the relatively large size of the fetal adrenal  compared with the fetal kidney  (note the fetal lobulations). It is important not to mistake adrenal glands for kidneys in cases of renal agenesis. **(Right)** Composite axial US in the 3rd trimester shows the ice cream sandwich appearance of the adrenal glands  just cephalad to the kidneys , which are round in cross section with nice corticomedullary differentiation.

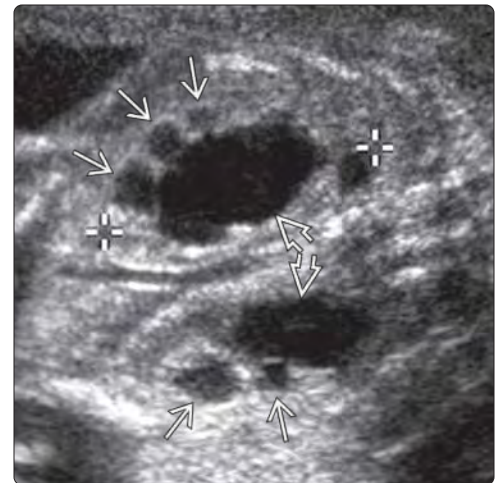
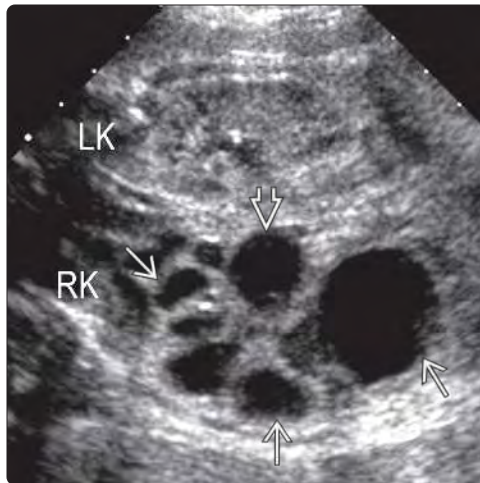
(Left) Axial T2WI MR of a 3rd-trimester fetus shows normal signal intensity and configuration of the adrenal glands . Note the low-signal cortex and high-signal medulla, creating the MR version of the ice cream sandwich. **(Right)** Immediately below the adrenal glands are the kidneys , which are intermediate in signal intensity with a high-signal renal pelvis.

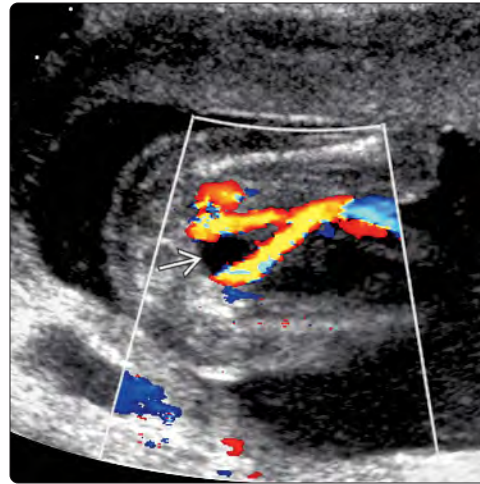
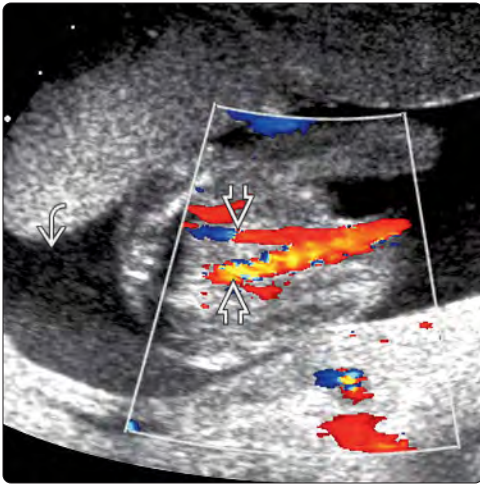


(Left) Coronal cut section of a 3rd-trimester fetal kidney shows the lobulated cortical margin (fetal lobulation) and distinct renal pyramids  in an array around the renal pelvis. **(Right)** Coronal US of the kidney in a 3rd-trimester fetus shows the normal hypoechoic pyramids . These should not be confused with dilated calyces. Also note that the adrenal gland  is well seen.

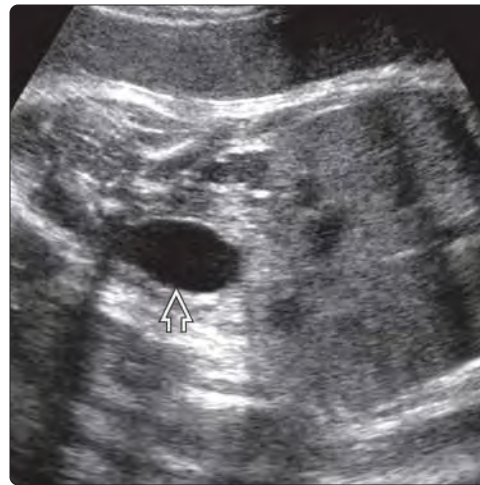
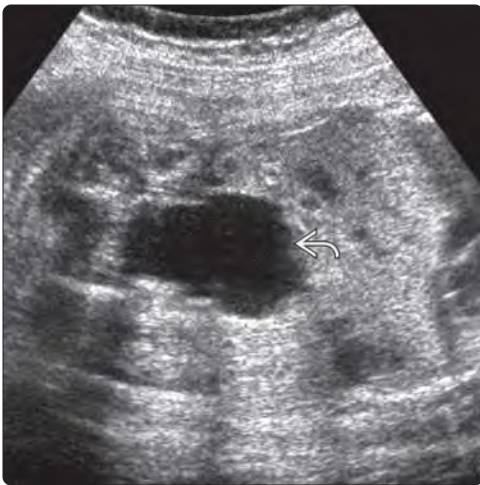
(Left) Coronal US shows multiple anechoic structures  within the right kidney, which appear to cluster around what could be a dilated renal pelvis . Real-time imaging is essential to determine if these communicate. In this case, they did not. This is a multicystic dysplastic kidney, not hydronephrosis. **(Right)** Conversely, in this case, the peripheral "cysts"  communicate with the central fluid collection  (i.e., renal pelvis). This fetus had bilateral ureteropelvic junction obstruction.

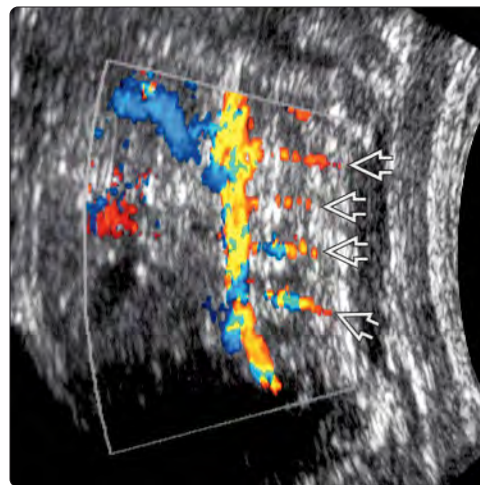
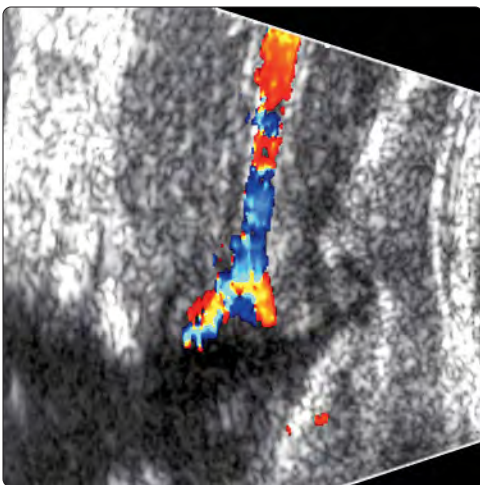




(Left) Axial color Doppler US shows 2 umbilical arteries . This is the anatomic landmark for the fetal bladder, but none was seen. Normal amniotic fluid and kidneys (not shown) make an anomaly unlikely. **(Right)** Another color Doppler US 7 minutes later shows the bladder starting to fill, confirming that this fetus is indeed normal. The bladder often changes appearance during the examination.



(Left) Coronal US shows a very distended bladder extending up to the liver margin . If this were persistent, it would be concerning for a lower urinary tract obstruction. **(Right)** A follow-up coronal US at the end of the exam shows the bladder has decompressed and now has a normal appearance. The urinary tract is a dynamic system, with the collecting system (renal pelvis, ureters, and bladder) filling and decompressing. Before diagnosing an abnormality, it is essential to determine if the finding is persistent.



(Left) Color Doppler US can be very helpful in evaluating urinary tract anomalies, especially to look for renal arteries in the setting of possible renal agenesis. In this coronal US of the aorta, no renal arteries are seen. **(Right)** It is important to be aware of potential pitfalls. When the transducer is angled posteriorly, multiple lumbar arteries are seen . One of these could be easily confused with a renal artery. Understanding normal anatomy and attention to detail is imperative in making the correct diagnosis.

KEY FACTS

IMAGING

- Best clue: ↑ anterior-posterior renal pelvis diameter (AP RPD)
 - Measure AP RPD with spine at 12:00 or 6:00 o'clock
- Normal AP RPD
 - < 4 mm from 16-27 weeks
 - < 7 mm when ≥ 28 weeks
- Mild cases are most often transient
 - Resolve at 32-week follow-up exam
- Associations
 - Minor marker for trisomy 21
 - Obstruction
 - Reflux
- Moderate and severe cases more likely to progress
 - More frequent surveillance indicated
 - Associated oligohydramnios more likely
- Use urinary tract dilation (UTD) classification system
 - UTD A1 considered low risk

- UTD A2-3 considered increased risk

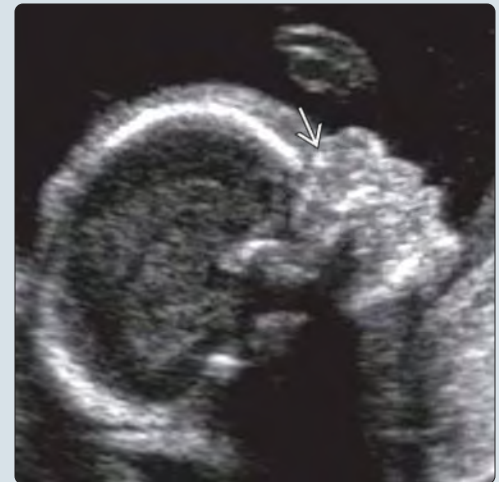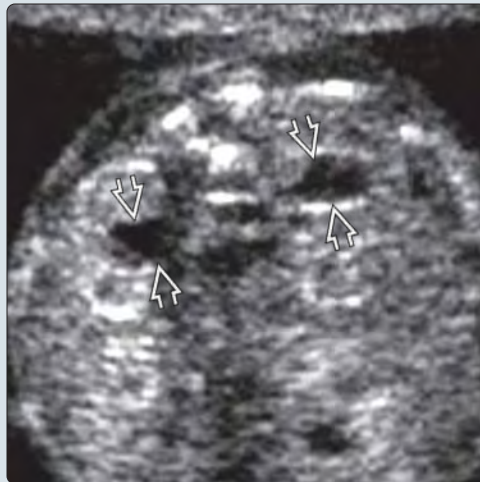
CLINICAL ISSUES

- UTD is diagnosed in 1-2% of all pregnancies
 - M:F = 2:1
- Transient/physiologic in 50-70%
- ↑ likelihood of postnatal uropathy when mild UTD progresses

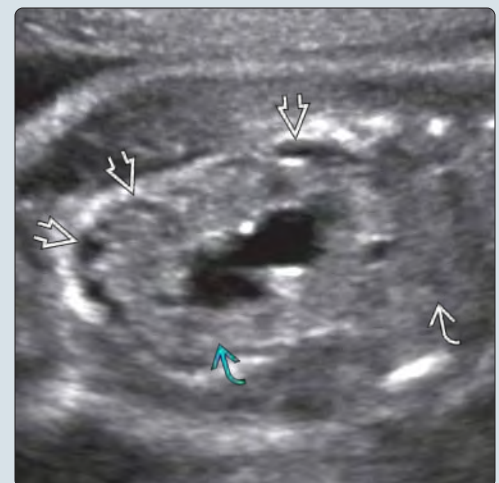
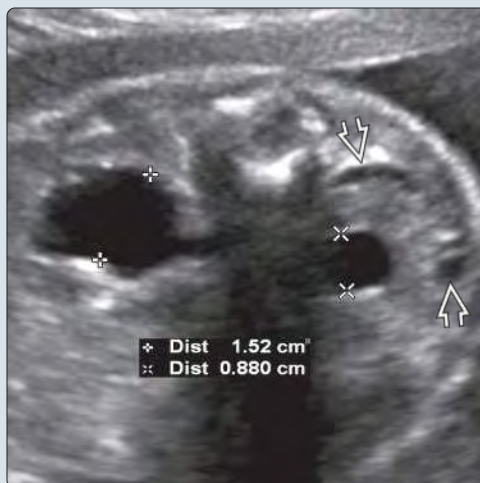DIAGNOSTIC CHECKLIST

- Look carefully at morphology of genitourinary tract to best determine level of obstruction
 - Upper tract obstruction involves only kidney
 - Lower tract obstruction more variable
- Look carefully at fetal renal parenchyma
 - Consider cystic dysplasia if renal echogenicity is > liver or spleen echogenicity
 - Look for loss of corticomedullary differentiation
 - Look for small cortical cysts

(Left) Axial ultrasound of the fetal kidneys at the 20-week anatomy scan shows bilateral mild renal pelvis dilation. The anterior-posterior renal pelvis diameter (AP RPD) was 4 mm bilaterally. This finding is considered a minor marker for trisomy 21. **(Right)** Fetal profile view in the same case shows a much more concerning marker for trisomy 21. The nasal bone is very small. A small ventricular septal defect was also seen. Amniocentesis results confirmed the suspicion for trisomy 21.



(Left) Bilateral ↑ AP RPD is seen in this 32-week fetus (normal is < 7 mm at 32 weeks). Although the right renal pelvis is more dilated than the left, there is a suggestion of cortical cysts involving the left kidney. **(Right)** Longitudinal view of the left renal parenchyma confirms the presence of cortical cysts. Also, the renal parenchyma echogenicity is greater than the spleen. These findings are diagnostic of renal cystic dysplasia, from high-grade obstruction in this case.



TERMINOLOGY

Abbreviations

- Urinary tract dilation (UTD)

Synonyms

- Pelviectasis, pyelectasis, fetal hydronephrosis

Definitions

- Renal collecting system distended with urine from variety of causes

IMAGING

General Features

- Best diagnostic clue
 - ↑ anterior-posterior renal pelvis diameter (AP RPD)

Ultrasonographic Findings

- Evaluation of 2nd- and 3rd-trimester kidneys
 - Image both kidneys in axial and longitudinal axis
 - Measure AP RPD with spine at 12 o'clock or 6 o'clock if feasible
 - Normal AP RPD
 - < 4 mm from 16-27 weeks and < 7 mm when ≥ 28 weeks
 - Calipers placed at renal pelvis and renal parenchyma junction
 - Normal renal parenchyma
 - Isoechoic or hypoechoic to liver
 - Should never contain cysts
 - Hypoechoic pyramids seen later in pregnancy
 - Can mimic calyceal dilation
 - Parenchymal thickness is mostly subjective assessment (thin considered abnormal)
 - Normative data has been published
 - Abnormal fluid-filled renal pelvis
 - Ballooned renal pelvis appearance
 - Bilateral or unilateral
 - Longitudinal views helpful for morphology
 - Look for peripheral calyceal distention
 - Look for evidence of renal duplication
 - Evaluate rest of GU tract
 - Is the ureter dilated?
 - Is the bladder normal?
 - Evaluate amniotic fluid volume
 - Isolated ↑ AP RPD and trisomy 21
 - Likelihood ratio of 1.1 is low
 - Look for other T21 markers and anomalies
 - Mild UTD may progress with advancing pregnancy
 - More likely if unilateral or asymmetric UTD
 - Obstructive causes
 - Lower urinary tract obstruction (LUTO)
 - Ureteropelvic junction (UPJ) obstruction
 - Ureterocele
 - Most often ectopic and associated with renal duplication
 - Ureterovesical junction obstruction
 - Other causes
 - Vesicoureteral reflux
 - Primary or associated with renal duplication

- Primary megaureter
- Cloaca

Imaging Recommendations

- Best imaging tool
 - Adequate visualization of complete GU system
- Protocol advice
 - Use UTD prenatal classification system for diagnosis and management
 - UTD A1 = antenatal type 1 and considered low risk
 - UTD A2-3 = antenatal type 2-3 and considered increased risk
 - UTD postnatal classification uses UTD P1, P2, and P3
 - P1 is low risk
 - Central dilation only (10 mm to < 15 mm AP RPD)
 - P2 is intermediate risk
 - ≥ 15 mm AP RPD
 - Peripheral calyceal dilation &/or abnormal ureters
 - Normal renal parenchyma
 - P3 is high risk
 - Any parenchymal or bladder abnormality

DIFFERENTIAL DIAGNOSIS

Ureteropelvic Junction Obstruction

- Obstruction at junction of ureter and renal pelvis
- Renal pelvis distention + variable calyceal distention
- Most common cause of congenital hydronephrosis
- May present as mild UTD at anatomy scan

Lower Urinary Tract Obstruction

- Level of genitalia, bladder, or ureters
- More likely to have bilateral UTD and oligohydramnios

PATHOLOGY

General Features

- Etiology
 - Mild UTD is often physiologic and resolves with advancing pregnancy
 - Other causes include obstruction and reflux
- Associated abnormalities
 - Aneuploidy
 - Renal obstruction/pathology

CLINICAL ISSUES

Presentation

- Most common signs/symptoms
 - Incidental finding in low-risk patient
 - In association with other aneuploidy markers

Demographics

- Gender
 - M:F = 2:1
- Epidemiology
 - UTD is diagnosed in 1-2% of all pregnancies

Natural History & Prognosis

- Transient/physiologic in 50-70%
- UPJ obstruction in 10-30%
- Vesicoureteral reflux in 10-40%

Urinary Tract Dilation: Antenatal Categories by AP RPD

AP RPD 16-27 Weeks, 6 Days	AP RPD ≥ 28 Weeks
Normal	
< 4 mm	< 7 mm
UTD A1 (Low Risk)	
4 mm to < 7mm	7 mm to < 10 mm
UTD A2-3 (Increased Risk)	
≥ 7 mm	≥ 10 mm

AP RPD = anterior-posterior renal pelvis diameter; A1, A2-3 = antenatal category 1, antenatal category 2-3.

Prenatal Diagnosis: Urinary Tract Dilation A1 vs. UTD A2-3

UTD A1	UTD A2-3 (Need Only 1 Finding)
Central renal pelvis dilation without peripheral calyceal dilation	Peripheral calyceal dilation
Normal parenchymal thickness	Abnormal parenchymal thickness
Normal parenchymal appearance	Abnormal parenchymal appearance
Normal ureters	Abnormal ureters
Normal bladder	Abnormal bladder
No unexplained oligohydramnios	Oligohydramnios from GU cause

Risk-Based Management of Urinary Tract Dilation A1 (Low Risk) and A2-3 (Increased Risk)

UTD A1 Management	UTD A2-3 Management
Prenatal period: Additional ultrasound ≥ 32 weeks	Prenatal period: Follow-up initially in 4-6 weeks; certain situations require more expedient follow-up or drainage procedures
After Birth	
1st ultrasound > 48 hours to 1 month	1st ultrasound > 48 hours to 1 month
2nd ultrasound: 1-6 months later	Certain situations require more expedient follow-up
Other Considerations	
Aneuploidy risk modification	Specialist consultation with nephrology &/or urology during and after pregnancy

- LUTO in 10-15%

DIAGNOSTIC CHECKLIST

Consider

- Assess maternal risk for aneuploidy
 - Maternal age
 - Genetic screening results

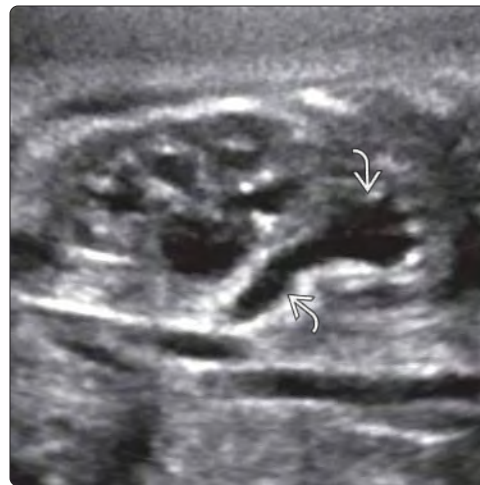
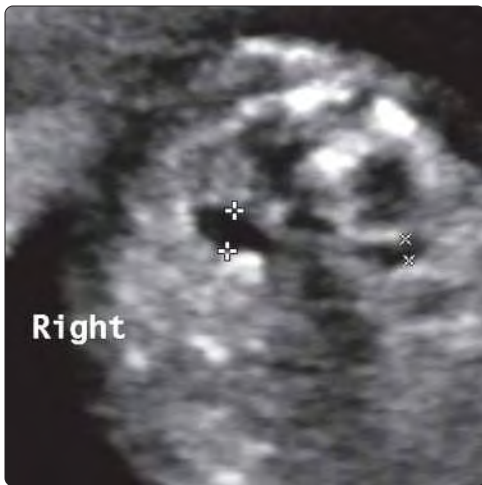
Image Interpretation Pearls

- Most cases of UTD A1 are transient and idiopathic
 - Follow-up earlier than 32 weeks not necessary
 - If resolved at follow-up, then further work-up is not necessary
- Look at morphology of GU tract to determine level of obstruction
- Look carefully at fetal renal parenchyma for postobstructive parenchymal change
 - Compare echogenicity of affected kidney with other kidney when process is unilateral

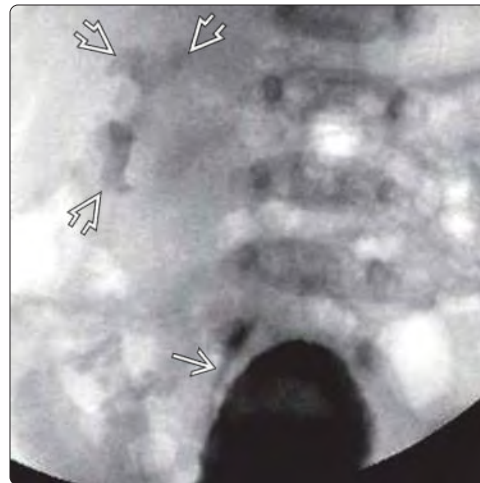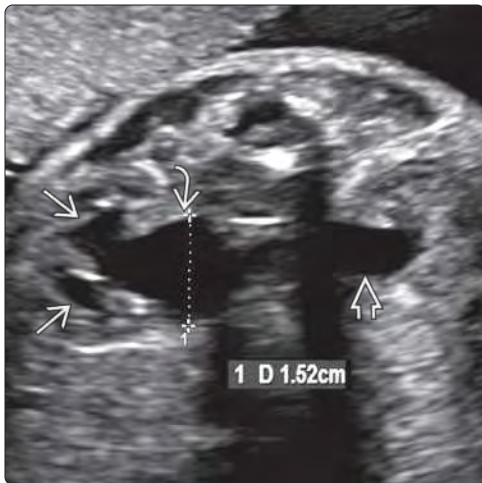
- Use hydronephrosis term sparingly; it is not a diagnosis, it is a finding
 - Implies obstructive process
- Any amount of calyceal distention is abnormal
 - More suggestive of obstruction than RPD alone
- Any parenchymal cystic change is abnormal
 - Even without renal collecting system dilation
- Postnatal imaging options
 - Ultrasound (not before 48° after delivery)
 - Neonatal dehydration minimizes degree of dilation
 - Voiding cystourethrogram to rule out reflux
 - Renal nuclear medicine scan to assess function

SELECTED REFERENCES

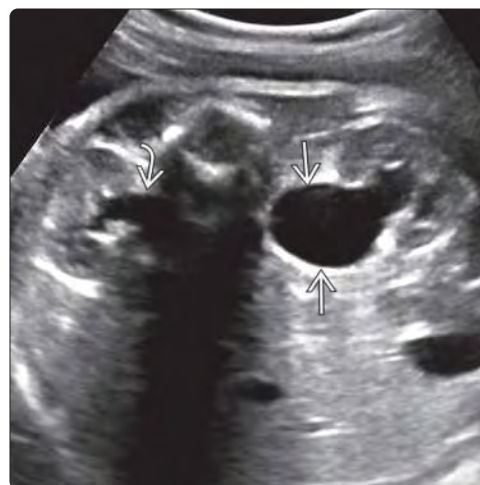
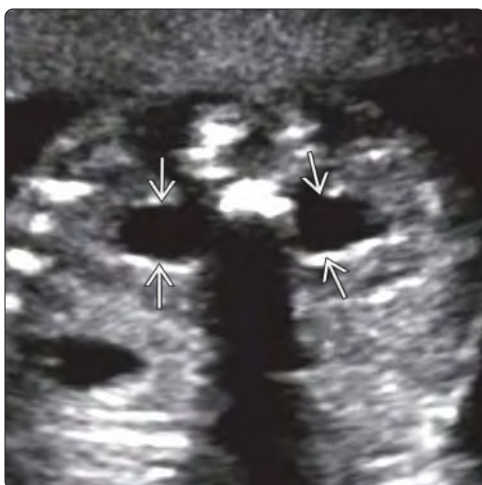
1. Nguyen HT et al: Multidisciplinary consensus on the classification of prenatal and postnatal urinary tract dilation (UTD classification system). *J Pediatr Urol.* 10(6):982-98, 2014
2. American Institute of Ultrasound in Medicine: AIUM practice guideline for the performance of obstetric ultrasound examinations. *J Ultrasound Med.* 32(6):1083-101, 2013
3. Hadar E et al: Sonographic evaluation of kidney parenchymal growth in the fetus. *Arch Gynecol Obstet.* 286(4):867-72, 2012



(Left) At the time of anatomy scan, the only finding in this 20-week fetus was mild right kidney AP RPD dilation of 4 mm. The left side was normal. Follow-up at 32 weeks was recommended. **(Right)** Duplication renal anomaly with dilation of the upper pole collecting system was seen on follow-up. An ectopic ureterocele was also seen in the bladder. In this case, the low-risk urinary tract dilation (UTD) A1 classification at 20-weeks progressed to UTD A2-3 on follow-up.



(Left) Right renal pelvis and peripheral calyceal distention was seen in this 3rd-trimester fetus. Only central renal pelvis distention < 7 mm was seen on the left. Postnatal work-up was recommended. **(Right)** Voiding cystourethrogram performed after delivery shows reflux of contrast from the bladder into the lower ureter and into dilated peripheral calyces. Vesicoureteral reflux is the cause of antenatal UTD in 10-40% of cases.



(Left) Axial ultrasound of the kidneys at 20 weeks shows bilateral symmetric UTD involving the renal pelves but not the calyces. The finding was isolated in a low-risk patient, and follow-up was recommended. **(Right)** Axial ultrasound through the kidneys at 35 weeks in the same fetus shows asymmetric renal pelvis dilation, with a markedly distended renal pelvis on the left and a normal renal pelvis on the right. Peripheral calyceal dilation on the left was also seen. Postnatal diagnosis was UPJ obstruction.

KEY FACTS

IMAGING

- Diagnosis of exclusion
 - Must exclude asymmetric horseshoe kidney, pelvic kidney, and crossed ectopic kidney
- Adrenal gland fills empty renal fossa in globular instead of triangular shape
 - Shape and position of adrenal can mimic kidney
 - Colon in empty renal fossa may also mimic kidney
- Absent renal artery
 - Color Doppler confirms diagnosis
 - Beware of adrenal or lumbar arteries mimicking renal artery
- Compensatory hypertrophy of remaining kidney in up to 90% of cases
 - Seen as early as 20 weeks
- Look for associated findings
 - Single umbilical artery
 - VACTERL association

TOP DIFFERENTIAL DIAGNOSES

- Pelvic kidney
 - May not be seen on initial screening ultrasound
- Aplastic kidney
- Asymmetric horseshoe kidney
- Crossed fused ectopia

PATHOLOGY




- Associated with multiple chromosomal abnormalities
- Uterine duplication anomalies can be present

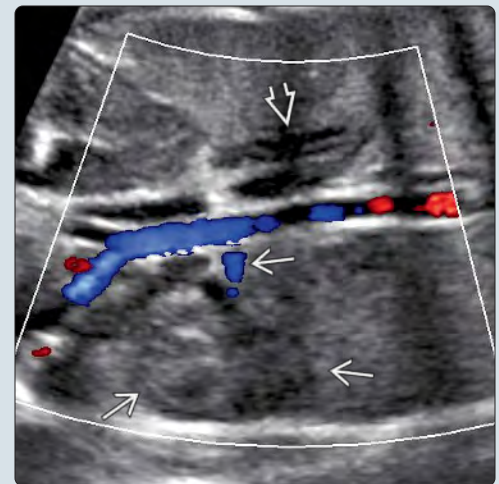
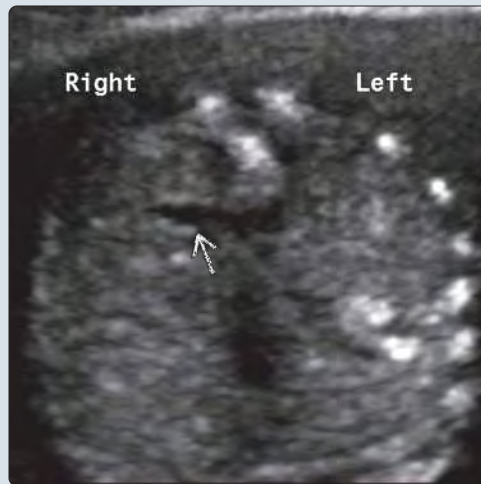
CLINICAL ISSUES




- Often incidental finding
- Occurs in up to 1:1,000 live births
- Postnatal ultrasound to confirm diagnosis

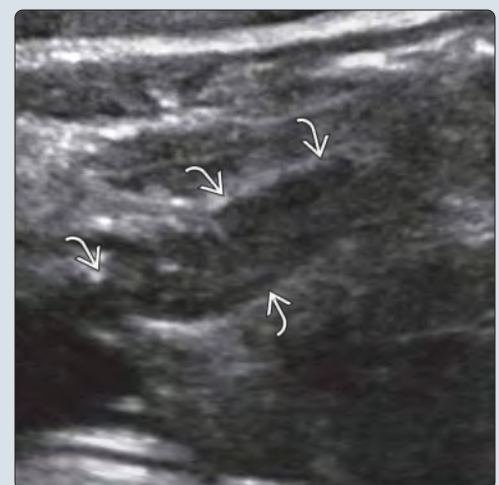
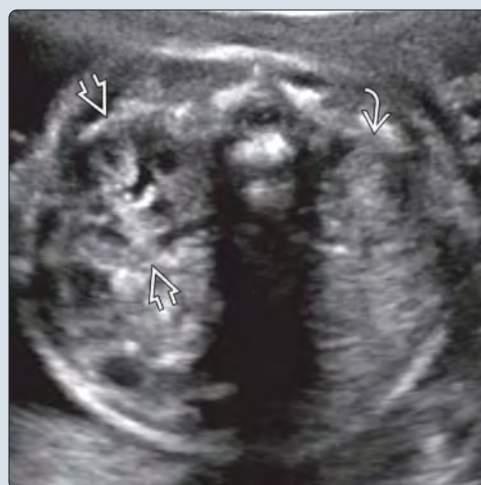
DIAGNOSTIC CHECKLIST

- If diagnosed in 2nd trimester, follow-up ultrasound in 3rd trimester to assess for pelvic kidney

(Left) At 21-weeks gestation, trace fluid in the renal pelvis  can help identify the normal right kidney, with an empty left renal fossa. Always look carefully around the bladder for a possible pelvic kidney. A follow-up scan in the 3rd trimester may be needed for definitive diagnosis. **(Right)** Doppler ultrasound can help confirm the absence of a renal artery. In this case, the left renal artery and kidney are present , and the right renal artery is absent. Note the right adrenal gland  is located in the right renal fossa and may mimic a kidney.



(Left) Third-trimester hypoechoic meconium-filled retroperitoneal colon  can mimic the presence of a kidney. However, compare the appearance to the normally located kidney . In the 3rd trimester, there is distinct corticomedullary differentiation as well as a renal pelvis. There is often compensatory hypertrophy of the solitary kidney. **(Right)** To avoid this pitfall, scan in a longitudinal plane to elongate the colon .



TERMINOLOGY

Abbreviations

- Renal agenesis (RA)

Definitions

- Absent unilateral kidney
 - Failure of development

IMAGING

General Features

- Best diagnostic clue
 - Empty renal fossa
 - Diagnosis of exclusion: Look for other developmental anomalies with ectopic renal locations
 - Pelvic kidney
 - Horseshoe kidney
 - Crossed fused renal ectopia
- Location
 - Left > right
 - 57% empty renal fossa on left

Ultrasonographic Findings

- Grayscale ultrasound
 - Empty renal fossa
 - Confirm on axial and longitudinal view
 - Compensatory renal hypertrophy
 - Contralateral normal kidney increases function
 - Size > 95th percentile
 - Seen up to 90% of cases
 - As early as 20 weeks
 - Adrenal gland fills empty renal fossa
 - Globular instead of triangular
 - Lying-down appearance
 - Can mimic kidney
 - Colon in empty renal fossa may also mimic kidney
 - Usually more prominent in late 2nd or 3rd trimester
- Color Doppler
 - Color Doppler confirms diagnosis
 - Coronal aorta view
 - Renal arteries arise about L2 off of aorta
 - Beware of adrenal or lumbar arteries mimicking renal artery
 - Celiac and superior mesenteric arteries arise near renal arteries as well

MR Findings

- Helpful only if sonographic findings inconclusive or other anomalies present

Imaging Recommendations

- Protocol advice
 - Use color Doppler to find renal arteries
 - Assess contralateral renal fossa
 - Renal morphology and size
 - Look carefully for pelvic kidney

DIFFERENTIAL DIAGNOSIS

Pelvic Kidney

- May not be seen on initial screening ultrasound

- Look for reniform "mass" near bladder
- Blood supply may be from distal aorta or iliac vessels

Aplastic Kidney

- Kidney is small and without function but present

Asymmetric Horseshoe Kidney

- Renal parenchyma crossing midline (isthmus) in horseshoe configuration

Crossed Fused Ectopia

- Both kidneys on 1 side of body

PATHOLOGY

General Features

- Etiology
 - Failure of ureteric bud induction of metanephric blastema
- Genetics
 - Reported associations with multiple chromosomal abnormalities
 - Trisomy 21
 - 45,X mosaicism
 - 22q11 microdeletion
- Associated abnormalities
 - Müllerian duct abnormalities
 - Uterine duplication anomalies
 - Can be seen in setting of VACTERL association
 - Single umbilical artery

CLINICAL ISSUES

Presentation

- Incidental finding in utero

Demographics

- Incidence ~ 1:3,000 on prenatal ultrasound

Natural History & Prognosis

- Remaining kidney larger
 - Increased susceptibility to injury
 - Susceptibility to toxic or ischemic insult
- 50% develop hypertension
- May have increased frequency of proteinuria, renal insufficiency

Treatment

- Postnatal ultrasound to confirm diagnosis
 - Consider including uterus in females

DIAGNOSTIC CHECKLIST

Image Interpretation Pearls

- If diagnosed in 2nd trimester, follow-up ultrasound in 3rd trimester to assess for pelvic kidney

SELECTED REFERENCES

1. Ación P et al: Reproductive outcome in uterine malformations with or without an associated unilateral renal agenesis. *J Reprod Med.* 59(1-2):69-75, 2014
2. Cunningham BK et al: Analysis of renal anomalies in VACTERL association. *Birth Defects Res A Clin Mol Teratol.* 100(10):801-5, 2014
3. Westland R et al: Unilateral renal agenesis: a systematic review on associated anomalies and renal injury. *Nephrol Dial Transplant.* 28(7):1844-55, 2013

KEY FACTS

TERMINOLOGY

- Duplicated renal collecting system split into separate upper and lower pole moieties
 - May be complete or partial duplication

IMAGING

- Duplicated kidney larger than contralateral side
 - Dilatation of upper pole collecting system typical
- 2 separate ureters drain upper and lower poles
 - Upper pole drained by ectopic ureter with ureterocele in bladder
 - Lower pole drained by normotopic ureter prone to reflux
- Bilateral duplication in 10-20%
- Severe obstruction may result in dysplastic changes

TOP DIFFERENTIAL DIAGNOSES

- Ureteropelvic junction obstruction
 - Ureter not seen
- Reflux

- Simple ureterocele

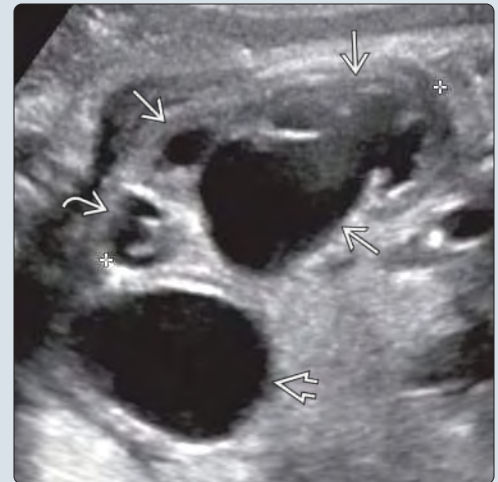
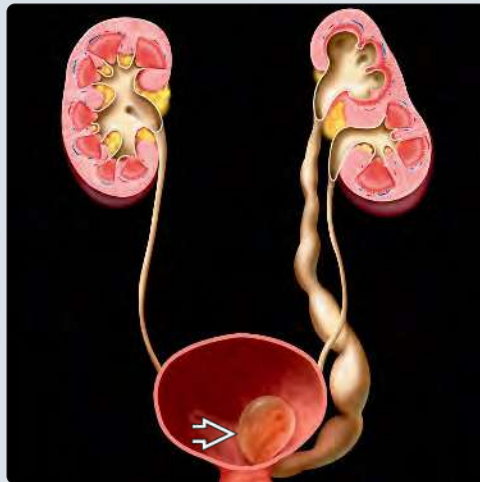
CLINICAL ISSUES

- Most common congenital malformation of urinary tract
- Usually incidental finding
- Obstructed upper pole moiety prone to infection due to urinary stasis
 - Prenatal diagnosis allows early intervention decreasing risk of urosepsis and renal damage
- More common in females
 - Gynecological anomalies in 50% of affected females

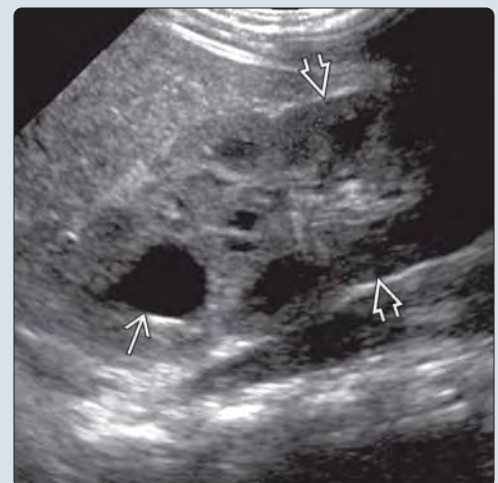
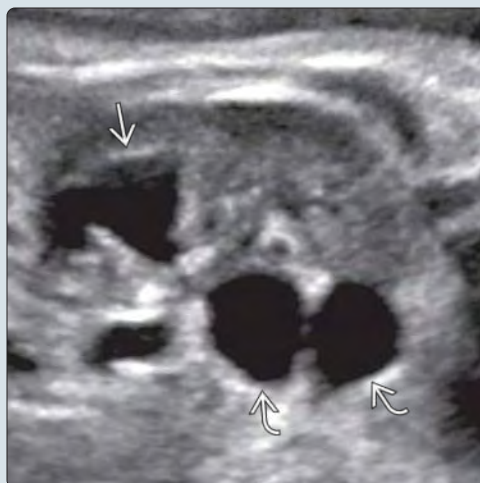
DIAGNOSTIC CHECKLIST

- Always evaluate for duplication in presence of hydronephrosis (unilateral or bilateral)
- Dilated upper pole moiety + cystic mass in bladder is diagnostic for duplication with ureterocele
- Majority of duplicated kidneys are > 95th percentile in length

(Left) Graphic shows a duplicated left-sided collecting system. The upper pole moiety is obstructed, with ureteral dilatation and an ectopic ureterocele that herniates into the bladder lumen. **(Right)** Coronal ultrasound shows an enlarged right kidney (calipers) with a markedly dilated upper pole. The lower pole is mildly dilated due to reflux. Initial view of the bladder appears normal; however, careful imaging in multiple planes should be performed to assess for a ureterocele, which was confirmed in this case.



(Left) At 28 weeks, upper pole dilation is present in this duplicated kidney. A markedly dilated ureter is partially seen. In cases where a ureterocele is not identified in the bladder, the ureter may be obstructed from ectopic implantation elsewhere in the low pelvis. **(Right)** Postnatal ultrasound confirms the dilated upper pole and normal lower pole. Postnatal ultrasounds for hydronephrosis should be performed at least 48 hours after delivery, to allow newborn relative dehydration to resolve.



TERMINOLOGY

Definitions

- Duplicated renal collecting system split into separate upper and lower pole moieties

IMAGING

General Features

- Best diagnostic clue
 - Dilatation of upper pole collecting system + ureterocele is diagnostic
- Weigert-Meyer rule
 - Ectopic upper pole ureter insertion inferior and medial to normotopic ureter, in trigone of bladder
 - Usually associated with ureterocele in bladder
 - Upper pole obstructs
 - Lower pole refluxes
- Bilateral duplication in 10-20%

Ultrasonographic Findings

- Kidney
 - Asymmetric renal size
 - Affected kidney larger than contralateral side
 - Unilateral renal enlargement may be only clue that duplication is present
 - Upper and lower pole moieties separated by band of renal parenchyma
 - Dilatation of upper pole collecting system
 - May appear cyst-like if significantly dilated
 - Actually represents dilated calyces
 - Evaluate sagittal or coronal planes to connect "cysts" into renal pelvis
 - Severe obstruction may result in dysplastic changes
 - Upper pole parenchyma may be replaced with large cysts that displace lower pole
 - Cysts may shrink over time → kidney starts to appear more normal
 - Reflux can cause lower pole dilation
- Ureters
 - 2 separate ureters drain upper and lower poles
 - Upper pole drained by ectopic ureter
 - Ureterocele usually present at distal end
 - Renal pelvis and ureter often dilated from obstruction
 - Lower pole drained by normotopic ureter
 - Ureterovesical junction of normotopic ureter distorted by ectopic ureterocele
 - Vesicoureteral reflux may occur
 - Ectopic ureter
 - Most commonly inserts into bladder
 - Extravesicular insertion sites also possible
 - Ejaculatory ducts
 - Vas deferens
 - Epididymis
 - Seminal vesicles
 - Uterus
 - Vagina
 - Urethra (least common)
- Bladder
 - Ureterocele associated with ectopic ureter

- Ureterocele = thin-walled, balloon-like structure in bladder
 - Often large
 - May cause bladder outlet obstruction
 - May obstruct contralateral ureter/kidney
 - May prolapse in and out of bladder

- Oligohydramnios can occur if ureterocele obstructs bladder outlet

Imaging Recommendations

- Always search for other signs of duplication in presence of hydronephrosis
 - Normal lower pole moiety
 - Asymmetric renal size
 - Dilated ureter(s)
 - Ureterocele
- Evaluate kidney in both transverse and longitudinal planes
 - Transverse views alone can lead to erroneous diagnosis of ureteropelvic junction obstruction
 - Lower pole moiety may be displaced inferiorly and difficult to see
 - Measure length
 - > 95% for gestational age
- Evaluate bladder several different times during study
 - Ureterocele may be misinterpreted as bladder if bladder is empty
 - Distended bladder may compress ureterocele
- Follow collecting system in real time
 - Renal pelvis → ureter → ureterocele
- Whenever 1 anomaly found, look for others
 - Contralateral renal malformation
 - May change prognosis and management
 - Multiple anomaly syndromes (e.g., VACTERL sequence)

DIFFERENTIAL DIAGNOSIS

Ureteropelvic Junction Obstruction

- Pelvis dilated
- Ureter not seen
- No ureterocele

Reflux

- Entire collecting system dilated
- No ureterocele
- Findings may vary between scans

Simple Ureterocele

- Ureter inserts in normal location
- Not associated with renal duplication
- Not usually seen in utero

Congenital Megaureter

- Fusiform dilatation of ureter
- Hydronephrosis variable
- Usually unilateral (left > right)
- Mainly affects males
- Normal bladder

Other Causes of Renal Enlargement

- Multicystic dysplastic kidney
- Mesoblastic nephroma
- Beckwith-Wiedemann syndrome

- Associated with omphalocele, macroglossia
- Autosomal recessive polycystic kidney disease
 - Bilateral enlarged echogenic kidneys

PATHOLOGY

General Features

- Etiology
 - Ureteral bud divides or duplicates prematurely
 - Accessory ureteric bud also inserts into metanephric blastema
 - Each ureteric bud induces formation of nephrons
 - Left-sided more often than right
 - May be complete or partial duplication of collecting system
 - Partial more common
 - 2 pelvocaliceal systems with either 1 or 2 ureters, which join prior to bladder insertion
- Genetics
 - Sporadic
 - Reports of familial tendency
- Associated abnormalities
 - Gynecological anomalies in 50% of affected females
 - Renal anomalies (including duplications) are commonly present with other anomalies

CLINICAL ISSUES

Presentation

- Most common signs/symptoms
 - Usually incidental finding at routine ultrasound
 - Can be found during evaluation of fetal hydronephrosis

Demographics

- Most common congenital malformation of urinary tract
 - Unilateral in 83-90% of cases
 - Ureterocele in up to 50% of duplications
- More common in females

Natural History & Prognosis

- Prognosis depends on degree of renal damage from reflux and obstruction
- Prenatal diagnosis decreases risk of urosepsis and renal damage
 - Obstructed upper pole moiety prone to infection due to urinary stasis
 - When diagnosis is known, prophylactic antibiotics administered from birth
 - Decreases rate of neonatal urinary tract infection
- Improved outcome with prenatal vs. postnatal diagnosis
 - Much lower incidence of preoperative infection
 - Much lower recurrent infection after correction
 - Higher rate of resolution of reflux
 - Younger age at correction
- Early surgical intervention preserves renal function
 - Excellent prognosis with early correction
- If not diagnosed in utero, duplication with obstruction/reflux usually presents in infancy
 - Recurrent urinary tract infections
 - Hydronephrosis
 - Urinary retention
 - Unsuccessful toilet training in girls, epididymitis in boys

- From ectopic insertion

Treatment

- In utero treatment not usually indicated
 - Consider incision of ureterocele if causing bladder outlet obstruction and oligohydramnios
- Complete work-up after delivery
 - Urology consult
 - Ultrasound of kidneys and bladder
 - Voiding cystourethrogram (VCUG) to visualize dynamic nature of ureterocele
 - Drooping lily sign on VCUG
 - Reflux into lower pole moiety via normotopic ureter
 - Obstructed upper pole moiety pushes lower pole calyces inferiorly
 - Radionuclide renal scan to assess renal function
 - Intravenous pyelogram not usually necessary
 - Delayed nephrogram and pyelogram of upper pole moiety due to obstruction
 - Helpful to evaluate extravescicular ectopic ureteral insertion sites
 - MR
 - May be helpful in complex cases
 - Useful in females to evaluate associated gynecological abnormalities
- Postnatal surgical options based on severity of abnormality
 - Endoscopic incision of ureterocele
 - Particularly if infected or obstructed
 - May convert obstructing ureterocele into refluxing one
 - Ureteral reimplantation
 - Ureteroureterostomy
 - Ureteropyelostomy
 - Heminephroureterectomy
 - Performed if poorly functioning upper pole

DIAGNOSTIC CHECKLIST

Consider

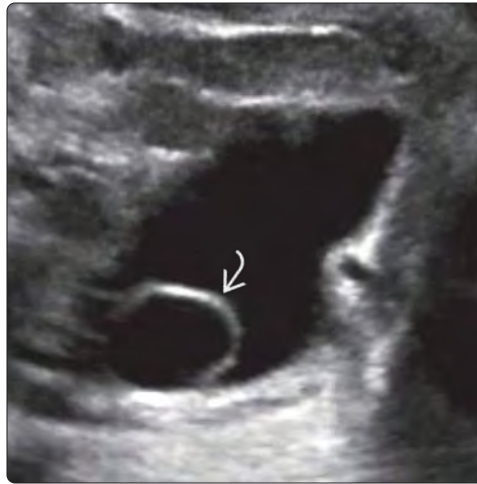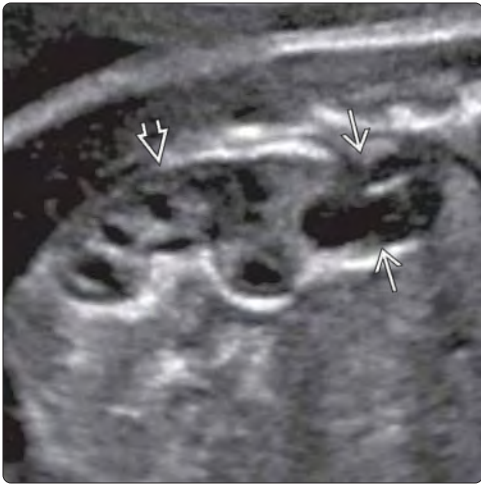- Always evaluate for duplication in presence of hydronephrosis (unilateral or bilateral)
- Postnatal pelvic ultrasound in females to search for associated gynecological malformations




Image Interpretation Pearls

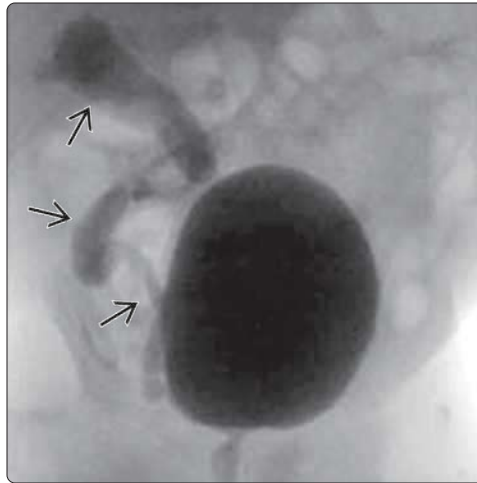
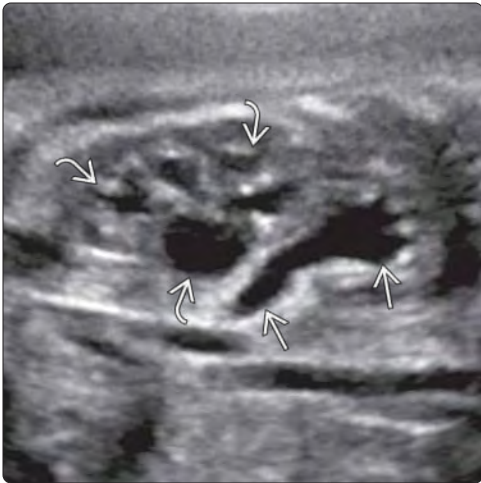
- Dilated upper pole moiety + cystic mass in bladder is diagnostic for duplication with ureterocele
- Majority of duplicated kidneys are > 95th percentile in length for gestational age




SELECTED REFERENCES

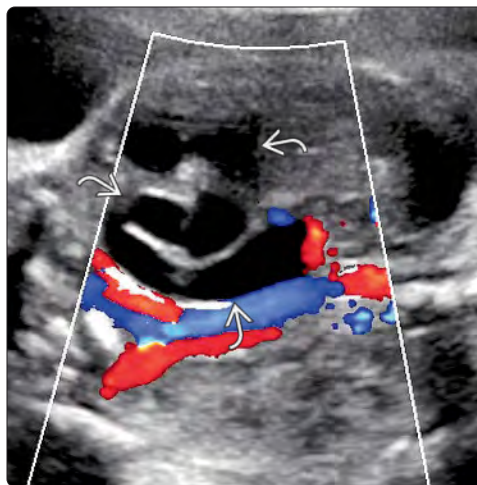
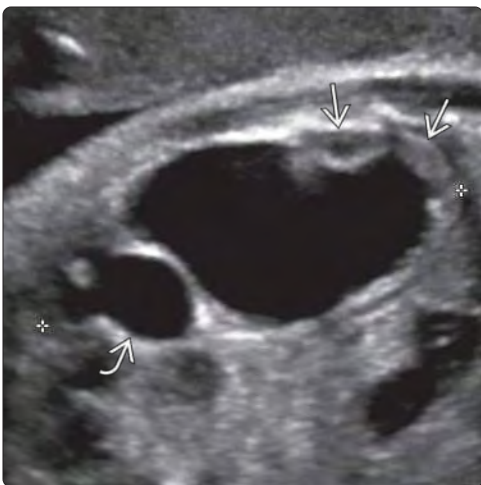
1. Dias T et al: Ultrasound diagnosis of fetal renal abnormalities. *Best Pract Res Clin Obstet Gynaecol.* 28(3):403-15, 2014
2. Lee NG et al: Evaluation of prenatal hydronephrosis: novel criteria for predicting vesicoureteral reflux on ultrasonography. *J Urol.* 192(3):914-8, 2014
3. Queiroga EE Jr et al: Antenatal diagnosis of renal duplication by ultrasonography: report on four cases at a referral center. *Urol J.* 10(4):1142-6, 2014
4. Godinho AB et al: Ureterocele: antenatal diagnosis and management. *Fetal Diagn Ther.* 34(3):188-91, 2013
5. Castagnetti M et al: Management of duplex system ureteroceles in neonates and infants. *Nat Rev Urol.* 6(6):307-15, 2009






(Left) In this renal duplication, the upper pole is a collection of unorganized cysts . Cysts may be present in the setting of cystic dysplasia from chronic upper pole obstruction. The lower pole  shows normal corticomedullary differentiation. **(Right)** In the fetal bladder, an ectopic ureterocele  has a balloon-like appearance at the bladder base. If large, these can prolapse and obstruct the bladder outlet.



(Left) At 32-weeks gestation, the upper pole is clearly distended with hydroureter , and the lower pole also demonstrates hydronephrosis  from reflux. **(Right)** Postnatal voiding cystogram of the same patient shows reflux of contrast into the lower pole collecting system , as typically seen in duplicated collecting systems.



(Left) At times, the hydronephrosis is severe and minimal residual renal parenchyma  is present around the obstructed upper pole. Especially when the lower pole is also dilated , the kidney can look like a cystic mass. To make the correct diagnosis, it is important to also look at the bladder and ureter. **(Right)** The ectopic ureter  is dilated to the level of the bladder (ureterocele not shown). The ureter can be differentiated from bowel by its anechoic contents, lack of peristalsis, and retroperitoneal location.

KEY FACTS

TERMINOLOGY

- Ectopic kidney located in pelvis

IMAGING

- Empty renal fossa with ipsilateral pelvic kidney
 - Check adjacent to iliac wing or bladder
 - May be smaller in size with abnormal morphology
- No contralateral compensatory renal hypertrophy
 - Unless nonfunctioning pelvic kidney
- Use color Doppler to find renal arteries
 - Variable blood supply to pelvic kidney
- Renal parenchymal morphology more easily identified later in gestation
 - Median 25-weeks gestation at diagnosis
- Can have concurrent renal pathology
 - Reflux, ureteropelvic junction obstruction, multicystic dysplastic kidney
- Consider MR if appearance suggests pelvic mass

TOP DIFFERENTIAL DIAGNOSES

- Unilateral renal agenesis
- Horseshoe kidney
- Pelvic mass

PATHOLOGY





- May be associated with dysplasia, hypoplasia, reduced renal function

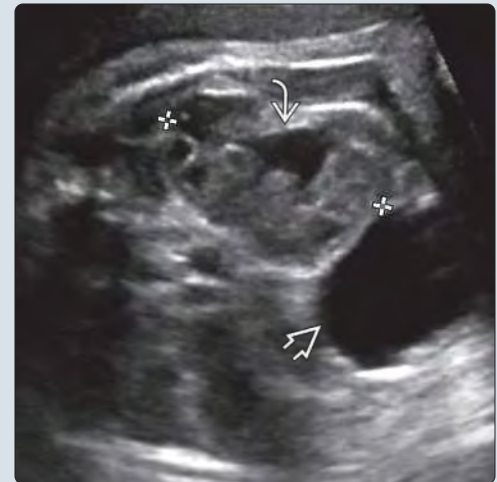
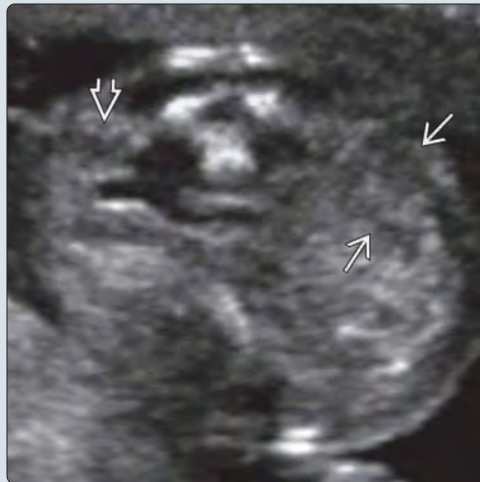CLINICAL ISSUES




- Usually incidental finding
- Up to 37% of fetuses with unilateral empty renal fossa actually have pelvic kidney
 - May not be readily identified until 3rd trimester

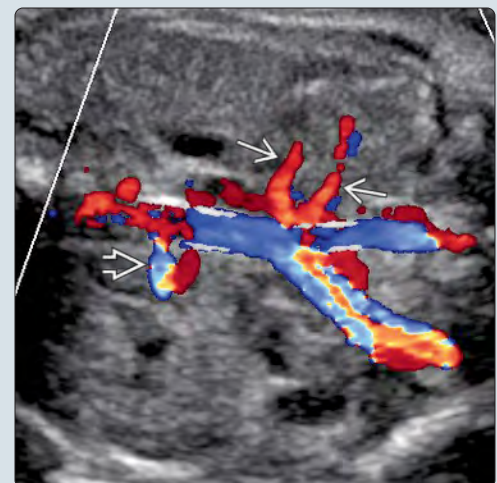
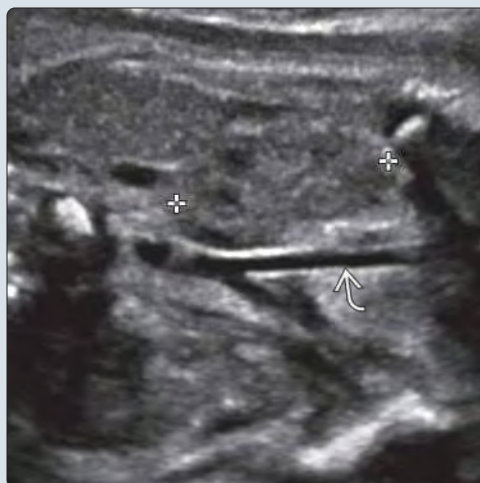DIAGNOSTIC CHECKLIST

- Follow-up US in later 2nd or 3rd trimester may help diagnose pelvic kidney in cases of apparent unilateral renal agenesis

(Left) Axial US through the renal fossa at 19-weeks gestation shows a single kidney . Bowel  fills the the opposite renal fossa and can be mistaken for a kidney. An empty renal fossa is the most common initial presentation of a pelvic kidney, as the ectopic kidney often cannot be identified early in pregnancy. **(Right)** Pelvic kidneys may have associated congenital renal anomalies. In this case, there is mild pelviectasis and malrotation, with the renal pelvis oriented anterolaterally  (bladder .



(Left) At 29 weeks, this right pelvic kidney (calipers) was identified adjacent to the right common iliac artery . The left kidney was normally located (not shown). **(Right)** Color Doppler can be very useful in finding a pelvic kidney in the case of an empty renal fossa. In this case, the left renal artery is normally located , and 2 right renal arteries originate near the aortic bifurcation .



TERMINOLOGY

Definitions

- Ectopic kidney located in pelvis

IMAGING

General Features

- Best diagnostic clue
 - Empty renal fossa
 - Ectopic kidney in fetal pelvis
- Location
 - Located superior to bladder
 - Off-midline or midline
- Size
 - May be smaller in size than normotopic kidney
- Morphology
 - May have abnormal morphology
 - Irregular shape
 - Rotation variable
 - Extrarenal calyces

Ultrasonographic Findings

- Grayscale ultrasound
 - Empty renal fossa
 - Adrenal gland fills empty renal fossa
 - Lying down appearance
 - Colon in empty renal fossa may mimic kidney
 - Up to 37% of fetuses with unilateral empty renal fossa actually have pelvic kidney
 - Pelvic kidney
 - Often difficult to see in early 2nd trimester
 - Echogenicity similar to bowel
 - Median 25-weeks gestation at diagnosis
 - Check adjacent to iliac wing or bladder
 - Renal parenchymal morphology more easily identified later in gestation
 - Look for hypochoic renal pyramids
 - Can have concurrent renal pathology
 - Reflux
 - Ureteropelvic junction obstruction
 - Cystic dysplasia due to chronic obstruction
 - Multicystic dysplastic kidney
 - No contralateral compensatory renal hypertrophy as with unilateral renal agenesis
 - Unless pelvic kidney is nonfunctioning
- Color Doppler
 - No renal artery to ipsilateral empty renal fossa
 - Variable blood supply to pelvic kidney
 - From 1 or more vessels off aorta or distal to aortic bifurcation

MR Findings

- Used only for problem solving
 - Helpful to differentiate pelvic kidney from bowel
 - Can help differentiate renal parenchyma from solid or cystic pelvic mass

Imaging Recommendations

- Be persistent in searching for absent kidney in cases of apparent unilateral renal agenesis

- Especially if no compensatory hypertrophy of existing kidney
- May find pelvic kidney in later 2nd or 3rd trimester

DIFFERENTIAL DIAGNOSIS

Unilateral Renal Agenesis

- Single kidney with compensatory hypertrophy

Horseshoe Kidney

- Asymmetric position of fusion may lead to appearance of unilateral low-lying kidney

Pelvic Mass

- Ovarian cyst
- Obstructed bowel
- Sacrococcygeal teratoma

PATHOLOGY

General Features

- Etiology
 - Renal parenchyma forms but not does ascend correctly during embryogenesis
 - May be associated with dysplasia, hypoplasia, reduced renal function

CLINICAL ISSUES

Presentation

- Most common signs/symptoms
 - Usually incidental finding

Demographics

- 37% of unilateral empty renal fossa
- Prevalence 1:713 live births

Natural History & Prognosis

- Often asymptomatic
- Complications later in life may occur
 - Vesicoureteral reflux with predisposition to urinary infections
 - Renal calculi
 - Renovascular hypertension

Treatment

- Postnatal US to confirm diagnosis
 - Consider looking for uterine anomalies in females
- Nuclear medicine evaluation of renal function

DIAGNOSTIC CHECKLIST

Image Interpretation Pearls

- Follow-up US in later 2nd or 3rd trimester may help diagnose pelvic kidney in cases of apparent unilateral renal agenesis

SELECTED REFERENCES

1. DeBenedictis CM et al: Incidental genitourinary findings on obstetrics/gynecology ultrasound. *Ultrasound Q.* 28(4):293-8, 2012
2. Batukan C et al: Prenatal diagnosis and postnatal outcome of pelvic kidneys. *Prenat Diagn.* 31(4):356-9, 2011
3. Oh KY et al: Prenatal diagnosis of renal developmental anomalies associated with an empty renal fossa. *Ultrasound Q.* 26(4):233-40, 2010

KEY FACTS

TERMINOLOGY

- Abnormality of fusion and ascent
- Kidneys fused in horseshoe configuration
- Isthmus = bridging tissue

IMAGING

- Can be symmetric or asymmetric
 - Left side more often longer/larger than right
- Kidneys more low-lying than usual
- Malrotation common
 - Lower poles medially oriented
 - Renal pelvis ventral to parenchyma in 97%
- Isthmus is anterior to aorta
 - May be parenchymal or fibrous
 - "Snags" on inferior mesenteric artery during ascent
- Color Doppler shows highly variable blood supply
- Can be associated with uteropelvic junction (UPJ) obstruction due to aberrant course of ureter

TOP DIFFERENTIAL DIAGNOSES





- Crossed fused renal ectopia

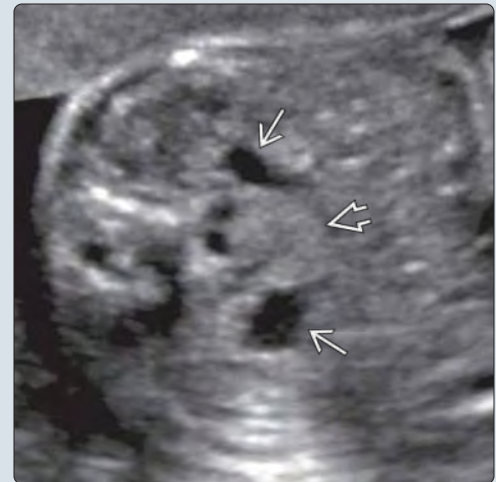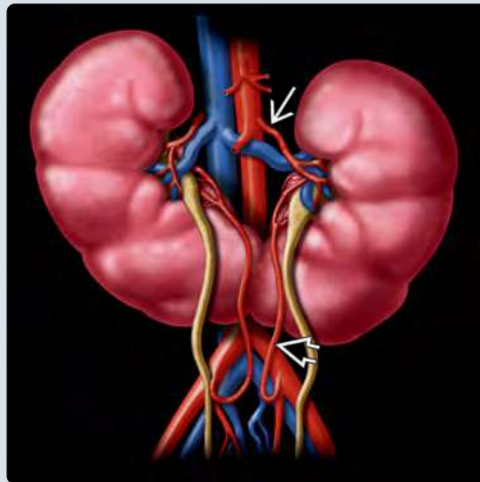
CLINICAL ISSUES





- 1:400 in general population
- Most cases clinically silent
- 1/3 of cases have other urogenital, gastrointestinal, cardiopulmonary, skeletal, or chromosomal anomalies
 - Turner syndrome most common aneuploidy
 - VACTERL association
- Prognosis depends on if associated aneuploidy or syndrome present
- No clinical or prognostic difference between horseshoe kidney and crossed fused renal ectopia

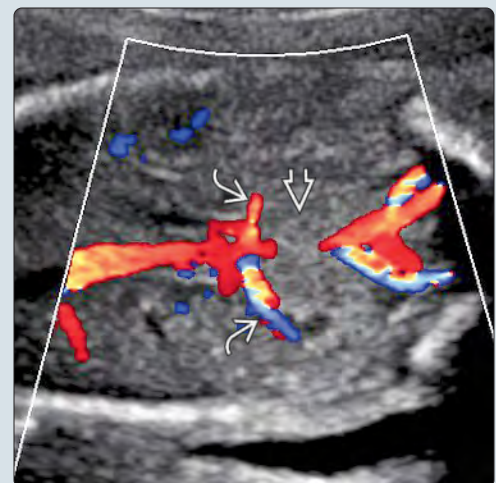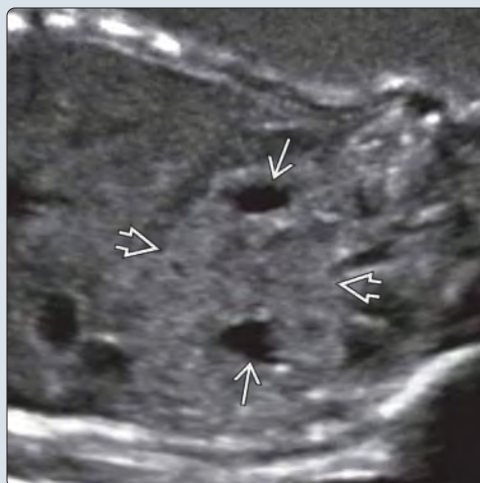
DIAGNOSTIC CHECKLIST

- Horseshoe kidney may be missed if isthmus is thin
 - Look for medial orientation of lower pole
- Look for associated anomalies

(Left) Graphic illustration of a horseshoe kidney shows medial deviation of the lower poles with a connecting isthmus across the midline. The blood supply is variable but most commonly comes from the aorta  &/or iliac arteries . **(Right)** Anteromedial orientation of the renal pelvis  can be a clue that a horseshoe kidney is present. Close inspection of the midline reveals renal parenchyma  bridging anterior to the aorta, even in the 2nd trimester.



(Left) A horseshoe kidney can appear deceptively like an abdominal mass . However, the parenchyma will have the hypoechoic medullary pyramids and relatively more echogenic cortex. The renal pelvis  can also be a clue that the "mass" is actually a horseshoe kidney. **(Right)** Coronal Doppler ultrasound in a different case shows an unusual curved course of the renal arteries  due to mass effect from the isthmus of the fused kidneys .



TERMINOLOGY

Definitions

- Kidneys fused in horseshoe configuration
 - Isthmus = bridging tissue

IMAGING

General Features

- Best diagnostic clue
 - Abnormal renal morphology
- Morphology
 - Horseshoe configuration
 - Most commonly lower pole fusion
 - Can be symmetric or asymmetric
 - Left side more often longer/larger than right
 - May have supernumerary ureters

Ultrasonographic Findings

- Grayscale ultrasound
 - Kidney lower poles connected by isthmus
 - Isthmus may be parenchymal or fibrous
 - Lower poles medially oriented
 - Malrotation common
 - Renal pelvis ventral to parenchyma in 97%
 - Look for anterior orientation of the renal pelvis
 - Kidneys more low-lying than usual
 - Bent or curved configuration in long axis
 - Tapering or elongation of lower pole
 - Poorly defined inferior edge of kidney
 - Upper pole fusion rare
 - Inverted horseshoe or doughnut morphology
 - Can be associated with ureteropelvic junction (UPJ) obstruction
 - Look for typical bullet-nosed appearance of renal pelvis
 - Ureter not dilated
- Color Doppler
 - Highly variable blood supply
 - Originates from aorta &/or iliac arteries
 - More rarely from inferior mesenteric artery, median sacral artery, or phrenic artery
 - Venous drainage also variable

Imaging Recommendations

- Coronal view helpful for orientation of kidneys
 - Also for identifying anterior midline isthmus tissue
- Most accurate imaging in 3rd trimester

DIFFERENTIAL DIAGNOSIS

Crossed Fused Renal Ectopia

- Both kidneys on 1 side
- Most commonly inferior pole of 1 fused to superior pole of other kidney

PATHOLOGY

General Features

- Etiology
 - Abnormality of fusion and ascent

- Isthmus prevents ascent due to mechanical obstruction by inferior mesenteric artery
- Fusion prevents medial rotation and results in anteriorly directed hila
- Lower pole of kidneys fused most commonly
 - Isthmus is anterior to aorta
 - "Snags" on inferior mesenteric artery during ascent
 - ◻ Results in relatively low-lying kidney(s)
- Ureter insertion onto renal pelvis most often superior and laterally displaced
 - Can lead to impaired drainage

CLINICAL ISSUES

Presentation

- Most common signs/symptoms
 - Incidentally found
 - Less common cause of unilateral empty renal fossa
 - Pelvic kidney more common
 - Aberrant ureteral course can lead to UPJ obstruction

Demographics

- Epidemiology
 - 1:400 in general population
 - M:F ratio ~ 2:1

Natural History & Prognosis

- Most cases clinically silent
 - Urolithiasis most common complication in 21-60%
 - Urinary tract infections more common due to impaired drainage
 - Risk of renal injury in trauma found to be similar to general population
- 1/3 of patients have other urogenital, gastrointestinal, cardiopulmonary, skeletal, or chromosomal anomalies
 - Turner syndrome
 - Trisomy 18
 - Hypospadias/cryptorchidism
 - VACTERL association
 - Prognosis depends on if aneuploidy or syndrome is present
- No clinical or prognostic difference between horseshoe kidney and crossed fused renal ectopia

Treatment

- Confirm with postnatal renal ultrasound
 - Consider including uterus in females

DIAGNOSTIC CHECKLIST

Image Interpretation Pearls

- Horseshoe kidney may be missed if isthmus is thin
 - Better clue may be medial orientation of lower pole
- Look for associated anomalies

SELECTED REFERENCES

1. Schiappacasse G et al: CT findings of the main pathological conditions associated with horseshoe kidneys. *Br J Radiol.* 88(1045):20140456, 2015
2. Yavuz S et al: Renal outcome of children with horseshoe kidney: a single-center experience. *Urology.* 85(2):463-6, 2015
3. Natsis K et al: Horseshoe kidney: a review of anatomy and pathology. *Surg Radiol Anat.* 36(6):517-26, 2014

KEY FACTS

TERMINOLOGY

- Both kidneys on same side of fetus

IMAGING

- Unilateral empty renal fossa
 - Adrenal gland fills empty renal fossa
 - Colon in empty renal fossa may mimic kidney
- Ectopic kidney frequently malrotated
 - Variable arterial supply to both ectopic kidney and normally situated kidney
 - 2 renal arteries on side of ectopic kidney
 - Subtypes based on orientation of ectopic kidney and location of fusion
- Ureter crosses midline to insert normally at bladder
- Look for hypochoic medullary pyramids to identify ectopic renal parenchyma
- 90% of crossed renal ectopic kidneys fused with other kidney
 - Remainder unfused in various configurations

TOP DIFFERENTIAL DIAGNOSES

- Asymmetric horseshoe kidney
- Unilateral renal agenesis
- Pelvic kidney

PATHOLOGY

- Associated findings
 - Imperforate anus
 - Skeletal abnormalities
 - Uterine anomalies

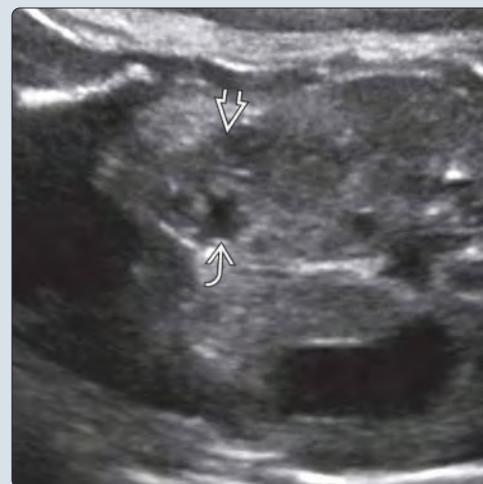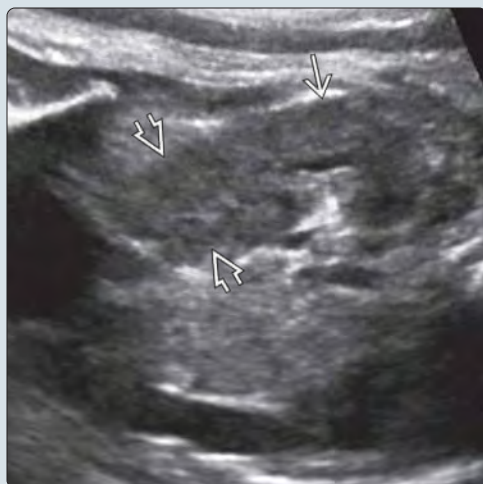
CLINICAL ISSUES

- Most often asymptomatic throughout life
- Left-to-right crossover > right to left

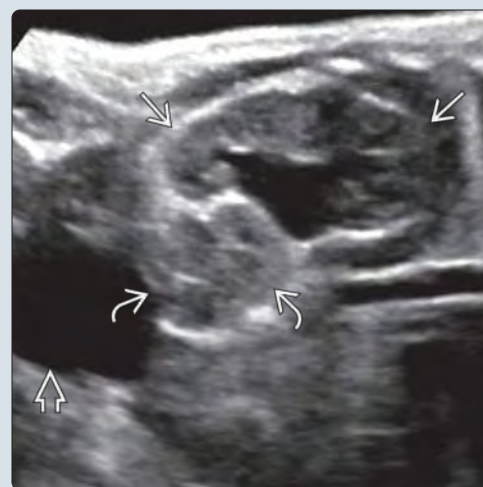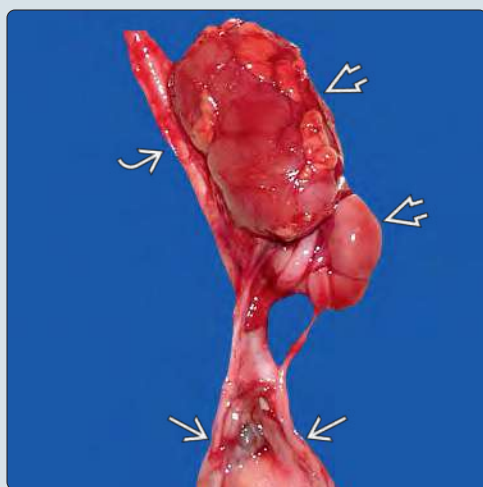
DIAGNOSTIC CHECKLIST

- Empty renal fossa not always renal agenesis
 - Look for ectopic or pelvic kidney
- Evaluate visible kidney for morphology, size, blood supply

(Left) Longitudinal US through the retroperitoneum of a 2nd-trimester fetus shows a normotopic right kidney with an apparent mass attached to the inferior pole. Note the echogenicity is similar to renal tissue. **(Right)** Imaging more anteriorly through the mass shows it is actually the cross-fused left kidney. The left renal pelvis helps confirm the diagnosis.



(Left) Autopsy specimen from a different case shows both kidneys fused on the same side of the aorta. Note that the ureter of the ectopic kidney crosses the midline and both ureters have a normal course as they enter the bladder. **(Right)** Coronal US at 36 weeks shows a right kidney with pelviectasis. There is an ectopic smaller left kidney on the same side that adjoins the lower pole of the right kidney just above the bladder.



TERMINOLOGY

Synonyms

- Ectopic kidney
- Cross-fused ectopic kidney

Definitions

- Abnormal fusion of developing kidneys
- Both kidneys on same side of fetus

IMAGING

General Features

- Best diagnostic clue
 - Empty renal fossa
 - Abnormal renal morphology of remaining kidney
- Morphology
 - Ectopic kidney frequently malrotated
 - Rotation of renal pelvis related to developmental time of fusion
 - Ureter crosses midline to insert normally at bladder
 - Subtypes include
 - Inferior ectopia
 - Sigmoid or S-shaped
 - Lump or cake
 - L-shaped or tandem
 - Disc, shield, or doughnut
 - Superior ectopia

Ultrasonographic Findings

- Grayscale ultrasound
 - Empty renal fossa
 - Usually assessed on axial view
 - Confirm on longitudinal view
 - Adrenal gland fills empty renal fossa
 - Lying down appearance
 - Globular instead of triangular
 - Can mimic kidney
 - Colon in empty renal fossa may mimic kidney
 - Abnormal morphology of remaining kidney
 - 90% of crossed renal ectopic kidneys fused with other kidney
 - Remainder unfused in various configurations
 - Fusion causes atypical, bilobed, enlarged kidney
 - More caudal position, greater axial rotation than horseshoe kidneys
- Color Doppler
 - 2 renal arteries on side of morphologically abnormal kidney
 - Variable arterial supply to both ectopic kidney and normally situated kidney
 - Various levels of aorta
 - Iliac artery

MR Findings

- Can be useful if suspect pelvic mass is actually developmental fusion anomaly

Imaging Recommendations

- Assessing for hypoechoic medullary pyramids can help identify ectopic renal parenchyma
- Use Doppler to confirm ectopic renal artery

DIFFERENTIAL DIAGNOSIS

Asymmetric Horseshoe Kidney

- Fusion anomaly usually at lower poles

Pelvic Kidney

- Ectopic kidney in fetal pelvis ipsilateral to empty renal fossa

Unilateral Renal Agenesis

- Complete absence of 1 kidney

PATHOLOGY

General Features

- Etiology
 - Fusion of metanephric blastema
- Associated abnormalities
 - Imperforate anus (4%)
 - Skeletal abnormalities (4%)
 - Uterine anomalies
 - More rare associated abnormalities
 - Cardiovascular septal defects
 - Hypospadias
 - Cryptorchidism
 - Urethral valves

CLINICAL ISSUES

Presentation

- Usually incidental finding
- If other anomalies, query aneuploidy or syndromes

Demographics

- 1:7,000 live births
- M:F ~ 3:2
- Left-to-right crossover > right to left

Natural History & Prognosis

- Most often asymptomatic throughout life
- Similar risk of urinary tract complications as horseshoe kidney
 - Infections, nephrolithiasis, hydronephrosis

Treatment

- Postnatal US to confirm diagnosis
 - May wish to include uterus in females

DIAGNOSTIC CHECKLIST

Image Interpretation Pearls

- Empty renal fossa not always renal agenesis
 - Carefully evaluate visible kidney for morphology, size, blood supply
 - Look for ectopic or pelvic kidney
- Asymmetric horseshoe kidney may mimic crossed fused ectopic kidney

SELECTED REFERENCES

1. Bhatt K et al: Crossed fused renal ectopia. *J Urol.* 191(2):475-6, 2014
2. Yin Z et al: A new subtype of crossed fused ectopia of the kidneys. *Urology.* 84(6):e27, 2014
3. Chang PL et al: Prenatal diagnosis of cross-fused renal ectopia: does color Doppler and 3-dimensional sonography help? *J Ultrasound Med.* 30(4):578-80, 2011

Bilateral Renal Agenesis

KEY FACTS

TERMINOLOGY

- Absence of renal tissue

IMAGING

- Anhydramnios in 2nd/3rd trimester
- No kidneys identified in renal fossa or elsewhere in fetal abdomen
- No urine in fetal bladder
- Color Doppler used to assess for renal arteries
 - If parenchyma not visible, check for arteries to infer presence/absence of kidneys
- Adrenal glands can be mistaken for kidneys
 - Fetal adrenal glands are relatively large, almost same size as kidneys early in gestation
 - Occupy renal fossa in absence of kidneys
 - Can represent potential pitfall in diagnosis of agenesis
- Associated findings
 - Pulmonary hypoplasia
 - Clubfeet, other joint contractures

PATHOLOGY

- Failed induction of metanephric blastema by ureteric bud leads to lack of nephron formation

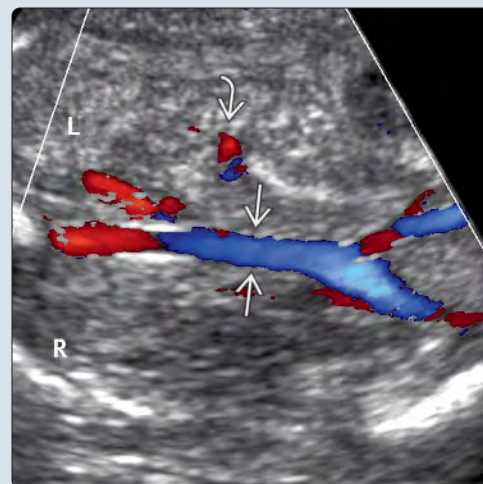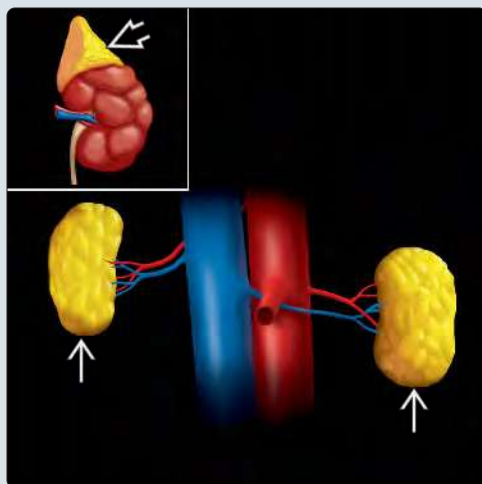
CLINICAL ISSUES

- Amniotic fluid is normal in 1st trimester, even with bilateral renal agenesis
 - Minimal renal contribution to amniotic fluid volume until after 16 weeks
- Bilateral agenesis is lethal
- Potter sequence (oligohydramnios sequence)
 - Uterine compression and lack of movement associated with abnormal facies, limb deformities
- Recurrence risk 3%
- Can be seen in aneuploidy and as part of syndrome

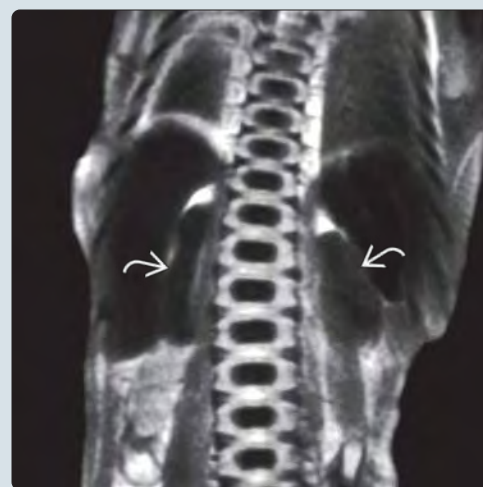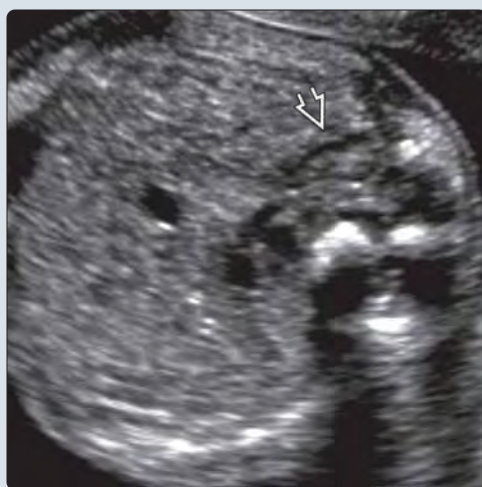DIAGNOSTIC CHECKLIST

- Consider fetal MR in setting of anhydramnios for confirmation of renal agenesis

(Left) Graphic shows the relatively large size of the normal fetal adrenal gland compared with the kidney (inset). In the setting of renal agenesis, the adrenal glands lose their triangular shape and have a flattened appearance, filling the renal fossa, and potentially being mistaken for kidneys. **(Right)** At 18-weeks gestation, there is anhydramnios with no renal parenchyma identified, and color Doppler of the aorta shows no renal arteries. The splenic artery can be a potential mimic of a renal artery.



(Left) Axial ultrasound after amnioinfusion shows no kidneys at the level of the renal fossa and a prominent adrenal gland. **(Right)** Coronal autopsy MR through the level of the renal fossa shows the prominent adrenal glands in the setting of renal agenesis. Note the flattened, lying down appearance of glands, which is typically present when the ipsilateral kidney is absent.



TERMINOLOGY

Synonyms

- Potter syndrome
 - Anhydramnios associated with abnormal facies, limb deformities
 - Not pathognomonic of renal agenesis
 - Can be seen with multiple causes of anhydramnios

Definitions

- Absence of renal tissue

IMAGING

Ultrasonographic Findings

- Anhydramnios in 2nd/3rd trimester
 - Normal fluid may be seen up to 16 weeks
- Lying down, flattened adrenals
 - Adrenal gland does not fold into normal Y or tricorn hat configuration if kidney is absent
 - Fetal adrenal glands are relatively large
 - Almost same size as kidneys early in gestation
 - Occupy renal fossa in absence of kidneys
- Absent bladder
 - Bladder anatomically present but cannot be visualized
 - No urine being produced
- Color Doppler
 - No demonstrable renal arteries
 - Usually originate from descending aorta at 90° angle
 - Look for bladder between umbilical arteries
- Associated findings
 - Pulmonary hypoplasia
 - Overall thorax size appears small compared to abdomen
 - Clubfeet, other joint contractures
 - Congenital heart disease in 14%
- 2-vessel cord seen with many renal anomalies
- Amnioinfusion can be performed to improve anatomy evaluation

MR Findings

- Normal urinary tract
 - Normal kidneys well seen by 15-weeks gestation
 - Renal parenchyma is intermediate signal
 - Urine in collecting system is high signal on T2WI
 - Adrenal glands lower signal than normal renal parenchyma
 - Signal approximates that of skeletal muscle
- Bilateral renal agenesis
 - No demonstrable renal tissue
 - Flattened, discoid adrenals in renal fossa
 - No urine in fetal bladder
 - Anhydramnios
- Perform all 3 scan planes to avoid false-positive diagnosis
 - Check for pelvic kidney or other anatomic variant

Imaging Recommendations

- **Beware pitfalls** in diagnosis of renal agenesis
 - Differentiate kidneys from adrenal glands
 - Fetal adrenals very prominent, especially early in gestation

- Adrenal hypertrophy described in pathologic series of renal agenesis
- Adrenals normally have ice cream sandwich or layered appearance
 - Echogenic adrenal medulla between layers of hypoechoic cortex
 - In renal agenesis, adrenals have flattened, discoid, lying down appearance
- Normal kidneys do not have layered appearance
 - Kidneys are bean-shaped in long axis, oval or round in cross section
 - Corticomedullary differentiation is evident, with hypoechoic pyramids (becomes more obvious with advancing gestation)
- Color Doppler shows flow in multiple abdominal vessels, which may be confused for renal arteries
 - Adrenal arteries are present and may be enlarged with adrenal hypertrophy
 - Lumbar arteries may also be mistaken for renal arteries
 - Celiac axis, superior mesenteric artery arise from aorta anteriorly rather than laterally
- Empty bladder
 - Watch for real-time changes of bladder
 - If change in size and shape seen, there must be some urine production
 - Would exclude diagnosis of bilateral renal agenesis
 - May see small bladder containing mucus secretion, especially with MR
 - Do not mistake for urine production
- Use endovaginal ultrasound
 - Fetal kidneys can be seen as early as 12 weeks
- Consider fetal MR for better anatomic visualization

DIFFERENTIAL DIAGNOSIS

Causes for Oligohydramnios

- **Premature rupture of membranes**
 - Fetal bladder will fill and empty
 - Kidneys present and normal
 - May be difficult to visualize if no fluid
 - Utilize color Doppler to assess for renal arteries
 - Correlate with clinical history
 - Can usually give history of gush of fluid
 - Sterile speculum examination for diagnosis
 - Rarely can reseal with relative increase in fluid
- **Severe fetal growth restriction**
 - Kidneys present and normal
 - Fetal bladder will fill and empty
 - Umbilical artery Doppler likely abnormal
- **Bilateral multicystic dysplastic kidneys**
 - Kidneys present
 - Renal parenchyma replaced with variably sized cysts
 - Most often leads to functional renal agenesis with anhydramnios
- **Autosomal recessive polycystic kidney disease**
 - Enlarged, hyperechoic kidneys present
 - Often > 2 standard deviations above mean for gestational age
 - Little to no urine in bladder
 - Oligo-/anhydramnios

- Fetal MR shows high signal intensity renal parenchyma
 - May see small discrete cysts

Causes for Absent Bladder

- No urine formation
 - Poor renal perfusion
 - In twin-twin transfusion syndrome, donor twin shunts blood to recipient
 - Donor renal perfusion is decreased
 - Decreased perfusion → decreased urine production → absent bladder
 - Abnormal/absent renal parenchyma
 - Bilateral multicystic dysplastic kidneys
- Bladder exstrophy
 - Urine produced as usual → normal amniotic fluid volume
 - Bladder open to abdominal wall
 - Look for soft tissue mass inferior to cord insertion
- Bladder rupture
 - Urinary ascites will be present
 - Usually associated with distal obstruction (e.g., posterior urethral valves)
 - Look for secondary obstructive nephropathy

PATHOLOGY

General Features

- Etiology
 - Failed induction of metanephric blastema by ureteric bud
 - No nephron formation
 - Some studies suggest association with maternal diabetes, prepregnancy obesity, smoking, early alcohol consumption
 - 2nd-trimester anhydramnios
 - Renal contribution to amniotic fluid is minimal until 16 weeks
 - Placenta/membranes responsible for majority of amniotic fluid volume prior to 16 weeks
- Genetics
 - Trisomy 7, 10, 21, 22
 - Branchio-oto-renal dysplasia syndrome
 - Autosomal dominant with variable expression
 - Renal anomalies, including agenesis
 - Deafness/malformed ears/branchial cysts
 - Cerebro-occulo-facial syndrome
 - Autosomal recessive
 - Micrognathia, joint contractures, renal anomalies
- Associated abnormalities
 - **Potter sequence (oligohydramnios sequence)**
 - Physical findings secondary to lack of movement and compression by uterine wall
 - Characteristic facies: Broad, flattened, beaked nose, low-set ears, receding chin, widely separated eyes with prominent infraorbital folds
 - Clubbed hands and feet
 - Renal agenesis may be part of VACTERL association
 - Vertebral, anorectal, cardiac anomalies, tracheoesophageal fistula, renal and limb anomalies
 - Sirenomelia
 - Fused lower extremities
 - Need to look at extremities carefully

- Often difficult to see secondary to anhydramnios
- Absence of normally tapered lumbosacral spine
- Bilateral renal agenesis, bilateral multicystic dysplastic kidneys

CLINICAL ISSUES

Presentation

- Oligohydramnios/anhydramnios

Demographics

- Gender
 - M:F ~ 3:1
- Epidemiology
 - 1:4-6,000 births

Natural History & Prognosis

- Bilateral agenesis is lethal
 - 33% stillborn
 - Survivors die of respiratory failure due to pulmonary hypoplasia
 - Longest documented survival 39 days
- Recurrence risk 3%
 - Higher if part of multiple anomaly complex

Treatment

- Counseling based on presence of lethal fetal anomaly
 - Offer termination as appropriate
 - If pregnancy continued, stress importance of nonintervention at birth

DIAGNOSTIC CHECKLIST

Consider

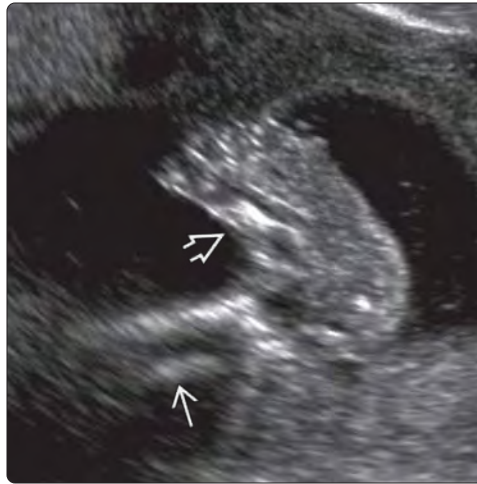
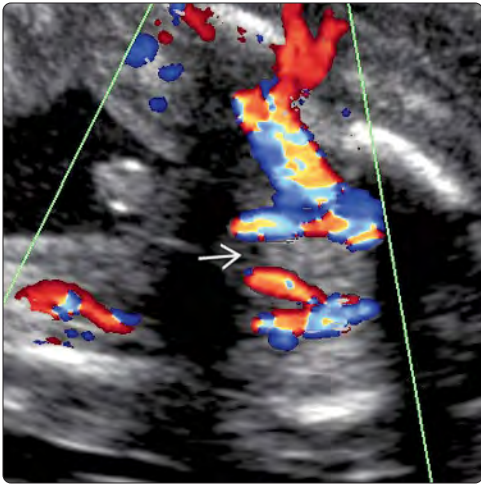
- Any condition with early onset severe oligohydramnios carries poor prognosis
 - Bilateral renal agenesis is lethal
 - Aim to make specific diagnosis in order to counsel parents appropriately

Image Interpretation Pearls

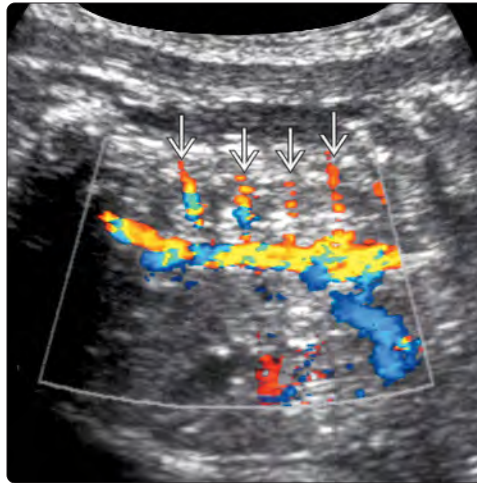
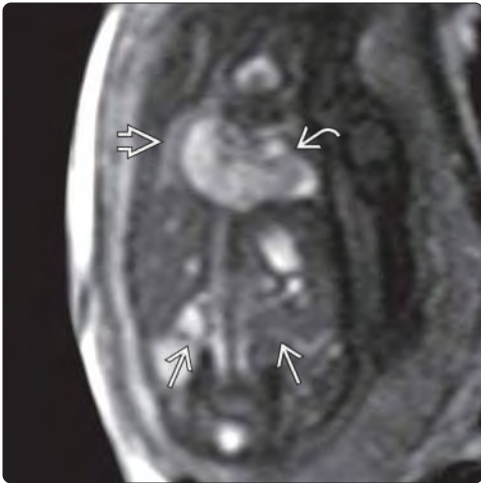
- Amniotic fluid volume is normal in 1st trimester, even with bilateral renal agenesis
- Adrenal glands can be mistaken for kidneys
 - Normal adrenal gland has ice cream sandwich appearance
 - Use MR in difficult cases

SELECTED REFERENCES

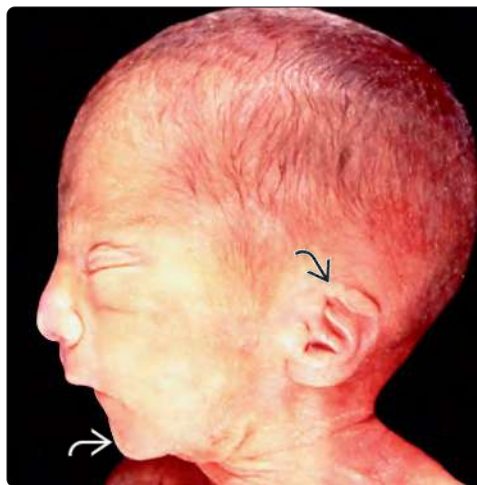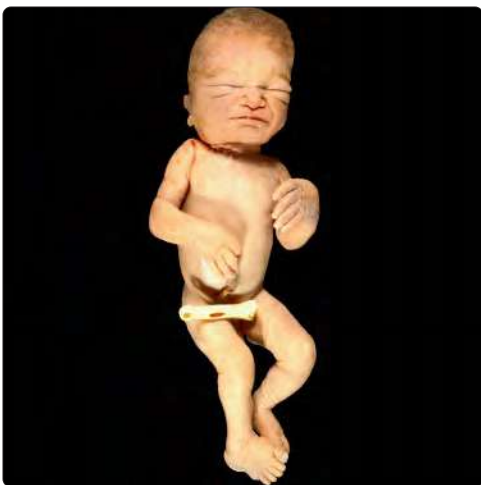1. Spiro JE et al: Renal oligo- and anhydramnios: cause, course and outcome—a single-center study. *Arch Gynecol Obstet.* 292(2):327-36, 2015
2. Ulkumen BA et al: Outcomes and management strategies in pregnancies with early onset oligohydramnios. *Clin Exp Obstet Gynecol.* 42(3):355-7, 2015
3. Geçer T et al: Complementary role of magnetic resonance imaging after ultrasound examination in assessing fetal renal agenesis: a case report. *J Med Case Rep.* 8:96, 2014
4. Manoj MG et al: Potter's syndrome - a fatal constellation of anomalies. *Indian J Med Res.* 139(4):648-9, 2014
5. Shastry SM et al: Potter's sequence. *J Clin Neonatol.* 1(3):157-9, 2012
6. Grijseels EW et al: Outcome of pregnancies complicated by oligohydramnios or anhydramnios of renal origin. *Prenat Diagn.* 31(11):1039-45, 2011
7. Harewood L et al: Bilateral renal agenesis/hypoplasia/dysplasia (BRAHD): postmortem analysis of 45 cases with breakpoint mapping of two de novo translocations. *PLoS One.* 5(8), 2010



(Left) Axial color Doppler US shows that in the expected location between the umbilical arteries, there is no visible bladder (→) (post amnioinfusion). The bladder is anatomically present in renal agenesis; however, lack of urine production causes the bladder to remain collapsed. (Right) US shows that after amnioinfusion, other fetal anomalies are more readily assessed. Clubfeet (→) and other joint contractures are commonly present (tibia and fibula (→)).



(Left) Coronal fetal MR for suspected bilateral renal agenesis shows no visible renal tissue (→). Note the complete lack of any amniotic fluid around the fetus. The chest is small, with the heart (→) essentially filling the thorax and only a small crescent of lung visible (→). (Right) Coronal color Doppler ultrasound shows multiple lumbar arteries (→) in this case of renal agenesis. This is a potential pitfall in attempted identification of the renal arteries.



(Left) Clinical photograph of a term infant born with renal agenesis shows the classic wrinkled skin with deep creases and abnormal positioning of the extremities due to lack of fluid. (Right) Profile view of the same infant shows the typical facies in the Potter sequence. The nose is flattened, the ears are low-set and abnormally folded (→), and there is micrognathia (→).

Ureteropelvic Junction Obstruction

KEY FACTS

IMAGING

- Renal pelvis and calyceal dilation ending abruptly at ureteropelvic junction (UPJ) is hallmark finding
- Any calyceal dilation is abnormal
 - Show that calyces connect with renal pelvis
- Kidney is often enlarged
- Renal pelvis is bullet-shaped
- Postobstructive renal dysplasia if severe
 - ↑ renal echogenicity
 - Cortical renal cysts
- Normal ureters and bladder if unilateral UPJ
- Associations
 - Contralateral renal abnormality in 25%
 - Bilateral UPJ obstruction in 10%
 - Extrarenal anomalies in 10%

TOP DIFFERENTIAL DIAGNOSES

- Multicystic dysplastic kidney
- Normal renal pyramids mimicking dilated calyces

- Upper pole dilation from lower tract obstruction

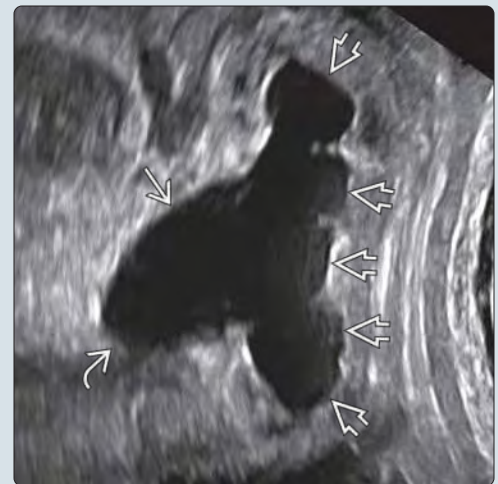
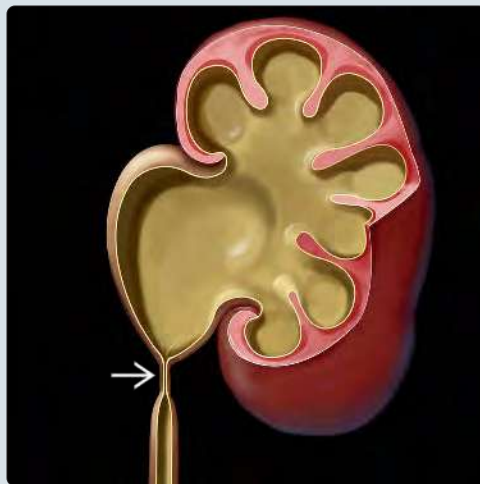
CLINICAL ISSUES

- Most common significant cause of prenatal urinary tract dilatation (UTD)
- 1:2,000 live births
- Prognosis excellent if unilateral
- Many resolve spontaneously and need no treatment
- ↑ risk of renal impairment if prenatal AP diameter ≥ 10 mm
- Corrective surgery highly successful in improving renal function

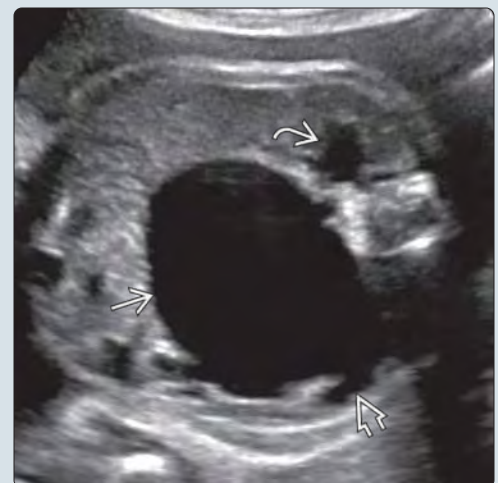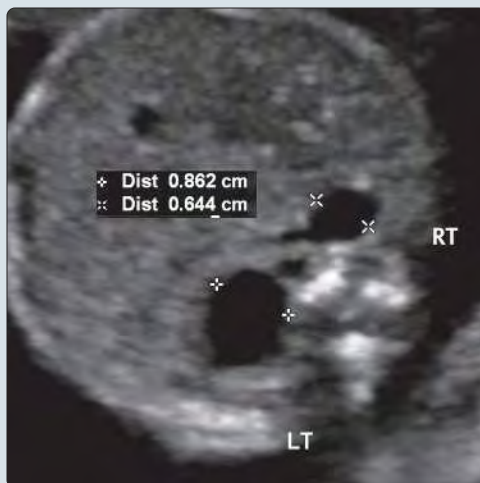DIAGNOSTIC CHECKLIST

- Use UTD classification system
 - Stratifies risk
 - Standardizes prenatal and postnatal follow-up
- UPJ may progress rapidly
- Monitor contralateral kidney

(Left) Graphic shows focal narrowing at the ureteropelvic junction (UPJ) causing renal pelvis and calyceal dilation. Notice the abrupt transition between the distended renal pelvis and the ureter. **(Right)** Coronal ultrasound of a fetus with left renal urinary tract dilation shows the classic bullet-shaped morphology of UPJ obstruction. The markedly distended renal pelvis is elongated and ends abruptly at the UPJ. The calyces are markedly dilated and blunted.



(Left) Axial ultrasound of the kidneys at 20 weeks shows bilateral renal pelvis dilation, left > right. UTD classification is 2-3 (moderate risk) because the left renal pelvis AP diameter is > 7 mm. **(Right)** At 32 weeks, in the same fetus, the left renal pelvis is massively dilated, and there is calyceal dilation and parenchymal thinning. The right renal pelvis measured < 7 mm (normal). The bladder, ureters, and amniotic fluid were normal. Postnatal diagnosis was high-grade UPJ obstruction requiring surgery.



TERMINOLOGY

Abbreviations

- Ureteropelvic junction (UPJ) obstruction

Synonyms

- Congenital hydronephrosis

Definitions

- Upper urinary tract obstruction at UPJ

IMAGING

General Features

- Best diagnostic clue
 - Dilation of renal pelvis and calyces without ureter or bladder distention
- Location
 - L > R
 - 10-40% bilateral

Ultrasonographic Findings

- Renal pelvis distention is hallmark finding
 - Elongated, funnel-shaped renal pelvis ends abruptly at UPJ
 - Obstruction can markedly progress in utero
 - ↑ anterior-posterior renal pelvis diameter (APRPD)
 - ≥ 4 mm between 16-27 weeks
 - ≥ 7 mm ≥ 28 weeks
- Dilated calyces
 - Show calyces connect with renal pelvis to differentiate from cysts
 - When severe, calyces may be flat and barely distend from renal pelvis
- Kidney is often enlarged
 - Cortical thinning common when severe
- Postobstructive renal dysplasia if severe
 - ↑ renal echogenicity at 1st
 - Loss of corticomedullary differentiation
 - May be difficult to see in fetus
 - Kidney echogenicity > liver is abnormal
 - Renal cysts (seen late)
 - Cortical and small at 1st
- Urinoma with high-grade obstruction (rare)
 - Fluid collection adjacent to obstructed kidney
 - Does not ↓ risk of renal damage
 - Is not considered "pop-off" valve with subsequent saving of renal function
- Otherwise normal ureter and bladder is key finding
- Bilateral UPJ obstruction in 10%
- Contralateral renal abnormality in 25%
 - Multicystic dysplastic kidney
 - Renal agenesis
 - Vesicoureteric reflux (diagnosed after delivery)
- Extrarenal anomalies in 10%
- Amniotic fluid findings most important prognosticator
 - Most often normal with unilateral UPJ obstruction
 - Oligohydramnios if bilateral severe renal anomalies
 - Fetus at risk for pulmonary hypoplasia
 - Polyhydramnios in minority of cases
 - ↓ renal concentrating ability → ↑ urine output

Imaging Recommendations

- Best imaging tool
 - Obtain axial and longitudinal views of kidneys
- Protocol advice
 - APRPD at time of diagnosis and parenchymal appearance determines follow-up recommendations
 - Amniotic fluid assessment very important
 - Look for signs of obstructive cystic dysplasia
 - Postnatal evaluation depends on severity
 - Postnatal ultrasound (> 48 hours after delivery for mild cases)
 - Voiding cystourethrogram
 - Functional scan

DIFFERENTIAL DIAGNOSIS

Multicystic Dysplastic Kidney

- Kidney tissue replaced by cysts (reniform shape often lost)
- May mimic postobstructive cystic dysplasia
- Poor or absent renal function

Lower Urinary Tract Dilation as Cause of Upper Tract Dilation

- Look for dilated bladder ± dilated ureters
- Bladder outlet obstruction
 - Enlarged bladder often thick walled
 - Posterior urethral valves most common diagnosis
- Prune-belly syndrome
- Vesicoureteral reflux (rarely diagnosed prenatally)

Normal Renal Pyramids

- Hypoechoic parenchymal pyramids may mimic calyx dilation
- Pyramids are superficial to calyces
- Pyramids more triangular than round
 - Pyramid point ends in calyx

PATHOLOGY

General Features

- Etiology
 - Abnormal UPJ interwoven muscularis layer
 - Impairs distensibility
 - 1/3 have accessory crossing vessel
 - Vessel lies anterior to UPJ
 - Perhaps leaves fibrous scar
 - Abnormal neural innervation at UPJ
 - Hirschsprung equivalent
- Genetics
 - Sporadic
 - Isolated cases are not associated with aneuploidy
- Associated abnormalities
 - 25% with contralateral renal anomaly
 - 10% with bilateral UPJ obstruction
 - 10% with nongenitourinary anomalies

Staging, Grading, & Classification

- Urinary tract dilation (UTD) classification system
 - Low-risk group is UTD A1 (A: Antenatal)
 - APRPD 4 to < 7 mm at 16-27 weeks
 - APRPD 7 to < 10 mm at ≥ 28 weeks
 - Low risk is isolated APRPD without calyceal dilation

Urinary Tract Dilation Prenatal Follow-Up Recommendations

Time of Diagnosis	US Findings	Follow-Up and Recommendations
16-27 weeks	Isolated APRPD of 4 to < 7 mm	1 additional follow-up at ≥ 32 weeks
16-27 weeks	≥ 7 mm APRPD (even if isolated) or calyceal dilation or parenchymal abnormality	Follow-up in 4-6 weeks (more expedient if bilateral or oligohydramnios); consider specialist consultation
≥ 28 weeks	Isolated APRPD of 7 to < 10 mm	1 additional follow-up at ≥ 32 weeks
≥ 28 weeks	≥ 10 mm APRPD (isolated) or peripheral calyceal dilation or parenchymal abnormality	Follow-up in 4-6 weeks (more expedient if bilateral or oligohydramnios); consider specialist consultation

APRD = anterior-posterior renal pelvis diameter.

Modified from Nguyen HT et al: Multidisciplinary consensus on the classification of prenatal and postnatal urinary tract dilation (UTD classification system). *J Pediatr Urol.* 10(6):982-98, 2014.

- Intermediate risk group is UTD A2-3
 - APRPD ≥ 7 mm at 16-27 weeks
 - APRPD ≥ 10 mm at ≥ 28 weeks
 - Significant isolated APRPD considered intermediate risk since calyceal dilation may be difficult to see when renal pelvis is markedly dilated
- Any additional parenchymal findings in setting of any renal pelvis dilation is UTD A2-3

Gross Pathologic & Surgical Features

- Junction of pelvis with ureter usually patent
 - Complete atresia rare

CLINICAL ISSUES

Presentation

- Most common signs/symptoms
 - Incidental unilateral finding at time of anatomy scan or follow-up for other reason
 - In association with contralateral renal anomaly
 - In association with amniotic fluid abnormality

Demographics

- Epidemiology
 - UPJ obstruction accounts for 10-30% of cases of UTD detected on antenatal ultrasound
 - 1:2,000 live births. M > F (2:1)

Natural History & Prognosis

- Excellent prognosis for unilateral UPJ
- Most with partial obstruction
- ↑ risk of renal impairment if prenatal AP diameter ≥ 10 mm
 - Prognosis still excellent if normal contralateral kidney
- Factors associated with poor prognosis
 - Bilateral renal anomalies
 - Solitary kidney affected
 - Early oligohydramnios
 - Pulmonary hypoplasia from oligohydramnios
 - Other (nongenitourinary) anomalies
- Postnatal presentation
 - Abdominal mass or pain
 - Urinary tract infection
 - Hematuria
- Standard neonatal work-up
 - Ultrasound > 48 hours after delivery if mild
 - Voiding cystourethrogram to evaluate for reflux

- Nuclear medicine renal scan for renal function
- Other possible imaging
 - CT angiography
 - Look for crossing renal artery
 - MR urography

Treatment

- Prenatal intervention rarely indicated
- Many resolve spontaneously and need no treatment
- Corrective surgery if renal function impaired
 - Pyeloplasty (95% success, 5% recurrence)
 - Open surgery
 - Resection of narrow UPJ segment
 - Endoscopic surgery
 - Endopyelotomy
 - Must know if crossing vessel present
 - Percutaneous drainage
 - Temporizing measure
 - Infection control

DIAGNOSTIC CHECKLIST

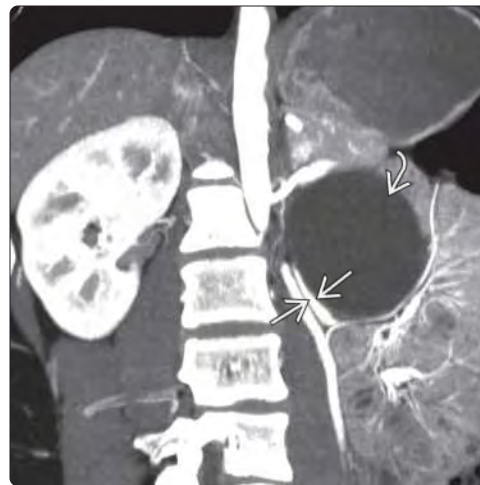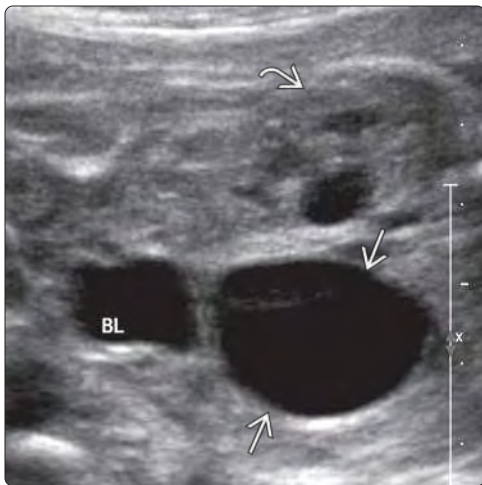
Image Interpretation Pearls

- Renal pelvis may elongate and touch bladder
 - Do not confuse for distended ureter
- Severe UPJ obstruction may look like unilocular cyst
 - Renal calyces may be dilated and effaced
 - Look for thin renal parenchyma
- Normal renal pyramids are hypoechoic and can mimic renal calyces

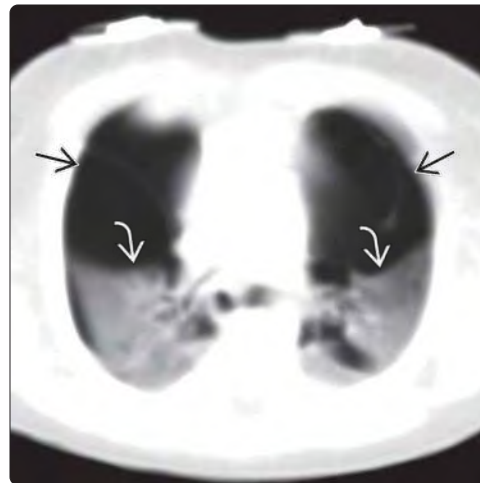
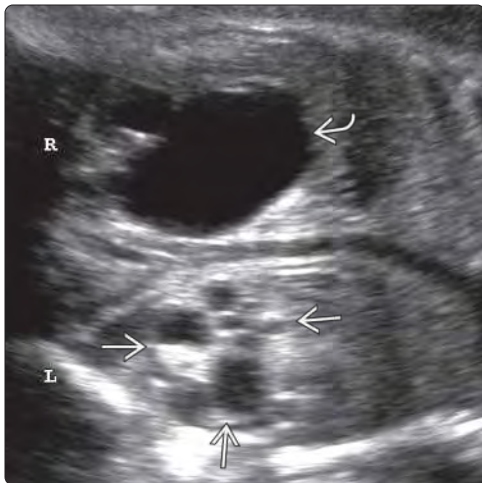
SELECTED REFERENCES

1. Rianthavorn P et al: Diagnostic accuracy of neonatal kidney ultrasound in children having antenatal hydronephrosis without ureter and bladder abnormalities. *World J Urol.* 33(10): 1645-50, 2015
2. Kumar M et al: Fetal renal anomaly: factors that predict survival. *J Pediatr Urol.* 10(6):1001-7, 2014
3. Nguyen HT et al: Multidisciplinary consensus on the classification of prenatal and postnatal urinary tract dilation (UTD classification system). *J Pediatr Urol.* 10(6):982-98, 2014
4. Ross SS et al: Observation of infants with SFU grades 3-4 hydronephrosis: worsening drainage with serial diuresis renography indicates surgical intervention and helps prevent loss of renal function. *J Pediatr Urol.* 7(3):266-71, 2011
5. Yang Y et al: Long-term follow-up and management of prenatally detected, isolated hydronephrosis. *J Pediatr Surg.* 45(8):1701-6, 2010
6. Thomas DF: Prenatally diagnosed urinary tract abnormalities: long-term outcome. *Semin Fetal Neonatal Med.* 13(3):189-95, 2008

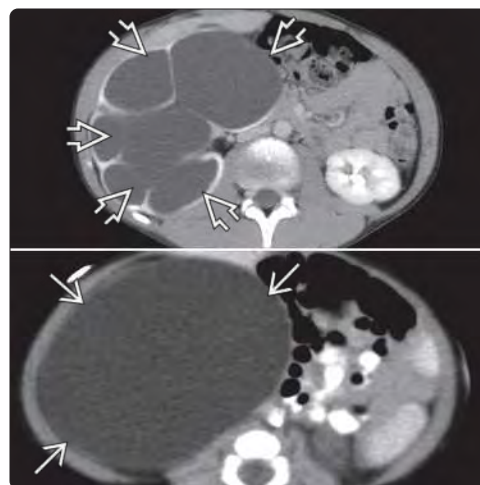
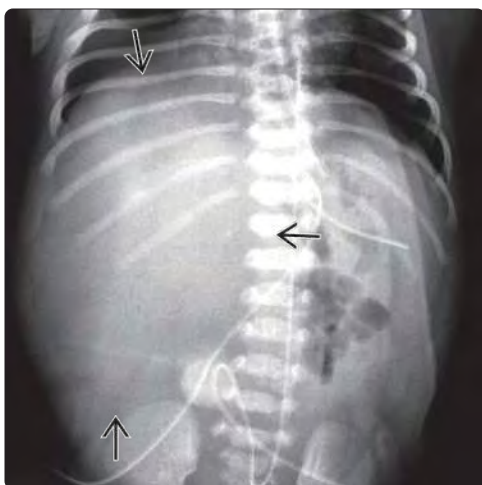
Ureteropelvic Junction Obstruction



(Left) Coronal ultrasound of the kidneys shows a dilated renal pelvis extending to the bladder. The elongated dilated pelvis should not be mistaken for a unilocular cyst or dilated ureter. The contralateral kidney is normal. **(Right)** Reconstructed coronal CT shows a UPJ obstruction from an accessory crossing artery. The left renal pelvis is distended and an accessory left renal artery is seen at the inferior margin of the distended renal pelvis.



(Left) Coronal ultrasound through the kidneys of a fetus with bilateral renal anomalies shows a right-sided UPJ obstruction and left-sided multicystic dysplastic kidney. There was early severe oligohydramnios. **(Right)** Neonatal chest CT of the same patient shows small lungs and bilateral large pneumothoraces, sequelae of severe pulmonary hypoplasia from longstanding oligohydramnios. Twenty-five percent of fetuses with UPJ obstruction have contralateral renal anomalies.



(Left) Frontal radiograph of a neonate with right-sided UPJ obstruction diagnosed in utero shows mass effect from an enlarged obstructed right kidney. Massive renal collecting system dilation in the fetus and neonate can mimic other abdominal masses and cause mass-related symptoms. **(Right)** CECT findings of severe UPJ obstruction shown in 2 cases demonstrate severe collecting system dilation. There is massive distention of the renal pelvis and calyces, as well as significant renal cortical thinning.

KEY FACTS

TERMINOLOGY

- Encapsulated collection of urine within Gerota fascia caused by urine leakage from severe renal obstruction

IMAGING

- Anechoic fluid around or abutting obstructed kidney
 - Elliptical or crescentic
- Associated severe renal obstruction
 - Ureteropelvic junction (UPJ) obstruction
 - Posterior urethral valves
 - Look for associated dilated bladder
 - Echogenic and cystic renal parenchyma
- MR may show displaced kidney better

TOP DIFFERENTIAL DIAGNOSES

- Lymphangioma
- Mesenteric cyst
- Enteric duplication cyst
- Meconium pseudocyst

- UPJ with massive renal pelvis distention
- Multicystic dysplastic kidney

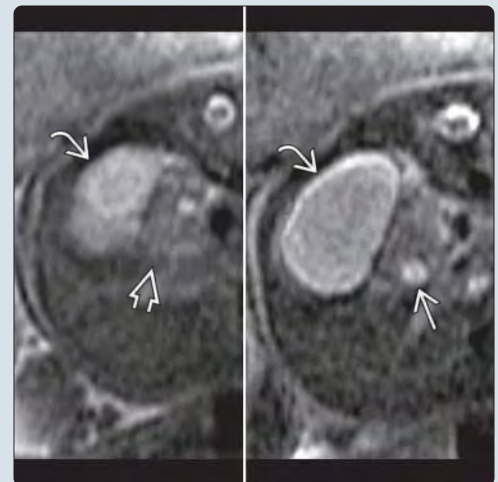
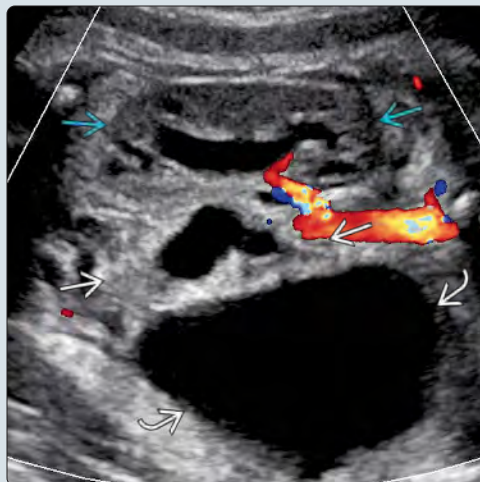
CLINICAL ISSUES

- Previous theory that urinoma is pop-off mechanism with better prognosis is not true
- Presence of urinoma is proof that obstruction is severe and prognosis is worse
- Fetal urinoma may resolve in utero or after delivery
 - Often reflects oliguria of affected kidney
 - Does not change prognosis
- Consider urinoma drainage if abdominal dystocia
 - Drainage does not help renal function

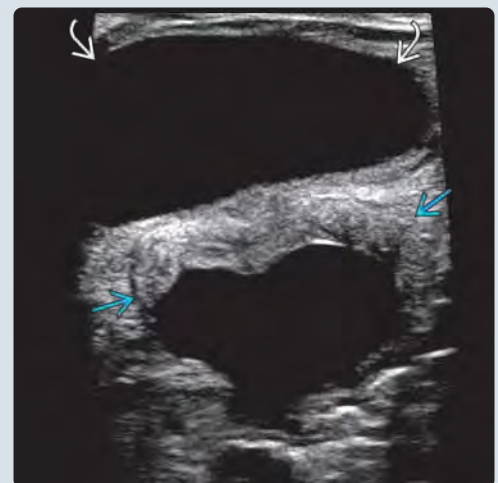
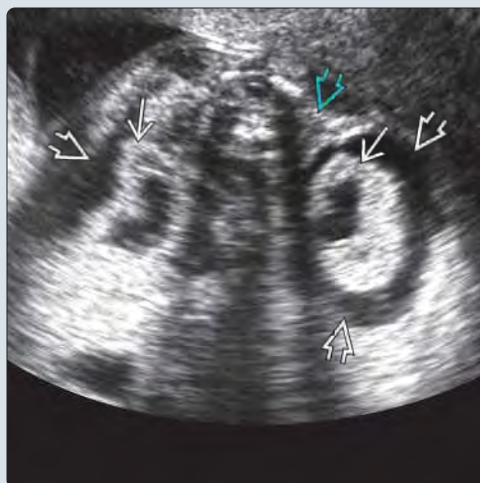
DIAGNOSTIC CHECKLIST

- Fluid collection touching lateral lumbar spine originates from most likely urinary tract
- Suggest surveillance ultrasound for contralateral kidney, amniotic fluid, and urinoma size

(Left) In this fetus with ureteropelvic junction (UPJ) obstruction, a urinoma displaces the kidney medially. The contralateral kidney is seen well. Notice that the severely obstructed affected kidney has echogenic renal parenchyma when compared to the contralateral kidney. **(Right)** Fetal MR shows a urinoma displacing the kidney medially. Note the cyst. Postobstructive renal parenchymal change is often seen in conjunction with urinomas since both are sequelae of severe obstruction.



(Left) In this fetus with posterior urethral valves, bilateral urinomas surround echogenic kidneys. Urinomas may be crescentic, as in this case, or elliptical. Almost always, the fluid has some contact with the lateral lumbar spine, as seen in this case. **(Right)** In a newborn with UPJ obstruction and urinoma, the unilocular urinoma displaces and compresses the atrophic echogenic kidney with hydronephrosis. This kidney showed no evidence for function on renal scintigraphy testing.



TERMINOLOGY

Definitions

- Encapsulated collection of urine within Gerota fascia caused by urine leakage from severe renal obstruction

IMAGING

General Features

- Best diagnostic clue
 - Unilocular flank cyst that displaces kidney
- Location
 - Right = left
- Size
 - Might be so large that kidney is distorted and displaced
- Morphology
 - Elliptical or crescentic

Ultrasonographic Findings

- Anechoic fluid around or abutting obstructed kidney
 - If large, will displace kidney and other organs
 - Kidney may be difficult to see
 - Unilocular more likely than septated fluid
 - 60% unilateral
- Associated severe renal obstruction
 - Ureter pelvic junction (UPJ) obstruction
 - Posterior urethral valves (PUV)
 - Variable renal parenchyma findings of obstruction
 - Echogenic parenchyma ± cysts
 - Variable amount of urinary tract dilation
 - Bladder ± ureter distention if PUV

MR Findings

- MR may aid in showing displaced kidney

DIFFERENTIAL DIAGNOSIS

Lymphangioma

- Multiseptated infiltrative mass
- More common in chest

Mesenteric Cyst

- Intraperitoneal cyst
- May compress kidney toward spine

Enteric Duplication Cyst

- Duodenal may mimic perinephric fluid collection
- Look for laminated bowel signature

Meconium Pseudocyst

- Look for additional meconium calcifications

UPJ With Massive Renal Pelvis Distention

- May mimic cyst
- Look for adjoining "cysts" of distended calyces

Multicystic Dysplastic Kidney

- Multiple cysts replace parenchyma
- Kidney loses reniform shape

PATHOLOGY

General Features

- Etiology

- High-grade obstruction → calyceal microperforation
 - Less likely renal pelvis perforation
- Most common causes of high-grade obstruction
 - PUV
 - UPJ obstruction

Gross Pathologic & Surgical Features

- Fluid beneath renal fascia or in retroperitoneal spaces
 - Leaked urine causes lipolysis, inflammation, fibrosis

CLINICAL ISSUES

Presentation

- Most common signs/symptoms
 - Secondary finding in fetus with obstructive uropathy
- Other signs/symptoms
 - May be misdiagnosed as renal or abdominal cyst

Demographics

- Gender
 - 70% of fetuses with urinoma are male
- Epidemiology
 - 3-17% of newborns with PUV have urinoma

Natural History & Prognosis

- Previous theory that urinoma is pop-off mechanism with better prognosis is not true
- Presence of urinoma suggests presence of severe urinary obstruction
- All kidneys with urinoma are subsequently shown to have decreased or no function
- Fetal urinoma may resolve in utero or after delivery
 - Often reflects oliguria of affected kidney
 - Does not change prognosis

Treatment

- Consider urinoma drainage if concerned about abdominal dystocia
- Drainage does not help renal function
- Urinomas reaccumulate if kidney is still functioning

DIAGNOSTIC CHECKLIST

Image Interpretation Pearls

- Fluid collection touching lateral lumbar spine most likely originates from urinary tract
- Look for displaced kidney anteromedial or posterolateral to urinoma
 - Consider MR helpful in identifying ipsilateral kidney
- Kidney with urinoma is probably nonfunctional; follow contralateral kidney and amniotic fluid carefully

SELECTED REFERENCES

1. Maki E et al: Imaging and differential diagnosis of suprarenal masses in the fetus. *J Ultrasound Med.* 33(5):895-904, 2014
2. Yitta S et al: The fetal urinoma revisited. *J Ultrasound Med.* 33(1):161-6, 2014
3. Stathopoulos L et al: Prenatal urinoma related to ureteropelvic junction obstruction: poor prognosis of the affected kidney. *Urology.* 76(1):190-4, 2010
4. Gorincour G et al: Fetal urinoma: two new cases and a review of the literature. *Ultrasound Obstet Gynecol.* 28(6):848-52, 2006
5. Kleppe S et al: Impact of prenatal urinomas in patients with posterior urethral valves and postnatal renal function. *J Perinat Med.* 34(5):425-8, 2006

Obstructive Renal Dysplasia

KEY FACTS

TERMINOLOGY

- Obstructive renal dysplasia (ORD)
- Genitourinary tract obstruction → renal parenchymal destruction and cyst formation

IMAGING

- ↑ echogenicity of renal parenchyma
 - Renal echogenicity > liver
 - Cortical cysts
- Variable urinary tract dilation (UTD)
- Ultrasound shows ORD progression
 - UTD → ↑ renal echogenicity → small peripheral cortical cysts → large cysts
- Amniotic fluid volume is variable
 - Bilateral ORD → severe oligohydramnios
- Causes of ORD
 - Posterior urethral valves in male fetus
 - Cloaca or urogenital sinus in female fetus
 - Ureteropelvic junction obstruction

- Vesicoureteral junction obstruction
- MR is helpful with difficult cases
 - Severe oligohydramnios limits ultrasound
 - Cystic kidneys have high signal on T2WI

TOP DIFFERENTIAL DIAGNOSES

- Multicystic dysplastic kidney
- Nonobstructive renal dysplasia
- Autosomal recessive polycystic kidney disease

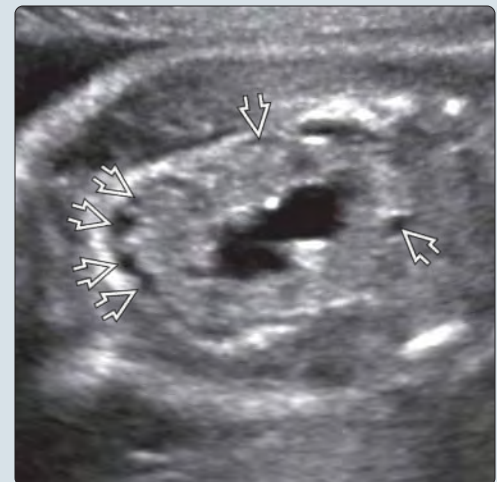
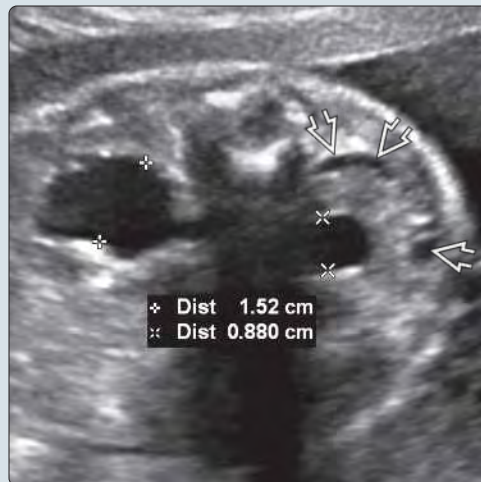PATHOLOGY

- Obstruction → ↑ pressure, fluid retention in nephrons → cortical cysts

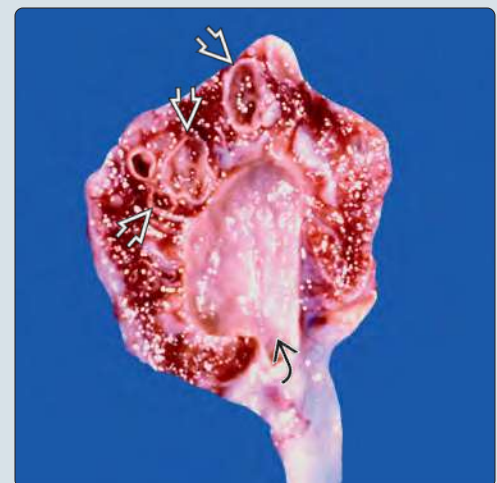
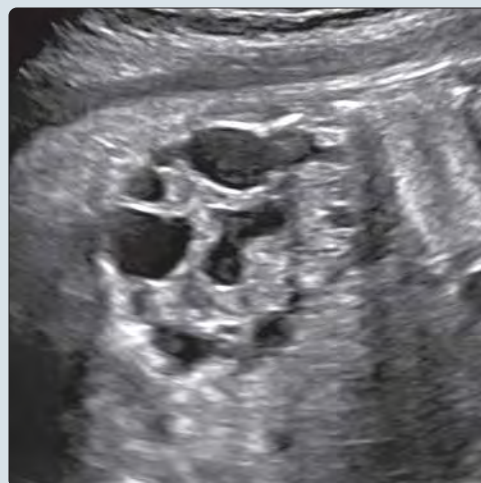
DIAGNOSTIC CHECKLIST

- Hyperechoic kidneys are predictive of renal dysplasia in 95% of cases
- Look for renal macrocysts in all cases of UTD
 - Form in subcortical area 1st

(Left) In this fetus with bilateral renal pelvis dilation, the left renal pelvis anteroposterior (AP) diameter (x calipers) is less than the right (+ calipers). However, subtle subcortical cysts ⊠ are seen, suggesting the obstruction has caused renal dysplasia. **(Right)** Coronal view through the same left kidney shows the peripheral cortical cysts ⊠ to better advantage (called rosary bead sign when they line up). Also, note the increased renal parenchymal echogenicity and loss of corticomedullary differentiation.



(Left) In the 3rd trimester of the same fetus with bilateral ureteropelvic junction (UPJ) obstruction, the cortical cysts have increased in size and further parenchymal cysts have formed. This progression is typically seen. **(Right)** Gross pathology of obstructive renal dysplasia shows renal pelvis distention ⊠ and variable-sized cysts ⊠ within the dysplastic renal parenchyma. The kidney is small and dysplastic from longstanding obstruction. Renal size is variable with obstructive renal dysplasia, especially during fetal life.



TERMINOLOGY

Abbreviations

- Obstructive renal dysplasia (ORD)
- Urinary tract dilation (UTD)

Synonyms

- Cystic renal dysplasia
- Congenital obstructive uropathy

Definitions

- Genitourinary tract (GU) obstruction → renal parenchymal destruction and cyst formation

IMAGING

General Features

- Best diagnostic clue
 - Echogenic kidneys ± macrocysts + UTD
- Location
 - Bilateral from lower urinary tract obstruction (LUTO)
 - Unilateral from upper tract obstruction
 - Segmental (rare) from partial GU obstruction

Ultrasonographic Findings

- **Increased echogenicity of renal parenchyma**
 - Renal echogenicity > liver
 - Loss of corticomedullary distinction (CMD)
 - However, CMD is often difficult to see in normal fetus (especially in 2nd trimester)
- **Cortical cysts**
 - Peripheral early cysts ("rosary beads")
 - Progression leads to variable-sized cysts
 - variable number cysts (many small vs. few large)
 - Kidney may be completely replaced by cysts
- Variable renal collecting system dilation
 - Renal size may be ↑, ↓, or normal
 - ↓ size suggests late finding
 - Kidney tends to maintain reniform shape
- Ultrasound shows ORD progression
 - UTD → ↑ renal echogenicity → small peripheral cortical cysts → large cysts
- Amniotic fluid volume is variable
 - Unilateral process with normal fluid
 - Bilateral ORD → oligohydramnios
- **Common causes of UTD → ORD**
 - LUTO
 - Posterior urethral valves (PUV) in male fetus
 - ◻ Distended thick-walled bladder
 - ◻ Keyhole morphology of urethra
 - ◻ ± dilated ureters
 - Cloaca or urogenital sinus in female fetus
 - ◻ Look for dilated fluid-filled vagina
 - Urethral atresia is rare (male and female)
 - Ureteropelvic junction (UPJ) obstruction
 - UTD affects only pelvis and calyces
 - ◻ Bullet-shaped renal pelvis at ureter junction
 - Must differentiate cysts from distended calyces
 - Bilateral UPJ in up to 1/3 of cases
 - Vesicoureteral junction obstruction
 - + ureterocele (balloon-like structure in bladder)

- ◻ Associated with renal duplication
- ◻ Upper pole ureter with ureterocele
- 1° vesicoureteral junction obstruction (rare)
 - ◻ Serpiginous dilated ureter mimics distended bowel

Imaging Recommendations

- Protocol advice
 - Look for ORD in all cases with UTD
 - Evaluate renal parenchyma echogenicity
 - ◻ Long view of right kidney showing liver
 - ◻ Long view of left kidney showing spleen
 - ◻ Normal renal echogenicity is similar to liver/spleen
 - Adequate bladder imaging is key for all fetuses with UTD
 - LUTO is most common cause of ORD
 - Look for bladder emptying and filling
 - Note bladder wall thickness (subjective)
 - Subjectively and objectively assess amniotic fluid
 - Short-term follow-up for fluid and kidney appearance
 - Sex of fetus is important for differential diagnosis
 - Document genitalia even if family does not want to know sex of baby

MR Findings

- MR is helpful with difficult cases
 - Poor visualization 2° to oligohydramnios
 - Massive bladder or ureter distention obscures kidneys
- Cystic kidneys have high signal on T2WI
 - Might see cysts not seen with ultrasound

DIFFERENTIAL DIAGNOSIS

Multicystic Dysplastic Kidney

- Renal tissue completely replaced by cysts
 - Kidney often loses reniform shape
 - Probably from ureter/pelvic infundibular atresia
 - Can look identical to late ORD
- Associated UTD not seen (key difference from ORD)
- Almost all have no significant renal function
- Survival depends on function of contralateral kidney
 - 20% bilateral multicystic dysplastic kidney (MCDK)
 - 40% with contralateral renal anomaly

Upper Urinary Tract Dilation (Severe Hydronephrosis)

- Distended calyces may be mistaken for cysts
 - Look for calyces connection with renal pelvis
 - Longitudinal views best
- UPJ obstruction most common cause
- Severe cases with dilated calyces + parenchymal cysts

Nonobstructive Renal Dysplasia

- Most often 2° to aneuploidy/syndromes
- Rarely isolated finding
- Common chromosome abnormalities
 - Trisomy 18, 13
- Syndromes
 - Meckel-Gruber syndrome
 - Cystic kidneys
 - Occipital cephalocele
 - Polydactyly
 - Tuberous sclerosis

- von Hippel-Lindau disease

Autosomal Recessive Polycystic Kidney Disease

- Bilateral large echogenic kidneys
 - From ↑ interfaces 2° to tubular ectasia
- Variable amount of function
- Severe oligohydramnios most common

PATHOLOGY

General Features

- Etiology
 - Obstruction → ↑ pressure, fluid retention in nephrons → cortical cysts
 - Cysts disturb nephron/tubular induction → ↓ number of normal nephrons
- Associated abnormalities
 - Pulmonary hypoplasia
 - Most important determinant of prognosis

Gross Pathologic & Surgical Features

- Earliest cysts are in subcapsular nephrogenic zone

Microscopic Features

- Cysts can develop in any portion of nephron
 - Glomeruli
 - Tubules
 - Collecting ducts
- Islands of normal nephrons between cysts
 - Unlike MCDK where normal nephrons are rarely seen

CLINICAL ISSUES

Presentation

- Most common signs/symptoms
 - Unilateral ORD most often noted on routine exam
 - UTD + renal cysts
 - Oligohydramnios from bilateral ORD
 - Uterine size small for dates
 - Distended fetal bladder
- Other signs/symptoms
 - Additional non-GU anomalies: ↑ risk for aneuploidy/syndromes

Demographics

- Gender
 - M > F (UPJ and LUTO more prevalent in male fetuses)

Natural History & Prognosis

- All cases with sonographic features of ORD will have some renal insufficiency
 - Depends on number of healthy nephrons
 - Fetal urinary analytes do not accurately predict function but are drawn if bladder drainage considered
 - New discovery of renal function biomarkers may predict postnatal renal function better
 - 12 fetal urinary peptides identified
 - Still requires bladder tap to evaluate
- Bilateral ORD with ↑ morbidity and mortality
 - Early severe oligohydramnios → pulmonary hypoplasia
 - Early PUV with worst prognosis
 - Almost all cases of PUV < 25 weeks have ORD

Treatment

- Fetal interventional procedures
 - Some studies show increased survival due to decreased severity of pulmonary hypoplasia
 - Most studies show drainage procedures **do not** improve renal function
 - Antenatal bladder drainage for LUTO
 - Placement of vesicoamniotic shunt
 - Fetoscopy with PUV resection (developing area of study)
 - Scope placed into bladder via trocar through fetal abdominal wall
 - PUV visualized and surgically resected
 - Inherent risks to fetus and mom with all procedures
 - Overall survival after intervention is 40-50%
 - Shunt complications (45% in 1 large series)
 - Preterm labor and delivery
- Newborn work-up and treatment
 - Ultrasound 1st to confirm diagnosis
 - Nuclear medicine renal scan to assess function
 - Treat cause of GU obstruction
 - Posterior urethral valve repair
 - Surgery for severe UPJ obstruction
 - Ureterocele surgical treatment
 - Renal transplant when necessary
 - Male fetuses with outflow obstruction account for 70% of renal transplants in children < 5 years

DIAGNOSTIC CHECKLIST

Consider

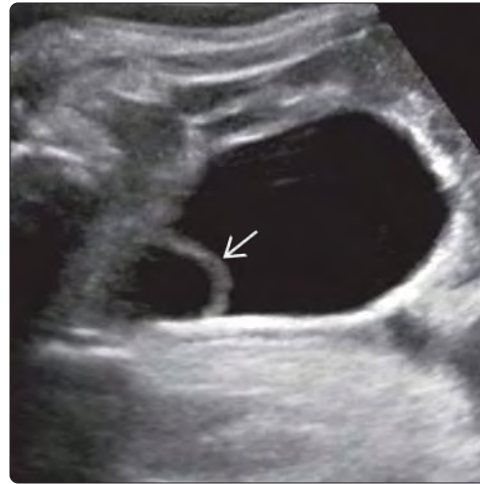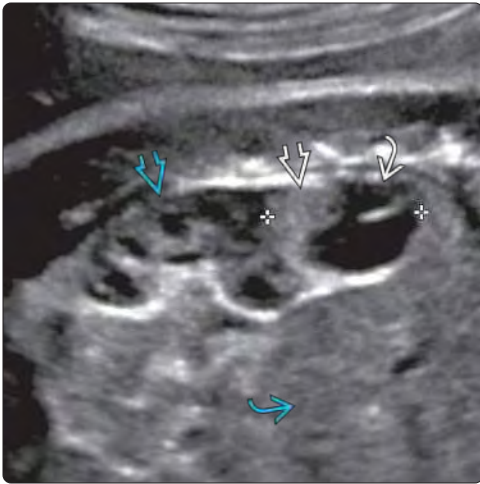
- Hyperechoic kidneys are predictive of renal dysplasia in 95% of cases
- Look for renal macrocysts in all cases of UTD
 - Form in subcortical area 1st
- Send family for urology and nephrology consult during pregnancy

Image Interpretation Pearls

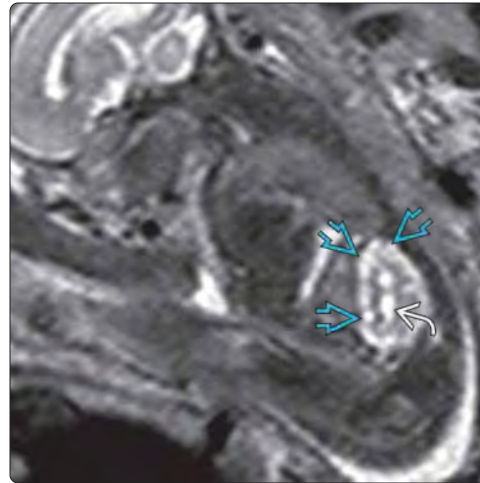
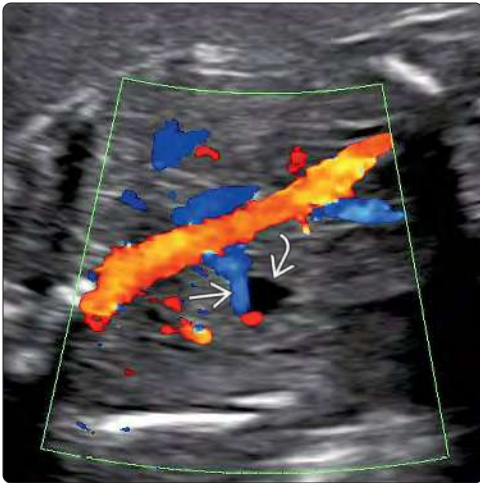
- May be difficult to differentiate ORD from MCDK
 - Hydronephrosis/hydroureter suggests ORD
 - May not be important to differentiate
 - Similar prognosis
 - Poor or no renal function for both
- Look carefully for other anomalies once ORD seen
 - Genetic testing recommended if ORD is not isolated
- When considering intervention for LUTO, remember that draining bladder will not save kidneys but may help lungs

SELECTED REFERENCES

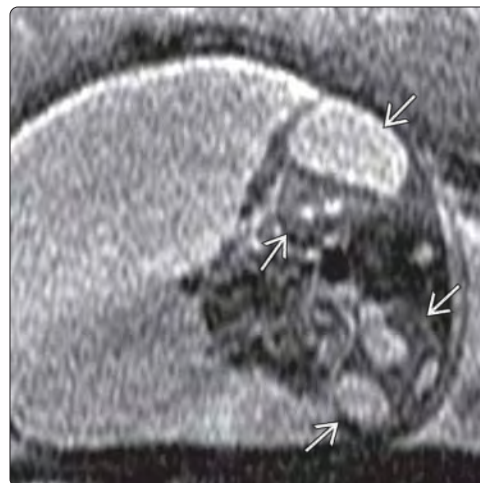
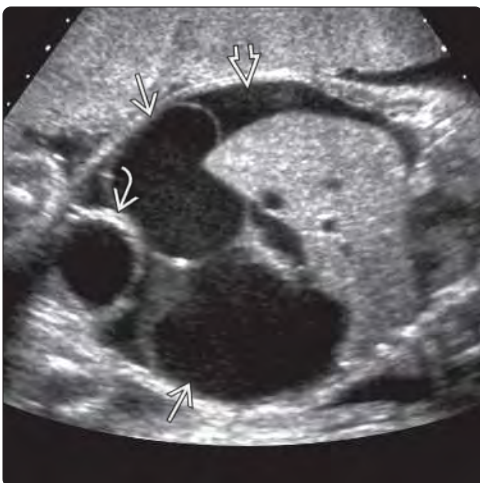1. Chow JS et al: Multidisciplinary consensus on the classification of antenatal and postnatal urinary tract dilation (UTD classification system). *Pediatr Radiol.* 45(6):787-9, 2015
2. de Grauw AM et al: The diagnostic value of routine antenatal ultrasound in screening for congenital uropathies. *J Matern Fetal Neonatal Med.* 1-5, 2015
3. Smith-Harrison LI et al: Current applications of in utero intervention for lower urinary tract obstruction. *J Pediatr Urol.* 11(6):341-7, 2015
4. Vemulakonda VM et al: Inter-rater reliability of postnatal ultrasound interpretation in infants with congenital hydronephrosis. *Int Urol Nephrol.* 47(9):1457-61, 2015
5. Thomas DF: Prenatally diagnosed urinary tract abnormalities: long-term outcome. *Semin Fetal Neonatal Med.* 13(3):189-95, 2008



(Left) Coronal view of the right kidney shows segmental upper pole cystic dysplasia (calipers) from renal duplication and upper moiety obstruction (note the calyceal dilatation). Note the ↑ upper pole echogenicity compared to the normal lower pole and liver. **(Right)** The ureterocele seen in the fetal bladder essentially "clinches" the diagnosis. Upper pole obstructing ureteroceles may cause segmental renal cystic dysplasia, which can mimic a suprarenal mass.



(Left) In this fetus with severe oligohydramnios, only 1 renal artery was seen and the renal pelvis was dilated, but the kidney wasn't seen well with ultrasound. **(Right)** A T2-weighted MR in the same fetus shows a high-signal solitary kidney with central collecting system distention and subtle cortical cysts, suggesting postobstructive renal cystic dysplasia. This fetus did have amniotic fluid earlier in the pregnancy. The newborn had nonlethal pulmonary hypoplasia and severe renal insufficiency.



(Left) Coronal ultrasound of a 3rd-trimester fetus with a sacrococcygeal teratoma and secondary bladder obstruction shows a thick-walled bladder, grossly distended ureters, and urinary ascites. The kidneys were not well evaluated, so an MR was performed. **(Right)** T2WI MR in the same patient shows the kidneys well. Both kidneys contained multiple large cysts. Lower urinary tract obstruction is the most common cause of bilateral obstructive renal dysplasia.

Multicystic Dysplastic Kidney

KEY FACTS

TERMINOLOGY

- Renal cystic dysplasia

IMAGING

- Multiple noncommunicating cysts in kidney
 - Intervening renal tissue is sparse and abnormal
 - 90% with ↑ renal size
 - Reniform shape often lost
- Bilateral multicystic dysplastic kidney (MCDK) in 20% (Potter type II)
 - Severe oligohydramnios or anhydramnios
 - Grim prognosis from pulmonary hypoplasia
- Contralateral renal anomaly (non-MCDK) in 5-40%
- Nonrenal anomalies in 5%
 - Consider genetic testing
- Follow-up US every 3-4 weeks
 - Evaluate contralateral kidney
 - MCDK can enlarge dramatically
 - Follow amniotic fluid

- Fetal MR helpful for complicated cases

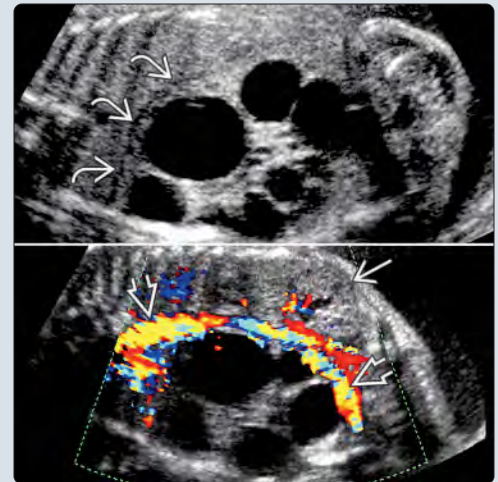
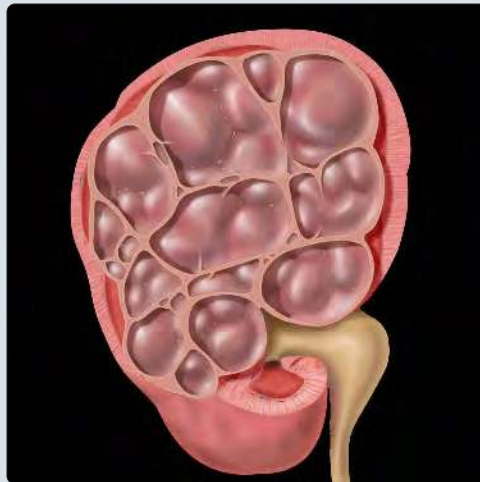
TOP DIFFERENTIAL DIAGNOSES

- Ureteropelvic junction obstruction
- Obstructive cystic dysplasia
- Dilated ureter

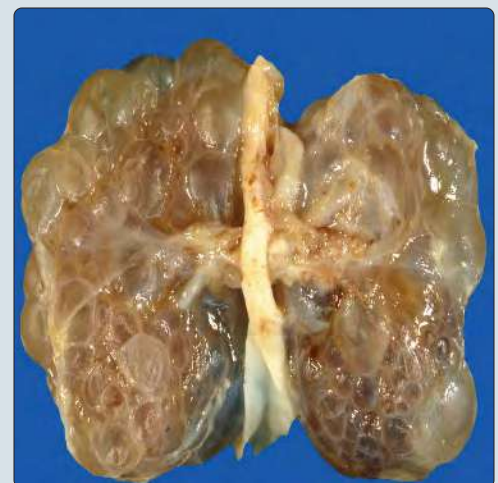
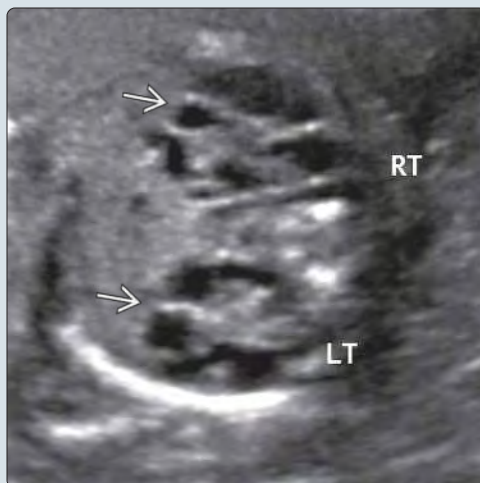
CLINICAL ISSUES

- Incidence
 - 1:1,000 unilateral; 1:5,000 bilateral
- MCDK is most often nonfunctioning kidney
 - Often involutes with time
- Compensatory hypertrophy of contralateral kidney is good prognosticator of healthy contralateral kidney
- Routine nephrectomy not performed
- Neonatal work-up
 - Confirmatory US
 - Voiding cystourethrogram (reflux common)
 - Isotope renal scan for function

(Left) Graphic of a multicystic dysplastic kidney (MCDK) shows that cysts of variable size have replaced the renal parenchyma. The cysts usually completely replace the kidney, but MCDK can be segmental, with some normal remaining parenchyma, as shown in the lower pole. **(Right)** Coronal US of fetus with left MCDK shows multiple cysts of variable size with intervening echogenic parenchyma. The kidney is large, and there is mass effect upon the diaphragm and abdominal vessels. A normal right kidney is also seen.



(Left) Axial image through the kidneys at the time of the anatomy scan at 20 weeks shows bilateral MCDKs. The renal parenchyma is almost completely replaced by cysts. Also, there is no measurable amniotic fluid. Prognosis is grim, secondary to severe pulmonary hypoplasia. **(Right)** Autopsy specimen shows bilateral MCDK. Both kidneys are large, and innumerable cysts of variable size are seen. (From DP: *Kidney Diseases.*)



TERMINOLOGY

Abbreviations

- Multicystic dysplastic kidney (MCDK)

Synonyms

- Renal cystic dysplasia
- Potter type II (bilateral MCDK)

Definitions

- Noncommunicating cysts + dysplastic renal tissue
- MCDK is essentially nonfunctioning kidney

IMAGING

General Features

- Best diagnostic clue
 - Variably sized cysts that do not connect with very little renal tissue otherwise seen
- Location
 - 80% unilateral, L > R
 - 20% contralateral anomaly (often bilateral MCDK)
- Size
 - 90% with ↑ renal size
- Morphology
 - Kidney may lose reniform shape

Ultrasonographic Findings

- Unilateral MCDK
 - Noncommunicating cysts of variable size and shape
 - Cysts may ↑ or ↓ during pregnancy
 - ↑ renal parenchyma echogenicity between cysts
 - From dysplasia, fibrosis, cartilage metaplasia
 - Renal length > 95th percentile in 90%
 - Segmental MCDK (rare): Only part of kidney is cystic
 - Often from duplex collecting system
 - Mimics suprarenal mass if upper moiety involved
 - Compensatory hypertrophy of contralateral kidney is good prognosticator
 - Suggests healthy contralateral kidney
 - Definition: Renal length > 2 standard deviations of mean
- Bilateral MCDK in 20%
 - Bilateral cystic kidneys with no fluid-filled bladder
 - Severe oligohydramnios or anhydramnios
 - Small chest, hand and feet contractures
 - Grim prognosis from pulmonary hypoplasia
- **Contralateral renal anomaly (non-MCDK) in 5-40%**
 - Ureteropelvic junction (UPJ) obstruction
 - Prognosis depends on severity
 - Renal agenesis
 - Grim prognosis
 - Contralateral renal hypoplasia
 - Vesicoureteric reflux
 - Most often postnatal diagnosis
- MCDK in renal variants
 - Pelvic kidney with MCDK
 - Presents as cystic pelvic mass
 - Horseshoe kidney with partial MCDK
 - Duplicated kidney with partial MCDK
- MCDK and amniotic fluid (AF)

- Unilateral MCDK
 - Normal AF + normal bladder
- Unilateral MCDK + contralateral renal anomaly
 - AF depends on severity of contralateral anomaly
- Bilateral MCDK
 - No or little AF
- Genetic testing recommended if MCDK is not isolated
 - **Associations with cystic kidneys**
 - Meckel-Gruber syndrome: Encephalocele, polydactyly
 - Trisomy 13: Holoprosencephaly is hallmark anomaly
 - Trisomy 18: Multiple anomalies

Imaging Recommendations

- Best imaging tool
 - Routine axial + longitudinal views of kidneys as part of anatomy scan
- Protocol advice
 - Careful anatomic survey
 - Determine if MCDK is isolated or not
 - Genetic counseling for nonisolated MCDK
 - Follow-up imaging during pregnancy (every 3-4 weeks)
 - Assess AF
 - MCDK cysts can enlarge dramatically
 - Assess contralateral kidney appearance

MR Findings

- MR helpful for complicated cases
 - Oligohydramnios may limit imaging with US
- Cysts are bright on T2WI

DIFFERENTIAL DIAGNOSIS

Ureteropelvic Junction Obstruction

- Most common cause of congenital hydronephrosis
- Distended renal pelvis and calyces appear cyst-like
 - Show dilated calyces connect with renal pelvis

Obstructive Cystic Dysplasia

- Cystic parenchymal change from obstruction
 - Hydronephrosis → cortical cysts
- Often see some normal renal tissue
 - Reniform shape often retained
- Can appear identical to MCDK

Autosomal Recessive Polycystic Kidney Disease

- Bilateral, large echogenic kidneys
 - Rare or no macroscopic cysts
- Oligohydramnios

Dilated Ureter

- Distended ureter is serpiginous and in cross section can mimic cysts of MCDK
- Etiology
 - Posterior urethral valves
 - Ureterovesical junction obstruction
 - Prune-belly syndrome
 - Primary megaureter (rare)

PATHOLOGY

General Features

- Etiology

- Ureteric bud theory
 - Atretic bud does not signal metanephros
 - Leads to abnormal branching
 - Loss of potential nephrons
 - Formation of aberrant structures in metanephros
 - Cysts, cartilage, stromal expansion
- Early obstruction theory
 - Early ureter obstruction → dysplasia
 - Metanephric tissue does not form nephrons
- Infection theory
 - 1-3% with MCDK have positive AF cultures
 - Enterovirus, cytomegalovirus, adenovirus
- Genetics
 - Isolated MCDK not associated with aneuploidy
 - Possible role of 3 genes (all renal cystic dysplasia)
 - *TCF2*, *PAX2*, uroplakins
 - 10% with family history of significant genitourinary malformation

Gross Pathologic & Surgical Features

- Enlarged kidney replaced by cysts with intervening dense fibrotic stroma
- Nonpatent ureter and renal pelvis

Microscopic Features

- Smooth-walled cysts
- Significant nephron deficit

CLINICAL ISSUES

Presentation

- Most common signs/symptoms
 - Incidental finding during anatomy scan
 - Severe oligohydramnios
 - Bilateral MCDK or severe contralateral anomaly
 - In association with other anomalies

Demographics

- Gender
 - M:F = 2:1
- Epidemiology
 - 1:4000 incidence

Natural History & Prognosis

- Unilateral MCDK
 - Nonfunctioning kidney in > 90%
 - MCDK kidneys tend to involute
 - 19-74 % involute over 9 months-10 yr
 - Most involution in first 18 months of life
 - Renal length of < 6 cm at birth associated with ↑ involution
 - Compensatory hypertrophy of contralateral kidney
 - Important prognosticator suggesting contralateral kidney is normal
 - 92% have compensatory hypertrophy if MCDK completely involutes
 - ↑ renal insufficiency if contralateral kidney is hypoplastic
 - Vesicoureteral reflux seen is common (20%)
 - Voiding cystourethrogram necessary for diagnosis
 - Increases risk for infection
 - Rare complications

- Hypertension: 25-50% resolve with removal of kidney
- Rare development of Wilms tumor
 - Controversial if true ↑ incidence
- MCDK + contralateral renal abnormality
 - Bilateral MCDK almost always fatal
 - Severe contralateral anomaly often fatal
 - Mild contralateral anomaly often correctable with variable prognosis
 - Contralateral UPJ in 7-15 %
 - Ureterovesical junction obstruction in 6%

Treatment

- Conservative management
 - Neonatal work-up
 - US to confirm diagnosis
 - Voiding cystourethrogram to evaluate for reflux
 - Isotope renal scan for function
 - US surveillance protocols are variable
 - Every 3-6 months for 1-2 yr then yearly until 4 yr of age
- Surgical excision reserved for complications
 - Recurrent infections
 - Hypertension
 - Wilms tumor

DIAGNOSTIC CHECKLIST

Consider

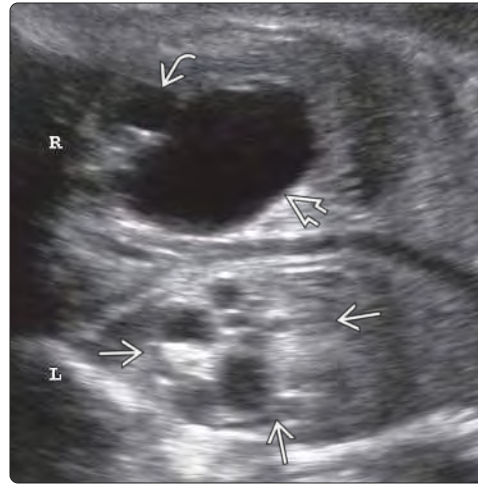
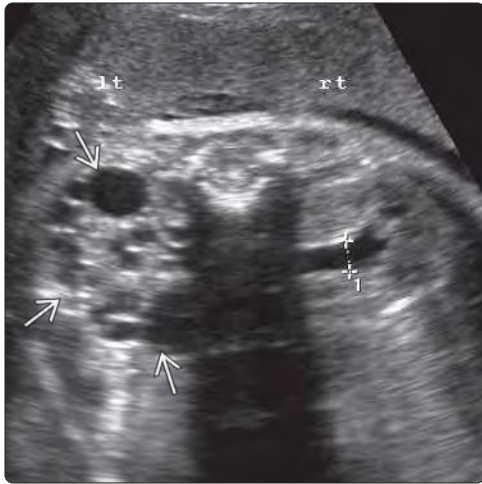
- Careful evaluation of contralateral kidney
- Follow AF index (reflects contralateral renal function)
- Consider genetic testing if other anomalies seen

Image Interpretation Pearls

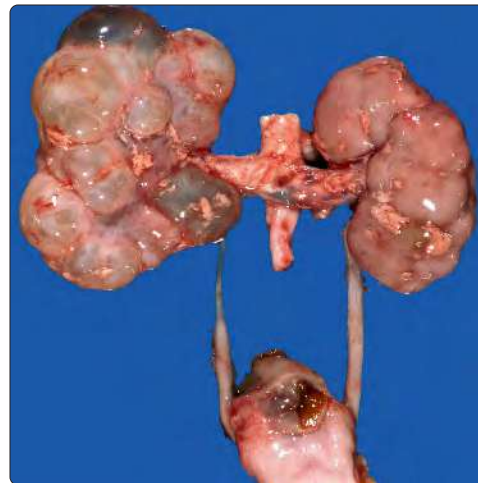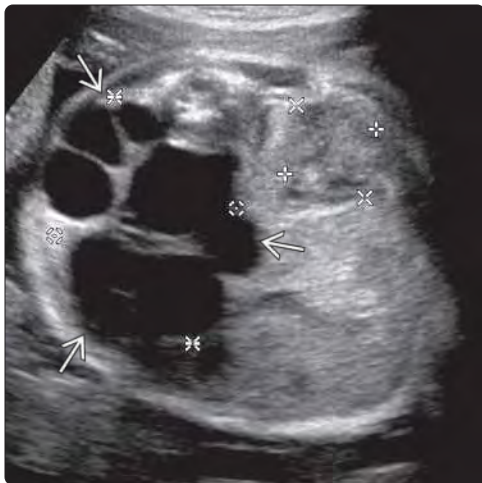- Beware of hydronephrotic type of MCDK
 - Large central cyst with small peripheral cysts
 - Careful scan shows cysts do not communicate
- Complex cystic mass in fetal pelvis may be MCDK in pelvic kidney
- Use MR if case is not typical or oligohydramnios limits anatomic evaluation

SELECTED REFERENCES

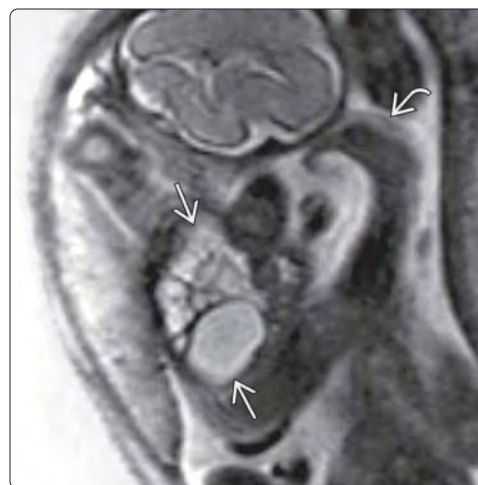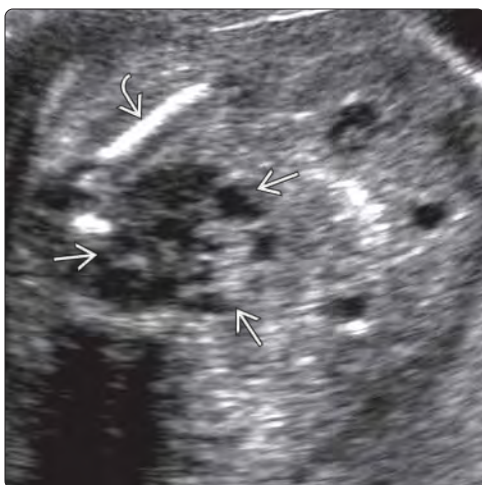
1. Maki E et al: Imaging and differential diagnosis of suprarenal masses in the fetus. *J Ultrasound Med.* 33(5):895-904, 2014
2. Krill A et al: Evaluating compensatory hypertrophy: a growth curve specific for solitary functioning kidneys. *J Urol.* 188(4 Suppl):1613-7, 2012
3. Hains DS et al: Management and etiology of the unilateral multicystic dysplastic kidney: a review. *Pediatr Nephrol.* 24(2):233-41, 2009
4. Thomas DF: Prenatally diagnosed urinary tract abnormalities: long-term outcome. *Semin Fetal Neonatal Med.* 13(3):189-95, 2008
5. Winyard P et al: Dysplastic kidneys. *Semin Fetal Neonatal Med.* 13(3):142-51, 2008
6. Kalyoussef E et al: Segmental multicystic dysplastic kidney in children. *Urology.* 68(5):1121.e9-11, 2006
7. van Eijk L et al: Unilateral multicystic dysplastic kidney: a combined pre- and postnatal assessment. *Ultrasound Obstet Gynecol.* 19(2):180-3, 2002
8. Lazebnik N et al: Insights into the pathogenesis and natural history of fetuses with multicystic dysplastic kidney disease. *Prenat Diagn.* 19(5):418-23, 1999



(Left) Axial image shows a left MCDK and mild right renal pelvis distention (calipers). It is assumed that the left kidney will not function, and, therefore, it is imperative the right kidney is followed carefully in utero and after delivery. (Right) Coronal US through the kidneys in a case with severe oligohydramnios shows a left MCDK and right uteropelvic junction (UPJ) obstruction (note the distended renal pelvis with an associated dilated calyx). When there is a severe contralateral abnormality, the prognosis is poor.



(Left) Axial image shows a massively enlarged MCDK, which crosses the midline and extends to the anterior abdominal wall. Compare the size with the normal contralateral kidney (calipers). MCDK kidneys often grow in fetal life but atrophy after birth. (Right) Autopsy specimen from a different case, with an MCDK on the right and normal kidney with fetal lobulations on the left, also shows the difference in size and shape between the affected and the normal kidney. (From DP: Kidney Diseases.)



(Left) Axial US through the fetal pelvis shows a complex cystic mass adjacent to the iliac crest. This was an MCDK pelvic kidney. A pelvic MCDK can mimic a complex mass leading to additional work-up. (Right) MR of a twin fetus with an MCDK and contralateral renal agenesis shows a large cystic kidney, as well as a clubfoot. The clubfoot is secondary to severe oligohydramnios. Fetal MR can be helpful with complicated cases and cases in which the larger field of view is helpful, as in this twin case.

Autosomal Recessive Polycystic Kidney Disease

KEY FACTS

TERMINOLOGY

- ARPKD is 1 of **hepatorenal fibrocystic diseases/syndromes**
 - New nomenclature to encompass full spectrum of disease
 - Underlying pathology is ciliopathy
- Single gene disorder resulting in bilateral, symmetric, cystic renal disease + hepatic fibrosis

IMAGING

- Enlarged, hyperechoic kidneys
 - Uniformly high signal intensity on T2WI MR
 - Small, discrete cysts or areas of tubular ectasia may be visible
- Oligohydramnios
- Pulmonary hypoplasia

TOP DIFFERENTIAL DIAGNOSES

- Trisomy 13
- Meckel-Gruber syndrome


- Beckwith-Wiedemann syndrome
- Bilateral multicystic dysplastic kidneys

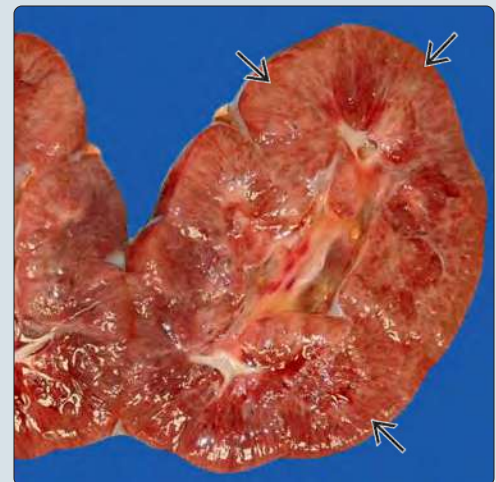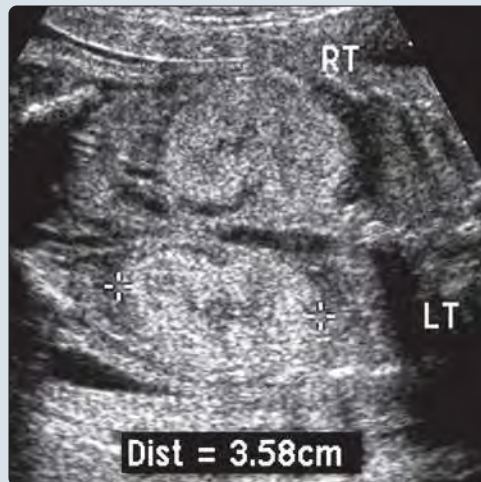
CLINICAL ISSUES





- Fetal diagnosis
 - Oligohydramnios → pulmonary hypoplasia → majority stillborn or neonatal death
- Neonatal survivors
 - 1-year survival: 85%
 - 10-year survival: 82%
 - 50% will need kidney transplant before age 20

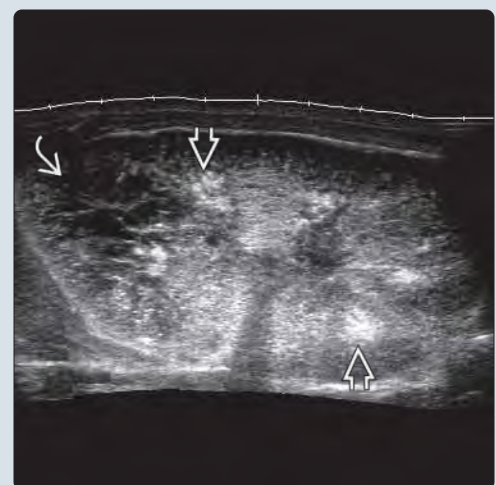
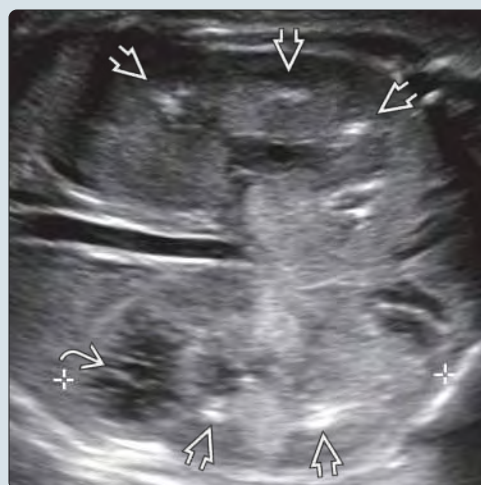DIAGNOSTIC CHECKLIST

- MR may refine diagnosis of renal anomalies associated with oligo-/anhydramnios
 - Low lung volumes may identify those at greatest risk of perinatal demise
- Prenatal diagnosis is possible if specific mutation known

(Left) Coronal US at 24 weeks shows large, echogenic kidneys. In this case, amniotic fluid volume was normal throughout pregnancy, and the diagnosis was established after delivery. **(Right)** Bivalved kidney from an autopsy of an infant who died from pulmonary hypoplasia shows the radially oriented, dilated tubules . Increased renal echogenicity results from the many interfaces created by the dilated renal tubules.



(Left) Coronal US at 31 weeks shows another sonographic pattern. In this case, the kidneys are very large (calipers measure a 9 cm left kidney) and the medullary pyramids  are echogenic. Also note the focal tubular ectasia  in the left upper pole. **(Right)** Extended field of view of the left kidney after delivery confirms the fetal observations of echogenic pyramids  and focal, upper pole tubular ectasia .



TERMINOLOGY**Abbreviations**

- Autosomal recessive polycystic kidney disease (ARPKD)

Definitions

- ARPKD is 1 of **hepatorenal fibrocystic diseases/syndromes**
 - New nomenclature to encompass full spectrum of disease
 - Underlying pathology is ciliopathy
- Single gene disorder resulting in bilateral, symmetric, cystic renal disease + hepatic fibrosis

IMAGING**General Features**

- Best diagnostic clue
 - Enlarged, hyperechoic kidneys

Ultrasonographic Findings

- Kidney size > 2 standard deviations above mean for gestational age (GA)
 - Renal enlargement may not occur until mid 2nd trimester
- Kidneys may be diffusely hyperechoic or have hyperechoic pyramids
- Cysts may be visible but do not predominate
- With modern equipment/high-resolution transducers tubular ectasia may be visible in 3rd trimester
- Normal hypoechoic cortex is present but difficult to discern with severe disease
- Oligohydramnios
- Fetal bladder may not be visible (poor urine output)
- Pulmonary hypoplasia

MR Findings

- Large kidneys of uniformly high signal intensity on T2WI
- Total lung volume measurement (TLV) may help predict outcome
 - TLV:GA < 0.90 predicted lethality with sensitivity 77.8%, specificity 95% in series of fetuses with severe genitourinary abnormalities

Imaging Recommendations

- Obtain serial renal measurements in at-risk fetuses
- Monitor amniotic fluid volume as early oligohydramnios → poor prognosis
- Measure thoracic circumference for objective assessment of pulmonary hypoplasia
- MR helpful with difficult maternal habitus, low fluid volume

DIFFERENTIAL DIAGNOSIS**Trisomy 13**

- Cystic dysplasia seen in 50%
 - Kidneys usually echogenic, enlarged; cysts may be visible

Meckel-Gruber Syndrome

- Cystic renal dysplasia is most consistent finding; seen in 95-100% of cases
 - Variable sonographic appearance of kidneys but usually grossly enlarged, echogenic kidneys

Beckwith-Wiedemann Syndrome

- Kidneys are large but normal morphology and echogenicity

Bilateral Multicystic Dysplastic Kidneys

- Macroscopic renal cysts are dominant feature

Autosomal Dominant Polycystic Kidney Disease

- Asymmetric renal enlargement, cysts may be visible in late 3rd trimester
 - Hyperechoic cortex, relatively hypoechoic medulla
 - increased corticomedullary differentiation
- Amniotic fluid normal

PATHOLOGY**General Features**

- Etiology
 - ARPKD is 1 of ciliopathies
 - Group of hereditary defects of primary (nonmotile) cilia
 - Primary cilium has many key roles in embryonic development, inherited disease
 - Wide range of overlapping syndromes involving liver, kidneys, multiple organ systems
- Genetics
 - Autosomal recessive with all typical forms due to *PKHD1* mutation
 - 750 mutations of *PKHD1* gene reported in ARPKD
 - 71.6% of patients with 2 mutations, 24.3% with 1, 2.4% with none
 - *HNF1B* mutations mimic ARPKD phenotype
 - Encodes for transcription factor hepatocyte nuclear factor-1 beta
 - Prognosis relates to genotype
 - Several studies have shown truncating mutations in ~ 55% of most severe cases
 - 2 truncating mutations: Severe genotype; correlates with renal but not hepatic involvement
 - Mutations are "private" (i.e., specific to individual families)
 - Widely discordant phenotypes occur in siblings

Gross Pathologic & Surgical Features

- Defects in structure ± function of primary cilium responsible for many features (e.g., liver fibrosis, cystic renal disease)
 - Ectatic distal convoluted tubules and collecting ducts
 - Increased volume of medulla → renal enlargement
 - Increase in reflective interfaces → high echogenicity on ultrasound
 - Increased "water" content in multiple tubules/cysts → high signal intensity T2WI

CLINICAL ISSUES**Presentation**

- Majority detected < 24 weeks
 - Diagnosis reported as early as 16 weeks in at-risk fetus

Demographics

- Epidemiology
 - 1:20,000-50,000 births
 - M = F

Hepatorenal Fibrocystic Diseases

Syndrome	Gene
Autosomal recessive polycystic kidney disease	<i>PKHD1</i>
Autosomal dominant polycystic kidney disease	<i>PKD1, PKD2</i>
Nephronophthisis	<i>NPHP1-18</i>
Joubert syndrome and related disorder	<i>JBTS1-22</i>
Bardet-Biedl syndrome	<i>BBS1-19</i>
Meckel-Gruber syndrome	<i>MKS1-11</i>
Oral-facial-digital syndrome type I	<i>OFD1</i>
Glomerulocystic disease	<i>PKD1, HNF1B, UMOD</i>
Short-rib thoracic dysplasia	<i>SRTD1-12</i>
Renal-hepatic-pancreatic dysplasia (Ivemark II)	<i>NPHP3, NEK8</i>
Zellweger syndrome	<i>PEX1-3, 5-7, 10-14, 16, 19, 26</i>

Autosomal recessive polycystic kidney disease is the commonest of the group of diseases now collectively described as the hepatorenal fibrocystic diseases.

Guay-Woodford LM: Autosomal recessive polycystic kidney disease: the prototype of the hepato-renal fibrocystic diseases. *J Pediatr Genet.* 3(2):89-101, 2014.

- o 40% with fetal presentation (most severe form)

Natural History & Prognosis

- Disease has variable phenotype
 - o Perinatal, neonatal, infantile, and juvenile forms described
- Perinatal form: 30-50% death rate
 - o Severe renal disease with resultant pulmonary hypoplasia from oligohydramnios
 - o Need for artificial ventilation at birth strongly correlates with mortality
 - o Neonatal survivors
 - 1-year survival: 92-95%
 - 10-year survival: 82%
 - Mean age at diagnosis of chronic renal failure: 4 years
 - Actuarial renal survival (end point defined as start of dialysis or death from renal failure)
 - 86% at 5 years, 71% at 10 years, 42% at 20 years
 - 75% develop systemic hypertension
 - 44% develop portal hypertension
 - 50% will need renal transplant before age 20
 - Survivors (especially those not requiring ventilation) have normal pulmonary function, no increase in lung infections
 - o Recent data suggests neurocognitive dysfunction in surviving children
- Juvenile form
 - o Minimal renal disease but marked hepatic fibrosis
- Cannot predict outcome of future children based on severity of index case

Treatment

- Genetic counseling
 - o Increased incidence of occult renal disease in family members
 - o Recurrence risk is 25% in future pregnancies
 - o Prenatal diagnosis is area of continued research
 - Preimplantation genetic diagnosis avoids trauma of pregnancy termination with affected fetus

- o Chorionic villus sampling/amniocentesis to test for specific mutation
 - Reliable prenatal diagnosis is possible in ~ 80% of affected families if
 - Definitive diagnosis in index case
 - DNA from index case and both parents
- Offer termination in confirmed cases
- If pregnancy continues
 - o Offer comfort care for severely affected cases, avoid cesarean section for nonviable fetus
 - o Plan delivery at tertiary center if infants may require respiratory support
- Monitor abdominal circumference (AC)
 - o Risk of abdominal dystocia, AC may determine timing of delivery
- Encourage autopsy confirmation of diagnosis if intrauterine or neonatal demise

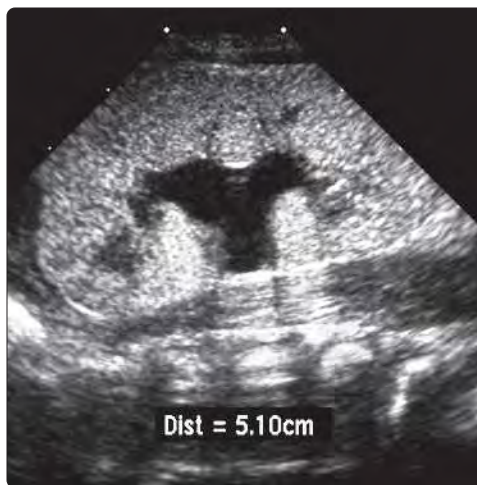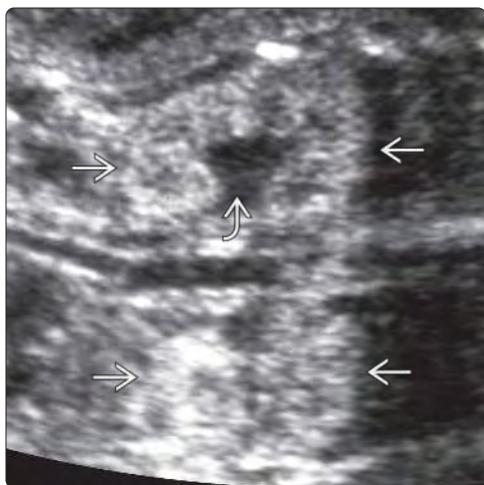
DIAGNOSTIC CHECKLIST

Consider

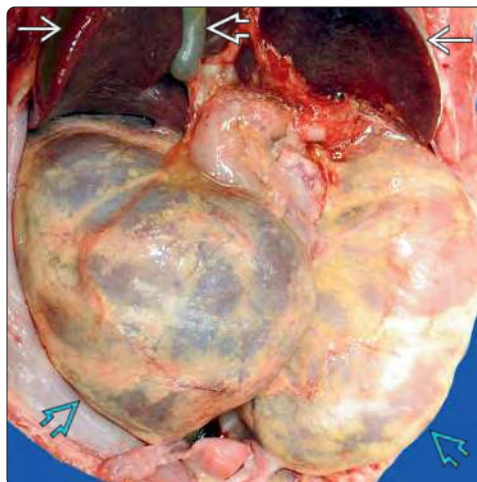
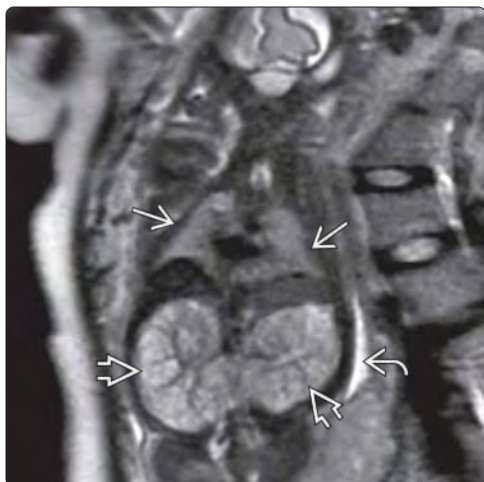- Phenotypic expression highly variable within individual families
 - o Cannot exclude juvenile form on basis of prenatal ultrasound alone
- Prenatal diagnosis possible if specific mutation known
 - o Strongly encourage autopsy/renal biopsy in lethal cases
- MR may refine diagnosis of renal anomalies associated with oligo-/anhydramnios, allows measurement of lung volumes

SELECTED REFERENCES

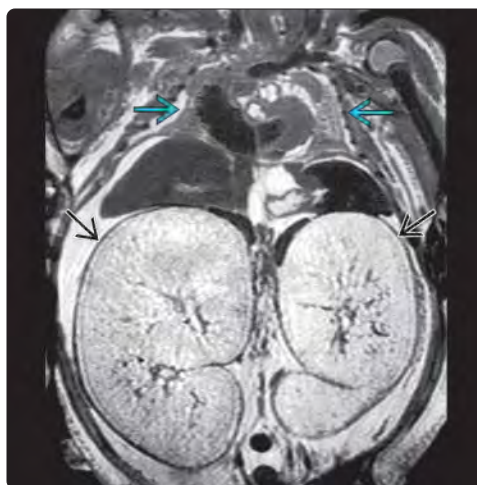
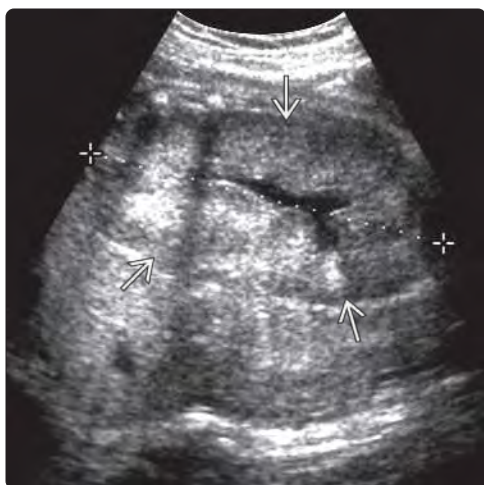
1. Hoyer PF: Clinical manifestations of autosomal recessive polycystic kidney disease. *Curr Opin Pediatr.* 27(2):186-92, 2015
2. Guay-Woodford LM: Autosomal recessive polycystic kidney disease: the prototype of the hepato-renal fibrocystic diseases. *J Pediatr Genet.* 3(2):89-101, 2014
3. Verghese P et al: Neonatal polycystic kidney disease. *Clin Perinatol.* 41(3):543-60, 2014
4. Liu YP et al: Autosomal recessive polycystic kidney disease: appearance on fetal MRI. *Pediatr Radiol.* 36(2):169, 2006



(Left) Coronal US shows a less common appearance of large, echogenic kidneys, with preserved hypoechoic pyramids. There is also mild pelvictasis. The fetal renal appearance may change as the disease progresses. (Right) Postnatal coronal US in the same patient shows the more typical appearance of diffusely echogenic parenchyma with loss of normal medullary architecture. This case illustrates the variability of the sonographic findings in autosomal recessive polycystic kidney disease (ARPKD).



(Left) Coronal MR of a 31-week fetus shows oligohydramnios. The kidneys are markedly enlarged with abnormal hyperintense parenchyma. The chest is small and bell-shaped. These findings are typical of ARPKD with poor urine production and resulting pulmonary hypoplasia. (Right) Autopsy shows the dramatically enlarged kidneys in situ. The liver has been elevated revealing the gallbladder on its undersurface. The kidneys extend from the diaphragm into the pelvis.



(Left) Sagittal ultrasound in a different case of ARPKD shows an enlarged, hyperechoic kidney (calipers). There is preservation of the normal hypoechoic cortex. This is a characteristic finding but may be difficult to discern on prenatal scans. (Right) Coronal T2WI postmortem MR shows a tiny thoracic cavity. The kidneys are massively enlarged with no normal remaining parenchyma. High signal intensity is caused by the dilated tubules.

KEY FACTS

TERMINOLOGY

- Benign mesenchymal renal tumor composed predominately of spindle cells

IMAGING

- Large, solid, vascular renal mass
 - May rarely have cystic areas
- Polyhydramnios (often severe) in ~ 70%
- Confirm renal origin of mass
 - Look for separate adrenal gland
 - Use color Doppler to find renal artery

TOP DIFFERENTIAL DIAGNOSES




- Wilms tumor
 - Ultrasound appearance identical
 - Most present later in childhood (extraordinarily rare in utero)
- Crossed fused ectopia
- Duplicated collecting system

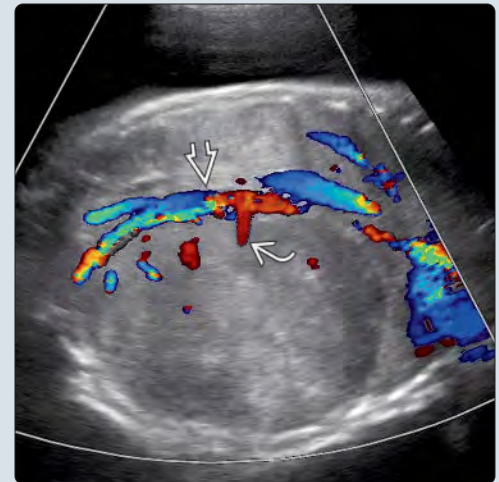
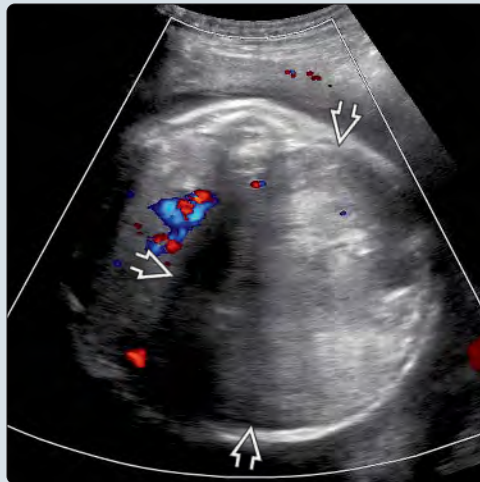
CLINICAL ISSUES






- Most common renal neoplasm in fetus and newborn
- ~ 5% of perinatal tumors arise from kidney
- Can show rapid growth despite benign histology
- Perinatal complications in ~ 75%
 - Severe polyhydramnios
 - Hydrops
 - Acute fetal distress
 - Neonatal respiratory distress
 - Neonatal hypertension
 - Neonatal hypercalcemia
- Surgical resection usually curative
 - Surgical complications reported in 26%

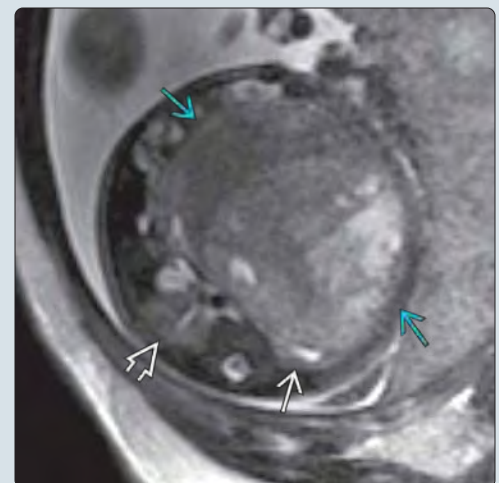
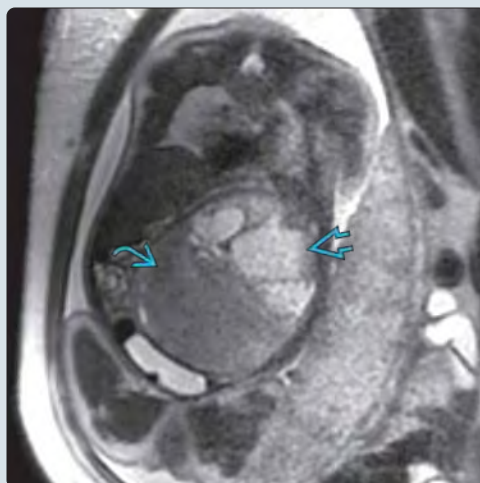
DIAGNOSTIC CHECKLIST

- Mesoblastic nephroma has excellent oncologic outcome but high risk for perinatal complications
- Mesoblastic nephroma is most likely diagnosis for unilateral, solid renal mass

(Left) This axial image through the fetal abdomen shows a large solid mass filling the left side of the abdomen and extending across the midline . When large, it can be difficult to determine the organ of origin of a mass, so it is important to scan in multiple planes and define normal structures. **(Right)** When the same mass is evaluated in the coronal plane, the left renal artery  is shown supplying the tumor (aorta ). The most common solid fetal renal tumor is a mesoblastic nephroma, which was confirmed postnatally.



(Left) Coronal MR of a 37-week fetus shows a large renal mass with both solid  and cystic  components. (From *DI: Pediatrics, 3e.*) **(Right)** The axial plane in the same fetus shows the relationship of the large mass  to the residual left kidney  ( shows the normal right kidney). Although predominately solid, cystic areas may be present within a mesoblastic nephroma. Polyhydramnios, a common associated finding, was also present in this case. (From *DI: Pediatrics, 3e.*)



TERMINOLOGY

Synonyms

- Fetal renal hamartoma
- Mesenchymal hamartoma

Definitions

- Benign mesenchymal renal tumor composed predominately of spindle cells

IMAGING

General Features

- Best diagnostic clue
 - Solid renal mass + polyhydramnios
- Morphology
 - Variable growth pattern
 - Often distinct, well-defined, intrarenal mass
 - Infiltrative growth pattern
 - Smaller masses retain reniform shape
 - Larger masses may fill abdomen, displacing bowel

Ultrasonographic Findings

- Generally solid
 - Iso- to slightly hyperechoic compared with normal renal parenchyma
 - May rarely have cystic areas
- Large masses may exert considerable mass effect
 - Abdominal circumference increased
 - Abdominal vessels and organs displaced
 - Bowel obstruction may occur
- Polyhydramnios in ~ 70%
 - Often severe
- Rarely oligohydramnios
 - Bad prognostic sign suggesting renal failure
- Color Doppler
 - Vascular mass
 - Hydrops may occur with significant arteriovenous shunting or from obstruction of venous return
 - Ring sign
 - Hypoechoic ring surrounding tumor
 - Vascular with Doppler imaging

MR Findings

- Helpful for confirming renal origin of mass
- Solid mass with uniform signal intensity
- Mild increased signal on T2WI

Imaging Recommendations

- Confirm renal origin of mass
 - Look for kidney and adrenal gland on side of mass
 - Adjacent mass may fill renal fossa and be confused for renal mass
 - Look for displaced kidney
 - Look for claw sign (normal renal parenchyma extending along borders of mass)
 - May not be seen in large or infiltrating masses
 - Consider MR if ultrasound cannot determine if mass is renal
- Color Doppler
 - Assess vascularity
 - Look for renal artery

- Confirms mass is in kidney
- Frequent follow-up exams
 - Worsening polyhydramnios
 - May become severe, resulting in preterm labor
 - Enlarging abdominal circumference
 - Rarely complicated by hydrops

DIFFERENTIAL DIAGNOSIS

Other Renal Tumors

- Wilms tumor
 - Ultrasound appearance identical to mesoblastic nephroma
 - Extraordinarily rare in utero
 - Average age at presentation is 3.6 yr
- Rhabdoid tumor also reported
- All solid fetal renal masses must be resected for histologic diagnosis

Crossed Fused Ectopia

- Unilateral enlargement
- Fused kidneys may cross midline
- Opposite renal fossa is empty

Duplicated Collecting System

- Unilateral renal enlargement
- Upper pole often hydronephrotic
 - Drained by ectopic ureter
 - Often obstructs
- Lower pole may or may not be dilated
 - Drained by orthotopic ureter
 - Often refluxes
- Look in bladder for ureterocele

Autosomal Recessive Polycystic Kidney Disease

- Bilateral, symmetric renal enlargement
- Diffusely hyperechoic kidneys
- Scattered small cysts may be seen but are not dominant feature
- May have oligohydramnios

Beckwith-Wiedemann Syndrome

- Organomegaly, including enlarged kidneys
- Macrosomia
- Macroglossia with protruding tongue
- Omphalocele
- Hemihypertrophy
- Polyhydramnios
- Hypoglycemia in neonatal period
- At risk for neonatal tumors
 - Wilms tumor
 - Hepatoblastoma

Multicystic Dysplastic Kidney

- Multiple, noncommunicating cysts of various sizes
- No significant solid components

Adrenal Lesions

- Neuroblastoma, extralobar sequestration
- Suprarenal location
- Kidney displaced inferiorly
- Normal adrenal gland not identified

Retroperitoneal Teratoma

- May be large
 - May be difficult to find displaced kidney
- Point of origin difficult to discern
- Heterogeneous masses
 - Mixed cystic and solid
 - Calcifications are most specific diagnostic feature

PATHOLOGY

General Features

- Genetics
 - Sporadic
 - Has been reported in siblings
 - Case reports of mesoblastic nephroma occurring with assisted reproduction technology
- Associated abnormalities
 - Rare associations with neuroblastoma, limb abnormalities, and other sporadic genitourinary, gastrointestinal, or central nervous system anomalies reported
- **Hypotheses of polyhydramnios**
 - Polyuria
 - Often seen in neonates with mesoblastic nephroma and is associated with hypercalcemia
 - In utero polyuria from hypercalcemia is most likely cause of polyhydramnios
 - Bowel obstruction
 - May contribute but does not explain all cases
 - May see significant polyhydramnios without bowel obstruction
 - Mass causes increased blood flow to kidney → ↑ urine output
 - Impaired concentrating ability of affected kidney

Gross Pathologic & Surgical Features

- Whorled appearance
 - Similar to uterine fibroid
- No capsule
 - Still appears well defined by ultrasound

Microscopic Features

- Benign mesenchymal tumor
- Spindle-shaped cells infiltrate normal renal parenchyma
- Cellular variant may be more aggressive and may even metastasize
 - Usually presents in older children

CLINICAL ISSUES

Presentation

- Fetal
 - Rapid, acute onset of polyhydramnios in 3rd trimester
 - Large for dates
 - Preterm labor
 - Solid abdominal mass
 - Increased abdominal circumference
- Neonatal
 - Obvious palpable mass on exam
 - Hypertension
 - Increased renin production

- Hypercalcemia
 - Attributed to parathormone and prostaglandin production
- Both hypercalcemia and hypertension resolve after resection

Demographics

- Most common renal neoplasm in fetus and newborn
- ~ 5% of perinatal tumors arise from kidney
 - Almost all are mesoblastic nephroma
 - Rare reported cases of Wilms or rhabdoid tumor
- M > F

Natural History & Prognosis

- Can show rapid growth despite benign histology
- Perinatal complications in ~ 75%
 - Severe polyhydramnios
 - Hydrops
 - Acute fetal distress requiring emergency cesarean section
 - Premature delivery
 - Respiratory distress
 - Neonatal hypertension
 - Neonatal hypercalcemia
- Large abdominal circumference may result in dystocia at delivery
- Surgical resection usually curative
 - Surgical complications reported in 26%
- Rare local recurrence or metastases for cellular mesoblastic nephroma
 - Lung most common site

Treatment

- Referral to tertiary care center for close monitoring
- Amnioreduction for polyhydramnios for patient comfort or preterm labor
- May require cesarean section for large abdominal circumference
- Referral to pediatric urologist
- Resection in neonatal period
 - Nephrectomy with wide margins usually curative
- Cellular variant may require adjuvant chemotherapy

DIAGNOSTIC CHECKLIST

Consider

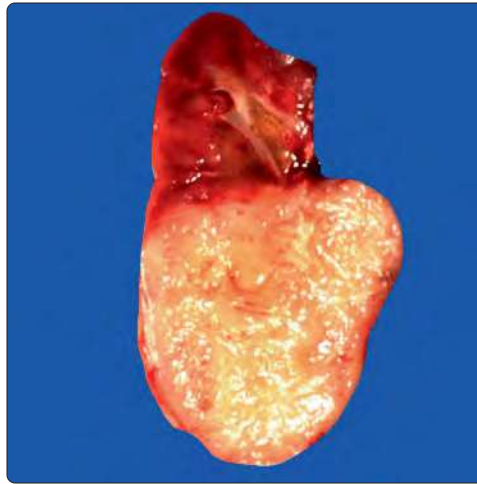
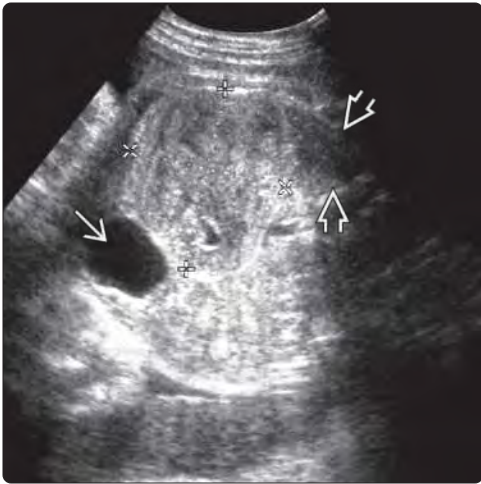
- MR to confirm mass is renal and not from surrounding structures
- Mesoblastic nephroma has excellent oncologic outcome but is at high risk for perinatal complications

Image Interpretation Pearls

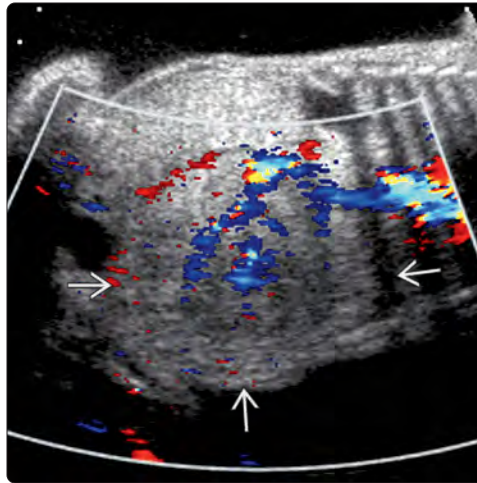
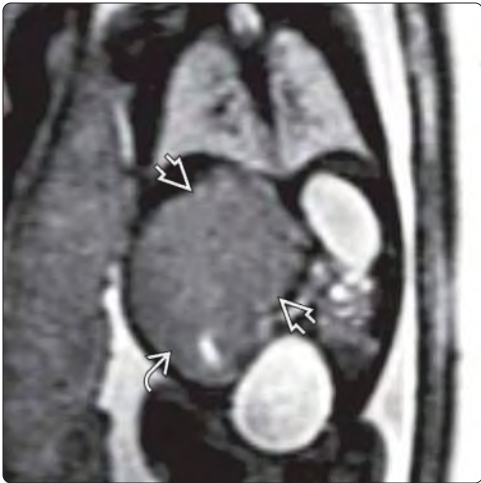
- Mesoblastic nephroma is most likely diagnosis for unilateral, solid renal mass

SELECTED REFERENCES

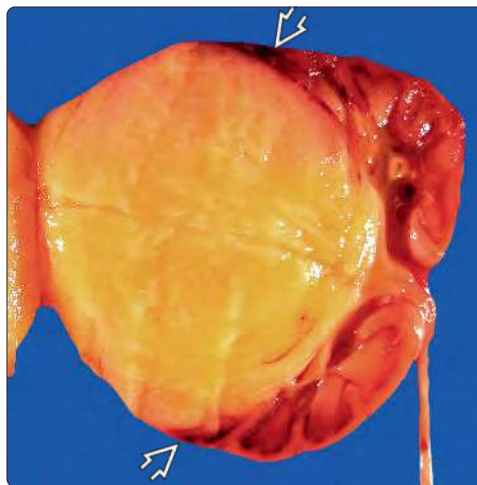
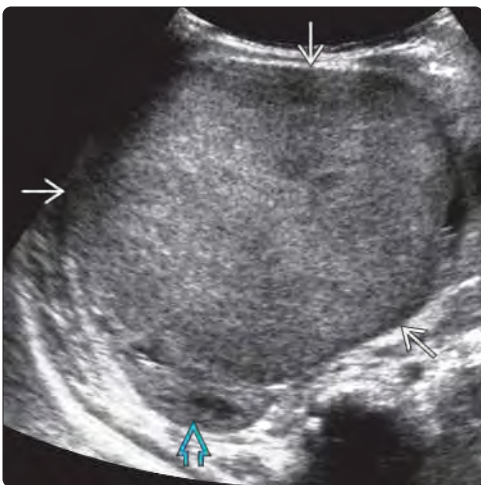
1. Do AY et al: Prenatal diagnosis of congenital mesoblastic nephroma. *Obstet Gynecol Sci.* 58(5):405-8, 2015
2. Takahashi H et al: Congenital mesoblastic nephroma: Its diverse clinical features - A literature review with a case report. *J Obstet Gynaecol.* 1-5, 2015
3. Wang ZP et al: Congenital mesoblastic nephroma: clinical analysis of eight cases and a review of the literature. *Oncol Lett.* 8(5):2007-2011, 2014
4. Esmer AC et al: Prenatal sonographic diagnosis of multicystic congenital mesoblastic nephroma. *J Clin Ultrasound.* 41 Suppl 1:59-61, 2013



(Left) Coronal oblique ultrasound of the right kidney shows a markedly enlarged lower pole (calipers) extending into the pelvis and abutting the bladder. The upper pole of the kidney is preserved. Close follow-up is warranted to watch for developing polyhydramnios or hydrops. **(Right)** Gross pathology after resection shows a well-defined, fleshy, lower pole mass with dense stromal architecture. The gross appearance is similar to that of a uterine fibroid.



(Left) Coronal T2WI MR shows a large, mildly hyperintense mass arising from the upper pole of the right kidney. It was resected soon after birth and was confirmed to be a mesoblastic nephroma. **(Right)** Coronal color Doppler shows the vascular nature of a mesoblastic nephroma. The patient went into preterm labor and delivered at 28.5 weeks. The tumor was resected on the 2nd day of life; however, bleeding could not be controlled, and the infant expired. Although the tumor is benign, perinatal complications are common.



(Left) Axial ultrasound of a neonate shows a large, homogeneous mass arising from the right kidney. The pregnancy had been complicated by severe polyhydramnios and preterm labor. **(Right)** Photograph of the resected kidney from the same case shows the homogeneous, well-defined nature of the mass. Normal renal parenchyma forms a claw around the mass, confirming it is renal in origin.

KEY FACTS

TERMINOLOGY

- Hemorrhage within adrenal gland

IMAGING

- Sonographic features vary depending on age of bleed
 - Active bleeding may be sonolucent
 - As clot solidifies, it may simulate echogenic mass
 - As clot liquefies, appearance changes from complex to simple cystic lesion
 - May see septated cyst
 - May see fluid-fluid level
- Adrenal hematomas may display rim of vascularity around mass
 - No internal flow

TOP DIFFERENTIAL DIAGNOSES

- Neuroblastoma
 - May be cystic, but appearance does not change as quickly as hemorrhage

- Bronchopulmonary sequestration
- Renal mass

PATHOLOGY

- Fetal adrenal 10-20x larger than adult when compared with body mass
- Thought to be more susceptible to hemodynamic stress than adult adrenal

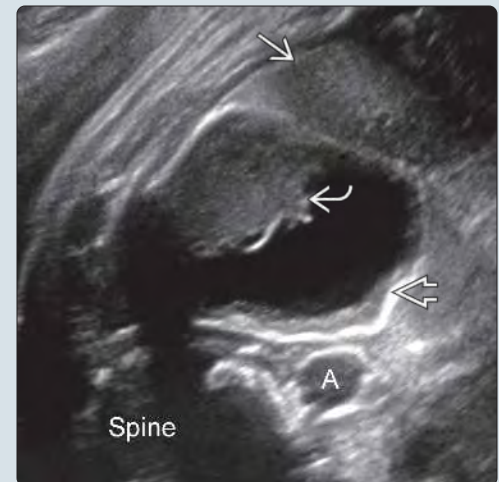
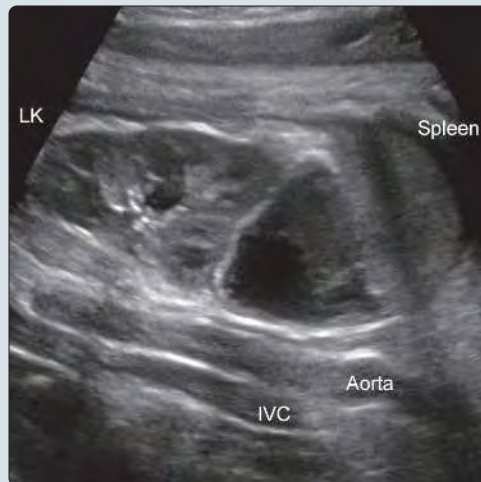CLINICAL ISSUES

- Monitor size with US
- Most will resolve spontaneously
 - Residual scar may calcify
- Avoid adrenalectomy

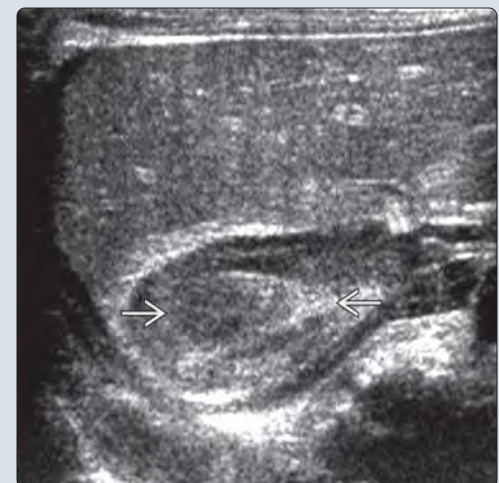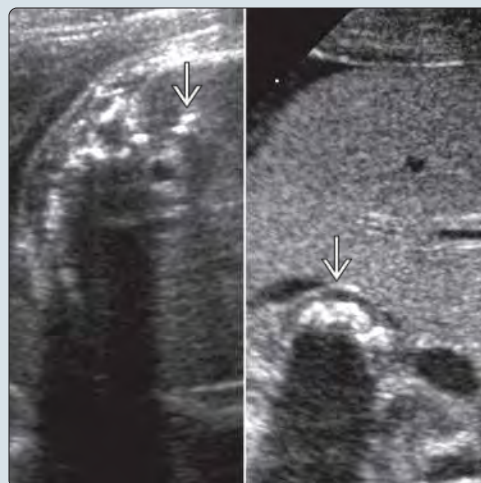
DIAGNOSTIC CHECKLIST

- Key to diagnosis of fetal adrenal hemorrhage is evolution of changes over time
- Cystic neuroblastoma is important differential diagnosis; prognosis is quite favorable when diagnosed prenatally

(Left) Third-trimester scan for size greater than dates shows a new suprarenal cystic mass. Using the 9L transducer, the exact anatomic location was shown, with mass effect on the upper pole of the left kidney (LK). There was no flow on Doppler interrogation. **(Right)** Axial zoomed US of the same lesion, using the highest resolution transducer available, shows retracting clot and mildly "shaggy" walls of the cyst, which is separate from the spleen and aorta (A). This is typical of an adrenal hemorrhage.



(Left) Composite fetal (left) and postnatal (right) US shows adrenal calcification. The fetus had unexplained hydrops and was delivered at 32 weeks for nonreassuring heart tracing. The working diagnosis was intrauterine infection with stress-induced bilateral adrenal hemorrhage. **(Right)** Axial postnatal US shows only a residual, mixed echogenicity "mass" within the right adrenal. This was substantially smaller than the mass seen in utero and resolved completely on follow-up.



TERMINOLOGY

Definitions

- Hemorrhage within adrenal gland

IMAGING

Ultrasonographic Findings

- Features vary depending on age of bleed
 - Active bleeding may be sonolucent
 - As clot solidifies, it may simulate echogenic mass
 - As clot liquefies, appearance changes from complex to simple cystic lesion
 - May see septated cyst
 - May see fluid-fluid level
- May be seen with Beckwith-Wiedemann syndrome (more likely complex internal architecture)
- Color Doppler
 - May see rim of vascularity around mass but no internal flow

MR Findings

- Look for blood products within/around suprarenal mass
- High signal T1WI, intermediate to low signal T2WI

Imaging Recommendations

- Protocol advice
 - Follow-up US to look for change
 - MR may be helpful to prove extrarenal origin if maternal habitus compromises sonographic image quality

DIFFERENTIAL DIAGNOSIS

Neuroblastoma

- Network of microscopic vessels within tumor
- Variable appearance: Homogeneously echogenic, mixed cystic-solid, or, rarely, even entirely cystic
 - Sonographic features do not change rapidly over time, unlike hemorrhage

Extralobar Bronchopulmonary Sequestration

- Should see separate adrenal gland
- Feeding vessel arising from aorta
- Uniform high signal on MR

Renal Mass

- Mass arises within kidney
- May be cystic or solid

PATHOLOGY

General Features

- Etiology
 - Fetal adrenal 10-20x larger than adult when compared with body mass
 - Highly vascular with blood supply from aorta, inferior phrenic, and renal arteries
 - Right adrenal drains directly to inferior vena cava; possibly more susceptible to increased venous pressure than left, which drains to left renal vein
 - Thought to be more susceptible to hemodynamic stress than adult adrenal
 - Etiology of adrenal stress
 - Hypoxia, chronic or acute
 - Growth-restricted fetuses have increased diastolic flow to adrenal gland
 - Trauma, sepsis, bleeding diathesis also contributory

- Associated abnormalities
 - Renal vein thrombosis (if left adrenal hemorrhage)

CLINICAL ISSUES

Presentation

- Most common signs/symptoms
 - Suprarenal cyst or mass seen on routine obstetric sonography
 - More commonly seen in premature infants in ICU

Demographics

- 1.7:1,000 in autopsy series
- 2-3:1,000 detected at birth or on postnatal US screening
- Occurs 2-3x more frequently on right than left
- Bilateral in 5-15% of cases
- In utero incidence unknown (reported cases first seen from 21-36 weeks)

Natural History & Prognosis

- Newborn findings include anemia, jaundice, hypovolemic shock, hypertension, renal or bowel obstruction, adrenal abscess development
- Adrenal insufficiency uncommon
 - Seen only with bilateral bleeding when > 90% of adrenal tissue destroyed
- May rupture → retroperitoneal or intraperitoneal hemorrhage
- Eventually resolve, leaving small, calcified scar
- Prognosis depends on causative insult more so than on hemorrhage itself
 - Many fetal cases are idiopathic

Treatment

- Monitor size with US
 - Most will resolve spontaneously
 - Lack of regression is indication for further work-up (CT or MR) ± surgical exploration
- Avoid adrenalectomy

DIAGNOSTIC CHECKLIST

Consider

- Cystic neuroblastoma is important differential diagnosis; prognosis is quite favorable when diagnosed prenatally

Reporting Tips

- Key to diagnosis of fetal adrenal hemorrhage is evolution of changes over time

SELECTED REFERENCES

1. Maki E et al: Imaging and differential diagnosis of suprarenal masses in the fetus. *J Ultrasound Med.* 33(5):895-904, 2014
2. Schrauder MG et al: Fetal adrenal haemorrhage—two-dimensional and three-dimensional imaging. *Fetal Diagn Ther.* 23(1):72-5, 2008
3. de Luca JL et al: Diagnostic and therapeutic dilemma with large prenatally detected cystic adrenal masses. *Fetal Diagn Ther.* 17(1):11-6, 2002

KEY FACTS

TERMINOLOGY

- Malignant tumor composed of neuroblasts, arising within sympathetic neural plexus or adrenal medulla

IMAGING

- > 90% of fetal cases arise in adrenal gland but may occur anywhere along sympathetic chain
- ~ 25% are cystic
 - May represent involuting tumor
- Liver most common location for metastases
 - Diffusely infiltrating liver metastases often difficult to diagnose
- Look for placental metastases especially if maternal symptoms of catecholamine excess

TOP DIFFERENTIAL DIAGNOSES

- Extralobar sequestration
 - Dominant feeding vessel from aorta helps differentiate from neuroblastoma

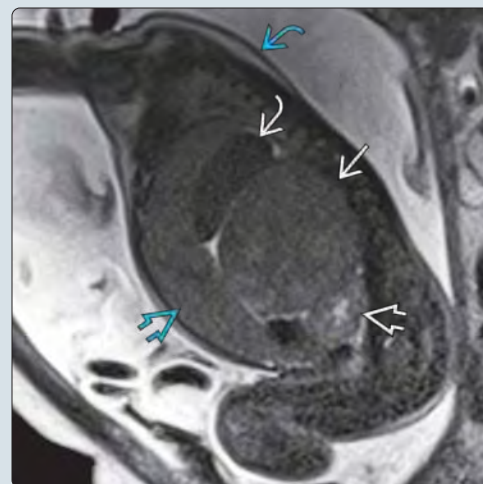
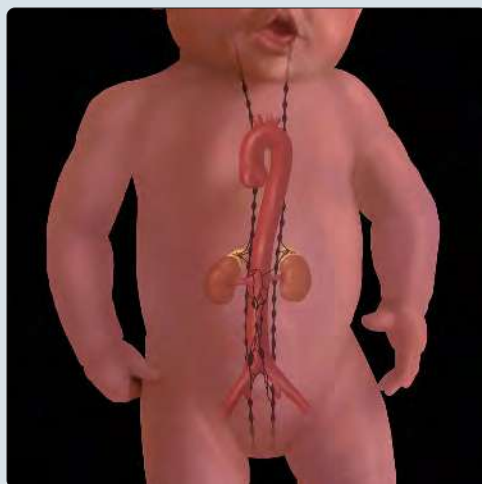PATHOLOGY

- Normal fetal adrenal contains neuroblastic nodules
- Fetal neuroblastoma may represent temporary defect in growth of these nodules that are destined to involute over time
- May explain nonaggressive nature of fetal tumors when compared to those in pediatric age group

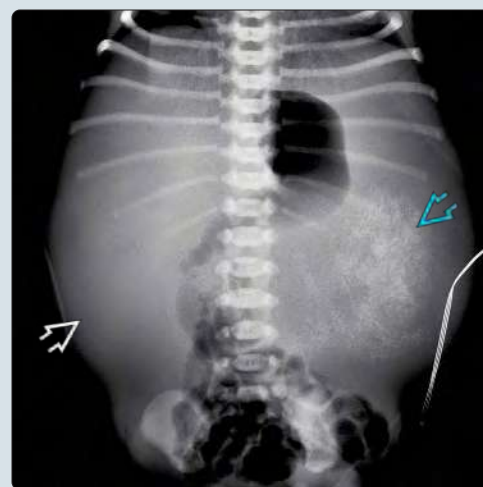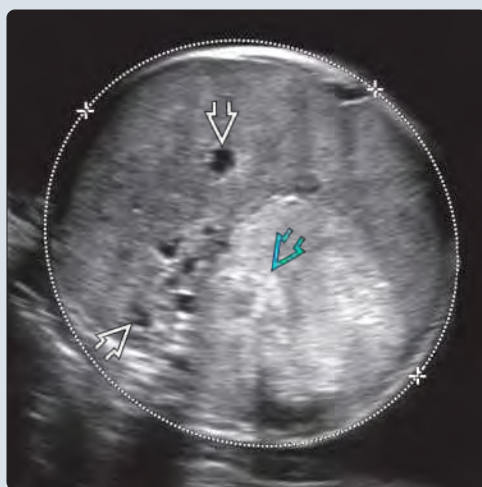
CLINICAL ISSUES

- Most common congenital malignancy
- Variable fetal course
 - May resolve spontaneously
 - Most remain stable without complications
 - Minority progress to hydrops and even death
- Most fetal neuroblastomas have both favorable stage and biologic markers
 - Excellent prognosis for this group
 - Many now advocate more conservative postpartum treatment approach

(Left) Neuroblastoma can occur anywhere along the sympathetic chain, which extends from the neck to the pelvis. In a fetus, > 90% of neuroblastomas arise from the adrenal medulla. **(Right)** Sagittal fetal MR shows a large suprarenal mass displacing the kidney inferiorly. There is dramatic hepatomegaly with the low-signal spleen sandwiched between the liver and the neuroblastoma. Other sequences showed diffuse metastatic disease throughout the liver. There is also skin edema.



(Left) Abdominal circumference view in the same patient shows stippled calcifications within the mass. The liver is heterogeneous with small, scattered, irregular cysts, the result of metastatic infiltration. **(Right)** Postnatal radiograph shows compression of bowel in the midline from the hepatomegaly on the right and neuroblastoma on the left. Note the faint calcifications. The infant began immediate multiagent chemotherapy with excellent response and is doing well.



TERMINOLOGY**Definitions**

- Malignant tumor composed of neuroblasts, arising within sympathetic neural plexus or adrenal medulla

IMAGING**General Features**

- Best diagnostic clue
 - No identifiable adrenal gland on side of mass
- Location
 - May occur anywhere along sympathetic chain
 - > 90% occur in adrenal gland
 - In contrast to pediatric population in which only 35% occur in adrenal gland
 - Cervical and thoracic tumors also reported
 - 60% are right sided
- Morphology
 - ~ 25% are cystic
 - May represent involuting tumor
 - Remainder are solid or complex
 - Solid masses are more likely to metastasize

Ultrasonographic Findings

- Variable appearance
 - Complex cystic mass with thick septations
 - Uniformly echogenic solid mass
 - Calcifications
 - Less common than in pediatric age group
- Color Doppler shows flow but usually is not highly vascular
 - Does not have single feeding vessel
 - Helps to differentiate from extralobar sequestration
- May have hydrops
 - Large masses
 - Metastases
- Hepatic metastases
 - May be diffusely infiltrating or discrete masses
- Placental metastases (rare)
 - Microscopic tumor emboli so may be appear normal
 - Bulky, hydropic placenta
 - Discrete masses less likely

MR Findings

- Confirm anatomic location
- Signal characteristics, variable depending on cystic or solid composition
 - Both low on T1WI
 - Cystic: Marked increased signal on T2WI
 - Solid: Moderate increased signal on T2WI
- Can help exclude adrenal hemorrhage from differential (high signal on T1WI)
- Useful for staging and evaluating metastases

Imaging Recommendations

- Confirm adrenal origin of mass
 - Document mass is separate from kidney
 - Look for normal adrenal
- Assess vascularity with color Doppler
 - Rule out dominant feeding vessel
- Careful examination for metastases

- Liver most common location for metastases
 - Diffusely infiltrating liver metastases are difficult to diagnose
 - Be suspicious when hepatomegaly or hydrops is present
- Close follow-up
 - Mass may either grow or regress
 - Look for hydrops

DIFFERENTIAL DIAGNOSIS**Extralobar Sequestration**

- More likely than neuroblastoma as cause of left-sided suprarenal mass, especially if solid
 - 90% on left
 - Uniformly echogenic solid mass
 - Present earlier (2nd trimester)
- Dominant feeding vessel from aorta
- Separate adrenal gland may be identified

Adrenal Hemorrhage

- Reported in utero but uncommon
- No color flow within mass
- MR can confirm blood products (bright on T1WI)

Duplicated Collecting System

- Hydronephrotic upper pole may be mistaken for cystic suprarenal lesion
- Look for ectopic ureterocele in bladder
- Separate adrenal gland should be identified

PATHOLOGY**General Features**

- Etiology
 - Normal fetal adrenal contains neuroblastic nodules
 - Histologically indistinguishable from neuroblastoma
 - Peak number of nodules 17- to 20-weeks gestation
 - Nodules involute over time
 - Present in 100% of fetal adrenals in 2nd trimester
 - Present in only 0.5-2.5% of newborn adrenal glands
 - Fetal neuroblastoma may represent temporary defect in growth of these nodules that are destined to involute over time
 - May explain nonaggressive nature of fetal tumors when compared to those in pediatric age group
 - Reports of increased incidence following assisted reproductive therapy suggest role of epigenetic reprogramming in some cases
 - Maternal environmental exposures suggested but not confirmed
- Genetics
 - Most are sporadic
 - 1-2% familial; autosomal dominant with incomplete penetrance
 - Germline mutations in 2 genes *ALK* and *PHOX2B*

Staging, Grading, & Classification

- International Neuroblastoma Staging System
 - Stage 1: Confined to adrenal gland
 - Stage 2: Extension beyond adrenal but does not cross midline

- Stage 3: Extension across midline
- Stage 4: Distant metastases
- Stage 4s (special): Unique grouping of metastases, with excellent prognosis
 - Skin, liver, and < 10% of bone marrow (not bone)
- International Neuroblastoma Risk Group Staging System
 - Introduced in 2009 as consensus approach to pretreatment risk stratification
 - L1: Locoregional tumor without imaged defined risk factors (IDRF)
 - IDRF is checklist of invasion/encasement of surrounding structures
 - L2: Locoregional tumor with 1 or more IDRF
 - M: Distant metastatic disease (except Ms)
 - Ms: Equivalent to 4s
- 70% fetal mortality rate if mother presents with preeclampsia from placental metastases
- International Neuroblastoma Risk Group Staging System
 - Low risk group
 - Localized (L1) and Ms disease, no unfavorable biologic markers
 - 70% of neonatal neuroblastoma
 - 95-100% 5-year survival
 - Intermediate risk group
 - L2 (nonlocalized disease) ± metastases; L1 + unfavorable biologic markers
 - 25% of neonatal neuroblastoma
 - 85-95% survival rate
 - High-risk group
 - L2 + M + unfavorable biologic markers
 - 5% of neonatal neuroblastoma
 - 30-40% 5-year survival

Microscopic Features

- Derive from primordial neural crest cells
- Cystic change may indicate ongoing involution
 - Cystic tumors have small aggregates of neuroblasts in cyst wall
 - Solid tumors have sheets of tumor cells
- Tumors may "mature" to more benign histologic type
 - Neuroblastoma: Malignant tumor composed of neuroblasts
 - Ganglioneuroblastoma: Malignant tumor with both immature and mature elements
 - Ganglioneuroma: Benign tumor composed of mature ganglion cells
- Biologic markers
 - *MYCN* amplification
 - Protooncogene on chromosome 2p
 - Multiple copies (> 10) in aggressive tumors
 - DNA index
 - Tumors with increased DNA content (index > 1) have more favorable prognosis
 - Most fetal neuroblastomas have favorable DNA index (> 1) and no *MYCN* amplification

CLINICAL ISSUES

Presentation

- Reported as early as 20 weeks
- Generally incidental finding in 3rd trimester
 - Adrenal mass most common
 - Thoracic and cervical masses reported
- Rarely, mother presents with preeclampsia or headaches
 - Fetal catecholamines may reach maternal circulation
 - Concerning for placental metastases

Demographics

- Epidemiology
 - Most common congenital malignancy
 - 30% of all fetal tumors
 - 2nd only to teratomas

Natural History & Prognosis

- Variable fetal course
 - May resolve spontaneously
 - Most remain stable without complications
 - Minority progress to hydrops and even death

Treatment

- Consider early delivery if rapidly growing or metastases, with deteriorating status
 - Chemotherapy may be started immediately after stabilization
- Given often indolent course, many advocate more conservative postpartum approach for stable masses
 - Urine catecholamines
 - Only elevated in 1/3 of cases
 - Baseline ultrasound, MR, and nuclear medicine MIBG scan
 - MIBG scan usually only positive if catecholamines are elevated
 - Surgical resection if > 5 cm
 - Consider biopsy of smaller solid masses
 - If favorable biologic markers and stage → follow
 - Poor biologic markers/stage or failure to involute → surgery
 - May choose to follow cystic masses

DIAGNOSTIC CHECKLIST

Consider

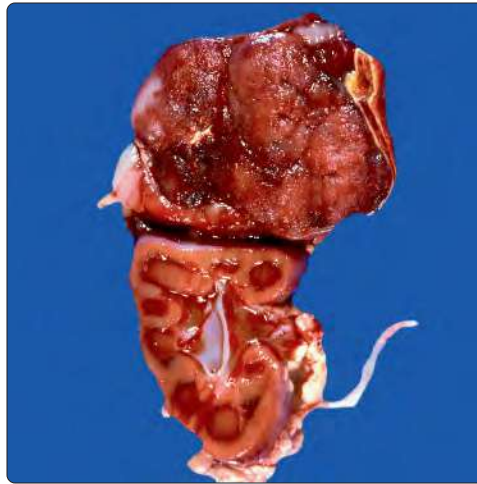
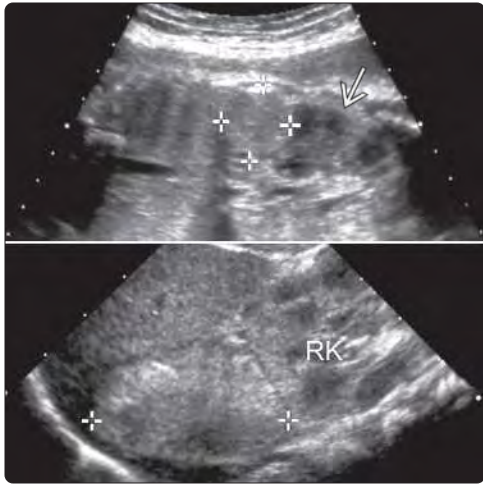
- Overall prognosis for fetal neuroblastoma is excellent
- Majority of tumors have favorable stage and biologic markers

Image Interpretation Pearls

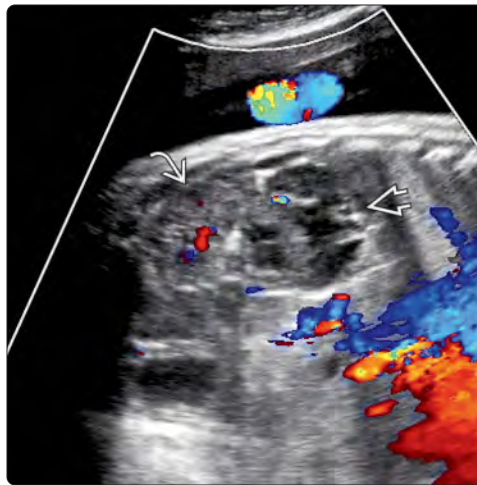
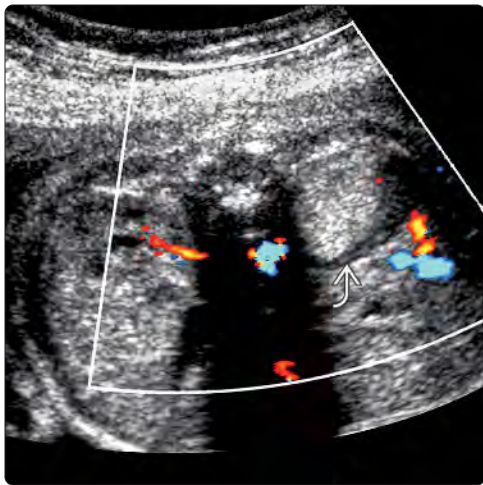
- Only 1/2 of suprarenal masses are neuroblastomas, so must carefully evaluate for other causes, especially extralobar sequestration

SELECTED REFERENCES

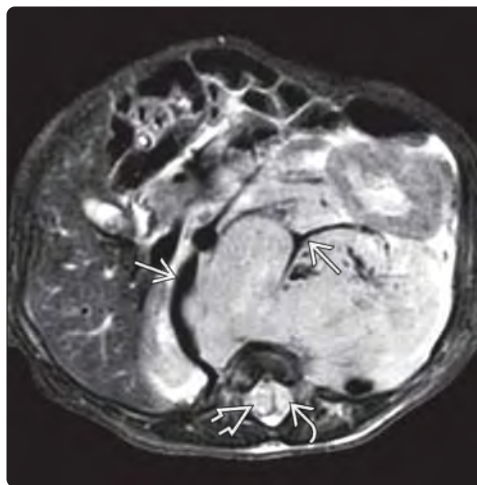
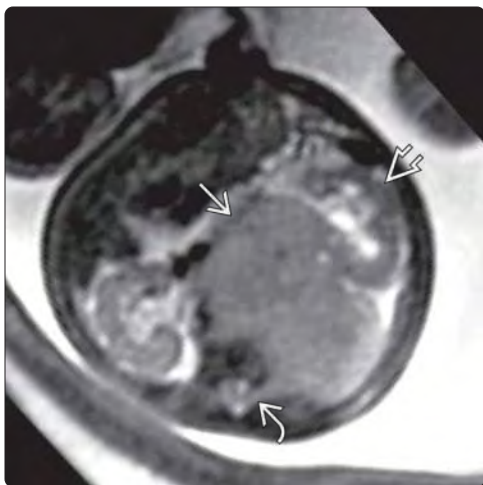
1. Koh V et al: Neuroblastoma in children under 12 months in Singapore—15-year experience and outcomes from KKH. *Fetal Pediatr Pathol.* 34(3):155-61, 2015
2. Kume A et al: Congenital neuroblastoma with placental involvement. *Int J Clin Exp Pathol.* 7(11):8198-204, 2014
3. Maki E et al: Imaging and differential diagnosis of suprarenal masses in the fetus. *J Ultrasound Med.* 33(5):895-904, 2014
4. Fisher JP et al: Neonatal neuroblastoma. *Semin Fetal Neonatal Med.* 17(4):207-15, 2012
5. Monclair T et al: The International Neuroblastoma Risk Group (INRG) staging system: an INRG Task Force report. *J Clin Oncol.* 27(2):298-303, 2009
6. Isaacs H Jr: Fetal and neonatal neuroblastoma: retrospective review of 271 cases. *Fetal Pediatr Pathol.* 26(4):177-84, 2007



(Left) Coronal ultrasound of the fetal abdomen (top) shows a solid, echogenic mass (calipers) above the right kidney. **(Bottom)** Sagittal ultrasound after delivery confirms a solid, suprarenal mass (calipers). **(Right)** Photograph of the surgical specimen shows the adrenal mass compressing the upper pole of the kidney. Most fetal neuroblastoma is low risk and has both a favorable stage and biologic markers. Current treatment recommendations are for a more conservative approach, with many being followed rather than resected.



(Left) Axial color Doppler ultrasound shows an echogenic mass in the left renal fossa (the left kidney was displaced inferiorly). A thin rim of normal adrenal cortex remains. It is important to interrogate the mass with color Doppler to rule out a feeding vessel, as would be seen with an extralobar sequestration. **(Right)** Coronal color Doppler ultrasound shows a suprarenal complex cystic mass (kidney). Fetal neuroblastoma is often cystic, which may represent involving tumor.



(Left) Axial T2WI fetal MR shows a large retroperitoneal mass that has invaded the neural foramen. The left kidney is displaced anteriorly. **(Right)** Postnatal axial T2WI MR in the same patient shows encasement and displacement of the abdominal vessels by the mass. Tumor invasion into the spinal canal is confirmed with displacement of the spinal cord to the right. Most fetal neuroblastomas arise from the adrenal gland, but they can occur anywhere along the sympathetic chain, as in this case.

KEY FACTS

TERMINOLOGY

- Autosomal recessive disorder of cortisol production
 - Virilizing type
 - Salt-wasting type

IMAGING

- Look at genitalia in sagittal view when fetal sex unclear
 - Female genital ridge points inferiorly
 - Male genital ridge points superiorly
- Virilization of female genitalia
 - Clitoromegaly ± fused labia
 - Labia can mimic scrotum
- Affected male patients with normal genitalia
- Adrenal glands may be normal or enlarged
 - Lose normal tricorn morphology
 - Adrenals may appear mass-like
 - Might see asymmetric enlargement
 - Fetal MR helpful to show that "mass" is adrenal gland

TOP DIFFERENTIAL DIAGNOSES



- Disorders of sexual development (other causes)
 - Hypospadias
 - Small penis (variety of etiologies)
- Other suprarenal masses
 - Neuroblastoma
 - Bronchopulmonary sequestration

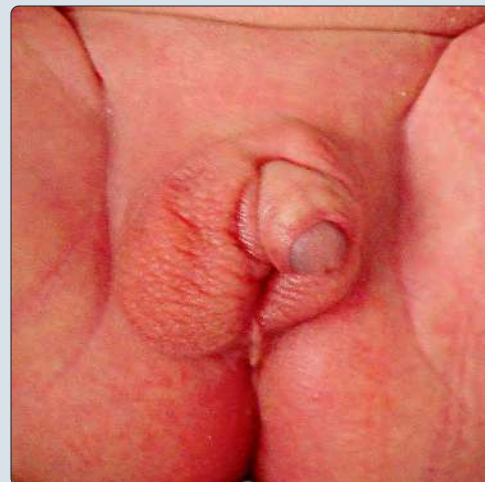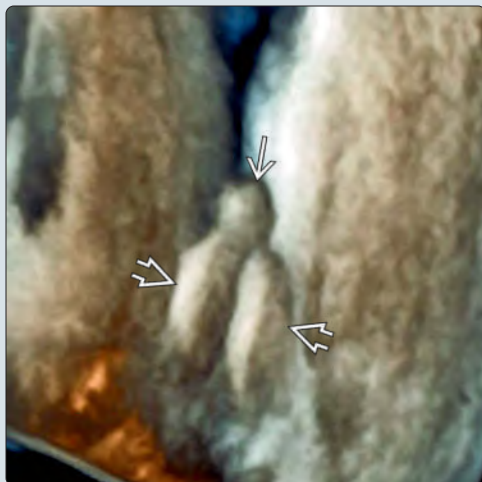
PATHOLOGY




- 95% from mutation in *CYP21A2* gene

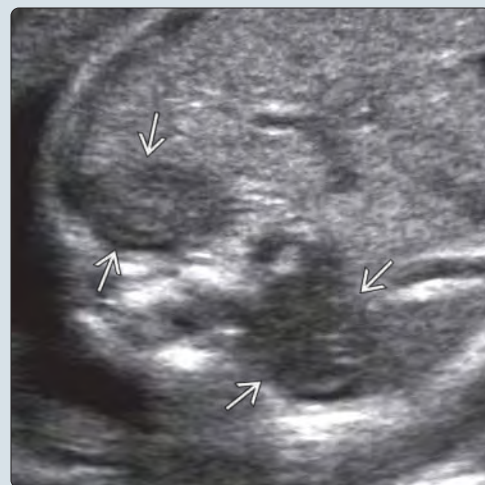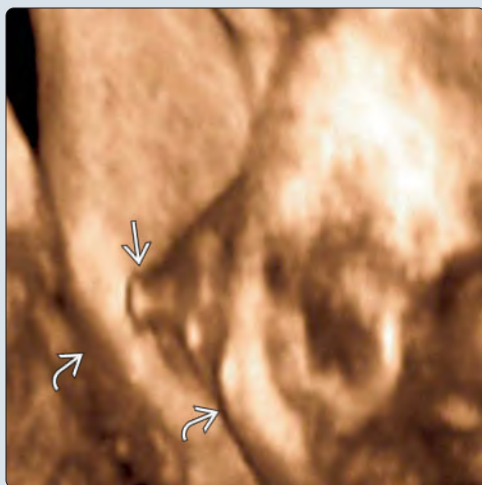CLINICAL ISSUES

- In utero treatment of high-risk patients is controversial
 - Low-dose dexamethasone before 9th week gestation
 - Later treatment has little effect
- Salt wasting from inadequate aldosterone synthesis
 - Can be lethal when severe
- Considered chronic disease with lifelong sequelae
 - Surgical intervention for genital ambiguity often pursued

(Left) 3D ultrasound of the perineum in a female fetus with congenital adrenal hyperplasia (CAH) shows clitoromegaly  resembling a penis and labia  that resemble a scrotum. **(Right)** Clinical photograph of a female child with CAH shows stigmata of genitalia virilization. The labia have scrotal-like skin folds, and the clitoris resembles a small penis. Girls and women with CAH will often have surgical revision.



(Left) Sagittal 3D ultrasound of clitoromegaly in another female fetus with CAH shows the prominent genital tubercle  pointing inferiorly, a clue that the sex is female. The legs are up and  points to the buttocks. **(Right)** Axial ultrasound of the adrenal glands, in the same case, shows enlarged globular adrenal glands , typical for CAH. The adrenal glands have lost their normal tricorn or Y-shaped appearance.



TERMINOLOGY

Abbreviations

- Congenital adrenal hyperplasia (CAH)

Definitions

- Autosomal recessive disorder of cortisol production
 - 95% are from 21-hydroxylase deficiency
 - Virilizing type &/or salt-wasting type
 - 5% from 11- or 17-hydroxylase deficiency

IMAGING

General Features

- Best diagnostic clue
 - Virilization of female genitalia
 - Affected male patients with normal genitalia
 - Enlarged adrenal glands

Ultrasonographic Findings

- Clitoromegaly ± fused labia
 - Female clitoral genital ridge can mimic penis
 - Labia can mimic scrotum
- Adrenal gland is normal or enlarged
 - Normative data available
 - Globular gland (lose normal tricorn morphology)
 - Might see asymmetric enlargement
 - Can mimic suprarenal mass
 - Fetal MR helpful to show "mass" is adrenal gland
 - Homogeneous enlarged adrenal gland with same signal characteristics as contralateral gland
 - Low signal on T2 MR

Imaging Recommendations

- Protocol advice
 - Look at genitalia in sagittal view when fetal sex unclear
 - Female genital ridge points inferiorly
 - Male genital ridge points superiorly
 - 3D helpful to show morphology

DIFFERENTIAL DIAGNOSIS

Other Disorders of Sexual Development

- **Hypospadias (severe)**
 - 2 echogenic lines at penile tip (prepuce folds)
 - Tulip sign: Small penis between scrotal folds
 - Associated chordee and cryptorchism
- **Small penis as etiology of disorder of sexual development**
 - "Buried penis" without hypospadias
 - Microphallus from variety of associations

Other Suprarenal Mass

- **Neuroblastoma**
 - Variable appearance (solid, cystic, mixed)
 - No separate adrenal gland in 90%
- **Bronchopulmonary sequestration**
 - Usually solid but can have cysts
 - Dominant systemic feeding vessel (from aorta)
 - Separate from adrenal gland

PATHOLOGY

General Features

- 95% from mutation in *CYP21A2* gene
- ↓ cortisol → ↑ adrenocorticotropic hormone production (pituitary gland) → ↑ adrenal androgen and progesterone
- ↓ aldosterone production also occurs (salt-wasting cause)

CLINICAL ISSUES

Presentation

- Most common signs/symptoms
 - High-risk fetus because of prior affected sibling
- Other signs/symptoms
 - Salt wasting from inadequate aldosterone synthesis
 - Most often present 1-4 weeks after delivery
 - Hyponatremia, hyperkalemia, hypoglycemia
 - Dehydration, vomiting, shock
 - Can be lethal when severe

Demographics

- Most common inherited metabolic disorder
- 1:10,000-15,000 newborns

Natural History & Prognosis

- CAH considered chronic disease with life-long sequelae
- Variable degree of female virilization
 - Infertility (androgen excess)
 - Ovarian adrenal rest tumors
 - ↑ psychosocial disorders reported
- Male manifestation also variable
 - Testicular adrenal rest tumors (TART)
 - Poor CAH control associated with ↑ TART
 - Do not misdiagnose as bilateral testicular tumors
 - Resolve with improved hormonal control
 - Infertility from hypogonadism and TART

Treatment

- In utero treatment of high-risk patients is controversial
 - Low-dose dexamethasone before 9th-week gestation
 - ~ 75% at-risk fetuses will get unnecessary therapy
 - Later treatment has little effect
 - New reports suggest that cell-free fetal DNA can identify affected fetuses as early as 6-weeks gestational age
 - Targeted testing of *CYP21A2* gene region
 - Also used to determine fetal sex
- Surgical intervention for genital ambiguity

SELECTED REFERENCES

1. Khattab A et al: Noninvasive prenatal diagnosis of congenital adrenal hyperplasia. *Endocr Dev.* 30:37-41, 2016
2. Odenwald B et al: Children with classic congenital adrenal hyperplasia experience salt loss and hypoglycemia: evaluation of adrenal crises during the first 6 years of life. *Eur J Endocrinol.* 174(2):177-86, 2016
3. Heland S et al: Preventing female virilisation in congenital adrenal hyperplasia: The controversial role of antenatal dexamethasone. *Aust N Z J Obstet Gynaecol.* ePub, 2015
4. Maki E et al: Imaging and differential diagnosis of suprarenal masses in the fetus. *J Ultrasound Med.* 33(5):895-904, 2014
5. van Vuuren SH et al: Size and volume charts of fetal kidney, renal pelvis and adrenal gland. *Ultrasound Obstet Gynecol.* 40(6):659-64, 2012

KEY FACTS

TERMINOLOGY

- Most common cause of fetal lower urinary tract obstruction
- Exclusively in male fetuses

IMAGING

- Distended bladder "funnels" into urethra
 - Keyhole sign from dilated posterior urethra
- Oligohydramnios
- Hydronephrosis/hydroureter
- Associated malformations in 43%
- Rupture → urinoma or urinary ascites
- Evaluate for signs of obstructive renal dysplasia
 - ↑ renal parenchymal echogenicity
 - Renal cortical cysts
 - Renal atrophy

TOP DIFFERENTIAL DIAGNOSES

- Prune-belly syndrome
- Cloacal malformation

PATHOLOGY

- Posterior urethral membrane acts as valve
 - Results in bladder outlet obstruction (usually partial)
 - Occurs exclusively in males

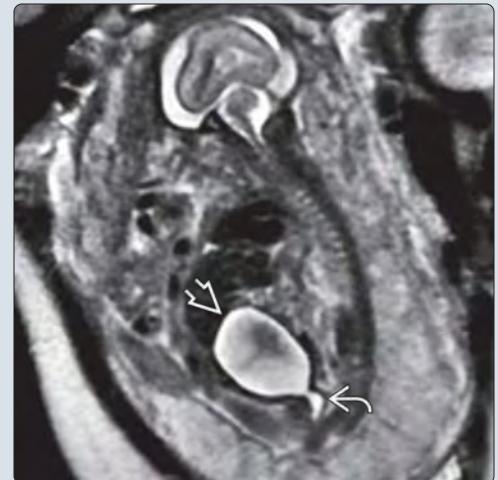
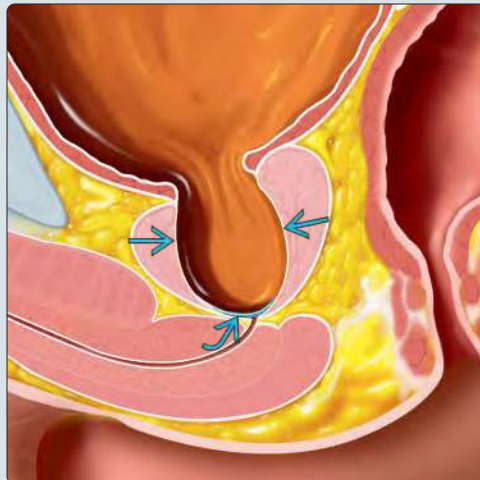
CLINICAL ISSUES

- Wide range of severity with overall mortality 25-50%
- Variable degree of fetal renal damage
 - Affects long-term outcomes and survival
- Consider intervention
 - Cases with good prognostic markers
 - Worsening urinary tract dilation or oligohydramnios
- Poor outcome predictors
 - Severe oligohydramnios and early gestational age
- No intervention if amniotic fluid volume normal

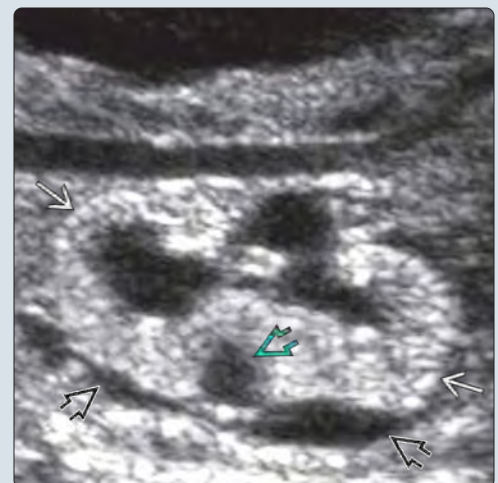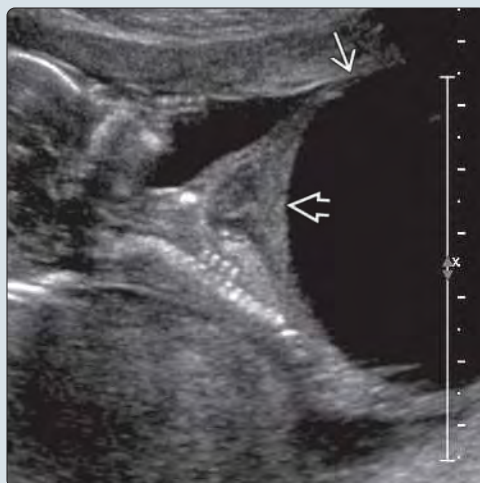
DIAGNOSTIC CHECKLIST

- Hallmark findings are dilated bladder + oligohydramnios in male fetus

(Left) Sagittal graphic shows the bladder funneling into a dilated posterior urethra. The valve forms a thin membrane of tissue, blocking antegrade flow of urine and creating a lower urinary tract obstruction. **(Right)** Sagittal T2WI MR shows a very distended bladder and dilated posterior urethra in this fetus with posterior urethral valves (PUV). Note the complete lack of amniotic fluid surrounding this fetus. This image shows the keyhole appearance of the bladder.



(Left) The obstructed bladder markedly distends the abdomen, with mass effect displacing the diaphragm upward. In combination with oligohydramnios, these findings can result in lung hypoplasia. **(Right)** Coronal ultrasound in a fetus with PUV shows an echogenic kidney with hydronephrosis, renal parenchymal cyst, and a rim of perinephric fluid indicating small urinoma. These findings are poor prognosticators for renal function.



TERMINOLOGY

Abbreviations

- Posterior urethral valves (PUV)
- Lower urinary tract obstruction (LUTO)

Definitions

- Urethral membrane acts as valve, resulting in LUTO
 - Obstruction is usually partial
 - Posterior urethra obstructed by valves
 - Occurs exclusively in males

IMAGING

General Features

- Best diagnostic clue
 - Dilated bladder + keyhole sign
 - Bladder "funnels" into dilated posterior urethra
- LUTO with subsequent upper tract dilation
 - PUV is 1 of several etiologies of LUTO

Ultrasonographic Findings

- Male fetus
 - Difficult to determine sex if oligohydramnios is severe
- Bladder distension
 - May fill entire abdomen
 - Dilated keyhole appearance of posterior urethra
 - If present, suggests diagnosis of PUV
 - ◻ Not always seen
 - ◻ Relatively sensitive but less specific sign of PUV
 - Urethral atresia can give similar appearance
 - Thick walled with prominent trabeculae
 - May not see with severe dilatation
 - More visible after vesicocentesis
 - ↑ bladder wall thickness with dilatation highly associated with PUV
- Hydronephrosis/hydroureter is variable
 - Renal severe obstruction findings
 - Postobstructive cystic dysplasia
 - Complete effacement of calyces
 - Dilated serpiginous ureters can mimic bowel
- Oligohydramnios is variable
 - Small, bell-shaped chest → pulmonary hypoplasia
 - Poor prognosis: 80% fatality rate
- Urinary complications
 - Bladder rupture → urinary tract decompression
 - Favorable prognostic sign, relieves pressure on kidneys
 - ◻ Urinary ascites ± peritoneal calcifications
 - ◻ Urinary pleural effusion (less common)
 - Collecting system rupture
 - Perinephric fluid collection = urinoma
 - Urinoma associated with worse renal prognosis
 - ◻ Indicates severe obstruction of upper tracts
- Associated malformations in 43%
 - Cardiac malformations
 - May be seen with VACTERL association

MR Findings

- Additive if severe oligohydramnios or maternal obesity
- Potential role for seeing renal cystic dysplasia

Imaging Recommendations

- Protocol advice
 - Determine fetal sex if possible
 - Follow all fetuses with large bladder
 - Often transient
 - ◻ Especially if normal urinary tract and amniotic fluid
- **Look for poor prognostic signs**
 - ↑ renal parenchymal echogenicity
 - Kidney echogenicity > liver
 - ◻ Loss of corticomedullary differentiation
 - Echogenic parenchyma thought to be due to fibrosis
 - ◻ Suggests, but is not diagnostic of, dysplasia
 - Likely due to back pressure from outflow obstruction
 - Irreversible (even if obstruction relieved)
 - Degree of urinary tract dilation does not correlate with degree of dysplasia
 - Renal cortical cysts
 - 100% predictive for dysplasia
 - Indicates irreversible damage
 - ◻ Fetus unlikely to benefit from in utero intervention
 - Described as early as 20-weeks gestation
 - Renal atrophy
 - Measure renal length (compare with normative data)
 - Worsening renal collecting system dilation
 - Unilateral "protects" other kidney (better prognosis)

DIFFERENTIAL DIAGNOSIS

Prune-Belly Syndrome

- Triad of findings
 - Lax or absent abdominal musculature
 - Thin-walled, dilated bladder
 - Cryptorchidism
- Entire urethra dilation might be seen
 - Less likely to have keyhole

Cloacal Malformation

- Exclusively in females
- Dilated, fluid-filled vagina can mimic bladder
 - Up to 60% with duplicated vagina (look for septum)
- Complex anomaly from failed embryonic cloacal division
 - Convergence of bladder, rectum, vagina
 - Single perineal opening

Megacystis-Microcolon

- More common in females (4:1)
- Thin-walled bladder without dilated posterior urethra
- Amniotic fluid normal to increased

Urethral Atresia (Rare)

- May have identical appearance to LUTO from PUV
- Male and female
- Complete obstruction
 - Severe oligohydramnios, may progress to anhydramnios

PATHOLOGY

General Features

- Etiology
 - Valve tissue forms thin membrane
 - Abnormal thickening/fusion of circular mucosal folds

- Genetics
 - Sporadic, rarely reported in siblings
 - Genetic testing offered for LUTO
 - Trisomy 18 associated with LUTO
 - PUV less likely to have aneuploidy
 - Bladder aspirate can be sent for genetic testing
 - Confirm fetal sex

Microscopic Features

- Smooth muscle hypertrophy in bladder/ureteral walls
 - May progress to fibrosis
 - Ureters remain distended despite relief of obstruction

CLINICAL ISSUES

Presentation

- Fetal bladder distension on anatomy scan
- Oligohydramnios
- Large fetal bladder in 1st trimester at time of nuchal translucency scan

Demographics

- Epidemiology
 - 1:8,000 to 25,000 liveborn males
 - Higher incidence in utero
 - Reflects ↑ in utero mortality rates

Natural History & Prognosis

- Wide range of severity
- Overall mortality 25-50%
 - > 90% with oligohydramnios
 - Oligohydramnios + early age at diagnosis → worse outcomes
 - Pulmonary hypoplasia → neonatal demise
- Mild and moderate cases in utero have better prognosis
 - Very mild cases may remain undetected until childhood
 - Rule out PUV in all newborns with persistent bladder dilation or hydronephrosis as fetuses
- Severity of fetal renal damage affects long-term outcomes
 - Renal insufficiency develops in up to 45% of survivors
 - Vesicoureteral reflux may persist in childhood
- Phenotypic features of severe oligohydramnios
 - Potter facies
 - Flexion contractures
 - Pulmonary hypoplasia

Treatment

- Termination often offered (especially severe cases)
- < 32 weeks, assess renal function
 - Perform serial bladder drainages over 3-4 days
 - 3rd sample most useful ("fresh" urine)
 - Normal fetal urine is hypotonic
 - Isotonic urine → poor renal function
 - **Good prognostic indicators**
 - Na < 100 mEq/L
 - Cl < 90 mEq/L
 - Osmolarity < 210 mOsm/L
 - β 2-microglobulin < 4 mg/L
 - Ca < 8 mg/dL
 - Sonographically normal kidneys (normal echogenicity, no cysts, preserved corticomedullary differentiation)

- β 2-microglobulin
 - Large amounts in fetal urine → renal damage
- > 32 weeks, assess progression
 - Worsening oligohydramnios → deliver → endoscopic valve ablation
- Consider intervention if good prognosticators and worsening oligohydramnios &/or hydronephrosis
 - Vesicoamniotic shunt
 - Goal is to prevent pulmonary hypoplasia
 - No real effect on improving renal function
 - 1/3 with complications
 - Shunt will occlude or migrate
 - Often pulled out by fetus
 - Anterior placenta relative contraindication
 - Vesicostomy if shunt fails
 - Shown to potentially improve pulmonary function
 - No effect on renal outcome
 - Fetal cystoscopy with endoscopic valve ablation
 - Recent experimental invasive procedure
 - Difficult to access fetal bladder due to angulation at bladder neck
 - Fetal selection criteria not clearly defined
- Generally no intervention if amniotic fluid volume normal
- No improvement in outcome for intervention late in pregnancy
- Antenatal detection can help facilitate early postnatal intervention
 - May aid in reducing incidence of chronic kidney disease
- Long-term sequelae from poor bladder function may necessitate urinary diversion surgery

DIAGNOSTIC CHECKLIST

Consider

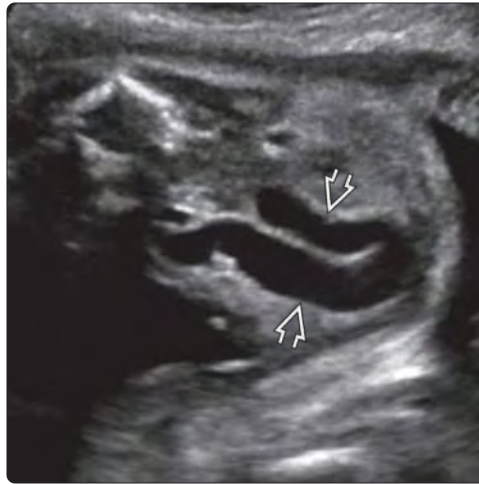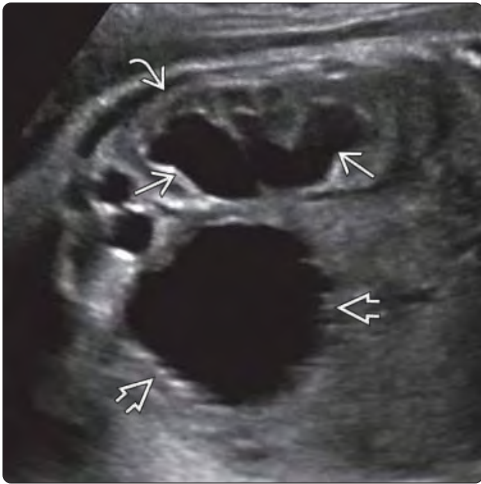
- Early oligohydramnios → poor prognosis
 - Early diagnosis of PUV allows consideration of intervention
- Intervention may result in live birth, but 45% of survivors still have renal insufficiency

Image Interpretation Pearls

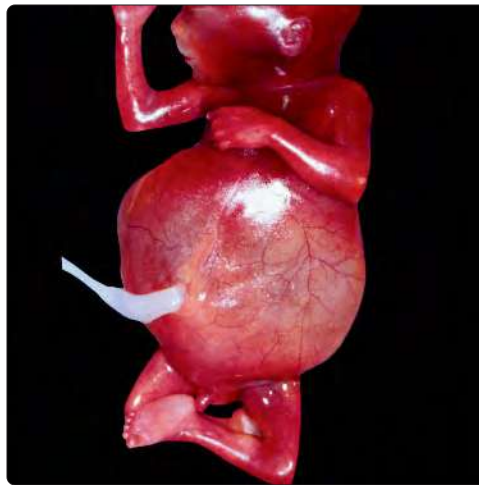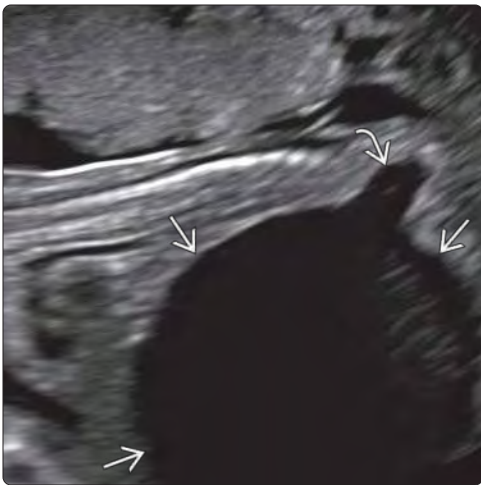
- Look at fetal sex first when LUTO diagnosed
 - Dilated thick-walled bladder + oligohydramnios in male fetus highly suspicious for PUV
 - Female fetus more likely to have cloacal malformation or urethral agenesis (rare)

SELECTED REFERENCES

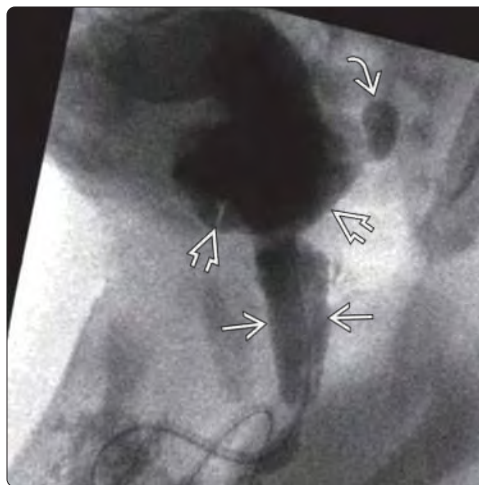
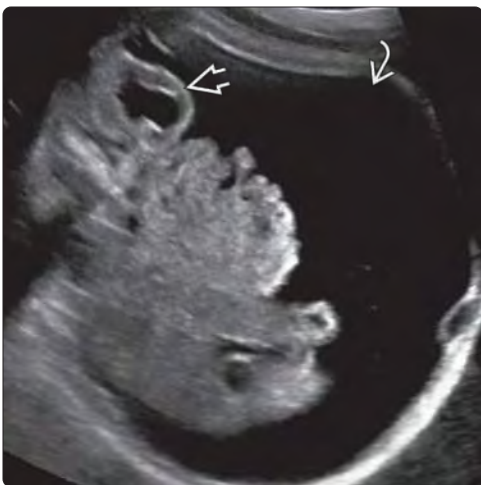1. Smith-Harrison LI et al: Current applications of in utero intervention for lower urinary tract obstruction. *J Pediatr Urol.* 11(6): 341-7, 2015
2. Sarhan OM et al: Did antenatal diagnosis protect against chronic kidney disease in patients with posterior urethral valves? A multicenter study. *Urology.* 82(6):1405-9, 2013
3. Ansari MS et al: Risk factors for progression to end-stage renal disease in children with posterior urethral valves. *J Pediatr Urol.* 6(3):261-4, 2010
4. Kohl T: Minimally invasive fetoscopic interventions: an overview in 2010. *Surg Endosc.* 24(8):2056-67, 2010
5. Wells JM et al: Urinomas protect renal function in posterior urethral valves—a population based study. *J Pediatr Surg.* 45(2):407-10, 2010



(Left) In this 3rd-trimester fetus with PUV, there is severe hydronephrosis and thinned renal parenchyma. The bladder wall is thickened and trabeculated, hallmark findings of bladder outlet obstruction from PUV. **(Right)** Hydroureter is also present and can be distinguished from the 3rd-trimester bowel by a lack of both peristalsis and internal debris. Tracing the ureter from the kidney on real-time imaging is also useful.



(Left) The dilated posterior urethra at the base of the dilated bladder results in a keyhole sign. PUV is the most common cause of lower urinary tract obstruction in a male fetus. **(Right)** Photograph of a 2nd-trimester fetus with PUV shows severe distension of the abdomen due to the grossly dilated bladder. Note the very small chest. Early oligohydramnios results in lethal pulmonary hypoplasia.



(Left) When bladder distention is severe, rupture can occur, resulting in urinary ascites, sometimes massive, as in this case. The collecting system may partially decompress, but persistent abnormal appearance of the kidneys is typical. **(Right)** Postnatal voiding cystourethrogram, in this newborn with PUV, shows a markedly dilated posterior urethra. There is an irregular, trabeculated bladder with a diverticulum posteriorly due to increased intravesical pressures.

KEY FACTS

TERMINOLOGY

- Characterized by 3 principle components
 - Dramatic collecting system dilatation
 - Deficiency of abdominal musculature
 - Cryptorchidism

IMAGING

- Gross dilatation of bladder, ureters, and renal pelvis
- Urethral dilation without obvious point of obstruction
- Abdominal wall laxity after bladder decompression
- Scan genitalia: Look for undescended testes
- Small, bell-shaped chest
 - Suggestive of pulmonary hypoplasia
- Oligohydramnios often present

TOP DIFFERENTIAL DIAGNOSES

- Posterior urethral valves
- Megacystis-microcolon-intestinal hypoperistalsis syndrome
- Cloaca

PATHOLOGY







- 10% of infants with prune belly will have cardiac anomalies

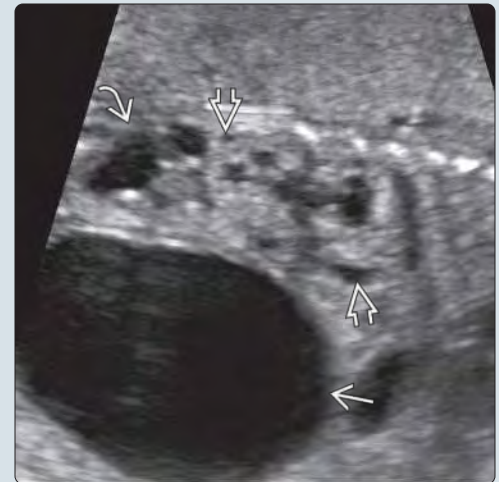
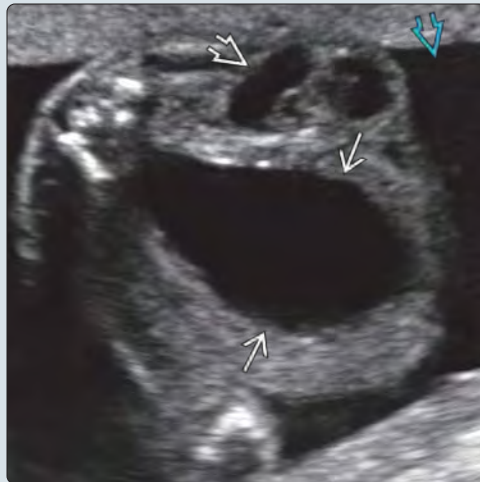
CLINICAL ISSUES






- Almost all cases are male fetuses
- Prognosis dependent on severity of oligohydramnios and renal damage
 - Vesicoamniotic shunt may aid in decompressing bladder and improving amniotic fluid status
 - Consider early intervention for best possible outcome
- Postnatal flaccid, "doughy" abdomen
- Neonate may require immediate assistance due to pulmonary hypoplasia
- ~ 1/2 of patients surviving infancy will develop chronic renal disease

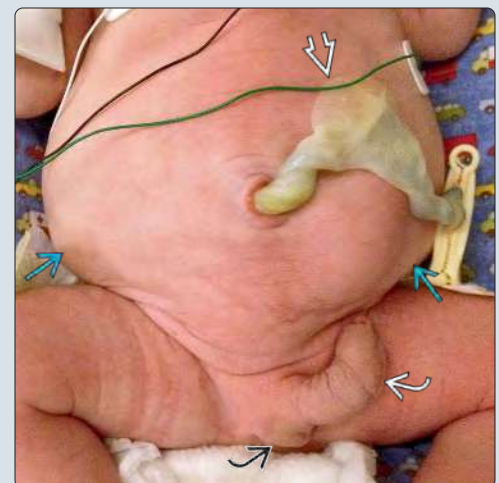
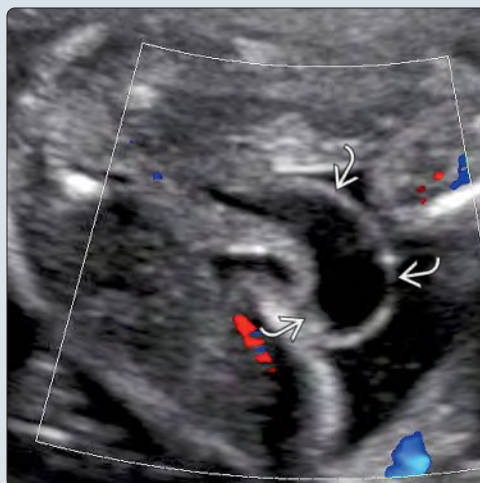
DIAGNOSTIC CHECKLIST

- Consider prune-belly syndrome when there is massive dilatation of entire collecting system

(Left) At 21-weeks gestation, the bladder is already markedly enlarged , extending well into the abdomen with adjacent hydroureter . Note the absence of a keyhole sign, which is usually seen with posterior urethral valves. Also, a fair amount of amniotic fluid is present . **(Right)** The kidneys are echogenic with cortical cysts , consistent with dysplasia and predictive of irreversible parenchymal damage. Associated hydroureter  and bladder dilation  are again seen.



(Left) One key finding that can help distinguish prune belly from other causes of lower urinary tract dilation is a dilated anterior urethra. In this fetus, an axial view through the perineum shows a massively distended penile urethra . **(Right)** Postnatal clinical photo of the same fetus shows abdominal wall laxity , distended penis due to megaurethra , and undescended testes (empty scrotal sac) . A cystic area in the cord  was also seen prenatally, consistent with patent urachus and urine collection near the cord base.



TERMINOLOGY

Synonyms

- Eagle-Barrett syndrome

Definitions

- Rare congenital disorder characterized by
 - Dramatic collecting system dilatation
 - Deficiency of abdominal musculature
 - Cryptorchidism

IMAGING

Ultrasonographic Findings

- Gross dilatation of entire collecting system
 - Large, thin-walled bladder
 - Lack of trabeculations to suggest chronic obstruction
 - Bilateral hydroureter
 - Bilateral hydronephrosis
- Renal parenchyma may be abnormal
 - Echogenic renal parenchyma suggests dysplasia
 - Not definitive
 - Renal cortical cysts predictive of dysplasia
 - Indicates irreversible damage
- Entire urethra may be dilated
 - No obvious point of obstruction
 - May see jet of urine with voiding during real-time scan
 - Color Doppler to assess for fluid flow exiting urethra
- Abdominal wall laxity
 - Seen best after bladder decompression
- Cryptorchidism
 - Testes typically descend into scrotum by 30 weeks gestation
 - Sonographically identified as oval echogenic glands in scrotal sac
- Small, bell-shaped chest suggestive of pulmonary hypoplasia
- Oligohydramnios often present
- Sonographic constellation of findings suggests fetal lower urinary tract obstruction (LUTO)
 - Hydronephrosis, hydroureter, bladder distention

Imaging Recommendations

- Difficult to differentiate from posterior urethral valves (PUV)
 - Prune-belly syndrome (PBS) does not have dilated posterior urethra
 - No keyhole sign as seen with PUV
 - Entire urethra may be dilated or penile portion
 - Ureters and kidneys always dilated with PBS
 - May be normal with PUV
 - Bladder wall is thin with PBS
 - Often thickened and trabeculated with PUV due to obstruction at urethral valves
- Scan genitalia
 - Look for undescended testes
 - Difficult if oligohydramnios is present

DIFFERENTIAL DIAGNOSIS

Posterior Urethral Valves

- May appear identical
- Look for dilated posterior urethra (keyhole sign)
- Hydronephrosis/ureter not always present
- Thick-walled bladder from outlet obstruction

Megacystis-Microcolon-Intestinal Hypoperistalsis Syndrome

- Rare cause of congenital intestinal and urinary dysfunction
 - Thought to be due to smooth muscle myopathy
 - Spectrum of intestinal motility defects
 - Autosomal recessive disorder
- Massive distention of urinary bladder with hydroureteronephrosis
- Normal amniotic fluid volume
- More common in females (4:1)
- High mortality rate in 1st year of life
 - Malnutrition, sepsis, renal failure
 - Supportive treatment and ileostomy
 - May require multiorgan transplant for survival
- Fetal MR could be useful for diagnosis
 - Define genitourinary anomalies
 - Look for associated gastrointestinal tract anomalies
 - Size of colon
 - Site of obstruction(s)
- Other nonimaging tests proposed to aid in prenatal diagnosis
 - Amniotic fluid digestive enzyme assay
 - Fetal urine biochemistry

Cloacal Malformation

- Seen in female fetuses only
- Failure of cloacal division
 - Classic cloaca with urethra, vagina, rectum fusion
 - Single perineal opening
- Rare cause of urinary outlet obstruction
- Dilated, urine-filled vagina is hallmark finding
 - Can mimic dilated bladder
 - Presents as cystic structure in pelvis

Urethral Atresia

- Rare cause of LUTO
- Complete obstruction of urethra
- Severe oligohydramnios to anhydramnios
- High mortality and morbidity
 - Progressive renal dysfunction
 - Pulmonary hypoplasia
- If stenosis rather than complete atresia, amniotic fluid volumes could be closer to normal

PATHOLOGY

General Features

- Etiology
 - Multiple proposed mechanisms
 - Primary abnormality in mesodermal development
 - ↑ fibrous/connective tissue, smooth muscle, and collagen along urinary tract
 - Primary urinary tract obstruction in early development

- No specific primary histologic abnormality of abdominal wall found
- Sporadic reports of other underlying abnormalities causing similar appearance of lax abdominal wall
 - Giant liver cysts, large ovarian cysts
- Large bladder inhibits descent of testes
 - Results in cryptorchidism
- Associated abnormalities
 - 10% of infants will have cardiac anomalies
 - Atrial septal defect
 - Patent ductus arteriosus
 - Ventricular septal defects
 - Tetralogy of Fallot
 - Can be seen with chromosomal anomalies
 - 2nd- or 3rd-trimester gestation
 - Oligohydramnios
 - Karyotype normal, no other malformations
 - Bladder aspiration shows normal renal function
- May require amnioinfusion prior to shunt placement
 - For proper placement of distal end outside of fetal abdomen
- Serial ultrasound required
 - Follow shunt position
 - Assess for continuing function
- May have complications of shunt placement
 - Malpositioning or dislodgement (~ 40% of cases)
 - Proximal end falls into fetal peritoneal space or out of abdomen
 - Occlusion of pigtail catheter
 - Urinary ascites
 - Preterm labor or rupture of membranes
 - Infection
 - Direct trauma to fetus or placenta

CLINICAL ISSUES

Presentation

- Most common signs/symptoms
 - Massive collecting system dilatation
 - Oligohydramnios
- Postnatal
 - Flaccid, "doughy" abdomen
 - Wrinkled appearance resembles prune
 - Potter facies may be seen if severe oligohydramnios
 - Wide-set eyes
 - Flattened palpebral fissures
 - Micrognathia
 - Low-set ears
 - Bell-shaped chest if pulmonary hypoplasia present
 - Associated with signs of respiratory distress
 - Cryptorchidism

Demographics

- Epidemiology
 - 1:30,000-1:50,000 live births
 - Rarely reported in females
 - More common in twin pregnancies than singleton

Natural History & Prognosis

- Depends on severity of oligohydramnios and renal damage
 - Chronic renal disease common in survivors
 - ~ 50% of patients surviving infancy will develop chronic renal disease
 - Usually in childhood or adolescence
 - Pulmonary hypoplasia can result in
 - Low amniotic fluid
 - Compression of thorax by hydronephrotic kidneys and enlarged bladder
- May also have patent urachus
 - Allows excretion of urine
 - Partial bladder decompression

Treatment

- Serial sonography required throughout pregnancy
 - Monitor degree of bladder dilatation
 - Assess amniotic fluid volume
- Vesicoamniotic shunt may aid in decompressing bladder and improving amniotic fluid status
 - Consider early intervention for best possible outcome
 - Performed only if certain criteria met

DIAGNOSTIC CHECKLIST

Consider

- Early intervention can help improve outcome
 - Only if specific criteria met
 - Shunt placement to ↓ bladder and ↑ amniotic fluid

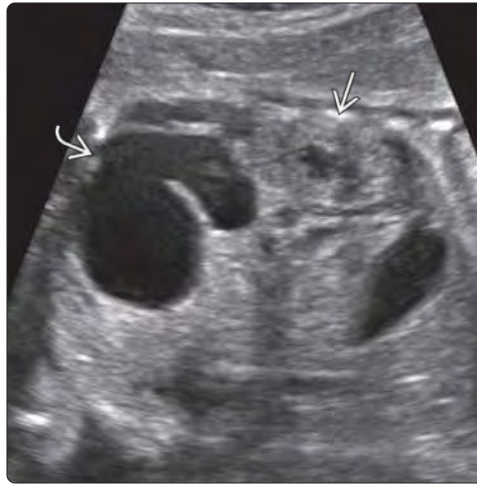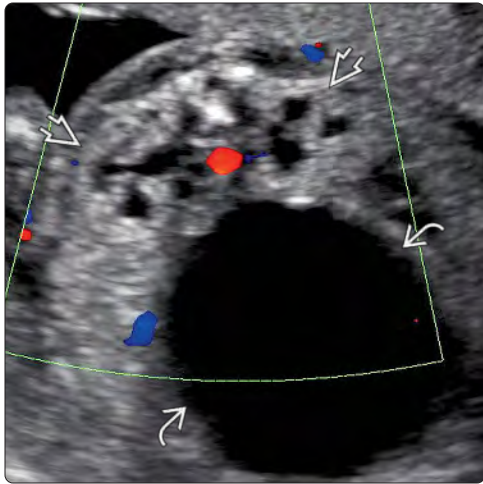
Image Interpretation Pearls





- Consider PBS diagnosis when massive dilatation of entire collecting system
- Almost all cases are male

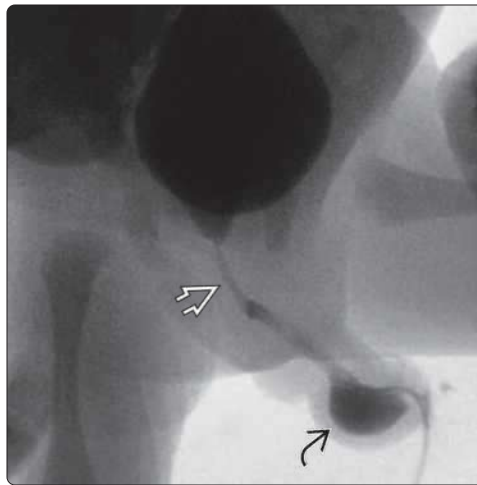
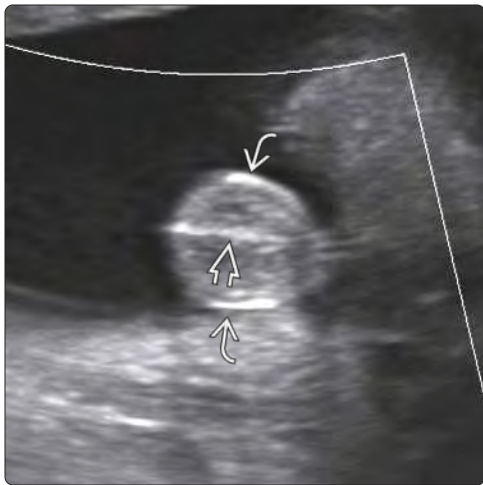
SELECTED REFERENCES





1. Seidel NE et al: Clinical manifestations and management of prune-belly syndrome in a large contemporary pediatric population. *Urology*. 85(1):211-5, 2015
2. Clayton DB et al: Lower urinary tract obstruction in the fetus and neonate. *Clin Perinatol*. 41(3):643-59, 2014
3. Müller Brochut AC et al: Fetal megacystis: experience of a single tertiary center in Switzerland over 20 years. *Fetal Diagn Ther*. 36(3):215-22, 2014
4. Rogers S et al: Prune belly with megalourethra. *Ultrasound Q*. 29(3):235-6, 2013
5. Tonni G et al: Prune-belly syndrome: case series and review of the literature regarding early prenatal diagnosis, epidemiology, genetic factors, treatment, and prognosis. *Fetal Pediatr Pathol*. 31(1):13-24, 2013
6. Hassett S et al: Prune belly syndrome. *Pediatr Surg Int*. 28(3):219-28, 2012
7. Nemeč SF et al: Male sexual development in utero: testicular descent on prenatal magnetic resonance imaging. *Ultrasound Obstet Gynecol*. 38(6):688-94, 2011
8. Osborne NG et al: Fetal megacystis: differential diagnosis. *J Ultrasound Med*. 30(6):833-41, 2011

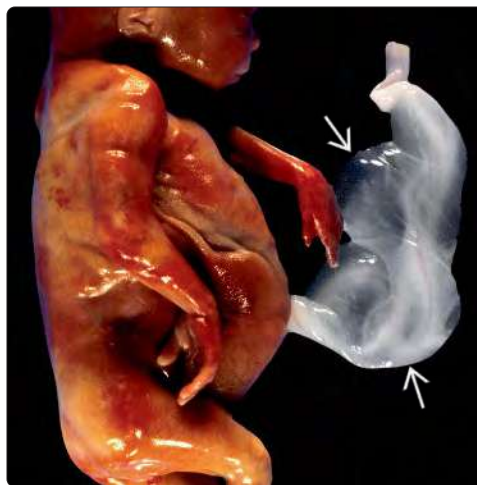
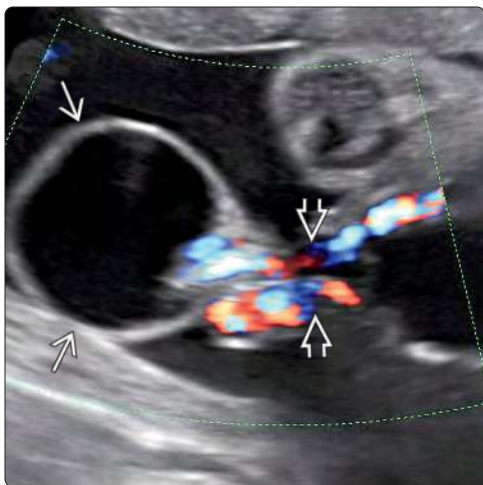
Prune-Belly Syndrome






(Left) In the 2nd trimester, the renal parenchyma is slightly echogenic , which is suggestive of dysplasia in the setting of a markedly dilated bladder  and prune-belly syndrome. (Right) In the same fetus at 31-weeks gestation, there is massive hydronephrosis , the renal parenchyma remains echogenic , and there is oligohydramnios. Pulmonary hypoplasia can result when concurrent oligohydramnios is present.



(Left) After 28-weeks gestation, the testes should be descended into the scrotal sac. When prune-belly syndrome is suspected, careful evaluation of the scrotum will show an empty sac  with a lack of the typical echogenic oval testes. Median raphe of the scrotum  is noted. (Right) Unlike with posterior urethral valves, in prune-belly syndrome the postnatal voiding cystourethrogram shows a normal nondilated posterior urethra . Instead, the anterior or penile urethra is dilated  and there is no obstruction to urination.



(Left) Doppler ultrasound at the abdominal wall cord insertion  shows a cystic avascular collection within the cord , consistent with a patent urachus, associated with prune-belly syndrome. (Right) Gross pathology shows the effect of a patent urachus in a fetus with prune-belly syndrome. The patent urachus allowed urine to decompress into the umbilical cord , with ~ 300 cc of urine-like fluid present on autopsy.

KEY FACTS

TERMINOLOGY

- Congenital dilatation of intramucosal segment of ureter with prolapse into bladder lumen
 - **Simple:** Occurs at normal ureterovesical junction
 - Not usually seen in utero
 - **Ectopic:** Almost always associated with renal duplication

IMAGING

- Anechoic, balloon-like, thin-walled cyst inside bladder
 - May fluctuate in size with bladder filling and ureteral peristalsis
 - If large, may obstruct contralateral ureter or cause bladder outlet obstruction
- Evaluate bladder several times during exam to assess for ureterocele
 - Ureterocele best seen when bladder partially full
 - If bladder empty, ureterocele may be misinterpreted as bladder
 - If fully distended, may compress ureterocele

TOP DIFFERENTIAL DIAGNOSES

- Mass effect from adjacent sigmoid colon
- Bladder "Hutch" diverticulum

PATHOLOGY

- Ectopic ureterocele inserts medially and inferiorly to trigone, near bladder neck; associated with upper pole of duplicated collecting system

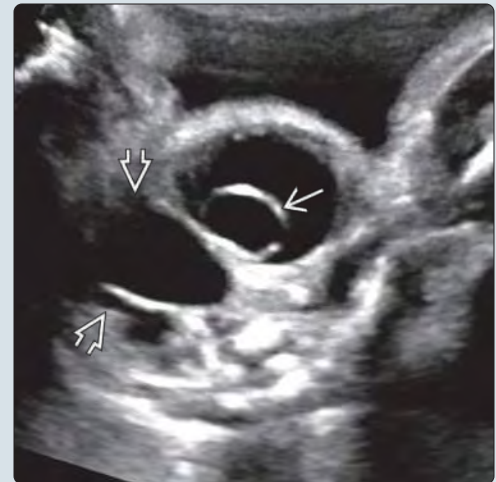
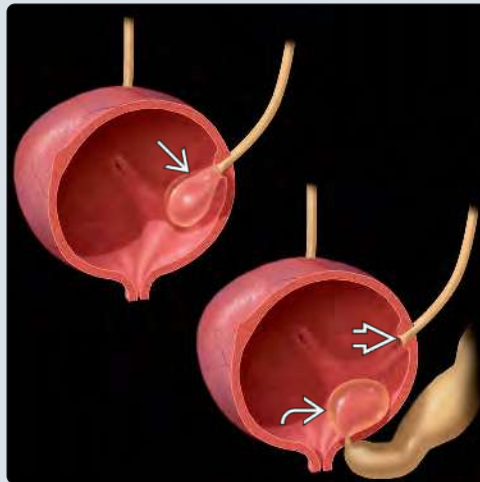
CLINICAL ISSUES

- Incidental finding in utero or found in work-up of hydronephrosis

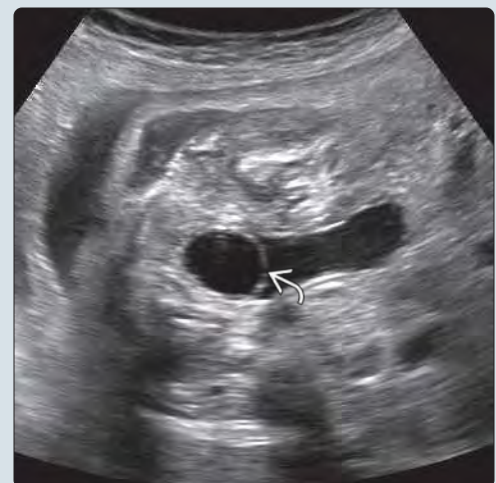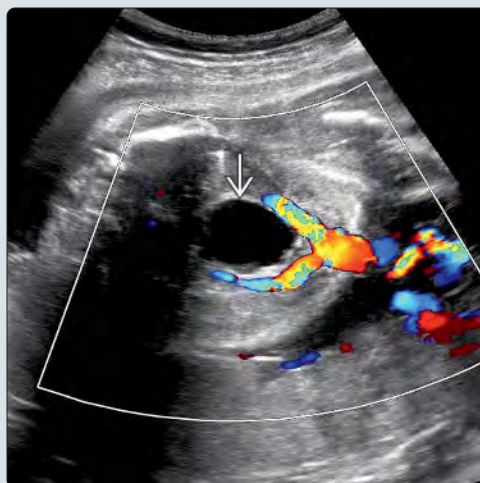
DIAGNOSTIC CHECKLIST

- Cystic mass in bladder is overwhelmingly likely to be an ectopic ureterocele
 - Always consider duplicated collecting system when ureterocele present
- Dilated upper pole moiety + cystic mass in bladder = duplicated collecting system with ureterocele

(Left) This graphic shows a simple ureterocele in the normal insertion position. In a duplicated system, as shown in the lower graphic, the ectopic ureter enters the bladder inferiorly and medially to the normotopic ureter. (Right) Oblique axial ultrasound of the bladder shows a large, anechoic ureterocele. Two left ureters are seen, which were dilated throughout their entire course and difficult to separate. Images of the left kidney showed a duplicated collecting system.



(Left) This fetus had what was suspected to be a duplicated renal collecting system with an obstructed upper pole, but imaging of the pelvis showed an apparently normal bladder. It is important to remember that a ureterocele can be misinterpreted as the bladder when the bladder is empty. (Right) An oblique coronal ultrasound 15 minutes later shows what was thought to be the bladder was actually a ureterocele. Both an empty and fully distended bladder can mask a ureterocele.



TERMINOLOGY

Definitions

- Congenital dilatation of intramucosal segment of ureter
 - Dilated segment prolapses into bladder lumen
- Variable types
 - **Simple**
 - Occurs at normal ureterovesical junction
 - Located at trigone of bladder
 - Not usually seen in utero
 - **Ectopic**
 - Almost always associated with renal duplication
 - Located medially and inferiorly to trigone, near bladder base
 - Ectopic ureter is usually stenotic at bladder
 - Ectopic ureter may insert outside of bladder
 - Directly onto perineum
 - Urethra
 - Females: Vagina, uterus
 - Males: Epididymis, seminal vesicles, ejaculatory ducts, vas deferens
 - **Cecoureterocele**
 - Uncommon type of ectopic ureterocele
 - Dissects submucosally into urethra
 - Can cause intermittent bladder outlet obstruction

IMAGING

General Features

- Best diagnostic clue
 - Thin-walled, cystic mass inside bladder lumen
 - Fluctuating size with bladder filling and ureteral peristalsis
 - Hydronephrosis predominately involving upper pole of kidney when associated with duplication
- Weigert-Meyer rule in renal duplication
 - Upper moiety ureter inserts inferiorly and medially to normal ureteric insertion site
 - Ectopic implantation → upper pole obstruction due to ectopic ureterocele
 - Lower renal pole moiety inserts normally in bladder trigone
 - Distortion of orifice by adjacent upper moiety ureterocele may result in reflux

Ultrasonographic Findings

- **Bladder**
 - Anechoic, balloon-like, thin-walled cyst inside bladder lumen represents ureterocele
 - Look for connection of "cyst" to distal ureter
 - Color Doppler may show ureteral jet
 - If ureterocele obstructing ureterovesicle junction, → hydroureter
 - May prolapse in and out of bladder
 - Can partially extend into urethra, bladder neck, or perineum
 - Ureterocele can invert when bladder full
 - Gives appearance of bladder diverticulum
 - Reverts to intravesical location when bladder empties
 - If ureterocele is large
 - May obstruct contralateral kidney

- May cause bladder outlet obstruction
- **Ureter**
 - Dilated ureter
 - Fluid-filled tube connects to renal pelvis
 - Adjacent to spine in retroperitoneum
 - Dilated bowel loops more central and anterior in abdomen
 - Both upper and lower pole ureters can be dilated in renal duplication
 - Ureterocele with obstructed ectopic ureter
 - Normotopic ureter dilated from reflux
- **Kidney**
 - Hydronephrosis usually worse in upper pole (obstructed system)
 - Lower pole may also have hydronephrosis from reflux
 - Kidney large relative to contralateral, nonduplicated kidney
 - Results in cystic dysplasia of upper pole renal parenchyma if obstruction severe
 - Dilated collecting system/cysts replace upper renal parenchyma
 - Lower pole pushed inferiorly due to mass effect from upper pole
- **Amniotic fluid**
 - Oligohydramnios may develop if ureterocele obstructs bladder outlet

Imaging Recommendations

- When hydronephrosis present, always search for other signs of renal duplication
 - Normal lower pole moiety (i.e., dilated collecting system upper pole only)
 - Dilated ureter(s)
 - Ectopic ureterocele
- Ureterocele + dilated upper pole collecting system = duplication
- Evaluate bladder several times during any fetal ultrasound
 - Ureterocele best seen when bladder partially full
 - If bladder is empty, ureterocele may be misinterpreted as bladder
 - When distended, bladder may compress ureterocele
- Evaluate kidney in both axial and longitudinal views
 - Axial view alone may mimic ureteropelvic junction obstruction
 - Lower pole moiety may be displaced inferiorly and difficult to see
- Follow collecting system in real time
 - Renal pelvis → ureter → ureterocele

DIFFERENTIAL DIAGNOSIS

Mass Effect From Sigmoid Colon

- Distal bowel dilatation → multiple low echogenicity structures in pelvis
- Urine is anechoic; meconium produces low-level echoes
- Look for changing shape as bladder fills and empties
- Colonic loops do not undergo significant peristalsis

Bladder "Hutch" Diverticulum

- Periureteral diverticulum of bladder
- Extrinsic, does not prolapse into bladder lumen

- Separate from distal ureter

Congenital Megaureter

- Fusiform dilation of ureter with normal bladder
 - Usually unilateral (left > right)
- May have hydronephrosis
- Mainly affects males
- Does not prolapse into bladder

PATHOLOGY

General Features

- Etiology
 - May be due to delayed canalization of Chwalla membrane during embryogenesis
 - Membrane separates ureteral bud from urogenital sinus
 - Distal ureter lumen expands between mucosa and muscle of bladder wall
 - ◻ Forms cystic dilation of terminal ureter
 - Ectopic ureterocele
 - Typically associated with upper pole of duplicated collecting system
 - Distorts adjacent normal ureteral orifice
 - Allows reflux into lower pole moiety
 - Orthotopic ureterocele
 - Located at normal ureteral orifice in bladder
 - Most often seen without renal duplication
- Genetics
 - Sporadic
- Associated abnormalities
 - Gynecological abnormalities in 50% of females with duplication
 - Contralateral duplication in 10-20%

CLINICAL ISSUES

Presentation

- Incidental finding in utero
- Found in work-up of hydronephrosis
- Typical presentation in infancy
 - Hematuria
 - Urinary tract infection
 - Hydronephrosis
 - Urinary retention
- Simple ureteroceles may be asymptomatic

Demographics

- Epidemiology
 - Female >> male
 - Left > right side
 - Ectopic:simple ureterocele = 3:1
 - Bilateral in up to 10% postnatally
 - Incidence of ectopic ureterocele parallels that of renal duplication
 - Renal duplication with ectopic ureterocele
 - ◻ 1:9,000 live births
 - Renal duplication without ureterocele (partial duplication)
 - ◻ 1:150 in general population
 - ◻ Ureters unite before bladder insertion

- ◻ Partial duplication less likely to have ureterocele

Natural History & Prognosis

- Prognosis depends on degree of obstruction
 - Excellent if no obstruction or reflux
 - Variable outcome if high-grade reflux or prolonged obstruction

Treatment

- In utero treatment not usually indicated
 - Consider incision of ureterocele if bladder outlet obstruction/oligohydramnios
 - Use of laser ablation reported
- Postnatal work-up in all cases
 - Ultrasound of bladder and kidneys
 - Assess for renal duplication if not seen in utero
 - Voiding cystourethrogram
 - Filling defect in bladder best seen on early filling image
 - ◻ Later images with bladder filled often obscure ureterocele
 - May identify associated duplicated collecting system
 - ◻ Vesicoureteral reflux into lower pole
 - ◻ Drooping lily sign: Obstructed upper pole pushes lower pole calyces inferiorly
 - MR may be helpful for complicated duplications
 - MR urogram may show extraventricular ureteral insertion site
 - Delineate associated gynecological abnormalities
 - Radionuclide renal scan to assess function
- Surgical options based on consequences of ureterocele
 - Endoscopic ureterocele decompression
 - Particularly if infected or obstructed
 - Ureteral reimplantation surgery
 - Heminephroureterectomy
 - Performed if poorly functioning upper pole

DIAGNOSTIC CHECKLIST

Consider

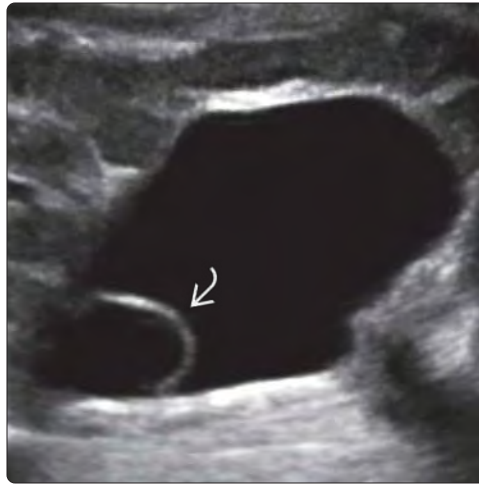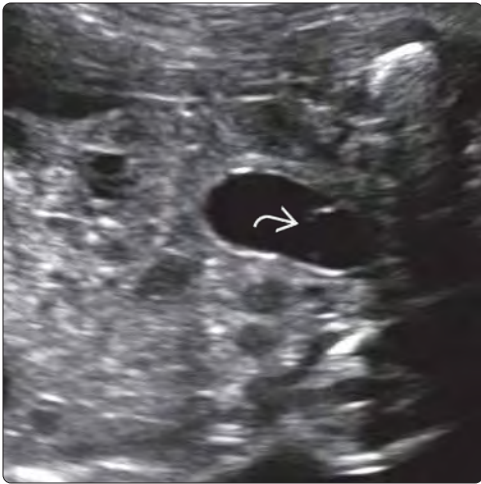
- Cystic mass in bladder is overwhelmingly likely to be ectopic ureterocele
 - Examine kidneys in both axial and longitudinal planes to look for duplicated collecting system
- Always consider collecting system duplication as cause of hydronephrosis

Image Interpretation Pearls

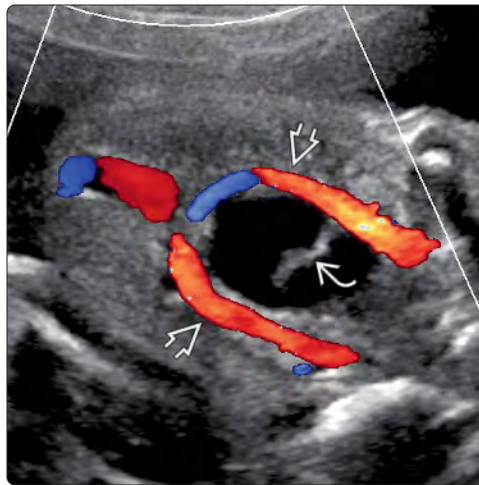
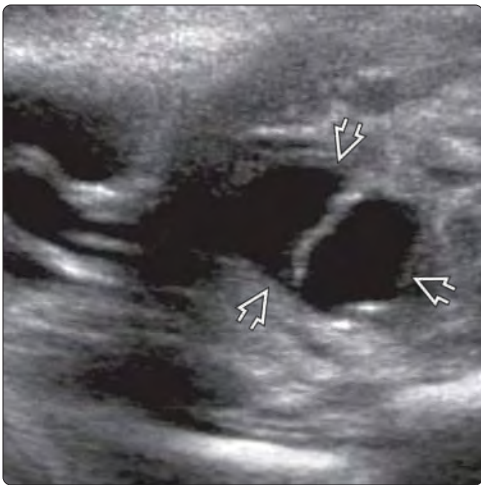
- Dilated upper pole moiety + cystic mass in bladder = duplicated collecting system with ureterocele

SELECTED REFERENCES

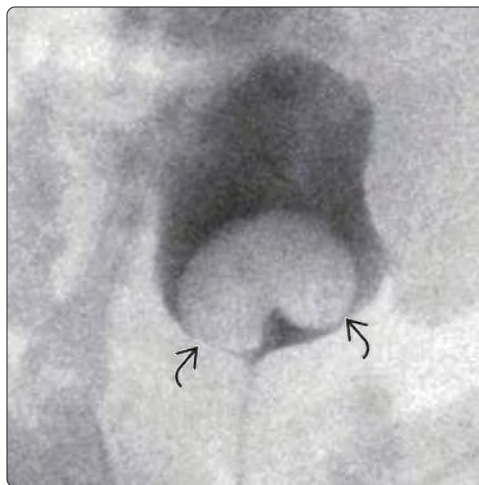
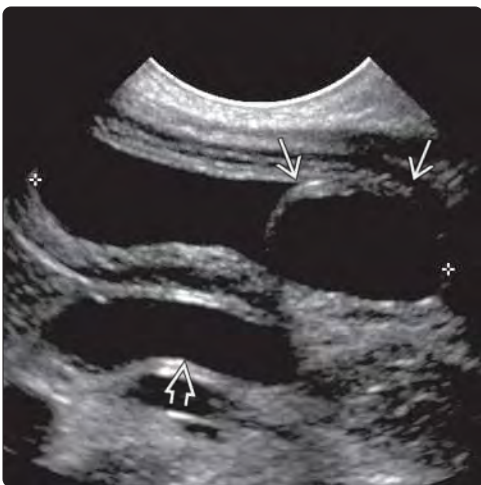
1. Timberlake MD et al: Minimally invasive techniques for management of the ureterocele and ectopic ureter: upper tract versus lower tract approach. *Urol Clin North Am.* 42(1):61-76, 2015
2. Torres Montebruno X et al: Fetoscopic laser surgery to deobstruct a prolapsed Ureterocele. *Ultrasound Obstet Gynecol.* 46(5): 623-6, 2015
3. Queiroga EE Jr et al: Antenatal diagnosis of renal duplication by ultrasonography: report on four cases at a referral center. *Urol J.* 10(4):1142-6, 2014
4. Godinho AB et al: Ureterocele: antenatal diagnosis and management. *Fetal Diagn Ther.* 34(3):188-91, 2013



(Left) In the 2nd trimester, the wall of the ureterocele is very thin and may be missed. Careful evaluation of the bladder with several angles of insonation is warranted, especially in the setting of a suspected renal duplication. **(Right)** In the same fetus at 27-weeks gestation, an ectopic ureterocele is clearly identified at the bladder base.



(Left) On initial evaluation, there appears to be a septated cystic pelvic mass. In a female fetus, ovarian cyst would be considered. **(Right)** Color Doppler can be useful to confirm the bladder location by visualizing the umbilical arteries draped around the bladder. The septated cystic "mass" is actually the bladder containing an ectopic ureterocele.



(Left) Postnatal ultrasound in the same case confirms the presence of a ureterocele at the bladder base (bladder marked by calipers). Also note the dilated ureter due to reflux. **(Right)** After birth, neonates with suspected ureteroceles should have a voiding cystourethrogram to document if the bladder outlet is obstructed and to assess for reflux. In this case, there is a large ureterocele, which creates a smooth filling defect at the bladder base.

KEY FACTS

TERMINOLOGY

- Group of disorders resulting from incomplete involution of allantois
- Urachus is intraabdominal portion of allantois
 - Any persistent segments are termed urachal remnants
 - Complete failure of closure → patent urachus
 - Most common type seen in fetus
 - Partial failure of closure → urachal cyst, diverticulum, or sinus

IMAGING

- Anterior, midline, fluid collection located between bladder and umbilical cord insertion
- May extend into base of umbilical cord forming allantoic cyst
 - Cord cyst may be large and most obvious finding
 - Edematous, cystic-appearing Wharton jelly from urine absorption into cord
- Real-time examination is important

- Try to connect cyst with bladder
 - May change size, often becoming larger when bladder decompresses
- Look for discontinuity in abdominal wall allowing communication with cord cyst

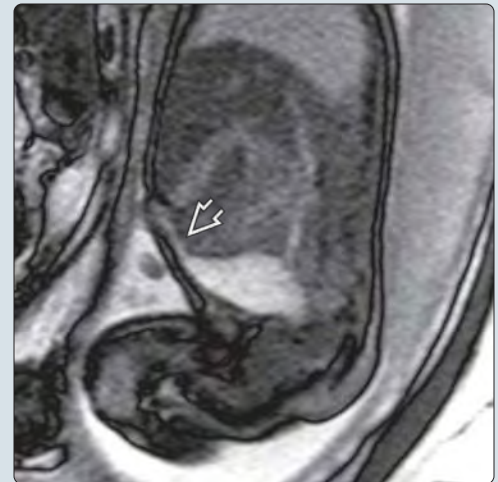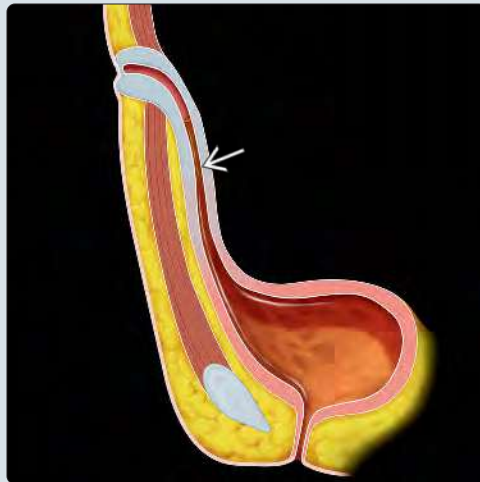TOP DIFFERENTIAL DIAGNOSES

- Other abdominal cysts are not restricted to anterior midline location
- Lower urinary tract obstruction
 - Dilated bladder may extend up to umbilicus and be confused with urachal anomaly
 - Remember there may be both obstructed bladder and patent urachus
 - Urachus serves as pop-off valve to decompress bladder

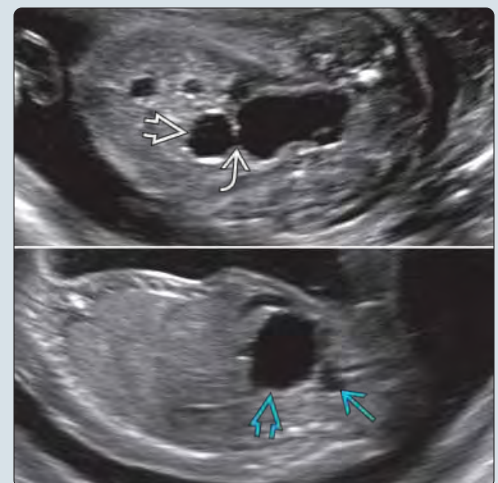
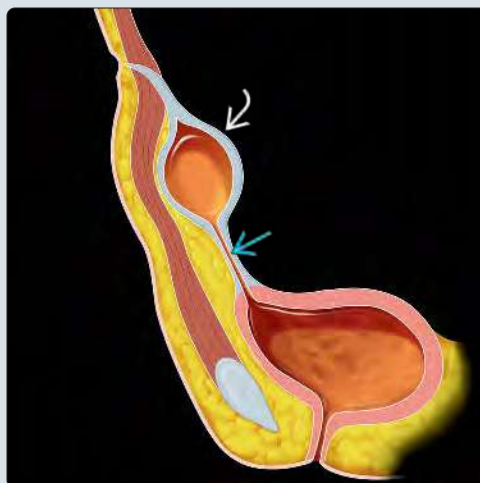CLINICAL ISSUES

- Excellent prognosis with repair
- Risk of infection and malignancy if not resected

(Left) Sagittal graphic shows a patent urachus extending from the dome of the bladder to the base of the umbilical cord. The urachus is the intraabdominal portion of the allantois and normally involutes by 6-weeks gestational age, forming the median umbilical ligament. **(Right)** Sagittal T2WI MR shows a very similar appearance to the graphic with high-signal urine within the patent urachus.



(Left) If the midportion of the urachus involutes, a cyst can form. If a connection remains, urine can pass between the bladder and cyst. During ultrasound evaluation, the cyst may increase in size when the bladder contracts during voiding, sending urine into the cyst. **(Right)** Oblique coronal US (top) shows a midline cyst, with an apparent connection to the bladder. A sagittal US later in the exam (bottom) shows the bladder is decompressed and the cyst has gotten larger, confirming the suspicion of a urachal cyst.



TERMINOLOGY

Definitions

- Group of disorders resulting from incomplete involution of allantois
 - **Patent urachus**
 - Most common type seen in fetus
 - Open channel from dome of bladder to umbilical cord insertion
 - Often associated with allantoic cord cyst
 - **Urachal cyst**
 - Persistence of intermediary segment of urachus forming cyst between bladder and umbilical cord insertion
 - Fibrous attachments to bladder and umbilicus
 - **Urachal diverticulum**
 - Persistence of deep segment of urachus creating diverticulum off anterior-superior bladder wall
 - Often incidental finding later in childhood or adulthood
 - **Urachal sinus**
 - Persistence of superficial segment of urachus opening onto skin surface
 - Usually diagnosed on postnatal physical exam

IMAGING

General Features

- Best diagnostic clue
 - Midline abdominal cyst communicating with umbilical cord cyst
- Location
 - Midline, anterior pelvis between bladder and umbilical cord insertion
 - Urachus lies in space of Retzius, between transversalis fascia and peritoneum

Ultrasonographic Findings

- Fluid-filled mass above bladder
 - Communication with bladder confirms patent urachus
- May extend into base of umbilical cord
 - Associated with allantoic cord cysts
 - Cyst may be large
 - Cyst fills via retrograde flow of urine through patent urachus
 - Edematous, cystic appearing Wharton jelly from urine absorption into cord
 - Small abdominal wall defect at site of communication between cyst and urachus
 - Bladder may herniate through defect
- Bladder outlet obstruction is risk factor
 - Urachus serves as pop-off valve to decompress bladder
- May be seen in 1st trimester
 - Megacystis
 - Umbilical cord cyst
 - Cord cyst may be most prominent finding
- Color Doppler
 - Helps differentiate cyst from cord vessels

Imaging Recommendations

- Monthly follow-up scans

- May increase or decrease in size, or even resolve, as gestation progresses
- Doppler evaluation important to look for umbilical vein thrombosis by compression from large cord cyst
- Real-time examination is important
 - Try to connect cyst with bladder
 - Look for discontinuity in abdominal wall
 - Connection between patent urachus and umbilical cord cyst
- Follow-up 1st-trimester megacystis ± suspected urachal abnormality
 - ≥ 14 mm has high risk of bladder outlet obstruction
 - < 14 mm resolves in 90% of cases
 - May be attributed to transient functional neurogenic bladder secondary to delayed development of autonomic innervation

MR Findings

- Urine within urachus is low signal on T1WI and high signal on T2WI
- Midline sagittal view best to show tract between umbilicus and bladder

DIFFERENTIAL DIAGNOSIS

Other Abdominal Cysts

- Location most important finding in differentiating from urachal anomaly
 - Other cystic masses are not restricted to anterior midline
- **Ovarian cyst**
 - Females only
 - Seen in 3rd trimester
- **Enteric duplication cyst**
 - Thick-walled cyst with hyperechoic mucosa and hypoechoic wall (gut signature)
- **Mesenteric cyst**
 - May be unilocular or multilocular
 - May be large and insinuate around bowel
- **Meconium pseudocyst**
 - Thick, irregular wall
 - Other sequelae of meconium peritonitis
 - Peritoneal calcifications, dilated bowel

Lower Urinary Tract Obstruction

- Dilated bladder may extend up to umbilicus and be confused with urachal anomaly
- Look for other associated features
 - Ureterectasis
 - Hydronephrosis
 - Cystic kidneys
 - Look for key hole appearance with posterior urethral valves
 - Oligohydramnios
- Remember there may be both obstructed bladder and patent urachus

Omphalocele

- Midline abdominal wall defect with herniation of abdominal contents into base of umbilical cord
- Color Doppler shows umbilical cord insertion on covering sac

PATHOLOGY

General Features

- Etiology
 - Embryology
 - Allantois forms from caudal end of yolk sac
 - Functions as primitive bladder and early blood-forming organ
 - Extend from cloaca into base to connecting stalk
 - Urachus is intraabdominal portion of allantois
 - Connects dome of bladder to umbilicus
 - Lumen normally obliterates at ~ 6-weeks gestational age
 - Forms median umbilical ligament
 - Any persistent segments are termed urachal remnants
 - Complete failure of closure → patent urachus
 - Partial failure of closure → urachal cyst, diverticulum, or sinus
- Genetics
 - Sporadic
 - Isolated finding not associated with aneuploidy
- Associated abnormalities
 - Umbilical cord cyst (allantoic cyst) or thickening
 - Thickening may be from urine absorption into Wharton jelly
 - Other genitourinary anomalies
 - Bladder exstrophy
 - Posterior urethral valves
 - Urethral atresia
 - Cloacal anomalies
 - Cryptorchidism
 - Renal anomalies
 - Omphalocele
 - Omphalomesenteric remnant

Gross Pathologic & Surgical Features

- Triangular attachment to dome of bladder
- Variable degrees of fibrosis/lumen obliteration

CLINICAL ISSUES

Presentation

- Fetal
 - Cystic abdominal mass
 - Umbilical cord cyst
 - May be incidentally detected in 1st trimester during 11- to 14-week nuchal translucency scan
- Postnatal
 - Patent urachus presents in newborn period
 - Persistent drainage from umbilicus
 - Periumbilical inflammation
 - Urinary tract infection
 - Urachal cyst may go undetected until childhood or adulthood
 - Suprapubic mass
 - Urinary symptoms including frequency and urgency
 - Infection, fever

Demographics

- Gender
 - M:F = 2:1

- Epidemiology
 - Patent urachus 1-2.5:100,000 live births

Natural History & Prognosis

- May spontaneously close in utero
 - Urachal sinus may remain
- Excellent prognosis with repair
- Risk of infection and malignancy if not resected
 - Develop adenocarcinoma in adulthood

Treatment

- Complete postnatal work-up, even if anomaly appears to have resolved in utero
 - Voiding cystourethrogram (VCUG) best test to document patency of urachus
 - Demonstrates connection between bladder and urachus
 - Ultrasound appearance depends on type and amount of persistent remnant
 - Typically thick, well-defined wall
- Surgical resection of entire tract
 - May need to be done as staged procedure if presenting with infection/inflammation
- Patent urachus with bladder outlet obstruction
 - Correct obstruction 1st
 - Urachus may spontaneously close when pressure relieved

DIAGNOSTIC CHECKLIST

Consider

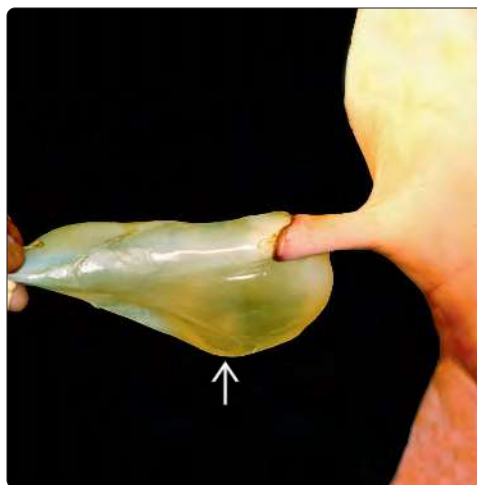
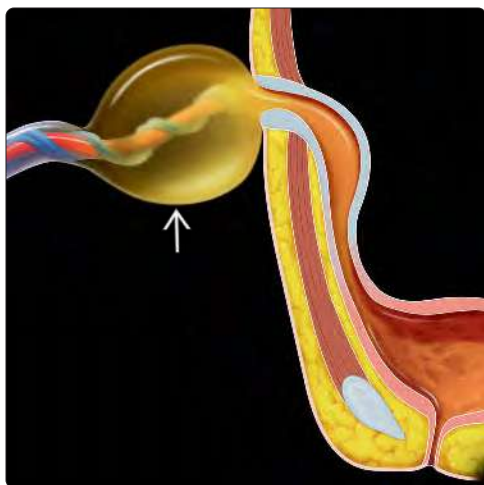- Whenever proximal umbilical cord cyst is seen, consider possibility of patent urachus

Image Interpretation Pearls

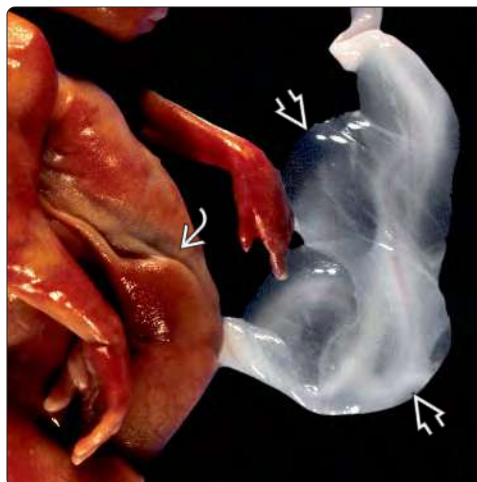
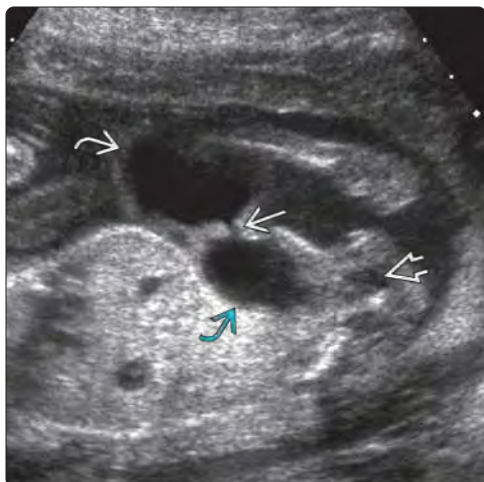
- Anterior, midline location most important diagnostic finding
 - Located between bladder and umbilicus
 - Most other cystic abdominal masses may be excluded based on paramedian location

SELECTED REFERENCES

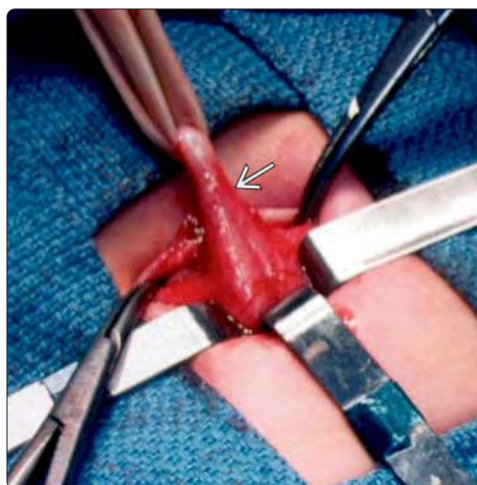
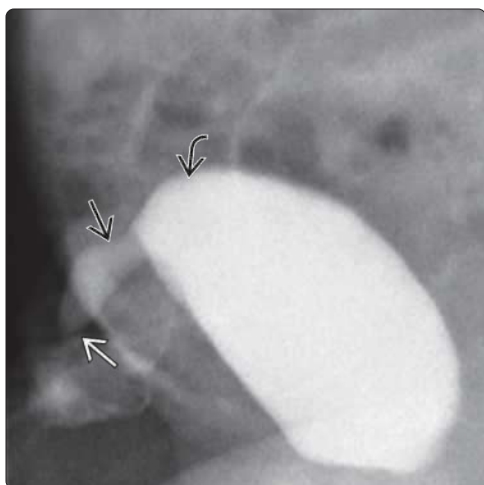
1. Riddell JV et al: Prenatal vesico-allantoic cyst outcome - a spectrum from patent urachus to bladder exstrophy. *Prenat Diagn.* 35(13):1342-6, 2015
2. Trong Thach T et al: Case Report: Pre- and postnatal management of an allantoic cyst with patent urachus and single umbilical artery. *F1000Res.* 4:124, 2015
3. Umeda S et al: Prenatal and postnatal clinical course of an urachus identified as an allantoic cyst in the umbilical cord. *Eur J Pediatr Surg.* 26(2):200-2, 2015
4. Naiditch JA et al: Current diagnosis and management of urachal remnants. *J Pediatr Surg.* 48(10):2148-52, 2013
5. Rasteiro C et al: Bladder emptying into an umbilical cord cyst: prenatal sonographic sign of allantoic cyst with patent urachus. *Ultrasound Obstet Gynecol.* 42(2):239-40, 2013
6. Tsai MS et al: Images in clinical medicine. Patent urachus. *N Engl J Med.* 365(14):1328, 2011
7. Sepulveda W et al: Megacystis associated with an umbilical cord cyst: a sonographic feature of a patent urachus in the first trimester. *J Ultrasound Med.* 29(2):295-300, 2010
8. Pal K et al: Allantoic cyst and patent urachus. *Indian J Pediatr.* 76(2):221-3, 2009



(Left) If the urachus remains widely patent, urine can flow into the base of the umbilical cord forming an allantoic cyst [1]. (Right) This clinical photograph shows a urine-containing allantoic cyst [2] at the base of the umbilical cord. A large cord cyst was seen prenatally and a patent urachus was suspected but could not be documented. A voiding cystourethrogram (VCUG) should be performed preoperatively to evaluate for a patent urachus and better define anatomy.



(Left) Sagittal US shows a patent urachus [1] communicating with an allantoic cord cyst [2] through a small defect [3]. The bladder [4] is decompressed. With bladder contraction, urine moves retrograde through the urachus into the base of the cord. (Right) This case of prune-belly syndrome shows a distended wrinkled abdomen [5] and fluid within the cord [6]. The urachus can serve as a pop-off valve in cases of bladder outlet obstruction. In this case, urine dissected through the Wharton jelly rather than forming a cyst.



(Left) Fluoroscopic VCUG in a newborn with urine leaking from the umbilicus shows contrast filling a tract [1] from the dome of the urinary bladder [2] to the umbilicus [3], consistent with a patent urachus. (Right) Intraoperative photograph taken during the resection of a patent urachus shows the triangular configuration of the urachal tract [4] as it extends cephalad. Resection of the entire tract is necessary as there is increased risk of infection and malignant transformation in any remnants.

KEY FACTS

TERMINOLOGY

- Atypical gonadal anatomy; cannot tell sex of fetus
- Preferred terminology is to say fetal "sex" not "gender"
 - Gender is self-identity
- Phallus refers to genital tubercle: Can be penis or clitoris

IMAGING

- Sex is indeterminable despite adequate visualization
 - Cannot differentiate penis from clitoris
 - Cannot differentiate scrotum from labia
- Disorders of sexual development (DSD) findings in XY fetus
 - Hypospadias is most common cause
 - Blunt-ending penis instead of normal taper
 - Echogenic prepuce folds at glans
 - ± chordee (ventral curvature of penis)
 - ± cryptorchidism (empty scrotal sac)
 - Epispadias: Dorsal urethral opening
 - Cryptorchidism ± other penile anomaly



- DSD findings in XX fetus
 - Clitoromegaly
 - Prominent or fused labia
 - Congenital adrenal hyperplasia (CAH) is most common cause
 - Adrenal glands may be normal or enlarged
- Associations
 - Aneuploidy: Trisomy 13, trisomy 18, triploidy + others
 - Bladder and cloacal exstrophy
 - Many associated syndromes

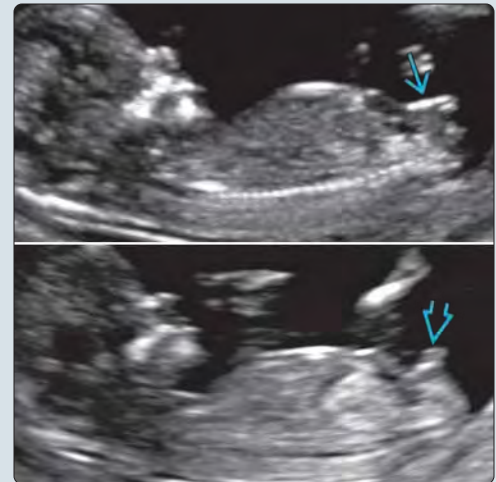
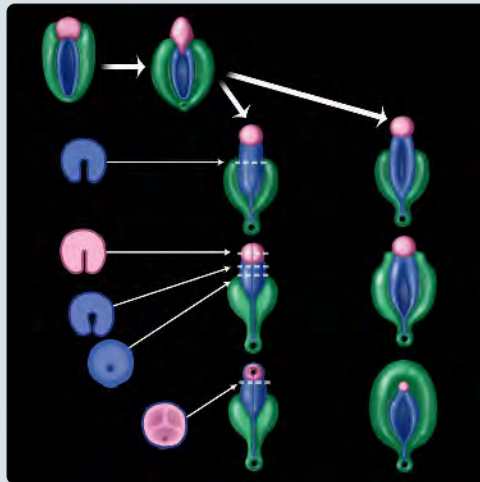
CLINICAL ISSUES




- DSD multidisciplinary team approach is ideal
 - Consultations can begin at time of in utero diagnosis
- Sex assignment should be postponed until diagnostic assessment is complete

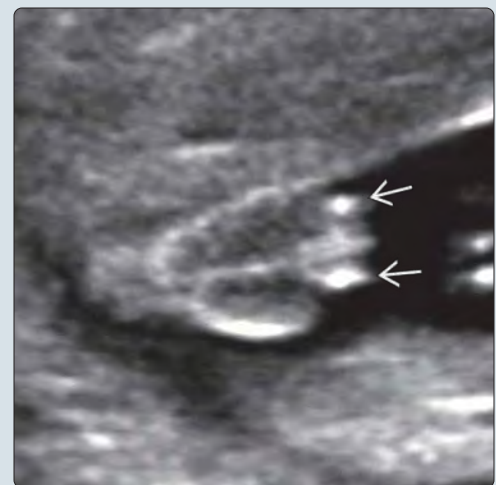
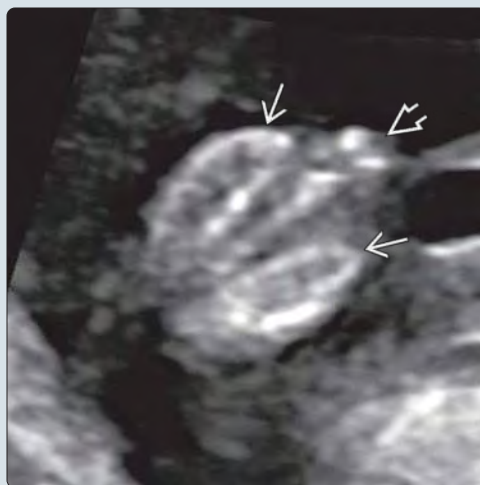
DIAGNOSTIC CHECKLIST

- Refer all cases for genetic counseling

(Left) Development of external genitalia is shown. Left column is for male and right column is for female. Pink is genital tubercle (becomes glans of penis in males and clitoris in females); green is labioscrotal swelling; and blue is cloacal folds and membrane. **(Right)** Sagittal views of the genital tubercle at 13 weeks in a female (top) and male (bottom) fetus show the difference in angle between the sexes. In the female fetus, the genital tubercle points caudal (down) , while in the male fetus, it points cranial (up) .



(Left) Axial view through the perineum at the time of anatomy scan shows DSD. There are bilateral soft tissue mounds  that may represent the labia or scrotum and a central phallus  that may be a clitoris or penis. Genetic testing showed XX. **(Right)** Similar genital morphology is seen in another fetus with DSD at 20 weeks. The fetal karyotype is XY, and the baby had hypospadias. One clue to the diagnosis is the echogenic prepuce folds . However, genetic testing is warranted for a confident diagnosis of sex.



TERMINOLOGY

Abbreviations

- Disorders of sexual development (DSD)

Synonyms

- Ambiguous genitalia (not preferred term but still used)

Definitions

- Chromosome-phenotype discordance
- Atypical gonadal anatomy; cannot tell sex of fetus
- General issues
 - Refer to fetal sex not gender (gender is self-identified)
 - Phallus refers to genital tubercle (penis or clitoris)
- Old terminology to be avoided

IMAGING

General Features

- Best diagnostic clue
 - Sex is indeterminable despite adequate visualization
 - Cannot differentiate penis from clitoris
 - Cannot differentiate scrotum from labia
 - Sex identification in fetus is generally very accurate
 - 12- to 14-week phallus similar in size for XX and XY fetuses
 - Clitoris points caudal, penis points cranial
 - 90-95% accuracy reported
 - 2nd and 3rd trimester
 - Echogenic lines of labia on axial view
 - Normal tapered penis and scrotum well seen
 - Testes in scrotum by 30 weeks

Ultrasonographic Findings

- **DSD findings in XY fetus**
 - Hypospadias: Ventral penile urethral opening
 - Location determines severity
 - Anterior (at or near glans): Least severe
 - Penile (along shaft)
 - Penoscrotal, scrotal, perineal: Most severe
 - Ultrasound findings
 - Blunt-ending penis instead of normal taper
 - Echogenic prepuce folds at glans
 - ± chordee (ventral curvature of penis)
 - ± small penis
 - ± cryptorchidism (empty scrotal sac)
 - Epispadias: Dorsal urethral opening
 - Small penis (± bifid)
 - Associated with bladder extrophy
 - Small penis ± cryptorchidism
 - Undervirilization etiology
 - Cryptorchidism ± other penile anomaly
 - Undescended testes (often normal if < 32 weeks)
 - Empty scrotum mimics labia
- **DSD findings in XX fetus**
 - Clitoromegaly
 - Mild clitoromegaly is often normal
 - Urethra opening may be on clitoris
 - Prominent or fused labia
 - Can mimic scrotum or cryptorchism
- **DSD and congenital adrenal hyperplasia (CAH)**

- Autosomal recessive disorder of cortisol production
- Virilizing type causes 46,XX DSD
 - Clitoromegaly ± fused labia
- Adrenal glands may be normal or enlarged
 - May lose normal trilobed morphology
 - Normative data tables available for measurements
- Treatment possible early in pregnancy (< 9 weeks)
- **DSD associations**
 - Aneuploidy: Trisomy 13, trisomy 18, triploidy + others
 - Many associated syndromes
 - Smith-Lemli-Opitz
 - Campomelic dysplasia (sex reversal)
 - Bladder and cloacal extrophy
 - Inferior abdominal wall defect extends into genitalia

Imaging Recommendations

- Best imaging tool
 - Evaluate genitalia in axial and sagittal planes
 - Look at adrenal glands if suspect CAH
 - 3D surface-rendered views might be helpful to better define morphology once DSD is suspected
- Protocol advice
 - Pay attention to morphology of tip of phallus
 - Look for testes in scrotum after 25 weeks
 - 97% are descended by 32 weeks
 - Use color Doppler to see urine stream
 - Find urethral orifice (tip vs. ventral vs. dorsal)
 - Offer genetic counseling for all cases
 - Do not assign sex at time of diagnosis and never assign gender
 - Look carefully for other anomalies

PATHOLOGY

General Features

- Etiology
 - Heterogeneous disorder with many etiologies
 - Anatomic, genetic, hormonal
 - Most common cause in XX fetus is CAH
 - Other causes
 - Isolated clitoromegaly/labial anomaly
 - 46,XX testicular DSD (no Y chromosome)
 - Vaginal or cloacal malformation
 - Most common cause in XY fetus is hypospadias
 - Other causes
 - Fetal growth restriction
 - Mixed gonadal dysgenesis
 - Ovotesticular DSD (ovarian + testicular tissue)
 - 46,XX testicular DSD [*SRY*(+)]
 - Luteinizing hormone/follicle-stimulating hormone deficiency
- Genetics
 - CAH is autosomal recessive with 25% recurrence risk
 - > 90% from 21-hydroxylase deficiency
 - Cell-free fetal DNA testing of *CYP21A2* gene for CAH
 - Aneuploidy: Trisomy 13 and triploidy > trisomy 18
 - DSD is almost never isolated finding
 - Sex chromosome aneuploidy
 - Analysis for *SRY* helpful
 - Many duplication and deletion syndromes

DSD Terminology Update

New Terminology	Prior Terminology	Description
Disorder of sex development (DSD)	Intersex	Abnormal genital development
46,XX DSD	Female pseudohermaphrodite	Overvirilization/masculinization of XX female
46,XY DSD	Male pseudohermaphrodite	Undervirilization/undermasculinization of XY male
Ovotesticular DSD	True hermaphrodite	Both ovarian and testicular tissue present
46,XX testicular DSD	XX sex reversal or XX male	Internal and external genitalia are male, testes present
46,XY complete gonadal dysgenesis	XY sex reversal or XY female	Streak gonads with müllerian structures, external genitalia is female

Lee PA et al: Consensus statement on management of intersex disorders. International Consensus Conference on Intersex. *Pediatrics*. 118(2):e488-500, 2006.

Staging, Grading, & Classification

- Consensus panel of intersex disorders presented DSD terminology update in 2006
 - Emphasizes genetic origin of disorders

CLINICAL ISSUES**Presentation**

- Most common signs/symptoms
 - DSD in high-risk patient
 - Prior child with CAH
 - Incidentally noted during routine ultrasound
 - Discordance between genetic sex by karyotype and phenotypic sex by ultrasound
 - In association with other anomalies

Demographics

- Epidemiology
 - Some aspect of DSD seen in 1-2% of all live births
 - 24% diagnosed in utero
 - Only 0.1-0.2% need surgery
 - CAH in 1:10,000-15,000 newborns

Natural History & Prognosis

- CAH considered chronic disease with life-long sequelae
 - XX manifestations
 - Variable degree of female virilization
 - Infertility (androgen excess)
 - Psychosocial disorders
 - Ovarian adrenal rest tumors
 - XY manifestations
 - Testicular adrenal rest tumors (TART)
 - Infertility from hypogonadism and TART
 - Salt wasting from inadequate aldosterone synthesis
 - Most often present 1-4 weeks after delivery
 - Can be severe and lethal
- Other diagnoses with variable treatment
 - Hormonal support and surgery are mainstay of therapies

Treatment

- DSD multidisciplinary team approach is ideal
 - Genetics, urology, psychiatry, endocrinology
 - Gonadal biopsy may be necessary
 - Consultations can begin at time of in utero diagnosis
- Sex assignment should not be rushed
 - Postpone until complete diagnostic assessment is performed

- CAH in utero treatment of high-risk patients is controversial
 - Low-dose dexamethasone before 9th week of gestation
 - Later treatment has little affect
- Hypospadias treatment depends on severity
 - Defer circumcision until urologic consult
- Bladder extrophy treatment is surgical with extensive genitoplasty

DIAGNOSTIC CHECKLIST**Consider**

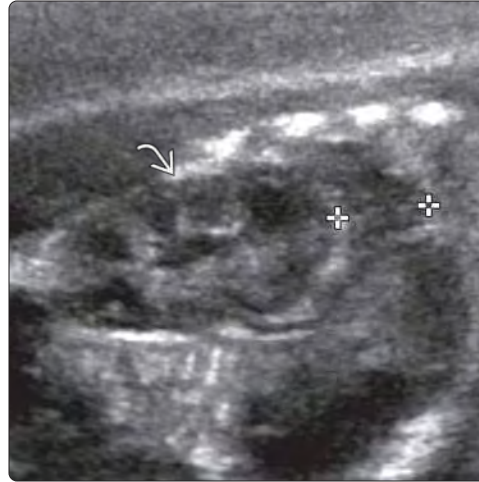
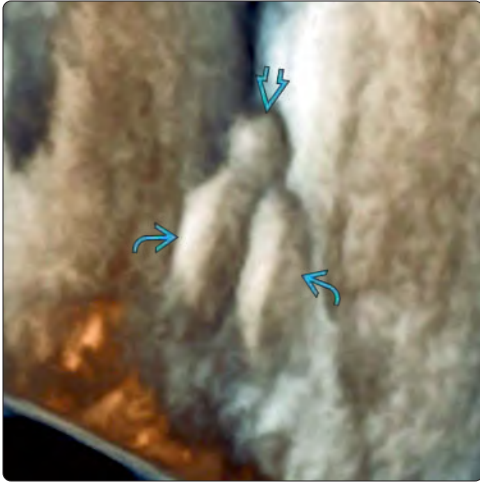- Advanced genetic testing
 - Cell-free fetal DNA
 - Determine fetal sex (99% accurate)
 - Testing of *CYP21A2* in maternal blood for CAH
 - Amniocentesis/chorionic villus sampling
 - Karyotype testing, consider microarray
 - Analysis for *CYP21A2* for CAH confirmation
 - Fluorescent in situ hybridization and polymerase chain reaction testing is additive
 - To determine deletion or duplication of *SRY*
- Make DSD diagnosis only if perineum is well seen, otherwise bring patient back
- Mild clitoromegaly is often normal finding
 - Often regresses during pregnancy
- Normal labial folds can be redundant and mimic clitoromegaly
- Gender is identification of one's own sex (regardless of genitalia)

Image Interpretation Pearls

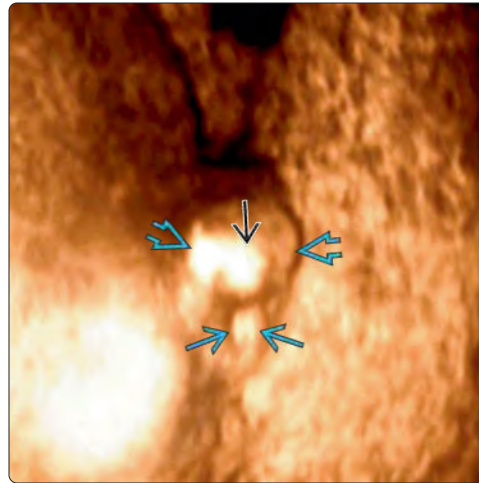
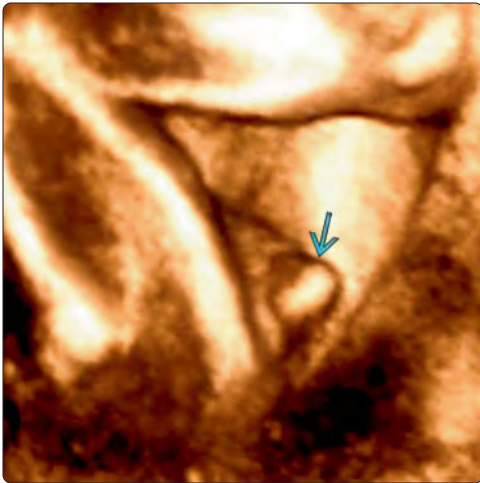
- Use terminology such as labioscrotal folds and genital tubercle or phallus when DSD is present
 - Not all mounds adjacent to phallus are scrotum
- Do not assign sex prenatally if DSD
 - Even when genetic results are available
 - Genetic sex not always followed

SELECTED REFERENCES

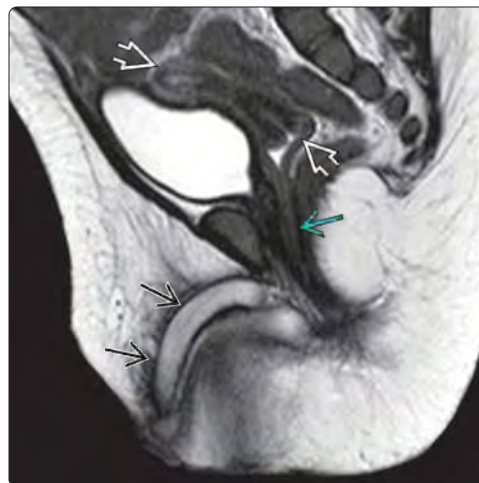
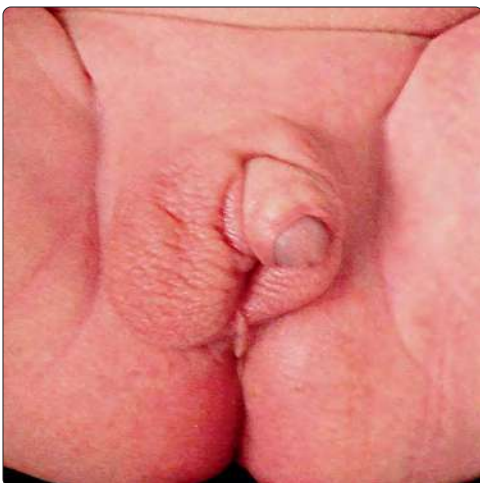1. Adam MP et al: Ambiguous genitalia: what prenatal genetic testing is practical? *Am J Med Genet A*. 158A(6):1337-43, 2012
2. Chitty LS et al: Prenatal management of disorders of sex development. *J Pediatr Urol*. 8(6):576-84, 2012
3. Moshiri M et al: Evaluation and management of disorders of sex development: multidisciplinary approach to a complex diagnosis. *Radiographics*. 32(6):1599-618, 2012
4. Katorza E et al: Sex differentiation disorders (SDD) prenatal sonographic diagnosis, genetic and hormonal work-up. *Pediatr Endocrinol Rev*. 7(1):12-21, 2009



(Left) 3D surface-rendered view shows clitoromegaly and prominent labioscrotal folds in a presumably virilized female fetus with congenital adrenal hyperplasia (CAH). The diagnosis was suspected because of family history of CAH. **(Right)** Coronal view of the kidney and adrenal gland (calipers) shows an enlarged adrenal gland in the same fetus. Normative data for adrenal size is available.

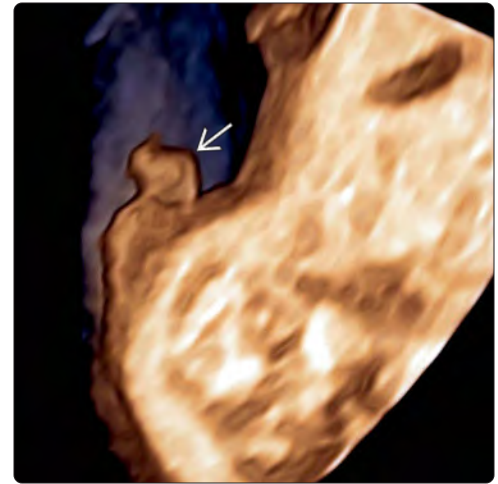
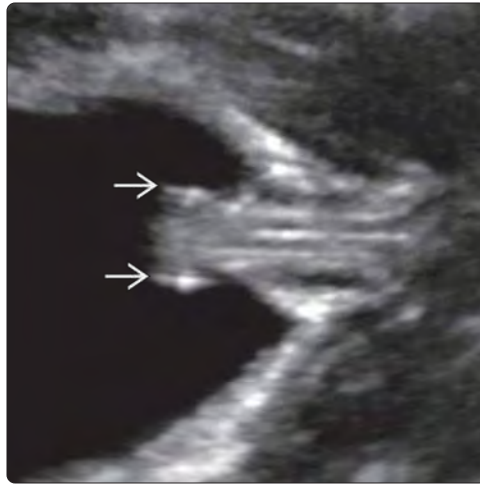


(Left) 3D ultrasound of the genitalia of a female fetus with known CAH (46, XX, DSD) confirms clitoromegaly. **(Right)** Coronal perineal 3D ultrasound view of the same female fetus with CAH shows clitoromegaly, the labial folds, and the introitus of the vagina.

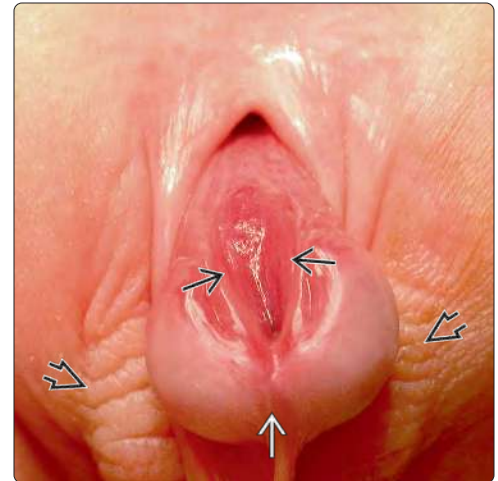
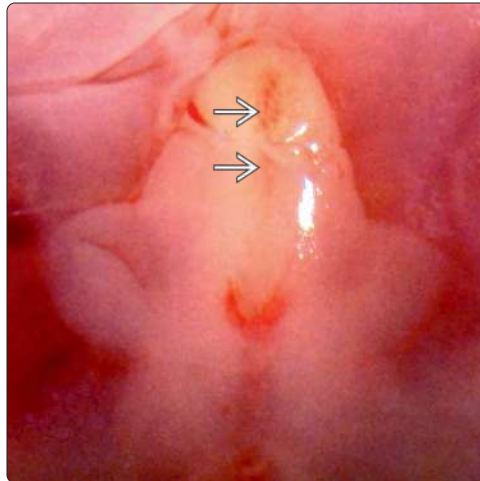


(Left) Clinical photograph of a 46, XX child with CAH shows significant clitoromegaly, very much resembling a penis, and labia with signs of virilization (scrotal folds on labial skin). **(Right)** Sagittal T2WI MR of a 46, XX child with CAH shows marked clitoromegaly. Although there has been significant virilization, the vagina, uterus, and ovaries (not shown here) are present.

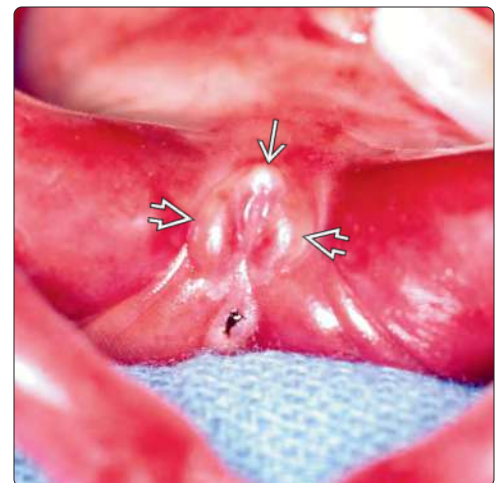
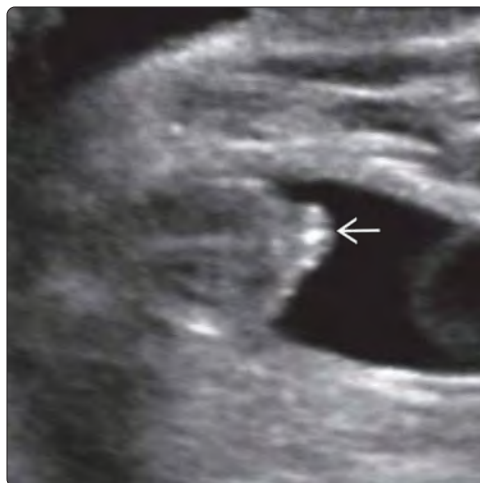
(Left) Ultrasound of the perineum in a male fetus with DSD from hypospadias shows a blunt-ending short penis with lateral prepuce folds [X]. The normal fetal penis should taper. (Right) Sagittal 3D ultrasound of a fetus with hypospadias shows associated chordee. The downward curve of the penis [X] is often associated with more severe hypospadias. Axial views may suggest a short penis because of this type of "folding."

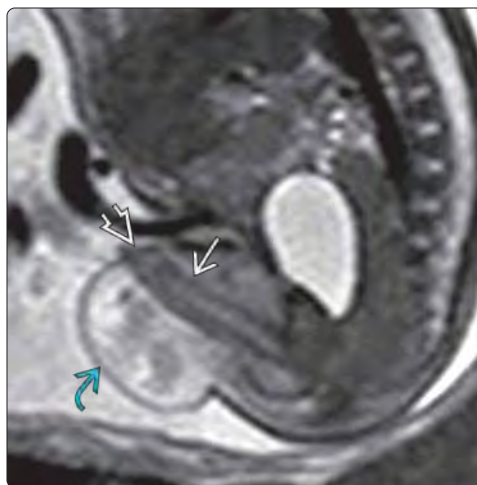
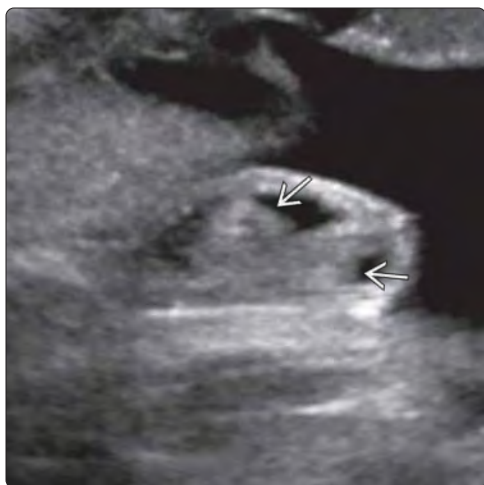

(Left) Gross pathology of a fetus with hypospadias shows the extended open urethral orifice along the ventral surface of the penile shaft [X], instead of a pinpoint at the tip of the penis. (Right) Clinical photograph of a child with DSD from penopubic epispadias shows the open urethra [X] along the dorsum of the penis [X] and cryptorchism [X]. (Courtesy S. Skoog, MD.)

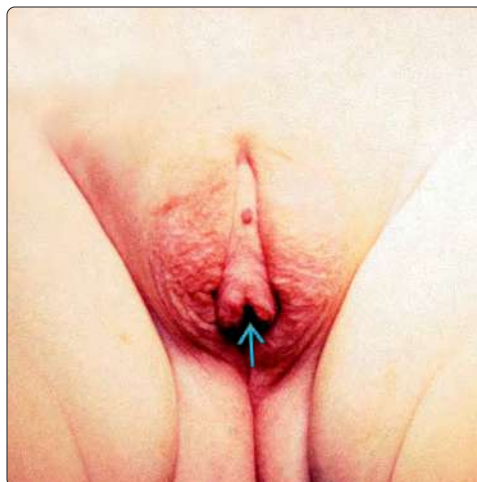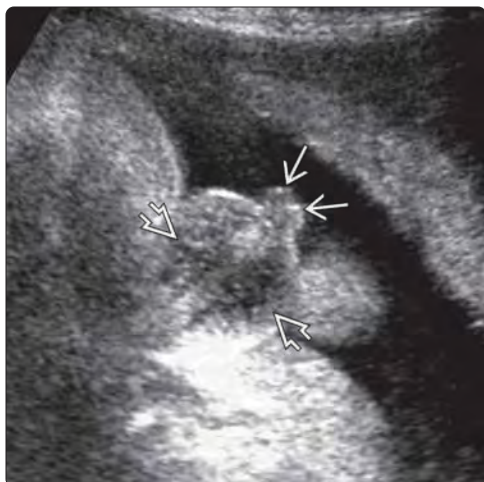


(Left) 46,XY, DSD in this fetus is from a small penis. Note that the tip of the penis is normally curved [X], without prepuce folds, making hypospadias a less likely diagnosis. Karyotype and microarray results were normal. (Right) Autopsy photograph of another case with 46, XY, DSD shows a small penis [X] and diminished scrotum [X].

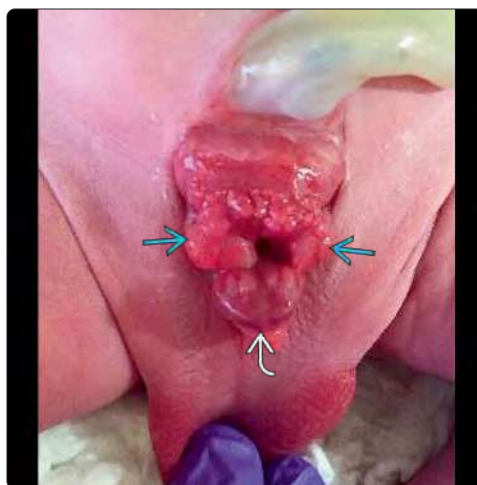
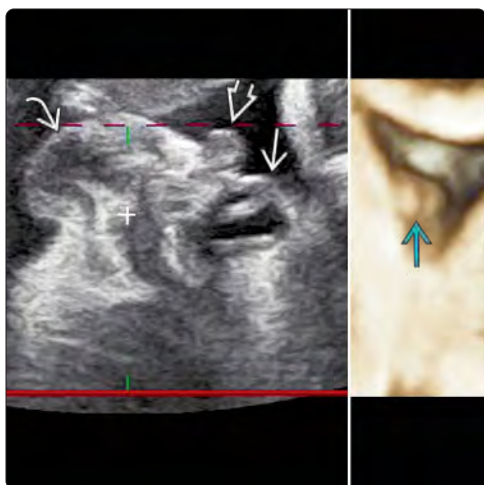




(Left) Axial view of this 30-week fetus shows a scrotum with small hydroceles and intrascrotal testes; however, a penis was not seen. The fetus also had other anomalies but normal XY karyotype. (Right) MR was performed in the same fetus (because of other anomalies) and shows a penile shaft with a normal-appearing tip of the penis at the edge of the scrotum. The diagnosis after delivery was "buried penis," from abundance of abdominal wall and penile skin. Most cases resolve as children grow.



(Left) Axial view of the perineum in a 3rd trimester fetus with 46, XY, DSD and multiple other anomalies shows a small bifid penis and empty scrotal sacs. (Right) Clinical photograph of a child with 46, XY, DSD from androgen insensitivity shows a small bifid penis and cryptorchidism, similar to the findings seen on the ultrasound. (Courtesy S. Skoog, MD.)



(Left) Sagittal view of a low abdominal wall defect shows the penis, scrotum, and an irregular, partially cystic structure immediately superior to the penis. A normal bladder was never seen, making this bladder exstrophy. The penis is small and on the 3D reconstruction has a linear defect. (Right) Clinical photograph of the same child with bladder extrophy shows the inferior abdominal wall defect and exposed polypoid bladder mucosa. The penis has epispadias and is flat and small.

KEY FACTS

TERMINOLOGY

- Urethral meatus on ventral side of penis, not tip
 - 50% distal (near glans)
 - 30% midpenile
 - 20% severe and proximal (penoscrotal, scrotal, perineal)

IMAGING

- Blunt or bulbous tip of penis
 - Lateral echogenic lines (prepuce lateral folds)
- Associate chordee (penis ventral in curvature)
- Tulip sign with severe hypospadias
 - Small curved penis between scrotal folds
- Associated anomalies
 - 40% with upper urinary tract anomalies
 - 7-10% with cryptorchidism and inguinal hernia
 - 7-9% with extraurogenital anomalies

TOP DIFFERENTIAL DIAGNOSES

- Clitoromegaly

- Micropenis
- Bladder exstrophy

PATHOLOGY




- Most often normal chromosomes
- Aneuploidy association
 - XXY, XXXXY, trisomy 13 and 18, triploidy
- Associated with many different syndromes
- Associated with fetal growth restriction

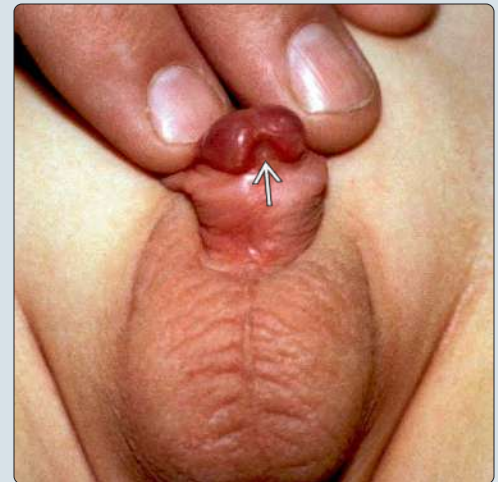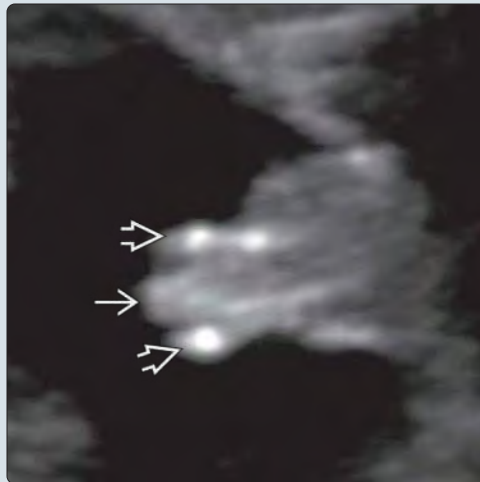
CLINICAL ISSUES





- 1:200-250 males
 - Mild cases often missed on ultrasound
- 4-12% recurrence risk

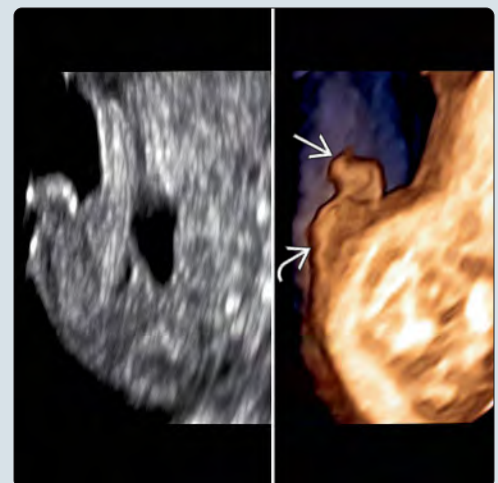
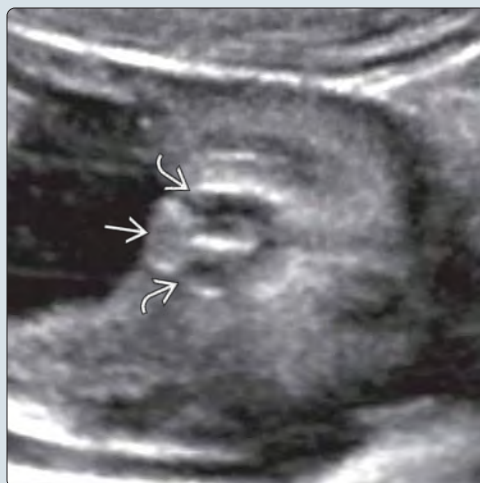
DIAGNOSTIC CHECKLIST

- "Disorder of sex development" is preferred term for significant genital anomaly
 - Avoid gender identification at time of scan
 - Recommend genetic counseling

(Left) In this case with distal hypospadias, the tip of the penis ends bluntly , and the 2 lateral echogenic lines on both sides  are the prepuce lateral folds. The dorsal hood is incomplete, giving the lateral folds this distinct appearance. **(Right)** Clinical photograph of a neonate with distal (glans) hypospadias shows the urethral orifice  is not quite at the tip of the penis. (Courtesy S. Skoog, MD.)



(Left) This case of severe hypospadias shows a small bulbous penis  between 2 empty scrotal sacs . It has been called the tulip sign with the 3 petals formed by the small penis and the scrotal sacs. This appearance can mimic female genitalia with clitoromegaly. **(Right)** Ventral chordee of the penis is seen by 2D and surface-rendered 3D images in this fetus with severe hypospadias. The tip of the penis  curves toward the scrotum . Hypospadias, chordee, and cryptorchidism are often seen together.



TERMINOLOGY

Definitions

- Urethral meatus on ventral side of penis, not tip
 - + failure of closure of ventral foreskin
 - + impaired corpus spongiosum differentiation

IMAGING

General Features

- Location
 - 50% distal (near glans)
 - 30% midpenile
 - 20% severe and proximal (penoscrotal, scrotal, perineal)
- Morphology
 - Penis often small &/or curved (chordee)

Ultrasonographic Findings

- Blunt or bulbous penis tip
 - Normal penis tapers to tip
- Lateral echogenic lines near glans
 - Prepuce lateral folds
 - From incomplete dorsal hood
- Chordee: Ventral curvature of penis from fibrous band
 - Makes penis look small and bent toward scrotum
- Tulip sign of severe hypospadias
 - Small curved penis between scrotal folds
 - Associated cryptorchidism
- Abnormal urine stream (color Doppler)
 - From ventral penis instead of tip
 - Fan-shaped instead of linear
- Associated distal penile cyst (rare)
 - Cyst from urethrocutaneous fistula
 - Fills and empties with micturition
- Associated anomalies
 - 40% with upper urinary tract anomalies
 - 7-10% with cryptorchidism and inguinal hernia
 - 7-9% with extraurogenital anomalies
 - Anorectal malformations
 - Congenital heart defects
 - Cleft lip and palate
 - Neural tube defect

Imaging Recommendations

- Protocol advice
 - Orthogonal views of genitalia (consider 3D)
 - Look at micturition direction and origin
 - Base of penis micturition suggests severe hypospadias

DIFFERENTIAL DIAGNOSIS

Clitoromegaly

- Enlarged clitoris mimics micropenis
- Labia mimic scrotal folds (without testes)
- Important association: Congenital adrenal hyperplasia

Micropenis

- Small penis with normal shape and stream
- Many different causes
- Associated cryptorchidism common

Bladder Exstrophy

- Infraumbilical abdominal wall defect
- Dysmorphic soft tissue may mimic abnormal penis

PATHOLOGY

General Features

- Etiology
 - Failure of urethral groove fusion
 - Normally closes from scrotum to tip of penis between 6.5-16.5 weeks
 - Excessive estrogen or antiandrogen exposure implicated as causative
- Genetics
 - Most often normal XY
 - XXY and XXXXY syndromes
 - Trisomy 13, trisomy 18, triploidy
- Associated abnormalities
 - Syndromes: Fraser, Opitz-Frias, Smith-Lemli-Opitz, 4p-, Aniridia-Wilms, and others
 - Fetal growth restriction (without syndrome)

CLINICAL ISSUES

Demographics

- Epidemiology
 - 1 in 200-250 males
 - 4-12% recurrence risk

Natural History & Prognosis

- Minimal hypospadias often asymptomatic
- Complications
 - Meatal stenosis
 - Inability to guide stream during micturition
 - Abnormal erection
 - Chordee can cause significant ventral curvature
 - Infertility

Treatment

- Mild hypospadias may not need surgery
 - Defer circumcision until decision made
- Surgical repair for moderate and severe cases

DIAGNOSTIC CHECKLIST

Image Interpretation Pearls

- Severe hypospadias may present as ambiguous genitalia

Reporting Tips

- Avoid gender identification if severe genital anomaly
 - "Disorder of sex development" is preferred term
- Recommend genetic counseling
 - Noninvasive cell-free fetal DNA screening
 - Invasive testing (chorionic villus sampling or amniocentesis) remains gold standard

SELECTED REFERENCES

1. Li Y et al: Canalization of the urethral plate precedes fusion of the urethral folds during male penile urethral development: the double zipper hypothesis. *J Urol.* 193(4):1353-59, 2015
2. Bamberg C et al: Prenatal two- and three-dimensional imaging in two cases of severe penoscrotal hypospadias. *J Clin Ultrasound.* 39(9):539-43, 2011

KEY FACTS

IMAGING

- Abdominal cyst in a female fetus especially if lower lateral abdomen or pelvis
 - Daughter cyst sign highly specific
- Gastrointestinal and urinary tracts normal
- Consider torsion if
 - New fluid-fluid level
 - Previously anechoic or hypoechoic cyst becomes hyperechoic

TOP DIFFERENTIAL DIAGNOSES

- Renal abnormalities
 - Multicystic dysplastic kidney
 - Hydronephrosis/ureteropelvic junction obstruction
- Gastrointestinal abnormalities
 - Dilated bowel, meconium pseudocyst
- Other intraabdominal cysts
 - Urachal
 - Enteric duplication

- Mesenteric
- Choledochal
- Hydrocolpos

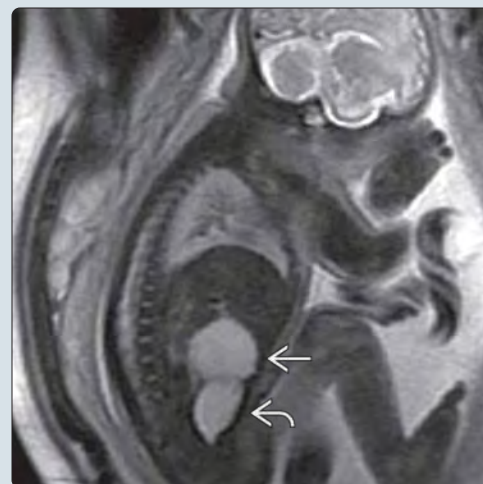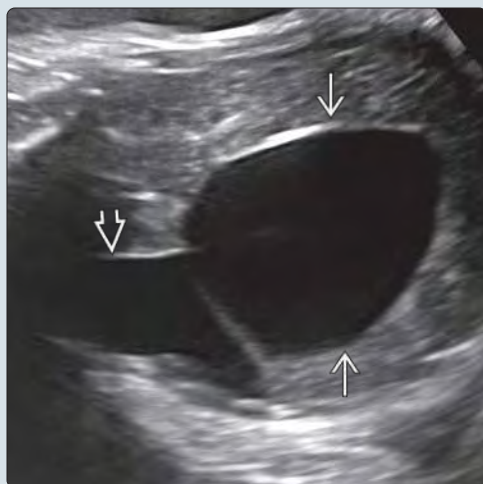
CLINICAL ISSUES

- Most common cause of intraabdominal cyst in female fetus
- Large cyst (> 6 cm) associated with increased risk of hemorrhage and torsion
- If torsion occurs, ipsilateral ovary usually not salvageable
 - Not indication for early delivery
- Most show substantial regression by 6 months of age
 - 64% spontaneous resolution if simple, 40% if complex
- Indications for surgical resection include cysts persisting for > 6 months, > 5 cm or enlarging
- Complex cysts more likely to require excision than simple

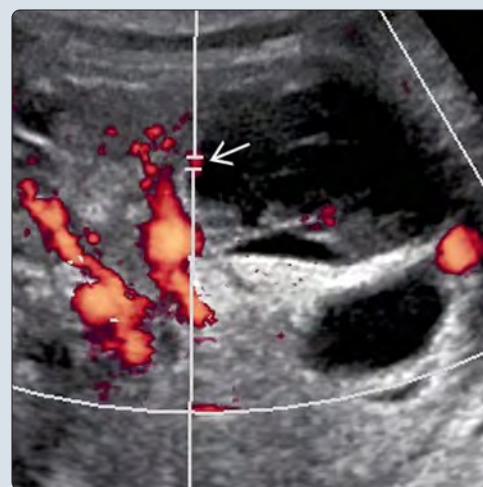
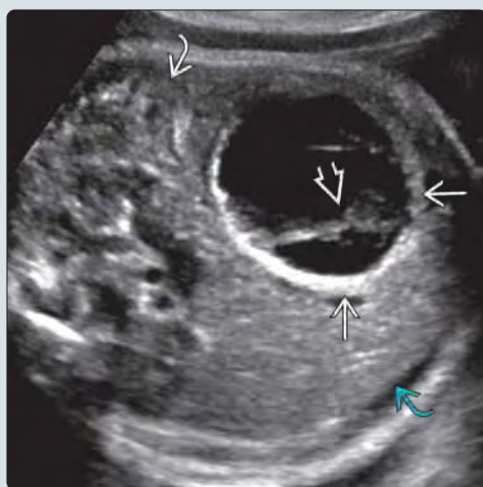
DIAGNOSTIC CHECKLIST

- If seen before 3rd trimester, it is very unlikely that cyst is ovarian in origin

(Left) Coronal US shows a simple cyst in the typical ovarian location, superolateral to the bladder. This cyst remained stable in utero but was excised postnatally, as it was > 5 cm in size. Pediatric ovaries are intraabdominal, thus more mobile than adult ovaries and at increased risk for torsion. **(Right)** Sagittal T2WI shows a simple cystic structure superior to the bladder in an otherwise normal 3rd-trimester female fetus. MR can be very helpful for diagnosis when maternal habitus or abdominal scarring limits sonographic evaluation.



(Left) Axial US in a 3rd-trimester female fetus shows a well-circumscribed, thick-walled cystic mass with internal amorphous echogenic material. It is anterior to the kidney and well-demarcated from the liver. **(Right)** Power Doppler showed flow in the wall of the mass (spectral Doppler not included). Despite this, at surgery, there was torsion and infarction of the ovary. Complex ovarian cysts are much more likely to have internal hemorrhage, which is strongly associated with torsion.



TERMINOLOGY**Definitions**

- Benign functional cyst within fetal ovary

IMAGING**General Features**

- Best diagnostic clue
 - Abdominal cyst containing daughter cyst in female fetus
- Most unilateral but can be bilateral
- Vary in size but may be large (up to 11 cm described)
- Ascites develops if cyst ruptures
- Usually found in lower lateral abdomen or pelvis
 - May cleave from ovary; if so, position in abdomen changes between scans
 - Occasionally found in upper abdomen when lax supporting ligaments allow for displacement
 - Very hard to differentiate displaced ovarian cyst from other intraabdominal cysts
- Gastrointestinal and urinary tracts structurally normal (may see secondary obstruction)

Ultrasonographic Findings

- Simple ovarian cyst
 - Well circumscribed
 - Generally anechoic, unilocular, avascular with imperceptible walls
 - May have occasional septations
 - Daughter cyst sign
 - Small cyst (ovarian follicle) along wall of cystic mass
 - Highly specific sign for ovarian origin (82% sensitive)
- Complex ovarian cyst
 - Internal echoes indicate hemorrhage
 - Often secondary to torsion
 - Appearance varies based on age of blood products
 - Diffusely echogenic with acute hemorrhage
 - Fluid-fluid level seen with repeat bleeds or as clot separates from serum
 - Crescentic or rounded echogenic mass formed by clot retraction
 - Apparent septations due to fibrin strands
 - Appears solid if organized hematoma
 - May develop thin echogenic wall, internal echogenicity from dystrophic calcification
- Torsion
 - Suggested by development of fluid-fluid level or internal echogenic material
 - Cyst may break loose and float in peritoneal cavity; described as autoamputation
- Ascites results from fluid transudation or cyst rupture

MR Findings

- Cystic mass separate from urinary, gastrointestinal tracts
- Septations or hemorrhage may be visible

Imaging Recommendations

- Confirm normal urinary tract
 - High number of cystic abdominal masses are related to urinary tract
- Confirm normal appearance of gastrointestinal and hepatobiliary systems

- Look for cyst complications
- Monitor size: Risk of complications increases with increasing cyst size
- Consider MR in difficult cases
 - Useful to confirm normal renal/liver anatomy if maternal habitus limits sonographic image quality

DIFFERENTIAL DIAGNOSIS**Renal Abnormalities**

- Multicystic dysplastic kidney
 - Usually multiple cysts present with no normal renal parenchyma
- Hydronephrosis/ureteropelvic junction obstruction
 - If severe, hydronephrosis can appear as cystic mass

Gastrointestinal Abnormalities

- Dilated bowel
 - Tubular configuration
 - Peristalsis confirmatory
- Meconium pseudocyst
 - Often irregular contour
 - Wall can calcify
 - Other sequelae of meconium peritonitis
 - Peritoneal calcifications
 - Dilated bowel

Other Intraabdominal Cysts

- Urachal cyst
 - Between dome of bladder and cord insertion
- Enteric duplication cyst
 - Presents earlier, in 2nd trimester
 - Look for gut signature
- Mesenteric cyst
 - May appear identical to ovarian cyst
 - Much less common
- Choledochal cyst
 - Associated with liver; look for connection with branching bile ducts

Intraabdominal Neoplasms

- Cystic teratoma
- Lymphangioma

Hydrocolpos

- Midline pelvic mass
- Posterior to bladder

PATHOLOGY**General Features**

- Etiology
 - Results from fetal ovarian response to maternal hormone/placental hormones

Gross Pathologic & Surgical Features

- Most are follicular in origin
- No malignant potential
 - Single reported case of bilateral ovarian malignancy in 30-week stillborn fetus

CLINICAL ISSUES**Presentation**

- Usually incidental finding in 3rd-trimester female fetus
 - Very unlikely that cyst is ovarian if seen before 3rd trimester
 - Fetal hypothalamic-pituitary-ovary axis becomes active at about 29 weeks

Demographics

- Epidemiology
 - Most common cause of intraabdominal cyst in female fetus
 - 1/3 of infant girls have ovarian "cysts"

Natural History & Prognosis

- Outcome seems to relate to size and internal architecture
 - Cyst > 5 cm
 - 85% oophorectomy, 15% spontaneous resolution
 - Cyst < 5 cm
 - 31% oophorectomy, 69% spontaneous resolution
 - 64% spontaneous resolution if simple, 40% if complex
- Large cyst (> 6 cm) associated with increased risk of
 - Hemorrhage (reported cases with fetal anemia ± hydrops)
 - Torsion (incidence reported to be as high as 50-78% in some series)
 - More likely prenatal than postnatal
 - 74% with concern for in utero torsion in 1 series of 69 cases
 - Infarction
 - Intestinal obstruction
 - Compression by large cysts or adhesions secondary to hemorrhage/torsion/infarction
 - Case reports of associated volvulus/perforation
 - Compression of other adjacent structures (e.g., ureters causing hydronephrosis)
 - Rupture (in utero or during delivery)
- Most show substantial regression by 6 months of age
 - 50% resolve by age 3 months
- May take up to 2 years for complete resolution
- Series of 16 cases at 1 institution
 - No size difference between those that required surgical excision and those that resolved spontaneously
 - 11/16 simple at diagnosis, 3 became complex
 - 1 torsion, 2 hemorrhage without torsion at time of surgery
 - 7/11 resolved either prenatally or within 2 months of birth
 - 5/16 complex at diagnosis
 - 1 decreased in size in utero, 4 stable in size
 - 1/4 resolved on postnatal follow-up
 - 3/4 went to surgery: 2 had torsion, 1 had isolated hemorrhage
 - No malignant neoplasms
 - Prognosis excellent, if no torsion
 - When torsion occurs, ipsilateral ovary usually not salvageable

Treatment

- Serial scans to monitor size, change in echogenicity

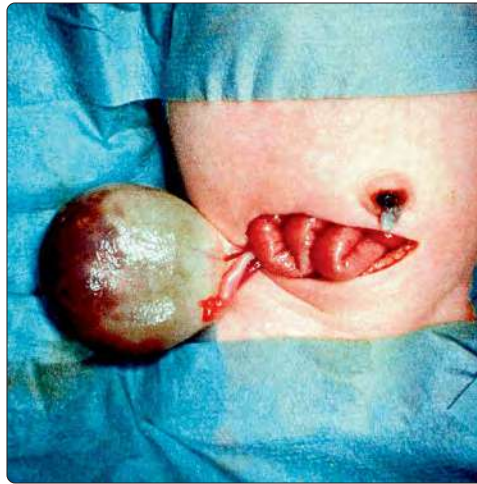
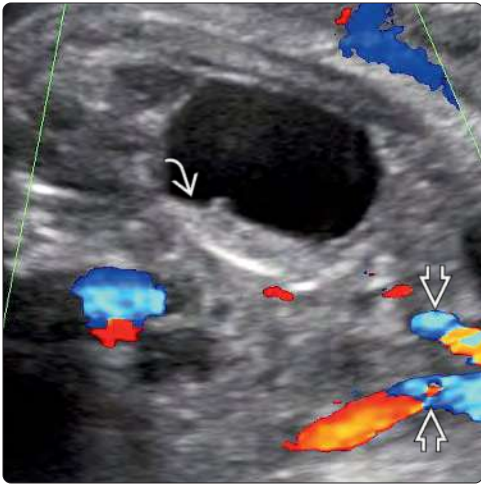
- Development of fluid level/internal complexity suggest hemorrhage or torsion
- Torsion is NOT indication for early delivery
- **Prenatal cyst drainage**
 - Controversial: Theoretical risks of intracystic bleeding, infection, preterm labor
 - Some authors advocate prenatal aspiration for cysts > 5 cm, or those increasing by > 1 cm/week
 - 86% resolution with aspiration and only 14% required neonatal surgery
- For very large cyst, consider elective cesarean section or aspiration prior to induction of labor
 - 74% of series of 66 cases successfully delivered vaginally even with cyst sizes up to 11 cm
- **Postnatal management**
 - Confirm cyst is truly ovarian with ultrasound
 - Follow-up every 4-6 weeks until resolution, increase in size, symptoms develop, or cyst persists > 6 months
 - Some authors advise neonatal cyst aspiration for simple cysts > 4 cm due to risk of torsion/ovarian infarction
 - Indications for surgical resection
 - Evidence of torsion, bowel or urinary tract obstruction
 - Cysts persisting for > 6 months, > 5 cm or enlarging
 - Some advocate postnatal observation for complex cysts if infant stable
 - Series of 11 cases, all resolved, ipsilateral ovary not found at long-term follow-up
 - Authors argue that surgery does not change outcome
 - Surgery should aim to preserve ovarian parenchyma but high likelihood that ipsilateral ovary will be nonfunctional
 - Laparoscopic surgery is feasible
 - Fenestration with ovarian preservation, cystectomy
 - Oophorectomy may be necessary if hemorrhagic infarction from torsion, detorsion can be attempted



DIAGNOSTIC CHECKLIST**Image Interpretation Pearls**

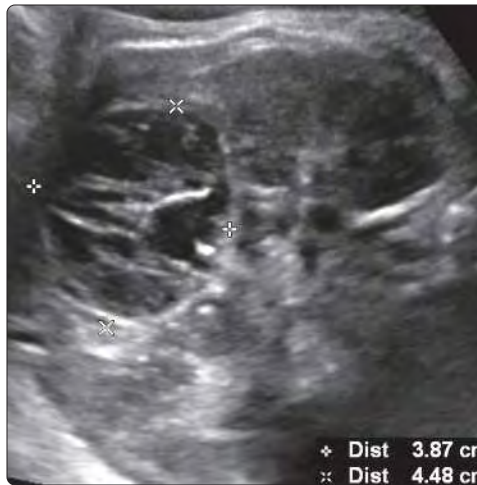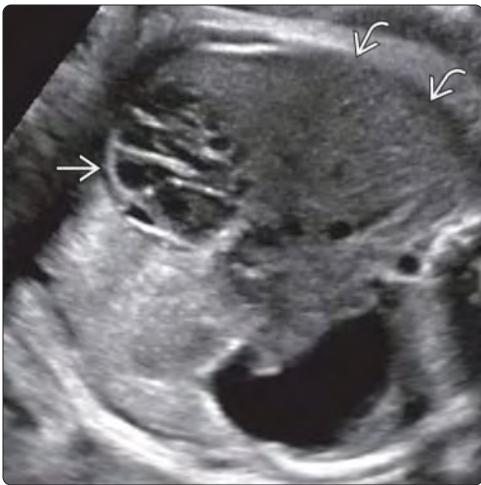
- Precise prenatal diagnosis of ovarian cyst may not be possible
- If seen before 3rd trimester, it is very unlikely that cyst is ovarian in origin
- Daughter cyst sign is highly specific for ovarian origin



SELECTED REFERENCES

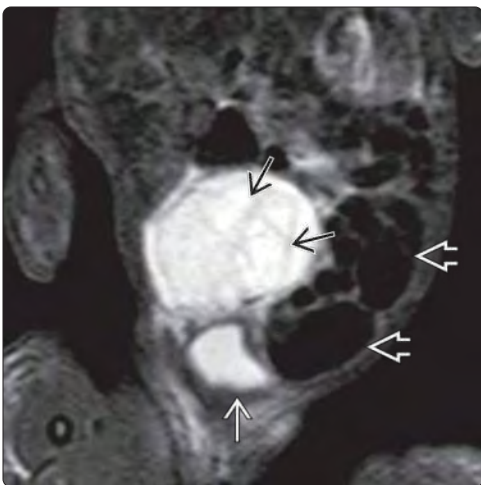1. Catania VD et al: Fetal intra-abdominal cysts: accuracy and predictive value of prenatal ultrasound. *J Matern Fetal Neonatal Med.* 29(10): 1691-9, 2016
2. Dera-Szymanowska A et al: Recurrent fetal complex ovarian cysts with rupture followed by simple cyst in the neonatal period with no adverse sequelae. *J Matern Fetal Neonatal Med.* 29(2): 328-30, 2016
3. Nakamura M et al: Postnatal outcome in cases of prenatally diagnosed fetal ovarian cysts under conservative prenatal management. *Fetal Diagn Ther.* ePub, 2014
4. Ozcan HN et al: Imaging findings of fetal-neonatal ovarian cysts complicated with ovarian torsion and autoamputation. *AJR Am J Roentgenol.* 205(1):185-9, 2015
5. Trinh TW et al: Fetal ovarian cysts: review of imaging spectrum, differential diagnosis, management, and outcome. *Radiographics.* 35(2):621-35, 2015
6. Vitezica I et al: Prenatal diagnosis and management of a massive fetal ovarian hemorrhagic cyst torsion with secondary fetal anemia. *J Clin Ultrasound.* 42(4):219-22, 2014
7. Quarello E et al: The 'daughter cyst sign': a sonographic clue to the diagnosis of fetal ovarian cyst. *Ultrasound Obstet Gynecol.* 22(4):433-4, 2003







(Left) Color Doppler US shows an avascular cystic mass with a fluid-fluid level  indicating intracystic hemorrhage. The umbilical arteries  flank the location of the bladder, indicating that the mass is laterally placed in the abdomen. **(Right)** Intraoperative photograph shows a large, hemorrhagic ovarian cyst. Fetal hydrops in this case was thought to be caused by anemia from the hemorrhage. Interestingly there was no torsion, but it should always be considered when hemorrhage is present.



(Left) Fetal ultrasound shows a multicystic mass  with poor delineation from the liver . Differential considerations included a liver mass, but the imaging features were not typical of either a congenital hepatic hemangioma or a mesenchymal hamartoma. **(Right)** Follow-up axial ultrasound shows a more rounded appearance (calipers) with a reticular, fishnet appearance to the internal echoes. There was no apparent adverse impact on fetal well-being, and the infant was delivered at term.



(Left) Neonatal T2WI with fat suppression in the same case shows a complex, cystic mass with low-signal, linear internal strands  superolateral to the bladder  and separate from bowel  and liver. Ovarian torsion was found at surgery. **(Right)** Photograph of a resected ovary in a similar case shows complete infarction with no viable ovarian parenchyma. Note the fibrin strands  within the clot; these account for some of the complexity and apparent internal septations seen on prenatal US and MR images.

KEY FACTS

TERMINOLOGY

- Vaginal obstruction with resulting distension of compliant vagina with vaginal and uterine secretions
- Isolated hydrocolpos is distinct entity from hydrocolpos in association with cloacal anomalies

IMAGING

- Unilocular, fluid-filled, conical retrovesicular mass funneling to perineum without fluid-fluid level
- Normal anal dimple
- Normal T1 hyperintense, meconium-filled rectum

TOP DIFFERENTIAL DIAGNOSES

- Cloacal malformation
 - Septated or bilobed, cystic pelvic mass representing obstructed, duplicated vaginas
 - Fluid-fluid level resulting from mixing of urine and vaginal secretions ± meconium
 - Commonly has associated abnormalities

- Absent normal T1 hyperintense, meconium-filled rectum on fetal MR

PATHOLOGY

- Isolated hydrocolpos results from imperforate hymen, transverse vaginal septum, or vaginal atresia
 - Copious secretions in response to maternal circulating hormones
- Additional congenital anomalies uncommon

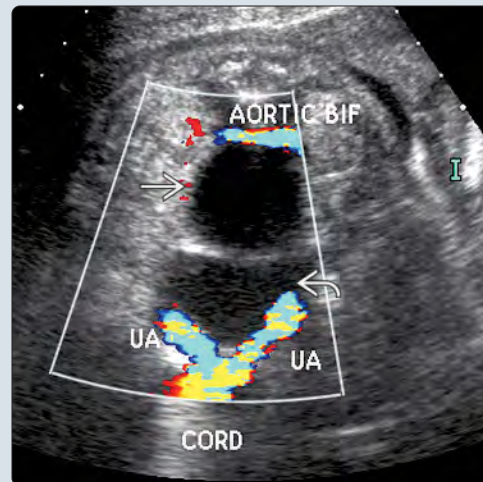
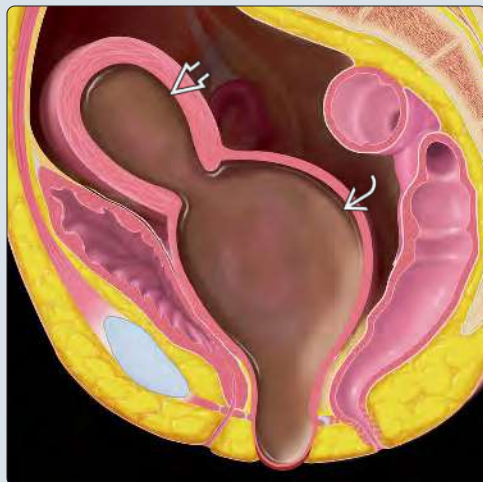
CLINICAL ISSUES

- Imperforate hymen present in 0.1% of term neonates
- Immediate drainage is important to prevent sepsis, perforation, or ongoing urinary tract obstruction

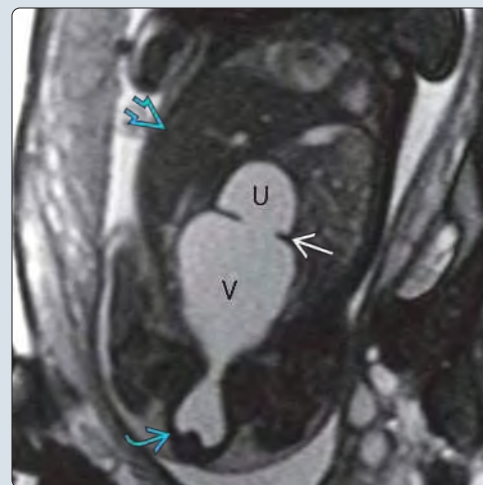
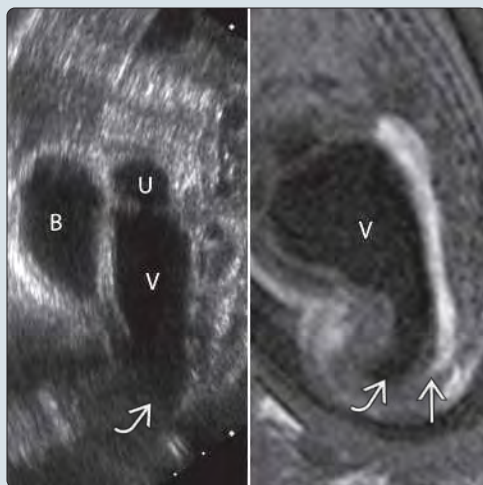
DIAGNOSTIC CHECKLIST

- Fetal MR recommended for characterization of pelvic structures and differentiation of isolated hydrocolpos from cloacal anomaly

(Left) Sagittal graphic of a fetus with an imperforate hymen shows a dilated vagina . Excessive secretion in response to maternal circulating hormones causing vaginal distention, which can be quite marked. The uterus may also expand with fluid (hydrometrocolpos) but, due to its thicker wall distension, is not as significant as the vagina and may not be seen in utero. (Right) Axial US shows a unilocular, anechoic mass posterior to the normal bladder , representing an obstructed vagina filled with uterine and vaginal secretions.



(Left) Sagittal US and T1 MR of the same patient shows the conical-shaped vagina (V) extending down to the perineum [bladder (B), uterus (U)]. The normal, hyperintense, meconium-filled rectum is seen as separate structure, excluding a cloacal anomaly. (Right) Coronal T2 MR in the same patient shows the markedly distended vagina (V) and uterus (U) extending up the level of the liver (open cervix). The distal vagina bulges at the perineum . This was shown to be an imperforate hymen at delivery.



TERMINOLOGY**Synonyms**

- Hydrometrocolpos (includes distension of uterus)

Definitions

- Vaginal obstruction with resulting distension of compliant vagina with vaginal and uterine secretions
- Isolated hydrocolpos
 - Distinct entity from hydrocolpos in association with cloacal anomalies

IMAGING**General Features**

- Best diagnostic clue
 - Unilocular, fluid-filled, conical retrovesicular mass funneling to perineum without fluid-fluid level

Ultrasonographic Findings

- Unilocular, anechoic, cystic pelvic mass posterior to bladder with characteristic funneling to perineum
- May have opened cervix with contiguous fluid distending uterine cavity
- Signs of local mass effect in pelvis
 - Anteriorly displaced bladder
 - Bilateral hydronephrosis or hydroureter
- Fetal perineum should be normal with normal anal dimple
- Additional congenital anomalies uncommon

MR Findings

- T1WI
 - Normal, hyperintense, meconium-filled rectum extending to perineum
- T2WI
 - Hyperintense cystic mass arising from deep pelvis with local mass effect

Imaging Recommendations

- Protocol advice
 - Ultrasound to carefully follow structures and evaluate fetal perineum, including anal dimple
 - Sagittal T2WI thin sections through fetal pelvis to evaluate relationship of vagina, bladder, and rectum
 - Sagittal T1WI to look for presence of normal, hyperintense, meconium-filled rectum

DIFFERENTIAL DIAGNOSIS**Cloacal Malformation**

- Septated or bilobed, cystic pelvic mass representing obstructed, duplicated vaginas
- Fluid-fluid level resulting from mixing of urine and vaginal secretions ± meconium
- Commonly have associated abnormalities
 - Developmental and secondary renal anomalies
 - Bowel dilatation
 - Lumbosacral anomalies
- Absent T1 hyperintense, meconium-filled rectum on MR

Ovarian Cyst

- Off midline, higher in pelvis
- Does not extend to perineum

PATHOLOGY**General Features**

- Etiology
 - Imperforate hymen is most common cause
 - Transverse vaginal septum
 - Vaginal atresia
 - Copious uterine and vaginal secretions in response to circulating maternal hormones
- Genetics
 - Familial forms of imperforate hymen reported
 - McKusick-Kaufman syndrome: Autosomal recessive syndrome with hydrocolpos and postaxial polydactyly

Gross Pathologic & Surgical Features

- Bulging hymenal membrane at introitus

CLINICAL ISSUES**Presentation**

- Most common signs/symptoms
 - Cystic pelvic mass on prenatal ultrasound
 - Often overlooked on initial neonatal physical exam
 - Urinary and bowel retention may develop due to local mass effect in neonatal period
 - More often presents later in life at menarche with abdominal pain &/or amenorrhea
- Other signs/symptoms
 - Uncommonly severe fetal urinary obstruction, oligohydramnios, and pulmonary hypoplasia

Demographics

- Epidemiology
 - Imperforate hymen present in 0.1% of term neonates
 - Symptomatic neonatal hydrocolpos more rare

Natural History & Prognosis

- Excellent prognosis if identified and treated
- Milder cases may spontaneously resolve in neonatal period as estrogens decline
 - May present as hematocolpos when menses begin
- Rare, lethal cases associated with other anomalies/distortion of umbilical vessels

Treatment

- Immediate drainage of significant obstruction to prevent sepsis, perforation, or ongoing urinary obstruction
- Incision of hymen or resection of vaginal septum

DIAGNOSTIC CHECKLIST**Reporting Tips**

- Report findings differentiating hydrocolpos from cloacal malformation

SELECTED REFERENCES

1. Capito C et al: Prenatal pelvic MRI: additional clues for assessment of urogenital obstructive anomalies. *J Pediatr Urol.* 10(1):162-6, 2014
2. Tsai HF et al: Prenatal ultrasonography and postnatal follow-up of a case of McKusick-Kaufman syndrome. *Taiwan J Obstet Gynecol.* 53(2):241-4, 2014
3. Murthy V et al: Two neonates with congenital hydrocolpos. *Case Rep Pediatr.* 2013:692504, 2013
4. Bhargava P et al: Prenatal US diagnosis of congenital imperforate hymen. *Pediatr Radiol.* 39(9):1014, 2009

DIFFERENTIAL DIAGNOSIS**Common**

- Ureteropelvic Junction Obstruction
- Posterior Urethral Valves

Less Common

- Duplicated Collecting System With Obstruction
- Ureterovesical Junction Obstruction
- Primary Ureterocele (Orthotopic)
- Vesicoureteral Reflux

Rare but Important

- Prune-Belly Syndrome

ESSENTIAL INFORMATION**Key Differential Diagnosis Issues**

- **Diagnosis of urinary tract dilation (UTD)**
 - Measure renal pelvis anterior-posterior diameter
 - Obtain midrenal axial view
 - Spine at 12 o'clock or 6 o'clock
 - Place calipers to measure only fluid in renal pelvis
 - Abnormal renal pelvis measurements
 - ≥ 4 mm between 16 wk and 27 wk 6 d
 - ≥ 7 mm after 28 wk
 - Obtain coronal and sagittal renal views
 - Look for calyx dilation
 - Evaluate renal parenchyma
 - Normal renal echogenicity is less than liver
 - Parenchymal cysts are never normal
 - Look for ureter dilation
 - Any persistent distention is abnormal
 - Evaluate lower urinary tract
 - Is bladder abnormally distended?
 - Look for bladder wall thickening
 - Evaluate urethra
 - Posterior urethra dilation
 - Keyhole bladder if focal and round
 - May look like funnel
 - Might see urethra distended to tip of penis
 - Evaluate genitalia (sex of baby)
 - Obstructive uropathy more common in boys
 - Duplicated kidney more common in girls
- Evaluate collecting system methodically to determine pattern of dilation or point of obstruction
- Amniotic fluid evaluation
 - Amniotic fluid index (AFI)
 - Divide uterus in 4 quadrants
 - AFI = sum of maximum vertical pocket in each pocket
 - Normal is generally 10-20 cm
 - Refer to normal tables (AFI/gestational age)
 - AFI of ≤ 5 cm considered severe
 - Maximum vertical pocket
 - Normal range considered 2-8 cm
 - Severe oligohydramnios: No pocket > 2 cm

Helpful Clues for Common Diagnoses

- **Ureteropelvic Junction Obstruction**
 - Key imaging findings

- Dilated renal pelvis ends abruptly at ureteropelvic junction (UPJ)
- Bullet-shaped renal pelvis
- Distended calyces
- Associated anomalies
 - 10% bilateral UPJ
 - 25% contralateral renal anomaly
 - 10% with extrarenal anomalies
- Etiology
 - Abnormal muscle layer or neural innervation at UPJ
 - Accessory crossing vessel in 1/3
- Prognosis is generally good if unilateral
 - Most are partial UPJ
- **Posterior Urethral Valves**
 - Obstructed posterior urethral membrane acts as valves
 - Partial or complete obstruction
 - Seen in male fetuses only
 - Keyhole bladder is hallmark finding
 - Distended bladder + distended posterior urethra
 - Bladder wall often thick
 - Bladder size may be massive
 - Variable renal and ureter dilation
 - Might see renal cystic dysplasia without dilation
 - Variable oligohydramnios
 - Depends on renal function
 - Partial vs. complete obstruction
 - Associated anomalies
 - Pulmonary hypoplasia
 - Severe or early oligohydramnios
 - VACTERL association
 - Cardiac malformations

Helpful Clues for Less Common Diagnoses

- **Duplicated Collecting System With Obstruction**
 - Duplicated renal parenchyma with variable collecting system duplication
 - Separate upper and lower pole moieties
 - Complete duplication = 2 separate ureters
 - Hallmark findings: Obstructed upper pole + ureterocele in bladder
 - Ectopic ureterocele associated with upper pole ureter
 - Weigert-Meyer rule
 - Ectopic ureter inserts inferior and medial to lower pole ureter
 - Upper pole obstructs
 - Lower pole ureter refluxes (mild findings in fetus)
 - Ureterocele may be large
 - Can cause bladder outlet obstruction
 - Contralateral renal obstruction
- **Ureterovesical Junction Obstruction**
 - Primary megaureter
 - Hydroureter without ureterocele or duplication
 - Congenital stenosis UVJ
 - Hypoplasia/atrophy muscle fibers
 - Paucity of ganglion cells
- **Primary Ureterocele (Orthotopic)**
 - Ureterocele without renal duplication
 - Ectopic ureterocele, associated with renal duplication, is 3x more common
 - Cystic dilation of distal submucosal ureter

- Partial or complete
- Bilateral in 10%
- o Prenatal ultrasound findings
 - Distended ureter balloons into bladder
- **Vesicoureteral Reflux**
 - o Retrograde flow of urine
 - Bladder → ureter or kidney
 - o Ultrasound findings
 - Variable/intermittent hydronephrosis
 - ↑ dilation immediately after voiding
 - o Definitive diagnosis made after delivery
 - Voiding cystourethrography
 - Nuclear cystography
 - o Grading system
 - I: Reflux into ureter only
 - II: Reflux reaches pelvis (normal calyces)
 - III: Mild calyceal blunting
 - IV: Progressive calyceal dilatation
 - V: Dilated tortuous collecting system with severe calyceal dilatation
 - o 80% newborns outgrow reflux
 - o Surgical treatment for persistent reflux
 - Ureteral reimplantation
 - Endoscopic periureteral injection

Helpful Clues for Rare Diagnoses

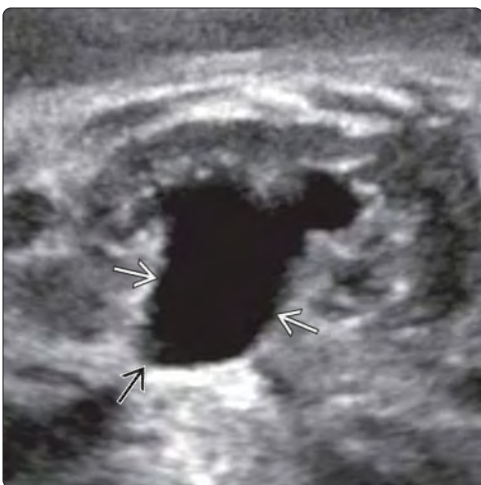
- **Prune-Belly Syndrome**
 - o 3 defining features
 - Dramatic collecting system dilatation
 - Bladder + ureters + renal collecting system
 - Deficient abdominal musculature
 - Male fetus with cryptorchidism
 - o Prenatal ultrasound findings
 - Large, thin-walled bladder
 - Sometimes with undulating wall
 - Bilateral hydroureter and hydronephrosis
 - Ureter often markedly tortuous
 - Diffuse urethral dilatation might be seen (no keyhole)
 - No obvious point of obstruction

- ± oligohydramnios
- o Very difficult to differentiate from posterior urethral valves

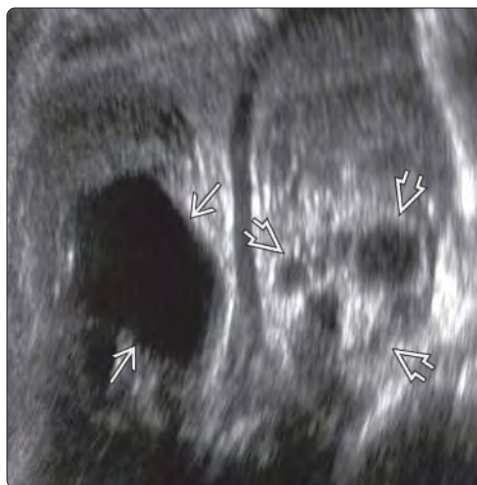
Other Essential Information

- **UTD classification system**
 - o UTD A1: Renal pelvis dilation only
 - o UTD A2-3: Any additional feature to UTD A1
 - Peripheral collecting system dilation
 - Ureter or bladder dilation
 - Renal parenchymal abnormality
 - Oligohydramnios
 - o Follow-up strategies
 - UTD A1: Follow-up at 32 weeks
 - > 48 hours after delivery
 - 2nd follow-up at 1-6 months if persistent
 - UTD A2-3: Depends on severity
 - q 4-8 weeks or some need treatment
 - Consider urology consult during pregnancy
- **Pitfalls**
 - o Renal pyramids may mimic dilated calyx
 - o Dilated calyces may mimic renal cysts
 - Look for connection with renal pelvis
 - o Ureterocele may prolapse in and out of bladder
 - o Large ureterocele may fill entire bladder
 - Ureterocele can mimic bladder
 - Especially after voiding when bladder collapses around ureterocele
- Look for secondary renal cystic dysplasia
 - o UTD + renal cysts
 - o Suggests significant renal damage
 - o Can mimic multicystic renal dysplasia
- Obstruction can decompress spontaneously
 - o Urinary ascites, urinoma
- Not all large fluid collections in pelvis are bladder
 - o Cloaca
 - o Abdominal cysts
 - Meconium pseudocyst
 - Mesenteric cyst, duplication cyst

Ureteropelvic Junction Obstruction



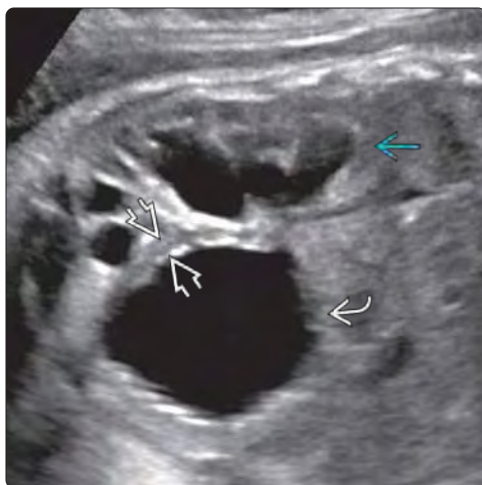
Ureteropelvic Junction Obstruction



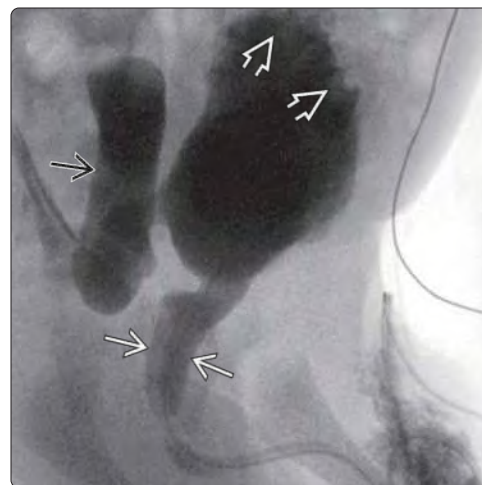
(Left) The classic bullet-shaped renal pelvis is seen in this case of ureteropelvic junction (UPJ) obstruction. The renal pelvis is markedly dilated and points to and ends abruptly at the UPJ. **(Right)** Similar renal pelvis morphology is seen in this fetus with right UPJ obstruction and left multicystic dysplastic kidney. Contralateral renal anomalies are seen in 10% of cases with UPJ obstruction. In this case, there was severe oligohydramnios and the fetus had secondary pulmonary hypoplasia.

Posterior Urethral Valves

(Left) Coronal view shows a dilated fetal bladder and hydronephrosis. The bladder wall is thickened and trabeculated, findings suggestive of lower urinary tract obstruction (LUTO). Posterior urethral valve disorder is the most common cause of LUTO. **(Right)** Postnatal voiding cystourethrogram in the same case shows a dilated posterior urethra, bladder trabeculation, and reflux into a dilated ureter.

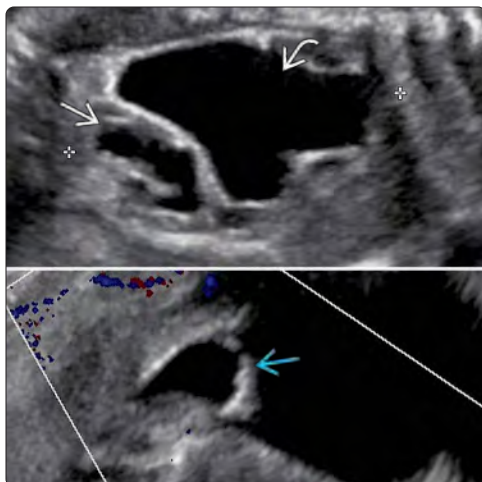


Posterior Urethral Valves

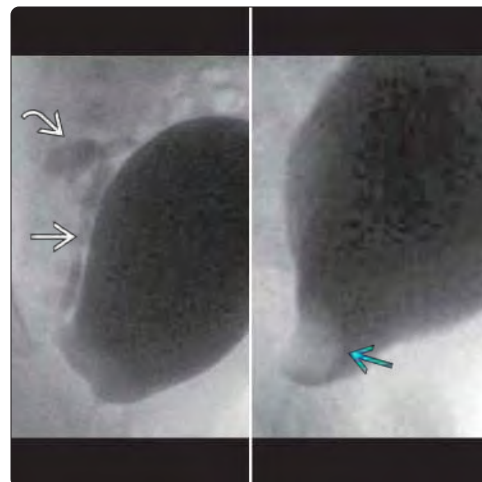


Duplicated Collecting System With Obstruction

(Left) In this case of renal duplication, the upper moiety is markedly dilated and separate from the mildly dilated lower moiety. An ectopic ureterocele in the bladder is the cause of the upper pole obstruction. **(Right)** Postnatal VCUG shows a filling defect in the lower bladder, from the ectopic ureterocele, and reflux into the other separate ureter that drains the lower moiety. The drooping lily sign is also seen, as the lower pole collecting system is inferiorly displaced by the obstructed upper pole.

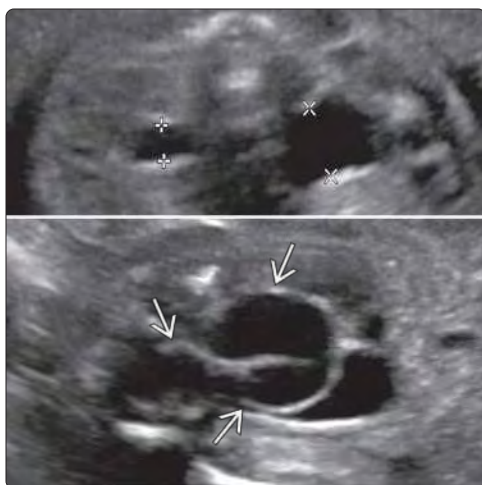


Duplicated Collecting System With Obstruction

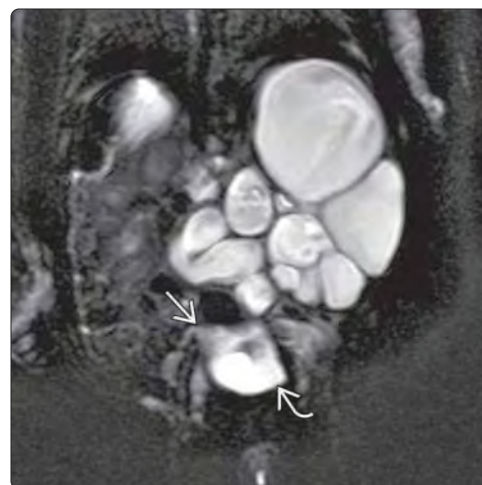


Ureterovesical Junction Obstruction

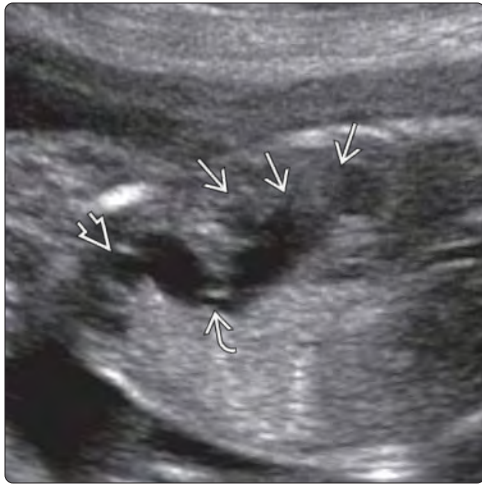
(Left) This fetus with left renal hydronephrosis (x calipers) and mild right renal dilation (+ calipers) also had a dilated serpiginous left ureter. Dilated ureters can mimic dilated bowel. **(Right)** Postnatal MR shows massively dilated left serpiginous ureter with an otherwise normal bladder. A normal right distal ureter was incidentally seen. Ureterovesical obstruction is not associated with ureterocele and is secondary to a primary narrowing or dysfunction of the distal ureter.



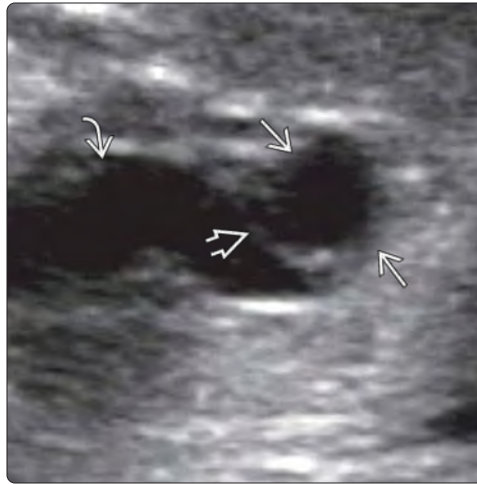
Ureterovesical Junction Obstruction



Primary Ureterocele (Orthotopic)

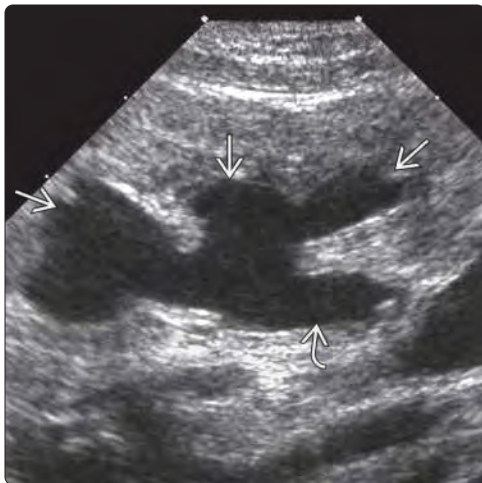


Primary Ureterocele (Orthotopic)

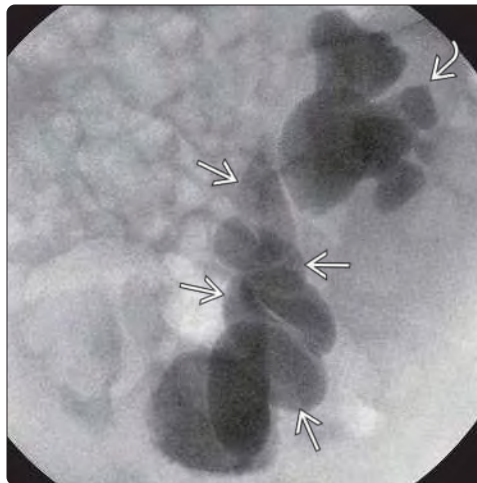


(Left) Coronal ultrasound shows a nonduplicated, hydronephrotic kidney with ureteral dilatation and a focal "cystic" distention at the ureter bladder junction. **(Right)** Axial ultrasound focused on the partially filled bladder in the same case shows the distended distal ureter ballooning into the bladder. This is an example of an orthotopic ureterocele, not associated with duplication. Ectopic ureteroceles associated with duplicated kidneys are much more common.

Vesicoureteral Reflux

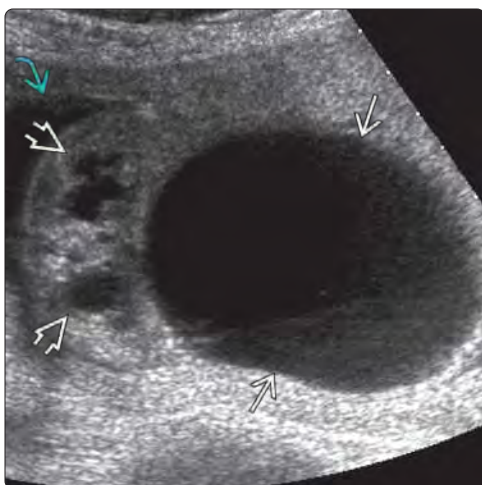


Vesicoureteral Reflux

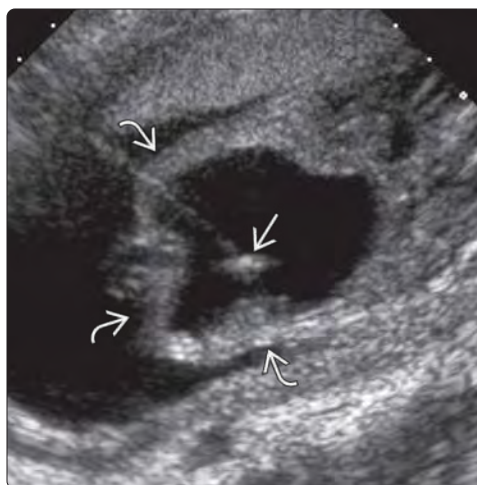


(Left) Coronal ultrasound of a neonate with prenatal diagnosis of hydronephrosis confirms calyceal and renal pelvis distention. Reflux is often a difficult fetal diagnosis but can be suggested if the degree of distention varies during the course of the study. **(Right)** Coronal radiograph of the VCUG, obtained immediately after voiding, shows significant reflux. The ureter is distended and tortuous. The renal pelvis and calyces are markedly dilated as well.

Prune-Belly Syndrome



Prune-Belly Syndrome



(Left) Axial ultrasound shows a large bladder and hydronephrosis. Note the lack of bladder wall thickening and the presence of some amniotic fluid. **(Right)** Vesicocentesis is performed to assess renal function. The needle is easily placed into the dilated bladder. Laxity of the abdominal wall becomes evident as the bladder is emptied. Fetuses with prune-belly syndrome also have undescended testes.

DIFFERENTIAL DIAGNOSIS

Common

- Autosomal Recessive Polycystic Kidney Disease
- Obstructive Cystic Dysplasia
- Trisomy 13

Less Common

- Meckel-Gruber Syndrome
- Beckwith-Wiedemann Syndrome

ESSENTIAL INFORMATION

Helpful Clues for Common Diagnoses

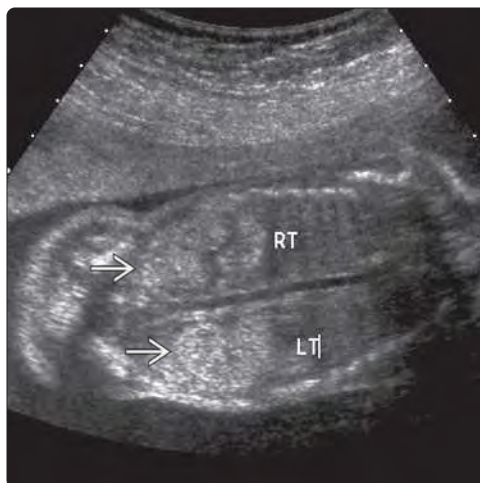- **Autosomal Recessive Polycystic Kidney Disease**
 - Kidneys may be diffusely hyperechoic or have hyperechoic pyramids
 - Result of cyst dilation of convoluted tubules and collecting ducts
 - Cortex may be preserved but difficult to discern with severe disease
 - Look for thin, hypoechoic rim around echogenic medulla
 - Renal enlargement may not occur until mid 2nd trimester
 - By late fetal life, kidneys may be anywhere from 3-10x normal size
 - May see small, scattered macroscopic cysts but not major feature
 - Oligohydramnios variable depending on severity of renal involvement
 - Early-onset oligohydramnios → poor prognosis
- **Obstructive Cystic Dysplasia**
 - Should see obvious urinary tract dilation (e.g., posterior urethral valves)
 - Chronic obstruction disrupts normal nephron tubular induction
 - Increased echogenicity with loss of corticomedullary differentiation
 - Indicates some degree of renal impairment
 - Renal size may be ↑, ↓, or normal

- ↓ size suggests late finding; often see associated oligohydramnios at this stage
- May see cortical cysts
 - Begin in periphery ("rosary beads") → large cysts
- **Trisomy 13**
 - Cystic dysplasia seen in 50%
 - Kidneys usually echogenic and enlarged; cysts may be visible
 - Early finding, which may be seen on 1st trimester-nuchal translucency scan
 - Multiple major anomalies in > 90%; many of which can be seen in 1st trimester
 - Brain/face: Holoprosencephaly, cyclopia, proboscis, hypotelorism, midline or bilateral cleft lip
 - Body: Cardiac defects, fetal growth restriction, postaxial polydactyly

Helpful Clues for Less Common Diagnoses

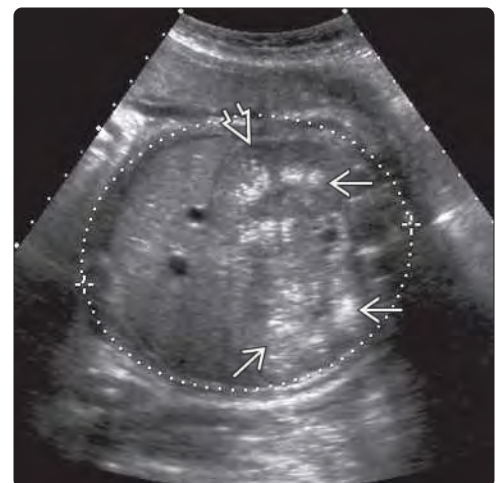
- **Meckel-Gruber Syndrome**
 - Triad of findings (2 findings required for diagnosis)
 - Renal cystic dysplasia most consistent finding, present in 95-100%
 - Encephalocele in 60-80%
 - Postaxial polydactyly in 55-75%
 - Renal involvement has variable appearance, but often severe
 - Grossly enlarged, echogenic kidneys most common
 - May have macroscopic cysts
 - Oligohydramnios common and often severe
 - Appearance may be identical to autosomal recessive polycystic kidney disease, so important to look for associated findings
- **Beckwith-Wiedemann Syndrome**
 - 3 hallmark findings: Macrosomia, macroglossia, omphalocele
 - Kidneys are large but often with normal morphology and echogenicity
 - May be mildly hyperechoic but usually preserved medullary pyramids
 - Fluid is usually normal

Autosomal Recessive Polycystic Kidney Disease

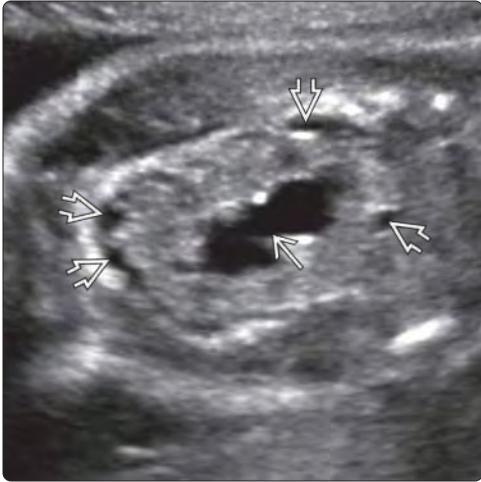


(Left) Coronal US in a 2nd-trimester fetus with autosomal recessive polycystic kidney disease (ARPKD) shows bilateral, enlarged, echogenic kidneys. Amniotic fluid may be normal to low depending on degree of remaining renal function. (Right) Axial US in a 36-week fetus with ARPKD shows renal enlargement with increased renal medullary echogenicity but preservation of some normal cortex. ARPKD primarily involves collecting ducts, so cortex may appear normal but is often compressed. Look for a thick, hypoechoic rim.

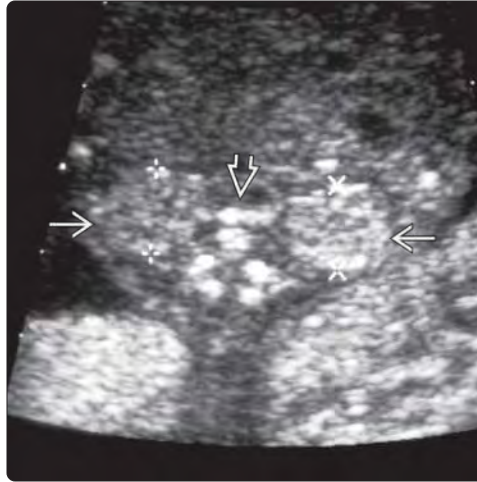
Autosomal Recessive Polycystic Kidney Disease







Obstructive Cystic Dysplasia

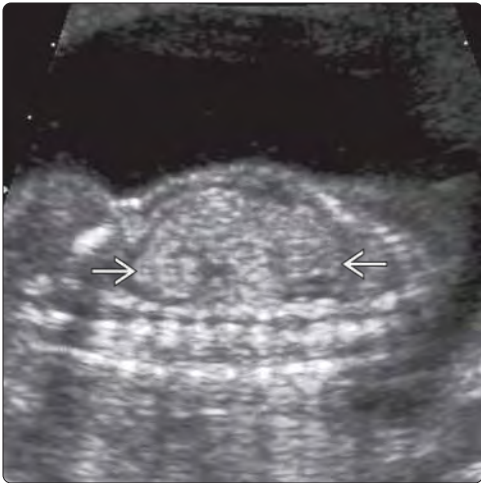

Obstructive Cystic Dysplasia

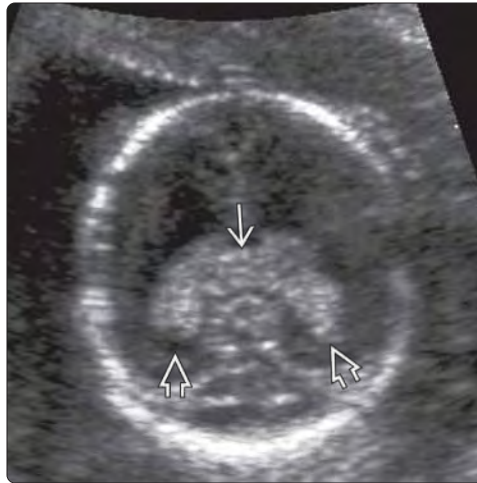





(Left) Coronal US of a fetus with urinary tract dilation (note the dilated renal pelvis ) shows diffuse increased renal echogenicity with small peripheral cortical cysts  ("rosary beads"). All cases with sonographic features of cystic dysplasia will have some degree of renal insufficiency. (Right) Axial US of a fetus with severe cystic dysplasia shows small, echogenic kidneys , which barely extend beyond the vertebral body . Renal size may be increased, decreased, or normal depending on the severity and chronicity of the obstruction.

Trisomy 13

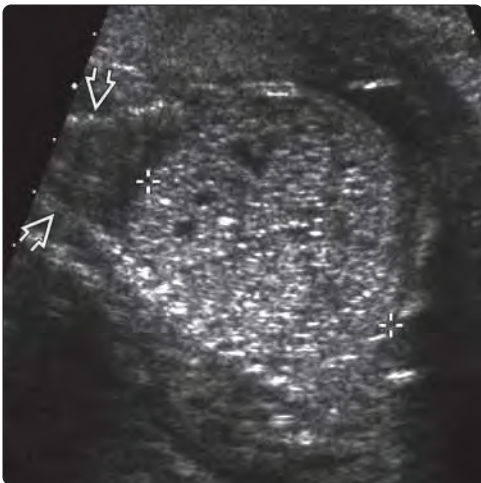


Trisomy 13

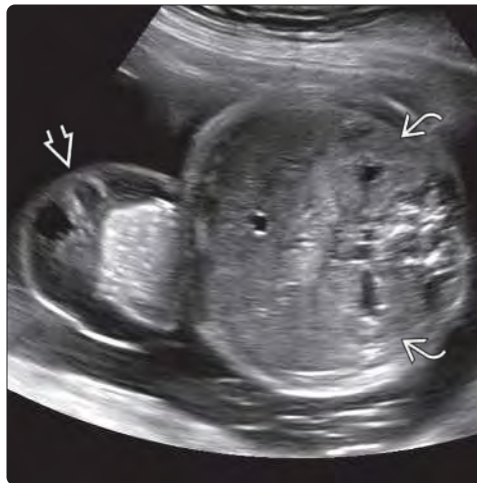





(Left) Sagittal US of a 2nd-trimester fetus with trisomy 13 shows an enlarged, echogenic kidney . Cystic dysplasia is seen in approximately 1/2 of all trisomy 13 cases and can be seen at the time of the nuchal translucency exam. (Right) Axial US of the brain in the same fetus shows semilobar holoprosencephaly with differentiation of occipital lobes  and ventricular communication across the midline  anteriorly. Other findings included polydactyly and hypotelorism.

Meckel-Gruber Syndrome



Beckwith-Wiedemann Syndrome



(Left) Sagittal US shows a massively enlarged, echogenic kidney (calipers) with a few scattered macroscopic cysts. There is a small, bell-shaped chest  and severe oligohydramnios. This fetus also had an encephalocele and polydactyly. (Right) This macrosomic fetus shows classic features of BWS, including an omphalocele  and large, mildly echogenic kidneys  (> 95 percentile for gestational age). Often the renal morphology and echogenicity is preserved, despite the large size. Fluid is usually normal.

DIFFERENTIAL DIAGNOSIS

Common

- Developmental Anomalies
 - Duplicated Collecting System
 - Unilateral Renal Agenesis With Compensatory Hypertrophy
 - Crossed-Fused Ectopia

Less Common

- Mesoblastic Nephroma
- Asymmetric Involvement of Bilateral Process
 - Beckwith-Wiedemann Syndrome
 - Meckel-Gruber Syndrome
 - Autosomal Recessive Polycystic Kidney Disease

Rare but Important

- Renal Vein Thrombosis

ESSENTIAL INFORMATION

Key Differential Diagnosis Issues

- Many causes of renal enlargement are secondary to developmental anomalies
 - Examine location and size of both kidneys carefully
 - Although abnormal in configuration, echogenicity is normal
 - Document appearance and position of adrenal glands
 - When kidney is missing or in ectopic location, adrenal gland lies within renal fossa
 - No longer has tricorn hat configuration
 - May have globular or lying-down appearance
- Systemic conditions that affect both kidneys may be asymmetric, particularly earlier in gestation
 - Kidneys often have increased echogenicity and may have cysts
- If large solid retroperitoneal mass is seen, determine if it is renal or adrenal in origin
 - Renal → mesoblastic nephroma
 - Adrenal → neuroblastoma
- Consider renal vein thrombosis if previously normal kidney abruptly increases in size

Helpful Clues for Common Diagnoses

- **Duplicated Collecting System**
 - Upper and lower pole moieties separated by band of renal parenchyma
 - Larger than contralateral kidney (unless both are duplicated)
 - 2 separate ureters drain upper and lower poles
 - Upper pole drained by ectopic ureter with ureterocele in bladder
 - Prone to obstruct; may see dilated ureter going to upper pole of kidney
 - Large ureterocele may be confused with bladder
 - Lower pole drained by normotopic ureter
 - Prone to reflux; less likely to see dilated ureter
- **Unilateral Renal Agenesis With Compensatory Hypertrophy**
 - Diagnosis of exclusion
 - Must exclude asymmetric horseshoe kidney, pelvic kidney, and crossed ectopic kidney

- Pitfalls in diagnosis
 - Adrenal gland
 - Globular shape and position in renal fossa can mimic kidney
 - Colon in empty renal fossa may also mimic kidney, especially in 3rd trimester
- Compensatory hypertrophy of remaining kidney in up to 90% of cases
 - Seen as early as 20 weeks
- **Crossed-Fused Ectopia**
 - Unilateral empty renal fossa
 - Ectopic kidney frequently malrotated
 - 90% of crossed renal ectopic kidneys fused with other kidney
 - Remainder unfused in various configurations
 - Ureter crosses midline to insert normally at bladder
 - Look for hypoechoic medullary pyramids to identify ectopic renal parenchyma

Helpful Clues for Less Common Diagnoses

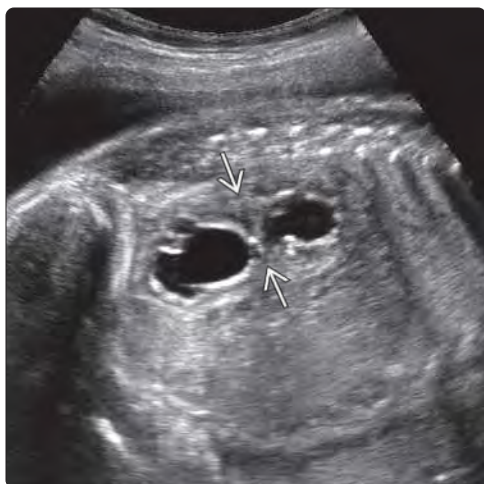- **Mesoblastic Nephroma**
 - Benign mesenchymal renal tumor
 - Large, solid renal mass; often with no normal remaining parenchyma
 - Exerts significant mass effect on surrounding structures
 - Abdominal circumference often enlarged
 - May rarely have cystic area
 - Use color Doppler looking for renal artery
 - Best performed in coronal plane
 - Polyhydramnios in ~ 70%, often severe
 - Can develop hydrops
- **Beckwith-Wiedemann Syndrome**
 - 3 hallmark findings: Macrosomia, macroglossia, and omphalocele
 - Kidneys frequently involved
 - Renal size enlarged but often normal echogenicity and morphology
- **Meckel-Gruber Syndrome**
 - Renal cystic dysplasia, encephalocele, postaxial polydactyl
 - Renal cystic dysplasia most consistent finding, present in 95-100%
 - Renal involvement has variable appearance but often severe
 - Grossly enlarged, echogenic kidneys most common
 - May have macroscopic cysts
 - Oligohydramnios common and often severe
- **Autosomal Recessive Polycystic Kidney Disease**
 - Large, echogenic kidneys
 - Renal enlargement may not occur until mid-2nd trimester but is frequently progressive
 - Asymmetric involvement not uncommon
 - Normal cortex may be preserved
 - Look for thin hypoechoic rim around echogenic medulla
 - Kidneys are diffusely hyperechoic and often massively enlarged in severe disease
 - Oligohydramnios frequent at this stage

Helpful Clues for Rare Diagnoses

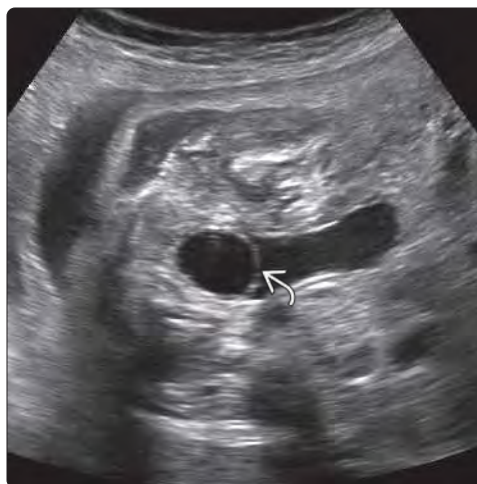• Renal Vein Thrombosis

- Obstruction of main or peripheral renal veins by thrombus
 - This is acute event; normal scan early in pregnancy supports diagnosis
 - Acute findings
 - Enlarged, echogenic kidney
 - May have prominent medullary pyramids
 - Linear echogenic medullary striations along interlobular veins
 - Look with color/pulsed wave Doppler for normal artery and venous waveforms
 - May be difficult in fetus
 - Compare to normal side
 - Can present with fetal distress, necessitating delivery
 - Chronic findings
 - Renal size decreases and may become atrophic, depending on chronicity and degree of recovery
 - Loss of normal echogenicity
- Linear and lace-like calcifications
 - Most cases occur in 3rd trimester or perinatal period
 - Risk factors
 - Maternal factors present in 60% of cases
 - Thrombophilia and prothrombotic factors (e.g., factor V Leiden thrombophilia)
 - Diabetes
 - Hypertension
 - Acute medical conditions (e.g., pyelonephritis)
 - In perinatal period asphyxia, dehydration, and sepsis/infection all implicated
 - Presentation at birth
 - Classic findings include flank mass, hematuria, and thrombocytopenia
 - Proteinuria, hypertension and renal dysfunction may also be present
 - All require postnatal evaluation
 - Ultrasound for morphology and blood flow
 - Nuclear medicine renal scan for function
 - Irreversible damage present in 70%

Duplicated Collecting System

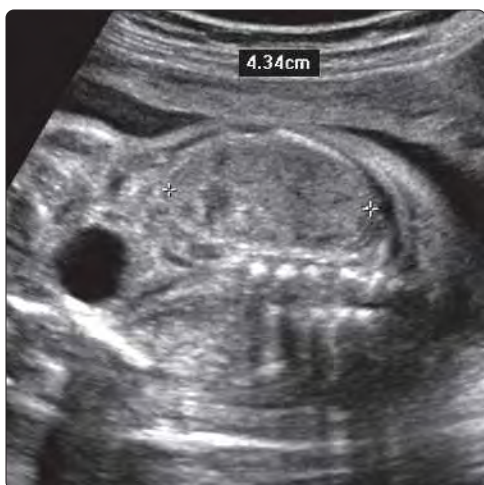


Duplicated Collecting System

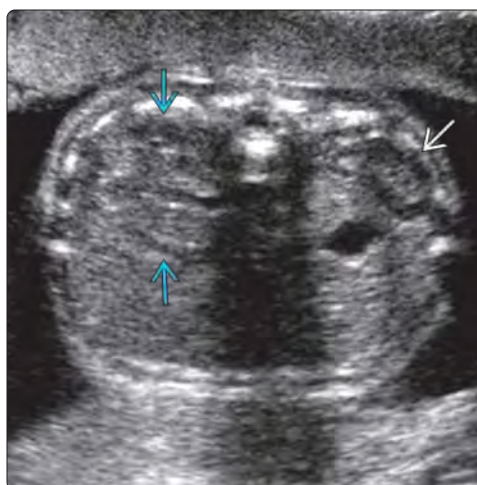


(Left) This midtrimester fetus has a unilaterally enlarged kidney with renal pelvis dilation. What is important to note is there are actually 2 renal pelves separated by a band of normal parenchyma. **(Right)** Whenever a renal duplication anomaly is suspected, be sure to carefully inspect the bladder. In this coronal view of the same fetus a ureterocele is seen. When the bladder is decompressed, a large ureterocele may be mistaken for the bladder and missed.

Unilateral Renal Agenesis With Compensatory Hypertrophy




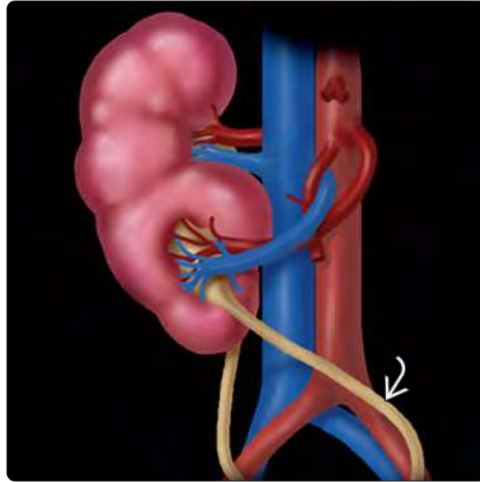
Unilateral Renal Agenesis With Compensatory Hypertrophy



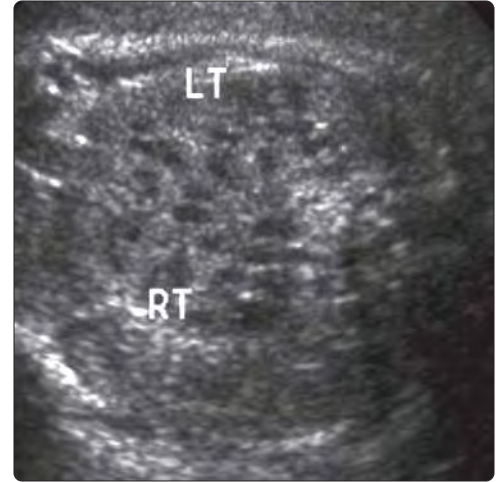
(Left) Coronal view of the right kidney in a fetus with left renal agenesis shows compensatory hypertrophy (calipers), measuring > 95th percentile for 26-weeks gestation. **(Right)** In a different fetus with unilateral renal agenesis there is an enlarged kidney in the right renal fossa. Note the prominent and somewhat globular appearance of the adrenal gland in the left renal fossa. This should not be mistaken for a kidney.

Crossed-Fused Ectopia





(Left) This graphic shows crossed-fused renal ectopia with the left kidney attached to the lower pole of the right. Note the ureter  crosses back across midline to insert into the bladder in its normal position. (Right) This oblique axial image shows the right kidney located across the midline and fused with the left. The presence of hypoechoic renal pyramids helps identify this as a kidney. The appearance overlaps with an asymmetric horseshoe kidney.

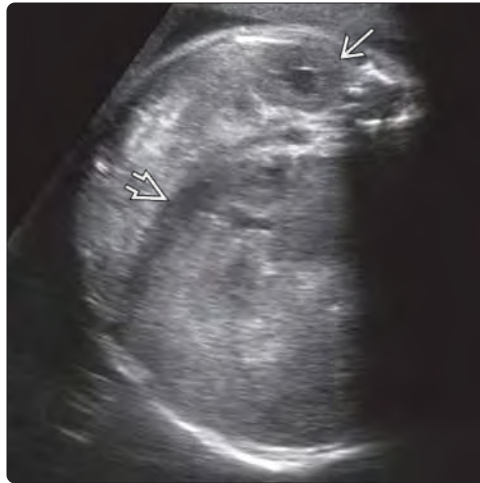

Crossed-Fused Ectopia

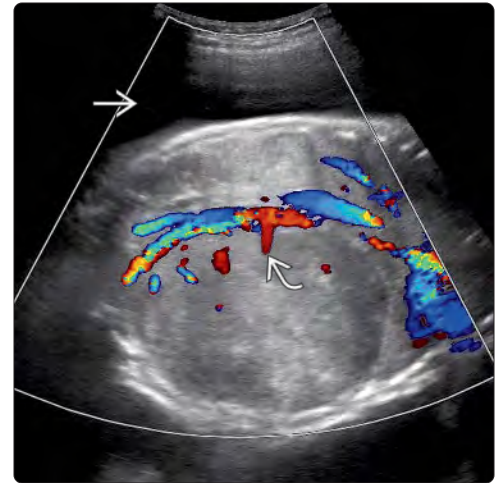


Mesoblastic Nephroma



(Left) This 3rd-trimester fetus presented with a large, solid abdominal mass, which crosses the midline  and enlarged the abdominal circumference. A normal right kidney  is present but the left kidney was not seen. A left adrenal gland was documented, making a neuroblastoma unlikely. (Right) The same case viewed in the coronal plane with color Doppler shows the renal artery  supplying this large mesoblastic nephroma. There is also significant polyhydramnios , a common associated finding.

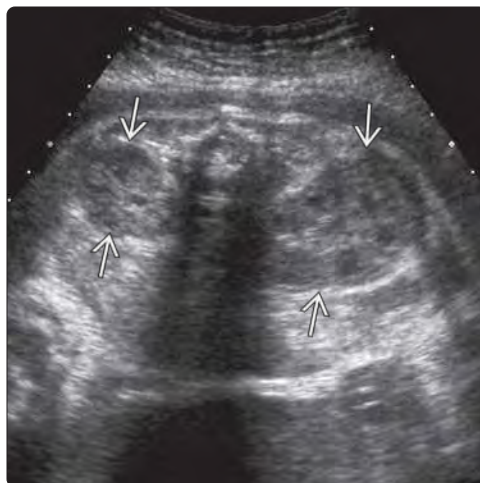


Mesoblastic Nephroma

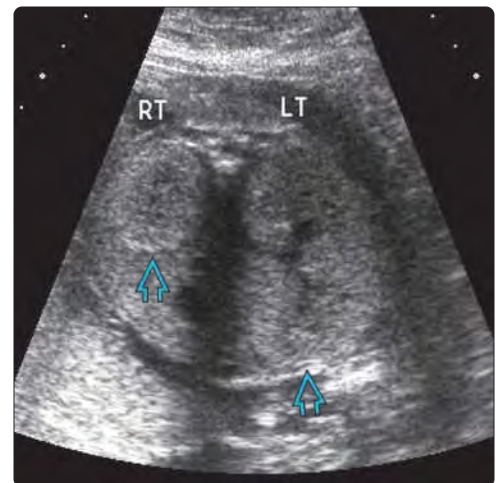


Beckwith-Wiedemann Syndrome

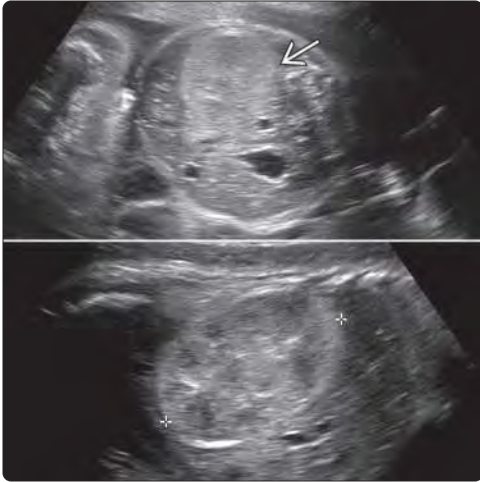
(Left) Axial image shows asymmetric renal enlargement  in this fetus with Beckwith-Wiedemann syndrome. Note that renal echogenicity and contour are preserved. Systemic diseases that affect both kidneys may be asymmetric. This fetus also had macrosomia and macroglossia. (Right) This midtrimester fetus with ARPKD has bilateral abnormally echogenic kidneys , but note the left is much larger than the right. It is not uncommon to see asymmetric involvement, particularly earlier in gestation.



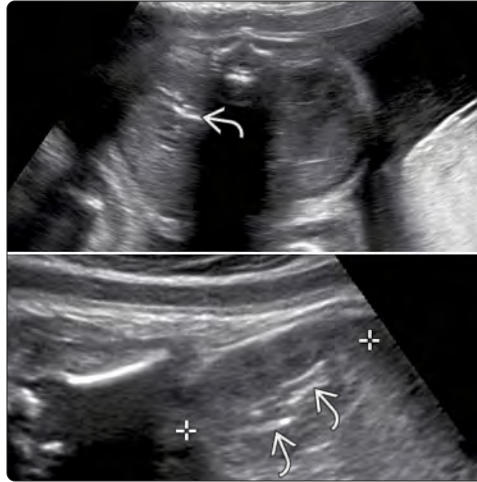
Autosomal Recessive Polycystic Kidney Disease



Renal Vein Thrombosis

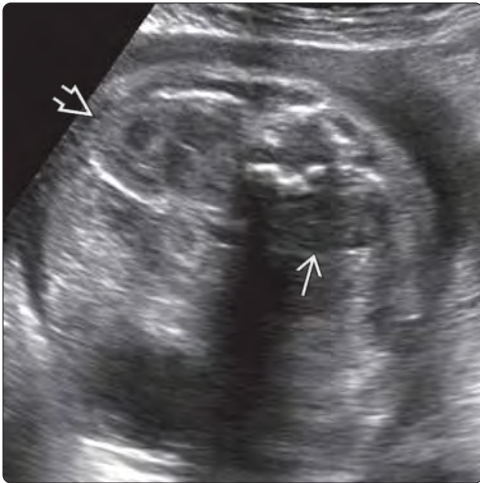


Renal Vein Thrombosis

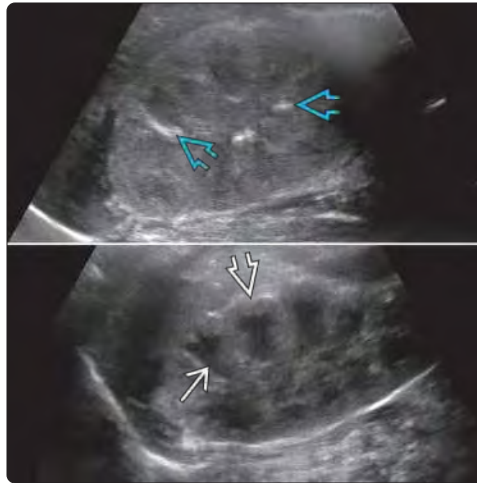


(Left) This fetus was referred for a solid abdominal mass at 30 weeks (upper). There had been a normal 2nd-trimester anatomy scan. The longitudinal view (lower) clearly shows it is an enlarged echogenic kidney (calipers). **(Right)** A follow-up scan 3 weeks later shows the kidney has decreased in size and echogenicity and there are now prominent linear striations following interlobular veins. This case is a classic example of the change in appearance over time with a renal vein thrombosis.

Renal Vein Thrombosis

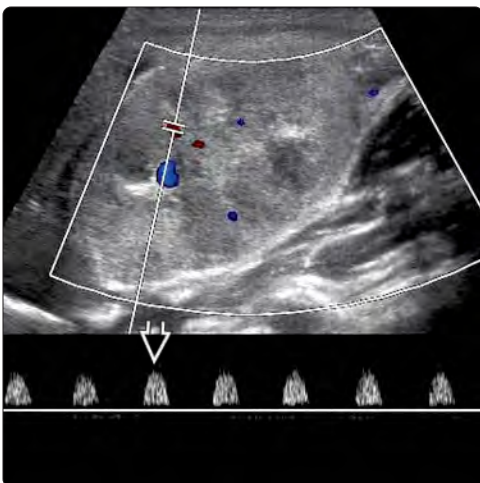


Renal Vein Thrombosis

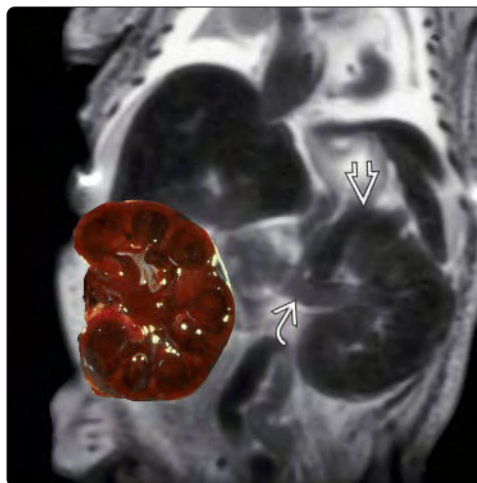


(Left) This is an unusual case of bilateral renal vein thrombosis, of different ages, in a fetus with factor V Leiden thrombophilia. The left kidney is small and atrophic, while the right is large and echogenic. The fetus was in marked distress and was delivered. **(Right)** A postnatal scan, in the same case, shows cortical atrophy on the left with markedly hypoechoic pyramids. Linear striations are seen within the enlarged right kidney.

Renal Vein Thrombosis



Renal Vein Thrombosis



(Left) This pulsed Doppler waveform of an arcuate artery of the right kidney, in the same case, is typical of renal vein thrombosis with very high intrarenal resistance. There is a delayed systolic peak and no diastolic flow. No venous flow was present. **(Right)** This is a composite image of a postmortem MR and the kidney from the autopsy in a case of 3rd-trimester fetal demise. The MR shows a large, uniformly hypointense left kidney with thrombus in the left renal vein. The gross specimen confirms hemorrhagic infarction.

DIFFERENTIAL DIAGNOSIS

Common

- Bronchopulmonary Sequestration (Extralobar)
- Neuroblastoma

Less Common

- Congenital Adrenal Hyperplasia
- Renal Duplicated Collecting System (With Obstruction)
- Gastric Duplication Cyst

Rare but Important

- Adrenal Hemorrhage

ESSENTIAL INFORMATION

Key Differential Diagnosis Issues

- Search for adrenal gland separate from mass
 - Neuroblastoma, congenital adrenal hyperplasia, and adrenal hemorrhage originate from adrenal gland
 - Normal adrenal gland
 - Layered hypoechoic cortex and hyperechoic medulla = ice cream sandwich sign
 - Normal gland with 3 limbs
- Assess mass effect on surrounding structures
 - Try to identify organ of origin
- Assess mass vascularity

Helpful Clues for Common Diagnoses

- **Bronchopulmonary Sequestration (Extralobar)**
 - 10-15% subdiaphragmatic
 - Majority are left sided
 - Displace stomach
 - Typically echogenic, solid mass
 - May see small cystic areas or cystic variant
 - Separate from adrenal gland
 - Color Doppler important for diagnosis
 - Look for dominant feeding vessel from aorta
 - Systemic supply from celiac axis is variant
 - Usually presents in 2nd trimester
- **Neuroblastoma**

- 90% arise from adrenal gland
- Variable appearance: Solid, cystic, mixed
 - Cystic masses are usually complex, with thick septations
- No identifiable adrenal gland on side of mass
 - However, 10% are extraadrenal
- Color Doppler may show diffuse vascularity
 - No dominant feeding vessel
- Prognosis is excellent
 - > 90% survival for fetal neuroblastoma
- Large, solid, and vascular masses associated with
 - Hydrops
 - Metastasis: Liver most common site

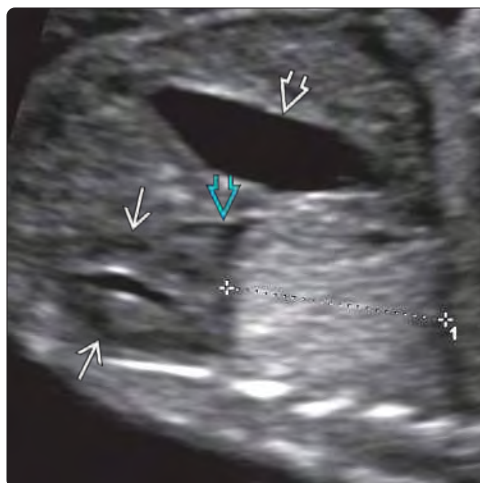
Helpful Clues for Less Common Diagnoses

- **Congenital Adrenal Hyperplasia**
 - > 90% due to 21-hydroxylase deficiency
 - Hypoechoic enlarged glands lose triangular shape
 - Bilateral symmetric or asymmetric morphology seen
 - Female fetuses may have virilization
 - Ambiguous genitalia from clitoromegaly
 - Antenatal treatment with dexamethasone is controversial
- **Renal Duplicated Collecting System (With Obstruction)**
 - Upper moiety obstructed because of ectopic ureterocele
 - Look in bladder for fluid-filled ureterocele
 - Postobstructive cystic dysplasia may occur
 - Mimics complex cystic mass
- **Gastric Duplication Cyst**
 - Look for mass effect on stomach
 - Bowel signature difficult to see in fetus

Helpful Clues for Rare Diagnoses

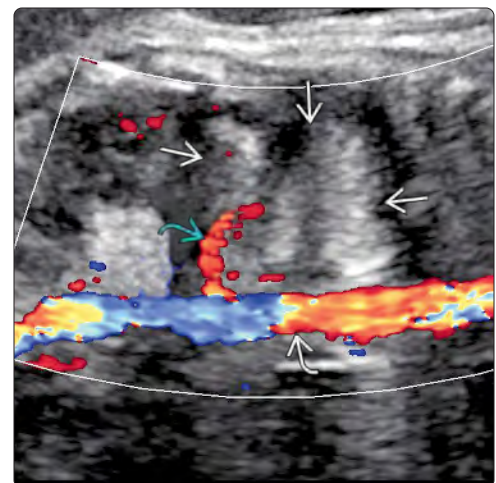
- **Adrenal Hemorrhage**
 - Rarely seen in utero
 - Variable appearance with evolution of blood products
 - No color flow within mass
 - MR can confirm blood products

Bronchopulmonary Sequestration (Extralobar)

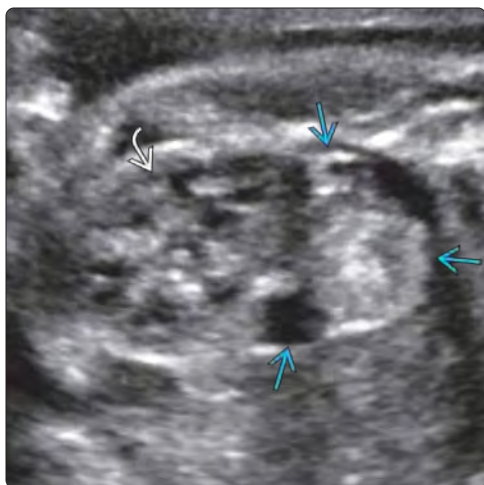


(Left) A suprarenal echogenic mass (calipers) is seen separate from an intact tri-limbed adrenal gland and superior to the left kidney. The stomach is displaced anteriorly. (Right) Coronal view of the aorta and mass in the same patient shows a large feeding vessel arising from the aorta. The hallmark findings of a mass separate from the adrenal gland and supplied by a dominant feeding vessel suggest the diagnosis of bronchopulmonary sequestration, rather than neuroblastoma.

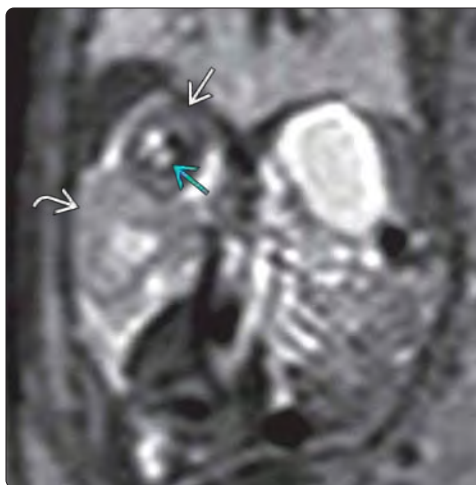Bronchopulmonary Sequestration (Extralobar)



Neuroblastoma

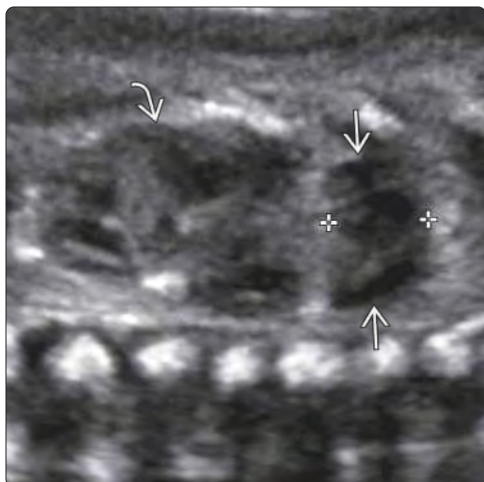


Neuroblastoma

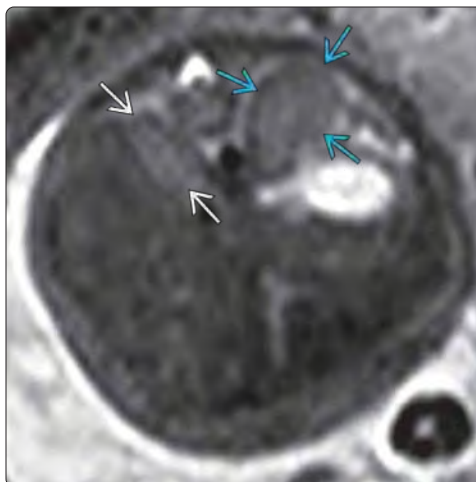


(Left) A complex mass with internal solid and cystic areas is seen superior to the kidney. A separate adrenal gland was not seen. (Right) Coronal T2 MR shows the mass with the internal cysts superior to the right kidney, and confirmed absence of a separate adrenal gland. While homogeneously solid neuroblastomas are more likely high signal on T2 imaging, most neuroblastomas are heterogeneous masses with variable echogenicity and signal intensity.

Congenital Adrenal Hyperplasia

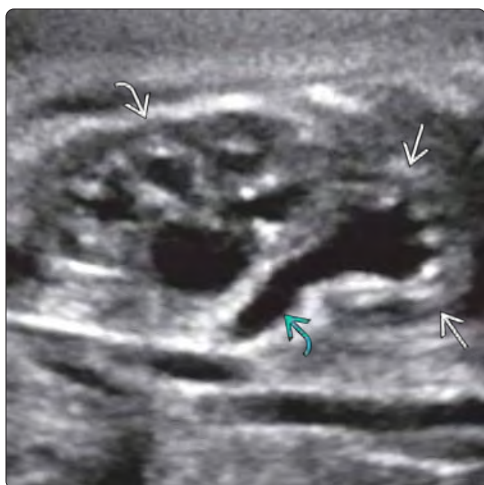


Congenital Adrenal Hyperplasia

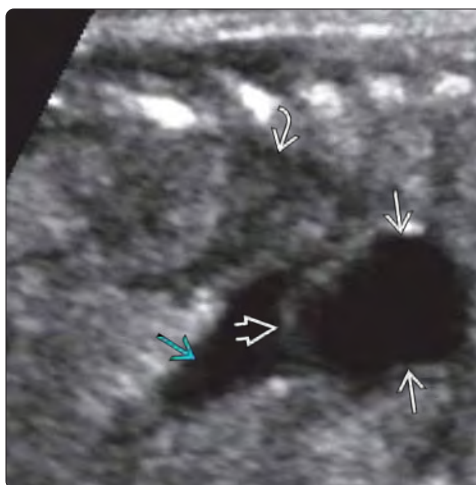


(Left) The adrenal gland, superior to the left kidney, is globular & enlarged. It has lost its normal tricorn morphology. Less severe findings were seen in the right adrenal gland in this female fetus with ambiguous-appearing genitalia from virilization (disorder of sexual development). (Right) Axial MR in the same fetus shows the enlarged left adrenal gland has the same signal characteristics as the less enlarged right adrenal gland. Adrenal enlargement associated with CAH can be asymmetric.

Renal Duplicated Collecting System (With Obstruction)



Gastric Duplication Cyst



(Left) A "mass" superior to the kidney is actually an obstructed small upper moiety of a duplicated kidney. The associated dilated ureter is a clue for the diagnosis. An ectopic ureterocele in the bladder is a hallmark finding as well. (Right) A unilocular cyst is seen superior to the left adrenal gland, and its inferior wall indents the fluid-filled stomach. These findings identify the stomach as the organ of origin for this suprarenal mass.

DIFFERENTIAL DIAGNOSIS

Common

- Hydrocele

Less Common

- Testicular Torsion
- Inguinal Hernia

Rare but Important

- Teratoma

ESSENTIAL INFORMATION

Helpful Clues for Common Diagnoses

- **Hydrocele**
 - **Simple hydrocele**
 - Anechoic fluid
 - Fluid forms half-moon crescent around testis
 - Testes are normal
 - Large hydrocele may displace testis
 - May be isolated or part of generalized hydrops
 - 2/3 unilateral, 1/3 bilateral
 - Present in 15% of male fetuses > 27 weeks
 - Usually transient finding with most resolved by birth
 - Surgical treatment needed in < 3% of cases
 - **Complex hydrocele**
 - Fluid with linear/focal echoes
 - Suggests secondary process: Testicular infarction/torsion, meconium from bowel perforation
 - May see calcification if secondary to meconium peritonitis

Helpful Clues for Less Common Diagnoses

- **Testicular Torsion**
 - Testis may be either large (acute) or small (chronic)
 - Variable echogenicity
 - Diffusely hypoechoic from edema
 - Heterogeneous from infarction
 - Scrotal edema

- Complex hydrocele from hemorrhage or inflammatory reaction
- Double-ring hemorrhage variant: Hemorrhage trapped in 2 spaces
 - Between visceral and parietal tunica vaginalis
 - Between tunica vaginalis and scrotum
- Doppler rarely helpful, unless obvious flow in normal testis
- Testis is rarely salvaged when torsion diagnosed in utero
 - Emergent delivery not indicated for suspected cases
- **Inguinal Hernia**
 - Bowel herniates through inguinal canal
 - Cystic/echogenic mass in scrotum
 - Hydrocele common and aids in diagnosis
 - Look for normal testis adjacent to mass
 - Peristalsis is pathognomonic but not always present
 - More commonly present after delivery rather than in utero
 - Increased abdominal pressure from crying, bowel movements, etc.

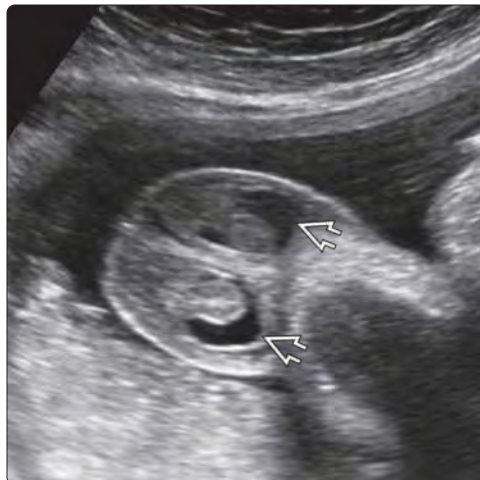
Helpful Clues for Rare Diagnoses

- **Teratoma**
 - Mixed cystic and solid scrotal mass replacing normal testis
 - Calcifications most specific finding but often not present
 - May present as abdominal mass in undescended testis

Other Essential Information

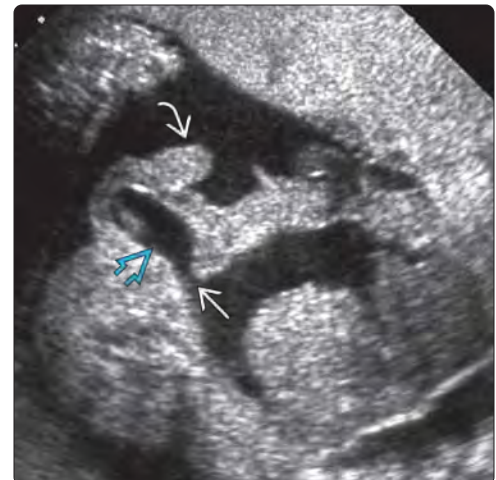
- Normal testicular descent at 25-32 weeks
- Processus vaginalis forms from evagination of peritoneal cavity and aids in descent of testis
 - Normally obliterates and becomes tunica vaginalis
 - Hydrocele forms if persistent patent processus vaginalis or fluid not resorbed
 - Patent processus vaginalis also risk factor for inguinal hernia
- Always consider torsion in setting of complex hydrocele

Hydrocele

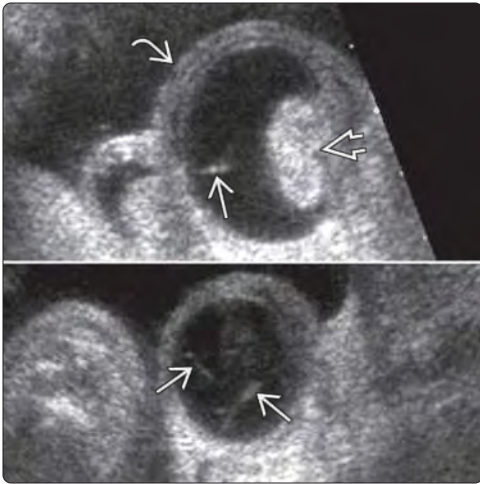


(Left) Oblique axial image through the scrotum in a 3rd-trimester fetus shows small simple hydroceles. They are anechoic and form a crescent around the testes. When small, they are of no clinical significance and generally resolve by birth. (Right) Sagittal ultrasound of the scrotum in a hydroptic fetus shows a hydrocele resulting from ascites extending through a patent processus vaginalis (penis).

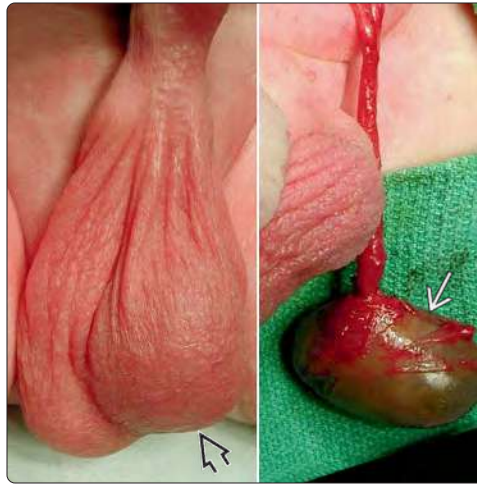Hydrocele



Testicular Torsion

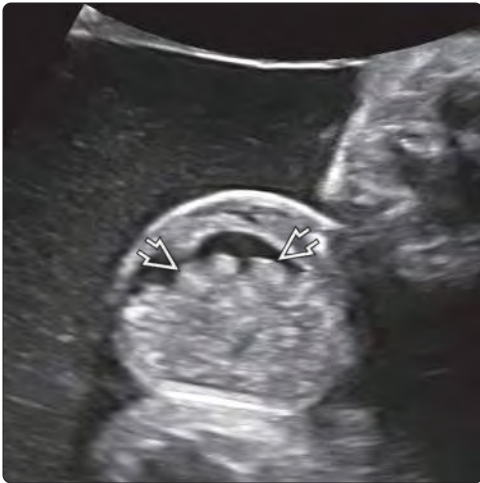


Testicular Torsion

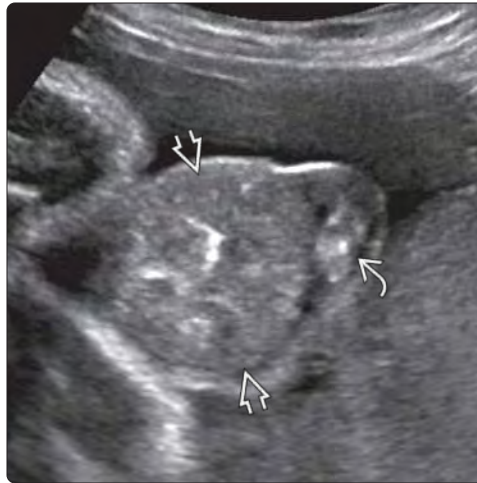

(Left) A composite image of testicular torsion shows an enlarged left hemiscrotum with a heterogeneously echogenic testis and scrotal skin thickening. The associated hydrocele is large and complex with linear septations. (Right) On physical exam, the left hemiscrotum was enlarged and somewhat dusky in appearance, as well as firm to palpation. The intraoperative photograph shows the infarcted testis. The testis is rarely salvaged when torsion occurs in utero and early delivery is not indicated.

Inguinal Hernia

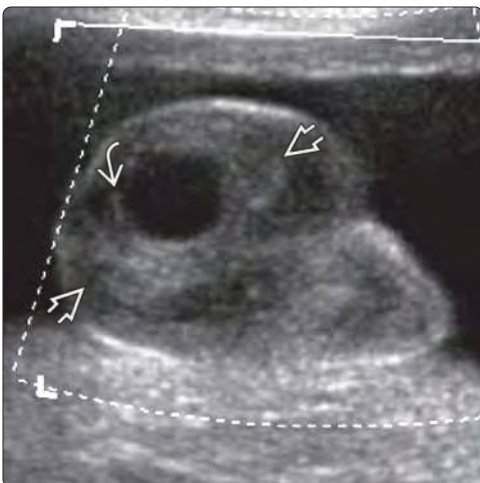


Inguinal Hernia

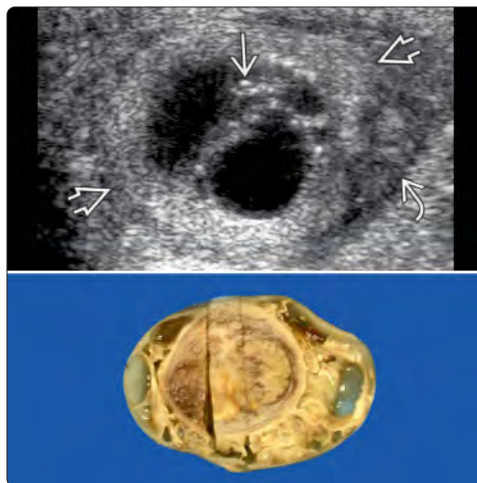


(Left) Ultrasound in a 3rd-trimester fetus shows a large scrotal mass. There is an associated hydrocele that is outlining multiple distinct bowel loops. Hernias occur when the bowel extends into the scrotum through the inguinal canal via a patent processus vaginalis. (Right) The herniated loops are meconium filled and appear more mass-like. One of the keys to the diagnosis is finding the testis separate from the mass. It is important to watch carefully during the real-time exam, as peristalsis is pathognomonic for a hernia.

Teratoma



Teratoma

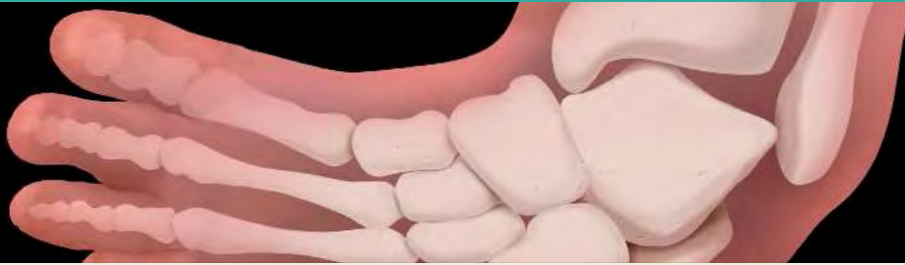

(Left) Image of the scrotum in a 3rd-trimester fetus shows a complex mass with both solid and cystic components. At least 1 septation was seen. (Right) A scan after delivery shows the complex mass. Scattered punctate calcifications are seen, which could not be resolved on the prenatal scan. Only a small crescent of normal testis remains. This mass was surgically resected and was a teratoma, which was essentially replacing the testis. Although rare, teratoma is the most common scrotal tumor.

This page intentionally left blank

SECTION 9

Musculoskeletal



Dysplasias

Approach to Skeletal Dysplasias	680
Bone Length Charts	686
Achondrogenesis, Hypochondrogenesis	688
Achondroplasia	694
Amelia/Phocomelia	698
Atelosteogenesis	702
Campomelic Dysplasia	706
Chondrodysplasia Punctata	710
Hypophosphatasia	714
Osteogenesis Imperfecta	718
Short Rib-Polydactyly Syndromes	722
Thanatophoric Dysplasia	726

Extremity Malformations

Clubfoot	732
Rocker-Bottom Foot	736
Sandal Gap Foot	738
Radial Ray Malformation	740
Clinodactyly	744
Polydactyly	746
Syndactyly	750
Split Hand/Foot Malformation	754
Arthrogryposis, Akinesia Sequence	758
Proximal Focal Femoral Dysplasia	764
Fibular/Tibial Hemimelia	768

Pertinent Differential Diagnoses

Mildly Short Femur/Humerus	770
Angulated Bones	774
Abnormal Ossification	780

Introduction

Several hundred different types of disorders with significant skeletal involvement are known, only a fraction of which can be reliably diagnosed prenatally. The skeletal dysplasias are a heterogeneous group of relatively rare conditions involving generalized abnormal bone growth. The prevalence of skeletal dysplasias is estimated to be approximately 2.4 per 10,000 births. Due to high perinatal mortality, the overall prevalence in perinatal deaths is much higher at 9 per 1,000. As with all prenatal diagnoses, the recognition of abnormal skeletal development is essential, although not always evident at the time that most screening ultrasounds are done. Some features, especially milder findings associated with nonlethal conditions, may only become obvious in the 3rd trimester.

Once abnormal development is suspected, this should be followed by a determination of the severity of the disorder. In other words, is the condition lethal or not? This single determination will dramatically change the approach to the rest of the pregnancy. The timing, mode, and location of the delivery will necessarily hinge on this important information. Is pregnancy termination an option for the couple? What about resuscitative measures at the time of delivery? With regard to any condition, the accuracy of the counseling provided to a family is dependent upon the accuracy of the diagnosis. With the skeletal dysplasias and related skeletal disorders, a precise prenatal diagnosis is often not possible. However, the determination of **lethality vs. nonlethality** can provide a basis of approach to the diagnosis. A multidisciplinary approach to the prenatal diagnosis of complex fetal abnormalities, including skeletal dysplasias, is highly recommended.

The Nosology Group of the International Skeletal Dysplasia Society is charged with the classification of hundreds of distinct skeletal disorders. Multiple revisions of the classification schema have been published since the original work in 1970, which relied primarily upon clinical, radiographic, and pathologic features. With the rapid evolution of molecular genetics, causative genes are known for about half of the **approximately 400 known disorders**; in some ways, this has increased the complexity of classification. In 2006, 372 different conditions with significant skeletal involvement were divided into **37 groups based on molecular, biochemical, &/or radiographic features**. Included were the skeletal dysplasias as well as metabolic bone disorders, dysostoses, and skeletal malformation or reduction syndromes. Whenever possible, this information has been included in descriptions of the individual disorders in this text. The most recent revision of the Nosology is scheduled for publication in the near future.

Approach to Skeletal Dysplasias

As with imaging of any fetal structures, solid knowledge of what is normal variation vs. abnormal is critical. A systematic and thorough evaluation of the fetus following established guidelines is essential. However, guidelines represent the minimal requirements for evaluation, and when dealing with complex conditions such as skeletal dysplasias, one must go beyond the minimal. When shortened long bones are suspected, all the long bones (bilateral) should be measured and compared to published standards (see table below). The calipers should be placed at the ends of the diaphyses, knowing that measurements may be problematic if significant curvature is present. Other skeletal elements that should be measured include the calvarium (biparietal diameter and

circumference), chest, and abdominal circumferences. Measurement of foot, scapular, and clavicular lengths is also recommended. Calculation of various ratios may assist in the diagnosis of a skeletal dysplasia, as well as determination of lethality. Pulmonary hypoplasia is common, especially in lethal skeletal dysplasias, and may be suggested by several means.

Are the Bones Short?

Evaluation of a possible skeletal dysplasia begins with evaluating the long bones. Sometimes bones that look short are not, and an evaluation may actually exclude a skeletal dysplasia. A helpful ratio is the femur:foot length, which is 1:1. A ratio less than 1:1 is suggestive of a skeletal dysplasia. Observation of the parents is often helpful in determining whether short stature is constitutional or pathologic. The same consideration is useful, for example, in determining whether a large or small head is familial. Long bones that are less than the 5th percentile but still within 2-3 standard deviations of the mean have a good likelihood of being either a normal variation or a nonlethal skeletal dysplasia. On the other hand, long bones that are 4+ standard deviations below the mean for gestation are likely to be associated with a skeletal dysplasia. Severe shortening is usually seen in lethal disorders.

If Short, What Segments Are Involved?

Proximal shortening (humerus, femur) is **rhizomelia**, whereas **mesomelia** is shortening of the middle segment of the limb (radius/ulna or tibia/fibula). **Acromelia** refers to small hands &/or feet, and **micromelia** refers to all segments being shortened. Involvement of different segments may help lead to a particular classification. Micromelia is more common in the more severe, often lethal, skeletal dysplasias.

Is the Bone Morphology Normal?

The long bones should be evaluated with respect to their shape. Are they curved or angulated? Crumpled appearing or fractured? Are the metaphyses broad or irregular? Does the ossification appear normal? The finding of underossification with fractures is an important distinction that may lead to a diagnosis, most commonly one of osteogenesis imperfecta. Defective ossification may also be seen in hypophosphatasia and achondrogenesis.

How Early in Gestation Was a Skeletal Abnormality Found?

Severe limb shortening in the 1st or 2nd trimester is very likely to be a skeletal dysplasia, frequently lethal, whereas 3rd-trimester, mild long-bone shortening may be either familial, a normal variation, or associated with growth restriction of the fetus. In addition, nonlethal skeletal dysplasias such as achondroplasia may be suspected when mild long-bone shortening is found on ultrasound in the latter part of pregnancy.

Is the Spine Normal?

Platyspondyly (i.e., flattening of the vertebral bodies with increased space between the vertebrae) is best observed on a sagittal view of the spine, but may be difficult to assess by ultrasound early in gestation. Abnormal curvature of the spine, such as lumbar **kyphosis or scoliosis**, may also be seen in many skeletal dysplasias. What about the distal spine? If missing or hypoplastic, **caudal dysplasia** may be present, with diabetic embryopathy included in the differential diagnosis. Is the spine normally ossified? Achondrogenesis is commonly associated with (often severe) underossification of the spine.

Key Measurements

Femur length:foot length ratio	< 1 suggests skeletal dysplasia
Femur length:abdominal circumference ratio	< 0.16 suggests lethality
Chest circumference:abdominal circumference ratio	< 0.8 suggests lethality

Is the Calvarium Unusually Shaped?

Abnormalities of the skull are very common in the skeletal dysplasias. **Craniosynostosis** of varied sutures may be found in many skeletal dysplasias and often explains the abnormal skull shapes. However, not all cases of craniosynostosis are skeletal dysplasias. They may be associated with other genetic syndromes or constitute isolated abnormalities. Complex craniosynostosis may result in a **kleblattschädel** (i.e., cloverleaf skull), which is common in type II thanatophoric dysplasia as well as some other nonskeletal syndromes, such as Pfeiffer syndrome. In severe skeletal dysplasias, the calvarium may be large or appear disproportionately large for the rest of the fetal body. Deficient ossification of the skull may be seen in osteogenesis imperfecta, hypophosphatasia, and achondrogenesis. Evaluation of the **fetal profile** from a sagittal view is often abnormal in skeletal dysplasias. Several features are common but relatively nonspecific, such as midface hypoplasia, depressed nasal bridge, frontal bossing, small nose, and micrognathia.

Is the Chest Small?

Abnormalities in the contour of the fetal chest and abdomen are commonly seen in skeletal dysplasias and are best appreciated in either coronal or sagittal views of the body of the fetus. There may be the appearance of a "shelf" where the smaller chest connects to the larger, protuberant appearing abdomen. This difference may be striking, especially in the more lethal conditions, and it predicts a high risk of pulmonary hypoplasia. The **ribs** are also evaluated when looking at the chest. If very short, the chest will be small; this is more commonly seen in lethal skeletal dysplasias. Fractures of the ribs may appear as displaced bone or as "beading" due to callus formation. Rib fractures are found in lethal type II osteogenesis imperfecta as well as in type IA achondrogenesis. A cardiothoracic ratio is often abnormal as the normal-sized heart appears to fill the fetal chest. The shape of the chest should also be evaluated. A bell-shaped chest is seen in several types skeletal dysplasia and is usually associated with a small chest. A long and very narrow chest with straight ribs may also be associated with pulmonary hypoplasia in conditions such as the short rib-polydactyly syndromes.

Are the Hands and Feet Normal?

Short digits, or **brachydactyly**, are very common in skeletal dysplasias. The great toe or thumbs may be broad or deviated. **Polydactyly** (extra digits) and **syndactyly** (fused digits) are less common, but will provide clues regarding possible diagnoses. Clubfeet may also be seen as early as the 1st trimester. Other postural abnormalities of the extremities may be seen, such as joint contractures and radial club hands due to radial ray deficiency. An ulnar deviated thumb, the so-called hitchhiker thumb, is associated with the allelic disorders diastrophic dysplasia and type II atelosteogenesis.

What About Other Skeletal Abnormalities?

Often overlooked, the **scapula** is an important structure to assess in cases of suspected campomelic dysplasia, where it is

usually hypoplastic or apparently absent. Likewise, the **clavicles** may be hypoplastic or absent in cleidocranial dysplasia.

Are There Any Other Structural Anomalies?

Although the predominant feature in most skeletal dysplasias is abnormal bone development, other associated anomalies such as orofacial clefts, cardiac defects, or genitourinary abnormalities may provide important clues regarding diagnostic possibilities. Increased nuchal translucency in the 1st trimester is a nonspecific finding seen in many skeletal dysplasias. Cystic hygromas or frank hydrops may also be seen in some conditions, such as achondrogenesis.

When Is Other Imaging Helpful?

Surface rendering by 3D ultrasound may help delineate phenotypic features useful in identification of specific syndromes; it may also help in counseling families. Additionally, it may prove useful in evaluating the fetal pelvis, which is abnormal in many cases of skeletal dysplasia and not easily evaluated by 2D ultrasound. 3D ultrasound may also further delineate extremity and spine abnormalities. Echocardiography in cases with suspected cardiac defects is also indicated. Fetal MR is not as useful in the evaluation of bone abnormalities, but may be used in cases with suspected visceral abnormalities.

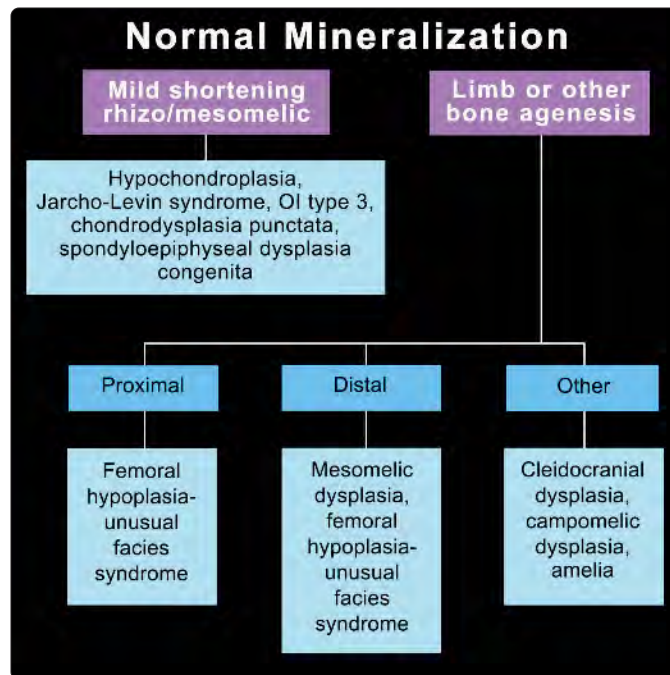
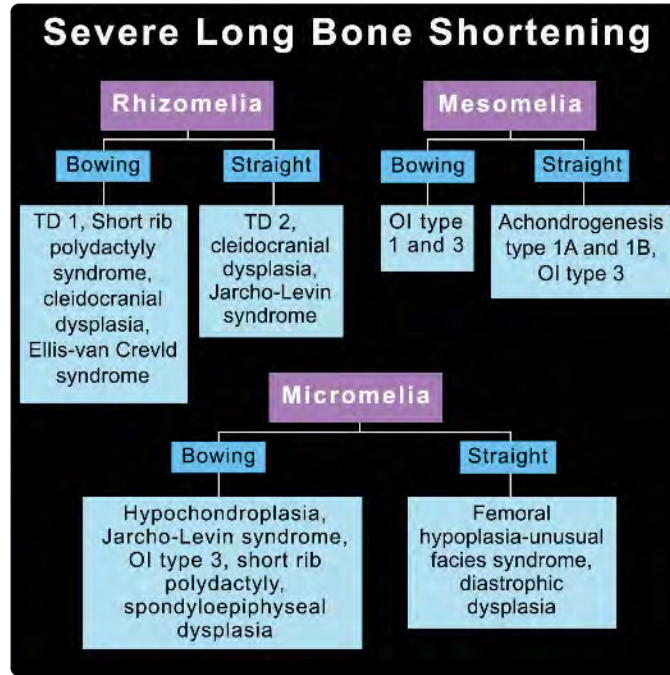
Clinical Implications

Lethal or Not?

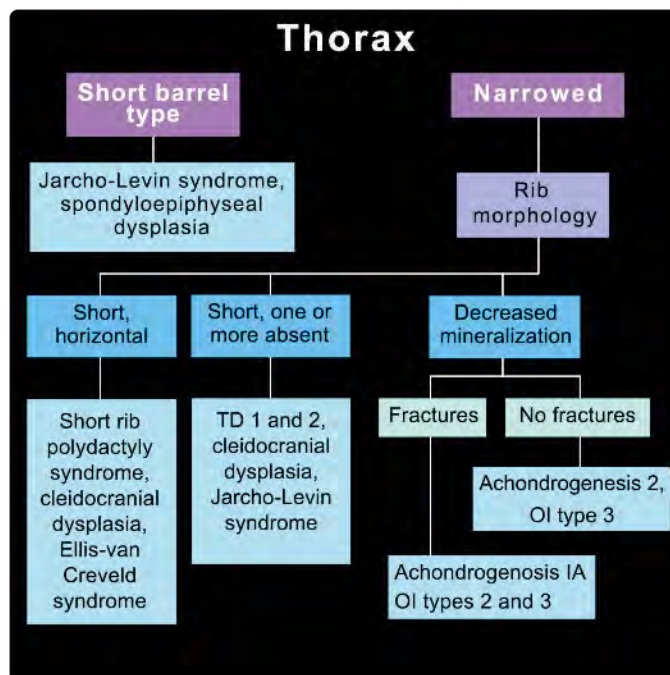
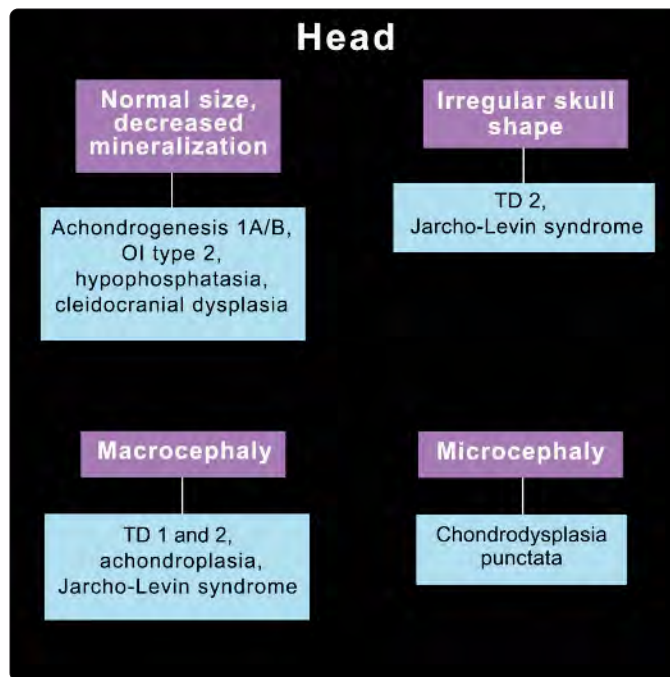
The delineation of the severity of a skeletal dysplasia is one of the most important diagnostic concerns. Whether a condition is lethal or not will determine the approach to counseling of the family, as well as guide any potential testing. Options of pregnancy management given a confirmed lethal skeletal dysplasia may include pregnancy termination, avoidance of operative delivery, and comfort care only at the time of delivery. **Features that increase the suspicion of lethality** include early-onset severe limb shortening, small chest with short ribs, marked bowing or fractures, hydrops, or cloverleaf skull. A femur length:abdominal circumference ratio less than 0.16 is also highly suggestive of a lethal disorder.

Prenatal Diagnosis

Prenatal diagnosis of skeletal dysplasias, many of which have overlapping features, is very challenging. Prenatal molecular testing is available for a select number of conditions. Specific sonographic features should be used to determine what testing may be appropriate. Postnatal evaluation is essential to confirm the diagnosis of a skeletal dysplasia in order to provide the most accurate recurrence risk information to a family. Minimal evaluation should include radiography, photographs, and examination by a clinical geneticist. In cases of demise, postmortem examination is highly recommended, preferably by an experienced perinatal pathologist.

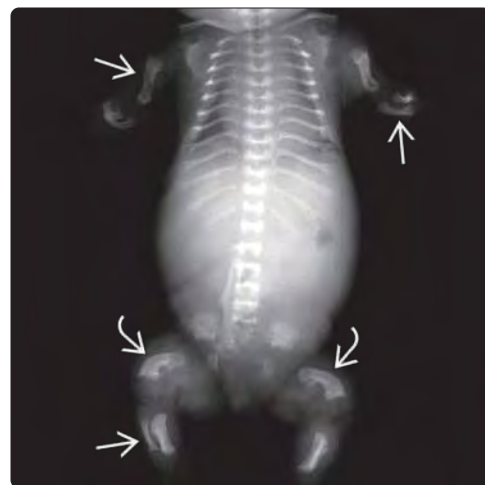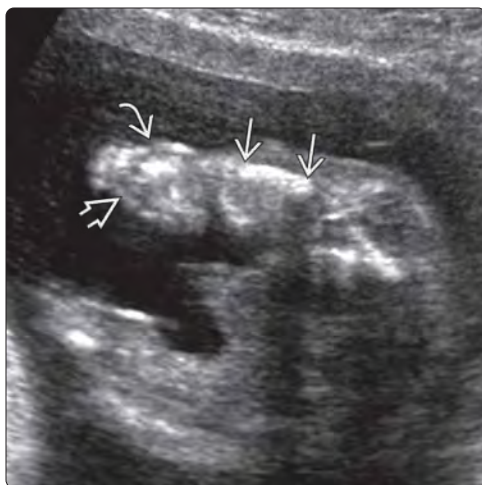


(Top) This flowchart illustrates an algorithm for the evaluation of fetuses with severe limb shortening and normal or mildly deficient mineralization. Abbreviations: TD = thanatophoric dysplasia; OI = osteogenesis imperfecta. **(Bottom)** This flowchart illustrates an algorithm for the evaluation of fetuses with mild limb shortening, normal or near normal mineralization, and an approach to fetuses with absence or severe hypoplasia of limbs or other bones (cleidocranial dysplasia - clavicles; campomelic dysplasia - scapulae). Adapted from: Dighe M et al: Fetal skeletal dysplasia: an approach to diagnosis with illustrative cases. *Radiographics*. 28(4):1061-77, 2008.

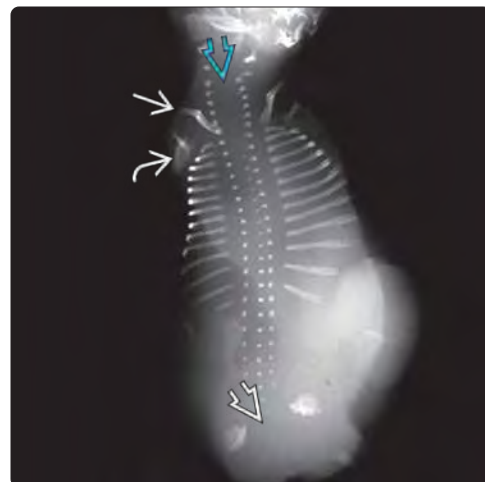
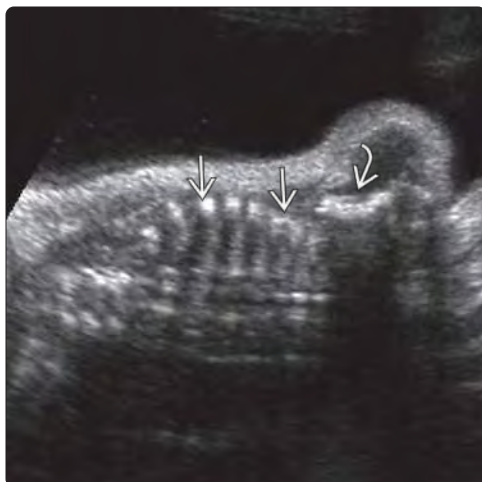


(Top) Evaluating the head shape, size, and degree of mineralization is important in formulating a differential diagnosis. This flowchart illustrates an algorithm for the evaluation of fetuses with abnormal size or shape of the calvarium. **(Bottom)** This flowchart illustrates an algorithm for the evaluation of fetuses with severe thoracic abnormalities, including those with rib abnormalities. Adapted from: Dighe M et al: Fetal skeletal dysplasia: an approach to diagnosis with illustrative cases. *Radiographics*. 28(4):1061-77, 2008.

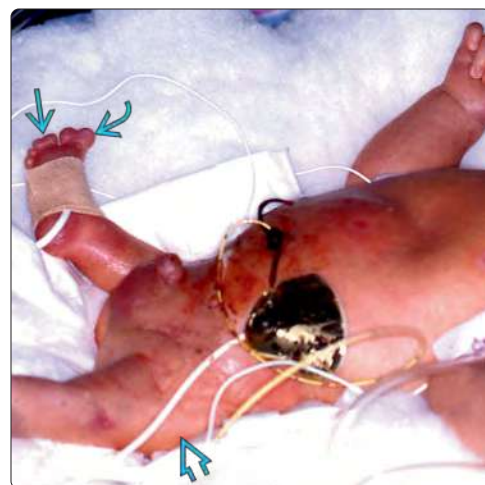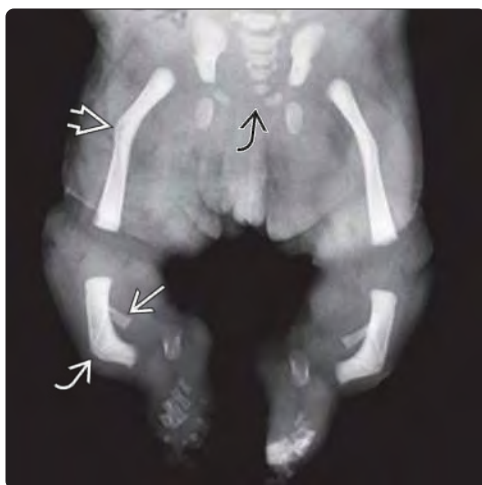(Left) Ultrasound of the lower extremities of a fetus with achondrogenesis illustrates several features of a lethal skeletal dysplasia, including severe micromelia and abnormal foot posture. Extremity edema, which is common in this condition, is also noted. **(Right)** Radiograph of a stillborn infant with type I TD showing severe micromelia of all 4 limbs. The so-called telephone receiver femur is a classic feature in type I TD. The femur in type II TD is also very short, but tends to be straighter.

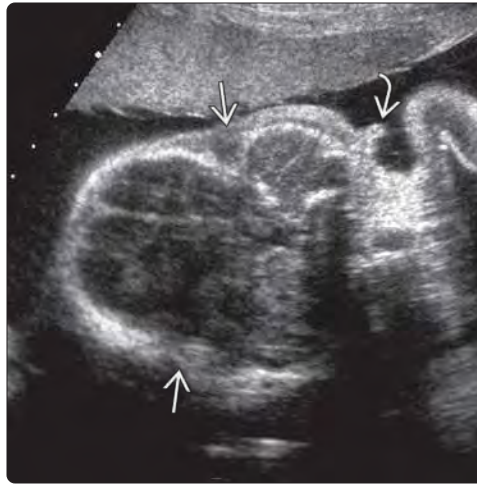
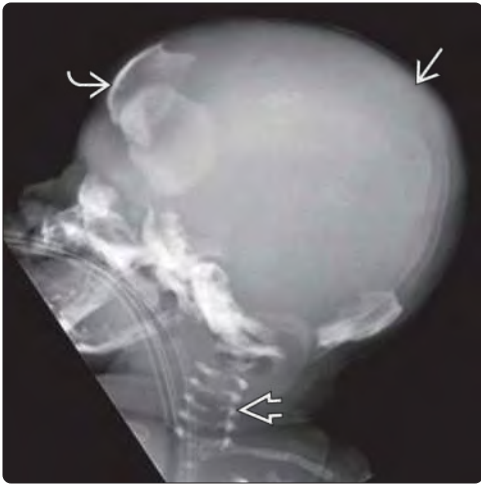






(Left) Ultrasound of a fetus at 29 weeks with hypochondrogenesis shows a normal scapula and a small chest with straight ribs. The skeletal features of hypochondroplasia are similar to, but less severe than in achondrogenesis type II, and the clinical distinction is often difficult. **(Right)** Radiograph shows a stillborn fetus with tetra-amelia. The abnormal clavicles and hypoplastic scapulae are the only residual structures of the shoulder girdle. The pelvis is severely hypoplastic, and the spine is poorly mineralized.

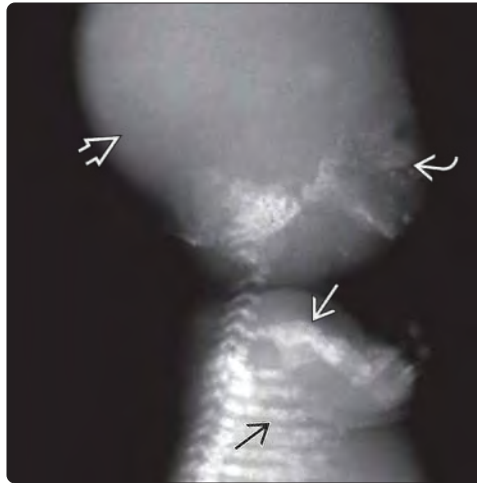
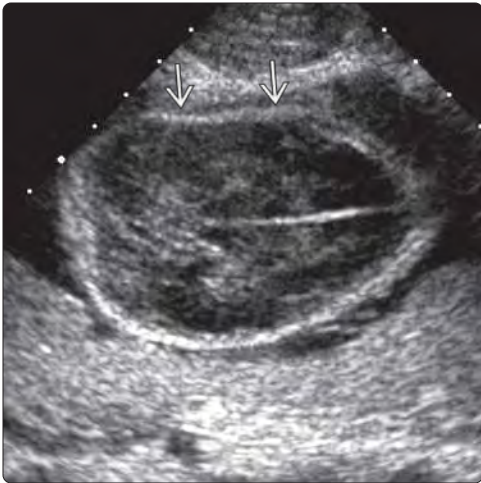







(Left) Term infant with campomelic dysplasia illustrates classic findings, including bowed femora, severely angulated tibiae, and hypoplastic fibulae and pelvis. **(Right)** Photograph shows a newborn infant with femoral hypoplasia-unusual facies syndrome. The infant was born to a mother with poorly controlled diabetes. Both femora are hypoplastic, although asymmetrical. The pelvis and lower spine were also abnormal. Preaxial polydactyly and toe syndactyly are noted.

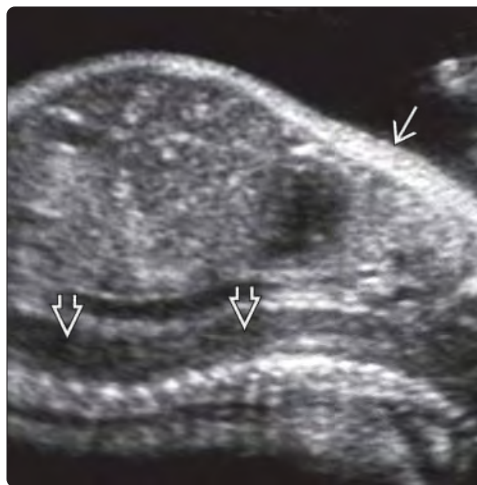
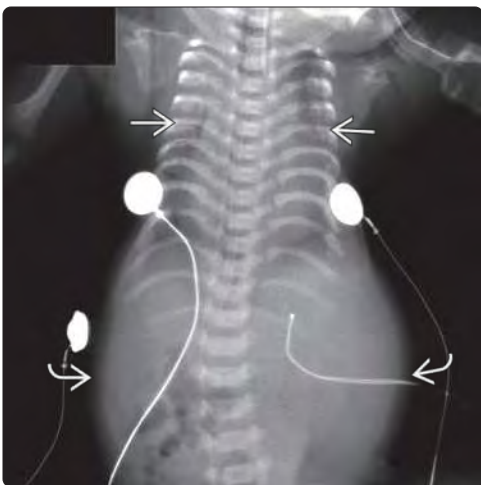






(Left) Radiograph of a newborn with perinatal lethal hypophosphatasia illustrates severe undermineralization of the membranous calvarium . The calvarium was soft and deformable to light palpation. The basal skull and frontal bones are the only ossified bones  in the skull. Note the thin, poorly mineralized cervical vertebrae . (Right) Ultrasound illustrates typical features of a cloverleaf  or kleeblattschädel skull. This abnormality is seen in type II thanatophoric dysplasia. Note the low-set ear .



(Left) Axial ultrasound of a 3rd-trimester fetus with osteogenesis imperfecta shows significant underossification of the calvarium manifested by depression of the skull  with normal pressure from the ultrasound transducer. (Right) Radiograph of a stillborn infant with perinatal lethal osteogenesis imperfecta shows a diffusely undemineralized skeleton. Note the undemineralized skull  and facial bones . Rib fractures  and crumpled long bones of the arm  are also seen.



(Left) Postmortem AP radiograph shows the very abnormal chest in Jeune asphyxiating thoracic dystrophy, one of the short rib-polydactyly syndromes. Note the small chest with short horizontal ribs  and protuberant abdomen . (Right) Sagittal ultrasound of a 3rd-trimester fetus with achondrogenesis shows a very small chest , as well as the classic finding of absent spine ossification .

Bone Length Charts

Lower Extremity Long Bones

GA wk	Femur				Tibia				Fibula			
	5th %	50th %	95th %	SD	5th %	50th %	95th %	SD	5th %	50th %	95th %	SD
15	1.26	1.68	2.10	0.26	1.06	1.46	1.86	0.24	1.06	1.46	1.86	0.24
16	1.54	1.97	2.39	0.26	1.31	1.71	2.12	0.25	1.33	1.74	2.14	0.25
17	1.83	2.25	2.68	0.26	1.56	1.97	2.38	0.25	1.61	2.01	2.42	0.25
18	2.11	2.54	2.97	0.26	1.82	2.23	2.64	0.25	1.87	2.28	2.69	0.25
19	2.39	2.82	3.26	0.26	2.08	2.49	2.90	0.25	2.13	2.54	2.95	0.25
20	2.67	3.10	3.54	0.27	2.33	2.75	3.16	0.25	2.38	2.79	3.20	0.25
21	2.94	3.38	3.82	0.27	2.58	3.00	3.42	0.25	2.62	3.03	3.45	0.25
22	3.21	3.65	4.09	0.27	2.83	3.25	3.67	0.25	2.85	3.27	3.69	0.25
23	3.47	3.92	4.36	0.27	3.07	3.49	3.91	0.26	3.08	3.50	3.92	0.26
24	3.74	4.18	4.63	0.27	3.31	3.73	4.16	0.26	3.30	3.72	4.15	0.26
25	3.99	4.44	4.89	0.27	3.54	3.97	4.39	0.26	3.51	3.94	4.36	0.26
26	4.24	4.69	5.14	0.27	3.76	4.19	4.62	0.26	3.72	4.15	4.57	0.26
27	4.49	4.94	5.39	0.28	3.98	4.41	4.84	0.26	3.92	4.35	4.78	0.26
28	4.73	5.18	5.64	0.28	4.19	4.62	5.05	0.26	4.11	4.54	4.97	0.26
29	4.96	5.42	5.87	0.28	4.39	4.82	5.26	0.26	4.29	4.72	5.16	0.26
30	5.18	5.64	6.10	0.28	4.58	5.01	5.45	0.27	4.47	4.90	5.34	0.27
31	5.40	5.86	6.32	0.28	4.76	5.20	5.64	0.27	4.63	5.07	5.51	0.27
32	5.61	6.07	6.54	0.28	4.94	5.38	5.82	0.27	4.79	5.24	5.68	0.27
33	5.81	6.27	6.74	0.28	5.11	5.55	6.00	0.27	4.95	5.39	5.84	0.27
34	6.00	6.47	6.94	0.29	5.27	5.72	6.16	0.27	5.09	5.54	5.99	0.27
35	6.18	6.65	7.12	0.29	5.42	5.87	6.32	0.27	5.23	5.68	6.13	0.27
36	6.35	6.83	7.30	0.29	5.58	6.03	6.48	0.28	5.36	5.82	6.27	0.28
37	6.51	6.99	7.47	0.29	5.72	6.18	6.63	0.28	5.49	5.94	6.40	0.28
38	6.66	7.14	7.62	0.29	5.87	6.32	6.78	0.28	5.60	6.06	6.52	0.28

Upper Extremity Long Bones

GA wk	Humerus				Radius				Ulna			
	5th %	50th %	95th %	SD	5th %	50th %	95th %	SD	5th %	50th %	95th %	SD
15	1.31	1.69	2.07	0.23	1.05	1.45	1.85	0.24	1.14	1.54	1.94	0.24
16	1.58	1.97	2.35	0.23	1.29	1.69	2.09	0.24	1.41	1.81	2.21	0.24
17	1.85	2.24	2.63	0.24	1.52	1.93	2.33	0.25	1.67	2.08	2.48	0.25
18	2.12	2.51	2.90	0.24	1.75	2.15	2.56	0.25	1.93	2.33	2.74	0.25
19	2.38	2.77	3.16	0.24	1.97	2.38	2.79	0.25	2.18	2.58	2.99	0.25
20	2.63	3.03	3.42	0.24	2.18	2.59	3.00	0.25	2.42	2.83	3.24	0.25
21	2.88	3.28	3.67	0.24	2.39	2.80	3.22	0.25	2.65	3.06	3.48	0.25
22	3.12	3.52	3.92	0.24	2.59	3.01	3.42	0.25	2.87	3.29	3.71	0.25
23	3.35	3.75	4.16	0.24	2.79	3.20	3.62	0.25	3.09	3.51	3.93	0.25
24	3.57	3.98	4.38	0.25	2.97	3.40	3.82	0.26	3.30	3.72	4.15	0.26
25	3.79	4.19	4.60	0.25	3.16	3.58	4.00	0.26	3.51	3.93	4.35	0.26
26	3.99	4.40	4.81	0.25	3.33	3.76	4.19	0.26	3.70	4.13	4.56	0.26
27	4.19	4.60	5.01	0.25	3.50	3.93	4.36	0.26	3.89	4.32	4.5	0.26
28	4.37	4.79	5.20	0.25	3.67	4.10	4.53	0.26	4.07	4.50	4.93	0.26
29	4.55	4.97	5.39	0.25	3.83	4.26	4.69	0.26	4.25	4.68	5.1	0.26
30	4.72	5.14	5.56	0.26	3.98	4.41	4.85	0.27	4.41	4.85	5.28	0.27
31	4.89	5.31	5.73	0.26	4.12	4.56	5.00	0.27	4.57	5.01	5.45	0.27

Upper Extremity Long Bones (Continued)

	Humerus				Radius				Ulna			
32	5.04	5.47	5.89	0.26	4.26	4.70	5.14	0.27	4.72	5.16	5.61	0.27
33	5.20	5.62	6.05	0.26	4.40	4.84	5.28	0.27	4.87	5.31	5.75	0.27
34	5.34	5.77	6.20	0.26	4.52	4.97	5.41	0.27	5.00	5.45	5.90	0.27
35	5.48	5.92	6.35	0.26	4.64	5.09	5.54	0.27	5.13	5.58	6.03	0.27
36	5.62	6.06	6.49	0.26	4.76	5.21	5.66	0.27	5.26	5.71	6.16	0.27
37	5.76	6.20	6.64	0.27	4.87	5.32	5.77	0.28	5.37	5.82	6.28	0.28
38	5.90	6.34	6.78	0.27	4.97	5.42	5.88	0.28	5.48	5.93	6.39	0.28

All measurements in cm. Data adapted from: Exacoustos C et al: Ultrasound measurements of fetal limb bones. *Ultrasound Obstet Gynecol.* 1(5):325-30, 1991; Merz E et al: Mathematical modeling of fetal limb growth. *J Clin Ultrasound.* 17(3):179-85, 1989; Jeanty P et al: A longitudinal study of fetal limb growth. *Am J Perinatol.* 1(2):136-44, 1984.

Other Important Measurements

GA wk	Scapula			Thoracic Circumference			Clavicle		
	-2 SD	Mean	+2 SD	5th %	50th %	95th %	5th %	50th %	95th %
16	0.8	1.2	1.6	6.4	9.1	11.9	1.39	1.54	1.69
17	0.9	1.3	1.7	7.3	10.0	12.8	1.57	1.73	1.90
18	1.0	1.4	1.8	8.2	11.0	13.7	1.74	1.92	2.10
19	1.1	1.5	1.9	9.1	11.9	14.6	1.91	2.10	2.29
20	1.2	1.6	2.0	10.0	12.8	15.5	2.06	2.27	2.47
21	1.3	1.7	2.1	11.0	13.7	16.4	2.21	2.43	2.65
22	1.4	1.8	2.2	11.9	14.6	17.3	2.34	2.58	2.81
23	1.5	1.9	2.3	12.8	15.5	18.2	2.48	2.72	2.97
24	1.6	2.0	2.4	13.7	16.4	19.1	2.60	2.86	3.12
25	1.6	2.1	2.5	14.6	17.3	20.0	2.72	3.00	3.27
26	1.7	2.2	2.6	15.5	18.2	21.0	2.84	3.12	3.41
27	1.8	2.3	2.7	16.4	19.1	21.9	2.95	3.25	3.55
28	1.9	2.4	2.8	17.3	20.0	22.8	3.05	3.37	3.68
29	2.0	2.4	2.8	18.2	21.0	23.7	3.15	3.48	3.81
30	2.1	2.5	3.0	19.1	21.9	24.6	3.25	3.59	3.93
31	2.2	2.6	3.1	20.0	22.8	25.5	3.34	3.70	4.06
32	2.3	2.7	3.1	20.9	23.7	26.4	3.43	3.80	4.17
33	2.4	2.8	3.2	21.8	24.6	27.3	3.52	3.90	4.29
34	2.5	2.9	3.3	22.8	25.5	28.2	3.60	4.00	4.40
35	2.6	3.0	3.4	23.7	26.4	29.1	3.68	4.10	4.51
36	2.7	3.1	3.5	24.6	27.3	30.0	3.76	4.19	4.61
37	2.8	3.2	3.6	25.5	28.2	30.9	3.84	4.28	4.72
38	2.9	3.3	3.7	26.4	29.1	31.9	3.91	4.37	4.82
39	3.0	3.4	3.8	27.3	30.0	32.8	3.98	4.45	4.92
40	3.1	3.5	3.9	28.2	30.9	33.7	4.05	4.53	5.01

All measurements in cm. Scapula data adapted from: Shere DM, Plessinger MA, Allen TA. Fetal scapular length in the ultrasound assessment of gestational age. *J Ultrasound Med* 13:523-28, 1994. Thoracic circumference data adapted from: Chitkara et al: *AM J Ob Gyn* 156:1069, 1072, 1987. Clavicle length data adapted from: Sherer DM et al: Fetal clavicle length throughout gestation: a nomogram. *Ultrasound Obstet Gynecol.* 27(3):306-10, 2006.

KEY FACTS

TERMINOLOGY

- Group of lethal osteochondrodysplasias due to failure of cartilaginous matrix formation
- Achondrogenesis has 3 main subtypes based on clinical features

IMAGING

- All types characterized by severe micromelia, deficient spine ossification, short trunk, and disproportionately large head
- Type IA achondrogenesis most severely affected
 - Poorly ossified skull
 - Completely unossified spine
 - Short ribs with multiple fractures
- Type IB achondrogenesis
 - Poorly ossified skull
 - Posterior pedicles of spine may be ossified
 - No rib fractures
- Type II achondrogenesis

- Normal skull ossification
- Poorly ossified spine
- Hypochondrogenesis
 - Normal skull ossification
 - Better ossification of vertebral bodies

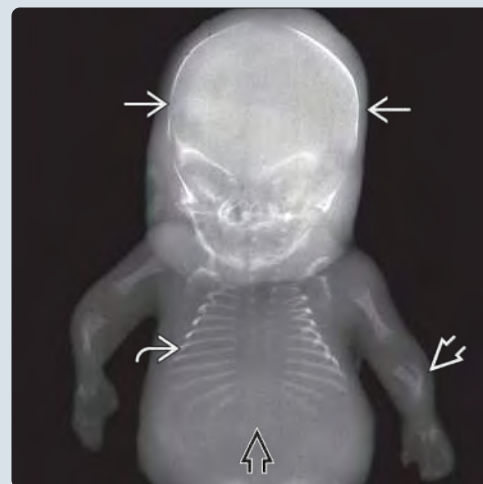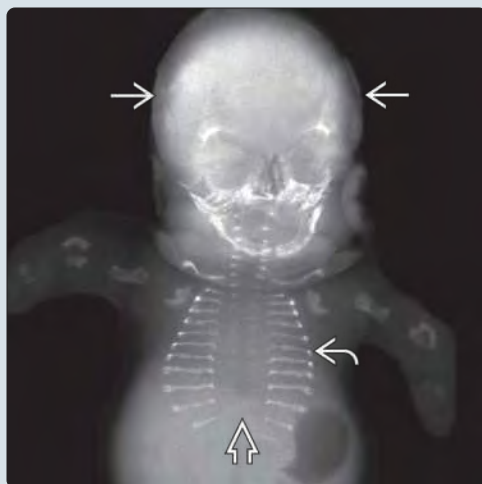TOP DIFFERENTIAL DIAGNOSES

- Hypophosphatasia
- Osteogenesis imperfecta
- Atelosteogenesis II
- Short rib-polydactyly syndrome

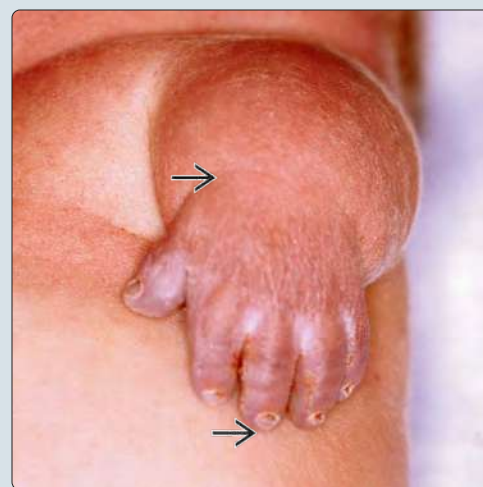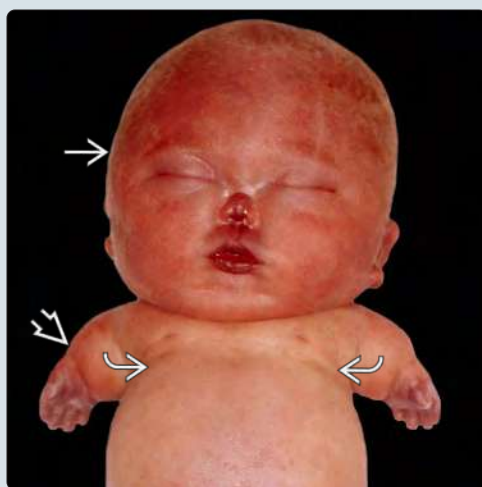PATHOLOGY

- Types IA and IB: Autosomal recessive
 - Type IA: Molecular basis not known
 - Type IB: Mutations in diastrophic dysplasia sulfate transporter gene [*SLC26A2* (DTDST)]
- Type II and hypochondrogenesis: Autosomal dominant
 - Mutations in type II collagen gene *COL2A1*

(Left) Radiograph shows poor skull ossification and thin, wavy ribs secondary to multiple fractures in a case of type IA achondrogenesis. Lack of spine ossification is apparent and is the most characteristic finding in achondrogenesis, both on prenatal ultrasound and postnatal radiography. **(Right)** Radiograph shows a well-ossified calvarium with lack of spine ossification in a case of type II achondrogenesis. Note the absence of rib fractures. Curved radii and ulnae are also seen.



(Left) Clinical photograph of a preterm stillborn infant with type II achondrogenesis shows the disproportionately large head and short neck. The midface is very flat with a small nose and mouth. Severe micromelia is seen. The chest is very small. The soft tissues, especially of the face, are edematous, evidence of in utero hydrops that is common in this condition. **(Right)** Note the extreme micromelia in the arm of the same infant with type II achondrogenesis. The hand is as large as the entire distal segment of the arm.



TERMINOLOGY

Definitions

- Group of lethal osteochondrodysplasias due to failure of cartilaginous matrix formation
 - Characterized by severe micromelia, unossified spine, short trunk, and disproportionately large head
- 3 main subtypes based on clinical features
 - Type IA achondrogenesis (Houston-Harris)
 - Type IB achondrogenesis (Fraccaro)
 - Type II achondrogenesis (Langer-Saldino)
- Hypochondrogenesis
 - Allelic disorder similar to achondrogenesis type II

IMAGING

General Features

- **Type IA achondrogenesis**
 - Most severely affected
 - Poorly ossified skull
 - Completely unossified spine
 - Short ribs with multiple fractures
 - Proximal femora with metaphyseal spikes
 - Arched ileum with hypoplastic ischium
- **Type IB achondrogenesis**
 - Poorly ossified skull
 - Posterior pedicles of spine may be ossified
 - No rib fractures
 - Crenated ileum
 - Distal femora with metaphyseal irregularities
- **Type II achondrogenesis**
 - Normal skull ossification
 - Deficient spine mineralization
 - Hypoplastic ileum with medial spike
 - Flared metaphyses
- **Hypochondrogenesis**
 - Normal skull ossification
 - Better ossification of vertebral bodies
 - Cleft palate common
 - Tubular bones short and broad
 - Hypoplastic ilia, pubic, and ischial bones unossified
 - Mild cases of achondrogenesis type II and severe hypochondrogenesis difficult to distinguish prenatally

Ultrasonographic Findings

- Lack of vertebral ossification: Very characteristic/distinguishing feature
- Severe micromelia
- Disproportionately large head with either normal or deficient ossification depending upon type
- Small thorax with protuberant abdomen
- Short flared ribs ± fractures
- Polyhydramnios
- Cystic hygroma; increased nuchal translucency common in 1st trimester
- Hydrops in 1/3 of cases
- Micrognathia
- Hypoplastic midface

Other Modality Findings

- Fetal skeletal survey findings

- Type II achondrogenesis: "Floating head"
 - Only skull ossified well enough to be seen on radiograph
 - Rarely used currently

Imaging Recommendations

- Best imaging tool
 - 1st-trimester endovaginal ultrasound
 - Can be diagnosed as early as 12-14 weeks
 - Diagnosis reported at 9 weeks with positive family history
 - Virtually all cases should be suspected by midtrimester due to lack of spine ossification
 - 3D/4D ultrasound
- Protocol advice
 - Careful evaluation of skeleton
 - Ossification of spine, calvarium
 - Morphology of long bones
 - Radiographs in 3rd trimester: Used in past ("floating head" with absent spine)
 - Directed fluoroscopic images focused on spine, cranium, and long bones

DIFFERENTIAL DIAGNOSIS

Hypophosphatasia

- Skull demineralized
- Fractures uncommon
- Diffuse severe underossification of all bones often with crumpled appearance on ultrasound

Osteogenesis Imperfecta

- Fractures are predominant finding in osteogenesis imperfecta (OI) types II-IV
- Skull poorly mineralized in OI
- Rib fractures severe in type II: Beaded appearance
- Long bone bowing in types III-IV
- Abnormal type I collagen

Atelosteogenesis II

- Thoracic platyspondyly
- Bowed radius, ulna, tibia
- Clubfeet
- Better ossification of vertebrae

Homozygous Achondroplasia

- Normal calvarial ossification

Thanatophoric Dysplasia

- Normal ossification
- Micromelia less extreme
- Hydrops uncommon
- Cloverleaf skull in type II

Short Rib-Polydactyly Syndrome

- Polydactyly
 - Both preaxial and postaxial
- May appear hydroptic

PATHOLOGY

General Features

- Genetics

- Types IA and IB: Autosomal recessive
 - 25% recurrence risk
- Type IA: Molecular basis not known
- Type IB: Mutations in diastrophic dysplasia sulfate transporter gene [*SLC26A2* (DTDST)]
 - Results in abnormal sulfation of chondroitin sulfate-containing proteoglycans
 - Achondrogenesis IB and diastrophic dysplasia are allelic disorders
 - Prenatal diagnosis possible by chorionic villus sampling if specific mutation known
- Type II: Autosomal dominant
 - Mutations in type II collagen gene *COL2A1*
 - Recurrence in case of siblings attributed to germline mosaicism
- Hypochondrogenesis: Autosomal dominant
 - Mutations in type II collagen gene *COL2A1*
- Type II achondrogenesis, hypochondrogenesis, spondyloepiphyseal dysplasia congenita, and Kniest dysplasia are part of spectrum of allelic disorders (type II collagenopathies)
- Associated abnormalities
 - Type II with occasional cleft soft palate
 - Hydrops in 1/3
 - Polyhydramnios, often severe
 - Type IA with occasional encephaloceles

Staging, Grading, & Classification

- Definitive diagnosis of subtype possible with histopathologic studies
 - Type IA: Pathognomonic period acid-Schiff-positive intracytoplasmic inclusion bodies
 - Type IB: Decrease in type II collagen
 - Fibers in cartilage matrix arranged in rings around chondrocytes
 - Type II: Structurally abnormal type II collagen
 - Electron microscopy: Retention of type II collagen within vacuoles
 - Increased amounts of type I collagen seen in cartilage

Microscopic Features

- Disorganization of chondrocytes
 - Failure of alignment in columns
- Cartilage matrix stains irregularly for mucopolysaccharides

CLINICAL ISSUES

Presentation

- Most common signs/symptoms
 - Severe micromelia skeletal dysplasia associated with deficient spine ossification
- Other signs/symptoms
 - Polyhydramnios
 - Cystic hygroma, hydrops

Demographics

- Age
 - No association with increased parental age
- Gender
 - Reported cases show excess of males
- Epidemiology
 - 2nd most common lethal short-limb chondrodysplasia

- 1:40,000-50,000 live births
- May account for 1:650 perinatal deaths
- Consanguinity found in families affected with type I

Natural History & Prognosis

- Lethal
- Increased incidence of prematurity
- Majority stillborn or die in 1st few hours due to pulmonary hypoplasia
- Occasional survival up to 3 months in cases of hypochondrogenesis

Treatment

- No prenatal or postnatal treatment
- Offer pregnancy termination
- If pregnancy continued and diagnosis certain
 - Avoid fetal monitoring in labor
 - No intervention for preterm labor
 - Psychosocial support for family
- If diagnosis unclear and liveborn infant, resuscitation appropriate until confirmatory tests performed
- Deliver in tertiary center with expertise in fetopathology and skeletal dysplasias
- Stress importance of full genetic evaluation
 - Recurrence risk
 - Genetic counseling
- Autopsy important for final specific diagnosis
 - Complete set of radiographs
 - Absent mineralization of spine
 - Large skull with wormian bones
 - Short, abnormal long bones with variety of abnormalities
 - Cell culture
 - Bone/cartilage biopsy
 - Karyotype generally low yield
 - International Skeletal Dysplasia Registry for atypical cases

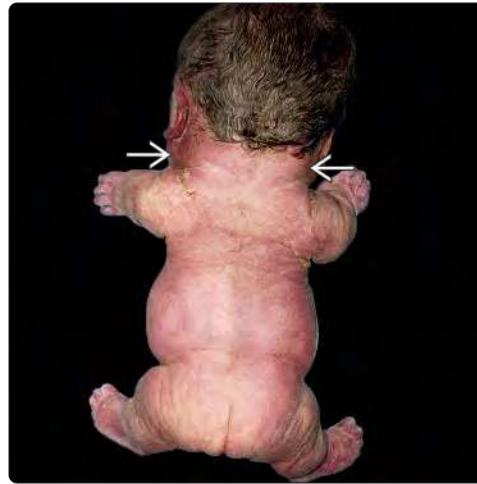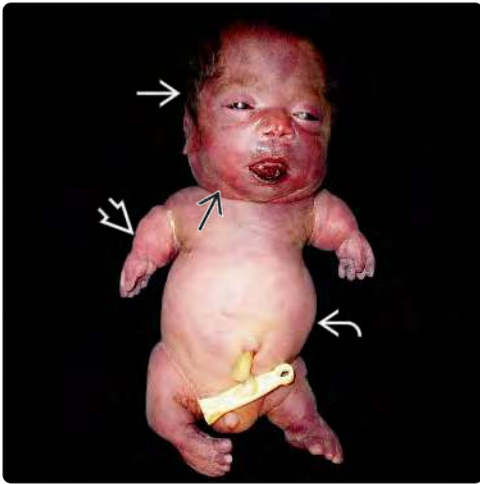DIAGNOSTIC CHECKLIST

Image Interpretation Pearls

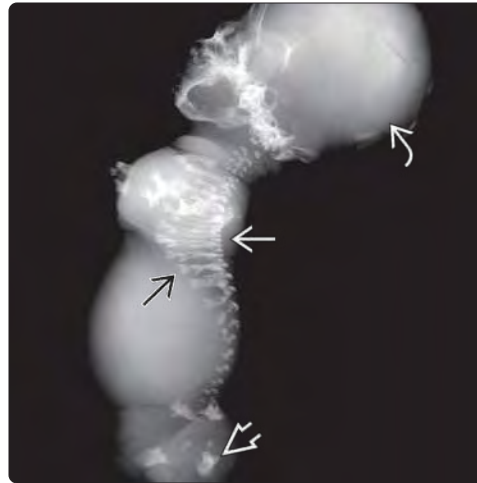
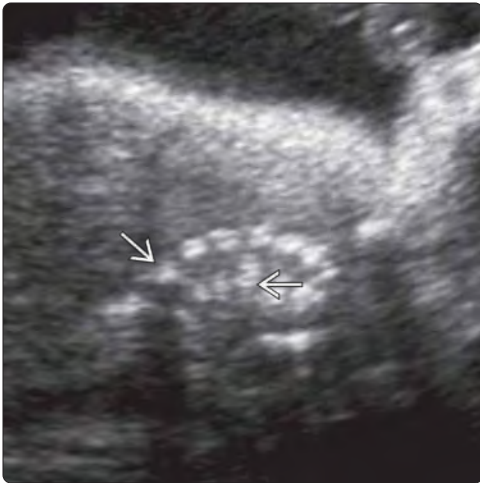- Severe micromelia with disproportionately large head
- Absent spine ossification classic finding
 - Transverse view shows < 3 ossification centers per spinal segment
- Absent spine ossification with normal calvarium in type II achondrogenesis
- Rib fractures with absence of long bone fractures in type IA
- No rib fractures in type IB

SELECTED REFERENCES

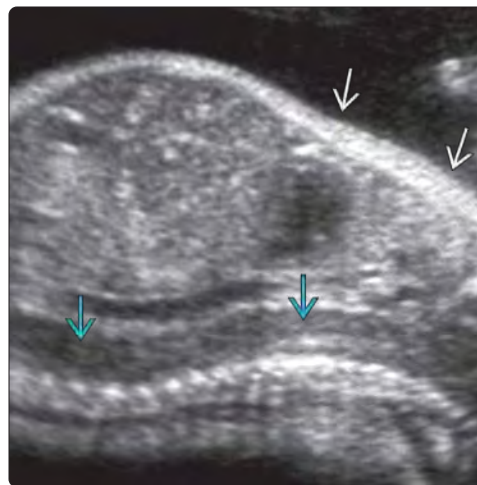
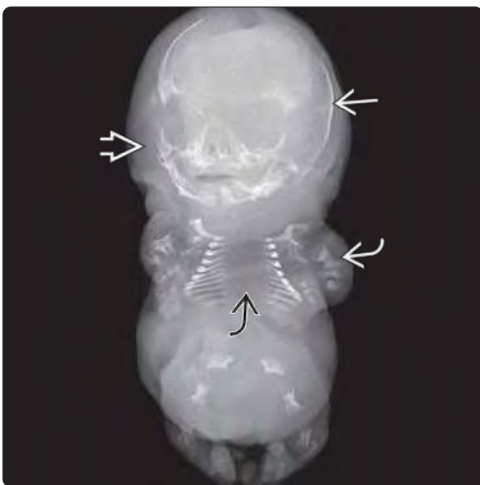1. Heinrich T et al: Co-occurrence of reciprocal translocation and *COL2A1* mutation in a fetus with severe skeletal dysplasia: implications for genetic counseling. *Cytogenet genome res.* 145(1):25-8, 2015
2. Weisman PS et al: Pathologic diagnosis of achondrogenesis type 2 in a fragmented fetus: case report and evidence-based differential diagnostic approach in the early midtrimester. *Pediatr Dev Pathol.* 17(1):10-20, 2014
3. Grigelioniene G et al: The phenotype range of achondrogenesis 1A. *Am J Med Genet A.* 161A(10):2554-8, 2013
4. Dawson PA: Sulfate in fetal development. *Semin Cell Dev Biol.* 22(6):653-9, 2011
5. Comstock JM et al: Recurrence of achondrogenesis type 2 in sibs: Additional evidence for germline mosaicism. *Am J Med Genet A.* 152A(7):1822-4, 2010



(Left) Clinical photograph shows a preterm stillborn infant with type IA achondrogenesis. Note the large head, protuberant abdomen, and severe micromelia. The head is not as disproportionate as is typical in type II. Note also the edematous soft tissue, especially of the face and neck. Hydrops was noted in utero. (Right) Photograph of the posterior aspect of the same infant shows the thick nuchal area with evidence of a small hygroma. Increased nuchal translucency is common in the 1st trimester.

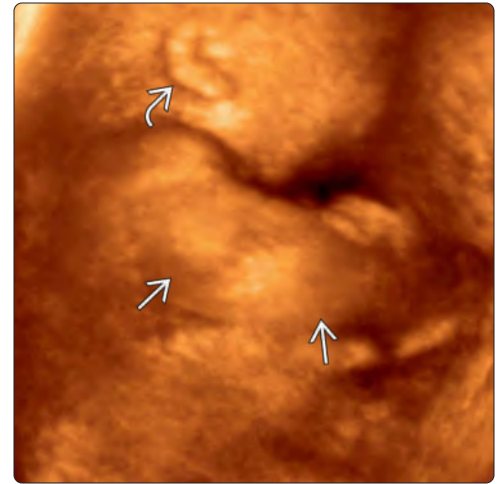
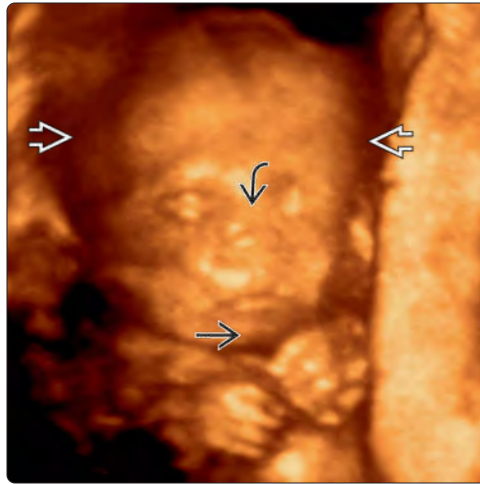


(Left) Longitudinal ultrasound of the fetal thorax shows the very short, crumpled-appearing ribs due to multiple fractures. This is a characteristic finding of type IA achondrogenesis. (Right) Lateral radiograph of a fetus with type IA achondrogenesis illustrates classic findings of near-absent ossification of the spine and calvarium, short ribs with splayed ends, and evidence of rib fractures. The ilia and pubic bones are unossified. The bones of the extremities are very short, with concave ends and metaphyseal spurs.

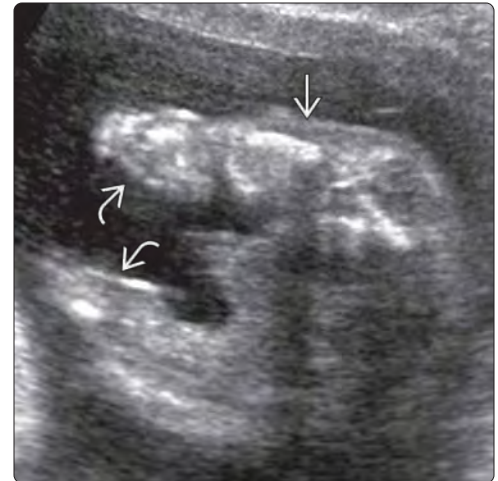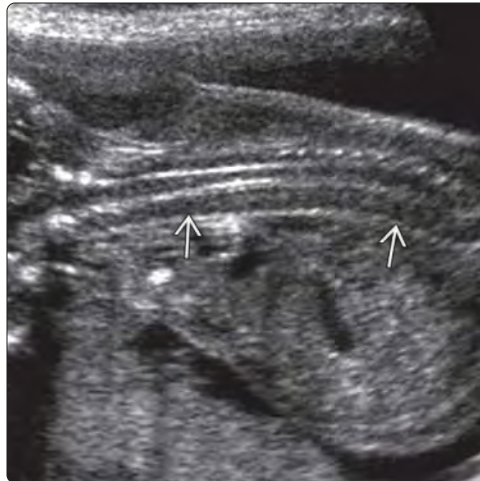


(Left) Radiograph of a stillborn fetus with type II achondrogenesis is shown. Note the large head with reasonably well-ossified calvarium and complete absence of spine ossification. There are no rib fractures. Severe micromelia is apparent. Significant soft tissue edema is also seen. (Right) Sagittal ultrasound in the early 3rd trimester illustrates absent ossification of the spine, the most characteristic ultrasonographic finding in fetuses with achondrogenesis. Note also the small chest.

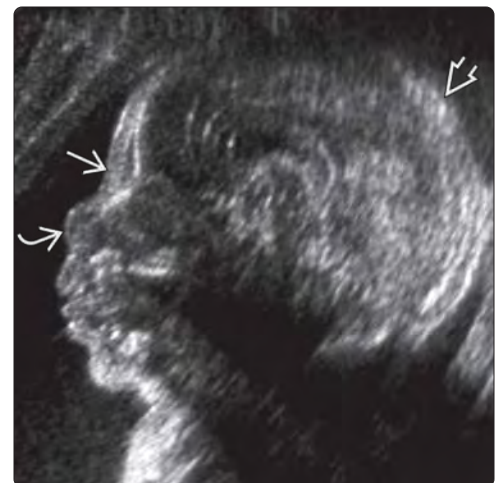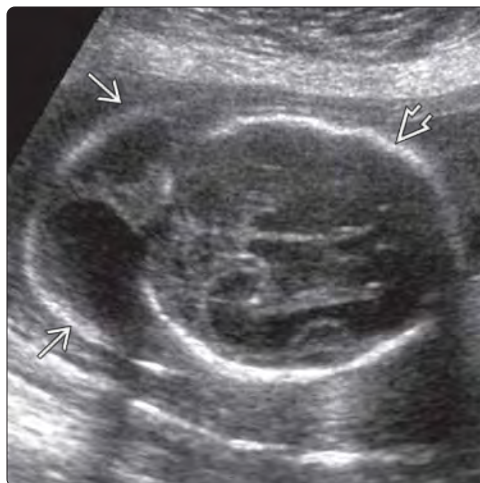
(Left) 3D ultrasound of the face in a midtrimester fetus with type II achondrogenesis shows the disproportionately large head, midface hypoplasia, and micrognathia. (Right) 3D ultrasound in the same fetus with type II achondrogenesis shows severe micromelia. A low-set, posteriorly rotated ear can also be seen. The helix appears thickened due to soft tissue edema associated with hydrops. Hydrops is a common finding in achondrogenesis.

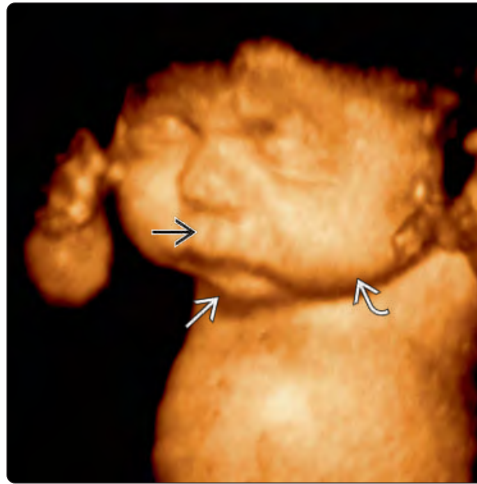
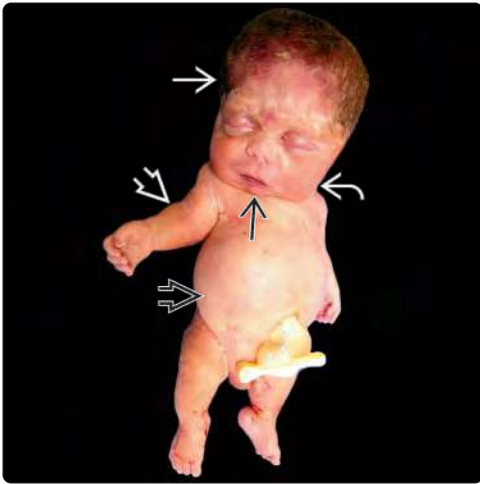
(Left) Ultrasound of a midtrimester (22 weeks) fetus with achondrogenesis shows the typical appearance of absent ossification of the vertebral bodies of the spine. The abnormal spine can easily be seen at the time of the anatomic survey. (Right) Ultrasound of the legs in the same patient shows short lower extremities and severe clubfeet. These are general features of achondrogenesis. To further subclassify as to which type, it is important to look at skull ossification and the presence or absence of rib fractures.

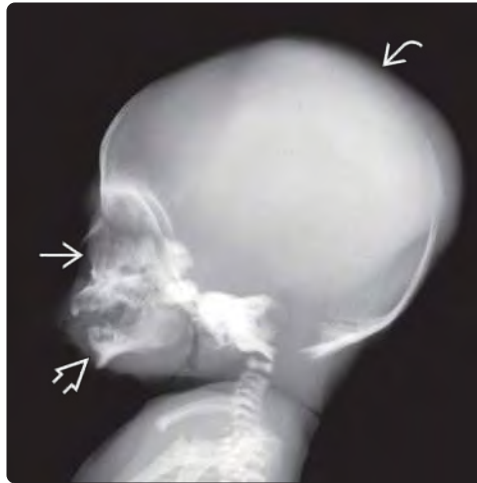
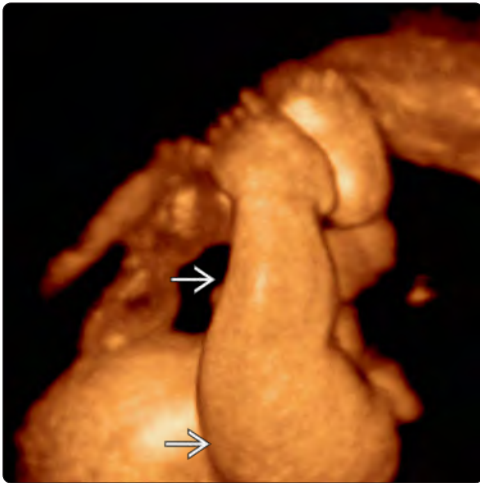
(Left) Axial ultrasound in this midtrimester fetus with achondrogenesis type II illustrates a large cystic hygroma and a reasonably well-ossified calvarium. Cystic hygroma and hydrops are common findings in achondrogenesis and may be preceded by increased nuchal translucency in the 1st trimester. (Right) This ultrasound of a fetus with type IA achondrogenesis shows typical findings of a poorly ossified calvarium and midface hypoplasia with a short upturned nose.

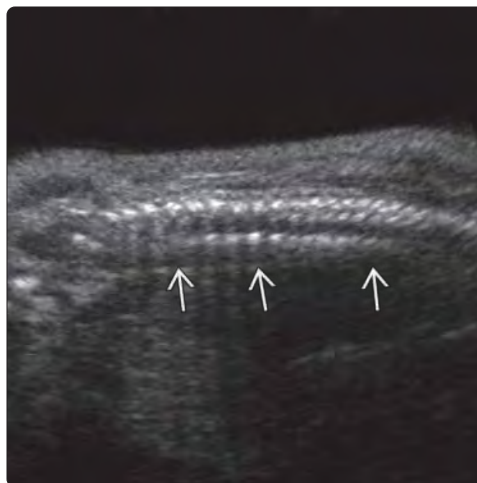
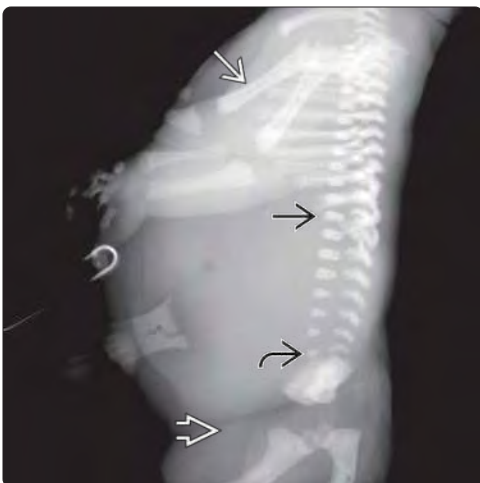



(Left) Clinical photograph of a preterm stillborn infant with hypochondrogenesis illustrates features very similar to achondrogenesis type II. There is a disproportionately large head, short neck, less severe micromelia, small chest, and protuberant abdomen. The eyes are prominent and a small mouth and micrognathia are also noted. (Right) 3D ultrasound of the same fetus shows the appearance in the late midtrimester. Micrognathia is striking. Note the prominent cheeks and long philtrum.



(Left) 3D ultrasound shows the less marked lower extremity micromelia in this infant with hypochondrogenesis. (Right) Lateral radiograph in hypochondrogenesis shows mildly deficient skull ossification, midface hypoplasia, and micrognathia. It is often difficult to distinguish hypochondrogenesis from milder forms of achondrogenesis type II on prenatal ultrasound; examination of the infant with postnatal radiographs is often necessary.



(Left) Lateral radiograph of a neonate with hypochondrogenesis shows small but reasonably ossified thoracic vertebral bodies. The lumbosacral spine is more abnormal with hypoplastic vertebral bodies. The bones of the extremities exhibit more normal tubulation and are less short than achondrogenesis. Pubic bones are unossified. (Right) Coronal oblique US shows the mildly underossified appearing spine in hypochondrogenesis. Ossification is usually more normal appearing than in achondrogenesis.

KEY FACTS

TERMINOLOGY

- Most common heritable, nonlethal, skeletal dysplasia
- Characterized by disproportionately short limbs (rhizomelia), large head with frontal bossing, midface hypoplasia, and short digits

IMAGING

- Short limbs with normal ossification, no fractures
- Proximal femoral diaphysis-metaphysis angle is increased
- Collar hoop sign: Small highly echogenic hook at end of diaphysis
- Progressive macrocephaly with frontal bossing
- Depressed nasal bridge with upturned nasal tip
- Chest normal to mildly bell-shaped

TOP DIFFERENTIAL DIAGNOSES

- Hypochondroplasia
- Thanatophoric dysplasia
- Homozygous achondroplasia

- Severe achondroplasia with developmental delay and acanthosis nigricans syndrome
- Pseudoachondroplasia
- Spondyloepiphyseal dysplasia

PATHOLOGY





- Autosomal dominant single-gene disorder
- *FGFR3* mutations (gain of function)
- Over 80% of cases are de novo mutations (sporadic)
- Homozygous achondroplasia is lethal

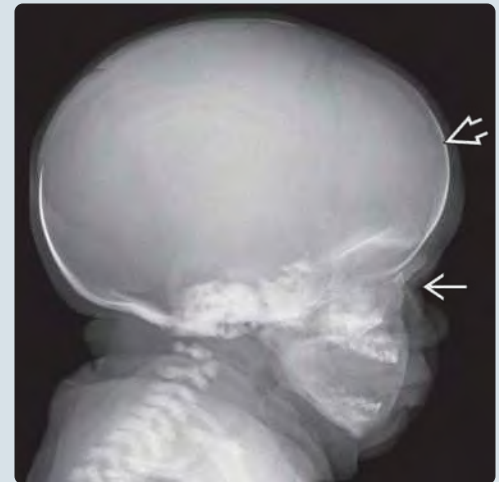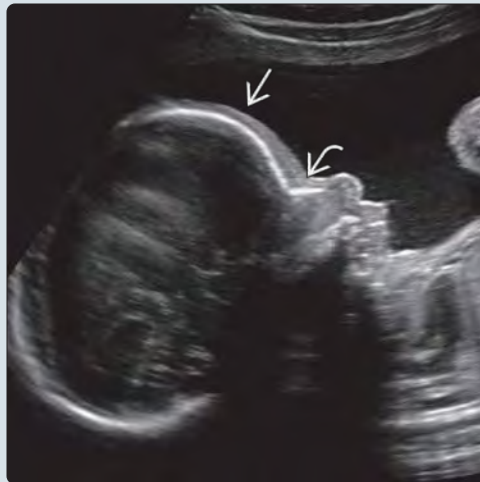CLINICAL ISSUES





- Normal intelligence
- Generally normal lifespan
- Increased incidence of orthopedic and neurologic complications

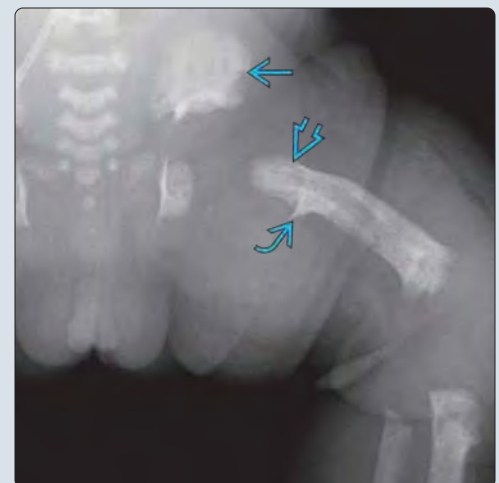
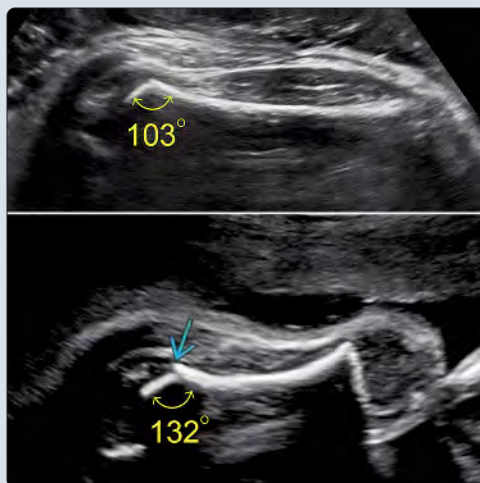
DIAGNOSTIC CHECKLIST

- Normal 2nd-trimester scan does not rule out achondroplasia

(Left) Sagittal US shows the typical 3rd-trimester profile of a fetus with achondroplasia. Note the frontal bossing  and the depressed nasal bridge . The head circumference was > 95% for gestational age. (Right) Lateral radiograph of an infant with achondroplasia shows the large, normally ossified calvarium, frontal bossing , and midface hypoplasia . This appearance is very similar to the prenatal ultrasound.



(Left) US shows a comparison of a normal midtrimester fetus (top) to a fetus with achondroplasia (bottom). The proximal femoral diaphysis-metaphysis angle is shown. The angle is increased in achondroplasia. This finding is felt to be a specific sign & may be detected before significant long bone shortening. There is also a small echogenic spur at the end of the diaphysis , called the collar hoop sign. (Right) Postnatal radiograph shows the flattened metaphyseal angle  and collar hoop . Note the squared iliac wing .



TERMINOLOGY

Definitions

- Most common heritable, nonlethal, skeletal dysplasia
- Characterized by disproportionately short limbs (rhizomelia), large head with frontal bossing, midface hypoplasia, and short digits
- Homozygous achondroplasia is lethal
 - Occurs when mutation inherited from each of 2 affected parents

IMAGING

General Features

- Best diagnostic clue
 - 3rd-trimester long bone shortening with macrocephaly
- Morphology
 - Rhizomelia
 - Proximal limb shortening

Ultrasonographic Findings

- **Long bones**
 - Short limbs with normal ossification, no fractures
 - Mild bowing of femora, no angulation
 - Bowing of other long bones often not seen prenatally
 - Proximal femoral diaphyseal-metaphyseal angle
 - Normal angle
 - 22 weeks: $98.5 \pm 6.8^\circ$
 - 32 weeks: $105.6 \pm 7.3^\circ$
 - Angle is increased in affected fetuses
 - In 1 study, 5 of 6 affected fetuses had angle $> 130^\circ$
 - Most consistent finding other than long bone shortening
 - Collar hoop sign: Small, highly echogenic hook at end of diaphysis
- **Bone growth**
 - Normal early scan with shortening manifesting between 21-27 weeks
 - Progressively discrepant growth
 - Often more obvious in 3rd trimester
 - Head circumference:femur length (FL) ratio increases (function of both short femur and large head)
 - Upper extremities more severely affected than lower
- **Head and face**
 - Progressive macrocephaly with frontal bossing
 - May be late finding
 - Depressed nasal bridge with upturned nasal tip
- **Spine**
 - Prominent thoracolumbar kyphosis
 - Platyspondyly
 - Decreased interpedicular distance in lumbar spine
- **Trident hands**
 - Short fingers, appear same length
 - Gap between 3rd-4th fingers
- Chest normal to mildly bell-shaped with protuberant abdomen
- Polyhydramnios may develop in 3rd trimester
 - Usually mild to moderate
- Homozygous (lethal) achondroplasia
 - Findings more severe and seen earlier

- At-risk fetuses (1 or both affected parents) should have serial sonograms for growth
- FL < 3 rd percentile at 17 weeks
- FL < 34 mm at 26 weeks by biparietal diameter

Imaging Recommendations

- Best imaging tool
 - Late 2nd to early 3rd-trimester ultrasound
 - 3D/4D ultrasound useful for evaluating hands and spine
- Protocol advice
 - Rule out lethal skeletal dysplasia
 - Micromelia
 - Small chest
 - Severe polyhydramnios

DIFFERENTIAL DIAGNOSIS

FGFR3 Mutation-Associated Disorders

- **Hypochondroplasia**
 - Short stature, short extremities, lumbar lordosis
 - Clinical characteristics similar to, but less severe, than in typical achondroplasia
 - Calvarium normal or slightly macrocephalic
 - Learning, behavioral disability
 - Molecular diagnosis possible in ~ 70% of cases
 - Most common mutation N540K substitution in *FGFR3*
 - Clinical and radiographic distinction from achondroplasia may be difficult
 - Autosomal dominant; majority of cases de novo with $< 0.01\%$ recurrence risk
- **Thanatophoric dysplasia (TD)**
 - More severe limb shortening (micromelia)
 - Small chest with pulmonary hypoplasia
 - Curved long bones, especially in TD type I
 - Cloverleaf skull in TD type II
 - Severe polyhydramnios in 3rd trimester
 - Perinatal lethal
- **Homozygous achondroplasia**
 - Lethal disorder
 - Occurs in 25% of offspring when 2 parents affected with achondroplasia
 - Severe limb shortening
 - Pulmonary hypoplasia
- **Severe achondroplasia with developmental delay and acanthosis nigricans syndrome**
 - Bony changes as severe as TD
 - Differentiation from TD and achondroplasia may be difficult without molecular analysis

Type I Collagen Abnormalities

- **Osteogenesis imperfecta**
 - Fractures dominant feature
 - Decreased ossification
 - Micromelia

Cartilage Oligomeric Matrix Protein-Associated Disorders

- **Pseudoachondroplasia**
 - Disproportionately short stature
 - Abnormal joints
 - Osteoarthritis requiring joint replacement

- **Spondyloepiphyseal dysplasia**
 - Rhizomelic dysplasia with similar long bone features
 - No frontal bossing
 - Micrognathia ± Robin sequence (cleft palate)

PATHOLOGY

General Features

- Etiology
 - *FGFR3* tyrosine kinase expressed by chondrocytes in growth plate of developing long bones
 - Overactivity of *FGFR3* signaling may impair chondrocyte function within epiphyseal growth plates
 - Decreased endochondral ossification
- Genetics
 - Autosomal dominant single-gene disorder
 - *FGFR3* mutations (gain of function)
 - *FGFR3* activity is increased → less ossification → reduced bone size, especially long bones
 - 97% of cases involve glycine-to-arginine substitution in codon 380 of *FGFR3* transmembrane domain (G380R)
 - *FGFR* located on short arm of chromosome 4
 - Over 80% of cases are de novo mutations (sporadic)
 - Homozygous achondroplasia is lethal
 - Recurrence risk: 1 parent affected
 - 50% of offspring with achondroplasia
 - 50% of offspring unaffected
 - Recurrence risk: Both parents affected
 - 50% of offspring with achondroplasia
 - 25% with homozygous (lethal) achondroplasia
 - 25% unaffected
 - Recurrence risk: Both parents unaffected
 - Sporadic: Low recurrence risk

CLINICAL ISSUES

Presentation

- Most common signs/symptoms
 - Long bone shortening in late 2nd and 3rd trimesters

Demographics

- Age
 - Associated with increased paternal age
- Gender
 - No gender predilection
- Ethnicity
 - Found in all ethnic groups
- Epidemiology
 - Heterozygous: 1:10,000-30,000 live births
 - Homozygous: Rare
 - Both parents must be affected or 1 parent with new mutation

Natural History & Prognosis

- Normal intelligence
- Generally normal lifespan
 - Some studies suggest risk of premature death compared with general population
 - Increased incidence of death in 1st year of life
 - Often sudden and unexpected

- Associated with acute foraminal compression of cervical spine or brainstem
- Increased incidence of orthopedic and neurologic complications
 - Cervical instability, stenosis, hydrocephalus
 - Limb bowing
 - Thoracolumbar kyphosis
 - Midface hypoplasia with upper airway obstruction
- Other problems in children
 - Delayed motor milestones
 - Recurrent middle ear problems
- Affected fetus in unaffected mother
 - Cesarean delivery often necessary due to macrocephaly
 - Polyhydramnios in 3rd trimester

Treatment

- Genetic counseling
 - 1 or both parents affected
 - Significant recurrence risk with each pregnancy
 - Prenatal or neonatal diagnosis of affected infant
- Prenatal diagnosis available
 - Diagnosis suspected by ultrasound
 - Molecular analysis of *FGFR3* mutations
 - Amniocentesis
 - Chorionic villus sampling
 - Cell-free fetal DNA
 - Preimplantation genetic diagnosis if mutations are known
 - Prevent homozygous lethal form in cases of 2 affected parents
- Pregnancy termination in cases of homozygous achondroplasia
- Postnatal treatments
 - Limb-lengthening and -straightening procedures
 - Cervicomedullary decompression for spinal stenosis
 - Bracing and spinal-fusion procedures

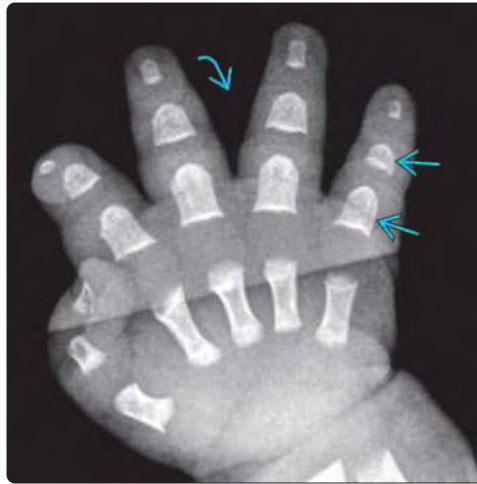
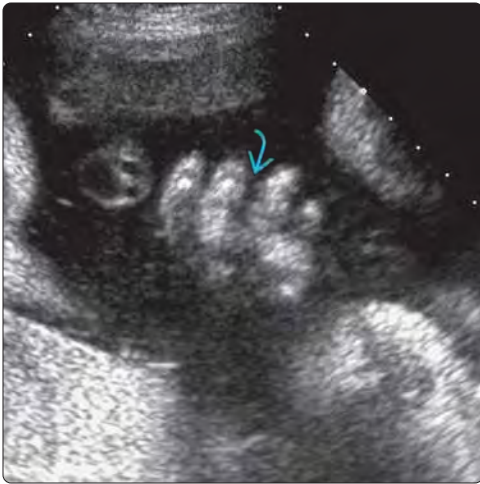
DIAGNOSTIC CHECKLIST

Image Interpretation Pearls

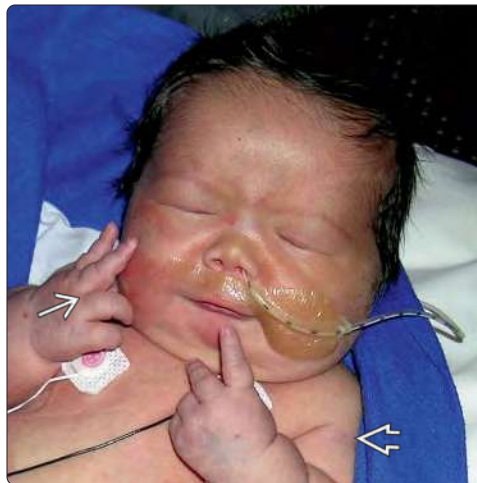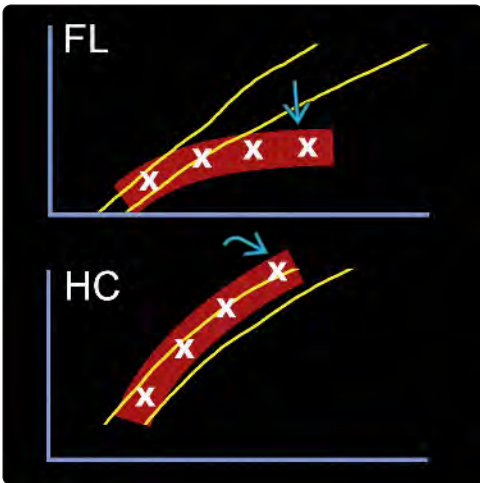
- Normal 2nd-trimester scan does not rule out achondroplasia
- Progressive limb shortening in late 2nd and 3rd trimester

SELECTED REFERENCES

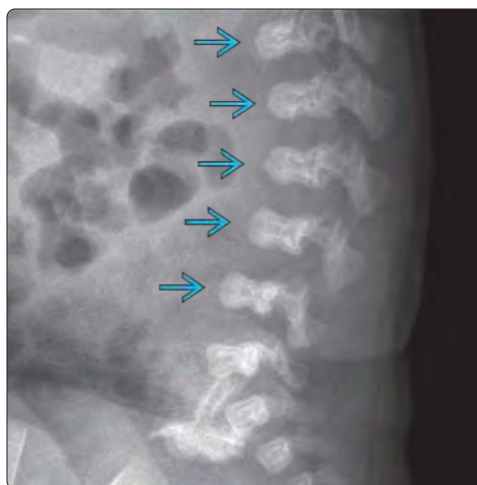
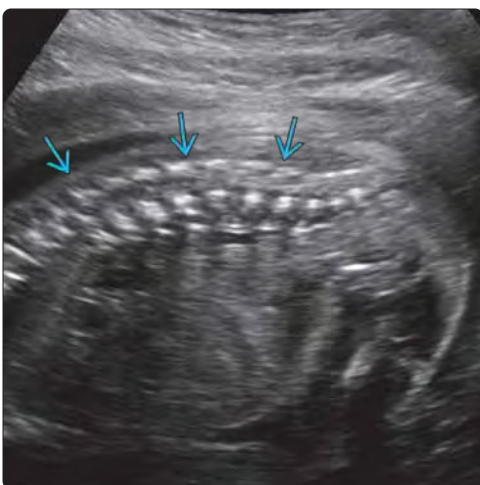
1. Khalil A et al: Widening of the femoral proximal diaphysis–metaphysis angle in fetuses with achondroplasia. *Ultrasound Obstet Gynecol.* 44(1):69-75, 2014
2. Pugash D et al: Prenatal ultrasound and MRI findings of temporal and occipital lobe dysplasia in a twin with achondroplasia. *Ultrasound Obstet Gynecol.* 44(3):365-8, 2014
3. Bustamante-Aragonés A et al: Non-invasive prenatal diagnosis of single-gene disorders from maternal blood. *Gene.* 504(1):144-9, 2012
4. Hatzaki A et al: *FGFR3* related skeletal dysplasias diagnosed prenatally by ultrasonography and molecular analysis: presentation of 17 cases. *Am J Med Genet A.* 155A(10):2426-35, 2011
5. Lim JH et al: Non-invasive prenatal detection of achondroplasia using circulating fetal DNA in maternal plasma. *J Assist Reprod Genet.* 28(2):167-72, 2011
6. Laederich MB et al: Achondroplasia: pathogenesis and implications for future treatment. *Curr Opin Pediatr.* 22(4):516-23, 2010
7. Boulet S et al: Prenatal diagnosis of achondroplasia: new specific signs. *Prenat Diagn.* 29(7):697-702, 2009



(Left) US shows the typical appearance of a trident hand of a fetus with achondroplasia. Note the brachydactyly (similar lengths of all the digits) and mildly splayed appearance. (Right) Radiograph of the hand of an infant with achondroplasia shows characteristic findings, including striking brachydactyly. The proximal and middle phalanges are short, broad, and cone-shaped. Separation of the digits is also noted.



(Left) This graph shows the femur length and head circumference plots in a fetus with achondroplasia. Initially, the femur length is normal with shortening becoming obvious in the 3rd trimester. The HC plot shows the development of macrocephaly over the course of gestation. (Right) Clinical photograph shows typical facial findings of achondroplasia with a flat midface, depressed nasal bridge, and upturned nasal tip. Note the trident hand and short humerus. Long bone shortening was not significant until the 3rd trimester.



(Left) Midtrimester fetus with achondroplasia shows a very prominent kyphosis of the thoracolumbar spine. (Right) Postnatal lateral radiograph of the lumbar spine in a patient with achondroplasia demonstrates an increased lumbar kyphosis with platyspondyly. Additional spine findings in achondroplasia include decreased interpedicular distance in the lumbar spine, but this is difficult to detect prenatally.

KEY FACTS

TERMINOLOGY

- Amelia: Absence of 1 or more limbs
- Micromelia: Shortening of both proximal and distal segments of limb
- Phocomelia: Shortening of limb with hand/foot arising near trunk
- Limb reduction defect: Absence of any portion of skeletal structures or soft tissues of limb
- Hemimelia: Absence of distal limb

IMAGING

- Missing or severely shortened extremities on 1st- or 2nd-trimester ultrasound
- Pattern of body involvement is key
 - Segment involved, symmetry
- Careful search for associated anomalies, especially orofacial clefts, thoracoabdominal defects, cardiac malformations
- Evaluation of morphology of bones of extremities to exclude skeletal dysplasia







- Search for evidence of amniotic bands

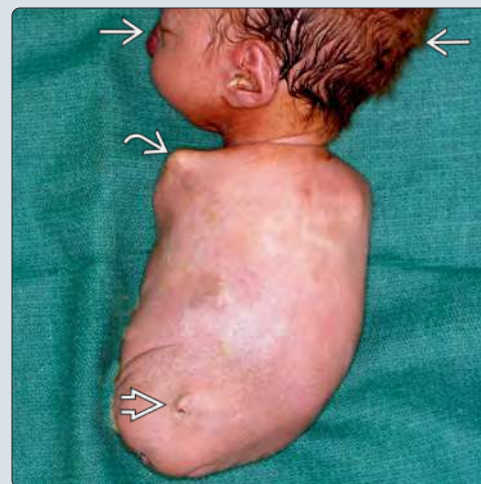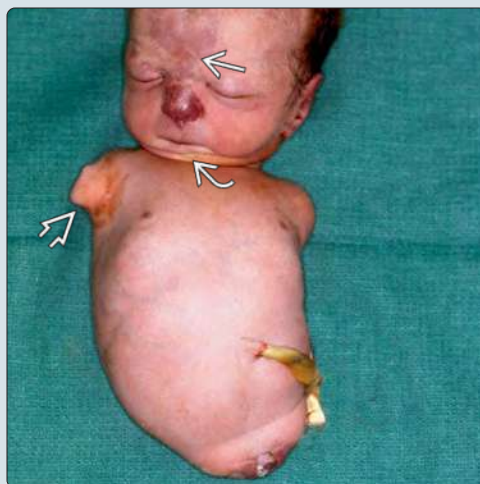
TOP DIFFERENTIAL DIAGNOSES




- Amelia/tetra-amelia
 - Roberts syndrome/Roberts SC syndrome
 - Amniotic bands
 - Thrombocytopenia-absent radius (TAR) syndrome
- Isolated phocomelia/amelia of 1 or more limbs
- DK phocomelia
- Micromelia: Achondrogenesis, atelosteogenesis, dyssegmental dysplasia, fibrochondrogenesis

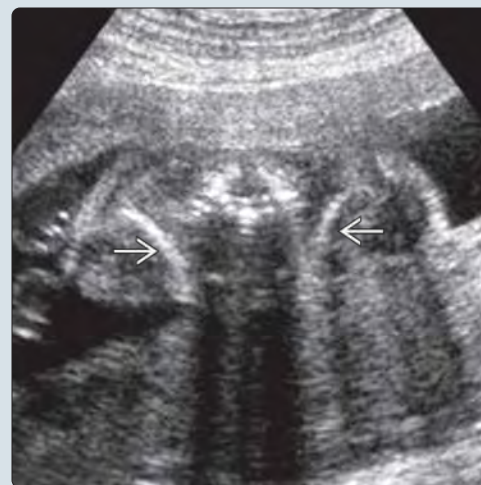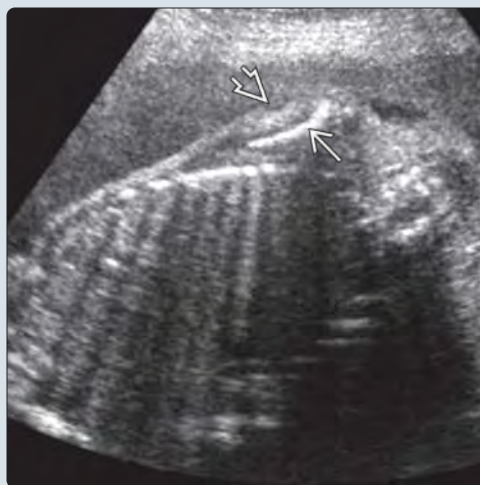PATHOLOGY

- Autosomal recessive: Roberts, TAR, DK-phocomelia, many types of micromelia
- Cases of recurrent tetra-amelia in consanguineous families: Presumed autosomal recessive
- Cytogenetic analysis looking for centromeric separation in suspected Roberts syndrome

(Left) Clinical photograph shows a term stillborn infant with tetra-amelia. Note the absence of all 4 limbs with a single rudimentary humerus . Severe micrognathia is apparent . A prominent glabellar hemangioma is also noted . **(Right)** Clinical photograph of the same infant shows an abnormal bony protuberance  at the shoulder. The head is disproportionately large  when compared to the body. Another bony protuberance is noted over the sacral area corresponding to the truncated distal spine .



(Left) Coronal oblique ultrasound shows a normal-appearing scapula  and absent upper extremity  in a midtrimester fetus with tetra-amelia. **(Right)** Axial ultrasound of the pelvis of the same midtrimester fetus with tetra-amelia shows hypoplastic ilia . The lower extremities were absent. The distal lumbar and sacral spine were also absent.



TERMINOLOGY**Definitions**

- **Amelia:** Absence of 1 or more limbs
- **Micromelia:** Shortening of both proximal and distal segments of limb
- **Phocomelia:** Shortening of limb with hand/foot arising near trunk
 - Proximal segment often most severely affected
- **Limb reduction defect:** Absence of any portion of skeletal structures or soft tissues of limb
 - May be transverse, longitudinal, or intercalary deficiency
- **Hemimelia:** Absence of distal limb

IMAGING**Imaging Recommendations**

- Best imaging tool
 - 1st-, 2nd-trimester ultrasound
 - Diagnosis possible in 1st trimester by endovaginal ultrasound
 - Diagnosis may be difficult late in 3rd trimester
 - 3D/4D ultrasound valuable in evaluating morphology of limbs
 - Useful in counseling family
- Protocol advice
 - Pattern of involvement key in formulating differential diagnosis
 - Symmetric vs. asymmetric limb anomalies
 - Are upper or lower limbs more severely affected?
 - Are hands and feet present/abnormal?
 - Which segment(s) of limbs affected?
 - Careful search for associated anomalies, especially orofacial clefts, thoracoabdominal defects, cardiac malformations
 - Clues for syndromal diagnosis
 - Search for evidence of amniotic bands

DIFFERENTIAL DIAGNOSIS**Amelia**

- **Roberts syndrome/Roberts SC syndrome**
 - SC-phocomelia considered same syndrome
 - Clinical characteristics
 - Tetraphocomelia 90% (only upper limbs affected in 10%)
 - Facial clefts in 80%
 - Severe pre- and postnatal growth restriction
 - Dysmorphic facies
 - Other anomalies: Genitourinary (GU), cardiac, syndactyly, ear and nose, anterior encephalocele, microcephaly
 - Autosomal recessive
 - Most die in utero or shortly after birth
 - Rare report of longer term survivor
 - Characteristic cytogenetic features: Premature centromere separation
 - Centromeric "puffing" in chromosomes with secondary constrictions (1, 9, 16, short arm of acrocentrics, short arm of Y)
 - Very specific for Roberts syndrome

- Sensitivity in prenatal diagnosis unknown
- Reported discordance with pre- and postnatal analysis

- **Tetra-amelia**
 - Rare: 0.4/100,000 live births
 - Reported associated anomalies include
 - Pulmonary agenesis, hypoplasia
 - Orofacial clefts
 - Absent ears and nose
 - Cardiac anomalies
 - GU anomalies including ambiguous genitalia
 - Imperforate anus
 - Ectodermal dysplasia
 - Associated visceral anomalies very common
 - High perinatal lethality
 - Autosomal recessive tetra-amelia due to mutations in *WNT3* gene
- **Isolated phocomelia/amelia**
 - Involving 1 or more limbs
- **Amniotic bands**
 - Asymmetric: Single or multiple limbs involved
 - Bizarre orofacial clefting and cranial abnormalities
 - Cleft lines do not follow embryologic lines of fusion
 - Body wall schisis defects
 - Strands of amnion may be seen in amniotic fluid on ultrasound or by gross examination of placenta
 - Constriction rings around extremities, digits
 - Pseudosyndactyly
- **Thrombocytopenia-absent radius syndrome**
 - Upper limb phocomelia, often severe
 - Lower limb anomalies in 50%
 - Hypomegakaryocytic thrombocytopenia
 - Facial capillary hemangiomata
 - Autosomal recessive
 - Distinct from Fanconi anemia
 - Thumbs normal in TAR
 - No increased chromosome breakage in TAR
- **DK-phocomelia**
 - von Voss-Cherstvoy syndrome
 - Phocomelia, encephalocele, thrombocytopenia, GU anomalies
 - Autosomal recessive
- **Thalidomide embryopathy**
 - Common sedative, morning sickness drug used in Europe in 1950s and early 1960s
 - Removed from market in 1962: Recognition of severe limb anomalies in offspring of mothers treated with thalidomide in early pregnancy
 - Mechanism of action: Interference with angiogenesis, inflammatory response
 - Characteristic pattern of anomalies: Tetraphocomelia, cardiac, GU, facial, nervous system
 - Approved by FDA in 1998 for treatment of complications of leprosy
 - Experimental treatment of HIV, ulcerative diseases, and inflammatory conditions
 - Single dose in pregnant woman confers full risk of embryopathy

Micromelia

- **Achondrogenesis**

- Lack of vertebral ossification
- Disproportionately large head with normal or deficient ossification
- Short ribs ± fractures
- Micrognathia
- Hydrops common
- Autosomal recessive IA, IB; II sporadic
- **Atelosteogenesis**
 - Macrocephaly
 - Micrognathia
 - Cleft palate
 - Short trunk with small chest, protuberant abdomen
 - "Hitchhiker" thumbs
 - Clubfeet
 - Short tubular bones with metaphyseal flaring
 - Wide gap between 1st and 2nd toes
 - Autosomal recessive: Mutations in diastrophic dysplasia sulfate transporter gene (*DTDST*)
- **Dyssegmental dysplasia**
 - Irregular vertebral bodies with multiple ossification centers (anisospondyly)
 - Short spine, small thorax with short ribs
 - Short, thick ischial and pubic bones
 - Short, wide, angulated tubular bones
 - Autosomal recessive
- **Fibrochondrogenesis**
 - Wide fontanels and sutures with proptotic eyes
 - Short tubular bones with bulbous ends
 - Defective posterior ossification of vertebral bodies with coronal clefts
 - Broad iliac bones with medial and lateral spurs
 - Autosomal recessive
- **Osteogenesis imperfecta type II**
 - Defects in type I collagen (*COL1A1*, *COL1A2*)
 - Severe abnormality in ossification, including skull
 - Multiple fractures of ribs, long bones
 - Sporadic; recurrences due to gonadal mosaicism
- **Short rib-polydactyly syndrome types I and III**
 - Postaxial polydactyly
 - Narrow thorax with protuberant abdomen
 - Multiple internal anomalies, including cardiac, GU, orofacial
 - Short tubular bones with ragged ends
 - Autosomal recessive
- **Diastrophic dysplasia family**
 - Encompasses **diastrophic dysplasia, achondrogenesis IB, and atelosteogenesis I**
 - Mutations in *DTDST* gene
 - Diastrophic dysplasia
 - Progressive kyphoscoliosis
 - Cleft palate
 - Clubfeet
 - "Hitchhiker" thumbs
 - Increased perinatal mortality; normal life span if no severe spinal complications
 - Autosomal recessive

PATHOLOGY

General Features

- Etiology
 - Mutations of *WNT3* genes in autosomal recessive tetra-amelia
 - Mutations in *DTDST* gene involved in diastrophic dysplasia, achondrogenesis IB, atelosteogenesis I
 - Mutations in *COL1A1*, *COL1A2* in OI II
 - Mutations in *ESCO2* in Roberts (cohesin family)
 - Interference with vascular development in some isolated phocomelia
- Genetics
 - Roberts, TAR, DK-phocomelia: Autosomal recessive
 - Micromelia: Many autosomal recessive
 - Cases of recurrent tetra-amelia in consanguineous families: Presumed autosomal recessive

CLINICAL ISSUES

Presentation

- Most common signs/symptoms
 - Missing or severely shortened extremities on 1st- or 2nd-trimester ultrasound
- Other signs/symptoms
 - Roberts syndrome: Orofacial clefting with phocomelia/amelia
 - Evidence of skeletal dysplasia with micromelia

Natural History & Prognosis

- Most chondrodystrophies with severe micromelia lethal in perinatal period

Treatment

- No prenatal treatment
- Survivors need orthopedic surgical management of progressive spinal, limb abnormalities

DIAGNOSTIC CHECKLIST

Consider

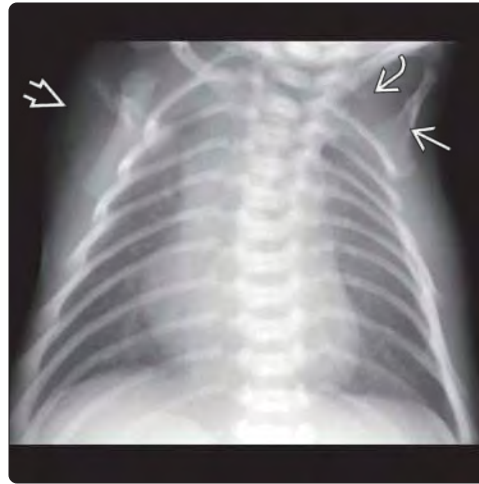
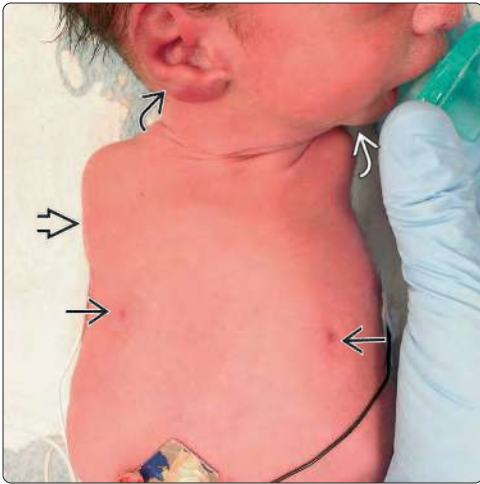
- Cytogenetic analysis looking for centromeric separation in suspected Roberts syndrome

Image Interpretation Pearls

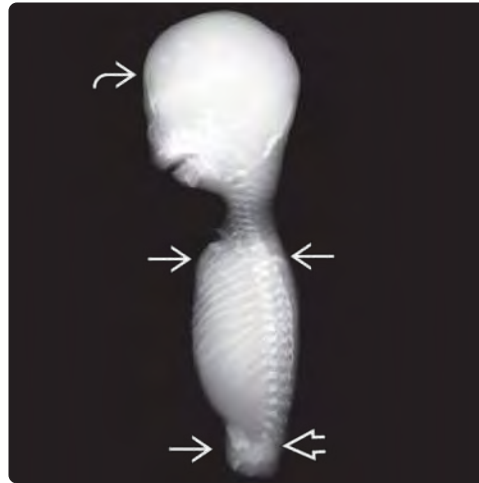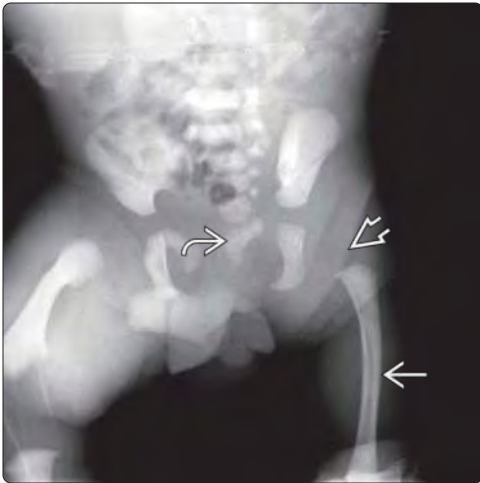
- Which segment of limb affected and symmetry of involvement important in determining differential diagnosis
- Evaluation of morphology of bones of extremities to exclude skeletal dysplasia
- Careful search for other structural anomalies

SELECTED REFERENCES

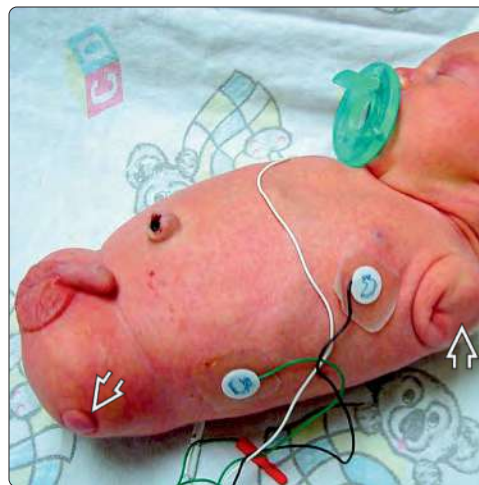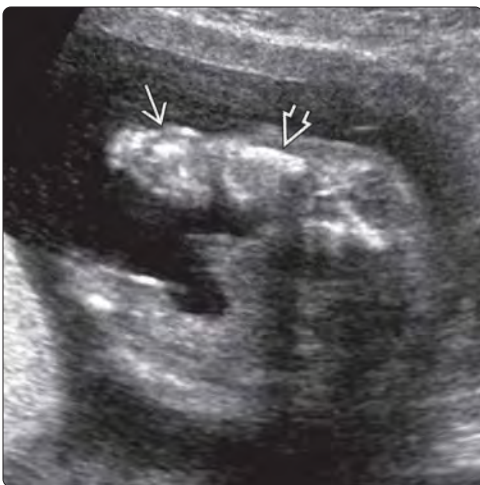
1. Haro E et al: Sp6 and Sp8 transcription factors control AER formation and dorsal-ventral patterning in limb development. *PLoS Genet.* 10(8):e1004468, 2014
2. Al-Qattan MM: WNT pathways and upper limb anomalies. *J Hand Surg Eur Vol.* 36(1):9-22, 2011
3. Eyaid W et al: A novel homozygous missense mutation (c.610G>A, p.Gly204Ser) in the *WNT7A* gene causes tetra-amelia in two Saudi families. *Am J Med Genet A.* 155A(3):599-604, 2011
4. Goh ES et al: The Roberts syndrome/SC phocomelia spectrum—a case report of an adult with review of the literature. *Am J Med Genet A.* 152A(2):472-8, 2010



(Left) Clinical photograph shows a term infant with upper extremity amelia. There was also phocomelia of the lower extremities. Note the micrognathia and large, low-set, posteriorly rotated ears. The nipples are hypoplastic and asymmetric. (Right) Anteroposterior radiograph of the same infant shows absence of the upper extremities and bilateral hypoplastic scapulae and clavicles.



(Left) Anteroposterior radiograph of an infant of a poorly controlled diabetic shows unilateral absence of the femur and a single distal long bone, consistent with a complex limb reduction defect. The distal spine and left pelvis are also hypoplastic. (Right) Lateral radiograph of a stillborn preterm infant with tetra-amelia shows the absence of all limbs, a disproportionately large head, and a severely hypoplastic pelvis.



(Left) Ultrasound of a midtrimester fetus with achondrogenesis shows severe micromelia of the lower extremities. Skin edema is also seen associated with hydrops, a common finding in many lethal chondrodystrophies. (Right) Clinical photograph of an infant with tetra-amelia shows fleshy protuberances at the site of the missing extremities.

KEY FACTS

IMAGING

- Rhizomelic limb shortening with disproportionately shortened and tapered humeri
- Flat midface
- Atelosteogenesis type 1
 - Distal hypoplasia/tapered humerus, femur
- Atelosteogenesis type 2
 - Micromelia with flared metaphyses, distal tapering, bowed radius, ulna
 - Proximally implanted "hitchhiker" thumb, great toe
- Atelosteogenesis type 3
 - Disproportionately short humerus, femur with distal tapering
 - Short broad phalanges with short 3rd metacarpal






TOP DIFFERENTIAL DIAGNOSES

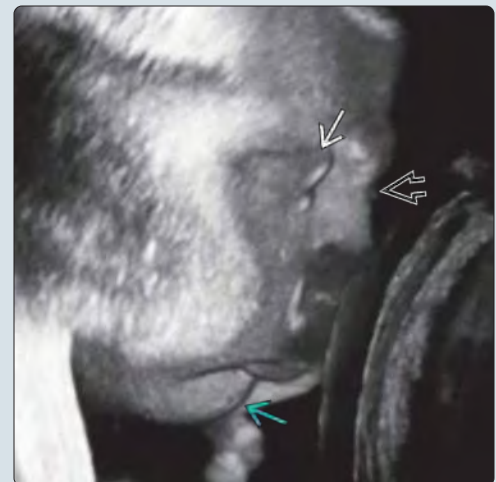
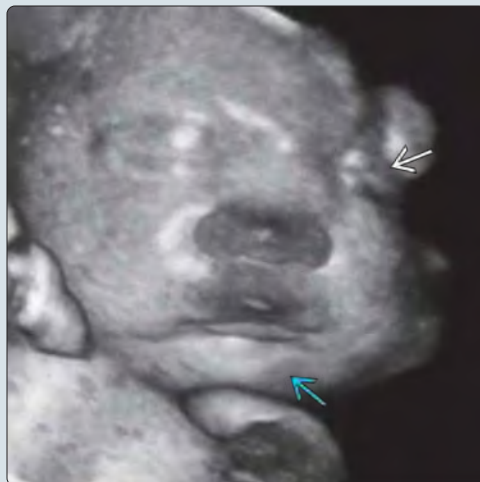- *FLNB*-related disorders







- Phenotypic spectrum from mild (spondylo-carpal-tarsal dysplasia and Larsen syndrome) to severe (atelosteogenesis types 1 and 3 and boomerang dysplasia)
- Sulfate transporter *SLC26A2* (*DTDST*)-related disorders
 - Allelic disorders ranging from mild (multiple epiphyseal dysplasia and diastrophic dysplasia) to perinatal lethal (achondrogenesis 1B, atelosteogenesis II, de la Chapelle dysplasia)

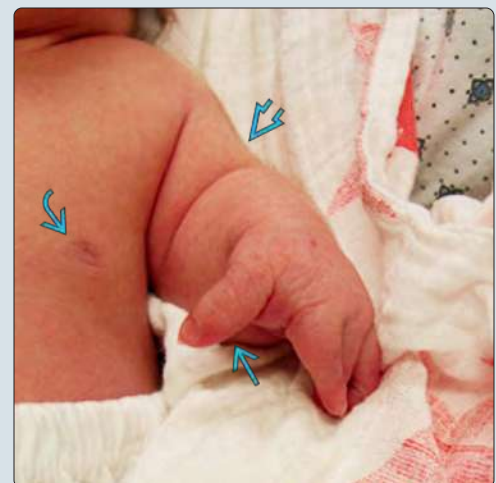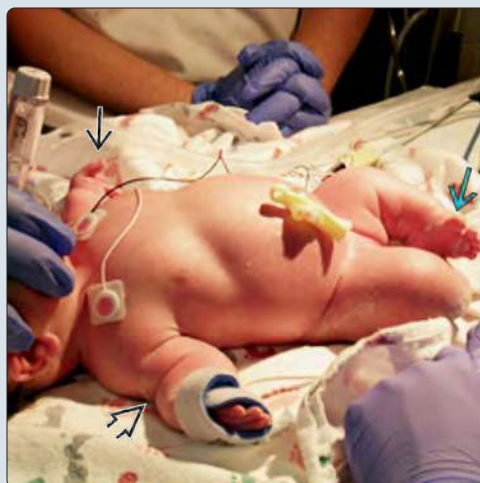CLINICAL ISSUES

- Atelosteogenesis types 1 and 2: Most are stillborn or die of cardiorespiratory failure in neonatal period
- Atelosteogenesis type 3: Compatible with longer term survival
 - Chronic respiratory problems and recurrent infections, related to laryngotracheomalacia
 - Conductive hearing loss, joint dislocations

(Left) Third-trimester 3D ultrasound of a fetus with type 2 atelosteogenesis is shown here. Note the small mouth, micrognathia , and protuberant eyes . The face is relatively round in appearance. Of all these features, micrognathia is the most consistent and most easily seen throughout gestation on prenatal ultrasound. (Right) Same fetus with type 2 atelosteogenesis shows the significant micrognathia , prominent nasal root , and prominent eyes .



(Left) Term neonate with type 2 atelosteogenesis illustrating significant micromelia  is shown. Note the clubfoot and the medially deviated great toe . A persistently abducted thumb  was also easily seen. (Right) Term neonate with type 2 atelosteogenesis shows the persistently abducted ("hitchhiker") thumb . Also note the micromelia , short trunk and neck, and hypoplastic nipple .



TERMINOLOGY**Definitions**

- Rhizomelic short limb skeletal dysplasia

IMAGING**Ultrasonographic Findings**

- Rhizomelic limb shortening with disproportionately shortened and tapered humeri
- Flat midface
- Deficient ossification of long bones, posterior spine
 - Not as prominent on ultrasound as on postnatal radiographs

Radiographic Findings

- **Atelosteogenesis type 1**
 - Distal hypoplasia/tapered humerus, femur
 - Short bowed radius, ulna with hypo-/aplasia of fibula
 - Spine with hypoplastic vertebrae, coronal clefts
 - Short broad tubular bones, partially unossified metacarpals and phalanges
- **Atelosteogenesis type 2**
 - Micromelia with flared metaphyses, distal tapering, bowed radius, ulna
 - Globular shape of 1st metatarsal and metacarpal
 - Proximally implanted "hitchhiker" thumb
 - Talipes equinovarus with widely spaced 1st-2nd toes
- **Atelosteogenesis type 3**
 - Small vertebral bodies, coronal clefts (thoracic and lumbar spine), sagittal clefts (thoracic spine)
 - Flared iliac wings, dislocated hips
 - Disproportionately short humerus, femur with distal tapering
 - Short, bowed tibia; fibula hypoplastic
 - Short, broad phalanges with short 3rd metacarpal

Imaging Recommendations

- Best imaging tool
 - Endovaginal ultrasound in high-risk families
- Protocol advice
 - Use of fetal MR, 3D/4D ultrasound may provide additional diagnostic information

DIFFERENTIAL DIAGNOSIS**FLNB-Related Disorders**

- Phenotypic spectrum from mild (spondylo-carpal-tarsal dysplasia and Larsen syndrome) to severe (atelosteogenesis types 1 and 3 and "boomerang" dysplasia)
- **"Boomerang" dysplasia**
 - Micromelia, severe
 - Boomerang-shaped, long tubular bones
 - Decreased ossification of long bones, spine
 - Hypertelorism, micrognathia, cleft palate, omphalocele, polyhydramnios
- **Larsen syndrome**
 - Congenital joint dislocations of hips, elbows, knees; clubfeet
 - Kyphoscoliosis
 - Macrocephaly with frontal bossing, cleft palate

Sulfate Transporter *SLC26A2* (*DTDST*)-Related Disorders

- Allelic disorders ranging from mild (multiple epiphyseal dysplasia and diastrophic dysplasia) to perinatal lethal (achondrogenesis 1B, atelosteogenesis 2, de la Chapelle dysplasia)
- Genotype-phenotype correlation possible in some cases where compound heterozygote of mild and severe mutation results in phenotype of intermediate severity
- **Diastrophic dysplasia**
 - Short stature, short extremities, multiple joint contractures
 - Clubfeet with widely spaced 1st-2nd toes
 - Proximally implanted "hitchhiker" thumbs
 - Cleft palate (50%)
- **Achondrogenesis 1B**
 - Deficient ossification skull, spine
 - Severe micromelia

PATHOLOGY**General Features**

- Genetics
 - Atelosteogenesis types 1 and 3 autosomal dominant
 - Mutations in *FLNB* (3p14.3)
 - Atelosteogenesis type 2 autosomal recessive
 - Mutations in diastrophic dysplasia sulfate-transporter gene *SLC26A2* (*DTDST*) (5q32-33)
 - Prenatal diagnosis possible by chorionic villus sampling/amniocentesis in families with known mutation
- Associated abnormalities
 - Pulmonary hypoplasia
 - Midface hypoplasia with depressed nasal bridge, micrognathia, cleft palate
 - Short broad hands, clubfeet, joint dislocations
 - Laryngotracheomalacia, laryngeal stenosis

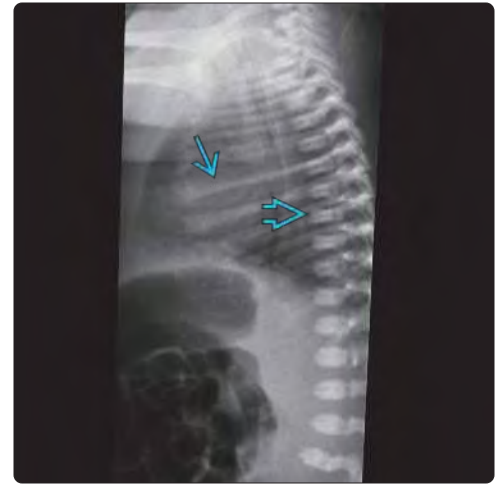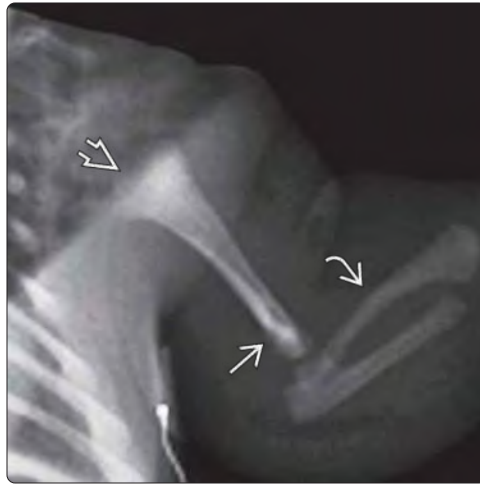CLINICAL ISSUES**Natural History & Prognosis**

- Atelosteogenesis types 1 and 2: Most are stillborn or die of cardiorespiratory failure in neonatal period
- Atelosteogenesis type 3: Compatible with longer term survival
 - Short stature common
 - Chronic respiratory problems and recurrent infections, related to laryngotracheomalacia
 - Conductive hearing loss, joint dislocations

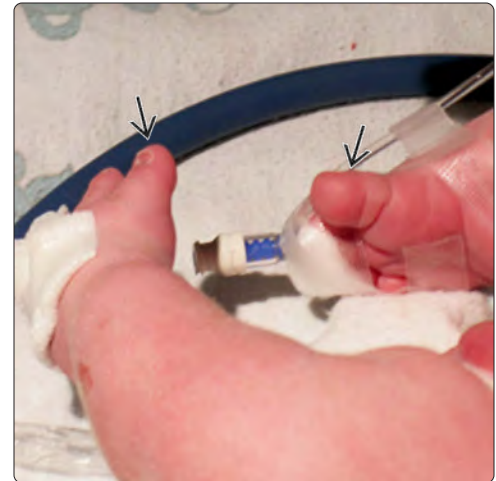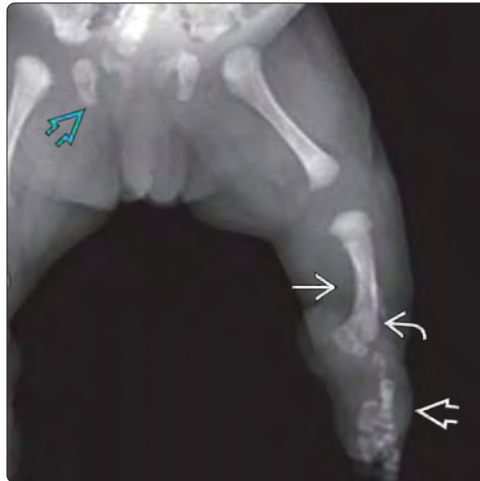SELECTED REFERENCES

1. Jeon GW et al: Identification of a de novo heterozygous missense *FLNB* mutation in lethal atelosteogenesis type I by exome sequencing. *Ann Lab Med.* 34(2):134-8, 2014
2. Wessels A et al: Atelosteogenesis type I: autopsy findings. *Pediatr Dev Pathol.* 14(6):496-500, 2011
3. Dwyer E et al: Genotype-phenotype correlation in *DTDST* dysplasias: Atelosteogenesis type II and diastrophic dysplasia variant in one family. *Am J Med Genet A.* 152A(12):3043-50, 2010
4. Farrington-Rock C et al: Mutations in two regions of *FLNB* result in atelosteogenesis I and III. *Hum Mutat.* 27(7):705-10, 2006
5. Krakow D et al: Mutations in the gene encoding filamin B disrupt vertebral segmentation, joint formation and skeletogenesis. *Nat Genet.* 36(4):405-10, 2004

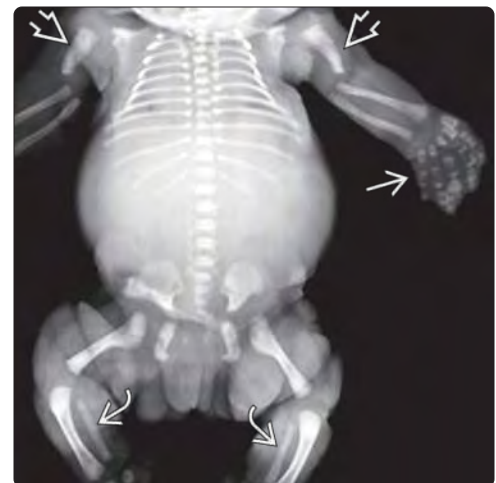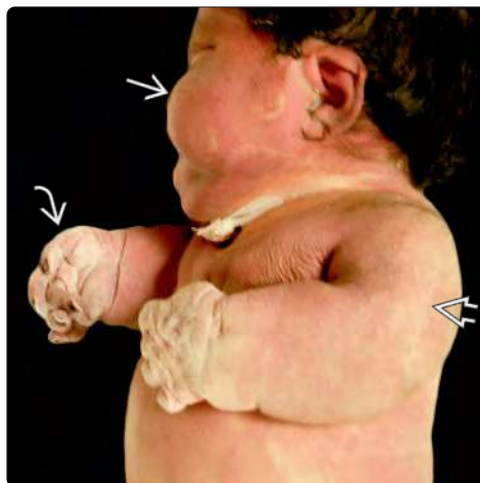(Left) Term neonate with type 2 atelosteogenesis shows the characteristic findings of a hypoplastic and tapered humerus and flared metaphysis. The radius is also curved. The tapered humerus is difficult to see by prenatal ultrasound where the bone may just appear short. (Right) Term neonate with type 2 atelosteogenesis shows straight but mildly shortened ribs and hypoplastic and widely spaced vertebral bodies.

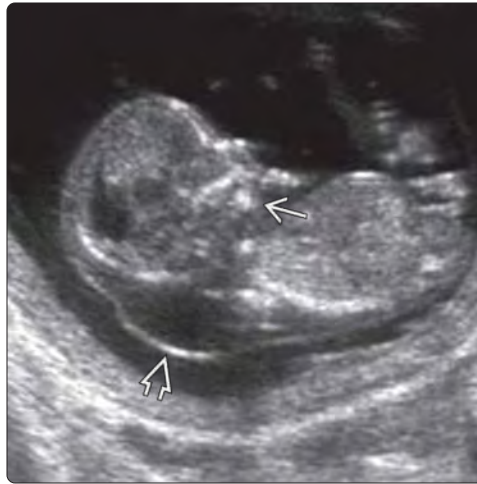
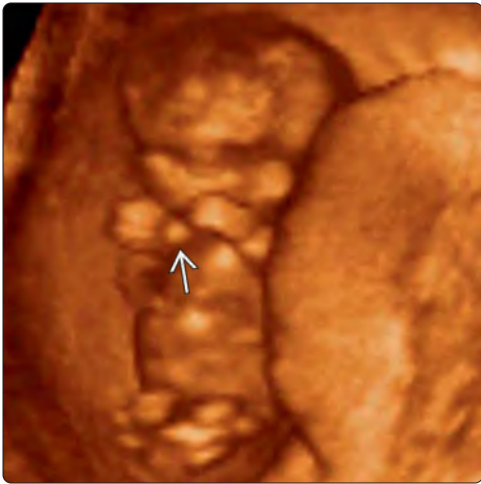
(Left) Term neonate with type 2 atelosteogenesis with a hypoplastic pelvis, short long bones, fibular aplasia, and curved tibia is shown here. Equinovarus deformity is also seen. On prenatal ultrasound, the fibulae may appear short and thin or absent. Clubfeet are almost always seen. (Right) Note the clubfeet and medially deviated toes in this newborn with type 2 atelosteogenesis. On radiography, the 1st metatarsal and metacarpal are globular-shaped.

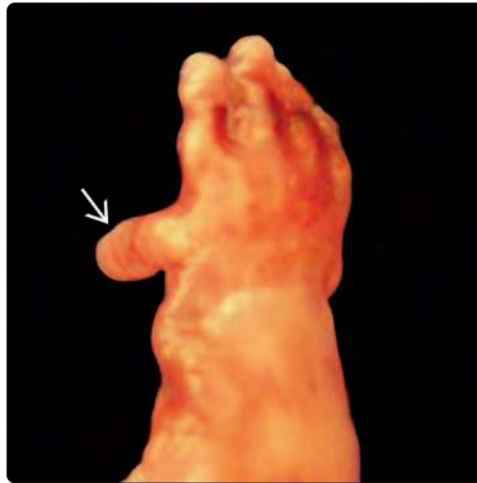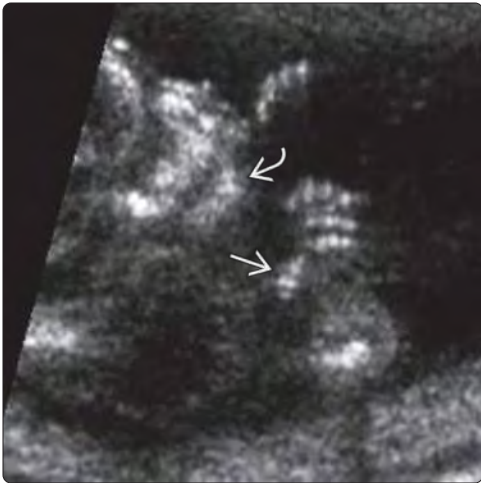


(Left) In a stillborn with type 3 atelosteogenesis, short humeri, severe midface hypoplasia, short neck, and tracheal atresia were present. Note the normal (nonabducted) thumbs. (Right) Radiograph of a newborn with type 3 atelosteogenesis shows characteristic skeletal findings. The humeri are disproportionately short and tapered. Short femora, bowed tibiae, and hypoplastic fibulae are also seen. The phalanges are short and square. Dedicated hand views showed a short 3rd metacarpal.

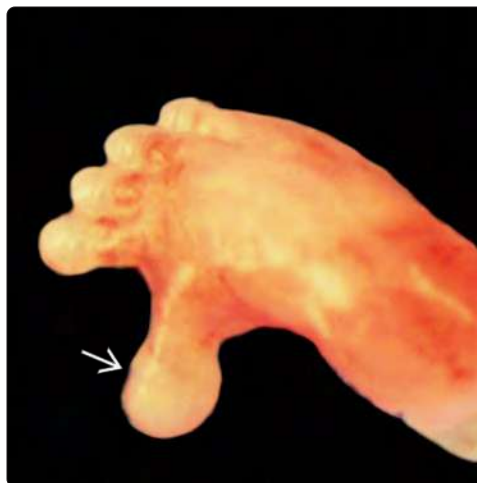
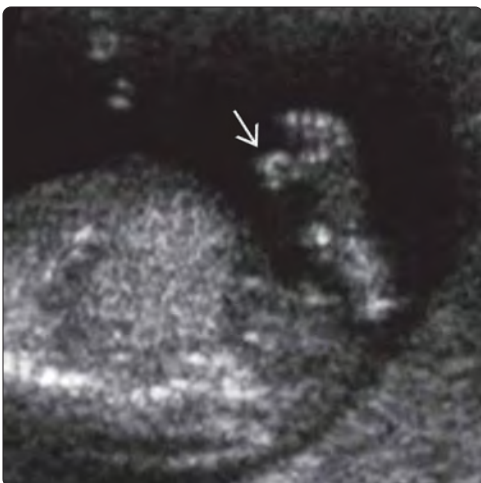



(Left) Thirteen-week fetus in a pregnancy at risk for autosomal recessive type 2 atelosteogenesis shows a deviated ("hitchhiker") thumb ➤. **(Right)** A large cystic hygroma ➤ and significant micrognathia ➤ are seen in this 13-week embryo with recurrent type 2 atelosteogenesis. Although nonspecific, a cystic hygroma (or increased nuchal translucency) is a relatively common finding in 1st-trimester skeletal dysplasias. In this sagittal view, the micrognathia can be easily seen.



(Left) "Hitchhiker" thumb ➤ and micrognathia ➤ are seen in this 13-week fetus with type 2 atelosteogenesis. In pregnancies at risk for this disorder due to a previous child and autosomal recessive inheritance, the diagnosis can be made, or at least strongly suspected, even in the 1st trimester. **(Right)** Clinical correlation of the previous ultrasound findings in a D&E specimen is shown here. Note the "hitchhiker" thumb ➤. Confirmation of the prenatal findings was possible in this case, even on a nonintact specimen.



(Left) Medially deviated toe ➤ results in widely spaced 1st and 2nd toes in the same 13-week fetus with recurrent type 2 atelosteogenesis. Careful evaluation of the hands and feet on prenatal ultrasound can help make this diagnosis in a fetus at increased risk. **(Right)** Correlative D&E specimen shows the medially deviated great toe ➤ and equinovarus deformity. This is a relatively extreme example of the appearance of the foot in this condition.

KEY FACTS

TERMINOLOGY

- Campomelia = bowed limbs
- Rare, semilethal osteochondrodystrophy

IMAGING

- Normal ossification without fractures
- Anterolaterally bowed femora, tibiae
 - Hypoplastic fibulae
- Hypoplastic scapulae is hallmark finding
- Disorder of sexual development
 - XY sex reversal (male to female)
- Bell-shaped chest, usually mild
- Midface hypoplasia

TOP DIFFERENTIAL DIAGNOSES

- Osteogenesis imperfecta
- Kyphomelic dysplasia
- Acampomelic campomelic dysplasia
- Femur-fibula-ulna complex

- Fibular hemimelia

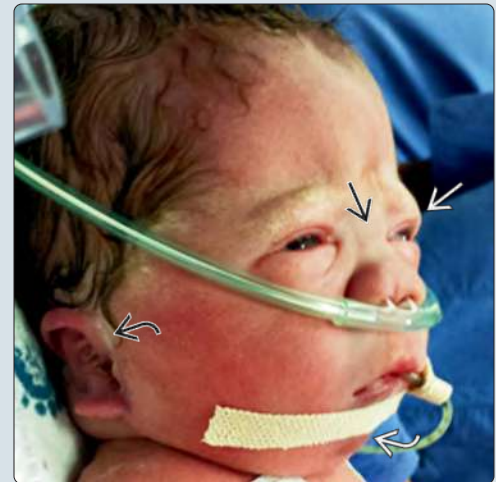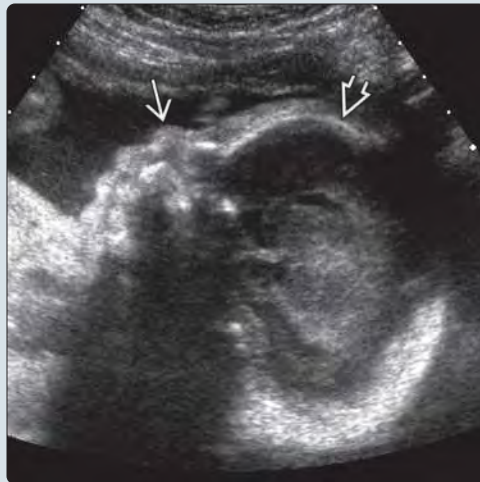PATHOLOGY

- Haploinsufficiency of *SOX9*
 - Key regulator in cartilage differentiation and early testis development
 - Airway cartilage also affected
 - Tracheobronchomalacia may be severe and adversely affects respiratory status

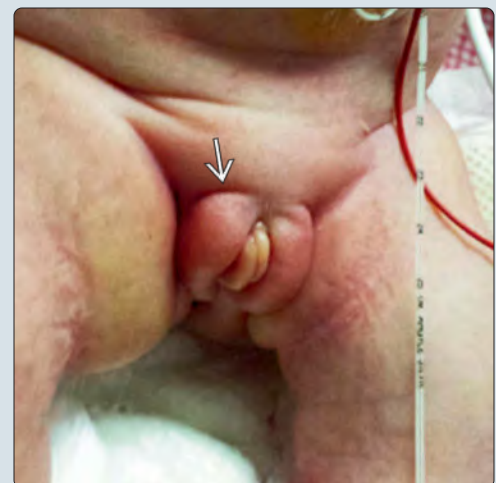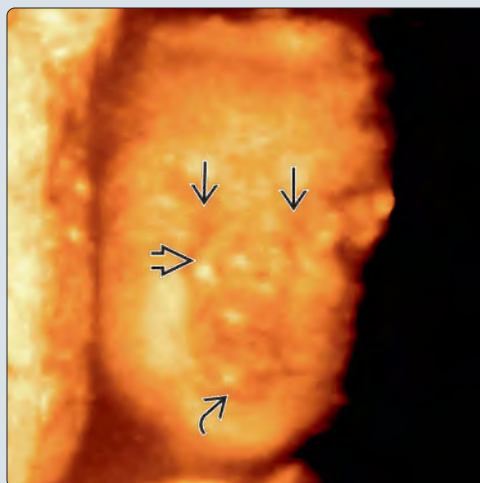
CLINICAL ISSUES

- Preponderance of phenotypic female patients due to XY sex reversal
 - 3/4 of male patients are sex reversed (appear phenotypically female) or have ambiguous genitalia
- Most die in infancy due to respiratory insufficiency
- Occasional longer term survivors
- Considered sporadic dominant
 - Recurrences attributed to gonadal mosaicism

(Left) Sagittal ultrasound of a late 2nd-trimester fetus with campomelic dysplasia shows midface hypoplasia with a short nasal tip [A]. Normal skull ossification is noted [B]. (Right) In this newborn infant with campomelic dysplasia, midface hypoplasia [C] is seen as well as proptotic eyes [D]. Mild micrognathia [E] and low-set ears [F] are also noted. The mouth is usually small and the neck short. The head may appear disproportionately large.



(Left) Coronal 3D ultrasound shows the appearance of the face in a fetus with campomelic dysplasia. Hypertelorism is noted [A] with a flattened midface, short nose [B], and small mouth with prominent lips [C]. (Right) External genitalia [D] of a newborn with campomelic dysplasia is shown. Although the infant generally appeared female and had a uterus by pelvic ultrasound, the karyotype was 46,XY. 50-70% of male infants with campomelic dysplasia exhibit sex reversal and are phenotypically female.



TERMINOLOGY**Definitions**

- Campomelia = bowed limbs
- Rare, semilethal osteochondrodystrophy
- Characterized by bowed extremities with absence of fractures, cutaneous dimpling, hypoplastic scapulae, sex reversal in male patients

IMAGING**Ultrasonographic Findings**

- Severe angulation of femora, tibiae, fibulae
 - Fibulae are usually hypoplastic
- Disorder of sexual development (ambiguous genitalia)
 - XY sex reversal (male to female)
- Hypoplastic scapulae
- No fractures
- Bell-shaped chest, usually mild
- Midface hypoplasia
- Micrognathia
- Clubfeet
- 1st-trimester increased nuchal translucency or cystic hygroma common

Postnatal Radiographic Findings

- Normal to mildly deficient ossification without fractures
- Anterolaterally bowed femora, tibiae
- Thoracic kyphoscoliosis
- Absent/delayed ossification of thoracic pedicles
- Hypoplastic scapulae consistent finding
- 11 pairs of ribs, may be misshapen

DIFFERENTIAL DIAGNOSIS**Osteogenesis Imperfecta**

- Decreased mineralization of skull, long bones
- Fractures are prominent feature

Kyphomelic Dysplasia

- Scapulae are normal
- Primarily femoral involvement

Acampomelic Campomelic Dysplasia

- Absence of bowing of extremities
- Hypoplastic scapulae

Femur-Fibula-Ulna Complex

- Short-limb dwarfism
- Varying degrees of femoral and fibular deficiency, upper limb abnormality

Fibular Hemimelia

- Absence of fibulae with defects in femora, tibiae, feet

PATHOLOGY**General Features**

- Etiology
 - Haploinsufficiency of *SRY*-related gene (*SOX9*)
 - *SOX9*: Transcription factor
 - Located at 17q24.3-q25.1

- Key regulator in cartilage differentiation and early testis development
- Milder phenotype, longer survival in some cases
- Genetics
 - Sporadic autosomal dominant
 - Recurrences likely due to gonadal mosaicism
 - Rare cases of mild phenotypic features in parent attributed to possible somatic mosaicism
- Associated abnormalities
 - Airway cartilage also affected
 - Tracheobronchomalacia very common and complicates respiratory status

CLINICAL ISSUES**Presentation**

- Most common signs/symptoms
 - Symmetric angulation of femora, tibiae, and fibulae
 - Hypoplastic scapulae
 - Female genitalia or ambiguous genitalia
- Other signs/symptoms
 - Cutaneous dimpling, especially pretibial on neonatal exam

Demographics

- Gender
 - Chromosomal sex ratio 1:1
 - Preponderance of phenotypic females due to XY sex reversal
 - 3/4 of male patients are sex reversed (appear phenotypically female) or have ambiguous genitalia
- Epidemiology
 - 0.05-1.60 per 10,000 live births

Natural History & Prognosis

- Most die in infancy due to respiratory insufficiency
- Occasional longer term survivors
- Tracheobronchomalacia may be severe

Treatment

- No prenatal treatment
- Delivery in tertiary care facility
 - Risk of respiratory insufficiency
 - Expertise in genetic fetopathology, skeletal dysplasias
- Orthopedic treatment of musculoskeletal abnormalities in survivors

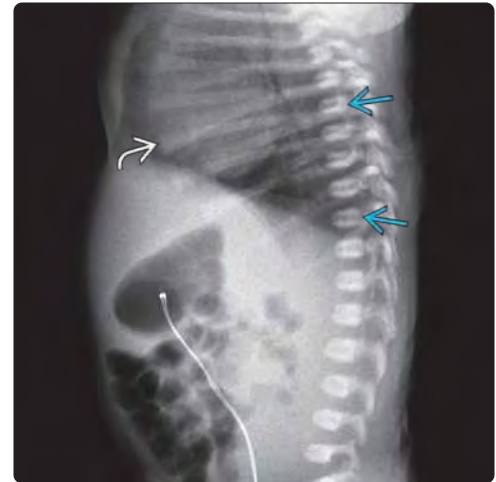
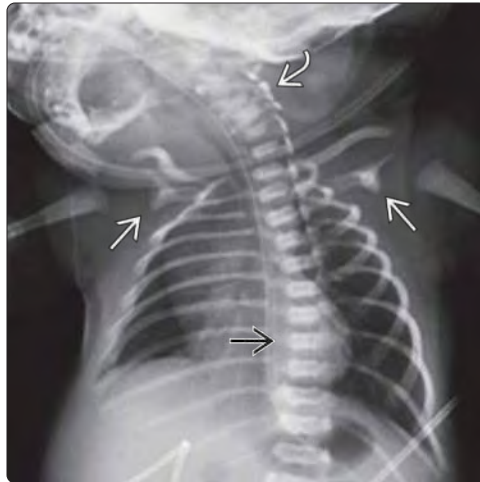DIAGNOSTIC CHECKLIST**Image Interpretation Pearls**

- Angulation of lower extremity bones with absent or hypoplastic scapulae

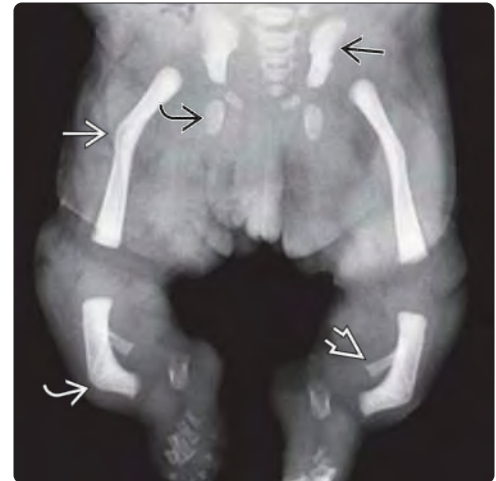
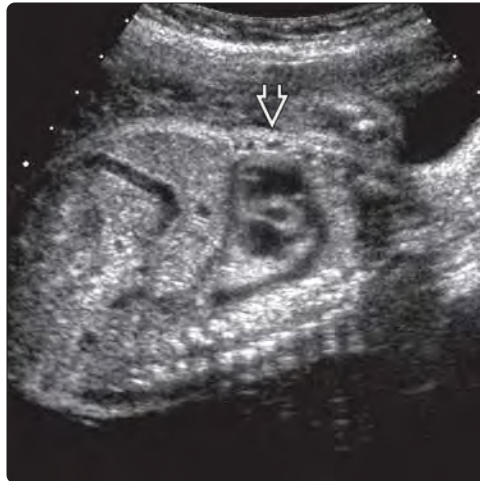
SELECTED REFERENCES

1. Jo A et al: The versatile functions of Sox9 in development, stem cells, and human diseases. *Genes Dis.* 1(2):149-161, 2014
2. Akiyama H et al: Unraveling the transcriptional regulatory machinery in chondrogenesis. *J Bone Miner Metab.* 29(4):390-5, 2011
3. Lee YH et al: Sox9 function in craniofacial development and disease. *Genesis.* 49(4):200-8, 2011
4. Harley VR: The molecular action of testis-determining factors SRY and SOX9. *Novartis Found Symp.* 244:57-66; discussion 66-7, 79-85, 253-7, 2002

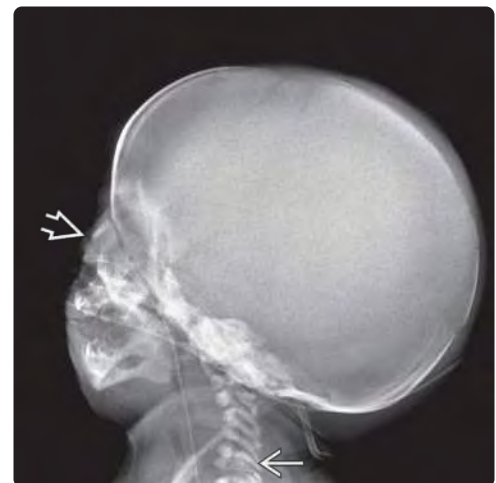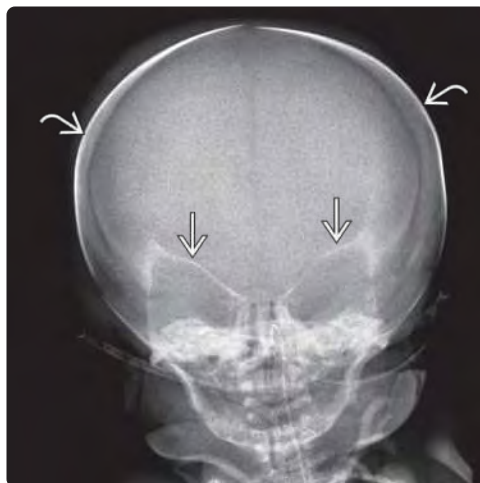
(Left) Radiograph of a term infant with campomelic dysplasia is shown. The scapulae are significantly hypoplastic, a classic finding in > 95% of infants with campomelic dysplasia. There are segmentation abnormalities in the cervical spine and hypoplastic transverse processes of the thoracic spine. Only 11 pairs of ribs are seen, also a common finding. **(Right)** Lateral radiograph of another infant shows mild platyspondyly with near-normal ribs. No fractures are noted, and the ribs are straight.

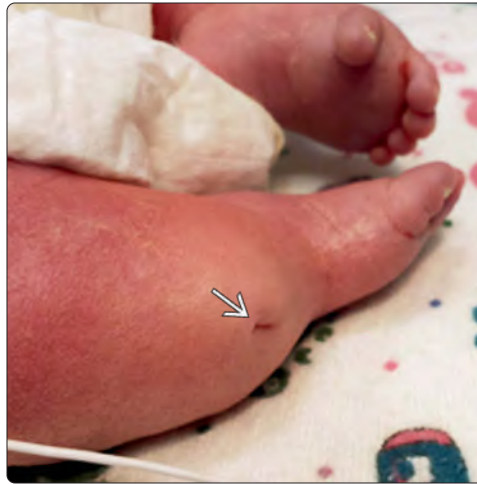
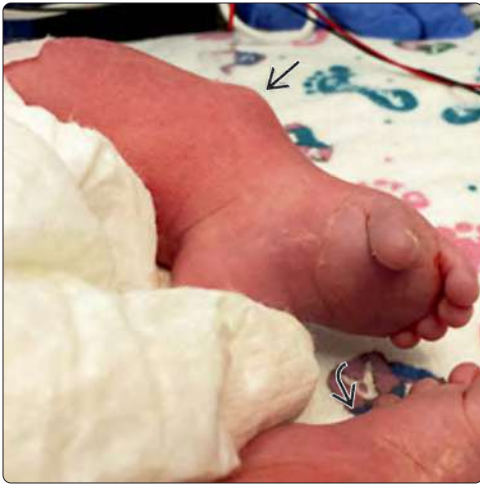




(Left) Sagittal ultrasound shows a slightly small chest in a 3rd-trimester fetus with campomelic dysplasia. The thoracic cavity is often not as severely affected as in some of the other skeletal dysplasias. **(Right)** Radiograph of a term infant with campomelic dysplasia illustrates classic findings, including bowed femora and severely angulated tibiae. The fibulae are hypoplastic. The pelvis is hypoplastic, and the ilia are vertically oriented.

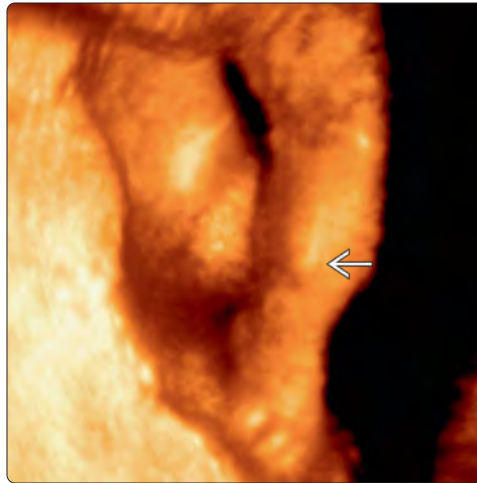
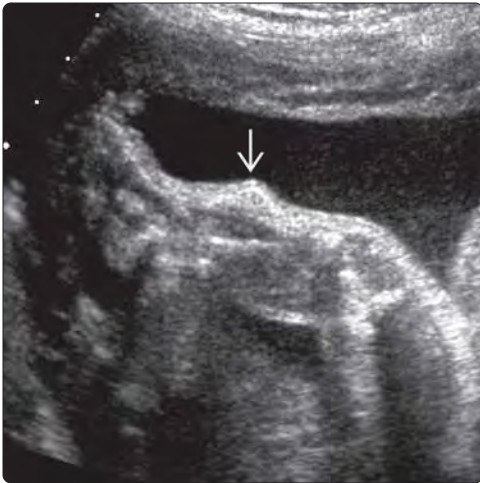




(Left) Anteroposterior radiograph of a newborn with campomelic dysplasia shows a very round calvarium. The orbital roofs are upslanting. **(Right)** Lateral radiograph of the same infant shows normal to mildly deficient ossification of the calvarium. Midface hypoplasia is also noted. Cervical vertebral fusion defects are also present in this case.

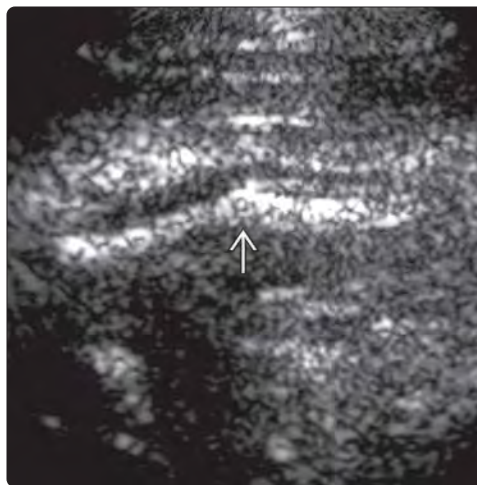
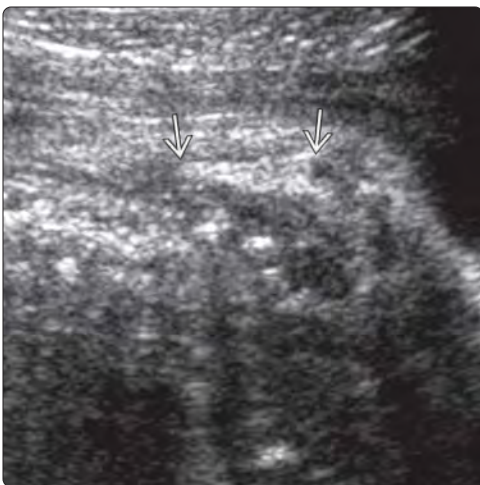






(Left) Severe anterior angulation of the tibia  is seen in this newborn with campomelic dysplasia. This can be seen on ultrasound and is an important clue in the prenatal diagnosis of this disorder. Both feet are clubbed , also a common finding. **(Right)** A prominent skin dimple  is seen and is located over the palpable tibial angulation. This is a very common finding in infants with campomelic dysplasia.



(Left) Ultrasound of a 3rd-trimester fetus shows the anterior bowing of the lower extremity with a sharp angulation . Other findings included bilateral club feet and hypoplastic scapulae. **(Right)** 3D ultrasound shows the typical midshaft angulation of the tibia . This is usually bilateral and symmetrical. A deep skin dimple is usually seen in the infant over the protuberance of the tibia.



(Left) Ultrasound shows a scapula that is present but hypoplastic  in this fetus with campomelic dysplasia. In the evaluation of the scapula in a fetus, the spine of the scapula and acromion are often present and near normal in size. The scapula should be measured in a sagittal or coronal plane from superior to inferior, as shown. **(Right)** Ultrasound shows femoral angulation  in a midtrimester fetus with campomelic dysplasia. Ossification is normal, and there are no fractures.

Chondrodysplasia Punctata

KEY FACTS

TERMINOLOGY

- Etiologic and genetically heterogeneous group of osteochondrodystrophies associated with punctate calcifications (stippled epiphyses) of long bones and spine, and maxillonasal hypoplasia
- Associated with single gene disorders, maternal conditions, metabolic abnormalities, chromosome abnormalities, and teratogen exposures

IMAGING

- Punctate calcifications involving epiphyses of long bones &/or spine
- Limb shortening
- Severe midface hypoplasia with flat nasal bridge

TOP DIFFERENTIAL DIAGNOSES

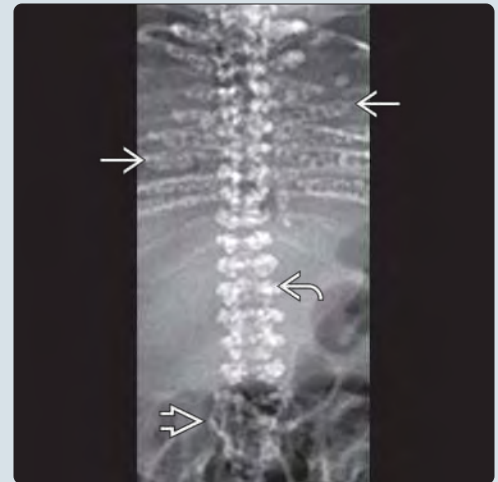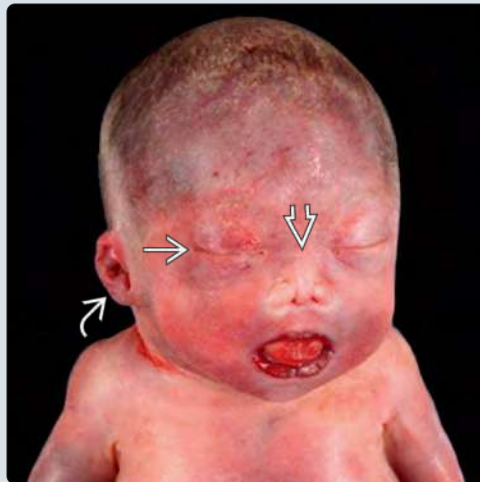- Chondrodysplasia punctata, rhizomelic type (RCDP1)
- Conradi-Hünermann syndrome (CDPX2)

- Chondrodysplasia punctata, brachytelephalangic type (CDPX1)
- Congenital hemidysplasia, ichthyosis, limb defects (CHILD syndrome)
- Other conditions associated with calcific stippling of epiphyses
 - Maternal collagen vascular disease
 - Maternal diabetes
 - Vitamin K deficiency
 - Warfarin (Coumadin) embryopathy
 - Binder maxillonasal dysplasia
 - Zellweger syndrome spectrum
 - Chromosomal

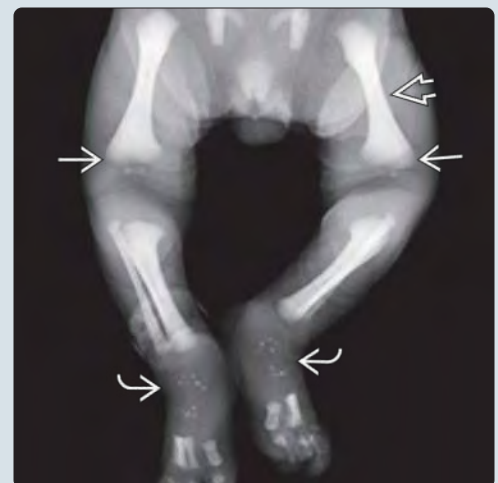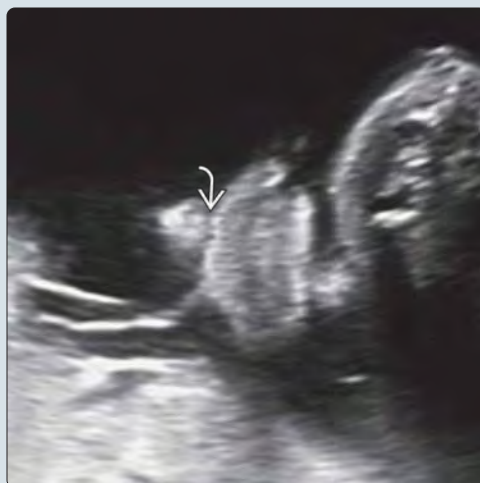DIAGNOSTIC CHECKLIST

- Punctate calcifications best seen in coronal plane focusing on area of joints, along spine
- Severe midface hypoplasia with shortened limbs → look for epiphyseal calcifications

(Left) Clinical photograph shows an infant with X-linked dominant Conradi-Hünermann syndrome. Note the midface hypoplasia with severe nasal hypoplasia. The palpebral fissures are mildly slanted and the ears are small. The neck is also quite short. (Courtesy D. Twickler, MD.)
(Right) Radiograph shows the spine of a neonate with Conradi-Hünermann syndrome. Note the extensive punctate calcifications involving the proximal ribs, spine, and pelvis. (Courtesy D. Twickler, MD.)



(Left) Coronal ultrasound shows a short columella with the tip of nose almost touching upper lip in 3rd-trimester fetus with severe nasal hypoplasia and chondrodysplasia punctata.
(Right) Radiograph shows the lower extremities of the same infant after birth. Mildly shortened long bones with flared metaphyses are seen. Stippled epiphyses are noted bilaterally in the ankles. In this case, the stippling was not visible on prenatal ultrasound.



TERMINOLOGY

Definitions

- Etiologic and genetically heterogeneous group of osteochondrodystrophies associated with punctate calcifications (stippled epiphyses) of long bones and spine and severe nasal hypoplasia
- Associated with single gene disorders, maternal conditions, metabolic abnormalities, chromosome abnormalities, and teratogen exposures

IMAGING

Ultrasonographic Findings

- Punctate calcifications involving epiphyses of long bones &/or spine
 - Epiphyseal stippling may not be visualized until late 2nd-3rd trimesters
 - Limb shortening, especially proximal segments
- Severe midface hypoplasia with flat nasal bridge
- Hydrops, polyhydramnios in Conradi-Hünemann

Radiographic Findings

- Rhizomelic chondrodysplasia punctata (RCDP)
 - Disproportionate short stature with proximal shortening of humeri ± femora
 - Splayed metaphyses (especially knee)
 - Punctate calcifications of epiphyses in infancy → epiphyseal irregularity
 - Coronal cleft of vertebral bodies seen on lateral spine x-ray; vertebrae irregular
 - Multiple joint contractures
 - Trapeziform upper ilium
- Conradi-Hünemann (X-linked dominant CDP)
 - Asymmetric shortening of long bones related to areas of epiphyseal calcifications
 - Joint contractures
 - Scoliosis
 - Occasional: Tracheal calcifications, dislocated patella, cleft or absent vertebral bodies

Imaging Recommendations

- Protocol advice
 - High-risk families: Search carefully for punctate calcifications, flat facial profile and limb shortening
 - Radiographic, biochemical/molecular confirmation in neonate essential for counseling

DIFFERENTIAL DIAGNOSIS

Chondrodysplasia Punctata, Rhizomelic Type (RCDP1)

- Autosomal recessive
- Genetically heterogeneous
- 3 types: Clinically indistinguishable, involve abnormalities of peroxisomal metabolism with deficiency of plasmalogens (function unknown); type 1 is peroxisomal biogenesis disorder while types 2 and 3 involve single peroxisome enzyme deficiencies
 - Type 1: Mutations in *PEX7* (6q22.4-24)
 - Type 2: Mutations in *DHPAT* gene encoding dihydroxyacetone phosphate acyltransferase (1q42)

- Type 3: Mutations in *AGPS* gene encoding alkylglycerone-phosphate synthase (2q31)
- Biochemical indicators suggestive of peroxisomal abnormality
 - Deficient red cell concentration of plasmalogens, elevated plasma concentration of phytanic acid in presence of normal plasma concentration of very long chain fatty acids
- Rhizomelic shortening of humerus and (to lesser extent) femur
- Profound postnatal growth deficiency
- Microcephaly with severe mental retardation
- Seizures (80%)
- Typical facial appearance with flat nasal bridge, ± upslanting palpebral fissures, dysplastic ears
- Cataracts: 72%; usually bilateral, symmetric
- Ichthyosis: 28%
- Occasional: Cardiac defects, CNS abnormalities, genital abnormalities, cleft palate

Conradi-Hünemann Syndrome (CDPX2)

- a.k.a. Conradi-Hünemann-Happle syndrome
- X-linked dominant: Usually lethal in males
- Mutations in emopamil-binding protein (EBP) (Xp11.23); disorder characterized by abnormal cholesterol synthesis
- Flat face with low nasal bridge, hypoplastic malar eminence
- Cataracts
- Asymmetric short limbs, joint contractures
- Scoliosis
- Thick adherent skin scales, especially in infancy; large pores and ichthyosis later
 - Skin lesions symmetrical, follow Blaschko lines
- Coarse, sparse hair with patchy alopecia
- Occasional: Microphthalmia, glaucoma, developmental delay, tracheal stenosis, cardiac defects, polydactyly

Chondrodysplasia Punctata, Brachytelephalangi Type (CDPX1)

- X-linked recessive
- ~ 25% have deletions or translocations involving Xp22.3
- Mutations in gene for arylsulfatase E (ARSE)
- Most affected males with minimal morbidity; improvement of skeletal abnormalities in adulthood
- Distal phalangeal hypoplasia (brachytelephalangy)
- Nasomaxillary hypoplasia
- Some with significant medical issues including respiratory compromise, cervical spine instability/stenosis, hearing loss
- Other manifestations include CDP, short stature, microcephaly, delayed development, cataracts, hearing loss, ichthyosis due to steroid sulfatase deficiency

Congenital Hemidysplasia, Ichthyosis, Limb Defects (CHILD Syndrome)

- X-linked dominant; lethal in males
- Majority sporadic, but rare familial (mother/daughter) cases reported
- Mutations in NAD(P)H steroid dehydrogenase-like gene (Xp28); also cases with EBP mutation (Xp11)
- Unilateral hypomelia ranging from amelia to mild hypoplasia of digits
- Unilateral ichthyosiform skin lesion with demarcation at midline; face not involved

- Hypoplasia of bones ipsilateral to skin lesion, joint contractures
- Punctate calcifications of epiphyses in infancy
- Cardiac defects; often cause of early death

Greenberg Dysplasia

- Autosomal recessive
- Mutation in lamin B receptor, 3-beta-hydroxysterol delta (14)-reductase (1q42.1)

Other Conditions Associated With Calcific Stippling of Epiphyses

- **Maternal conditions**
 - Maternal collagen vascular disease
 - Originally reported in offspring of patient with systemic lupus erythematosus
 - Noncardiac manifestations of neonatal lupus more common than the cardiac manifestations
 - Subsequently described in offspring (including siblings) of mothers with scleroderma and mixed connective tissue disorder
 - Attributed to placental transmission of maternal autoantibodies (anti-Ro, anti-La, anti RNP) that affect normal development of fetal growth plates
 - Maternal diabetes
 - Vitamin K deficiency
 - Bariatric procedures
 - Hyperemesis gravidarum, severe
- **Embryopathy**
 - Warfarin (Coumadin)
 - Critical timing of exposure: 6-9 weeks post fertilization
 - Severe nasal hypoplasia, rhizomelia
 - Congenital rubella
 - Alcohol embryopathy
 - Hydantoin embryopathy
- **Binder maxillonasal dysplasia**
 - Nasal hypoplasia phenotype associated with many cases of CDP
 - Vitamin K deficiency suspected in some cases
- **Zellweger syndrome spectrum**
 - Autosomal recessive
 - Mutations in 12 different *PEX* genes identified
 - Very long chain fatty acid levels (initial screen)
 - Phenotypic spectrum of peroxisome biogenesis disorders, most severe being Zellweger syndrome
 - Distinctive facies, hypotonia, poor feeding, seizures, hepatic dysfunction
 - Punctate stippling of patellae and other long bones
- **Smith-Lemli-Opitz**
 - Defect of cholesterol biosynthesis, autosomal recessive
- **Chromosomal**
 - Trisomy 21
 - Trisomy 18

CLINICAL ISSUES

Presentation

- Most common signs/symptoms
 - Severe maxillonasal hypoplasia often resulting in respiratory distress at birth
 - Short long bones with stippled epiphyses

- More easily seen on postnatal radiographs

- Other signs/symptoms
 - Ichthyosiform skin lesions

Natural History & Prognosis

- CDP rhizomelic type
 - Most do not survive 1st decade of life; some neonatal deaths
 - Major cause of death is respiratory problems
 - Development of scoliosis, seizures, severe feeding problems, cataracts, hearing loss in survivors
 - Resolution of epiphyseal calcifications with development of epiphyseal abnormalities
 - Improvement of joint contractures with time, physical therapy
- CDP Conradi-Hünemann type
 - Frequent infections, often lethal, in infancy; failure to thrive
 - Survival beyond infancy predicts longer term survival
 - Resolution of epiphyseal calcifications by 9 months
 - Development of scoliosis, cataracts in survivors

Treatment

- No prenatal treatment
- Offer genetic counseling
 - Prenatal diagnosis may be available when specific mutation is known
 - Prenatal diagnosis of CDP-rhizomelic type (RCDP1) by assay of plasmalogen biosynthesis
- Postnatal treatment of cataracts for visual stimulation
- Physical therapy
- Treatment of infections
- Dermatologic treatment
 - Etretinate has been used in severe lesions of CHILD syndrome
- Maxillonasal hypoplasia may require surgery in older individuals; nasal stents & oxygen therapy in infants
- Surgical therapy for older individuals with cervical spine stenosis/instability

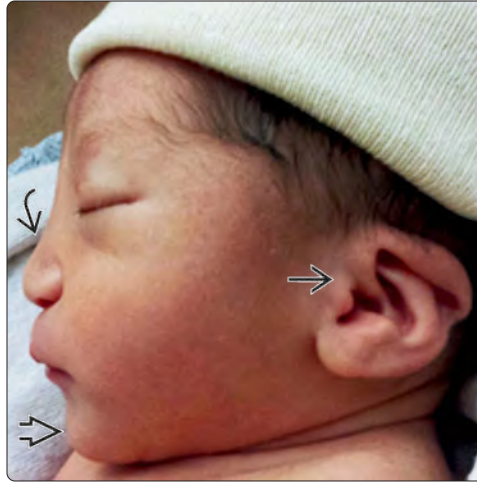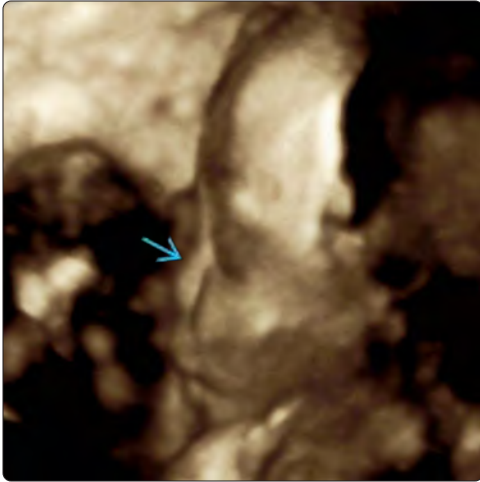
DIAGNOSTIC CHECKLIST

Image Interpretation Pearls

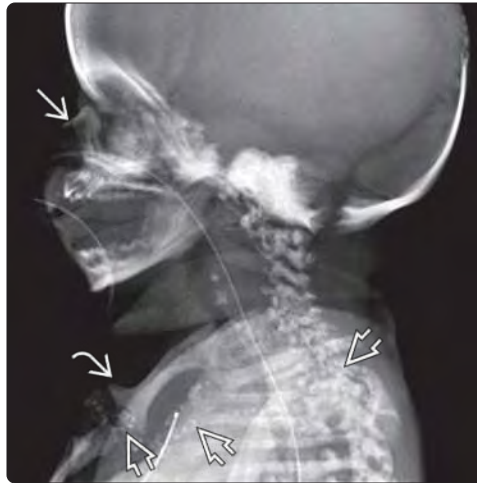
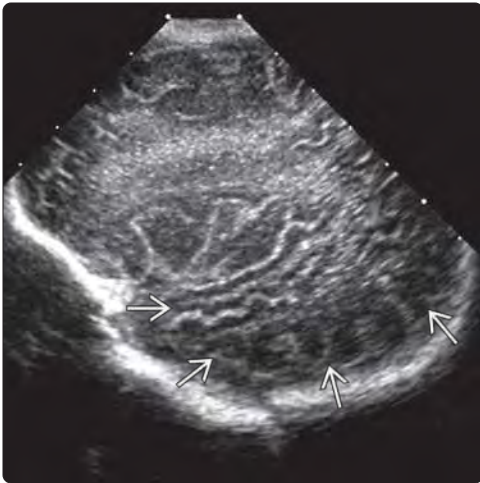
- Punctate calcifications best seen in coronal plane focusing on area of joints, along spine
- Severe mid-face hypoplasia with shortened limbs → look for epiphyseal calcifications
- Short limbs with stippled epiphyses and hydrops → consider Conradi-Hünemann

SELECTED REFERENCES

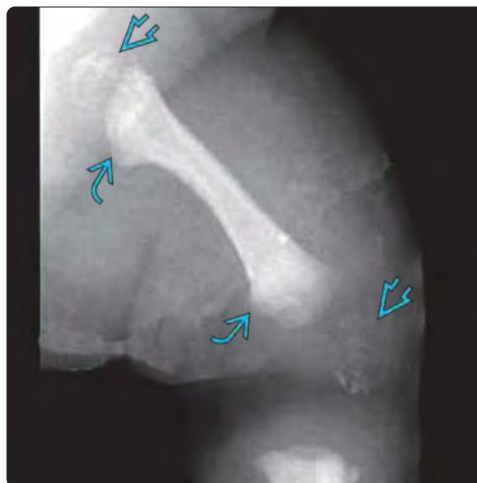
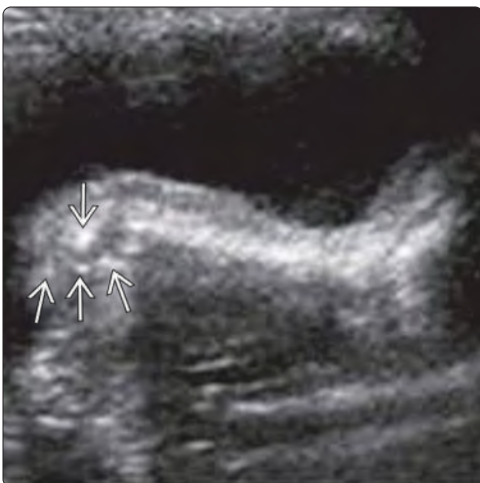
1. Cañueto J et al: The role of the abnormalities in the distal pathway of cholesterol biosynthesis in the Conradi-Hünemann-Happle syndrome. *Biochim Biophys Acta.* 1841(3):336-44, 2014
2. Bams-Mengerink AM et al: The neurology of rhizomelic chondrodysplasia punctata. *Orphanet J Rare Dis.* 8:174, 2013
3. Braverman NE et al: Peroxisome biogenesis disorders: Biological, clinical and pathophysiological perspectives. *Dev Disabil Res Rev.* 17(3):187-96, 2013
4. Cañueto J et al: Clinical, molecular and biochemical characterization of nine Spanish families with Conradi-Hünemann-Happle syndrome: new insights into X-linked dominant chondrodysplasia punctata with a comprehensive review of the literature. *Br J Dermatol.* 166(4):830-8, 2012
5. Waterham HR et al: Genetics and molecular basis of human peroxisome biogenesis disorders. *Biochim Biophys Acta.* 1822(9):1430-41, 2012



(Left) 3D ultrasound shows fetus at 31 weeks with significant nasal hypoplasia [↖]. Shortened limbs (4-5 standard deviations below the mean) were apparent from the midtrimester. The mother had a history of mixed connective tissue disease. (Right) Clinical photograph of the same infant born at term with severe nasal hypoplasia [↖] and midface hypoplasia. Note the low-set, posteriorly rotated ear [↖] with overfolded helix and prominent antihelix. There is mild micrognathia [↖] as well as short long bones.



(Left) Parasagittal head ultrasound of a newborn infant with chondrodysplasia punctata, rhizomelic type shows an irregular gyral pattern in the temporal lobe, concerning for polymicrogyria [↖]. This is a migration abnormality commonly seen in this disorder. (Right) Lateral radiograph of a newborn with rhizomelic chondrodysplasia punctata shows several features of the disorder. Severe nasal hypoplasia [↖] and punctate calcifications [↖] are seen. A shortened humerus with flared metaphysis [↖] is also seen.



(Left) Ultrasound of the knee of a fetus with rhizomelic chondrodysplasia punctata shows multiple punctate calcifications [↖]. Epiphyseal calcifications can be difficult to visualize and must be specifically targeted. (Right) Postnatal radiograph of the leg shows rhizomelic shortening of the femur with flared metaphyses [↖] and stippled calcifications [↖] of both the proximal and distal epiphyses.

KEY FACTS

TERMINOLOGY

- Rare inherited disorder of bone metabolism resulting in function loss of gene *ALPL* coding for tissue-nonspecific alkaline phosphatase (TNSALP) with 3 subtypes
 - Perinatal lethal: Micromelia & severe hypomineralization
 - Infantile: Rickets-like skeletal changes, fractures, premature shedding of teeth
 - Late onset (adult form): Bowing, pseudofractures, ectopic calcifications in spinal ligaments & joint cartilage, rachitic changes in ribs

IMAGING

- Perinatal lethal type: Micromelia & severe undermineralization of bones & calvarium on midtrimester US
 - True fractures uncommon
 - Bones may appear moth eaten in late gestation

TOP DIFFERENTIAL DIAGNOSES

- Osteogenesis imperfecta; achondrogenesis type 1A; hypophosphatemic rickets; neonatal hyperparathyroidism, severe form

PATHOLOGY

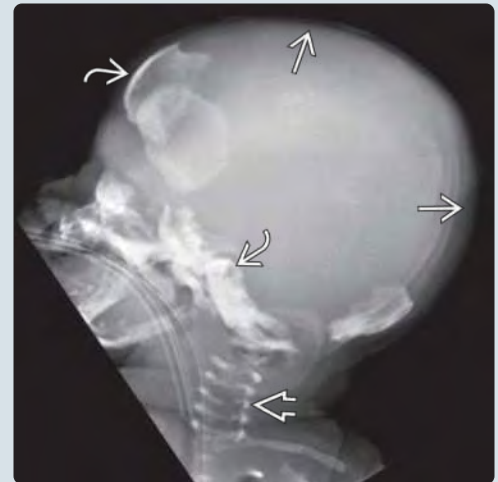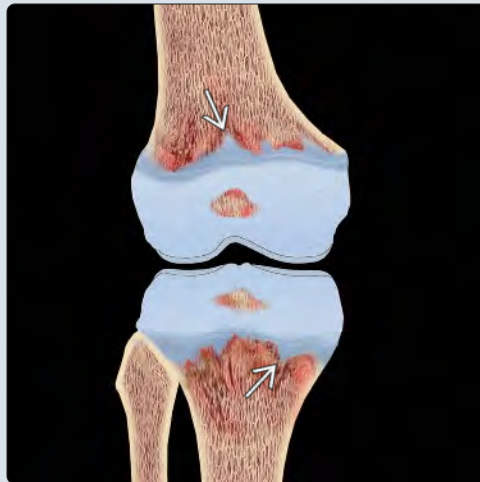
- Mutations in tissue nonspecific ALP gene [*TNSALP* or (*ALPL*)]
- Perinatal lethal/infantile: Autosomal recessive
- Adult form both autosomal recessive & dominant
 - Carriers with ↓ serum ALP/↑ urinary phosphoethanolamine

CLINICAL ISSUES

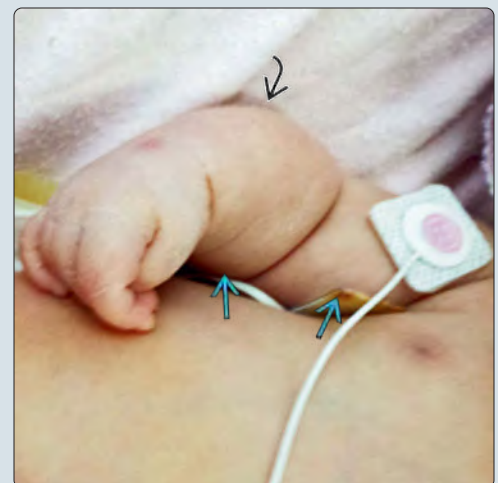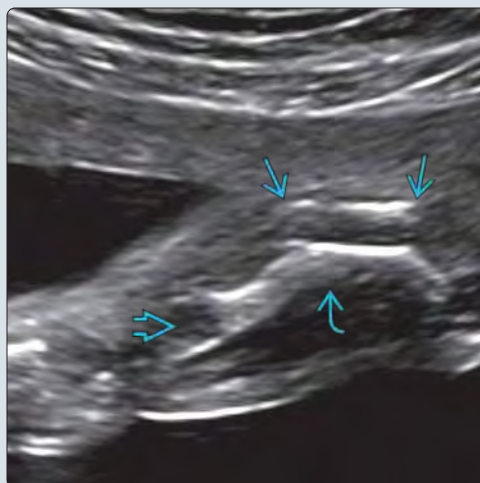
- 1 per 100,000 births (perinatal lethal type)
- Prenatal diagnosis
 - Measure ALP activity in chorionic villi, cultured amniocytes, or fetal blood
 - Direct mutational analysis possible

(Left) Coronal graphic depicts hypophosphatasia, with marked irregularity of the growth plates and tongues of cartilage extending into the metaphyseal region.

(Right) Lateral radiograph of a term newborn with perinatal lethal hypophosphatasia illustrates the severe undermineralization of the membranous calvarium. The calvarium is soft and deformable to light palpation. The basal skull and frontal bones are the only ossified bones in the skull. Note the thin, poorly mineralized cervical vertebrae.



(Left) Ultrasound of the forearm at 28-weeks gestation shows a severely undermineralized, "moth-eaten" radius and short, poorly formed ulna in a fetus with perinatal lethal hypophosphatasia. The metaphysis in particular is underossified. **(Right)** Clinical photograph of the arm of a newborn infant with perinatal lethal hypophosphatasia is shown. Micromelia is striking with apparent pseudoarthrosis. The fingers are slender and normal in length.



TERMINOLOGY

Definitions

- Rare inherited disorder of bone metabolism resulting in loss of function of gene *ALPL* coding for tissue-nonspecific alkaline phosphatase (TNSALP)
- 3 subtypes
 - **Perinatal lethal**
 - Micromelia and severe hypomineralization
 - **Infantile**
 - Rickets-like skeletal changes, fractures, premature shedding of teeth
 - **Late onset (adult form)**
 - Bowing, pseudofractures, ectopic calcifications in spinal ligaments and joint cartilage, rachitic changes in ribs

IMAGING

General Features

- Best diagnostic clue
 - Perinatal lethal type: Micromelia and severe undermineralization of bones and calvarium on midtrimester ultrasound

Ultrasonographic Findings

- Perinatal lethal type
 - Profound hypomineralization of membranous skull
 - Long bones
 - Micromelia
 - Thin with bowing (fractures uncommon)
 - Severely decreased ossification
 - Spurs along midshaft
 - Spine
 - Absent neural arch ossification ± vertebral body ossification

Radiographic Findings

- Infantile form with delayed ossification of cranium, ribs, and tubular bones
 - Metaphyseal ossification defects
 - Bowing of long bones

DIFFERENTIAL DIAGNOSIS

Osteogenesis Imperfecta

- Fractures predominant finding in types II-IV
- Rib fractures severe in type II with beading
- Poor skull mineralization

Achondrogenesis Type 1A

- Absent spine ossification
- Multiple rib fractures
- Poor calvarial ossification

Hypophosphatemic Rickets

- Inherited defect in phosphate transport
- Short stature with bent long bones

Neonatal Hyperparathyroidism (Severe Form)

- Severe hypercalcemia
- Respiratory distress
- Demineralization of skeleton

PATHOLOGY

General Features

- Etiology
 - Mutations in tissue nonspecific alkaline phosphatase (ALP) gene [*TNSALP* or (*ALPL*)]
 - Degree of deficiency correlates with clinical severity
- Genetics
 - Perinatal lethal/infantile: Autosomal recessive
 - Adult form both autosomal recessive and dominant
 - Carriers with ↓ serum ALP/↑ urinary phosphoethanolamine

CLINICAL ISSUES

Presentation

- Most common signs/symptoms
 - Hypomineralization, bowed limbs
- Other signs/symptoms
 - Premature shedding of teeth
 - Decreased/absent serum ALP activity
 - ↑ plasma pyridoxal 5'-phosphate
 - Hypercalcemia and hypercalcuria

Demographics

- Epidemiology
 - 1 per 100,000 births (perinatal lethal type)

Natural History & Prognosis

- Perinatal hypophosphatasia: Lethal
- Infantile hypophosphatasia
 - Hypercalcemia: Irritability, poor feeding, vomiting, failure to thrive
 - Craniosynostosis: ↑ intracranial pressure
 - Nephrocalcinosis
 - Increased mortality: Cardiorespiratory complications, ↑ intracranial pressure
 - Delayed walking, abnormal gait
 - Spontaneous improvement in limb bowing may occur
- Late onset
 - Metatarsal stress fractures may be 1st sign
 - Short stature is common

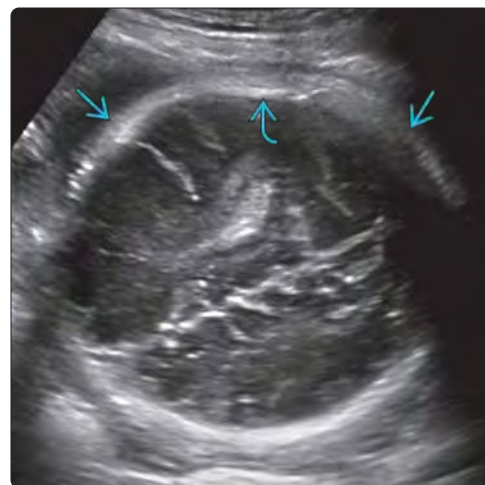
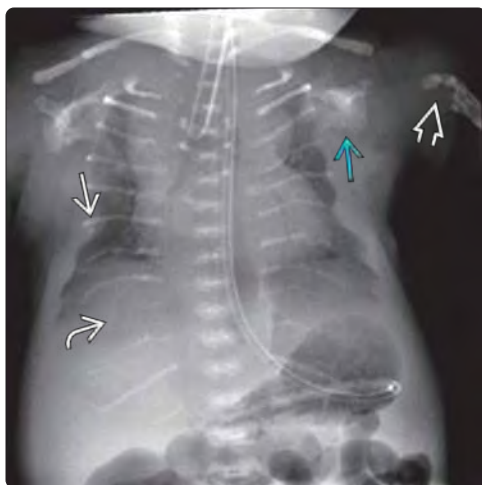
Treatment

- Prenatal diagnosis
 - Measure ALP activity in chorionic villi, cultured amniocytes, or fetal blood
 - Direct mutational analysis possible
- Hypercalcemia responsive to dietary restriction
 - Disappointing results with enzyme therapy, calcitonin
- Aggressive dental care to preserve teeth
- Intramedullary rods may stabilize fractures
- Bone marrow transplantation

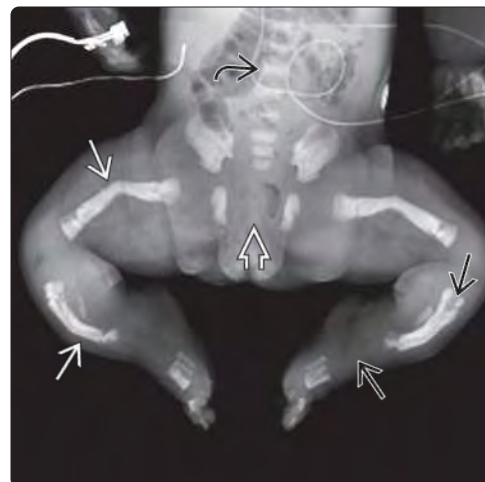
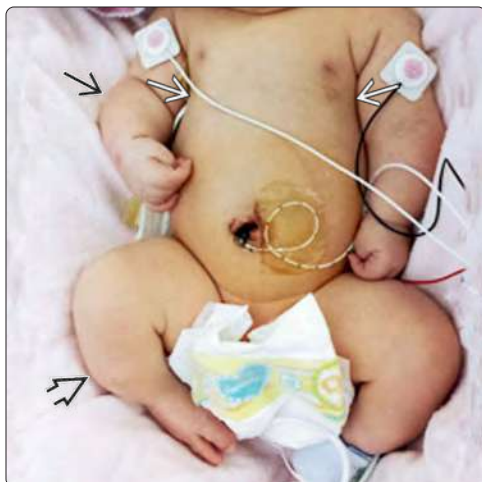SELECTED REFERENCES

1. Kosnik-Infinger L et al: Enzyme replacement therapy for congenital hypophosphatasia allows for surgical treatment of related complex craniosynostosis: a case series. *Neurosurg Focus.* 38(5):E10, 2015
2. Liu J et al: Enzyme replacement for craniofacial skeletal defects and craniosynostosis in murine hypophosphatasia. *Bone.* 78:203-11, 2015
3. Whyte MP et al: Hypophosphatasia: validation and expansion of the clinical nosology for children from 25 years experience with 173 pediatric patients. *Bone.* 75:229-39, 2015

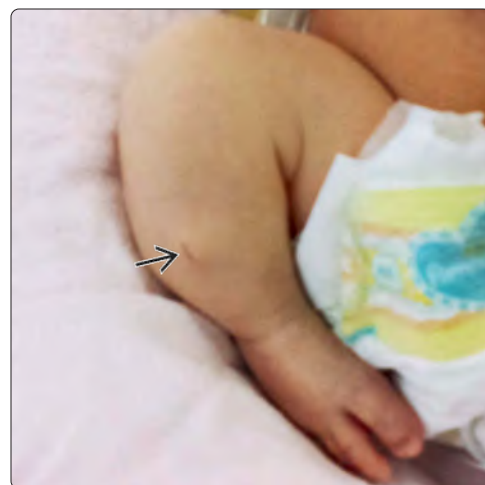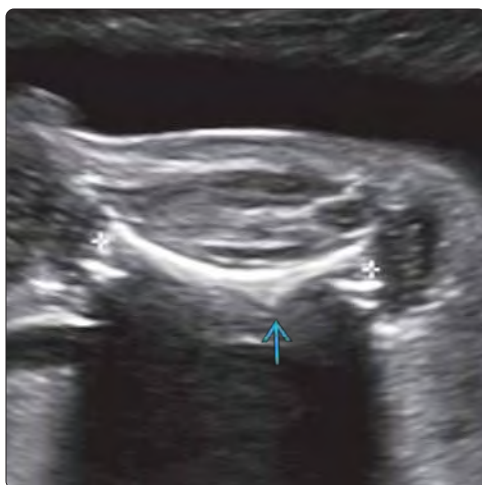(Left) In this chest radiograph of a newborn with perinatal lethal hypophosphatasia, note the severe generalized lack of ossification. In particular, the ribs are extremely thin but without fractures, and there is a completely unossified rib. The scapulae are hypoplastic. The humeral metaphysis is abnormal. **(Right)** Late 3rd-trimester ultrasound of a fetus with perinatal lethal hypophosphatasia shows significant lack of ossification, with the brain being seen "too well." Note how the skull is deformed by transducer pressure.

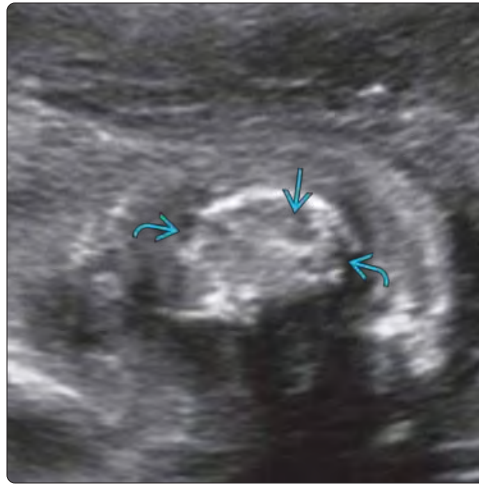
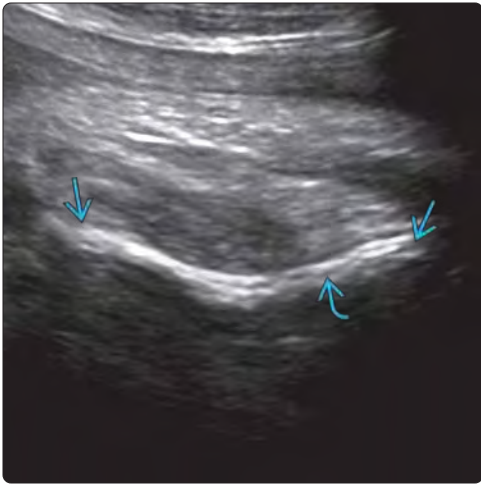


(Left) In this photograph of a newborn infant with perinatal lethal hypophosphatasia, micromelia and curved long bones are evident. Note also the small chest. **(Right)** This radiograph shows classic findings in perinatal lethal hypophosphatasia, including angulated bones, flattened underossified vertebral bodies, and lack of pelvic ossification. Multiple other areas of severe underossification are also seen.

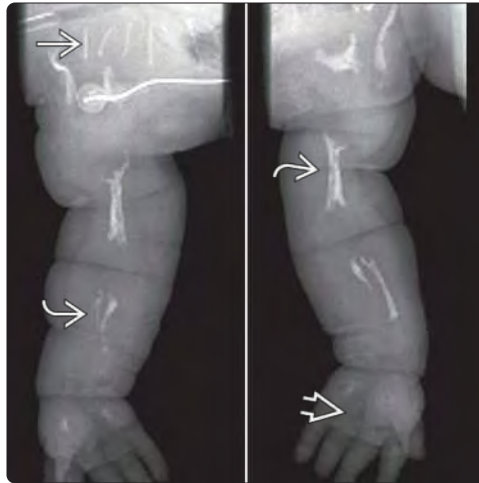
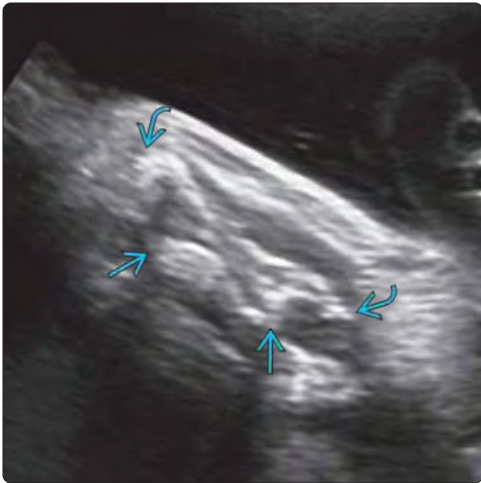

(Left) An ultrasound of the lower extremity of a fetus with perinatal lethal hypophosphatasia at 28-weeks gestation illustrates the anteriorly curved tibia. A bony spur can be seen, a common finding in this condition. **(Right)** In this photograph of the leg of the same infant, the curved lower extremity is evident. A pretibial dimple is also seen. This corresponds to a palpable bony spur as shown in the ultrasound.

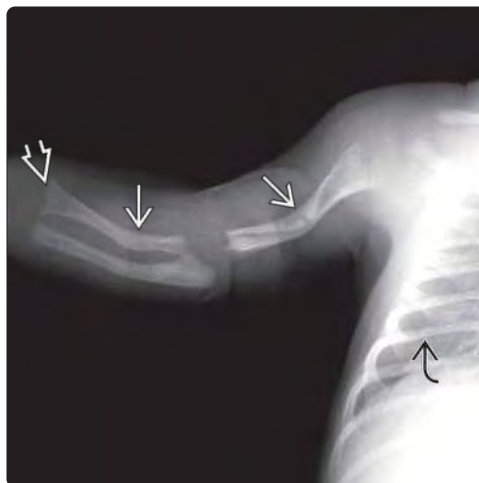
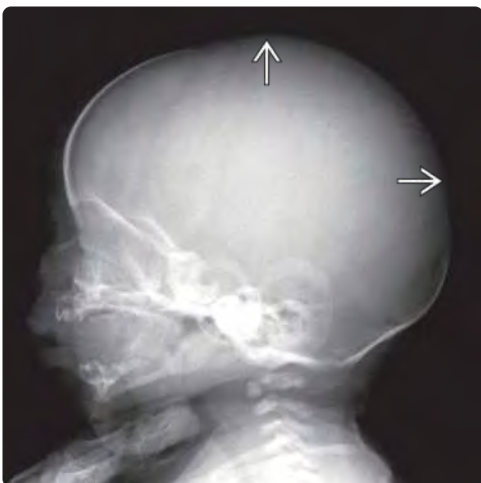



(Left) Ultrasound of a fetus at 35-weeks gestation with perinatal lethal hypophosphatasia is shown. The femur is bowed, short, and poorly mineralized, especially the metaphyseal ends . There is a moth-eaten appearance to the bone . This irregular ossification is an important clue regarding this rare diagnosis. **(Right)** Ultrasound of the scapula in the same fetus shows an irregular contour , severe underossification, and, again, the moth-eaten appearance of the bone.



(Left) Ultrasound of the forearm in the same case shows severe shortening and almost complete lack of ossification in the radius and ulna . **(Right)** Radiographs of both upper extremities of an infant diagnosed postnatally with perinatal lethal hypophosphatasia are shown. Note the severe lack of ossification and abnormal morphology of the long bones and the extremely thin ribs . Ossification is almost completely absent in the hands .



(Left) Lateral radiograph shows the hypomineralized skull of a newborn with infantile hypophosphatasia. This is far less severe than seen in the perinatal lethal type. **(Right)** Another radiograph from the same infant shows thin, bowed bones . Note the hypomineralization. Thin, straight ribs without fractures are also seen . The metaphyseal irregularities are less pronounced than in the perinatal lethal form. Given the more subtle findings, prenatal diagnosis may be challenging.

KEY FACTS

TERMINOLOGY

- Genetically and clinically heterogeneous group of connective tissue disorders presenting with osteoporosis and fractures
 - 90% of cases due to abnormalities in type I collagen (*COL1A1*, *COL1A2*)
- Newer osteogenesis imperfecta (OI) nomenclature further subdivides classic phenotypes (van Dijk and Sillence 2014)
 - Phenotypes with mild to moderate severity (previously types I, IV, V)
 - Nondeforming OI with blue sclerae (type I)
 - Common variable OI with normal sclerae (type IV)
 - OI with interosseous membrane calcification (type V)
 - Phenotypes that are progressively deforming and perinatally lethal (previously types II, III)
 - Perinatally lethal OI (type II)
 - Progressively deforming (type III)

IMAGING




- Presence of fractures distinguishes OI from most other skeletal dysplasias
- Long bone shortening/angulation secondary to fractures
- Callus formation gives bones crumpled appearance
- Poorly mineralized skull
 - Skull deformation from normal transducer pressure

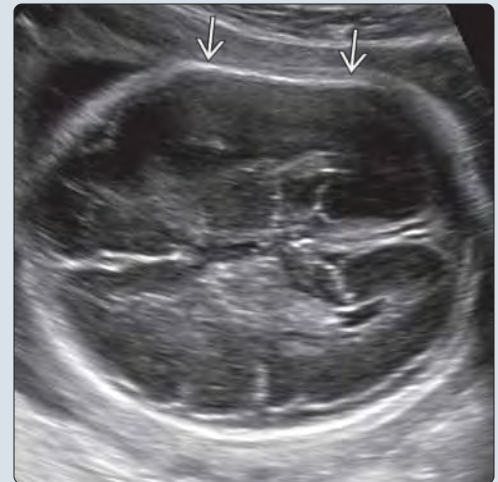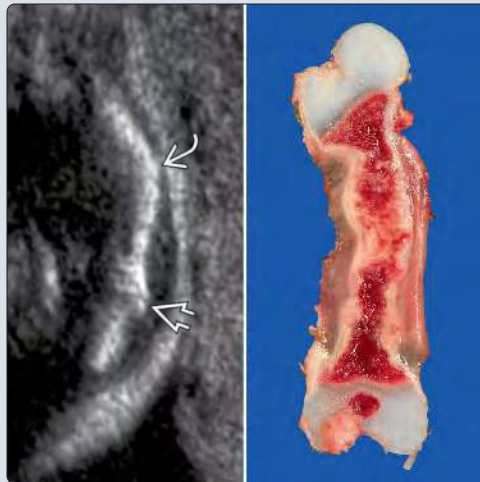
TOP DIFFERENTIAL DIAGNOSES




- Thanatophoric dysplasia
- Achondrogenesis
- Campomelic dysplasia
- Hypophosphatasia

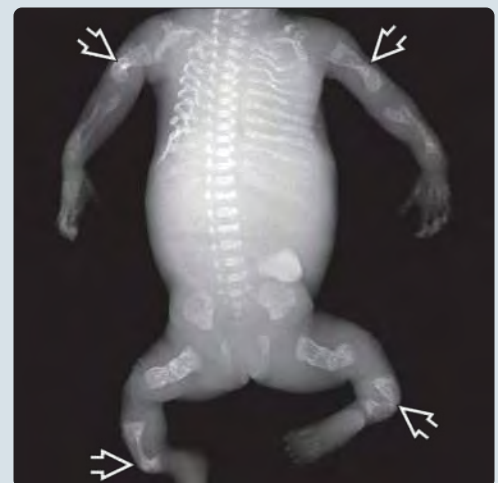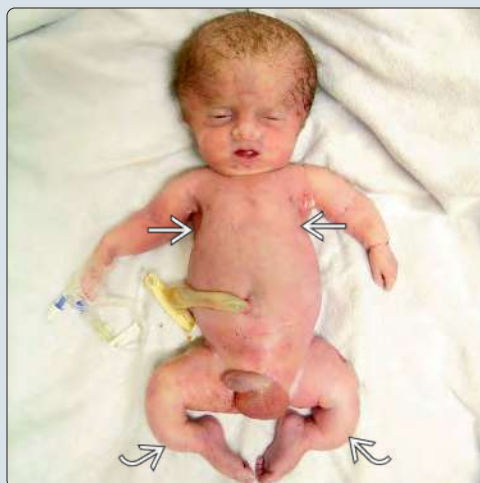CLINICAL ISSUES

- Deliver in center with expertise in genetic fetopathology, skeletal dysplasias
- Autopsy with x-rays if termination or demise

(Left) Longitudinal femoral US of a fetus with nonlethal osteogenesis imperfecta (OI) shows curvature of the femur  & distal fracture with callus formation . The autopsy photograph from a case of perinatal lethal OI shows severe crumpling of femur. In general, fewer fractures are seen in the nonlethal forms of OI. **(Right)** Cranial US of a 3rd-trimester fetus with OI shows undermineralization with flattening of the skull  with normal transducer pressure. Often the brain is seen "too well" when the skull lacks normal ossification.



(Left) Photograph shows a preterm neonate with perinatal lethal (type II) OI. Note the small chest . The legs exhibit marked bowing and pseudoarthroses  due to multiple fractures. **(Right)** Frontal radiograph in the same case shows diffuse osteopenia. There are multiple rib fractures creating a beaded appearance. The arms and legs are short due to angulation and deformity resulting from the fractures .



TERMINOLOGY

Abbreviations

- Osteogenesis imperfecta (OI)

Definitions

- Genetically and clinically heterogeneous group of connective tissue disorders presenting with osteoporosis and fractures
 - 90% of cases due to abnormalities in type I collagen (*COL1A1*, *COL1A2*)
- Historically, OI has been classified into 5 basic phenotypic groups (I-V) with clinical descriptors
- Currently 17 different genetic causes of OI are known
- Newer OI nomenclature further subdivides classic phenotypes
 - Phenotypes with mild to moderate severity (previously types I, IV, V)
 - Phenotypes that are progressively deforming and perinatally lethal (previously types II, III)

IMAGING

General Features

- Best diagnostic clue
 - Presence of fractures distinguishes OI from most other skeletal dysplasias

Ultrasonographic Findings

- Extremities
 - Long bone shortening/angulation secondary to fractures
 - Pseudarthrosis formation
 - Callus formation gives bones "crumpled" appearance
 - Decreased mineralization
- Chest
 - Multiple rib fractures ("beading") in perinatal lethal type
- Brain
 - Anatomy "seen too well" with no reverberation artifact
 - Poorly mineralized skull
 - Skull deformation from normal transducer pressure

Radiographic Findings

- Generalized osteopenia
- Delayed calvarial formation with multiple wormian bones
- Thin ribs with beaded appearance due to fractures
- Tubular bones with thin cortex, thin shafts
- Severe cases with collapsed vertebral bodies, rib fractures, broad bent tubular bones due to compression fractures

Imaging Recommendations

- Best imaging tool
 - Midtrimester US
 - 1st-trimester endovaginal US in high-risk patients
- Protocol advice
 - Measure all long bones/assess for fractures
 - Severe shortening in perinatal lethal form
 - Compare chest to abdominal circumference
 - Small chest → increased risk for pulmonary hypoplasia
 - Normal US does not exclude OI in high-risk patient
 - Less severe forms may present with apparently isolated bent femora

DIFFERENTIAL DIAGNOSIS

Thanatophoric Dysplasia

- Ossification generally normal, including calvarium
- Severe long bone shortening, bowing
- Type I with bowed ("telephone receiver" femora); straighter femora in type II
- Macrocephaly with clover leaf-shaped calvarium (kleeblattschädel) in type II

Achondrogenesis

- Spine mineralization deficient/variable skull ossification
- Hydrops, cystic hygroma common
- Severe micromelia
- Rib fractures in type IA

Campomelic Dysplasia

- Hypoplastic scapulae
- Sharp angulation of femur, tibia/fibula may be mistaken for fractures
- Normal skull ossification
- Sex reversal common

Hypophosphatasia

- Generalized hypomineralization of all bones with moth-eaten appearance
- Fractures less common
- Micromelia
- Low serum alkaline phosphatase in neonate, parents

PATHOLOGY

General Features

- Genetics
 - Mutations in *COL1A1*, *COL1A2* genes of type I collagen identified in 90%
 - Most OI types autosomal dominant
 - De novo mutations in 60% with mild OI
 - Most recurrences of type II attributed to gonadal mosaicism
 - Recurrence risk up to 3%
 - Multiple autosomal recessive genes now reported
- Associated abnormalities
 - Dentinogenesis imperfecta
 - Hearing loss
 - Blue or gray sclerae

Staging, Grading, & Classification

- van Dijk and Sillence classification (2014): Based on phenotype combined with causative genes
 - **Nondeforming OI with blue sclerae (type I)**
 - Fractures rare at birth
 - Blue sclerae
 - Type IA, normal teeth; IB with dentinogenesis imperfecta (60%)
 - Hearing loss (35-50%)
 - Bone fragility improves with adolescence; may recur after menopause
 - Wormian bones on skull radiograph
 - Autosomal dominant: *COL1A1*, *COL1A2* autosomal dominant
 - **Perinatally lethal OI (type II)**

- Dark grayish-blue sclerae; short, thick, tubular bones
- Small chest with "beaded" ribs
- Severe limb shortening, appear crumpled due to fractures
- Demineralization of skull
- Autosomal dominant: *COL1A1*, *COL1A2*
- Autosomal recessive: *CRTAP*, *LEPRE1*, *PPIB*
- **Progressively deforming (type III)**
 - Multiple fractures at birth, progressive severe deformity of limbs, spine, skull
 - Sclerae white or grayish-blue
 - Triangular facies
 - Severe short stature
 - Spinal cord compression
 - Often nonambulatory
 - Autosomal dominant: *COL1A1*, *COL1A2*
 - Autosomal recessive: *BMP1*, *CRTAP*, *FKBP10*, *LEPRE1*, *PLOD2*, *PPIB*, *SERPINF1*, *SERPINH1*, *TMEM38B*, *WNT1*, *CREB3L1*
- **Common variable OI with normal sclerae (type IV)**
 - Clinical and radiographic spectrum between type I and type III
 - Sclerae white or grayish-blue
 - Short stature
 - Dentinogenesis imperfecta common
 - Hearing loss in later life
 - Autosomal dominant: *COL1A1*, *COL1A2*, *WNT1a*
 - Autosomal recessive: *CRTAP*, *PPIB*, *SP7*
 - X-linked: *PLS3*
- **OI with calcification in interosseous membranes (type V)**
 - Non-type I collagen defects (*IFITM5*); autosomal dominant
 - "Pure" phenotype, similar to spondylometaphyseal dysplasia

Gross Pathologic & Surgical Features

- OI type II (perinatal lethal type)
 - Thin cortical bone, sparse trabecular bone
 - Increased osteoclasts/osteocytes

CLINICAL ISSUES

Presentation

- Most common signs/symptoms
 - Multiple fractures on 2nd-trimester US
 - Cases of type III/IV OI reported with isolated bent femora in utero
- Other signs/symptoms
 - 1st-trimester cystic hygroma, increased nuchal translucency
 - Detected as early as 12-14 weeks

Demographics

- Age
 - Tendency toward increased paternal age in lethal OI
- Gender
 - F > M
- Epidemiology
 - 1/10,000-1/20,000 live births
 - Incidence of maternal OI in pregnancy 1/20,000-30,000

Natural History & Prognosis

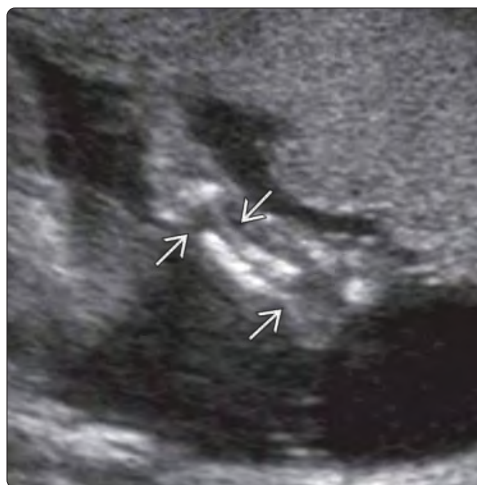
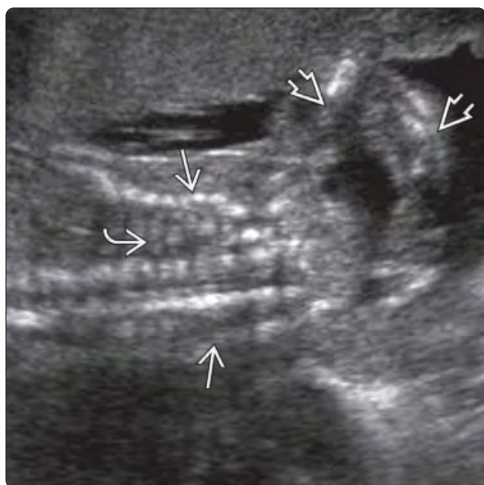
- Variable according to type
 - Type I, IV: Normal to slightly decreased life span
 - Type II: Perinatal lethal
 - Type III: Significantly shortened life span
- Pregnancy in women with OI
 - Increased uterine atony, bruising, bleeding tendency
 - Increased ambulation difficulties, back pain
 - Preterm delivery
 - Restrictive lung disease if very short stature
 - 25-50% risk of fetal transmission depending on mutation
 - Maternal echocardiogram to evaluate aorta
 - Cesarean delivery controversial
 - Maternal pelvic fractures
 - Case reports of uterine rupture with vaginal delivery, attributed to decreased total collagen in myometrium
- Other medical/musculoskeletal complications
 - Arthritis, scoliosis, tendon ruptures, back pain, aortic root dilation, basilar invagination

Treatment

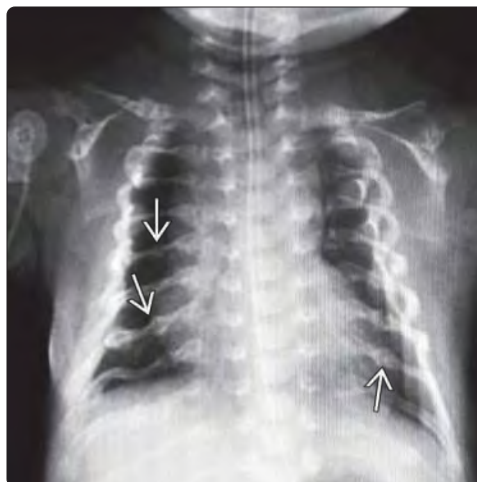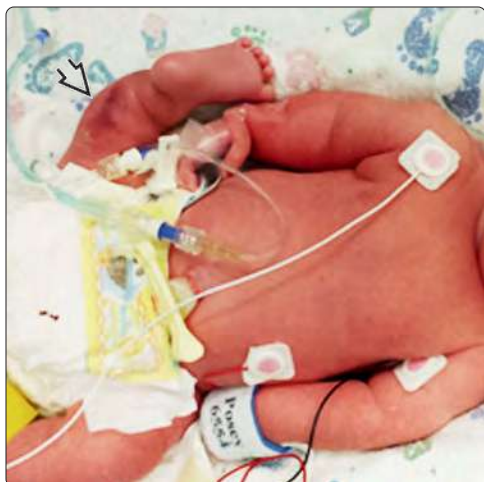- No prenatal treatment for fetus
 - Experimental bisphosphonate therapy in maternal OI (preconception)
- Genetic counseling indicated in all cases
- Biochemical/collagen analysis from chorionic villus sampling or amniocentesis
 - Molecular analysis possible in some cases
 - Preimplantation genetic diagnosis reported
- Suspected lethal or severe OI
 - Pregnancy termination is option
 - Confirmation of diagnosis important for genetic counseling
- Deliver in center with expertise in genetic fetopathology, skeletal dysplasias
- No benefit from cesarean section
 - No increase in survival in lethal OI
 - No decrease in perinatal fractures in nonlethal OI
 - Avoidance of instrumental delivery
- Autopsy with x-rays if termination or demise
 - Tissue for biochemical, molecular confirmation
- Postnatal
 - Intramedullary rods to straighten and stabilize long bones in severe OI
 - Cyclic bisphosphonate therapy in severe OI
 - Decreases bone turnover and increases bone density
 - Decreases fracture frequency, pain
 - Physical therapy, bracing

SELECTED REFERENCES

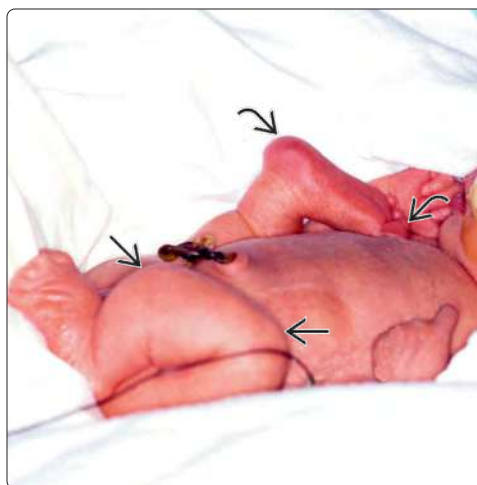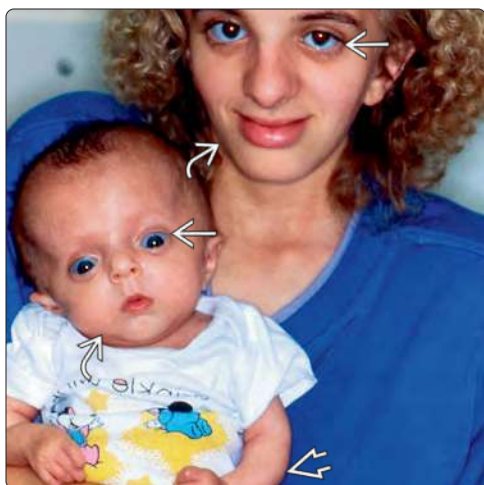1. Cozzolino M et al: Management of osteogenesis imperfecta type I in pregnancy; a review of literature applied to clinical practice. *Arch Gynecol Obstet.* ePub, 2016
2. Reyes C et al: Risks and benefits of bisphosphonate therapies. *J Cell Biochem.* 117(1):20-8, 2016
3. Forlino A et al: Osteogenesis imperfecta. *Lancet.* ePub, 2015
4. Shaker JL et al: Recent developments in osteogenesis imperfecta. *F1000Res.* 4(F1000 Faculty Rev):681, 2015
5. Van Dijk FS et al: Osteogenesis imperfecta: clinical diagnosis, nomenclature and severity assessment. *Am J Med Genet A.* 164A(6):1470-81, 2014



(Left) Coronal ultrasound through the thorax and one upper extremity of a midtrimester fetus shows a small chest and irregular ribs with multiple fractures. Note also the multiple fractures in the long bones of the arm. **(Right)** This is a closer look at the forearm in the same case. There is irregular ossification in the radius and ulna. Often the bony segments are displaced and appeared bowed or curved. This is perinatal lethal (type II) OI.



(Left) Clinical photograph of a newborn infant with a form of OI that fits clinically between perinatal lethal type II and progressively deforming type III. The chest is lower normal in size, and the limbs are short. Multiple fractures are noted in the extremities, giving the legs, in particular, a bowed appearance. **(Right)** CXR of the same infant shows a slightly small chest with multiple rib fractures. This is less severe than that seen in the perinatal lethal form of OI.



(Left) Clinical photograph shows a mother and infant both affected with type IV OI. Note the strikingly dark blue sclerae, triangular faces, and pseudarthrosis. **(Right)** Clinical photograph shows the same infant with type IV OI as a newborn. Note the striking pseudarthroses, which are a result of multiple fractures in utero. Micromelia is also apparent when comparing the near normal foot length to that of the long bones.

Short Rib-Polydactyly Syndromes

KEY FACTS

TERMINOLOGY

- Short rib-polydactyly syndrome (SRPS)
- Short rib-thoracic dysplasia ± polydactyly (SRTD)
- Group of rare osteochondrodysplasias characterized by short tubular bones, short horizontal ribs with severely constricted thorax, ± polydactyly, ± visceral anomalies
- Autosomal recessive skeletal ciliopathies
- Includes: Jeune (asphyxiating thoracic dystrophy), Saldino-Noonan, Verma-Naumoff, Majewski, and Beemer-Langer syndromes

IMAGING

- Best diagnostic clue: Triad of micromelia, polydactyly, short horizontal ribs
- Diagnosis possible by 15-16 weeks gestation based on micromelia, very short ribs
- Increased nuchal translucency in 1st trimester
- Radiographs performed after delivery as part of evaluation
 - Short, horizontal ribs with small thorax

- Medial and lateral iliac spurs
- Short extremities with bowing
- Other non-skeletal anomalies: Especially cardiac, renal, orofacial, genital
- Normal ossification of bones
- Postaxial polydactyly variably present

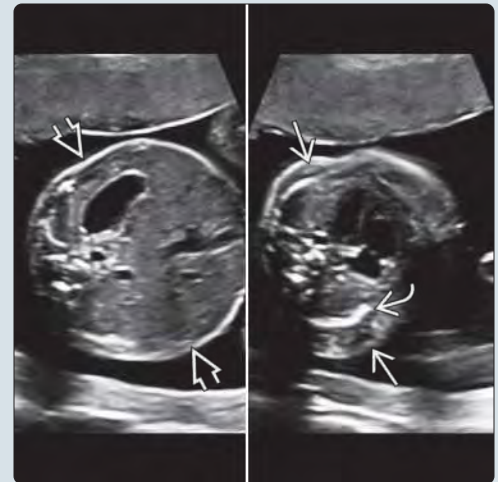
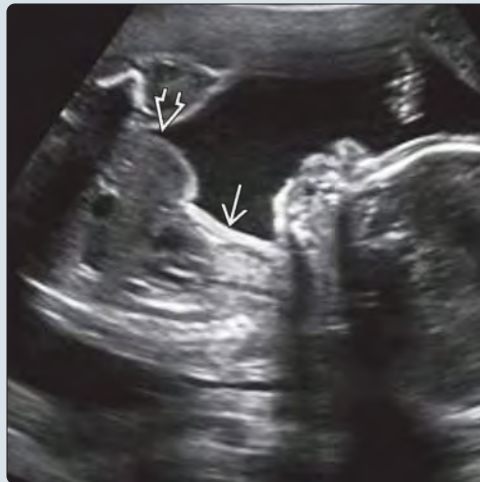PATHOLOGY

- Primary ciliary dyskinesia involving chondrocytes, including airway

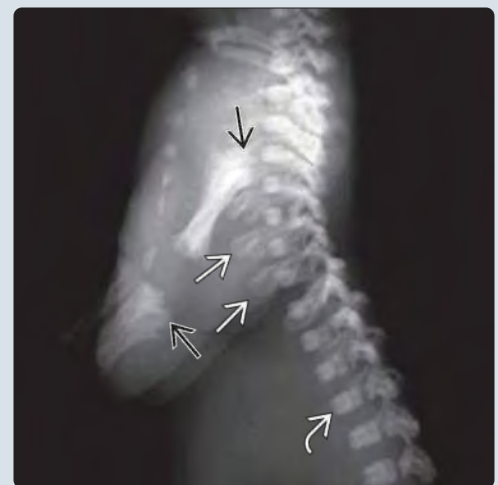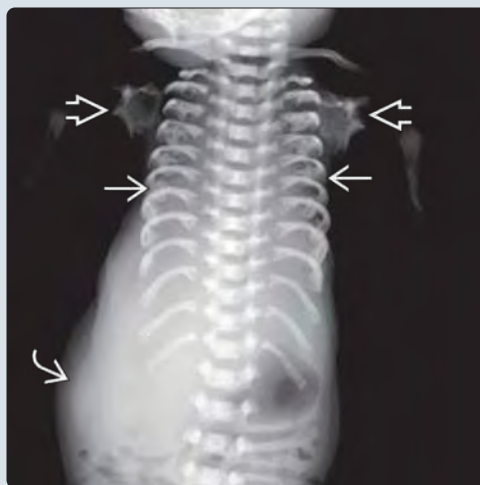
CLINICAL ISSUES

- Phenotype highly variable
- Long narrow thorax
- Brachydactyly, short limbs
- Significant respiratory insufficiency at birth
 - Constricted thorax
 - Subglottic stenosis from abnormal airway formation

(Left) Sagittal US of a fetus at 24 weeks shows the very small chest compared with the normal-sized abdomen. The ribs were very short. All the long bones were mildly shortened and bowed femora were noted. The suspected diagnosis of Jeune asphyxiating thoracic dystrophy was confirmed after birth. **(Right)** Axial images of the same fetus at 24-weeks gestation demonstrate the small chest and short ribs as compared with the normal-sized abdomen. This is typical in a fetus with Jeune syndrome.



(Left) Postmortem anteroposterior radiograph shows the very abnormal chest in short rib-polydactyly type III (Verma-Naumoff type). Note the short horizontal ribs with broad ends, protuberant abdomen, and irregular scapulae with multiple bony spurs. **(Right)** Lateral radiograph of the same infant with Verma-Naumoff SRPS type III shows the severely shortened ribs. The vertebral bodies are small and irregular and the metaphyses of the upper extremity bones are broad and irregular.



TERMINOLOGY

Synonyms

- Short rib-polydactyly syndrome (SRPS)
- Short rib-thoracic dysplasia ± polydactyly (SRTD)

Definitions

- Group of rare osteochondrodysplasias characterized by short tubular bones, short horizontal ribs with severely constricted thorax, ± polydactyly, ± visceral anomalies
 - Significant phenotypic overlap and genetic heterogeneity between various subtypes (SRTD1-14; SRPS1-4), which vary based on visceral involvement and appearance of metaphyses
 - All belong to group of autosomal recessive skeletal ciliopathies

IMAGING

General Features

- Best diagnostic clue
 - Triad of micromelia, polydactyly, short horizontal ribs
 - Diagnosis possible by 15- to 16-weeks gestation based on micromelia, very short ribs
 - Increased nuchal translucency in 1st trimester in high-risk families
- **Short rib-thoracic dysplasia ± polydactyly (SRTD1, 3): Jeune syndrome, also known as asphyxiating thoracic dystrophy**
 - Thorax long and narrow with short horizontal ribs
 - Cystic renal dysplasia
 - Polydactyly less common (14%)
 - Long bones less severely affected with more normal tibiae
 - Perinatal lethality due to severe respiratory insufficiency common
 - Childhood survivors often develop renal, hepatic disease
 - SRTD1 maps to 15q13
 - SRTD3 caused by mutations in *DYNC2H1* gene
- **Short rib-thoracic dysplasia ± polydactyly (SRTD3): Saldino-Noonan (SRPS type I) and Verma-Naumoff (SRPS type III) have similar findings**
 - Postaxial polydactyly
 - Hydrops
 - Cardiac: Septal defects, coarctation, transposition of great vessels
 - GI/GU: Renal cysts, cloacal anomalies, vaginal atresia, vaginal fistulas, imperforate anus
 - Perinatal lethal
 - Radiographic findings: Hypoplastic iliac bones with flattened acetabular roofs, rounded vertebrae with coronal clefts, long bones with pointed ends/convex central area with lateral metaphyseal spikes/ragged-appearing ends, absence of fibulae in SRPS type I
 - Visceral anomalies less common in SRPS type III
 - SRTD3 caused by mutations in *DYNC2H1* gene
- **Short rib-thoracic dysplasia ± polydactyly (SRTD6): Majewski (SRPS type II)**
 - Pre- and postaxial polydactyly
 - Hydrops
 - Orofacial clefts, often midline

- Ambiguous genitalia
- Central nervous system (CNS) abnormalities
- Radiographic findings: Short horizontal ribs, short tubular bones with smooth ends, short ovoid tibiae (shorter than fibulae), normal iliac bones
- SRTD6 caused by mutations in *NEK1* gene
- **Short rib-thoracic dysplasia ± polydactyly (SRTD12): Beemer-Langer (SRPS type IV)**
 - Pre- and postaxial polydactyly in 50%
 - Visceral anomalies: Omphalocele, cardiac, cystic/hypoplastic kidneys, lobulated tongue, oral frenula, ambiguous genitalia
 - Median orofacial cleft
 - CNS: Hydrocephalus, holoprosencephaly, hamartomas
 - Cystic hygroma reported in 1st trimester
 - Radiographic findings: Short horizontal ribs, small iliac bones, short tubular bones with smooth metaphyses, bowed radii and ulnae
 - Mutations in *NEK1* and *DYNC2H1* excluded in small cohort of patients
- Other small series of patients classified as SRTD2, 4, 5, 7, 8, 9, 10, 11, 13, 14 with variety of similar features

Ultrasonographic Findings

- Small chest with short ribs
 - Thoracic circumference < 5th percentile with normal abdominal circumference
- Cystic kidneys may be seen
- Other nonskeletal anomalies: Especially cardiac, orofacial, genital
- Normal ossification of bones
- Short tubular bones
 - May have mild angulation but no fractures
- Increased nuchal translucency reported in 1st trimester
- Oligohydramnios if severe renal disease
- Postaxial polydactyly variably present

Radiographic Findings

- Radiographs performed after delivery as part of evaluation
 - Short, horizontal ribs with small thorax
 - Short iliac, ischia, and pubic bones
 - Medial and lateral iliac spurs
 - Short extremities with bowing
 - Cone-shaped epiphyses
- Abnormalities most marked in infancy, survival associated with less severely affected thorax

Imaging Recommendations

- Endovaginal imaging in high-risk families
- 3D/4D US useful in 2nd-3rd trimesters

DIFFERENTIAL DIAGNOSIS

Ellis-van Creveld Syndrome

- Chondroectodermal dysplasia
- Rare; increased incidence in Amish
- Less severe thoracic involvement, short long bones
- Upper lip midline partial cleft
- Cardiac defect in 60% (septal defect, single atrium)
- Postaxial polydactyly
- Survival associated with normal intelligence

- Mutations in *EVC1* and *EVC2* genes on 4p16; autosomal recessive

Mohr-Majewski Syndrome

- Orofacial digital syndrome (OFD) type IV
- Distinction between SRPS and OFD IV is unclear
 - May be part of single spectrum
- Severe tibial involvement, ribs longer
- Neonatal survival possible

Barnes Syndrome

- Small thorax, small pelvis, laryngeal stenosis
- Rib shortening milder than Jeune syndrome
- Absence of iliac spurs, renal disease
- Autosomal dominant

Uniparental Disomy 14 (Paternal)/Kagami-Ogata Syndrome

- Recognizable phenotype with small bell-shaped thorax
- Characteristic coat-hanger rib sign (caudal anterior rib bowing) on radiograph
- Involves imprinted region of chromosome 14q
- Facial abnormalities
- Abdominal wall defects
- Placentomegaly
- Polyhydramnios

Sensenbrenner Syndrome (Cranioectodermal Dysplasia)

- Rare autosomal recessive heterogeneous skeletal ciliopathy
- Sagittal craniosynostosis
- Distinctive facial features
- Short stature
- Narrow thoracic cage
- Ectodermal features: Sparse hair, hypodontia, microdontia
- Mutations in 4 genes have been implicated: *WDR35*, *IFT122*, *IFT43*, *WDR19*

Mainzer-Saldino Syndrome

- Skeletal ciliopathy
- Cone-shaped epiphyses
- Early-onset severe retinal dystrophy
- Chronic renal failure with end-stage renal disease by teens
- Mutations in *IFT172*, an intraflagellar transport gene
- Usually sporadic

PATHOLOGY

General Features

- Etiology
 - Primary ciliary dyskinesia involving chondrocytes, including airway
 - Mutations in *DYNC2H1*, component of cytoplasmic dynein complex involved in generation and maintenance of cilia (ciliopathy); multiple other genes also involved
 - Skeletal phenotype due to abnormal sonic hedgehog signaling in chondrocyte cilia
 - Chondrocytes with abnormal cytoskeletal microtubular architecture
- Genetics
 - Autosomal recessive, almost exclusively
- Associated abnormalities

- Variable visceral involvement
 - Hepatic fibrosis, pancreatic fibrosis, retinal degeneration, cardiac defects, orofacial clefts
- Significant risk of perinatal lethality due to thoracic constriction, hepatic/renal insufficiency, cardiac failure

Microscopic Features

- Loss of synchrony in cartilage removal and osteogenic differentiation at all growth plates
- Irregular, patchy enchondral ossification
- Pulmonary hypoplasia with marked reduction in number of alveoli
- Cystic renal dysplasia and periportal hepatic fibrosis in Jeune syndrome

CLINICAL ISSUES

Presentation

- Most common signs/symptoms
 - Phenotype is highly variable
 - Long narrow thorax
 - Brachydactyly, short limbs
 - Cystic renal dysplasia
 - Postaxial polydactyly variable
- Other signs/symptoms
 - Significant respiratory insufficiency at birth related to constricted thorax, subglottic stenosis from abnormal airway formation

Demographics

- Epidemiology
 - Rare: 1/70,000 births

Natural History & Prognosis

- Neonatal and infantile deaths due to pulmonary hypoplasia in 70%
- Survival associated with growth of thoracic cavity
- Mild cases present in childhood with short stature ± renal disease
- Renal insufficiency, renal failure by late childhood in survivors with Jeune syndrome
- Severe liver involvement → biliary cirrhosis → portal hypertension

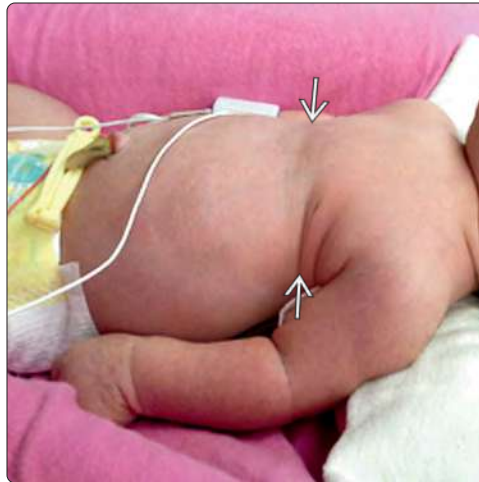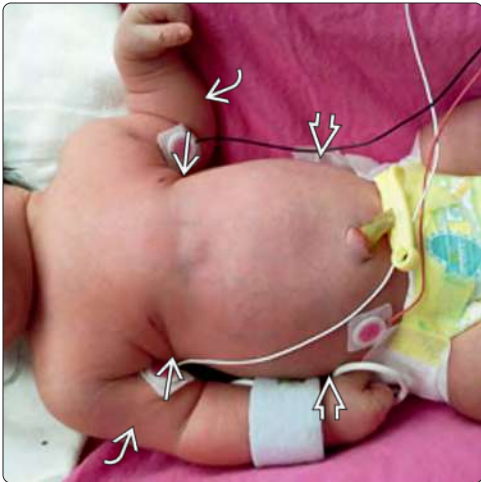Treatment

- Offer genetic counseling
- Option of pregnancy termination
- Postnatal confirmation of diagnosis crucial for recurrence risk counseling
- Rib/thoracic cage expansion procedures
- Ursodeoxycholic acid: Stabilizes hepatic function
- Renal transplantation

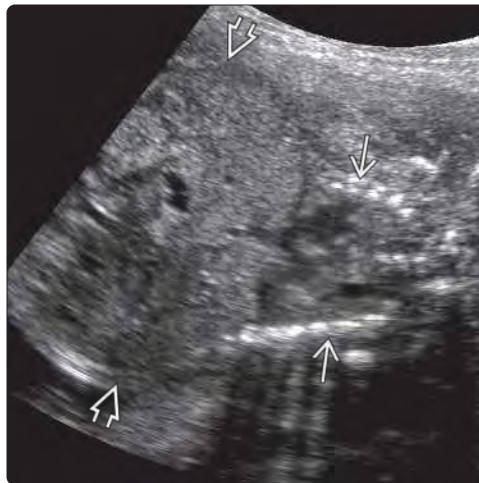
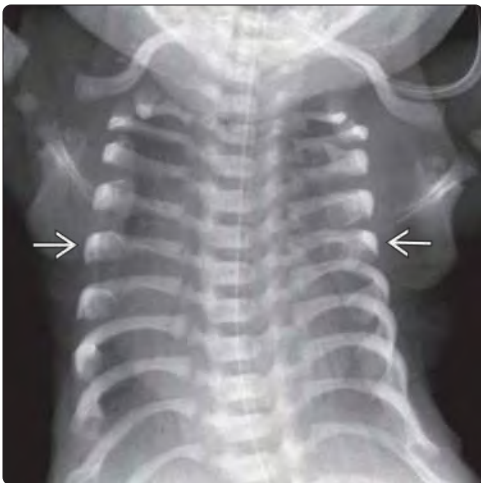SELECTED REFERENCES

1. Mei L et al: Targeted next-generation sequencing identifies novel compound heterozygous mutations of *DYNC2H1* in a fetus with short rib-polydactyly syndrome, type III. *Clin Chim Acta.* 447:47-51, 2015
2. Schmidts M: Clinical genetics and pathobiology of ciliary chondrodysplasias. *J Pediatr Genet.* 3(2):46-94, 2014
3. Baujat G et al: Asphyxiating thoracic dysplasia: clinical and molecular review of 39 families. *J Med Genet.* 50(2):91-8, 2013
4. Huber C et al: *WDR34* mutations that cause short-rib polydactyly syndrome type III/severe asphyxiating thoracic dysplasia reveal a role for the NF- κ B pathway in cilia. *Am J Hum Genet.* 93(5):926-31, 2013

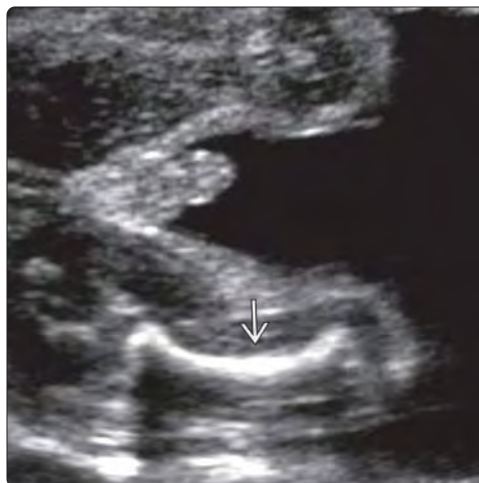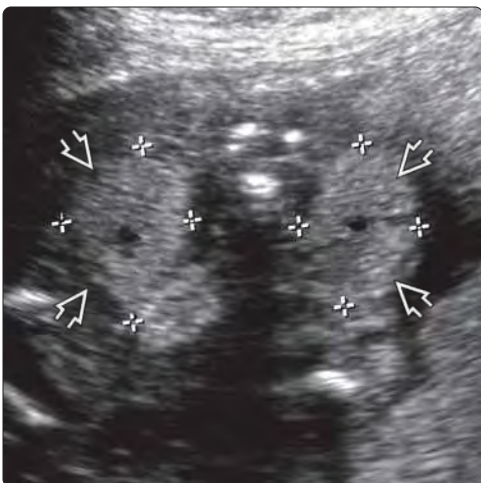
Short Rib-Polydactyly Syndromes



(Left) Newborn infant with Jeune asphyxiating thoracic dystrophy (SRTD1) shows the extremely small chest with the narrow thorax. The chest almost has a pinched look and is in sharp contrast to the protuberant abdomen. Shortened limbs are also apparent. **(Right)** This is the same infant with Jeune viewed from the side. Note again the severely constricted thorax. The small chest results in pulmonary hypoplasia with a 70% mortality rate in the neonatal/infant period. This infant died shortly after birth.



(Left) Anteroposterior radiograph shows the narrow thorax of this newborn with Jeune syndrome. Note the short, straight ribs with normal ossification. The heart is not enlarged but appears so because of the small thoracic cavity. **(Right)** Midtrimester US shows a fetus confirmed postnatally to have Jeune asphyxiating thoracic dystrophy (SRTD1). Note the strikingly narrowed thorax when compared with the abdomen. AC was in 55th percentile, while chest circumference was well below 5th percentile for gestation.



(Left) Transverse US of the abdomen of a midtrimester fetus with suspected Jeune syndrome illustrates bilateral enlarged, echogenic kidneys, concerning for cystic dysplasia. This is a common associated finding in several of the short rib-polydactyly syndromes and can lead to oligohydramnios if severe. **(Right)** Ultrasound of this midtrimester male fetus with Jeune syndrome shows a curved, short femur with normal ossification. Short and mildly curved long bones, especially the femur, are common in this condition.

KEY FACTS

TERMINOLOGY

- Lethal skeletal dysplasia due to activating mutations in fibroblast growth factor receptor 3 gene (*FGFR3*)
- Divided into 2 subtypes based on morphologic findings
- Thanatophoric is Greek for death bearing

IMAGING

- **Thanatophoric dysplasia type I**
 - Long bones severely affected
 - Micromelia
 - Prominent bowing
 - Telephone receiver femur
 - Normal ossification
 - No evidence of fractures
 - Macrocephalic, relatively normal-shaped skull
- **Thanatophoric dysplasia type II**
 - Kleeblattschädel (cloverleaf) skull
 - Femurs longer, less curved
 - Platypondyly less marked

- Other findings similar to TD type I

TOP DIFFERENTIAL DIAGNOSES

- Achondrogenesis
- Homozygous achondroplasia
- Campomelic dysplasia
- Osteogenesis Imperfecta
- Fibrochondrogenesis
- Carpenter syndrome

PATHOLOGY

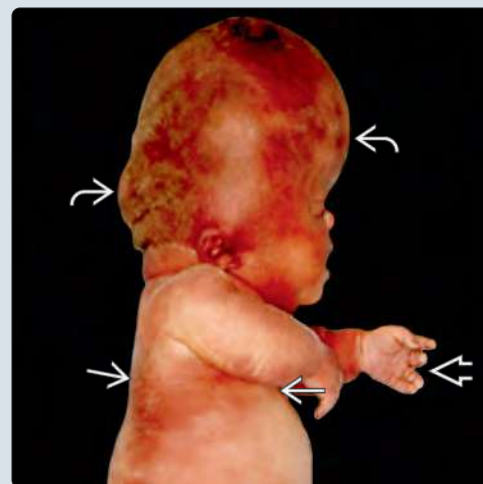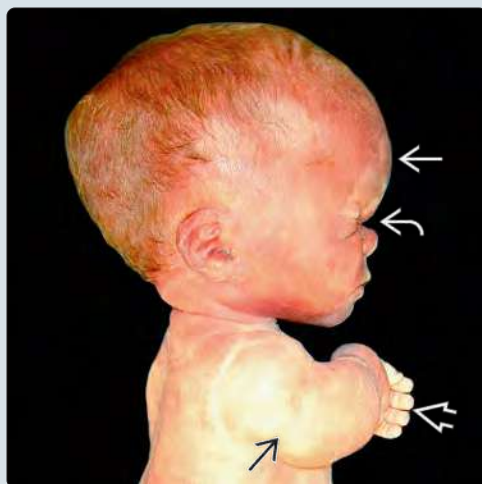
- Identifiable mutation found in up to 99% of TD type I and more than 99% of TD type II
- Sporadic, new, dominant mutation of *FGFR3* gene on short arm of chromosome 4

CLINICAL ISSUES

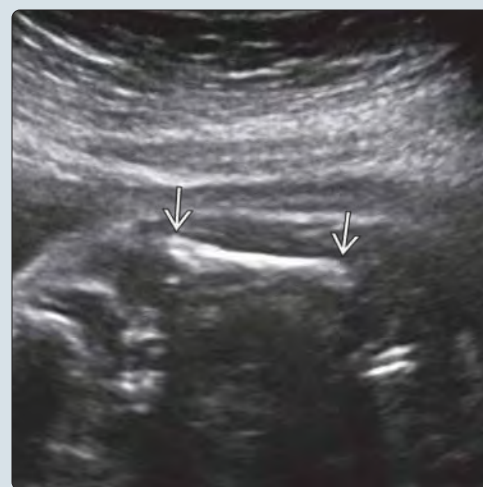
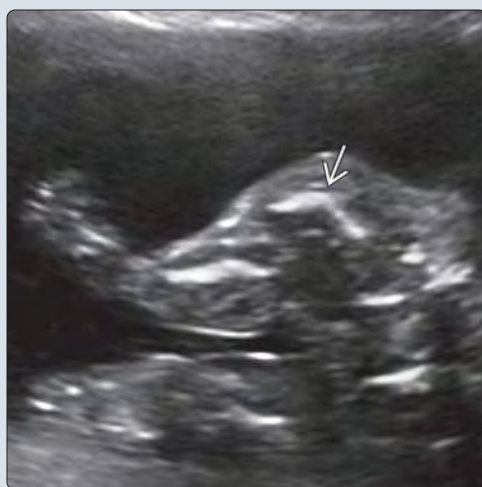
- Most common type of lethal osteochondrodystrophy
- 75% have severe polyhydramnios by late 2nd trimester
- Autopsy important for final specific diagnosis

(Left) Clinical photograph of TD type I shows marked frontal bossing with depressed nasal bridge and short upturned nasal tip. Note the head is disproportionately large, but relatively normal in shape. Micromelia of all extremities is typical. There is also brachydactyly.

(Right) In comparison, this is a clinical photograph of TD type II showing the kleeblattschädel skull shape. Again, the head is disproportionately large for the body. The chest is very small. Note the typical trident hand.



(Left) Ultrasound shows the femur of a midtrimester fetus with TD type I. Note the short, curved telephone receiver appearance. There is overlap in the clinical findings in TD types I and II, but in TD type I, the femurs are more severely affected, as in this case. **(Right)** In this fetus with type II TD, the femur is shortened but straight. While the femur may be slightly curved in type II, it contrasts with the marked curvature typical of type I.



TERMINOLOGY

Synonyms

- Thanatophoric dysplasia (TD), lethal skeletal dysplasia, thanatophoric dwarfism, lethal osteochondrodysplasia

Definitions

- Lethal skeletal dysplasia due to activating mutations in fibroblast growth factor receptor 3 gene (*FGFR3*)
- Divided into 2 main subtypes based on morphologic findings
- Thanatophoric is Greek for death bearing

IMAGING

General Features

- Best diagnostic clue
 - TD type I: Telephone receiver femur
 - TD type II: Kleeblattschädel (cloverleaf) skull
 - Micromelia with curved long bones
 - Polyhydramnios, often severe in 3rd trimester

Ultrasonographic Findings

- **TD type I**
 - Long bones severely affected
 - Micromelia
 - All measure well below 5th percentile for gestational age
 - Prominent bowing
 - Telephone receiver femur
 - Normal ossification
 - No evidence of fractures
 - Progressive shortening observed throughout gestation
 - Head
 - Macrocephalic, relatively normal-shaped skull
 - Depressed nasal bridge
 - Short, upturned nasal tip
 - Hypoplastic mid face
 - Frontal bossing, severe in 3rd trimester
 - Thorax
 - Small, narrow
 - Short horizontal ribs
 - Abnormal cardiothoracic ratio
 - Spine
 - Platyspondyly
 - Prominent lumbar kyphosis
 - Normal ossification
 - Hands
 - Very short phalanges
 - Trident-shaped hands
 - Miscellaneous
 - Polyhydramnios, often severe, especially in 3rd trimester
 - Limitation in joint mobility noted
- **TD type II**
 - Kleeblattschädel (cloverleaf) skull common in type II
 - Rarely seen in type I
 - Femurs longer, straighter than in type I
 - Platyspondyly less marked than in type I
 - Other findings similar to TD type I

Radiographic Findings

- Neonatal/post mortem
 - Spine
 - Notched end plates with H configuration on frontal view
 - Platyspondyly is less severe in type II
 - Prominent lumbar kyphosis
 - Pelvis
 - Hypoplastic with medial spicules
 - Accessory pelvic ossification centers
 - Short, broad pubic and ischial bones
 - Small sacrosiatic notch
 - Long bones
 - Micromelia
 - Short and broad tubular long bones
 - Prominent bowing, especially TD type I
 - Flared irregular metaphyses
 - No fractures
 - Calvarium
 - Small facial bones
 - Large calvarium
 - Variable craniosynostosis
 - Kleeblattschädel (cloverleaf) skull common in type II; rare in type I

Imaging Recommendations

- Best imaging tool
 - Midtrimester ultrasound, both 2D and 3D/4D
 - 1st-trimester transvaginal ultrasound
- Measure, assess morphology of all long bones
- Carefully assess calvarium shape, profile
- Evaluate fetal spine
- 3D/4D ultrasound may be additive in many cases
 - Useful for spatial relationships
 - Evaluation of facial dysmorphism
 - Relative proportion of appendicular skeletal elements
 - Images aid in counseling parents

DIFFERENTIAL DIAGNOSIS

Achondrogenesis

- Absent spine ossification
- Variable skull ossification

Homozygous Achondroplasia

- Both parents affected → 25% risk of homozygous achondroplasia
- Lethal due to severe pulmonary hypoplasia
- May not be apparent until > 20 weeks

Campomelic Dysplasia

- Hypoplastic scapulae
- Sharp midshaft tibial angulation
- Lower extremities more severely affected

Osteogenesis Imperfecta

- Bones acutely angulated or crumpled from fractures
- Decreased ossification, especially calvarium
- Ribs appear "beaded" due to calluses from multiple fractures

Fibrochondrogenesis

- Cloverleaf skull common
- Dumbbell-shaped long bones
- Hypoplastic posterior vertebrae with clefts

Carpenter Syndrome

- Cloverleaf skull
- Polysyndactyly
- Cardiac abnormalities
- Umbilical hernia/omphalocele
- Limbs straight, not as short

PATHOLOGY

General Features

- Etiology
 - *FGFR3* member of tyrosine kinase receptor family
 - Tyrosine kinase important in cell growth and differentiation
 - Not due to simple haploinsufficiency
- Genetics
 - Sporadic, new, dominant mutation of *FGFR3* gene on short arm of chromosome 4
 - Identifiable mutation found in up to 99% of TD type I and more than 99% of TD type II
 - TD type I involves lysine to arginine substitution at position 248 in ~ 2/3 of cases
 - TD type II involves lysine to glutamine substitution at position 650 in tyrosine kinase domain of receptor
 - Very low recurrence risk; germline mosaicism is theoretic possibility but not previously reported
 - Has occurred in monozygous twins
 - Discordance for kleeblattschädel skull reported
 - Amniocentesis or chorionic villus sampling analysis detects *FGFR3* mutations
- Associated abnormalities
 - Cleft palate
 - Heterotopias
 - Polymicrogyria
 - Other microscopic central nervous system abnormalities
- Defective differentiation of chondrocytes in cartilage growth plates

CLINICAL ISSUES

Presentation

- Most common signs/symptoms
 - Usually found on routine screening ultrasound
 - Can be diagnosed as early as 14 weeks
 - 1st-trimester associations
 - Increased nuchal thickness
 - Reversed diastolic flow in ductus venosus
- Other signs/symptoms
 - May be diagnosed late when polyhydramnios causes increased uterine size
 - 75% severe polyhydramnios by late 2nd trimester

Demographics

- Epidemiology
 - Most common lethal osteochondrodystrophy
 - 1st described as distinct entity by Maroteaux in 1967

- 1:10,000-40,000 live births in USA
- No ethnic or gender predilection
- Advanced paternal age is risk factor
 - 50% occur with paternal age > 35 yr

Natural History & Prognosis

- Lethal within 1st few hours to days of life
 - Small thorax: Pulmonary hypoplasia
 - Central apnea also primary cause of death
 - Abnormal skull/spine/small foramen magnum → brainstem compression
 - Rare survivors beyond infancy have been described
 - Ventilator dependent
 - Mental retardation with seizures

Treatment

- No fetal or neonatal treatment available
- Amniocentesis
 - Molecular testing for *FGFR3* mutations to confirm diagnosis
 - Therapeutic reduction amniocentesis for maternal symptoms in continuing pregnancy or prior to labor
- Offer pregnancy termination
- If pregnancy progresses and diagnosis is certain
 - Avoidance of fetal monitoring, cesarean section
 - No intervention for preterm labor
 - Psychological support for family, perinatal hospice
- If diagnosis unclear and infant liveborn, resuscitation appropriate until confirmatory tests performed
- Autopsy important for final specific diagnosis
 - Radiographs essential
 - DNA analysis for *FGFR3* mutations
 - Bone/cartilage biopsy
 - International Skeletal Dysplasia Registry at Cedars-Sinai Hospital in Los Angeles for variant cases
- Deliver in tertiary center with expertise in fetal genetic pathology/skeletal dysplasia

DIAGNOSTIC CHECKLIST

Consider

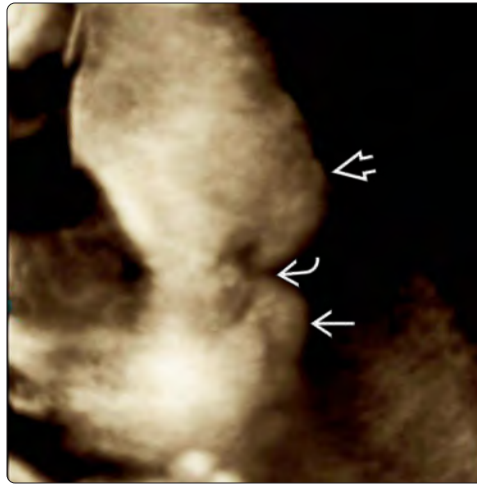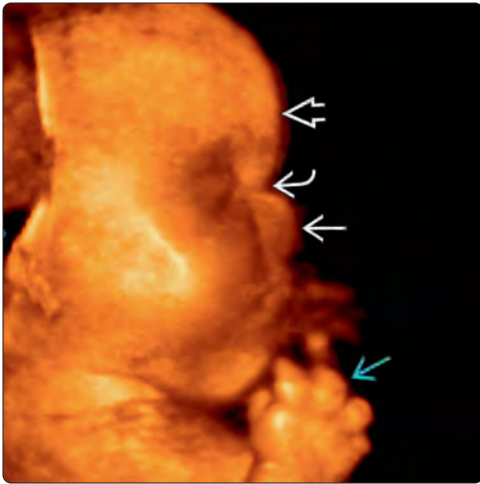
- 3D ultrasound often useful in elaborating phenotype, especially when counseling parents

Image Interpretation Pearls

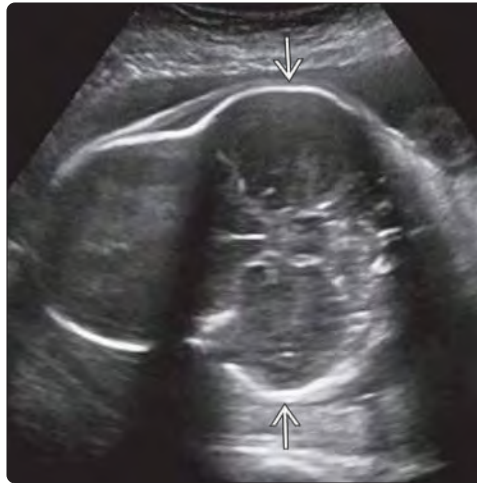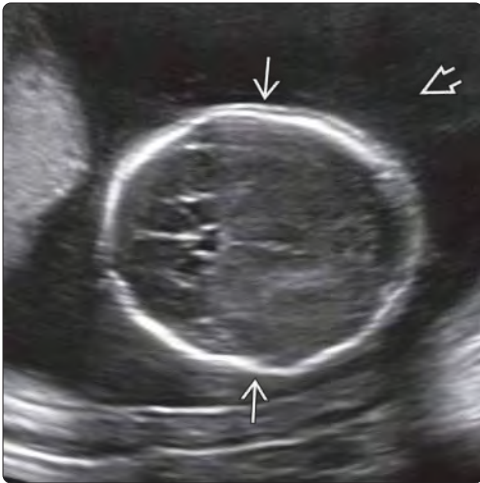
- Micromelia with normal ossification, curved femora, and cloverleaf skull are classic features

SELECTED REFERENCES

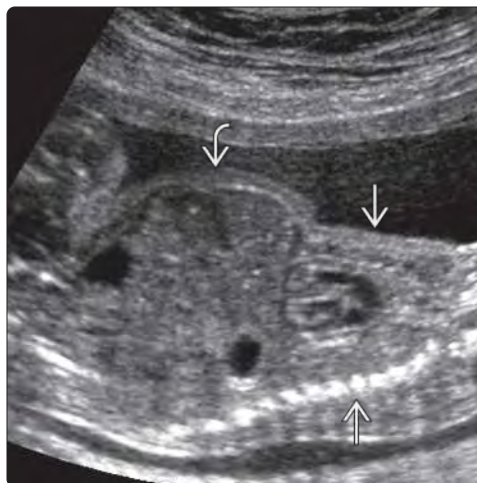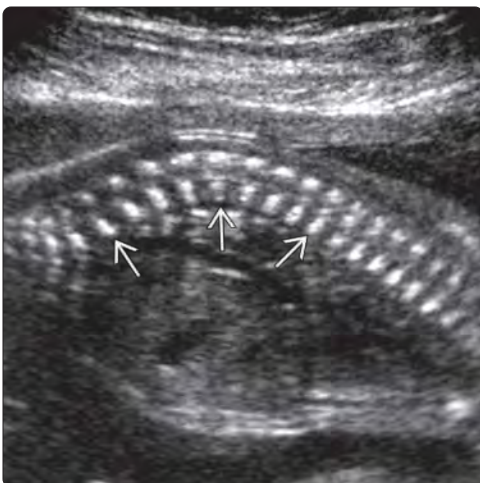
1. Chitty LS et al: Non-invasive prenatal diagnosis of achondroplasia and thanatophoric dysplasia: next generation sequencing allows for a safer, more accurate and comprehensive approach. *Prenat Diagn.* 35(7):656-62, 2015
2. Del Piccolo N et al: Effect of thanatophoric dysplasia type I mutations on *FGFR3* dimerization. *Biophys J.* 108(2):272-8, 2015
3. Zhen L et al: Increased first-trimester nuchal translucency associated with thanatophoric dysplasia type 1. *J Obstet Gynaecol.* 1-3, 2015
4. Pazzaglia UE et al: Thanatophoric dysplasia. Correlation among bone X-ray morphometry, histopathology, and gene analysis. *Skeletal Radiol.* 43(9):1205-15, 2014
5. Xue Y et al: *FGFR3* mutation frequency in 324 cases from the International Skeletal Dysplasia Registry. *Mol Genet Genomic Med.* 2(6):497-503, 2014



(Left) 3D ultrasound of a midtrimester fetus shows the pronounced frontal bossing, depressed nasal bridge, and short upturned nasal tip that are typical sonographic features of type I TD. Brachydactyly is also noted. (Right) In this 29-week fetus with type II TD, severe frontal bossing is apparent due to the abnormal cloverleaf or kleeblattschädel skull shape. Like in TD type I, a depressed nasal bridge and short upturned nose are seen.

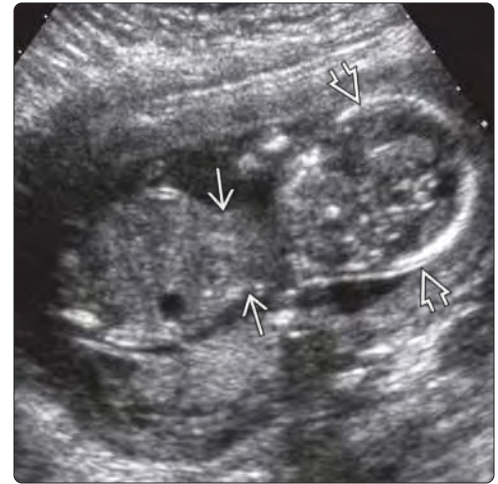
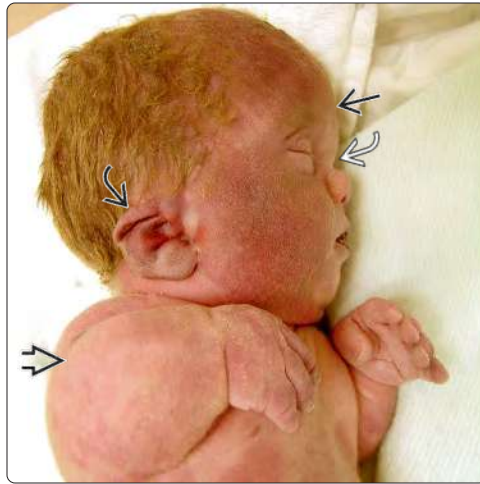

(Left) Although disproportionately large for the body, the calvarial shape in TD type I is usually relatively normal, as seen in this ultrasound of a 21-week fetus. Ossification is also normal. Mildly increased amniotic fluid is already present at this early gestation. Severe polyhydramnios is inevitable by the 3rd trimester in TD. (Right) Axial ultrasound in this 29-week fetus shows an abnormal skull configuration with temporal-parietal prominence typical of a kleeblattschädel, or cloverleaf, skull in TD type II.

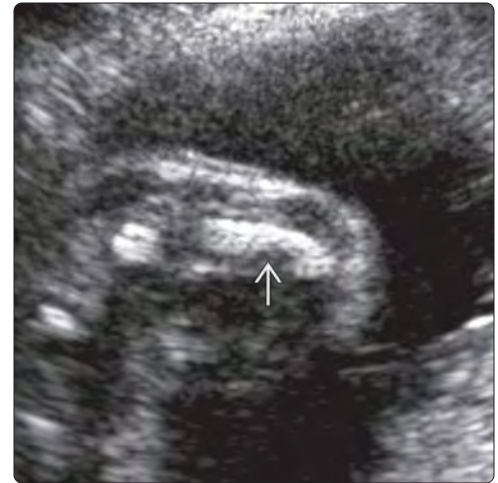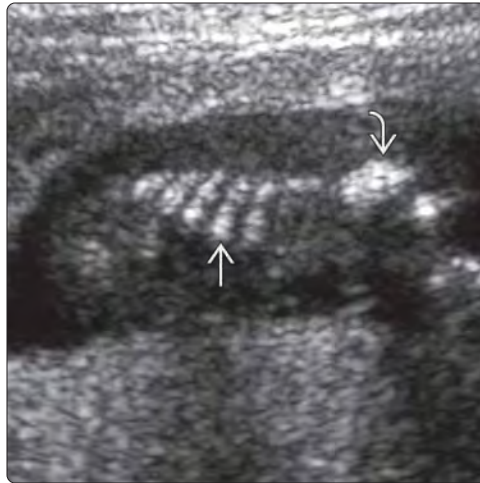


(Left) Sagittal ultrasound of a 3rd-trimester fetus with TD shows platyspondyly and marked thoracolumbar kyphosis that is common in TD as well as in other severe skeletal dysplasias. Platyspondyly is usually more prominent in TD type I than TD type II. (Right) Sagittal ultrasound shows the small chest size when compared with the larger, more protuberant abdomen in a 3rd-trimester fetus with TD type I.

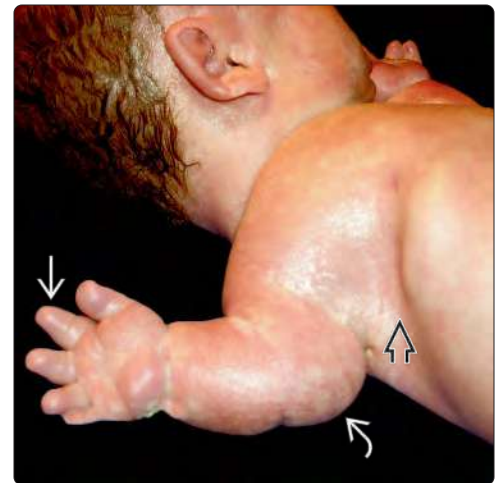
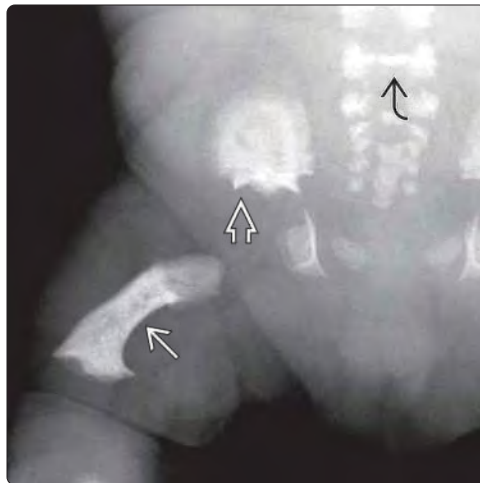
(Left) Stillborn infant with classic features of TD type I. The calvarial shape is normal although large. Frontal bossing with a depressed nasal bridge, short nose, and low-set ears are seen. Micromelia is also evident. **(Right)** Coronal ultrasound shows findings of TD type I in a 15-week fetus. Note the apparent macrocephaly and the very small chest. Increased nuchal translucency (NT) was previously seen in the 1st trimester. Increased NT is a nonspecific finding that is common in many skeletal dysplasias.

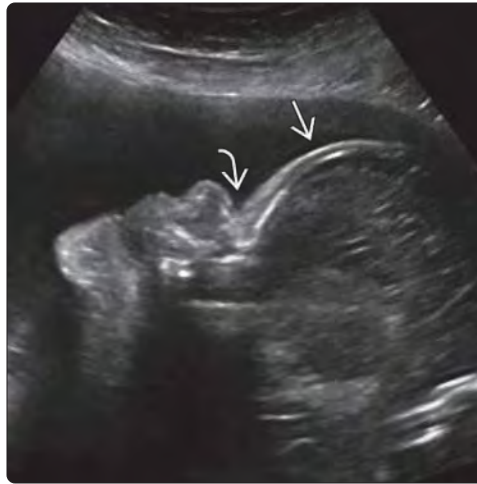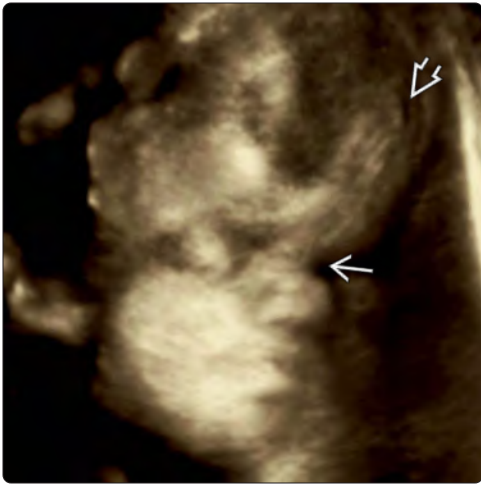


(Left) Coronal oblique ultrasound in the same fetus with TD type I shows straight ribs without evidence of fractures. The scapula is also seen, which helps differentiate TD type I from campomelic dysplasia. **(Right)** Ultrasound shows the femur of a midtrimester fetus with TD type I. Note the short, curved telephone receiver appearance. There is overlap in findings in TD type I and II, but in TD type I, the femurs are more severely affected, as in this case.

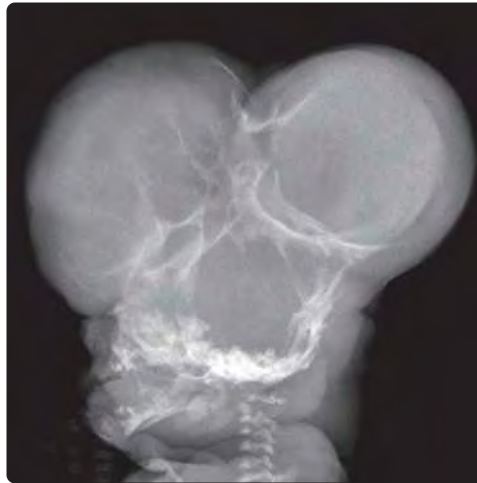
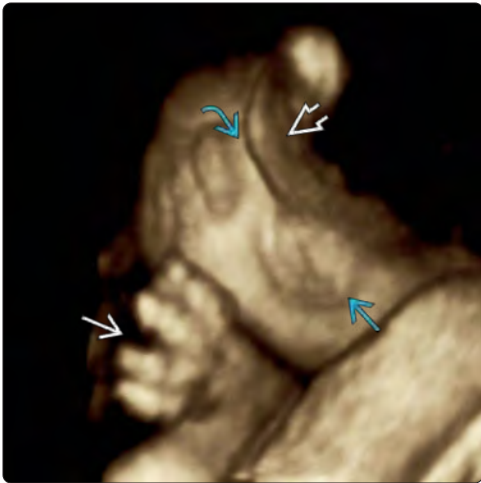
(Left) Radiograph shows the curved telephone receiver femur of TD type I. Platypondyly is obvious in the lumbar spine, and the spiculated appearance of the iliac wing is shown. **(Right)** Clinical photograph of a stillborn infant illustrates several features of TD type I, including brachydactyly, trident hand, micromelia, and short, horizontal ribs creating a bell-shaped chest.

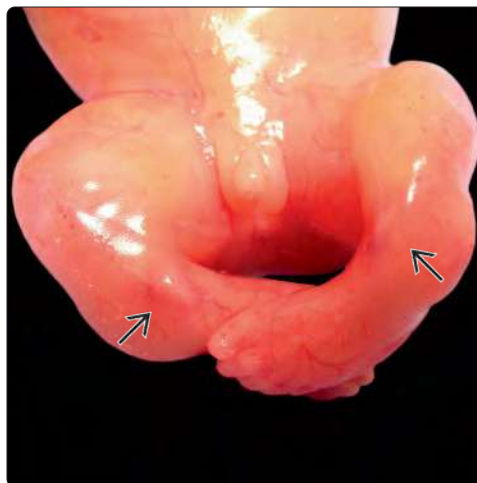
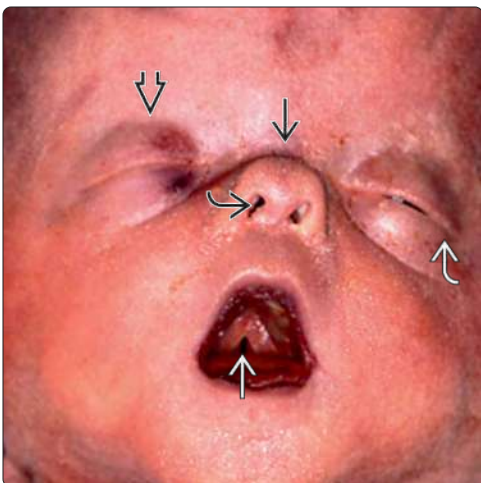




(Left) In this 3D ultrasound of a 29-week fetus with type II TD, the markedly abnormal calvarial shape is apparent. This cloverleaf or kleeblattschädel skull is common in type II TD. The depressed nasal bridge can also be seen. (Right) A sagittal image of the same fetus at 29 weeks shows the striking frontal prominence and depressed nasal bridge. Kleeblattschädel calvarium with its complex pattern of craniosynostosis results in the strikingly abnormal shape.



(Left) 3D ultrasound of this 3rd-trimester fetus with TD shows brachydactyly with a classic trident appearance. Proptotic eyes due to shallow orbits and frontal bossing with a depressed nasal bridge can also be seen. (Right) Lateral radiograph of a stillborn with TD type II shows a particularly severe kleeblattschädel or cloverleaf skull.



(Left) Clinical photograph of a stillborn infant with TD type II shows a cleft palate, depressed nasal bridge, orbital proptosis, and downslanting palpebral fissures. The nose is short and upturned with anteverted nares. (Right) Clinical photograph of a stillborn fetus illustrates a phenotype associated with the San Diego variant of TD. The sharp angulation of the extremities was mistaken for campomelic dysplasia on ultrasound. A typical FGFR3 mutation confirmed the diagnosis of TD postnatally.

KEY FACTS

TERMINOLOGY

- Talipes equinovarus
- Ultrasound classification
 - Isolated if no other anomalies seen (2/3)
 - Complex if other anomalies seen (1/3)

IMAGING

- Coronal tibia/fibula view shows varus foot
 - Foot is turned in at ankle
- Sagittal view shows pointed toes
- Plantar foot view shows short angulated foot
- 3D ultrasound helpful to show severity and morphology
- 2/3 of cases are bilateral

TOP DIFFERENTIAL DIAGNOSES

- Rocker-bottom foot
- Ectrodactyly
- Amniotic band syndrome

PATHOLOGY

- Complex club foot associated with aneuploidy (10-30%)
 - Trisomy 18 most common
- Isolated club foot with low aneuploidy rate (1.7-2.3%)
- Associated findings
 - Spina bifida is most common
 - Musculoskeletal and neurologic anomalies
 - Oligohydramnios from any cause

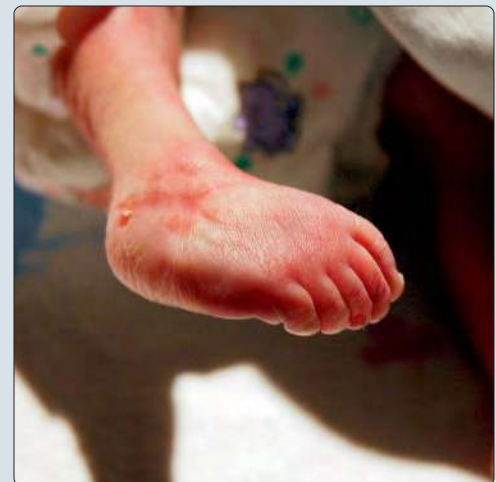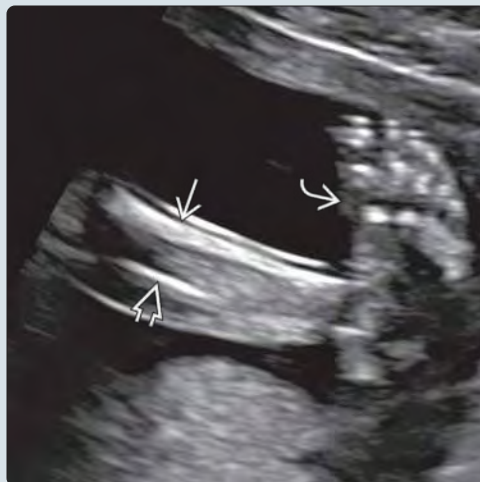
CLINICAL ISSUES

- Most common musculoskeletal anomaly (1:1000 newborns)
- Prognosis depends on associated anomalies
- Conservative management tried first

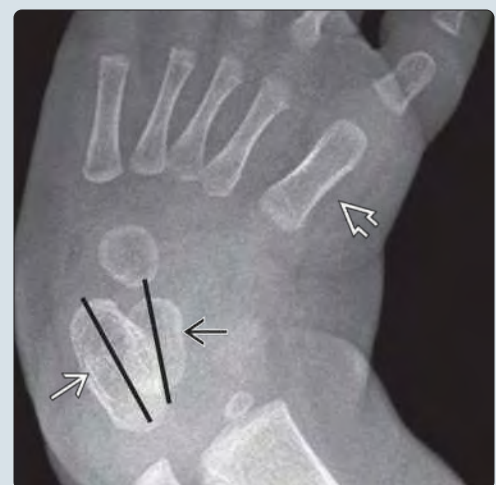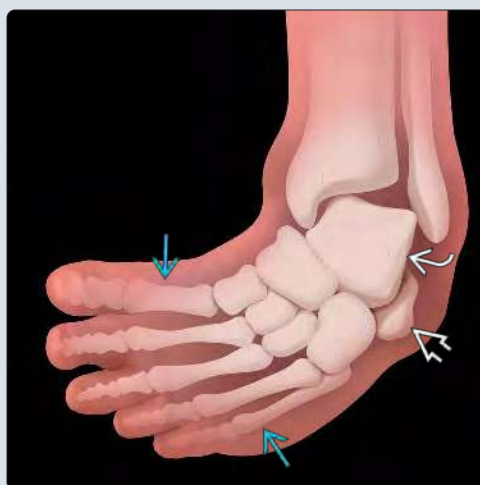DIAGNOSTIC CHECKLIST

- Beware of transient foot position
- Look carefully at upper extremities and note fetal movement for more complex disorder

(Left) In this 21-week fetus with isolated unilateral clubfoot, the coronal long axis of the foot is seen in the same plane as the coronal axis of the tibia and fibula. Normally, the metatarsals should be seen in the short axis when the tibia and fibula are seen in the coronal plane. **(Right)** Clinical photograph shows talipes equinovarus. The right foot is rotated inward (varus) and plantar flexed (equinus).



(Left) Graphic of a clubfoot shows the varus position of the talus with adducted forefoot bones and inversion of the calcaneus, giving the foot a classic inverted clubfoot morphology. **(Right)** AP foot radiograph in a 9-month-old infant shows typical clubfoot findings with reduced angle between the talus and calcaneus (hindfoot varus). Varus angulation of the forefoot is also present with the long axis of the talus being very lateral to the 1st metatarsal.



TERMINOLOGY**Abbreviations**

- Clubfoot (CF)

Definitions

- Talipes equinovarus is most common
 - Midfoot cavus (high arch)
 - Forefoot adductus (toes turned in)
 - Hindfoot varus (heel turned in)
 - Hindfoot equinus (heel pulled up)
- Isolated CF in 2/3 (no other anomalies on prenatal scan)
- Complex CF in 1/3 (+ structural anomalies or aneuploidy)
- Bilateral in 2/3, unilateral in 1/3

IMAGING**General Features**

- Best diagnostic clue
 - Foot is turned in with toes pointed
- Detection rates improving (75-80% recently reported)
 - 2-12% false-positive rates reported

Ultrasonographic Findings

- Coronal tibia/fibula view shows varus foot
 - Might see full coronal metatarsals instead of short axis
- Sagittal view shows pointed toes
- Plantar foot view shows short angulated foot
 - Forefoot adduction + hindfoot varus
- 1/3 with other anomalies
 - Spina bifida most common
 - Musculoskeletal and neurologic
- Associated with chronic severe oligohydramnios

Imaging Recommendations

- Best imaging tool
 - Adequate lower extremities views
 - Coronal view of tibia/fibula + short axis foot
 - Plantar view of foot
 - 3D ultrasound to assess severity and morphology
- Protocol advice
 - Genetic testing suggested for complex CF
 - Not necessary for isolated CF (controversial)

DIFFERENTIAL DIAGNOSIS**Rocker-Bottom Foot**

- Convex foot ± CF
- Strong association with trisomy 18

Ectrodactyly

- Split hand/foot deformity ("lobster claw")
- Isolated or with other anomalies

Amniotic Band Syndrome

- Entrapment of fetal parts by disrupted amnion
- Amputations, limb constriction, body clefts

PATHOLOGY**General Features**

- Etiology
 - Early limb development disruption

- 80% with anterior tibial artery hypoplasia
- Lack of fetal movement from any cause
- Genetics
 - Complex CF associated with aneuploidy (10-30%)
 - Trisomy 18, trisomy 13, triploidy, chromosome 22q11 deletion syndrome, sex chromosome anomalies
 - Isolated CF with low aneuploidy rate (1.7-2.3%)
 - Familial club foot: 12-20%
- Associated abnormalities
 - Spina bifida is most common
 - Musculoskeletal and neurologic anomalies
 - Arthrogryposis akinesia sequence
 - Skeletal dysplasia
 - Myotonic dystrophy
 - VACTERL association
 - Oligohydramnios from any cause
 - Prenatal isolated CF with 4% rate of malformations at birth

CLINICAL ISSUES**Demographics**

- Epidemiology: 1-3:1000
- Gender: M:F = 2:1

Natural History & Prognosis

- Complex CF with worse prognosis
 - Prognosis depends on associated anomalies
- Bilateral vs. unilateral with same prognosis if isolated CF
 - Most grow up to wear ordinary shoes and live normal active lives

Treatment

- Conservative management
 - Gentle manipulation, serial casting
- Surgical therapy if conservative fails
 - Percutaneous Achilles tenotomy
 - Achilles tendon lengthening
 - Bone operation
 - Surgery at 6 months when necessary

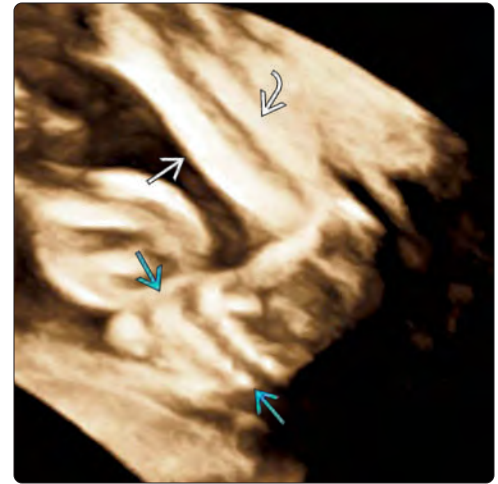
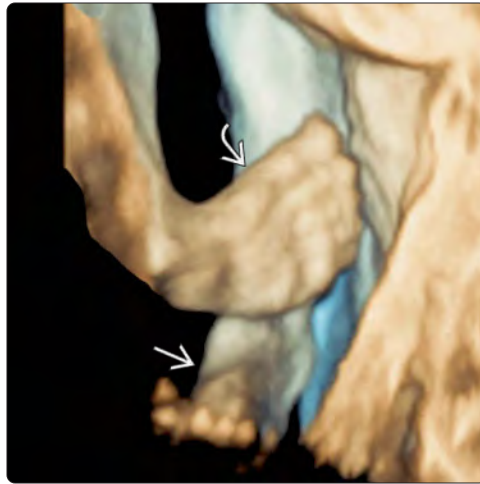
DIAGNOSTIC CHECKLIST**Image Interpretation Pearls**

- Look carefully at upper extremities and note fetal movement when CF seen
- Beware of transient foot position
 - Particularly in 3rd trimester
 - Higher false-positive diagnoses
 - Obtain follow-up for mild positive cases

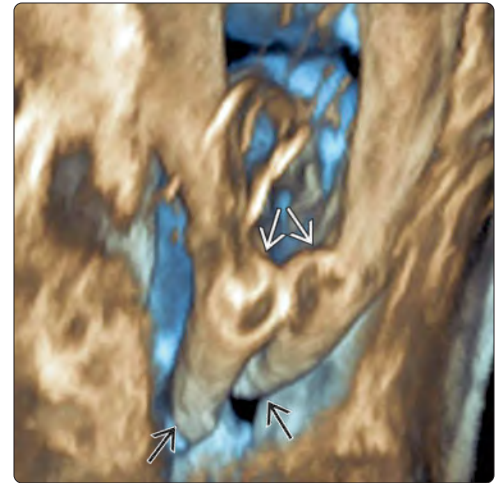
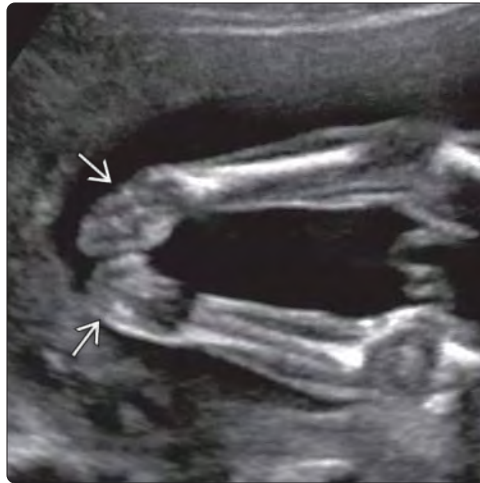
SELECTED REFERENCES

1. Toufaily MH et al: Congenital talipes equinovarus: frequency of associated malformations not identified by prenatal ultrasound. *Prenat Diagn.* 35(3):254-7, 2015
2. Viaris de le Segno B et al: Prenatal diagnosis of clubfoot: Chromosomal abnormalities associated with fetal defects and outcome in a tertiary center. *J Clin Ultrasound.* 44(2):100-5, 2015
3. Mahan ST et al: Prenatal screening for clubfoot: what factors predict prenatal detection? *Prenat Diagn.* 34(4):389-93, 2014
4. Seravalli V et al: Prevalence and prenatal ultrasound detection of clubfoot in a non-selected population: an analysis of 549931 births in Tuscany. *J Matern Fetal Neonatal Med.* 1-4, 2014

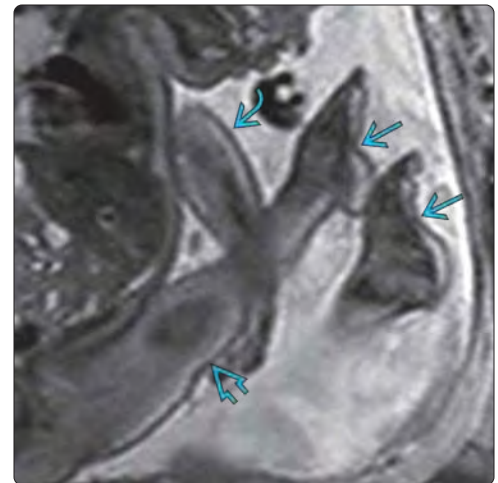
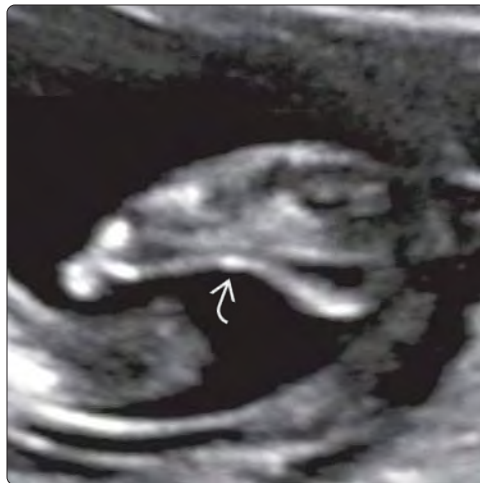(Left) In this case of isolated unilateral clubfoot at 24 weeks, 3D ultrasound shows a right clubfoot and a normal left foot. 3D images allow for better appreciation of the severity of the clubfoot. **(Right)** 3D bone-rendered views allows for visualization of the tibia, fibula, and metatarsals. Being able to count metatarsals and toes is important for ruling out amniotic bands or ectrodactyly. Five metatarsals are seen in this 23-week fetus with isolated clubfoot.

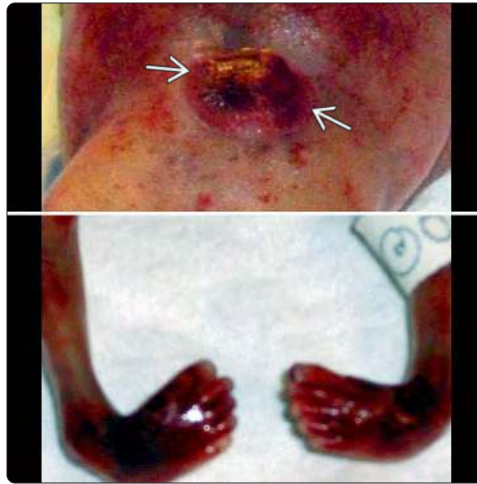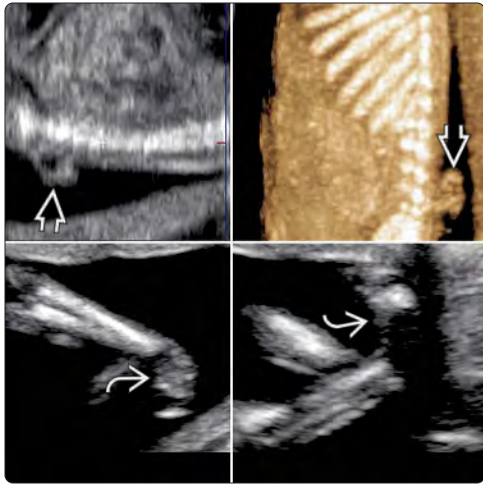


(Left) At the time of this anatomy scan, this 20-week, 4-day fetus was found to have bilateral clubfoot deformity. On this lower extremity coronal view, the feet are seen inverted towards the midline and towards each other. No other anomalies were seen. **(Right)** 3D ultrasound of the same fetus shows the downward pointing toes and lifted heels to better advantage.

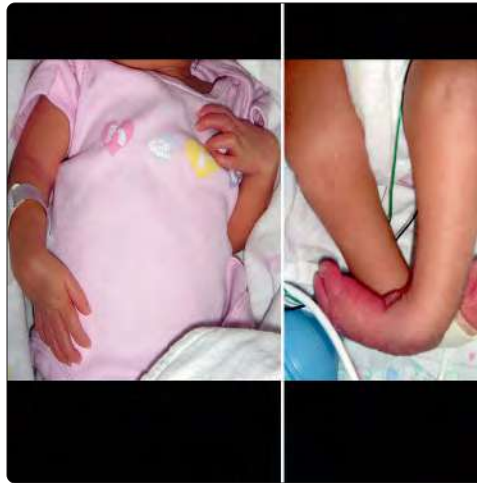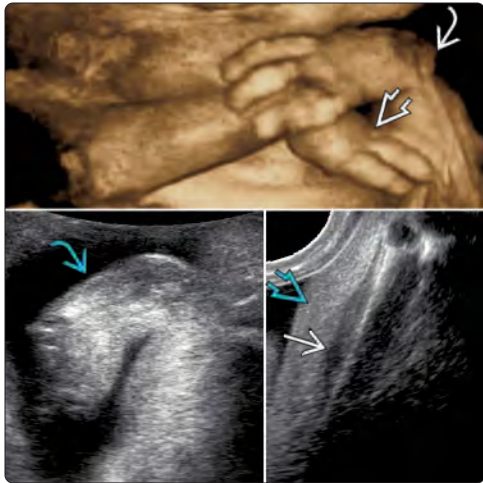


(Left) A close-up lateral view of the foot in a fetus with a clubfoot shows marked plantar flexion. The image is reminiscent of a ballerina in pointe shoes, which is not a normal foot position for a fetus. The fetus also had bilateral upper extremity contractures. **(Right)** MR performed in another fetus with clubfeet and upper extremity contractures shows the extreme midfoot cavus (high arch) seen with clubfeet. The legs and arms were fixed in a hyperextended position in this fetus with arthrogryposis.

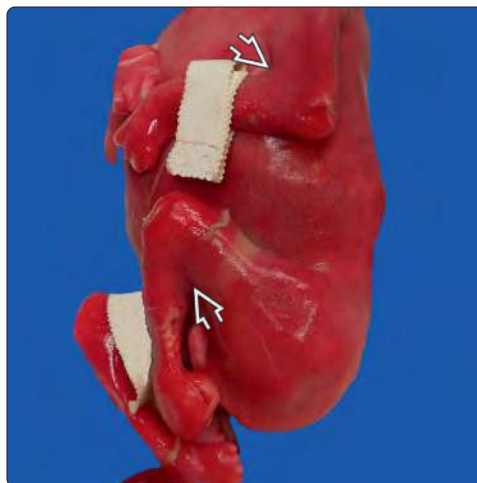
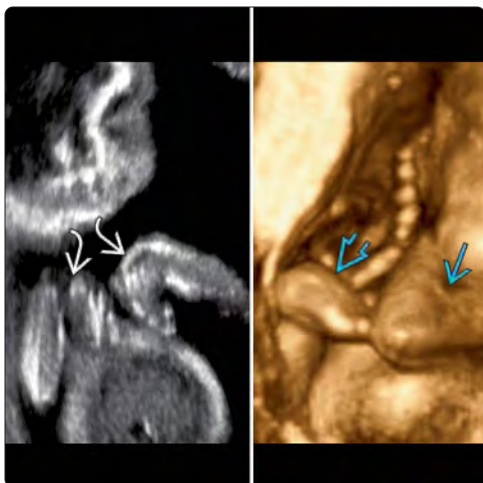




(Left) 3D and 2D ultrasounds in this fetus with lumbar meningocele show bilateral clubfeet. Spina bifida is the most common association with clubfeet, most often bilateral. (Right) Clinical photograph obtained shortly after the ultrasound in the same patient confirms the spina bifida and clubfeet seen at the 20-week scan.



(Left) In this fetus with distal arthrogyriosis, the fetal wrists were consistently flexed and the metacarpal-phalangeal joints and hands were hyperextended. In addition, there were bilateral clubfeet with noticeable atrophy of lower extremity musculature (compared to subcutaneous fat). (Right) Clinical photograph of the newborn, in the same case, shows the findings seen by ultrasound. Careful evaluation of the upper extremities should be performed when bilateral club feet are seen.



(Left) This midgestation fetus with multiple pterygium syndrome and hydrocs (not shown) had fixed contractures of the hands, a subtle elbow web, and severe clubfoot. (Right) Clinical photograph of the same fetus shows the features of multiple pterygium syndrome, including the webbed elbows and knees.

KEY FACTS

TERMINOLOGY

- Congenital vertical talus
- Definition
 - Hindfoot equinus
 - Hindfoot valgus
 - Midfoot dorsiflexion

IMAGING

- Convex sole of foot + upturned toes
 - Seen best with 3D ultrasound
- 70% bilateral
- Rarely isolated finding in fetus
- Key associations
 - Trisomy 18
 - Spine anomalies
 - Other extremity anomalies
 - Clubfoot
 - Arthrogryposis fetal akinesia deformation sequence

TOP DIFFERENTIAL DIAGNOSES

- Clubfoot
- Ectrodactyly
- Amniotic band syndrome

PATHOLOGY

- Intrinsic hindfoot anomaly (most common cause)

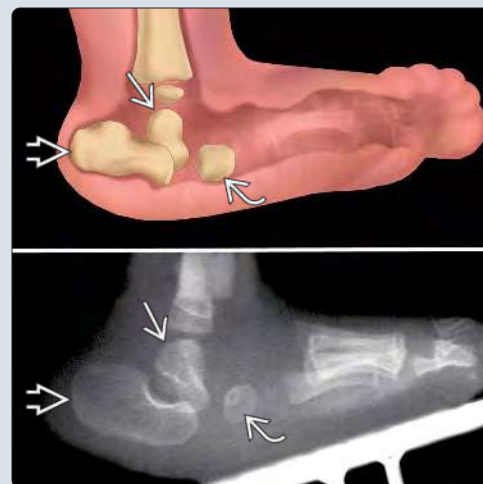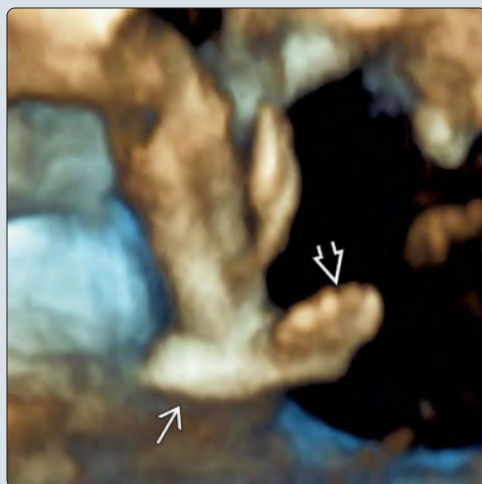
CLINICAL ISSUES

- 50% isolated in live birth population
 - Considered severe foot anomaly with morbidities
- Treatment trending toward minimally invasive approach
 - Serial manipulation + casting
- Extensive soft tissue release surgeries still performed

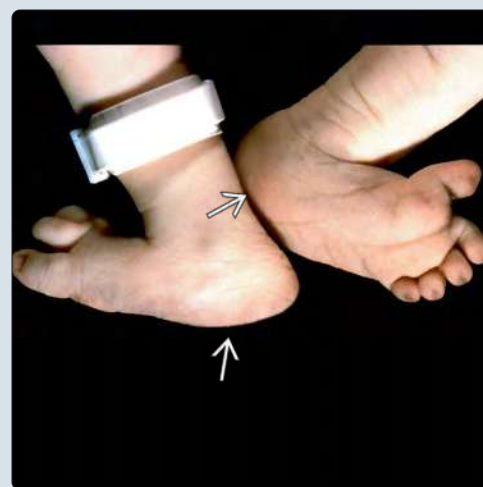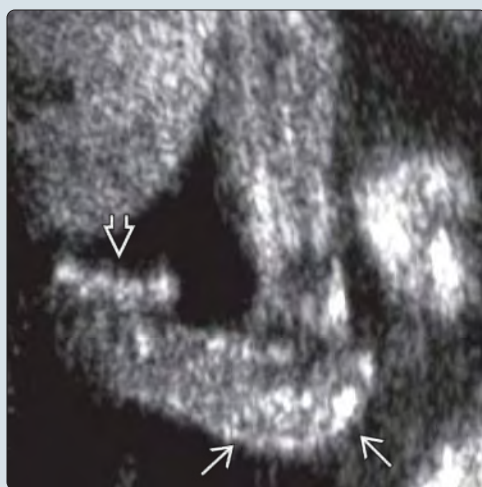
DIAGNOSTIC CHECKLIST

- Genetic testing recommended
- Follow-up on cases that appear isolated
 - Associated anomalies may be subtle

(Left) 3D ultrasound at the time of anatomy scan in a fetus with trisomy 18 shows classic morphology of rocker-bottom foot. The toes are upturned and the sole of the foot is convex. This fixed foot position is often easier to demonstrate with 3D than standard 2D ultrasound. **(Right)** A graphic depiction and radiograph of the foot of a neonate with VACTERL association shows the vertical talus, equinus calcaneus, and dorsally dislocated navicular, diagnostic of rocker-bottom foot.



(Left) Sagittal ultrasound shows severe rocker-bottom foot in a 2nd-trimester fetus with multiple other anomalies. The foot resembles a Persian slipper as the sole is convex and the toes are upturned. **(Right)** Clinical photograph of a neonate with spine anomalies and bilateral rocker-bottom foot shows the classic appearance of hindfoot equinus and splayed upturned toes.



TERMINOLOGY

Abbreviations

- Rocker-bottom foot (RF)

Synonyms

- Congenital vertical talus

Definitions

- Hindfoot equinus and valgus
 - Associated midfoot dorsiflexion
 - Dorsal dislocation of navicular on head of talus

IMAGING

General Features

- Best diagnostic clue
 - Plantar convexity on lateral foot image
 - Sole of foot is convex (dorsum is concave)
 - Uprturned toes (contractures of extensor tendons)
 - Persian slipper appearance of foot
- Location
 - 70% bilateral

Ultrasonographic Findings

- Rarely isolated when seen in utero
 - 50% isolated in neonatal series
- Strong association with trisomy 18 (T18)
 - Look for other abnormalities associated with T18
 - Choroid plexus cyst
 - Clenched hand with overlapping fingers
 - Cardiac, abdominal wall, and facial defects
 - Fetal growth restriction
- Associated with other anomalies
 - RF + clubfoot (CF) most common
 - Varus foot + convex sole
 - Valgus foot + convex sole more rare
 - Arthrogyposis association (look for contractures)
 - Spine anomalies (VACTERL, spina bifida)

Imaging Recommendations

- Best imaging tool
 - 3D ultrasound + multiplanar views
- Protocol advice
 - Good routine lower extremity evaluation
 - Short and long axis foot views are key
 - Early diagnosis associated with higher risk for aneuploidy
 - Evaluate extremities at time of nuchal translucency screening
 - Beware of transient foot position

DIFFERENTIAL DIAGNOSIS

Clubfoot

- More common than RF
- Talipes equinovarus: Medially rotated flexed foot

Ectrodactyly

- Split hand/foot deformity

Amniotic Band Syndrome

- Entrapment of fetal parts by disrupted amnion
- Amputations, constrictions, body wall defects

PATHOLOGY

General Features

- Etiology
 - Intrinsic hindfoot anomaly
 - Intrinsic abnormality of muscle
 - Restricted in utero environment
 - Chronic oligohydramnios
- Genetics
 - T18 most common association
 - Other trisomies: 13, 15
 - Syndromes
 - De Barys: Cutis laxa, musculoskeletal and neurologic abnormalities
 - Costello: Faciocutaneouskeletal syndrome
 - Rasmussen: Ear and foot anomalies
 - 20% of isolated cases have family history of vertical talus
- Associated abnormalities
 - Spina bifida
 - CF is more common (24%)
 - Arthrogyposis fetal akinesia deformation sequence
 - Multiple limb contractures
 - Polyhydramnios
 - Multiple pterygium syndrome

CLINICAL ISSUES

Demographics

- Epidemiology
 - 1:10,000 live births
 - 50% isolated in live birth population

Natural History & Prognosis

- Depends on karyotype and associated anomalies
- Isolated still considered severe anomaly with morbidity
 - Stiffness, functional disability, pain

Treatment

- Extensive soft tissue release surgeries is standard
- More recent minimally invasive approach with excellent short-term results (long-term studies underway)
 - Serial manipulation and casting

DIAGNOSTIC CHECKLIST

Consider

- Genetic testing recommended
- Follow-up on cases that appear isolated
 - Rule out transient finding
 - Reevaluate for associated anomalies

Image Interpretation Pearls

- Look carefully at feet when associated anomalies seen

SELECTED REFERENCES

1. Miller M et al: Congenital vertical talus: Etiology and management. *J Am Acad Orthop Surg.* 23(10):604-11, 2015
2. Rice KJ et al: Diagnosis of fetal limb abnormalities before 15 weeks: cause for concern. *J Ultrasound Med.* 30(7):1009-19, 2011
3. McKie J et al: Congenital vertical talus: a review. *Clin Podiatr Med Surg.* 27(1):145-56, 2010

KEY FACTS

TERMINOLOGY

- Gap between 1st and 2nd toes
- May involve 1 or both feet

IMAGING

- 2D or 3D plantar foot view best for diagnosis
 - Big toe abducted
- Most often seen in normal fetus
 - 2-5% of normal fetuses
- Can be minor marker for aneuploidy
 - Minor marker for trisomy 21 (T21)
 - Look for other markers for T21
 - Minor marker for trisomy 18 (T18)
 - Not isolated finding
 - Look for anomalies and T18 markers
- Seen with other foot anomalies
 - Clubfoot and rocker-bottom foot
- Rarely seen with other skeletal dysplasias

TOP DIFFERENTIAL DIAGNOSES

- Syndactyly
 - Associated with multiple syndromes including Apert and Carpenter
- Ectrodactyly (split hand/foot deformity)
- Amniotic bands
 - Toe gaps from amputation

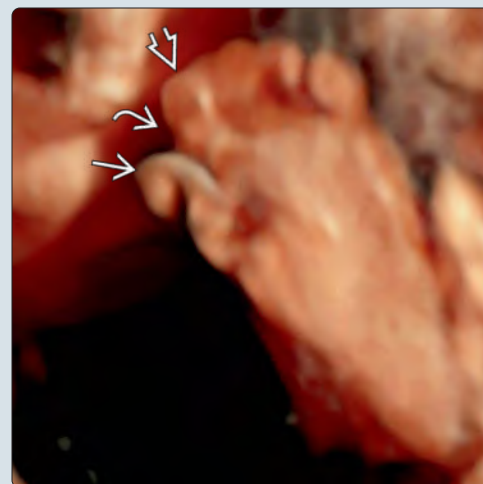
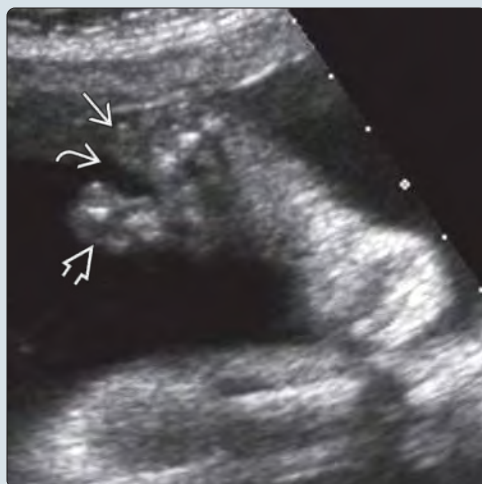
CLINICAL ISSUES

- Most often seen in normal fetus
 - May be familial or idiopathic
 - No treatment necessary
- No good relative risk ratio data for T21
- Consider amniocentesis if high risk for aneuploidy or other anomalies seen

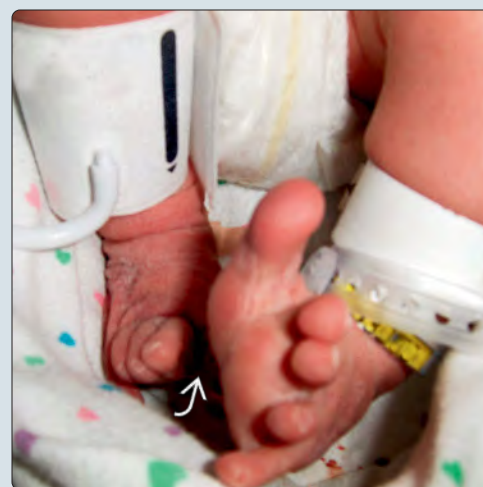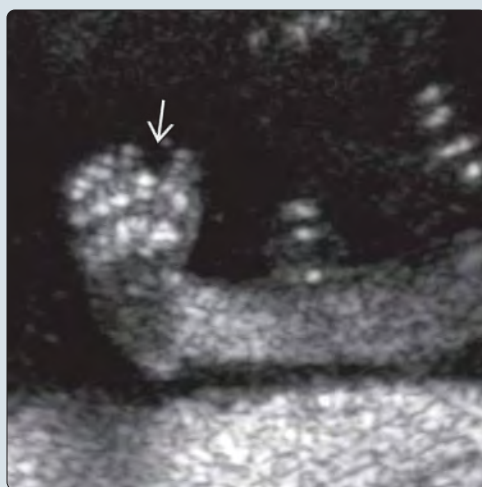DIAGNOSTIC CHECKLIST

- Examine for extended period of time to rule out positional finding

(Left) In this fetus with trisomy 21, proven by amniocentesis, the big toe is abducted from the 2nd toe, leaving a persistent sandal gap. The fetus also had a small nasal bone and most importantly, congenital heart defect (atrioventricular septal defect). **(Right)** This 3D surface rendered view of the foot in a 28-week fetus with trisomy 18 shows a short, medially deviated big toe causing a sandal gap between the big toe and the 2nd toe. The fetus also had a cardiac defect and severe growth restriction.



(Left) Ultrasound shows a sandal gap deformity in a fetus with bilateral clubfeet and normal chromosomes. The foot plantar surface is seen in the same plane as the coronal view of the lower leg, which is diagnostic for clubfoot. **(Right)** Photograph of a neonate with bilateral clubfoot and sandal gap deformity shows all the left toes are splayed with significantly increased distance between the 1st and 2nd toes. The right foot also had a sandal gap but the other toes were not affected. The baby also had a cardiac defect and cleft palate.



TERMINOLOGY**Abbreviations**

- Sandal gap foot (SGF)

Definitions

- Gap between 1st and 2nd toes

IMAGING**General Features**

- Best diagnostic clue
 - Increased space between 1st and 2nd toes
- Location
 - Unilateral or bilateral
- Morphology
 - Big toe angled medially
 - Big toe may be short

Ultrasonographic Findings

- 2D or 3D plantar foot view best for diagnosis
 - Not routinely seen on standard lower extremity views
- Big toe abducted and other toes normal
- Most often seen in normal fetus (often familial)
- SGF and trisomy 21 (T21)
 - 45% of fetuses with T21 have SGF
 - Look for other markers for T21
 - Increased nuchal fold thickness
 - Absent nasal bone
 - Echogenic intracardiac focus
 - Echogenic bowel
 - Mild renal urinary tract dilation
 - Clinodactyly
- SGF and trisomy 18 (T18)
 - Not isolated finding
 - SGF more severe in fetuses with T18
 - Short 1st metatarsal + SGF
 - Look for anomalies and T18 markers
 - Congenital heart defect
 - Choroid plexus cyst
 - Single umbilical artery
 - Clenched hands with overlapping fingers
- SGF + other foot anomaly
 - Clubfoot
 - Coronal view of lower leg and plantar view of foot on same image
 - Rocker-bottom foot
 - Toes splayed and upwardly displaced
 - Additional abnormal gaps
- SGF and amniocentesis
 - Not indicated if isolated finding in low-risk patient
 - Consider amniocentesis only if ↑ risk for T21 or T18
 - Other anomalies or markers present
 - Abnormal maternal serum testing results

Imaging Recommendations

- Protocol advice
 - Rule out transient positional finding (do not overcall)
 - Look carefully for other markers and anomalies
 - Compare finding with patient a priori risk for aneuploidy

DIFFERENTIAL DIAGNOSIS**Syndactyly**

- Fusion of adjacent digits
 - Soft tissue or bony fusion
 - Isolated or part of syndrome
- Associated with several syndromes
 - Apert syndrome
 - Broad 1st toe, mitten hand
 - Carpenter syndrome

Ectrodactyly

- Split hand/foot deformity
 - Lobster claw deformity
- Deficiency of middle phalanx
 - Missing fingers/toes

Amniotic Bands

- Rupture of amnion with entrapment of fetal parts
- Toe gaps from amputation
 - Best to count toes
- Bizarre body wall/facial defects

PATHOLOGY**General Features**

- Genetics
 - Usually normal
 - T21 (rarely isolated)
 - T18 (never isolated)
- Associated abnormalities
 - In conjunction with skeletal dysplasia
 - Pyknodysostosis
 - Werner mesomelia

CLINICAL ISSUES**Presentation**

- Most common signs/symptoms
 - In association with other anomalies or markers

Demographics

- Epidemiology
 - 2-5% of normal fetuses have SGF
 - 45% of fetuses with T21 have SGF

DIAGNOSTIC CHECKLIST**Consider**

- T21 only if other markers are present or patient is at higher risk for T21 based on maternal screening findings

Image Interpretation Pearls

- Examine for extended period of time to rule out positional finding

SELECTED REFERENCES

1. Sanjay SC et al: Case report - pyknodysostosis. J Clin Diagn Res. 9(5):TD09-10, 2015
2. Fang YM et al: Use of the genetic sonogram in the United States in 2001 and 2007. J Ultrasound Med. 27(11):1543-8, 2008
3. Benacerraf BR: The role of the second trimester genetic sonogram in screening for fetal Down syndrome. Semin Perinatol. 29(6):386-94, 2005

Radial Ray Malformation

KEY FACTS

TERMINOLOGY

- Spectrum of anomalies including absence or hypoplasia of radius, radial carpal bones, &/or thumb

IMAGING

- Should be detected on routine anatomic survey at 18-20 weeks
 - Single forearm bone
 - Radial deviation of hand
 - Absent or abnormal thumb
- Abnormal hand/wrist posture may be seen in 1st trimester
- Other findings
 - Congenital heart disease
 - Thrombocytopenia

TOP DIFFERENTIAL DIAGNOSES

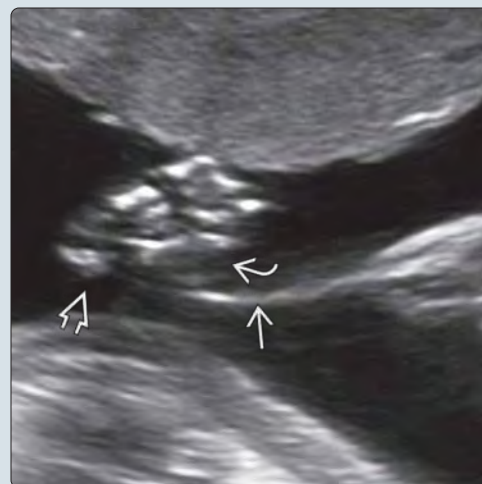
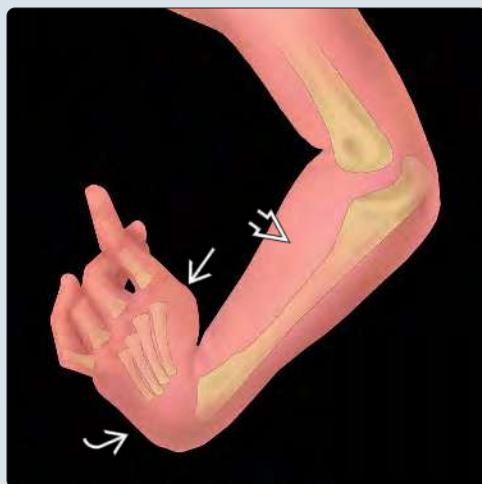- Multiple different etiologies
- Isolated: May be uni- or bilateral with variable thumb defects

- VACTERL association
- Chromosomal: Trisomy 18, 13q deletion
- Holt-Oram syndrome: Cardiac septal defects with upper extremity abnormalities
- Diabetic embryopathy: Range of limb defects including femoral hypoplasia, radial ray, preaxial polydactyly
- Thrombocytopenia-absent radius syndrome (TAR): Thumbs are present
- Fanconi anemia
- Teratogens: Valproic acid
- Nager acrofacial dysostosis: Facial anomalies, radial ray defects

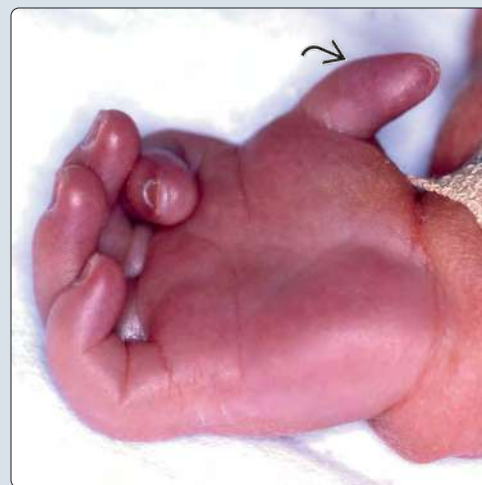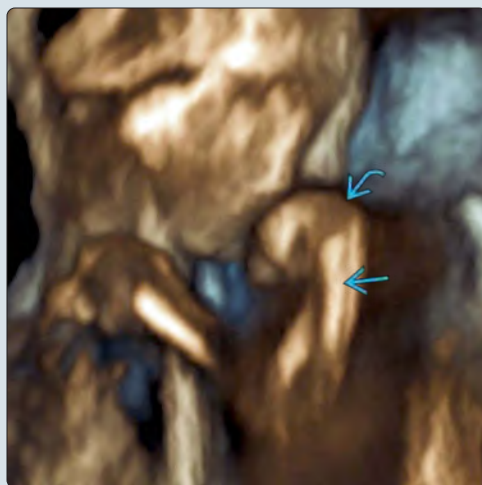
CLINICAL ISSUES

- Prognosis depends on underlying cause
- Limb defects (including radial ray) noted in approximately 1/3 of spontaneous 2nd-/3rd-trimester abortuses with anomalies
- Recurrence risk dependent upon underlying condition

(Left) Graphic illustrates the characteristic features of a radial ray malformation. The thumb may be absent, malpositioned, hypoplastic, or triphalangeal ("digitalization"). Hand position is often abnormal and the radius is absent or hypoplastic. **(Right)** Ultrasound of a fetus at 20 weeks with an isolated radial ray malformation. The ulna is present, but there is no radius. There is radial deviation at the wrist ("radial club hand"). There were 4 fingers but no thumb.



(Left) 3D ultrasound of a fetus with trisomy 18 and a radial ray defect shows a single forearm bone (the ulna) with acute radial deviation of the hand at the wrist. **(Right)** Clinical photograph of a neonate with multiple anomalies including diaphragmatic hernia and VSD shows a malpositioned, hypoplastic thumb as part of an associated radial ray malformation. Radial ray defects are commonly associated with chromosomal anomalies and syndromes so it is imperative to look for other anomalies.



TERMINOLOGY

Synonyms

- Radial ray hypoplasia/aplasia

Definitions

- Spectrum of anomalies including absence or hypoplasia of any of following
 - Radius
 - Radial carpal bones
 - Thumb

IMAGING

General Features

- Best diagnostic clue
 - Single forearm bone
 - Radial deviation of hand

Ultrasonographic Findings

- Grayscale ultrasound
 - Radius is absent or hypoplastic
 - Hand position abnormal
 - Radial deviation ("radial club hand")
 - Fixed on prolonged scanning
 - Can be detected as early as 1st trimester
 - Thumb appearance variable
 - Absent or hypoplastic
 - Proximal implantation
 - Triphalangeal ("digitalization")
 - If adducted, may be difficult to see on ultrasound
 - Other anomalies/syndromes common
 - Multiple anomalies increase likelihood of aneuploidy or VACTERL association
- 3D
 - Useful to show hand position, count digits
 - Evaluation of thumb
 - May show facial detail allowing specific syndromal diagnosis
 - Helpful in counseling families

Imaging Recommendations

- Best imaging tool
 - Targeted endovaginal ultrasound in 1st trimester if positive family history
- Measure all long bones
 - Nomograms exist for lengths
 - Radial ray malformation may be associated with other bone anomalies
- Fetal echocardiogram recommended in all cases
- Careful search for other structural anomalies
 - 86% of patients with hypoplastic thumbs have other anomalies
 - 44% either Holt-Oram or VACTERL association
- Distinguish from arthrogryposis, which also has abnormal hand position
 - Lack of fetal movement causes extremity contractures
 - Radial or ulnar deviation of hands
 - Both forearm bones and all digits present
- Monitor growth
 - Fetal growth restriction (FGR)

- Chromosome abnormality, especially trisomy 18
- Cornelia de Lange syndrome (CDLS)
- Fanconi anemia

DIFFERENTIAL DIAGNOSIS

Isolated

- May be uni- or bilateral with variable thumb defects

VATER/VACTERL Association

- Characteristic anomalies include vertebral, anorectal, tracheoesophageal fistula ± esophageal atresia, renal, cardiac, limb (radial ray)

Chromosomal

- Trisomy 18
 - Usually multiple anomalies
 - Growth restriction often severe
 - Radial ray malformations often bilateral, asymmetrical
- 13q deletion
 - Hypoplastic thumbs, syndactyly, CNS malformation

Holt-Oram Syndrome

- Cardiac defects
 - Atrial septal defect 34%, ventricular septal defects 23%
- Upper extremity anomalies, often severe, asymmetric; radial ray, phocomelia

Diabetic Embryopathy

- Highest incidence in women with poorly controlled diabetes
- Range of limb defects including femoral hypoplasia, radial ray, preaxial polydactyly
- Multiple anomalies including neural tube defect, cardiac, brain

Thrombocytopenia-Absent Radius (TAR) Syndrome

- Bilateral absence of radii with presence of both thumbs
- Thumbs may have functional abnormality
- Thrombocytopenia, congenital or within 1st few months of life
- Other skeletal anomalies: Lower limbs, ribs, vertebrae
- Other anomalies: Cardiac, genitourinary (GU)
- Associated with interstitial microdeletion in 1q21.1

Fanconi Anemia

- Radial ray defect in 49%, including thumb abnormalities (hypoplasia, aplasia, supernumerary)
- Fetal growth restriction
- 75% with other anomalies of GU, eye, CNS, gastrointestinal, cardiac, skin hyperpigmentation
- Median age of hematologic abnormalities onset: 7 years (range: Birth to 31 years)
- Increased risk of malignancy, especially acute leukemias

Teratogens

- Fetal valproate syndrome
 - Limb anomalies in 45-65%, including radial ray
 - Neural tube defects in 1-2%
 - FGR
 - Cognitive delays

Other Syndromes With Radial Ray Defects

- **Nager acrofacial dysostosis:** Micrognathia, zygomatic hypoplasia, ear malformations, radial ray defects
- **CDLS:** Limb reduction defects, facial dysmorphism, FGR, diaphragmatic hernia; 50-60% due to mutation in *NIPBL* gene
- **Diamond-Blackfan anemia (Aase-Smith syndrome II):** Radial hypoplasia, triphalangeal thumb, red cell aplasia, other congenital malformations and growth failure
- **Duane-radial ray syndrome:** Autosomal dominant characterized by radial ray abnormalities, ocular and (sometimes) renal anomalies; mutations in *SALL4* gene

PATHOLOGY**General Features**

- Etiology
 - Embryology
 - Damage to apical ectoderm of limb bud at 6-12 weeks
 - Normal hand is fully formed by 14 weeks
 - Maternal diabetes
 - Highest risk in women with poor control
 - Teratogens
 - Valproic acid thought to cause defective chondrogenesis
- Genetics
 - Autosomal dominant
 - Holt-Oram mutations in *TBX5*
 - Nager syndrome mutations in *SF3B4* gene on 1q21
 - Autosomal recessive
 - Fanconi pancytopenia: Mutations in fanconi anemia complementation group genes
 - TAR syndrome: Microdeletion of 200 kb region at 1q21.1 (distinct from region involved in 1q21.1 deletion/duplication syndrome)
 - Aneuploidy
 - Trisomy 18, 13
 - Diploid/triploid mixoploidy
 - Rare X-linked recessive forms

CLINICAL ISSUES**Presentation**

- Most common signs/symptoms
 - Should be detected on routine anatomic survey at 18-20 weeks
 - Single forearm bone
 - Abnormal hand position
 - Absent or abnormal thumb
 - Abnormal hand/wrist posture may be seen in 1st trimester
- Other signs/symptoms
 - Congenital heart disease
 - Thrombocytopenia

Demographics

- Epidemiology
 - 1:30,000-80,000 live births
 - Bilateral in 50%, but may be asymmetrical
 - Fetal incidence higher due to trisomies/lethal syndromes with higher loss rate

- Limb defects (including radial ray) noted in approximately 1/3 of spontaneous 2nd-/3rd-trimester abortuses with anomalies

Natural History & Prognosis

- Depends on underlying cause, associated anomalies
 - Thrombocytopenia-absent radius (TAR) syndrome
 - Risk of bleeding
 - 40% of liveborns die in early infancy
 - Fanconi anemia
 - Progressive bone marrow failure in childhood, malignancy risk
 - Trisomy 18: Limited lifespan
- Recurrence risk dependent upon underlying condition
 - Trisomy 18 overall recurrence risk approximately 1% until age 35, then maternal age-specific risk
 - Autosomal recessive conditions: 25%
 - Autosomal dominant
 - If parent affected, 50%
 - If new mutation, low recurrence risk
 - Recurrence due to gonadal mosaicism vs. undiagnosed condition in parent

Treatment

- Genetic counseling
- Cytogenetic analysis/comparative genomic hybridization microarray
 - Aneuploidy
 - Fanconi anemia: Increased chromosome breakage after exposure to DNA cross-linking agent, such as diepoxybutane or mitomycin C
 - Microdeletions in TAR
- Exclude maternal diabetes
- Examine parents for subtle defects
 - Severity of extremity malformations highly variable
- Consider cordocentesis if family history of TAR
 - Thrombocytopenia
 - Microdeletion detection
- Detailed clinical evaluation of infant and family members
- Referral to specialist centers for reconstructive surgery
 - Hypoplastic thumb: Pollicization of index finger or toe transplantation to increase hand functionality

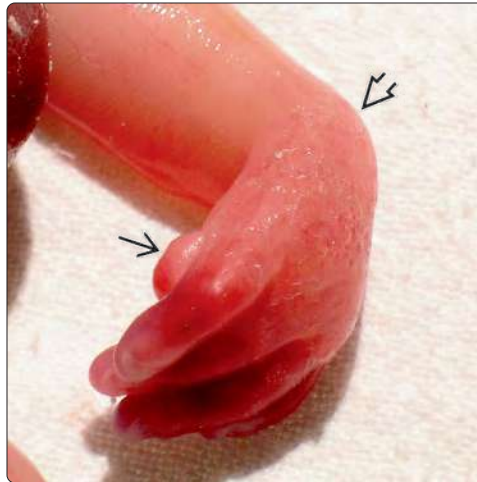
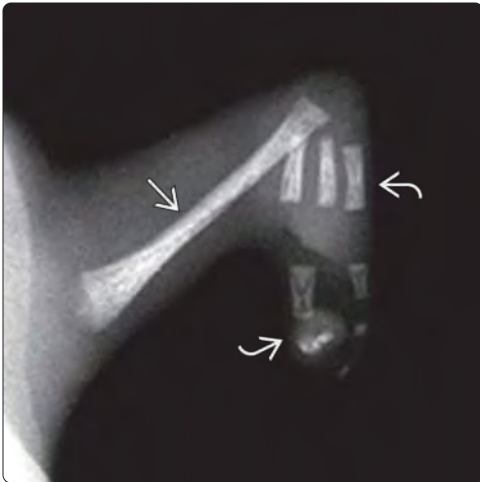DIAGNOSTIC CHECKLIST**Image Interpretation Pearls**

- Syndrome identification important in radial ray malformation
 - Prognosis and specific clinical complications vary for each condition
- Thumb morphology may lead to specific diagnosis

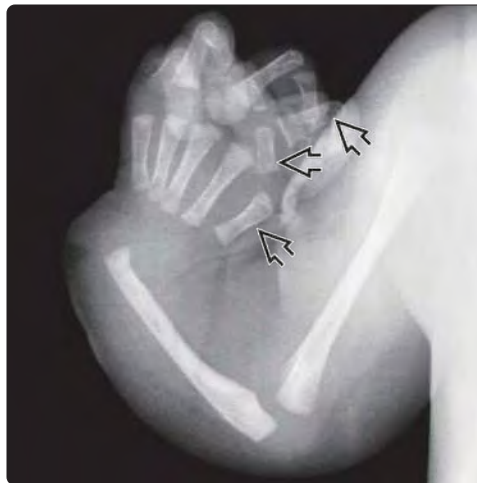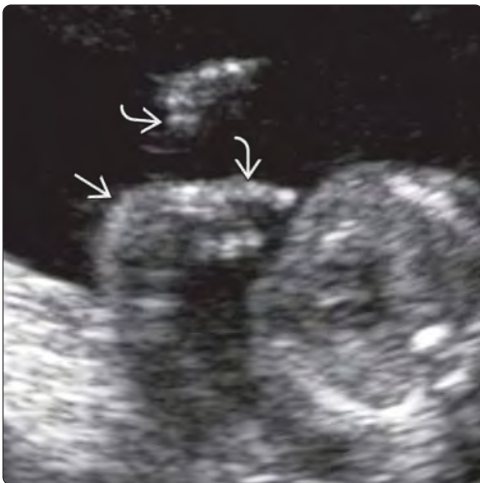SELECTED REFERENCES

1. Al-Qattan MM: The ubiquitin/SUMO pathway and radial ray deficiency syndromes. *Ann Plast Surg.* 70(2):240-5, 2013
2. Bottillo I et al: Prenatal diagnosis and post-mortem examination in a fetus with thrombocytopenia-absent radius (TAR) syndrome due to compound heterozygosity for a 1q21.1 microdeletion and a RBM8A hypomorphic allele: a case report. *BMC Res Notes.* 6:376, 2013
3. Pakkasjärvi N et al: Characteristics and associated anomalies in radial ray deficiencies in Finland—a population-based study. *Am J Med Genet A.* 161A(2):261-7, 2013
4. Stoll C et al: Associated malformations among infants with radial ray deficiency. *Genet Couns.* 24(2):223-34, 2013

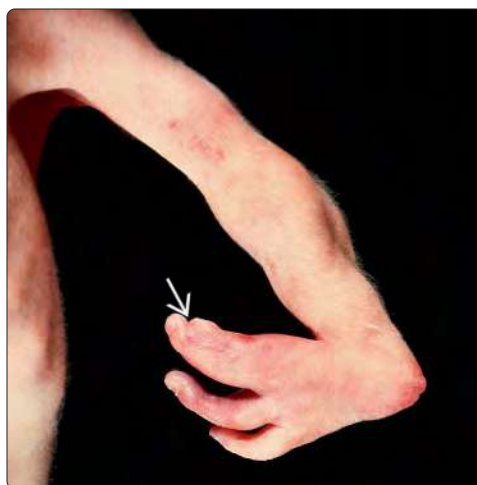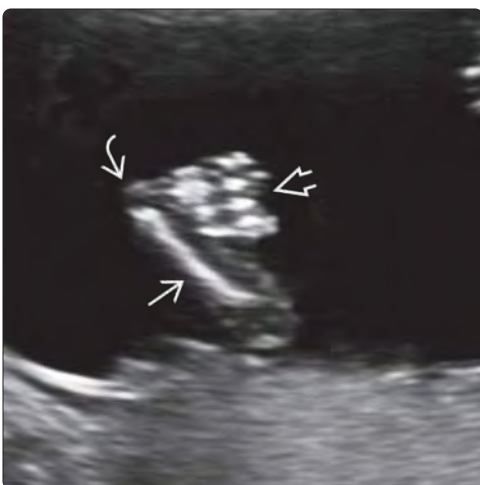
Radial Ray Malformation



(Left) Radiograph of a stillborn with severe diabetic embryopathy shows aplasia of the radius and ulna. The humerus is the only long bone in the arm. Oligodactyly is also seen. This is an extreme form of radial ray malformation with the entire forearm absent. **(Right)** Clinical photograph of a different stillborn from a poorly controlled diabetic exhibits a more typical radial ray malformation. An abnormally deviated wrist and hypoplastic thumb are noted.



(Left) Ultrasound shows a radial ray malformation in a midtrimester fetus with thrombocytopenia-absent radius syndrome (TAR). Radial deviation of the wrist is noted, but the thumbs are present, an important finding in the diagnosis of TAR. **(Right)** Radiograph shows the arm of an infant with TAR. The radius is absent, but all the bones of the thumb are present. Presence of a thumb is a distinguishing feature of this entity.



(Left) Ultrasound at 14 weeks shows a single forearm bone and a sharply angled, medially deviated hand with 4 digits and absent thumb. Radial ray malformation may be suspected in the 1st trimester when a single forearm bone and abnormal hand posture are seen. **(Right)** Autopsy photograph shows the typical appearance of a radial ray malformation in a case of trisomy 18. Note the typical hand position and absent thumb. Syndactyly of the 2nd and 3rd digits is also noted.

KEY FACTS

TERMINOLOGY

- Radial deviation of distal 5th finger

IMAGING

- Seen best on coronal hand view in 2nd trimester
 - 5th finger curves toward 4th
 - Commonly bilateral
 - Captured well with 3D
- 2-4% of normal fetuses have clinodactyly
- Clinodactyly is minor marker for trisomy 21 (T21)
 - 60% of T21 fetuses have clinodactyly
 - Look for other T21 markers

TOP DIFFERENTIAL DIAGNOSES

- Syndactyly: Fusion of digits
 - Associated with syndromes
- Polydactyly: Extra digits
 - Associated with syndromes

PATHOLOGY





- Etiology
 - Trapezoidal/delta-shaped middle phalanx
 - Secondary to epiphyseal rectangular bar
- Familial clinodactyly
 - Autosomal dominant
 - Variable expression
- Other syndromic associations besides T21

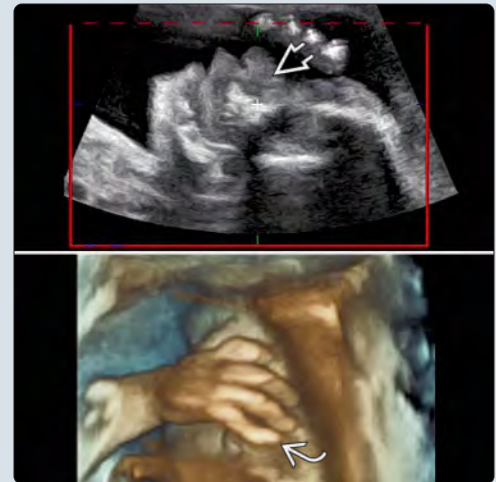
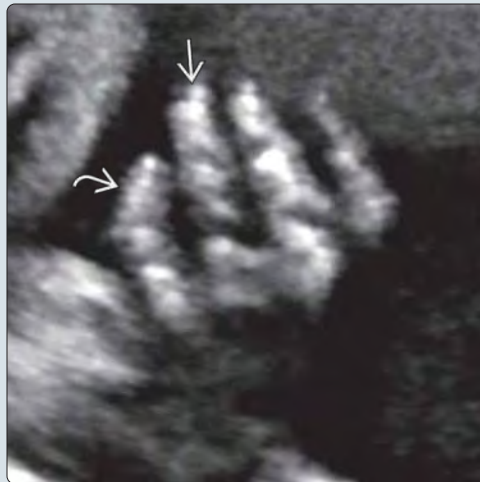
CLINICAL ISSUES




- Excellent prognosis when isolated
- Functional limitations common if > 30-40°
 - May need surgical treatment

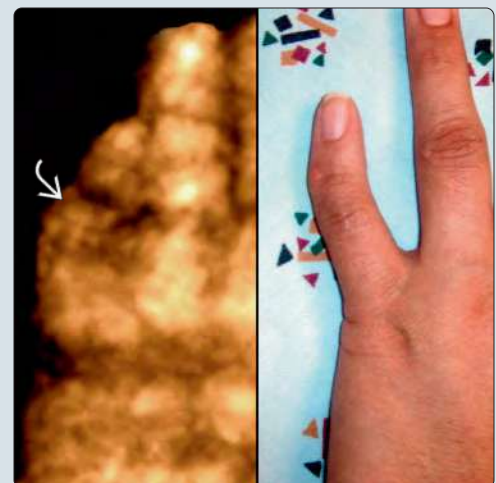
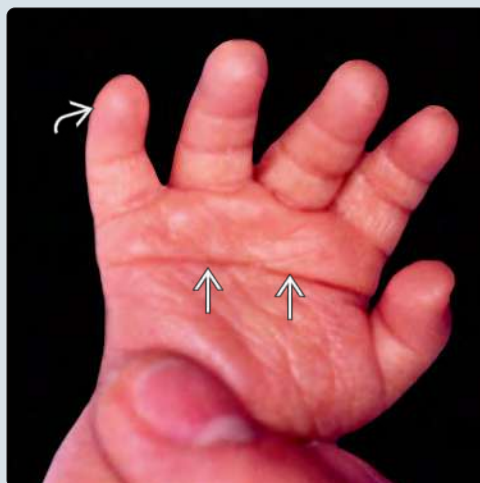DIAGNOSTIC CHECKLIST

- Consider genetic counseling if not isolated
- Ask family if anyone else has clinodactyly when isolated

(Left) Fifth-finger clinodactyly is seen in this fetus with trisomy 21 (T21). The little finger  curves toward the ring finger . This fetus also had a cardiac defect (AV canal) and other markers for T21. **(Right)** In this fetus with T21 and clinodactyly , there was also an absent nasal bone . Genetic testing should be considered when multiple markers for T21 are seen. Also, this case demonstrates the ease with which clinodactyly can be seen with 3D ultrasound.



(Left) Clinical photograph shows a newborn with trisomy 21. The fingers are short, with 5th finger clinodactyly  and a simian crease . **(Right)** 3D ultrasound shows a short middle phalanx  with inward curvature of the 5th finger. When the finding was discussed with the patient, she and her sister held up their hands to show the sonologist that they both had bilateral clinodactyly. The mother's 5th finger is shown. This is a case of hereditary clinodactyly, most often an autosomal dominant trait.



TERMINOLOGY

Definitions

- Deviation of digit in coronal plane
 - 5th finger middle phalanx (MP) most often affected
 - Little finger deviates toward ring finger

IMAGING

Ultrasonographic Findings

- Tip of 5th finger curves toward 4th finger
 - Seen best on coronal hand view in 2nd trimester
 - Captured well with 3D
 - Commonly bilateral
- 2-4% of normal fetuses have clinodactyly
- Clinodactyly is minor marker for trisomy 21 (T21)
 - 60% of T21 have clinodactyly
 - Look for other T21 markers
 - ↑ nuchal fold
 - Absent nasal bone
 - Echogenic intracardiac focus
 - Echogenic bowel
 - Renal pelvis distention
 - Short humerus/femur
 - Sandal gap foot
 - Short MP better marker than curved finger
 - Considered short if 5th MP < 70% of 4th MP
- Trisomy 21 hand morphology
 - T21 fetuses more likely to keep hand open
 - Poor tone
 - All 5 digits are short
 - Clinodactyly + short digits more worrisome
 - Can use nomograms for 17-26 weeks
 - Look for simian crease
 - Single transverse palmar crease
 - 45% of T21 vs. 4% of normal

Imaging Recommendations

- Best imaging tool
 - Coronal view of open hand
 - With 2D or 3D
- Protocol advice
 - Document open hands as part of routine anatomy exam

DIFFERENTIAL DIAGNOSIS

Syndactyly

- Fusion of digits
 - Bony or soft tissue fusion
 - May be isolated or + other anomalies
- Associated syndromes and aneuploidy
 - Triploidy (3rd and 4th digits most common)
 - Apert syndrome
 - Polysyndactyly (mitten hands)
 - Craniosynostosis and other anomalies

Polydactyly

- Extra digits
 - Postaxial (extra digit on ulnar side)
 - Preaxial (extra digit on radial side)
- Common syndromes and aneuploidy

- Trisomy 13
- Meckel-Gruber syndrome

PATHOLOGY

General Features

- Etiology
 - MP is trapezoidal or delta-shaped instead of rectangular
 - Secondary to epiphyseal rectangular bar
- Genetics
 - Familial clinodactyly
 - Autosomal dominant
 - Variable expression
 - Incomplete penetrance
 - Associations
 - T21
 - Rubinstein-Taybi syndrome
 - Apert syndrome
 - Oculodental digital dysplasia

Staging, Grading, & Classification

- Surgery considered if > 20° angulation
- Functional limitations common if > 30-40°

CLINICAL ISSUES

Presentation

- Most common signs/symptoms
 - Incidental finding during anatomy scan
 - In conjunction with other anomalies/markers

Natural History & Prognosis

- Excellent prognosis when isolated
 - Severe cases with functional difficulties
 - Difficulty with keyboard is most common complaint

Treatment

- Surgery for severe cases
 - Wedge osteotomy
 - Epiphyseal bar resection
 - Remove longitudinal physis

DIAGNOSTIC CHECKLIST

Consider

- Careful search for other markers of T21
 - Assess maternal risk for T21
 - Consider genetic counseling if other markers seen
- Ask family if anyone else has clinodactyly
 - Remember variable penetrance so might be mild

SELECTED REFERENCES

1. Goldfarb CA et al: Osteotomy for clinodactyly. *J Hand Surg Am.* 40(6):1220-4, 2015
2. Goldfarb CA: Congenital hand differences. *J Hand Surg Am.* 34(7):1351-6, 2009
3. Smith-Bindman R et al: Second trimester prenatal ultrasound for the detection of pregnancies at increased risk of Down syndrome. *Prenat Diagn.* 27(6):535-44, 2007
4. Rypens F et al: Obstetric US: watch the fetal hands. *Radiographics.* 26(3):811-29; discussion 830-1, 2006
5. Maymon R et al: All five digits of the hands of fetuses with Down syndrome are short. *Ultrasound Obstet Gynecol.* 23(6):557-60, 2004

KEY FACTS

TERMINOLOGY

- 1 or more extra digits or parts of digits
 - Postaxial: Ulnar or fibular side
 - Preaxial: Radial or tibial side

IMAGING

- Easy to both under and over diagnose
- Careful scanning for other abnormalities and syndromes
- Bilateral in ~ 50%
- Syndactyly may also be present
- 3D ultrasound valuable tool for evaluation of hands, feet, and digits
- Endovaginal ultrasound in late 1st trimester

TOP DIFFERENTIAL DIAGNOSES

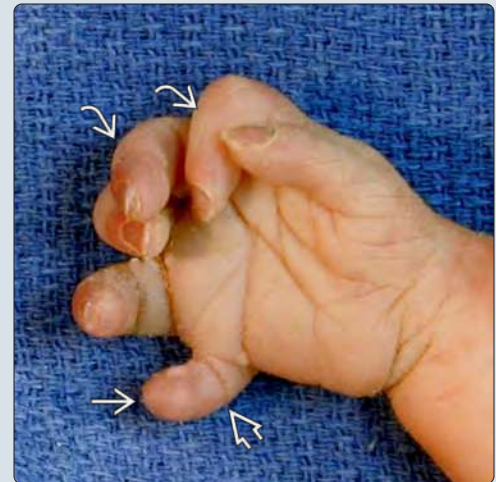
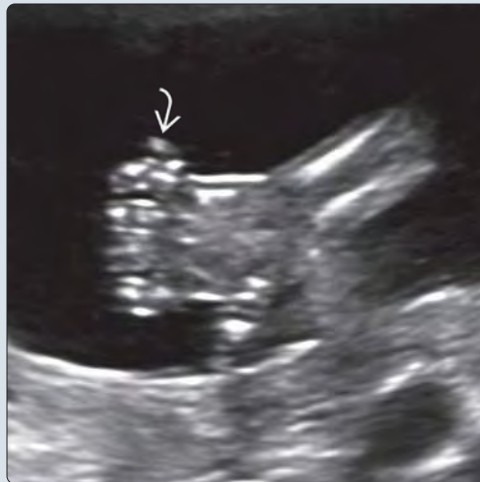
- Nonsyndromal polydactyly
 - Isolated
 - Familial
- Syndromal polydactyly

- Trisomy 13
- Meckel-Gruber syndrome
- Diabetic embryopathy
- Smith-Lemli-Opitz/RSH syndrome
- Carpenter syndrome
- Short rib-polydactyly syndromes
- Ellis-van Creveld syndrome
- Pallister-Hall syndrome
- Greig cephalopolysyndactyly

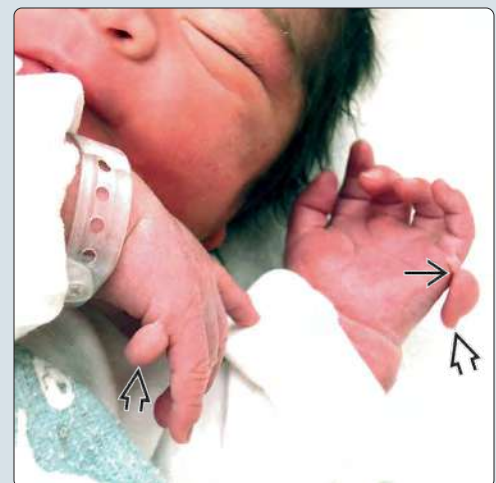
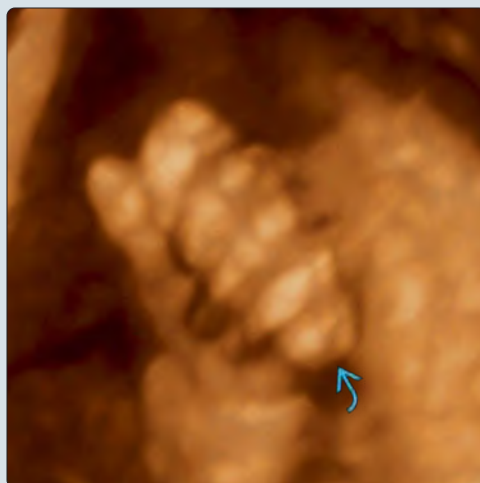
PATHOLOGY

- Maternal diabetes risk factor for preaxial polydactyly
- Inheritance variable according to condition
 - Some associated syndromes are autosomal recessive, autosomal dominant
 - Isolated polydactyly generally autosomal dominant with variable penetrance
- Preaxial polydactyly and triphalangeal thumb more likely to be part of syndrome

(Left) Ultrasound of the hand of a fetus with trisomy 13 at 22-weeks gestation. Postaxial polydactyly is noted with a small extra digit. An obvious bone is not seen. Postaxial polydactyly is one of the most common features in trisomy 13, in addition to severe brain, eye, cardiac, and genitourinary abnormalities. **(Right)** A 6th, fully formed digit is seen in this hand of a stillborn with Smith-Lemli-Opitz (SLOS). Clinodactyly and camptodactyly are also seen. Polydactyly and syndactyly are common findings in SLOS.



(Left) 3D ultrasound of the hand of a midtrimester fetus shows postaxial polydactyly. Isolated polydactyly is usually autosomal dominant with variable penetrance. (From *DI: Pediatrics, 3e.*) **(Right)** Clinical photograph in a different patient shows bilateral postaxial polydactyly of the hands. Note the narrow attachment. Postaxial polydactyly of the feet and bilateral clubfeet were also seen in this infant with Bardet-Biedl syndrome.



TERMINOLOGY

Definitions

- 1 or more extra digits or parts of digits
- Most common varieties are postaxial (ulnar, fibular side) and preaxial (radial, tibial side)
 - **Postaxial** (also called posterior) polydactyly
 - Type A: Extra digit well formed, articulates with 5th or extra metacarpal
 - Type B: Pedunculated postminimi, extra digit not well formed, skin tag
 - Synpolydactyly: Postaxial polydactyly with syndactyly
 - **Preaxial** (also called anterior) polydactyly
 - Type I: Thumb polydactyly
 - Type II: Polydactyly of triphalangeal thumb
 - Type III: Polydactyly of index finger
 - Type IV: Polysyndactyly (preaxial polydactyly with syndactyly)
- Crossed polydactyly: Coexistence of preaxial and postaxial polydactyly with discrepancy between axes of polydactyly between hands and feet
- Rare polydactyls, higher-order polydactyls

IMAGING

General Features

- Morphology
 - Variable
 - Formed digit ± nail, but without bone(s)
 - Bifid digit
 - Broad digit
 - Soft tissue nubbin (digiti postminimi)
 - Triphalangeal thumb
 - Bilateral in ~ 50%
 - Hand more often bilateral than foot

Ultrasonographic Findings

- Need to confirm in both axial and coronal views
 - Oblique views may give erroneous appearance of polydactyly
- Extra digit may be small or angulated
- May be fleshy nubbin without bone
 - Difficult to see in utero
 - Often missed on prenatal ultrasound
- Postaxial
 - Extra digit in same plane as normal digits
- Preaxial
 - Extra digit often proximally located
- Syndactyly may also be present

Imaging Recommendations

- Best imaging tool
 - 3D ultrasound valuable tool for evaluation of hands, feet, and digits
 - Endovaginal ultrasound in late 1st trimester
- Count and recount
 - Easy to both under and over diagnose
 - Make sure hands (or feet) are not together
 - Erroneous appearance of polydactyly
 - Confirm in both axial and coronal planes
- Careful scanning for other abnormalities

- Cardiac echo if other abnormalities identified

DIFFERENTIAL DIAGNOSIS

Nonsyndromal Polydactyly

- **Isolated**
 - Most often postaxial
- **Familial**
 - Higher incidence in African Americans

More Common Syndromal Polydactyly

- **Trisomy 13**
 - Usually multiple anomalies involving cardiac, central nervous system, renal, gastrointestinal
 - 75% with postaxial polydactyly
 - Critical region 13q31 → q34
- **Meckel-Gruber (Meckel) syndrome**
 - Classic triad of posterior encephalocele, cystic renal dysplasia, postaxial polydactyly
 - May have similar appearance to trisomy 13 in utero; important distinction, given autosomal recessive inheritance in Meckel-Gruber
- **Diabetic embryopathy**
 - Preaxial polydactyly
 - Multiple anomalies including cardiac, renal, skeletal, brain
- **Smith-Lemli-Opitz/RSH syndrome**
 - Inborn error of cholesterol metabolism
 - Severe IUGR
 - Microcephaly, holoprosencephaly
 - Cryptorchidism/abnormal genitalia
 - Cardiac defects
 - Clenched hands, syndactyly, polydactyly
- **Carpenter syndrome**
 - Craniosynostosis of multiple sutures
 - Cardiac defects
 - Preaxial polydactyly
 - Syndactyly
- **Pallister-Hall syndrome**
 - Hamartoma of tuber cinereum
 - Central polydactyly
- **Greig cephalopolysyndactyly (GCPS)**
 - Preaxial polydactyly or mixed pre- and postaxial polydactyly
 - Macrocephaly
 - Mild GCPS spectrum continuous with preaxial polysyndactyly type IV and crossed polydactyly

Rarer Syndromal Polydactyly

- **Short rib-polydactyly syndromes, including Jeune**
 - Narrow chest with short, parallel ribs
 - Micromelia
 - Postaxial polydactyly
 - Renal dysplasia
 - Cardiac defects
 - Genitourinary anomalies
- **Ellis-van Creveld syndrome (chondroectodermal dysplasia)**
 - Small chest
 - Polydactyly
 - Cardiac defects
 - Increased incidence in Amish population

- **Majewski syndrome**
 - Type of lethal short rib-polydactyly syndrome
 - Preaxial and postaxial polydactyly (7 toes)
 - Cleft lip/palate
- **Mohr syndrome (oral-facial-digital syndrome II)**
 - Multiple facial anomalies: Median clefts, malformed nose, tongue malformations
 - Postaxial polydactyly of hands with polysyndactyly of feet ± postaxial polydactyly of ft (7 toes)
- **Bardet-Biedel syndrome**
 - Obesity, short stature
 - Postaxial polydactyly
 - Rod-cone dystrophy
 - Complex renal, GU anomalies
- **Pseudotrisomy 13**
 - Holoprosencephaly
 - Postaxial polydactyly
 - Normal chromosomes

PATHOLOGY

General Features

- Etiology
 - Embryology
 - Upper limb buds appear day 24
 - Lower limb buds appear day 26
 - Hands and feet begin as paddle-shaped plates
 - Digital rays develop in 5 sectors along anterior/posterior axis
 - Separate fingers and toes in 8th week
 - Maternal diabetes risk factor for preaxial polydactyly
 - Teratogens: Azathioprine, valproic acid
- Genetics
 - Variable according to condition
 - **Autosomal recessive**
 - Meckel-Gruber, short rib polydactyly, Smith-Lemli-Opitz, Joubert, Majewski, Mohr, Bardet-Biedl
 - **Autosomal dominant**
 - Pallister-Hall syndrome, Greig cephalopolysyndactyly
 - Isolated polydactyly is generally autosomal dominant with variable penetrance
 - **Known gene mutations**
 - *GLI3*: Greig cephalopolysyndactyly, some cases of postaxial polydactyly, Pallister-Hall
 - Deficiency of 7-dehydrocholesterol reductase: Smith-Lemli-Opitz
 - **Chromosomal**
 - Trisomy 13
 - Deletion of 7p13: Greig cephalopolysyndactyly
- Associated abnormalities
 - Preaxial polydactyly and triphalangeal thumb more likely to be part of syndrome
 - Preaxial polydactyly
 - Carpenter syndrome
 - Infant of diabetic mother
 - Majewski syndrome
 - Small chest + polydactyly
 - Short rib polydactyly syndromes
 - Ellis-van Creveld
 - Majewski syndrome

- Syndactyly often associated
 - Usually adjacent to duplicated digit
 - More common in feet than hands

Gross Pathologic & Surgical Features

- Variable amounts of development
 - Soft tissue only (skin tag)
 - Variable amounts of phalangeal development
 - Duplicated digit may be functional or rudimentary and nonfunctional

CLINICAL ISSUES

Demographics

- Epidemiology
 - **Postaxial**
 - Isolated postaxial polydactyly 10x more common in African Americans
 - 1:3,000 Caucasian
 - 1:300 African American
 - More common in males
 - **Preaxial** (less common)
 - 1:10,000
 - 3-4x more common in Native Americans than in Caucasians or African Americans
 - More common in hand
 - More often unilateral
 - More common in females
 - When found with other anomalies in infant of diabetic mother, confirms diabetic embryopathy

Natural History & Prognosis

- Variable depending upon presence of other anomalies, syndrome
- Isolated with excellent prognosis
- In utero autoamputation reported
 - May be born with only small residual bump

Treatment

- Consider karyotype if other anomalies present
- Thorough family history
- Genetic counseling regarding syndromes
- Resection of extra digit varies in complexity
 - Without bone, may be done in nursery
 - With bone, often wait until 1-2 yr old
 - May require joint reconstruction or tendon transfer

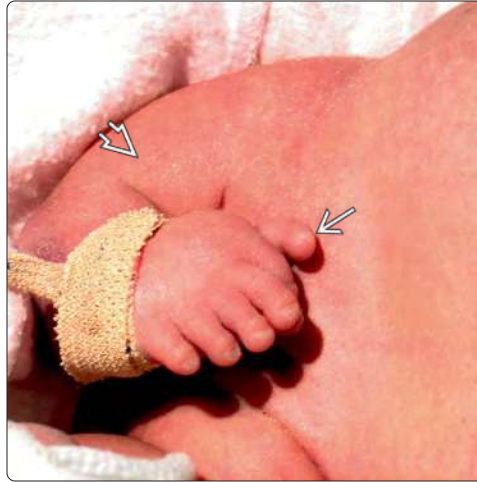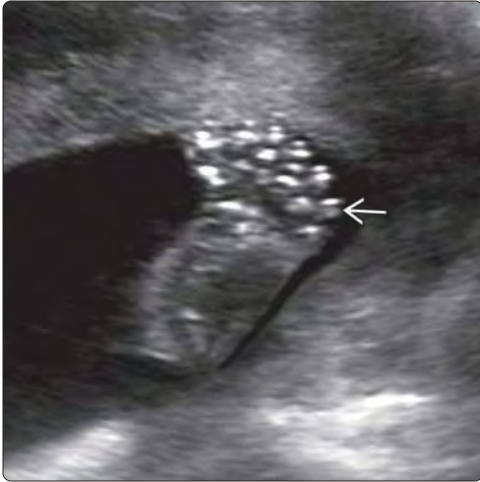
DIAGNOSTIC CHECKLIST

Consider

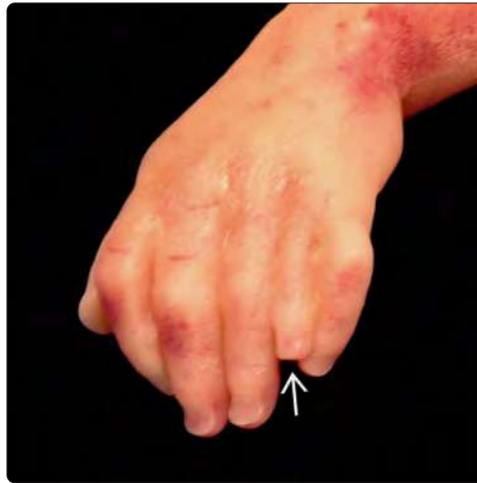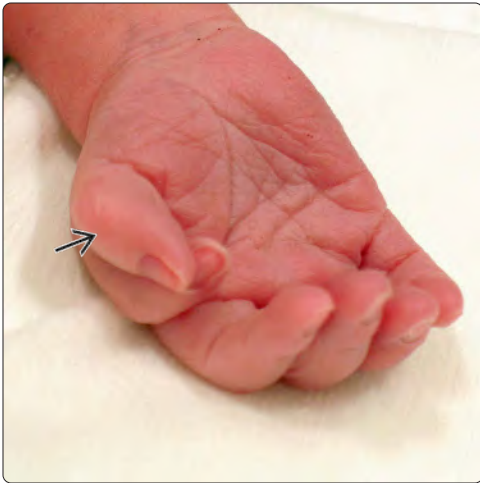- 3D ultrasound to aid in diagnosis

SELECTED REFERENCES

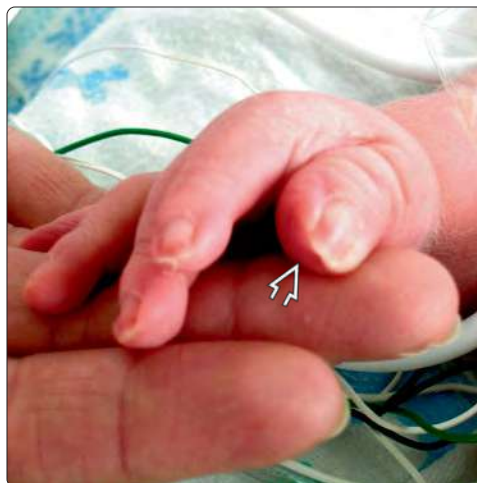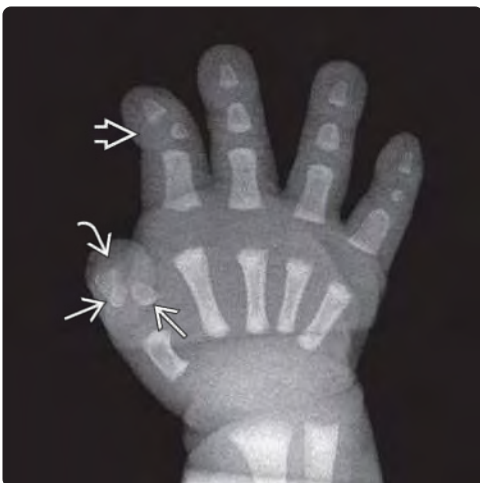1. Costa Gde A et al: Investigation of possible teratogenic effects in the offspring of mice exposed to methylphenidate during pregnancy. *Reprod Biomed Online*. 32(2):170-7, 2016
2. Delgadillo D 3rd et al: Supernumerary digits of the hand. *Eplasty*. 16:ic3, 2016
3. Gupta P et al: Intranatal torsion of polydactyly: a rare event. *Fetal Pediatr Pathol*. 1-4, 2016
4. Little KJ et al: Congenital anomalies of the hand-principles of management. *Orthop Clin North Am*. 47(1):153-68, 2016
5. Deng H et al: Advances in the molecular genetics of non-syndromic polydactyly. *Expert Rev Mol Med*. 17:e18, 2015



(Left) Ultrasound of the foot of a fetus at 21 weeks with trisomy 13 shows a well-formed 6th digit. Postaxial polydactyly may involve either the upper or lower extremities, or both, and may be unilateral or bilateral in trisomy 13. (Right) Clinical photograph shows preaxial polydactyly of the foot in a newborn infant with severe diabetic embryopathy. Severe malformation of the lower leg and ankle is also evident. Preaxial polydactyly is much less common than postaxial, but in diabetes, it is a marker for diabetic embryopathy.



(Left) Clinical photograph of the hand of a nonsyndromic newborn infant. Isolated preaxial polydactyly involving the thumb of 1 hand is noted. The extra digit is well formed, although abnormal, and function of the normal thumb may be impaired as well. (Right) Clinical photograph shows an unusual case of insertional polydactyly in a stillborn fetus with trisomy 13. Note the well-formed, but smaller digit. The location between the 4th and 5th fingers is uncommon for the inserted digit.



(Left) Radiograph of a term infant with Pfeiffer syndrome shows the unusual configuration of the thumb with duplication of the proximal phalanx and hypoplasia of the distal phalanx. Brachydactyly is also seen. (Right) Clinical photograph of the hand of the same infant with Pfeiffer syndrome shows the resultant broad curved thumb. Although externally the thumb is not obviously duplicated, the radiograph clearly shows evidence of preaxial polydactyly.

KEY FACTS

TERMINOLOGY

- Syndactyly: Greek for digits grown together
- Partial or incomplete syndactyly: Affects only proximal segments of digits
- Complete syndactyly: Affects length of digits to level of nails
- Polysyndactyly/synpolydactyly: Combination of duplicated and fused digits
- Symphalangism: Synostosis of joints of digits
- Zygodactyly: Shallow, membranous webbing of 2nd-3rd toes, most prominent on plantar surface
- Acrosyndactyly: Soft tissue attachment of distal digits with nonattached proximal segments

IMAGING

- Inability to see separate digits on open-hand view of fetus
- Careful search for other limb, structural anomalies
- Examination of hands and feet of parents, siblings

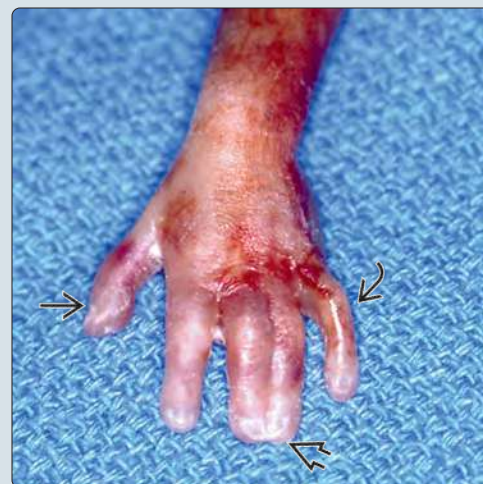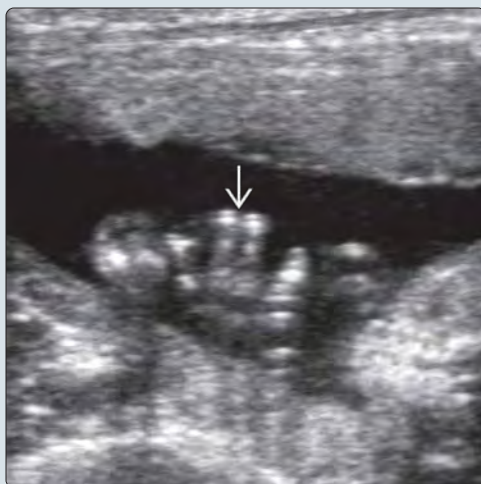TOP DIFFERENTIAL DIAGNOSES

- Nonsyndromal syndactyly
 - Familial 2-3 toe syndactyly (most common); amniotic bands
- Syndromal syndactyly
 - Smith-Lemli-Opitz syndrome; Apert syndrome; triploidy; Carpenter syndrome; Pfeiffer syndrome; diabetic embryopathy

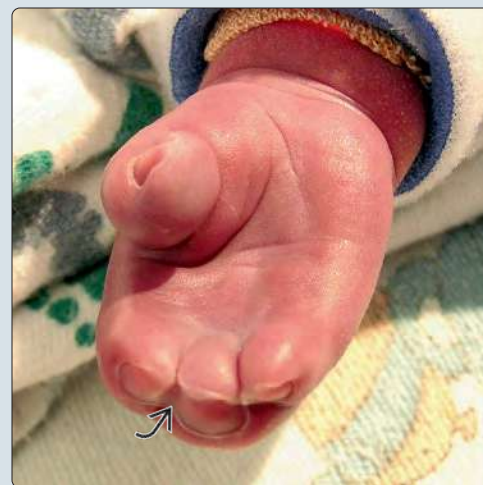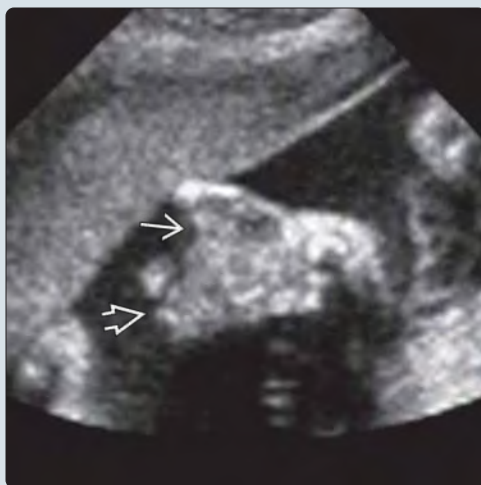PATHOLOGY

- Separation failure of digits prior to 6th week of development
- Programmed cell death essential to remove interdigital tissue, thus allowing separation of digits
- Nonsyndromal syndactyly usually has good prognosis
- Prognosis in syndromal syndactyly dependent upon particular syndrome

(Left) Ultrasound of the hand shows 3-4 syndactyly. This pattern is often seen in triploidy, and a careful search for other anomalies is warranted. **(Right)** Clinical photograph illustrates the characteristic 3-4 syndactyly in a stillborn with triploidy (69,XXY). Clinodactyly of the 5th digit is also seen. Note the disproportionately large thumb. Multiple anomalies and growth restriction are usually seen by the midtrimester. The pregnancy may also be complicated by severe preeclampsia.



(Left) Ultrasound of a midtrimester fetus with Apert syndrome shows complete syndactyly of digits 2-5. The thumb can be seen separate from the fingers, although partial syndactyly is apparent. Other findings of Apert syndrome include an abnormal head shape from craniosynostosis of the coronal ± other sutures. **(Right)** Clinical photograph shows the mitten syndactyly characteristic of Apert syndrome. Note the unusual fusion of the nails which appear larger than normal.



TERMINOLOGY

Definitions

- Syndactyly: Greek for digits grown together
- Partial or incomplete syndactyly: Affects only proximal segments of digits
- Complete syndactyly: Affects length of digits to level of nails
- Polysyndactyly/synpolydactyly: Combination of duplicated and fused digits
- Symphalangism: Synostosis of joints of digits
- Zygodactyly: Shallow, membranous webbing of 2nd-3rd toes, most prominent on plantar surface
- Acrosyndactyly: Soft tissue attachment of distal digits with nonattached proximal segments

IMAGING

General Features

- Best diagnostic clue
 - Inability to see separate digits on open-hand view of fetus
 - Often easiest in 1st trimester
- Multiple types of syndactyly exist, characterized by digits involved
- Phenotypic overlap exists
- **Classification centers on 5 types**
 - Type I Syndactyly: All autosomal dominant (locus 2q34-q36)
 - Subtype 1: Zygodactyly
 - Most common type
 - Partial or complete cutaneous syndactyly of 2nd and 3rd toes
 - No hand involvement
 - Unilateral or bilateral; no bony involvement
 - Subtype 2
 - Bilateral cutaneous &/or bony webbing of 3rd-4th fingers and of 2nd-3rd toes
 - Subtype 3 (rare)
 - Bilateral cutaneous and bony webbing of 3rd-4th fingers
 - Subtype 4 (rare)
 - Bilateral cutaneous webbing of 4th-5th toes
 - Type II: Synpolydactyly
 - Syndactyly of 3rd and 4th fingers with duplication of 3rd or 4th finger in web
 - Type III (locus 6q21-q23.2)
 - Complete, bilateral syndactyly of 4th and 5th fingers
 - Mutations in *GJA1* gene
 - Associated camptodactyly (persistent flexion) of 4th finger to accommodate difference in lengths of fingers
 - This type seen in oculodentodigital dysplasia
 - Type IV: Polysyndactyly, Haas type (locus 7q36)
 - Complete syndactyly of all fingers, often associated with hexadactyly
 - Mutations in sonic hedgehog regulatory element
 - Similar to type of syndactyly seen in Apert syndrome, although no bony fusion as in Apert
 - Type V (locus 2q31-q32)
 - Very rare

- Associated with metacarpal and metatarsal synostosis
- Fusion of 4th and 5th or 3rd and 4th metacarpals/metatarsals; soft tissue syndactyly of 3rd and 4th fingers, 2nd and 3rd toes
- Mutations in *HOXD13* gene

Imaging Recommendations

- Best imaging tool
 - 3D imaging often helpful to further evaluate digits
 - Endovaginal imaging in late 1st trimester, especially with family history
- Protocol advice
 - Careful search for other limb, structural anomalies
 - Presence/absence/abnormal position or width of thumbs
 - Evidence of craniosynostosis
 - Examination of hands and feet of parents, siblings
 - Abnormal crease patterns, subtle syndactyly
 - Consider karyotype if other structural anomalies or growth restriction are present

DIFFERENTIAL DIAGNOSIS

Nonsyndromal Syndactyly

- **Familial 2-3 toe syndactyly**
 - Isolated
 - Autosomal dominant
- **Amniotic bands**
 - Sometimes called pseudosyndactyly as distal digits may be held together by strands of amnion and appear fused on ultrasound
 - Associated unusual clefts and schisis defects of calvarium, face, body wall
 - Amputations of digits, limbs, or parts of limbs
 - Constriction rings, especially around extremities

Syndromal Syndactyly

- **Saethre-Chatzen syndrome (acrocephalosyndactyly type III)**
 - *TWIST1* gene mutations in 46-60% cases
 - Facial asymmetry with ptosis, coronal synostosis
 - Syndactyly of digits 2 and 3 of hands
 - Usually normal intelligence
 - Autosomal dominant
- **Fraser syndrome (cryptophthalmos-syndactyly syndrome)**
 - Cryptophthalmos (93%)/anophthalmia/microphthalmia
 - Syndactyly (54%)
 - Other anomalies: Absent lacrimal ducts, renal agenesis, müllerian anomalies, displacement of umbilicus
 - Genetic heterogeneity with mutations in *FRAS1* or *FREM2* genes
- **Greig cephalopolysyndactyly syndrome (GCPS)**
 - Mutations in *GLI3*
 - Preaxial or mixed pre- and postaxial polydactyly, syndactyly
 - Ocular hypertelorism, macrocephaly
 - Autosomal dominant
- **Oral-facial-digital syndrome, type I (OFD1)**
 - Lobulated tongue with hamartomas
 - Median cleft, hypertelorism

- Brachydactyly, polydactyly, syndactyly
- X-linked dominant
- **Smith-Lemli-Opitz syndrome**
 - Y syndactyly of toes 2-3 common
 - Postaxial polydactyly
 - Severe fetal growth restriction (FGR)
 - Multiple anomalies including CNS, heart, clefts
 - Autosomal recessive, mutations in *7-DHC* reductase
- **Split hand-foot malformation**
 - Subtle syndactyly often seen in otherwise asymptomatic carriers
- **Apert syndrome**
 - Mitten syndactyly of hands and feet; both bony and soft tissue fusion
 - Acrocephaly due to coronal synostosis
- **Triploidy**
 - Characteristic 3-4 syndactyly of fingers
 - Severe FGR
 - Multiple anomalies including central nervous system, cardiac, gastrointestinal, limb
 - Association with partial molar pregnancy, maternal severe preeclampsia in midtrimester
- **Carpenter syndrome**
 - Craniosynostosis
 - Cardiac anomalies, omphalocele
 - Complex digital anomalies including brachydactyly with clinodactyly, camptodactyly, and syndactyly
- **Pfeiffer syndrome**
 - Craniosynostosis, often severe cloverleaf shape
 - Exophthalmos, often severe
 - Complex partial syndactyly of hands, feet
- **Diabetic embryopathy**
 - Highest risk in poorly controlled diabetic
 - Multiple anomalies including cardiac, neural tube defect, other central nervous system, limb
 - Preaxial polydactyly classic finding
 - Syndactyly of hands and feet

PATHOLOGY

General Features

- Etiology
 - Failure of separation of digits occurring prior to 6 wk development
 - Bone morphogenetic proteins (BMPs) act directly to trigger apoptosis at apical ectodermal ridge (AER) of developing limb
 - Aberrant BMP receptor signaling leads to lack of interdigital apoptosis, resulting in syndactyly
- Genetics
 - Nonsyndromal familial cases are autosomal dominant
 - Incomplete penetrance
 - Variable expressivity
 - Syndromal dependent upon individual syndrome
 - Sporadic, amniotic bands
- Associated abnormalities
 - Other limb anomalies
 - Clefting, ectodermal dysplasia in EEC syndrome
 - Craniosynostosis in FGFR-related syndromes
 - Other structural anomalies, FGR in aneuploidy

- Dermatoglyphic abnormalities

CLINICAL ISSUES

Presentation

- Most common signs/symptoms
 - Simple vs. complex syndactyly
 - Simple syndactyly involves only soft tissues of digits
 - Complex syndactyly involves bone &/or nails in addition to soft tissues
 - Fingers may appear attached in open hand view on ultrasound
 - Diagnosis of syndactyly often difficult on prenatal ultrasound
- Other signs/symptoms
 - Other limb, structural anomalies suggestive of syndromal syndactyly

Demographics

- Age
 - No association with increased parental age
- Gender
 - More common in males
- Epidemiology
 - 1:2,000-3,000 live births
 - Most common congenital malformation of limb
 - Syndactyly is common feature in at least 25-30 syndromes
 - Syndactyly of toes more common than fingers

Natural History & Prognosis

- Nonsyndromal syndactyly usually has good prognosis
- Prognosis in syndromal syndactyly dependent upon particular syndrome
- Symphalangism associated with significant impairment due to lack of normal joint formation

Treatment

- Cosmetic vs. functional treatment
 - Dependent upon which digits involved
 - Osseous or soft tissue involvement
 - Multiple surgeries, including significant skin graft procedures, may be required

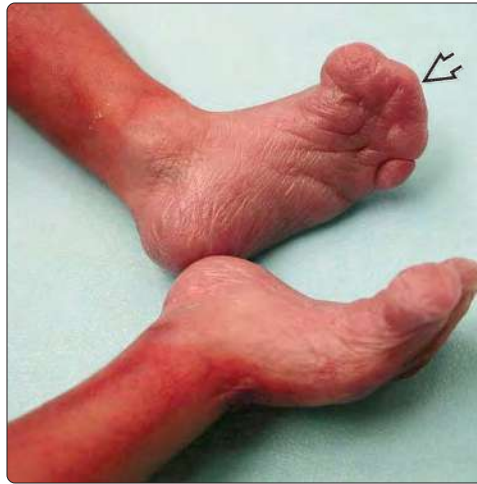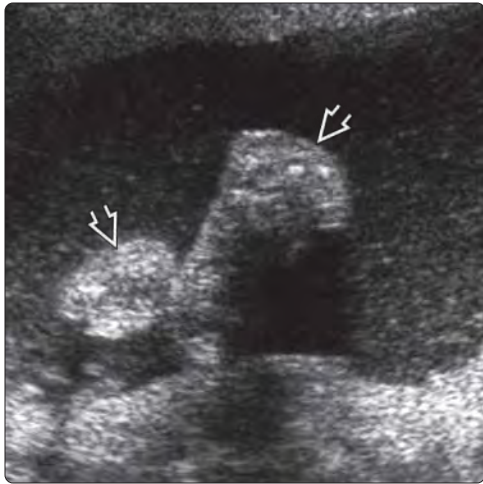
DIAGNOSTIC CHECKLIST

Image Interpretation Pearls

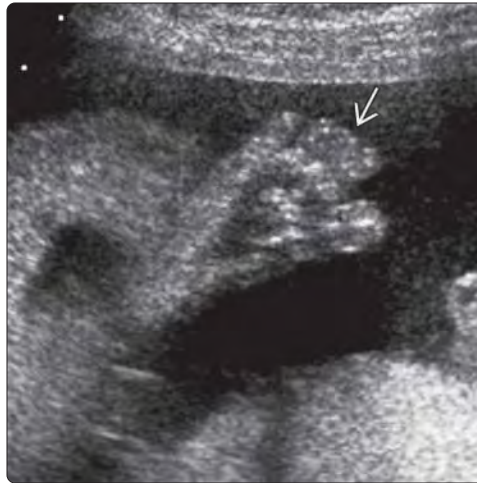
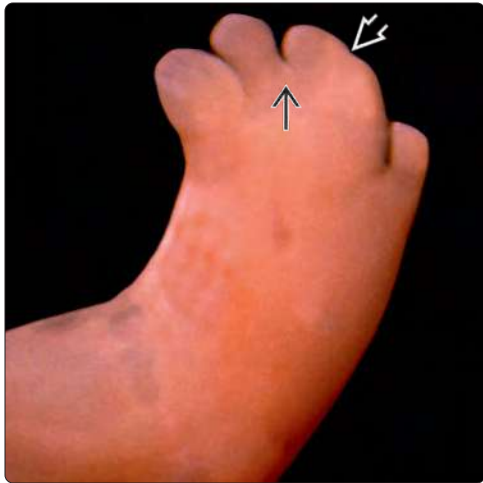- Elicit open-hand view by fetal stimulation
 - Persistent inability to visualize spread fingers concerning for syndactyly
 - Syndactyly often missed prenatally due to limitations of ultrasound

SELECTED REFERENCES

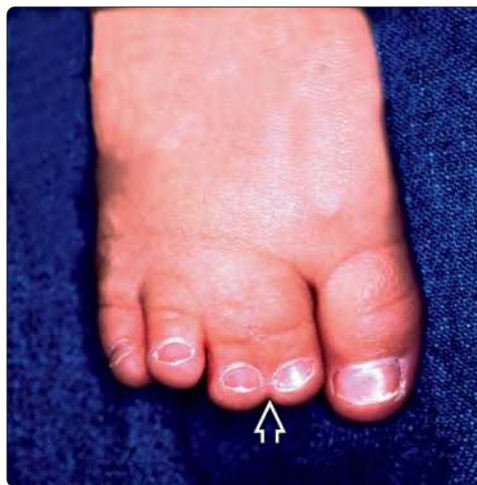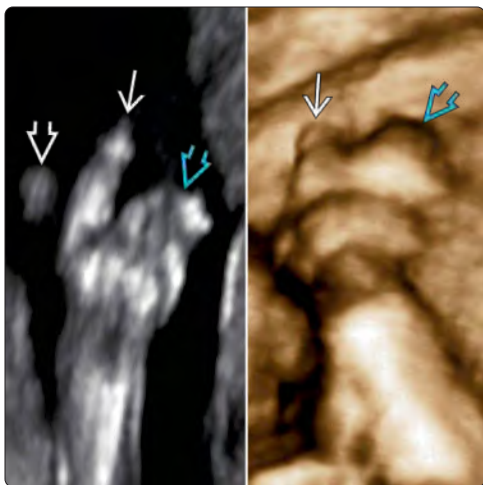
1. Kaltcheva MM et al: BMPs are direct triggers of interdigital programmed cell death. *Dev Biol.* 411(2):266-76, 2016
2. Little KJ et al: Congenital anomalies of the hand-principles of management. *Orthop Clin North Am.* 47(1):153-68, 2016
3. Wall LB et al: Synpolydactyly of the hand: a radiographic classification. *J Hand Surg Eur Vol.* 41(3):301-7, 2016
4. Deng H et al: Advances in the molecular genetics of non-syndromic syndactyly. *Curr Genomics.* 16(3):183-93, 2015



(Left) Ultrasound of the feet in a fetus with Apert syndrome shows extensive syndactyly with distal foot appearing broad and club-like; no individual toes are seen. **(Right)** The clinical photograph at autopsy shows the broad appearance from the extensive fusion. There is often bony fusion as well as soft tissue fusion.



(Left) Clinical photograph of the dorsal foot of a spontaneously aborted early 2nd-trimester fetus. Partial syndactyly of toes 2-3 and complete syndactyly of toes 3-4 is noted. No nails are seen. Multiple other anomalies were present and the association of syndactyly with other anomalies is suggestive of a syndromal cause. **(Right)** Midtrimester ultrasound of an otherwise normal fetus shows unusual syndactyly of toes 2-4. This was a unilateral abnormality and was an isolated finding after birth.



(Left) This is a case of familial syndactyly. The thumb & 2nd finger are normal but there is fusion of 3rd-5th digits. The mother had identical fusion pattern. Syndactyly may be isolated or syndromic. It is always important to look at the parents. While familial 2nd-3rd toe fusion is most common, other patterns can occur as in this case. **(Right)** Clinical photograph shows the most common type of syndactyly involving the 2nd and 3rd toes. This type of syndactyly is commonly transmitted as an autosomal dominant trait.

Split Hand/Foot Malformation

KEY FACTS

TERMINOLOGY

- Ectrodactyly
- Characterized by deficiency/hypoplasia of phalanges, metacarpals, metatarsals, and deep median cleft; fusion of remaining digits
- One of the most complex distal limb abnormalities

IMAGING

- Cleft appearance of hands &/or feet with missing digits
- Orofacial cleft in association with cleft hands or feet should prompt consideration of ectrodactyly-ectodermal dysplasia clefting syndrome (EEC syndrome)
- Should be seen in routine midtrimester hand and foot views
- Perform endovaginal ultrasound in 1st trimester in high-risk pregnancy
- Careful evaluation for other limb abnormalities, clefts, other structural anomalies

- Related disorders: EEC, limb-mammary syndrome (LMS), split hand/foot malformation with long bone deficiency (SHFLD), acro-dermato-ungual-lacrima-tooth syndrome (ADULT)

TOP DIFFERENTIAL DIAGNOSES

- Amniotic bands
- Diabetic embryopathy

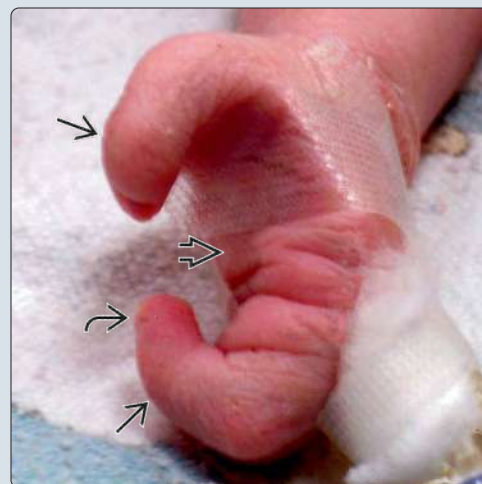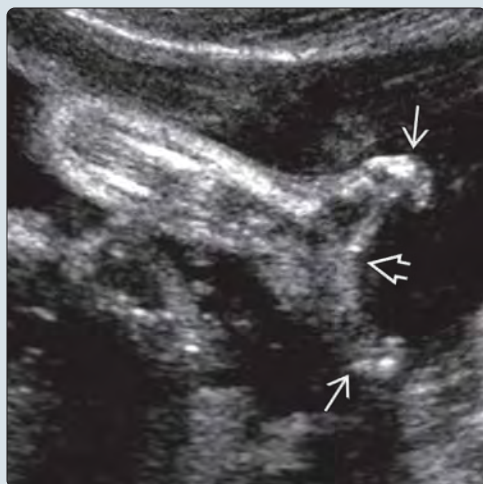
PATHOLOGY

- Classification schema is complex
- Nonsyndromal split hand/foot malformation (SHFM) maps to at least 7 different loci
- Most autosomal dominant inheritance with variable expressivity and reduced penetrance

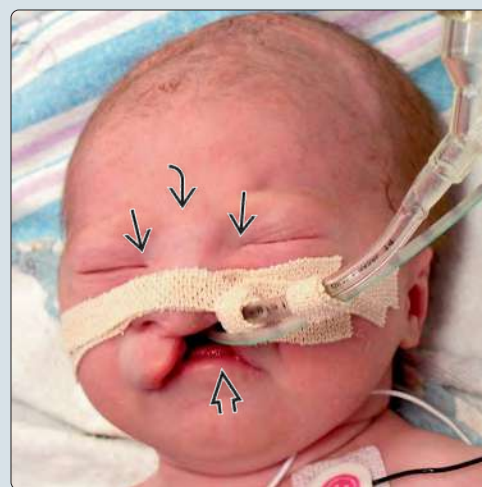
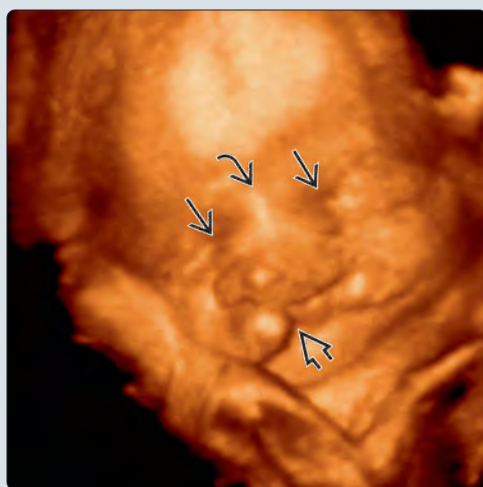CLINICAL ISSUES

- At least 75 syndromes reported with SHFM as feature
- SHFM accounts for 8-17% of all limb malformations

(Left) Ultrasound of a 3rd trimester fetus shows the classic appearance of the split hand malformation. Note the wide cleft [arrow] with 2 remaining digits [arrow]. **(Right)** Clinical photograph of the same infant at birth shows the striking appearance of the hand with 2 opposable digits [arrow] and a large median cleft [arrow] with central ray deficiency. In addition, the nails are quite hypoplastic [arrow]. Forty percent of individuals with split hand/foot have an associated syndrome, so further evaluation is required.



(Left) 3D ultrasound of the face in the same case shows hypertelorism [arrow], broad nasal root [arrow], and a large unilateral cleft lip and palate [arrow]. These are typical facial features of ectrodactyly-ectodermal dysplasia clefting (EEC) syndrome, an autosomal dominant condition. **(Right)** Clinical photograph of the same infant at birth illustrates the same features of unilateral cleft lip and palate [arrow], hypertelorism [arrow], and broad nasal root [arrow]. In addition, absent eyelashes and sparse hair were also evident.



TERMINOLOGY

Abbreviations

- Split hand/foot malformation (SHFM)

Synonyms

- Ectrodactyly
- Split hand/foot deformity (although malformation is more appropriate term)

Definitions

- One of the most complex distal limb abnormalities
- Characterized by deficiency/hypoplasia of phalanges, metacarpals, metatarsals, and deep median cleft; fusion of remaining digits
 - Central ray defect characteristics
 - Cleft hand
 - Monodactyly type with radial deficiency, absence of cleft
 - Aplasia/hypoplasia of phalanges, metacarpals, metatarsals, nails
 - Variable syndactyly
 - May be unilateral or bilateral
 - May involve only 1 or both hands, or hands and feet
- May occur in isolation or as part of syndrome with mental retardation, orofacial clefts, ectodermal abnormalities, other complex limb deficiencies, hearing loss
 - 40% of individuals with split hand/foot have associated abnormalities suggestive of syndrome
- Features are highly variable
 - Subtle digital abnormalities, abnormal crease patterns or syndactyly in obligate carrier
 - Cutaneous cleft without bony deficiencies
 - Deep cleft with medial ray deficiency
 - Monodactyly with single digit remnant

IMAGING

General Features

- Best diagnostic clue
 - Cleft appearance of hands &/or feet with missing digits on midtrimester ultrasound
 - Syndactyly of digits on either side of cleft (soft tissue ± bony fusion)
 - Orofacial cleft in association with cleft hands or feet should prompt consideration of ectrodactyly-ectodermal dysplasia clefting (EEC) syndrome

Imaging Recommendations

- Best imaging tool
 - Endovaginal (EV) ultrasound in 1st trimester in high-risk pregnancy
 - Should be seen on routine midtrimester hand and foot views
 - 3D ultrasound helps delineate features, which helps in counseling families
- Protocol advice
 - Careful evaluation for other limb abnormalities, clefts, other structural anomalies
 - Evaluation of parental hands and feet for evidence of clefting, syndactyly, or abnormal crease pattern

- Abnormalities may be quite subtle given variable expressivity in autosomal dominant conditions
- Hand films of high-risk individuals may be informative even when clinical exam is apparently normal

- Look for additional findings in related disorders
- **Ectrodactyly-ectodermal dysplasia clefting syndrome (EEC)**
 - Ectrodactyly of hands &/or feet
 - Ectodermal dysplasia
 - Hypopigmentation, sparse hair, absent or sparse lashes and brows, hypodontia, dystrophic nails, lacrimal duct abnormalities; conical teeth; apocrine abnormalities
 - Cleft lip ± palate
 - Genitourinary abnormalities
 - Hearing loss, may be later onset
 - EEC1 maps to 7q11.2-q21.3
 - EEC3 involves mutations in *P63* gene
- **Split hand/foot malformation with long bone deficiency (SHFLD)**
 - Ectrodactyly often unilateral
 - Bilateral absence or hypoplasia of tibiae most common
 - Probable autosomal dominant with reduced penetrance
- **Acro-dermato-ungual-lacrimal-tooth syndrome (ADULT)**
 - Phenotypic overlap with EEC
 - Ectrodactyly with ectodermal dysplasia features
 - Mutations in *P63* gene
- **Limb-mammary syndrome (LMS)**
 - Allelic with ADULT syndrome
 - Ectrodactyly of hands &/or feet
 - Hypoplasia/aplasia of mammary gland and nipple
 - Phenotypic overlap with ulnar-mammary syndrome (UMS)
 - Ulnar ray defect with apocrine, genital, dental abnormalities
 - UMS: Caused by mutations in *TBX3* gene
 - Mutations in *P63* gene

DIFFERENTIAL DIAGNOSIS

Amniotic Band Syndrome

- Distal digital amputations
- Pseudosyndactyly with distal digits held together by bands
- Extremities with constriction rings
- Digital abnormalities do not exhibit typical pattern of central ray deficiency
- Bizarre craniofacial or body wall clefts that do not follow normal embryologic fusion lines

Limb Reduction Defects

- Characterized by transverse terminal deficiency of limb(s)
- Rudimentary digits often present

Radial-Ulnar Deficiencies

- Transverse or intercalary deficiency
 - Preaxial = radial side; postaxial = ulnar side

Syndactyly

- May involve any or all digits of hands or feet
- Central rays usually present

Diabetic Embryopathy

- Highest risk in poorly controlled diabetic
- Many different anomalies common including cardiac, neural tube defect, brain, limb
- Caudal embryo anomalies common (e.g., caudal dysplasia, femoral hypoplasia)

PATHOLOGY**General Features**

- Etiology
 - Developmental errors in initiation and maintenance of apical ectodermal ridge of limb bud
 - Multiple signaling molecules, growth factors and transcription factors thought to be involved
- Genetics
 - Genetically heterogeneous
 - Mutations at 7 different chromosomal loci in isolated SHFM (SHFM1-6 and SHFM/SHFLD)
 - ◻ Most inherited in autosomal dominant fashion (SHFM1, 3, 4, 5)
 - ◻ Few families with autosomal recessive or X-linked recessive inheritance
 - Variable expressivity
 - Reduced penetrance
 - Mutations in *P63* have been found in autosomal dominant ectrodactyly syndromes including EEC, ADULT, and LMS as well as nonsyndromic SHFM
 - Transcription factor *P63* is homologous to *P53* tumor suppressor
 - *P63* plays critical role in regulation and formation of apical ectodermal ridge in limbs
 - Mice lacking *p63* activity have partial or complete truncation of various limbs
 - Chromosomal rearrangements involving 7q21-q22

Staging, Grading, & Classification

- Classification schema is complex
 - Typical vs. atypical
 - Atypical often unilateral, sporadic, involving hand only with deficiency of 3 central rays; also called symbrachydactyly
 - Typically bilateral, involving both hands and feet, often with positive family history; may involve central ray absence with deep median cleft or monodactyly type
 - Anatomic
 - Classification based on surgical considerations
 - Monodactyly, bidactyly, oligodactyly
 - Genetic
 - Nonsyndromal SHFM maps to at least 7 different loci
 - ◻ SHFM1 (7q21.3-q22.1): Most de novo; some inherited as autosomal dominant
 - ◻ SHFM2 (Xq26): Single family report; X-linked
 - ◻ SHFM3 (10q24): Accounts for 20% of cases in humans; *DACTYLIN*, human homolog of mouse dactylaplasia
 - ◻ SHFM4 (3q27): *P63* mutations; accounts for 10-16% of isolated cases; inherited as autosomal dominant
 - ◻ *SHFM5* (2q31): Deletions of region encompass entire *HOXD* gene cluster

- ◻ SHFM6 (12q13; *WNT10B*): Autosomal recessive inheritance identified in 3 consanguineous families and 1 sporadic case
- ◻ SHFM/SHFLD (SHFM with long bone deficiency involving tibia/fibula) (17p13.3 tandem duplication): Same duplication accounts for 12% of cases of SHFM without long bone involvement
 - Syndromal SHFM: Some also linked to these loci

CLINICAL ISSUES**Presentation**

- Other signs/symptoms
 - Clinically heterogeneous
 - 40% of split hand/foot malformation patients have associated congenital anomalies not involving limbs
 - At least 75 syndromes reported with split hand/foot malformation as feature
 - Significant phenotypic overlap

Demographics

- Epidemiology
 - Occurs in ~ 1/18,000 liveborn infants
 - Studies including livebirths, stillbirths, and terminations with similar rates of occurrence
 - SHFM accounts for 8-17% of all limb malformations

Natural History & Prognosis

- Dependent upon associated anomalies
- May have significant orthopedic complications
- EEC syndrome with multiple complications involving hearing and visual difficulties; recurrent eye, respiratory, and genitourinary infections
 - Significant variability even within families; complications may vary amongst family members

Treatment

- No prenatal treatment
- Referral for genetic counseling
- Fetal karyotype should be offered
- Prenatal syndrome diagnosis possible if mutation identified
- Postnatal treatment is surgical
 - Improve functionality of hands
 - Improve or enable ambulation
 - Repair of orofacial clefts
 - Lacrimal duct abnormalities

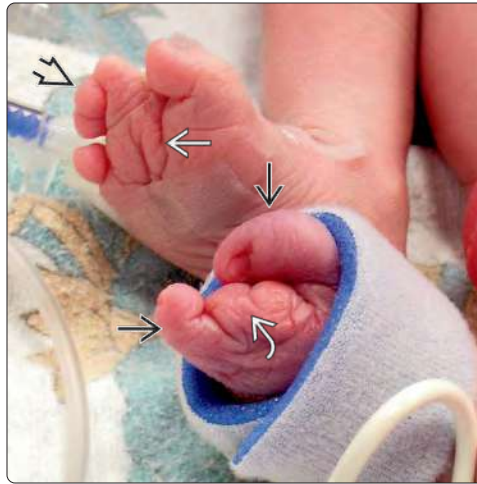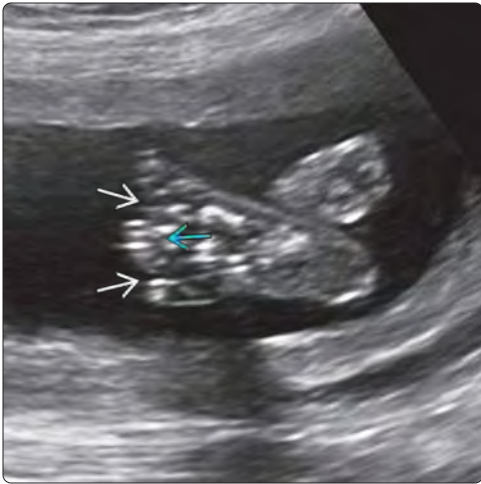
DIAGNOSTIC CHECKLIST**Consider**

- Endovaginal imaging in 1st trimester in high-risk families
- 3D ultrasound to further evaluate limb malformations, facial features

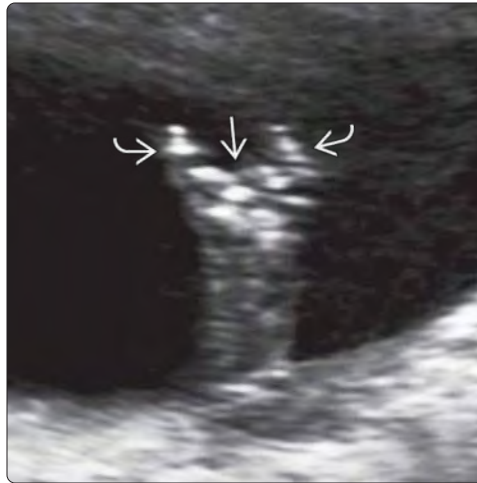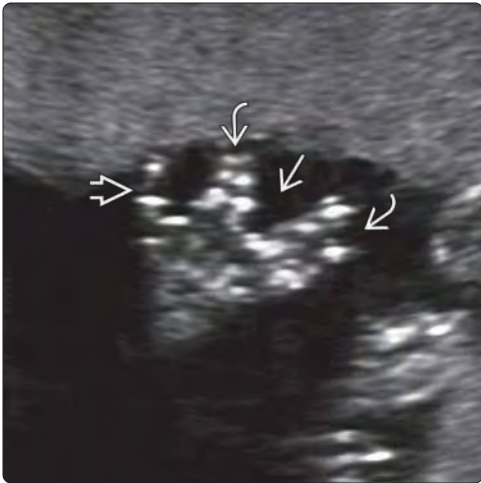
SELECTED REFERENCES

1. Klar AJ: Selective chromatid segregation mechanism proposed for the human split hand/foot malformation development by chromosome 2 translocations: A perspective. *Dev Biol.* 408(1):7-13, 2015
2. Lu J et al: Prenatally diagnosed fetal split-hand/foot malformations often accompany a spectrum of anomalies. *J Ultrasound Med.* 33(1):167-76, 2014
3. Sowińska-Seidler A et al: Split-hand/foot malformation - molecular cause and implications in genetic counseling. *J Appl Genet.* 55(1):105-15, 2014
4. Gurrieri F et al: Clinical, genetic, and molecular aspects of split-hand/foot malformation: an update. *Am J Med Genet A.* 161A(11):2860-72, 2013

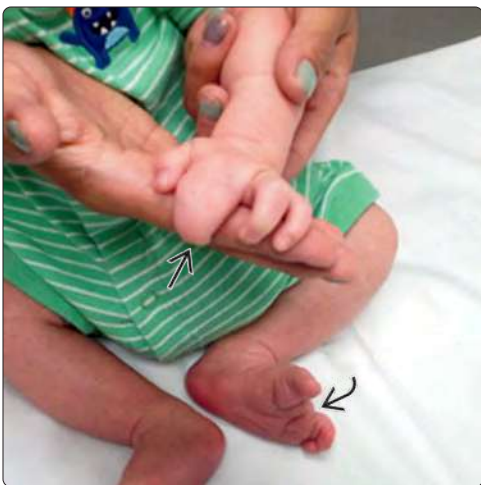Split Hand/Foot Malformation



(Left) Ultrasound shows a fetus at 22 weeks with split hand/foot malformation. Both feet and 1 hand appeared to be affected. Note the clefts adjacent to the great and 5th toe. There appears to be syndactyly of toes 2, 3, and 4. **(Right)** Clinical photograph of the feet of an infant with EEC syndrome shows incurving great and 5th toes with missing toes 2,3, and 4 on the left. Syndactyly of the middle 3 toes is seen on the right foot. An unusual crease pattern is also seen.



(Left) Ultrasound of a fetus at 17-weeks gestation with split hand/foot malformation. There is a midline cleft of the hand and apparent syndactyly of digits 2, 3 and 4, 5. The thumb appears to be present. The family history was negative for split hand/foot, syndactyly, orofacial clefts, or other birth defects. **(Right)** Ultrasound of the foot of the same fetus at 17-weeks gestation shows a large midline cleft. Only 2 digits are seen. Syndactyly is particularly difficult to see on prenatal ultrasound, especially involving the feet.



(Left) Photograph of an infant with EEC syndrome shows the asymmetry of the extremity malformations. Only 1 hand and the ipsilateral foot were involved. Note the syndactyly involving digits 2-3 of the hand and the large cleft of the foot with missing toes 2-3. **(Right)** Hands of the older brother illustrate the clinical variability between siblings. This is the postsurgical appearance of the digits; surgery was performed to provide greater function. Prominent clefts and hypoplastic distal digits are seen.

Arthrogryposis, Akinesia Sequence

KEY FACTS

TERMINOLOGY

- Abnormalities related to lack of fetal movement

IMAGING

- Multiple congenital joint contractures involving 2 or more body areas
- Lack of extremity motion despite fetal stimulation
- Unusual or persistent abnormal posturing of limbs
 - Persistent "pike" position of lower limbs with hyperextended knees
 - Crosslegged "tailor's position" of lower limbs
 - Extended elbows with internally rotated, flexed wrists ("waiter's tip")
 - Clubfeet/rocker-bottom feet, may be very severe
 - Clenched hands
- Lack of facial movement
 - Persistent open mouth throughout exam
 - Micrognathia
- Polyhydramnios from decreased fetal swallowing







- Evaluate degree of involvement
 - Progressive vs. static
 - Generalized vs. focal

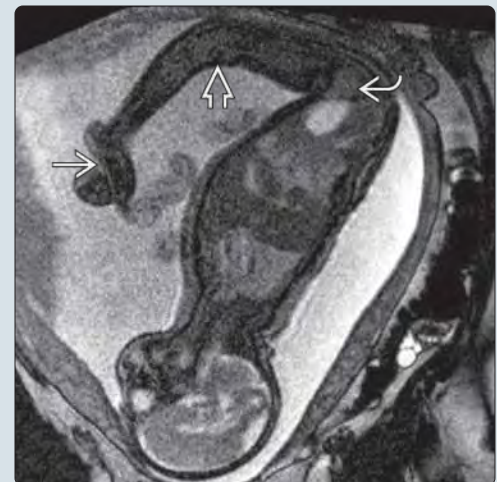
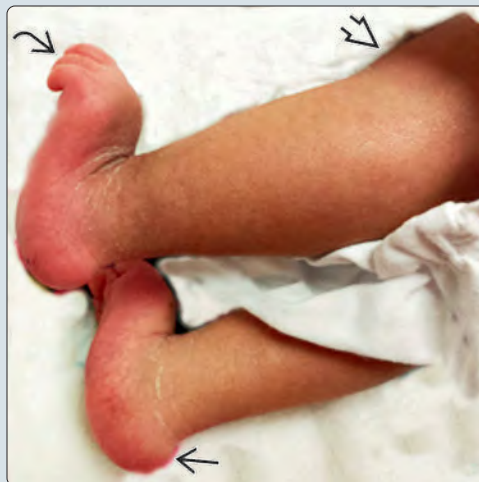TOP DIFFERENTIAL DIAGNOSES




- Multiple different etiologies
 - Trisomy 18
 - Distal arthrogryposis
 - Amyoplasia
 - Multiple pterygium syndrome
 - Spinal muscular atrophy
 - Acetylcholine receptor (AChR) antibodies
 - Restrictive dermopathy
 - Caudal regression sequence
 - Gaucher type 2

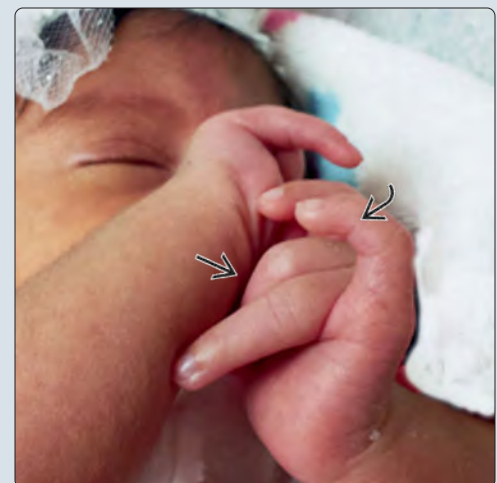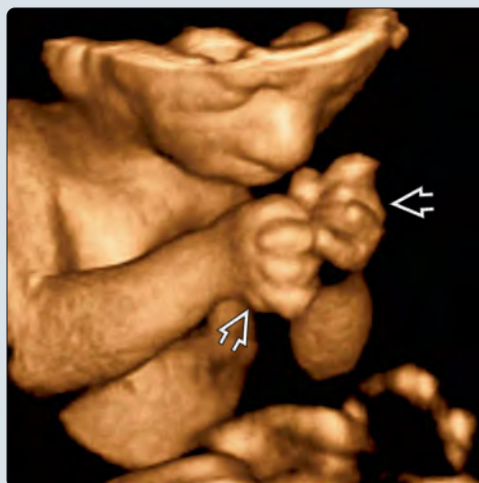DIAGNOSTIC CHECKLIST

- Progressive generalized lack of fetal movement with hydrops predicts high risk of lethality

(Left) Newborn infant with arthrogryposis involving primarily the distal extremities. Note the rocker-bottom feet with prominent calcaneus  and fixed, flexed toes . The knees are hyperextended  but could be passively flexed. **(Right)** Sagittal T2WI MR shows a fetus with arthrogryposis. Note the flexed hips , hyperextended knees , and clubfeet . Polyhydramnios is also present. Lower extremity findings vary but a persistent "pike" position with hyperextended knees is a common finding.



(Left) 3D ultrasound shows a fetus with arthrogryposis who had multiple findings, including overlapping clenched fingers , polyhydramnios, clubbed feet, and severe micrognathia. Real-time ultrasound showed truncal movements but no extremity movements. Chromosomes were normal. **(Right)** Newborn infant with distal arthrogryposis is shown. Note the very abnormal finger posture . The digits could not be extended. Some flexion creases were present , but others were deficient due to lack of movement in utero.



TERMINOLOGY

Synonyms

- Multiple congenital contractures
- Fetal akinesia/hypokinesia deformation sequence
- Arthrogryposis multiplex congenita
- Pena-Shokeir phenotype

Definitions

- Arthrogryposis refers to symptom complex caused by multiple different etiologies
 - Abnormalities related to lack of fetal movement in utero
- Multiple congenital joint contractures/ankyloses involving 2 or more body areas
- Pena-Shokeir phenotype
 - Heterogeneous group of disorders with micrognathia, multiple contractures, camptodactyly (persistent finger flexion), polyhydramnios
 - Many are autosomal recessive
 - Lethal due to pulmonary hypoplasia
- Distal arthrogryposis
 - Subset of nonprogressive contractures without associated primary neurologic or muscle disease

IMAGING

General Features

- Best diagnostic clue
 - Lack of extremity motion despite fetal stimulation
 - Persistent unusual or abnormal posturing of limbs
 - Early finding often clubfeet and clenched hands
 - Progressive decreased movement over gestation

Ultrasonographic Findings

- Lack of extremity motion
 - May be seen as early as 1st trimester
 - Often progressive over course of gestation
 - In severe conditions, only movement may be truncal "writhing" motion
 - Progressive osteopenia in late gestation, especially affected limbs
- Unusual or persistent abnormal posturing of limbs
 - Persistent "pike" position of lower limbs with hyperextended knees
 - Cross-legged "tailor's position" of lower limbs, especially in breech fetus
 - Extended elbows with internally rotated, flexed wrists ("waiter's tip")
 - Clubfeet/rocker-bottom feet, may be very severe
 - Clenched hands never open
- Lack of facial movement
 - Persistent open mouth throughout exam
 - No apparent swallowing motion during observation
 - Micrognathia
- Polyhydramnios: Decreased fetal swallowing
 - May be severe in late gestation
- Pulmonary hypoplasia
 - Short gracile ribs
 - Variable fetal breathing motion
- Short umbilical cord due to lack of fetal movement
- 1st-trimester nuchal edema or cystic hygroma

- With history of prior affected pregnancy finding suggests recurrence
- Increased skin thickening, hydrops predicts poor prognosis

MR Findings

- Fetal MR for evaluation of CNS in 3rd trimester
 - Lissencephaly
 - Hydrocephalus
 - Spinal cord abnormalities

Imaging Recommendations

- Best imaging tool
 - 3D-4D ultrasound provides added information on joint positioning
- Careful survey for associated anomalies
- Evaluation of degree of involvement
 - Progressive vs. static
 - Generalized vs. focal
 - Upper &/or lower extremity involvement
- Multiple structural anomalies and fetal growth restriction (FGR)
 - Increased risk for trisomy 18
- Upper extremity in "waiter's tip" position
 - Amyoplasia
- "Whistling" face with pursed lips on profile
 - Freeman-Sheldon syndrome
- Risk of respiratory difficulties at birth increased with
 - Polyhydramnios
 - Generalized decreased fetal movement
 - Hydrops

DIFFERENTIAL DIAGNOSIS

Trisomy 18

- Multiple structural anomalies, FGR
- Clenched hands, overlapping digits

Distal Arthrogryposis

- Most common cause of multiple congenital contractures
- **Distal arthrogryposis type 1A**
 - Overlapped fingers with abnormal digital flexion creases
 - Talipes equinovarus and vertical talus
- **Freeman-Sheldon syndrome**
 - Distal arthrogryposis type 2A
 - "Whistling" face: Mouth may be only few mm in diameter
 - Ulnar deviation of fingers with camptodactyly
 - Hypoplastic thumbs

Amyoplasia

- Extended elbows with internally rotated shoulders and flexed wrists ("waiter's tip")
- Symmetric contractures upper > lower
- Round face with micrognathia
- Midline facial hemangioma
- Generally good prognosis with normal cognition
- Rare association with gastroschisis

Multiple Pterygium Syndrome

- Severe contractures with webbing across joints
- Cystic hygroma
- Prenatal or neonatal lethal

Spinal Muscular Atrophy

- 2nd most common recessive disorder in Caucasians with carrier frequency of 1/50
- Heterogeneous group of (often) lethal neuromuscular disorders
- Loss/destruction of anterior horn cells
- > 95% due to homozygous deletions of exons 7 and 8 in survivor motor neuron (*SMN1*) gene

Acetylcholine Receptor Antibodies

- Myasthenia gravis
 - Acetylcholine receptor (AChR) antibodies in ~ 85% of patients with myasthenia gravis
 - AChR antibodies cross placenta and block neuromuscular transmission in fetus
 - Neonatal myasthenia in 12% of affected mothers
 - Occasional stillbirth
- AChR clustering protein rapsyn
 - Early onset: Severe arthrogryposis
 - Late onset: Weakness, features similar to seronegative myasthenia gravis

Restrictive Dermopathy

- Tight rigid skin with erosions
- Micrognathia, small mouth
- Severe arthrogryposis
- Perinatal lethal

Caudal Regression Sequence

- Absent lower spine
- Lower extremity contractures
- Maternal diabetes risk factor

Gaucher Type 2: Perinatal Lethal Type

- Lysosomal storage disease due to glucocerebrosidase deficiency
- Hepatosplenomegaly and hydrops

PATHOLOGY

General Features

- Etiology
 - Destruction of anterior horn cells may be an underlying cause
 - Maximum sensitivity to hypoxia at 8- to 14-weeks gestation
- Genetics
 - Chromosomal abnormality in ~ 2%
 - Trisomy 18, mosaic trisomy 8
 - Autosomal dominant
 - Distal arthrogryposis: Caused by mutations in genes encoding fast-twitch contractile proteins
 - Autosomal recessive
 - Pena-Shokeir
 - Spinal muscular atrophy
 - Restrictive dermopathy
 - Scandinavian lethal congenital contractures
 - Fowler syndrome: Proliferative vasculopathy, hydranencephaly, akinesia
 - Sporadic
 - Teratogen exposure: 1st trimester-misoprostol
- Associated abnormalities

- Absent flexion creases
- Skin dimples over affected joints
- Atrophic affected limbs

Microscopic Features

- Affected muscles replaced by fat, fibrous tissue
- Anterior horn cell depletion
- Evidence of hypoxic/ischemic damage in spinal cord, brain

CLINICAL ISSUES

Presentation

- Most common signs/symptoms
 - Lack of fetal movement and abnormal extremity position on 1st- or 2nd-trimester ultrasound

Demographics

- Epidemiology
 - 1:3,000 live births

Natural History & Prognosis

- Depends on
 - Number and severity of contractures
 - Associated anomalies/chromosomal disorders
- Ventilator dependence at birth → poor prognosis
- Survivors require intensive orthopedic/physical therapy care

Treatment

- Genetic counseling: Offer karyotype
- If prior affected pregnancy
 - Serial ultrasounds every other week through 24 weeks
 - Evaluate fetal movement at all small and large joints
- Deliver at tertiary center
 - Risk of respiratory failure
 - Expertise in genetics, fetopathology
- Mode of delivery
 - Vaginal delivery may be compromised by fixed extremity position
 - Fracture risk due to osteopenia
- Complete autopsy in cases of fetal or neonatal death
 - Evaluation of brain, spinal cord, muscle, peripheral nerves

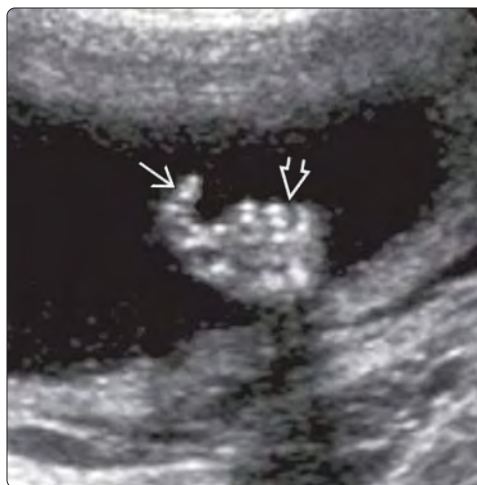
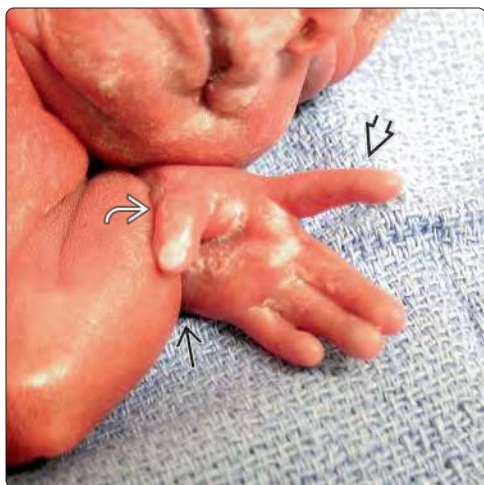DIAGNOSTIC CHECKLIST






Image Interpretation Pearls

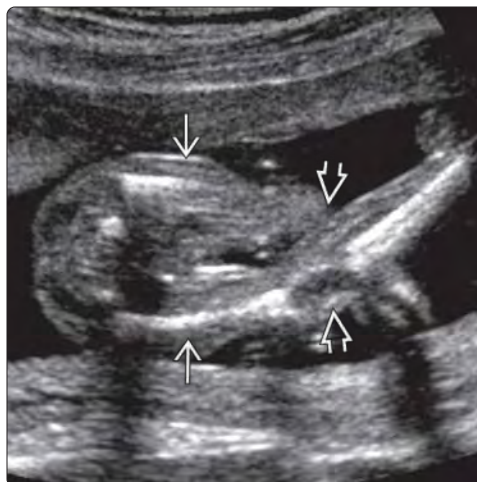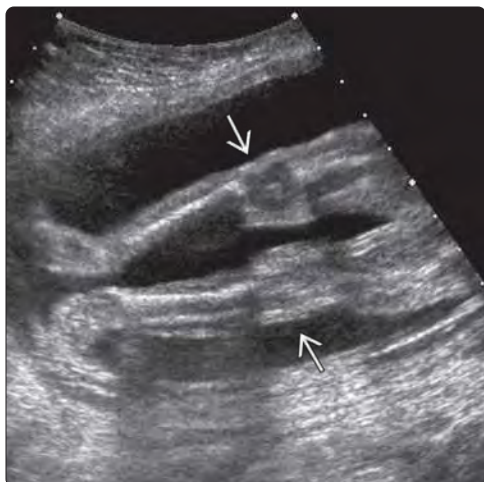- Progressive generalized lack of fetal movement with hydrops predicts high risk of lethality




SELECTED REFERENCES

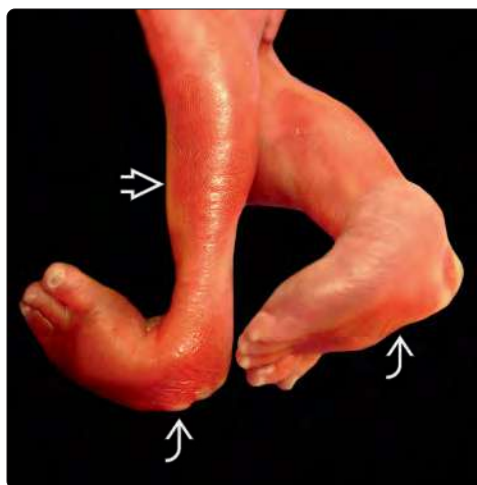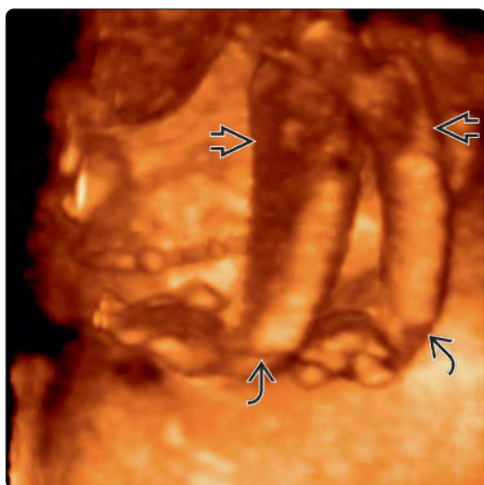
1. Hall JG et al: Summary of the 2nd International Symposium on Arthrogryposis, St. Petersburg, Russia, September 17-19, 2014. *Am J Med Genet A.* 167(6):1193-5, 2015
2. Beck AE et al: Genotype-phenotype relationships in Freeman-Sheldon syndrome. *Am J Med Genet A.* 164A(11):2808-13, 2014
3. Hall JG: Arthrogryposis (multiple congenital contractures): diagnostic approach to etiology, classification, genetics, and general principles. *Eur J Med Genet.* 57(8):464-72, 2014
4. Rink BD: Arthrogryposis: a review and approach to prenatal diagnosis. *Obstet Gynecol Surv.* 66(6):369-77, 2011
5. Bamshad M et al: Arthrogryposis: a review and update. *J Bone Joint Surg Am.* 91 Suppl 4:40-6, 2009
6. Hausmanowa-Petrusewicz I: Phenotype and genotype correlation in childhood spinal muscular atrophy. *Neurol Neurochir Pol.* 35 Suppl 3:29-35, 2001







(Left) Clinical photograph of a stillborn infant illustrates a peculiar hand position with ulnar deviation of the wrist , adducted thumb , and abducted 2nd finger . The smooth palmar surfaces of the hand and fingers infer lack of movement in utero. Both hands exhibited identical posture. **(Right)** Ultrasound of a midtrimester fetus shows a clenched hand  with camptodactyly of the 2nd finger . This is characteristic of the hand posture in trisomy 18. Approximately 2% of arthrogryposis cases are caused by aneuploidy.

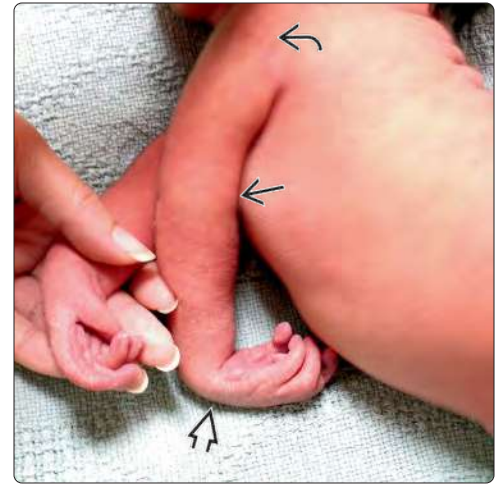
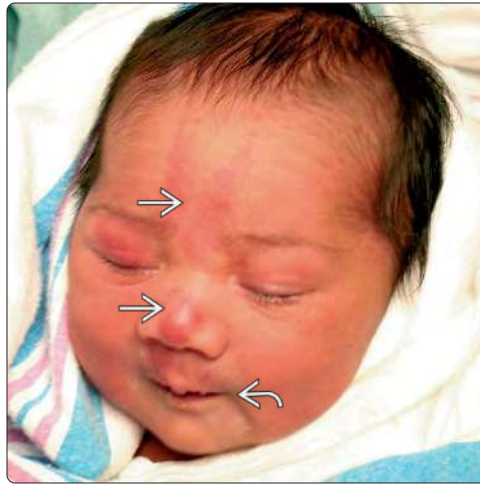
(Left) Coronal ultrasound shows persistently straight legs  in this fetus with arthrogryposis. No spontaneous movement of the hip, knee, or ankle joints was seen from the early 2nd trimester on. **(Right)** Coronal ultrasound in another fetus with arthrogryposis shows tightly adducted hips , and varus abnormality of the knees . The legs remained crossed at the knees and did not move spontaneously. Bilateral clubfeet were also seen.

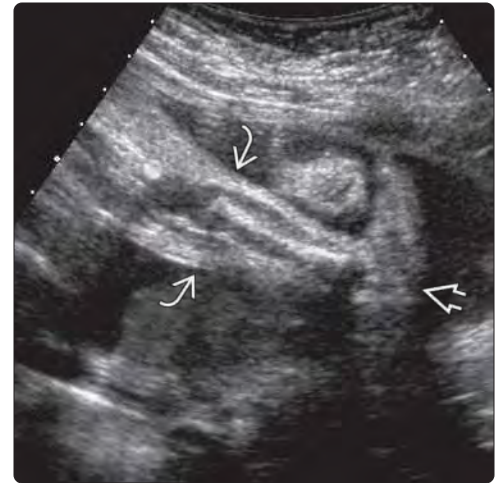
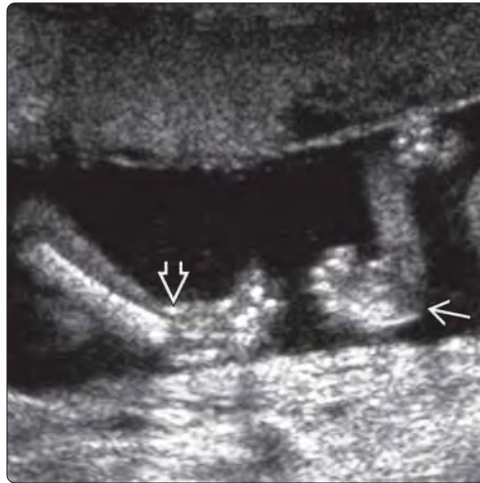


(Left) 3D ultrasound of the lower extremities of a midtrimester fetus with severe, progressive fetal arthrogryposis akinesia sequence shows hyperextended knees  and bilateral clubfeet . Polyhydramnios was also present. **(Right)** Clinical photograph shows the same fetus, stillborn at 23 weeks. There were multiple asymmetric joint contractures, including severe clubfeet . Note the atrophic musculature  from lack of movement.

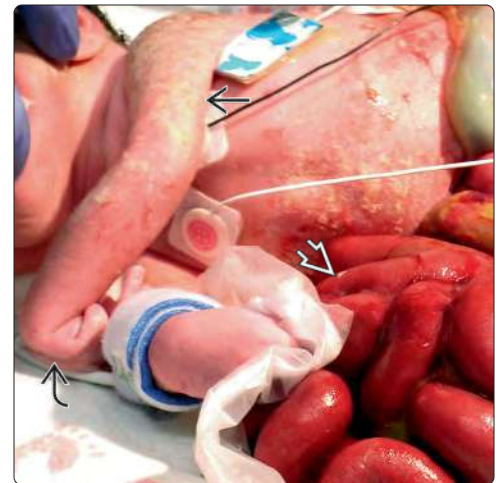
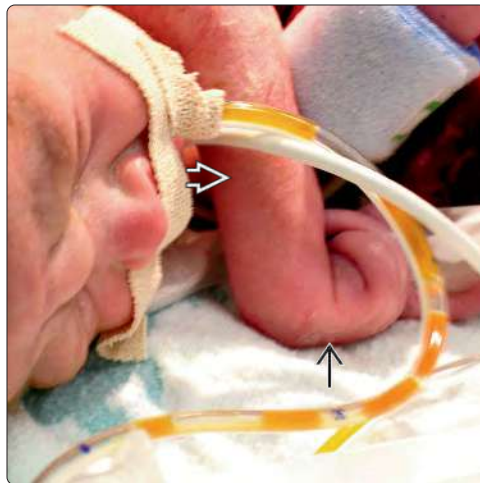(Left) Clinical photograph of a newborn infant with amyoplasia illustrates typical round facies and midfacial hemangioma. Note also the small mouth. (Right) Clinical photograph of the same infant shows the very typical posture of internally rotated shoulders, hyperextended elbows, flexed wrists ("waiter's tip"), and thin curved fingers. Note the atrophic appearance of the arms. Flexion creases on the palmar surfaces of the hands are typically underdeveloped or absent.

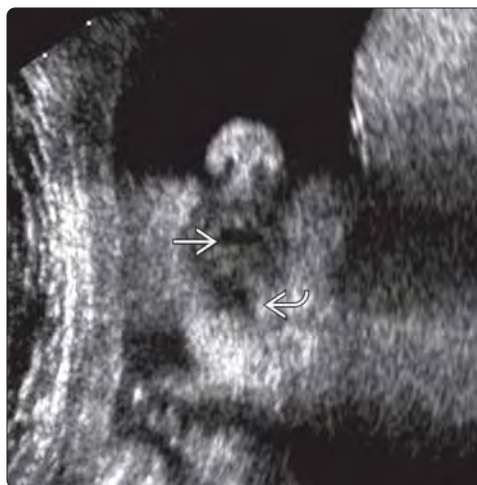
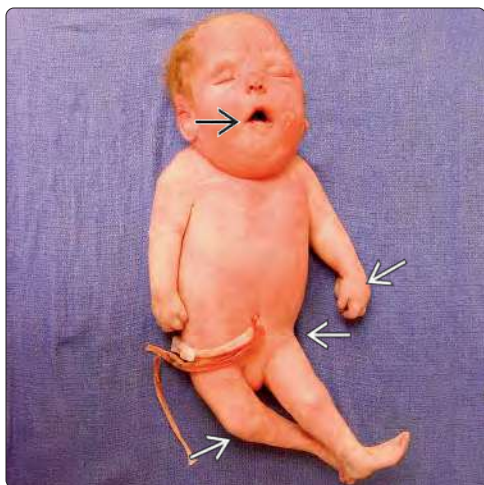

(Left) Ultrasound of an infant with arthrogryposis shows abnormal flexure of the leg with clubfoot and flexed wrist with clenched fingers. These joint abnormalities are typically seen at the time of midtrimester screening ultrasounds. (Right) Lower extremity ultrasound in a different case shows persistently extended and crossed legs ("scissored") with clubfeet. This posture is concerning for significant neurologic impairment.

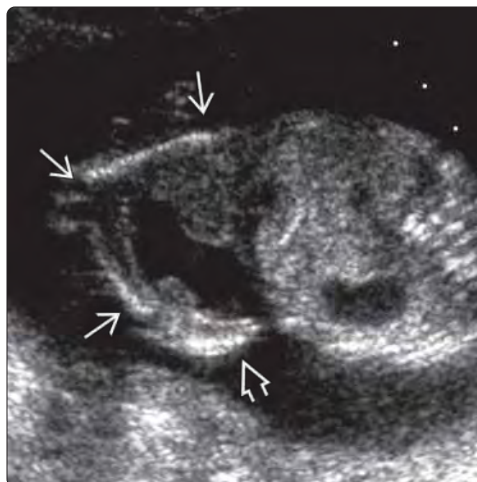
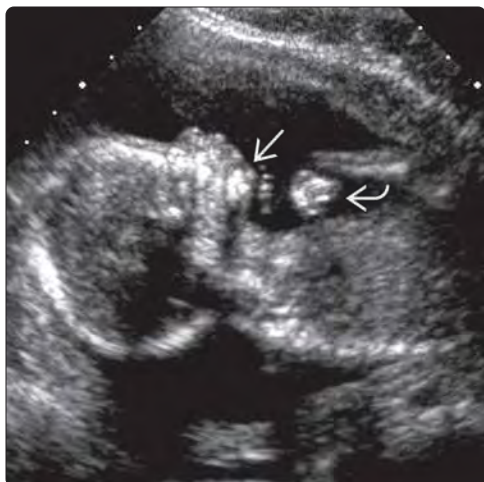


(Left) Clinical photograph shows a premature infant with gastroschisis and amyoplasia, a relatively rare but recognizable association. Note the typical hand posture and atrophic-appearing arm. (Right) Another photograph of the same infant shows the abdominal wall defect. Note the thin, atrophic-appearing arm with the extended elbow and internally rotated flexed hand.

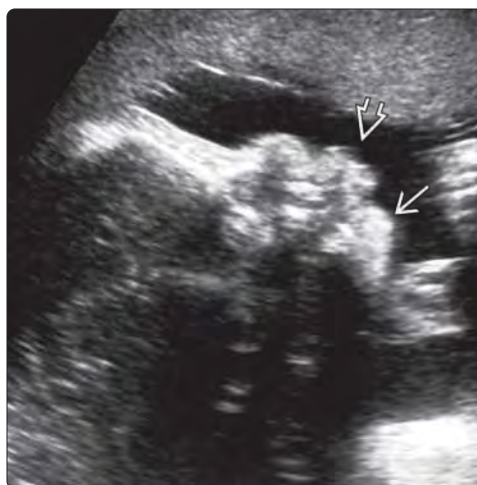
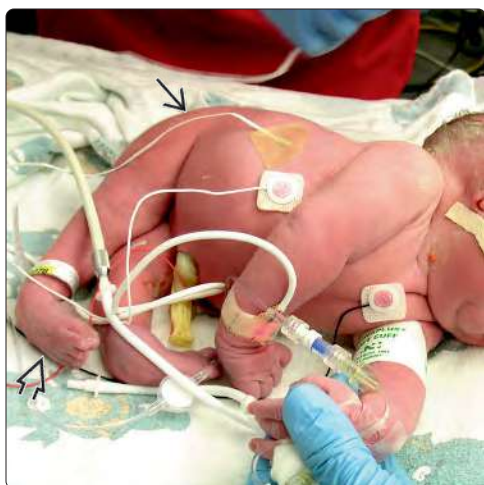



(Left) Clinical photograph of a stillborn infant with severe Smith-Lemli-Opitz syndrome shows multiple fixed joint contractures involving the hands, hips, and knees. Note the persistent open mouth. Polyhydramnios was severe in this case from lack of fetal swallowing. (Right) Coronal oblique ultrasound shows a persistently open mouth and recessed chin in a 3rd-trimester fetus with hydrops and severe arthrogyposis. Lack of normal mouth movements impairs swallowing, resulting in polyhydramnios.



(Left) Sagittal ultrasound in another fetus with severe progressive arthrogyposis shows micrognathia. The wrist is flexed and the hands are held in a clenched position. (Right) Ultrasound of the lower extremities in the same fetus shows the severely abnormal posture of the fetal leg and hyperextended foot. Arthrogyposis can be caused by many different entities and genetic counseling should be offered in all cases.



(Left) Clinical photograph of a newborn infant with a thoracolumbar myelomeningocele shows typical arthrogyrotic changes of the lower extremities. Flexed hips with extended knees, atrophic legs, and clubfeet are noted. (Right) Ultrasound of a 3rd-trimester fetus shows the pursed ("whistling") lips seen in Freeman-Sheldon syndrome (distal arthrogyrosis type 2A). Mild micrognathia is also noted.

Proximal Focal Femoral Dysplasia

KEY FACTS

TERMINOLOGY

- Dysplasia or aplasia of proximal femur
 - Spectrum of dysplasia ranges from mild shortening to absent femur to level of condyles

IMAGING

- Femur is short and angulated
 - Subtrochanteric varus bowing of femur
- Proximal and distal femur may be discontinuous
- Bone mineralization is normal
- Leg length discrepancy due to deficient femur
- Flexion contractures can be present
- Lower extremity usually flexed, abducted, and externally rotated at hip

TOP DIFFERENTIAL DIAGNOSES

- Femoral-fibula-ulna syndrome
 - Some authors include PFFD in this spectrum
- Femoral hypoplasia-unusual facies syndrome

- Characteristic facial features
- Trisomy 21
 - Mild rhizomelic limb shortening
- Early onset fetal growth restriction

PATHOLOGY

- Femoral head can be absent or discontinuous from distal femur
- Pseudoarthrosis may be present with varus angulation
- Distal femoral shaft has classic pencil-point appearance

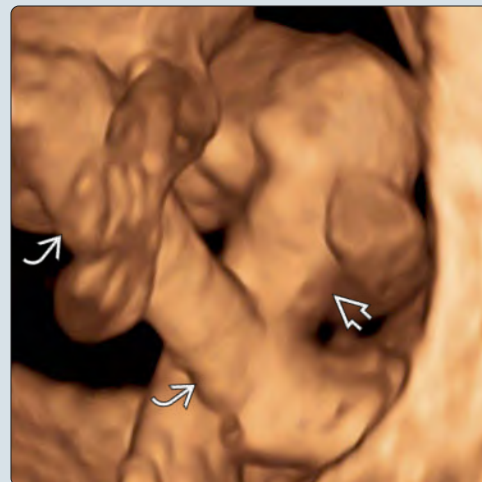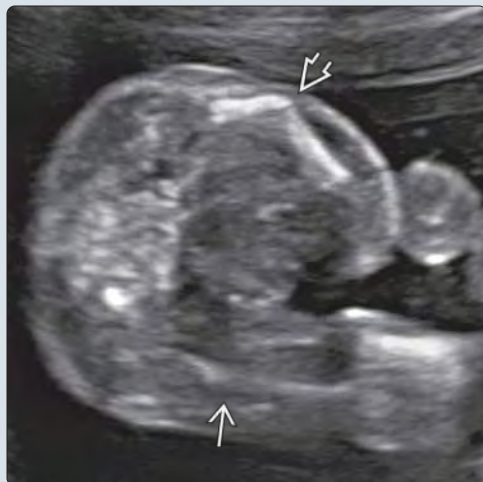CLINICAL ISSUES

- Consider diabetic embryopathy if history of maternal diabetes

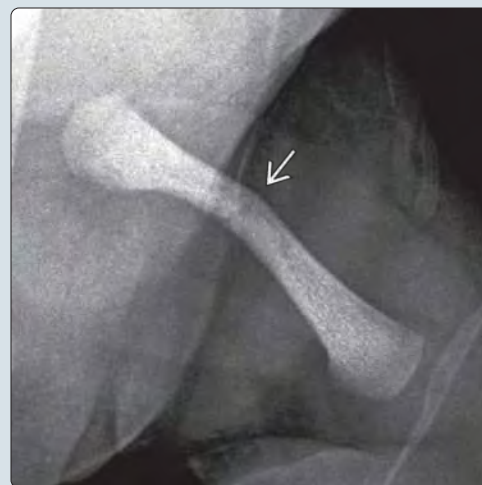
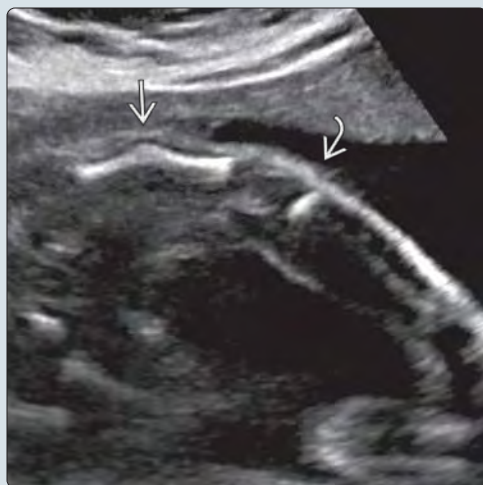DIAGNOSTIC CHECKLIST

- If one femur appears short, measure other long bones to exclude global skeletal abnormality
- Downside femur can appear bowed due to artifact

(Left) Axial ultrasound shows the right femur is angulated and short compared to the left (partially seen). The mineralization appears normal, unlike other causes of bent bones, such as osteogenesis imperfecta or hypophosphatasia. **(Right)** 3D ultrasound of the lower extremities in the same fetus shows the foreshortening of the right lower extremity compared with the normal left side.



(Left) In this 23-week fetus, there is shortening and focal angulation of the left femur, with varus angulation at the knee, as typically seen with proximal focal femoral dysplasia (PFFD). Check the opposite side carefully as PFFD can be bilateral in 10-20% of cases. **(Right)** Postnatal radiograph of the left femur in the same patient confirms the focal varus angulation of the proximal femoral diaphysis.



TERMINOLOGY

Abbreviations

- Proximal focal femoral dysplasia (PFFD)

Definitions

- Dysplasia or aplasia of proximal femur
 - Normal development fails to occur
- Spectrum of dysplasia ranges from mild shortening to absent femur to level of condyles

IMAGING

General Features

- Best diagnostic clue
 - Asymmetric length of 1 femur
 - Difference may be subtle to severe
 - Short femurs bilaterally without other skeletal abnormalities
 - 10-20% of cases are bilateral
- Location
 - Proximal femur

Ultrasonographic Findings

- Grayscale ultrasound
 - Femur is short and angulated
 - Subtrochanteric varus bowing of femur
 - Attempt to evaluate as upside femur to avoid bowing artifact seen often on downside femur
 - Compare to contralateral femur
 - If proximal femur present, femoral head may be dysmorphic or absent
 - Proximal and distal femur may be discontinuous
 - Distal femur often pencil-pointed if discontinuous
 - Hemipelvis also affected in most cases
 - If mild, may not be detected prenatally
 - If severe, can see dysplasia or aplasia of ipsilateral acetabulum and pelvis
 - Bone mineralization is normal
 - Unlike other skeletal dysplasias with undermineralization causing bowing &/or fractures
 - Leg length discrepancy due to deficient femur
 - Flexion contractures can be present
- 3D
 - To show osseous anatomy
 - Can show underlying bony discontinuity of femur and abnormal femoral head morphology
 - Can be useful to show typical short thigh due to underlying short angulated femur
 - Lower extremity usually flexed, abducted, and externally rotated at hip

Imaging Recommendations

- Best imaging tool
 - Ultrasound used to characterize femur length and morphology
 - Can also be used to evaluate ipsilateral hemipelvis
 - MR usually reserved for postnatal evaluation
 - Aids in evaluation of acetabulum, cartilaginous femoral epiphysis, knee ligaments
- Protocol advice

- Evaluate both femurs if one measures short for gestational age
- Measure other long bones to disprove global skeletal anomaly

DIFFERENTIAL DIAGNOSIS

Femoral-Fibula-Ulna Syndrome

- Defects of femur, fibula, &/or ulna
- Usually sporadic
- Upper limbs more often affected than lower
- More often unilateral than bilateral
- Some authors include PFFD in this spectrum rather than its own entity

Femoral Hypoplasia-Unusual Facies Syndrome

- Strongly associated with diabetic embryopathy
- Femoral hypoplasia present
 - Unilateral or bilateral
 - May be seen with clubfoot
- Facial features help distinguish
 - Upslanting palpebral fissures
 - Long philtrum with thin upper lip
 - Short broad tipped nose
 - Micrognathia
 - Cleft palate
- May have other skeletal, cardiovascular, or genitourinary malformations

Conditions With Bilateral Symmetric Short Femurs

- **Trisomy 21**
 - Mild rhizomelic limb shortening
 - Minor marker for trisomy 21
 - Short humeral length more sensitive marker
- **Turner syndrome**
 - Mild rhizomelic limb shortening
 - Associated prominent cystic hygroma present
 - May have early onset symmetric fetal growth restriction (FGR)
- **Early onset FGR**
 - Most often symmetric growth restriction
 - Bilateral femurs < 5th percentile
 - Strong association with aneuploidy
 - Unlike asymmetric FGR, more often due to fetal etiology rather than maternal/placental
 - Lower birth weights and higher rates of small for gestational age fetuses
 - Isolated short femurs associated with low levels of pregnancy-associated plasma protein-A
- **Ethnic variation**
 - Often constitutional if symmetric
 - Parents usually of short stature
 - More often in Asian or Hispanic fetuses

PATHOLOGY

General Features

- Etiology
 - Associated with diabetic embryopathy
 - Exact etiology unknown
 - Seen with maternal drug exposures

- Specifically thalidomide
 - Vascular insult to developing embryo in 4th-8th weeks of gestation
 - Viral exposure
 - Trauma
- Genetics
 - Thought to be sporadic
- Associated abnormalities
 - Can have associated fibular hemimelia

Staging, Grading, & Classification

- Aitken classification (1969)
 - Class A
 - Femoral head present
 - Femur intact
 - Subtrochanteric thinning
 - Varus angulation common
 - Class B
 - Femoral head present
 - Moderate segment of proximal femur absent
 - No osseous connection between femoral head and shaft
 - Class C
 - Femoral head absent
 - Acetabulum dysplastic
 - Large segment of proximal femoral shaft absent
 - Class D
 - Entire proximal femur and acetabulum absent

Gross Pathologic & Surgical Features

- Varying degrees of proximal femoral dysplasia
 - Milder version has dysmorphic femoral head
 - Associated with subtrochanteric thinning and varus angulation
 - More severe anomaly has almost completely absent femur with hemipelvis aplasia
- Femoral head can be discontinuous from distal femur
 - Pseudoarthrosis may be present with varus angulation
 - Most often subtrochanteric
 - Distal femoral shaft has classic pencil-point appearance

CLINICAL ISSUES

Presentation

- Most common signs/symptoms
 - Can be missed in utero
 - Findings may be subtle
 - Only one femur routinely imaged for biometry and growth
 - Postnatal exam shows short thigh tapering toward knee
 - Hypoplastic thigh muscles
 - Characteristic hip position
 - Flexion
 - Abduction
 - External rotation
 - Ipsilateral knee can be unstable and dislocate

Demographics

- Epidemiology
 - Incidence of 1:50,000-200,000
- Unilateral in 90% of cases

Natural History & Prognosis

- Characterization with postnatal radiographs, hip ultrasound, and MR
 - Radiography will show typical osseous findings
 - Short femur
 - Abnormal femoral head (if ossified) and acetabulum
 - Coxa varum
 - Disconnected distal femur with pencil-point shape
 - Ultrasound useful to identify unossified femoral head
 - PFFD can be misdiagnosed as hip dysplasia if limb length discrepancy not detected
 - MR shows cartilaginous structures, proximal femur, and acetabulum
 - Can aid in early treatment planning
 - Visualizes anatomy of femoral head and acetabulum
 - Does not depend on ossification for evaluation
- Prognosis depends on severity of hypoplasia

Treatment

- Reconstruction of hip joint with femoral osteotomies may be possible in mild cases
- Limb lengthening techniques can be considered
- Hip and knee instability may limit options
- Severe cases may require amputation and prosthesis

DIAGNOSTIC CHECKLIST

Consider

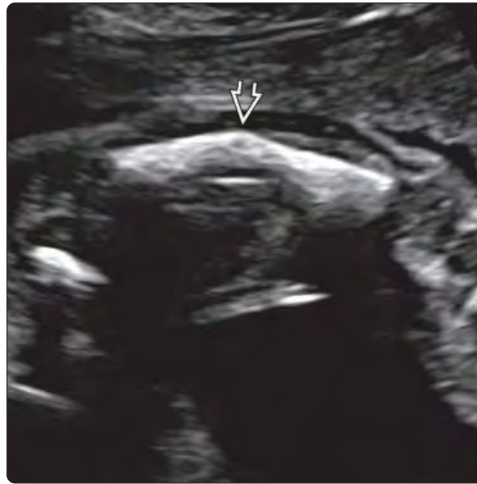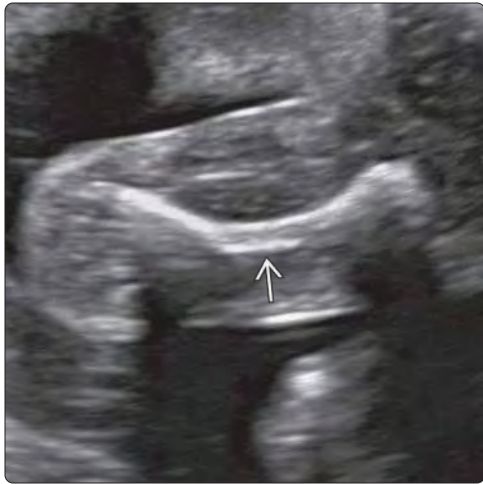- Diabetic embryopathy if history of maternal diabetes

Image Interpretation Pearls

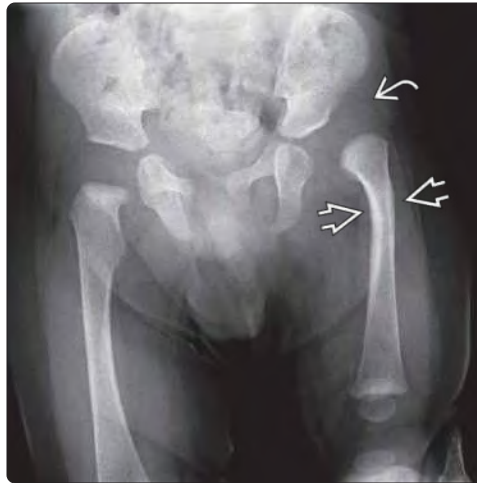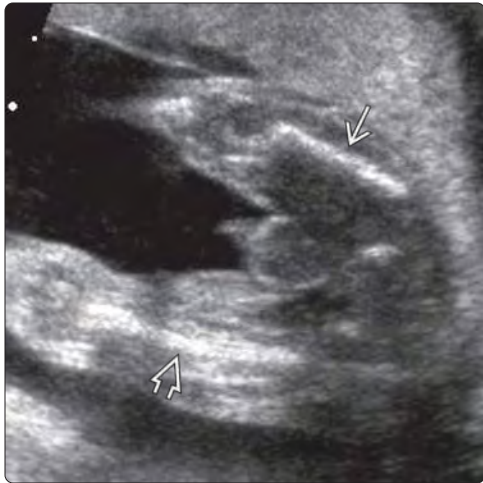
- If one femur appears short, measure other long bones to exclude global skeletal abnormality
- If femur is not exactly in plane when image obtained, can simulate mild shortening
 - Repeat measurement if shortening is mild
- Downside femur can appear bowed due to beam artifact
 - Reposition transducer to obtain another view

SELECTED REFERENCES

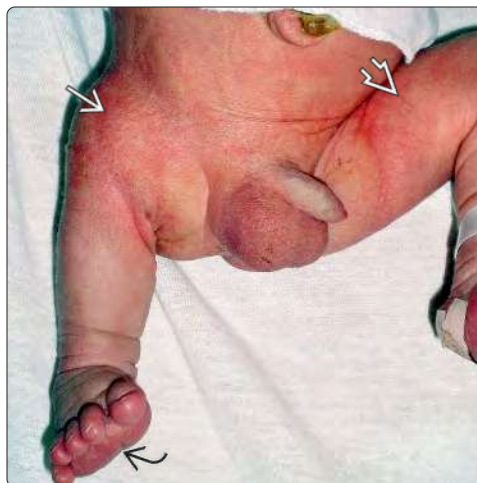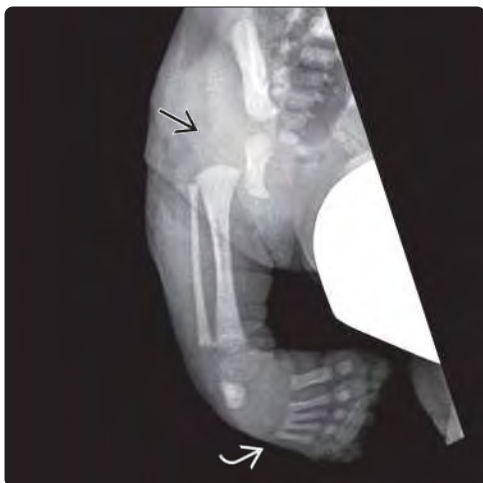1. Bedoya MA et al: Common patterns of congenital lower extremity shortening: diagnosis, classification, and follow-up. *Radiographics*. 35(4):1191-207, 2015
2. Ackman J et al: Long-term follow-up of Van Nes rotationplasty in patients with congenital proximal focal femoral deficiency. *Bone Joint J*. 95-B(2):192-8, 2013
3. Dođer E et al: Unilateral isolated proximal femoral focal deficiency. *Case Rep Obstet Gynecol*. 2013:637904, 2013
4. Lin TH et al: Prenatal diagnosis of proximal femoral focal deficiency: a case report and literature review. *Taiwan J Obstet Gynecol*. 52(2):267-9, 2013
5. Biko DM et al: Proximal focal femoral deficiency: evaluation by MR imaging. *Pediatr Radiol*. 42(1):50-6, 2012
6. Koenig JK et al: MR evaluation of femoral neck version and tibial torsion. *Pediatr Radiol*. 42(1):113-5, 2012
7. Mailath-Pokorny M et al: Prenatal diagnosis of unilateral proximal femoral focal deficiency at 19 weeks' gestation: case report and review of the literature. *Ultrasound Obstet Gynecol*. 38(5):594-7, 2011
8. Westberry DE et al: Proximal focal femoral deficiency (PFFD): management options and controversies. *Hip Int*. 19 Suppl 6:S18-25, 2009
9. Aitken GT. Proximal femoral focal deficiency-definition, classification, and management. In: *Proximal Femoral Focal Deficiency: A Congenital Anomaly*. Washington DC: National Academy of Sciences. 1-22, 1969



(Left) At 21 weeks, this right femur appeared bowed but was the downside femur when imaged. If the contralateral normal left femur was not compared, this could be mistaken for beam artifact. **(Right)** Repeat imaging of the right femur in the near field shows there is focal angulation of the femoral diaphysis, and the femur was short compared to the left. Findings are consistent with PFFD.



(Left) Second-trimester ultrasound shows the left femur is markedly shorter than the right. Note the prenatal ultrasound does not show angulation of the femur bone. **(Right)** The postnatal radiograph shows a short left femur with proximal mild varus angulation and subtrochanteric thinning. Closer look at the left hip also shows a shallow acetabulum and superolateral dislocation of the femoral head.



(Left) Postnatal radiograph in a case of prenatally diagnosed severe PFFD shows an absent right femur and clubfoot. PFFD can vary from quite subtle to complete absence of the femur, as seen in this case. **(Right)** Correlative clinical photograph shows the shorter upper right leg, and an inverted right foot.

KEY FACTS

TERMINOLOGY

- Shortening or absence of fibula [fibular hemimelia (FH)] or tibia [tibial hemimelia (TH)]

IMAGING

- Longitudinal deficiency of fibula or tibia
 - Ranges from mild deficiency to complete absence
- FH
 - Strong association with shortened &/or anteriorly bowed tibia
 - Also seen with ipsilateral valgus deformity and lateral foot abnormalities
 - May be seen with proximal focal femoral dysplasia
- TH
 - Can be seen with ipsilateral varus foot deformity and medial foot deficiency
 - Fibula most often normal in appearance
- 3D ultrasound can be useful to assess lower extremity positioning and contour

TOP DIFFERENTIAL DIAGNOSES

- Proximal focal femoral dysplasia, femur-fibula-ulna syndrome, femoral hypoplasia-unusual facies syndrome

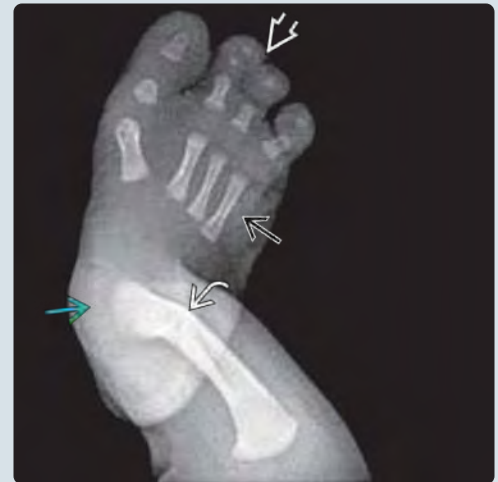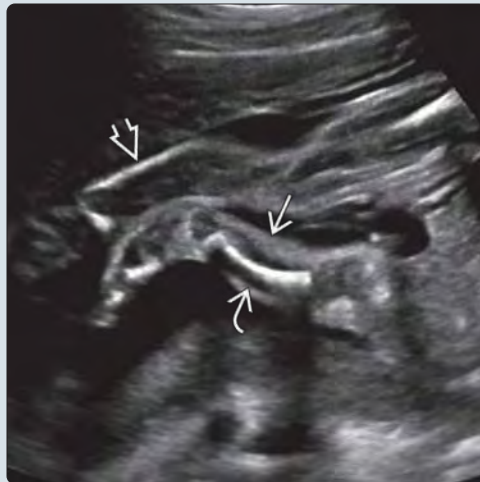CLINICAL ISSUES

- Both FH and TH are most often sporadic
- FH much more common than TH
 - Most common long bone agenesis
- Prognosis depends on extent of deficiency and associated abnormalities proximal and distal to long bone
- Postnatal radiographs warranted for complete characterization of defect
- Treatment options include limb lengthening procedures or amputation

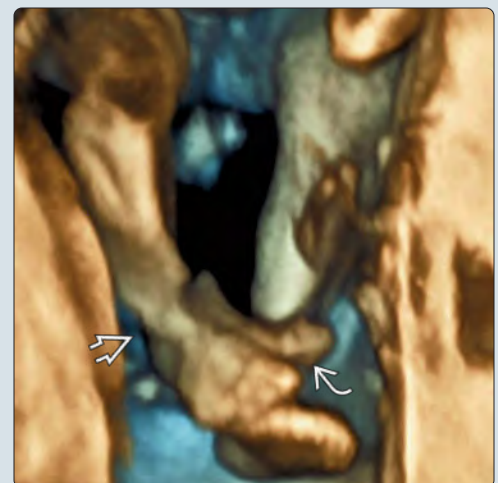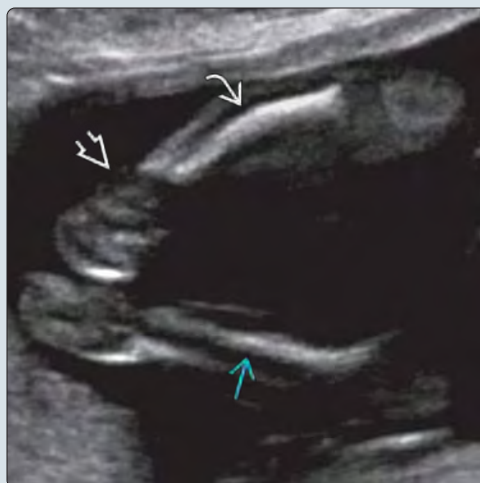
DIAGNOSTIC CHECKLIST

- Routinely compare right and left lower extremity lengths
- If 1 long bone short, measure others to exclude global skeletal dysplasia

(Left) Comparison of both lower extremities is essential. In this case, the left lower extremity is short compared to the right, with only the tibia present. The tibia is anteriorly bowed, a common finding with fibular hemimelia (FH). **(Right)** Postnatal film in the same patient with FH shows the fibula is completely absent. There is anterior bowing of the tibia with valgus angulation at the ankle. There are 4 metatarsals & 4 toes. Foot malformations can be seen with both FH & tibial hemimelia (TH).



(Left) At 21 weeks, the right tibia is shortened (2nd percentile) and bowed compared to the left. Note the mild varus angulation at the right ankle, which is often seen with TH. The right fibula was normal (not shown). **(Right)** 3D ultrasound of the same fetus shows the varus foot deformity. In addition, there is a medial foot anomaly; the great toe is abnormally large and abducted suggesting a bifid or duplicated toe. The medial foot is more often affected with TH.



TERMINOLOGY

Definitions

- Shortening or absence of fibula [fibular hemimelia (FH)] or tibia [tibial hemimelia (TH)]

IMAGING

General Features

- Best diagnostic clue
 - Longitudinal deficiency of fibula or tibia
- Morphology
 - Ranges from mild deficiency to complete absence of long bone

Ultrasonographic Findings

- **FH**
 - Deformed or shortened fibula with proximal remnant
 - May be completely absent
 - Normal ossification
 - FH strongly associated with shortened or anteriorly bowed tibia
 - Strong association with lateral foot and femoral abnormalities
 - May be seen in conjunction with proximal focal femoral dysplasia
 - Valgus deviation of foot
- **TH**
 - Deformed or shortened tibia with normal ossification
 - May be completely absent
 - Associated with ipsilateral varus foot deformity and medial foot deficiency
 - Fibula most often normal in appearance
 - May be difficult to know if fibula or tibia is absent if only 1 long bone in lower extremity
 - FH is more common
 - **Assess for varus vs. valgus foot deformity**
 - Valgus (outward angulation) → FH
 - Varus (inward angulation) → TH

Imaging Recommendations

- Best imaging tool
 - Prenatal evaluation with sonography is sufficient
 - 3D ultrasound can be useful to assess lower extremity positioning and contour
- Protocol advice
 - Measure long bones to exclude skeletal dysplasia
 - Compare left and right extremities

DIFFERENTIAL DIAGNOSIS

Proximal Focal Femoral Dysplasia

- Short, angulated femur with normal mineralization
- May be associated with FH

Femur-Fibula-Ulna Syndrome

- Femoral, fibular, and ulnar hypoplasia/aplasia

Femoral Hypoplasia-Unusual Facies Syndrome

- Characteristic facial features with femoral hypoplasia
- Strongly associated with diabetic embryopathy

PATHOLOGY

General Features

- Varying absence of long bone ossification
 - Usually replaced with fibrous or fibrocartilaginous material

Staging, Grading, & Classification

- Various classification systems exist for FH and TH
 - FH: Achtermann and Kalamchi, Coventry and Johnson, Stanitski
 - TH: Clement, Jones

CLINICAL ISSUES

Presentation

- Most common signs/symptoms
 - Incidentally found on prenatal ultrasound

Demographics

- Epidemiology
 - FH (rare) much more common than TH (very rare)
 - Most common congenital anomaly of fibula
 - Most common long bone agenesis
- FH
 - 60-80% unilateral
 - Right > left
 - M:F ratio 2:1
- Both FH and TH are most often sporadic
 - May be part of more complex syndromes

Natural History & Prognosis

- Prognosis depends on extent of deficiency and associated abnormalities proximal and distal to long bone
 - Femoral malformations
 - Malpositioning at knee/ankle/foot

Treatment

- Postnatal radiographs warranted for complete characterization of defect
 - May over- or underestimate true extent of malformation due to lack of ossification
- Postnatal MR can help detect underlying nonossified fibrous or fibrocartilaginous portions
- Surgical treatment after birth
 - Limb lengthening procedure
 - Amputation with potential prosthesis

DIAGNOSTIC CHECKLIST

Consider

- 3D ultrasound for evaluation of leg positioning and foot

Image Interpretation Pearls

- Routinely compare right and left lower extremity lengths
- If 1 long bone short, measure others to exclude global skeletal dysplasia

SELECTED REFERENCES

1. Bedoya MA et al: Common patterns of congenital lower extremity shortening: diagnosis, classification, and follow-up. *Radiographics*. 35(4):1191-207, 2015
2. Bergère A et al: Imaging features of lower limb malformations above the foot. *Diagn Interv Imaging*. 96(9):901-14, 2015

DIFFERENTIAL DIAGNOSIS**Common**

- Idiopathic
- Chromosome Abnormality
 - Trisomy 21
 - Turner Syndrome
- Fetal Growth Restriction

Less Common

- Heterozygous Achondroplasia
- Osteogenesis Imperfecta
- Proximal Focal Femoral Dysplasia

ESSENTIAL INFORMATION**Key Differential Diagnosis Issues**

- Is short femur or humerus present bilaterally vs. isolated asymmetric?
 - Measure femur and humerus on both sides to compare
 - Consider measuring all extremity bones if femur/humerus is dramatically short
 - More likely skeletal dysplasia
 - If isolated to 1 long bone, could be focal defect of that limb
 - Check morphology of affected extremity
- Assess morphology of osseous structures
 - Are long bones straight vs. bent?
 - Bent bones suggests in utero fractures &/or abnormal bone density
 - Skull shape
 - Abnormal can aid in assessment of skeletal dysplasia
 - Bone density
 - Can be difficult to assess in utero until later in gestation
 - Poor ossification of skull can be useful clue for abnormal bone density
- Many syndromes are associated with mildly short long bones
 - Ranges from chromosomal abnormalities to multisystem disorders

Helpful Clues for Common Diagnoses

- **Idiopathic**
 - Often constitutional if symmetric and parents are short
 - May be seen in fetuses of Asian or Hispanic descent
 - Shorter average femur and humerus than white or African American pregnancies
 - Biologic inherent variation has most impact in 3rd trimester
- **Trisomy 21**
 - Minor marker for trisomy 21 (T21)
 - Short humerus length (HL) more sensitive than short femur length (FL)
 - FL and HL compared to biparietal diameter (BPD)
 - Expected FL = $-9.3 + 0.90$ (BPD)
 - Expected HL = $-7.9 + 0.84$ (BPD)
 - Abnormal → measured:expected FL ≤ 0.91 or HL ≤ 0.90
 - Look for other signs of T21
 - ≥ 1 minor markers seen in 50-70% of T21 fetuses

- Major anomalies in 25-30% (cardiac, duodenal atresia, etc.)
- Correlate with sequential screening or maternal serum quadruple screen
 - Serum screen risk for T21 reported for both
 - Nuchal translucency in 1st trimester increased in T21
 - Nasal bone may be absent
 - T21 detection rates $> 90\%$ reported
- **Turner Syndrome**
 - Mild rhizomelia present at time of 2nd-trimester screening
 - Nuchal cystic hygroma is predominant obvious finding
 - Usually large fluid collection in lateral and posterior neck
 - Can have multiple thin septations
 - 60% of fetuses with cystic hygromas have Turner syndrome
 - Can present with nonimmune hydrops
 - Excess fetal fluid collection in 2 separate areas
 - ◻ Skin (anasarca)
 - ◻ Chest (pleural effusion)
 - ◻ Abdomen (ascites)
 - Associated with cardiovascular anomalies (20-40%)
 - Coarctation of aorta
 - ◻ Narrow aortic arch with focal turbulence at narrowed area on color Doppler ultrasound
 - ◻ Left-to-right shunt through foramen ovale
 - Hypoplastic left heart
 - ◻ Small or nonexistent left ventricle, which is hypocontractile and hypertrophic
 - ◻ Dilated, hypertrophied right ventricle
 - Genitourinary findings may be present
 - Horseshoe kidney
 - ◻ Kidneys fused across midline inferiorly
 - ◻ Isthmus of renal tissue or fibrous connection anterior to aorta
 - May have early symmetric growth restriction
- **Fetal Growth Restriction**
 - 1st assess if dating is correct
 - If incorrect, fetal biometry measurements may be falsely abnormal
 - Estimated fetal weight < 10 th percentile for gestational age
 - Abdominal circumference (AC) < 5 -10th percentile
 - ◻ May be 1st abnormal growth parameter, with poor interval growth
 - Other growth parameters may become abnormal with time if symmetric fetal growth restriction (FGR)
 - Symmetric FGR has strong association with aneuploidy
 - Uniformly small fetal biometry for gestational age
 - Often presents in 2nd trimester
 - Search carefully for anatomic abnormalities to correlate
 - ◻ Chromosomal associations: Triploidy, trisomy 18, trisomy 13
 - ◻ Anomalies: Single umbilical artery, gastroschisis, cardiovascular anomalies, velamentous cord insertion
 - Asymmetric FGR present when AC small compared to head circumference (head sparing)

- Most often from uteroplacental insufficiency
- Oligohydramnios may be present
 - Especially in cases of trisomy 13, 18
- Use pulsed Doppler to assess for umbilical artery flow
 - Increased placental resistance leads to decreased diastolic flow

Helpful Clues for Less Common Diagnoses

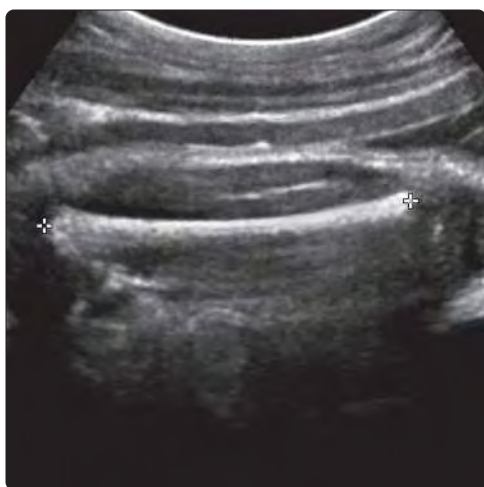- **Heterozygous Achondroplasia**
 - Long bone shortening noted in late 2nd or 3rd trimester
 - Early scan may be normal with progressively discrepant bone growth
 - Usually manifests between 21-27 weeks
 - Humerus affected more severely than femur
 - Normal ossification and morphology
 - No fractures or bowing
 - Look for other signs to make diagnosis
 - Frontal bossing
 - Depressed nasal bridge with upturned nasal tip
 - Macrocephaly
 - Thoracolumbar kyphosis
 - Trident hands
 - Polyhydramnios may develop in 3rd trimester
 - Usually mild to moderate
 - Autosomal dominant
 - Check parental chromosomes to assess for recurrence risk
 - 80% are new mutations
 - Homozygous achondroplasia is lethal with early severe findings
- **Osteogenesis Imperfecta**
 - Bent bones due to in utero fractures
 - Measure all long bones in suspected fetus
 - Severe shortening in osteogenesis imperfecta type II
 - Less severe types have milder shortened
 - Decreased mineralization
 - Skull can be manually deformed from transducer pressure
 - Small chest circumference with "beading"
 - Due to multiple rib fractures

- Genetic counseling indicated for recurrence risk
 - Most mutations autosomal dominant
- **Proximal Focal Femoral Dysplasia**
 - Consider if focal isolated defect of proximal femur(s)
 - Most commonly unilateral (90%)
 - Affected femur may have acute varus angulation due to discontinuity of proximal femur
 - Femoral head can be absent in severe cases
 - Hemipelvis usually affected
 - Ranging from shallow acetabulum → hemipelvis hypoplasia
 - Occasionally seen with fibular hypoplasia/aplasia
 - Associated with diabetic embryopathy in setting of femoral-facial syndrome
 - Check for other anomalies seen with maternal diabetes
 - Caudal regression, cardiac anomalies, brain anomalies, etc.
 - Depending on severity of defect and postnatal clinical follow-up, can have excellent prognosis with correction

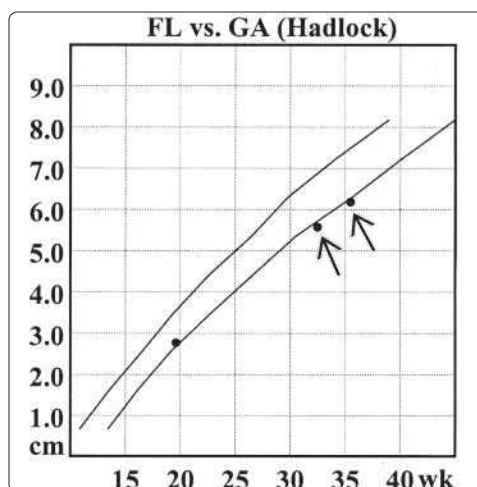
Other Essential Information

- If femur/humerus is not exactly in scan plane during measurement, can easily simulate mild shortening
 - Measure upside femur/humerus for most accurate length
- If one femur is short, measure contralateral side to assess whether finding is bilateral
 - If unilateral, consider proximal focal femoral dysplasia
- If both femurs and humeri are short, consider measuring all long bones
 - Assess for skeletal dysplasia
 - Look for other signs of T21

Idiopathic



Idiopathic



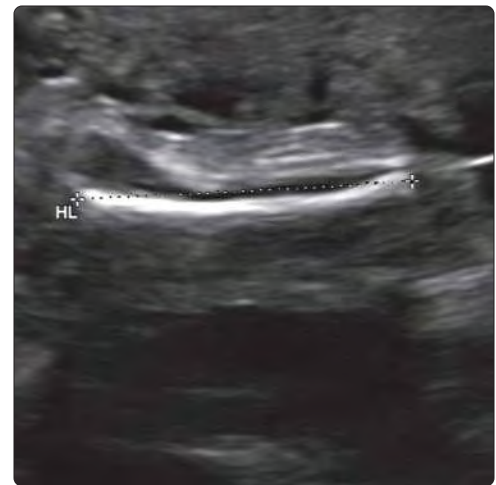(Left) In the 3rd trimester, the femur length (FL) measured < 5th percentile; however, the fetus was normally grown and the femur was morphologically normal. (Right) Growth chart plotting FL against gestational age (GA) in the same fetus shows the mildly short femur. Note the difference is more pronounced in the 3rd trimester [B], which is usually the case. This is most often constitutional and you should check the stature of the parents.

Trisomy 21

(Left) In this fetus presenting late to care, the growth parameters at 28 2/7 weeks are suggestive of rhizomelic limb shortening [E]. (Right) Rhizomelic limb shortening is seen with trisomy 21, and short humeral lengths (HLs) are a more sensitive marker than FLs. The HL is considered short if the measured:expected ratio is ≤ 0.90 when compared to the BPD. In this case, the HL measured:expected ratio was abnormal at 0.84. The fetus was confirmed to have trisomy 21.

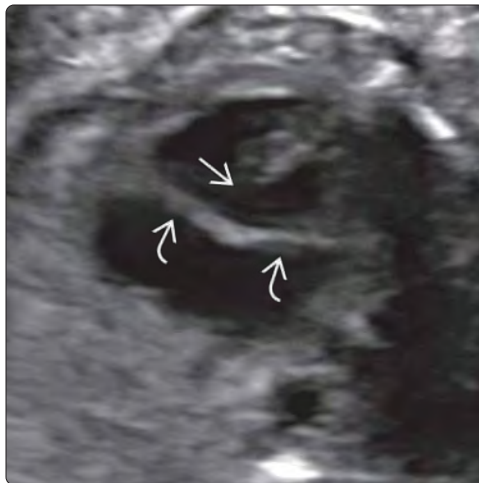
% for 28w2d	
BPD	24%
HC	27%
AC	23%
FL	9% ←
HL	<05% ←

Trisomy 21

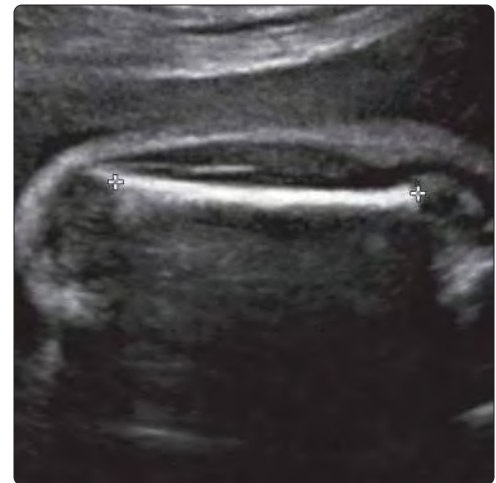

Trisomy 21

(Left) This fetus shows the typical appearance of an atrioventricular septal defect (AVSD), with a single AV valve plane [E] and a ventricular septal defect (VSD) [E]. Trisomy 21 is present in ~ 40% of AVSD cases and should prompt a careful search for other associated findings. (Right) In the same fetus, the femur measures < 5th percentile (calipers), with an abnormal measured:expected FL. Amniocentesis was offered and confirmed trisomy 21.

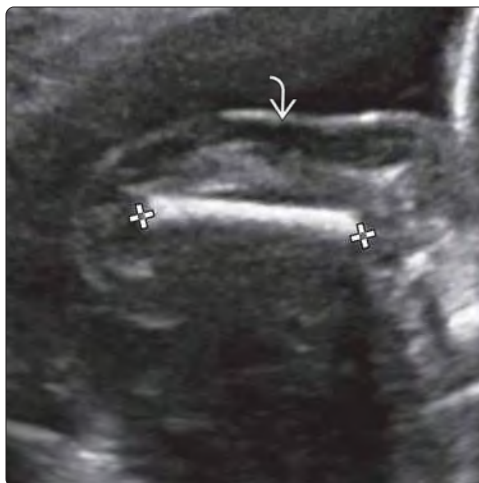


Trisomy 21

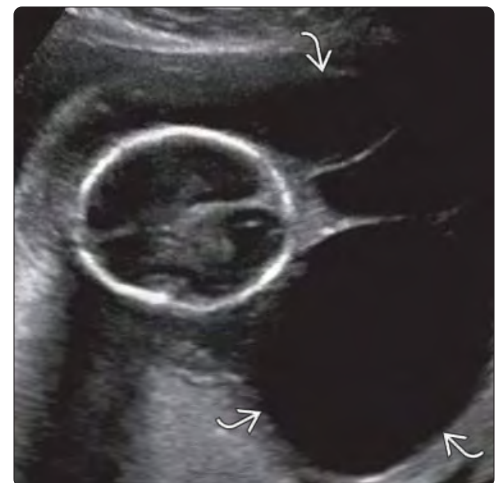


Turner Syndrome

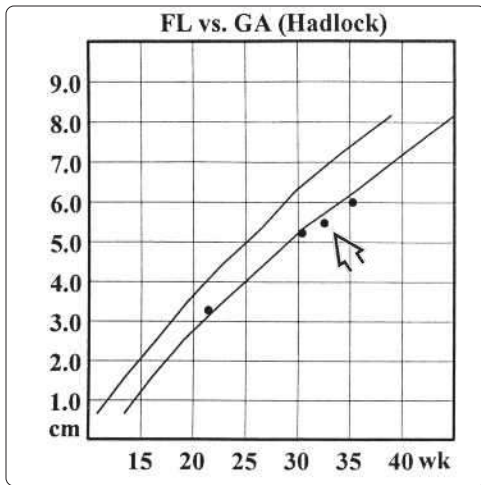
(Left) In this fetus, the FL (calipers) lagged by 2 weeks at 20-weeks gestation. Note the hypoechoic skin edema as well [E]. (Right) In the same fetus, a massive cystic hygroma is present at the posterior and lateral neck [E]. The combination of rhizomelic limb shortening and large cystic hygroma is highly suggestive of Turner syndrome.



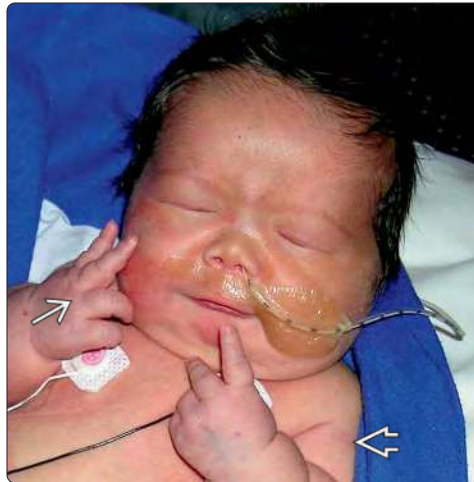Turner Syndrome



Fetal Growth Restriction

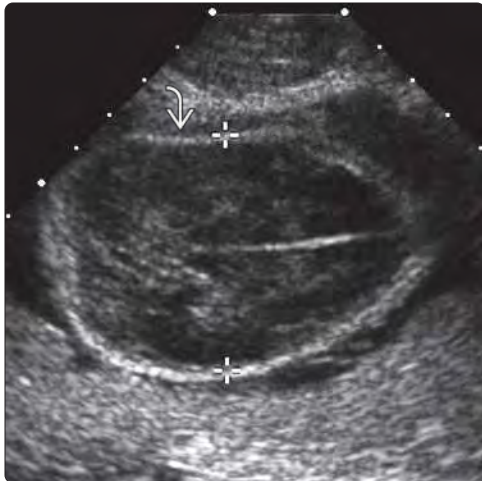


Heterozygous Achondroplasia

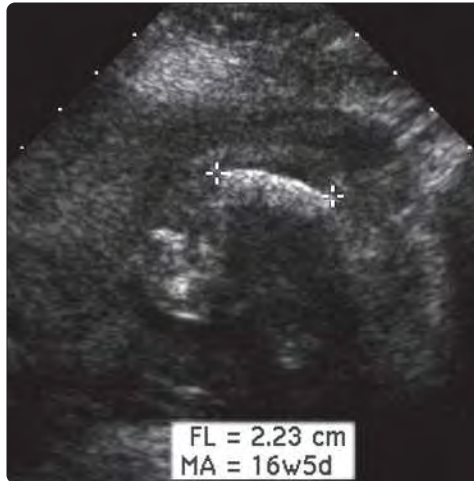


(Left) When assessing FL, comparison to the other fetal measurements is useful. In this chart, the FL was in the low normal range at the anatomy scan but has fallen below the 5th percentile in the setting of symmetric fetal growth restriction in the 3rd trimester. (Right) Clinical photograph shows typical facial findings of achondroplasia with a flat midface, depressed nasal bridge, and upturned nasal tip. Note the trident hand and short humerus. In utero the femur measured 24 weeks at 31-weeks gestation.

Osteogenesis Imperfecta

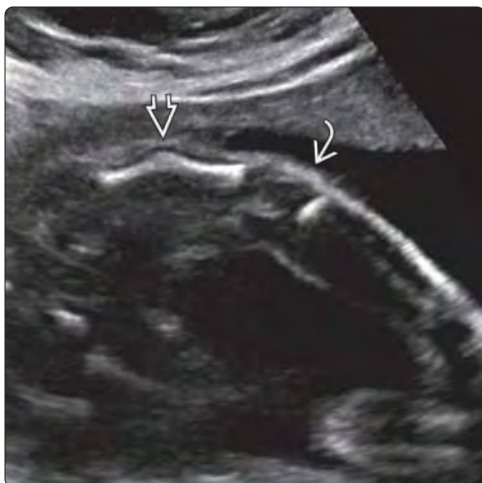

Osteogenesis Imperfecta

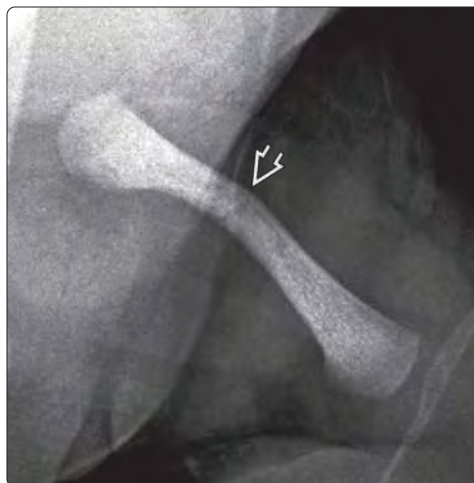


(Left) In this fetus, the skull is poorly mineralized and deformed by transducer pressure. The near field structures of the brain are unusually well seen due to the lack of reverberation. (Right) The femur (calipers) is short for GA and poorly mineralized, therefore appearing thickened. Careful imaging of the ribs also identified a beaded appearance suggestive of fractures. The appearance is consistent with osteogenesis imperfecta.

Proximal Focal Femoral Dysplasia



Proximal Focal Femoral Dysplasia



(Left) In this 23-week fetus, there is shortening and focal angulation of the left femur with varus angulation at the knee, as typically seen with proximal focal femoral dysplasia (PFFD). (Right) Postnatal radiograph of the same patient confirms the PFFD with varus angulation at the proximal diaphysis. This is an important diagnosis to consider when shortening is unilateral.

DIFFERENTIAL DIAGNOSIS

Common

- Thanatophoric Dysplasia
- Osteogenesis Imperfecta
- Diabetic Embryopathy

Less Common

- Campomelic Dysplasia
- Abnormal Joint Angulation

Rare but Important

- Kyphomelic Dysplasia
- Hypophosphatasia
- Fetal Trauma

ESSENTIAL INFORMATION

Key Differential Diagnosis Issues

- Are there fractures?
- Is ossification normal?
- Is angulation midshaft or at joint?
- Is distal limb normal?
- One limb vs. more than one limb affected?
- Are both segments of limb affected?
- Are abnormalities limited to long bones or are other skeletal elements affected?
- Are any segments missing or hypoplastic?
- Are there other nonskeletal structural anomalies?

Helpful Clues for Common Diagnoses

- **Thanatophoric Dysplasia**
 - Micromelia
 - Normal ossification without fractures
 - Macrocephaly with frontal bossing, midface hypoplasia
 - Short ribs with bell-shaped thorax
 - Platyspondyly with lumbar kyphosis
 - Type I: Telephone receiver femur, normal-shaped calvarium
 - Type II: Femora less curved, cloverleaf-shaped skull (Kleeblattschädel)
 - Polyhydramnios often severe in 2nd trimester
 - Other anomalies rare
 - Lethal within first few hours to days of life
- **Osteogenesis Imperfecta**
 - Fractures are prominent feature
 - Decreased ossification of all bones
 - Type II (perinatal lethal) with extensive in utero fractures, limb deformities
 - "Beaded" ribs due to healing fractures
 - Deformable skull with normal pressure from US transducer
 - Nonlethal types associated with less severe limb shortening, fewer in utero fractures
 - Progressive deformation, shortening may occur in type III/IV
 - Type III/IV may present with isolated bent femur in utero
 - Size of chest correlated with risk of lethal outcome
- **Diabetic Embryopathy**
 - Uncontrolled maternal diabetes most prevalent human teratogen

- Abnormal femur common
 - Usually bilateral, but often discordant
 - Short, angulated, or curved femur
- Associated tibia-fibula abnormality
- Preaxial polydactyly
- Other structural defects common in poorly controlled diabetes
 - Cardiac: VSD most common
 - Others include transposition of great arteries, aortic stenosis, truncus arteriosus, double outlet right ventricle, hypertrophic cardiomyopathy
 - Central nervous system: Anencephaly, holoprosencephaly, spina bifida
 - Anorectal malformation

Helpful Clues for Less Common Diagnoses

- **Campomelic Dysplasia**
 - Severe angulation of femora, tibiae, fibulae
 - Anterolateral bowing especially common
 - Scapula absent or hypoplastic
 - XY sex reversal (male to female) or ambiguity
 - Genotypic males appear phenotypically female
 - Normal ossification
 - Bell-shaped chest
 - Kyphoscoliosis
 - 1st-trimester cystic hygroma or increased nuchal translucency
 - Characteristic skin dimpling over area of angulation, especially pretibial
 - Autosomal dominant with mutations in *SOX9*
- **Abnormal Joint Angulation**
 - Fixed vs. movable joint
 - Normal distal extremity associated with dislocated joint
 - Knees, hips most commonly affected
 - Genu recurvatum
 - Movement at joint often observed in utero despite dislocation
 - May be unilateral or bilateral
 - May be associated with fetal malpresentation
 - Prolonged dislocation may result in dysplastic joint
 - Abnormal distal extremity often associated with abnormal joint or proximal bone
 - Joint usually without spontaneous movement
 - Wrist most commonly affected, but ankle also possible
 - Angle of deviation predicts which bone is hypo- or aplastic
 - Angulation is toward hypoplastic element
 - Radial deviation associated with hypoplasia or aplasia of radius and thumb
 - Radial ray defects
 - Ulnar deviation less common; associated with ulnar hypoplasia
 - Tibial or fibular hypoplasia or aplasia associated with fixed angulation of ankle toward hypoplastic side
 - Tibial or fibular hemimelia
 - Associated oligodactyly common; same side as missing or hypoplastic bone

Helpful Clues for Rare Diagnoses

- **Kyphomelic Dysplasia**

- Disproportionate short stature
- Short, narrow chest
- Angulation or bowing of long bones
- Rhizomesomelic shortening of long bones; less severe
- Normal ossification
- Flared, irregular metaphyses
- Improvement of bone findings with age
- Normal development
- **Hypophosphatasia**
 - Multiple subtypes including perinatal lethal, infantile, childhood, and late onset (adult)
 - Later onset, less severe clinical course
 - Undermineralization of calvarium results in brain being seen "too well" on US
 - Soft skull bones lead to progressive deformation of calvarium over time
 - Perinatal lethal type with prominent midtrimester US findings of severe undermineralization and micromelia of all long bones and calvarium
 - In general, long bones thin and bowed with absent posterior shadowing

- Spurs often seen along midshaft of long bones
- Early onset loss of deciduous teeth often clue about childhood or later onset types
- **Fetal Trauma**
 - Isolated fractures due to fetal trauma rare in absence of severe maternal trauma

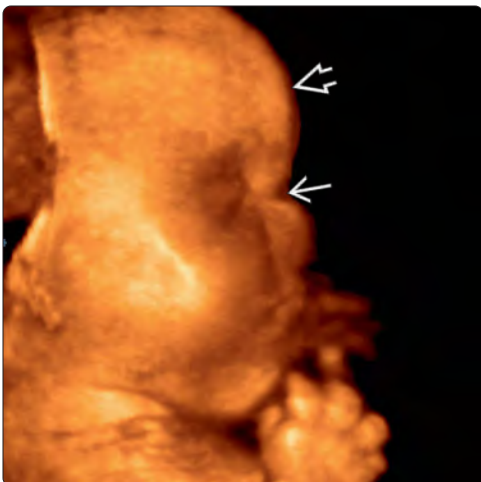Other Essential Information

- Distinguish between angulated bones and angulated joints when evaluating fetus
- Curvature of multiple bones predicts generalized osteochondrodystrophy
 - Severity of associated limb length shortening and chest size will assist in prediction of lethal vs. nonlethal skeletal dysplasia

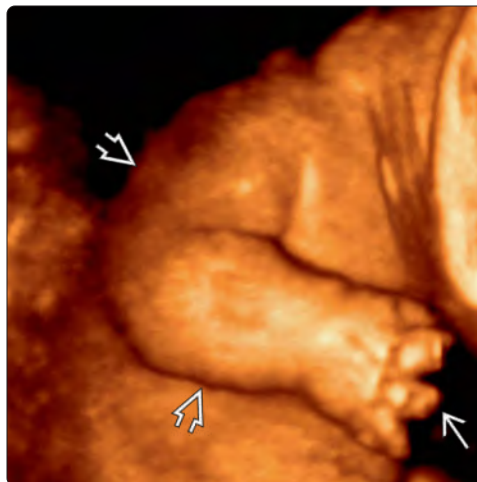
Alternative Differential Approaches

- Presence of fractures of major importance
 - Severity and number of in utero fractures may help distinguish lethal vs. nonlethal disorder
 - Rib fractures without long bone fractures seen in type IA achondrogenesis

Thanatophoric Dysplasia

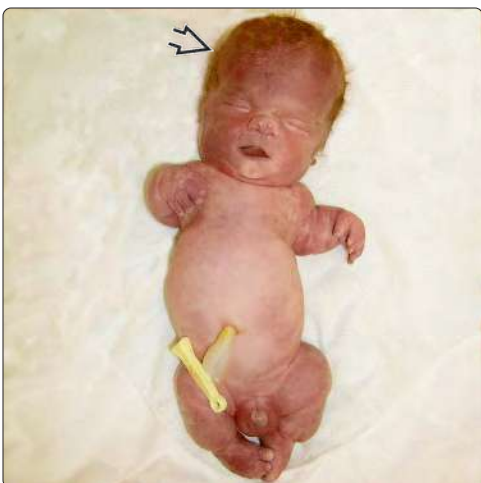

Thanatophoric Dysplasia

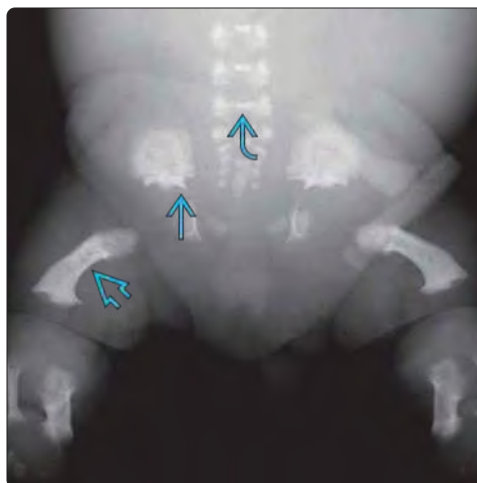

(Left) 3D US shows a 3rd-trimester fetus with known type I thanatophoric dysplasia. By this gestation, polyhydramnios, often severe, is invariably present. The head is macrocephalic and significant frontal bossing is usually apparent. Note also the depressed nasal root with a short nasal tip. (Right) In this 3D image of the same fetus, note the micromelia and the so-called trident hand.

Thanatophoric Dysplasia



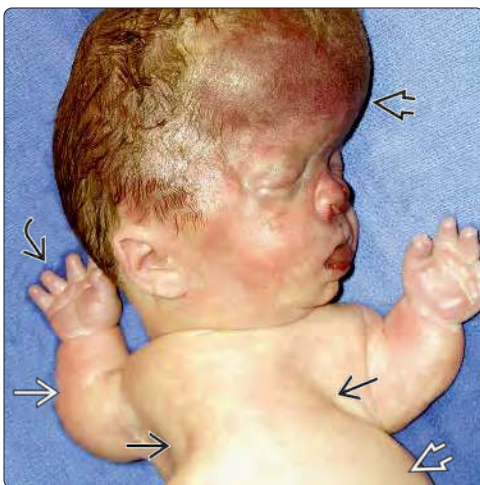
Thanatophoric Dysplasia



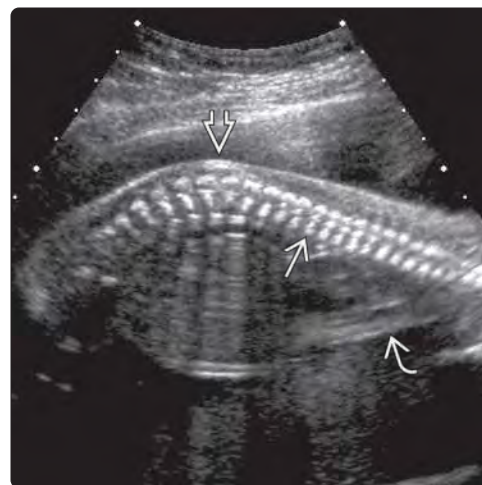
(Left) Image shows term stillborn infant with type I thanatophoric dysplasia. The tiny chest and disproportionately large head and long trunk are readily apparent. The head is macrocephalic but normally shaped in type I. Rhizomesomelic shortening with curved femora is typical. Severe micromelia can be seen. (Right) AP radiograph shows short, curved femora typical of type I thanatophoric dysplasia. Note also the spicules on the inferior iliac wings and platyspondyly involving the lumbar spine.

Thanatophoric Dysplasia

(Left) Stillborn infant with typical phenotypic features seen in type II thanatophoric dysplasia. The calvarium is abnormally shaped with a cloverleaf appearance (kleeblattschädel), often with extreme frontal prominence. Micromelia is noted as well as the extremely small thorax, especially when compared with the much larger abdomen. The trident hand is also seen. (Right) Sagittal US shows lumbar kyphosis and platyspondyly in a fetus with thanatophoric dysplasia. Note the small chest.

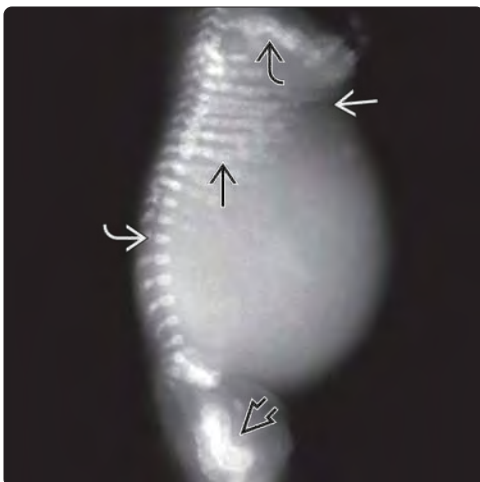

Thanatophoric Dysplasia

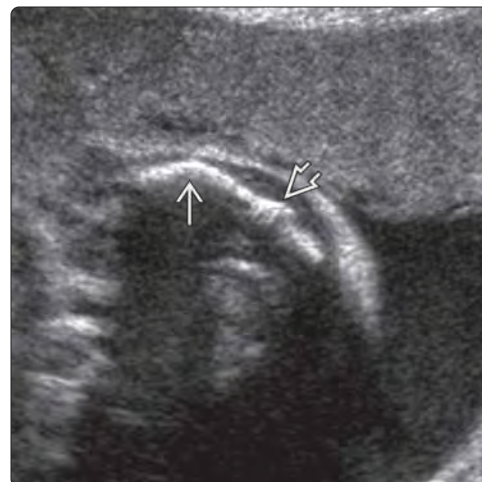


Osteogenesis Imperfecta

(Left) Sagittal radiograph shows beaded appearance of the ribs due to multiple healing fractures, typical of perinatal lethal osteogenesis imperfecta (OI). Irregular curvature of the humerus and femur is also due to multiple fractures. The long bones in this type of OI often have a crumpled appearance due to multiple fractures. Note also the small chest and platyspondyly. (Right) US shows a curved femur with callus formation due to a healed fracture in a fetus with type IV OI.

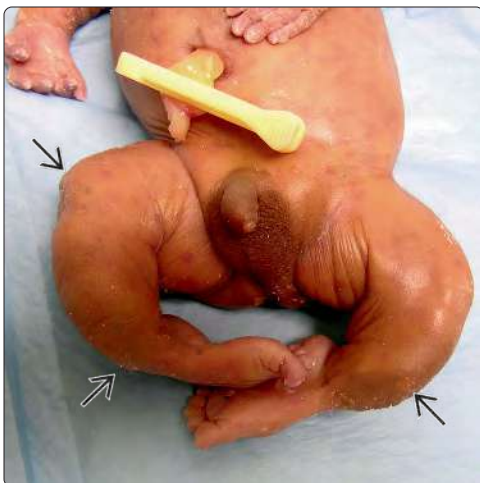


Osteogenesis Imperfecta

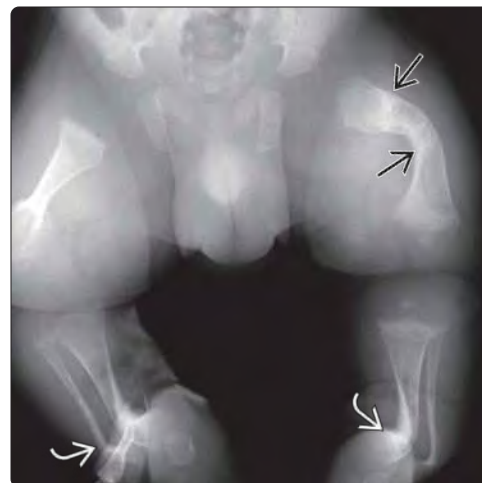

Osteogenesis Imperfecta

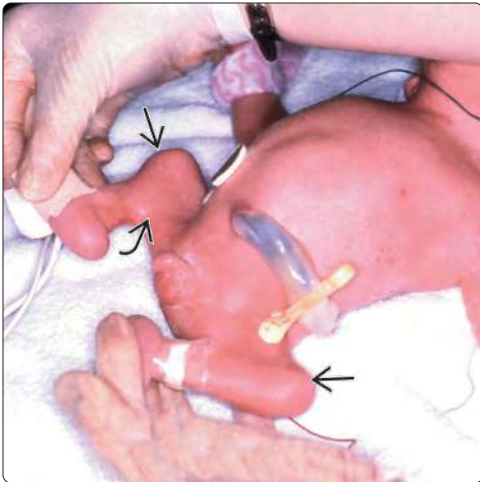(Left) Clinical photograph shows typical appearance of the lower extremities in perinatal lethal OI type II. The limbs are quite short and the pseudoarthroses are due to multiple fractures in utero. (Right) Radiograph of a newborn with type IV OI shows that the long bones appear mildly lucent due to decreased ossification. Note the asymmetry of the abnormalities. One femur is curved with sclerotic changes due to healed fractures. Both tibiae and fibulae are bowed distally.



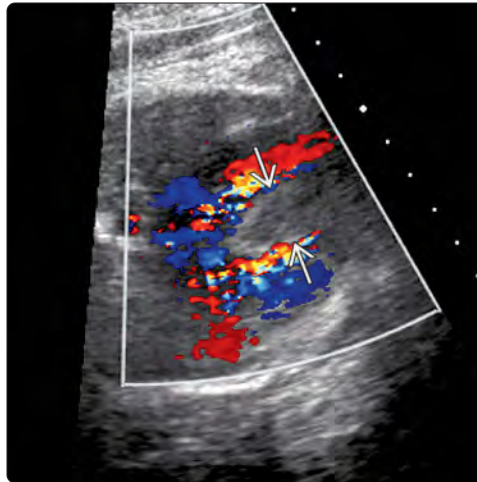
Osteogenesis Imperfecta



Diabetic Embryopathy

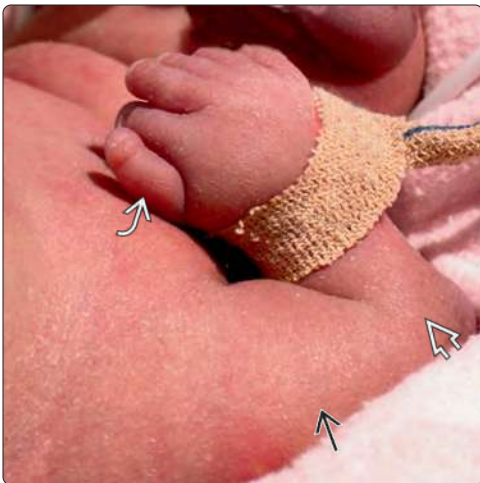

Diabetic Embryopathy

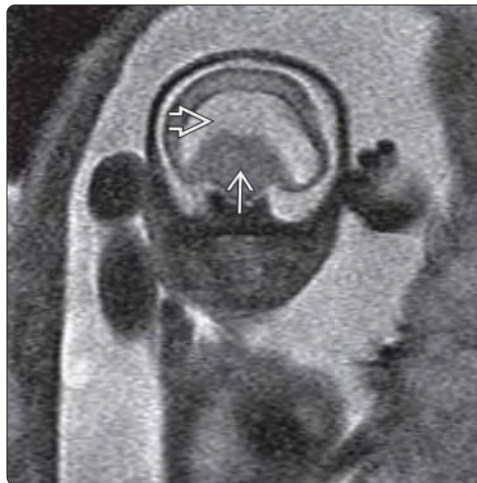

(Left) This newborn has diabetic embryopathy-related caudal regression due to uncontrolled maternal diabetes. Note the fixed posture of the short lower extremities and the popliteal pterygia due to lack of joint movement in utero. The spine ended in the midlumbar region. The infant died after a few days of life. (Right) US at 33-weeks gestation illustrates a fetal cardiac complication of uncontrolled diabetes in pregnancy. Note the thick interventricular septum due to cardiomyopathy.

Diabetic Embryopathy

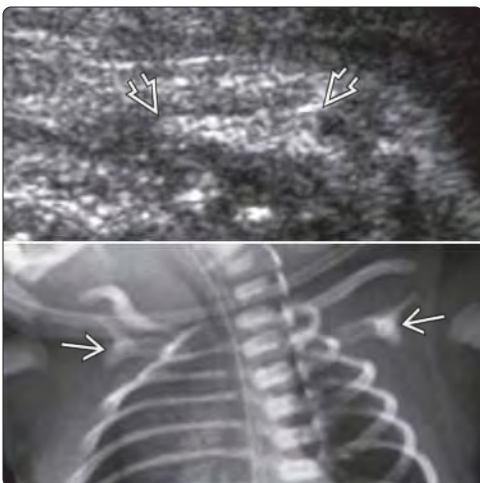


Diabetic Embryopathy

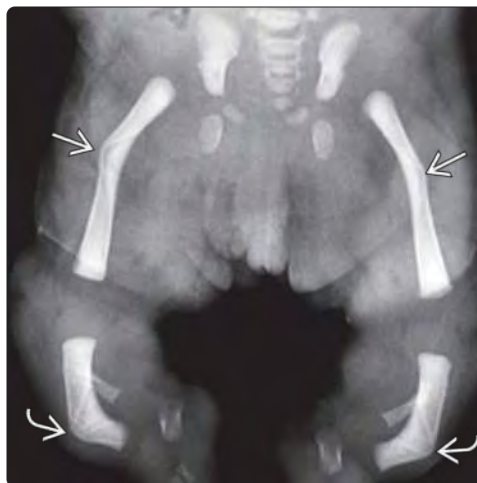


(Left) Clinical photograph shows severe lower extremity anomalies in this preterm infant of a poorly controlled diabetic. Femoral hypoplasia with absent tibia and fibula, abnormal angulation of the "ankle", and preaxial polydactyly are present. (Right) Coronal T2WI MR shows a monoventricle and fused thalami characteristic of alobar holoprosencephaly in a fetus of a mother with poorly controlled diabetes. The anomalies seen in diabetic embryopathy usually affect multiple organ systems.

Campomelic Dysplasia



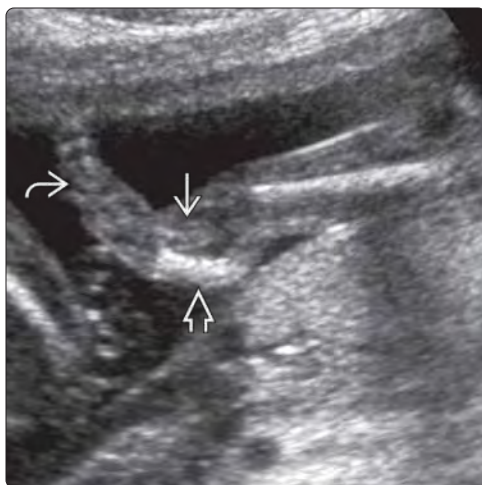
Campomelic Dysplasia



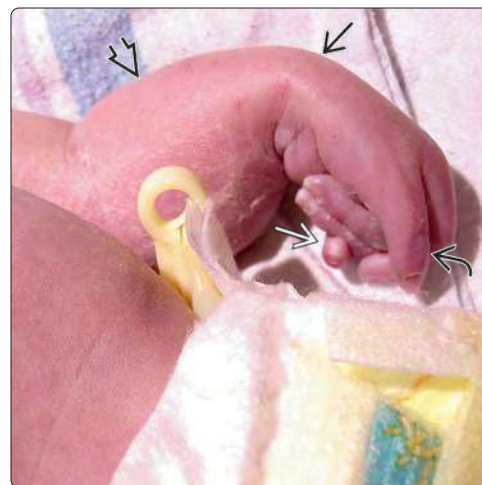(Left) The scapulae are invariably absent or hypoplastic in campomelic dysplasia. A longitudinal US shows a very hypoplastic scapula. The radiograph (different case) shows the scapular spines are present, but the blades are completely missing. (Right) Radiograph illustrates the other most common feature of campomelic dysplasia. The femora are mildly bowed and there is anterior angulation of the tibiae. A pretibial skin dimple is usually seen in the infant.

Abnormal Joint Angulation

(Left) US shows a fetus with absent ulna, hypoplastic radius, fixed ulnar deviation of the wrist, and abnormal hand with oligodactyly. The defect was bilateral and limited to the upper extremities. (Right) Radial ray defect shows evidence of absent radius. Note the radially deviated wrist and clenched and overlapping fingers. The thumb is hypoplastic with a hypoplastic nail. When evaluated, absent creases were also noted, due to decreased fetal movement of the hand in utero.

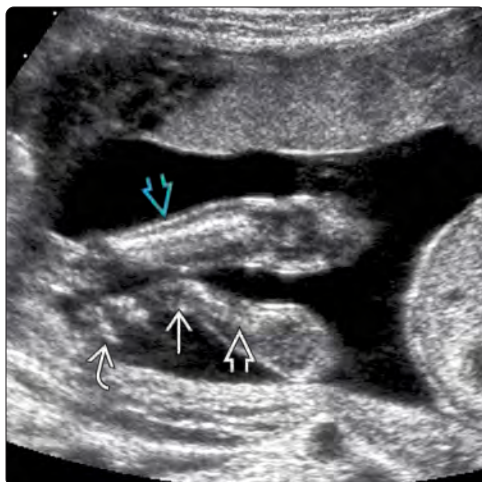


Abnormal Joint Angulation

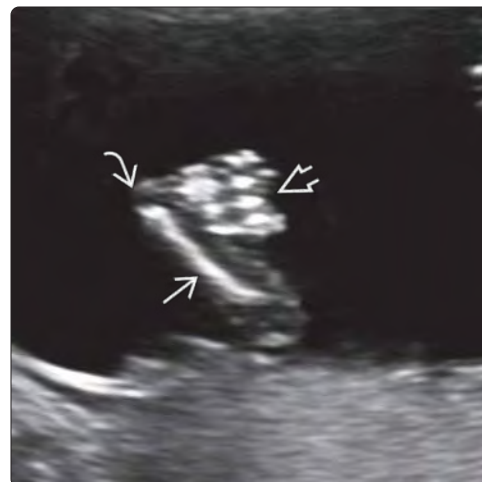


Abnormal Joint Angulation

(Left) Coronal US shows unilateral fibular hemimelia with a fixed laterally deviated ankle joint. The tibia is short and dysplastic, while the fibula appears to be absent. Oligodactyly of the foot is seen. The ankle appeared fixed in position, and the deviation is characteristically toward the side of the hypoplastic or missing bone. The contralateral leg is often normal. (Right) US at 14 weeks shows a radial ray defect with absent radius, radial deviation of the wrist, and only 4 digits.

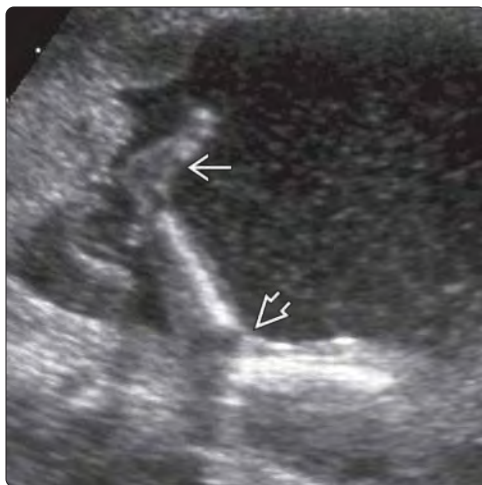


Abnormal Joint Angulation

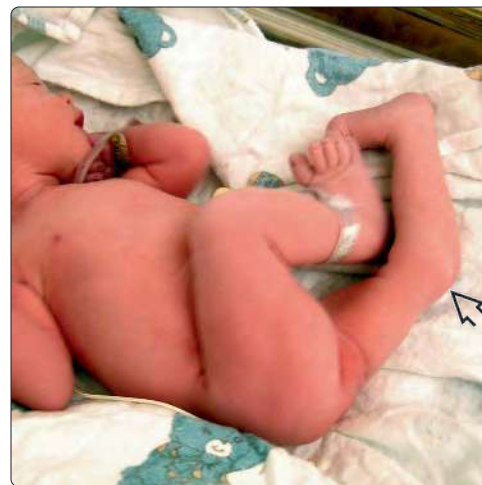

Abnormal Joint Angulation

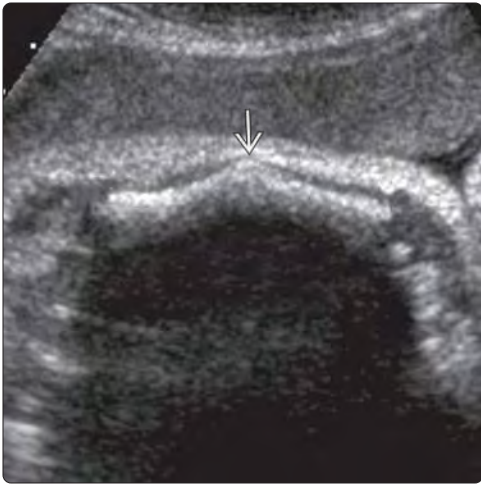(Left) Sagittal US shows a congenitally dislocated knee with hyperextension of the lower leg, known as genu recurvatum. First noted at the patient's 18-week US, the fetal leg, including the knee, moved but was never seen in a normal position. (Right) Clinical photograph shows the same fetus at birth with a congenitally dislocated knee. Splinting therapy was unsuccessful, and the infant required surgical correction.



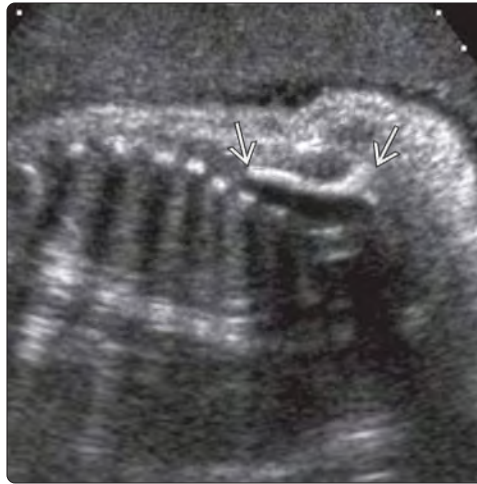Abnormal Joint Angulation





Kyphomelic Dysplasia

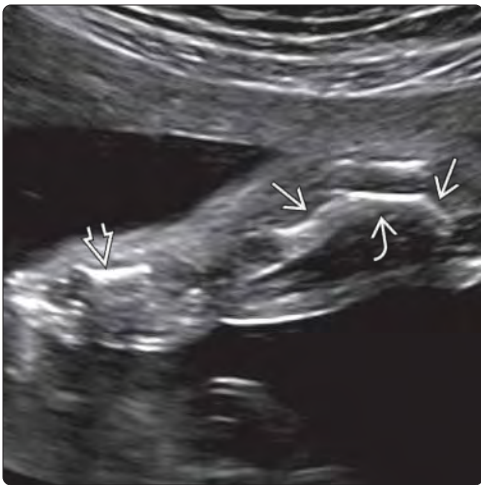


Kyphomelic Dysplasia

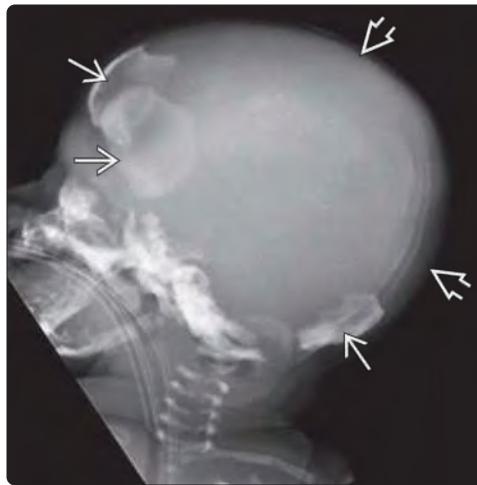






(Left) Coronal US shows an angulated femur  in a fetus diagnosed after birth with kyphomelic dysplasia. Ossification is normal, and no fractures were seen in the mildly shortened long bones. (Right) Third-trimester coronal US in the same fetus with kyphomelic dysplasia shows a normally sized and ossified scapula , making campomelic dysplasia an unlikely consideration in the differential diagnosis.

Hypophosphatasia

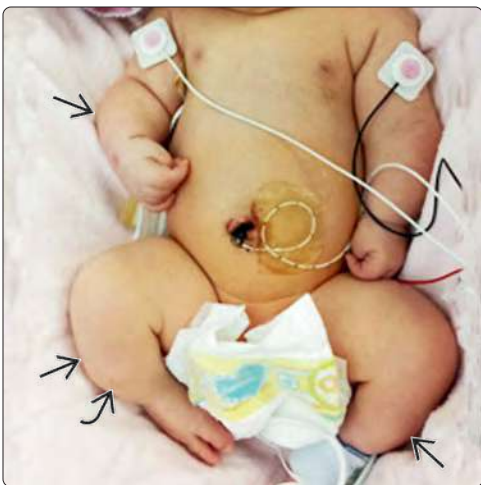

Hypophosphatasia

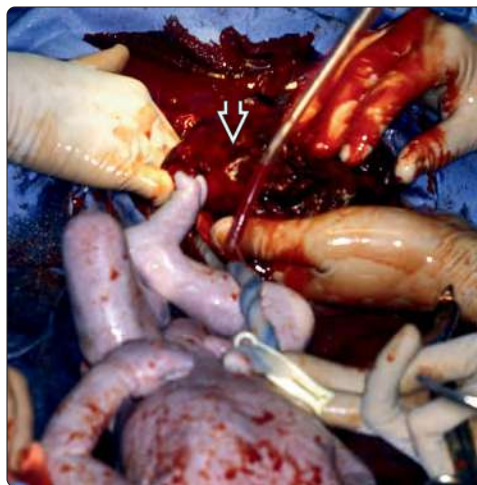





(Left) Lower extremity US in a 3rd-trimester fetus with perinatal lethal hypophosphatasia shows the severe underossification that is typical in this condition. The femur is ragged appearing with irregular angulation  and a heterogeneous echotexture  to the bone. The distal leg bones are hard to see, although a small tibia  is noted. (Right) Lateral radiograph of an infant with perinatal lethal hypophosphatasia shows the severely underossified skull  with a few "islands" of bone .

Hypophosphatasia



Fetal Trauma



(Left) Photograph of a newborn with perinatal lethal hypophosphatasia shows mild bowing  of the extremities due to the angulated bones. A pretibial skin dimple  is seen overlying a bent bone. This is also seen in campomelic dysplasia. (Right) Complete placental abruption  with death of the fetus was due to direct maternal abdominal trauma in a motor vehicle accident. Fetal fractures are uncommon in the absence of significant maternal trauma. Pregnancy loss, when it occurs, is usually the result of abruption.

DIFFERENTIAL DIAGNOSIS

Common

- Arthrogryposis, Akinesia Sequence
- Osteogenesis Imperfecta

Less Common

- Achondrogenesis
- Hypochondrogenesis

Rare but Important

- Hypophosphatasia
- Atelosteogenesis

ESSENTIAL INFORMATION

Key Differential Diagnosis Issues

- Are there fractures?
 - Presence or absence of fractures most important clue for differential
- Are fractures generalized or limited to portion of skeleton (e.g., ribs)?
- Do long bones appear short?
- If short long bones, is there micromelia?
- Is there angulation or curvature of long bones without fractures?
- Is underossification generalized or limited to part of skeleton?
 - Long bones, spine, pelvis?
- Is calvarium involved?
- Does fetus move normally, or is there evidence of generalized lack of movement or fixed joints?

Helpful Clues for Common Diagnoses

- **Arthrogryposis, Akinesia Sequence**
 - Lack of movement in utero → decreased mineralization
 - Appearance of long bones and ribs often very thin, especially late in gestation
 - Fractures rare in utero; may occur at time of birth
 - Onset of findings variable from 1st trimester through early 3rd trimester

- In general, earlier onset of abnormal/ lack of movement, more severe bone findings
- Hydrops occurs in severe, longstanding akinesia
 - Often associated with lethal outcome
- **Osteogenesis Imperfecta**
 - Presence of fractures due to undermineralization is hallmark feature of osteogenesis imperfecta
 - More severe forms are associated with more fractures in utero
 - Perinatal lethal form with multiple fractures in utero
 - Beaded appearance of ribs due to multiple fractures
 - Deformable calvarium by transducer pressure due to underossification

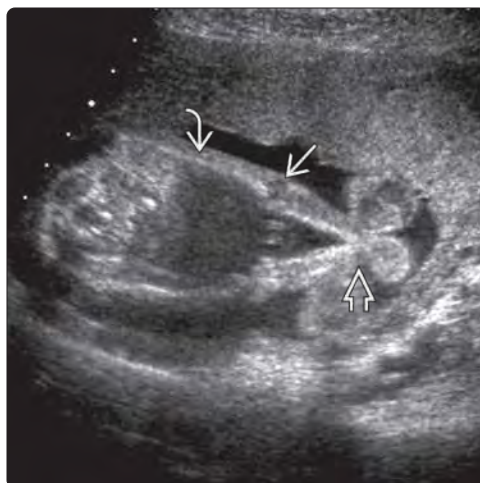
Helpful Clues for Less Common Diagnoses

- **Achondrogenesis**
 - Large calvarium, micromelia
 - Severely decreased ossification of spine for all types
 - Poorly ossified calvarium in IA, IB
 - Rib fractures in type IA; none in IB
 - Normal cranial ossification, absence of rib fractures in type II
- **Hypochondrogenesis**
 - Part of spectrum of achondrogenesis type II, but less severe findings
 - Fractures rare

Helpful Clues for Rare Diagnoses

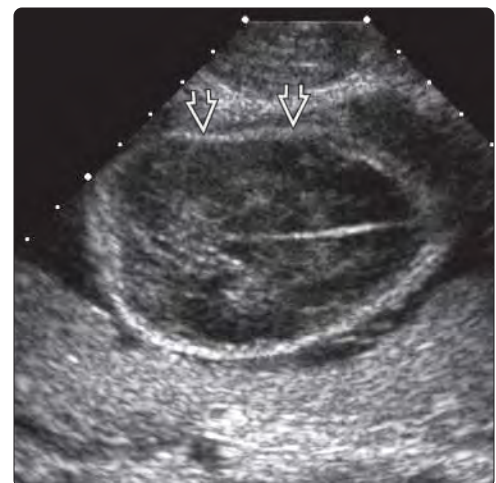
- **Hypophosphatasia**
 - Generalized lack of ossification is severe in perinatal lethal form
 - Calvarium poorly ossified
 - Small thorax, short limbs
 - Fractures rare, but may involve ribs which may have rachitic rosary appearance
- **Atelosteogenesis**
 - Deficient long bone ossification
 - Rhizomelic limb shortening with tapered humeri
 - Narrow thorax

Arthrogryposis, Akinesia Sequence

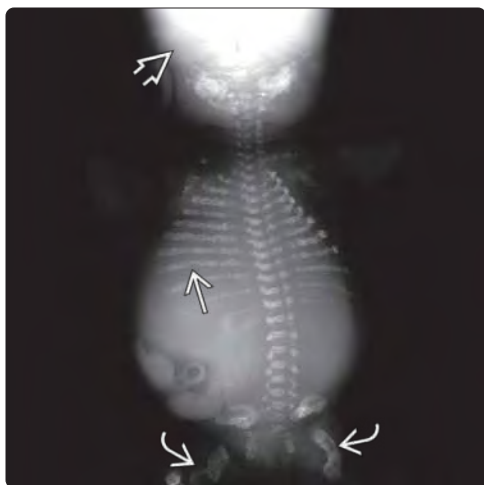


(Left) Upper extremity image shows hyperextended elbows and flexed wrists in a midtrimester fetus with akinesia sequence. The bones appear thin, but without fractures. The ribs are often gracile-appearing. Underossified bones in fetal akinesia sequence are the consequence of lack in movement in utero. (Right) US of a fetus with osteogenesis imperfecta (OI) shows severe underossification. Note the flattening of the calvarium that occurs with normal pressure from the US transducer.

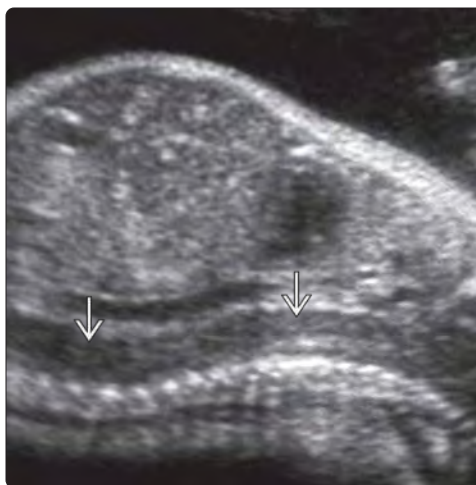
Osteogenesis Imperfecta



Osteogenesis Imperfecta

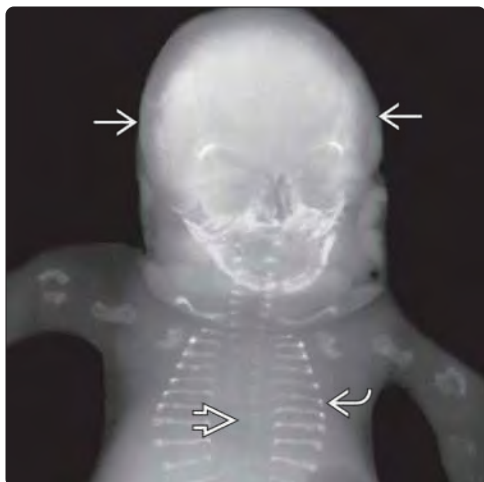

Achondrogenesis

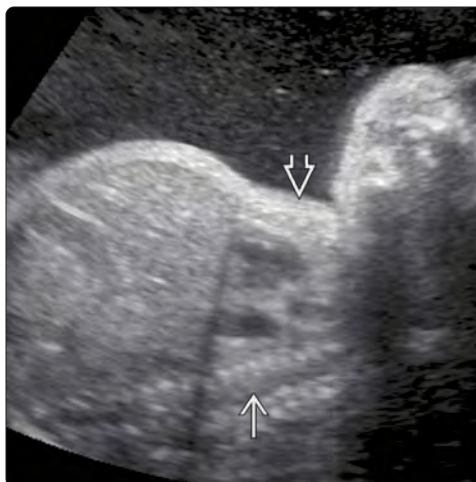


(Left) Radiograph of a preterm stillborn infant with perinatal lethal OI shows characteristic features of this disorder. Undermineralization of the entire skeleton is noted with fractures as a prominent feature. The calvarium is underossified and the long bones are "crumpled" due to multiple fractures. The ribs appear beaded due to multiple fractures as well. (Right) US shows a fetus with achondrogenesis. Note the lack of ossification of the spine, a distinguishing feature of this disorder.

Achondrogenesis

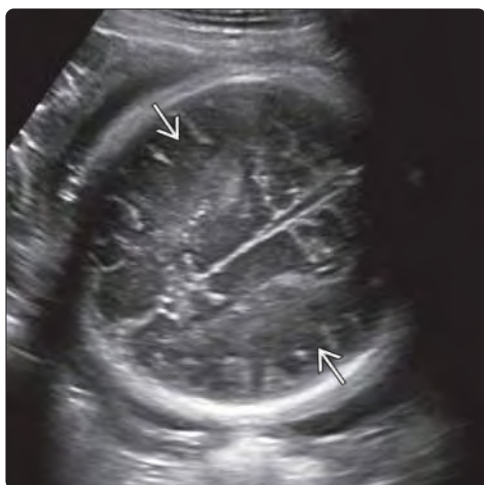

Hypochondrogenesis

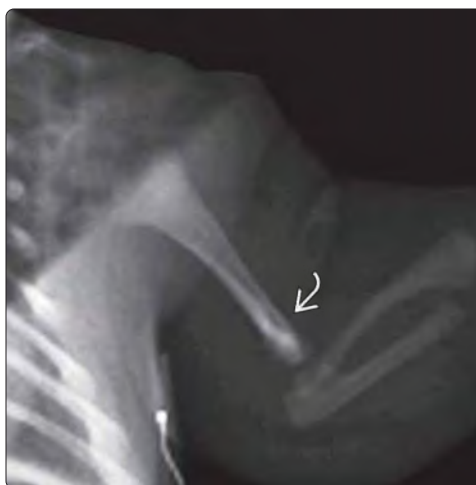

(Left) Radiograph of a fetus with achondrogenesis type IA shows there is poor skull ossification and thin, wavy ribs secondary to multiple fractures. Note the lack of vertebral body ossification. Type IB has a similar appearance but no rib fractures. (Right) Sagittal US shows the small chest of a 3rd-trimester fetus with hypochondrogenesis. Mild underossification of the spine is seen.

Hypophosphatasia



Atelosteogenesis

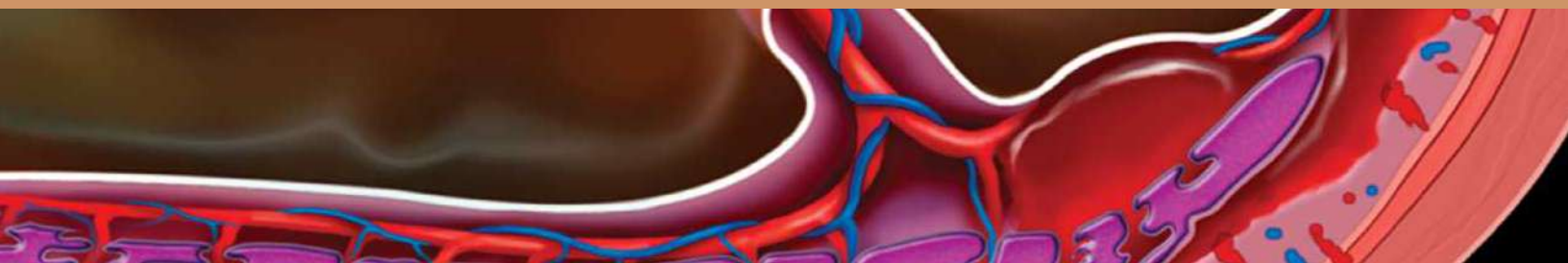


(Left) US in the 3rd trimester of a fetus with perinatal lethal form of hypophosphatasia shows that although bone of the calvarium is present, the brain is seen "too well" bilaterally, which by inference predicts that the skull is undemineralized. (Right) A characteristic finding in atelosteogenesis is the hypoplastic, distally tapered humerus. Hypoplasia and undermineralization of bones of the pelvis and lower limbs are also common findings.

This page intentionally left blank

SECTION 10

Placenta, Membranes, and Umbilical Cord



Introduction and Overview

Approach to the Placenta and Umbilical Cord	784
---	-----

Placenta and Membrane Abnormalities

Placental Abruption	790
Placenta Previa	794
Vasa Previa	798
Morbidly Adherent Placenta	800
Placental Lake, Intervillous Thrombus	806
Succenturiate Lobe	810
Circumvallate Placenta	812
Marginal and Velamentous Cord Insertion	814
Chorioangioma	816
Placental Teratoma	820
Placental Mesenchymal Dysplasia	822

Umbilical Cord Abnormalities

Single Umbilical Artery	824
Umbilical Vein Varix	826
Persistent Right Umbilical Vein	828

Pertinent Differential Diagnoses

Placental Cysts and Masses	830
Umbilical Cord Cysts and Masses	834

Embryology of the Placenta

Days 14-28 From Last Menstrual Period

The trophoblast becomes distinct from the embryonic cell mass around the 16-cell stage of development. Implantation occurs on days 20-28 from last menstrual period as the blastocyst binds to the endometrial epithelium. The trophoblast plaque lodges near uterine spiral arteries and the syncytium proliferates and erodes adjacent capillaries and venules to form lacunae. Next, the primitive syncytium is invaded by cords of cytotrophoblast cells and primary villi and intervillous spaces are formed.

5-10 Weeks From Last Menstrual Period

Mesoderm from the primitive yolk sac grows down the center of the primary villi to form secondary villi. Capillaries develop in situ and transform the secondary villi to tertiary villi. Branching morphogenesis of the tertiary villi occurs as densely collagenized connective tissue stroma and thick-walled fetal vessels provide the enlarging placenta with greater structural support.

10-12 Weeks From Last Menstrual Period

Direct arterial circulation is established to the intervillous space. Chorionic frondosum is established and the rest of the chorion atrophies to form the "smooth chorion."

12-20 Weeks From Last Menstrual Period (2° Implantation)

The trophoblast invades the inner 3rd of the myometrium and spiral arteries are remodeled. Fixed low-pressure arterial vascular dilatation is established with the invasion of the muscular wall and dissolution of the muscular media.

22-30 Weeks From Last Menstrual Period (Terminal Villogenesis)

Terminal villi are established via the processes of capillary growth, coiling, and further branching angiogenesis. Fetal capillaries are brought closer in proximity to oxygenated maternal blood in the intervillous space.

Embryology of the Umbilical Cord

In the blastocyst, a loose meshwork of extraembryonic mesoderm surrounds the embryonic disc. As the endoderm forms the yolk sac and the ectoderm forms the amnion, the extraembryonic mesoderm cavitates centrally and forms the exocoelom. A connecting stalk joins the chorionic mesoderm to the embryonic structure. The allantois, a small caudal outgrowth from the embryo, protrudes into the connecting stalk. The embryo rotates and prolapses into the amniotic cavity, progressively lengthening the connecting stalk.

The allantoic vessels establish continuity with the vessels developing in the placental villi. Two umbilical arteries (UA) originate from the internal iliac arteries, and 2 umbilical veins (UV) arise from allantoic veins. The right UV atrophies at 8 weeks, and the left UV drains into the left portal vein and ductus venosus. The 2 UAs fuse or connect by an anastomosis within 15 mm of the placental insertion site.

The cord is covered in Wharton jelly derived from extraembryonic mesenchyme and composed of myofibroblasts and ground substance. Wharton jelly helps maintain turgor and protects against compression. The cord itself is nourished by diffusion of oxygen and nutrients from the umbilical vessels. The normal cord is spiraled, usually counterclockwise. Normal fetal movement establishes cord coiling.

Imaging Techniques and Normal Anatomy

1st-Trimester Gestational Sac (5-7 Weeks)

Trophoblastic tissue and chorionic villi form a diffuse echogenic ring around the gestational sac (GS). The yolk sac, early embryo, and early amnion can be seen at this stage. A double decidual sac sign (DDSS) might be seen as the echogenic GS is eccentrically located within the decidual reaction of the endometrium. The DDSS, however, is not always seen, and one should not rely on this sign alone as an indicator for an intrauterine pregnancy (IUP). The presence of a round fluid collection in the uterus may be the only finding for a potentially viable IUP. Seeing a yolk sac in the GS is encouraging and a normal yolk sac is thin-walled and measures < 7 mm.

1st-Trimester Placenta (8-14 Weeks)

The chorionic frondosum (CF), early placenta, is initially a focal thickening at the site of GS attachment. The umbilical cord most often inserts in the center of the CF, seen best with color Doppler.

The amnion is clearly seen surrounding the embryo and fetus at this stage and is not yet fused with the chorion. The yolk sac is extraamniotic, located between the amnion and chorion. Normal amnion fusion occurs around 14 weeks.

2nd-Trimester Placenta

The 2nd-trimester placenta is homogeneous and uniformly echogenic. A hypoechoic subplacental venous complex resides between the placenta and the myometrium. Occasional sonolucencies are considered normal. These placenta lakes can be transient and mostly represent intervillous dilated spaces filled with maternal blood. Grayscale imaging shows slow swirling blood, most often not demonstrable with color Doppler.

Placental location is part of the standard mid-gestation fetal anatomy scan. The exact location of placental implantation should be documented and reported in the 2nd trimester. Most placentas are located in the fundal to mid uterus and are typically described as anterior, posterior, right lateral, or left lateral.

The placenta's relationship to the internal cervical os should be assessed in every scan. Transvaginal ultrasound is used to assess the placenta edge to cervical os distance if the lower uterine segment is not seen well by transabdominal scanning or if a low-lying placenta is suspect.

The placenta is considered low-lying if the inferior margin is within 2 cm of the internal cervical os, by transvaginal technique. Most low-lying placentas diagnosed in the 2nd trimester resolve by the 3rd trimester. Follow-up scans at 28-32 weeks should be performed to show resolution, or persistence. A placenta previa is diagnosed when the internal os is covered by the placenta; most do not resolve with advancing pregnancy.

3rd-Trimester Placenta

The 3rd-trimester placenta is heterogeneous in echotexture and commonly contains sonolucencies and calcifications. After 30 weeks, basal calcifications (at the placenta/myometrial junction) and cotyledon calcifications are considered normal findings.

As in the 2nd trimester, placenta location and relationship to the internal cervical os should be assessed and reported. Failure to see the inferior edge of the placenta should lead to

endovaginal scanning to rule out a low-lying placenta or previa if not previously cleared in the 2nd trimester. Color Doppler should be used to rule out the presence of fetal vessels near the internal os (vasa previa).

Umbilical Cord

The presence of 2 UAs and 1 UV should be documented and reported. Orthogonal images of a free loop of cord and transverse views through the fetal bladder can be used. Color Doppler will show the 2 UAs extending around the bladder to insert upon the iliac arteries. Avoid evaluating the number of vessels near the placental cord insertion (PCI) site because arteries fuse near the PCI site.

The PCI site should be documented when possible and especially with multiple gestations and cases of abnormal placentation. The cord insertion is considered marginal if it is within 2 cm of any edge of the placenta and velamentous if fetal vessels insert or travel under membranes, at a distance from the placental edge. Marginal insertions are at risk for becoming velamentous insertions, which are associated with growth restriction, cord accident, and vasa previa.

Beware of Pitfalls

Full Maternal Bladder

With a full maternal bladder, the anterior uterine wall can approximate the posterior uterine wall and falsely elongate the lower uterine segment. A normally implanted placenta may appear to be low-lying. Reimaging with transabdominal or transvaginal ultrasound after the bladder is empty is necessary to rule out placenta previa.

Focal Myometrial Contraction

Focal thickening of the uterine wall behind the placenta can mimic a fibroid. Also, a focal myometrial contraction (FMC) in the lower uterine segment can approximate the anterior and posterior uterine walls, and a normally implanted placenta may appear to be low-lying. With transvaginal scanning, a small amount of amniotic fluid can often be seen adjacent to the internal os, and the cervix-placenta relationship can be better evaluated. Alternatively, scanning after the FMC resolves is helpful.

Succenturiate Lobe

One or more accessory placentas may be present, and these lobes are connected by fetal vessels. If any of the lobes are in the lower uterine segment, a transvaginal ultrasound is necessary to look for vasa previa.

Acute Placental Hemorrhage

Acute blood may be isoechoic to the placenta, and a retroplacental hemorrhage may appear as placental thickening. Color Doppler is helpful in differentiating between the vascular myometrium and placenta from the avascular hematoma.

Umbilical Cord False Knot

Multiple loops of cord in close proximity may mimic a cord knot. Careful scanning and repeat scanning as the fetus moves, along with pulse Doppler, should be performed to determine if there is a true knot.

Approach

When Do I Follow-Up a Low-Lying Placenta?

If the inferior edge of the placenta is ≤ 2 cm from the internal cervical os in the 2nd trimester, then follow-up is indicated. This measurement is made with endovaginal scanning (transabdominal is not accurate). Follow-up in the 3rd

trimester, at 28-32 weeks, will show that the vast majority of asymptomatic, low-lying placentas have resolved. Asymmetric previa may also resolve with advancing pregnancy.

Are Placental Sonolucencies Clinically Relevant?

Most placental sonolucencies represent normal venous lakes, and many are transient findings. Early, numerous, and large sonolucencies may be significant. If multiple lucencies are seen before 20-25 weeks, or > 3 sonolucencies measuring > 3 cm are seen, then it is reasonable to be concerned about placental insufficiency and follow the pregnancy for growth and fluid. The placenta accreta spectrum can have large, irregular, tornado-like sonolucencies. Also, multiple lucencies may actually represent multiple placental cysts, and the diagnosis of gestational trophoblastic neoplasia should be considered.

How Thick Should the Placenta Be?

The placenta increases in thickness with advancing gestation. As a general rule, the placenta thickness (in mm) follows the gestational age (in weeks). For example, a 20-week placenta measures 20 mm, and a 30-week placenta measures 30 mm. In general, the placenta should not measure greater than 40 mm. Placentomegaly can be seen with fetal hydrops, macrosomia, Beckwith-Wiedemann syndrome, and diabetes. A thin or small placenta is associated with growth restriction and aneuploidy.

What If I See a Nuchal Cord?

The incidence of a single-loop nuchal cord at delivery is 20-25%, and single-loop nuchal cord at delivery is not associated with increased risk of neonatal morbidity or mortality. Therefore, identification of single-loop nuchal cord by ultrasound is considered an incidental finding. In addition, the false-positive rate for diagnosis of a nuchal cord with ultrasound is 20% since many cases are not imaged in multiple projections. The management of nuchal cord with multiple loops is controversial. Three or more loops may be associated with high enough morbidity to argue for elective cesarean delivery. Fetal monitoring and cord Doppler evaluation is recommended if multiple loops or a tight loop is suspected.

When Is MR of the Placenta Helpful?

MR is rarely necessary to assess the placenta, but can be helpful if placenta visualization is limited by maternal size or posterior location of the placenta. MR may help in some cases with placenta accreta or gestational trophoblastic disease. Most studies have not shown any advantage of MR over ultrasound for diagnosing abnormally invasive placenta. However, the placenta is seen well with MR. MR also has the advantage of a larger field of view and the ability to show deeper structures in the maternal pelvis.

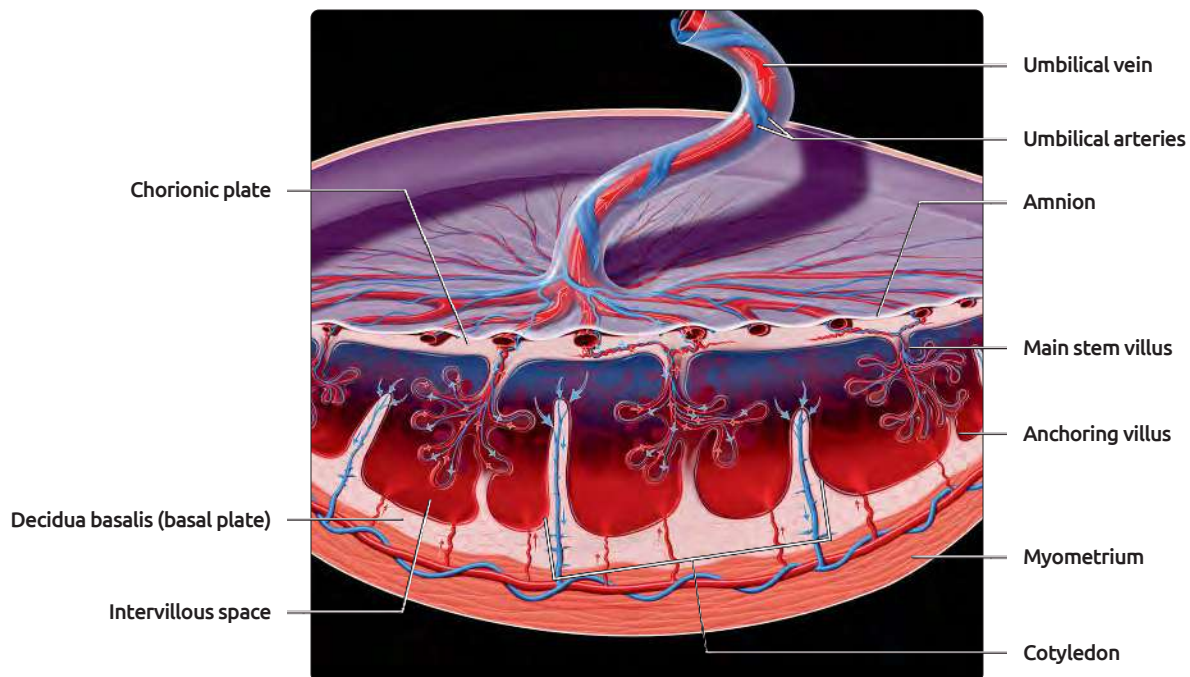
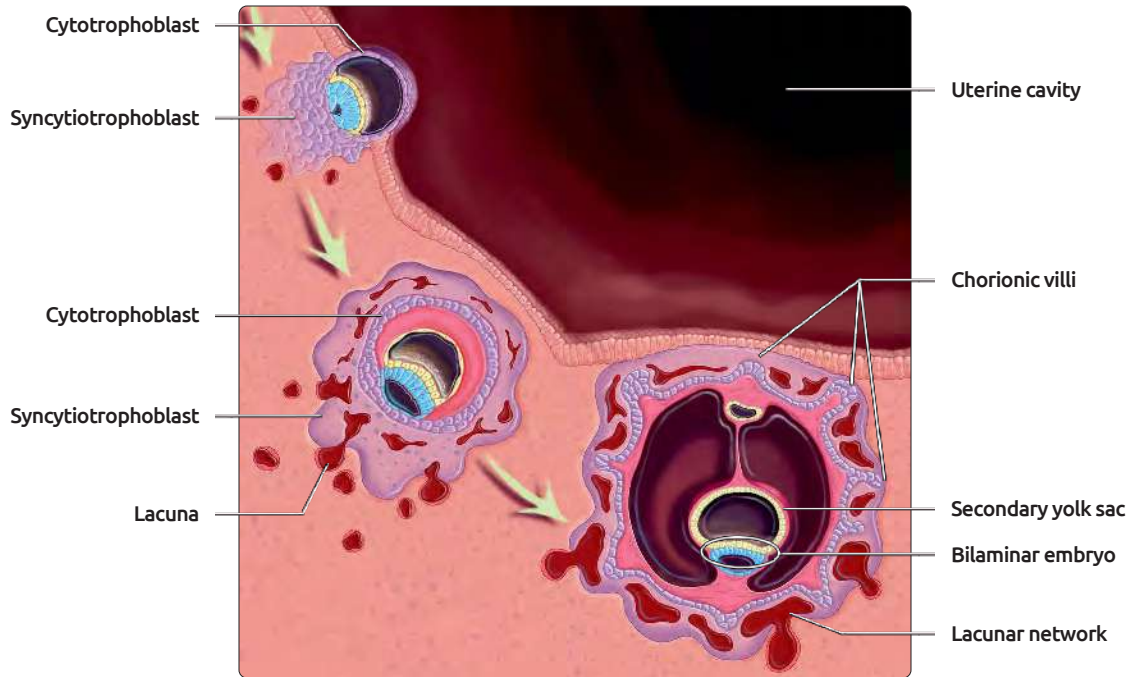
What If the Cord Is Hypocoiled?

Straight umbilical cords are most often an idiopathic finding, but are also associated with single umbilical artery and fetal movement disorders. Careful scanning of the fetus for additional anomalies, particularly involving the extremities, is recommended.

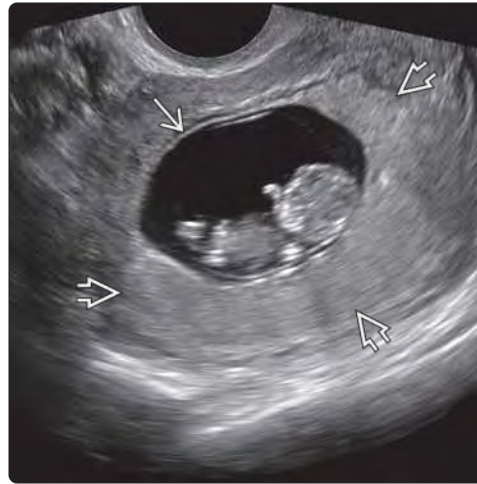
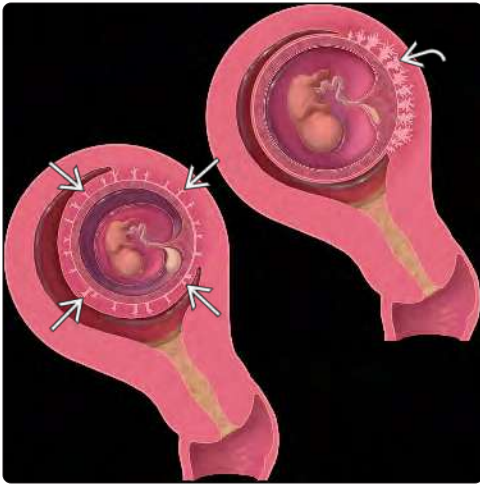Selected References





- Collins SL et al: Proposal for standardised ultrasound descriptors of abnormally invasive placenta (AIP). *Ultrasound Obstet Gynecol.* ePub, 2015
- Vintzileos AM et al: Using ultrasound in the clinical management of placental implantation abnormalities. *Am J Obstet Gynecol.* 213(4 Suppl):S70-7, 2015
- Moshiri M et al: Comprehensive imaging review of abnormalities of the umbilical cord. *Radiographics.* 34(1):179-96, 2014

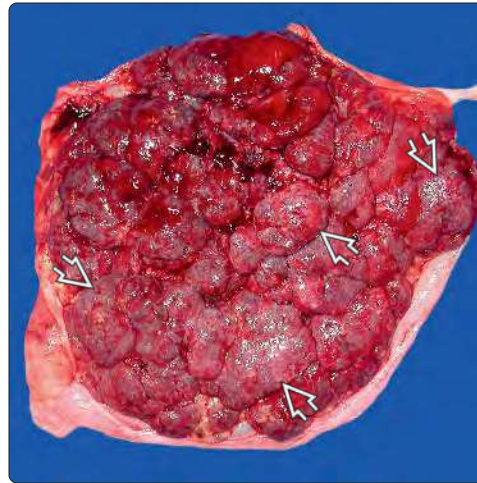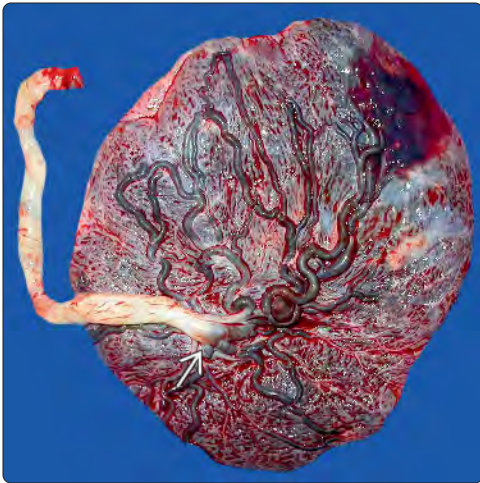
Approach to the Placenta and Umbilical Cord





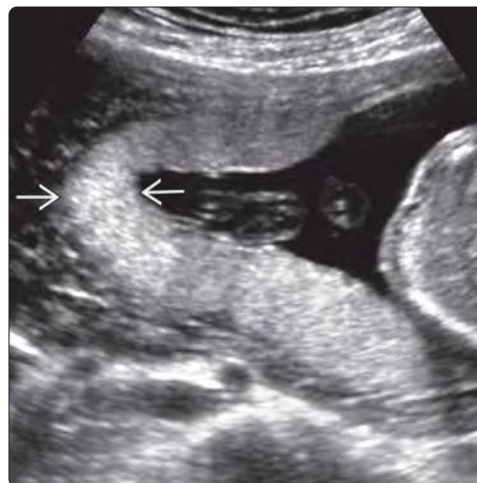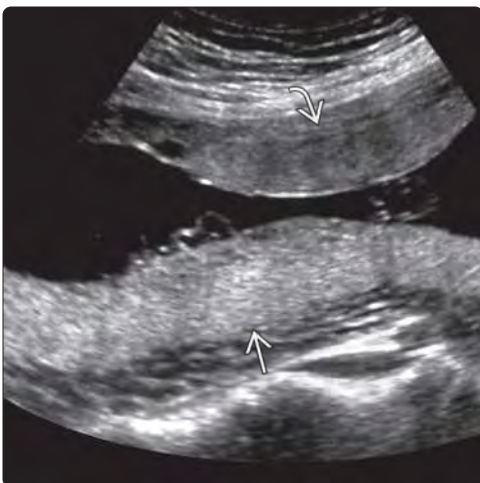
(Top) This graphic series shows early placental development. The syncytiotrophoblast is a rapidly growing multinucleated mass, which invades and ruptures endometrial capillaries forming lacunae. The cytotrophoblast is a layer of mononucleated cells, which invades the syncytiotrophoblast matrix and forms early chorionic villi. Oxygen exchange occurs between the villi and the lacunae, and oxygen also diffuses into the extraembryonic tissue. The bilaminar embryo forms adjacent to the secondary yolk sac. **(Bottom)** Graphic of placental vascularity shows main stem villi, the final branching point of the umbilical artery (UA) and umbilical vein (UV), bathing in maternal blood in the intervillous space. Deoxygenated blood is blue and from the UAs while oxygenated blood is red, returning to the fetus via the UV.










(Left) Graphic shows chorionic villi  evenly distributed around the early gestational sac. At 10 weeks, the chorionic frondosum (CF, early placenta)  is established while other villi atrophy. **(Right)** A transvaginal ultrasound of a 9-week pregnancy shows early placentation. The focal posterior trophoblastic thickening  is the CF/early placenta. The anterior trophoblastic tissue has almost completely resorbed .

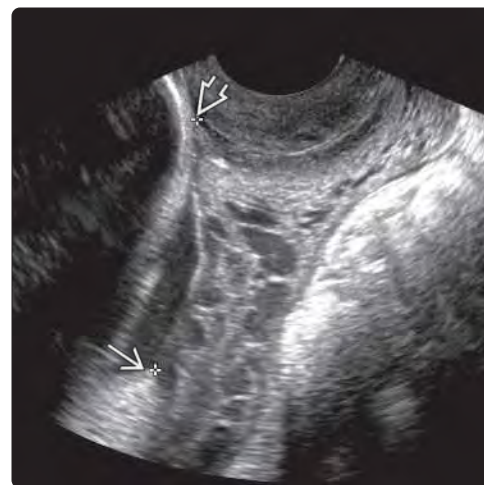
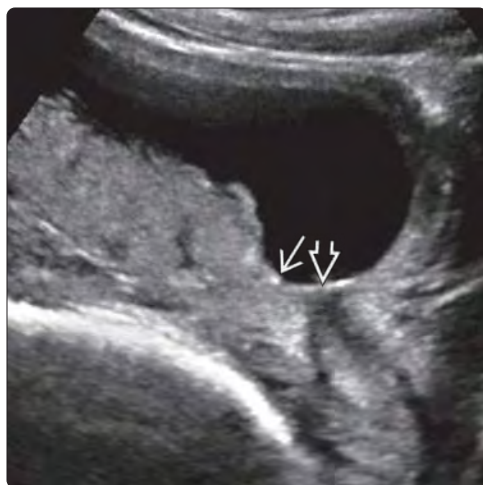



(Left) Gross pathology of the fetal surface of a term placenta shows a normal placenta cord insertion (PCI) site . Branching vessels arise from the cord. This surface of the placenta and cord are covered with amnion. **(Right)** Gross pathology of the maternal surface of a term placenta shows multiple placental lobes . The lobes served as intervillous spaces for maternal-fetal nutrient and gas exchange.

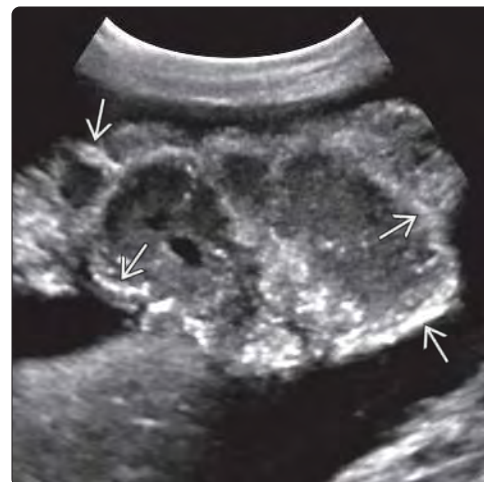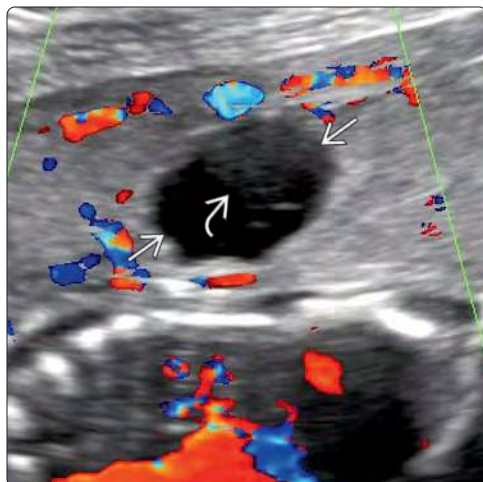




(Left) Sagittal ultrasound of the uterus shows an anterior  and posterior placenta . Initial appearance is suspicious for a large posterior placenta and a succenturiate anterior lobe. **(Right)** Axial ultrasound of the same case shows a connection  between the anterior and posterior placenta. Therefore, this placenta location is right lateral without a succenturiate lobe. Orthogonal views and whole uterine scanning is necessary to accurately determine placental location.

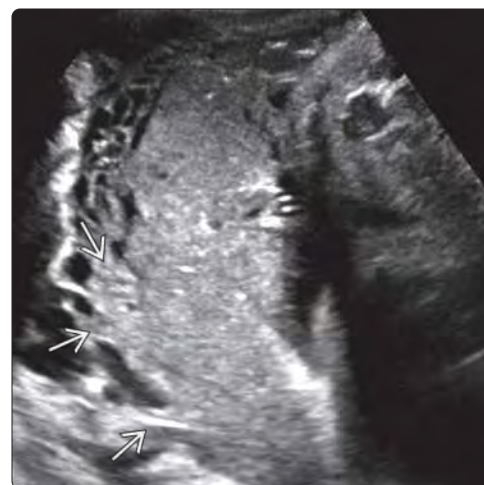
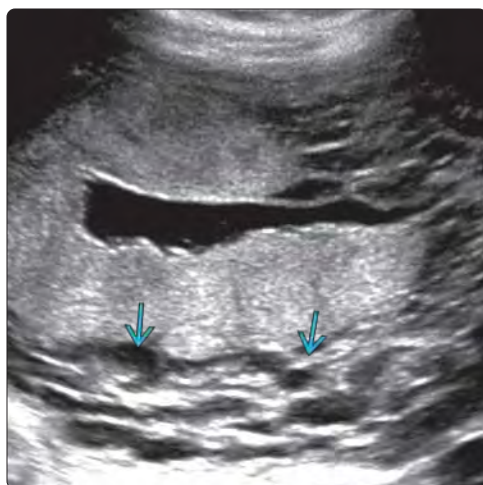
(Left) Transabdominal sagittal ultrasound of the lower uterine segment shows the inferior edge of the posterior placenta  in close proximity to the internal cervical os . This finding was confirmed with endovaginal scanning; therefore, the case was reported as low-lying placenta and follow-up at 28-32 weeks recommended. **(Right)** At 32 weeks, transvaginal ultrasound shows the inferior edge of the placenta  is far from the internal cervical os , and vaginal delivery is possible.

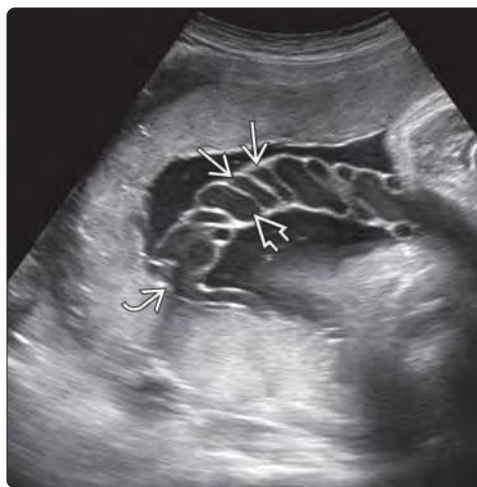
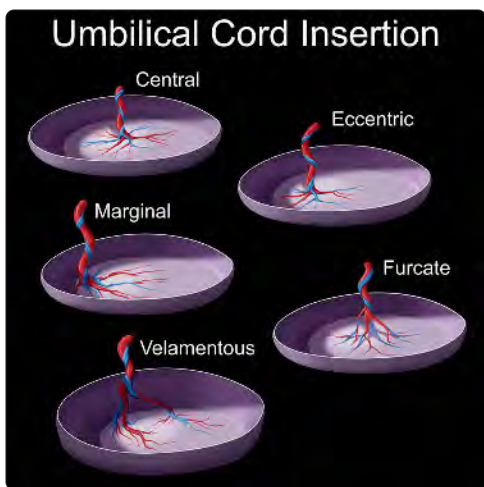


(Left) Color Doppler ultrasound of a placental sonolucency  demonstrates lack of flow within the structure. However, swirling flow could be seen in part of this lesion in real time. A subtle intraluminal echogenicity , without flow, is probably a small thrombus in this placental lake. **(Right)** Axial ultrasound of a late 3rd-trimester placenta shows extensive basal and cotyledon calcifications . Normal amniotic fluid and fetal growth was documented, and the finding was thought to be normal for gestational age.

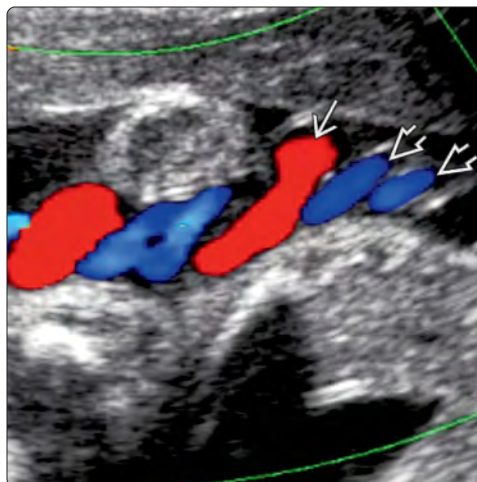



(Left) Axial ultrasound of a right lateral placenta and uterine wall shows large myometrial veins  behind the placenta. Prominent myometrial veins are seen more often with posterior placentas and are considered a normal finding. **(Right)** In another case with right lateral placenta and history of myomectomy, there is loss of the normal hypoechoic zone behind the placenta due to focal placental invasion . Posterior placenta accreta was confirmed at cesarean hysterectomy delivery.

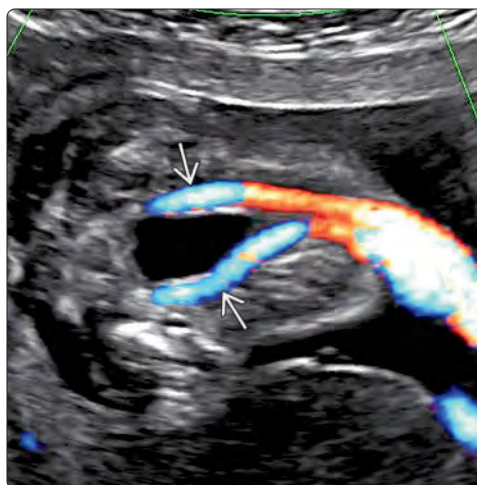
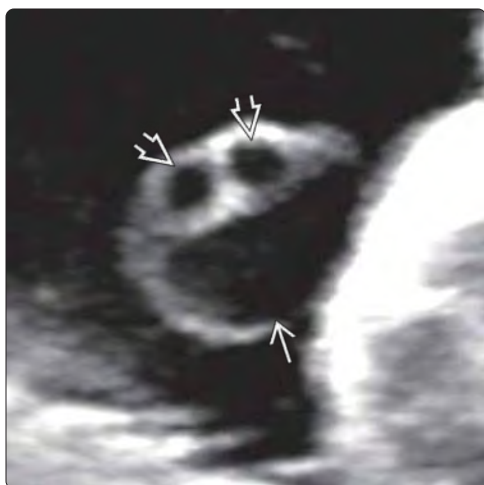




(Left) Central and eccentric cord insertions are most common. Marginal, velamentous, and furcate are more often associated with pathology. Velamentous and furcate cords leave vessels vulnerable to injury. Marginal insertion may be less efficient for perfusion. (Right) Longitudinal view of a normal umbilical cord shows the PCI site [arrow]. The UAs [arrowheads] are smaller in diameter and can be distinguished from the UV [arrow].



(Left) Cord coiling refers to the frequency of the UAs (blue) coiling around the UV (red). Normal coiling ranges from 1-3 coils per 10-cm length of cord. Both overcoiling (top) and undercoiling (bottom) have been associated with adverse outcomes in some studies. (Right) Longitudinal color Doppler ultrasound of a normal 3-vessel cord shows 2 arteries [arrowheads] and 1 vein [arrow] carrying blood in different directions (UV: Blood to the fetus; UA: Blood to the placenta).



(Left) Axial magnified view of a segment of cord confirms the presence of 2 arteries [arrowheads] and 1 vein [arrow]. The echogenic material between the vessels that surrounds the cord and gives it structural integrity is Wharton jelly. (Right) The axial color Doppler ultrasound at the bladder base view can be used to confirm the presence of 2 UAs [arrowheads]. The arteries flank the bladder and join the iliac arteries posteriorly.

KEY FACTS

TERMINOLOGY

- Partial or total premature detachment of placenta

IMAGING

- Appearance depends on age and size of hematoma
 - Acute hematoma: Often isoechoic to placenta
 - Subacute hematoma: Hypoechoic to placenta
 - Resolving/chronic hematoma: Sonolucent
- Marginal abruption (most common)
 - Hemorrhage from edge of placenta
- Retroplacental abruption (2nd most common)
 - Hematoma between placenta and uterus
- Preplacental abruption (rare)
 - Hematoma on fetal surface of placenta

TOP DIFFERENTIAL DIAGNOSES







- Leiomyoma
- Focal myometrial contraction
- Chorioangioma

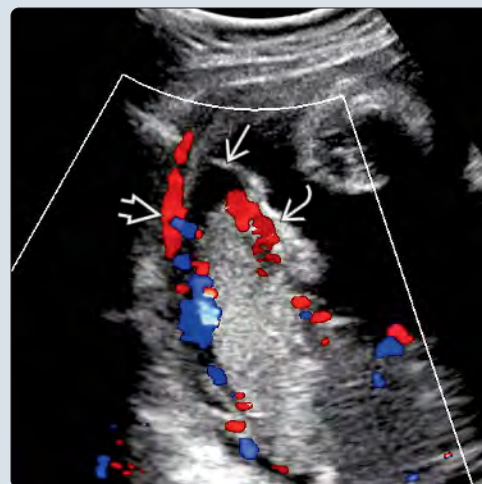
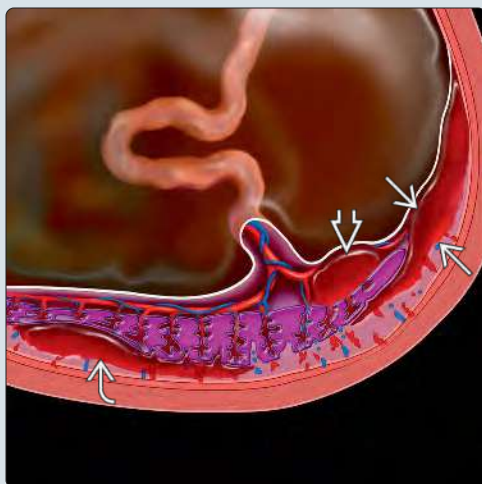
CLINICAL ISSUES




- 1% of all pregnancies
- Placental abruption is clinical diagnosis
 - Vaginal bleeding (82%)
 - Pain (26%)
 - Uterine hypertonia (26%)
- Ultrasound shows clot in only 20-30%
- Key associations and risk factors
 - Prior abruption
 - Placenta previa
 - Gestational hypertensive disease
 - Smoking
 - Maternal motor vehicle accident

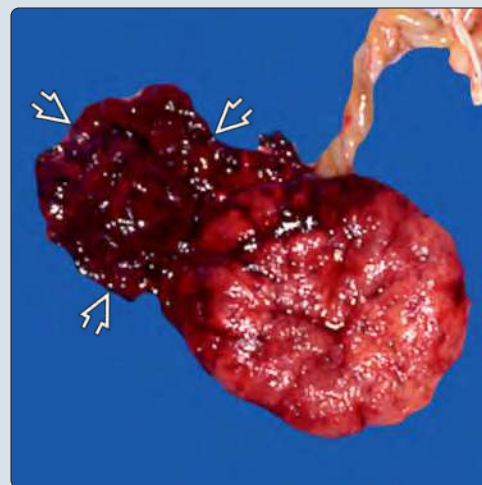
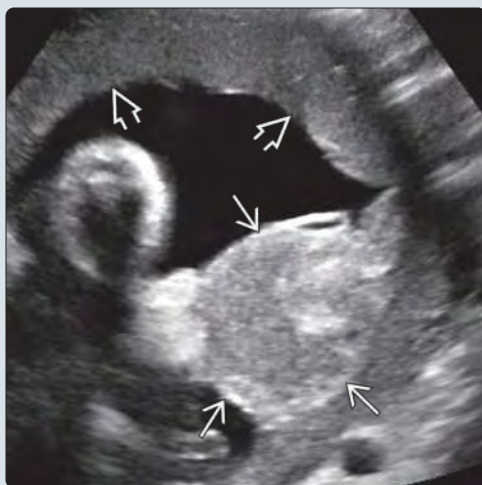DIAGNOSTIC CHECKLIST

- Look for abruption and previa in all 2nd and 3rd trimester cases with vaginal bleeding or tender uterus
- Evaluate fetal heart rate carefully and at beginning of scan
 - Fetal bradycardia leads to emergency delivery

(Left) Graphic shows placental abruption (PA) sites. Marginal PA  occurs at the placental edge. Retroplacental abruption  occurs between the placenta and uterine wall, and preplacental abruption  occurs in front of the placenta, between the placenta and membranes. (Right) In this example of a small marginal PA, the edge of the placenta  has been lifted off the uterine wall . A small sonolucent hematoma is seen , suggesting the abruption is old. Color Doppler shows flow in the placenta and uterus but not in the clot.



(Left) This large marginal PA  is located adjacent to an otherwise well-attached anterior placenta . The PA is acute and thus the clot is isoechoic to the placenta. Also, a lifted edge of the placenta is not always seen with ultrasound. (Right) Clinical photograph of a large marginal abruption, resulting in fetal death, shows the large blood clot  extending from the margin of the placenta.



TERMINOLOGY

Abbreviations

- Placental abruption (PA)

Definitions

- Partial or total premature detachment of placenta

IMAGING

General Features

- Best diagnostic clue
 - Marginal PA: Lifted edge of placenta + blood clot
 - Retroplacental abruption: Thick placenta
 - May or may not see actual blood clot
- Location
 - Marginal, retroplacental, preplacental

Ultrasonographic Findings

- **Appearance of hematoma depends on size and age**
 - Acute hematoma
 - Echogenic blood: Often isoechoic to placenta
 - Color Doppler helpful
 - Differentiate clot from placenta/uterus
 - No flow in hematoma
 - Subacute hematoma (most common)
 - Clot is heterogeneous or hypoechoic
 - Septations common
 - May contain fluid-fluid level if large
 - Easier to resolve clot vs. placenta
 - Resolving/chronic hematoma
 - Blood is liquefying and approaches sonolucent
 - Associated echogenic amniotic fluid is common
 - Etiology
 - Acute large bleed traverses amnion
 - Clot proteins diffuse into fluid
 - 2° fetal echogenic bowel from ingesting echogenic amniotic fluid
- **Marginal PA**
 - Most common type of abruption
 - 91% < 20 weeks are marginal
 - 67% > 20 weeks are marginal
 - Hemorrhage from edge of placenta
 - Can see raised edge in 50%
 - Hematoma adjacent to placenta
 - Curvilinear clot near placenta
 - Remote hematoma
 - Clot at distance from placenta
 - Blood dissects under chorionic membrane
 - Look in front of cervical os
 - Estimate amount of placenta detached
 - Look for accompanying cervical change
 - Cervical effacement/funneling
- **Retroplacental abruption** (2nd most common)
 - Hematoma between placenta and uterus
 - Large detachment more likely
 - ↑ risk of fetal morbidity
 - Appears acutely as placentomegaly
 - Isoechoic blood behind placenta
 - Direct hemorrhage into placenta possible

- Power Doppler helpful
 - Delineates clot from placenta
- **Preplacental abruption** (rare)
 - Hematoma on fetal surface of placenta
 - Subchorionic or subamniotic clot
 - Mimics placental mass
 - Chorioangioma
 - Large venous lake
 - Rarely, clot may compress cord
 - Find placental cord insertion
 - Use Doppler to evaluate flow
- **Twins and abruption**
 - Hematoma may dissect between membranes
 - Looks like cyst between membranes when old

Imaging Recommendations

- Best imaging tool
 - Careful complete inspection of placenta and uterus
 - Use both grayscale and color Doppler
- Protocol advice
 - Assess for signs of fetal distress
 - Fetal bradycardia
 - Abnormal cord Doppler
 - Poor biophysical profile score
 - Perform transvaginal ultrasound
 - Rule out previa as cause of bleeding
 - Assess cervical length
 - Quantify amount of placental detachment

DIFFERENTIAL DIAGNOSIS

Myoma

- Hypoechoic uterine wall mass
- Placenta may implant upon myoma
 - Mimic retroplacental clot
 - Myoma has blood flow (clot does not)
 - ↑ risk for PA

Placenta Previa

- Presentation similar to PA presentation
- Previa + PA common
 - Low-lying placenta more likely to detach

Focal Myometrial Contraction

- Normal transient myometrial thickening
 - Appears mass-like
 - Will resolve with time
 - Power Doppler often shows flow
- Inner myometrium affected more than outer

Chorioangioma

- Vascular placental mass
 - Doppler almost always shows flow
- Can mimic preplacental abruption if located on fetal surface of placenta

PATHOLOGY

General Features

- Etiology
 - Abnormal trophoblast invasion → rupture of spiral arteries → premature placental separation

- Mostly from abnormal placentation early in pregnancy
- Dissection of blood
 - At decidual-placental interface
 - Around placental margin
 - Behind membranes
- Associated abnormalities
 - Placenta previa (13-14x ↑ risk for PA)
 - Myoma (2.6x ↑ risk for PA)

Staging, Grading, & Classification

- Revealed PA (80%)
 - "Revealed" because patient presents with bleeding
 - Blood tracks between membranes and out via cervix/vagina
 - Amount of bleeding does not correlate with PA size
- Concealed PA (20%)
 - Abruption is retroplacental
 - Present with uterine irritability, not bleeding
- Ultrasound classification based on location
 - Marginal (most common)
 - Retroplacental
 - Preplacental

CLINICAL ISSUES

Presentation

- Most common signs/symptoms
 - PA is clinical diagnosis
 - Classic presentation
 - Vaginal bleeding (82%)
 - Pain (26%)
 - Uterine hypertonia (26%)
 - Nonreassuring fetal status (65%)
 - Ultrasound shows clot in only 20-30%
 - 88% positive predictive value when clot seen
 - Abnormal maternal serum screen results
 - 1st-trimester PAPP-A \leq 5th percentile
 - 2nd-trimester α -fetoprotein \geq 95th percentile
- Other signs/symptoms
 - Couvelaire uterus (rare)
 - Blood infiltrates \rightarrow myometrium \rightarrow serosa
- Risk factors for PA
 - Prior PA (10-30x ↑ risk)
 - Gestational hypertensive disease
 - Smoking
 - Multiparity
 - Premature rupture of membranes
 - Multiple gestation
 - Advanced maternal age
 - Addictive behavior
 - Alcohol, cocaine, other
 - Trauma
 - 7x ↑ risk if motor vehicle accident
 - Regardless of other maternal injury

Demographics

- Epidemiology
 - 1% of all pregnancies
 - 2% among preterm deliveries
 - 0.3% among term deliveries

- 6% if PA in prior pregnancy

Natural History & Prognosis

- Maternal complications
 - Clotting disorders
 - Hemorrhagic shock
 - Maternal death < 1% in developed countries
- Fetal complications
 - Perinatal mortality 9-12%
 - Improved from 20% in 1970s
 - Prematurity with associated morbidity
 - Fetal growth restriction
 - Mostly with large and recurrent abruptions
- Prognosis associated with size/type of PA
 - Excellent if < 30% placenta detached
 - Worse for retroplacental concealed PA

Treatment

- Cesarean section if acute distress
- Expectant management if stable
- Early delivery if placental insufficiency

DIAGNOSTIC CHECKLIST

Consider

- Look for PA in all 2nd- and 3rd-trimester cases with vaginal bleeding or tender uterus
- Look carefully for retroplacental abruption
 - Acutely tender uterus \pm vaginal bleeding
- Consider PA surveillance in patients with history of prior PA

Image Interpretation Pearls

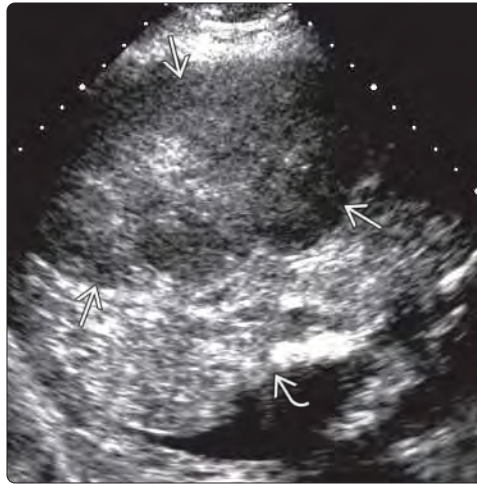
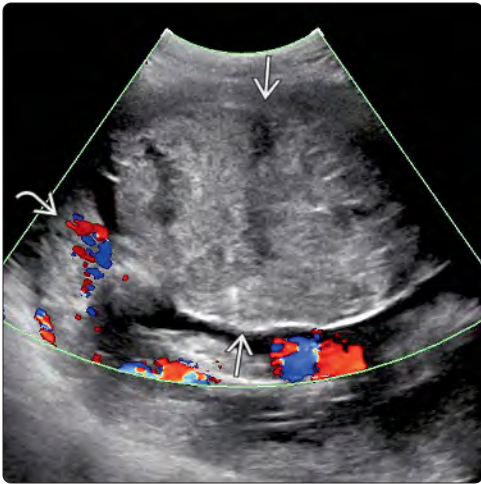
- Use power Doppler in cases of placental thickening
 - Clot will have no flow
 - Differentiate from myometrium and placenta (with flow)
- Evaluate fetal heart rate carefully and at beginning of scan
 - Bradycardia leads to emergency delivery
- Look for abruption if patient involved in MVA
 - Even if no other maternal injuries

Reporting Tips

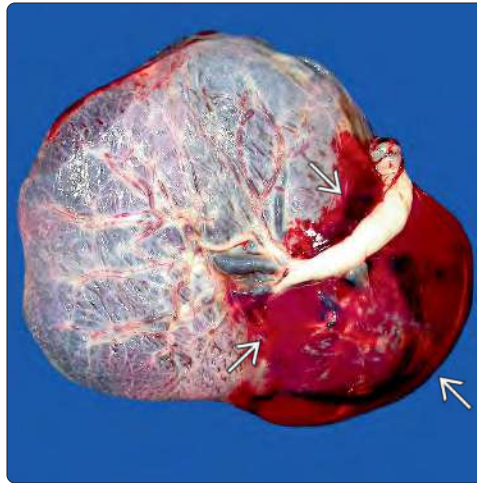
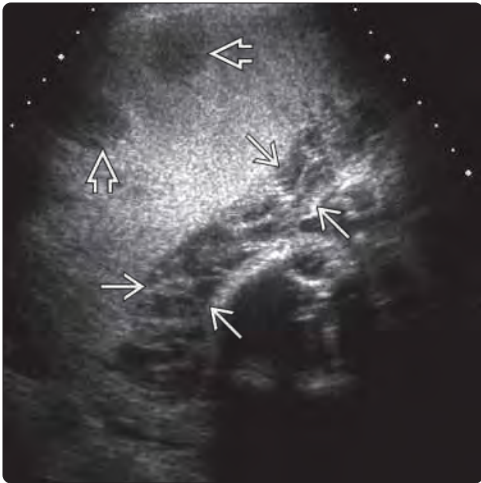
- Clarify that ultrasound does not detect most cases of PA
 - Report "no ultrasound evidence for PA," not "no PA"
 - PA is clinical diagnosis
- Consider follow-up ultrasound for fluid, growth, and cervical length

SELECTED REFERENCES

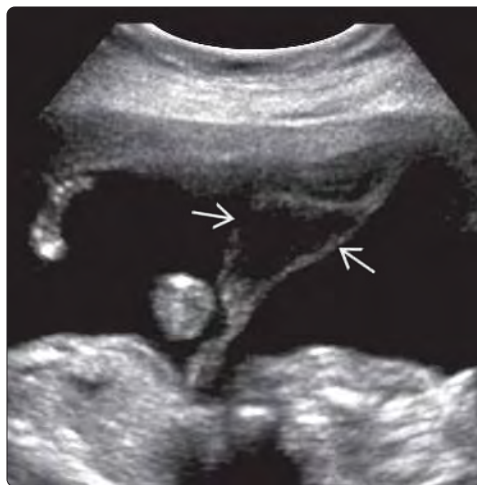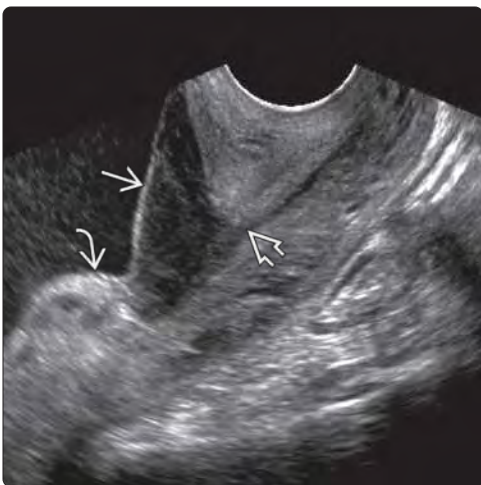
1. Kasai M et al: Prediction of perinatal outcomes based on primary symptoms in women with placental abruption. *J Obstet Gynaecol Res.* 41(6):850-6, 2015
2. Parker SE et al: Placental abruption and subsequent risk of pre-eclampsia: a population-based case-control study. *Paediatr Perinat Epidemiol.* 29(3):211-9, 2015
3. Ruiter L et al: Incidence and recurrence rate of placental abruption: a longitudinal linked national cohort study in the Netherlands. *Am J Obstet Gynecol.* 213(4):573, 2015
4. Blumenfeld YJ et al: Association between maternal characteristics, abnormal serum aneuploidy analytes, and placental abruption. *Am J Obstet Gynecol.* 211(2):144.e1-9, 2014
5. Boisramé T et al: Placental abruption: risk factors, management and maternal-fetal prognosis. Cohort study over 10 years. *Eur J Obstet Gynecol Reprod Biol.* 179:100-4, 2014
6. Tikkanen M: Etiology, clinical manifestations, and prediction of placental abruption. *Acta Obstet Gynecol Scand.* 89(6):732-40, 2010



(Left) This patient with acute retroplacental and intraplacental hemorrhage presented with preterm labor. Acute clot is isoechoic to the placenta, making it appear thick and heterogeneous. Doppler shows no flow (compare to a small attached area of normal placenta with flow). **(Right)** Axial ultrasound in a case with old retroplacental abruption shows a hypoechoic blood clot beneath the placenta. With time, blood becomes more hypoechoic. Notice how this chronic abruption mimics a retroplacental myoma.



(Left) Hematoma on the placental surface as well as focal retroplacental hematomas are seen in this case of PA. Preplacental abruption is rare and often presents in conjunction with marginal and retroplacental PA. **(Right)** Clinical photograph shows a large preplacental hemorrhage located near the cord insertion and extending toward the placental margin.



(Left) Transvaginal ultrasound in a patient with 3rd-trimester bleeding shows the placental edge lifted off the uterine wall with a hematoma extending across the internal cervical os. Low-lying placentas are at risk for abruption. **(Right)** In this case of dichorionic gestation with PA of 1 placenta, a complex fluid collection (hematoma) has dissected between the twin membranes. Twin membrane cysts may be secondary to old blood or unfused membranes. In this case, the collection was echogenic 2 weeks earlier.

KEY FACTS

TERMINOLOGY

- New revised classification with 3 categories only
 - Placenta previa (PP): Placenta covers internal os (IO)
 - Low-lying placenta (LLP): Placenta edge \leq 2 cm from IO
 - Normal: Placenta edge $>$ 2 cm from IO
- Avoid terms marginal or partial PP (deemed confusing)

IMAGING

- Transabdominal ultrasound is good screening tool
 - Show placenta $>$ 4 cm from IO to rule out PP
- Transvaginal ultrasound (TVUS) essential for diagnosis
 - Best way to evaluate lower uterine segment
 - Accurate measurement between placental edge and IO
- Important PP associations
 - Placenta accreta spectrum
 - \uparrow risk if prior cesarean section
 - Especially with increasing number of cesarean sections
 - Vasa previa: Fetal vessels cross IO

TOP DIFFERENTIAL DIAGNOSES

- Full maternal bladder
- Focal myometrial contraction
- Placental abruption

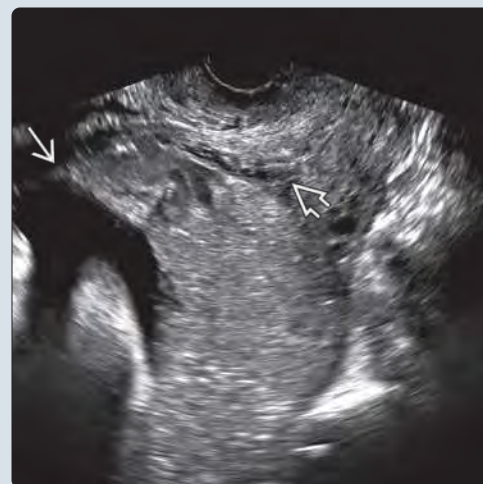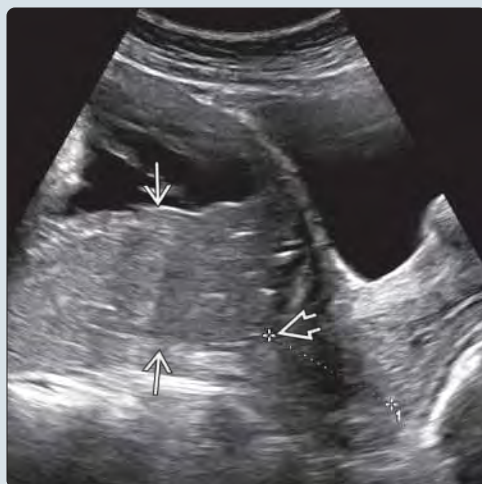
CLINICAL ISSUES

- \downarrow incidence as pregnancy advances
 - 2% at early 2nd-trimester scan using TVUS
 - Most are asymptomatic
 - $>$ 90% will resolve by term
 - 0.5% incidence of PP at term
- Treatment
 - Complete PP requires cesarean delivery
 - 50-75% of LLP may be able to delivery vaginally

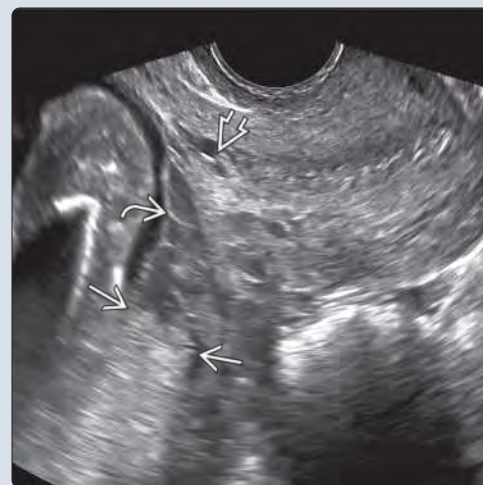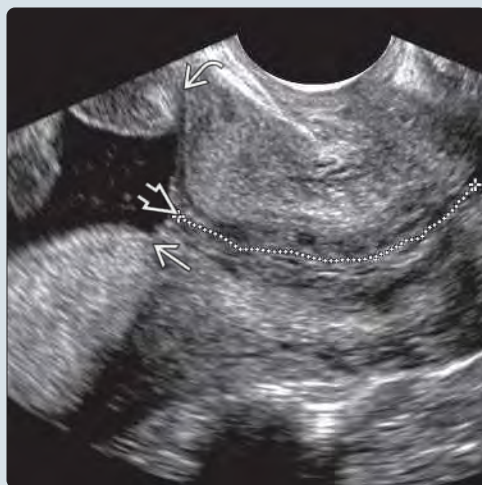
DIAGNOSTIC CHECKLIST

- TVUS to rule out PP and LLP in all patients with bleeding in 2nd/3rd trimester

(Left) Sagittal transabdominal ultrasound of the lower uterine segment shows a posterior placenta covering the internal os of the cervix in this patient with asymptomatic placenta previa (PP). **(Right)** Carefully performed transvaginal ultrasound shows the lower uterine anatomy to better advantage. The anterior edge of the placenta is several centimeters anterior to the internal cervical os. It is not surprising that this PP did not resolve with advancing pregnancy.



(Left) Transvaginal ultrasound of a low-lying placenta shows the placental edge close to, but not covering, the cervical os. In addition, an anterior cesarean section scar defect is seen but the placenta does not implant upon the scar. **(Right)** In this patient with placental bleeding, the placenta parenchyma is $>$ 2 cm from the internal os; however, placental veins approach and minimally cross the cervix. Marginal sinus previa is a variant of PP, which may be missed if transvaginal ultrasound is not performed.



TERMINOLOGY

Abbreviations

- Placenta previa (PP)
- Low-lying placenta (LLP)

Definitions

- Placenta extending to or covering internal os (IO) after 16 weeks
- New revised classification with 3 categories only
 - PP: Placenta covers IO
 - LLP: Placenta edge \leq 2 cm from IO
 - Normal: Placenta edge $>$ 2 cm from IO
- Previous classification with marginal and partial PP deemed confusing

IMAGING

Ultrasonographic Findings

- Placenta located in lower uterine segment (LUS)
 - Seen on routine transabdominal sagittal LUS image
 - \uparrow echoes between cervix and fetus
 - Nonengaged, "floating" presenting fetal part
 - Transvaginal ultrasound (TVUS) essential for diagnosis
 - Measurements of edge to IO only valid on TVUS
- $>$ 90% of 2nd-trimester LLP and PP will resolve
 - Often asymptomatic, recommend follow-up at 32 weeks
- **Complete PP:** Symmetric vs. asymmetric
 - Symmetric complete PP
 - Placenta centrally implanted on cervix
 - Will not resolve with advancing pregnancy
 - Asymmetric complete PP
 - Edge of placenta crosses IO
 - May resolve with advancing pregnancy
 - If $>$ 10 mm crosses IO, then less likely to resolve
- **LLP:** All other cases with placenta edge \leq 2 cm from IO
 - Includes previously called marginal and partial PP
- **Marginal sinus PP:** Subset of LLP
 - Placental veins at edge of placenta are \leq 2 cm from IO
 - Maternal veins, not fetal
 - Do not confuse with vasa previa
 - Placental parenchyma may be $>$ 2 cm from IO
- **Important PP associations**
 - Placenta accreta spectrum
 - 5% of PP have associated accreta/percreta
 - \uparrow risk if prior cesarean section + anterior PP
 - \uparrow risk with \uparrow number of prior cesarean sections
 - Look for disrupted myometrial zone
 - Look for placental lacunae
 - Tornado-shaped venous spaces in placenta
 - Vasa previa in 2 scenarios with LLP
 - Velamentous cord insertion + LLP
 - Fetal vessels cross IO
 - Succenturiate lobe (accessory placenta)
 - Main lobe or succenturiate lobe may be low lying
 - Fetal vessels travel between placentas and cross IO
 - Color Doppler shows crossing vessels
 - Pulsed Doppler to diagnose fetal vessels

Imaging Recommendations

- Best imaging tool
 - TVUS to identify placental relationship to IO
 - Transabdominal is adequate for screening
 - Show edge $>$ 4 cm from IO
- Protocol advice
 - TVUS if high-risk patient or LUS not seen clearly
 - Scan while carefully inserting probe
 - Measure cervical length
 - Measure distance between placenta edge and IO
 - Use Doppler to look for low-lying vessels
 - Differentiate fetal from maternal

DIFFERENTIAL DIAGNOSIS

Full Maternal Bladder

- Approximates anterior and posterior uterine wall
 - Normally implanted placenta appears low
- Falsely elongates cervix

Focal Myometrial Contraction

- May mimic placenta
 - Can appear mass-like and echogenic
- Contraction can cause approximation of uterine walls
 - Similar to maternal full bladder
- Resolves with time
- TVUS can often differentiate cervix from contraction
 - Slip of fluid seen at IO

Placental Abruption

- Premature placental detachment
 - Often with accompanying clot
- Acute clot often isoechoic to placenta
 - Marginal abruption near IO may mimic PP
- Color Doppler helpful
 - No flow in clot

PATHOLOGY

General Features

- Etiology
 - Abnormal implantation
 - Endometrial damage from any cause
 - Blastocyst implants low
 - Poor placental migration because of impaired LUS stretch
 - LUS with cesarean section scar
 - Placental migration rate is \sim 5 mm/week
 - PP may resolve 2° to trophotropism
 - Atrophy in areas of poor blood supply (i.e., LUS)
 - Growth in areas of better blood supply
- Associated abnormalities
 - 2x \uparrow risk for growth restriction in multiparous women
 - Vasa previa
 - Placenta accreta
 - Abruption

Staging, Grading, & Classification

- New revised classification
 - PP: Placenta margin covers IO
 - LLP: Placenta edge \leq 2 cm from IO

- Normal: Placenta edge > 2 cm from IO
- Traditional classification thought to be confusing
 - Complete PP
 - Placenta completely covers IO
 - Symmetric or asymmetric
 - Partial PP
 - Placenta partially covers IO
 - Marginal PP
 - Placenta just reaches margin of IO
 - LLP
 - Placenta edge within 2 cm of IO

CLINICAL ISSUES

Presentation

- Most common signs/symptoms
 - Incidental finding on routine ultrasound
 - Painless bleeding
 - ± preterm labor
- Other signs/symptoms
 - Postpartum hemorrhage
 - Placental edge within 4 cm of IO associated with ↑ risk for postpartum hemorrhage
 - Reason: LUS is weakly contractile

Demographics

- Age
 - ↑ risk with advanced maternal age
- Epidemiology
 - ↓ incidence as pregnancy advances
 - 1 of every 200 births (0.5%)
 - 2% at early 2nd-trimester scan using TVUS
 - Up to 20% if transabdominal scan only
 - High-risk patients
 - Prior cesarean section
 - In one large series, 21% with LLP or PP had ≥ 1 cesarean deliveries
 - This population also at risk for accreta
 - Prior placenta previa
 - Advanced maternal age
 - Multiparity
 - In vitro fertilization in nulliparous patient
 - Smoking

Natural History & Prognosis

- Most LLPs seen at midgestation resolve
 - Faster growth of placenta-free uterine wall compared to uterine wall covered by placenta
 - Placenta migrates out of lower uterine segment
- LLP and PP in 3rd trimester more likely to be symptomatic
 - 25% have bleeding, prompting cesarean delivery
 - 43% with postpartum bleeding
 - 18% require blood transfusion
- Characteristics of PP and LLP that are less likely to resolve
 - Complete PP crossing > 10 mm over IO
 - PP after 32 weeks
 - Thin placenta edge
 - Thick marginal PP more likely to resolve
- Marginal sinus PP more likely to bleed
 - 10x greater risk for sudden severe hemorrhage
- Excellent prognosis with appropriate management

- Maternal mortality < 1%

Treatment

- Cesarean delivery
 - Obligatory for complete PP
- Recent studies suggest trial of labor for LLP
 - 11-20 mm from IO
 - 50-75% may be able to deliver vaginally
 - 5-11 mm from IO
 - 30% may be able to deliver vaginally
 - Many institutions perform elective cesarean deliveries in these patients
 - Incidence of complications does not correlate with exact distance between placental edge and IO

DIAGNOSTIC CHECKLIST

Consider

- TVUS to rule out PP and LLP in all patients with bleeding in 2nd/3rd trimester
- Consider PP or LLP diagnosis if LUS posterior myometrium appears unusually thick
 - May be from unsuspected posterior succenturiate lobe
 - At risk for vasa previa

Image Interpretation Pearls

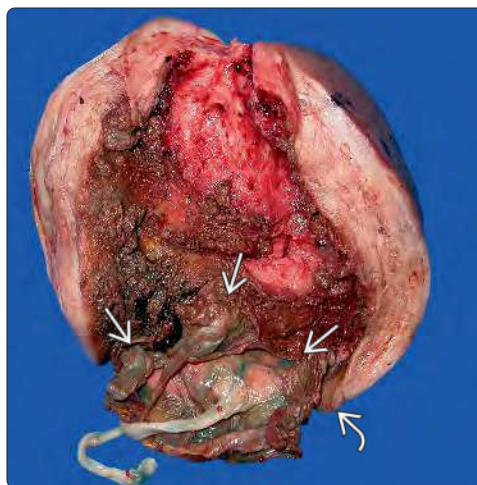
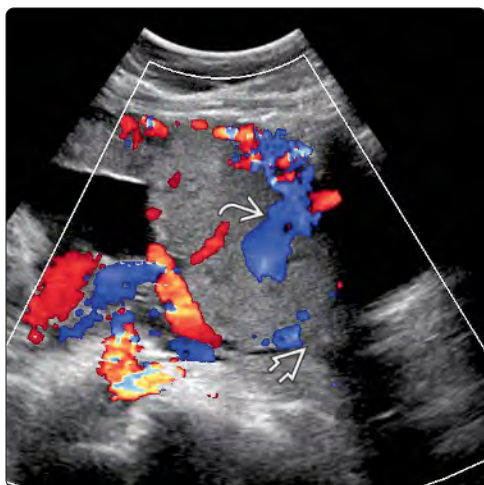
- Rule out vasa previa in all cases with PP
 - Find placental cord insertion site
 - Rule out low velamentous cord
 - Look for succenturiate lobe
 - Use TVUS color Doppler
- Rule out accreta in all cases with prior cesarean section
 - Look for tornado-shaped placenta lacunae
 - Consider MR
- Beware of false-positive PP from full maternal bladder
 - Anterior and posterior myometrium approximate
 - Mimic cervix
 - Reimage with TVUS after patient voids

Reporting Tips

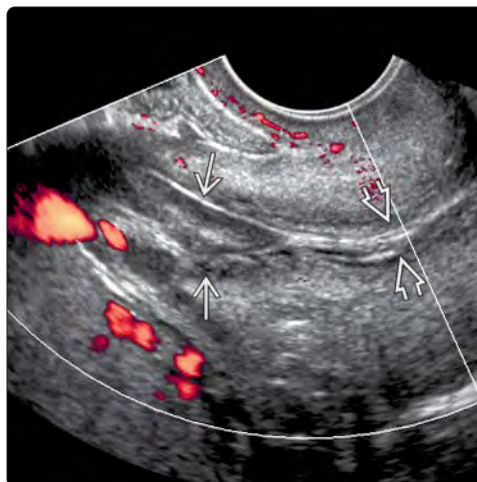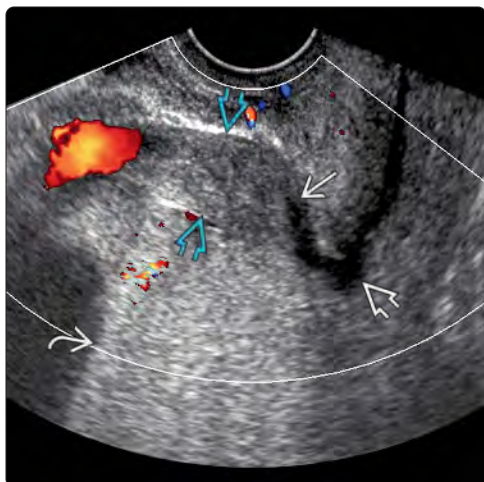
- Follow-up at 32 weeks for asymptomatic PP or LLP diagnosed in 2nd trimester
- Further follow-up at 36 weeks if persists at 32-week scan
- Earlier follow-up if symptomatic

SELECTED REFERENCES

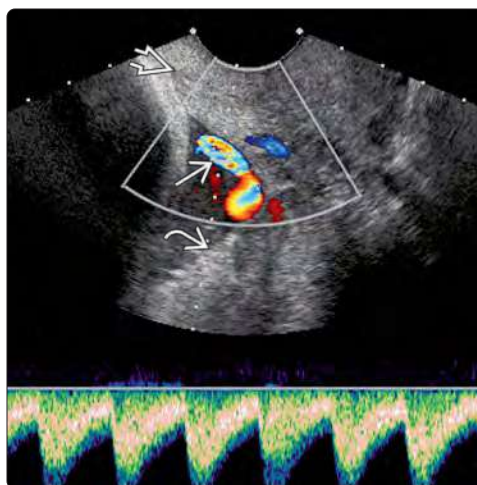
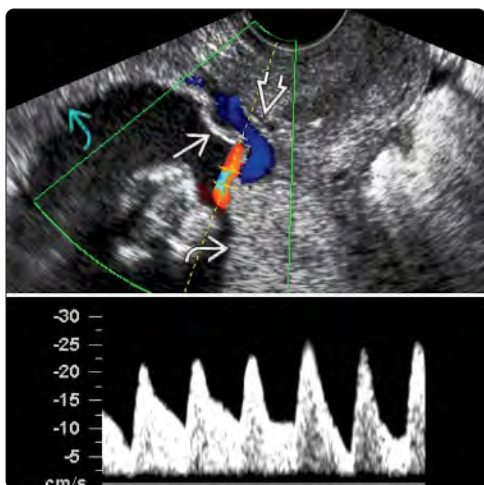
1. Silver RM: Abnormal placentation: placenta previa, vasa previa, and placenta accreta. *Obstet Gynecol.* 126(3):654-68, 2015
2. Quant HS et al: Transabdominal ultrasonography as a screening test for second-trimester placenta previa. *Obstet Gynecol.* 123(3):628-33, 2014
3. Reddy UM et al: Fetal imaging: executive summary of a joint Eunice Kennedy Shriver National Institute of Child Health and Human Development, Society for Maternal-Fetal Medicine, American Institute of Ultrasound in Medicine, American College of Obstetricians and Gynecologists, American College of Radiology, Society for Pediatric Radiology, and Society of Radiologists in Ultrasound Fetal Imaging Workshop. *J Ultrasound Med.* 33(5):745-57, 2014
4. Räisänen S et al: Placenta previa and the risk of delivering a small-for-gestational-age newborn. *Obstet Gynecol.* 124(2 Pt 1):285-91, 2014
5. Bronsteen R et al: Effect of a low-lying placenta on delivery outcome. *Ultrasound Obstet Gynecol.* 33(2):204-8, 2009
6. Oppenheimer LW et al: A new classification of placenta previa: measuring progress in obstetrics. *Am J Obstet Gynecol.* 201(3):227-9, 2009
7. Oyelese Y: Placenta previa: the evolving role of ultrasound. *Ultrasound Obstet Gynecol.* 34(2):123-6, 2009
8. Shukunami K et al: A small-angled thin edge of the placenta predicts abnormal placentation at delivery. *J Ultrasound Med.* 24(3):331-5, 2005



(Left) Color Doppler transabdominal ultrasound of PP and placenta accreta in a patient with history of 2 prior cesarean sections shows the placenta covering the internal os and vascular lacunae bridging the placenta and myometrium . **(Right)** Gross pathology of PP and placenta accreta shows the placenta attached to the lower uterine segment and cervix . Almost all cases of placenta accreta result in hysterectomy at the time of delivery.



(Left) In this patient with PP and prior cesarean section, the placenta crosses the internal os and the C-section scar . The uterine wall is otherwise intact and there is no accreta. Patients with prior cesareans are at risk for PP and low-lying placenta, even in the absence of accreta. **(Right)** In this patient with PP and bleeding, a blood clot is seen causing funneling of the internal cervical os. The mid and distal cervix is closed. Bleeding PP can lead to emergency cesarean delivery and preterm birth.



(Left) Transvaginal pulse Doppler and color Doppler view of vasa previa from the succenturiate lobe show low-lying anterior and posterior placentas with fetal vessels crossing over the internal os . **(Right)** In this case of a low-lying posterior placenta , color Doppler shows submembranous vessels within 2 cm of the internal cervical os . Pulse Doppler proves fetal arterial flow diagnostic of vasa previa. Doppler should be used in all cases with low-lying placenta to rule out vasa previa.

KEY FACTS

TERMINOLOGY

- Submembranous umbilical vessels near cervical os
 - Unprotected vessels prone to compression and tear
 - Vessel covers or < 2 cm from internal cervical os

IMAGING

- 90% associated with low-lying placenta
- Type 1: Vasa previa with velamentous cord insertion
 - Low-lying vessels from low cord insertion
- Type 2: Vasa previa with succenturiate lobe
 - Low-lying vessels travel between 1° and 2° placenta
- Transvaginal US + color Doppler are best tools
 - Pulse Doppler necessary to prove visualized vessels are fetal and not maternal in origin

TOP DIFFERENTIAL DIAGNOSES








- Marginal sinus previa
- Chorioamniotic separation
- Marginal placental abruption

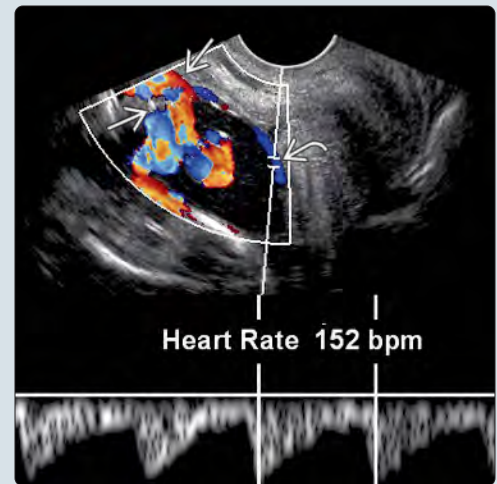
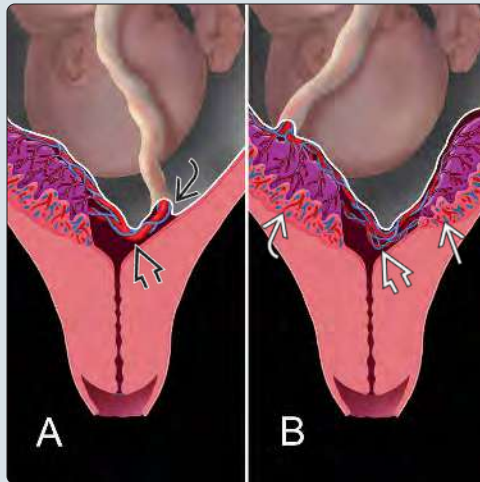
CLINICAL ISSUES








- Incidence: 1/1,200-5,000
- Likelihood ratios (LR) for high-risk patients
 - IVF patient: LR = 8
 - Placenta previa: LR = 23
 - 5% with vasa previa
 - Succenturiate-lobe placenta: LR = 22
- Prognosis depends on accurate prenatal diagnosis
 - 44-50% survival rate if VP is not diagnosed prenatally
 - 97-100% survival rate if VP is diagnosed prenatally
- Consider hospitalization at 28-32 weeks
- Consider elective C-section at 35-37 weeks

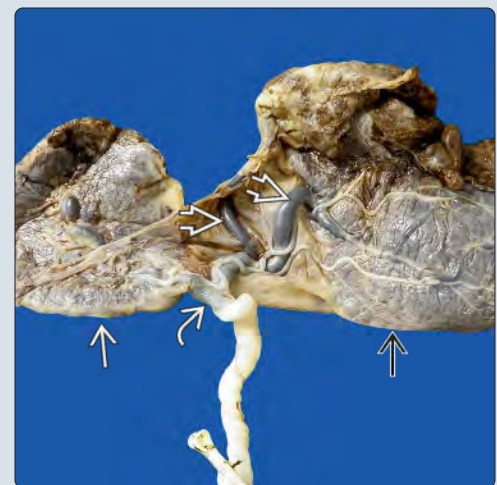
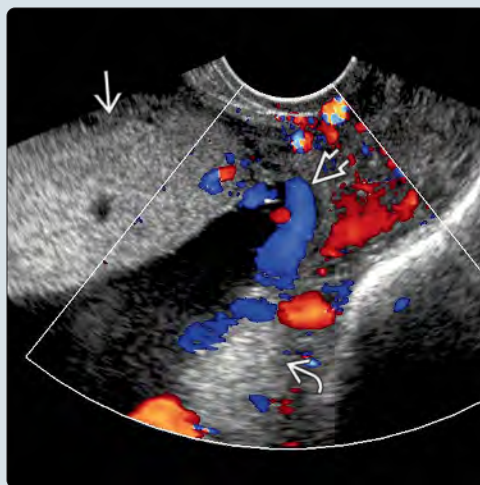
DIAGNOSTIC CHECKLIST

- Identify placental cord insertion in all cases but pay particular attention in cases with low-lying placenta
- Vasa previa diagnosis is considered critical finding

(Left) Graphic of type 1 (A) and type 2 (B) vasa previa morphology. In type 1, there is a low-lying placenta, velamentous cord insertion , and fetal vessels  near or covering the cervical os. In type 2, fetal vessels  travel over or near the os, between the main placenta  and an accessory (succenturiate) lobe . (Right) Transvaginal US of type 1 vasa previa shows a velamentous cord insertion  and a subvelamentous fetal artery  crossing the cervical internal os. Pulse Doppler proves this is a fetal vessel.



(Left) In this case, transvaginal color Doppler US shows a low-lying anterior placenta lobe  and a posterior accessory lobe  with communicating vessels  crossing the internal cervical os. The cord insertion was also velamentous and low lying in this case. (Right) The delivered placenta, in the same case, shows subvelamentous vessels  and a cord insertion , which is also velamentous and closer to the accessory lobe  than the main lobe . Note the cord immediately divides upon insertion (mangrove sign).



TERMINOLOGY

Abbreviations

- Vasa previa (VP)

Definitions

- Submembranous umbilical vessels near cervical os
 - Unprotected by Wharton Jelly and prone to compression and tear

IMAGING

General Features

- Best diagnostic clue
 - Fetal vessels < 2 cm from cervical internal os seen best with transvaginal US (TVUS) + color Doppler
- Location
 - 90% of VP associated with low-lying placenta
 - Low-lying placenta = placental margin < 2 cm from internal cervical os

Ultrasonographic Findings

- Low-lying placenta + velamentous cord insertion (VCI)
 - Cord inserts on membranes near internal cervical os
 - Any fetal vessel < 2 cm from os = VP
- Low-lying placenta with succenturiate lobe
 - Fetal vessels travel between lobes
 - Any fetal vessel < 2 cm from os = VP
- TVUS + color Doppler show fetal vessels best
 - Pulsed Doppler to prove vessels are fetal
 - Show arterial flow + document fetal heart rate
- Pitfalls
 - Cord presentation (free loop of cord)
 - Uterine/cervical varicosity (maternal venous flow)

Imaging Recommendations

- Protocol advice
 - Identify placental cord insertion routinely
 - Use TVUS and color Doppler if low-lying placenta

DIFFERENTIAL DIAGNOSIS

Marginal Sinus Previa

- Low-lying placenta with placental veins near cervix
- Normal placental cord insertion

Chorioamniotic Separation

- Linear sonolucency near os without flow

Marginal Placental Abruptio

- Blood at os may mimic placenta or vessel

PATHOLOGY

General Features

- Associated abnormalities
 - In vitro fertilization (IVF), monozygotic twins, abnormal placentation (any cause)

Staging, Grading, & Classification

- Type 1: VP from VCI
- Type 2: VP from succenturiate lobe

CLINICAL ISSUES

Presentation

- Most common signs/symptoms
 - Asymptomatic presentation
 - VP identified during routine US
 - Clinical palpation of vessel over intact membranes
 - Symptomatic presentation
 - Cord compression → heart decelerations, bradycardia
 - Neonatal morbidity and mortality from hemorrhage

Demographics

- Epidemiology
 - 1/1,200-5,000
 - 1/202 in IVF patient
 - Likelihood ratios (LR) for high-risk patients
 - IVF patients: LR = 8
 - Low-lying placenta: LR = 23
 - ◻ 5% in 1 recent series
 - Succenturiate-lobe placenta: LR = 22

Natural History & Prognosis

- 44-50% survival rate if VP is not diagnosed prenatally
- 97-100% survival rate if VP is diagnosed prenatally

Treatment

- Consider hospitalization at 28-32 weeks
 - Steroids for lung maturation
- Consider elective C-section at 35-37 weeks

DIAGNOSTIC CHECKLIST

Consider

- Prenatal diagnosis of VP is critical
- High index of suspicion in all cases with low-lying placenta

Image Interpretation Pearls

- Identify placental cord insertion in all patients
 - Special attention in high-risk patients
- Placental cord insertion site may not be focal with VCI
 - VCI mangrove sign is common
 - Large branching vessels immediately at insertion
 - Like exposed roots of mangrove tree
- Use color Doppler with transvaginal US in all cases with low-lying placenta
 - May not see vessels with grayscale alone
- Use pulsed Doppler if crossing vessels seen
 - Differentiate fetal vessels from maternal vessels

Reporting Tips

- Presence of VP is considered critical finding
- All appropriate caretakers should be notified immediately

SELECTED REFERENCES

1. Matsubara S et al: Vasa previa: Another ultrasound sign and caution at cesarean section. *J Matern Fetal Neonatal Med.* 1-2, 2015
2. Ruiter L et al: Systematic review of accuracy of ultrasound in the diagnosis of vasa previa. *Ultrasound Obstet Gynecol.* 45(5):516-22, 2015
3. Wortman AC et al: Bleeding complications in pregnancies with low-lying placenta. *J Matern Fetal Neonatal Med.* 1-5, 2015
4. Bręborowicz GH et al: Prenatal diagnosis of vasa previa. *J Matern Fetal Neonatal Med.* 1-3, 2014
5. Kuwata T et al: The 'mangrove sign' for velamentous umbilical cord insertion. *Ultrasound Obstet Gynecol.* 40(2):241-2, 2012

Morbidly Adherent Placenta

KEY FACTS

TERMINOLOGY

- Abnormal penetration of placental tissue beyond endometrial lining of uterus
- Imaging cannot differentiate pathological subtypes, therefore newer terms used to describe spectrum include morbidly adherent placenta (MAP), placental adhesive disorders, and abnormally invasive placenta

IMAGING

- Most sensitive US indicator of MAP is presence of large, irregular lacunae
- Dark intraplacental bands are single best MR feature
 - Focal interruption of myometrial wall is 2nd most predictive
- Uterine/placental bulging or disruption of normal inverted pear shape

TOP DIFFERENTIAL DIAGNOSES

- Uncomplicated placenta previa, placental sonolucencies

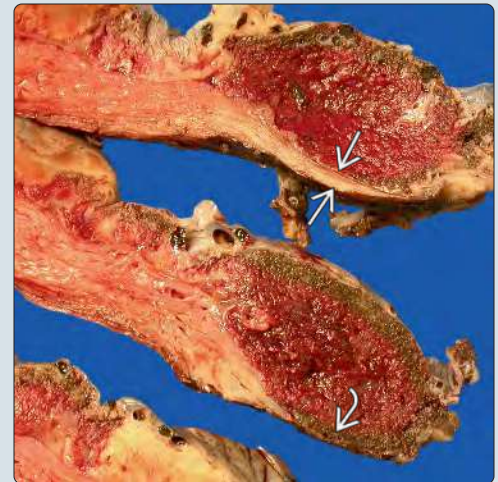
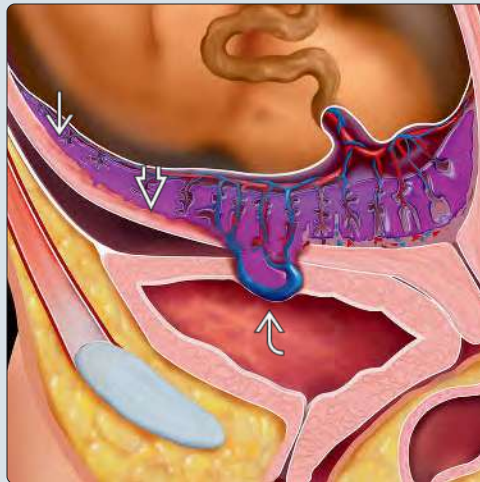
CLINICAL ISSUES

- Most important risk factors are prior cesarean section (CS), placenta previa (PP)
 - 3% in women with PP but no CS
 - 11% with PP + 1 CS, 40% with PP + 2 CS, > 60% with PP + > 3 CS
- Significant risk of maternal/fetal demise; planned delivery by multidisciplinary team results in best outcomes
- In USA, most centers plan cesarean hysterectomy at 34-35 weeks after betamethasone administration

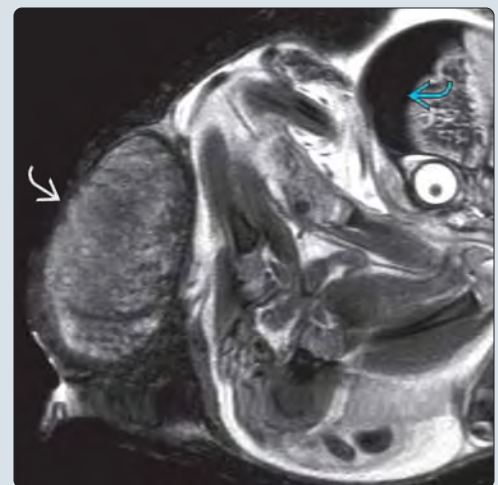
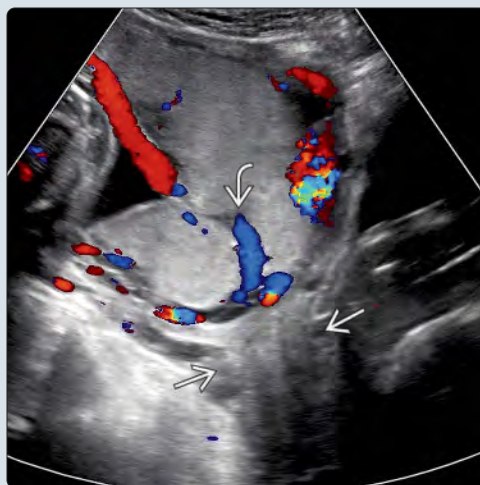
DIAGNOSTIC CHECKLIST

- High index of suspicion for MAP in setting of PP &/or prior CS with placental implantation over scar
- Be familiar with normal appearance of placenta and placental/myometrial interface on US and MR
- Look for abnormal tornado vessels, placental bands, uterine bulging as signs of MAP
 - Presence of multiple findings increases US specificity

(Left) Graphic illustrates progressively more abnormal placentation from accreta with chorionic villi attaching to the myometrium via defective decidual basalis, to increta with myometrial invasion, to percreta with myometrial breach and bladder invasion. **(Right)** Slices through a cesarean hysterectomy specimen show the placenta implanted on the thin lower uterine segment, crossing the prior C-section scar. There is focal loss of myometrium in at least one area.



(Left) Sagittal US shows a placenta previa (cervix) and 1 large tornado vessel in a 41-year-old with 1 prior C-section and a D&C. She had no desire for future fertility, and so chose planned cesarean hysterectomy. Placenta accreta was present on histology. **(Right)** Hysterectomy was performed for other reasons and the intact uterus scanned. The uterine wall subjacent to the placenta is thinned but intact. Pathology showed a placenta increta. There is an incidental fetal subdural hematoma.



TERMINOLOGY

Definitions

- Abnormal penetration of placental tissue beyond endometrial lining of uterus
 - 3 stages identified on histopathology
 - 75-80% placenta accreta: Placenta attached to myometrium without muscular invasion
 - 15% placenta increta: Chorionic villi (CV) invade myometrium
 - 5% placenta percreta: CV penetrate serosa ± invade adjacent structures
- Clinically similar and imaging cannot differentiate, therefore newer terms used to describe spectrum include
 - Morbidly adherent placentation (MAP), placental adhesive disorders, abnormally invasive placenta

IMAGING

General Features

- Must recognize normal placental findings on US and MR
- Placenta is uniform, intermediate echogenicity on US
 - Normal retroplacental hypoechoic zone or "clear zone" should be present over entire placental surface
 - Normal bladder mucosa is highly echogenic
- Placenta is homogeneous in signal intensity on MR
 - Low-signal, thin, uniformly spaced septa between cotyledons
 - Numerous flow voids just under placenta
 - 3 layered uterine wall: Low-signal, thin inner and outer layers surround thicker intermediate signal layer
 - Normal pregnant uterus has inverted pear shape with smooth contour, no focal bulging

Ultrasonographic Findings

- Grayscale ultrasound
 - Most sensitive indicator of MAP is presence of lacunae
 - Large, irregular, tornado-shaped vessels with turbulent flow in placental substance
 - Loss of retroplacental hypoechoic zone or "clear zone"
 - Often not seen in anterior placentas, can be obliterated with transducer pressure
 - Other findings associated with placental invasion
 - Interruption of bladder wall/uterine interface
 - Focal exophytic mass extending through uterine serosa, most often seen invading bladder
 - Myometrium \leq 1 mm thick
 - Placental "bulging" into myometrium
- Color Doppler
 - "Bridging vessels" extend beyond myometrium
 - Beware bladder varices as pitfall: Common in 2nd/3rd trimester

MR Findings

- T2WI
 - Dark intraplacental bands are single best feature to predict MAP
 - Abnormal vascularity: Dark T2, high-signal TRUFI
 - Randomly distributed, thick, extend from placental myometrial interface
 - Hemorrhage/infarction, seen as dark T2, dark TRUFI bands

- Focal interruption of myometrial wall is 2nd most predictive but detection varies with reader experience
- Heterogeneous placental signal intensity (beware; this normally increases with gestational age)
- Uterine/placental bulging/disruption of normal inverted pear shape
- Myometrial thinning not reliable sign of invasion
- Placenta percreta
 - Extension of intermediate signal placental tissue beyond uterine margins
 - Loss of fat planes between uterus/pelvic organs
 - Direct invasion or "tenting" of bladder
- DWI
 - May help define placental-myometrial interface
 - Myometrium low signal, placenta high signal
- T1WI FS may be used to show foci of hemorrhage

Imaging Recommendations

- Best imaging tool
 - Ultrasound primary diagnostic tool for MAP
 - MR may be better for posterior placenta, prior uterine surgery/injury
- Protocol advice
 - Use highest resolution transducer to assess uterine wall
 - Use transvaginal ultrasound with Doppler for previa/anterior placenta
 - Have bladder partly full for easier evaluation of uterine interface

DIFFERENTIAL DIAGNOSIS

Uncomplicated Placenta Previa

- Normal homogeneous placental echogenicity

Placental Sonolucencies

- Round in shape, decrease in size/disappear with change in patient position

PATHOLOGY

General Features

- Most important risk factors are prior cesarean section (CS), placenta previa (PP)
 - 3% in women with PP but no CS
 - 11% with PP + 1 CS, 40% with PP + 2 CS, > 60% with PP + > 3 CS
 - About 1% if > 3 prior CS without PP

CLINICAL ISSUES

Presentation

- Classical presentation was uncontrollable hemorrhage at time of attempted placental separation
- Prospective prenatal diagnosis now more likely

Demographics

- Epidemiology: 1:500 to 1:2,500 deliveries
- Prevalence has increased 10x over last 50 years
 - True prevalence difficult to estimate; underestimated by pathologic studies, overestimated by purely clinical diagnoses
 - Variability largely based on cesarean section rates

2D Grayscale Sonographic Features of MAP

Imaging Feature	Suggested Definition
Loss of clear zone	Loss, or irregularity, of hypoechoic plane in myometrium underneath placental bed
Abnormal placental lacunae	Presence of numerous lacunae including some that are large and irregular often containing turbulent flow visible in grayscale imaging
Bladder wall interruption	Loss or interruption of bright bladder wall (hyperechoic band or line between uterine serosa and bladder lumen)
Myometrial thinning	Thinning of myometrium overlying placenta to < 1 mm or undetectable
Placental bulge	Deviation of uterine serosa away from expected plane, caused by abnormal bulge of placental tissue into neighboring organ, typically bladder; uterine serosa appears intact but outline shape is distorted
Focal exophytic mass	Placental tissue seen breaking through uterine serosa and extending beyond it; most often seen inside filled urinary bladder

These are the standard descriptors proposed by the European Working Group on Abnormally Invasive Placenta.

Collins SL et al: Proposal for standardised ultrasound descriptors of abnormally invasive placenta (AIP). *Ultrasound Obstet Gynecol.* ePub, 2015.

US Scoring for Evaluation of Suspected MAP

Stage	Loss of Clear Zone	Number of Lacunae	Bladder Interface Interruption
0	No	0	No
1	< 1 cm &/or	1	No
2	1-2 cm &/or	> 2	No
3	> 2 cm &/or	> 2	Yes

Use of a simple prenatal scoring system is suggested as an aid to prenatal risk assessment. Stage 0: Normal placentation; stage 1: Low probability of MAP; stage 2: Moderate possibility of MAP; stage 3: High suspicion of MAP.

Gilboa Y et al: A novel sonographic scoring system for antenatal risk assessment of obstetric complications in suspected morbidly adherent placenta. *J Ultrasound Med.* 34(4):561-7, 2015.

- o CS rate in USA was 33% in 2011 per Center for Disease Control and Prevention

Natural History & Prognosis

- Significant risk of maternal/fetal demise
 - o High risk of catastrophic hemorrhage ± disseminated intravascular coagulation
 - o 28% postoperative infection
 - o 15% uterine rupture with placenta percreta
- Even planned cesarean hysterectomy has significant morbidity
 - o Hemorrhage requiring > 4 units blood
 - o Bladder/ureteral injury
 - o Up to 50% of women require ICU stay postoperatively

Treatment

- Planned delivery by multidisciplinary team results in best outcomes **but** only ~ 25% patients are referred based on survey from 2013
- In USA, most centers plan cesarean hysterectomy at 34-35 weeks after betamethasone administration
- More conservative options used in Europe, Canada include
 - o Triple P procedure
 - Perioperative placental localization with delivery via transverse incision above upper placental border
 - Pelvic devascularization
 - Placental nonseparation with myometrial excision, uterine reconstruction

- o Cesarean section with uterine preservation, placenta left in situ or partially removed (controversial)
 - 28.6% recurrence risk in subsequent pregnancies

DIAGNOSTIC CHECKLIST

Image Interpretation Pearls

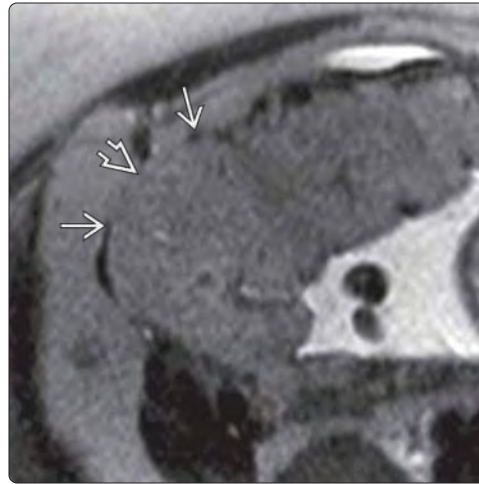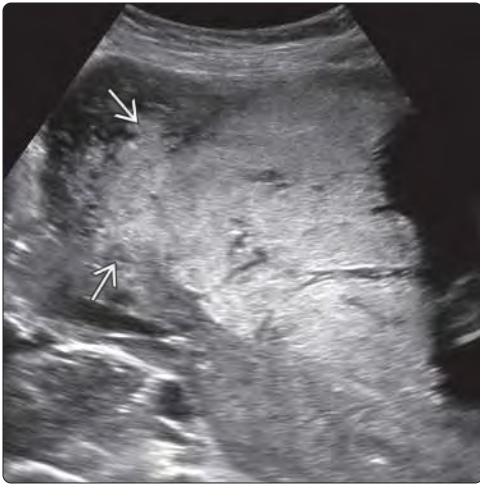
- Be familiar with normal appearance of placenta and placental/myometrial interface on US and MR
- Look for abnormal tornado vessels, placental bands, uterine bulging as signs of MAP
- Presence of multiple findings increases US specificity

Reporting Tips

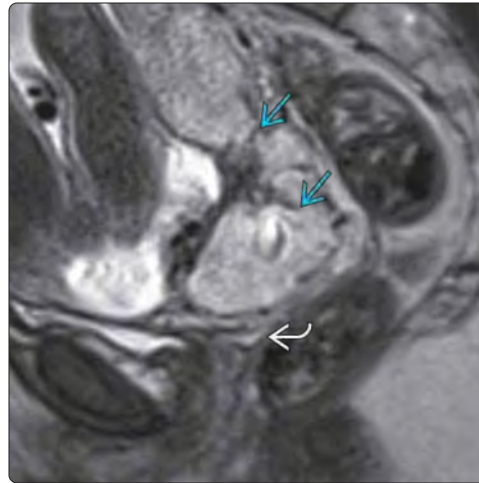
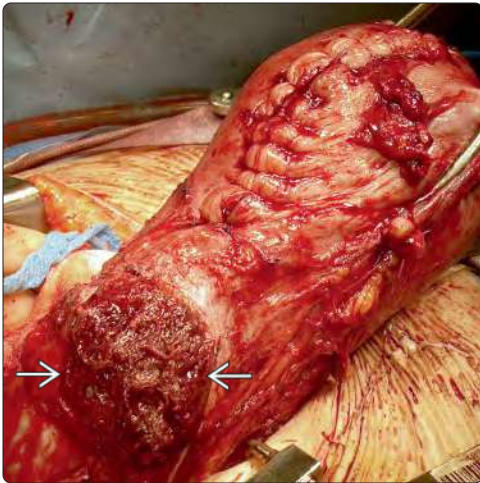
- Diagnosis challenging even for experts; technical and anatomic pitfalls abound
- High index of suspicion for MAP in setting of placenta previa &/or prior cesarean section with placental implantation over scar

SELECTED REFERENCES

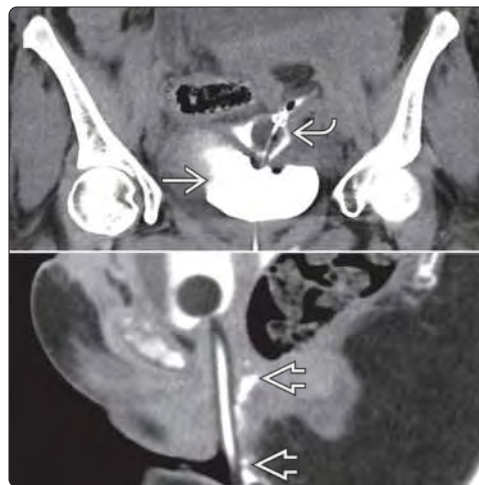
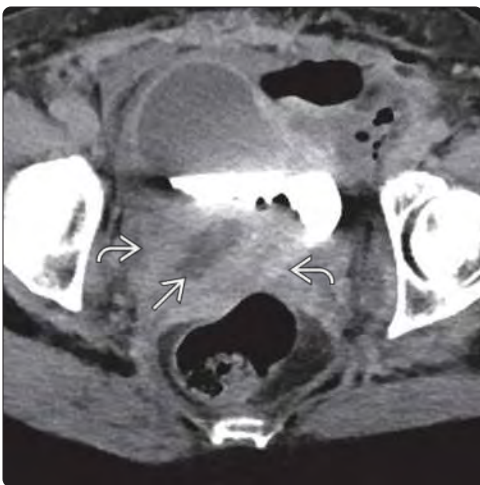
1. Bailit JL et al: Morbidly adherent placenta treatments and outcomes. *Obstet Gynecol.* 125(3):683-9, 2015
2. Silver RM et al: Center of excellence for placenta accreta. *Am J Obstet Gynecol.* 212(5):561-8, 2015
3. Bowman ZS et al: Risk factors for placenta accreta: a large prospective cohort. *Am J Perinatol.* 31(9):799-804, 2014



(Left) In a patient with a history of perforation during a D&C, the curved, 6 MHz transducer shows placental invasion into the right superior myometrium. While prior cesarean is the commonest cause of MAP, any decidual disruption increases risk. **(Right)** T2WI MR in same the case confirms sonographic finding of disruption of placental-myometrial interface. Despite the lack of low-signal myometrium, there was no frank percreta at surgery. This illustrates the difficulty of differentiating subtypes by imaging alone.



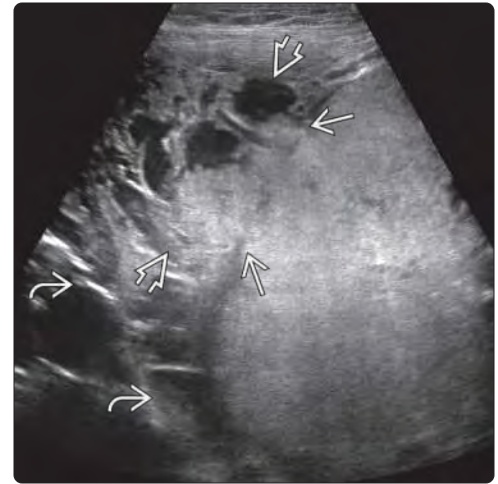
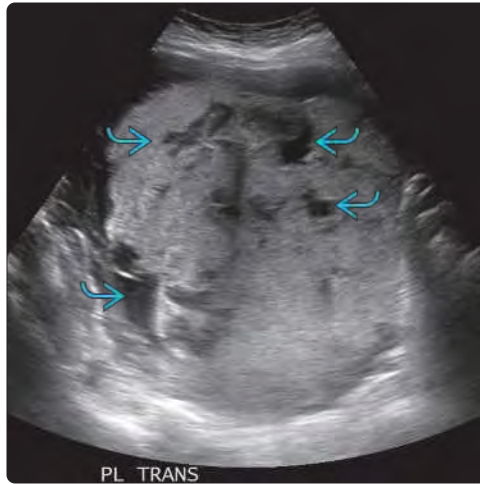
(Left) Intraoperative photograph in a different case shows frank percreta with placenta visible through a large defect in the bulging lower uterine segment. It is not uncommon for blood loss in these surgeries to reach 2,500 mL, even for planned cesarean hysterectomy. **(Right)** Sagittal T2WI MR in a different case with placenta previa and prior low posterior uterine perforation shows dark placental bands and no recognizable cervical stroma at the vaginal apex. Placenta percreta was surgically confirmed.



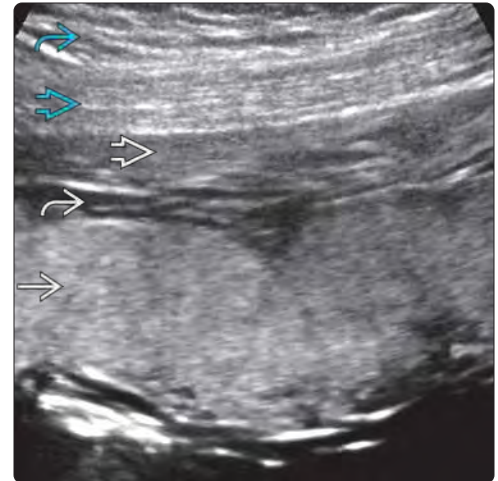
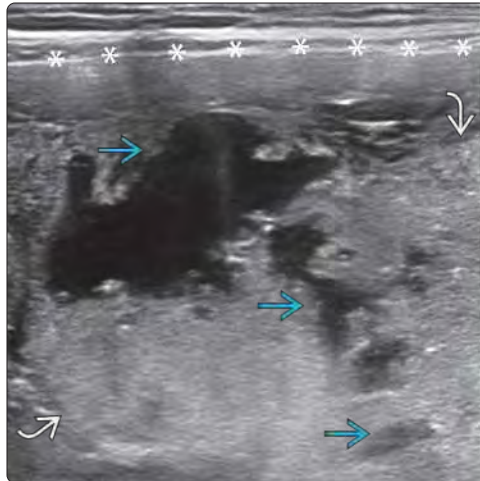
(Left) In the same patient as prior MR, a CT IVP following a technically challenging cesarean hysterectomy with significant blood loss shows a dilated right ureter surrounded by enhancing tissue thought to be residual placenta. **(Right)** Follow-up coronal CECT shows the catheter balloon outside of the bladder due to breakdown of the cystostomy required during hysterectomy. Sagittal image shows contrast in the vagina fistula due to a vesicovaginal fistula. Cesarean hysterectomy can have significant morbidity.

Morbidly Adherent Placenta

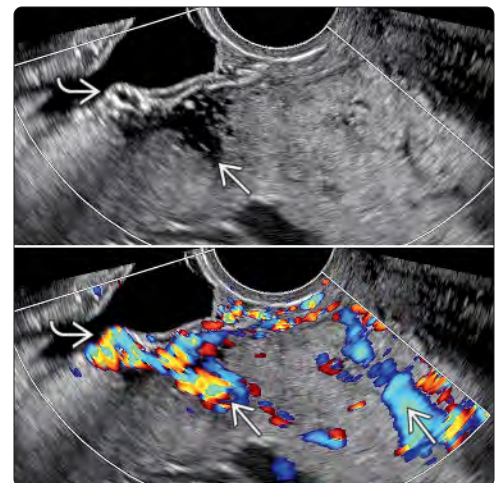
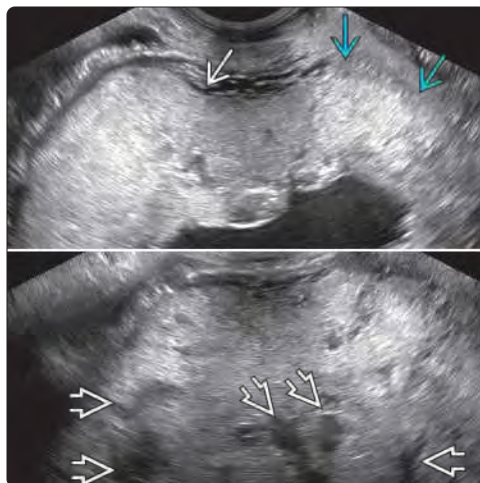
(Left) Transverse US through the lower uterine segment using curved 6 MHz transducer nicely demonstrates the abnormal placental echotexture seen with MAP. The placenta is thick, inhomogeneous, and contains multiple large vascular lacunae (blue arrows) called tornado vessels. **(Right)** In this case of a prior superolateral perforation, a linear 9 MHz transducer was used to obtain high-resolution images of the myometrial disruption (white arrows) and extension of placenta (white arrows) into the parametrium (white arrows).

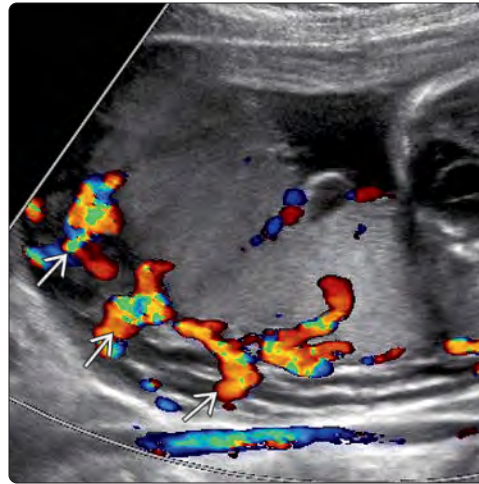
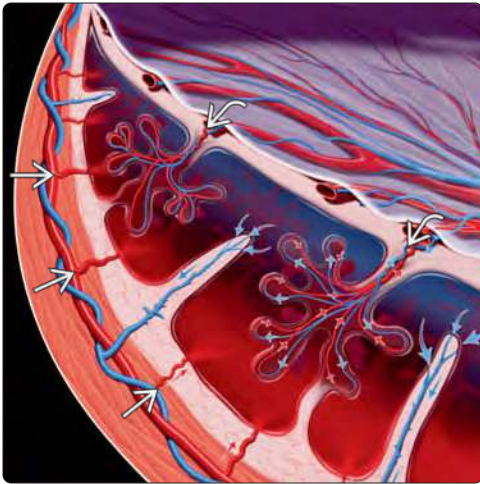


(Left) Always use the highest resolution transducer available to obtain the most information. In this case, placental tissue (white arrows) with tornado vessels (blue arrows) is within millimeters of the abdominal wall (asterisks). **(Right)** Contrast the appearance in prior image with this normal case. The anterior placenta (white arrows), subplacental vessels (white arrows), myometrium (white arrows), abdominal wall muscles (white arrows), and subcutaneous fat (white arrows) are easily distinguished. Preoperative mapping of the placenta is used to plan both skin and uterine incision placement.

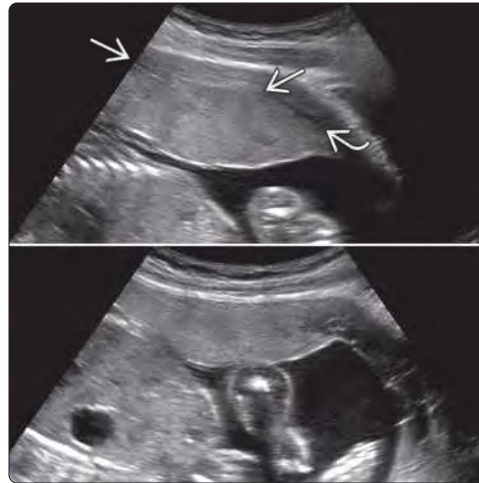
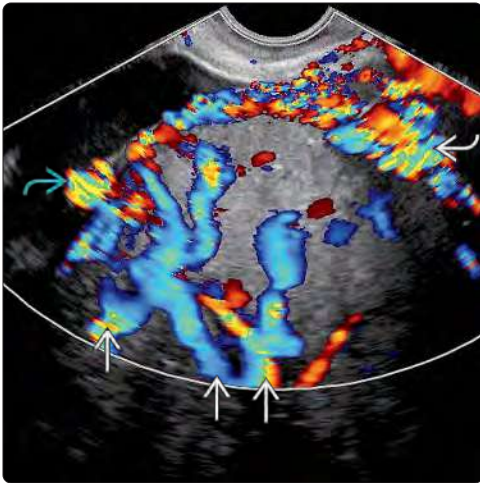


(Left) Vaginal ultrasound is excellent for suspected MAP associated with placenta previa and prior cesarean section. The upper image shows a placental "bulge" (white arrows) and loss of the subplacental hypoechoic zone (white arrows). The lower image shows a thick placenta with homogeneous echotexture and multiple lacunae (white arrows). **(Right)** In this patient with a history of endometrial ablation and prior D&C, transvaginal US shows lacunae/tornado vessels (white arrows) and "bridging vessels" traversing the placenta to enter the bladder wall (white arrows).

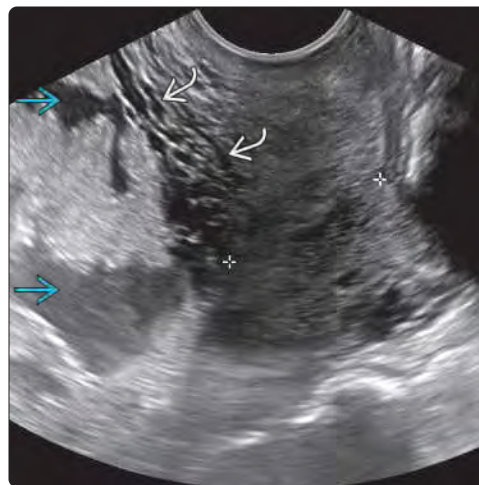
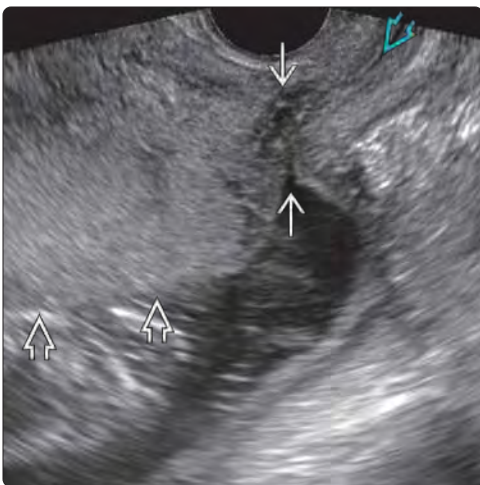




(Left) Graphic illustrates placenta vasculature; uteroplacental blood flow at term is estimated to be 750 mL/min. The maternal spiral arteries supply a vascular space into which chorionic villi "dangle," allowing for efficient gas exchange. (Right) Color Doppler US shows normal vascular pattern with multiple maternal vessels supplying the placenta, demarcated by the decidua basalis. It is a good idea to look at normal placental blood flow in order to have a visual reference for abnormal flow in the setting of MAP.



(Left) Transvaginal US in a case of MAP shows many large tornado vessels in the substance of the placenta and increased, disordered flow at the level of the decidual basalis and bladder wall. Be careful with the color gain settings and avoid "color bleed," which can cause confusion. (Right) Excessive transducer pressure (lower image) can obscure the normal placental-myometrial interface and obliterate the subplacental hypoechoic zone, a technical pitfall. This sign of MAP is extremely subjective.



(Left) Be sure of the incision type for prior C-sections. A low transverse scar may be visible on TVUS, as in this case in which the placenta ends just shy of the scar, without evidence of invasion. Classical scars are midline and best imaged abdominally. The cervical canal is noted. (Right) TVUS shows tornado vessels and innumerable subplacental vascular spaces severely distorting normal anatomy in this patient with placenta previa and multiple prior low transverse incisions. Calipers mark cervical canal.

KEY FACTS

TERMINOLOGY

- Placental lake (PL)
 - Avillous vascular space with blood flow
- Intervillous thrombus (IVT)
 - Avillous vascular space with thrombus or fibrin

IMAGING

- Homogeneous sonolucencies in placenta
 - Surrounded by otherwise normal placenta
- PL with slow swirling streams of blood
 - Seen best with grayscale imaging
 - May change appearance and size during exam
- IVT without flow
 - Does not change size or appearance
- Large, multiple, or early sonolucencies may be significant
- Distinguish simple PL from far more extensive vascular lacunae seen in placenta accreta

TOP DIFFERENTIAL DIAGNOSES





- Chorioangioma
- Gestational trophoblastic neoplasia
- Placental abruption

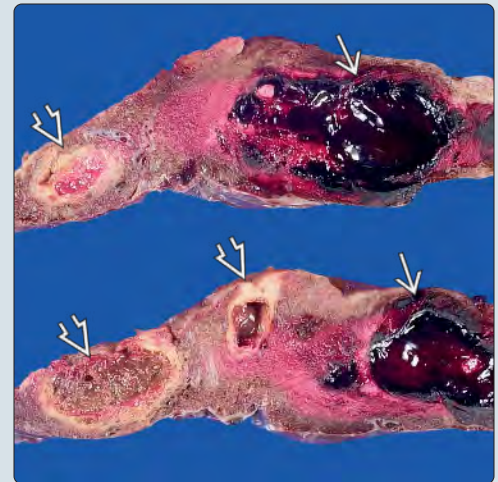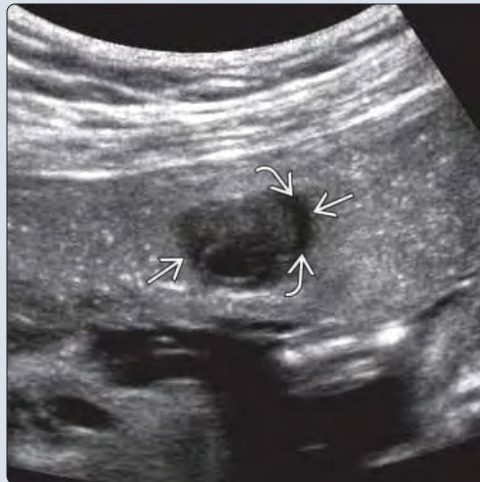
CLINICAL ISSUES




- Most often incidental finding with excellent prognosis
 - 2-18% prevalence on 2nd-trimester scan
- Associated with maternal hypertensive disorders
- ↑ risk for placental insufficiency when extensive
 - Fetal growth restriction
 - Oligohydramnios
 - Abnormal fetal Doppler values

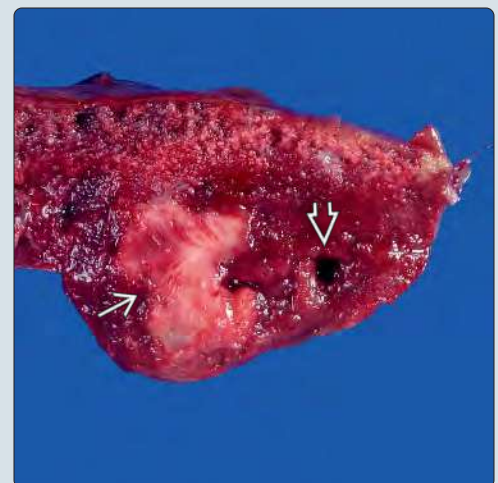
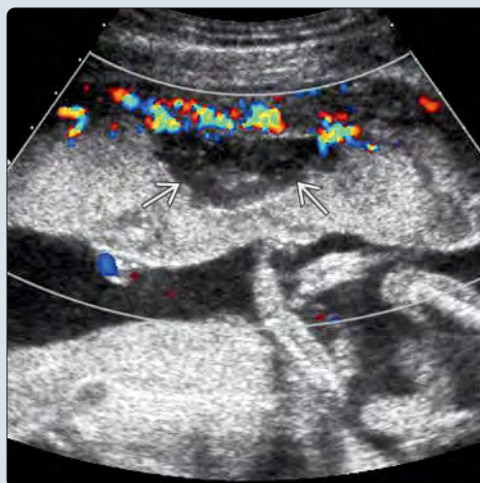DIAGNOSTIC CHECKLIST

- Follow-up ultrasound for early, large, multiple lesions
 - < 25 weeks at presentation
 - > 5 cm in size
 - > 3 in number

(Left) An intervillous thrombus (IVT)  with a retracting blood clot and adjacent sonolucent serum  is seen surrounded by an otherwise normal placenta. **(Right)** This small placenta with IVT and infarcts exemplifies the association between the 2 and the risk for placental insufficiency when large and multiple placental lesions are seen. A large IVT  is seen as well as multiple older infarcts , which are mostly focal areas of fibrosis. (From DP: Placenta.)



(Left) A large retroplacental IVT  is seen in the anterior placenta of a dichorionic twin gestation. No swirling flow was seen on grayscale imaging and no flow is seen with color Doppler. **(Right)** Gross pathology of a different placenta shows both a fibrotic IVT  and a small placental lake . Even though they are both hypoechoic lesions on ultrasound, the fluid nature of the lake will show sluggish flow, while none is seen in the fibrotic IVT. (From DP: Placenta.)



TERMINOLOGY

Abbreviations

- Placental lakes (PL)
- Intervillous thrombus (IVT)

Synonyms

- Placental sonolucencies
- Venous lakes

Definitions

- PL: Avillous vascular space with blood flow
- IVT: Avillous vascular space with thrombus or fibrin

IMAGING

General Features

- Best diagnostic clue
 - Sonolucent or hypoechoic foci in placenta
- Location
 - Central or basal PL
 - Surrounded by normal placenta
 - Subchorionic PL
 - Along fetal surface of placenta
 - May bulge into amniotic cavity
- Size
 - > 2 x 2 cm for diagnosis
 - > 5 cm considered large
 - PL may change size during scan
- Morphology
 - Round, oval most common

Ultrasonographic Findings

- Homogeneous sonolucencies in placenta
 - Multiple lesions are common
 - Bordered by otherwise normal placenta
- Swirling streams of blood seen in PL
 - Seen best with real-time grayscale imaging
 - Flow is swirling, slow, turbulent
 - Color Doppler often negative
 - Power Doppler may show flow
 - Set color scale low (≤ 0.6 kHz)
 - Filter to eliminate wall motion
 - Occasional fluid-fluid level seen
 - Red blood cells settle in serum
- PL shape and size often change during exam
 - Change in maternal position
 - 2° to uterine contraction
- IVT appearance
 - Hypoechoic more likely than sonolucent
 - No swirling seen on grayscale
 - No flow on Doppler
 - IVT does not change size during exam
 - IVT and PL often seen together in same placenta
- PL and IVT more often seen in thick placentas
 - Placenta > 3 cm is 6x more likely to have sonolucencies
- Early, numerous, and large sonolucencies may be significant
 - If < 20-25 weeks: > 3 lesions, > 3 cm
 - If > 25 weeks: > 3-5 lesions, > 5 cm
- Placental mesenchymal dysplasia is rare subset
 - 0.02% of pregnancies

- Innumerable sonolucencies in thick placenta
 - Mimics gestational trophoblastic neoplasia (GTN)
 - Often need amniocentesis to rule out GTN
- Severe fetal growth restriction (FGR)
 - ↑ fetal morbidity and mortality

MR Findings

- T1WI
 - PL: ↓ intensity (flow)
 - IVT: ↑ intensity (thrombus)
- T2WI
 - PL and IVT often isointense

Imaging Recommendations

- Best imaging tool
 - Evaluate entire placenta in 2nd and 3rd trimester
- Protocol advice
 - Look for swirling blood in sonolucencies
 - Document with cine loops if indicated
 - Helps differentiate PL from other masses
 - PL and IVT are most often incidental findings
 - Follow-up not necessary if
 - Occasional lesions
 - Normal fetal growth and fluid
 - 3rd-trimester placenta
 - Large, multiple, or early sonolucencies may be significant
 - Rule out FGR
 - Assess amniotic fluid
 - Consider umbilical artery Doppler evaluation
 - Rule out GTN if thick cystic placenta
- Distinguish simple PL from far more extensive vascular lacunae seen in placenta accreta
 - Bizarre, irregular, tornado-shaped
 - Parallel, linear vascular bands

DIFFERENTIAL DIAGNOSIS

Chorioangioma

- Benign vascular tumor
 - Flow easily seen with Doppler
- Solitary circumscribed, solid mass
- Often near umbilical cord origin

Gestational Trophoblastic Neoplasia

- Partial mole/triploidy
 - Placenta often cystic
 - Fetus with severe FGR ± anomalies
- Complete hydatidiform mole
 - Diffusely cystic placenta
 - No fetus or embryo
 - Paternal chromosomes
- Coexistent mole
 - Complete mole + normal twin
 - 2 placentas are present
 - Normal placenta with normal fetus
 - Cystic placenta without fetus

Placental Abruptio

- Preplacental abruptio can mimic PL
 - Bulges into amniotic cavity, no blood flow
- Marginal and retroplacental abruptio

- Hypoechoic blood clot from placenta
- Old blood becomes sonolucent
- Patients tend to be symptomatic
 - Bleeding, preterm labor

PATHOLOGY

General Features

- Etiology
 - Chorangiomas
 - Villous hypervascularization in terminal villi
 - PL contains only maternal blood
 - Islands of red blood cells in lake of serum
 - Normal oxygen exchange in PL
 - Role of PL in normal pregnancy
 - PL regulates placental pressure
 - ↑ intervillous space helps equalize pressure
 - IVT from thrombosis of PL
 - ↑ IVT associated with infarction
 - ↑ adjacent villous infarction
 - ↑ fibrin deposits
- Genetics
 - Not associated with fetal aneuploidy
- Associated abnormalities
 - More common with large PL (> 5 cm) &/or extensive placental involvement
 - FGR
 - Maternal hypertensive disorders
 - Antiphospholipid syndrome
 - Elevated maternal serum α-fetoprotein (AFP)
 - Placental abruption
 - 1st-trimester bleeding (threatened abortion)
 - Increased incidence of PL and IVT reported

Staging, Grading, & Classification

- Phenotypical classification by location
 - Retroplacental
 - Subchorionic
 - Full thickness
 - Lake previa
 - PL in low-lying placenta with lake in front of cervix

Gross Pathologic & Surgical Features

- 25% of placentas with PL have additional IVT and infarct seen on postdelivery pathologic assessment
- Placental mesenchymal dysplasia (rare)
 - Mesenchymal stem villous hyperplasia
 - Enlarged cystic placenta with dilated chorionic vessels

CLINICAL ISSUES

Presentation

- Most common signs/symptoms
 - Most often incidentally noted in normal pregnancy
 - Hypertensive patient
 - Antiphospholipid syndromes
 - Autoimmune disorder
 - Circulating antiphospholipid antibodies
 - 2° placental thrombosis and infarction
 - In association with FGR
 - Seen in follow-up for 1st-trimester bleeding

- Other signs/symptoms
 - Elevated maternal serum AFP

Demographics

- Epidemiology
 - 2-18% incidence on 2nd-trimester scan
 - 25-40% at delivery

Natural History & Prognosis

- Most often normal finding with excellent prognosis
 - Occasional PL or IVT in 3rd trimester
- Extensive PL, IVT with ↑ risk for placental insufficiency

Treatment

- If associated with placental insufficiency, then early delivery may be necessary
- Treatment for antiphospholipid syndrome if patient meets diagnostic criteria

DIAGNOSTIC CHECKLIST

Consider

- Follow-up growth ultrasound for early, large, or extensive lesions
 - Look for signs of placental insufficiency
 - FGR, oligohydramnios, abnormal fetal Doppler values
- Rule out more significant placental lesions
 - Abruption, GTN

Image Interpretation Pearls

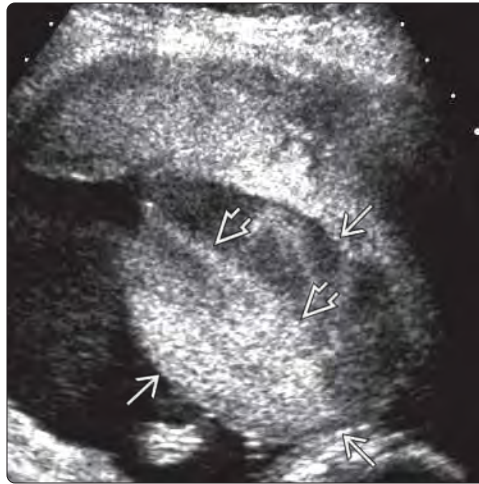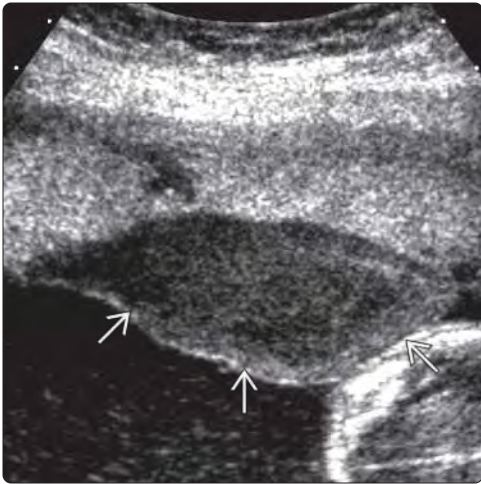
- Real-time grayscale imaging is best way to diagnose PL
 - Increase gain to see swirling blood
- Change maternal position if atypical appearance
 - Size of PL may change
 - May see fluid-fluid level shift

Reporting Tips

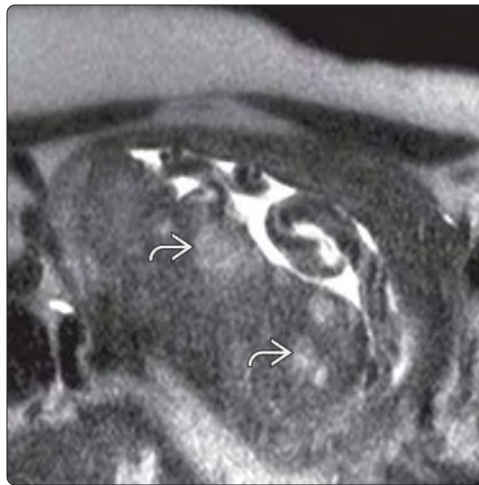
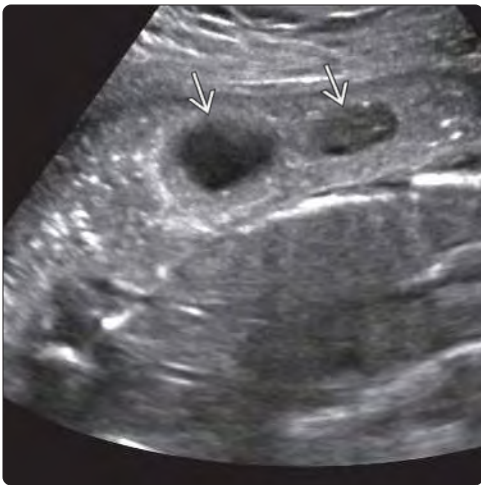- Recommend follow-up for more significant findings
 - Lesions seen < 25 weeks
 - > 5 cm PL or IVT
 - > 3 lucencies

SELECTED REFERENCES

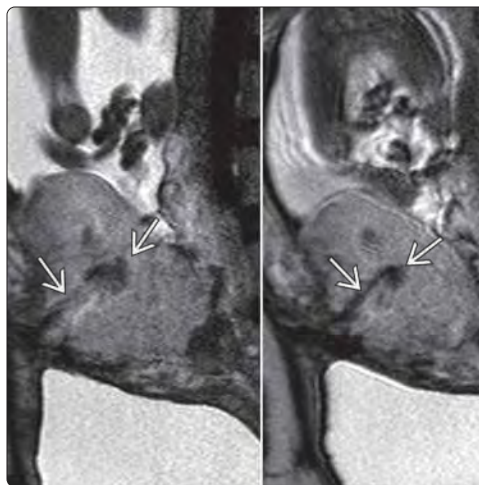
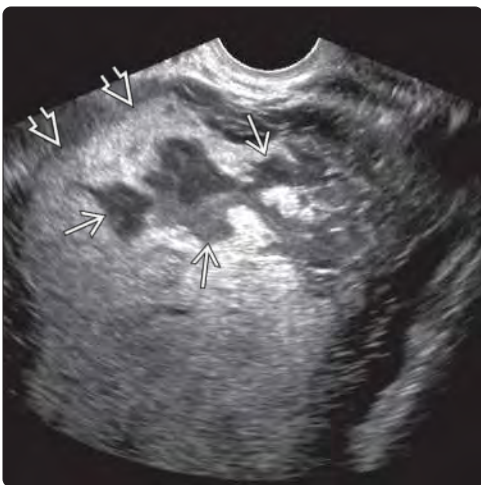1. Veerbeek JH et al: Placental pathology in early intrauterine growth restriction associated with maternal hypertension. *Placenta*. 35(9):696-701, 2014
2. Nayeri UA et al: Systematic review of sonographic findings of placental mesenchymal dysplasia and subsequent pregnancy outcome. *Ultrasound Obstet Gynecol*. 41(4):366-74, 2013
3. Hwang HS et al: The clinical significance of large placental lakes. *Eur J Obstet Gynecol Reprod Biol*. 162(2):139-43, 2012
4. Kofinas A et al: The role of second trimester ultrasound in the diagnosis of placental hypoechoic lesions leading to poor pregnancy outcome. *J Matern Fetal Neonatal Med*. 20(12):859-66, 2007
5. Morikawa M et al: Magnetic resonance image findings of placental lake: report of two cases. *Prenat Diagn*. 25(3):250-2, 2005
6. Reis NS et al: Placental lakes on sonographic examination: correlation with obstetric outcome and pathologic findings. *J Clin Ultrasound*. 33(2):67-71, 2005
7. Van Horn JT et al: Histologic features of placentas and abortion specimens from women with antiphospholipid and antiphospholipid-like syndromes. *Placenta*. 25(7):642-8, 2004
8. Moldenhauer JS et al: The frequency and severity of placental findings in women with preeclampsia are gestational age dependent. *Am J Obstet Gynecol*. 189(4):1173-7, 2003



(Left) Axial ultrasound shows a single large subchorionic placental lake . Slow swirling flow was seen at the time of ultrasound. Notice how the mass-like lake bulges into the amniotic cavity. **(Right)** This view of the same lake, later in the exam and after maternal position change, exemplifies the dynamic nature of the lesion. The lake is larger and contains a fluid-fluid level . The appearance is secondary to maternal red blood cells settling within the serum of the lake.



(Left) In this pregnancy complicated by 2nd-trimester fetal growth restriction and oligohydramnios, multiple placental sonolucencies were seen, some with flow and some without. **(Right)** T2WI MR in another case with oligohydramnios and growth restriction shows many areas of abnormal high signal throughout the placenta. Pathology of the placenta showed thrombosis of over 70% of the placental vasculature, attributed to maternal coagulopathy. The fetus died in utero.



(Left) Transvaginal ultrasound performed for placenta accreta shows tornado-shaped angular placental lesions with flow. These are more angular than typical placental lakes. The associated bulge is also seen. **(Right)** T2WI MR in the same case shows the signal void of flowing blood in the placenta lacunae . Note the linear band-like morphology on MR. While lacunae are common in normal pregnancies; however, when multiple, large, or bizarrely shaped, such as this case, close observation is warranted.

KEY FACTS

TERMINOLOGY

- Succenturiate lobe (SL): 1 or more accessory placental lobes connected by submembranous fetal vessels

IMAGING

- Grayscale shows 2 or more separate placentas
 - Color Doppler shows connecting vessels
- SL may be low lying
 - SL crosses internal os = SL previa
 - Vasa previa type 2 can occur
 - Transvaginal ultrasound (TVUS) best for diagnosis
- Protocol advice
 - Scan entire uterus before assigning placental location
 - Identify cord insertion site
 - TVUS for all low-lying placentas and all patients with unexplained bleeding
 - Look for hidden small posterior SL
 - Doppler to rule out vasa previa

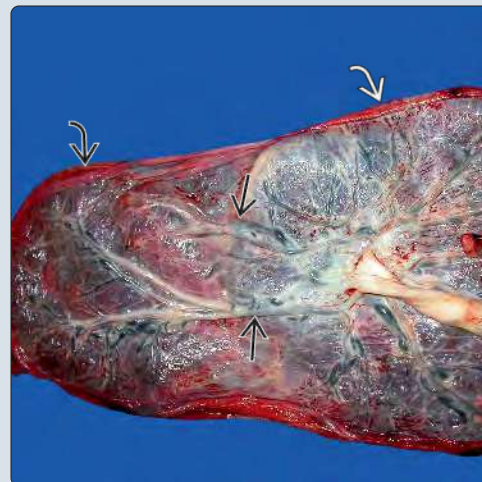
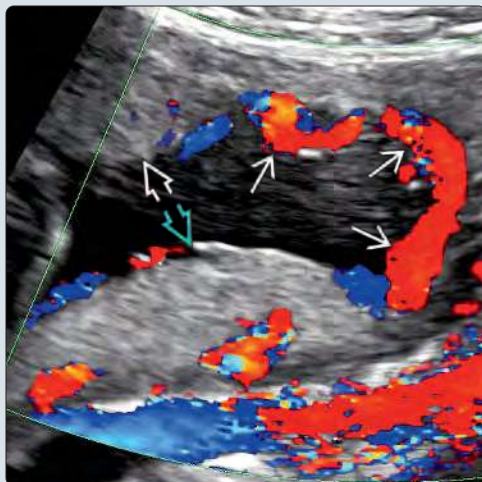
TOP DIFFERENTIAL DIAGNOSES

- Acute placental abruption
- Focal myometrial contraction

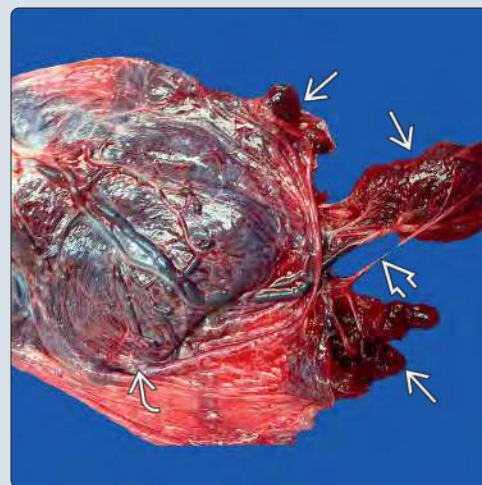
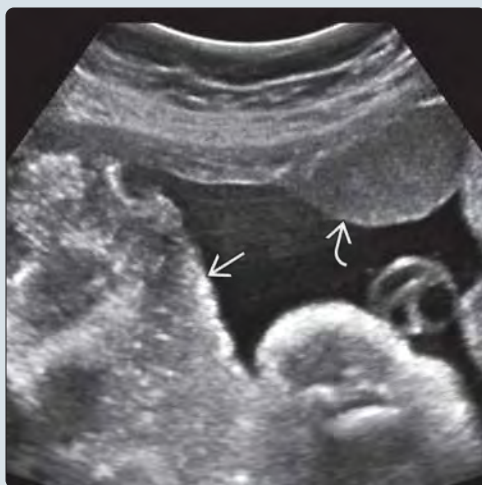CLINICAL ISSUES

- Presentation
 - Incidental finding on routine ultrasound
 - Bleeding from SL previa or vasa previa
- Incidence
 - 5-6% of all pregnancies
 - ↑ in twin pregnancies
 - ↑ with in vitro fertilization
- Excellent prognosis if isolated
 - ↑ risk for retained placenta after delivery
- SL with velamentous cord insertion has more complications
 - ↑ risk of growth restriction, ↑ risk for cord trauma
- Failure to diagnose SL with vasa previa can lead to ↑ perinatal morbidity and mortality

(Left) An anterior and posterior placenta are connected by submembranous communicating vessels carrying fetal blood. The main placental lobe in this case is posterior, and the anterior lobe is considered accessory. (Right) This gross pathology specimen of a main placental lobe and a succenturiate lobe shows large connecting submembranous vessels. These vessels are prone to tear and injure if near the cervical os.



(Left) In this 3rd-trimester case, the main placenta is large and calcified and a small homogenous succenturiate lobe is incidentally noted. (Right) Gross pathology of a placenta with several accessory lobes shows the main placental lobe connected by vessels to 3 small accessory lobes. A vessel is even seen connecting 2 of the accessory lobes. If 1 of the lobes is left behind, the patient will have symptoms from retained products of conception.



TERMINOLOGY

Abbreviations

- Succenturiate lobe (SL)

Synonyms

- Accessory placenta
- Bilobed or bilobated placenta

Definitions

- 1 or more accessory lobes apart from main placenta
 - Lobes connected by submembranous fetal vessels

IMAGING

General Features

- Best diagnostic clue
 - 2 separate placentas seen on routine ultrasound
- Location
 - Anywhere in uterus, including low-lying placenta
- Size
 - SL is smaller than primary lobe

Ultrasonographic Findings

- Grayscale ultrasound
 - 2 separate placental masses
 - Umbilical cord insertion usually on main placenta
 - Often marginal or velamentous
 - SL may be low-lying or cross internal os
 - SL crosses internal os = SL previa
 - Vasa previa type 2 can occur
 - Low-lying main placenta &/or low-lying SL
 - Communicating vessels cross internal cervical os
 - Bleeding from vasa previa is fetal blood
 - Transvaginal ultrasound (TVUS) best for diagnosis
 - Bilobate or bilobed placenta is SL variant
 - 2 equal placental masses with central thinning
 - Cord inserts on thinned area
 - Velamentous cord insertion
- Color Doppler
 - Best to identify communicating vessels

Imaging Recommendations

- Best imaging tool
 - Grayscale ultrasound to identify accessory placenta
 - Color Doppler to identify communicating vessels
 - TVUS to identify low-lying placenta and vasa previa
- Protocol advice
 - Scan entire uterus before assigning placental location
 - TVUS when placenta is low lying
 - Look for hidden posterior SL
 - Look for vasa previa
 - TVUS for all patients with unexplained bleeding
 - Look for hidden small posterior SL

DIFFERENTIAL DIAGNOSIS

Acute Placental Abruptio

- Acutely, blood is isoechoic to placenta
- Color Doppler shows no flow in hematoma

Focal Myometrial Contraction

- Can mimic SL
- Distorts inner > outer myometrium
- No submembranous connecting vessels
- Resolves with time

PATHOLOGY

General Features

- Etiology
 - Trophotropism theory
 - Parts of placenta grow and parts resorb
 - Fetal vessels originally on surface of placenta become submembranous when underlying placenta resorbs
- Associated abnormalities
 - Velamentous cord insertion
 - Vasa previa

CLINICAL ISSUES

Presentation

- Most common signs/symptoms
 - Incidental finding on routine ultrasound
 - Bleeding from SL previa or vasa previa

Demographics

- Age
 - ↑ incidence with advanced maternal age
- Epidemiology
 - 5-6% of all pregnancies
 - ↑ in twin pregnancies
 - ↑ with in vitro fertilization

Natural History & Prognosis

- Excellent prognosis if isolated
 - ↑ risk for retained placenta after delivery
- SL + velamentous cord insertion
 - ↑ risk of growth restriction, ↑ risk for cord trauma
- SL + vasa previa
 - ↑ perinatal morbidity and mortality if not diagnosed prenatally

DIAGNOSTIC CHECKLIST

Consider

- Posterior SL previa as cause for vaginal bleeding (might only see with TVUS)

Image Interpretation Pearls

- Use color Doppler to rule out complications of SL
 - Vasa previa
 - Velamentous cord insertion

SELECTED REFERENCES

1. Cavaliere AF et al: Succenturiate lobe of placenta with vessel anomaly: a case report of prenatal diagnosis and literature review. *Clin Imaging.* 38(5):747-50, 2014
2. Suzuki S et al: Abnormally shaped placentae in twin pregnancy. *Arch Gynecol Obstet.* 281(1):65-9, 2009
3. Suzuki S et al: Clinical significance of pregnancies with succenturiate lobes of placenta. *Arch Gynecol Obstet.* 277(4):299-301, 2008
4. Stafford IP et al: Abnormal placental structure and vasa previa: confirmation of the relationship. *J Ultrasound Med.* 23(11):1521-2, 2004

KEY FACTS

TERMINOLOGY

- Placental band or shelf
- Created when chorionic membrane does not insert at edge of placenta but at some inward distance from margin

IMAGING

- Thick placenta edge
- Margin of placenta rolled towards cord insertion
- Placental shelf attaches along margin of placenta

TOP DIFFERENTIAL DIAGNOSES

- Synechiae (amniotic sheets)
 - Membranes attach to uterine wall
- Amniotic bands
 - Membranes attach to fetus
- Septate uterus
 - Septum central in fundus

PATHOLOGY

- Etiology: Early placental margin insult
 - Infarct, hemorrhage, fibrin deposit
- Placenta extrachorialis
 - Chorion plate smaller than basal plate
 - Villi grow between membranes and are elevated

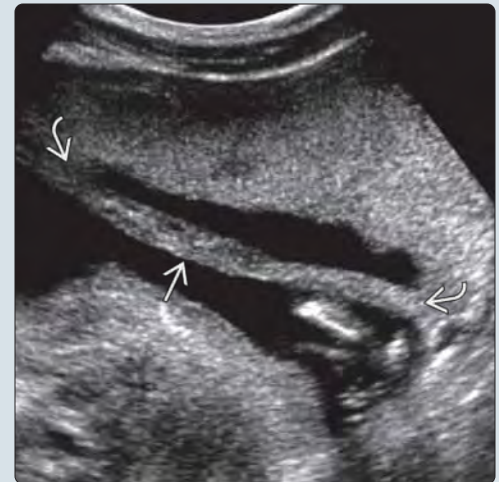
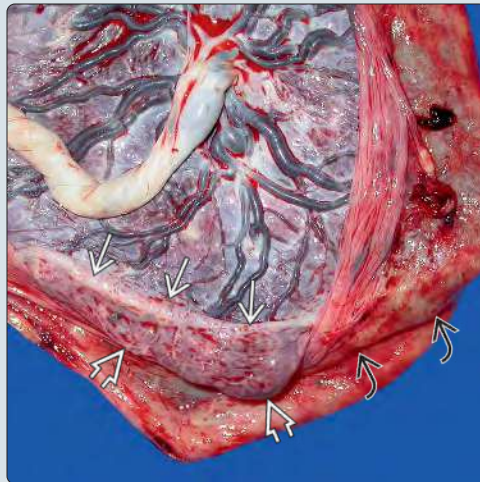
CLINICAL ISSUES

- Most often incidental finding during US
 - 0.5-18.0% incidence after delivery
- Excellent prognosis if partial and isolated
- ↑ incidence of preterm delivery, abruption, growth restriction reported
 - Complications more likely with complete circumvallate placenta (CP)

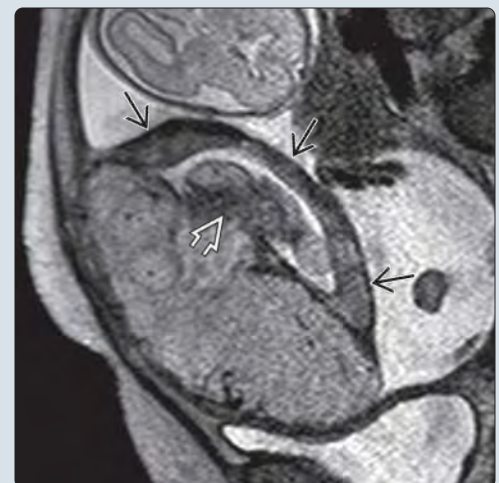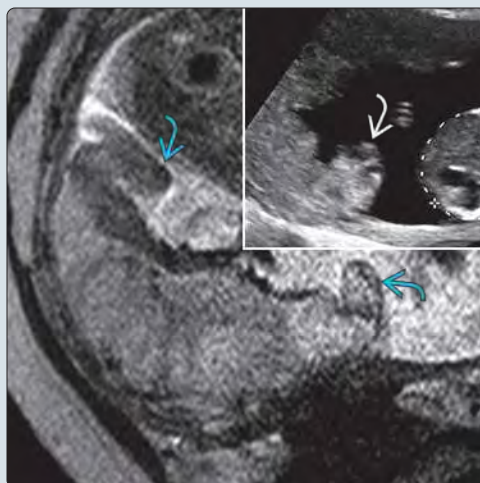
DIAGNOSTIC CHECKLIST

- Look carefully at rest of placenta and cord insertion
- Follow-up for fetal growth when > 2/3 of margin involved

(Left) Gross pathology of a circumvallate placenta shows the membranes attached to the fetal surface of the placenta, several centimeters from the true edge of the placenta. The placental tissue growing along the membranes is lifted off the main placenta (placenta extrachorialis). **(Right)** US of a circumvallate placenta shows a thick band attached to the margins of the placenta. A placental edge lift with an associated placenta-to-placenta band is the hallmark of circumvallate placenta.



(Left) A fetal MR shows a circumvallate placenta with the placental margins lifted off the uterus and curling centrally. The insert shows a similar rolled edge on a 2nd-trimester US. **(Right)** Another MR, in the same patient, shows the placental shelf extending from placental margin to placental margin. The midplacental bulge seen here has been described as a finding seen best with MR or surface 3D US, and it should not be confused for an additional placental anomaly.



TERMINOLOGY**Abbreviations**

- Circumvallate placenta (CP)

Synonyms

- Placental band or shelf
- Extrachorial placenta

Definitions

- Chorionic membrane does not insert at edge of placenta but at some inward distance from margin
 - Placenta edge is thickened and rolled up
 - Edge protrudes into uterine cavity

IMAGING**General Features**

- Best diagnostic clue
 - Shelf of tissue contiguous with placenta protrudes into uterine cavity
- Morphology
 - Usually only partial
 - Complete CP involves 100% of edge (rare)

Ultrasonographic Findings

- Elevated placental margin
 - Infolding margin is toward cord insertion site
 - Margin becomes fibrosed with time
 - Peripheral echogenic rim
- Marginal placental shelf
 - Short band of tissue attaches on placenta only
 - Within 3 cm of margin
 - Does not attach to uterine wall

Imaging Recommendations

- Protocol advice
 - Scan placental margin in orthogonal planes when suspicious of CP
 - Edge is rolled in 1 plane and appears as band in other

DIFFERENTIAL DIAGNOSIS**Synechiae (Amniotic Sheets)**

- Caused by uterine scar
 - Infolding of membrane around adhesions
- 2- to 3-mm bands
 - Often see triangular attachment point
 - May see blood flow in synechia
- Originate from any point in uterine cavity
 - Placenta may abut or adhere to synechia

Amniotic Band Syndrome

- Secondary to amniotic membrane rupture
- Amnion entraps fetus
 - Amputation, body wall defects
- Thin avascular bands
 - May involve placenta

Septate Uterus

- Septum in fundus
 - Uterine duplication anomaly
- Placenta may implant on septum

PATHOLOGY**General Features**

- Etiology
 - Early placental marginal insult
 - Hemorrhage, infarct, fibrin deposit
 - Marginal membranes tether as result
 - Discrepant size between chorion and basal plates
 - Results in raised placenta and membranes
 - Placenta extrachorialis
 - Parenchymal villous chorionic tissue
 - Beyond tethered membranes

Gross Pathologic & Surgical Features

- Pale yellow to white peripheral ring
- Fibrinoid degeneration of villi between membranes

CLINICAL ISSUES**Presentation**

- Most common signs/symptoms
 - Most often pathologic diagnosis after delivery
 - Incidental finding during US
- Other signs/symptoms
 - ↑ incidence of preterm delivery, abruption, growth restriction reported

Demographics

- Epidemiology
 - 0.5-18.0% incidence after delivery reported

Natural History & Prognosis

- Excellent prognosis if partial and isolated

DIAGNOSTIC CHECKLIST**Consider**

- Follow-up US for fetal growth when > 2/3 of margin involved

Image Interpretation Pearls

- When intrauterine membranes are seen, look carefully at attachment points
 - CP if membranes attach only on placenta
 - Synechia if membranes attach to uterine wall
 - Amniotic bands if membranes attach to fetus
- Look carefully at rest of placenta and cord insertion when CP seen
- Center of placenta may bulge towards uterine cavity
 - More commonly seen on surface rendered 3D US or MR

SELECTED REFERENCES

1. Mostafa M et al: HDlive image of circumvallate placenta. *Ultrasound Obstet Gynecol.* ePub, 2015
2. Taniguchi H et al: Circumvallate placenta: associated clinical manifestations and complications-a retrospective study. *Obstet Gynecol Int.* 2014;986230, 2014
3. Arlicot C et al: Three-dimensional surface rendering of the chorionic placental plate: the "tire" sign for the diagnosis of a circumvallate placenta. *J Ultrasound Med.* 31(2):340-1, 2012
4. Suzuki S: Clinical significance of pregnancies with circumvallate placenta. *J Obstet Gynaecol Res.* 34(1):51-4, 2008

Marginal and Velamentous Cord Insertion

KEY FACTS

TERMINOLOGY

- Marginal placental cord insertion (MPCI)
 - Umbilical cord inserts within 2 cm of placenta edge
- Velamentous cord insertion (VCI)
 - Umbilical cord inserts on membranes

IMAGING

- Marginal placental cord insertion
 - All branching vessels are on fetal surface of placenta
 - MPCI can progress to VCI if margin resorbs
- Velamentous cord insertion
 - Cord inserts at variable distance from placenta
 - Vessels often diverge immediately upon insertion and travel beneath membranes toward placenta
 - At risk for vasa previa if VCI is in lower uterine segment
- New guidelines recommend documentation of placental cord insertion in all cases
 - Reliably seen at time of nuchal translucency scan

TOP DIFFERENTIAL DIAGNOSES

- Submembranous vessels from succenturiate lobe

PATHOLOGY

- Etiology: "Trophotropism" of placenta
 - Early cord insertion is in center of chorionic disc
 - Parts of placenta grow and parts resorb
 - Cord insertion ends up marginal or velamentous
- Submembranous vessels not protected by Wharton jelly and are susceptible to injury

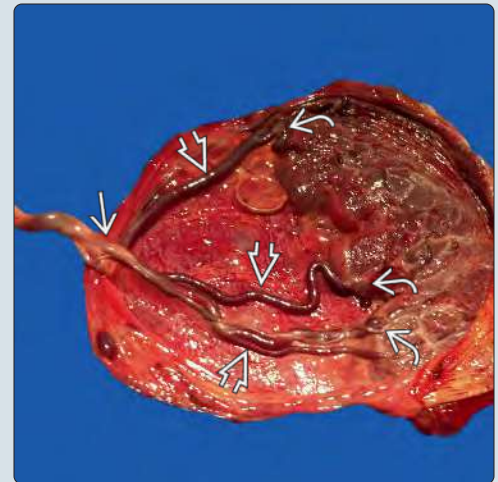
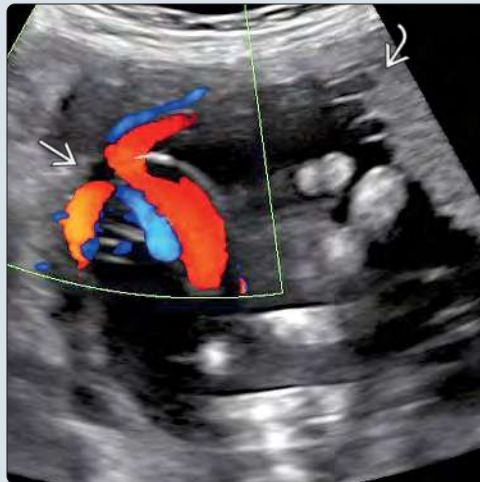CLINICAL ISSUES

- VCI incidence: 1-2% singleton, 7% dichorionic twins, up to 40% monochorionic twins
- VCI associated with ↑ risk for adverse perinatal outcome

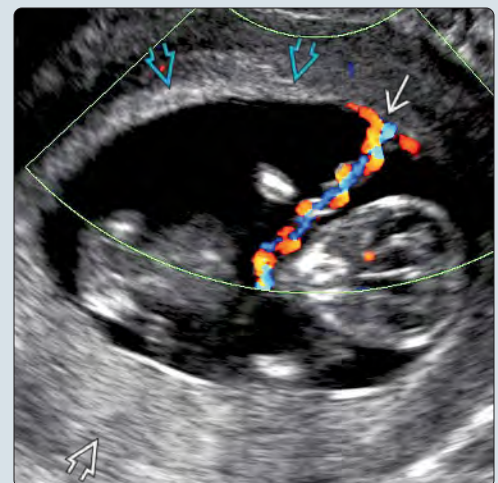
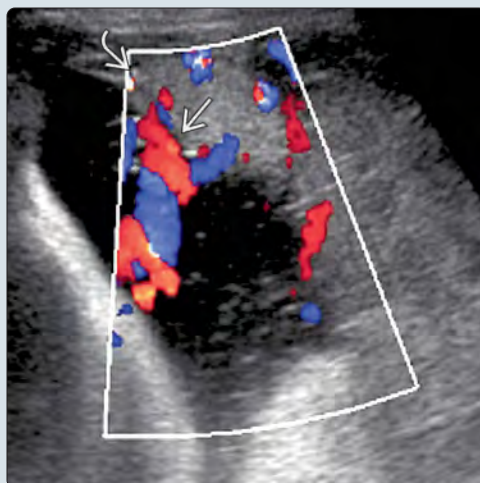
DIAGNOSTIC CHECKLIST

- Rule out vasa previa when VCI is in lower uterine segment
- Follow-up for growth and for MPCI evolving to VCI

(Left) In this case of velamentous cord insertion (VCI), the umbilical cord inserts directly on the uterine wall ~ 5 cm from the closest placental edge. **(Right)** Gross pathology of a patient with VCI shows the cord inserts 10 cm from the placental edge. The cord divides on the membrane and the splayed subvelamentous fetal vessels are not protected by Wharton jelly as they travel to the placenta. Note the associated small placenta. This pregnancy had a normal outcome.



(Left) In this case of marginal cord insertion, the umbilical cord inserts within 2 cm of the placental edge. No subvelamentous fetal vessels were seen. **(Right)** In this case, VCI is seen at the time of nuchal translucency screening. The anterior cord insertion is on the uterine wall and most of the early placenta is posterior; although, a thin slip of placenta does extend anterior at this time. The fetal and placental cord insertion sites are seen well at this stage of pregnancy.



TERMINOLOGY

Definitions

- Marginal placental cord insertion (MPCI): Umbilical cord (UC) inserts near placenta margin
- Velamentous cord insertion (VCI): UC inserts on membranes

IMAGING

General Features

- Best diagnostic clue
 - Color Doppler of UC insertion site shows MPCI or VCI
- Morphology
 - VCI may be several centimeters from placental edge
 - Placenta often thick and small

Ultrasonographic Findings

- MPCI: UC inserts < 2 cm from placental margin
 - All branching vessels are on fetal surface of placenta
 - Color Doppler confirms diagnosis
 - May progress to VCI
- VCI: UC inserts on membranes, **not** placenta
 - Vessels often diverge immediately upon insertion
 - Travel beneath membranes towards placenta
 - Mangrove tree sign
 - At risk for vasa previa if VCI is in lower uterine segment

Imaging Recommendations

- Protocol advice
 - New guidelines recommend documentation of placental cord insertion (PCI) in all cases
 - PCI seen in 99% of cases at time of anatomy scan
 - Reliably seen at time of nuchal translucency scan
 - Find PCI 1st with grayscale
 - Search for subvelamentous vessels if near margin
 - Confirm with color Doppler
 - Use transvaginal ultrasound to look for vasa previa if VCI in lower uterine segment
 - Color Doppler to identify small vessels near cervical os
 - Pulse Doppler to prove vessels are fetal

DIFFERENTIAL DIAGNOSIS

Submembranous Vessels From Succenturiate Lobe

- Vessels under membrane between placental lobes
- PCI may be normal, marginal, or velamentous
- Also associated with vasa previa

Chorioamniotic Separation

- Linear echoes near placental margin
- No flow on color Doppler

PATHOLOGY

General Features

- Etiology
 - "Trophotropism" of placenta
 - Parts of placenta grow and parts resorb
 - Cord insertion ends up marginal or velamentous
 - MPCI → VCI
 - Placental margin resorbs → vessels left submembranous

- Associated abnormalities
 - Fetal growth restriction
 - Single umbilical artery (SUA)
 - 18% SUA with MPCI
 - 9% SUA with VCI

Gross Pathologic & Surgical Features

- Small placenta
- Submembranous vessels not protected by Wharton jelly and are susceptible to injury

CLINICAL ISSUES

Presentation

- Most common signs/symptoms
 - Most often idiopathic and incidentally noted
 - High-risk patients
 - Advanced maternal age and multiparous patients
 - Monochorionic twin pregnancies

Demographics

- Epidemiology
 - VCI incidence
 - 1-2% for singleton pregnancies
 - 7% for dichorionic twins
 - Up to 40% reported in monochorionic twins
 - ◻ Not associated with ↑ risk for twin-twin transfusion

Natural History & Prognosis

- VCI associated with ↑ risk for adverse perinatal outcome
 - Preterm birth, low birth weight, perinatal mortality
 - Complications at time of labor
 - Hemorrhage, manual extraction of placenta
- MPCI with same risks but ↓ incidence of adverse outcomes

DIAGNOSTIC CHECKLIST

Image Interpretation Pearls

- Obligated to rule out vasa previa with transvaginal ultrasound when VCI is in lower uterine segment

Reporting Tips

- Surveillance ultrasound
 - Follow-up for growth at 28-32 weeks in low-risk cases diagnosed at 20 weeks
 - More frequent surveillance for higher risk pregnancies
- Report that early MPCI may evolve into VCI by term

SELECTED REFERENCES

1. Ebbing C et al: Third stage of labor risks in velamentous and marginal cord insertion: a population-based study. *Acta Obstet Gynecol Scand.* 94(8):878-83, 2015
2. Esakoff TF et al: Velamentous cord insertion: is it associated with adverse perinatal outcomes? *J Matern Fetal Neonatal Med.* 28(4):409-12, 2015
3. Bowman ZS et al: Velamentous cord insertion with variable umbilical cord Doppler changes. *J Ultrasound Med.* 33(11):2039-41, 2014
4. Bręborowicz GH et al: Prenatal diagnosis of vasa previa. *J Matern Fetal Neonatal Med.* 1-3, 2014
5. Kuwata T et al: The 'mangrove sign' for velamentous umbilical cord insertion. *Ultrasound Obstet Gynecol.* 40(2):241-2, 2012

KEY FACTS

TERMINOLOGY

- Placental mass composed of capillaries, cellular stroma, and trophoblast
 - Reactive proliferation, not true neoplasm

IMAGING

- Most common on fetal side of placenta, near cord insertion
- Well-defined, hypoechoic mass
- Color Doppler essential for making diagnosis
- Amount of flow in mass is quite variable
 - Greater arterial flow increases risk of developing high-output cardiac failure and hydrops
 - Vascularity may be more important than size for predicting outcome
 - Vascularity may either increase or decrease as gestation progresses
 - Flow through mass is from fetal circulation
- Masses ≥ 5 cm are considered large and are more likely to have complications



- Chorioangiomatosis may present as multiple small masses or diffusely heterogeneous placenta
 - More likely to cause complications
- Monitor for complications
 - Polyhydramnios common with large or multiple masses
 - Hydrops or fetal anemia from arteriovenous shunting
 - Fetal growth restriction

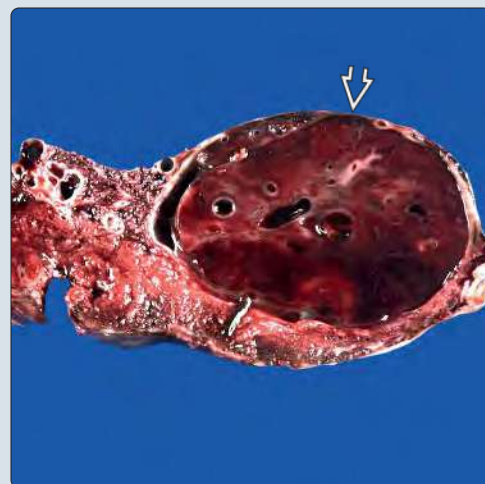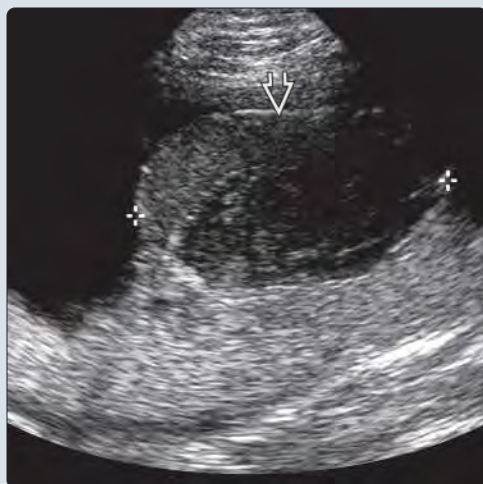
TOP DIFFERENTIAL DIAGNOSES




- Venous lakes and intervillous thrombi
- Placental hematoma

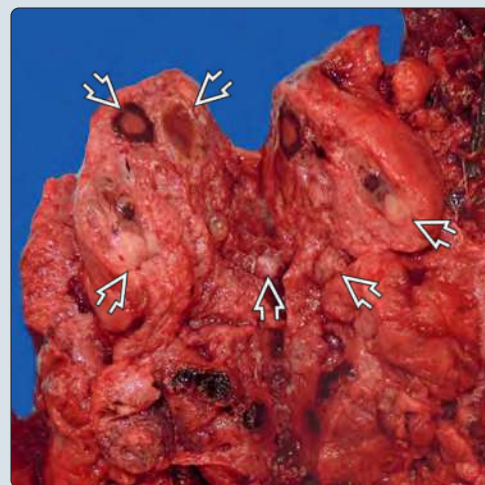
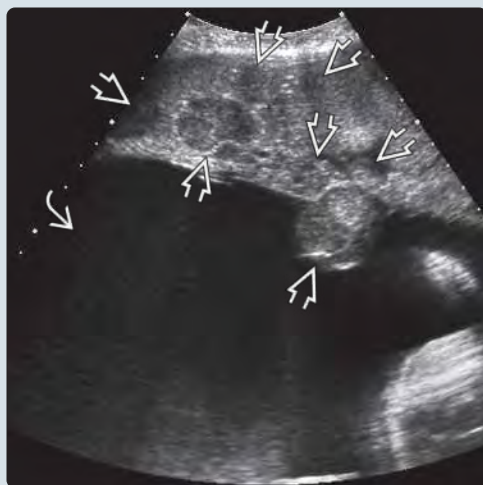
CLINICAL ISSUES

- Excellent prognosis if small and single
 - Generally no treatment necessary
- Amnioreduction for polyhydramnios
- Consider early delivery or other intervention for impending fetal hydrops

(Left) US of the placenta shows a well-defined, hypoechoic, 6-cm mass . It is located on the fetal side of the placenta, bulging into the amniotic cavity. Flow was seen on color Doppler. These are all classic features of a chorioangioma. Despite its large size, it had no adverse effect on the pregnancy. **(Right)** A cross section of the placenta shows a chorioangioma bulging under the chorionic plate . The well-circumscribed, red, firm appearance is characteristic of these highly vascular lesions. (From DP: Placenta.)



(Left) US of the placenta shows multiple solid hypoechoic masses  (chorioangiomatosis), which increase the likelihood of complications. There was severe polyhydramnios , which required multiple amnioreductions. **(Right)** The cut surface of the placenta shows a bumpy contour with innumerable small masses . When multiple and small, the placenta may appear diffusely heterogeneous by US, without discrete masses. Chorioangiomatosis should be considered and the patient followed for complications.



TERMINOLOGY

Definitions

- Placental mass composed of capillaries, cellular stroma, and trophoblast
 - Reactive proliferation, not true neoplasm

IMAGING

General Features

- Best diagnostic clue
 - Hypoechoic, vascular placental mass
- Location
 - Most common on fetal side of placenta, near cord insertion
 - Less common locations
 - Maternal surface, replacing lobule
 - Pedunculated mass surrounded by membranes
 - May involve umbilical cord
- Size
 - Majority are small and incidentally noted at delivery
 - Most < 5 cm
 - May be minute and only seen on histologic sectioning
 - Masses ≥ 5 cm are considered large and are more likely to be diagnosed prenatally
- Morphology
 - Encapsulated masses
 - Usually solitary but may be multiple (chorioangiomas)

Ultrasonographic Findings

- **Chorioangioma**
 - Generally well-defined hypoechoic mass
 - May be more heterogeneous if areas of hemorrhage, infarction, or degeneration with hyaline deposition
 - Color Doppler essential for making diagnosis
 - Amount of flow in mass is quite variable
 - Greater arterial flow increases risk of developing high-output cardiac failure and hydrops
 - Flow through mass is from fetal circulation
 - May see increased flow around mass even if mass itself is hypovascular
- **Chorioangiomas**
 - May see multiple small masses or diffusely heterogeneous placenta
 - More likely to cause complications

MR Findings

- T1WI
 - Isointense to placenta
 - May have high-signal rim from hemorrhage
- T2WI
 - Heterogeneous, high signal intensity
 - May have low-signal rim from hemorrhage

Imaging Recommendations

- Measure mass
 - < 5 cm unlikely to have complications
 - ≥ 5 cm more likely to have complications
 - Described in up to 50% of cases
- Document vascularity

- Vascularity may be more important than size for predicting outcome
- Vascularity may either increase or decrease as gestation progresses
- Follow every 2-3 weeks for size, vascularity, and fetal assessment
- Evaluate for complications
 - Polyhydramnios common with large or multiple masses
 - Hydrops from arteriovenous shunting or fetal anemia
 - Initial hypertrophic cardiomyopathy → dilated cardiomyopathy from progressive cardiac decompensation
 - Ascites
 - Pleural effusion
 - Pericardial effusion
 - Skin thickening
 - Fetal anemia
 - Hemolysis of red blood cells
 - Evaluate flow in middle cerebral artery to determine need for transfusion
 - Fetal growth restriction
 - May result from chronic hypoxia from unoxygenated blood that bypasses maternal circulation through chorioangioma

DIFFERENTIAL DIAGNOSIS

Venous Lakes

- Look for subtle motion
 - Pooling venous blood
 - Changing patient position may make more obvious
- Flow too slow to be seen with Doppler
 - Better seen with grayscale

Intervillous Thrombi

- No flow
- Surrounded by normal placental parenchyma
 - Does not change placental contour

Placental Hematoma

- No flow with Doppler
- Appearance evolves over time

Submucosal Fibroid

- Uterine wall mass
- Separate from placenta

Triploidy

- 3 complete sets of chromosomes
- Placental appearance varies according to extra set of chromosomes
 - Large and cystic if extra set is paternal (diandry)
 - Normal or small if extra set is maternal (digyny)
- Fetus is abnormal
 - Multiple anomalies
 - Severe growth restriction

Placental Teratoma

- Very rare
- Arises between amnion and chorion
- Heterogeneous mass with cystic and solid components
- Calcifications may be present

Placental Metastases

- Very rare
- Maternal
 - Melanoma
 - May metastasize to fetus
 - Breast, lymphoma
- Fetal
 - Neuroblastoma
 - Occurs with large primary tumors
 - Hydrops usually present

PATHOLOGY**General Features**

- Etiology
 - Not seen in 1st-trimester abortuses so unlikely to arise from defective initial villous formation
 - Placental hypoxia thought to trigger angiogenesis and excessive capillary proliferation
 - Pathophysiology of polyhydramnios is unclear, but several hypotheses proposed
 - May be transudate from leaky tumor vessels over large vascular surface area
 - Mechanical obstruction of blood flow by masses near cord insertion site
- Associated abnormalities
 - Fetal hemangiomas
 - Cutaneous and liver
 - Beckwith-Wiedemann syndrome
 - Single umbilical artery

Gross Pathologic & Surgical Features

- Encapsulated, firm masses
- Color varies from purple-red to tan depending on cellular makeup

Microscopic Features

- Capillary vessels set within variably cellular and collagenous stroma, surrounded by trophoblast layers
- May have associated trophoblastic hyperplasia with pleomorphism and atypia
 - Never malignant despite variable mitotic activity
- Older lesions may have degenerative changes
 - Myxoid and hyaline deposition
 - Explains why some masses become more echogenic and less vascular by US

CLINICAL ISSUES**Presentation**

- Most common signs/symptoms
 - Incidental finding
 - Typically present in 3rd trimester
 - Rare to diagnose before 20 weeks
- Other signs/symptoms
 - Polyhydramnios
 - Elevated maternal serum α -fetoprotein
 - Rarely, fetal hydrops
 - Preterm labor
 - Likely from polyhydramnios, but does not explain all cases

- Rarely, preeclampsia reported

Demographics

- Epidemiology
 - 0.6-1.0% of placentas at delivery
 - Most too small to visualize by US
 - Many microscopic
 - Large (≥ 5 cm) have been reported to occur in 1:3,500-16,000 births
 - Most found in women > 30 years
 - Fetuses are more often female (72% in 1 study)
 - More common in women living at higher elevation
 - More common in preeclampsia and multiple gestations

Natural History & Prognosis

- Excellent prognosis if small and single
 - Generally remain asymptomatic
- Poorer if hydrops present
 - At risk for perinatal death

Treatment

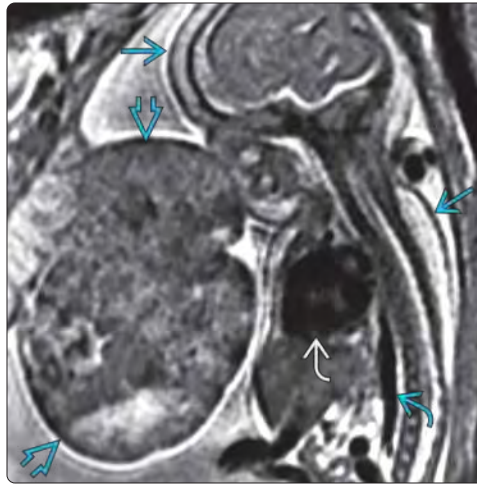
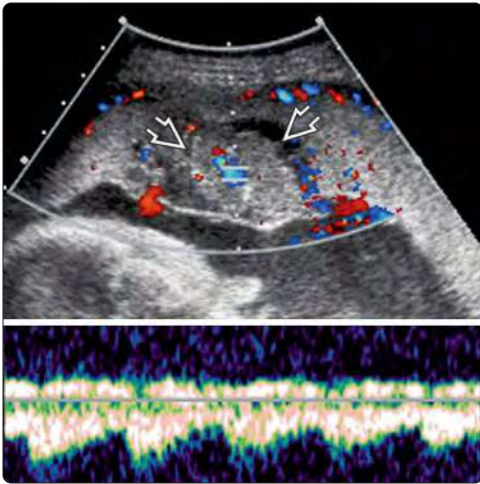
- Generally no treatment necessary
- Amnioreduction for polyhydramnios
 - Reduce likelihood of premature delivery
- Consider intervention for impending fetal hydrops
 - Steroids and early delivery
 - Transfusion for anemia
 - Vessel ligation, laser coagulation, alcohol injection, and embolization all described
 - Variable results

DIAGNOSTIC CHECKLIST**Image Interpretation Pearls**

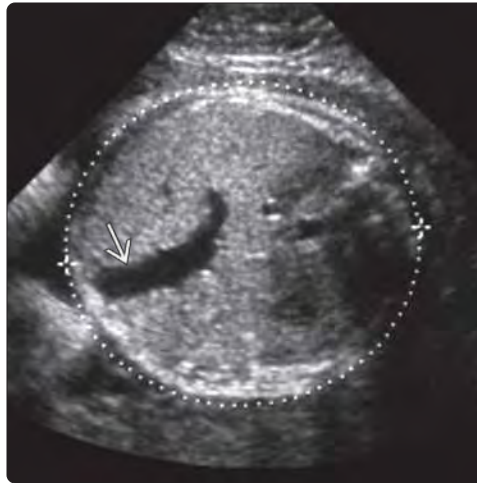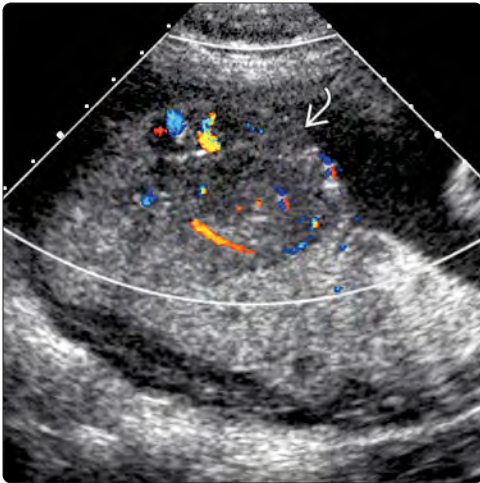
- Always evaluate placental masses with Doppler
- Close follow-up as size and vascularity may change with advancing gestational age

SELECTED REFERENCES

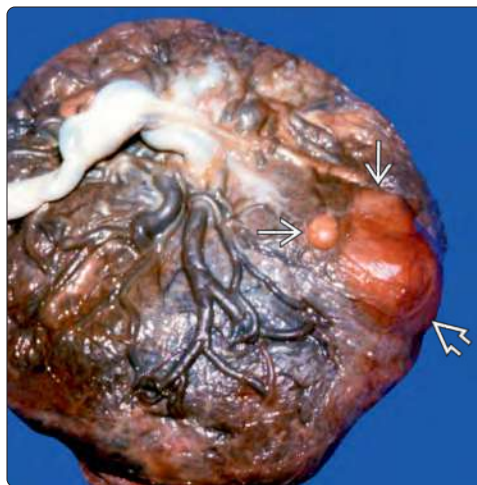
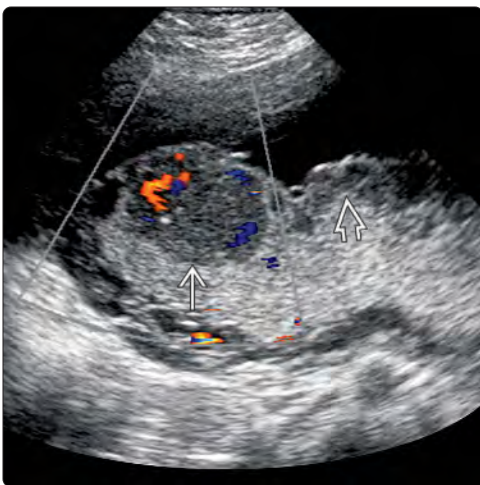
1. Al Wattar BH et al: Placenta chorioangioma: a rare case and systematic review of literature. *J Matern Fetal Neonatal Med.* 27(10):1055-63, 2014
2. Fan M et al: Placental chorioangioma: literature review. *J Perinat Med.* 42(3):273-9, 2014
3. Jarcevic R et al: Placental chorioangioma. *J Obstet Gynaecol Can.* 36(3):201-2, 2014
4. Liu H et al: Natural history and pregnancy outcome in patients with placental chorioangioma. *J Clin Ultrasound.* 42(2):74-80, 2014
5. Kesrouani AK et al: Rapid evolution of placental chorioangioma: natural progression and outcome. *J Ultrasound Med.* 32(3):545-7, 2013
6. Babic I et al: Antenatal embolization of a large placental chorioangioma: a case report. *J Med Case Rep.* 6:183, 2012
7. Jones K et al: Fetoscopic laser photocoagulation of feeding vessels to a large placental chorioangioma following fetal deterioration after amnioreduction. *Fetal Diagn Ther.* 31(3):191-5, 2012
8. Wou K et al: Pregnancy outcomes and ultrasonographic diagnosis in patients with histologically-proven placental chorioangioma. *Placenta.* 32(9):671-4, 2011
9. Sepulveda W et al: Endoscopic laser coagulation of feeding vessels in large placental chorioangiomas: report of three cases and review of invasive treatment options. *Prenat Diagn.* 29(3):201-6, 2009
10. Taori K et al: Chorioangioma of placenta: sonographic features. *J Clin Ultrasound.* 36(2):113-5, 2008



(Left) Color and pulsed wave Doppler show flow within a placental chorioangioma. Vascularity may increase or decrease as the gestation progresses and is an important predictor of potential complications. (Right) Sagittal T2WI MR shows a large, heterogeneous, pedunculated placental mass, causing hydrops in this 26-week fetus. Note the skin edema, cardiomegaly, and enlarged inferior vena cava. Intervention should be considered when hydrops is present.



(Left) An incidental placental mass was seen during a routine fetal screening. Moderate flow was demonstrated on Doppler imaging. (Right) A transverse US through the fetal abdomen in the same case shows enlargement of the umbilical vein. There was also mild cardiomegaly. Significant arteriovenous shunting within a chorioangioma may cause hydrops in the fetus. This fetus never developed hydrops and was delivered without complication.



(Left) Color Doppler US shows a well-defined, vascular, hypoechoic mass on the fetal surface of the placenta. Doppler is essential to differentiate a chorioangioma from more common avascular placental masses. Other hypoechoic areas were also seen but less well defined. (Right) The gross image from the same case shows the dominant chorioangioma, with surrounding smaller ones.

KEY FACTS

TERMINOLOGY

- Benign nontrophoblastic placental mass composed of all 3 germ cell layers
- Remains controversial whether true neoplasm or extreme form of acardiac twin

IMAGING

- Lies between amnion and chorion
- Usually on fetal surface of placenta
- Soft tissue mass with variable echogenicity
- Calcification common but no organized skeletal structures
- No clear cranial or caudal end
- Absence of umbilical cord
 - Blood supply from placental arteries, not umbilical arteries
- Internal components hypovascular with little or no flow on color Doppler

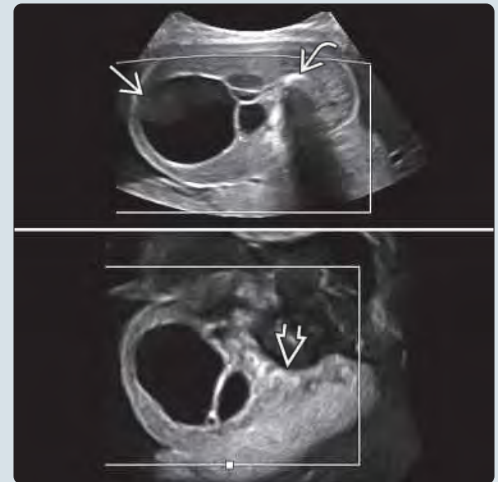
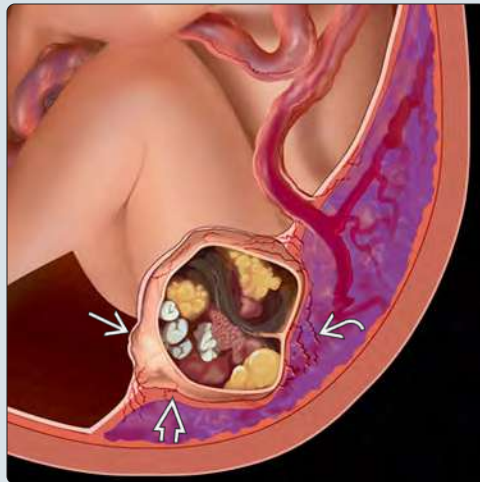
TOP DIFFERENTIAL DIAGNOSES

- Acardiac twin-in-twin reversed arterial perfusion (TRAP)
 - Monochorionic placenta with superficial artery-to-artery anastomosis
 - Acardiac twin has separate umbilical cord
 - Located in amniotic cavity, not contiguous with placenta
 - Has definite fetus-like appearance with axial organization and development of central skeleton
 - Lower body more developed than upper
- Chorioangioma
 - Well-defined hypoechoic mass
 - Vascular on color Doppler

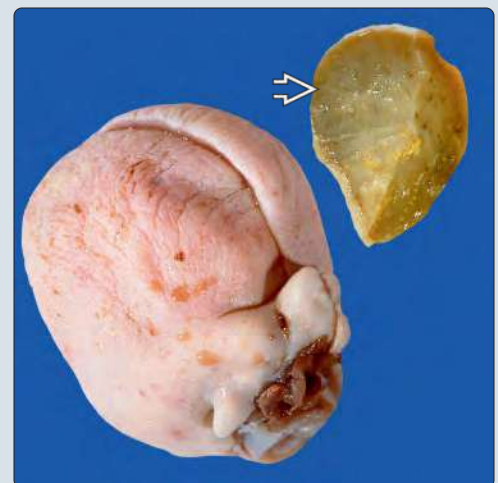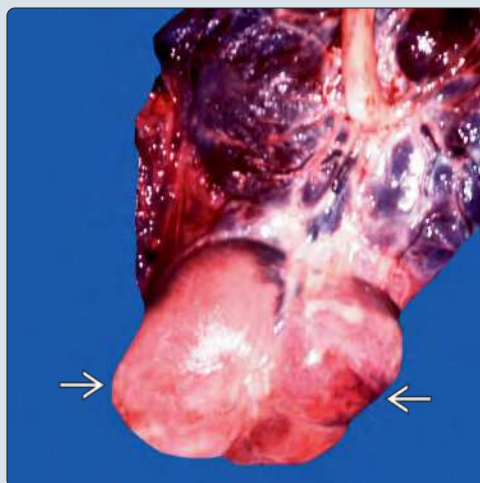
DIAGNOSTIC CHECKLIST

- Must rule out acardiac twin from TRAP
 - Far more serious condition
 - Untreated pump twin mortality 35-75%
 - Always look for umbilical artery flow into mass

(Left) Graphic shows a placental teratoma situated between the amnion and chorion, with the blood supply coming from intraplacental vessels and not directly from the umbilical artery. **(Right)** Images from a 3D acquisition show a complex mass with cystic components and shadowing calcifications. A TRAP twin was considered, but the mass was never seen to be free-floating. On the sagittal projection (bottom), it is clearly shown to be contiguous with the anterior margin of the placenta.



(Left) Gross pathology of the placenta in a similar case shows the lobular contour of the teratoma. It was located between the amnion and chorion, which is typical. **(Right)** With the membranes removed, the teratoma has an obvious skin covering. A portion of the cut surface shows it is predominately composed of fat. Amorphous calcifications were present but no skeletal elements and no clear cranial or caudal end are seen. All of these features support a teratoma rather than an acardiac twin.



TERMINOLOGY

Definitions

- Benign nontrophoblastic placental mass composed of all 3 germ cell layers
 - Endoderm, mesoderm, ectoderm
- Remains controversial whether true neoplasm or extreme form of acardiac twin

IMAGING

General Features

- Location
 - Lies between amnion and chorion
 - Usually on fetal surface of placenta
 - Rarely in membranes
 - Case reports of pedunculated teratomas
- Size
 - Reported range: 2-11 cm in diameter
- Morphology
 - Smooth, round or oval tumors
 - May contain hair, teeth, bone, etc.

Ultrasonographic Findings

- Grayscale ultrasound
 - Soft tissue mass with variable echogenicity
 - Calcification common but no organized skeletal structures
 - No clear cranial or caudal end
 - Absence of umbilical cord
- Color Doppler
 - Blood supply from placental arteries, not umbilical arteries
 - Internal contents of teratoma are hypovascular with little or no flow

DIFFERENTIAL DIAGNOSIS

Acardiac Twin-in-Twin Reversed Arterial Perfusion (TRAP)

- Monochorionic placenta with superficial artery-to-artery anastomosis
- Acardiac twin perfused with deoxygenated blood from pump (normal) twin
 - Reverse perfusion allows continued but abnormal development
- Definite fetus-like appearance
 - Has axial organization with development of central skeleton
 - Lower body more developed than upper
- Acardiac twin has separate umbilical cord
 - Flow in umbilical artery of abnormal twin is toward fetus (normal direction is away from fetus, toward placenta)
- Located in amniotic cavity, not contiguous with placenta
- Pump twin high-output state may lead to hydrops

Chorioangioma

- Well-defined hypoechoic mass
 - May be more heterogeneous if areas of hemorrhage, infarction, or degeneration with hyaline deposition
- Calcifications uncommon
- Vascular on color Doppler

- May cause hydrops

PATHOLOGY

General Features

- Etiology
 - Germ cell theory
 - Early in embryogenesis, primitive gut evaginates into umbilical cord
 - Primordial germ cells migrate through gut wall into surrounding connective tissue
 - Germ cells become entrapped between amnion and placental surface

Gross Pathologic & Surgical Features

- Predominately fatty mass but may see calcifications, teeth, hair

Microscopic Features

- Most common histologic elements include skin with dermal appendages, ganglion-like cells and nervous structures, gut structures, osteocartilaginous structures, and smooth and striated muscle
- Absence of segmental organization of skeletal structures
- Histologically mature with no evidence of malignancy
- Arterial supply most commonly from placental arterial branch, not umbilical cord

CLINICAL ISSUES

Presentation

- Most common signs/symptoms
 - Incidental finding

Demographics

- Epidemiology
 - Very rare, < 50 reported cases

Natural History & Prognosis

- No clear clinical significance
- No adverse effects on pregnancy

DIAGNOSTIC CHECKLIST

Consider

- Must rule out acardiac twin from TRAP
 - Far more serious condition
 - Untreated pump twin mortality 35-75%
 - Always look for umbilical artery flow into mass

SELECTED REFERENCES

1. Barisik NM et al: Mature placental teratoma: case report. *Open J Path*, 3:131-32, 2013
2. Prashanth A et al: Placental teratoma presenting as a lobulated mass behind the neck of fetus: a case report. *Case Rep Obstet Gynecol*. 2012:857230, 2012
3. Buyukkurt S et al: Prenatal diagnosis of placental teratoma: a case report. *Eur J Obstet Gynecol Reprod Biol*. 146(2):233-4, 2009
4. Gaffar BA et al: Placental teratoma or fetus acardius amorphous? *Hematol Oncol Stem Cell Ther*. 1(1):57-61, 2008
5. Tan G et al: Large teratoma of the placenta. *Int J Gynecol Ob*. 11(2), 2008
6. Ahmed N et al: Sonographic diagnosis of placental teratoma. *J Clin Ultrasound*. 32(2):98-101, 2004
7. Elagoz S et al: Placental teratoma. A case report. *Eur J Obstet Gynecol Reprod Biol*. 80(2):263-5, 1998

Placental Mesenchymal Dysplasia

KEY FACTS

TERMINOLOGY

- Abnormal placental development characterized by placentomegaly, stem-villous hydropic cyst formation, and abnormal villous stroma

IMAGING

- Thickened, cystic placenta

TOP DIFFERENTIAL DIAGNOSES

- Partial mole (triploidy)
 - Fetus usually has multiple anomalies
- Twin pregnancy with complete hydatidiform mole
 - Normal twin has normal (i.e., noncystic) placenta
- Chorangiomas
 - Chorangiomas are typically hypervascular solid masses

PATHOLOGY

- ~ 20% have Beckwith-Wiedemann syndrome

- Absence of trophoblastic proliferation differentiates PMD from partial mole

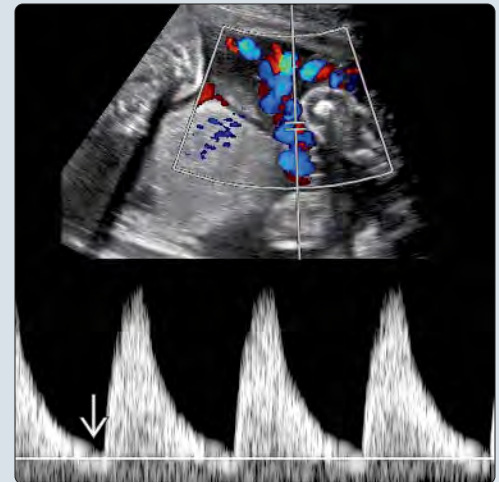
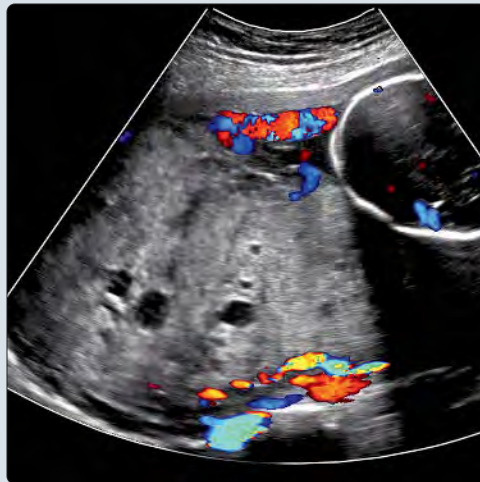
CLINICAL ISSUES

- Consider karyotype to exclude triploidy
- Only known maternal complication is preeclampsia
- Fetal complications include growth restriction, preterm delivery, and fetal death
 - Growth restriction often early and severe
 - > 50% deliver before 37 weeks, of which > 50% due to spontaneous preterm labor
- In absence of severe growth restriction and preterm delivery, infants do well, but that is minority of cases

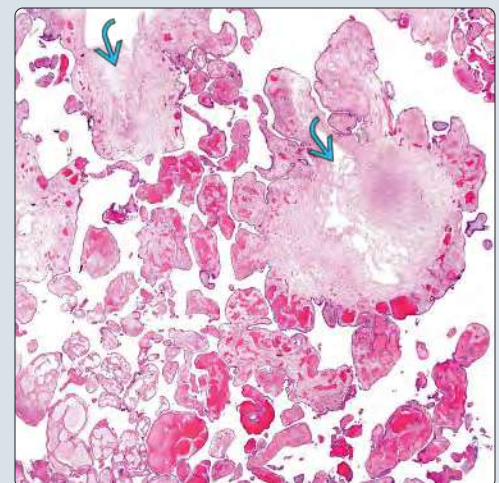
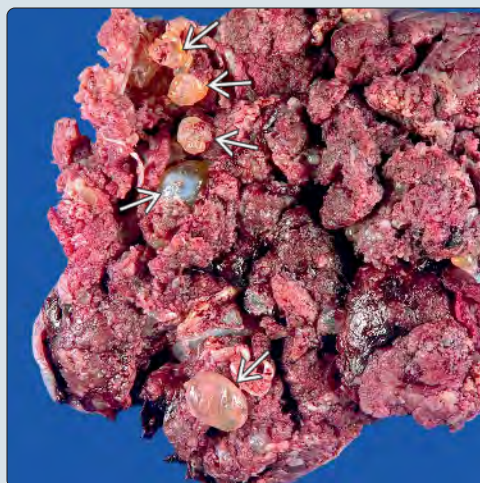
DIAGNOSTIC CHECKLIST

- Consider PMD if molar placental changes + \uparrow ms AFP + normal to slightly \uparrow β hCG
- Need to follow pregnancy closely for developing growth restriction and fetal well-being

(Left) Color Doppler images through the placenta in the midtrimester show dramatic thickening and several cystic spaces. (Right) Umbilical artery Doppler shows absent end diastolic flow \Rightarrow indicating abnormal placental hemodynamics. The fetus was severely growth restricted but structurally normal. This helps differentiate placental mesenchymal dysplasia (PMD) from triploidy where there are usually multiple fetal anomalies. Emergency cesarean section was performed for severe maternal preeclampsia.



(Left) The diagnosis of PMD is suspected on gross exam when there is an enlarged, bulky placenta containing scattered grape-like cysts \Rightarrow within the parenchyma. (From DP: Placenta.) (Right) On histology, there are enlarged hydropic villi \Rightarrow distended with myxomatous stroma and dilated vascular spaces but no trophoblastic proliferation, the lack of which is the key finding to differentiate PMD from gestational trophoblastic neoplasia.



TERMINOLOGY

Abbreviations

- Placental mesenchymal dysplasia (PMD)

Definitions

- Abnormal placental development characterized by placentomegaly, stem-villous hydropic cyst formation, and abnormal villous stroma

IMAGING

Ultrasonographic Findings

- Grayscale ultrasound
 - Thickened placenta with large cystic spaces
 - Seen as early as 13-weeks gestation
- Color Doppler
 - May see enlarged vessels along fetal surface of placenta

DIFFERENTIAL DIAGNOSIS

Partial Mole (Triploidy)

- Fetus usually has multiple anomalies
- Thick cystic placenta with fetal growth restriction
 - Diandric triploidy (e.g., dispermy or 69XXY)
 - High β hCG (also seen in 38% of reported cases of PMD)

Twin Pregnancy With Complete Hydatidiform Mole

- Normal twin has normal (i.e., noncystic) placenta

Chorangiomas

- Chorangiomas are typically hypervascular solid masses
- Larger masses may undergo hemorrhage/infarction to appear cystic

PATHOLOGY

General Features

- Genetics
 - Aneuploidy uncommon
 - 78% normal karyotype in 1 series of 66 cases
 - 1 each trisomy 13, triploidy, Klinefelter
 - ~ 20% have Beckwith-Wiedemann syndrome (BWS)
 - Recent studies propose androgenetic/biparental mosaicism as etiology
 - Phenotype → mild PMD to complete mole, depending on extent/distribution of androgenetic cell line
 - When confined to chorionic mesoderm, membranes, vessels → PMD
 - When expressed in trophoblast → complete mole
- Associated abnormalities
 - Strong association with BWS
 - Increasing number of cases reported with associated fetal hepatic hamartoma
 - Scattered reports of association with gastroschisis, chorangioma, multiple gestation

Gross Pathologic & Surgical Features

- Bulky enlarged placenta with variably dilated, varicose-like, chorionic plate vessels
- Parenchyma shows grape-like cysts, and regions of tan gelatinous-appearing foci may be found in otherwise spongy red-brown villous parenchyma

- Excessively long, hypercoiled umbilical cord in some cases

Microscopic Features

- Absence of trophoblastic proliferation differentiates PMD from partial mole
- Vascular abnormalities
 - Enlarged stem villi with dilated vessels
 - \pm fetal artery thrombosis, villous hemorrhage

CLINICAL ISSUES

Presentation

- Most common signs/symptoms
 - Multicystic placenta
- Other signs/symptoms
 - Fetal growth restriction: Often severe, early onset
 - Fetal overgrowth when associated with BWS
 - Maternal serum AFP levels are high in PMD, β hCG normal or only mildly elevated

Demographics

- 1st described in 1994, likely underreported as underrecognized
- 80% occur in females

Natural History & Prognosis

- No proven correlation between placental size/weight and specific maternal or fetal complication
- Only known maternal complication is preeclampsia
 - No long-term risk for gestational trophoblastic neoplasia (unlike partial mole)
- Fetal complications include growth restriction, preterm delivery, and fetal death
 - 50% fetal growth restriction
 - 13-43% intrauterine or neonatal demise reported
 - More common in growth restricted fetuses rather than BWS
 - > 50% deliver before 37 weeks
 - > 50% of these due to spontaneous preterm labor

Treatment

- Consider karyotype to exclude triploidy
- Careful monitoring for growth and fetal well-being
- Close maternal surveillance for signs of preeclampsia
- In absence of severe growth restriction and preterm delivery, infants do well, but that is minority of cases
 - Normal outcome in only 9% of cases in 2013 systematic review

DIAGNOSTIC CHECKLIST

Consider

- PMD if molar placental changes + \uparrow ms AFP + normal to slightly \uparrow β hCG

SELECTED REFERENCES

1. Nayeri UA et al: Systematic review of sonographic findings of placental mesenchymal dysplasia and subsequent pregnancy outcome. *Ultrasound Obstet Gynecol.* 41(4):366-74, 2013
2. Parveen Z et al: Placental mesenchymal dysplasia. *Arch Pathol Lab Med.* 131(1):131-7, 2007
3. Pham T et al: Placental mesenchymal dysplasia is associated with high rates of intrauterine growth restriction and fetal demise: A report of 11 new cases and a review of the literature. *Am J Clin Pathol.* 126(1):67-78, 2006

KEY FACTS

TERMINOLOGY

- Also referred to as 2-vessel cord

IMAGING

- Only 1 umbilical artery seen on transverse color Doppler image through fetal pelvis
- Free loop of cord with 2 vessels instead of 3
- Diagnosis can be made in 1st, 2nd, or 3rd trimester
- Isolated in 2/3 of cases
 - 2x increased risk for placental insufficiency
 - Fetal growth restriction
 - Maternal hypertension
 - Preterm delivery
 - Associated with placental anomalies
 - Succenturiate lobe and velamentous cord insertion
- 1/3 of fetuses have other anomalies
 - Renal and cardiac anomalies most common
- Aneuploid in 10% (trisomy 18 and 13, not 21)

TOP DIFFERENTIAL DIAGNOSES





- Umbilical vessel thrombosis
- Fused umbilical arteries

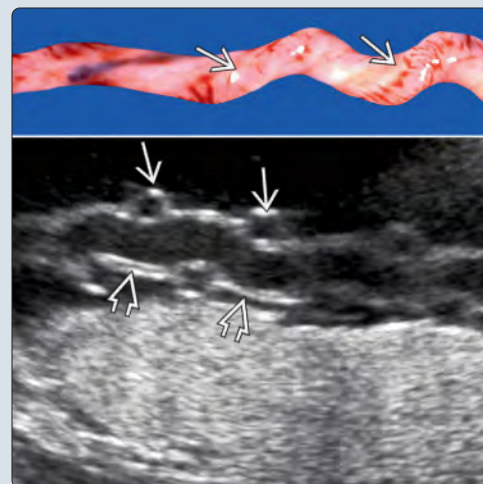
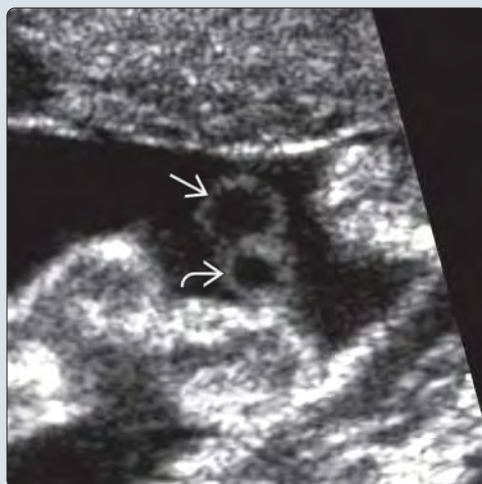
CLINICAL ISSUES





- 0.5-5.0% of all pregnancies
- 8% false-positive diagnosis on prenatal scans

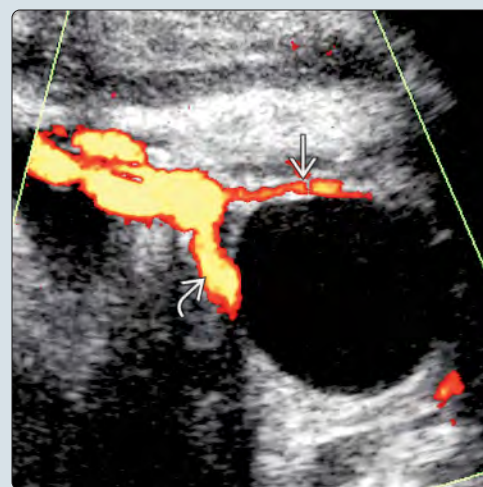
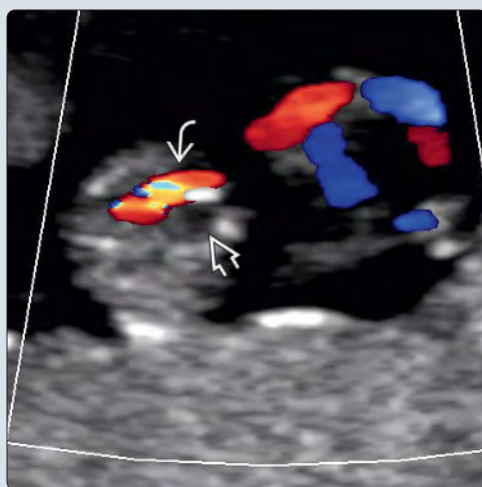
DIAGNOSTIC CHECKLIST

- Follow-up for fetal growth recommended in cases of isolated single umbilical artery (SUA)
- Look carefully at placental cord insertion site and placental morphology
- Offer genetic counseling if not isolated
- Look for SUA if ↑ nuchal translucency
 - Increases risk of aneuploidy
- Hypoplastic umbilical artery is variant of SUA
 - Carries same risks and associations

(Left) Axial US shows only 2 vessels in the umbilical cord. The umbilical artery (UA)  has a thicker wall than the umbilical vein (UV) . The increased diameter of the single umbilical artery (SUA) is most apparent on cross-sectional views. **(Right)** Gross image and longitudinal US of an umbilical cord with a SUA show a hypocoiled cord. The UA  coils around a relatively straight UV . This finding is common with SUA. A severely hypocoiled cord will show a parallel UA and UV. Hypocoiled vessels may be more prone to injury.



(Left) An SUA  is seen adjacent to the fetal bladder  at the time of nuchal translucency screening in this 13-week fetus. In addition, there were other anomalies detected and invasive genetic testing was performed (yielding normal results). One-third of fetuses with SUA will have other anomalies. **(Right)** Axial power Doppler US in a fetus shows a small UA  compared to the normal UA . Hypoplastic UAs are a variant of SUA and carry the same risks and associations.



TERMINOLOGY

Abbreviations

- Single umbilical artery (SUA)

Synonyms

- 2-vessel cord

Definitions

- Umbilical cord carries only 1 artery and 1 vein
 - Absence of right or left umbilical artery (UA)
- Hypoplastic umbilical artery (HUA) is variant of SUA
 - 1 UA is > 50% smaller than other UA

IMAGING

General Features

- Best diagnostic clue
 - Only 1 UA seen on transverse color Doppler image through fetal pelvis
 - 1 UA adjacent to urine-filled fetal bladder
 - SUA travels from cord insertion site into iliac artery
 - Free loop of cord with 2 vessels instead of 3
 - Show in orthogonal planes
 - Seen best on cross section
- Location
 - 70% absent left UA
- Size
 - SUA is larger than UA in dual UA cord
- Morphology
 - SUA cord less coiled than dual UA cord

Ultrasonographic Findings

- SUA diagnosis can be made in 1st, 2nd, or 3rd trimester
 - 8% false-positive diagnosis
 - Dual UA cord at delivery
- SUA is isolated finding in 2/3 of cases
 - ↑ risk of fetal growth restriction
 - Abnormal placental morphology
 - Succenturiate lobe, velamentous cord insertion
- 1/3 of cases are not isolated
 - Aneuploidy association in 10%
 - Trisomy 18 (T18) and trisomy 13 (T13)
 - Look for markers and anomalies
 - ↑ risk if ↑ nuchal translucency
 - Invasive genetic testing not indicated if isolated finding in low-risk patient
 - Genitourinary, cardiovascular, and gastrointestinal anomalies
 - SUA always seen with sirenomelia (rare diagnosis)
 - Fused lower extremities, renal agenesis
 - UA inserts directly into aorta
 - Twin reversed arterial perfusion sequence
 - 2/3 of acardiac twins have SUA
- HUA within spectrum of SUA
 - More difficult diagnosis than SUA
 - Seen best on color Doppler fetal pelvis view
 - Doppler abnormalities in small UA common
 - Increased resistance (higher systolic:diastolic ratio)
 - Similar associations as SUA

Imaging Recommendations

- Protocol advice
 - Look carefully for additional anomalies when SUA seen
 - Consider serial ultrasound exams for growth
 - Look carefully at placental cord insertion site and placental morphology

DIFFERENTIAL DIAGNOSIS

Umbilical Vessel Thrombosis (Rare)

- UV or UA thrombosis
- Maternal thrombophilia association

Fused Umbilical Arteries

- Often within 3 cm of placenta
- Longer fused segments mimic SUA
- Not associated with other abnormalities/aneuploidy

PATHOLOGY

General Features

- Etiology
 - Primary agenesis of 1 UA
 - Thrombotic atrophy of 1 UA
 - Persistent original single allantoic artery of body stalk
 - Vitelline artery connects directly to aorta
 - Sirenomelia most common example
- Associated abnormalities
 - Isolated SUA associated with placental insufficiency
 - Small for gestational age fetus (↑ odds ratio of 2.1)
 - Pregnancy induced hypertension
 - Medically indicated preterm birth

Gross Pathologic & Surgical Features

- Less Wharton jelly noted around 2 vessel cords

CLINICAL ISSUES

Presentation

- Most common signs/symptoms
 - Incidental finding on routine cord view
 - SUA + other anomalies
 - SUA + fetal growth restriction
 - Isolated SUA associated with abnormal maternal screening test results
 - Elevated pregnancy-associated plasma protein A
 - Elevated α-fetoprotein

Demographics

- Epidemiology
 - 0.5-5.0% of all pregnancies

SELECTED REFERENCES

1. Battarbee AN et al: Association of isolated single umbilical artery with small for gestational age and preterm birth. *Obstet Gynecol.* 126(4):760-4, 2015
2. Tulek F et al: The effects of isolated single umbilical artery on first and second trimester aneuploidy screening test parameters. *J Matern Fetal Neonatal Med.* 28(6):690-4, 2015
3. Voskamp BJ et al: Relationship of isolated single umbilical artery to fetal growth, aneuploidy and perinatal mortality: systematic review and meta-analysis. *Ultrasound Obstet Gynecol.* 42(6):622-8, 2013
4. Hua M et al: Single umbilical artery and its associated findings. *Obstet Gynecol.* 115(5):930-4, 2010

Umbilical Vein Varix

KEY FACTS

TERMINOLOGY

- Several definitions in use
 - Focal dilatation of umbilical vein (UV) > 9-mm diameter
 - Varix diameter 50% > intrahepatic portion of UV
 - UV diameter > 2 standard deviations above mean for gestational age

IMAGING

- Cyst-like space in upper abdomen with venous flow on Doppler
- Usually intraabdominal, extrahepatic
- UV varix may be 1st manifestation of elevated venous pressure
 - Formal fetal echocardiogram should be performed
 - Monitor for signs of impending hydrops




TOP DIFFERENTIAL DIAGNOSES

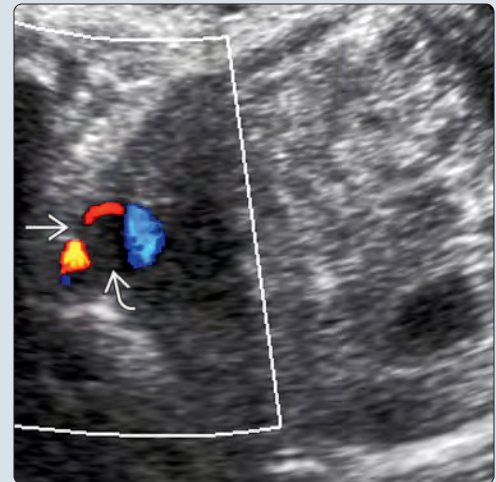
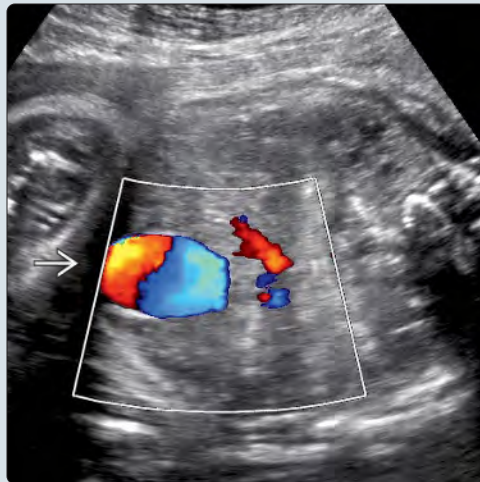
- Abdominal cysts
 - Choledochal cyst





- Meconium pseudocyst
- Ovarian cyst
- Enteric duplication cyst
- Urachal cyst
- Umbilical cord cysts

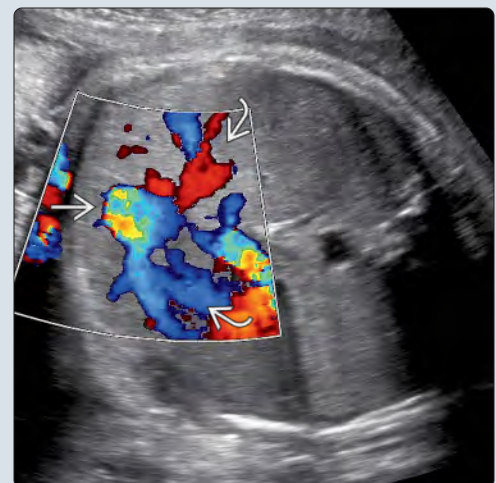
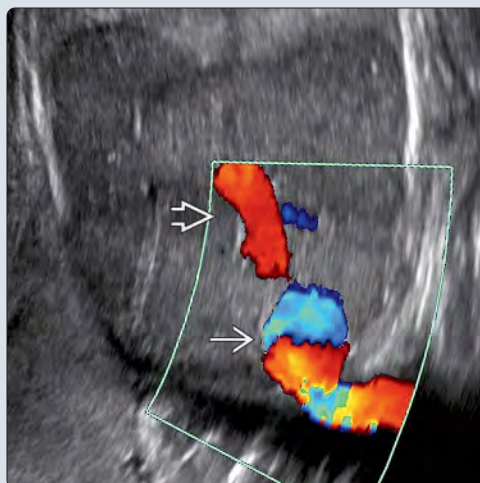
CLINICAL ISSUES

- ~ 35% have other anomalies
 - Cardiovascular, renal most common
- Management
 - Detailed anatomic survey + formal fetal echocardiogram
 - Close fetal monitoring advised but no standard protocol
 - Emphasis on fetal growth, varix size, presence of thrombus, signs of cardiac decompensation
 - Increase surveillance if fetal growth restriction develops
 - Early delivery no longer considered essential if UV varix isolated

(Left) Axial color Doppler US shows complete filling of a 13-mm umbilical vein varix (UVV) . The swirling color is a manifestation of eddying flow as the blood from the normal-caliber umbilical vein enters the varix. Whether or not the degree of turbulence in the varix can be characterized by color Doppler is debatable. **(Right)** This case shows incomplete filling of a UVV  due to partial thrombosis with clot  filling about 1/2 of the varix. This occurred at 37 weeks and 1 day. The infant was delivered by cesarean section and did well.



(Left) Coronal color Doppler US nicely demonstrates the size of the varix  in comparison to the size of the intrahepatic umbilical vein . **(Right)** Axial color Doppler US shows enlargement of the portal veins  in association with a UVV . This suggests impaired venous circulation. There is a case report in which this finding was associated with progressive liver enlargement and resulted in intrauterine fetal demise (IUFD). All testing was negative for liver disease, infection, and aneuploidy.



TERMINOLOGY

Abbreviations

- Umbilical vein varix (UVV)

Definitions

- Focal dilatation of umbilical vein (UV) > 9-mm diameter
- Diameter 50% > intrahepatic portion of UV
- UV diameter > 2 standard deviations above mean

IMAGING

General Features

- Best diagnostic clue
 - Upper abdominal cyst-like space with venous flow
- Location
 - Usually intraabdominal, extrahepatic
 - May be intrahepatic or in free-floating loops of cord

Ultrasonographic Findings

- Upper abdominal oval or elongated, thin-walled, anechoic "cyst"
- Must show continuity of "cyst" with UV and presence of blood flow to make this diagnosis
 - Runs between abdominal cord insertion site and inferior edge of liver
 - May occur in association with persistent right umbilical vein
- Reported sizes range from 8-30 mm

Imaging Recommendations

- Protocol advice
 - Measure on axial image of fetal abdomen immediately cephalad to umbilical vein insertion
 - Outer edge to inner edge
 - Careful search for other anomalies
 - UVV may be 1st manifestation of elevated venous pressure
 - Formal fetal echocardiogram should be performed
 - Monitor for signs of impending hydrops
 - Use color Doppler
 - Failure of entire varix/aneurysm to fill with color on Doppler concerning for thrombus

DIFFERENTIAL DIAGNOSIS

Normal Fluid-Filled Structures

- Stomach, gallbladder

Other Abdominal Cysts

- Choledochal cyst
- Meconium pseudocyst
- Ovarian cyst
- Enteric duplication cyst
- Urachal cyst

Umbilical Cord Cysts

- Allantoic cyst
 - Umbilical vessels separated by cyst
- Cysts and pseudocysts other than allantoic
 - Displace cord vessels rather than separate them (paraxial location)

PATHOLOGY

General Features

- Associated abnormalities
 - ~ 35% with other abnormalities
 - ~ 33% associated with other pregnancy complications; causal relationship unclear
 - Oligohydramnios, fetal growth restriction

CLINICAL ISSUES

Presentation

- Most common signs/symptoms
 - Cyst-like lesion in fetal abdomen with venous signal on Doppler interrogation

Demographics

- Epidemiology
 - Incidence of 0.5-2.8:1,000 in fetal ultrasound series

Natural History & Prognosis

- Variable outcomes reported
 - Must differentiate **isolated** from those with other findings
 - 2013 series of 102: All with good outcome
 - Author's institution: 32 cases (2006-2014) with no intrauterine fetal demise (IUFD)
 - 2011 literature review: 4.5% IUFD (total 154 cases of isolated UVV)
 - 8.1-14.3% unexplained IUFD in other smaller series
 - Various series including those **with other findings**
 - Other anomalies (including trisomy 21) (~ 35%)
 - ◻ Cardiovascular, renal most common
 - Chromosomal abnormalities (~ 10%)
 - ◻ Majority with additional sonographic findings
 - IUFD (24%)
 - Hydrops (5%)
- Thrombosis associated with hydrops, IUFD
- UVV of intraamniotic segment may bleed through amniotic sheath → fetal exsanguination

Treatment

- Detailed anatomic survey + formal echocardiography
 - Offer karyotype if other abnormalities or risk factors
- Close fetal monitoring
 - No standard protocol
 - Emphasis on fetal growth, varix size, presence of thrombus, signs of cardiac decompensation
 - Increase surveillance if fetal growth restriction develops
- Recent series suggest that preterm delivery not indicated when UVV isolated

SELECTED REFERENCES

1. Lee SW et al: Clinical characteristics and outcomes of antenatal fetal intra-abdominal umbilical vein varix detection. *Obstet Gynecol Sci.* 57(3):181-6, 2014
2. Bas-Lando M et al: The prenatal diagnosis of isolated fetal varix of the intra-abdominal umbilical vein is associated with favorable neonatal outcome at term: a case series. *Arch Gynecol Obstet.* 288(1):33-9, 2013
3. Mankuta D et al: Isolated fetal intra-abdominal umbilical vein varix: clinical importance and recommendations. *J Ultrasound Med.* 30(2):273-6, 2011

Persistent Right Umbilical Vein

KEY FACTS

TERMINOLOGY

- Persistent right umbilical vein (PRUV): Embryologic right umbilical vein (UV) remains open

IMAGING

- Intrahepatic PRUV most common (90-95%)
 - Intrahepatic UV hooks toward stomach
 - Gallbladder medially displaced
 - Often isolated finding
- Extrahepatic PRUV (5-10%)
 - PRUV bypasses liver and portal system and inserts directly into right atrium or inferior vena cava
 - PRUV runs anterior to liver
 - More likely to have associated anomalies

TOP DIFFERENTIAL DIAGNOSES

- UV varix (normal hook away from stomach)
- Choledochal cyst (no flow on color Doppler)

PATHOLOGY

- Intrahepatic PRUV
 - Left UV occludes instead of right
 - PRUV provides normal flow
- Extrahepatic PRUV
 - PRUV drains into systemic veins (right atrium, inferior vena cava most often)
 - Ductus venosus may be obliterated
- Associations
 - Complex cardiovascular anomalies
 - Trisomy 18, Noonan syndrome
 - Fetal growth restriction

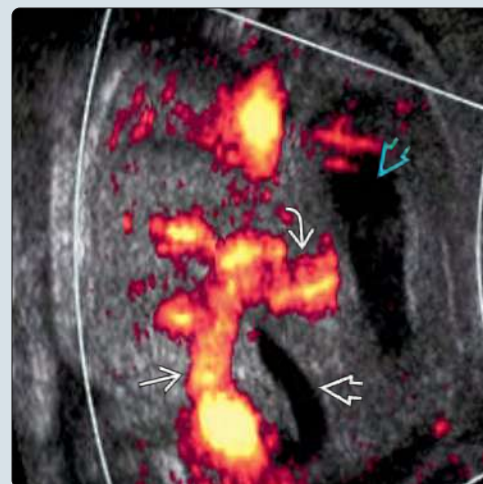
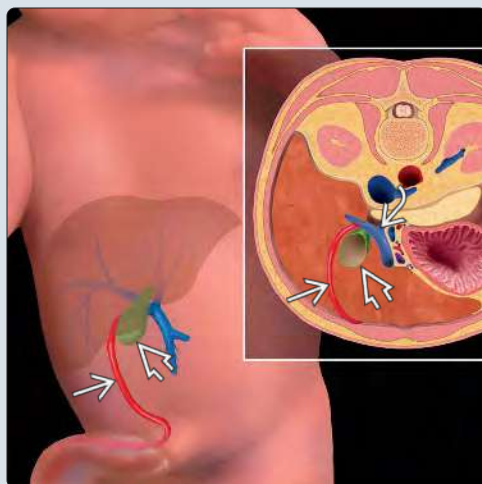
CLINICAL ISSUES

- Incidence: 1:526 fetuses
- Excellent prognosis if isolated

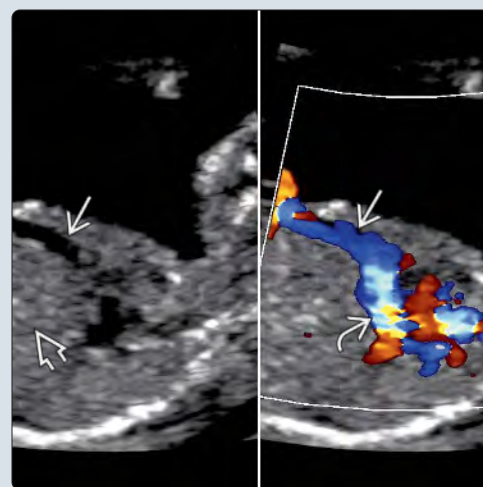
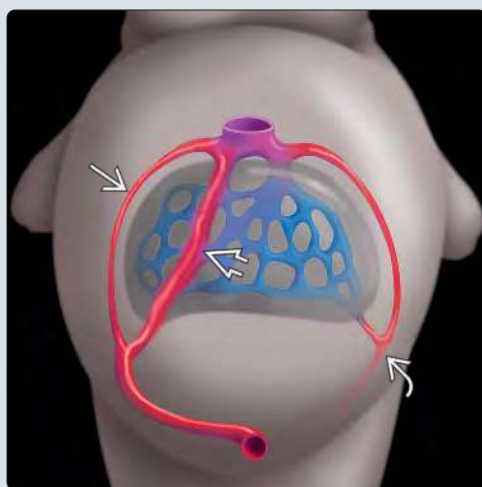
DIAGNOSTIC CHECKLIST

- Recommend formal fetal echocardiography

(Left) The graphic shows a persistent right umbilical vein (PRUV) entering the liver and displacing the gallbladder medially. Within the liver (inset), the PRUV and left portal vein hook toward the stomach. (Right) The abdominal circumference view in this fetus shows the PRUV entering the liver and joining the left portal vein. The gallbladder is displaced medially, and the venous curve/hook is towards the stomach.



(Left) Normally, the right umbilical vein involutes by the 7th week. PRUV occurs when the left umbilical vein involutes instead of the right. PRUV can be intrahepatic, which does not alter the blood distribution to the fetus, or extrahepatic, which bypasses the liver and portal system. An extrahepatic PRUV is more likely to have associated anomalies. (Right) In this fetus with extrahepatic PRUV, the aberrant right umbilical vein courses anterior to the liver and inserts directly into the right atrium.



TERMINOLOGY

Abbreviations

- Persistent right umbilical vein (PRUV)
- Umbilical vein (UV)

Definitions

- Embryologic right UV remains open, and left UV obliterates
- 2 types of PRUV
 - Intrahepatic PRUV (most common)
 - Right UV joins at sinus venosus and proceeds to ductus venosus
 - Extrahepatic PRUV (rare)
 - Right UV bypasses liver and drains directly into right atrium, inferior vena cava, or iliac vein

IMAGING

General Features

- Best diagnostic clue
 - **Intrahepatic PRUV: UV hooks toward stomach**
 - Normally hooks **away** from stomach
 - **Extrahepatic PRUV: UV bypasses liver (no hook in liver)**

Ultrasonographic Findings

- **Intrahepatic PRUV (90-95%)**
 - PRUV passes to right of gallbladder (GB)
 - GB medially displaced
 - PRUV fuses with left portal vein
 - Curves towards stomach
 - Typically seen on abdominal circumference (AC) view
 - Normal portal venous and ductus venosus connections
 - Often isolated finding
- **Extrahepatic PRUV (5-10%)**
 - PRUV bypasses liver and portal system
 - UV courses superiorly anterior to liver
 - Seen best on sagittal view with color Doppler
 - Drains into inferior vena cava or right atrium
 - Single umbilical artery common
 - More likely to have associated anomalies
- Color Doppler and 3D ultrasound
 - Helps show course and connections of PRUV

Imaging Recommendations

- Protocol advice
 - Look at UV curve on all AC images
 - Consider echocardiography
 - Especially for extrahepatic PRUV cases
 - Consider genetic testing if other anomalies seen

DIFFERENTIAL DIAGNOSIS

Umbilical Vein Varix

- Intraabdominal varix most common
- May be associated with growth restriction and aneuploidy

Choledochal Cyst

- Focal or diffuse biliary distention, which may displace GB
- No flow on color Doppler

PATHOLOGY

General Features

- Etiology
 - Normal embryology
 - Initially 2 UVs present, and right obliterates by 7th week
 - Left connects to portal veins and ductus venosus
 - Intrahepatic PRUV
 - Left UV occludes, but PRUV provides normal flow
 - Does not alter blood distribution to fetus
 - Extrahepatic PRUV
 - PRUV drains into systemic veins
 - Right atrium, inferior vena cava most often
 - Ductus venosus may be obliterated
- Genetics
 - Associated with T18 and Noonan syndrome
- Associated abnormalities
 - 26% at time of scan (more likely if extrahepatic PRUV)
 - Cardiovascular most common
 - Growth restriction reported

CLINICAL ISSUES

Presentation

- Most common signs/symptoms
 - Intrahepatic PRUV: Incidentally noted on routine AC view
 - Extrahepatic PRUV: Seen with other anomalies

Demographics

- Epidemiology
 - 1:526 fetuses

Natural History & Prognosis

- Excellent prognosis if isolated
- Prognosis related to associated anomalies and genetic testing results

DIAGNOSTIC CHECKLIST

Consider

- PRUV diagnosis in cases of abnormal-appearing GB

Image Interpretation Pearls

- Diagnosis missed if abnormal direction of UV hook not noticed on AC view
- Look for additional anomalies when PRUV seen

Reporting Tips

- Recommend formal fetal echocardiography

SELECTED REFERENCES

1. Martinez R et al: Perinatal outcome after ultrasound prenatal diagnosis of persistent right umbilical vein. *Eur J Obstet Gynecol Reprod Biol.* 168(1):36-9, 2013
2. Weichert J et al: Persistent right umbilical vein: a prenatal condition worth mentioning? *Ultrasound Obstet Gynecol.* 37(5):543-8, 2011
3. Hoehn T et al: Persistent right umbilical vein associated with complex congenital cardiac malformation. *Am J Perinatol.* 23(3):181-2, 2006
4. Nakstad B et al: Abnormal systemic venous connection possibly associated with a persistent right umbilical vein; a case report. *BMC Pediatr.* 4(1):7, 2004
5. Wolman I et al: Persistent right umbilical vein: incidence and significance. *Ultrasound Obstet Gynecol.* 19(6):562-4, 2002

DIFFERENTIAL DIAGNOSIS**Common**

- Placental Lake, Intervillous Thrombus
- Focal Myometrial Contraction (Mimic)
- Placental Abruption
- Placental Implantation on Myoma (Mimic)
- Chorioangioma
- Gestational Trophoblastic Disease

Less Common

- Placental Mesenchymal Dysplasia
- Placental Teratoma

ESSENTIAL INFORMATION**Key Differential Diagnosis Issues**

- Routinely evaluate whole placenta in orthogonal views
 - Sagittal views
 - Midsagittal (with lower uterine segment)
 - Rule out placenta previa
 - Right and left parasagittal
 - Axial views
 - Upper, mid, lower
 - Find umbilical cord insertion site routinely
 - Marginal insertion is within 2 cm of placental edge
 - Velamentous insertion is on membranes
- Identify anatomic location of mass
 - **Mass within placenta parenchyma**
 - Placental lake
 - Intervillous thrombus
 - Chorioangioma
 - Intraplacental abruption
 - Almost often with concurrent marginal, retroplacental, or preplacental abruption
 - Teratoma (rare)
 - May be exophytic on placenta surface
 - **Mass behind placenta**
 - Retroplacental abruption
 - Myoma
 - Focal myometrial contraction (FMC)
 - **Mass replacing placenta**
 - Complete hydatidiform mole
 - Placental mesenchymal dysplasia
- Interrogate mass with Doppler
 - **Masses with flow**
 - Chorioangioma
 - Complete hydatidiform mole
 - Myoma behind placenta
 - Teratoma (rare)
 - **Masses with little or no flow**
 - Abruption (hematoma with no flow)
 - FMC (similar or less than other myometrium)
 - Characterize pattern of flow
 - Variable flow with chorioangioma
 - Some are highly vascular
 - Peripheral flow with myoma
 - Linear contiguous flow with FMC

Helpful Clues for Common Diagnoses

- **Placental Lake, Intervillous Thrombus**
 - Often seen together
 - Lakes will have swirling blood
 - Thrombus will have no flow
 - Hypoechoic round or oval mass
 - Surrounded by normal placenta
- **Focal Myometrial Contraction (Mimic)**
 - Transient uterine wall contraction
 - Normal finding throughout pregnancy
 - Will resolve or change with time
 - May take > 30 minutes
 - May need to reassess on follow-up exams
 - Inner contour affected most
 - Inner uterine bulge
 - Outer contour relatively preserved
 - FMC tends to be isoechoic to uterine wall
- **Placental Abruption**
 - Identify abruption location
 - Marginal (most common)
 - Retroplacental
 - Preplacental (most rare)
 - Any may have intraplacental component
 - Retroplacental abruption can mimic mass
 - Thick placenta may be only finding
 - Acute blood isoechoic to placenta
 - Blood becomes hypoechoic with time
 - Doppler shows no flow in hematoma
 - Look for signs of fetal distress
 - Bradycardia
 - Abnormal biophysical profile
 - Fluid/movement/breathing assessment
 - Abnormal fetal Doppler parameters
 - Assess amount of placenta detached
 - < 30% associated with good prognosis
 - > 50% associated with poor prognosis
- **Placental Implantation on Myoma (Mimic)**
 - Myoma appearance is variable
 - Focal hypoechoic or heterogeneous mass in uterus
 - ± calcifications
 - Myomas may degenerate during pregnancy
 - Central cystic change
 - Decreased blood flow
 - Present with pain
 - Retroplacental myomas are associated with abruption
 - Use Doppler to differentiate blood from myoma
 - Large and multiple myomas associated with fetal growth restriction
- **Chorioangioma**
 - Benign, vascular placental tumor
 - Most < 5 cm
 - Common location is on fetal side of placenta, near cord insertion site
 - Ultrasound features
 - Well-defined mass
 - Generally hypoechoic
 - Heterogeneous if hemorrhage, infarction or degenerating
 - Variable amount of blood flow

- Use color Doppler to assess vascularity

- **Gestational Trophoblastic Disease**

- Most common type is hydatidiform mole
 - 100% paternal genetic makeup
 - Typical ultrasound appearance
 - Placental cysts
 - Anembryonic gestational sac
 - Associated perigestational hemorrhage
 - Doppler findings
 - ↑ flow between cysts
 - High-velocity, low-impedance flow
 - Associated theca lutein cysts
 - Bilateral, multiseptated ovarian cysts
 - Seen in 50% of cases
- Triploidy
 - Variable amount of placental cysts
 - Abnormal fetus with growth restriction
 - Highly associated with theca lutein cysts
- Invasive mole and choriocarcinoma are rare complications

Helpful Clues for Less Common Diagnoses

- **Placental Mesenchymal Dysplasia**

- Placentomegaly and abnormal chorionic villi
 - Large placenta with cysts on ultrasound
 - Secondary severe fetal growth restriction
- Mimics gestational trophoblastic disease (triploidy)
 - Need genetic testing to differentiate

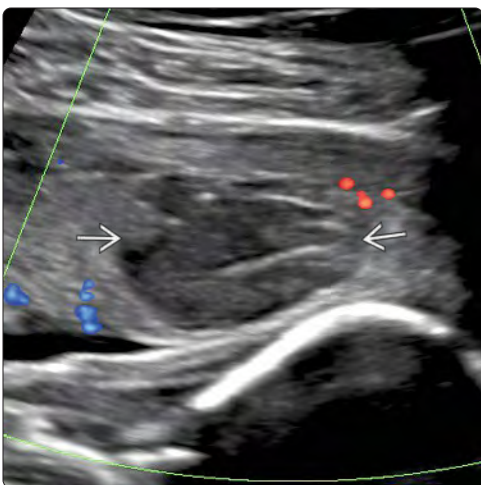
- **Placental Teratoma**

- Extremely rare
- Benign mature teratoma
- Calcifications suggest diagnosis
- Differentiate from demised twin next to placenta and twin reversed arterial perfusion (TRAP)
 - Direct blood supply from placenta, not through umbilical cord as in TRAP
- Histogenesis theories
 - Twin incorporated in placenta
 - Hindgut fetal germ cells grow into placenta

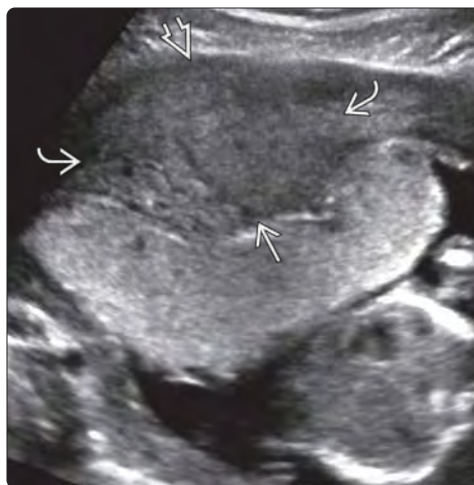Other Essential Information





- Placental masses may be either incidental at time of exam or symptomatic
- Symptoms associated with abruption
 - Retroplacental abruption
 - Pain/preterm labor
 - Fetal distress
 - Less likely to have bleeding
 - Marginal abruption
 - Bleeding ± contractions
 - Preplacental hemorrhage
 - Asymptomatic or fetal distress if near cord insertion
 - Large abruptions often multifocal
 - Can bleed directly into placenta
 - Evaluate placenta 1st in cases of preterm labor and bleeding
 - If large abruption or fetal distress, then curtail exam
 - Viable fetus may need emergent delivery
 - Patients at high risk for abruption
 - Prior history of abruption
 - Trauma
 - Hypertension
 - Smoking, cocaine
 - Increased parity, advanced maternal age
 - Placenta implanted on myoma
- Signs and symptoms of molar pregnancy
 - Large uterus for dates
 - Bleeding
 - Hyperemesis
 - From ↑ human chorionic gonadotropin levels
 - Preeclampsia
- Signs and symptoms associated with large chorioangioma
 - > 5 cm considered large
 - Elevated maternal serum α-fetoprotein
 - Hydrops fetalis
 - ↑ arterial flow leads to high-output cardiac failure
 - Fetal anemia
 - Polyhydramnios
 - Preterm labor and preeclampsia

Placental Lake, Intervillous Thrombus



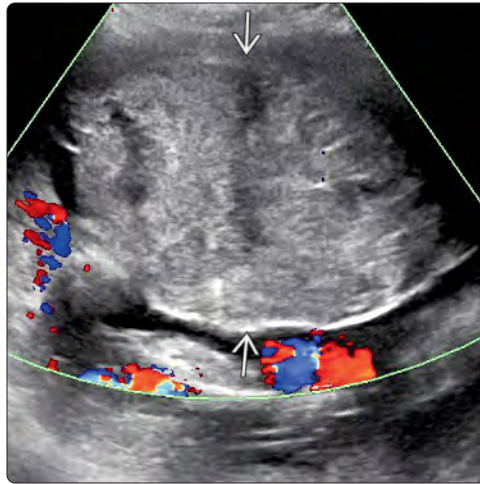
Focal Myometrial Contraction (Mimic)



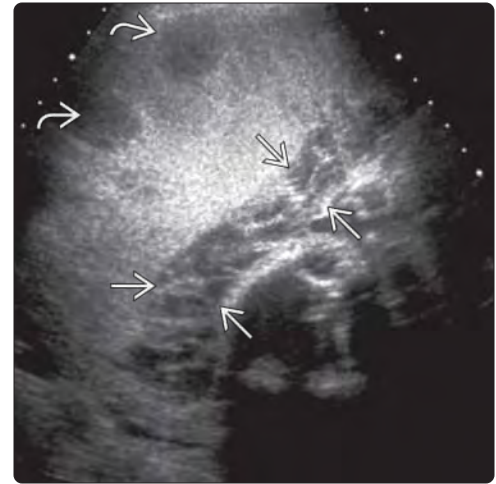
(Left) This 23-week placenta contains an oval, hypoechoic, minimally complex mass , which is surrounded by normal placenta and has no blood flow. It is theorized that thrombosis of a placental lake leads to intervillous thrombus. (Right) In this case, a focal myometrial contraction (FMC)  is seen behind the placenta. Notice the inner contour  of the myometrium is affected more than the outer contour  and the FMC is isoechoic to the rest of the myometrium. The FMC eventually resolved.

Placental Abruption

(Left) The placenta is thick, heterogeneous, and avascular secondary to a large acute intraplacental abruption. The patient presented with preterm labor. Acute blood is isoechoic to placenta parenchyma. **(Right)** Sagittal ultrasound of the placenta in another patient with preterm labor and no bleeding shows both retroplacental and preplacental hematomas. With large abruptions, mass-like hematomas can be seen in several locations.

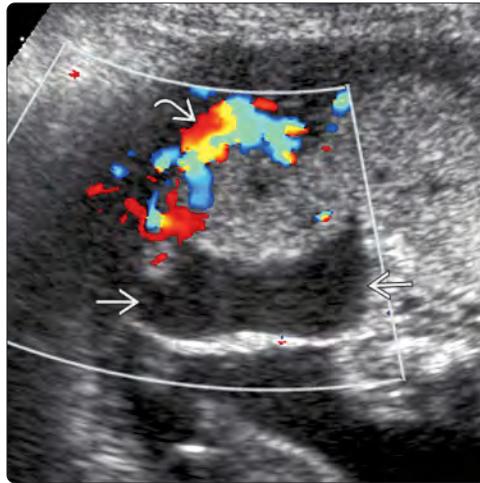


Placental Abruption

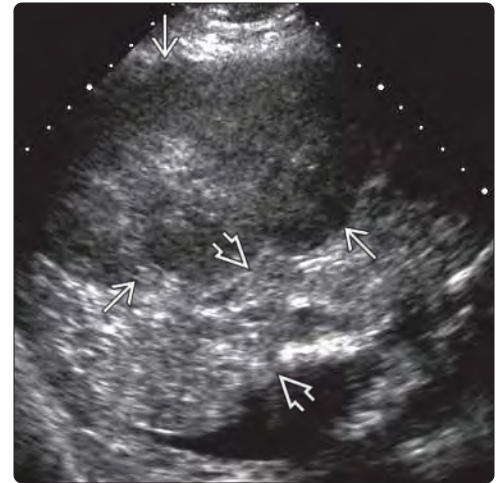


Placental Abruption

(Left) In this case of an old preplacental abruption, the blood is hypoechoic and avascular. Color Doppler shows retroplacental flow behind the otherwise well-attached anterior placenta. **(Right)** In another case of old abruption, the hypoechoic hematoma is behind the placenta. Originally, the hematoma was isoechoic to the placenta. Old retroplacental abruptions mimic other hypoechoic myometrial masses, such as fibroids.

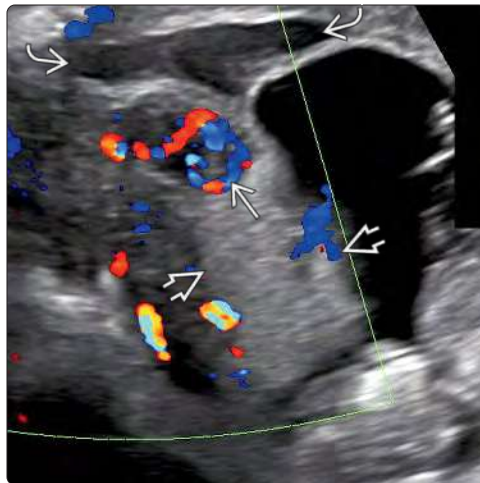


Placental Abruption

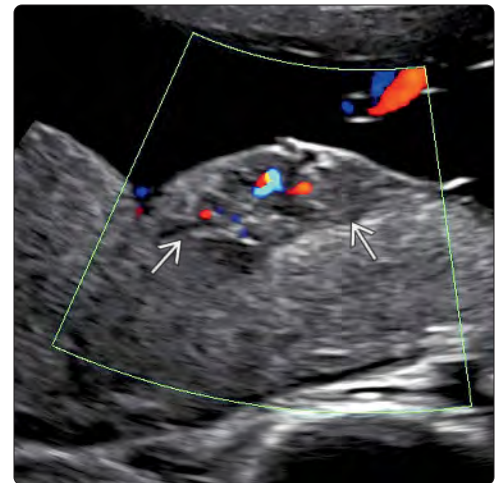

Placental Implantation on Myoma (Mimic)

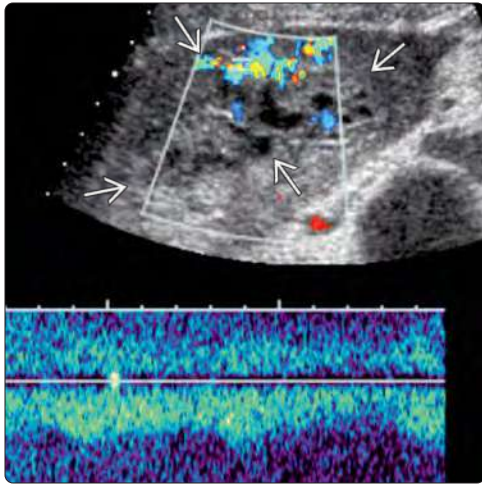
(Left) In this early 2nd-trimester pregnancy presenting with bleeding, part of the placenta implants on a vascular fibroid with peripheral flow. In addition, there is a marginal abruption. Placental implantation on a fibroid increases the risk for abruption. **(Right)** In this case, a hypoechoic placental surface mass contains blood flow. Chorioangiomas are typically small, vascular, and located on the placental surface, near the cord insertion site. The presence of blood flow helps differentiate these common masses from other diagnoses.



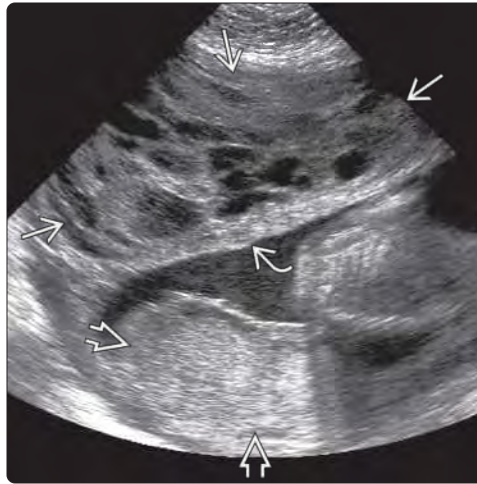
Chorioangioma



Gestational Trophoblastic Disease

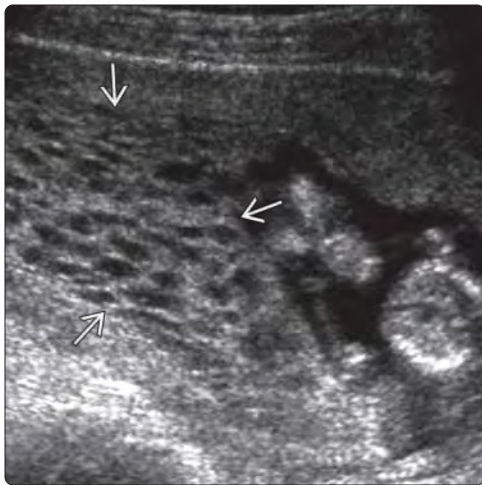


Gestational Trophoblastic Disease

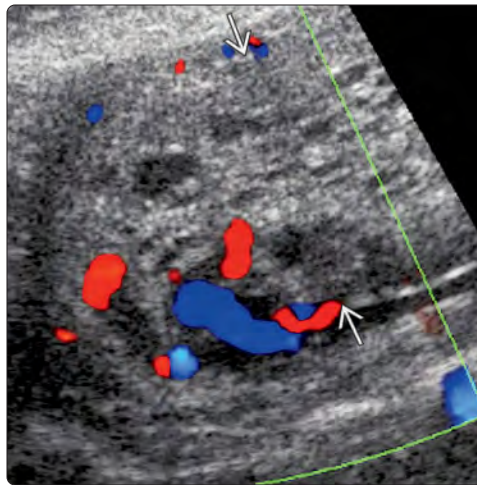


(Left) Sagittal color and pulsed Doppler ultrasound of an early 2nd-trimester pregnancy shows that the uterus is filled by a cystic, vascular mass and that there is no fetus. This is an example of a classic hydatidiform mole diagnosis. (Right) Axial transabdominal ultrasound in another case shows a molar pregnancy and a coexistent twin. The mole is cystic and is separated from the normal placenta by a thick dividing membrane.

Gestational Trophoblastic Disease

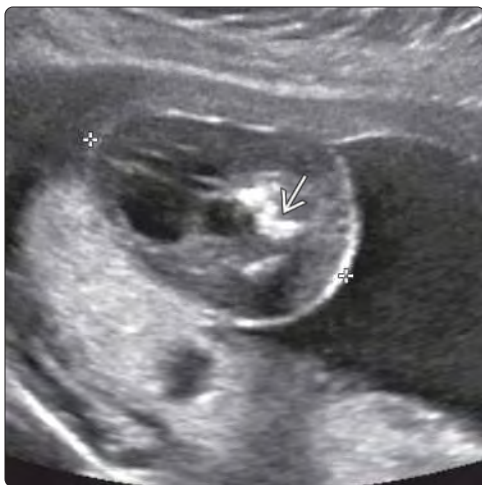

Placental Mesenchymal Dysplasia

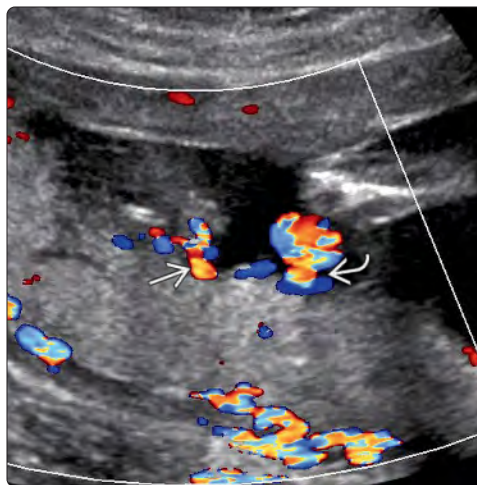


(Left) This 20-week placenta is enlarged and cystic. The fetus demonstrated early, severe growth restriction and amniocentesis results were triploidy. (Right) In this case with a thick cystic placenta and fetal growth restriction, the amniocentesis results were normal. The fetus died in utero and the placental pathology showed mesenchymal dysplasia. Sonographic features are identical to a cystic placenta from triploidy and genetic testing is recommended. Both carry a grim prognosis.

Placental Teratoma



Placental Teratoma



(Left) The exophytic placental mass contains calcification, a characteristic finding for the rare diagnosis of placental teratoma. (Right) Color Doppler of the mass in the same case shows direct blood supply to the teratoma from the placenta, not through an umbilical cord. The normal cord insertion for the fetus is also seen.

DIFFERENTIAL DIAGNOSIS

Common

- Physiologic Gut Herniation
- Umbilical Cord Cyst
 - True Cyst
 - Allantoic Cyst
 - Omphalomesenteric Duct Cyst
 - Pseudocyst
 - Cystic Wharton Jelly
- Omphalocele

Less Common

- Cord Knot
 - False Knot
 - True Knot
- Hypercoiled Cord
- Cord Hematoma
- Cord Thrombosis
- Cord Mass
 - Cord Hemangioma
 - Cord Teratoma

ESSENTIAL INFORMATION

Key Differential Diagnosis Issues

- Cord embryology
 - 7-8 weeks
 - Early connecting stalk connects embryo to chorion via omphalomesenteric duct
 - 12-16 weeks
 - Allantois develops as outpouching from primitive gut & extends into connecting stalk
 - Umbilical cord blood vessels develop via allantois
 - Allantois functions as primitive bladder & early blood forming organ
 - Persistent segments of allantois are termed urachal remnants
 - Allantois involutes to become median umbilical ligament
 - Urachus serves as "pop-off valve" to decompress bladder if outlet obstruction
 - Cysts may form from remnants of allantois or omphalomesenteric duct & are often transient finding
 - Vessels
 - 2 umbilical arteries (UA) & 2 umbilical veins are present at 6 weeks
 - Right umbilical vein regresses by 8 weeks
- Cord assessment is part of all OB scans
- **Look at abdominal cord insertion site**
 - At time of nuchal translucency (NT) assessment
 - Physiologic bowel herniation resolves by 12 weeks
 - At midgestation anatomy scan
 - Show intact abdominal wall on all sides
 - Difficult in 3rd trimester
- **Look at placental cord insertion (PCI) site**
 - 1st-trimester assessment at time of NT scan
 - At time of anatomy scan & in 3rd trimester
 - PCI evaluation is particularly important if multiple gestations

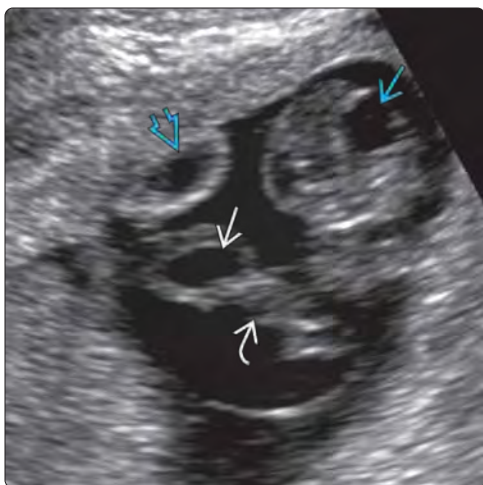
- Monozygotic twinning is highly associated with abnormal PCI for 1 or both fetuses
- Velamentous cord insertion associated with increased risk of fetal morbidity
 - Vasa previa if near cervical os
 - Associated with fetal growth restriction
- Document 2 arteries & 1 vein
 - Free loop of cord image
 - Long axis & short axis
 - 2 UA around fetal bladder on color Doppler axial view of bladder
- Evaluate general cord morphology
 - Long axis views & 3D best
 - Are vessels normal in size & echogenicity?
 - Is cord length & width normal?
 - Normal length is 50-60 cm by end of 2nd trimester
 - Difficult to evaluate unless markedly short or long
 - Normal cord diameter is < 2 cm
 - Mostly determined by amount of Wharton jelly
 - Is there appropriate degree of "twist" to vessels?
 - Umbilical cord index (UCI) = number of cord spirals/cm of cord
 - Hypercoiled: $UCI \geq 0.60$
 - Hypocoiled: $UCI \leq 0.29$
 - UCI correlates well with postnatal findings

Helpful Clues for Common Diagnoses

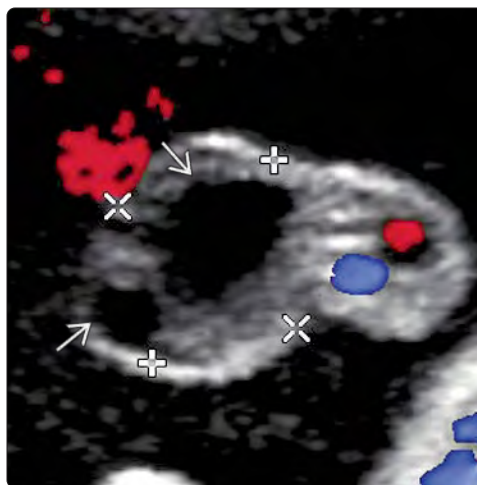
- **Physiologic Gut Herniation**
 - Normal embryological developmental phenomenon
 - Bowel elongates, herniates into base of cord, rotates 270°, then returns to peritoneal cavity
 - Bowel returns to abdomen by 12 weeks
 - Should not extend > 1 cm into base of cord
 - Never contains liver
- **Umbilical Cord Cyst:** Categorized as true cysts & pseudocysts
 - Locations
 - Paraxial (eccentric): Do not displace vessels
 - Axial (central): Vessels are splayed
 - May occur anywhere along UC length
 - Fetal & placental ends > free loop
 - Generally thin walled, anechoic, often multiple
 - If echogenic content, consider intracystic hemorrhage, which may lead to cord compromise
 - Isolated cord cysts often resolve spontaneously
 - 1st-trimester incidence is 3.4% & 20% persist
- **True Cyst**
 - **Allantoic & Omphalomesenteric Duct Cysts**
 - **Allantoic cysts may be associated with patent urachus**
 - Always near fetal insertion
 - Often associated with bladder obstruction (bladder decompresses into patent urachus & base of cord)
 - Might see intracorporeal patent urachus (cystic mass superior to, & communicating with, bladder)
 - May grow & compress cord
 - **Omphalomesenteric duct cyst**
 - 2° to omphalomesenteric duct remnant
 - May be associated with abdominal wall & other anomalies






- **Pseudocyst**
 - **Cystic Wharton jelly** is mucopolysaccharide-rich membrane that covers cord
 - Edema & liquefaction of Wharton jelly leads to cord thickening & cysts
 - Associations: Fetal trisomy, omphalocele, diabetes
 - **Omphalocele**
 - Small omphaloceles containing only small bowel most likely to be confused with cord mass
 - Smooth echogenic mass protruding from central anterior abdominal wall with covering membrane
 - Association with aneuploidy higher than liver-containing omphalocele
 - Associated cyst, most commonly omphalomesenteric duct cyst, & ascites common
- Helpful Clues for Less Common Diagnoses**
- **Cord Knot**
 - False knots more common than true knots
 - Due to kinks in cord, not true knot
 - No known clinical significance
 - True knot is rare (< 1% of singleton pregnancies)
 - Most are loose & occur in utero or during birth
 - Marginal impact on fetal well-being
 - Tight knots may lead to asphyxia & demise
 - Hanging noose sign: Loop of cord closely surrounded by another loop of cord
 - Reported to lead to 4x increase in fetal loss
 - Risk factors include advanced maternal age, multiparity, long umbilical cord
 - Cord entanglement is hallmark finding in monoamniotic twin gestations
 - **Hypercoiled Cord**
 - Appears thickened & cystic or mass-like
 - Color Doppler shows flow in vessels
 - Associations: Polyhydramnios, growth restriction, diabetes, anomalies
 - **Cord Hematoma**
 - Extravasation of blood into Wharton jelly surrounding cord vessels
 - May occur following invasive prenatal procedures
 - At risk for cord compression
 - Use Doppler to look for increased vascular resistance
 - Clot may be seen adherent to cord secondary to intraamniotic bleeding from any cause
 - Less likely to cause cord compression if intraamniotic
 - **Cord Thrombosis**
 - Hypoechoic intravascular material distending vessels on grayscale images
 - Lack of flow on color or power Doppler
 - Venous thrombosis is cause of sudden fetal demise
 - Most cases with surviving fetuses are reported as pathological finding after emergency delivery for distress in labor
 - Umbilical vein varix is risk factor
 - May occur following invasive prenatal procedures
 - Especially if hematoma compresses vessels
 - May occur in association with large cord cysts
 - Particularly at placental end of cord
 - **Cord Hemangioma**
 - Most commonly at placental insertion site
 - Angiomatous mass
 - Surrounding Wharton jelly edema & cystic degeneration common
 - Ultrasound findings
 - Fusiform shape
 - Echogenic or multicystic
 - May have small punctate calcifications
 - Vascular flow may be seen with Doppler
 - **Cord Teratoma**
 - Rare (12 reported cases in literature)
 - Solid & cystic with possible calcifications
 - No increased prevalence for any particular site
- Other Essential Information**
- Multiple umbilical cord cysts associated with increased risk of poor outcome
 - Straight cords with few or absent helices are associated with adverse fetal outcomes

Umbilical Cord Cyst



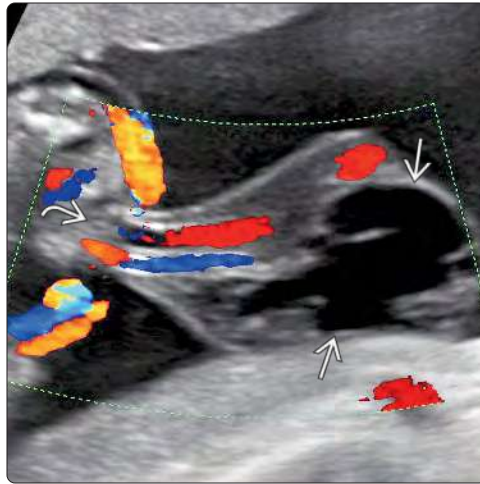
Umbilical Cord Cyst



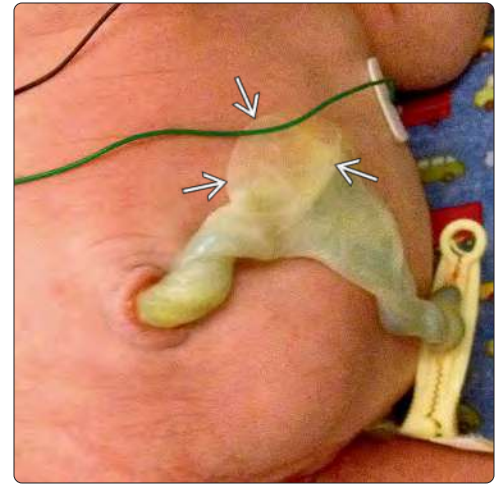
(Left) A small cyst  is seen in the umbilical cord  of this early embryo. The other normal cystic "lesions" seen here are the yolk sac  and the rhombencephalon . 80% of umbilical cord cysts seen in the 1st trimester resolve. **(Right)** Two small eccentric umbilical cord cysts  were seen at the time of anatomy scan in this 20-week fetus. No other anomalies were seen, and the finding was considered of low risk to the pregnancy. Umbilical cord cysts form from remnants of the allantois or omphalomesenteric duct.

Allantoic Cyst

(Left) This is an allantoic cyst associated with a patent urachus. An eccentric umbilical cord cyst is seen near the fetal cord insertion site. The fetus had a markedly dilated bladder from prune-belly syndrome. (Right) The deflated umbilical cord cyst is seen in the same case after delivery. Note the abdominal laxity and wrinkled skin, classic for prune-belly syndrome. Patent urachus and allantoic cysts near the cord insertion site are associated with bladder obstruction and distention.

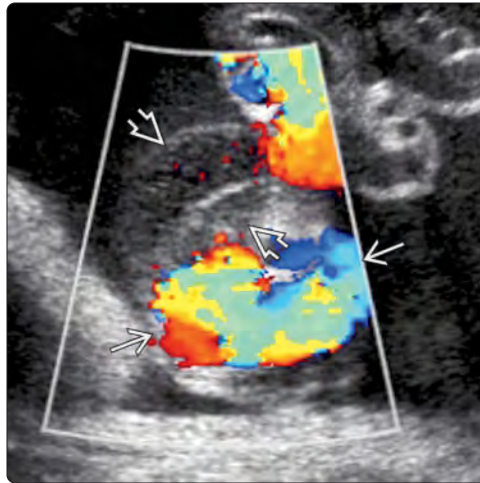


Allantoic Cyst

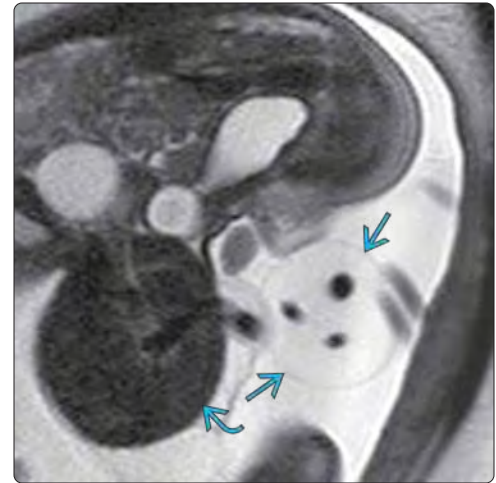

Cystic Wharton Jelly

(Left) In this case, a segment of the umbilical cord is thick, secondary to cystic degeneration of Wharton jelly. This finding can mimic a cord mass. The fetus also had macroglossia and macrosomia, and was diagnosed with Beckwith-Wiedemann syndrome after delivery. The fetus did not have an omphalocele. (Right) Fetal MR in another fetus with liver-containing omphalocele shows a thickened cystic cord. Mucoïd degeneration of Wharton jelly is associated with omphalocele and aneuploidy.

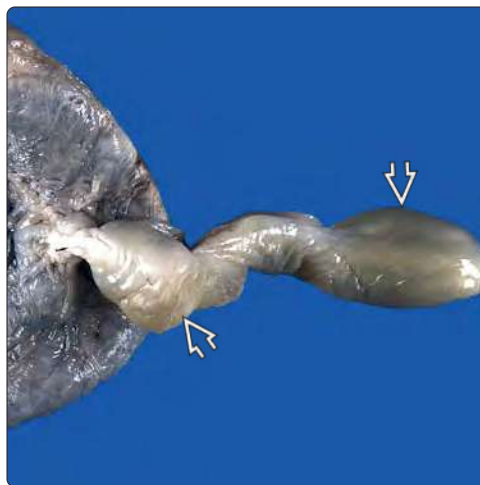


Cystic Wharton Jelly

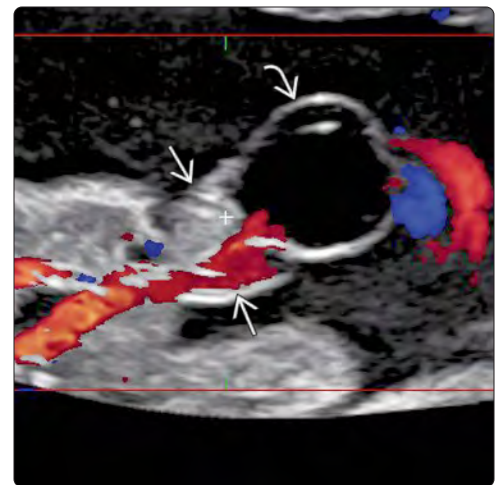


Cystic Wharton Jelly

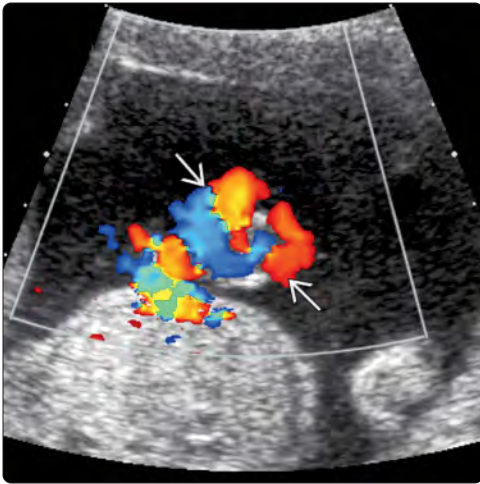
(Left) This gross image of the cord shows a glistening surface with marked cord edema from degenerated Wharton jelly. (From DP: Placenta.) (Right) This fetus has a small bowel-only omphalocele. There is an associated cyst, which is either Wharton jelly degeneration or a true cyst, most commonly an omphalomesenteric duct cyst. When omphaloceles contain only the small bowel, there is a higher risk of aneuploidy.



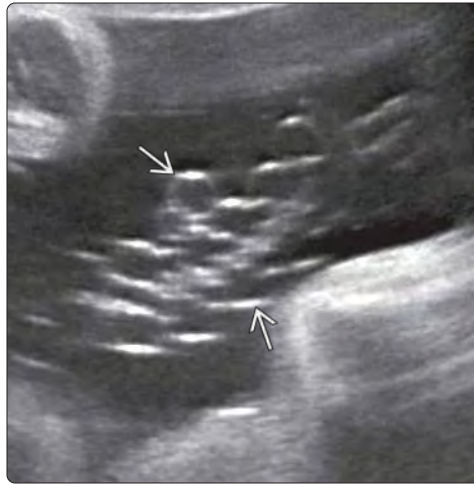
Omphalocele



False Knot

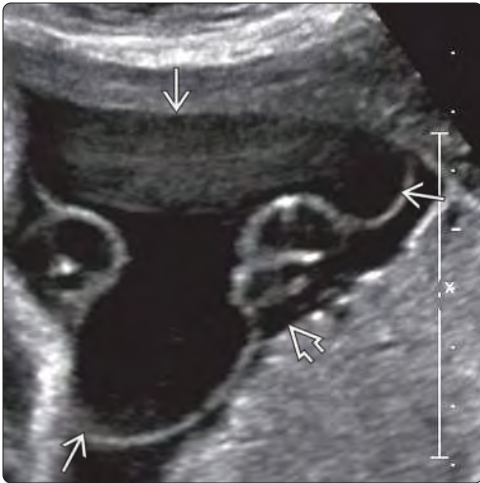


Hypercoiled Cord

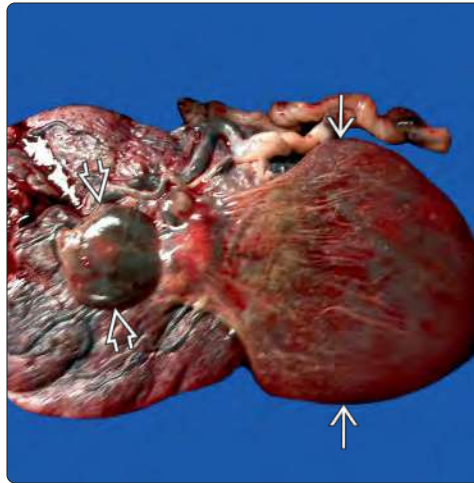


(Left) Color Doppler ultrasound shows an apparent cord knot close to the abdominal wall insertion site in a singleton pregnancy. There were no other findings. This was a false knot due to kinked vessels rather than a true knot. (Right) This 2 vessel umbilical cord appears thickened & cystic, but color Doppler showed flow throughout the cord. The vessels appear stacked upon each other because the cord is hypercoiled. The pregnancy was complicated by polyhydramnios from duodenal atresia.

Umbilical Cord Cyst

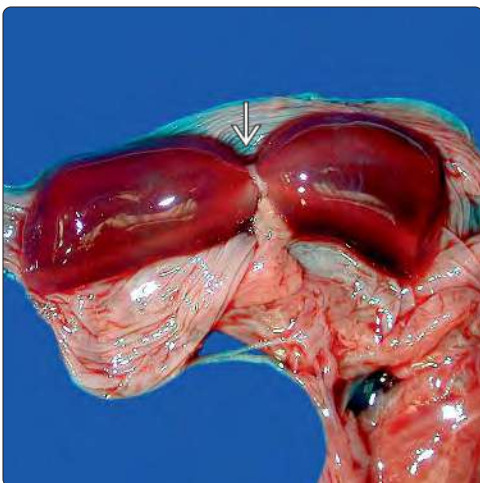

Cord Hematoma

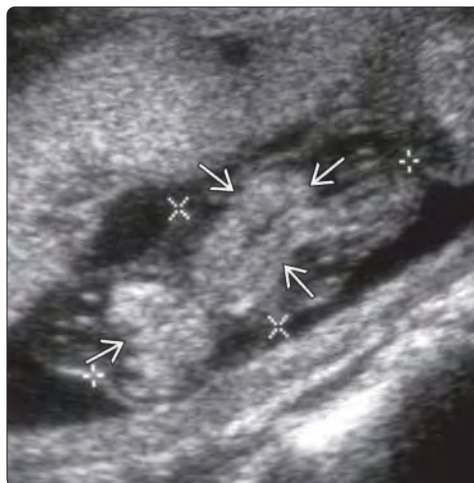


(Left) A large anechoic umbilical cord cyst is seen near the cord insertion site. Multiple other thin-walled anechoic cysts were seen in this case with an otherwise normal fetus. (Right) Clinical photograph of the same case shows a large blood-filled cyst & a 2nd smaller blood-filled cyst. This is a rare complication, & in this case, most likely occurred during delivery. A cord hematoma may also occur as a result of an invasive prenatal procedure. Potential complications include vessel compression and thrombosis.

Cord Thrombosis



Cord Hemangioma



(Left) Gross pathology shows an amniotic band wrapped tightly around the cord, resulting in thrombosis & fetal demise. This was particularly unfortunate as the only fetal anomaly involved the fingers of one hand. (Right) An echogenic fusiform mass is seen in the center of the cord. Post delivery pathology revealed a hemangioma. Cord masses, such as hemangioma & teratoma, are rare.

This page intentionally left blank

SECTION 11

Multiple Gestations



Approach to Multiple Gestations	840
Dichorionic Diamniotic Twins	846
Monochorionic Diamniotic Twins	850
Monochorionic Monoamniotic Twins	854
Discordant Twin Growth	858
Twin-Twin Transfusion Syndrome	862
Twin Reversed Arterial Perfusion	866
Conjoined Twins	870
Triplets and Beyond	874
Fetus-in-Fetu	878

Background Information

Between the early 1980s and late 1990s, there was a 52% increase in the twin birth rate, mostly in women over 30. This is attributed to increased utilization of assisted reproduction techniques (ART) as well as increasing maternal age. Indeed, the number of 44- to 49-year-old mothers increased 10x in the same period. Between 1980 and 2006, the twin birth rate increased by almost 70% for the same reasons.

Embryology

Dizygotic twinning occurs when two ova are fertilized by separate spermatozoa. This can be spontaneous or as a result of ART techniques. Each fertilized ovum develops independently; therefore, there are two chorions, amnions, yolk sacs, and embryos. The process is the same for higher order multiples.

Dichorionic twinning can be a result of dizygotic gestation but can also occur with fertilization of a single ovum (monozygotic twinning). If the zygote produced by fertilization splits within three days of conception, there is complete duplication of all cell lines with formation of chorions, amnions, yolk sacs, and embryos. This is the "best" type of monozygotic twinning in that the likelihood of two live births is highest.

Monochorionic (MC) twinning occurs when the split of the developing structures occurs later than the third day post conception. There are several variants.

- **Monochorionic diamniotic twins:** If blastocyst inner cell mass splits between 4th and 8th days post conception, chorion has already formed; pregnancy is thus monochorionic, but there will be 2 embryos, each with its own amnion and chorion
- **Monoamniotic twins:** If split occurs after 8th day post conception, chorion and amnion are already formed, as is yolk sac; therefore, only duplication is of embryo; two embryos develop within single amniotic sac, which in turn is associated with single yolk sac and chorion
- **Conjoined twins:** If split of developing embryo occurs after 13th day post conception, split is incomplete; some structures are duplicated and some are shared; degree of sharing determines prognosis for survival and separability

Imaging Techniques and Normal Anatomy

The first trimester is the best time to evaluate chorionicity in a multiple pregnancy. Transvaginal sonography (TVUS) provides much higher resolution images than transabdominal scanning and is the preferred modality. Chorionicity determines prognosis; therefore, the sooner it is established, the sooner a plan of management can be established. It is advised that an image documenting chorionicity be permanently retained in each patient record.

In higher order multiples, the same principles apply: Count the chorionic sacs, then the amniotic sacs, then the embryos. On very early scans, before visibility of the embryo and amnion, the yolk sacs may be counted as a surrogate for amnions; however, the amnionity must be verified by direct visualization of amniotic membranes as soon as possible. Chorionicity and amnionity gets complicated with high-order multiples. For example, triplets can be trichorionic triamniotic, dichorionic triamniotic (one singleton with a monochorionic

diamniotic pair), dichorionic diamniotic (one singleton with a monoamniotic pair), or, rarely, monochorionic triamniotic.

Multiple pregnancies are at increased risk for anomalies and aneuploidy. Early evaluation allows for early diagnosis with the potential for selective reduction of an abnormal fetus.

Doppler is an important component of multiple gestation surveillance. Color Doppler is helpful to map the placental cord insertion sites. Multiples with marginal or velamentous insertion are at increased risk of growth restriction, and in monochorionic twins, velamentous cord insertion is a marker for unequal placental sharing. Color Doppler is also the best method to detect vasa previa. Aneuploidy screening in the first trimester includes assessment of the ductus venosus waveform; abnormal ductus flow may also indicate increased risk for structural abnormality (e.g., congenital heart disease) or for twin-twin transfusion syndrome (TTTS) in monochorionic diamniotic twins. In the second and third trimester, Doppler interrogation of the umbilical arteries, middle cerebral arteries, and ductus venosus is used to diagnose and stage twin anemia polycythemia sequence and TTTS, as well as to monitor twins with growth discordance. Much research is directed toward improving assessment of TTTS with the use of Doppler parameters obtained during echocardiography.

Approach

How Many Embryos and Where?

Potential pitfalls in the diagnosis of a multiple pregnancy can occur, especially in the ART population. Müllerian duct anomalies are more common in the ART population, and it is possible for there to be a pregnancy in each horn of a bicornuate uterus or for twins to be present in one horn and only decidualized endometrium in the other. ART patients are at increased risk for ectopic pregnancy; the presence of an intrauterine pregnancy (IUP) in this population does not exclude a heterotopic pregnancy.

What Is the Chorionicity/Amnionity?

If each gestational sac has a thick chorionic ring, twins are dichorionic, triplets trichorionic, etc. The next structure to become visible is the yolk sac; the number of yolk sacs parallels the number of amnions. If two embryos are seen in a chorionic sac with two yolk sacs, the pregnancy is likely monochorionic diamniotic. The delicate amniotic membrane becomes visible later and is best seen with TVUS. If only one amniotic membrane is seen, the differential diagnosis is between monochorionic monoamniotic twins and conjoined twins. Conjoined twins in the first trimester are likely to be in fixed relationship to each other as the embryos are small and bridging tissues are less pliable. The key observation with conjoined twins is skin contiguity between them at the site of attachment.

Chorionicity is an important determinant of outcome in multiples. Much of the perinatal morbidity and mortality relates to preterm birth, which is in turn related to chorionicity. Early delivery is much more likely in a complicated monochorionic pregnancy than in a dichorionic twin gestation. The probability of delivering two live infants decreases progressively from dichorionic to monochorionic to monoamniotic pregnancies.

Who Is Who?

The position of the embryos/fetuses changes as growth occurs, but it is important to track the growth of each fetus

accurately and consistently. If selective reduction is being considered, it is crucial that the correct embryo be identified. If there is an obvious malformation, it is easy to keep track. However, if chorionic villus sampling (CVS) reveals aneuploidy, then there may not be a structural difference to guide reduction. It is wise to document the position of each sac very carefully prior to CVS to both make sure that each chorion is sampled accurately and ensure that, if anomaly is identified, the correct embryo is reduced. Mapping is particularly complex in higher order multiples but is especially important if reduction is being considered.

Whatever labeling strategy is used (in our lab the fetus closest to the cervix is identified as A, the presenting twin), it is important to be consistent. Ideally, each twin should be identified by as many features as possible in order to avoid confusion. For example, a description of "twin A, female, maternal left, cephalic presentation, posterior placenta" leaves no doubt. Obviously, monoamniotic twins are the most challenging to label consistently as there is a single placenta and they are free to move around with respect to each other.

Signs of Increased Risk of Aneuploidy?

Evaluation of nuchal translucency is appropriate in multiple gestations. It can be combined with maternal age or maternal serological testing. Maternal serum screening in multiple gestation provides a risk per pregnancy; in singletons, the risk is per fetus. There are conflicting reports on the utility of cell free fetal DNA testing in multiple pregnancy; it may be less reliable in this setting than in a singleton pregnancy.

Major Anomaly?

Anatomic survey at the time of nuchal translucency screening can identify several major anomalies such as anencephaly/holoprosencephaly, abdominal wall defects, cystic hygroma, and abnormal cardiac axis which, in turn, identifies significant congenital heart disease.

Where Are Placental Cord Insertion Sites?

Marginal cord insertion may become velamentous as pregnancy progresses. Velamentous cord insertion increases the risk for vasa previa and, in monochorionic twins, it is a marker for unequal placental sharing and increased risk for selective fetal growth restriction.

Fetuses Conjoined?

The outcome for conjoined twins is poor with the majority dying in utero or in the immediate postpartum period. If parents wish to pursue separation, it is important to map the anatomy as accurately as possible prior to delivery. Echocardiography of conjoined twins is easier in utero as there are more options for acoustic access. Fetal MR can be very helpful to layout anatomy with the advantage that the fetuses are stable on placental support and do not require sedation.

What Else to Look for in Second and Third Trimesters? Are There Anomalies?

Structural anomalies are more common in multiples than singletons and, within multiples, are more common in monozygotic than dizygotic twins. Maternal serum screening provides a risk per pregnancy; in singletons, the risk is per fetus. The genetic sonogram is of greater importance in multiples; it can identify the fetus with an open neural tube defect causing true elevation of maternal serum alpha fetoprotein or identify sonographic markers for aneuploidy to direct amniocentesis.

Are There Specific Complications of Monochorionic Placentation?

Specific complications of monochorionic twinning include TTTS, twin anemia polycythemia sequence (TAPS), twin reversed arterial perfusion sequence (TRAP), and the so-called twin "embolization" syndrome seen in the event of demise of one MC twin. In MC twins, always check the direction of flow in the umbilical artery of an anomalous twin; doing so will lead to a confident diagnosis of TRAP if it is reversed. The reverse-perfused twin is nonviable, therefore pregnancy management is focused on survival of the normal, pump twin. If the twins are monoamniotic, cord entanglement is an almost universal observation.

Are There Placental Variants?

Succenturiate lobes and vasa previa are increased in multiples. A succenturiate lobe is not a risk factor for poor outcome per se, but it is important that the delivering care provider knows of its existence to ensure that the placenta is carefully inspected for complete delivery. In vasa previa, fetal arteries run across the cervix; exsanguination and demise occur rapidly if the vessels are damaged during cervical dilatation or at the time of spontaneous membrane rupture.

In a patient with a multiple pregnancy and a prior cesarean section, there is more placental tissue than in a singleton, and placenta accreta is a definite risk. The relationship of placental tissue to the prior hysterotomy should be carefully evaluated. ART patients may have had myomectomy or metroplasty, placing them at risk for abnormal placental adherence at the surgical site. These patients are difficult to assess sonographically, and MR may be the best modality in this group.

Is There Growth Discordance or Selective Growth Restriction?

Multiple gestations are at increased risk of growth restriction, and most are monitored more frequently than singletons to assess interval growth of each fetus as well as whether or not growth is concordant. The outcome for discordant twins is worse if there is preterm delivery or if the twins are monochorionic.

Role of Doppler

Umbilical artery (UA) Doppler is a component of staging for TTTS and many authorities recommend middle cerebral artery Doppler following treatment by laser coagulation to detect TAPS. As the Solomon technique of "dichorionization" of the placenta becomes more widespread, it is likely that post laser TAPS will become less common.

Several studies have shown the impact of placental anastomoses on UA Doppler. Arterio-arterial anastomoses were found on pathologic analysis of 100% of monochorionic diamniotic twin placentas with intermittent absent or reversed end-diastolic flow in the UA, compared to only 3.6% of those with normal umbilical artery Doppler findings. In a study of UA Doppler in 96 pairs of uncomplicated monochorionic diamniotic twins, isolated Doppler abnormalities were encountered in 22.9% before 28 weeks. The Doppler abnormalities did not predict twin-specific complications but were associated with increased sonographic surveillance and antenatal hospitalizations. Variable flow patterns result from variable directions of artery to artery shunt flow between the twins; this illustrates the importance

Impact of Chorionicity

	Dichorionic	Monochorionic
Risk of aneuploidy (age related)	Monozygotic = singleton rate Dizygotic = 2x singleton fetus	Monochorionic = singleton risk
	Dizygotic = (singleton) ² for both fetuses	
Risk of anomalies	Risk per fetus in dizygotic approximates that of singleton Monozygotic 2-3 X dizygotic	3-5x dichorionic
	1:25 risk major anomaly	1:15 diamniotic 1:6 monoamniotic
Risk of 2nd-/3rd-trimester demise		3-4x dichorionic
Perinatal morbidity and mortality		3-5x dichorionic
Probability of 2 live births	95.8% if normal ultrasound at 12 weeks	74.4% if normal ultrasound at 12 weeks
Probability of 2 live infants at 28 days after delivery	97.5% if 2 live fetuses at 24 weeks	95.1% if 2 live fetuses at 24 weeks

Twin pregnancies have higher risk of perinatal morbidity and mortality than singletons. Preterm birth at < 37 weeks gestation occurs in up to 60% of twins. In the STORK study of 3117 twin pairs from 2000-2010, the total risk of early pregnancy loss before 24 weeks was significantly higher in MC than DC twins with a loss rate of at least 1 fetus in 6.03% of MC twins vs. 0.66% in DC twins.

Sonographic Monitoring of Uncomplicated Twin Pregnancy

	Dichorionic	Monochorionic
1st trimester	Dating, position, chorionicity, aneuploidy risk assessment, major anomaly search	Dating, position, chorionicity, aneuploidy risk assessment, major anomaly search
2nd /3rd trimester	Detailed anatomy, cervical length at ~ 20 weeks Monthly growth from time of anatomy scan	Detailed anatomy, cervical length at ~ 20 weeks Monthly growth from time of anatomy scan Amniotic fluid volume assessment every 2 weeks from 16 weeks
Doppler Studies	Not routine	Umbilical artery and middle cerebral artery Doppler monthly from 20 weeks

Recommendations are based on the ISUOG Practice Guidelines published in 2016. These are not mandatory; each individual practice may chose what studies to perform for their patient population. There is data to suggest that routine Doppler studies in uncomplicated monochorionic twins may result in increased surveillance and intervention without improved outcome.

ISUOG Practice Guidelines: role of ultrasound in twin pregnancy. *Ultrasound Obstet Gynecol.* 47(2):247-63, 2016.

of analyzing the whole clinical picture in any complicated pregnancy.

Preterm Birth

The median gestational age for twins is 36 weeks 5 days compared to 39 weeks for singletons. Approximately 50% of twins weigh < 2.5 kg at birth, and twins are almost 10x more likely than singletons to have very low birth weight (< 1.5 kg).

There is no clear consensus on the best method of screening for preterm birth or what treatment to institute in patients that present as high risk. Fetal fibronectin and cervical length are popular tests; both have strong negative predictive value. Cervical length > 35 mm prior to 26 weeks has a strong negative predictive value for preterm birth prior to 35 weeks.

Although preterm birth is a major factor in poor outcome, when medically indicated, it actually decreases perinatal mortality.

Maternal Complications

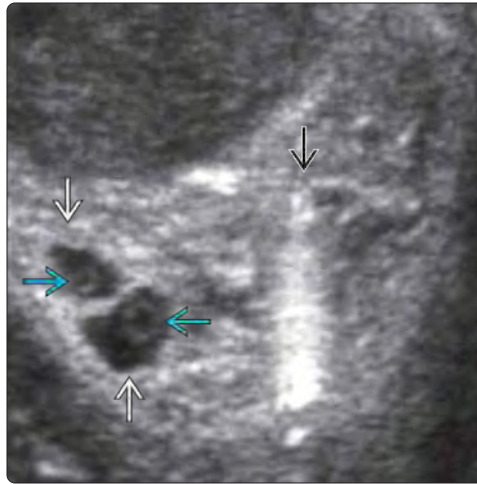
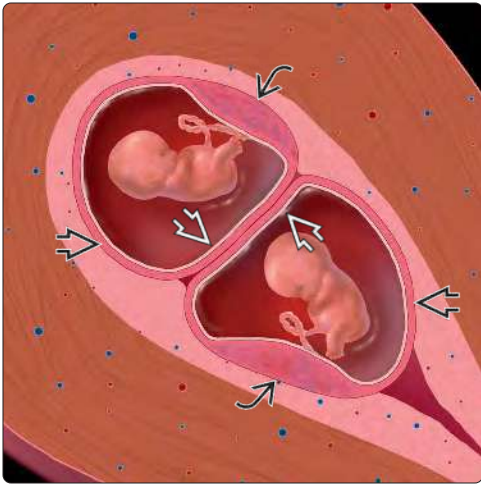
There is a 2x increase in the risk for preeclampsia, postpartum hemorrhage, and death and a 3x increased risk of eclampsia compared to singleton pregnancies.

Conclusion

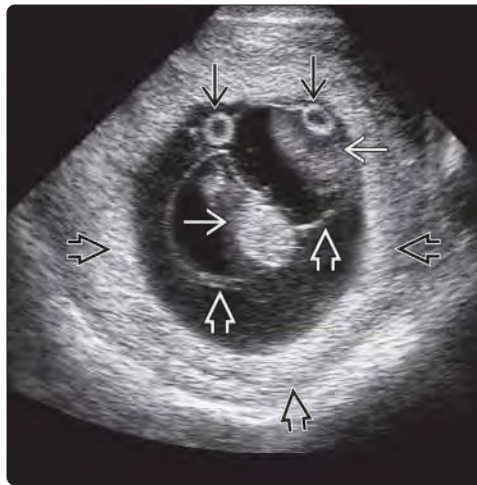
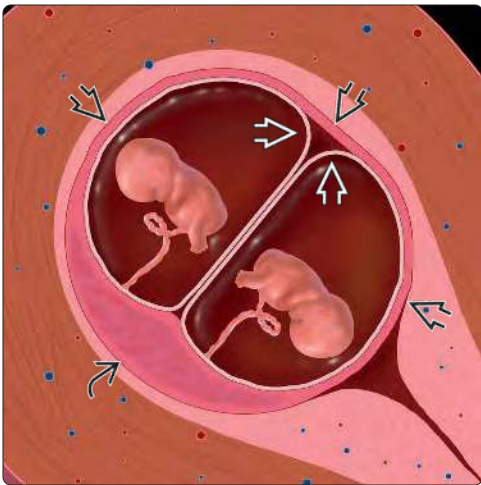
US is an integral part of the management of multiple pregnancies. Careful surveillance of these pregnancies allows tailored management to produce the best possible outcome in each individual case.

Selected References

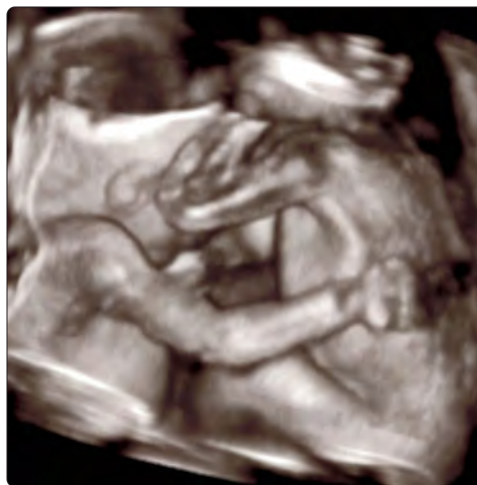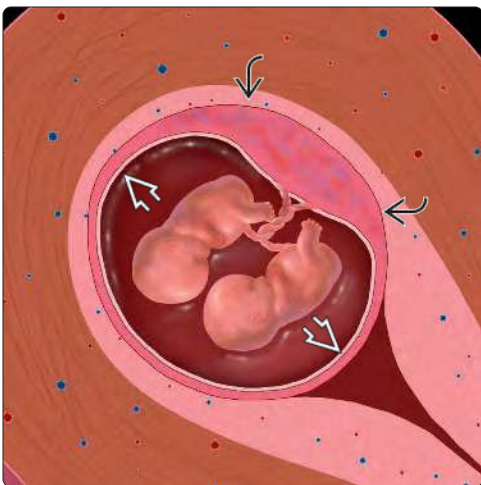
1. ISUOG Practice Guidelines: role of ultrasound in twin pregnancy. *Ultrasound Obstet Gynecol.* 47(2):247-63, 2016
2. American College of Obstetricians and Gynecologists et al: ACOG Practice Bulletin No. 144: Multifetal gestations: twin, triplet, and higher-order multifetal pregnancies. *Obstet Gynecol.* 123(5):1118-32, 2014



(Left) Graphic illustrates dichorionic twins. Two embryos are seen, each within its own amnion (thin white line) and chorion (thick pink line). Two layers of chorion and amnion make a thick intertwin membrane. There is a thickening of the chorion where the placentas are developing. (Right) This patient was concerned that she could no longer feel her IUD strings. 3D US shows the IUD tilted to the left of the uterine cavity and dichorionic twins implanted to the right. There are 2 thick chorionic rings and 2 yolk sacs.

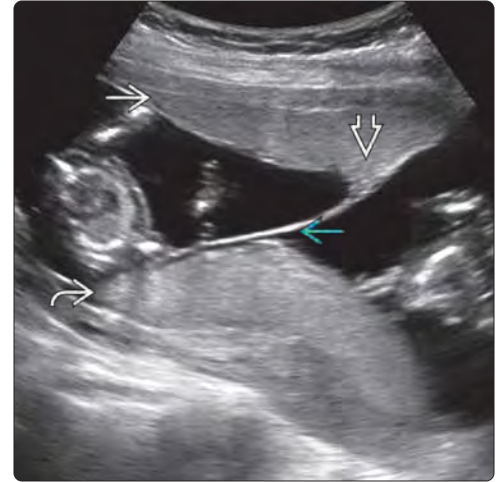
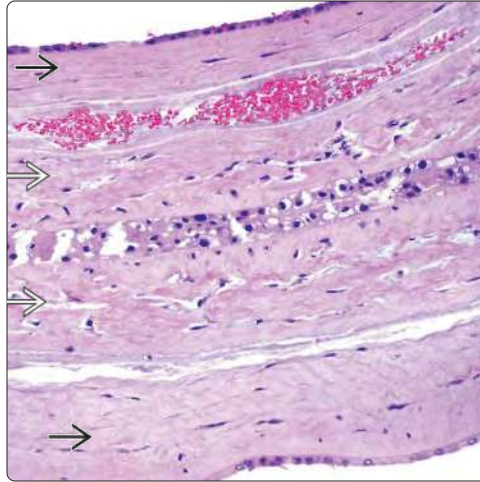


(Left) Graphic illustrates a monochorionic pregnancy. Note the differences between monochorionic and dichorionic pregnancies. Here, each embryo is within a separate amniotic sac surrounded by a single chorionic sac with a single placenta. The intertwin membrane is thin as it is composed of only 2 layers of amnion. (Right) TVUS shows the thin intertwin membrane composed of 2 layers of amnion without interposed chorionic tissue. Two embryos and yolk sacs are also seen.

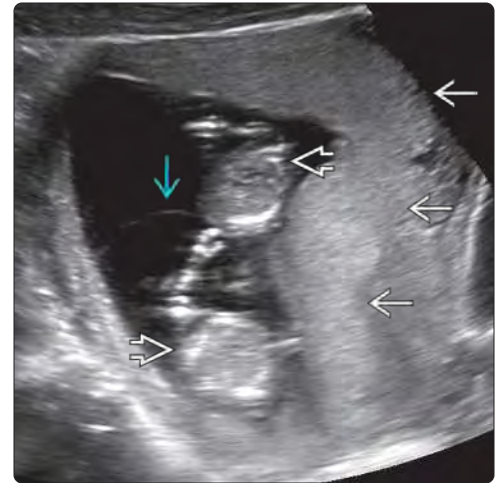
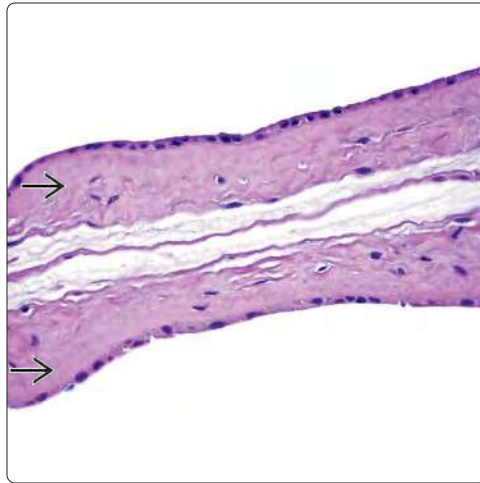


(Left) Graphic illustrates cord entanglement between monoamniotic twins. The cords are closely inserted on a single placenta, and both embryos are within a single amniotic sac. (Right) 3D surface-rendered image of twins shows them with their arms around each other. This is only possible when both fetuses are in the same sac, i.e., monoamniotic.

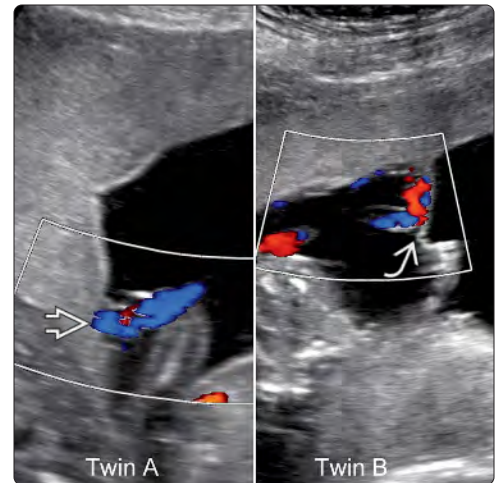
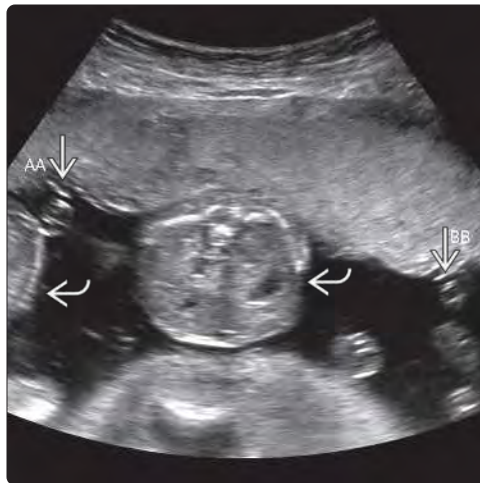
(Left) Photomicrograph of a thick membrane from dichorionic twins shows 2 layers of chorion between the 2 layers of amnion with trophoblastic cells or villi between them. **(Right)** Transabdominal US shows separate anterior and posterior placentas with a twin peak sign and a thick intertwin membrane in these dichorionic twins.

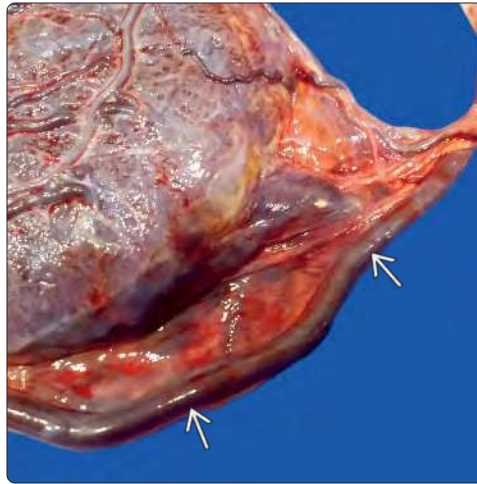
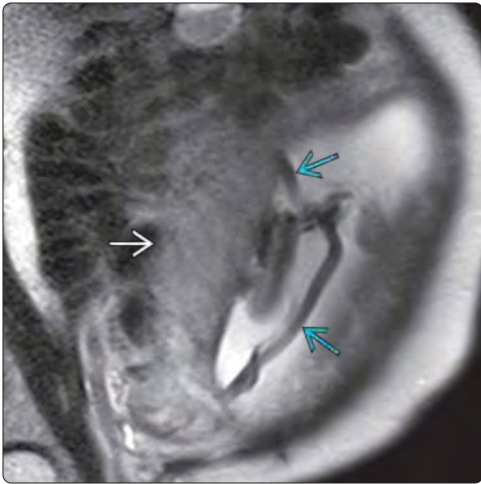





(Left) Photomicrograph of a thin membrane from MDT twins shows that it is composed of just 2 layers of amnion. The amnion has only of a single layer of epithelial cells, a basement membrane, and a collagen layer. **(Right)** Transabdominal US shows a single anterior placenta with 2 fetuses separated by a barely perceptible, thin intertwin membrane. These are monochorionic diamniotic twins.

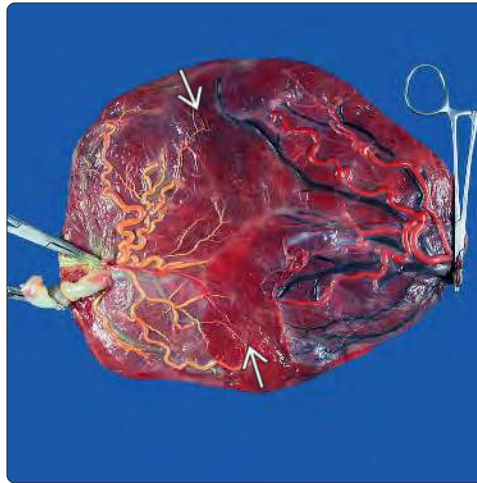
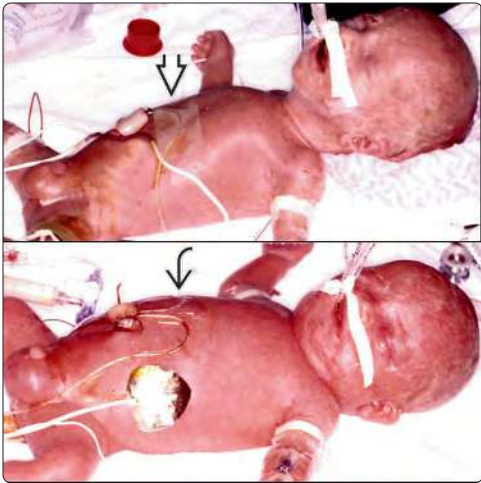




(Left) Assessment of cord insertion sites is particularly important in multiple pregnancy. Transabdominal US shows normal placental cord insertion sites for these monochorionic diamniotic twins. Both cords insert into the placenta and are widely separated on the placental disc. **(Right)** In contrast, in this case, twin A's cord shows a marginal insertion into the edge of the placenta, and twin B's cord has a velamentous insertion into the intertwin membrane.

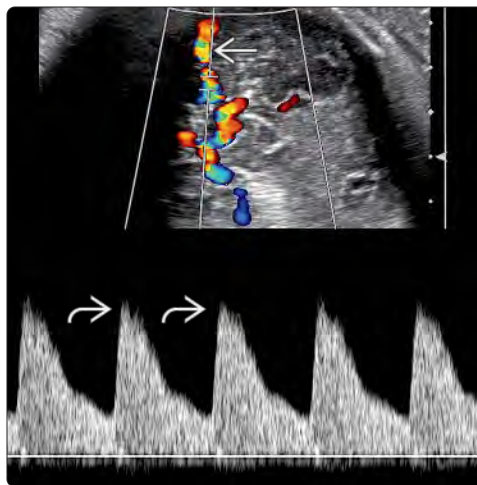
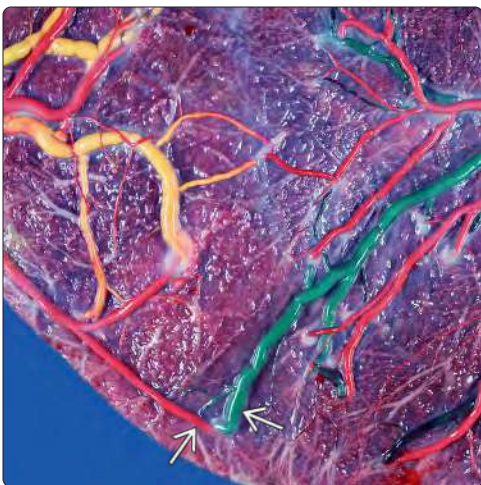







(Left) MR was performed for evaluation of a chest mass. The finding of velamentous cord insertion was unexpected. Note the long course of unprotected vessels  running in the membranes prior to reaching the placenta . (Right) Gross pathology shows the long membranous course of the umbilical vein  in this case of velamentous cord insertion. In twins, velamentous cord insertion increases the risk for discordant growth, and it is a proxy marker for unequal placental sharing in monochorionic placentas.



(Left) Composite image shows very preterm infants from a monochorionic twin pregnancy complicated by twin-twin transfusion syndrome. The donor  is oligemic and growth restricted, and the recipient  is plethoric and volume overloaded. (Right) This placenta is from a case of twin-twin transfusion treated with the "dichorionizing" Solomon laser technique, which involves coagulation of entire vascular equator . Laser coagulation of placental vessels is now the treatment of choice for severe TTTS. (From DP: Placenta.)



(Left) Image of a placenta from a TTTS case treated with selective laser shows a residual small artery (red) to vein (green) anastomosis ; these are usually at the placental margin. Chronic slow shunting results in the twin anemia polycythemia sequence (TAPS). (From DP: Placenta.) (Right) Pulsed Doppler US of the middle cerebral artery  shows elevated peak systolic velocity  consistent with anemia. Middle cerebral artery Doppler can be performed after laser treatment for TTTS to detect TAPS. Treatment is supportive.

Dichorionic Diamniotic Twins

KEY FACTS

IMAGING

- 1st trimester
 - Thick echogenic chorion completely surrounds each embryo
- 2nd/3rd trimester
 - 2 placentas
 - Thick intertwin membrane
 - Twin peak sign: Wedge of chorionic tissue extending into base of intertwin membrane
 - Different gender is most specific sign of dizygotic (DZ) twins

TOP DIFFERENTIAL DIAGNOSES

- Monochorionic (MC) diamniotic twins
 - Thin intertwin membrane
- MC monoamniotic twins
 - No intertwin membrane

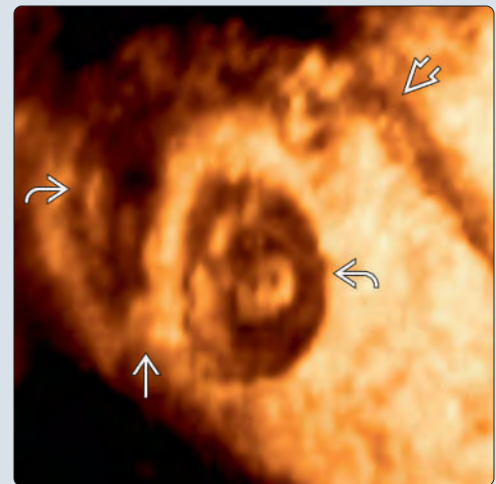
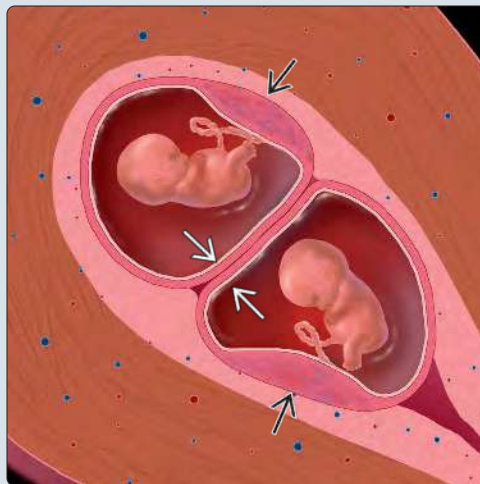
CLINICAL ISSUES

- 70% of twins are dizygotic (DZ), 30% are monozygotic (MZ)
 - Of MZ, 30% are dichorionic (DC)
- Twins account for 1.1% of pregnancies in USA, but 10% perinatal morbidity and mortality
 - 95.8% probability of delivering 2 live infants if normal US at 12 weeks in DC twins
 - Plan delivery at 38 weeks for uncomplicated DC twins
- Maternal complications > singleton pregnancy
 - Hypertension, preeclampsia, antepartum and postpartum hemorrhage
- Cell-free DNA screening is not recommended for women with multiple gestations
- Cervical cerclage potentially harmful in multiple gestation

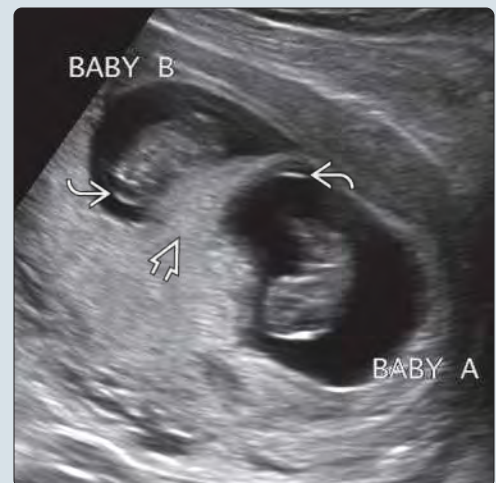
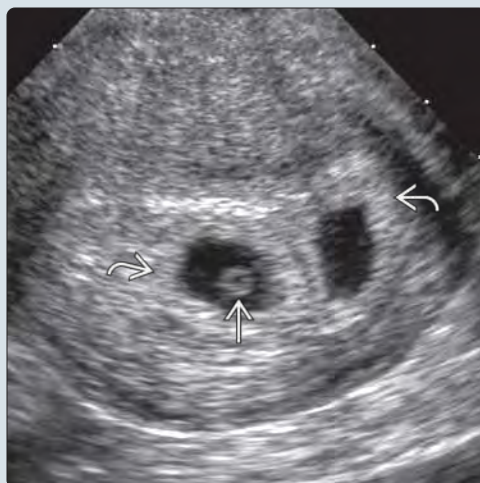
DIAGNOSTIC CHECKLIST

- Transvaginal US in 1st trimester is best modality for determination of chorionicity and amnionicity
- Twin prognosis determined by chorionicity not zygosity

(Left) Graphic of dichorionic (DC) twins shows a thick intertwin membrane composed of 2 thin layers of amnion (white lines) and 2 thick layers of chorion (pink lines). The placentas are separate. **(Right)** 3D ultrasound shows a DC twin pregnancy with a thick intertwin membrane. The linear structure to the right of the image is an intrauterine contraceptive device that, even though well positioned, failed to prevent pregnancy in this case.



(Left) Transabdominal ultrasound shows 2 distinct gestational sacs. These are, in fact, the separate chorionic rings in a DC twin pregnancy. The yolk sac is visible in the right-sided sac. **(Right)** Transabdominal ultrasound at a later gestational age shows 2 embryos with the delicate amniotic membranes barely visible inside the echogenic chorionic sacs. The broad-based triangle of chorion where the sacs abut each other creates the twin peak sign.



TERMINOLOGY

Abbreviations

- Dichorionic (DC) diamniotic twins

Definitions

- 2 fetuses in separate chorionic sacs

IMAGING

General Features

- Best diagnostic clue
 - Thick echogenic chorion completely surrounds each embryo in 1st trimester
 - 2nd trimester: Twin peak sign
 - Wedge of chorionic tissue extending into base of intertwin membrane

Ultrasonographic Findings

- **1st trimester**
 - Thick echogenic chorion completely surrounds each sac
- **2nd trimester**
 - Fetal genders
 - Different genders → dizygotic (DZ) → DC
 - 2 placentas (may be difficult to prove)
 - Adjacent implantation sites
 - Succenturiate lobe in monochorionic (MC) placenta may be source of confusion
 - Thick intertwin membrane
 - No finite measurement
 - All membranes look thin in 3rd trimester
 - Count layers with high-resolution transducer; if > 2, must be DC
 - Twin peak or lambda sign
 - Chorion forms echogenic triangle
 - Triangle base on placental surface, apex fades into intertwin membrane

Imaging Recommendations

- 1st-trimester scan to confirm gestational age (GA), chorionicity, measure nuchal translucency (NT)
- Genetic sonogram assumes greater importance in multiples as serum screening is less effective
 - Serum screening gives pregnancy specific risk in multiples, not fetus specific as in singletons
- Look for anomalies
 - 2-3x more common in twins than singletons
 - Anomalies in monozygotic (MZ) twins 50% > dizygotic (DZ) twins
- Monitor growth
- Monitor amniotic fluid volume
 - Use single deepest pocket
 - Sagittal scan plane, transducer perpendicular to floor, not maternal abdomen
- Assess placental implantation sites
 - Increased risk of placenta/vasa previa
- Assess placental cord insertion sites
 - Marginal/velamentous cord → increased risk for growth restriction
- Consider cervical length measurement

DIFFERENTIAL DIAGNOSIS

Monochorionic Diamniotic Twins

- Must be same gender
- Single placental mass
- Thin intertwin membrane

Monochorionic Monoamniotic Twins

- Must be same gender
- No intertwin membrane
- Cord entanglement common

PATHOLOGY

General Features

- Embryology
 - Zygote divides within 3 days of conception → complete duplication of cell lines
- DZ twinning increased with maternal family history of twins

CLINICAL ISSUES

Presentation

- Most common signs/symptoms
 - Size > dates
 - Hyperemesis gravidarum
- Other signs/symptoms
 - Hyperreactio luteinalis may occur
 - Syndrome akin to hyperstimulation syndrome occurring in response to normal pregnancy
 - Almost always benign and self-limited

Demographics

- Epidemiology
 - Early US suggests that as many as 12% of spontaneous conceptions are twins
 - Only about 50% of twins identified in early 1st trimester → 2 live births
 - 70% are DZ, 30% are MZ
 - Of MZ twins
 - ◻ 30% DC diamniotic twins
 - ◻ 60-65% MC diamniotic twins
 - ◻ 5-10% MC monoamniotic twins
 - ◻ < 1% conjoined
 - DZ twins
 - 7-11 per 1,000 births in USA (geographic incidence varies)
 - African American > Caucasian > Asian
 - MZ twins
 - 4 per 1,000 births in USA, independent of race/age/parity
 - Assisted reproduction
 - MZ twinning with assisted reproduction 3.8x general population rate
 - However, most multiples with assisted reproduction are DZ
 - Twins account for 1.1% of pregnancies in USA, but 10% perinatal morbidity and mortality
 - MC > DC twins

Natural History & Prognosis

- Early (10-14 week) demise of 1 fetus described in 6% DC twins
- Probability of delivering 2 live infants if normal US at 6 weeks
 - MC 39%, DC 75.8%
- Probability of delivering 2 live infants if normal US at 12 weeks
 - MC 74.4%, DC 95.8%
- Age-related risk of aneuploidy in MZ twins equal to singleton rate
- Age-related risk of aneuploidy in DZ twins higher than singleton rate
 - Risk of 1 fetus being affected: 2x singleton risk
 - Risk of both fetuses being affected: (Singleton risk)²
 - Maternal serum screening less reliable in multiples
- DC twin loss rate within 4 weeks of amniocentesis > that for singletons
 - 2.7% DC twins with amniocentesis
 - 0.6% control singletons with amniocentesis
- Maternal complications > singleton pregnancy
- Perinatal mortality reported in 10% with preterm delivery as commonest cause
 - Median GA at delivery 36 weeks
 - Fetal growth restriction
- Twin demise
 - DC twins 3-4x less likely to have twin demise than MC pregnancies
 - Biggest risk to survivor, regardless of chorionicity, is preterm delivery
 - 50-80% of surviving co-twins delivered preterm
 - 86% due to preterm labor
 - Risks are negligible other than those of prematurity (separate vascular systems prevent ischemic injury)
 - No proven increase in infection
 - ↑ likelihood of C-section for nonreassuring fetal status
- Premature rupture of membranes in 7.4% of twins (3.7% of singletons)
 - Presenting > trailing

Treatment

- Concept of specialized clinic for twins has gained popularity globally
 - Decrease cesarean rates, incidence of late prematurity, maternal inpatient stay without increase in maternal/neonatal complications
 - Standard protocols with aggressive monitoring
 - Weekly office visits and antenatal testing > 34 weeks for DC twins
 - Comprehensive US every 3-4 weeks
 - Planned delivery at 38 weeks for DC twins
- Cervical measurements controversial
 - Short cervix is predictor of preterm birth, but cervical cerclage is potentially harmful in multiple gestation
 - Cervical length > 35 mm at 23 weeks identifies group at low risk for preterm delivery
- For aneuploidy screening each fetus of DC twins is treated like separate individual
 - Risk for each calculated with published singleton NT values

- Trisomy 21 NT detection rate in 448 twins pregnancies was 88% with 7.3% false-positive rate
- Comparing 1st-trimester NT with 2nd-trimester maternal serum screen
 - High false-positive rate in serum screening → 18.3% amniocentesis rate in twin group (7.5% rate in singletons)
- Cell-free DNA screening is not recommended for women with multiple gestations
- Chorionic villus sampling preferred to amniocentesis for aneuploidy diagnosis
 - Results available earlier
 - Selective termination (ST) is safer earlier in pregnancy
 - Loss rate following amniocentesis is higher in twins than singletons
 - Careful technique vital to prevent contamination or erroneous sampling
- Look for anomalies: Incidence increased in multiple gestations
 - Options include termination of pregnancy, ST of anomalous fetus, or expectant management
- ST in DC (or higher order chorionicity) best by intracardiac injection of potassium chloride
 - Best performed early (< 18 weeks) to decrease pregnancy loss, preterm delivery rates
 - Overall rate of pregnancy loss before 24 weeks ~ 7.5%
 - ST in MC pregnancies requires cord ligation/coagulation due to placental vascular anastomoses
- DC fetal demise
 - Consider steroids for fetal lung maturity
 - Surveillance for preterm labor, fetal well-being, growth
 - Expectant management until 38 weeks
- Chorionicity has no significant impact on maternal outcomes

DIAGNOSTIC CHECKLIST

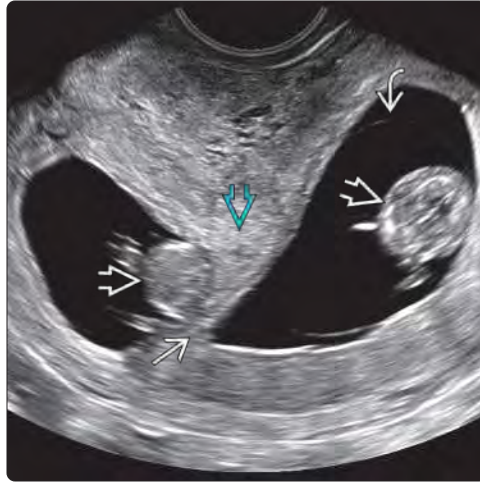
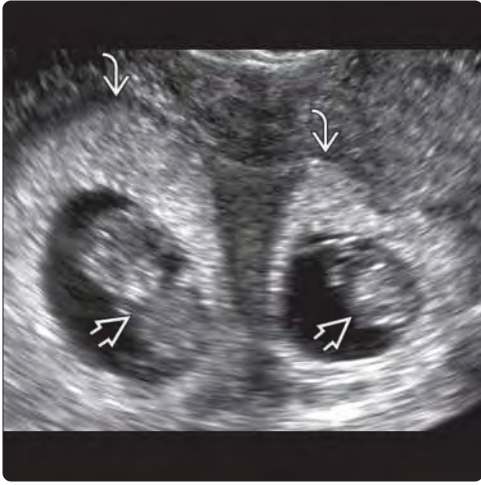
Image Interpretation Pearls

- TVUS in 1st trimester is best modality for determination of chorionicity and amnionity
- Twin prognosis relates to chorionicity not zygosity

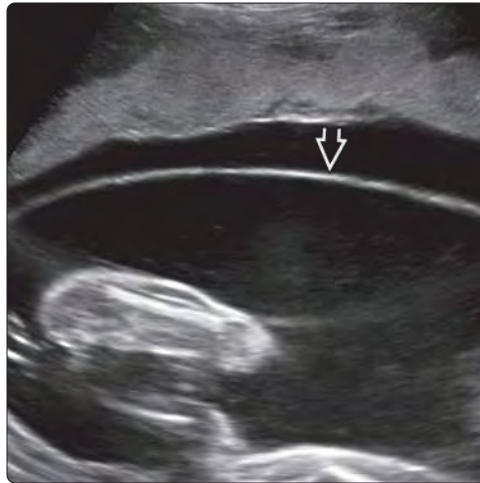
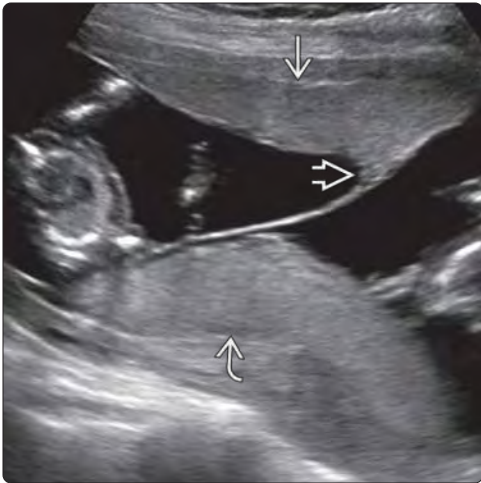
SELECTED REFERENCES

1. Committee Opinion No. 640: Cell-free DNA screening for fetal aneuploidy. *Obstet Gynecol.* 126(3):e31-7, 2015
2. Carter EB et al: The impact of chorionicity on maternal pregnancy outcomes. *Am J Obstet Gynecol.* 213(3):390.e1-7, 2015
3. Henry A et al: Pregnancy outcomes before and after institution of a specialised twins clinic: a retrospective cohort study. *BMC Pregnancy Childbirth.* 15:217, 2015
4. Rosner JY et al: Abnormal biochemical analytes used for aneuploidy screening and adverse pregnancy outcomes in twin gestations. *Am J Perinatol.* 32(14):1331-5, 2015
5. van de Mheen L et al: Pregnancy outcome after fetal reduction in women with a dichorionic twin pregnancy. *Hum Reprod.* 30(8):1807-12, 2015
6. Blumenfeld YJ et al: Accuracy of sonographic chorionicity classification in twin gestations. *J Ultrasound Med.* 33(12):2187-92, 2014
7. Egic AS et al: Degree and rate of growth discordance in dichorionic twins conceived by in vitro fertilization. *Obstet Gynecol Int.* 2014:543728, 2014
8. Ratha C et al: An analysis of pregnancy outcome in dichorionic and monochorionic twins given special antenatal and intranatal care: a four-year survey. *J Obstet Gynaecol India.* 64(4):255-9, 2014
9. National Collaborating Centre for Women's and Children's Health (UK): 2011

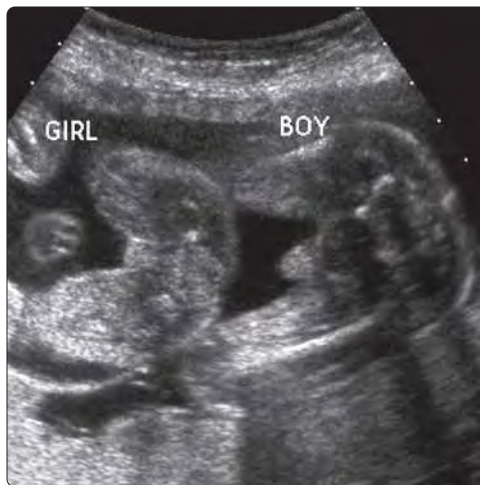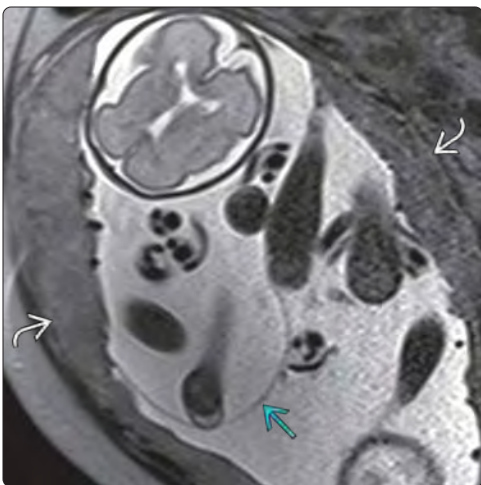
Dichorionic Diamniotic Twins



(Left) Transvaginal ultrasound shows 2 embryos, each one is fully surrounded by its own thick, echogenic chorion. (Right) Transvaginal ultrasound shows 2 fetuses with a thick intertwin membrane at the apex of a twin peak. Note how thin the amnion is in comparison to the chorion (which forms the twin peak) and thick membrane.



(Left) Transabdominal ultrasound shows separate anterior and posterior placentas. The fetuses are separated by a thick membrane, which abuts the anterior placenta in the λ configuration of the twin peak. (Right) Transabdominal ultrasound shows a thick membrane in the 2nd trimester. This is composed of sequential layers of amnion, chorion, chorion, and amnion. The thin membrane in monochorionic diamniotic twinning is composed of only the 2 amnions.



(Left) T2WI shows a quite thin membrane in this known DC pregnancy, but there are clearly 2 placentas. It can be very hard to judge membrane thickness in the 3rd trimester. If chorionicity is unknown late in pregnancy, evaluation of fetal gender and number of placentas becomes more important. The 1st trimester is the best time to establish chorionicity. (Right) Transabdominal ultrasound shows different genders. These twins are therefore dizygotic and, by definition, DC.

Monochorionic Diamniotic Twins

KEY FACTS

IMAGING

- 1st trimester
 - 2 yolk sacs (YS)
 - YS are surrogate for amnions (easier to see)
 - Must confirm diamnionicity with visualization of membrane; get short-term follow-up
- 2nd trimester
 - Single placental mass
 - Twins must be same gender
 - Thin intertwin membrane
 - No "twin peak" (lambda sign)
- Protocol
 - Attempt to identify placental cord insertion sites
 - Look for anomalies
 - Monitor growth
 - Check amniotic fluid volume
- Look for specific complications of monochorionic twinning
 - Unequal placental sharing

- Twin-twin transfusion sequence
- Twin reversed arterial perfusion sequence
- Perform formal fetal echocardiography
 - Relative risk 9.2x for congenital heart disease

TOP DIFFERENTIAL DIAGNOSES

- Dichorionic diamniotic twins
- Monochorionic monoamniotic twins

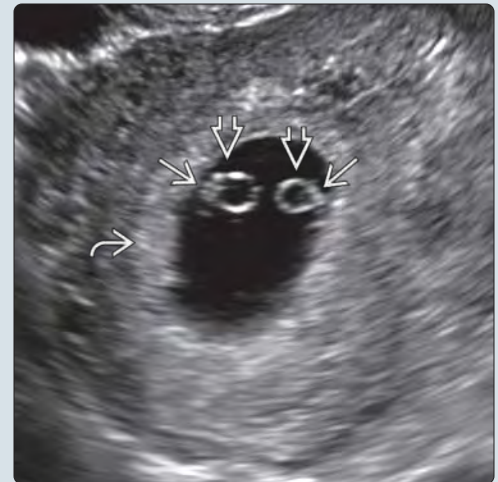
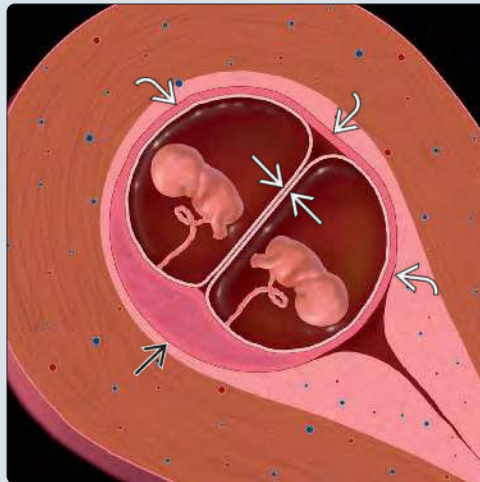
CLINICAL ISSUES

- Perinatal morbidity and mortality of monochorionic twins 3-5x that of dichorionic twins

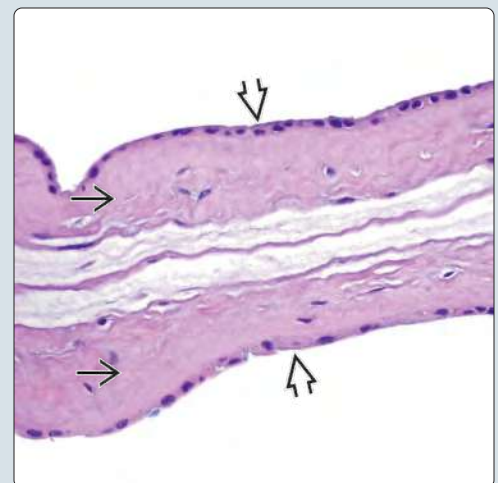
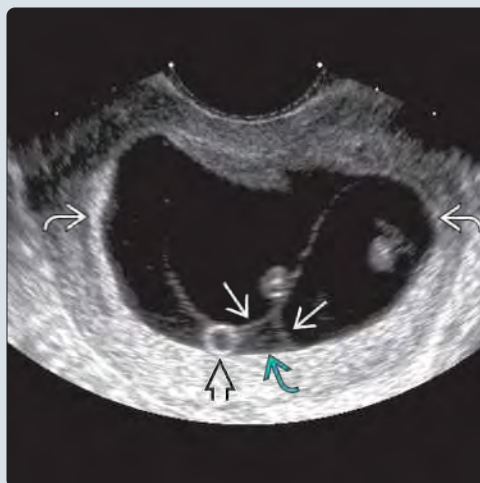
DIAGNOSTIC CHECKLIST

- Prognosis in twins depends on chorionicity not zygosity
- Best assessment of chorionicity is based on combining all available sonographic features rather than using any one sign alone

(Left) Graphic of monochorionic diamniotic twins (MDT) shows a thin membrane formed by the apposition of the 2 thin layers of amnion. There is a single placenta and a single chorionic sac. **(Right)** Vaginal US in an early MDT pregnancy shows a single chorionic sac, 2 yolk sacs, and 2 tiny embryos. The amniotic membranes, though formed, are not yet visible. They will expand as the embryos grow.



(Left) Vaginal US in a later MDT pregnancy shows a single chorionic sac. One of the 2 yolk sacs was visible in this plane, which nicely demonstrates delicate amniotic sacs surrounded by the echogenic fluid of the extraembryonic coelomic space. **(Right)** Photomicrograph of a "thin" membrane from MDT twins shows that it is composed of just 2 layers of amnion. The amnion has only of a single layer of epithelial cells with a basement membrane and a collagen layer.



TERMINOLOGY

Abbreviations

- Monochorionic diamniotic twins (MDT)

Definitions

- Zygosity refers to type of conception
 - Monozygotic (MZ) or identical twins result from mitotic division of zygote originating from fertilization of 1 ovum by 1 sperm
 - Dizygotic (DZ) or nonidentical twins are result of multiple ovulations, with 2 sperm fertilizing 2 ova
- Chorionicity refers to type of placentation
 - MZ pregnancies may be monochorionic (MC) or dichorionic (DC) depending on when zygote divides
 - DZ twins always have DC placentation

IMAGING

General Features

- Best diagnostic clue
 - 1st trimester
 - 2 embryos, each within separate amniotic sac, inside single chorionic sac
 - 2nd trimester
 - Thin intertwin membrane without twin peak

Ultrasonographic Findings

- Grayscale ultrasound
 - **1st trimester**
 - 2 yolk sacs (YS) in single chorionic sac
 - YS are surrogate for amnions; easier to see in very early scans
 - **Must confirm diamnionicity with visualization of membrane**
 - **2nd trimester**
 - Single placental mass
 - Twins must be same gender
 - Thin intertwin membrane
 - No "twin peak" (lambda sign)
 - T sign: Membranes approach placenta at ~ 90° angle, no wedge of chorionic tissue at base
 - Sensitivity 100%, specificity 98.2% for MDT
 - Thin intertwin membrane is subjective
 - Mean MC membrane: 1.4 mm, mean DC membrane: 2.4 mm (cutoff level 1.5-2 mm)
 - All membranes look thin in 3rd trimester
 - Sensitivity for dichorionicity falls to 52% in 3rd trimester
- Color Doppler
 - Use during endovaginal (EV) sonography of cervix for possible associated vasa previa
 - Spectral Doppler useful for evaluation of specific MC complications
 - Unequal placental sharing or selective fetal growth restriction (sFGR)
 - Twin-twin transfusion syndrome (TTTS)
 - Twin anemia polycythemia sequence (TAPS)
 - **Routine use of Doppler is not recommended in uncomplicated MDT**

- Variable waveforms reflect changing intertwin shunts through placental anastomoses
- Do not herald bad outcome in otherwise normal pregnancy

Imaging Recommendations

- Best imaging tool
 - EV scan in 1st trimester
- Evaluate nuchal translucency (NT) in 1st trimester
 - If abnormal
 - Increased risk of aneuploidy
 - Increased incidence of TTTS
 - Further increased if ductus venosus flow also abnormal
 - Discordant NT of at least 20% used to screen for risk of early loss, TTTS
- Look for anomalies
 - MC twin anomaly rate 3-5x that of singletons or DC twins
 - Use MR to clarify anomalies
 - Intervention contraindicated if both fetuses abnormal
- Perform formal fetal echocardiography
 - Prevalence of congenital heart disease (CHD) increased over general population risk
 - Those complicated by TTTS have higher incidence of pulmonary stenosis in recipient ± coarctation in donor
- Attempt to identify placental cord insertion sites
 - Increased marginal/velamentous cord insertion
 - Associated with unequal placental sharing, discordant growth
 - Velamentous cord → 13x risk of discordant birth weights
- Exclude vasa previa
- Monitor growth
 - Discordant growth
 - Most frequently defined as > 20% difference in estimated fetal weight
- Check for symmetric amniotic fluid volume
 - **Asymmetric fluid distribution important sign of TTTS**
 - If discordant growth, smaller twin may have oligohydramnios
 - Isolated polyhydramnios/oligohydramnios concerning for anomaly of affected twin
- Look for specific complications of MC twinning
 - Unequal placental sharing
 - TTTS
 - Twin reversed arterial perfusion (TRAP)
- Use MR to evaluate survivor's brain after co-twin demise
 - 26% risk of neurological damage

DIFFERENTIAL DIAGNOSIS

Dichorionic Diamniotic Twins

- Fused placentas may appear as one
- Twin peak sign usually present
- Intertwin membrane thicker
- Fetal gender may differ in DZ twins

Monochorionic Monoamniotic Twins

- No intertwin membrane
- Cord entanglement common

PATHOLOGY

General Features

- Genetics
 - Risk of aneuploidy in MDT = singleton risk
 - Each fetus has same risk of being affected with Down syndrome
 - NT measurements are averaged to calculate single risk estimate for entire pregnancy
- Embryology
 - MDT occur when inner cell mass of blastocyst splits between 4th and 8th day post conception
- MC placentation → vascular connections between fetuses: Risk of
 - TTTS
 - TRAP
 - So-called "twin embolization" syndrome, which is consequence of single twin demise
 - Vascular anastomoses exist between twins due to MC placentation
 - Demise of one twin → sudden loss of placental bed vascular resistance
 - Live twin becomes acutely hypotensive
 - End result is "hypoperfusion" with ischemic lesions of brain and kidneys
- Up to 23% of MDT will have abnormal Doppler findings in absence of other abnormalities
 - Reflect variable flow in large arterio-arterial anastomoses
 - In one series, > 50% of otherwise uncomplicated MDT twins with absent end diastolic flow remained stable over 6 weeks, ~ 30% stable over 12 weeks
 - No progressive disease
 - No TTTS, no fetal growth restriction

CLINICAL ISSUES

Demographics

- Epidemiology
 - MZ twins = 4:1,000 births in USA
 - 60% of MZ twins are MC

Natural History & Prognosis

- MC morbidity and mortality 3-5x that of DC
 - 12% TTTS (may be combined with sFGR)
 - 15% sFGR (unequal placental sharing)
 - 5% spontaneous TAPS in 3rd trimester
- Early demise (10-14 weeks) of one twin described in 3% MC twins
- 2nd-/3rd-trimester single twin demise less common
 - ~ 15% of co-twins also die
 - ~ 26% of survivors suffer neurologic injury (e.g., encephalomalacia)
- MDT at ↑ risk for CHD
 - Abnormal placentation may contribute to abnormal heart development (e.g., TTTS)
 - Relative risk 9.2x for CHD in MDT twins
 - In those with TTTS, relative risk for CHD is further increased by 2.78x
- Preterm premature rupture of membranes (PPROM) more common in twins

- 7.4% compared with 3.7% of singletons
- Intertwin membrane rupture is unique to MC twins
 - Results in functional MA twins
 - Complicated by preterm delivery: Average gestational age at delivery of 29 weeks in one series
 - Overall perinatal mortality of 44% in same group

Treatment

- 1st-trimester scans to determine size, chorionicity, measure NT, exclude TRAP
- Serial scans for growth and fluid
- Careful evaluation for anomalies, specific complications
- In event of twin demise
 - Counsel parents regarding risk of encephalomalacia/other ischemic tissue injury
 - If demise occurs, previability termination can be offered
 - Demise after viability is not indication for emergent delivery
- Emergency delivery may be indicated with impending demise of one twin
- PPROM managed as for singletons once viable
- PPROM in previable multiples
 - Termination of entire pregnancy may be best approach
 - Some limited success with selective reduction of fetus in ruptured sac
- Women with uncomplicated MDT can undergo delivery between 34 weeks and 0 days, and 37 weeks and 6 days
 - Vaginal delivery "is reasonable option" if presenting fetus is vertex per American College of Obstetrics and Gynecology guidelines

DIAGNOSTIC CHECKLIST

Consider

- Determine chorionicity and amnionicity in every case
- Prognosis in twins depends on chorionicity not zygosity

Image Interpretation Pearls

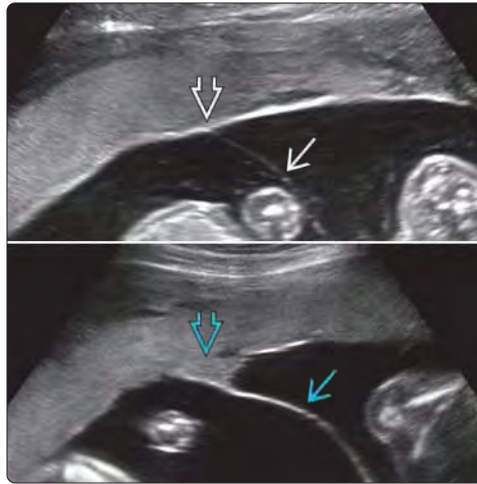
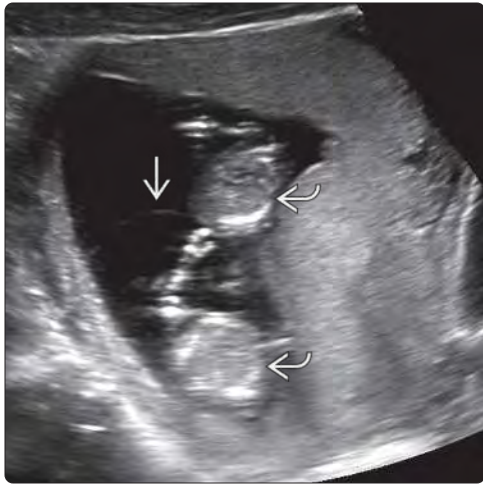
- In early 1st trimester, count YS per chorionic sac as surrogate for amnions
 - Verify diamniotic with vaginal US later in 1st trimester
- Thin intertwin membrane best sign after 1st trimester
- If genders different, twins cannot be MC
- Amniotic fluid discordance most important single predictor of poor outcome
 - Maximum vertical pocket difference > 4 cm associated with significant increased risk of TTTS

Reporting Tips

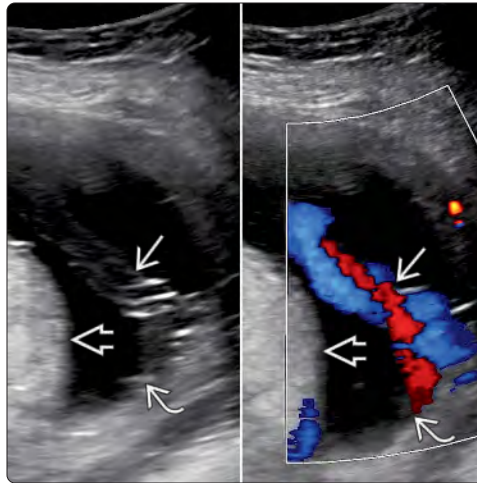
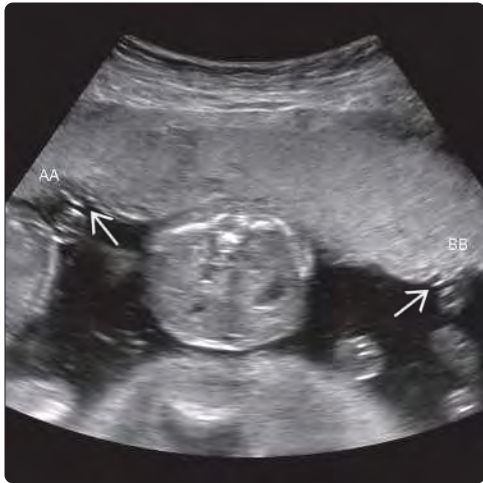- Best assessment of chorionicity is based on combining all available sonographic features rather than using any one sign alone

SELECTED REFERENCES

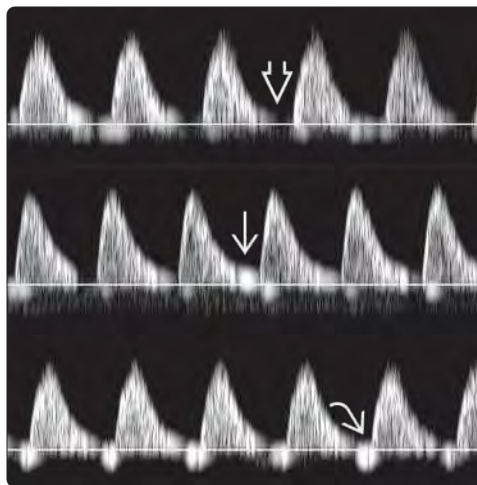
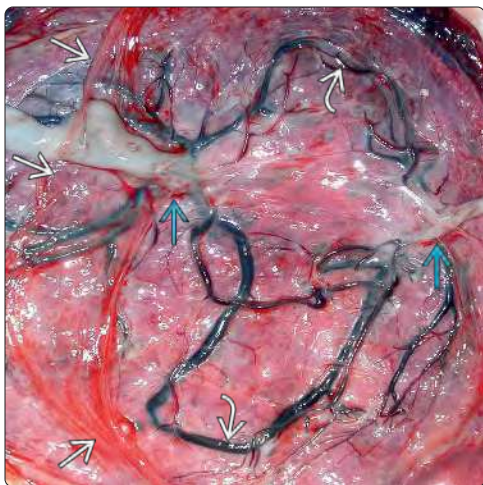
1. ISUOG practice guidelines: role of ultrasound in twin pregnancy. *Ultrasound Obstet Gynecol.* 47(2):247-63, 2016
2. Allaf MB et al: Does early second-trimester sonography predict adverse perinatal outcomes in monochorionic diamniotic twin pregnancies? *J Ultrasound Med.* 33(9):1573-8, 2014
3. American College of Obstetricians and Gynecologists et al: ACOG practice bulletin no. 144: multifetal gestations: twin, triplet, and higher-order multifetal pregnancies. *Obstet Gynecol.* 123(5):1118-32, 2014



(Left) Abdominal US at 13 weeks shows the twins separated by the very delicate, thin, diamniotic membrane, which is barely perceptible even with a 6 MHz transducer in a slim patient. Vaginal US is very helpful for membrane assessment in the 1st trimester. (Right) Abdominal images at 19 weeks show the difference between a thin, diamniotic membrane and a thick, dichorionic membrane. Note the "T" junction of the diamniotic membranes as opposed to the dichorionic "twin peak" or lambda sign.



(Left) Abdominal US of normal placental cord insertion sites in monochorionic (MC) twins shows that both enter the placental disc and that they are quite far apart. The intertwin membrane was not visible in this picture. (Right) In contrast, a composite grayscale and color Doppler US shows an abnormal, velamentous cord insertion. Cord inserts on the membranes, and vessels run along the membranes to reach the placenta. Velamentous cord insertion is a proxy marker for unequal placental sharing.



(Left) Surface view of a MDT placenta with a thin retracted membrane shows close cord insertion sites and several large arterio-arterial anastomoses. These allow blood exchange between the twins. Variations in the direction and degree of shunting result in alterations of cord Doppler waveforms. (Right) Cord Doppler in such a case shows intermittent antegrade, absent, and reversed end diastolic flow. This reflects variable shunting and does not herald bad outcome in otherwise uncomplicated MC twins.

KEY FACTS

TERMINOLOGY

- 2 fetuses in single amniotic sac

IMAGING

- 1st trimester
 - Single yolk sac is reliable predictor on vaginal scans > 7 wk
- 2nd trimester
 - No intertwin membrane
 - Single placental mass
 - Majority of cases have cord entanglement

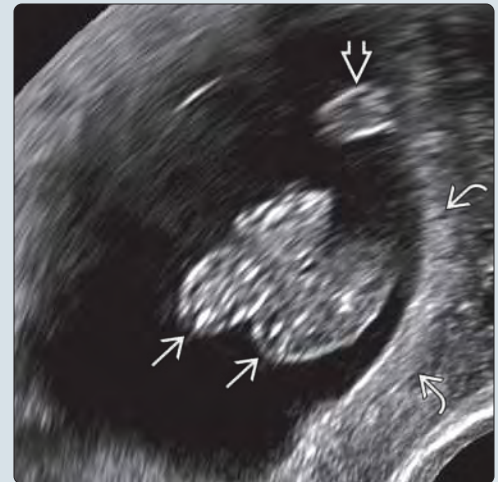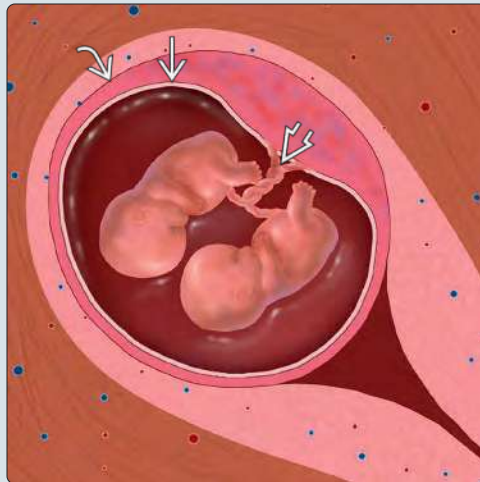
TOP DIFFERENTIAL DIAGNOSES

- Conjoined twins
- Diamniotic twins with absent intertwin membrane
 - Twin-twin transfusion syndrome (TTTS)
 - Twin anomaly
 - Premature rupture of membranes
 - Intertwin membrane rupture

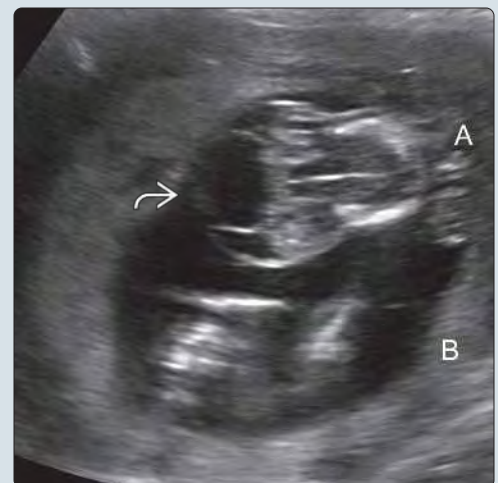
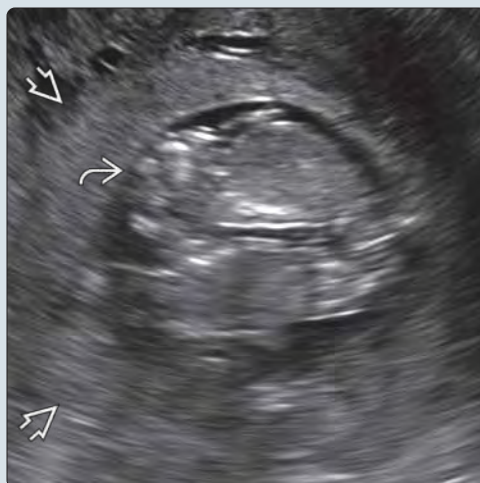
CLINICAL ISSUES

- Careful screen for anomalies (particularly cardiac)
- Intensive monitoring of fetal well-being
- Diligent search for TTTS
 - More challenging as there is no stuck twin
 - Look at bladders, growth, evidence of cardiac decompensation
- Cord entanglement may not be as serious as once thought
 - 228 fetuses (i.e., 114 pairs) with cord entanglement had overall survival of 88.6%
- Adverse outcomes most effected by prematurity and presence of anomalies
- Best management protocol remains controversial
 - 2014 international collaborative study states "if close fetal surveillance is instituted after 26-28 wk, and delivery takes place at ~ 33 wk of gestation, risk of fetal or neonatal death is low no matter surveillance setting"

(Left) Graphic of monoamniotic twins shows a single chorion, single amnion, and single placenta. The cord origins are close, and the cords are entangled. **(Right)** TVUS at 9 weeks shows 2 embryos with 1 yolk sac and chorion. The amnion was visible surrounding the embryos on real-time evaluation. It can be difficult to exclude conjoined twinning in early monoamniotic twins as the embryos are often very close to each other. It is easier to see independent movement as the amnion expands.



(Left) TVUS at 11 weeks shows 2 embryos within a single chorionic cavity without a visible intertwin membrane. The cranial end of the superior embryo was irregular in shape, and we were suspicious for exencephaly vs. encephalocele. Patient habitus was challenging given BMI of 60. **(Right)** Follow-up in the same case at 15 weeks confirms an abnormal cranium in fetus A with a large occipital encephalocele. Major anomalies are reported in 6-28% of monochorionic monoamniotic twins.



TERMINOLOGY

Abbreviations

- Monochorionic monoamniotic twins (MMT)

Definitions

- 2 fetuses in single amniotic sac

IMAGING

General Features

- Best diagnostic clue
 - Cord entanglement

Ultrasonographic Findings

- Grayscale ultrasound
 - 1st trimester
 - Single yolk sac (YS) is reliable predictor of MMT on vaginal scans > 7 wk
 - Must confirm lack of intertwin membrane on subsequent scan to prove diagnosis
 - 2nd trimester
 - No intertwin membrane
 - Single placental mass
 - Same gender
 - Umbilical cord entanglement
 - Mass of vessels with differing fetal heart rates
 - Described as early as 10 wk gestational age (GA)
 - Umbilical cord fusion
 - Separate cords fuse at short distance from placental insertion
 - Y-shaped or forked appearance
 - Not branching entanglement as seen with cord knot
- Pulsed Doppler
 - Systolic notch in umbilical artery (UA) was thought to be abnormal
 - More recent study states UA notch and cord entanglement, without other signs of fetal deterioration, are not indicative of adverse perinatal outcome
 - 6/6 sets with cord entanglement
 - 4/6 with UA notch (2/4 with notching in both cords)
 - UA, middle cerebral artery, ductus venosus Doppler, biophysical profile normal in all
- 3D
 - May be helpful in differentiation from conjoined twins, evaluation of anomalies

Imaging Recommendations

- Count YS as number YS ~ number amnions
- Check fetal gender: If different, twins must be dizygotic therefore dichorionic diamniotic (DC)
- Assess umbilical cord placental insertion sites for marginal or velamentous cord
- Look for cord entanglement
- Careful search for anomalies; 25% discordant for major anomaly
 - Cardiac anomalies most common; consider formal fetal echocardiography
 - Renal agenesis particularly difficult to diagnose in one of MMT pair

- No oligohydramnios: Amniotic fluid produced by normal cotwin
- Evaluate for twin-twin transfusion syndrome (TTTS)
 - Polyhydramnios only
 - Donor oligohydramnios cannot be assessed due to lack of intertwin membrane
 - Small or absent bladder in 1 fetus
 - Hydrops in 1 fetus (usually with normal or large bladder)
 - Look for UA Doppler abnormality to support diagnosis
- Use MR to evaluate brain injury (twin demise, pre-/postintervention)

DIFFERENTIAL DIAGNOSIS

Conjoined Twins

- Contiguous skin covering between fetuses
- Cords may be fused but do not appear knotted

Diamniotic Twins With Absent Intertwin Membrane

- Twin-twin transfusion syndrome
 - Recipient twin larger, polyhydramnios ± hydrops
 - Donor twin smaller, in fixed position (stuck twin)
- Twin demise
 - Anhydramnios, no cardiac activity in sac of dead twin
- Twin anomaly (e.g., renal agenesis, sirenomelia in 1 twin)
- Premature rupture of membranes
- Intertwin membrane rupture
 - Most commonly complication of intervention
 - Failure to see membrane after earlier documentation

PATHOLOGY

General Features

- Associated abnormalities
 - TTTS (6-8%)
 - Less common than in monochorionic diamniotic twins (MDT) as more bidirectional shunts in MMT placentas
 - Twin reversed arterial perfusion sequence (TRAP)
 - Result of artery to artery anastomosis in monochorionic (MC) placentation
- Embryology
 - MMT occurs when embryo splits after 8th postconception day

Gross Pathologic & Surgical Features

- Cord insertion sites on placenta closer than in monochorionic diamniotic (MDT)
 - Mean intercord distance: 5-cm MMT
 - Mean intercord distance: 17.5-cm MDT
- Proximate cord insertion defined as intercord distance ≤ 4 cm
- Velamentous cord in 4%

CLINICAL ISSUES

Presentation

- Most common signs/symptoms
 - Cord entanglement, absent intertwin membrane

Demographics

- Epidemiology
 - M < F

- 5-10% of monozygotic (MZ) twinning
 - MZ twin pregnancies account for 30% of all naturally conceived twins
 - MZ twinning rates following assisted reproduction therapy (ART) are 2-12x natural occurrence
- May be up to 5% monochorionic twins

Natural History & Prognosis

- Cord entanglement was thought to be main cause of poor outcome, but newer evidence shows prematurity and congenital anomalies are far more significant
 - Fetal anomalies associated with 42.9% perinatal mortality
 - Major anomalies seen in 6-28%
 - In structurally normal MMT twins, perinatal mortality (PNM) is ~ to that in MDT
- 2013 literature review on **outcome of 228 fetuses (i.e., 114 pairs) with cord entanglement**
 - Control group from pooled reports of outcome in twins without cord entanglement at birth
 - Overall survival: 88.6%
 - Double survival in 84.2% of pairs
 - Single demise in 8.8% of pairs
 - Double loss in 7% of pairs
 - Perinatal mortality (PNM): 11.4% (26 fetuses)
 - 65% intrauterine fetal demise (IUFD), 14-33 wk GA
 - 35% died at birth (2 anomalies, 5 due to prematurity, 2 attributed to cord entanglement)
 - Neonatal morbidity: 21.1%
 - Apgar < 7 at 5 min, ICU admission, respiratory distress syndrome, neurological impairment or necrotizing enterocolitis
 - Final assessment: **Cord entanglement is minor complication of monoamniotic twin pregnancies**
- 2015 metaanalysis of 13 studies of PNM > 24 wk was 4.5%
 - However, most losses occur before 24 wk
 - Spontaneous double loss < 22 wks was 20.8% MMT in 2015 Danish series
 - Compared to 0.9% for DC, 2.4% MDT
 - 68% loss rate documented in one series with 1st-trimester diagnosis
- 2014 international collaborative retrospective analysis of 386 fetuses (193 pairs)
 - 26% congenital anomalies
 - 2.6% with TTTS (1 surviving child of 6 affected fetuses)
 - 18.1% individual fetal demise (70 fetuses of 42 pairs)
 - 5.7% neonatal demise (anomalies, brain injury, prematurity, birth asphyxia)
 - 67.6% surviving neonates without major anomaly
 - **Risk of IUFD became equal to that of nonrespiratory complication of prematurity at 32 wk 4 days**
 - Study conclusion was to consider elective preterm delivery at ~ 33 wk
- 2012 Japanese series of 202 fetuses (101 pairs)
 - Prospective risk of an IUFD 13.9% in those who reached 22 wk
 - Decreased to 4.5-8.0% between 30 and 36 wk
- Increased risk of brain/renal hypoxic injury in survivor if single twin IUFD
 - 38% risk of death
 - 46% risk of neurological damage

- Immediate delivery does not prevent hypoxic tissue damage in survivor
 - Adds risks of prematurity to existing risks of hypoxia

Treatment

- Careful search for anomalies and complications of monochorionic twinning
- Consider selective termination for discordant major anomaly
- Monthly scans to assess growth
 - Increase frequency if concern for discordance
- Scan every 2 wk for fluid volume, signs of TTTS
- Intensive monitoring
 - Many centers admit patients at viability (USA 24 wk, other countries 26-28 wk)
 - Recent studies show no difference in outcome between inpatient and outpatient monitoring
 - Outpatient care is cheaper, less disruptive to family, mothers more active so less risk of venous thromboembolism, deconditioning etc.
 - Low threshold for admission at any point for prolonged monitoring
 - Daily nonstress testing (NST) starting at 24-28 wk
 - Increasing frequency of decelerations may herald serious cord compression
 - Continuous heart monitoring if variable decelerations increase in frequency or severity
 - Some authors recommend biophysical profile (BPP) as primary screen of fetal well being
 - Less false-positive testing than with NSTs
 - Nonreactive NST is triaged with BPP
- 2014 international collaborative study states "if close fetal surveillance is instituted after 26-28 wk, and delivery takes place at ~ 33 wk of gestation risk of fetal or neonatal death is low no matter surveillance setting"
- Steroid administration for lung maturation at 26-28 wk
- Timing and mode of delivery are controversial
 - Cesarean section traditionally preferred to avoid cord accident
 - Elective preterm delivery at 32 wk is common
- **Insufficient randomized controlled evidence on which to draw strong conclusions about best management**

DIAGNOSTIC CHECKLIST

Consider

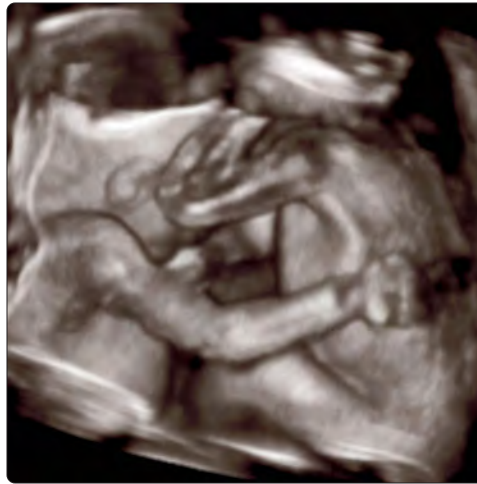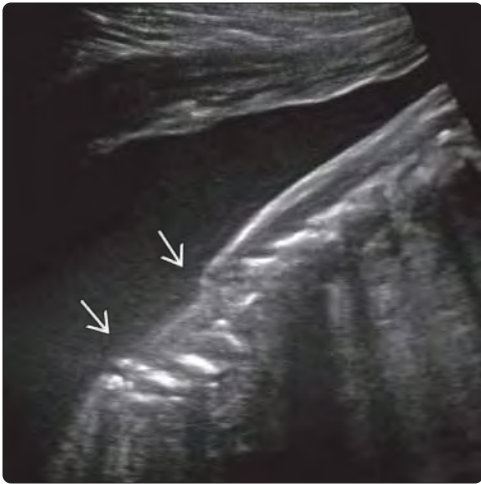
- Focus of management is on detection of structural anomalies, TTTS, risk of prematurity

Image Interpretation Pearls

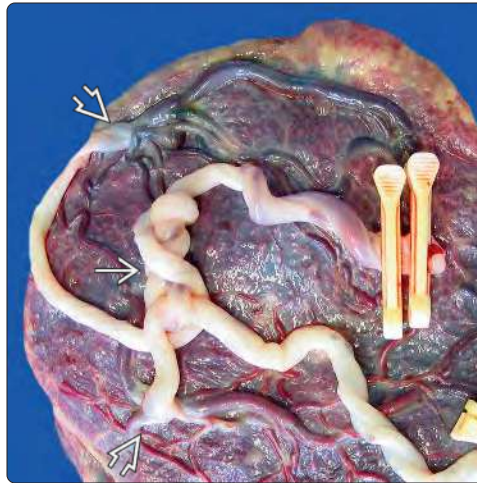
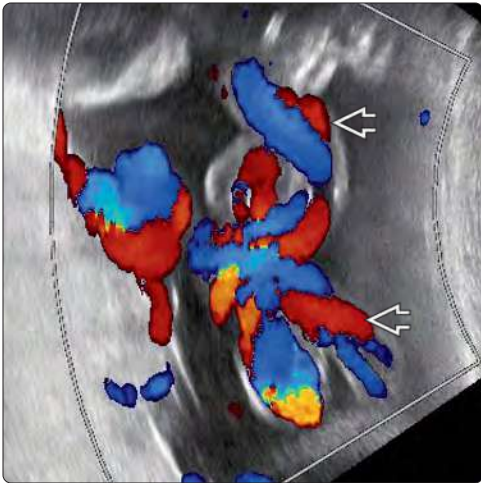
- Cord knot implies fetuses in same sac

SELECTED REFERENCES

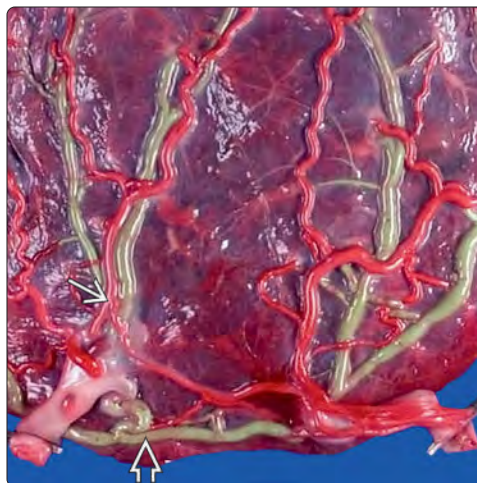
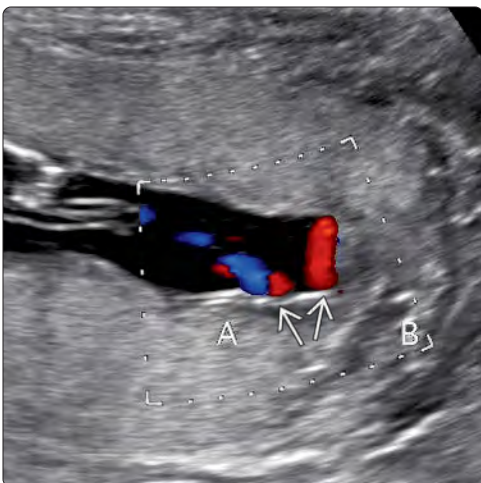1. Prefumo F et al: The natural history of monoamniotic twin pregnancies: a case series and systematic review of the literature. *Prenat Diagn.* 35(3):274-80, 2015
2. Van Mieghem T et al: Prenatal management of monoamniotic twin pregnancies. *Obstet Gynecol.* 124(3):498-506, 2014



(Left) Sagittal ultrasound shows disruption of the skin line in a monoamniotic twin with myeloschisis \Rightarrow . This case illustrates how elevated maternal serum α -fetoprotein in twins is not always simply attributable to the presence of more than 1 fetus. (Right) 3D surface rendering shows these 23-week twins expressing some "brotherly love" as they hug each other. Fetuses can only touch each other if they are in the same amniotic sac.



(Left) Color Doppler shows a complex cord knot \Rightarrow in monoamniotic twins. Cord entanglement in relation to demise in monoamniotic twins is controversial, and recent studies suggest that it is does not play as large a role as previously thought. These twins did well. (Right) Gross pathology in a similar case shows a complex cord knot \Rightarrow . Also note that entanglement occurred even though the cord insertion sites \Rightarrow are quite far apart on the placental surface. There is also marginal insertion of the superior cord. (Courtesy H. Thacker, MD.)



(Left) Color Doppler at 14 weeks shows proximate placental cord insertion sites \Rightarrow . IUFD occurred at 16 weeks without clear etiology, but large-volume shunting through placental anastomoses may have been a factor. (Right) Dye injection delineates various types of placental anastomoses, with artery-to-artery (red) \Rightarrow and vein-to-vein (green) \Rightarrow shunts. Bidirectional shunts are more common in MMT placentas; therefore, TTTS occurs less often. When present, it is an important complication. (From DP: Placenta.)

KEY FACTS

TERMINOLOGY

- Discordant twin growth (DTG) is most commonly defined as 20% difference in estimated fetal weight (EFW) between larger and smaller fetuses
- Percentage difference in EFW = $\frac{\text{EFW larger} - \text{EFW smaller}}{\text{EFW larger}} \times 100$

IMAGING

- Abdominal circumference (AC) difference > 20 mm in 2nd/3rd trimester
- Ratio of large AC/small AC > 1.3 predicts severe birth weight discordance better than EFW

TOP DIFFERENTIAL DIAGNOSES

- Twin-twin transfusion syndrome (TTTS)
 - Specific complication of monochorionic twinning secondary to placental arteriovenous vascular anastomoses
 - Donor twin oligemic with oligohydramnios

- Recipient twin volume overloaded with polyhydramnios
- Discordant growth may be present but is not mandatory feature


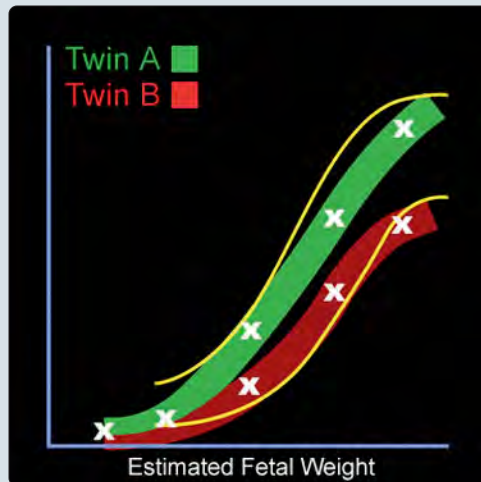
CLINICAL ISSUES

- Serious morbidity increased 8x in preterm discordant twins

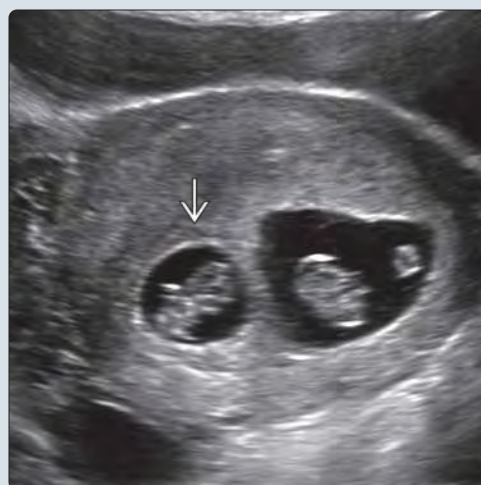DIAGNOSTIC CHECKLIST

- Crown rump length discrepancy in 1st trimester should trigger careful evaluation
 - In absence of structural or chromosomal abnormality, it is only weak predictor of mortality
- DC twins may exhibit benign twin growth rate deviations
- Monochorionic (MC) twins should have same growth potential
 - DTG is abnormal even in absence of growth restriction
 - Maintain high index of suspicion for TTTS in MC twins with DTG

(Left) Graphic demonstrates 3rd-trimester growth lag for twin B with the estimated fetal weight dropping below the 10th percentile, while twin A is normally grown. Yellow lines represent 10th and 90th percentiles of EFW vs. gestational age. (Right) Despite being delivered by emergency C-section at 36 weeks for growth restriction, low fluid, & abnormal Doppler, these monochorionic twins had no adverse consequences. At 11 months, there was a 5-lb weight difference, but both boys are healthy & developmentally normal.



(Left) Transverse 1st-trimester ultrasound shows an obvious discrepancy in sac size in this dichorionic (DC) twin pair. The smaller twin looks "crowded." (Right) At the 18-wk scan, the fetuses were within days of each other in size, and the patient had an uneventful delivery at 38 wk. In the absence of aneuploidy and structural malformation, 1st-trimester size discrepancy is not associated with adverse outcome, especially in DC twinning where it is likely that the genetically different fetuses have different growth potential.



Fetus A				
	w	d	2SD	cm
BPD	19	1	12	4.33
HC	18	4	10	15.66
AC	18	0	14	12.44
FL	17	6	10	2.59
HL	17	6	23	2.52

Fetus B				
	w	d	2SD	cm
BPD	18	2	12	4.04
HC	17	6	8	14.70
AC	18	0	14	12.39
FL	17	3	10	2.48
HL	18	1	23	2.58

TERMINOLOGY

Definitions

- Literature confusing on topic because of variable definitions of discordant twin growth (DTG), fetal growth restriction (FGR)
 - DTG: Estimated fetal weight (EFW) difference 20% vs. 25%
 - Or at least 1 twin with FGR
 - Or 1 twin with FGR + 25% difference birth weight, not EFW
 - Or FGR + abnormal Doppler
 - FGR: EFW < 10th vs. < 5th vs. < 3rd percentiles
 - Or AC < 5th percentile
- Per American College Obstetricians and Gynecologists practice bulletin, DTG is most commonly defined as 20% difference in EFW between larger and smaller fetuses
- Percentage difference in EFW = $\frac{\text{EFW larger} - \text{EFW smaller}}{\text{EFW larger}} \times 100$

IMAGING

General Features

- Best diagnostic clue
 - EFW difference > 20% is most commonly used definition

Ultrasonographic Findings

- Grayscale ultrasound
 - Crown rump length (CRL) disparity in 1st trimester
 - Abdominal circumference (AC) difference > 20 mm in 2nd/3rd trimester
 - Ratio of large AC/small AC > 1.3 predicts severe birth weight discordance better than EFW
- Pulsed Doppler
 - Significance of abnormal cord Doppler differs between monochorionic (MC) and dichorionic (DC) placentas
 - **Sustained abnormal Doppler in DC** placenta reflects abnormal placental vascular resistance
 - **Variable abnormal Doppler findings in MC twins with DTG** occur as result of changing volume and direction of flow through placental vascular anastomoses
 - Type 1: Consistently positive end diastolic flow in small twin
 - Balanced, bidirectional, arterio-arterial shunting with arteriovenous shunting as well
 - Low risk of deterioration; survival nearly 100%
 - Type 2: Persistent absent end diastolic flow (AEDF) in small twin
 - Small or no arterio-arterial anastomoses
 - 90% eventually deteriorate; survival rates approximately 60%
 - Type 3: Intermittent AEDF flow in small twin
 - Most unequally shared placentas, but large arterio-arterial anastomoses with extensive intertwin blood exchange
 - Intermediate prognosis with 80% survival, **but** most unpredictable group
 - Highest risk of survivor exsanguination/acute hypotension if 1 twin dies
- Color Doppler
 - Useful to assess for placental cord insertion sites

- Velamentous cord insertion
 - Marker for unequal placental sharing in MC twins
 - Associated with 13x increase in discordant birth weight
 - Associated with increased risk of vasa previa
- Also compare size of umbilical cords; smaller fetus may have smaller cord

Imaging Recommendations

- Protocol advice
 - Determine chorionicity and amnionicity in all multiples
 - Demise of 1 twin in MC twins much higher risk to survivor than DC twin demise
 - Document placental cord insertion sites
 - Check placental implantation sites
 - FGR associated with implantation on septum/fibroids
 - Meticulous survey for anomalies, signs of aneuploidy
 - Perform serial biometry for detection of discordant growth
 - Maintain high index of suspicion for twin-twin transfusion syndrome (TTTS) in MC twins with DTG
 - DTG is not mandatory feature of TTTS
 - Hallmark findings is combination of oligohydramnios/polyhydramnios
 - UA Doppler may help differentiate healthy, constitutionally small twin from similar-sized twin with FGR
 - Also look at fluid volume, fetal activity, nonstress testing and biophysical profile
 - Consider use of MR to clarify anomalies, evaluate placental relationship to uterine septa/fibroids

DIFFERENTIAL DIAGNOSIS

Twin-Twin Transfusion Syndrome

- Discordant growth may be present but is not mandatory feature
- Type-specific complication of MC twinning secondary to unbalanced arteriovenous shunt through placental anastomoses
 - Donor twin with oligohydramnios, poor growth, hypoxia/anemia
 - Recipient twin with polyhydramnios, good growth

PATHOLOGY

Gross Pathologic & Surgical Features

- Main cause of MC DTG is unequal placental sharing
 - Twin with FGR has smaller placental share or abnormal placenta, often velamentous cord insertion

CLINICAL ISSUES

Presentation

- Most common signs/symptoms
 - CRL disparity 1st trimester
 - Poor growth on surveillance scan in 2nd/3rd trimesters

Demographics

- Epidemiology
 - May occur in MC or DC pregnancies
 - **Average growth discrepancy in all twins is 10%**
 - Probably only clinically significant at > 25%

Impact of Discordant Growth on Outcomes in Otherwise-Uncomplicated, Monochorionic, Diamniotic Twins

	Concordant	Discordant	P value
Intrauterine fetal demise	0.9%	4.6%	.15
Preterm delivery < 34 wk	26.4%	65.2%	< .01
Preterm delivery < 28 wk	4.0%	34.8%	< .01
Newborn intensive care admission	23.3%	68.2%	< .01

Date from retrospective cohort study, single tertiary care center, excluding TTTS, structural anomalies, selective reduction, or BW < 10th percentile.

Harper LM et al: Significance of growth discordance in appropriately grown twins. Am J Obstet Gynecol. 208(5):393.e1-5, 2013.

- **But** commonest definition of DTG is > 20% difference in EFW
- 4% DTG attributed to different genders (i.e., dizygotic and thus, by definition, DC)
- DTG seen in up to 25% of MC twins

Natural History & Prognosis

- Only 50-60% of small twins in utero have birthweight < 10th percentile for gestational age
- Significance of discordance depends on **chorionicity**
 - DTG of 20% in appropriately grown DC twins had no adverse impact on perinatal outcome
 - DTG most likely reflects different growth potential rather than abnormal placentation
 - "Benign" twin growth rate deviations
 - MC twins should have same growth potential
 - Growth discordance more likely to represent pathologic process
 - DTG in MC twins → increased risk of preterm birth, intensive care unit admission, even when both appropriately grown
 - 7x increase in neurological morbidity in MC discordant twins compared to DC
 - Many relate to intrauterine demise of one or iatrogenic prematurity
- Serious morbidity increased 8x in discordant twins with preterm birth

Treatment

- 1st-trimester discordance must be worked up for structural or chromosomal anomalies
 - Nuchal translucency measurements predict ↑ risk for aneuploidy and TTTS
 - Offer genetic counseling ± karyotype
 - Chorionic villus sampling allows early diagnosis of aneuploidy
 - Selective termination easier to perform earlier in pregnancy
 - In absence of structural or chromosomal anomalies, CRL difference is only weak predictor of mortality
- Determine chorionicity
 - Significant increase in morbidity if DTG and MC placenta
- Serum screening
 - Maternal serum α-fetoprotein (MSAFP) is useful in twin pregnancies
 - MSAFP > 5 multiples of median associated with adverse outcome regardless of chorionicity
 - Also detected all cases of open neural tube defects

- Offer selective termination for anomalous or aneuploid fetus
- Follow-up for growth
 - Every 4 weeks for concordant twins
 - MC twin have fluid checks every 2 weeks as well for early detection of TTTS
 - Discordant twins followed more frequently
 - Monitor twins with velamentous cord insertion closely
- Management decisions should not be based on EFW differences alone
 - Multiple factors influence decision to deliver
- Consider conservative nonintervention in DC twins with early-onset DTG and deteriorating well-being of smaller fetus
 - Avoid risks of iatrogenic prematurity for normally grown twin
 - Co-twin demise has little adverse impact on survivor
- International consensus on best treatment for MC twins with DTG is lacking

DIAGNOSTIC CHECKLIST

Image Interpretation Pearls

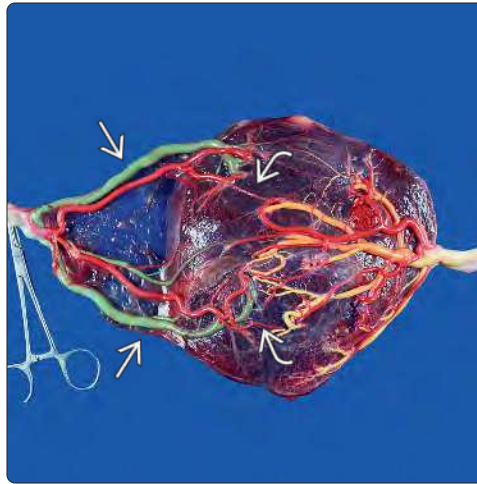
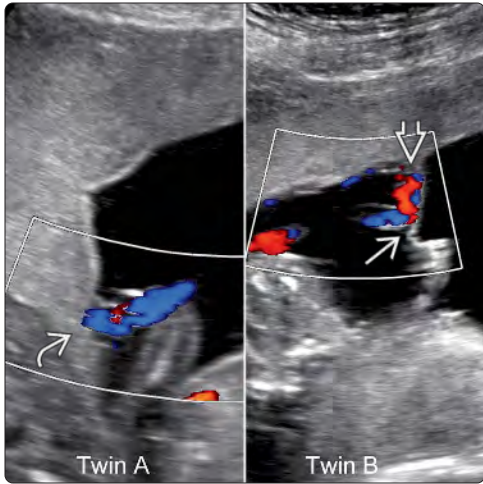
- In absence of structural or chromosomal abnormality, crown rump length discrepancy is only weak predictor of mortality
- EFW discordance of > 25% is best overall predictor of perinatal mortality irrespective of chorionicity or individual fetal size
- **But** once anomaly, aneuploidy, and TTTS are excluded EFW and AC discordance have poor predictive value for adverse perinatal outcome






Reporting Tips

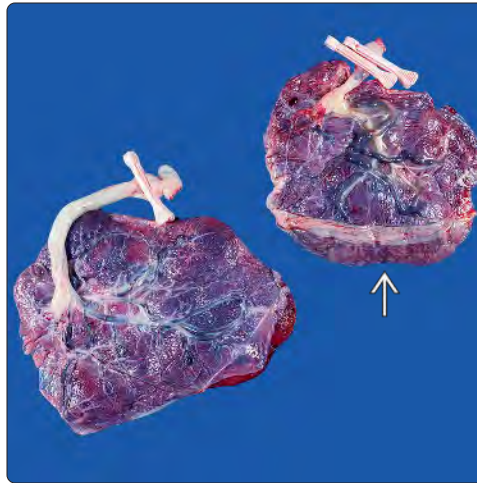
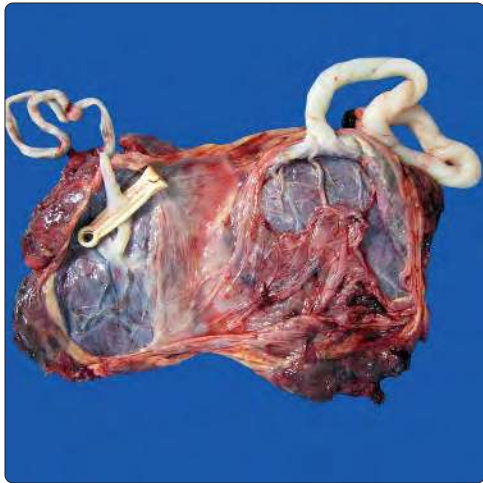- Benign twin growth rate deviations may occur in dichorionic twins
- DTG is abnormal in MC twins even in absence of growth restriction as they should have same growth potential
- Maintain high index of suspicion for TTTS in monochorionic twins with DTG

SELECTED REFERENCES

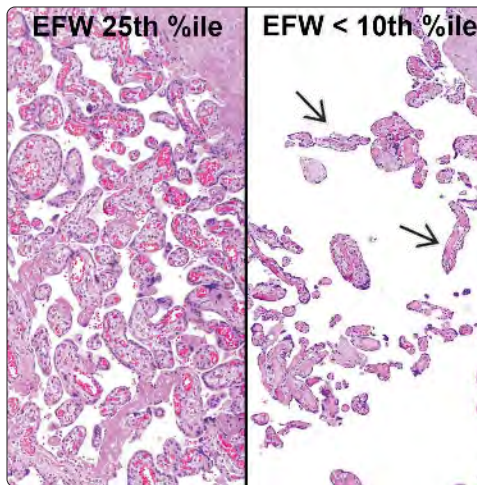
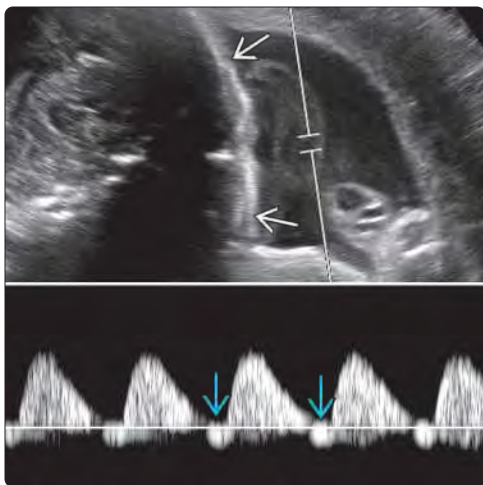
1. D'Antonio F et al: Second-trimester discordance and adverse perinatal outcome in twins: the STORK multiple pregnancy cohort. BJOG. 121(4):422-9, 2014
2. Lewi L et al: Growth discordance. Best Pract Res Clin Obstet Gynaecol. 28(2):295-303, 2014






(Left) Color Doppler imaging is very helpful for evaluation of the placental cord insertion site. In this pair, A has a marginal cord insertion , and B's cord insertion is velamentous  on the inter-twin membrane . Interestingly, neither twin was growth restricted. (Right) Photograph of the placenta of MC twins delivered at 35 weeks for growth restriction of 1 twin shows a velamentous cord insertion  and a smaller placental share for that twin. Note the placental equator . (From DP: Placenta.)



(Left) Discordant fetal growth may be reflected in large and small cords, as in this DC placenta. (From DP: Placenta.) (Right) Placentas from DC twins delivered at 30 weeks for fetal growth restriction (FGR) & reversed end diastolic flow (REDF) in the smaller twin confirm small placental size . Histology showed prominent perivillous fibrin deposition. In both these examples, DC discordant twin growth was pathological, but benign variance in size may occur due to different genetic makeup. (From DP: Placenta.)



(Left) Doppler of a free-floating cord loop adjacent to the fetal head  in a DC twin with FGR shows REDF . This is associated with a high risk of intrauterine demise; a C-section was performed. (Right) Placental histology from MC twins with REDF and severe FGR in twin B (birthweights A: 1220 g, B: 780 g) shows distal villous hypoplasia. The villi from B's (right) placenta look like sticks and twigs  in comparison to the normal, plentiful, branching villi in twin A's placenta (left).

Twin-Twin Transfusion Syndrome

KEY FACTS

TERMINOLOGY

- Monochorionic (MC) twin complication caused by intrauterine transfusion of blood from donor to recipient via arteriovenous (AV) placental anastomoses
- Staging based on fluid volume, bladder size, Doppler findings, presence of hydrops

IMAGING

- **Donor**
 - Oligohydramnios defined as maximum vertical pocket (MVP) ≤ 2 cm
 - "Stuck twin" describes severe oligohydramnios with smaller, donor twin in fixed position by uterine wall
 - Doppler abnormalities in donor usually involve umbilical artery (UA)
- **Recipient**
 - Polyhydramnios defined as MVP ≥ 8 cm at < 20 weeks, > 10 cm at > 20 weeks

- Doppler abnormalities in recipient more likely to involve ductus venosus (DV) or umbilical vein (UV)
- Cardiomyopathy due to volume overload
- Pulmonary atresia, pulmonary stenosis (PS) incidence as high as 9.6%
- NIH sponsored TTTS trial found that echocardiographic evidence of cardiomyopathy was strongest predictor of recipient demise

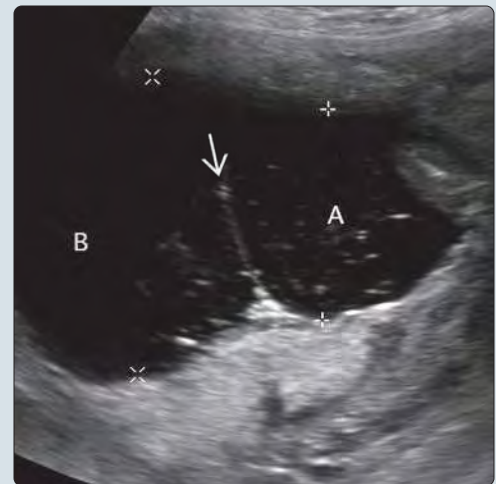
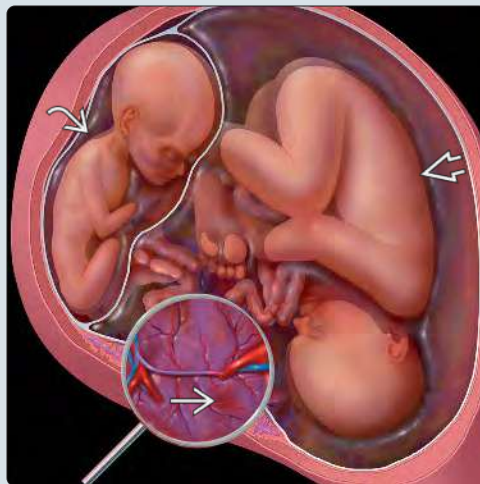
PATHOLOGY

- Placental vascular anastomoses occur in almost all monochorionic twins
- TTTS occurs when there is unbalanced AV shunt between twins

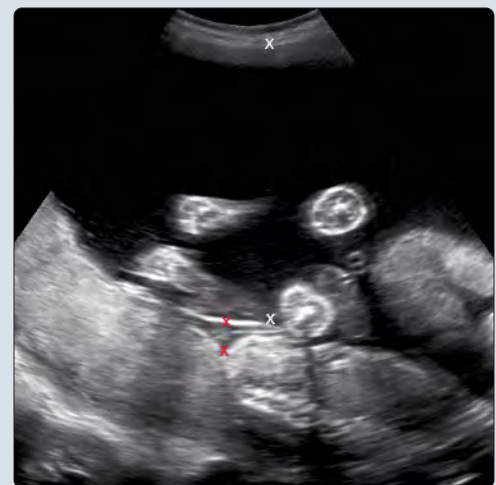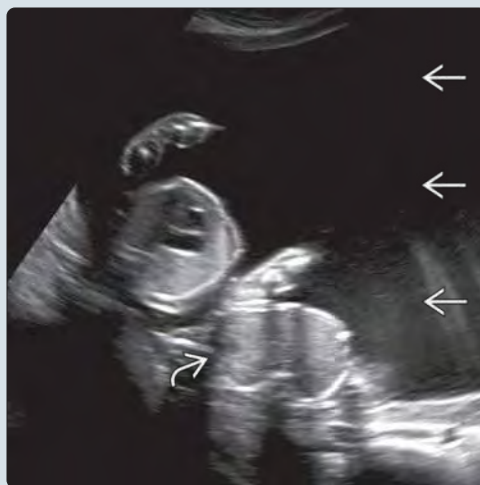CLINICAL ISSUES

- Check MVPs every 2 weeks from 16 weeks in all MC twins
- Stage TTTS at diagnosis to determine treatment
- Laser coagulation is treatment of choice for stages 2, 3, and 4 TTTS in continuing pregnancies at < 26 weeks

(Left) Graphic shows discordant MC twins with a unidirectional AV shunt of deoxygenated blood from the oligemic, poorly grown donor (oligohydramnios) to the hypervolemic recipient (polyhydramnios). **(Right)** At 17 weeks 5 days, there is symmetric distribution of fluid around the thin intertwin membrane. A difference of > 4 cm between maximum vertical pockets is concerning for developing TTTS. The combination of oligohydramnios (< 2 cm) and polyhydramnios (> 8 cm) is diagnostic.



(Left) Follow-up scan in the same case at 27 weeks shows dramatic polyhydramnios. The membrane was no longer visible because it was "shrink-wrapped" around the donor twin, which was unable to move at all while the recipient twin was very active. **(Right)** Fluid volumes about the twins are now quite different with clear development of oligohydramnios (red x) and polyhydramnios (white x). The patient was referred for laser therapy. Unfortunately, her membranes ruptured a week after treatment, and she delivered live, preterm infants.



TERMINOLOGY

Abbreviations

- Twin-twin transfusion syndrome (TTTS)

Definitions

- Monochorionic twin complication caused by intrauterine transfusion of blood from donor twin (D) to recipient twin (R) via arteriovenous (AV) placental anastomoses
- Staging based on fluid volume, bladder size, Doppler findings, presence of hydrops

IMAGING

Diagnostic Criteria

- Monochorionic (MC) twins
- Oligohydramnios in one sac + polyhydramnios in other
 - Seen only in MC diamniotic twins (MDT); diagnosis in monoamniotic twins is more challenging

Ultrasonographic Findings

- **Donor**
 - Oligohydramnios defined as maximum vertical pocket (MVP) ≤ 2 cm
 - "Stuck twin" describes severe oligohydramnios with smaller, donor twin in fixed position by uterine wall
 - Variant "cocoon" or intrauterine sling; D cocooned in membranes, sling reflects back to uterine wall
 - D suspended by sling, floats in pool of R fluid
 - Look for differing echogenicity of fluid; D urine more concentrated \rightarrow fluid more echogenic
 - Echogenic bowel described as sign of hypoxia in donor
 - Doppler abnormalities in D usually involve umbilical artery (UA)
 - Absent (AEDF) or reversed end diastolic flow (REDF)
- **Recipient**
 - Polyhydramnios defined as MVP ≥ 8 cm at < 20 weeks, > 10 cm at > 20 weeks
 - Doppler abnormalities in R more likely to involve ductus venosus (DV) or umbilical vein (UV)
 - Look for increased pulsatility or reversed A wave in DV
 - Look for pulsatile UV flow
 - ◻ Indicates imminent hydrops
 - Cardiomyopathy due to volume overload
 - Cardiomegaly, tricuspid regurgitation, impaired ventricular function, biventricular hypertrophy
 - Pulmonary atresia, pulmonary stenosis (PS) incidence as high as 9.6%
 - Isolated PS seen in 0.2% uncomplicated MDT, 2.9% of TTTS cases treated with laser
 - 18% regressed after laser, 65% required neonatal valve dilation in series published in 2015
- **Discordant twin growth not mandatory feature**
 - Only 20% of donor twins met criteria for selective growth restriction (sFGR) in one large series of TTTS
- Umbilical cords may differ in size: R larger than donor D

Imaging Recommendations

- Check MVPs every 2 weeks from 16 weeks in all MC twins
- Stage TTTS at diagnosis to determine treatment
 - Multiple staging systems exist; Quintero most established

- Fetal echocardiography essential
 - Incidence of structural heart defects with TTTS 15-23x that in singletons
 - Incidence in TTTS fetuses 2.8x that of MC twins without TTTS
- Cincinnati system combines echocardiography and Quintero systems as 50-60% of Quintero stage I and II cases have evidence of cardiac dysfunction
- NIH-sponsored TTTS trial found that echocardiographic evidence of cardiomyopathy was strongest predictor of recipient demise
- Consider middle cerebral artery peak systolic velocity (MCA PSV) to assess for twin anemia/polycythemia sequence (TAPS) post laser therapy
 - Chronic shunt via small AV anastomoses, not associated with fluid discrepancy
 - MCA PSV > 1.5 MoM (multiples of median) in one, < 1 MoM in other twin

DIFFERENTIAL DIAGNOSIS

Premature Rupture of Membranes of One Twin

- If known dichorionic pregnancy, TTTS excluded

Anomalous Twin Causing Stuck Appearance

- Normal co-twin will not have high-output state or polyhydramnios

Selective Fetal Growth Restriction

- $> 20\%$ difference between estimated fetal weights
- Smaller twin may have oligohydramnios
- Normally grown twin will have normal fluid

PATHOLOGY

General Features

- Etiology
 - TTTS occurs when there is unbalanced arteriovenous shunting between twins
 - Superficial and deep anastomoses may coexist
 - Superficial: Between branches of cord vessels on chorionic plate
 - ◻ Artery to artery (A-A) or vein to vein (V-V); these have bidirectional flow
 - Deep: Unidirectional artery to vein (AV) flow as donor UA pierces placenta to supply cotyledon drained by recipient UV
 - ◻ Artery and vein meet in "nose to nose" configuration
 - ◻ Different from normal, paired vessels; visible target for selective laser

Staging, Grading, & Classification

- Quintero system most established; other systems include echocardiography
- Cardiovascular profile scoring (CVPS)
 - Points based on hydrops, DV/UV/UA Doppler, cardiothoracic ratio, cardiac function based on ventricular systolic function and atrioventricular valve regurgitation
- Children's Hospital of Philadelphia (CHOP)

Staging Systems for TTTS

Stage	Donor	Recipient	Fluid	Doppler	Cardiomyopathy	Other
Quintero System						
I	Bladder visible		Oli/poly	Normal		
II	Bladder not seen		Oli/poly	Normal		
III	Bladder not seen		Oli/poly	Abnormal		
IV	Bladder not seen	Ascites or hydrops	Oli/poly	Abnormal		
V	Bladder not seen		Oli/poly	Abnormal		Demise
Cincinnati System						
I	MVP < 2 cm	MVP > 8 cm				
II	Bladder not visible	Bladder visible				
III				Abnormal in both	A: Mild, B: Moderate, C: Severe	
IV						Hydrops

Quintero Stage III can be subclassified as III-D, III-R, or III-DR depending on whether Doppler abnormalities are seen in the donor, the recipient or both. The criteria for mild, moderate, and severe cardiomyopathy in the Cincinnati system include AV regurgitation, ratio of RV to LV wall thickness, and myocardial performance index. In both systems, hydrops or demise can be in one or both twins.

- Points based on 4 Doppler and 9 echo parameters (including heart size, ventricular and valve function, venous Doppler, great artery size, pulmonary insufficiency)

CLINICAL ISSUES

Presentation

- MC twins with asymmetric fluid

Demographics

- TTTS complicates 10-15% of monochorionic pregnancies
 - TAPS occurs in 2-13% of post laser TTTS case
- Spontaneous TAPS in 3-5% MC twins: Onset in 3rd trimester

Natural History & Prognosis

- Prognosis worse with early presentation, higher stage
- **Laser coagulation of placental vessels (LCPV)**
 - Overall survival rates post laser: 55-82.5% (at least one survivor in 73-90.5%)
 - 0-16% recur, 1.4-14% progress (can repeat LCPV)
 - 2-13% develop TAPS
 - Outcomes improving with increasing experience
 - Median GA at delivery 34 weeks
- Stage-related outcome for LCPV
 - Stage 1: Both survive 75.9%, at least one survives in 93.1%
 - > 75% stable or regress without invasive intervention
 - Stage 2: Both survive 60.5%, at least one in 82.7%
 - Stage 3: Both survive 53.8%, at least one in 82.5%
 - Stage 4: Both survive 50%, at least one in 70%
- 7% risk pregnancy loss, preterm birth (PTB) post LCPV
 - PTB risk increased if cervical length < 15 mm, prior PTB, lower maternal age, larger cannula size, amnioinfusion, ruptured membranes
- Neurological impairment in 5-23% of survivors especially if co-twin demise

- Measure cerebroplacental ratio (CPR): Pulsatility index MCA/pulsatility index of UA
 - CPR < 1.0 associated with poorer neurodevelopmental outcome at age 2
- Single center follow-up of 190 infants (to age 6)
 - 79.5% had normal examination and standardized neurodevelopmental test results
 - 11.6% had minor neurological deficiencies and normal test results
 - 8.9% had major neurological deficiencies &/or test results more than 2SD below mean

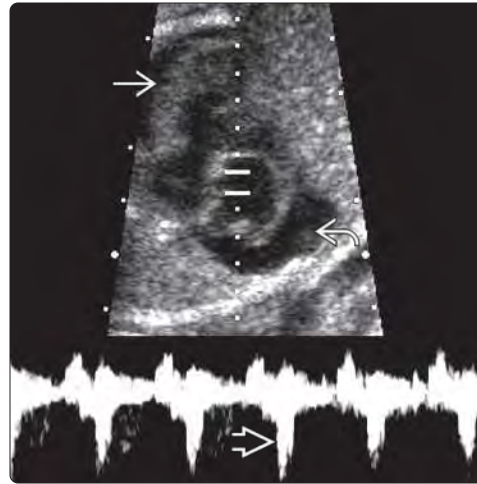
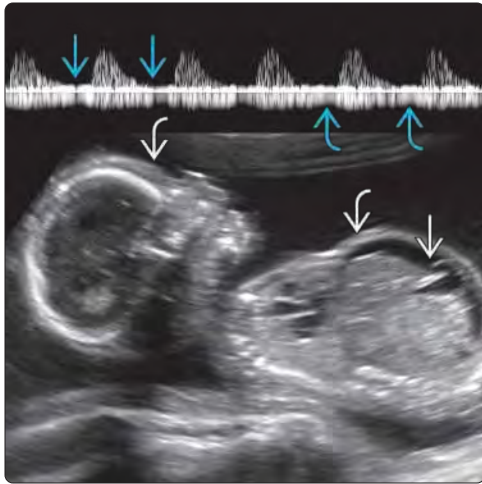
Treatment

- Steroid administration considered from 24 weeks 0 days to 33 weeks 6 days if stage ≥ 3 or LCPV is planned
- **LCPV is treatment of choice** for stages 2, 3, and 4 TTTS in continuing pregnancies at < 26 weeks
 - Management of stage 1 disease is controversial as many will stabilize without intervention
- Treatment window is 16-26 weeks (widened to 15-29 weeks with increasing experience)
 - Selective coagulation of anastomoses at placental vascular equator is most common
 - Some do sequential coagulation of D to R A-V connections followed by R to D connections
- Solomon technique coagulates in between the selective sites to achieve "equatorial dichorionization"
 - Higher double survival at 6 moths (68.4% vs. 50.7%)
 - Lower rates of recurrence, less development of TAPS
- Monitor for development of TAPS post LCPV

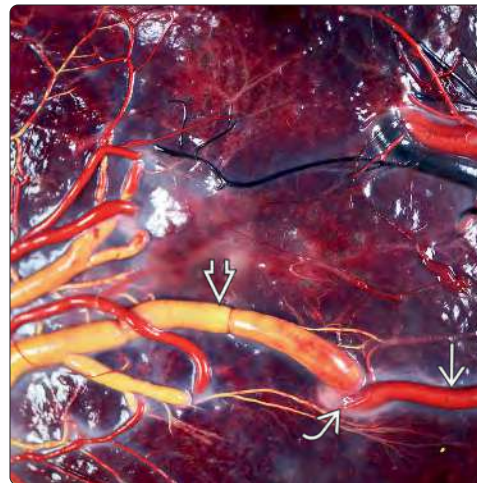
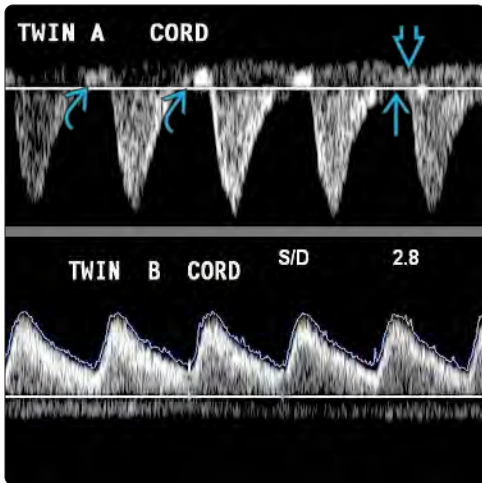
SELECTED REFERENCES

1. Behrendt N et al: Twin-twin transfusion and laser therapy. *Curr Opin Obstet Gynecol.* 28(2):79-85, 2016
2. Chmait RH et al: Fetal brain-sparing after laser surgery for twin-twin transfusion syndrome appears associated with two-year neurodevelopmental outcomes. *Prenat Diagn.* 36(1):63-7, 2016
3. Diehl W et al: Twin-twin transfusion syndrome: treatment and outcome. *Best Pract Res Clin Obstet Gynaecol.* 28(2):227-38, 2014

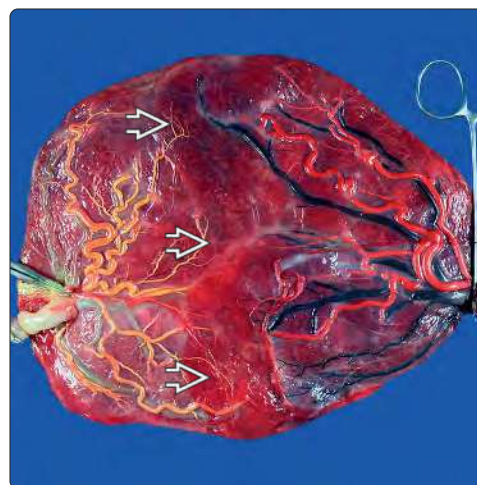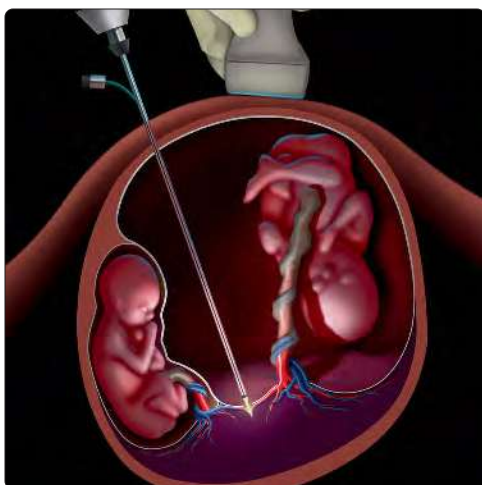
Twin-Twin Transfusion Syndrome



(Left) Continued shunting from donor to recipient causes volume overload, which can, as in this case, lead to hydrops. Note the skin thickening and ascites. The cord Doppler is also abnormal with absent end diastolic flow and pulsatile umbilical vein flow. This is stage 4 TTTS. (Right) In another case, pulsed Doppler ultrasound shows tricuspid regurgitation in the recipient as well as thick myocardium and pericardial effusion. These are all signs of cardiac decompensation.



(Left) Abnormal Doppler findings are used to stage TTTS. In this case, the donor (A) shows either absent or reversed end diastolic flow and pulsatile umbilical vein flow. The recipient (B) has normal cord flow. This is stage III-D TTTS. (Right) Close-up view of the placenta from a case complicated by TTTS shows a large arteriovenous anastomosis from the donor artery to the recipient vein. These deep placental anastomoses manifest as "nose-to-nose" vessels on the placental surface. (From DP: Placenta.)



(Left) Graphic illustrates endoscopic laser coagulation of the chorionic anastomoses that cause TTTS. Access to the placenta is via the large amount of fluid in the recipient's sac. The "stuck" donor twin is seen on the left. (From DP: Placenta.) (Right) Laser was performed for TTTS 16 weeks prior to delivery in this case. The vascular equator is devoid of intertwin communications as a result of "dichorionization." All intertwin vascular connections along the equator are lasered with this technique. (From DP: Placenta.)

KEY FACTS

TERMINOLOGY

- Anomalous twin [twin reversed arterial perfusion (TRAP) twin] perfused by deoxygenated blood from pump twin
- Blood enters fetus via umbilical artery (UA)
 - Reversed perfusion → selective development of torso/lower extremities
 - Lack of umbilical vein flow into heart → impaired/absent cardiac development

IMAGING

- Must be monozygotic gestation
- Flow in umbilical artery (UA) of anomalous twin is toward fetus
- Acardiac twin dysmorphic with edema and cyst formation in soft tissues
 - Edema attributed to lack of vascular to lymphatic communication
- Pump twin high output state may → hydrops
- Recognizable in 1st trimester

TOP DIFFERENTIAL DIAGNOSES

- Twin with anomalies mimicking TRAP twin

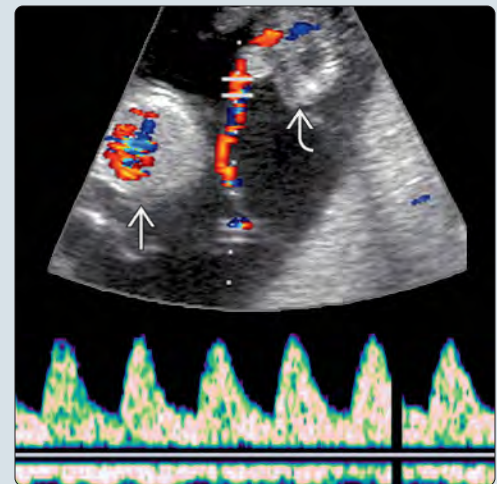
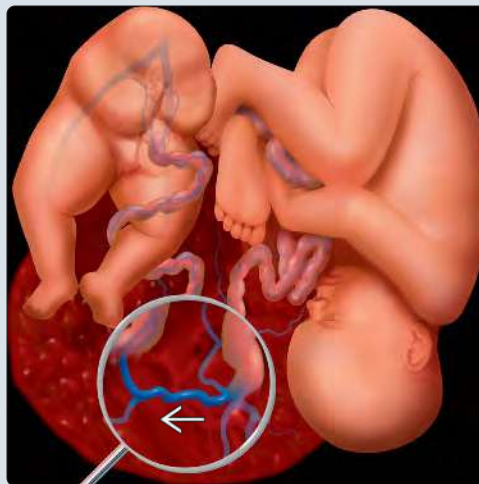
CLINICAL ISSUES

- TRAP twin anomalies are lethal
- Best potential outcome is 1 healthy infant
 - Do not consider intervention unless pump twin is normal
- Untreated, pump twin mortality ~ 50% in modern series
- Pump twin survival improves with intervention; summary of published cases ~ 80% survival
 - Goal of intervention is to interrupt blood supply to acardiac twin
 - Current data suggest that intrafetal radiofrequency ablation is treatment of choice if intervention is indicated

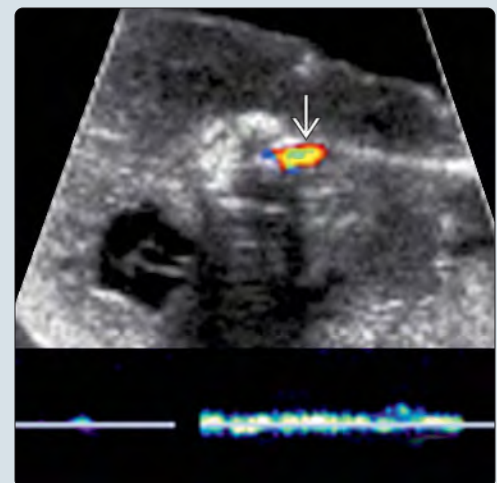
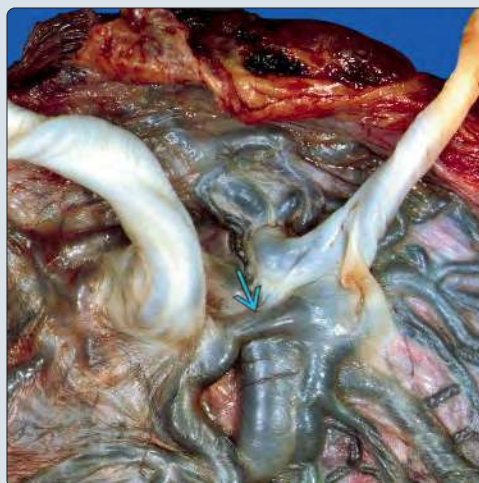
DIAGNOSTIC CHECKLIST

- You will never miss this diagnosis if you check direction of UA flow in anomalous twins

(Left) Graphic depicts a normal twin perfusing an abnormal cotwin via an artery (deoxygenated blood) to artery placental anastomosis. Abnormal circulation with selective perfusion of the lower extremities impairs development of the heart, torso, and head. (Right) Color Doppler ultrasound at 14 weeks gestation shows umbilical arterial flow from the normal pump twin toward the abnormal, edematous acardiac twin. Reverse flow in the umbilical artery is diagnostic of TRAP.



(Left) Acardiac twinning is commonly associated with close approximation of the umbilical cords. There is a large artery-to-artery anastomosis noted between the 2 cords. (From DP: Placenta.) (Right) Color Doppler shows twinkle artifact from spinal bony elements in a dead TRAP fetus following radiofrequency ablation. This does not represent blood flow, as proven by the spectral tracing. An inexperienced sonographer thought that the RFA had failed when she saw what she assumed to be blood flow.



TERMINOLOGY

Abbreviations

- Twin reversed arterial perfusion (TRAP)

Definitions

- Anomalous twin (TRAP twin) perfused by deoxygenated blood from pump twin
- Blood enters fetus via umbilical artery (UA)
 - Reversed perfusion → selective development of torso/lower extremities
 - Lack of umbilical vein flow into heart → impaired/absent cardiac development

IMAGING

General Features

- Best diagnostic clue
 - Flow in UA of anomalous twin is toward fetus
 - Should be away from fetus toward placenta

Ultrasonographic Findings

- Grayscale ultrasound
 - Must be monochorionic gestation
 - 1/3 monoamniotic
 - TRAP twin dysmorphic with edema and cyst formation in soft tissues
 - Edema attributed to lack of vascular to lymphatic communication
 - Rudimentary heart may exist
 - Often no identifiable cranial structures
 - Presence and structure of upper extremities extremely variable
 - Usually recognizable torso and lower extremities
 - Lower extremities move spontaneously
 - Single UA in 66% of acardiac twins
 - Polyhydramnios
 - Pump twin high output state may → hydrops
- Pulsed Doppler
 - **Reversed flow in UA of anomalous twin is pathognomonic**
 - Look for signs of impending hydrops in pump twin
 - Abnormal flow in ductus venosus
 - Reversed flow in inferior vena cava
 - Pulsatile umbilical vein flow
 - Doppler findings associated with poor prognosis
 - Low pulsatility index in TRAP compared to pump twin
 - Small difference in resistive index (RI) between twins
 - ◻ Better outcome with RI difference > 0.2
 - ◻ Poor outcome with RI difference < 0.05 (cardiac failure, brain hypoperfusion)
 - ↑ peak systolic velocity in middle cerebral artery of pump twin
 - ◻ Indicates shunt significant enough to cause fetal anemia
- Color Doppler
 - Look for tricuspid regurgitation in pump twin
 - Beware twinkle artifact in acardiac twin after ablation
 - Color does not equal flow
 - ◻ May get color signal (twinkle) from any highly reflective surface

- Use pulsed Doppler to verify waveform

MR Findings

- May be used prior to intervention
 - Confirm normal brain in pump twin
 - Exclude anomalies in pump twin
- Post intervention may be used to assess adverse effects on pump twin
 - Intracranial hemorrhage
 - Encephaloclastic changes
 - Porencephalic cyst formation

Imaging Recommendations

- Careful search for anomalies of pump twin
 - Intervention only indicated to salvage healthy pump twin
- Monitor size of acardiac twin
 - Prolate ellipsoid formula (width × height × length × 0.523) most accurate
 - TRAP twin > 70% of pump twin → increased risk of pump twin compromise
 - ◻ TRAP twin as % pump twin 103.0% ± 52.0% with pump twin compromise
 - ◻ TRAP twin as % pump twin 56.9% ± 44.3% without pump twin compromise
 - Compare abdominal circumferences (AC)
 - Prognosis worse if ≥ 50% difference
- Fetal echocardiography
 - Used to calculate combined cardiac index (CCI)
 - CCI = cardiac output of both ventricles indexed to estimated fetal weight
 - CCI may identify those pump twins at high risk of pump failure better than weight comparison/polyhydramnios
 - Posttreatment CCI measurement confirms volume unloading, shows recovery of ventricular systolic function
- Potential risk prediction with umbilical vein diameter (UVD) ratios to prevent unnecessary intervention
 - UVD ratios large in cases without complications
 - UVD ratio small and decreasing in cases at risk for complications

DIFFERENTIAL DIAGNOSIS

Anomalous Twin

- Anencephaly
- Destructive process (e.g., amniotic bands)
 - Cardiac structures present
- Cystic hygroma
 - Normal cranium and presence of cardiac activity
- Flow in UA away from fetus in all cases

Fetal Demise

- Anhydramnios in sac of dead twin (if diamniotic)
- No flow in dead twin cord

Placental Teratoma

- May arise from cord or placenta
- No cord, no body organization
- TRAP twin is always skin covered

PATHOLOGY**General Features**

- Etiology
 - TRAP twin has no normal placental circulation: Blood supply is from pump twin
 - Reverse perfusion from artery-to-artery placental anastomoses
 - TRAP twin perfused with deoxygenated blood from pump twin
 - Reverse perfusion allows continued but abnormal development
 - Deoxygenated blood → arrested development in early embryogenesis
 - Deoxygenated blood → hypoxic damage to developing tissues
 - Umbilical arteries → iliac arteries → selective perfusion of lower torso
 - Upper body maldevelopment more apparent than lower
 - Form follows function: Absence of normal circulation impairs cardiac development
 - Venous return to pump twin via vein-to-vein anastomoses
 - Volume preload as well as pump afterload adds to pump twin cardiac stress
- Genetics
 - No consistent chromosomal abnormality
 - No recurrence risk

CLINICAL ISSUES**Presentation**

- Most common signs/symptoms
 - Grossly anomalous twin with abnormal or absent cardiac activity
 - Recognizable in 1st trimester

Demographics

- Incidence of early acardiac twinning may be as much as 2.6% in monochorionic placentation
 - May also occur in high order multiples
 - Many fail spontaneously

Natural History & Prognosis

- TRAP twin anomalies are lethal; best potential outcome is one healthy infant
- Preterm birth (PTB) adds to risks for pump twin
 - Rapidly growing acardiac twin → uterine distension → increased risk PTB
 - Shunt demand → hydrops in pump twin → polyhydramnios → additional increased risk PTB
- Untreated, pump twin mortality ~ 50% in modern series
- 60% of cases diagnose before 14 wk have spontaneous demise of TRAP twin
 - 61% of those have pump twin demise or brain injury
- Outcome data for pump twin showed worse prognosis with increased size of acardiac twin
 - Birthweight ratio of acardiac to pump twin > 70%
 - Preterm delivery: 90% (35% if < 50%)
 - Polyhydramnios: 40% (18% if < 50%)
 - Pump twin hydrops: 30% (0% if < 50%)

- Pump twin survival improves with intervention; summary of published cases ~ 80% survival
 - Intrafetal intervention seems better than cord occlusion
 - GA at treatment had no impact on survival rate but inverse association with GA at birth
 - Mean GA at birth 38 wk for treatment at 13 wk, 34 wk for treatment at 27 wk
- Metaanalysis suggested early treatment with US-guided intrafetal laser would be most beneficial but noted that randomized study needed for confirmation
- No studies have addressed morbidity for surviving pump twins

Treatment

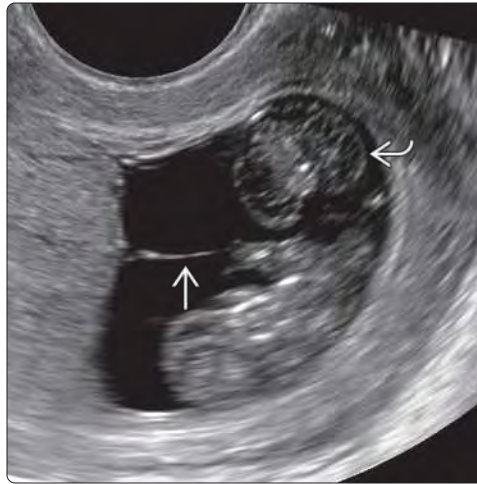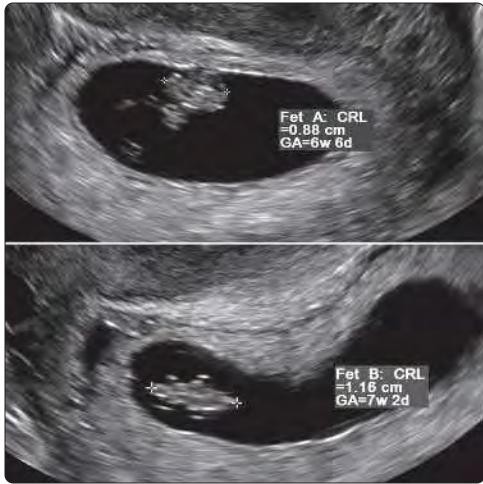
- Offer termination
- Offer karyotype as 33% abnormal with trisomies most common
- Conservative nonintervention
- Intervention with goal to interrupt blood supply to acardiac twin
 - Modern series favor US-guided intrafetal ablation
 - Targets TRAP twin aorta or pelvic vessels
 - Radiofrequency ablation most often used
 - 86-100% success rate reported with no PROM
 - Average GA at birth 37 wk (range: 26-39)
 - Microwave creates heat without circuit and has less thermal spread
 - Small series with good outcome
- Metaanalysis concludes that intervention is better than conservative management for overall pump twin survival
 - Especially if ≥ 1 poor prognostic indicators
 - Polyhydramnios
 - Abnormal Doppler findings indicating cardiac strain in pump twin
 - Pump twin hydrops
 - TRAP weight > pump twin weight



DIAGNOSTIC CHECKLIST**Image Interpretation Pearls**

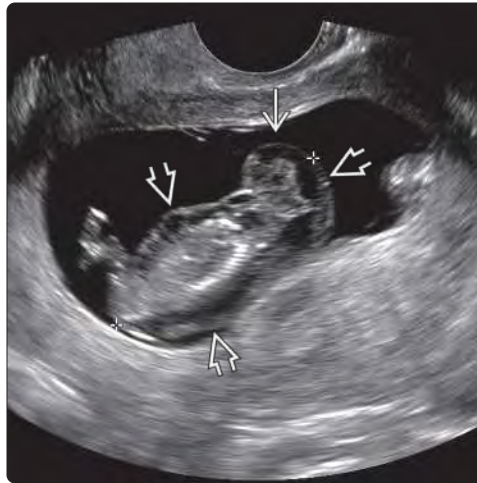
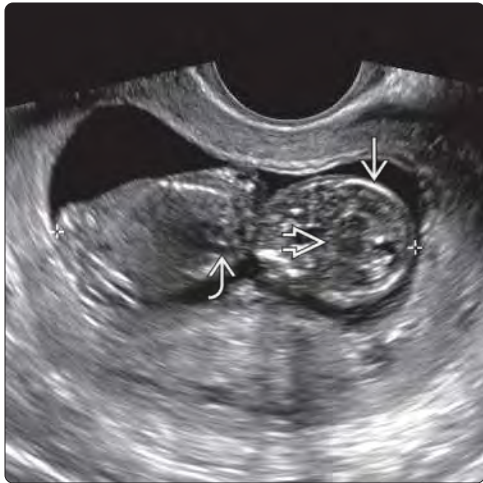
- You will never miss this diagnosis if you check direction of UA flow in anomalous twins






SELECTED REFERENCES

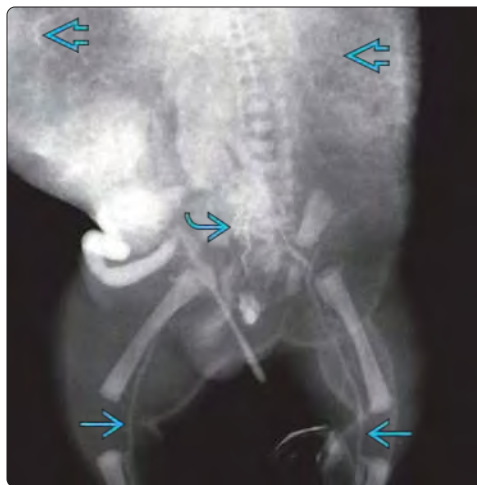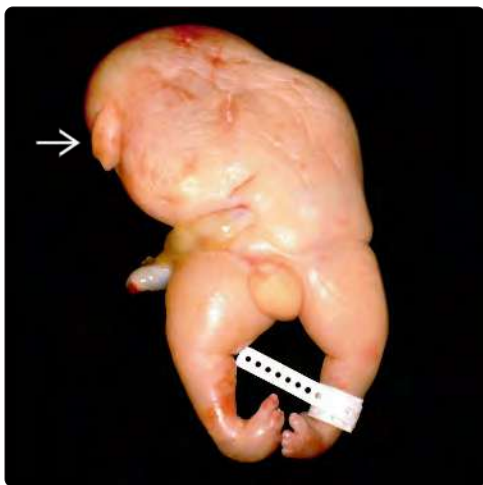
1. Mone F et al: Intervention versus a conservative approach in the management of TRAP sequence: a systematic review. *J Perinat Med.* ePub, 2015
2. Takano M et al: Experience of fetoscopic laser photocoagulation and cord transection for twin-reversed arterial perfusion sequence. *J Obstet Gynaecol Res.* 41(9):1326-9, 2015
3. van Gemert MJ et al: Twin reversed arterial perfusion sequence is more common than generally accepted. *Birth Defects Res A Clin Mol Teratol.* 103(7):641-3, 2015
4. Berg C et al: Twin reversed arterial perfusion (TRAP) sequence—does monoamniocity preclude early intervention? *Ultrasound Obstet Gynecol.* 44(2):241-2, 2014
5. Chaveeva P et al: Optimal method and timing of intrauterine intervention in twin reversed arterial perfusion sequence: case study and meta-analysis. *Fetal Diagn Ther.* 35(4):267-79, 2014
6. Prefumo F et al: Fetoscopic cord transection for treatment of monoamniotic twin reversed arterial perfusion sequence. *Ultrasound Obstet Gynecol.* 43(2):234-5, 2014
7. Oliver ER et al: Twin reversed arterial perfusion sequence: a new method of parabolic twin mass estimation correlated with pump twin compromise. *J Ultrasound Med.* 32(12):2115-23, 2013







(Left) TVUS in monozygotic twins shows marked early size discrepancy. The heart rate in fetus A was 59 BPM compared to 129 in fetus B and the embryo looked amorphous. (Right) Follow-up 3 weeks later in the same case showed a thin intertwin membrane  proving diamnionicity. The smaller embryo is now clearly abnormal with diffuse soft tissue edema . At this point, the diagnosis of TRAP could have been confirmed by Doppler of the umbilical artery. Flow into the embryo is pathognomonic.



(Left) Three weeks later (same case), fetus B demonstrates normal growth and anatomy with ossified cranium , normal brain structures for GA , and symmetric cardiac ventricles . (Right) The cotwin now shows typical TRAP morphology with absent cranial structures  and diffuse soft tissue edema . The normal twin is the pump for the abnormal one and is at risk of high-output cardiac failure. In this case, spontaneous demise of both twins occurred prior to scheduled consultation for RFA.



(Left) This acardiac twin demonstrates well-formed lower extremities and relatively normal external male genitalia. There is only 1 rudimentary upper extremity  and no cranial formation. (From DP: Placenta.) (Right) Autopsy arteriogram with injection into the umbilical artery shows relatively normal lower extremity vascular architecture , whereas superior to the umbilicus, there is just a tangle of abnormal mid-sized , and small  vessels. (From DP: Placenta.)

Conjoined Twins

KEY FACTS

TERMINOLOGY

- Fetal fusion of variable degree
- Nomenclature
 - Site of fusion + suffix "pagus"
 - Prefix "di" denotes separate parts associated with conglomerate structures

IMAGING

- Contiguous skin covering between fetuses
 - Variable presentation does not exclude diagnosis
- High incidence of congenital heart disease
- Fused umbilical cords common
- Polyhydramnios in 50%
- Imaging protocol
 - Fetal echocardiogram essential
 - 3D US reconstructions easier for parents to understand
 - Fetal MR helpful to assess degree of organ sharing

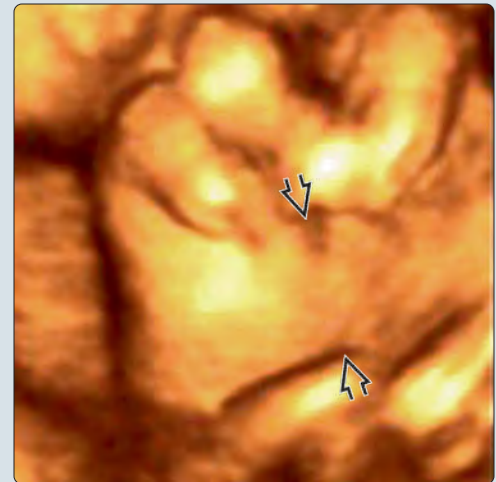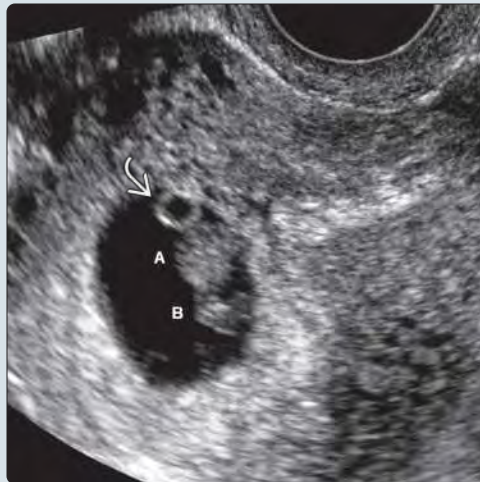
CLINICAL ISSUES

- Majority deliver preterm
 - 40% stillborn
 - 75% die within initial 24 hours of life
- Emergency separation is associated with very poor outcome
- Delayed separation much preferred
- Despite meticulous investigation, certain anatomy can only be discovered intraoperatively
- Huge ethical and legal dilemmas for parents and teams involved in care of conjoined twins
 - Even if twins separable, consider long-term morbidity from associated defects

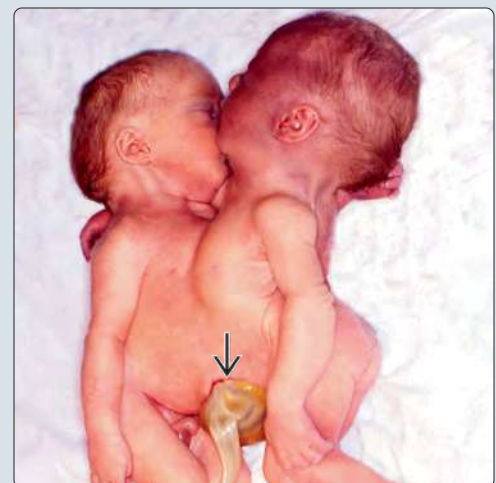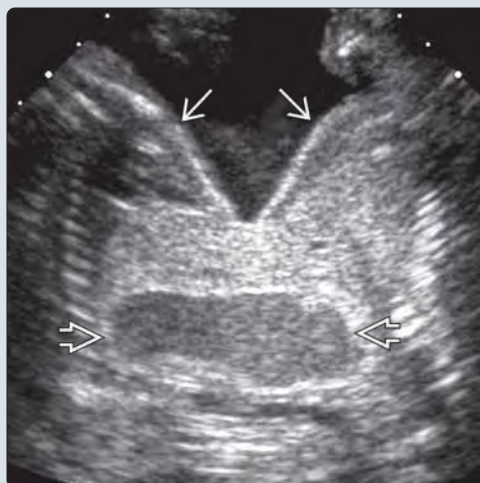
DIAGNOSTIC CHECKLIST

- Must be contiguous skin covering for diagnosis of conjoined twins

(Left) Transvaginal US shows 2 embryos (A, B) and a single yolk sac. The embryos were inseparable on prolonged inspection. This pregnancy ended in spontaneous abortion. **(Right)** 3D surface-rendered US demonstrates the skin continuity across the abdomens of this pair of omphalopagus conjoined twins. Monoamniotic twins may be very close to each other and appear to be hugging, but they will not have contiguous skin covering.



(Left) Longitudinal oblique transabdominal US in omphalopagus twins shows separate thoracic cavities, but a single, large, fluid-filled structure in the upper abdomen. This turned out to be a dilated, shared duodenum. These twins were successfully separated. **(Right)** Gross pathology shows thoracopagus conjoined twins. The fetuses face each other with their spines hyperextended. The chests and abdomens are fused with the cord inserted on a common omphalocele. A shared heart precluded separation.



TERMINOLOGY

Synonyms

- Siamese twins

Definitions

- Fetal fusion of variable degree
- Nomenclature
 - Site of fusion + suffix "pagus"
 - Prefix "di" denotes separate parts associated with conglomerate structures
 - **Dicephalus:** Conglomerate mass with 2 identifiable heads

IMAGING

General Features

- Best diagnostic clue
 - Contiguous skin covering between fetuses

Ultrasonographic Findings

- Grayscale ultrasound
 - Monochorionic twinning
 - Single placental mass
 - No intertwin membrane
 - ◻ Occasional reports of unusual variants with limited fusion in monochorionic diamniotic gestation
 - Fetuses inseparable, but relative position not always constant
 - Variable presentation possible if pliable fused tissues
 - Often hyperextension of cervical spines, unusual limb positioning
 - Fused umbilical cords common with 2-7 vessels
 - Polyhydramnios in 50%
 - Omphalopagus twins: 80% share liver
 - 30% incidence of congenital heart disease (CHD)
 - Thoracopagus twins: 90% share pericardium, 75% share heart
- Color Doppler
 - May be very helpful in craniopagus twins
 - Complete craniopagus: Shared brain substance, precludes separation
 - ◻ Vessels seen coursing between brains
 - Partial craniopagus: Brain separate, cranium shared
 - ◻ Separation can be attempted, but requires extensive reconstruction of cranial vault
 - Color Doppler very useful in evaluation of liver blood supply
 - Common portal vein precludes separation
- 3D
 - 3D US reconstructions easier for parents to understand
- Fetal echocardiography: Acoustic access is better in utero than post delivery
 - CHD is major prognostic indicator
 - Cardiac anomaly may drive decision for emergent separation
 - Ex utero intrapartum treatment procedure may be option for those requiring immediate separation
 - Series of 53 sets of conjoined twins categorized as
 - Separate hearts and pericardium (10)
 - Separate hearts with common pericardium (2)

- Fused atria, separated ventricles (2)
- Fused atria and ventricles (39)
- CHD in 88.6% (18.8% 1 fetus, 69.8% both)
 - High predominance of right-sided lesions
 - ◻ Pulmonary atresia or stenosis (35.7%), tricuspid atresia (11.9%), hypoplastic right ventricle (21.4%)

Imaging Recommendations

- Protocol advice
 - Use MR to clarify anomalies, as either fetus may have lethal anomaly in addition to being conjoined
 - If pregnancy continues, fetal MR essential for presurgical planning
 - Elucidates degree of organ sharing
 - ◻ T2WI excellent for brain/renal/chest detail
 - ◻ T1WI for additional bowel and liver information

DIFFERENTIAL DIAGNOSIS

Twin Reversed Arterial Perfusion

- Separate fetuses, 1 with absent or rudimentary cardiac structures
- Umbilical arterial flow is toward abnormal fetus

Monochorionic Monoamniotic Twins

- Fetuses in same sac, but with no contiguous skin covering

PATHOLOGY

General Features

- Embryology
 - Fissure theory
 - Incomplete cleavage embryonic disc after 13th day post conception
 - Fusion theory
 - Secondary fusion between initially separate embryonic discs
- Parasitic conjoined twins
 - Embryonic demise in 1 twin of conjoined pair
 - Residual body parts of dead twin perfused by survivor

Staging, Grading, & Classification

- Thoracopagus
 - Separate hearts and pericardium
 - Separate hearts, common pericardium
 - Fused atria, separate ventricles (no survivors from attempted separation)
 - Fused atria and ventricles (separation not attempted)
- Minimally conjoined omphalopagus twins (MCOT)
 - Subset of omphalopagus twins with bowel/bladder bridge
 - Fused peritoneal cavities via low abdominal wall defect
 - Fused distal small intestine with variable anorectal malformations
 - Patent urachus
- Craniopagus
 - Partial: No significant sharing of dural sinuses
 - Total: Shared dural venous sinuses

Conjoined Twins

Types of Union	Subclassification	Location of Fusion
Ventral	Cephalopagus	Top of head to umbilicus, may have 2 faces
	Thoracopagus	Upper thorax to umbilicus, heart ALWAYS involved (even if only single interatrial vessel)
	Omphalopagus	Umbilicus ± lower thorax but NEVER heart
	Ischiopagus	Umbilicus to common pelvis (2 sacrums, 2 pubic symphyses) often end to end with spines in straight line
Dorsal	Pygopagus	Sacrococcygeal, perineal ± spinal cord, usually 1 anus, 2 rectums
	Rachipagus	Above sacrum, may extend to occiput
	Craniopagus	Any part of skull EXCEPT face/foramen magnum
Lateral	Parapagus	Side by side, common pelvis, 1 or 2 sacrums, 1 symphysis pubis

Spencer R. Anatomic description of conjoined twins: a plea for standardized terminology. *J Pediatr Surg.* 31(7):941-4, 1996.

CLINICAL ISSUES

Presentation

- Can be diagnosed in 1st trimester

Demographics

- Epidemiology
 - 1:50,000 gestations but high loss rate → 1:250,000 live births
 - Craniopagus less common (1:2,500,000)
 - 70% female

Natural History & Prognosis

- Majority deliver preterm
 - 40% stillborn, 75% die within initial 24 hours of life
- MCOT often require emergency surgery due to ruptured abdominal wall defect/enterostomy requirement
- 2006: Series of 31 pairs seen at 1 center
 - 58% liveborn sets inseparable and died within weeks
 - 38% successful separation (long-term outcome not defined)
- 2009: Series of 22 sets seen at 1 center
 - 27% inseparable or refused
 - Overall, 73% attempted separation with surgical survival rate of 53%
- 2013: Series of 30 sets seen at 1 center
 - Overall, 70% attempted separation with surgical survival rate of 66.7%
 - 8 ischiopagus (7 separated, 11 surviving infants)
 - 9 thoracopagus twins (only 1 separable with 1 surviving infant, 1 pair not separated but survived)
 - 3 omphalopagus twins (3 separated, 5 surviving infants)
 - 1 craniopagus (1 separated, 1 surviving infant)
- Long-term morbidity from associated defects
 - Unequal sharing of limbs, incomplete pelvic girdle, need for perineal reconstruction
 - Vaginoplasty
 - Urethroplasty
 - Anoplasty
 - Incomplete chest wall or skull vault
 - Short bowel syndromes, biliary atresia/stenoses

Treatment

- Offer termination

- If pregnancy continues, plan delivery at tertiary center
- Cesarean section required, frequently needs vertical uterine incision
 - Increased immediate maternal morbidity
 - Increased risk in future pregnancies
- Not indication for early delivery
 - Morbidity and mortality increase with low birth weight
 - Problems of prematurity add to those of being conjoined
- Separation requires multidisciplinary team
 - Delayed separation much preferred
 - Emergent separation has much poorer outcome, only considered when
 - 1 twin with rudimentary heart/lethal anomaly or demise of 1 twin
 - If lethal anomaly, sacrificed twin may act as tissue donor for survivor

DIAGNOSTIC CHECKLIST

Consider

- Huge ethical and legal dilemmas for parents and teams involved in care of conjoined twins
- Despite meticulous investigation, certain anatomy can only be discovered intraoperatively
- Decision to proceed with pregnancy and attempted separation requires multidisciplinary team and extensive family counseling
- Emergency separation is associated with dismal outcome

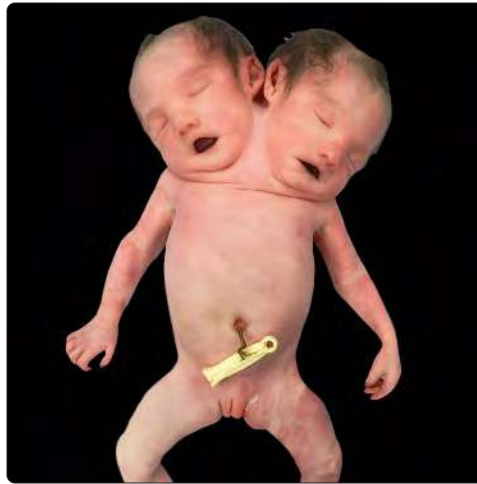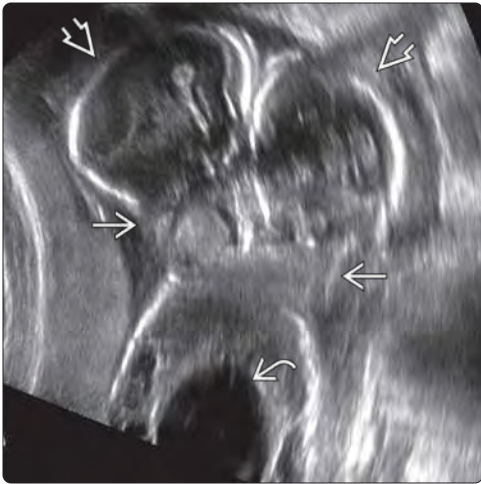
Image Interpretation Pearls

- Must be contiguous skin covering for diagnosis of conjoined twins

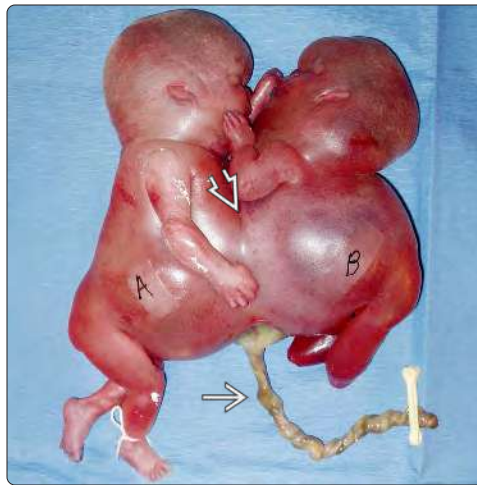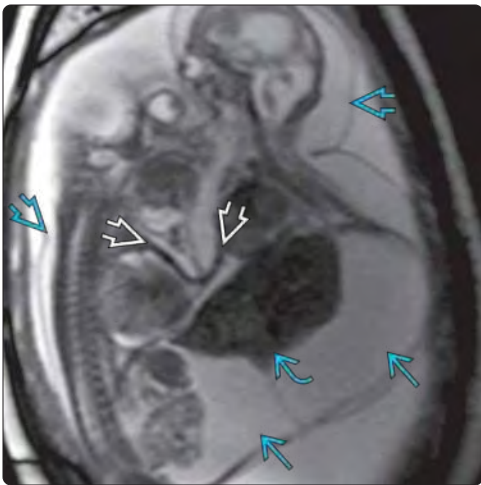SELECTED REFERENCES

1. Stahr N et al: In utero and postnatal imaging findings of parasitic conjoined twins (ischiopagus parasiticus tetrapus). *Pediatr Radiol.* 45(5):767-70, 2015
2. Burans C et al: 3-dimensional ultrasound assisted counseling for conjoined twins. *J Genet Couns.* 23(1):29-32, 2014
3. Wu Y et al: Fetal echocardiographic characteristics of fused heart in thoracopagus conjoined twins. *Echocardiography.* 31(7):E218-21, 2014
4. Lopes LM et al: Twenty-five years of fetal echocardiography in conjoined twins: lessons learned. *J Am Soc Echocardiogr.* 26(5):530-8, 2013
5. Tannuri AC et al: Conjoined twins: twenty years' experience at a reference center in Brazil. *Clinics (Sao Paulo).* 68(3):371-7, 2013
6. Wen X et al: Thoraco-omphalopagus conjoined twins: impact of ultrasound assessment on successful surgical separation. *Clin Imaging.* 37(1):138-42, 2013

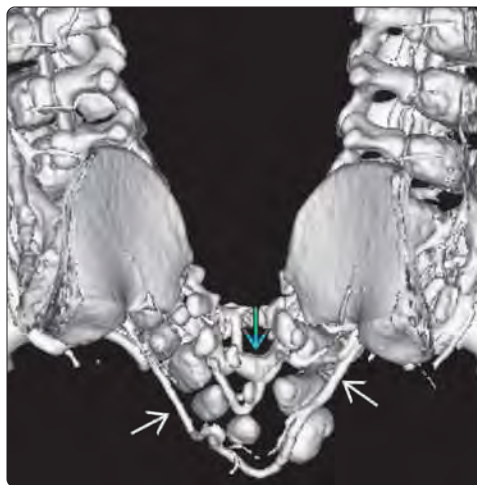
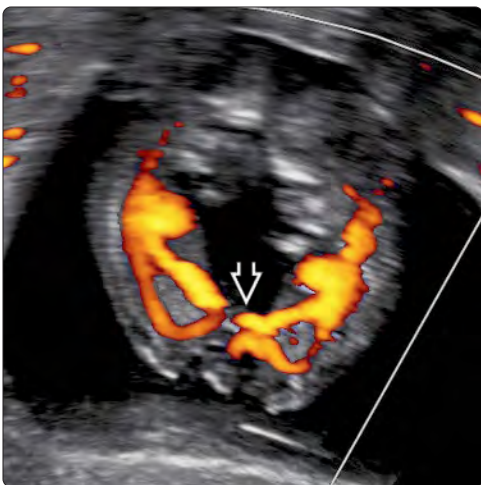Conjoined Twins



(Left) Coronal oblique US shows 2 heads and necks on a single torso. As is so often the case, there are multiple anomalies; in this instance, bladder outlet obstruction. This patient chose to terminate the pregnancy. (Right) Autopsy image shows a similar example of dicephalus conjoined twins. There are rare reports of this type of conjoined twins surviving into adulthood. (From DP: Placenta.)



(Left) Coronal T2WI in a set of omphalopagus conjoined twins shows hydrops (worse on the smaller one) with skin edema and ascites. There was a single shared liver with a single umbilical vein, which bypassed the liver, entered 1 heart, and then connected to the other heart by a large anomalous vessel. (Right) Autopsy image of the same case confirms the diffuse skin edema, omphalopagus conjoined twinning, and single umbilical cord.



(Left) Sagittal power Doppler US shows conjoined twins with a very narrow connecting bridge of tissue at the umbilical cord insertion site. These twins would have been excellent candidates for separation, but the pregnancy ended in spontaneous intrauterine demise within weeks of this scan. (Right) Longitudinal oblique CT reconstruction in liveborn pygopagus twins shows vascular and neural elements involved in the connecting tissue bridge but no bony fusion. These twins were successfully separated.

KEY FACTS

TERMINOLOGY

- 3 or more fetuses
 - Separate or shared chorionic sacs
 - Separate or shared amniotic sacs

IMAGING

- Establishment of chorionicity is critical
 - Determines management
- Measure nuchal translucency
 - Assumes greater importance in screening for aneuploidy
 - Maternal serum screening and cell-free fetal DNA limited in multifetal gestations
- Check placental cord insertion for velamentous cord, vasa previa
- Measure cervical length with endovaginal (EV) sonography
- Track growth and amniotic fluid
 - Use maximum vertical pocket for each fetus to track fluid distribution

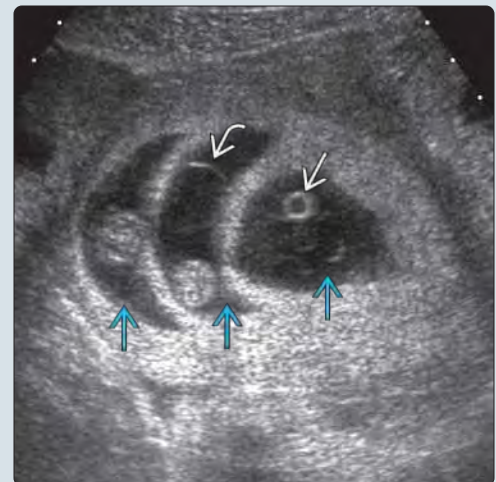
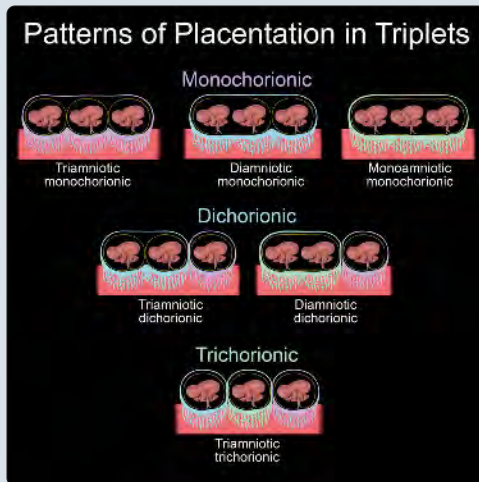
CLINICAL ISSUES

- Triplet and higher-order multiple births continuing to trend downward
 - ↓ in number of embryos transferred per IVF cycle
 - Only about 20% of triplets are spontaneously conceived
- Associated with significantly increased maternal and fetal complications
 - Hypertensive complications proportional to fetal number
 - 2nd-/3rd-trimester loss rate higher than for singletons or twins
 - 14-17% of triplets, 2-5% of twins

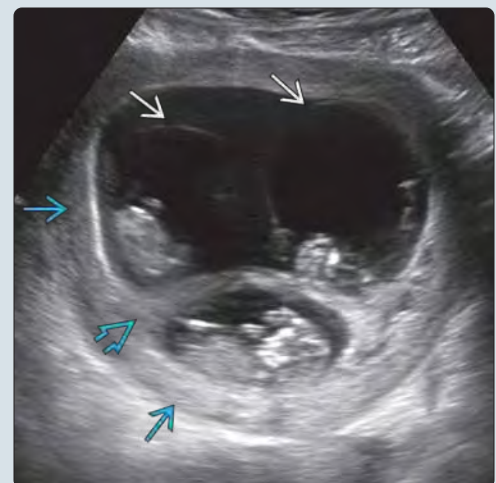
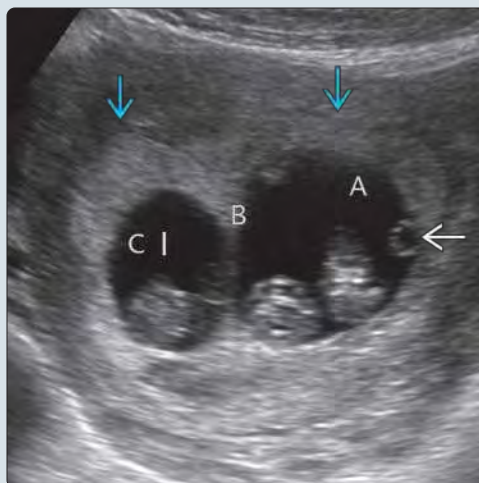
DIAGNOSTIC CHECKLIST

- Document chorionicity and amnionicity with EV sonography in 1st trimester
- Document fetal positions carefully
 - Vital if selective termination to be performed based on CVS results

(Left) Triplets may be monochorionic, dichorionic, or trichorionic, with any combinations of amniotic sacs. Monozygous triplets may be mono-, di-, or triamniotic. Dizygous triplets may be di- or trichorionic. Trizygous triplets must be trichorionic. Combinations of monozygous and polyzygous multiples are common. Multichorionic placentas may be separate or fused. (Right) TAUS shows 3 thick-walled sacs in trichorionic triplets. All 3 embryos were visible in real time. Note the yolk sac and amnion.



(Left) TAUS shows 2 thick-walled sacs indicating dichorionic triplets. With 1 yolk sac and no membrane there was concern that A and B were a monoamniotic pair. Vaginal US performed later in the study revealed a thin membrane proving diamnionicity. Final diagnosis was dichorionic, triamniotic triplets. (Right) TAUS shows 2 thick-walled sacs with a twin peak sign in dichorionic triplets. The fine, delicate amniotic membranes are barely visible in the anterior sac. These are dichorionic triamniotic triplets.



TERMINOLOGY

Definitions

- 3 or more fetuses
 - Separate or shared chorionic sacs
 - Separate or shared amniotic sacs

IMAGING

Ultrasonographic Findings

- 1st trimester
 - Variable number of chorionic sacs
 - Variable number of yolk sacs/amnions
 - Variable number of heart beats per sac
- 2nd trimester
 - Count number/location of placentas
 - Look for membrane thickness and presence of twin peak sign
 - Check fetal gender

Imaging Recommendations

- Best imaging tool
 - Endovaginal (EV) ultrasound in 1st trimester
- Protocol advice
 - **1st trimester**
 - Establishment of chorionicity is critical: Determines management
 - Measure heart rates (normal is > 120 beats per minute at 6 weeks)
 - Measure crown rump length
 - Document placental cord insertion sites
 - Measure nuchal translucency and assess visible anatomy
 - **2nd trimester**
 - Careful anomaly screen
 - Track growth
 - Measure amniotic fluid, ensure symmetric distribution around all fetuses
 - Assess for complications of monochorionic placentation
 - Twin-twin transfusion syndrome (TTTS)
 - Twin reversed arterial perfusion (TRAP)
 - Conjoined fetuses
 - Measure cervical length with EV sonography
 - Use Doppler to exclude vasa previa at same time as cervical length measured
 - **3rd trimester**
 - Track growth and amniotic fluid distribution

DIFFERENTIAL DIAGNOSIS

Twins With Perigestational Hemorrhage

- Extra sac will be subchorionic in location
- Perigestational hemorrhage often contains low-level internal echoes
- No yolk sac or embryo in sac created by bleed
- Resolves over time

PATHOLOGY

General Features

- Only about 20% of triplets are spontaneously conceived

- Delayed child bearing → increased maternal age, more use of assisted reproductive treatment (ART)
 - 1:3 chance of multiple gestation over age 45 yr
 - Majority of higher-order multiples result from ART
 - No more than 2 embryos should be implanted at a time (some authors advise 1 embryo per implantation attempt)
 - ART triplets more likely to be trichorionic than other combinations

CLINICAL ISSUES

Demographics

- Epidemiology
 - Peak incidence 193.5 per 100,000 in 1998, 153.4 per 100,000 live births by 2009
 - 2012 data revealed triplet and higher-order multiple births continuing to trend downward
 - ↓ in number of embryos transferred per IVF cycle
 - ↑ number of reduction procedures

Natural History & Prognosis

- Associated with significantly increased maternal and fetal complications
 - Risks increase with increasing number of fetuses
- Neonatal outcome depends on GA at delivery and birthweight
- Maternal complications
 - 1st-trimester bleeding, hyperemesis gravidarum
 - Ovarian hyperstimulation syndrome
 - Hypertensive complications proportional to fetal number
 - 6.5% for singletons, 12.7% for twins, 20% for triplets
 - Preeclampsia risk increased 2x or more with ART
 - 30% of women with triplets developed preeclampsia in 1 study
 - May have atypical presentation
 - Gestational diabetes, anemia, malnutrition
 - Cesarean delivery required in most higher order multiples
 - Vaginal birth possible in concordantly grown triplets with cephalic presentations
- Fetal complications
 - Spontaneous reduction (embryonic demise) occurs in up to 10% in 1st trimester
 - 2nd-/3rd-trimester loss rate higher than for singletons or twins
 - 14-17% of triplets, 2-5% of twins
 - Discordant growth: Greater risk unequal placental sharing with increasing number of fetuses
 - Risk of TTTS/TRAP sequence/conjoined twinning in monochorionic pairs
 - Preterm delivery risk is significant
 - ~ 90% of triplets deliver preterm
 - Virtually 100% of quadruplets and above deliver prematurely
 - Increased need for newborn intensive care unit admission

Treatment

- 1st-trimester nuchal translucency assumes greater importance in screening for aneuploidy

Outcomes in High-Order Multiples

	Gestational Age at Delivery	Perinatal Mortality	Fetal Demise	Neonatal Demise	Mechanical Ventilation
Triplets	32.1 weeks	9.6%	2.9%	6.9%	15.8%
Quadruplets	30.4 weeks	12.1%	4.4%	8.0%	21.7%
Quintuplets	28.8 weeks	29.3%	8.8%	22.5%	19.8%

Adapted from Gibson R. Birthweight, gestational age, and perinatal mortality and morbidity in triplets, quadruplets, and quintuplets. Presented at Society of Maternal Fetal Medicine, 2003.

- Maternal serum screening and cell-free fetal DNA limited in multifetal gestations
 - Risk is pregnancy specific rather than fetus specific
- Chorionic villus sampling (CVS) preferred over amniocentesis for invasive prenatal diagnosis
 - Lower loss rate, results available earlier, information helpful in planning fetal reduction
- **Selective multifetal pregnancy reduction**
 - Typically performed at 10-13 weeks; should be done only by someone highly skilled in technique
 - Risk of procedure involves potential loss of entire pregnancy
 - Consider CVS prior to reduction to eliminate risk of 2nd-trimester aneuploidy diagnosis in remaining fetuses
 - In trichorionic (TC) triplets, reduction from 3 to 2 decreases risk of severe preterm birth (PTB)
 - Increased GA at birth by ~ 3 weeks compared to ongoing triplets
 - In dichorionic triamniotic triplets miscarriage rate 8.9%, severe PTB rate 33.3% with no intervention
 - Miscarriage 14.5%, severe PTB 5.5% with reduction of monochorionic pair
 - Miscarriage 8.8%, severe PTB 11.8% with reduction of one of monochorionic pair
 - Miscarriage 23.5%, severe PTB 17.6% with reduction of fetus with separate placenta
 - Reduction of triplets to a singleton is controversial
 - TC triplets reduced to twins delivered earlier (36.6 vs. 37.9 weeks), had lower mean birth weights (2364g vs. 2748g) compared to those reduced to singletons
 - Pregnancy loss < 24 weeks and PTB rates similar between those reduced to twins and singletons
 - Gestational diabetes, gestational hypertension similar as well
- **Selective termination** specifically targets abnormal fetus for reduction; usually performed later than selective reduction
 - Fetuses discordant for anomaly
 - 1st-trimester TVUS can identify certain malformations (e.g., anencephaly)
 - 13-14 week reduction allows for selective termination of abnormal fetuses
 - No statistical difference in outcome between 10 and 13 week reductions
 - Abnormal karyotype; requires precise mapping of gestational sacs at time of CVS
- Loss rate 11.1% for selective fetal termination in higher-order multiples compared to 2.4% in twins
- Clinical monitoring for evidence of preterm labor, preeclampsia, diabetes
- Monthly scans for growth and fluid
 - More frequent follow-up with monochorionicity, anomalies, discordant growth or fluid, cervical shortening
 - Measurement of cervical length controversial in asymptomatic women with multifetal gestations
 - American College of Obstetricians and Gynecologists guidelines state prophylactic cerclage should not be used
 - Neither cerclage nor progesterone proven to prolong pregnancy in multiples

DIAGNOSTIC CHECKLIST

Consider

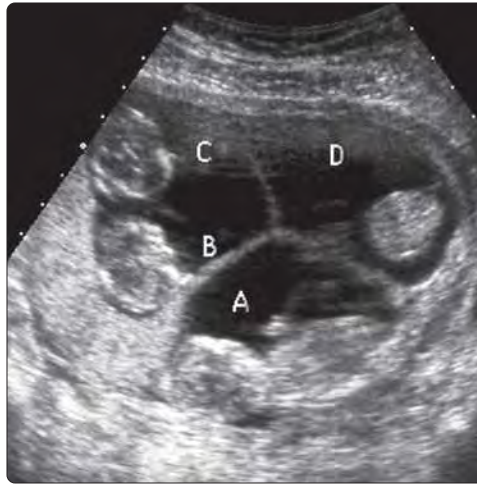
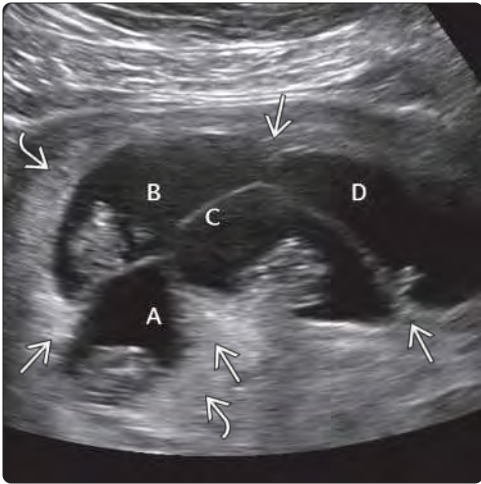
- Perinatal complication rate increases with increasing plurality
- Care is directed at aggressively and proactively preventing preterm delivery

Reporting Tips

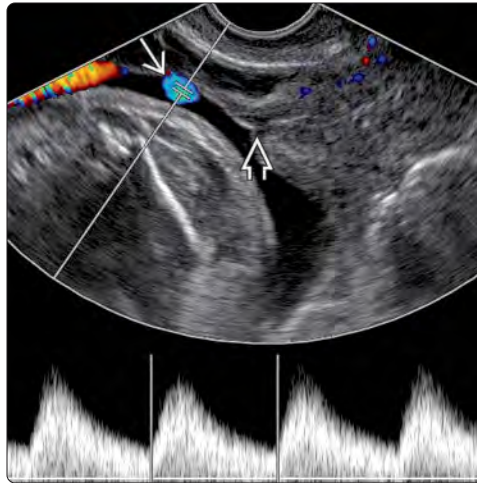
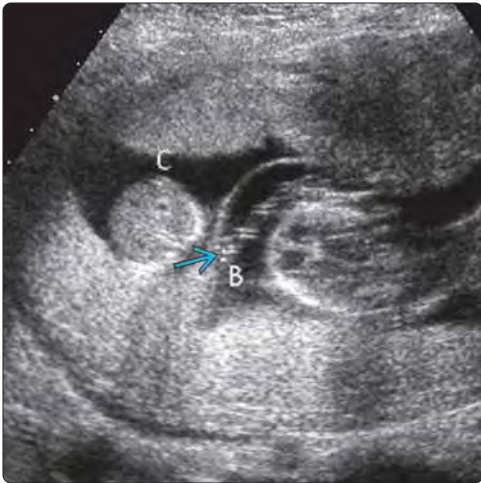
- Document chorionicity and amnionicity with EV sonography in 1st trimester
- Check placental cord insertion sites for velamentous cord, vasa previa
- Document fetal positions carefully
 - Vital for planned reduction of aneuploid fetuses
 - Essential to track individual fetal growth
- Use maximum vertical pocket for each fetus to track fluid distribution

SELECTED REFERENCES

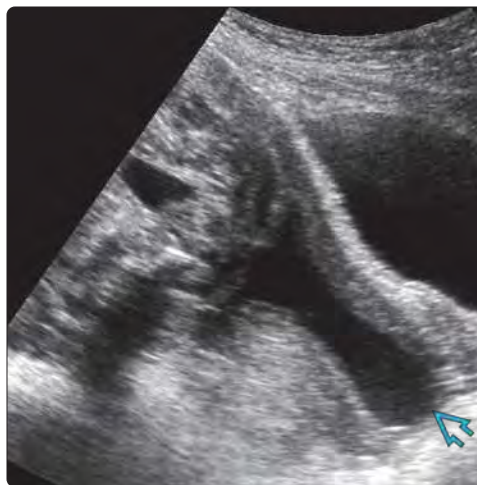
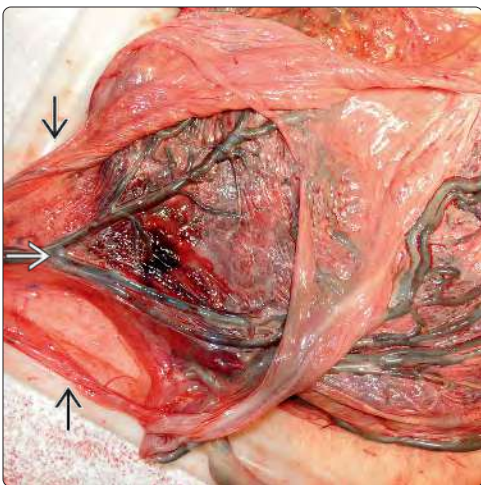
1. Fennessy KM et al: Triplet pregnancy: is the mode of conception related to perinatal outcomes? *Twin Res Hum Genet.* 18(3):321-7, 2015
2. Morlando M et al: Dichorionic triplet pregnancies: risk of miscarriage and severe preterm delivery with fetal reduction versus expectant management. Outcomes of a cohort study and systematic review. *BJOG.* 122(8):1053-60, 2015
3. American College of Obstetricians and Gynecologists et al: ACOG Practice Bulletin No. 144: Multifetal gestations: twin, triplet, and higher-order multifetal pregnancies. *Obstet Gynecol.* 123(5):1118-32, 2014
4. Dutta A et al: Evidence-based triplet delivery: avoiding rocks and hard places. *J Obstet Gynaecol.* 34(5):439-41, 2014
5. Haas J et al: Pregnancy outcome of early multifetal pregnancy reduction: triplets to twins versus triplets to singletons. *Reprod Biomed Online.* 29(6):717-21, 2014
6. Rafael TJ et al: Cervical stitch (cerclage) for preventing preterm birth in multiple pregnancy. *Cochrane Database Syst Rev.* 9:CD009166, 2014
7. van de Mheen L et al: Prediction of preterm birth in multiple pregnancies: development of a multivariable model including cervical length measurement at 16 to 21 weeks' gestation. *J Obstet Gynaecol Can.* 36(4):309-19, 2014



(Left) TAUS shows 4 gestational sacs with 2 placentas, but there are 4 twin peaks. Additional images confirmed quadrachorionic quadruplets. (Right) TAUS shows trichorionic triamniotic quadruplets. There is no membrane between B and C, the monoamniotic pair. At 28 weeks, fetuses B and C died for unknown reasons; cord entanglement had not been seen. Quads A and D were delivered by C-section at 36 weeks.



(Left) Ultrasound in trichorionic triplets shows velamentous insertion of triplet B's cord. High-order multiples are at risk for poor placentation and abnormal placental cord insertion. Velamentous cord insertion increases risk for fetal growth restriction. (Right) TVUS shows vasa previa. This is another complication of velamentous cord insertion. The unprotected umbilical artery runs in the membranes and is within 2 cm of the internal os.



(Left) Gross pathology shows velamentous cord insertion into the membranes of one sac. Velamentous cord and vasa previa are more common in multiple gestations. Evaluation of the placental cord insertion site is now part of the AIUM guidelines. (Right) TA US shows cervical dilation with funneling membranes to the level of the external os at 18 weeks. Rescue cerclage was placed but failed with delivery of the triplets at 22 weeks. Recent studies indicate that cerclage is potentially harmful in multiple gestations and should be avoided.

KEY FACTS

TERMINOLOGY

- Variant of monochorionic diamniotic twinning in which one abnormal fetus is entirely encompassed within body of other twin

IMAGING

- Well-circumscribed, mixed fluid and solid components
 - Fetus suspended within sac containing fluid or sebaceous material
- 80% of reported cases in retroperitoneal area
- Internal calcifications common
 - Presence of vertebral bodies confirms diagnosis

TOP DIFFERENTIAL DIAGNOSES

- Teratoma
- Meconium pseudocyst
- Other solid fetal masses

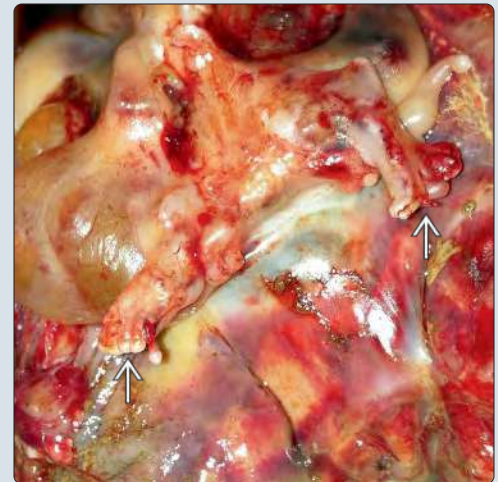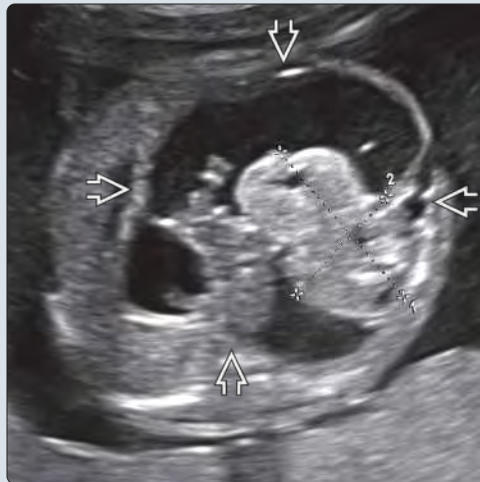
CLINICAL ISSUES

- Not indication for preterm delivery
- Large masses may cause sufficient abdominal distension that cesarean delivery is required to prevent abdominal dystocia
- Some secrete β -hCG or AFP
- If diagnosis suspected prenatally
 - Counsel parents that postnatal imaging confirmation will be required
 - Final diagnosis may not be made until surgical resection
- Prognosis
 - Excision is curative
 - Fetus-in-fetu carries no risk of malignancy

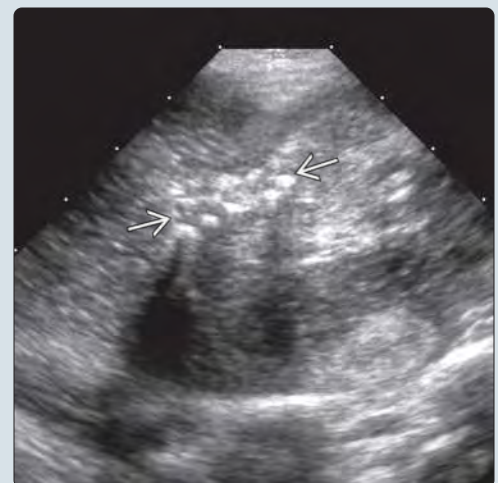
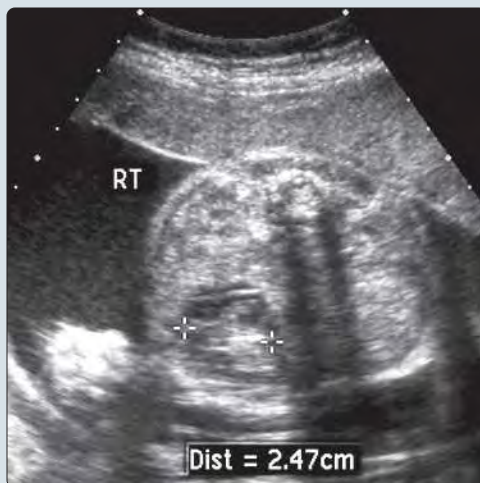DIAGNOSTIC CHECKLIST

- Diagnosis is based on presence of neural axis

(Left) Axial ultrasound through the fetal abdomen at 23 weeks shows a part cystic, part solid mass with calipers on one of the solid portions. It was urgently resected at birth in an attempt to treat respiratory compromise, but the infant expired from pulmonary hypoplasia attributed to thoracic compression by this very large mass. **(Right)** Zoomed photo of the operative specimen shows well-formed feet on the surface of the mass.



(Left) Transverse ultrasound shows a part cystic, part solid mass (calipers) in the right abdomen in this female fetus. The mass was distinct from the urinary tract and did not appear associated with the bowel. This mass grew rapidly over the next several weeks. **(Right)** Ultrasound performed on day 1 of life in the same case shows vertebral bodies in a lumbosacral configuration within the mass. Surgical exploration was performed without further imaging.



TERMINOLOGY**Definitions**

- Variant of monozygotic diamniotic twinning in which abnormal fetus is encompassed within body of other twin

IMAGING**General Features**

- Best diagnostic clue
 - Complex intrafetal mass
- Morphology
 - 88% single (as many as 11 described in 1 case)

Ultrasonographic Findings

- Well-circumscribed mass with mixed fluid and solid components
 - Enclosed within distinct sac
- 80% of reported cases in retroperitoneum
 - Also described in skull, scrotum, sacrum, mouth, and adrenal gland
- Internal calcifications common
 - Presence of vertebral bodies confirms diagnosis

Imaging Recommendations

- Protocol advice
 - If calcific elements seen in mass, use multiple scan planes to assess morphology
 - Extremity bones, vertebral column
 - Careful assessment for organ of origin (MR may be helpful)
 - Use color Doppler for vascularity
 - Fetus-in-fetu not reported to be highly vascular
 - Helps differentiate from fetal neoplasms, which are often hypervascular

DIFFERENTIAL DIAGNOSIS**Teratoma**

- Overlap in findings
- No vertebral segmentation or organogenesis
- More common in females

Meconium Pseudocyst

- Associated with bowel obstruction
 - Dilated, hyperperistaltic bowel loops
- Intraperitoneal free fluid ± calcification if perforation

Other Solid Fetal Masses

- Hemangioendothelioma
- Mesoblastic nephroma
- Adrenal hematoma/neuroblastoma

PATHOLOGY**General Features**

- Asymmetric monozygotic twinning with attachment of smaller twin inside normal co-twin

Gross Pathologic & Surgical Features

- Historically regarded as well-differentiated teratomas

- Some pathologists require vertebral axis for diagnosis; others feel presence of structures with advanced maturation (eyes, skin, colon, central nervous tissue) is sufficient
 - All cases have been anencephalic
 - No functional heart
 - Commonly identified: Lower limbs, central nervous tissue, gastrointestinal tract
 - Appearance similar to acardiac twin in twin reversed arterial perfusion
- Fetus suspended within sac containing fluid or sebaceous material

CLINICAL ISSUES**Presentation**

- Most common signs/symptoms
 - Complex abdominal mass
- Other signs/symptoms
 - May not be diagnosed prenatally

Demographics

- Gender
 - Male predominance (teratomas more common in females)
- Epidemiology
 - Rare entity: < 100 cases published prior to 2005 review
 - Reported incidence of 1:500,000

Natural History & Prognosis

- Fetus-in-fetu carries no risk of malignancy
- Retroperitoneal mass may cause hydronephrosis, prevent descent of testes
- Large masses → abdominal distension → risk for abdominal dystocia
- Excision is curative

Treatment





- Monitor growth
- Not indication for preterm delivery
- If diagnosis suspected prenatally
 - Counsel parents that postnatal imaging confirmation will be required
 - Final diagnosis may not be made until surgical resection
- Some secrete β -hCG or AFP
 - Case reports of elevated maternal serum AFP
 - If elevated in child, confirm return to zero after resection

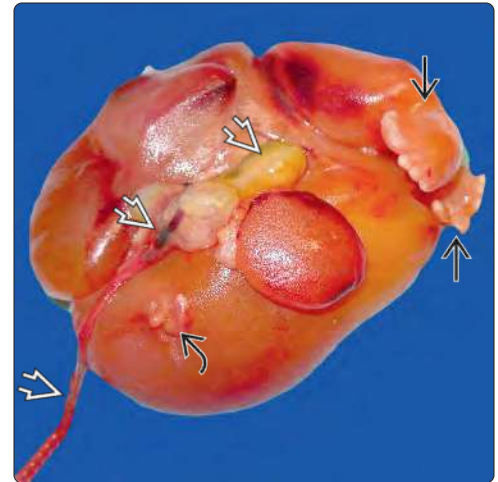
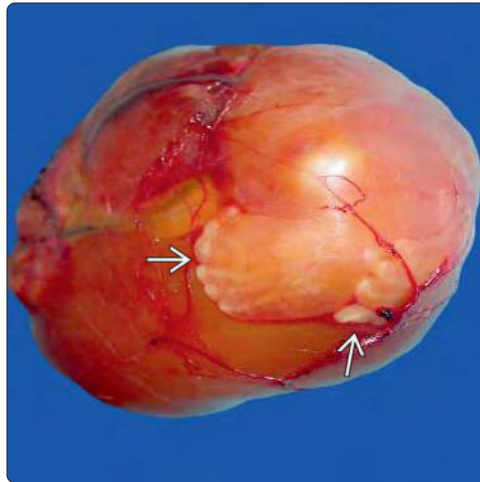
DIAGNOSTIC CHECKLIST**Image Interpretation Pearls**




- Diagnosis is based on presence of neural axis

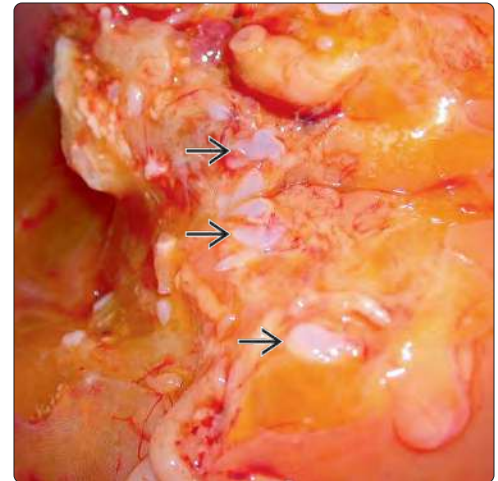
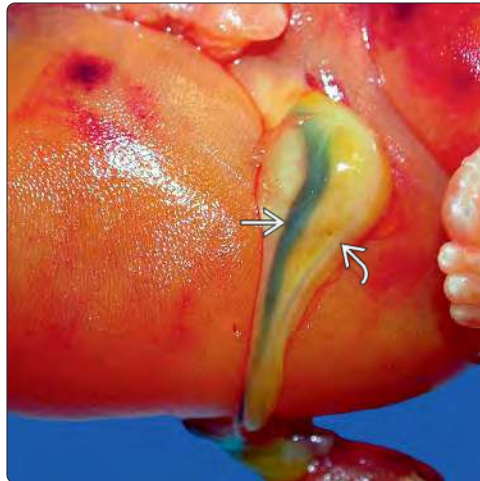SELECTED REFERENCES


1. McNamara HC et al: A review of the mechanisms and evidence for typical and atypical twinning. *Am J Obstet Gynecol.* 214(2):172-91, 2015
2. Goyal RB et al: Fetus in fetu: report of two cases. *APSP J Case Rep.* 5(3):28, 2014
3. Ji Y et al: Fetus in fetu: two case reports and literature review. *BMC Pediatr.* 14:88, 2014
4. Sathe PA et al: Fetus in fetu: an institutional experience. *Pediatr Dev Pathol.* 17(4):243-9, 2014
5. Has R et al: Prenatal sonographic diagnosis of fetus in fetu. *J Ultrasound Med.* 32(12):2212-4, 2013

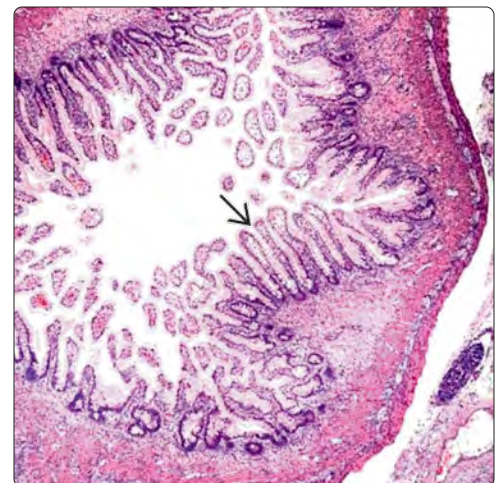
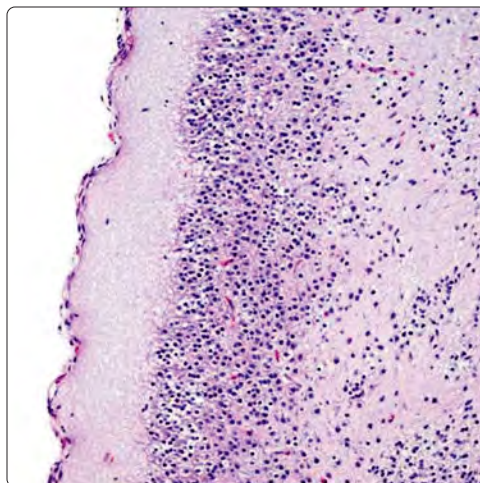
(Left) Gross pathology of the resected specimen in continuation of the same case shows a well-circumscribed, membrane-bound mass. Two feet  can be seen through the translucent membrane. **(Right)** Gross pathology with the membrane removed shows the lower extremities , an upper extremity bud , and the umbilical cord . Note the resemblance to a twin reversed arterial perfusion sequence fetus (another form of asymmetric monochorionic twinning).

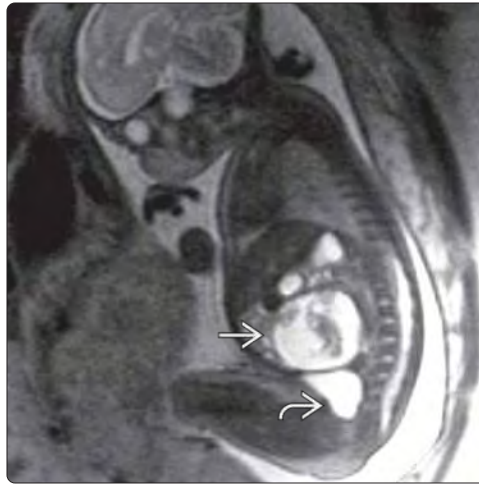
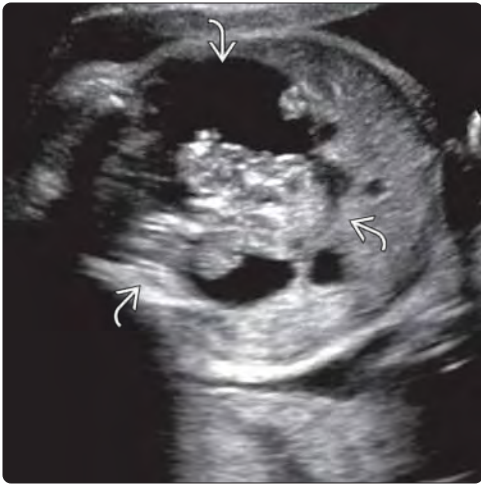
(Left) Gross pathology shows a 2-vessel cord with the umbilical vein  and a single umbilical artery . This is not uncommon in reported cases of fetus-in-fetu. **(Right)** Dissection of the mass confirms the presence of numerous vertebral bodies . Many authors consider the presence of a neural axis an essential characteristic of fetus-in-fetu and a key point of differentiation from a mature teratoma.

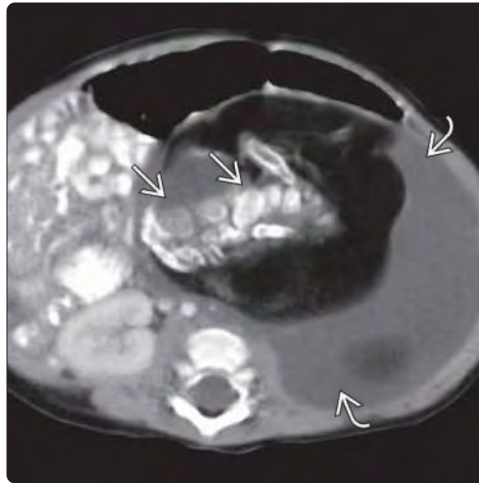
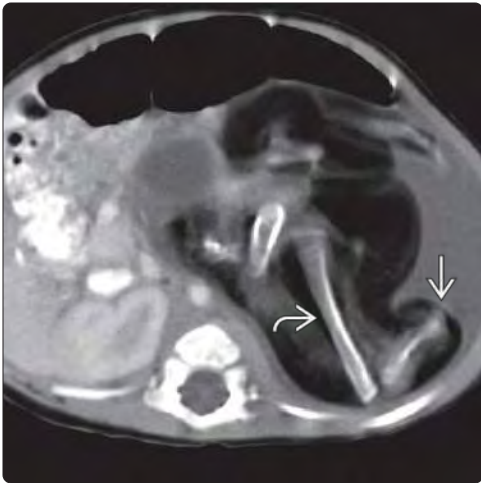


(Left) Histologic evaluation of sections of the various components of this mass revealed the presence of differentiated brain, respiratory, bowel, and mesenchymal tissues. This is an example of brain tissue. **(Right)** Hematoxylin & eosin stain shows well-developed gastrointestinal tract tissues. Note the villi  lining the lumen.

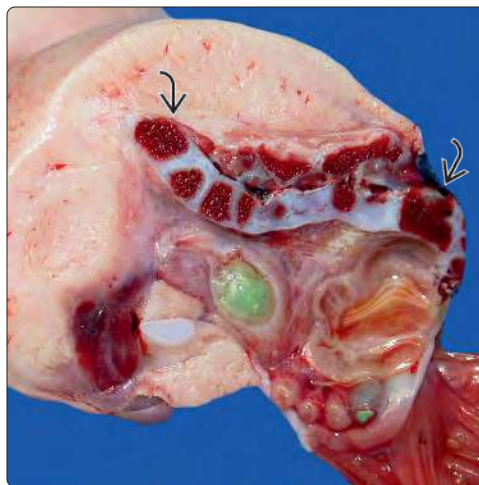
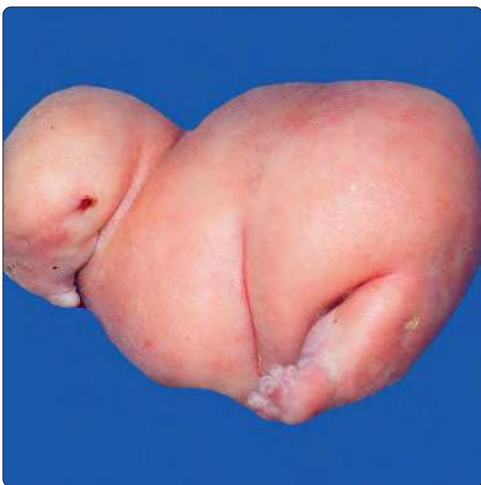



(Left) Transverse ultrasound shows a complex intraabdominal mass. Fetus-in-fetu often presents in this way as the fetus is suspended within the fluid-filled amniotic sac. (Right) Sagittal T2WI MR in the same case shows the mixed signal mass superior to the bladder and separate from the liver. Other images from the study showed normal kidneys and adrenal glands.



(Left) Axial CECT in a neonate who had a palpable abdominal mass shows a retroperitoneal fetus-in-fetu with a foot and a femur beautifully outlined by fat. (Right) Axial CECT in the same case shows clear evidence of neural axis development with several vertebral bodies in a lumbosacral-coccygeal configuration. This confirms the diagnosis of fetus-in-fetu rather than teratoma. Note that the fetus is within a fluid-filled sac.

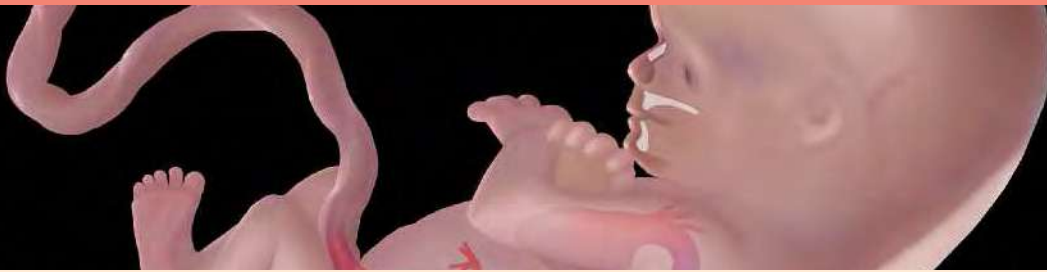

(Left) Gross pathology of the resected specimen shows a well-developed skin covering. Again there are no recognizable upper extremities or cranial structures. (Right) Gross pathology after the specimen was opened confirms the presence of a well-developed spinal column.

This page intentionally left blank

SECTION 12

Aneuploidy



Approach to Genetic Screening	884
Trisomy 21	890
Trisomy 18	896
Trisomy 13	902
Turner Syndrome (45,X)	908
Triploidy	912

Background Information & Current Guidelines

Chromosome abnormalities occur in approximately 1/160 live births. Trisomy 21 (T21), trisomy 18 (T18), & trisomy 13 (T13) account for the majority. The incidence for live born neonates with T21 is reported as 1:700 while the first-trimester prevalence is 1:300. The prevalence of aneuploidy is highest in the first trimester since many are lost or terminated subsequently. Women who are advanced maternal age (AMA), defined as ≥ 35 years at the time of delivery, are at higher risk for trisomies.

Current guidelines for screening for aneuploidy utilize ultrasound, noninvasive genetic screening, & invasive diagnostic testing techniques. The American College of Obstetrics & Gynecology (ACOG) recommends offering routine first-trimester screening for aneuploidy at 11-13 6/7 weeks of gestation for all women. Increased nuchal translucency (NT) measurement is the hallmark finding for aneuploidy at this gestational age. Maternal serum screening for major aneuploidy includes cell-free fetal DNA testing, first-trimester screen & second-trimester quadruple screen. Diagnostic testing is invasive & includes chorionic villus sampling (CVS) & amniocentesis.

Strategies For Aneuploidy Screening

Cell-Free Fetal DNA (cfDNA) Test

cfDNA in maternal blood can be used to screen for T21, T18, T13, & sex chromosome aneuploidy. The test can be reliably performed as early as 10-11 weeks gestation & the list of potential genetic defects detectable by this technique is growing. In singleton pregnancies, cfDNA can detect > 99% of cases of fetal T21 with a false-positive rate (FPR) of 0.1%. Positive predictive values (PPV) for cfDNA are better than for conventional maternal serum screening tests. Detection rates for trisomy 18 & 13 are lower at 96% & 91%, respectively, with a higher FPR of 0.26%. Approximately 90% of Turner (45,X) & 93% of other sex chromosome anomalies are detectable with FPR of 0.37. Interestingly, nondiagnostic results from "low fetal fraction" increases the likelihood of aneuploidy (invasive testing should be considered in these cases). Current screening strategies for cfDNA fall into two categories; first, routine screening of whole population (regardless of risk), & second, contingent screening based on results of screening by another method (maternal serum screening, ultrasound screening, combined tests).

First-Trimester Screening (11- to 14-Week Scan)

The measurable fluid behind the fetal neck is the nuchal translucency (NT). The NT is compared with the crown rump length & maternal age. Other ultrasound markers for aneuploidy include absent nasal bone, & abnormal ductus venosus & tricuspid valve flow. Incorporating maternal serum testing of two biochemical markers, pregnancy-associated plasma protein-A (PAPP-A) & human chorionic gonadotropin (hCG), improves first-trimester detection rates of T21 from 70% to 87% (5% FPR) for NT evaluation alone & to detection rate of 95% (3% FPR) if NT & other markers are evaluated.

Second-Trimester Screening

The maternal serum quadruple test measures α -fetoprotein (AFP), estriol, inhibin, & hCG & has a detection rate of 80% for T21 (5% FPR). The role of the anatomy scan (typically at 18-20 weeks) is to look for structural abnormalities & markers of aneuploidy. With a few exceptions, most major anatomic anomalies are associated with aneuploidy. The presence of more than one minor marker is also associated with

aneuploidy. cfDNA testing can be considered as further screening in the second trimester.

Combined First- & Second-Trimester Screening

With integrated screening, the patient is given a single risk assessment at the completion of the first- & second-trimester tests. T21 detection rates of 94-96% have been reported. However, integrated screening is not popular because patients are not told their first-trimester results & cannot have early invasive testing.

With stepwise sequential screening, the first screen results are shared with the patient, & if screen positive, she is offered invasive testing. If screen negative, she proceeds with second-trimester testing. With contingent sequential screening, only women with intermediate increased risk go on to second-trimester screening. Women who screen negative have only a second-trimester ultrasound, & those who screen positive are offered invasive genetic testing. Detection rates for T21 using sequential screening are 91-92% (5% FPR).

Imaging Techniques & Normal Anatomy

First-trimester screening is performed by certified sonographers.

- For the NT, magnified view of fetal profile is obtained; neck is not overly flexed or extended, & calipers are placed so that only fluid is measured
- Nasal bone (NB) is deemed present or absent on a midsagittal profile view; ultrasound beam is perpendicular to nose so that tip of nose, nasal bone, & frontal bone are all seen separately
- Ductus venosus is small vessel with turbulent flow seen on sagittal view of lower chest & upper abdomen; normal flow is consistently toward heart, & retrograde flow is considered abnormal
- Tricuspid flow assessment with Doppler possible to rule out tricuspid valve regurgitation
- Additional anatomy survey can be performed at this time, a& up to 2/3 major anomalies are detectable at time of NT screening; anatomic survey includes visualization of normal falx with "butterfly choroid," facial profile, heart, cord insertion site, stomach, bladder, & extremities; in addition, number of umbilical cord vessels & placental cord insertion site can be seen well

Second-trimester screening

- Most structural anomalies & minor markers are seen on standard second-trimester views

Approach

How are likelihood ratios (LR) used?

- When marker seen, a priori risk for aneuploidy for that patient is multiplied by LR to determine a new risk; with exception of nuchal fold thickening & absent nasal bone, single isolated marker rarely significantly increases risk in low-risk patient
- Isolated very "low-risk" markers, such as choroid plexus cyst & intracardiac echogenic focus, can be ignored if patient is otherwise low risk for aneuploidy

What is risk of invasive genetic testing?

- Genetic amniocentesis & CVS carry procedure-related loss rates of 1/300-500

What about women with multiple gestations?

- Serum testing is not accurate, so most are offered ultrasound screening or invasive testing

Maternal Age & Aneuploidy Risk

Maternal Age at Term	Risk for Trisomy 21	Risk for Any Chromosome Abnormality
20	1/1,480	1/525
25	1/1,340	1/475
30	1/940	1/384
35	1/353	1/178
37	1/199	1/122
39	1/111	1/80
40	1/85	1/62
42	1/54	1/38
45	1/35	1/18

Data from the American College of Obstetrics and Gynecologists (ACOG).

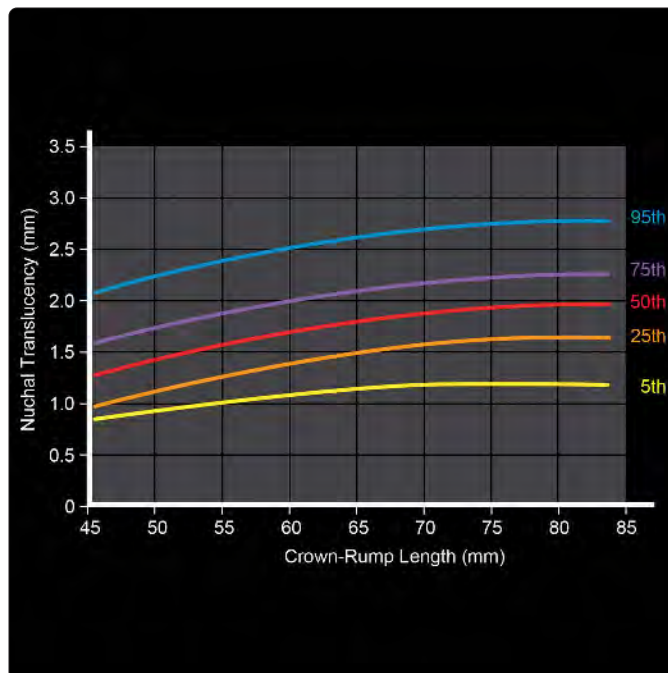
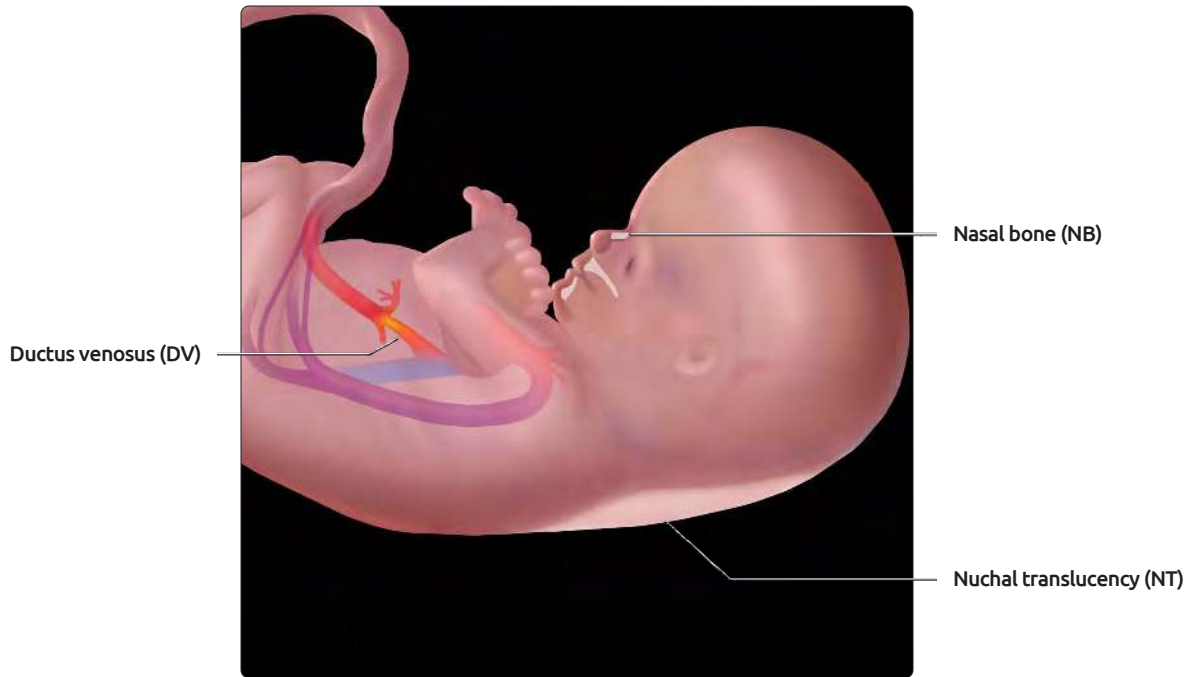
Serum Results & Aneuploidy

Screening Protein	Trisomy 21	Trisomy 18	Trisomy 13	Turner Syndrome (45,X)
PAPP-A*	↓	↓	↓	↓
hCG*	↑	↓	↓	Mild ↑
AFP	↓	↓	↑	↓
hCG	↑	↓	Normal	↓ or ↑ if hydrops
Estriol	↓	↓	Normal	↓
Inhibin A	↑	↓	↑	↓ or ↑ if hydrops

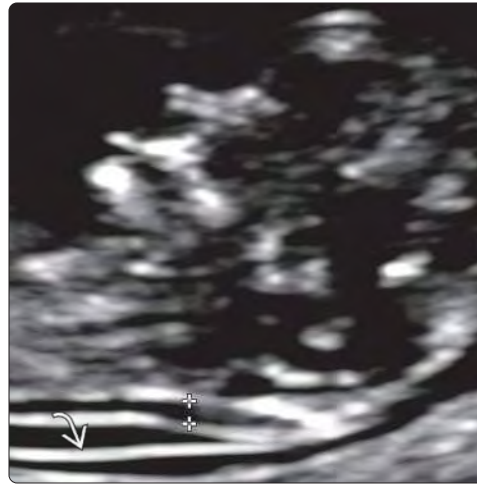
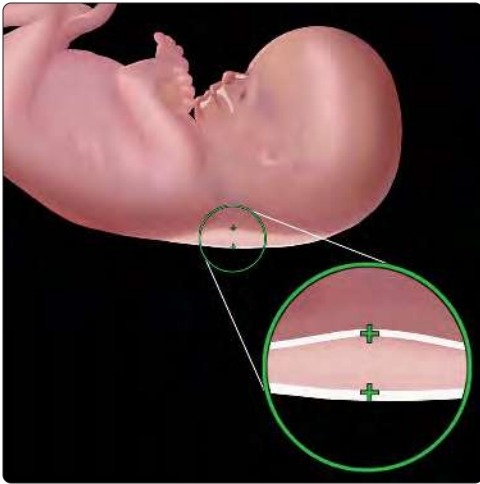
*1st-trimester screening protein.

Anomalies, Markers, & Aneuploidy

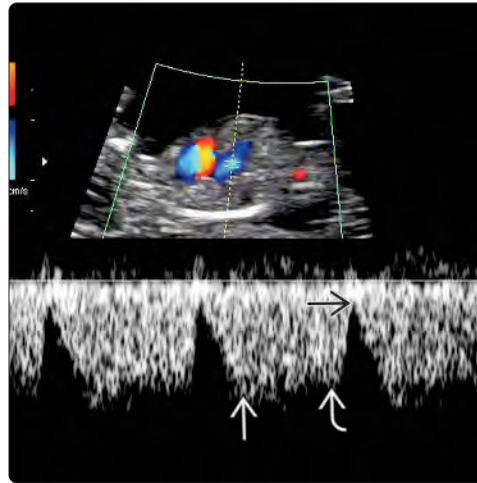
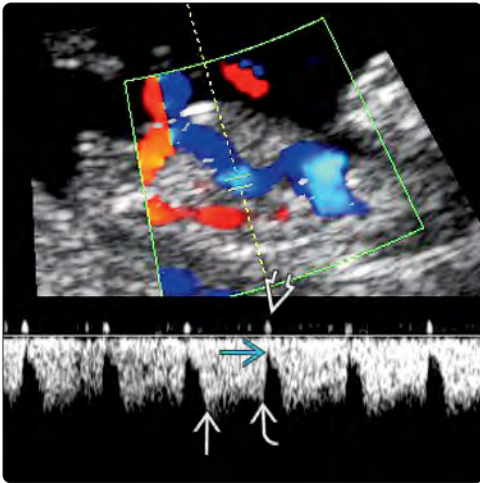
	Incidence	Likelihood Ratio (LR) or % With Aneuploidy	Most Common Aneuploidy
Isolated Markers			
↑ nuchal fold ≥ 6 mm		11-18.6 LR	T21
Small or absent nasal bone	0.5-1.2% (ethnic variability)	23.3-83 LR	T21
Echogenic bowel	0.4-1.8%	5.5-6.7 LR	T21
Short humerus	5%	2.5-5.8 LR	T21
Short femur	5%	1.2-2.2 LR	T21
Pelviectasis	0.6-4.5%	1.5-1.6 LR	T21
Intracardiac echogenic focus	4-7%	no ↑ LR if low-risk screen results	T21
Choroid plexus cyst	1%	no ↑ LR if low-risk screen results	T18
Single umbilical artery	1%	no ↑ LR if low-risk screen results	T18
Anomalies			
Cystic hygroma	1/6,000	50-75%	Turner > T21 > T18 > T13
Holoprosencephaly	1/16,000	40-60%	T13 > T18
Cardiac defect	7-9/1,000	5-30%	T21, T18, T13, abnormal 22, 8, 9
Atrioventricular septal defect	5% of all cardiac defects	40-70%	T21
Omphalocele	1/5,800	30-40%	T18 > T13
Diaphragmatic hernia	1/3,500-4,000	20-25%	T18, T13, T21, Turner
Duodenal atresia	1/10,000	20-30%	T21
Bladder outlet obstruction	1-2/1,000	20-25%	T13, T18
Mild ventriculomegaly	7-15/1,000	5%	T21 > T18, T13



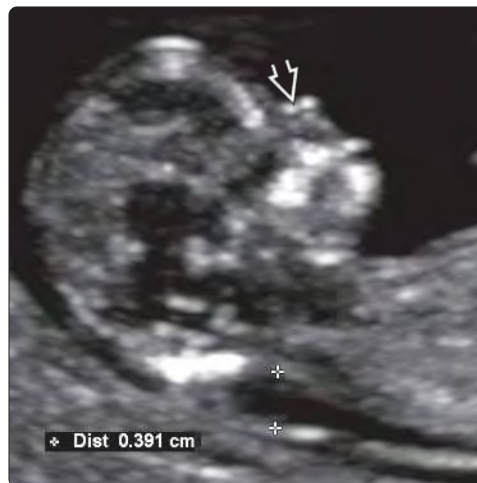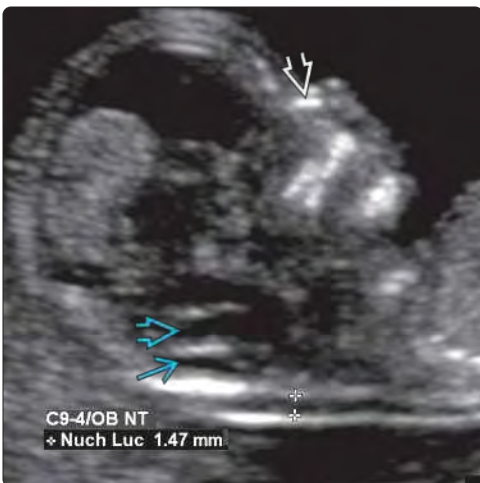
(Top) Between 11 & 14 weeks, screening for aneuploidy involves assessing the appearance of the NT, NB, & DV waveform. The NT should be carefully measured & compared with the crown rump length. The NB is either present or absent, & the flow direction within the DV should be consistently antegrade, toward the heart. Early anatomic survey can also be performed at this time. **(Bottom)** NT measurements are compared with fetal crown-rump length. Measurements greater than the 95th percentile are considered abnormal. (Used with permission from Nicolaides KH et al. *The 11- to 14-week scan: The diagnosis of fetal abnormalities from the Diploma in Fetal Medicine series, 1999.*)






(Left) Accurate NT measurement involves correct placement of calipers. The caliper cross-hatches are placed so that only the fluid is measured. NT measurements are compared with crown rump length & maternal serum screen results. (Right) A normal NT is correctly measured here (calipers). The unfused amnion can be seen separate from the fetal skin & should not be mistaken for fetal skin. In addition, the image is adequately magnified to include only the fetal head, neck, & upper chest.

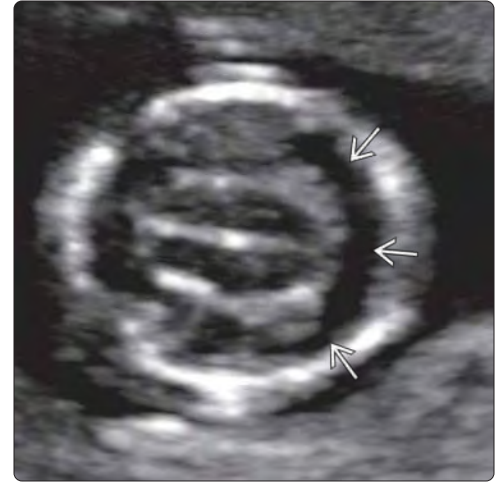
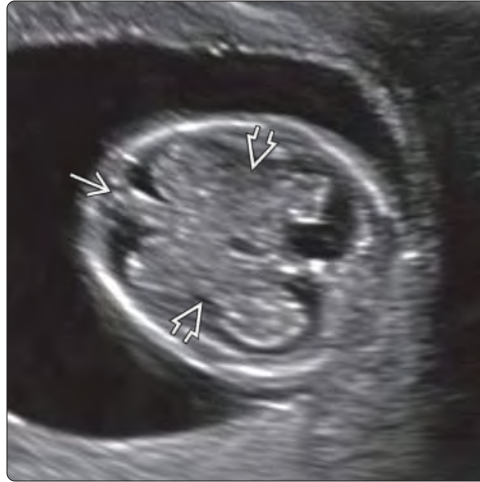





(Left) The DV waveform is triphasic with systolic (S) peaks, diastolic (D), & atrial (A) peaks. The DV flow is abnormal if the A peak is retrograde, away from the heart. The A peak here is normal, but there is an additional small retrograde peak secondary to inclusion of flow in the inferior vena cava. This is a common normal finding. (Right) By increasing the pulsed Doppler sweep speed, the DV waveform is "widened" & the S, D, & A components can be better seen.

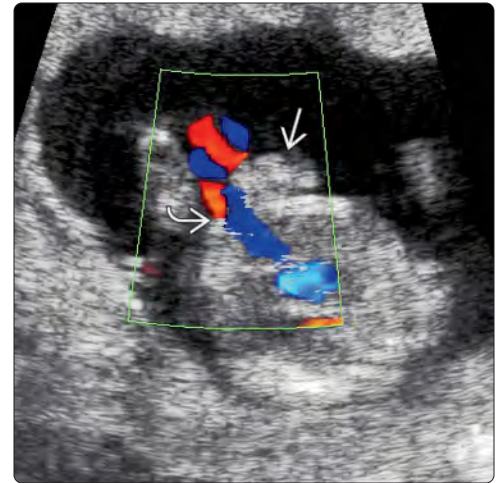
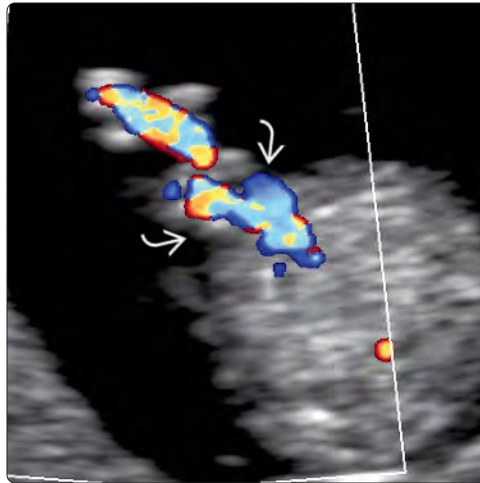





(Left) Normal NT (1.47 mm) & nasal bone (NB) is seen in a 12-week, 5-day fetus. An appropriately high-frequency probe (C9-4) has been used. The normal internal transluency (IT) of the 4th ventricle & future cisterna magna is also seen, suggesting a lower risk for spina bifida. (Right) In this fetus, the NT is increased (3.91 mm) & the nasal bone is absent. NT > 3 mm is always abnormal. Chorionic villus sampling (CVS) results were trisomy 18.

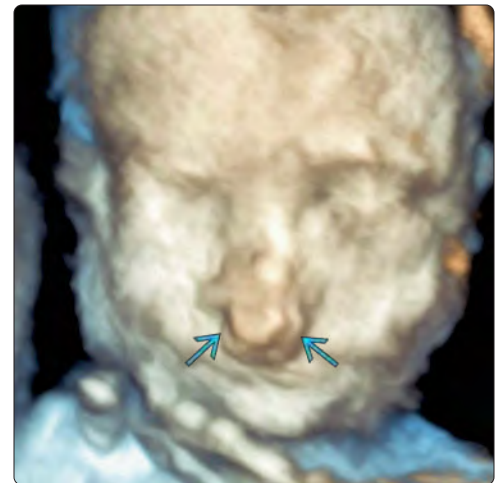
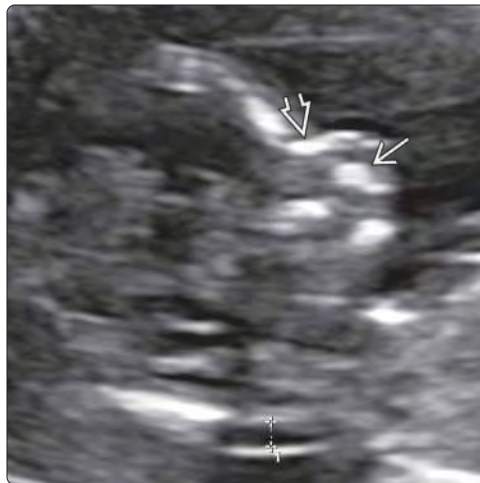
(Left) Anatomy scan at the time of NT screening shows normal falx  & choroid plexus  anatomy. The butterfly sign has been used to describe this normal view. **(Right)** In this 13-week fetus, the falx is absent & there is fusion of the ventricles anteriorly . Findings are classic for holoprosencephaly, a hallmark anomaly seen in trisomy 13. CVS confirmed the diagnosis of trisomy 13.

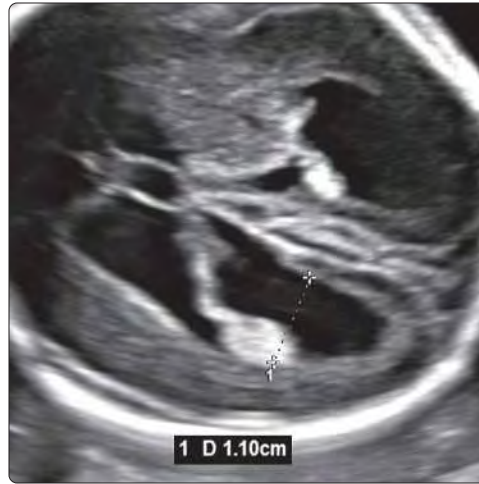
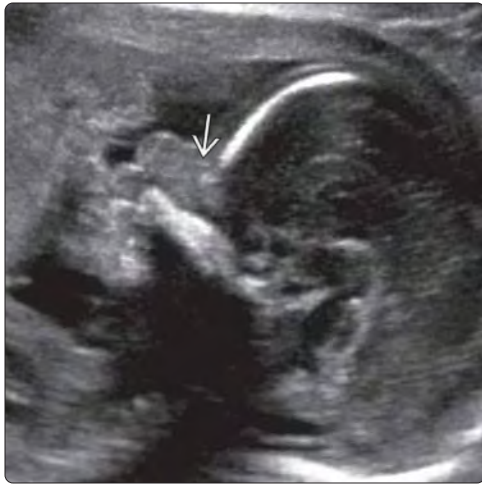

(Left) A normal umbilical cord insertion site  on the abdomen is seen at the time of NT screening. **(Right)** In this fetus with gastroschisis, diagnosed at 13 weeks, the cord inserts normally , but there is extracorporeal bowel  to the right of the cord insertion site. Physiologic bowel herniation occurs at the cord base & resolves by 12 weeks; therefore, the diagnosis of gastroschisis can be made at 13 weeks.

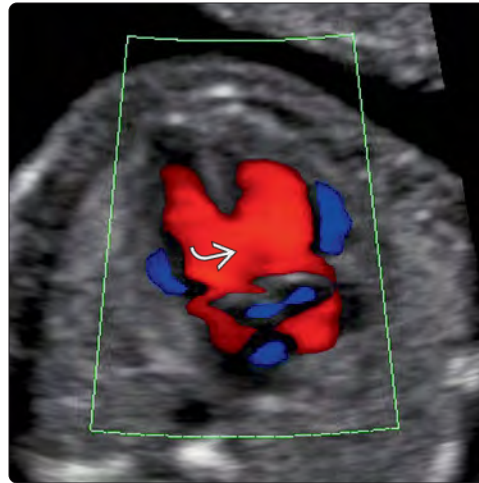
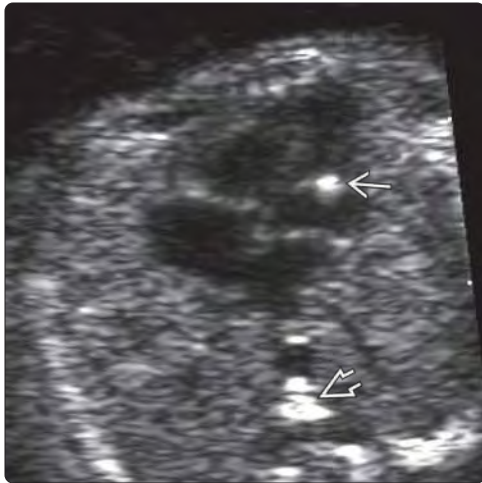


(Left) At the time of NT screening, an abnormal profile was noted because of a premaxillary protrusion of bone  caudal to the normal nasal bone . The presence of anteriorly displaced bony palate is usually from bilateral cleft lip & palate. The diagnosis was made at this time. **(Right)** First trimester diagnosis was confirmed at 20 weeks. 3D US of the fetal face shows the bilateral cleft lip defect  & the premaxillary protrusion of the anterior palate.

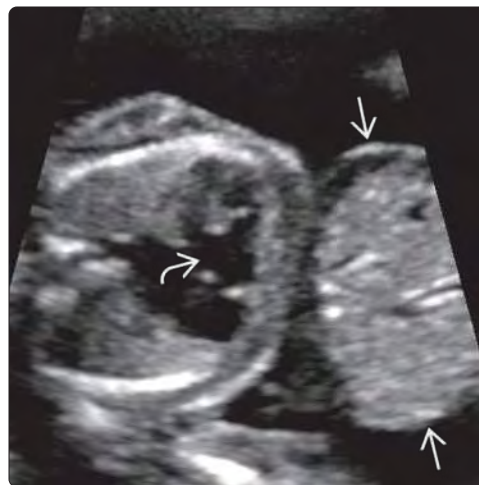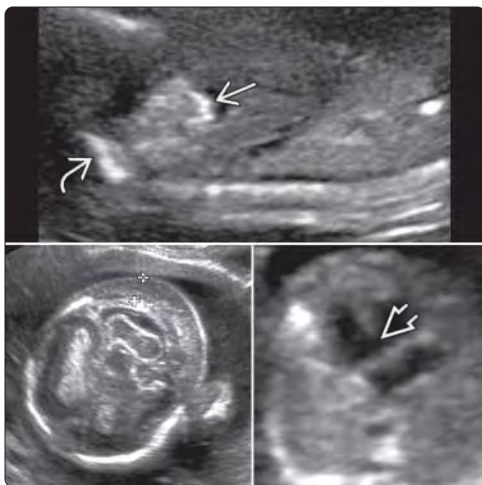




(Left) Absent or hypoplastic nasal bone \Rightarrow , as seen in this fetus at 21 weeks, is a strong marker for aneuploidy both in the 1st & the 2nd trimester. Amniocentesis results in this case were 1q21.1 duplication. (Right) This fetus with trisomy 21 has mild lateral ventriculomegaly (MILVD), measured here at 11 mm. MILVD is a finding associated with aneuploidy as well as early obstructive hydrocephalus, infection, & other CNS anomalies. Fetal MR can help differentiate between some diagnoses.



(Left) Typical appearance of an echogenic cardiac focus (ECF) \Rightarrow is demonstrated here in an otherwise normal fetus. The ECF is as bright as bone \Rightarrow . Consider maternal serum testing for risk assessment. No further follow-up or testing is necessary if the patient is low risk. ECF is not associated with cardiac defects in low-risk patients. (Right) This fetus with trisomy 21 has atrioventricular septal defect \Rightarrow , an anomaly strongly associated with aneuploidy, particularly trisomy 21.



(Left) Several findings for trisomy 21 are seen in this early 2nd-trimester scan. The bowel \Rightarrow is hyperechoic (as bright as bone \Rightarrow). The nuchal fold (calipers) is increased, & there is a small ventricular septal defect \Rightarrow . (Right) In this fetus with trisomy 18, a liver-containing omphalocele \Rightarrow & atrioventricular septal defect \Rightarrow are seen. Fetuses with trisomy 18 typically have multiple severe anomalies.

KEY FACTS

IMAGING

- 1st-trimester findings (11- to 14-week scan)
 - ↑ NT: ↑ fluid behind neck on midsagittal view
 - Absent nasal bone
 - Abnormal ductus venosus and tricuspid flow
 - Other anomalies may be seen
- 2nd-trimester minor markers (15-22 weeks)
 - ↑ nuchal fold thickness (≥ 6 mm)
 - Absent or small nasal bone
 - Short femur length/short humerus length
 - Echogenic bowel
 - Intracardiac echogenic focus
 - Renal pelvis dilatation
 - Mild lateral ventriculomegaly
- Hallmark anomalies associated with T21
 - Atrioventricular septal defect
 - Esophageal atresia
 - Duodenal atresia

TOP DIFFERENTIAL DIAGNOSES



- Turner syndrome
- Trisomy 18
- Trisomy 13

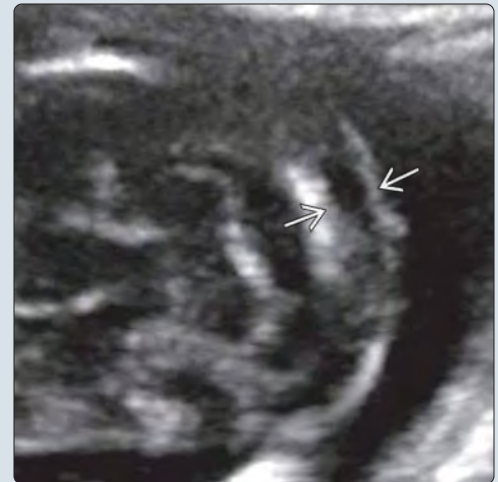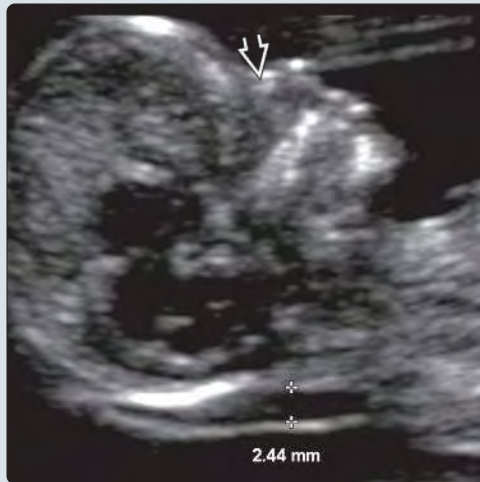CLINICAL ISSUES




- 35% of T21 born to women ≥ 35 years
- 1:2,000 risk at 20 years vs. 1:100 risk at 40 years

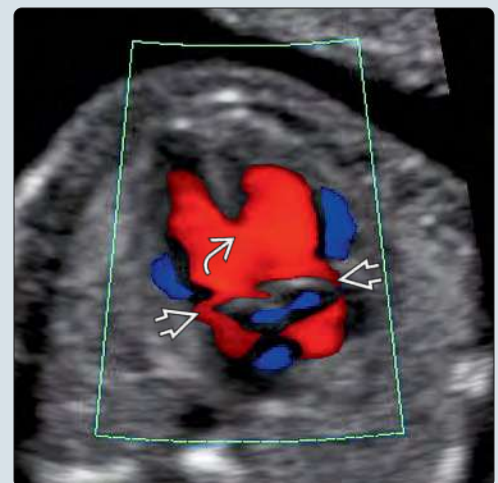
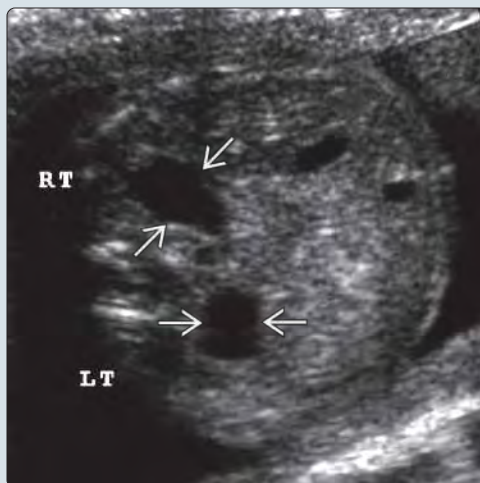
DIAGNOSTIC CHECKLIST

- Cell-free fetal DNA is best screening test
 - cfDNA detects 99.2% (0.1% false-positive rate) in high-risk population
 - Currently not routine for low-risk patients
- NT + other ultrasound markers + maternal serum markers detects 95% (3-5% false-positive rate)
- Use likelihood ratios for 2nd-trimester markers
- Chorionic villus sampling and amniocentesis remain only true diagnostic tests

(Left) In this 12-week fetus, the nuchal translucency (calipers) is greater than expected for the crown rump length. A nasal bone is present . Maternal serum screen results were also suspicious for T21 and amniocentesis in the 2nd trimester was performed, diagnostic for T21. The pregnancy was continued. **(Right)** Increased NT in the 1st trimester often evolves into increased nuchal fold  in the 2nd trimester. Both findings are from abnormal lymphatics and skin associated with T21.



(Left) Bilateral renal pelvis dilation  is seen in this 2nd-trimester fetus with T21. This finding is considered both a marker for aneuploidy and potential progressive hydronephrosis. **(Right)** In another fetus with T21, color Doppler 4-chamber view of the heart shows a large ventricular septal defect  and mitral and tricuspid valves positioned at the same level , typical findings of atrioventricular septal defect (AVSD). Up to 1/2 of the fetuses with AVSD have aneuploidy; most common diagnosis is T21.



TERMINOLOGY**Abbreviations**

- Trisomy 21 (T21)

Synonyms

- Down syndrome

Definitions

- **Likelihood ratios (LR)**
 - **Positive LR:** ↑ risk of T21 compared with pretest risk due to presence of finding
 - Absent nasal bone = 23x ↑ risk than a priori risk
 - **Negative LR:** ↓ risk of T21 compared with pretest risk secondary to absence of finding
 - Normal nasal bone = 50% less risk than a priori risk
- Markers for aneuploidy are not anomalies
 - Most occur in normal fetuses

IMAGING**General Features**

- Best diagnostic clue
 - ↑ nuchal translucency (NT) in late 1st trimester
 - ± other markers and anomalies
 - Multiple markers for T21 in 2nd trimester
 - Major anomalies associated with T21

Ultrasonographic Findings

- **Findings at time of NT evaluation (11- to 14-week scan)**
 - ↑ NT: ↑ fluid behind neck on midsagittal view
 - Absent nasal bone (NB) on midsagittal face view
 - Must see fetal skin separate from NB
 - Head cannot be overly extended
 - Box-like palate confirms sagittal view
 - Abnormal ductus venosus flow (DV)
 - Reversal of a-wave in DV
 - Sample on sagittal view of abdomen
 - Abnormal tricuspid flow (TF)
 - Tricuspid regurgitation by Doppler evaluation
 - Additional anomalies detectable
- **2nd-trimester markers (15-22 weeks)**
 - ↑ nuchal fold thickness (≥ 6 mm)
 - Measure on routine posterior fossa image
 - Skull outer table to skin/amniotic fluid interface
 - Overly coronal views cause false-positive
 - Absent or hypoplastic NB and midface hypoplasia
 - Median nasal bone at 20 weeks 5-7 mm
 - Normative data for different ethnic populations reported
 - Look for flat face + ↑ prenasal soft tissue
 - Short femur length (FL), short humerus length (HL)
 - Definition: FL or HL < expected compared to biparietal diameter (BPD), not gestational age
 - Expected FL = 0.90 (BPD) - 9.3
 - Expected HL = 0.84 (BPD) - 7.9
 - FL or HL considered short if measured:expected ratio is ≤ 0.91 for FL, ≤ 0.90 for HL
 - Short HL more sensitive marker than short FL
 - Echogenic bowel (hyperechoic bowel)
 - Bowel echogenicity ≥ bone considered abnormal

- Focal echogenic bowel more worrisome than diffuse
- High-frequency probes falsely ↑ bowel echogenicity
 - Use < 5 MHz transducer
 - Turn down gain so only bone and bowel seen
- Associated with other complications of pregnancy
 - Infection, cystic fibrosis, placental insufficiency, intraamniotic bleed
 - Bowel anomaly (atresias, ischemia, rupture)
- Intracardiac echogenic focus (IEF)
 - Bright dot ≥ bone in ventricle of heart
 - Left = right, might be multiple
 - Probably from microcalcification of papillary muscle
 - Ethnic variability reported
 - 10-30% of normal Asian fetuses have IEF
 - 7% of African American; 8% of Middle Eastern
- Mild renal pelvis dilation (pelviectasis)
 - ≥ 4 mm at anatomy scan considered abnormal
 - M:F = 2:1
 - Follow-up to rule out progressive distention/obstruction
- Mild ventriculomegaly (10-12 mm)
 - Normal lateral ventricle (LV) is < 10 mm at atria
 - Follow-up to rule out progressive hydrocephalus
- Other markers (less reliable data about associations)
 - 5th finger clinodactyly (tip of finger curves inward)
 - Hypoplastic midphalanx
 - Sandal gap foot
 - Gap between 1st and 2nd toes
 - Chorionic separation
 - Unfused amnion and chorion after 16 weeks
- Markers not associated with T21
 - Choroid plexus cyst (hallmark for T18)
 - Single umbilical artery
- **Major anomalies associated with T21**
 - Cardiac defects (25-50%)
 - Atrioventricular septal defect
 - Ventricular septal defect
 - Tetralogy of Fallot
 - Other valvular and complex cardiac defects
 - Gastrointestinal anomalies (10%)
 - Duodenal atresia
 - Esophageal atresia
 - Omphalocele (more common with T18)
 - Central nervous system anomalies (4-8%)
 - Moderate to severe ventriculomegaly
 - Holoprosencephaly (more common with T13)
- Hepatosplenomegaly suggests leukemia, with transient abnormal myelopoiesis being most common subtype
 - Often self-limited with excellent prognosis

Imaging Recommendations

- Best imaging tool
 - NT assessment in 1st trimester
 - Look for additional markers and anomalies
 - 2nd-trimester anatomy sonogram
 - ≥ 1 finding seen in 50-70% of T21 fetuses
- Protocol advice
 - Correlate ultrasound findings with maternal a priori risk
 - Recommend genetic counseling when markers seen

T21 2nd Trimester Markers

Marker	Incidence	Likelihood Ratio (LR)	Other Considerations
Small or absent nasal bone	0.5-1.2%	23-83	Ethnic variability
↑ nuchal fold ≥ 6 mm (15-20 weeks)	Not reported in source	11.0-18.6	> 99% specificity for aneuploidy, 40-50% sensitivity
Echogenic bowel	0.4-1.8%	5.5-6.7	Other associations: Cystic fibrosis, fetal growth restriction, infection, GI obstruction, intraamniotic bleed
Short humerus	5%	2.5-5.8	Consider follow-up for growth in 3rd trimester
Short femur	5%	1.2-2.2	Consider follow-up for growth in 3rd trimester
Pelviectasis	0.6-4.5%	1.5-1.6	Follow-up at 32 weeks (look for progression)
Intracardiac echogenic focus	4-7%	No significant ↑ LR if low-risk screen results	No follow-up or echocardiography if low-risk screen results

Reddy UM et al: Fetal imaging: executive summary of a joint Eunice Kennedy Shriver National Institute of Child Health and Human Development, Society for Maternal-Fetal Medicine, American Institute of Ultrasound in Medicine, American College of Obstetricians and Gynecologists, American College of Radiology, Society for Pediatric Radiology, and Society of Radiologists in Ultrasound Fetal Imaging Workshop. *J Ultrasound Med.* 33(5):745-57, 2014.

DIFFERENTIAL DIAGNOSIS

Turner Syndrome (45,X)

- Very large NT in 1st trimester
- Cystic hygroma is hallmark finding
 - Fluid collection behind neck with septations
 - Can be seen at any time in pregnancy
 - Associated with hydrops
- Associated cardiac and renal anomalies

Trisomy 18

- Rarely with isolated markers
 - Choroid plexus cyst is hallmark marker
- Multiple major anomalies
 - Cardiac, extremities, omphalocele
- Fetal growth restriction

Trisomy 13

- Rarely with isolated markers
- Holoprosencephaly is hallmark finding

PATHOLOGY

General Features

- Genetics
 - Autosomal trisomy of all or part of chromosome 21
 - 5% caused by translocation, 1% mosaic

CLINICAL ISSUES

Presentation

- Most common signs/symptoms
 - Abnormal ultrasound
 - Abnormal cell-free fetal DNA (cfDNA) results
 - Abnormal 1st-trimester maternal serum test
 - ↑ human chorionic gonadotropin (hCG)
 - ↓ pregnancy-associated plasma protein-A (PAPP-A)
 - Abnormal 2nd-trimester maternal serum test
 - ↓ α-fetoprotein (AFP)
 - ↑ hCG protein
 - ↓ estriol

- ↑ inhibin A protein

Demographics

- Age
 - 35% of T21 born to women ≥ 35 years
- Epidemiology
 - 40-50% termination rates (regional differences)
 - Live birth rate: 1:700 (USA), 1:1,000 (Europe)
 - 1st-trimester prevalence: 1:300

Natural History & Prognosis

- 80% of children born with T21 will reach 60 years of age
- Varying degrees of cognitive delay

DIAGNOSTIC CHECKLIST

Consider

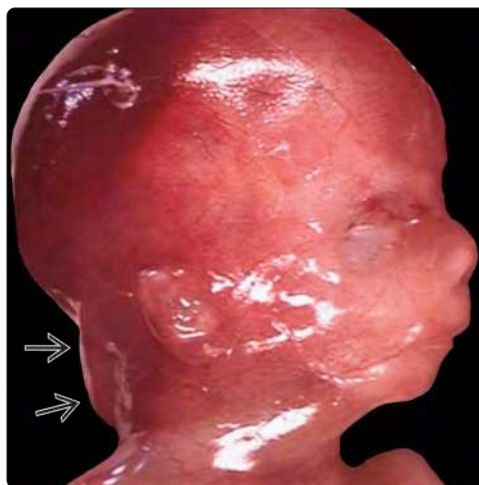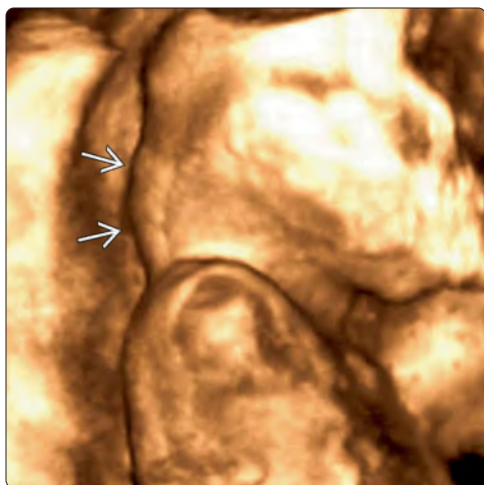
- Detection rates for different screening tests
 - cfDNA detects 99.2% (0.1% false-positive rate)
 - NT alone detects 87% (5% false-positive rate)
 - NT + other ultrasound markers + maternal serum markers detects 95% (3-5% false-positive rate)
- Use LR when minor markers seen in low-risk patients
 - Correlate with a priori risk based on best screening
- Offer chorionic villus sampling or amniocentesis for diagnosis in high-risk patients

Image Interpretation Pearls

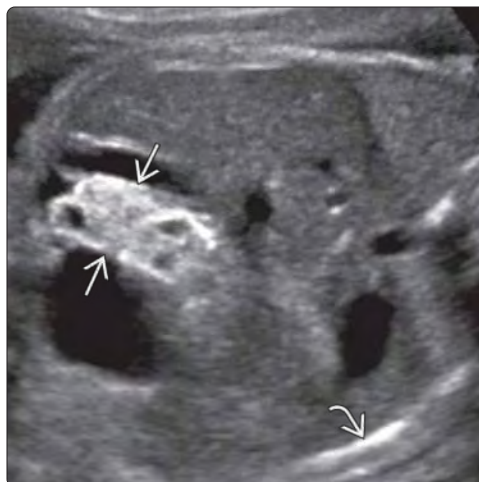
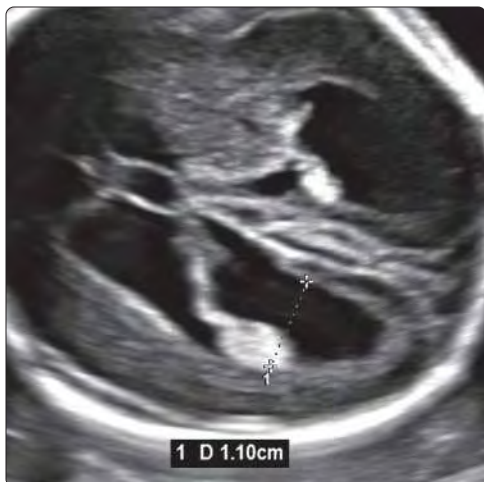
- Some markers may progress to real anomalies and need follow-up
 - Pelviectasis → obstructive hydronephrosis
 - Ventriculomegaly → obstructive hydrocephalus
 - Echogenic bowel → bowel obstruction

SELECTED REFERENCES

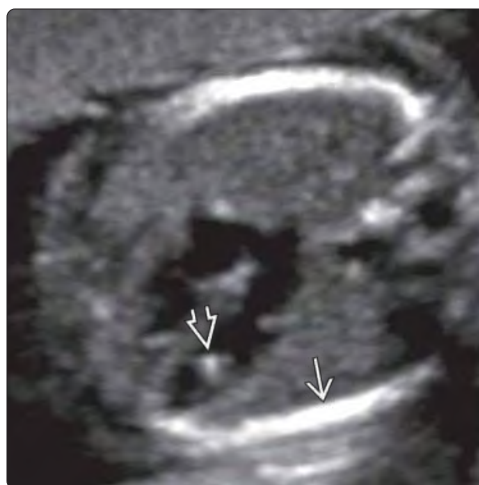
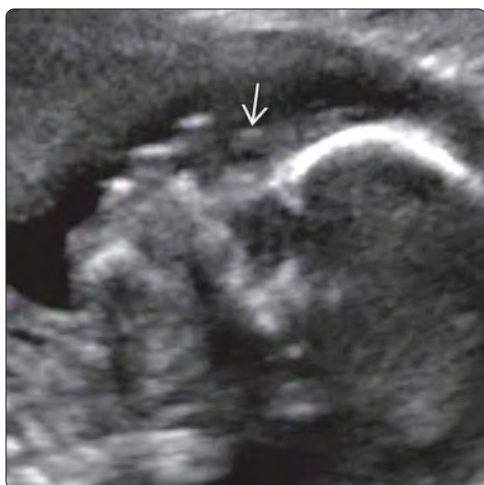1. Abele H et al: First trimester ultrasound screening for Down syndrome based on maternal age, fetal nuchal translucency and different combinations of the additional markers nasal bone, tricuspid and ductus venosus flow. *Prenat Diagn.* 35(12):1182-6, 2015
2. Gil MM et al: Analysis of cell-free DNA in maternal blood in screening for fetal aneuploidies: updated meta-analysis. *Ultrasound Obstet Gynecol.* 45(3):249-66, 2015



(Left) 3D ultrasound of the back of the neck shows nuchal fold thickening in a 2nd trimester fetus with T21. 3D reconstructed images often make it easier to discuss the findings with the parents. (Right) Clinical photograph demonstrates nuchal fold thickening in a 2nd-trimester fetus with T21. Abnormal lymphatics and loose redundant skin are associated with T21.

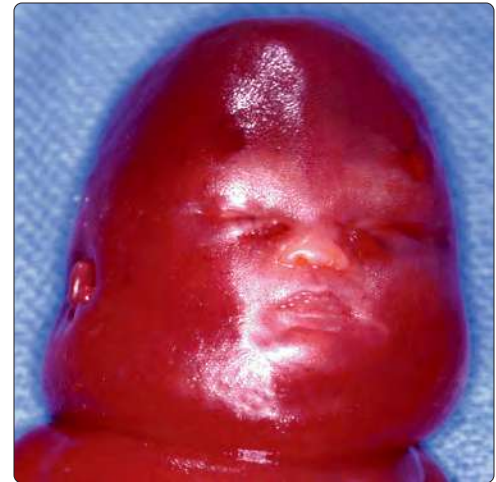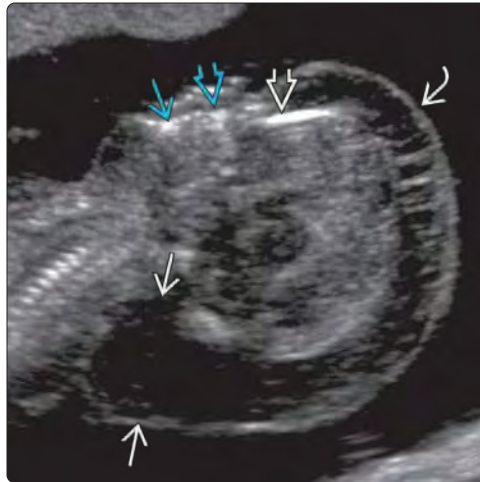


(Left) This 2nd-trimester fetus with mild ventriculomegaly had other markers for T21, and the family opted for amniocentesis for diagnosis. No other brain anomalies were seen. (Right) Echogenic bowel is another marker for T21. The bowel echogenicity is equal or greater than bone. Other associations include fetal infection and cystic fibrosis. Amniocentesis, in this case, ruled out the other diagnoses and was diagnostic for T21.



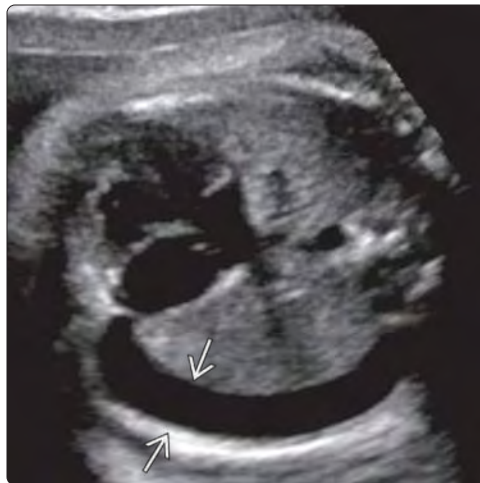(Left) Absent nasal bone, as seen in this fetus with T21, is a strong marker with a likelihood ratio of 23. Even as an isolated finding, most low-risk patients become high risk when the nasal bone is small or absent, and genetic counseling is recommended for this finding. (Right) In contrast, a single echogenic focus does not significantly alter risk in low-risk patients but is important to note if other markers are present. Note that an intracardiac echogenic focus must be as bright as bone.

(Left) In this fetus with markedly increased nuchal translucency, additional features of T21 include anasarca involving the scalp and a flat midface. Notice that the frontal bone, maxilla, and mandible are all at the same level.

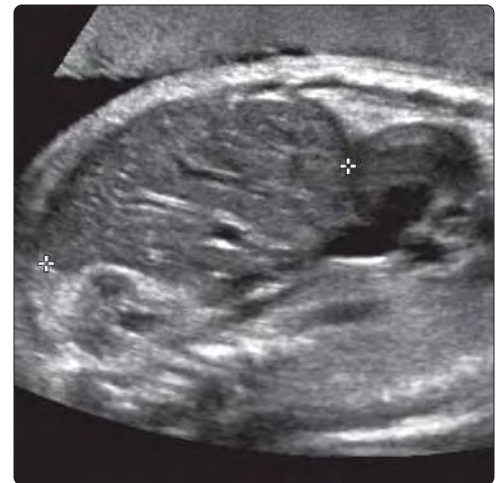

(Right) Clinical photograph of a T21 fetus with hydrops reveals diffuse body wall edema, which was the only finding. T21 can present with fetal anasarca and hydrops from lymphatic malformation or cardiac failure. The prognosis is grim for fetuses with hydrops.

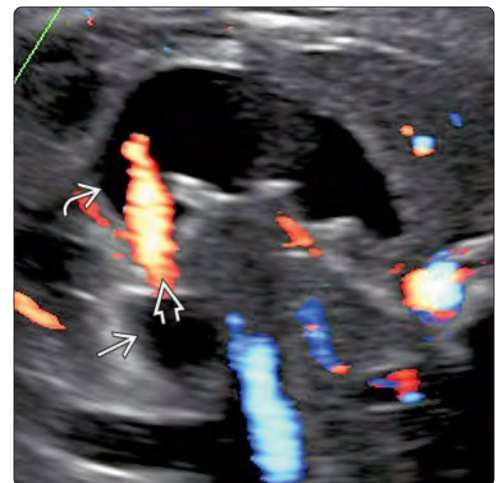
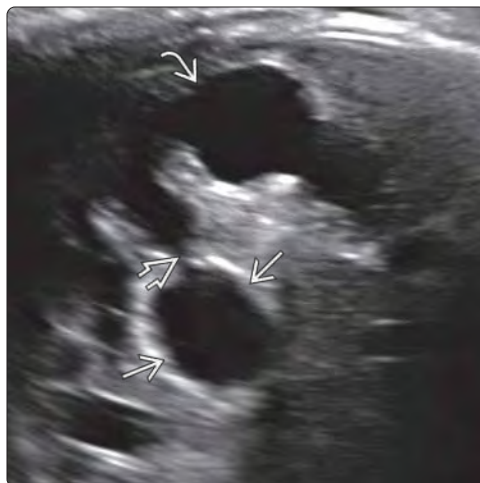
(Left) A unilateral right pleural effusion is seen in this fetus with T21. It progressed, becoming larger, then bilateral with early hydrops.

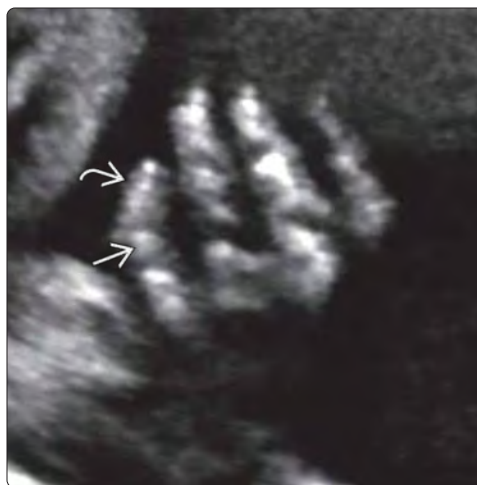
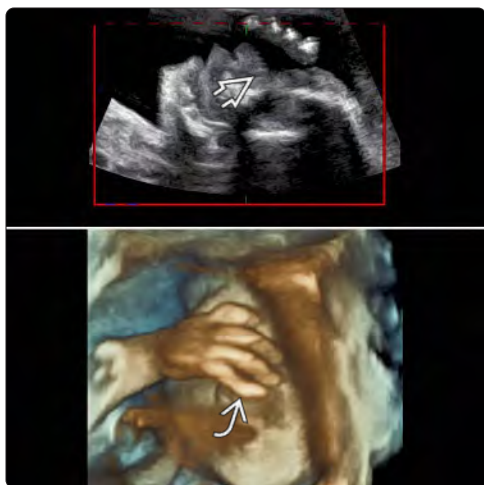


Thoracentesis revealed chylothorax, a lymphatic defect, and placement of a shunt reversed the hydrops. **(Right)** In another fetus with T21, the liver is markedly enlarged (calipers). Fetuses with T21 are at increased risk for leukemia, most commonly transient abnormal myelopoiesis, which presents as hepatosplenomegaly and has an excellent prognosis.

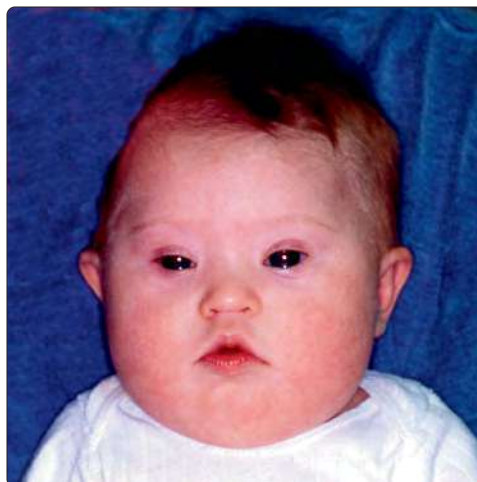
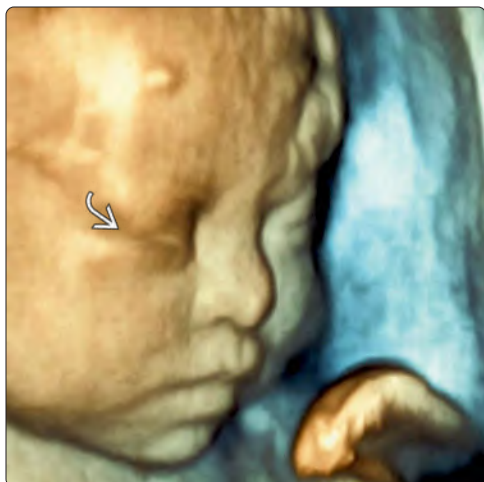
(Left) In this fetus with T21, the only finding was duodenal atresia at 34 weeks. The duodenum is dilated and ends abruptly. Seeing the pylorus, connecting the dilated stomach to the duodenum, proves that the fluid-filled structure is the duodenum and not an abdominal cyst. **(Right)** Color Doppler US in the same case shows regurgitation of fluid from the duodenum into the stomach. Red Doppler signal is from fluid traveling toward the transducer, out of the duodenum.

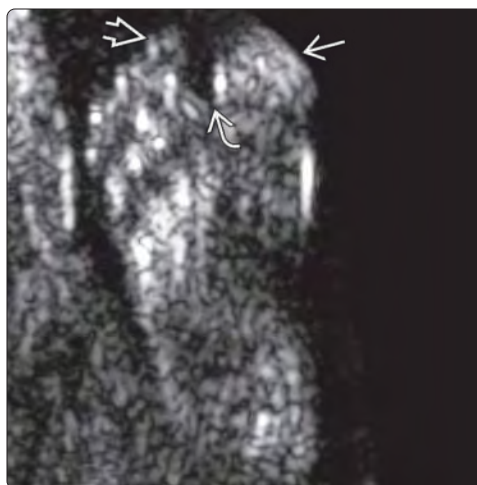
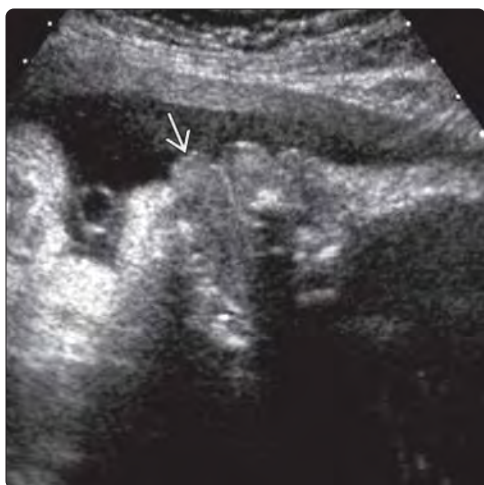



(Left) This fetus with an absent nasal bone has its hand in front of its face. On the reconstructed 3D image, there is 5th finger clinodactyly, a soft marker which can be seen with T21. (Right) Ultrasound of the hand in another fetus with T21 shows 5th-finger clinodactyly. The middle phalanx is short, leading to curvature of the tip of the little finger toward the ring finger. As an isolated finding in a low-risk patient, clinodactyly is considered idiopathic and sometimes seen in multiple other normal family members.



(Left) 3D ultrasound of the face in a 3rd-trimester fetus with T21 shows classic features of flat midface and upslanted palpebral fissures. Macroglossia is another facial feature that is not seen in this case. (Right) Clinical photograph in another child with T21 shows additional facial features of redundant skin of the inner eyelid (epicanthic fold) and a low-set small nasal bridge.



(Left) Sagittal US shows a flat midface and macroglossia in a 3rd-trimester fetus with T21. Fetal tongue is enlarged and was seen extending outside the mouth for the duration of the exam. Macroglossia is rarely a 2nd-trimester finding. (Right) Plantar view of the fetal foot shows a sandal gap. A persistent gap was seen between the 1st and 2nd toe in this fetus with multiple other anomalies and T21. Subtle extremity findings including sandal gap and clinodactyly are more often seen in normal fetuses than T21.

KEY FACTS

TERMINOLOGY

- Autosomal trisomy of chromosome 18

IMAGING

- Multiple anomalies is hallmark finding
- Findings at time of nuchal translucency (NT) scan in > 90%
 - ↑ NT, absent nasal bone + other anomalies
 - Structural anomalies seen best with transvaginal ultrasound
- 2nd-trimester anomalies in almost all fetuses
 - Cardiac defects, omphalocele, diaphragmatic hernia, spina bifida, brain anomalies, musculoskeletal anomalies
 - Clenched hands + overlapping index finger
 - Markers are rarely isolated
 - Choroid plexus cysts (CPCs), single umbilical artery (SUA), strawberry-shaped calvarium
- Fetal growth restriction (FGR)
 - Often early, progressive, and severe

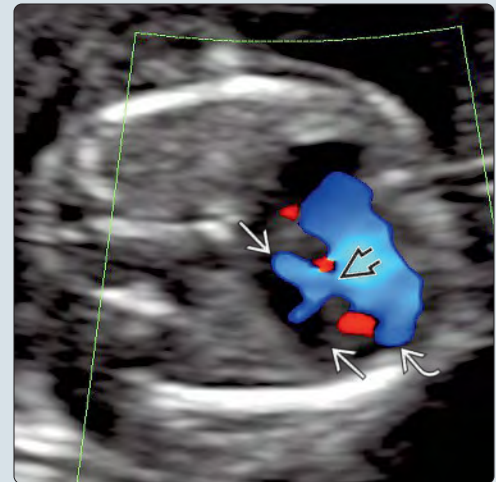
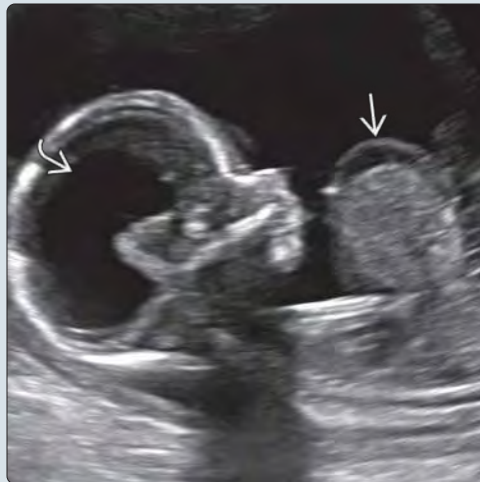TOP DIFFERENTIAL DIAGNOSES

- Trisomy 13
- Triploidy
- Pena-Shokeir syndrome (pseudotrismy 18)
- Smith-Lemli-Opitz syndrome

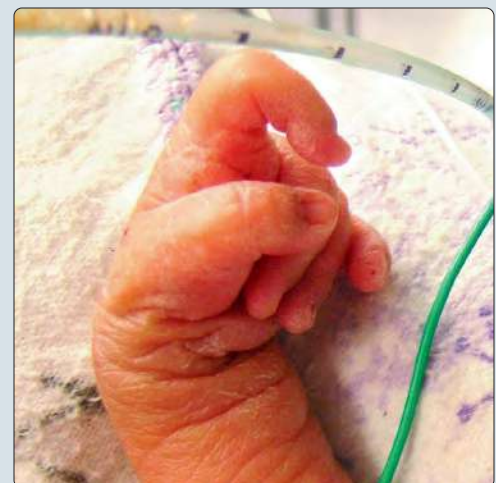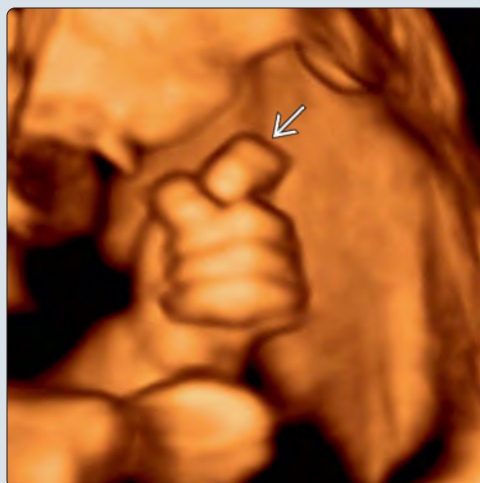CLINICAL ISSUES

- Screening tests
 - Cell-free fetal DNA detection rate is 96%
 - 1st-trimester serum biochemistry with 90% detection
 - Maternal serum quadruple test with 80% detection
- Prognosis if pregnancy is continued
 - 1/2 with intrauterine fetal demise (IUFD)
 - Ultrasound findings are poor predictor for IUFD
 - 20% survive beyond 1st month of life
 - 5-10% survive beyond 1st year of life in most studies
- 3.8 likelihood ratio (LR) for recurrence of trisomy 18
- 1.4 LR for recurrence of any trisomy

(Left) Multiple severe anomalies were identified at the time of an anatomy scan in this 20-week fetus. On the sagittal view through the head, chest, and upper abdomen, an omphalocele and ventriculomegaly are seen. **(Right)** A ventricular septal defect, abnormal heart axis, and small left ventricle are also seen on the 4-chamber view of the heart. Not one hallmark anomaly is associated with T18; however, the diagnosis should be suspected in fetuses with multiple anomalies in different organ systems.



(Left) 3D ultrasound of a 3rd-trimester fetus with T18 shows a clenched hand with an overlapping index finger. Multiple other anomalies were also present. **(Right)** Clinical photograph shows the typical hand position seen with T18. The hand is held clenched with overlapping fingers, and the index finger typically overlaps the other clenched fingers.



TERMINOLOGY**Abbreviations**

- Trisomy 18 (T18)

Synonyms

- Edwards syndrome

Definitions

- Autosomal trisomy of chromosome 18

IMAGING**General Features**

- Best diagnostic clue
 - 1st trimester
 - Increased nuchal translucency (NT) + other anomalies
 - 2nd trimester
 - Multiple major anomalies (none are hallmark)
 - Choroid plexus cyst (CPC) is considered marker
 - Almost never isolated finding
 - Fetal growth restriction (FGR)

Ultrasonographic Findings

- Findings at time of NT scan in > 90%
 - Increased NT measurement
 - Definition: ↑ subcutaneous fluid behind fetal neck
 - ↑ NT is greater in T18 than trisomy 21 (T21)
 - Other anomalies seen at time of NT scan in > 80%
 - Absent nasal bone
 - Reversal of flow in ductus venosus
 - Fetal anomalies, often multiple
 - Cardiac defects
 - Omphalocele
 - Megacystis
 - Facial anomalies
 - Limb anomalies
- 2nd-trimester anomalies in almost all fetuses with T18
 - Cardiac defects (90%)
 - Variety of defects associated with T18
 - Ventricular septal defect
 - Tetralogy of Fallot
 - Double outlet right ventricle
 - Complex defects
 - Might see isolated cardiac defect
 - Likelihood ratio (LR) of 26 for T18
 - Musculoskeletal anomalies (75%)
 - Clenched hands + overlapping index finger (50%)
 - Unilateral or bilateral
 - Radial ray malformation
 - Rocker-bottom foot
 - Clubfoot
 - Arthrogryposis
 - Urinary tract anomalies (35%)
 - Lower urinary tract obstruction
 - Hydronephrosis
 - Brain anomalies (30%)
 - Posterior fossa anomalies common
 - Dandy-Walker, inferior vermian defect
 - Cerebellar hypoplasia, mega cisterna magna
 - Holoprosencephaly

- Hallmark anomaly for trisomy 13 but T18 is 2nd most common aneuploidy cause
 - Alobar, semilobar, and lobar
 - Dysgenesis of corpus callosum
 - Unexplained ventriculomegaly
- Facial anomalies (20%)
 - Cleft lip and palate (especially if bilateral or midline)
 - Often associated with midline brain anomalies
 - Micrognathia
 - Low-set ears
 - Hypertelorism/microphthalmia
- Cystic hygroma ± hydrocephalus (20%)
 - Hallmark anomaly for Turner syndrome
- Gastrointestinal anomalies (20%)
 - Omphalocele
 - Bowel only with highest risk for aneuploidy
 - Liver containing still has ↑ risk for aneuploidy
 - Diaphragmatic hernia
 - T18 most common karyotype abnormality
 - Esophageal atresia
 - More common with T21
- Spina bifida (12%)
 - T18 most common karyotype abnormality
 - Associated Chiari 2 malformation
- Abnormal placenta
 - Small placenta
 - Rarely cystic (more likely triploidy)
- Polyhydramnios
 - Fetal growth restriction + polyhydramnios most worrisome
- Progressive FGR in most fetuses
 - Many with early onset FGR (14-24 weeks)
- 2nd-trimester markers for T18 (almost never isolated)
 - CPC is hallmark marker
 - 50% of T18 fetuses have CPC; however, 1-2 % of normal fetuses also have CPC
 - When isolated CPC is present, fetus is more likely to be normal than have T18
 - Large CPC (> 10 mm) with higher association
 - Bilateral not associated with higher risk
 - Almost always resolve by 32 weeks
 - Strawberry-shaped calvarium
 - Narrow front with lateral calvarial bulge
 - Single umbilical artery (SUA) in 50% of T18 fetuses
 - 1-2% of normal fetuses have SUA
 - Increased nuchal fold of ≥ 6 mm

Imaging Recommendations

- Best imaging tool
 - 1st-trimester NT screening + anatomy scan
 - 2nd-trimester anatomy scan
- Protocol advice
 - Use transvaginal ultrasound to look at fetal anatomy in 1st trimester when NT is increased
 - If anomalies seen, offer chorionic villus sampling (CVS) instead of serum screening tests
 - When CPC seen in 2nd trimester, look carefully at fetal extremities and fetal heart
 - Consider formal echocardiography if heart not seen well or cardiac axis is abnormal

- Do not automatically change dating if fetus is measuring small; it may be early FGR
 - Need to look at whole picture

DIFFERENTIAL DIAGNOSIS

Pena-Shokeir Syndrome (Pseudotrisonomy 18)

- Many overlapping features with T18 with neurogenic arthrogryposis being major feature
- Consider by some in spectrum of fetal akinesia sequence
- 92% die within 1st month of life
- Autosomal recessive inheritance

Trisomy 13

- Holoprosencephaly (alobar, semilobar, lobar)
- Associated facial anomalies
 - Bilateral or midline cleft lip and palate
 - Hypotelorism, cyclopia, absent globes
 - Nasal anomalies, proboscis
- Cardiac anomalies, omphalocele, polydactyly
- FGR

Triploidy

- Complete extra set of chromosomes
- Severe early FGR
- Cystic placenta is hallmark finding (not always present)
- Multiple anomalies

Smith-Lemli-Opitz Syndrome

- FGR (microcephaly is key feature)
- Clenched hands
- Abnormal genitalia
- Autosomal recessive inheritance

PATHOLOGY

General Features

- Genetics
 - 2nd most common cause of aneuploidy
 - 1st is T21
 - Autosomal trisomy of all or most of chromosome 18
 - 80% complete triplicate copy
 - 10% are mosaic, 10% with translocation

CLINICAL ISSUES

Presentation

- Most common signs/symptoms
 - Multiple anomalies ± minor markers in 2nd trimester
 - Increased 1st-trimester NT ± anomalies
 - Abnormal cell-free fetal DNA (cfDNA) results
 - 96% detection rate, false-positive rate of 0.49%
 - Failed cfDNA result can mean ↑ risk for T18 and T13
 - Failed because of low fetal fraction of DNA
 - Diagnostic testing should be offered
 - Abnormal 1st-trimester serum biochemistry results
 - ↓ pregnancy-associated plasma protein-A
 - ↓ β subunit HCG
 - 90% detection rate
 - Abnormal maternal serum quadruple test screen
 - ↓ α-fetoprotein
 - ↓ human chorionic gonadotropin protein

- ↓ estriol
- ↓ inhibin A protein
- 80% detection rate

Demographics

- Age
 - Advanced maternal age at higher risk
- Epidemiology
 - Prevalence: 1 in 6,000-8,000 live births
 - Higher fetal incidence ~ 1/2,500
- Recurrence risk
 - 3.8 LR for recurrence of T18
 - 1.4 LR for recurrence of any trisomy

Natural History & Prognosis

- Majority of fetuses with diagnosis are electively terminated
- ~ 50% with intrauterine fetal demise (IUFD) when pregnancy continued
 - Ultrasound findings do not predict IUFD
- ~ 50% are liveborn
 - 20% survive beyond 1st month of life
 - Median survival of 3-15 days reported
 - 5-10% survive beyond 1st year of life in most studies
- 5-year survival rate of 12.3% in recent multistate study
 - Predictors of longer term survival: > 37-weeks gestation, no severe congenital heart disease, no omphalocele
- No improved long-term survival with aggressive obstetric and neonatal interventions
 - Delivery with cesarean section did not improve survival
- Survivors are severely disabled

Treatment

- Termination
- Palliative care
- Supportive and aggressive care in some cases
- Tocolysis and cesarean section avoided in most cases

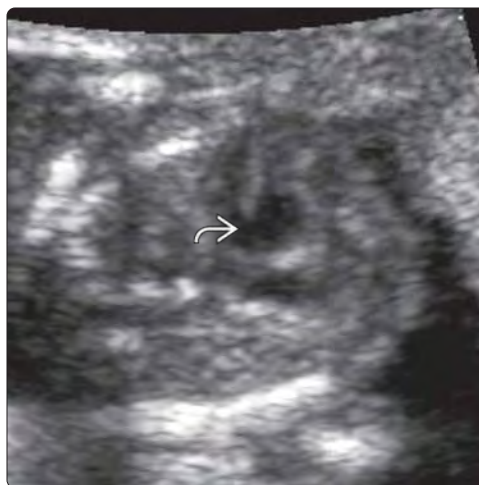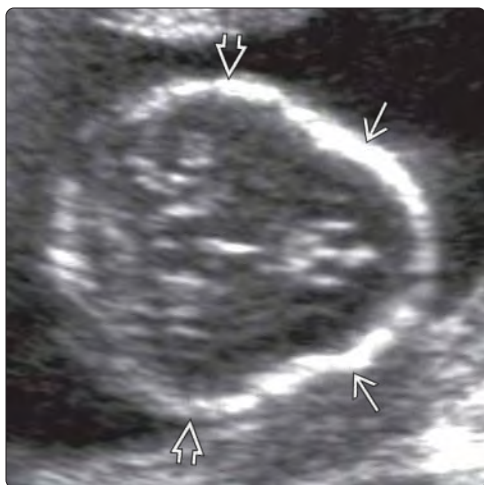
DIAGNOSTIC CHECKLIST

Consider

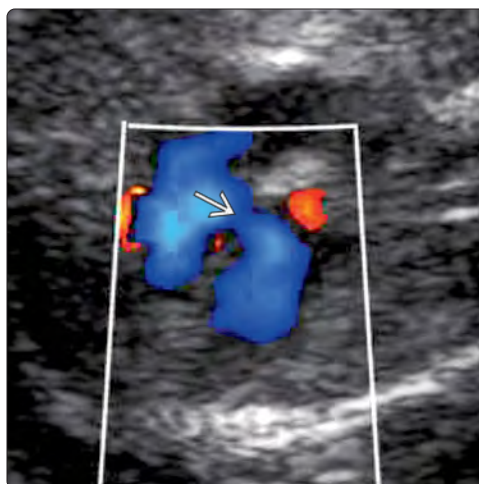
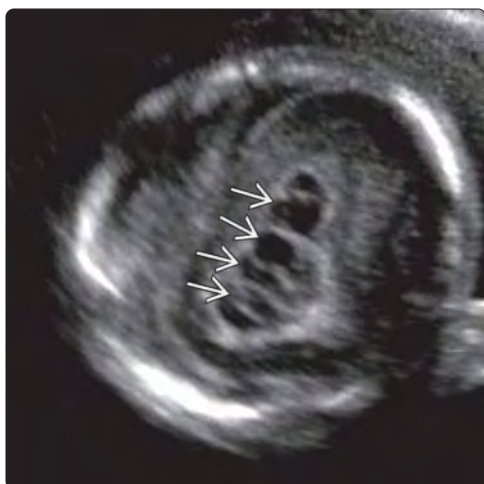- If anomaly seen at time of NT screening, offer diagnostic genetic testing
 - CVS and amniocentesis are diagnostic tests
 - cfDNA is screening test
- Offer diagnostic genetic testing for anomalies associated with aneuploidy
- Referral for genetic counseling when isolated markers seen
 - In low-risk patients, markers are mostly ignored
 - Often need maternal serum screening test to assign risk

SELECTED REFERENCES

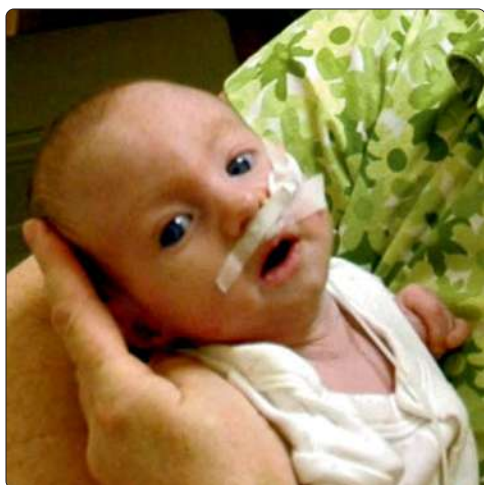1. Revello R et al: Screening for trisomies by cell-free DNA testing of maternal blood: consequences of failed result. *Ultrasound Obstet Gynecol.* ePub, 2016
2. Meyer RE et al: Survival of children with trisomy 13 and trisomy 18: A multi-state population-based study. *Am J Med Genet A.* 170(4):825-37, 2015
3. Russo FM et al: Parental counseling in trisomy 18: Novel insights in prenatal features and postnatal survival. *Am J Med Genet A.* 170(2):329-36, 2015
4. Wagner P et al: First-trimester screening for trisomy 18, 13, triploidy and Turner syndrome by a detailed early anomaly scan. *Ultrasound Obstet Gynecol.* ePub, 2015
5. Bronsteen R et al: Second-trimester sonography and trisomy 18. *J Ultrasound Med.* 23(2):233-40, 2004



(Left) Axial view through the calvarium in this midgestation fetus with T18 shows narrow frontal bones and lateral calvarial bulging, giving the head a strawberry shape. This finding is subtle but should lead to a careful search for other anomalies. (Right) In the same fetus, a moderate-sized ventricular septal defect is seen in the heart. The fetus also held its arms and legs in consistent extension, arthrogryposis. The presence of several abnormalities, some subtle, led to amniocentesis in this low-risk patient.

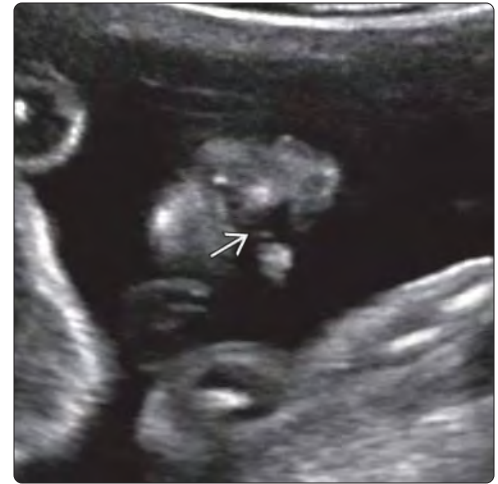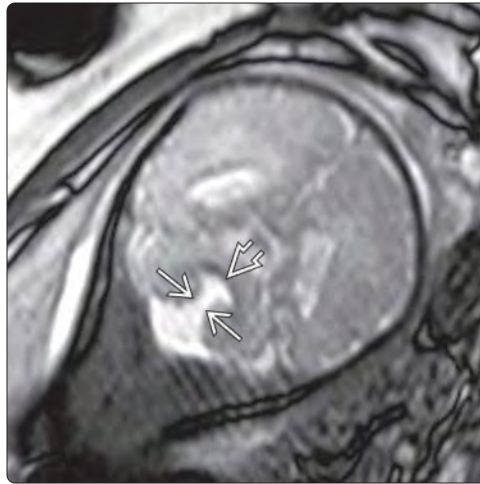


(Left) Multiple choroid plexus cysts (CPC) were seen in this early 2nd-trimester fetus. The contralateral choroid plexus also contained cysts, none of which were large. (Right) The presence of CPCs led to careful examination of the fetal heart. Color Doppler 4-chamber heart view shows a small ventricular septal defect. Amniocentesis results revealed T18, and the fetus died in utero at 28 weeks. Ultrasound is a poor predictor of which fetuses with T18 will die in utero. This fetus did not have severe anomalies.

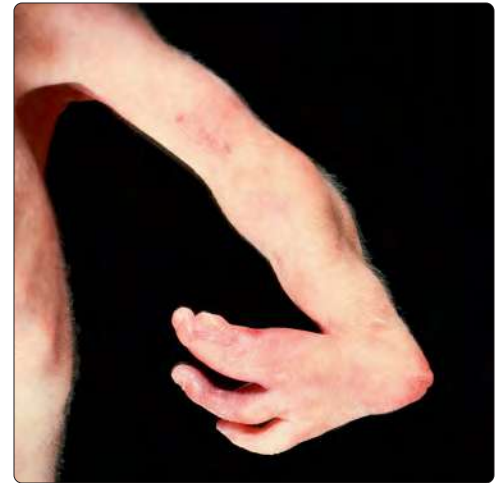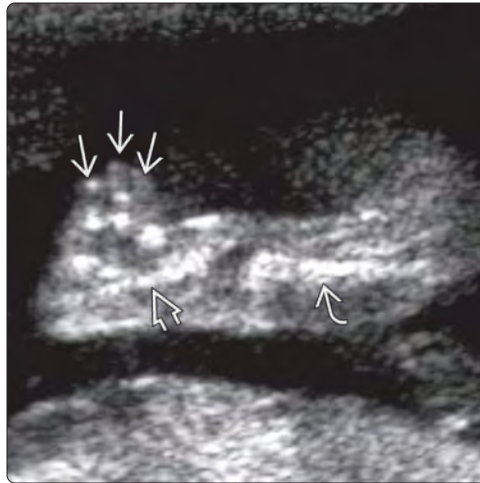


(Left) This clinical photograph of a liveborn baby with T18 shows that some newborns have mild features. Approximately 1/2 of pregnancies that do not terminate result in a liveborn child. (Right) The baby's hands are clenched and the index, and 5th fingers overlap the middle and ring fingers. This baby also had tetralogy of Fallot, which was corrected. She lived to 11 months of age.

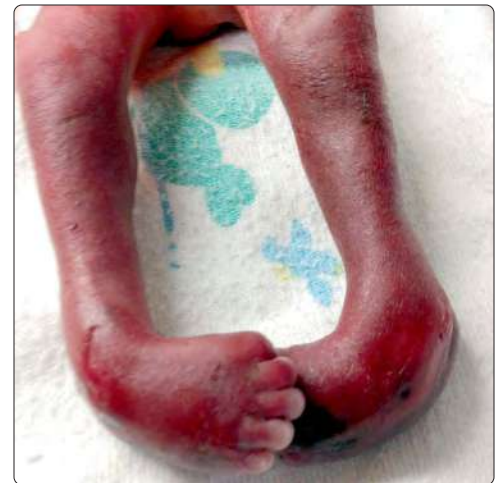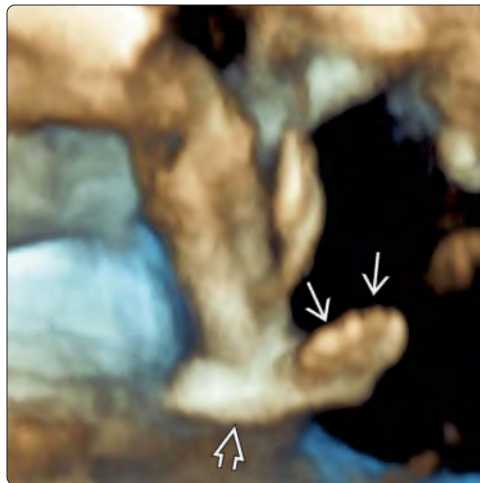
(Left) Coronal T2WI shows a vermian defect, allowing communication of the the cisterna magna with the 4th ventricle, creating a keyhole appearance. Posterior fossa anomalies are associated with aneuploidy and T18 is the most common association. (Right) Unilateral cleft lip was 1 of several anomalies seen in this fetus with T18. Isolated cleft lip and palate are less likely to be associated with aneuploidy.

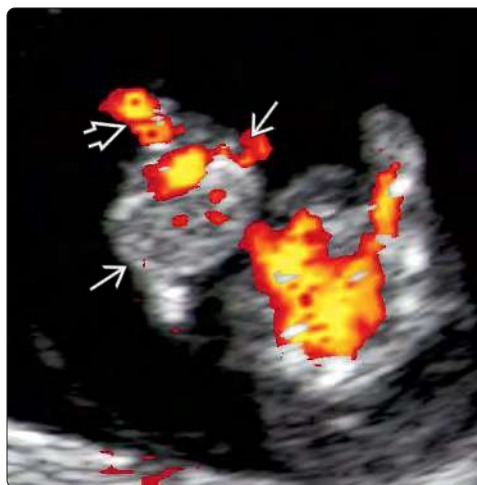
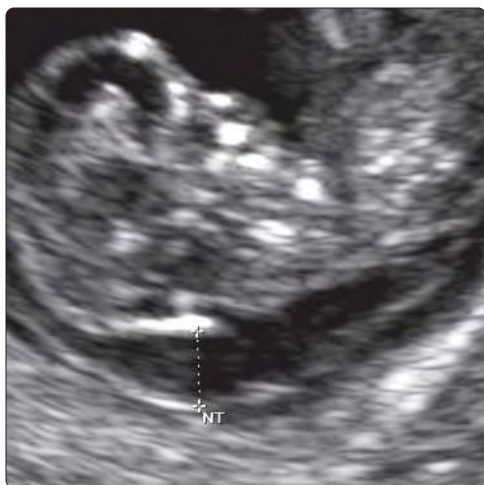

(Left) Long-axis view of the arm shows a radial ray anomaly in a 2nd-trimester fetus with T18. There is only 1 bone in the forearm, and the radius is missing (note the humerus). The hand is deviated medially, and only 3 fingers are present. The thumb and index fingers are missing. (Right) Photograph of a radial ray anomaly in another fetus with T18 shows a missing thumb, short forearm, and medial deviation of the hand.

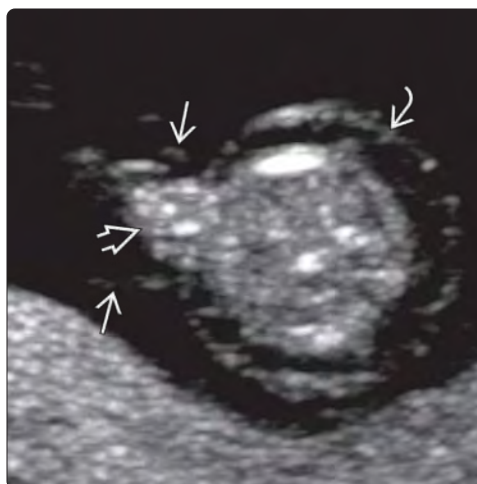
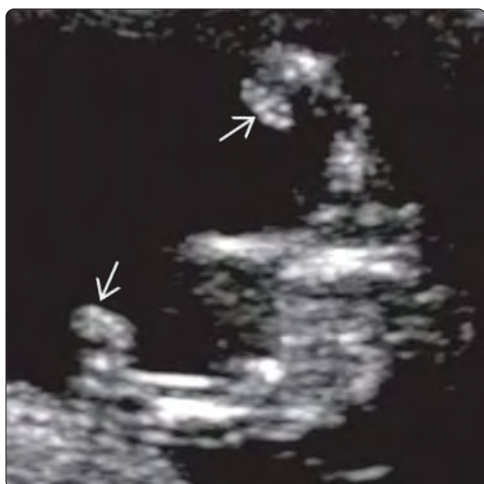

(Left) 3D ultrasound of the lower extremity of a 20-week fetus with T18 shows classic rocker-bottom foot morphology. The hind foot is convex (like the bottom of a rocking chair) and the toes are upturned. A vertical talus causes this appearance. (Right) Clinical photograph of another fetus with T18 who died at 28 weeks shows bilateral club feet. Extremity anomalies, such as these, and arthrogryposis are common with T18.

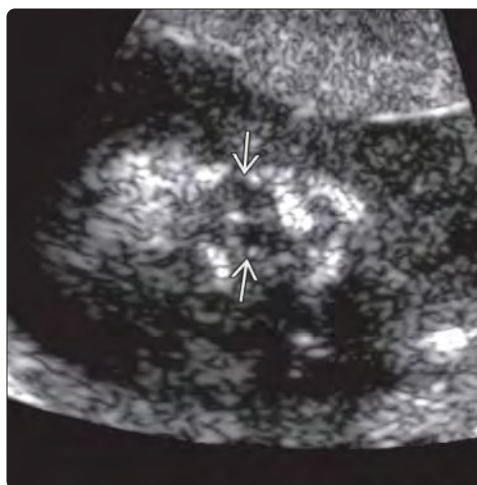
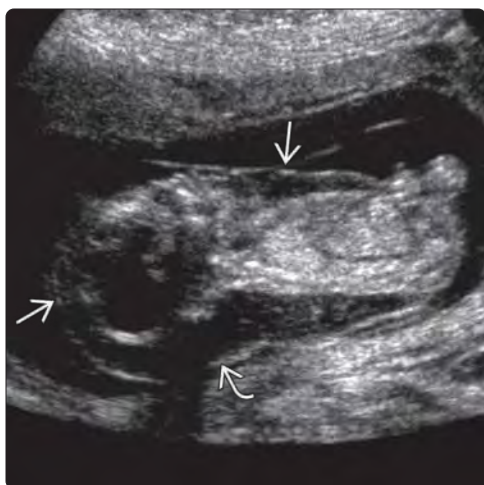




(Left) Midline sagittal ultrasound shows a markedly increased nuchal translucency (NT) (calipers) in this 12-week fetus. (Right) In addition, there is a large, well-encapsulated anterior abdominal wall defect with the cord inserting upon the extracorporeal abdominal contents. These findings are diagnostic for omphalocele. Chorionic villus sampling was performed on the same day, and the diagnosis of T18 was made early in the pregnancy. Note that physiologic bowel herniation should have resolved by 12 weeks.



(Left) Transverse ultrasound through the upper extremities shows that the hands are medially deviated, suggesting a 1st-trimester diagnosis of bilateral radial ray malformation. (Right) Transverse view through the abdomen in the same case shows a bowel-containing omphalocele with a surrounding membrane and body wall edema. Anatomy scan at the time of NT screening helps identify > 90% of fetuses with T18.



(Left) This 13-week fetus has significant body wall edema and ↑ NT with septations (not shown), consistent with cystic hygroma and hydrops. (Right) In addition, an image of the face shows 2 eyes in close proximity (hypotelorism), associated with holoprosencephaly (not shown). Although a hallmark finding for Turner syndrome (cystic hygroma) and a hallmark finding for T13 (holoprosencephaly) are seen, this fetus has T18 (a diagnosis without a hallmark anomaly).

KEY FACTS

TERMINOLOGY

- Synonym: Patau syndrome

IMAGING

- Holoprosencephaly is hallmark finding
 - Alobar, semilobar, lobar
 - + associated facial anomalies
 - Hypotelorism or cyclopia
 - Nasal anomaly or proboscis
 - Midline or bilateral cleft lip/palate
- Cardiac defects (80%)
 - Hypoplastic left heart + intracardiac echogenic focus highly associated with trisomy 13 (T13)
- Enlarged echogenic kidneys (50%)
- Postaxial polydactyly (75%)
- Fetal growth restriction (50%)
 - Early onset
- Detectable at time of nuchal translucency (NT) screening
 - ↑ NT, absent nasal bone

- Many key anomalies may be seen at this time

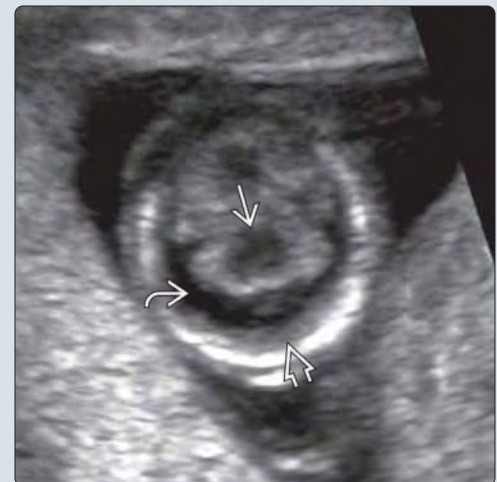
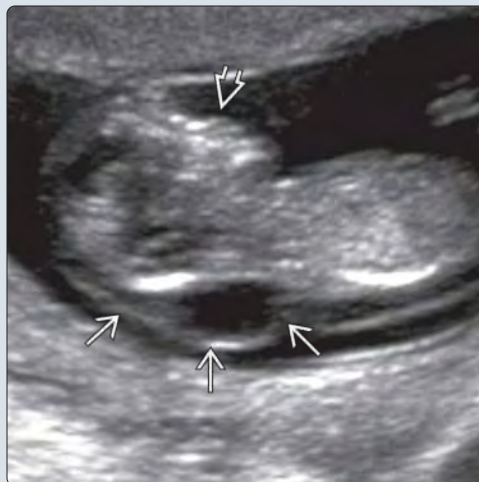
TOP DIFFERENTIAL DIAGNOSES

- Holoprosencephaly without T13
- Trisomy 18 (T18)
- Meckel-Gruber syndrome

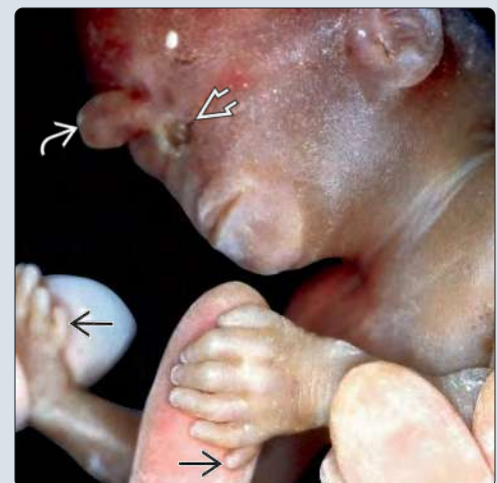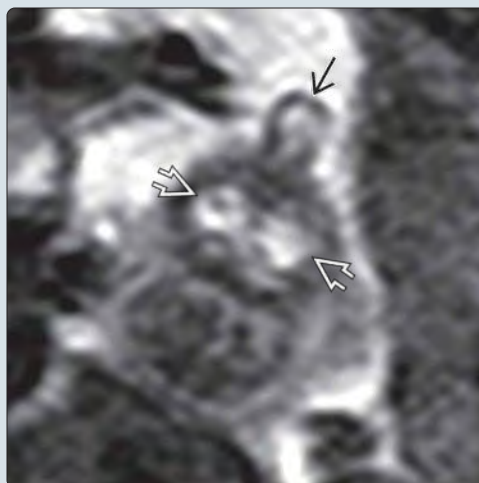
CLINICAL ISSUES

- Offer genetic testing when hallmark anomalies seen
 - Chorionic villus sampling at 11-14 weeks
 - Amniocentesis in 2nd trimester
 - Use of cell-free fetal DNA is controversial
- 3rd most common trisomy (after trisomy 21 and T18)
- Advanced maternal age (AMA) at higher risk
- Prognosis when pregnancy continued
 - 1/2 with intrauterine death and 1/2 liveborn
 - 80% of liveborn die 1st day of life
 - < 10% reach 1st birthday by most reports

(Left) At the time of nuchal translucency (NT) screening, a markedly increased nuchal translucency [red box] and absent nasal bone [red box] were noted. Endovaginal exam to look at the rest of fetal anatomy was performed. **(Right)** Images through the fetal calvarium, in the same fetus, shows fused thalami [red box], monoventricle [red box], and a thin anteriorly fused brain mantle [red box], classic findings of holoprosencephaly. The patient chose to have chorionic villus sampling on the same day and the results showed trisomy 13 (T13).



(Left) Fetal MR in a 2nd-trimester case of T13 shows classic facial features associated with holoprosencephaly. There is severe hypotelorism [red box] and a central superior proboscis [red box], instead of a nose. **(Right)** Clinical photograph of classic phenotypical features of T13 shows postaxial polydactyly [red box], proboscis [red box] and a single fused eye [red box] (i.e., cyclopia). The facial features are associated with holoprosencephaly, usually alobar.



TERMINOLOGY**Abbreviations**

- Trisomy 13 (T13)

Synonyms

- Patau syndrome

Definitions

- Autosomal trisomy of chromosome 13

IMAGING**General Features**

- Best diagnostic clue
 - Holoprosencephaly + other anomalies (> 90%)
 - Cardiac defects
 - Enlarged echogenic kidneys
 - Polydactyly
 - Fetal growth restriction (FGR)
 - Increased nuchal translucency (NT) ± other anomalies

Ultrasonographic Findings

- Central nervous system anomalies (70%)
 - Holoprosencephaly in 40-50%
 - Midline fusion anomaly of brain
 - Variable severity from complete lack of separation of cerebral cortex to anterior fusion anomaly only
 - Alobar (most severe), semilobar, lobar (least severe)
 - Fully or partially fused thalami (alobar, semilobar)
 - Monoventricle/dorsal sac (alobar)
 - Variable amount of brain mantle fusion
 - Variable presence of falx
 - Absent cavum septi pellucidi (CSP)
 - Might be only finding with lobar
 - 90% with associated facial anomaly
 - Microcephaly (progressive and severe)
 - Head circumference < 3 SD below mean
 - Cerebellar anomalies
 - Dandy-Walker malformation
 - Cerebellar hypoplasia + mega cisterna magna
 - Agenesis of corpus callosum
 - Variable ventriculomegaly
- Facial anomalies (50%)
 - Mostly as associated with holoprosencephaly
 - Face predicts brain
 - Orbit anomalies
 - Cyclopia, hypotelorism
 - Microphthalmos, anophthalmia
 - Abnormal nose
 - Absent or small/dysmorphic nose
 - Proboscis
 - Tube-like nose, located superior to orbits
 - Midline or bilateral cleft lip/palate
 - Premaxillary protrusion on profile view when bilateral
 - Low-set ears
- Cardiac defects (80%)
 - Hypoplastic left heart (HLH)
 - HLH + intracardiac echogenic focus (IEF) highly associated with T13
 - Ventricular septal defect

- Other complex defects
- Renal anomalies (50%)
 - Echogenic kidneys from cystic dysplasia
 - Urinary tract dilation
- Musculoskeletal findings (50%)
 - Post axial polydactyly (75%)
 - Extra finger on ulnar side
 - Clenched hand/overlapping digits
 - More common with trisomy 18 (T18)
 - Rocker-bottom feet
 - More common with T18
 - Clubfeet
- Gastrointestinal anomalies
 - Omphalocele: Often bowel containing
 - Echogenic bowel
- FGR in (50%): Typically early onset and progressive
 - FGR + polyhydramnios worrisome for T13 and T18
- 2nd-trimester markers (rarely isolated)
 - IEF (30%)
 - Single umbilical artery (25%)
 - ↑ nuchal fold or cystic hygroma (20%)
 - Echogenic bowel (5%)
- ↑ NT ± other anomalies at 11-14 weeks in 90% of cases
 - Alobar holoprosencephaly
 - Absent falx, fused brain mantle, ball-like thalamus
 - Omphalocele
 - Extracorporeal bowel after 12-weeks gestation is not physiologic bowel herniation
 - Extracorporeal liver is never normal
 - Megacystis (large bladder)
 - Tachycardia
 - Fetal heart rate > 95 percentile for CRL
 - > 185 BPM close-set eyes at 45 mm CRL
 - > 175 BPM at 85 mm CRL
 - Abnormal ductus venosus waveform
 - Reversal of a-wave
 - Tricuspid regurgitation
 - Abnormal profile of face
 - Absent nasal bone
 - Premaxillary protrusion
 - Proboscis

Imaging Recommendations

- Best imaging tool
 - 1st-trimester NT screening
 - 2nd-trimester anatomy scan
- Protocol advice
 - Suspect T13 in all cases with holoprosencephaly
 - Suspect brain anomaly when midline facial anomaly seen and vice versa
 - Consider fetal MR when CNS findings are minimal

DIFFERENTIAL DIAGNOSIS**Holoprosencephaly Without T13**

- Alobar
- Semilobar
- Lobar
 - May be missed with ultrasound
 - Consider fetal MR if CSP is absent

- Better prognosis when isolated

Trisomy 18 (T18)

- Multiple severe anomalies
 - Cardiac anomalies
 - Musculoskeletal
 - Clenched hand with overlapping fingers
 - Holoprosencephaly
 - T18 is 2nd most common cause
 - Omphalocele
 - Most common chromosome abnormality with this anomaly
- Choroid plexus cyst is marker
 - Almost never isolated
- Early FGR
- Increased NT in 1st trimester

Meckel-Gruber Syndrome

- Brain anomalies
 - Encephalocele (most common)
 - Dandy-Walker malformation
 - Holoprosencephaly (rare)
- Polydactyly
- Echogenic kidneys
- Autosomal recessive with 25% recurrence risk

PATHOLOGY

General Features

- Etiology
 - 75% triplicate copy of chromosome 13
 - 20% translocation
 - 5% mosaic

CLINICAL ISSUES

Presentation

- Most common signs/symptoms
 - Abnormal 1st- or 2nd-trimester ultrasound
 - > 90% T13 detection rate
 - Abnormal maternal serum screen results
 - 1st trimester
 - ◻ ↓ β subunit HCG (β-HCG)
 - ◻ ↓ pregnancy-associated plasma protein-A (PAPP-A)
 - ◻ Results identical for T18
 - 2nd trimester
 - ◻ ↑ α-fetoprotein (AFP)
 - ◻ ↑ inhibin A protein
 - ◻ Normal human chorionic gonadotropin (HCG)
 - ◻ Normal estriol
 - ◻ 71% detection rate
 - Use of cell-free fetal DNA for screening is controversial
 - 91.6% detection rate
 - ◻ Lower than for other trisomies
 - 0.097% false-positive rate
 - ◻ Lower prevalence of T13 leads to 967 false-positive diagnoses per 1 million women of average risk
 - Positive predictive value is 8.7% in average-risk women and 82.6 % in high-risk women

Demographics

- Age

- Advanced maternal age (AMA) at higher risk
 - AMA: ≥ 35 yr at time of delivery
- Epidemiology
 - 3rd most common trisomy
 - Trisomy 21 and 18 more common
 - 1 in 5,000 -10,000 birth prevalence
 - Increasing prenatal diagnosis rate and decreasing birth rates reported
 - ◻ Earlier diagnosis → ↑ termination rates
 - 1% of spontaneous abortions are T13

Natural History & Prognosis

- Prognosis when pregnancy continued
 - 1/2 with intrauterine death and 1/2 liveborn
 - 80% of liveborn die 1st day of life
 - < 10% reach 1st birthday by most reports
- Recent multi-state study in USA showed 9.7% 5-yr survival when liveborn
 - Common characteristics of longer survivors
 - No holoprosencephaly
 - Less serious cardiac defects
 - Gestational age at delivery > 37 weeks
 - Supportive medical care and surgeries
 - ◻ Feeding tubes, tracheostomy, apnea treatment
 - ◻ Cardiac surgery as needed

Treatment

- Tocolysis and cesarean section avoided
- Palliative care
- Long-term support for less affected children

DIAGNOSTIC CHECKLIST

Consider

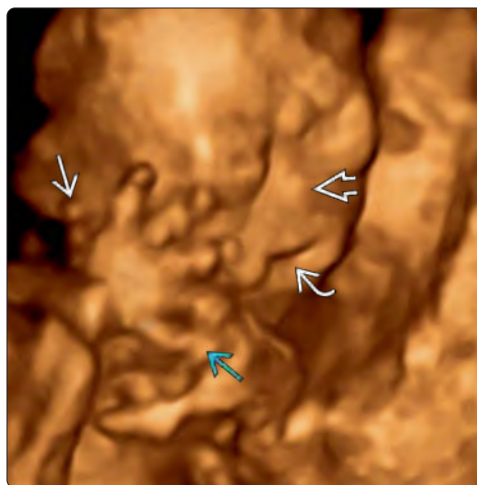
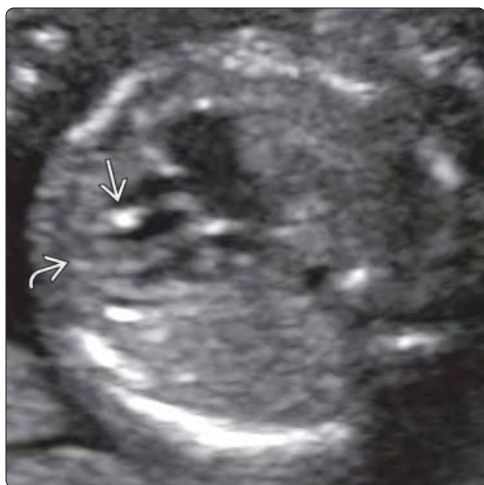- Suspect T13 when midline brain, heart, or facial anomalies seen
- Early FGR raises suspicion for aneuploidy

Image Interpretation Pearls

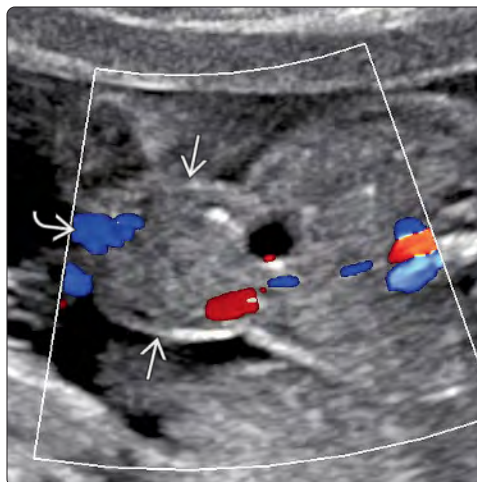
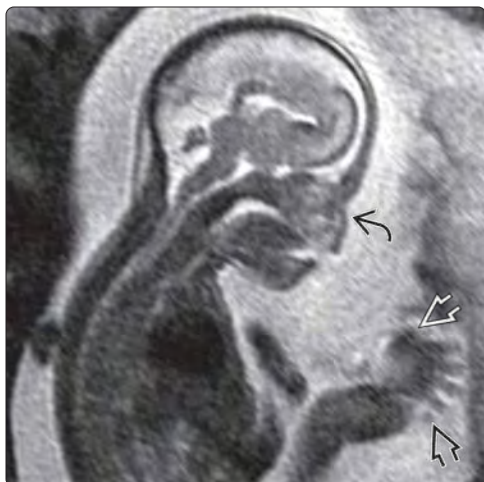- Early diagnosis of T13 is possible
 - Look at anatomy at time of NT screening
 - Endovaginal ultrasound additive
- Look for cavum septi pellucidi in all 2nd-trimester scans
 - Consider fetal MR if minor midline anomalies seen
 - Biparietal diameter and posterior fossa images
- Look carefully at fetal brain when midline or bilateral cleft lip/palate diagnosed
- Count finger and toes when holoprosencephaly diagnosed

SELECTED REFERENCES

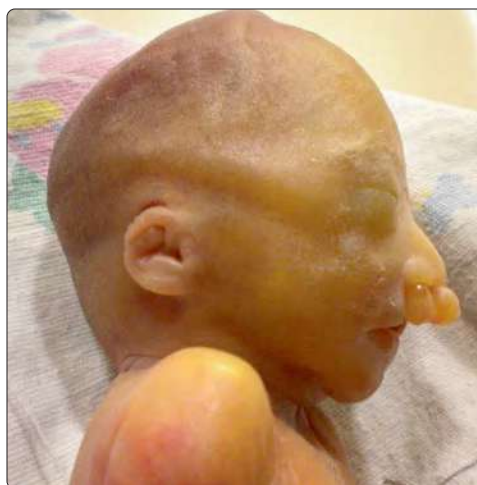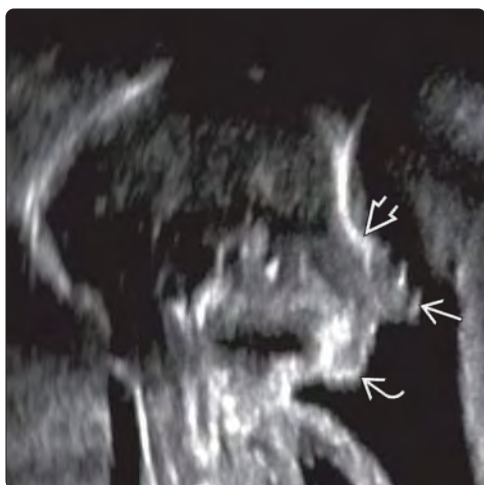1. Barry SC et al: Natural history of fetal trisomy 13 after prenatal diagnosis. *Am J Med Genet A.* 167A(1):147-50, 2015
2. Meyer RE et al: Survival of children with trisomy 13 and trisomy 18: A multi-state population-based study. *Am J Med Genet A.* 170(4):825-37, 2015
3. Bruns DA et al: Nine children over the age of one year with full trisomy 13: a case series describing medical conditions. *Am J Med Genet A.* 164A(12):2987-95, 2014
4. Verweij EJ et al: Non-invasive prenatal testing for trisomy 13: more harm than good? *Ultrasound Obstet Gynecol.* 44(1):112-4, 2014
5. Geipel A et al: Nuchal fold thickness, nasal bone absence or hypoplasia, ductus venosus reversed flow and tricuspid valve regurgitation in screening for trisomies 21, 18 and 13 in the early second trimester. *Ultrasound Obstet Gynecol.* 35(5):535-9, 2010
6. Solomon BD et al: Holoprosencephaly due to numeric chromosome abnormalities. *Am J Med Genet C Semin Med Genet.* 154C(1):146-8, 2010



(Left) In this fetus with T13, there is an echogenic cardiac focus (ECF) and the axis of the heart is closer to 0° than 45°. ECF, when isolated, is rarely associated with aneuploidy. Other anomalies were seen in this case, including outflow tract anomalies of the heart. (Right) 3D ultrasound of the face shows a midline cleft lip, absent nose, and postaxial polydactyly (thumb). Patients may better appreciate facial anomalies when 3D images are reviewed with them.

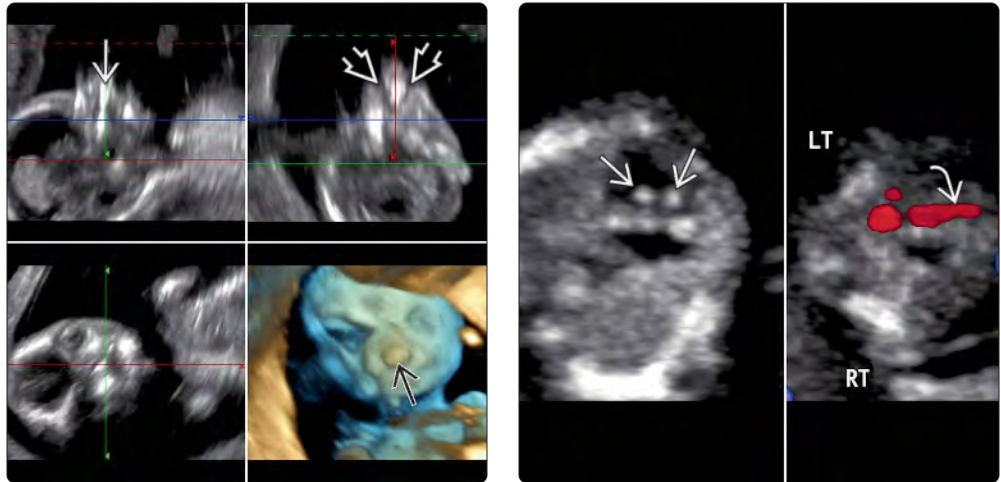


(Left) MR in another fetus with T13 shows a flattened face and abnormal nose and polydactyly. Six digits can be counted beginning with the thumb, with the extra digit on the ulnar side. (Right) Color Doppler ultrasound of this 20-week fetus with T13 shows the umbilical cord insertion site is upon an omphalocele which contains only small bowel. Since omphaloceles have a covering membrane, the bowel is not free floating.

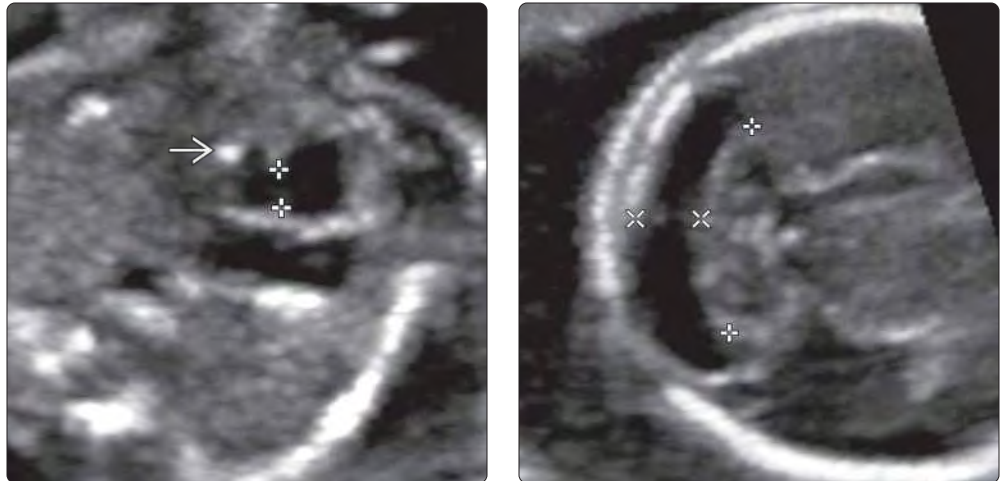


(Left) This is the profile of the same 20-week fetus with the omphalocele. There is a premaxillary protrusion of tissue caused by dysplastic anterior palate and soft tissue from bilateral cleft lip and palate. An otherwise normal nasal bone and chin are seen. (Right) Clinical photograph of the same case shows the dysmorphic tissue beneath the nose caused by bilateral cleft lip and palate. Also, notice the low-set ears. The top of the ear should be at the same level as the eyelids, on a profile view.

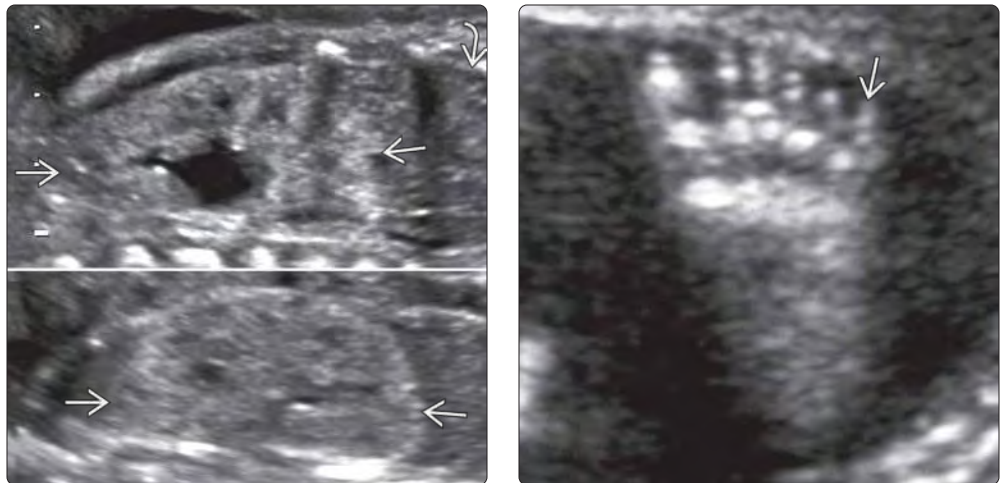
(Left) Multiplanar 3D ultrasound of the fetal face performed at 15 weeks shows premaxillary protrusion of the dysplastic anterior palate. The subtle bilateral cleft lip soft tissue defect is seen best on the axial image. The coronal surface-rendered image shows the mass-like protruding palate typical of bilateral cleft lip and palate. **(Right)** Markers for aneuploidy seen in the same fetus include echogenic cardiac foci and single umbilical artery adjacent to the bladder. Amniocentesis confirmed T13.

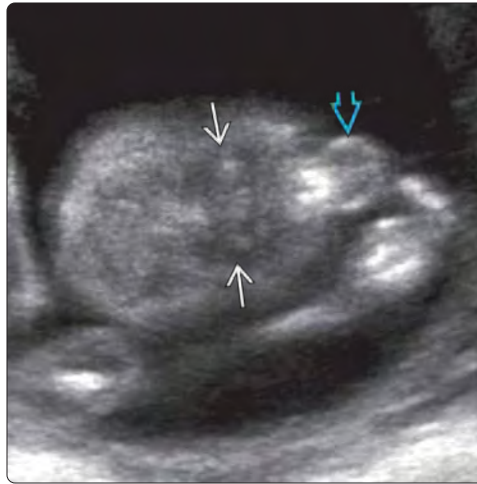
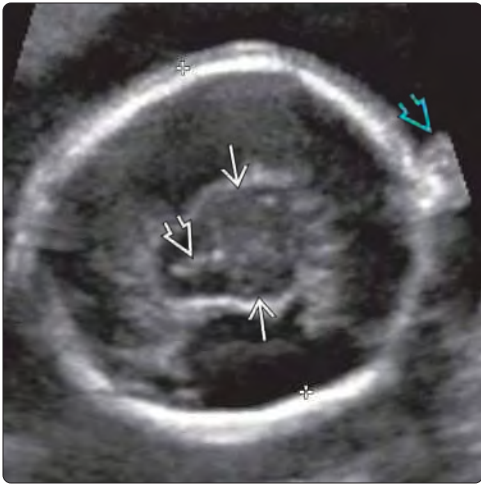







(Left) Four-chamber heart view In this midgestation fetus with T13 shows an echogenic cardiac focus and a large ventricular septal defect (calipers). **(Right)** Images through the calvarium, in the same case, shows a large cisterna magna (x-calipers) secondary to a small cerebellum (+ calipers). Forebrain anomalies were also seen. Cardiac and cerebellar anomalies are both associated with T13.

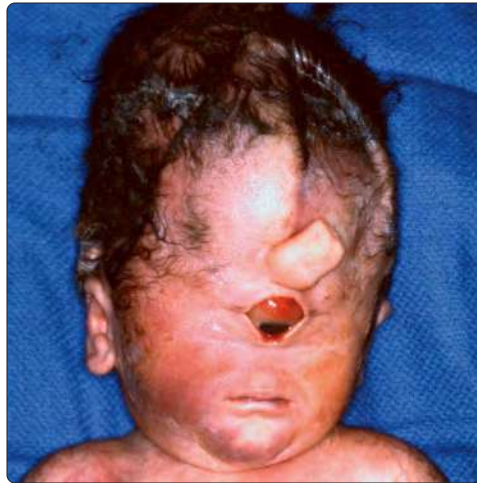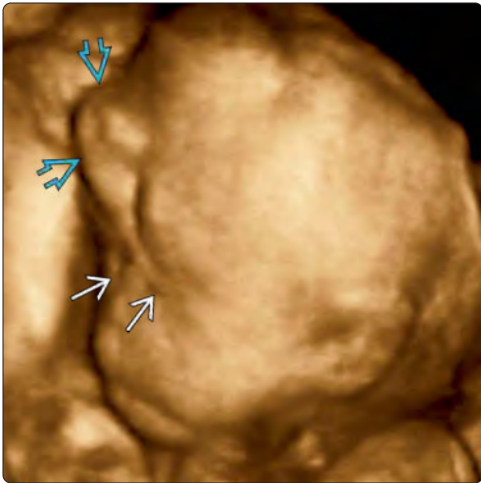




(Left) Coronal ultrasound through the kidneys in this 3rd-trimester fetus with mild features of T13 shows bilateral enlarged echogenic kidneys, a common finding with T13. Note the kidneys are significantly more echogenic than the liver and the spleen. **(Right)** In this 3rd-trimester fetus with holoprosencephaly and T13, ultrasound of the fetal foot shows polydactyly. A well-developed 6th toe is present next to the pinkie toe. Polydactyly associated with T13 can involve the feet, as well as hands.

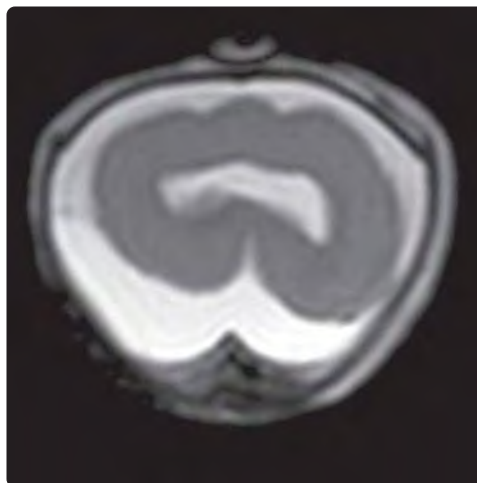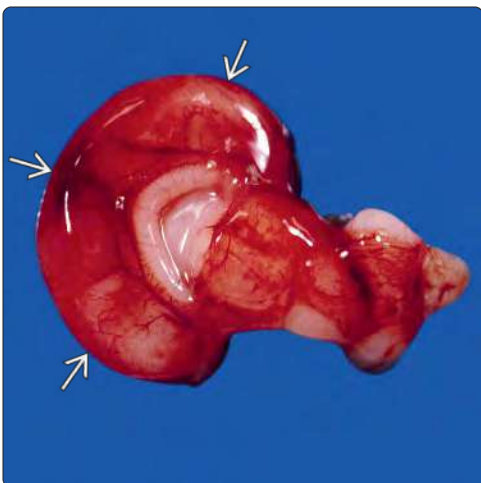





(Left) In this fetus with T13, the anterior portion of the thalamus is globular and fused  whereas the posterior portion is divided by an echogenic line . Fusion of the thalami can be partial in holoprosencephaly, even severe forms. The falx is absent and soft tissue seen anterior to the calvarium is from a proboscis . (Right) Coronal ultrasound of the face, in the same fetus, shows small close-set eyes  and a proboscis , superior to the orbits. These facial features are always seen in conjunction with brain anomalies.



(Left) In this late 2nd-trimester fetus with T13, 3D surface-rendered views show a proboscis  and small close set eyes , typical facial features associated with holoprosencephaly (\pm T13). (Right) A clinical photograph of a neonate with T13 and holoprosencephaly shows a proboscis, cyclopia, and a small mouth. A spectrum of facial features is associated with holoprosencephaly; however, proboscis and hypotelorism/cyclopia are classic findings.



(Left) Gross pathology of alobar holoprosencephaly shows the cup-type fused brain mantle , characteristic of T13. (Right) Autopsy MR of a newborn with T13 who died within hours of birth, shows the same fused brain mantle morphology. Although this was a near-term infant, notice the extremely immature appearance of the cerebral cortex, without discernible gyri and sulci. Autopsy MR can be offered to families who decline surgical autopsies.

KEY FACTS

TERMINOLOGY

- Complete or partial deficiency of X chromosome

IMAGING

- 2nd-trimester findings
 - Cystic hygroma is hallmark finding
 - Often very large
 - 60% of fetuses with cystic hygroma have Turner syndrome
 - Associated nonimmune hydrops is common
 - Must see fluid in 2 separate areas to diagnose hydrops
 - Cystic hygroma considered one of these areas
 - Hallmark cardiovascular defect is coarctation of aorta
 - Hypoplastic left heart if severe
 - Horseshoe kidney
 - Short femur and humerus
- 1st-trimester findings in > 90% of cases
 - Very large nuchal translucency measurements
 - Cystic hygroma ± hydrops can be seen early

- 75% will have retrograde ductus venosus flow
- Normal nasal bone seen

TOP DIFFERENTIAL DIAGNOSES

- Noonan syndrome
- Trisomy 21 (Down syndrome)
- Chest lymphangioma

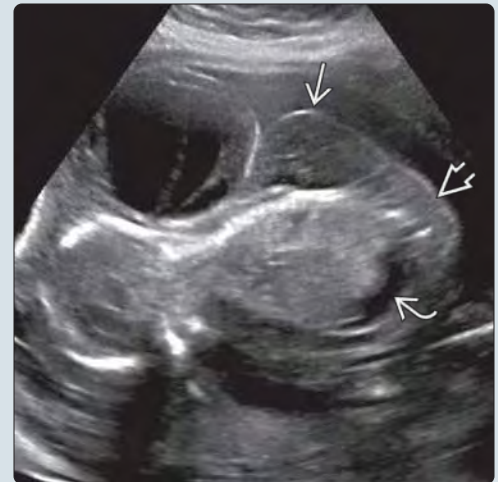
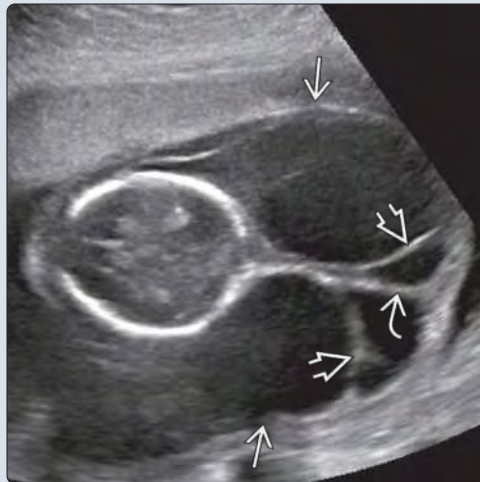
PATHOLOGY

- Complete absence of X chromosome = monosomy X
- Xp or Xq deletion
- At least 50% with some degree of mosaicism

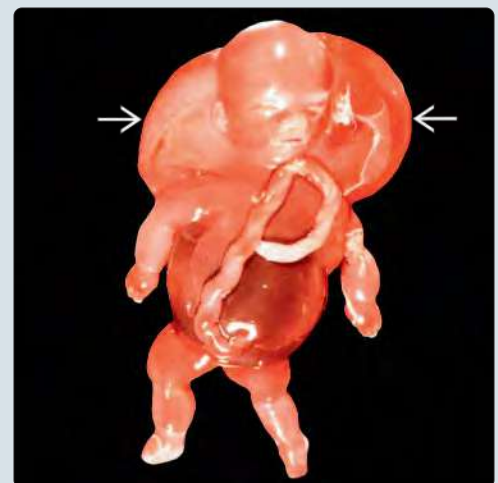
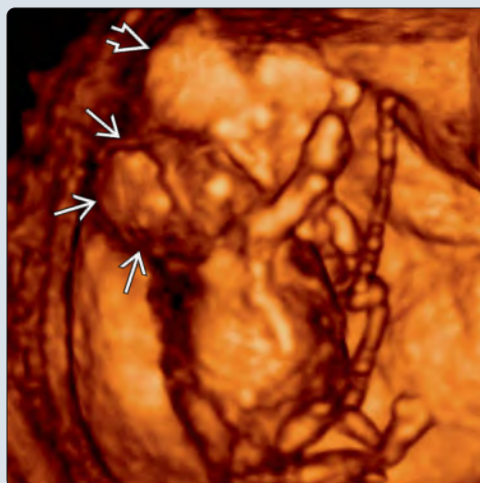
CLINICAL ISSUES

- 75% spontaneously miscarry
- Cell-free fetal DNA 89% detection rate
 - May miss mosaicism
- Advanced maternal age not at higher risk
- Prognosis with hydrops is dismal
- Marked phenotype variability for survivors

(Left) This fetus with Turner syndrome has a typical large cystic hygroma. Multiple septations are seen in addition to the central nuchal ligament. **(Right)** Sagittal view through the same fetus shows the extension of the cystic hygroma down the back as well as anasarca and ascites. Hydrops is often associated with cystic hygroma and Turner syndrome. Prognosis is poor when these features are seen.



(Left) 3D ultrasound of a 12-week fetus with monosomy X shows the focal posterior bulge of a cystic hygroma behind the head. Over 90% of Turner syndrome cases will have abnormal findings in the 1st trimester. **(Right)** Clinical photograph of an early 2nd-trimester fetus with Turner syndrome shows a large cystic hygroma and body wall edema. Most, but not all, fetuses with Turner syndrome diagnosed prenatally will suffer in utero fetal demise.



TERMINOLOGY**Abbreviations**

- Turner syndrome (TS)

Synonyms

- Monosomy X (45,X)

Definitions

- Female fetus, child or adult with complete or partial absence of X chromosome

IMAGING**General Features**

- Best diagnostic clue
 - 1st trimester: Markedly ↑ nuchal translucency (NT)
 - 2nd trimester
 - Female fetus with large, septated cystic hygroma
 - Hydrops fetalis

Ultrasonographic Findings

- Nuchal cystic hygroma (CH) is hallmark finding
 - 60% of fetuses with CH have TS
 - CHs tend to be very large
 - Involve posterior and lateral neck
 - May mimic pockets of amniotic fluid
 - Small CH mimics edematous thick nuchal fold
 - CH contains multiple thin septations
 - Midline thick septum is nuchal ligament
- Associated nonimmune hydrops is common
 - Definition: Excess fetal fluid accumulation
 - Areas where fluid can accumulate
 - Skin (anasarca)
 - Chest (pleural effusion)
 - Bilateral > unilateral
 - Abdomen (ascites)
 - Must see fluid in 2 separate areas to diagnose hydrops
 - CH is considered separate area
 - CH + anasarca = hydrops
 - CH + pleural effusion = hydrops
 - CH + ascites = hydrops
 - Cardiovascular anomalies (20-40%)
 - Coarctation of aorta (45%)
 - Narrow aortic arch
 - Left-to-right shunt across foramen ovale
 - Small left ventricle when severe
 - Difficult prenatal diagnosis
 - Hypoplastic left heart (15%)
 - Genitourinary findings
 - Horseshoe kidney is hallmark finding
 - Kidneys fused inferiorly
 - Isthmus of renal tissue anterior to aorta
 - Seen best on transverse and coronal views
 - Normal female genitalia is most common finding
 - Ambiguous genitalia is less likely
 - Turner mosaic (45,X/46,XY)
 - Mixed gonadal dysgenesis
 - Short femur and humerus
 - Rhizomelic pattern
 - Early onset growth restriction is often mild

- 1st-trimester findings present in > 90% of cases
 - Very large NTs are associated with TS
 - CH and hydrops is detectable at time of NT screening
 - Abnormal ductus venosus (DV) flow
 - 75% of TS with retrograde DV flow
 - Normal nasal bone seen with TS

Imaging Recommendations

- Best imaging tool
 - 1st-trimester NT screening
 - 2nd-trimester anatomy scan
- Protocol advice
 - Offer genetic testing for all cases with CH
 - Use high gain settings to see thin septations in CH
 - Measure amniotic fluid carefully, large CH can mimic amniotic fluid pockets especially in cases with oligohydramnios
 - Recommend formal fetal echocardiography

DIFFERENTIAL DIAGNOSIS**Noonan Syndrome**

- Can look identical to TS
 - Cystic hygroma
 - Hydrops
- Cardiac defects
 - Pulmonic stenosis
- Short limbs
- Karyotype is normal
 - Autosomal dominant
 - Often new mutation
- M:F = 1:1

Trisomy 21 (Down Syndrome)

- Nuchal thickening more common than in CH
 - Hydrops sometimes seen but more rare
- ↑ NT in 1st trimester
 - Less increased than with TS
 - Absent nasal bone
 - Abnormal ductus venosus flow
- Associated minor markers (not typical for TS)
 - Echogenic cardiac focus
 - Echogenic bowel
 - Mild ventriculomegaly
 - Mild renal pelviectasis
- Hallmark major anomalies
 - Atrioventricular septal defect
 - Duodenal atresia
- M:F is 1:1

Chest or Neck Lymphangioma

- Cystic mass of chest wall
 - Often axillary but can occur anywhere
 - Usually large with septations
 - Infiltrative
- Lateral neck lymphangioma often unilateral and without hydrops
- Not associated with aneuploidy
- M:F = 1:1

PATHOLOGY**General Features**

- Etiology
 - Abnormal proteoglycan levels in TS
 - Influence cell migration of neural crest
 - Affects aortic arch formation
 - Influence lymphatic and blood vessels formation
 - Results in lymphatic vessel hypoplasia
 - No lymphatic sacs with TS (vs. enlarged lymphatic sacs with trisomy 21)
 - Hydrops
 - Fluid overload from lymphatic failure
- Genetics
 - Absence or structural abnormality of one copy of X chromosome
 - Complete absence of X chromosome = Monosomy X
 - Absent short arm of X = Xp deletion
 - Long arm deletion of X = Xq deletion
 - At least 50% with some degree of mosaicism
 - Degree of mosaicism does not correlate with phenotype
 - Recent studies show more sophisticated genetic techniques identify an additional 30% mosaics in patients previously thought to have monosomy X

CLINICAL ISSUES**Presentation**

- Most common signs/symptoms
 - Abnormal 1st-trimester screening results
 - 96-100% detection rates reported
 - ↑ ↑ NT, abnormal DV
 - Abnormal maternal serum screen result
 - Used in conjunction with NT
 - ↓ pregnancy-associated plasma protein-A (PAPP-A)
 - ↑ human chorionic gonadotropin protein (hCG)
 - Cell free DNA detection of TS
 - 89% detection rate
 - False-positive rate of 0.2 %
 - May miss mosaicism
 - Abnormal maternal serum quadruple test screen
 - 80% detection rates for TS
 - ↓ α-fetoprotein (AFP)
 - ↓ estriol
 - ↓ hCG but ↑ hCG if hydrops
 - ↓ inhibin but ↑ inhibin if hydrops
- Other signs/symptoms
 - Presentation with 2nd-trimester anomalies
 - Presentation with fetal demise
 - Oligohydramnios from cardiac and renal dysfunction
 - Polyhydramnios less common

Demographics

- Age
 - **Not** associated with advanced maternal age (AMA)
- Gender
 - Female fetus
- Epidemiology
 - Most common sex chromosome abnormality in females

- Birth prevalence: 1:2,000 girls
- 12-14% of all prenatal chromosome abnormality diagnoses are TS
- 15% of spontaneous miscarriages have TS
- When diagnosed prenatally, 75% are spontaneously miscarried

Natural History & Prognosis

- Marked phenotype variability for survivors
 - Suggested etiology of phenotype variability
 - Mosaics
 - Incomplete X inactivation
 - X chromosome imprinting
 - Gene dosage effects
 - Parental origin of X chromosome
 - 80% maternal X
- Classic phenotype features
 - Webbed neck
 - Broad chest
 - Short limbs
 - Cubitus valgus and genu valgum
 - Short 4th metacarpal/metatarsal
- Associations seen in survivors
 - Infertility from gonadal dysgenesis
 - 1/3 with spontaneous puberty
 - Aortic coarctation, bicuspid aortic valve, aortic dilation
 - Risk of aortic dissection increased with age
 - Metabolic syndrome
 - Autoimmune disorders and low-grade inflammation
 - Hypertension
 - Hepatic dysfunction
 - Normal verbal IQ
 - Delayed motor skills
 - Hearing impairment

Treatment

- Prenatal treatment adjusted for findings
 - Fluid drainage procedures
 - Prognosis with hydrops is dismal
 - Respiratory resuscitation at delivery
- Survivors benefit from multidisciplinary clinic involvement

DIAGNOSTIC CHECKLIST**Consider**

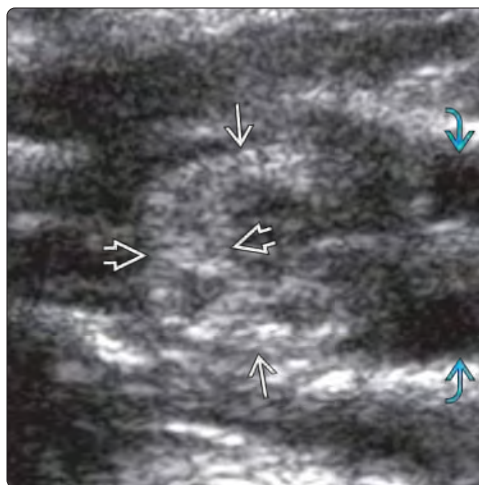
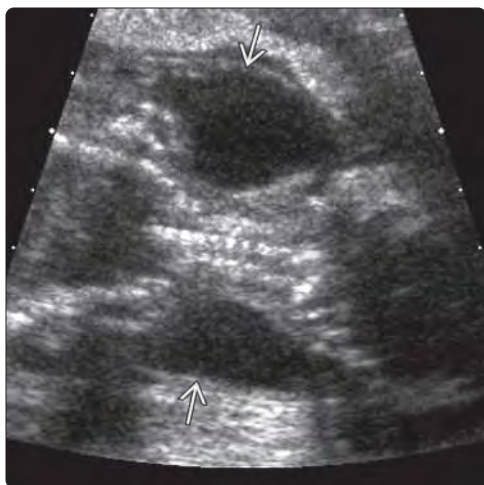- Suspect Turner syndrome when cystic hygroma diagnosed

Image Interpretation Pearls

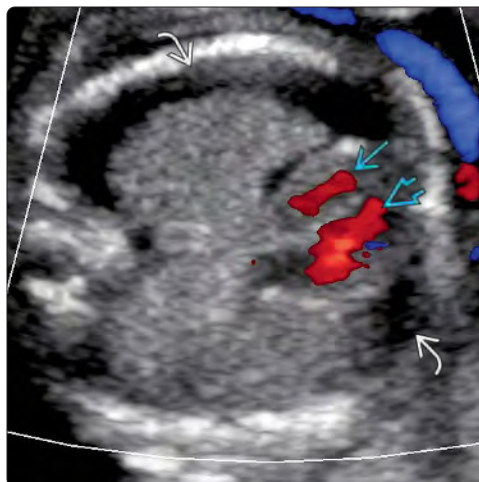
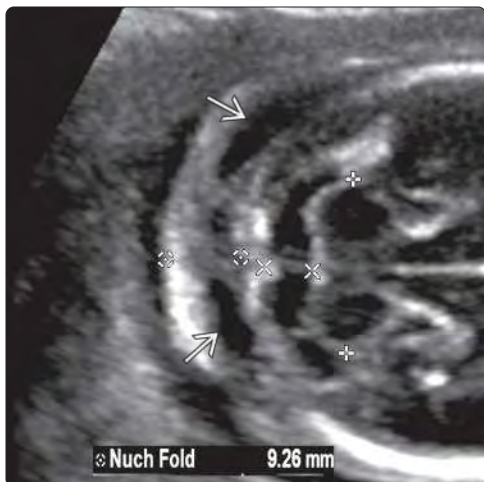
- Obtain routine aorta arch views
- Look for horseshoe kidney

SELECTED REFERENCES

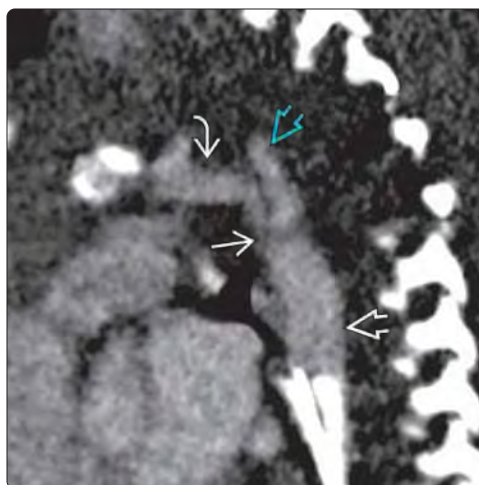
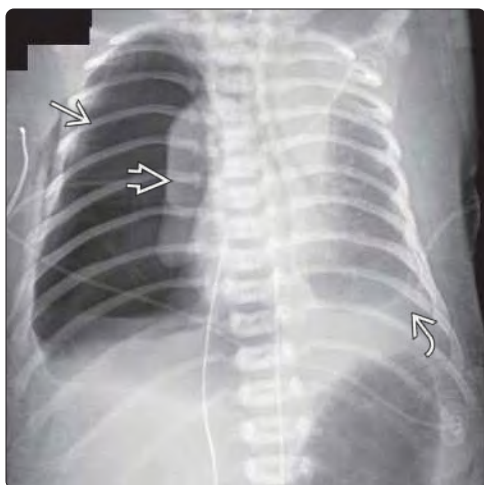
1. Christiansen M et al: Nuchal translucency distributions for different chromosomal anomalies in a large unselected population cohort. *Prenat Diagn.* 36(1):49-55, 2015
2. Levitsky LL et al: Turner syndrome: update on biology and management across the life span. *Curr Opin Endocrinol Diabetes Obes.* 22(1):65-72, 2015
3. Hooks J et al: Non-invasive risk assessment of fetal sex chromosome aneuploidy through directed analysis and incorporation of fetal fraction. *Prenat Diagn.* 34(5):496-9, 2014
4. Papp C et al: Prenatal diagnosis of Turner syndrome: report on 69 cases. *J Ultrasound Med.* 25(6):711-7; quiz 718-20, 2006



(Left) In this fetus with Turner syndrome and oligohydramnios, the lateral neck cystic hygroma mimics pockets of amniotic fluid. If necessary, cystic hygroma fluid can be aspirated and sent for genetic analysis. (Right) In the same fetus, bilateral pleural effusions and a horseshoe kidney are seen. The renal parenchyma is echogenic, suggesting parenchymal dysplasia, and the inferior poles are joined via an isthmus. This fetus suffered in utero demise.



(Left) In this fetus with monosomy X, the nuchal fold is thickened and only mildly cystic. Not all fetuses with Turner syndrome have large cystic hygromas. (Right) Axial view through the chest, in the same fetus, shows bilateral pleural effusions and a small left ventricle compared to the right. Aortic coarctation was diagnosed on fetal echocardiogram. Lymphatic malformation and aortic anomalies are hallmark findings with Turner syndrome.



(Left) Chest x-ray of a newborn with Turner syndrome who had large bilateral pleural effusions since midgestation shows a right tension pneumothorax, with shift of the mediastinum and a contracted small right lung, as well as a persistent left pleural effusion. (Right) Sagittal CT reconstruction in the same case shows coarctation of the aorta, which was also suspected in utero. Compare the size of the transverse aortic arch to the descending thoracic aorta. Subclavian artery is noted.

KEY FACTS

TERMINOLOGY

- Synonym: Partial mole
- Definition: 69 chromosomes (entire extra haploid set)
 - Diandric triploidy is more common (extra set is paternal)
 - Digynic triploidy (extra set is maternal)

IMAGING

- Diandric triploidy phenotype
 - Large cystic placenta (hydropic)
 - Symmetric fetal growth restriction (FGR)
 - Ovaries enlarged with theca lutein cysts
- Digynic triploidy phenotype
 - Normal or small placenta
 - Asymmetric FGR (relative macrocephaly)
- Multiple anomalies (none pathognomonic)
- 1st-trimester findings
 - Abnormal gestational sac in early 1st trimester
 - Abnormal anatomy at nuchal translucency screening

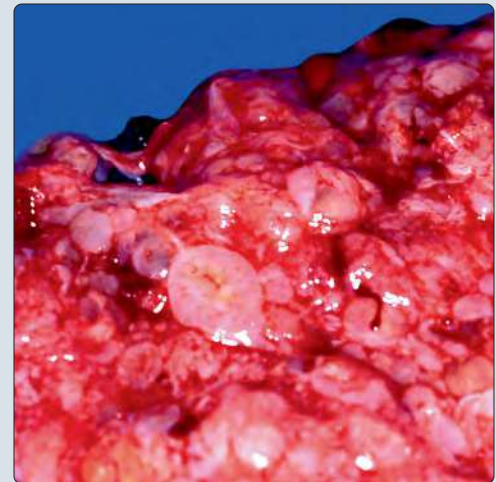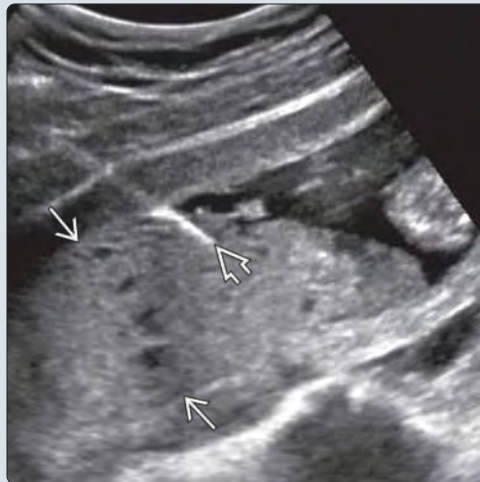
TOP DIFFERENTIAL DIAGNOSES

- Twin molar pregnancy
 - Hydatidiform mole with coexistent fetus
- Placental hydropic change
 - Failed pregnancy (fetal/embryonic demise)
- Placental mesenchymal dysplasia
 - Associated with preeclampsia
- Trisomy 18 and 13

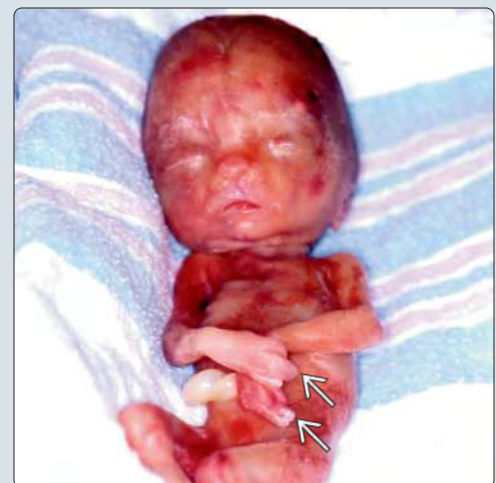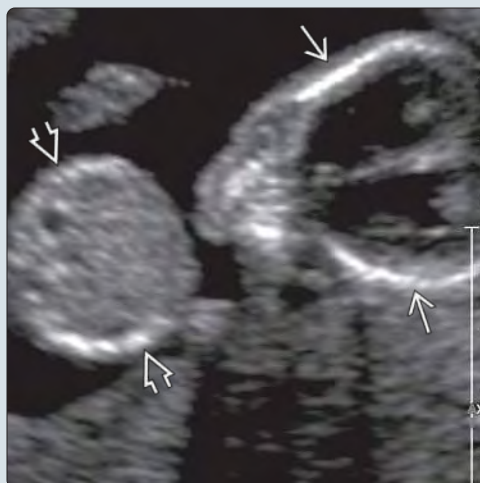CLINICAL ISSUES

- Maternal complications
 - Preeclampsia
 - Placental abruption
 - Postpartum hemorrhage
- Triploidy considered a fatal diagnosis
 - Most with intrauterine fetal demise
 - Lethal in neonatal period if live birth

(Left) Ultrasound-guided chorionic villus sampling is performed in this 13-week pregnancy with a thick cystic placenta and early fetal growth restriction. The needle tip is seen within the placenta. Noninvasive testing can not reliably detect triploidy at this time. **(Right)** Photograph of the placenta from a triploid pregnancy shows typical hydropic villi, which give the placental surface an irregular, cystic appearance. This placental phenotype is seen mostly with diandric triploidy.



(Left) Relative macrocephaly is seen in this early 2nd-trimester fetus with triploidy. The head is significantly larger than the abdomen, although, both were smaller than expected for gestational age. This fetal phenotype is typical for digynic triploidy. **(Right)** Clinical photograph of a fetus shows the typical features of triploidy. Note the relative small size of the body to the head. There is also bilateral syndactyly of the 3rd and 4th digits, a common feature in triploidy.



TERMINOLOGY

Synonyms

- Partial mole

Definitions

- 69 chromosomes (entire extra haploid set)
 - Diandric triploidy = extra set is paternal (more common)
 - Digynic triploidy = extra set is maternal

IMAGING

General Features

- Best diagnostic clue
 - Early fetal growth restriction (FGR)
 - Often asymmetric
 - Multiple fetal anomalies
 - Cystic placenta

Ultrasonographic Findings

- Findings vary depending on extra chromosome source
 - **Diandric triploidy phenotype**
 - Large cystic placenta (hydropic)
 - Symmetric FGR
 - Ovaries enlarged with theca lutein cysts
 - **Digynic triploidy phenotype**
 - Normal or small placenta
 - Profound asymmetric FGR
 - Relative macrocephaly + small body
- Early and severe FGR is hallmark finding
 - Often seen as early as 11-14 weeks
- Multiple anomalies (none pathognomonic)
 - Central nervous system (60%)
 - Dandy-Walker malformation
 - Ventriculomegaly
 - Neural tube defects
 - Holoprosencephaly spectrum
 - Cardiac defects (42%)
 - Face/neck
 - Cystic hygroma and hydrops
 - Eye anomalies: Hypertelorism, microphthalmia
 - Cleft lip/palate, micrognathia
 - Musculoskeletal
 - Syndactyly of 3rd and 4th digit
 - Clubbed feet
 - Gastrointestinal
 - Omphalocele (bowel-containing)
 - Genitourinary
 - Hydronephrosis, renal cystic dysplasia
 - Disorders of sexual differentiation
 - Single umbilical artery
 - Oligohydramnios
 - 1st-trimester findings
 - Abnormal gestational sac trophoblast
 - Empty irregular gestational sac
 - Abnormal anatomy at time of nuchal translucency (NT) screening
 - NT often normal
 - Additional anomalies and FGR detectable

Imaging Recommendations

- Best imaging tool
 - When to have high index of suspicion
 - Large cystic placenta
 - Severe early FGR
 - Enlarged ovaries with multiple follicles (theca lutein cysts)
- Protocol advice
 - Perform transvaginal ultrasound for fetal anatomy
 - Look for anomalies at time of NT scan
 - 85% have detectable 1st-trimester anomaly

DIFFERENTIAL DIAGNOSIS

Hydatidiform Mole + Coexistent Fetus (Twin)

- Look for separate, normal-appearing placenta
- Unlike triploidy, fetus with normal anatomy/growth

Placental Hydropic Change in Fetal Demise

- Can look identical to triploidy with demise
- Pathologist makes diagnosis
 - No trophoblastic proliferation

Placental Lakes

- Fetus is normal
- Commonly seen after 20 weeks
- Look for slow blood flow
- Often change size and shape during examination

Placental Mesenchymal Dysplasia

- Placental pseudo-moles
- Seen with preeclampsia and FGR
- Associated with
 - Placentomegaly
 - Beckwith-Wiedemann syndrome

Infection With Fetal Growth Restriction

- Fetal findings
 - Ventriculomegaly
 - Intracranial and intrahepatic calcifications common
- Positive maternal serology

Trisomy 18

- FGR
- Multiple fetal anomalies
- Placenta most often normal or small

Trisomy 13

- Holoprosencephaly is hallmark anomaly
- Renal dysplasia, polydactyly
- FGR does not manifest as early

PATHOLOGY

General Features

- Etiology
 - Diandric (paternal extra chromosome set)
 - Dispermy (most common)
 - Ovum fertilized with 2 sperm
 - Fertilization with diploid sperm
 - Digynic (maternal extra chromosome set)
 - Diploid egg

- Tetraploidy may also occur
 - 4 sets of chromosomes
 - Ratio of tetraploidy:triploidy is 1:3
 - Rarely progress past 1st trimester
- Genetics
 - 85% diandric 15% digynic triploidy in recent study
 - Diandric cases
 - 51% with 69,XXY
 - 43% with 69,XXX
 - 6% with 69,XXY
 - No fetus identified in any cases
 - Digynic cases
 - 55% 69,XXX
 - 45% 69,XXY

Microscopic Features

- Diandric placentas with cysts
 - Cystic placental change
 - Enlarged villi (≥ 3 mm)
 - 2 populations of villi in 1 placenta
 - Irregular villi
 - Scalloped borders, trophoblastic inclusions
 - Trophoblastic hyperplasia
- Digynic placentas with trophoblast hypoplasia

CLINICAL ISSUES

Presentation

- Most common signs/symptoms
 - Cell-free fetal DNA (cffDNA) detection is possible but not always reliable
 - Laboratories differ; check before sending sample
 - Digynic cases with low cffDNA fraction
 - Often escape detection
 - Additional SNP microarray can help determine parental origin
 - 11-14 week screening detects 85% of triploidy fetuses
 - Diandric triploidy
 - Mild \uparrow NT
 - \uparrow human chorionic gonadotropin hormone (hCG)
 - \downarrow pregnancy-associated plasma protein A (PAPP-A)
 - Often with screen positive results for trisomy 21
 - Digynic triploidy
 - Normal NT
 - \downarrow hCG
 - \downarrow PAPP-A
 - Screen positive result for trisomy 18 or 13
 - Other ultrasound findings
 - Thick placenta with partial mole
 - Asymmetric FGR
 - Anomalies can be seen early
 - 2nd-trimester maternal screening results
 - Diandric triploidy
 - \uparrow hCG
 - \uparrow α -fetoprotein (AFP)
 - \uparrow inhibin A
 - Digynic triploidy
 - \downarrow hCG
 - \downarrow AFP
 - \downarrow estriol

- Maternal complications
 - Preeclampsia
 - Occurs with diandric triploidy
 - Often presents < 20 weeks
 - Complications from hydropic placenta
 - Placental abruption
 - Postpartum hemorrhage
 - Retained placenta

Demographics

- Age
 - Advanced maternal age not at higher risk
 - Incidence may actually decrease with advancing maternal age
- Epidemiology
 - 1-2% of conceptions
 - 10% of spontaneous abortions
 - 1:6614 at NT screening (11-14 weeks)
 - 1:250,000 at 20 weeks

Natural History & Prognosis

- Most with intrauterine fetal demise
- Lethal in neonatal period if live birth

Treatment

- Offer genetic testing for diagnosis
 - Chorionic villus sampling
 - Amniocentesis
- Termination offered, perinatal hospice
- Monitor mother for preeclampsia
- Avoid fetal monitoring and cesarean delivery

DIAGNOSTIC CHECKLIST

Consider

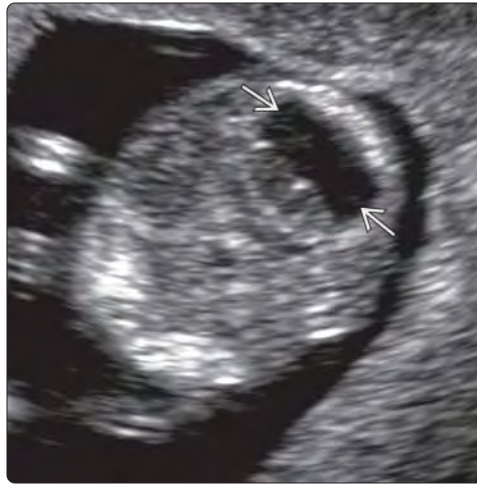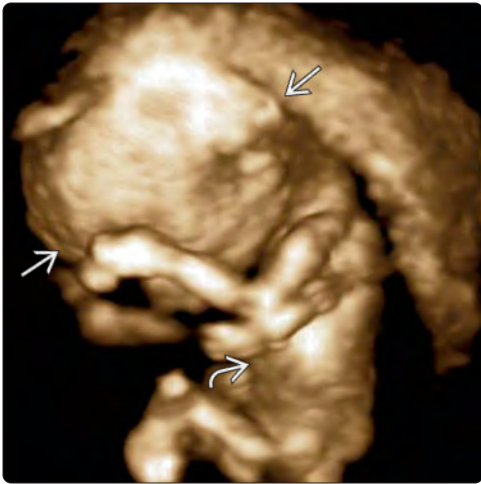- Triploidy diagnosis in cases of early asymmetric growth and relative macrocephaly

Image Interpretation Pearls

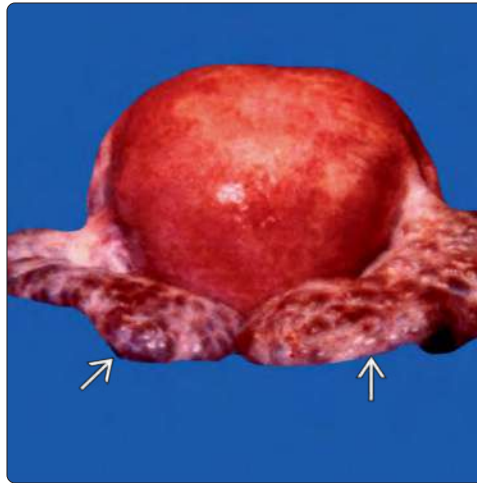
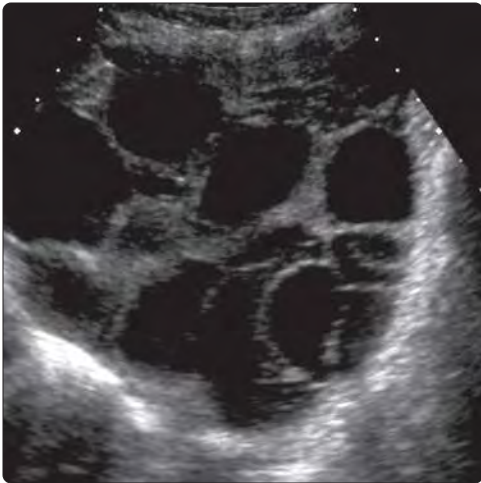
- Be suspicious of triploidy in 2 different circumstances
 - Any time there is an enlarged, cystic placenta and living embryo
 - In setting of severe asymmetric FGR, even if placenta is normal
- 85% have 1 or more anomalies, but no single anomaly is pathognomonic of triploidy
 - Ventriculomegaly + syndactyly is suggestive combination; however, syndactyly is difficult prenatal diagnosis
 - Posterior fossa abnormalities are common
 - Look for anomalies at time of NT scan

SELECTED REFERENCES

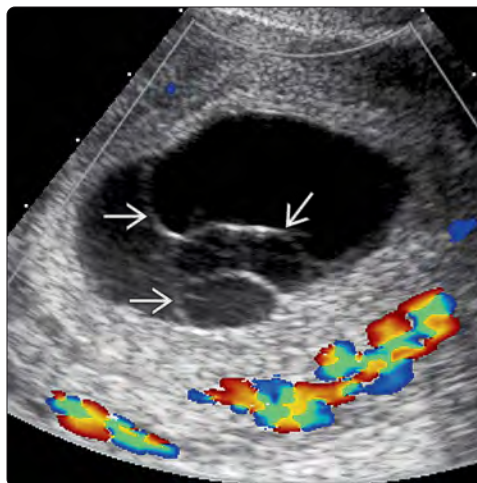
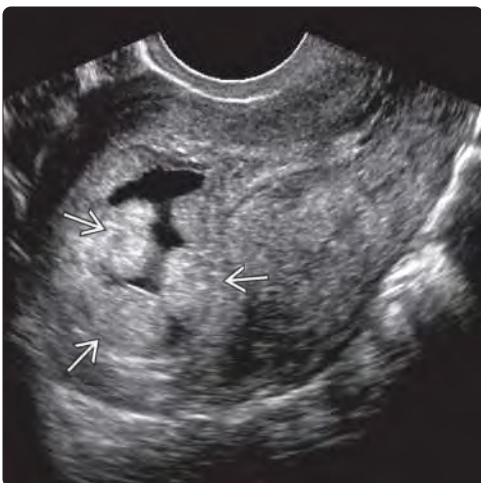1. Fleischer J et al: Digynic triploidy: utility and challenges of noninvasive prenatal testing. *Clin Case Rep.* 3(6):406-10, 2015
2. Wagner P et al: First-trimester screening for trisomy 18, 13, triploidy and Turner syndrome by a detailed early anomaly scan. *Ultrasound Obstet Gynecol.* ePub, 2015
3. Joergensen MW et al: Triploid pregnancies: genetic and clinical features of 158 cases. *Am J Obstet Gynecol.* 211(4):370.e1-19, 2014
4. Nicolaides KH et al: Prenatal detection of fetal triploidy from cell-free DNA testing in maternal blood. *Fetal Diagn Ther.* 35(3):212-7, 2014
5. Lakovscek IC et al: Natural outcome of trisomy 13, trisomy 18, and triploidy after prenatal diagnosis. *Am J Med Genet A.* 155A(11):2626-33, 2011



(Left) 3D ultrasound at the time of nuchal translucency (NT) screening in a fetus with triploidy shows asymmetric fetal size with relative macrocephaly compared to the fetal body. Other fetal anomalies were also seen and chorionic villus sampling performed. **(Right)** Endovaginal ultrasound of the fetal brain at the time of NT screening shows a large posterior fossa cyst in another fetus with triploidy. 85% of fetuses with triploidy have abnormal findings at the time of NT scan, although NT is often normal.



(Left) Ultrasound of the adnexa shows an enlarged cystic ovary in a pregnancy complicated by triploidy. The theca lutein cysts are secondary to high circulating levels of hCG, typically seen with diandric triploidy. **(Right)** Photograph of the uterus and ovaries in another case of triploidy shows bilateral theca lutein cysts within the ovaries.

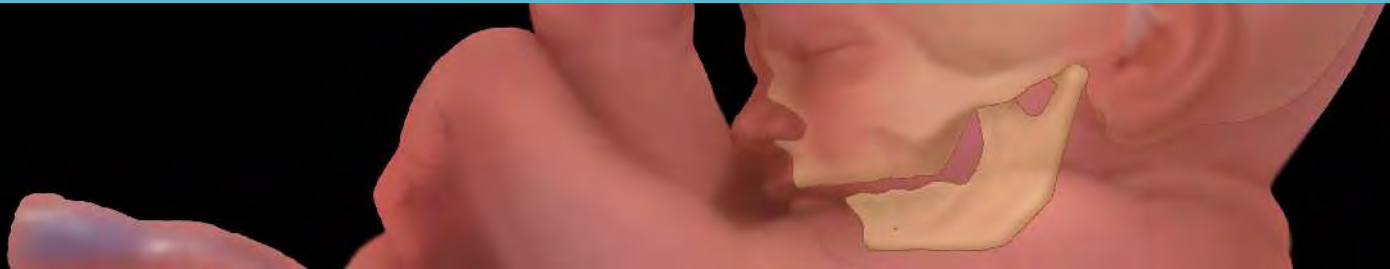


(Left) Multiple echogenic bumps from trophoblastic proliferations protrude into the otherwise empty gestational sac in this amembryonic gestational sac. Genetic testing of products of conception showed triploidy. **(Right)** In another early triploidy case, multiple intracavitary trophoblastic cysts are seen. Triploidy karyotype occurs in 1% of all conceptions and 10% of spontaneous abortions. The 69,XYX karyotype is most typically associated with amembryonic gestation.

This page intentionally left blank

SECTION 13

Syndromes and Multisystem Disorders



22q11 Deletion Syndrome	918
Aicardi Syndrome	920
Amniotic Band Syndrome	924
Apert Syndrome	928
Beckwith-Wiedemann Syndrome	932
Carpenter Syndrome	936
CHARGE Syndrome	938
Cornelia de Lange Syndrome	940
Cystic Fibrosis	944
Diabetic Embryopathy	946
Fraser Syndrome	950
Fryns Syndrome	952
Goldenhar Syndrome	954
Holt-Oram Syndrome	956
Idiopathic Infantile Arterial Calcification	960
Joubert Syndrome	962
Klippel-Trenaunay-Weber Syndrome	966
Meckel-Gruber Syndrome	970
Multiple Pterygium Syndromes	974
Neu-Laxova Syndrome	976
Noonan Syndrome	978
PHACES Syndrome	980
Pfeiffer Syndrome	982
Pierre Robin Sequence	986
Sirenomelia	988
Smith-Lemli-Opitz Syndrome	992
Treacher Collins Syndrome	996
Tuberous Sclerosis	1000
VACTERL Association	1004
Valproate Embryopathy	1008
Warfarin (Coumadin) Embryopathy	1010
Walker-Warburg Syndrome	1012

KEY FACTS

TERMINOLOGY

- Synonyms
 - Velocardiofacial syndrome
 - DiGeorge syndrome
- Syndrome of congenital heart and palatal defects caused by microdeletion of 22q11.2
- 1 of the most recognizable chromosome abnormalities causing heart defects

IMAGING

- Conotruncal heart defects
 - Truncus arteriosus, tetralogy of Fallot
- Cleft palate
- Micrognathia
- Hypertelorism, prominent broad nasal bridge
- Thymic hypoplasia

TOP DIFFERENTIAL DIAGNOSES






- Isolated conotruncal heart defects

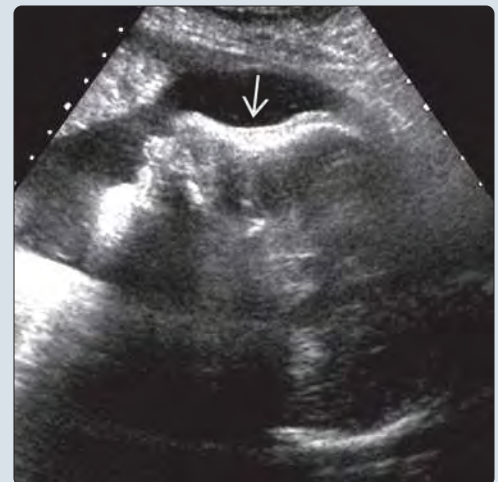
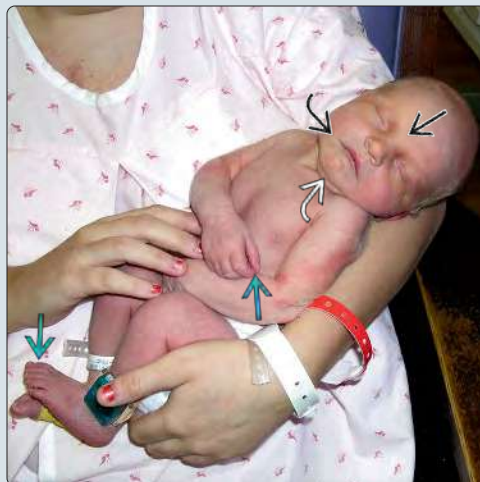PATHOLOGY





- Haploinsufficiency of 3 genes in del22q11.2 [*TBX1*, *CRKL*, *MAPK1 (ERK2)*] cause disruption of neural crest cell migration and abnormalities of development of secondary (anterior) heart field
- Autosomal dominant
 - Most affected individuals with de novo deletion

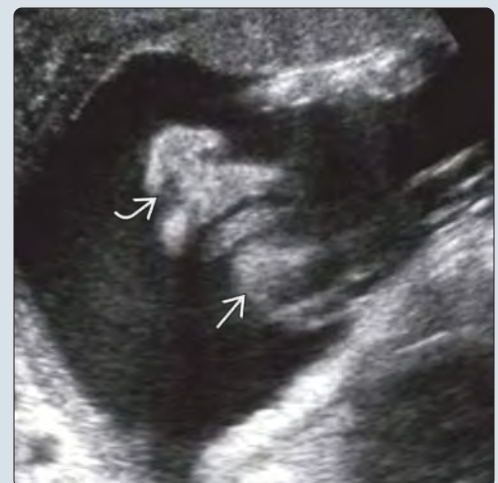
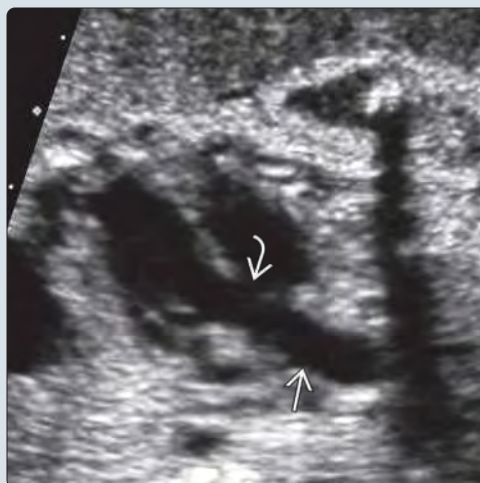
CLINICAL ISSUES

- Phenotype often quite subtle
- Congenital heart disease (74%)
- Palatal abnormalities (69%) including velopharyngeal insufficiency
- Characteristic facial features (majority of patients)
- Learning disabilities (70-90%)
- Immune deficiency (77%)
- Neuropsychiatric problems
 - del22q11.2 may account for up to 1-2% of schizophrenics in general population

(Left) Clinical photograph shows an infant with deletion of 22q11.2. The infant's mother was also affected, with a history of a repaired truncus arteriosus. Note the prominent broad nasal bridge , wide-spaced eyes, thin lips with downturned corners of the mouth , and small jaw . The toes and fingers are also long and thin . **(Right)** Sagittal ultrasound of a 3rd-trimester fetus with known deletion of 22q11.2 shows a classic profile with a prominent nasal bridge .



(Left) Ultrasound of a 25-week fetus shows truncus arteriosus, a typical conotruncal heart defect seen in deletion of 22q11.2. Note the single great vessel  arising over a ventricular septal defect . **(Right)** Coronal ultrasound shows the face of a fetus with deletion of 22q11.2. Note the small chin  and anteverted nares . Although clefts of the palate are often seen in this syndrome, even with an intact palate, velopharyngeal insufficiency is common.



TERMINOLOGY**Synonyms**

- Velocardiofacial syndrome
- DiGeorge syndrome

Definitions

- Syndrome of congenital heart and palatal defects caused by microdeletion of 22q11.2

IMAGING**Ultrasonographic Findings**

- Conotruncal heart defects
 - Truncus arteriosus
 - Right-sided aortic arch and abnormal branching common
 - Interrupted aortic arch
 - Tetralogy of Fallot
 - Tetralogy with absent pulmonary valve or pulmonary atresia
- Cleft palate
 - Difficult to diagnose in absence of cleft lip
- Micrognathia
- Hypertelorism, prominent broad nasal bridge
- Thymic hypoplasia
 - Measure thymus and compare to normative data

DIFFERENTIAL DIAGNOSIS**Isolated Conotruncal Heart Defect**

- Always look for other abnormalities that would suggest syndrome or aneuploidy

PATHOLOGY**General Features**

- Etiology
 - Haploinsufficiency of 3 genes in del22q11.2 [*TBX1*, *CRKL*, *MAPK1 (ERK2)*] cause disruption of neural crest cell migration and abnormalities of development of secondary (anterior) heart field
- Genetics
 - Autosomal dominant with variable penetrance
 - Most affected individuals with de novo deletion (93%); 7% inherited from parent
 - Significant inter- and intrafamilial variation despite same 3-4 Mb deletion (involves minimum of 22 contiguous genes)
 - Diagnosis
 - Cannot be diagnosed on routine karyotype; 1 of the following required
 - FISH analysis with probe at *HIRA* (TUPLE1) gene
 - Multiplexed quantitative real-time PCR may detect hemizygous deletion
 - Comparative genomic hybridization microarray

CLINICAL ISSUES**Presentation**

- Postnatal signs and symptoms
 - Phenotype often quite subtle

- Congenital heart disease (74%)
 - Conotruncal malformations most common
- Palatal abnormalities (69%)
 - Velopharyngeal insufficiency, submucosal cleft palate, cleft palate with resultant difficulties with speech
- Characteristic facial features (majority of patients)
 - Prominent broad nasal bridge, widely spaced eyes, downturned mouth, small recessed jaw, anteverted nares, bulbous nasal tip
- Long thin fingers and toes
- Learning disabilities (70-90%)
- Immune deficiency (77%)
 - Thymic hypoplasia/aplasia with associated T-cell defects
- Hypocalcemia (50%)
- Neuropsychiatric problems
 - Schizophrenia (25-30% risk)
 - del22q11.2 may account for up to 1-2% of schizophrenics in general population
 - Psychosis, autism, attention deficit/hyperactivity disorder, depression
- Hearing loss
- Laryngotracheoesophageal anomalies
- Autoimmune disorders
- Seizures

Demographics

- 1/3,000 live births

Treatment

- Genetic counseling in all cases
- Examination of parents by clinical geneticist to evaluate for subtle findings
- Prenatal diagnosis by FISH analysis of amniocytes in high-risk pregnancies based on affected parent or finding of conotruncal heart defect ± cleft palate
 - Noninvasive testing via cell free fetal DNA in maternal blood becoming more available
- Delivery in tertiary care center
- Monitoring and treatment of hypocalcemia
- Surgical management of heart defects

DIAGNOSTIC CHECKLIST**Image Interpretation Pearls**

- Increased suspicion of del22q11.2 in cases with conotruncal heart defects with aortic arch and ductus arteriosus abnormalities

SELECTED REFERENCES

1. Gross SJ et al: Clinical experience with single-nucleotide polymorphism-based noninvasive prenatal screening for 22q11.2 deletion syndrome. *Ultrasound Obstet Gynecol.* 47(2): 177-83, 2015
2. Tang KL et al: Behavioral and psychiatric phenotypes in 22q11.2 deletion syndrome. *J Dev Behav Pediatr.* 36(8):639-50, 2015

KEY FACTS

TERMINOLOGY

- Described in 1965 as clinical triad of infantile spasms, agenesis of corpus callosum, and chorioretinal lacunae
- Phenotype now known to be more complex

IMAGING

- Agenesis of corpus callosum is most consistent finding in fetus
- Cortical dysplasia
- Intracranial cysts in 25-100% depending on series
- Cerebellar anomalies in 6-95% depending on series
- Microphthalmia

TOP DIFFERENTIAL DIAGNOSES

- Agenesis/dysgenesis of corpus callosum
 - Isolated or syndromic
- Dandy-Walker malformation
- Arachnoid cyst
- Intracranial hemorrhage

PATHOLOGY





- Seen only in females and 47,XXY karyotype
 - Must have 2 X chromosomes
 - Probable X-linked dominant with early embryonic lethality in hemizygous males
- Affected females do not reproduce; therefore, all cases thought to be new mutations

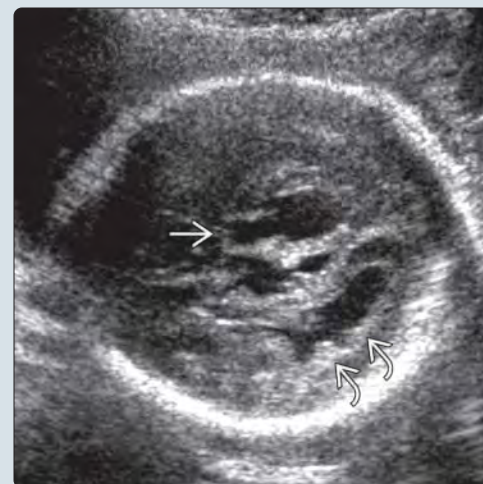
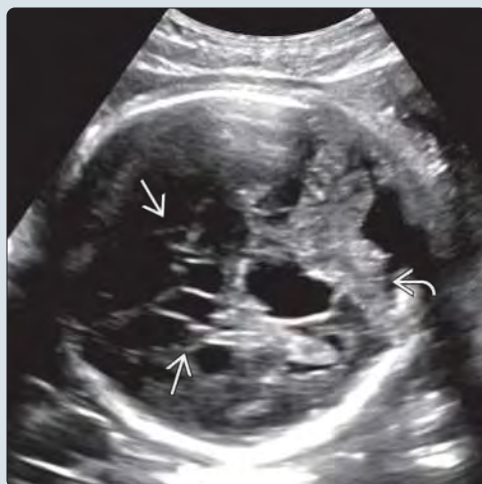
CLINICAL ISSUES




- USA incidence 1:105,000 live births
- Estimated survival rate of 76% at 6 years, 40% at 14 years
 - Risk of death peaked at age 16 in 1 series
- Median age of survival estimated at 18.5 ± 4 years
- Intractable seizures

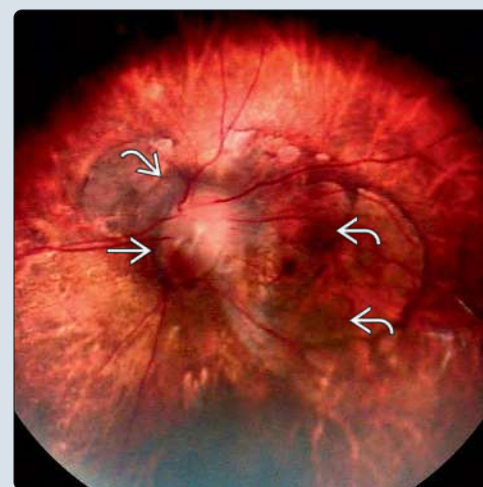
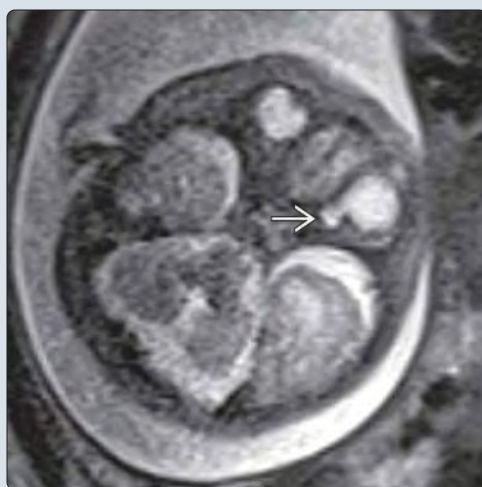DIAGNOSTIC CHECKLIST

- Consider Aicardi syndrome in female fetus with callosal agenesis/dysgenesis, especially if posterior fossa abnormalities or abnormal cortical mantle

(Left) 3rd-trimester US to follow a "simple" interhemispheric cyst showed a more complex midline cystic structure , as well as a dysplastic cerebellar hemisphere . Final diagnosis was Aicardi syndrome. **(Right)** Axial US of the brain in a 2nd-trimester fetus shows a complex interhemispheric cyst  and nodular gray matter heterotopia . MR was performed for further evaluation; the diagnosis of Aicardi syndrome was suggested and subsequently confirmed by postnatal ophthalmic exam.



(Left) Axial T2WI shows an optic nerve coloboma . This observation in a female fetus with agenesis of the corpus callosum (ACC), cortical dysplasia, and vermian rotation led us to suggest Aicardi syndrome. The diagnosis was confirmed by ophthalmic exam. **(Right)** Clinical photograph of funduscopy in a patient with Aicardi syndrome shows the typical appearance of chorioretinal lacunae  and optic nerve head coloboma  in this condition.



TERMINOLOGY

Definitions

- Clinical triad of infantile spasms, agenesis of corpus callosum (ACC), and chorioretinal lacunae described in 1965
- In 1999, criteria broadened to include 2 classic + 2 other major or supporting features
 - Major features
 - Cortical malformation (mostly polymicrogyria)
 - Periventricular/subcortical heterotopia
 - Cysts around third ventricle/choroid plexus
 - Choroid plexus papilloma
 - Optic disc/nerve coloboma
 - Supporting features
 - Costovertebral abnormalities
 - Microphthalmia or other eye abnormalities
 - Gross cerebral hemispheric asymmetry

IMAGING

General Features

- Best diagnostic clue
 - ACC in female fetus

Ultrasonographic Findings

- Callosal agenesis/dysgenesis
 - Absent cavum septi pellucidi (CSP) if ACC
 - Parallel lateral ventricles
 - Colpocephaly
 - Correlates strongly with both agenesis/dysgenesis
 - Use TVUS ± 3D volume acquisition to show CC in sagittal view
 - Look for the anchor-shaped "anterior complex" to identify genu of CC on axial views
 - From posterior to anterior, this consists of: CSP (between frontal horns), genu of CC, pericallosal sulcus, anterior interhemispheric fissure
- Intracranial cysts
- Choroid plexus cysts/papillomas
- Cerebellar malformation
 - Dandy-Walker malformation
 - Vermian dysgenesis
- May have microcephaly
- Facial asymmetry
 - 3D surface reconstructions very helpful
- Microphthalmia
- Vertebral segmentation anomalies

MR Findings

- MR findings are described on postnatal series, but fetal MR allows documentation of many of these features
 - Callosal abnormalities reported in majority of cases
 - Agenesis (66%)
 - Dysgenesis (33%)
 - Scattered reports of cases without callosal malformation
 - Intracranial cysts in 25-100% depending on series
 - Single > multiple
 - Intra- and extraaxial
 - Midline, intraventricular, pineal, posterior fossa
 - Choroid plexus cyst/papilloma

- Cortical dysplasia varies significantly between series
 - Cortical heterotopias
 - Bilateral > unilateral
 - Periventricular with most common location along body of lateral ventricle
 - Single nodules > confluent row
 - Pachygyria
 - Polymicrogyria
 - Postnatal series demonstrated 100% predominantly frontal/perisylvian
 - Often associated with underopercularization of sylvian fissure
 - Opercular abnormalities
 - Cerebral hemisphere asymmetry in 20-100% depending on series
- Cerebellar anomalies in 6-95% depending on series
 - Superior foliar prominence of vermis, inferior vermian hypoplasia
 - Dysplastic or hypoplastic cerebellar hemispheres with associated large cisterna magna
 - Subcortical &/or periventricular cerebellar heterotopias
 - Cerebellar intraparenchymal cysts and extraaxial cysts
- Tectal enlargement in 43% in 1 series
- Pituitary abnormalities

Imaging Recommendations

- In fetuses with ACC
 - Check gender
 - Careful evaluation of spine for segmentation anomalies
 - Evaluate face for ocular abnormalities
 - 3D surface reconstructions can be helpful
 - Check both eyes present, normal in size, lenses present
 - Look at brain in several imaging planes, from multiple access points with different transducers
 - Nodular ventricular lining suggests heterotopia
 - Look at opercularization of sylvian fissures: Abnormal opercularization correlates with cortical dysplasia
 - At 24 weeks, insular cortex makes 90° angle with temporal lobe
 - By 28 weeks, posterior half of insular cortex is 50% covered
 - By 32 weeks, posterior half of insular cortex is fully covered
 - Look at development of gyri and sulci over time
 - Helps with recognition of asymmetric hemispheres
- MR extremely helpful to assess for associated cortical and cerebellar anomalies that may refine diagnosis/determine prognosis
 - Serial US and MR studies important to show full spectrum of findings
 - Not all features are apparent at 18-20 weeks anatomy scan

DIFFERENTIAL DIAGNOSIS

Agenesis/Dysgenesis of Corpus Callosum

- Isolated or syndromic
- Aicardi syndrome is only one of many associations
- Prognosis for ACC is variable

- Important to make as specific diagnosis as possible

Dandy-Walker Malformation

- Isolated or syndromic
- Prognosis for posterior fossa anomalies is worse with associated supratentorial brain findings

Arachnoid Cyst

- Isolated cyst
- No cortical dysplasia
- Normal corpus callosum

Intracranial Hemorrhage

- May cause ventriculomegaly, nodular ventricular lining
 - Adherent clot, ependymitis
 - Changes over time; heterotopia does not
- Porencephalic cyst may be confused with other intracranial cysts
 - Porencephalic cysts replace destroyed brain
 - Space-occupying cysts displace adjacent brain, no associated signs of hemorrhage
- Not associated with microphthalmia, costovertebral defects

PATHOLOGY

General Features

- Genetics
 - Seen only in females and 47,XXY karyotype (i.e., must have 2 X chromosomes)
 - Probable X-linked dominant with early embryonic lethality in hemizygous males
 - Affected females do not reproduce; therefore, all cases thought to be new mutations
 - Single report of recurrence in 2 siblings attributed to possible germinal mosaicism
 - Concordant and discordant twins reported
 - Locus at Xp22.3 has been suggested but not confirmed
- Associated abnormalities
 - Ocular findings
 - Microphthalmia
 - Coloboma
 - Optic nerve/chiasmal hypoplasia
 - Retinal migrational defects
 - Costovertebral defects in ~ 39%
 - Hemivertebrae
 - Scoliosis
 - Absent/malformed ribs
 - Infrequent association with cleft lip and palate

CLINICAL ISSUES

Presentation

- ACC is most consistent finding in fetus

Demographics

- Epidemiology
 - 1 per 105,000 live births in USA
 - USA prevalence > 853 cases; worldwide estimate is several thousand

Natural History & Prognosis

- Once thought to be associated with high early childhood mortality, severe intellectual impairment, and seizures
- Newer data
 - Estimated survival rate of 76% at 6 years, 40% at 14 years
 - Risk of death peaked at age 16 in one series
 - Median age of survival estimated at 18.5 ± 4 years
 - Maximum developmental level ~ 12-month-old in 91%
 - Small proportion are only moderately or mildly developmentally delayed
 - Sparing of macula and smaller lacunar size correlate with better vision
- Infantile spasms
 - Mean age of onset at 9 weeks
 - Majority progress to intractable seizure disorder
 - Refractory to medical therapy
 - Variable response to surgical procedures
 - Corpus callosotomy
 - Vagus nerve stimulator implantation

DIAGNOSTIC CHECKLIST

Consider

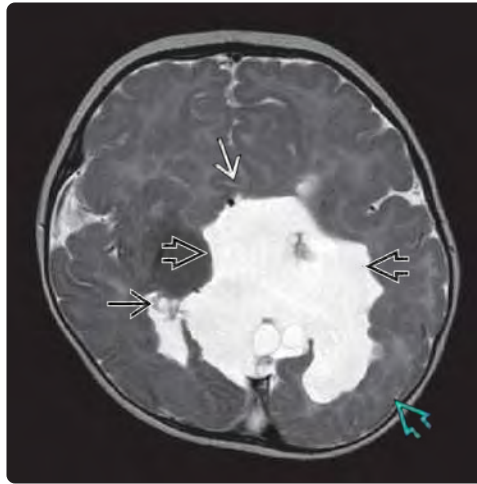
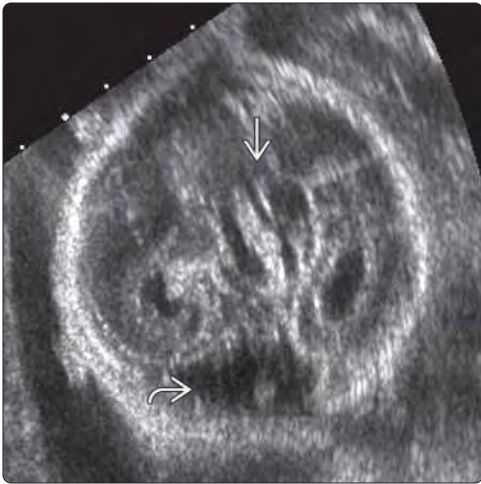
- Initial description in 1965 based on clinical presentation
 - Phenotype now known to be more complex
 - Broad spectrum of abnormal findings on neuroradiology imaging and clinical exam







Image Interpretation Pearls

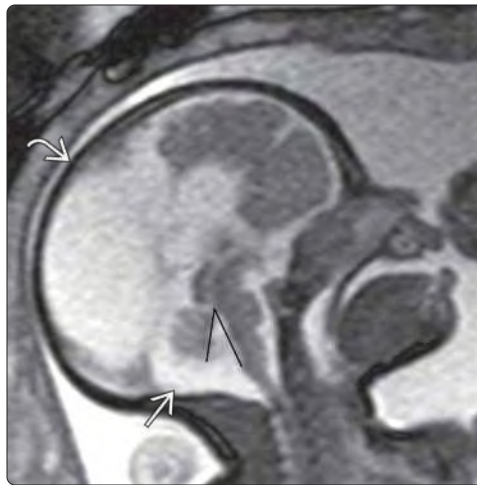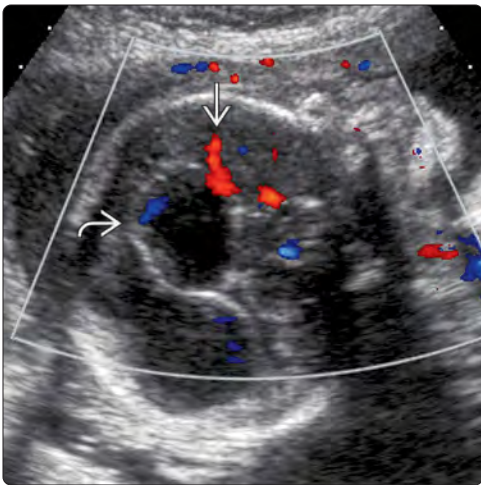
- Consider Aicardi syndrome in female fetus with ACC, especially if posterior fossa abnormalities or abnormal cortical mantle
- Aicardi syndrome remains clinical diagnosis
 - No characteristic facial phenotype or genetic testing for confirmation of diagnosis
 - Chorioretinal lacunae on ophthalmologic exam are pathognomonic for the disorder





SELECTED REFERENCES

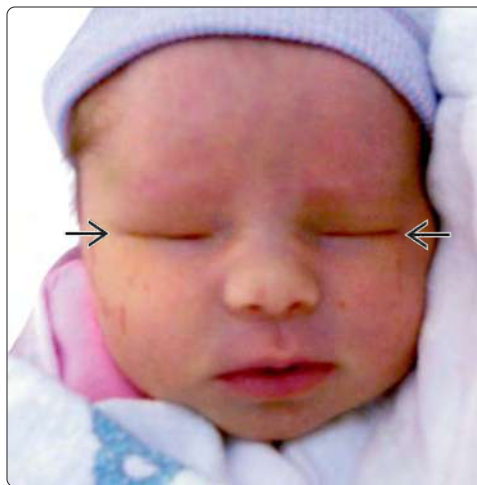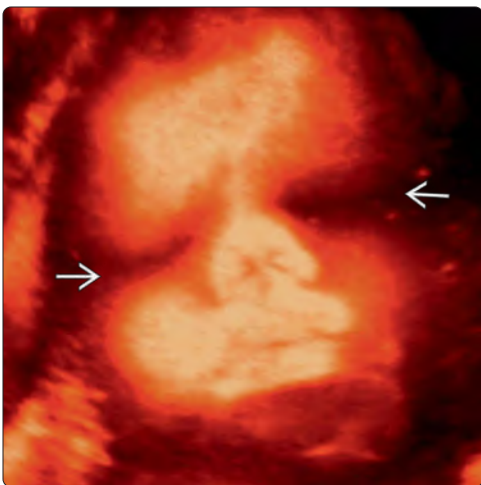1. Kasasbeh AS et al: Palliative epilepsy surgery in Aicardi syndrome: a case series and review of literature. *Childs Nerv Syst.* 30(3):497-503, 2014
2. Pires CR et al: Aicardi syndrome: Neonatal diagnosis by means of transfontanelar ultrasound. *World J Radiol.* 6(7):511-4, 2014
3. Hergan B et al: Serial fetal MRI for the diagnosis of Aicardi syndrome. *Neuroradiol J.* 26(4):380-4, 2013
4. Sandhu PS et al: Novel presentation of Aicardi syndrome with agenesis of the corpus callosum and an orbital cyst. *J Ultrasound Med.* 29(5):843-6, 2010
5. Columbano L et al: Prenatal diagnosed cyst of the quadrigeminal cistern in Aicardi syndrome. *Childs Nerv Syst.* 25(5):521-2, 2009
6. Muthugovindan D et al: Aicardi syndrome mimicking intrauterine hydrocephalus. *Brain Dev.* 31(8):638-40, 2009
7. Steffensen TS et al: Cerebellar migration defects in aicardi syndrome: an extension of the neuropathological spectrum. *Fetal Pediatr Pathol.* 28(1):24-38, 2009
8. Hopkins B et al: Neuroimaging aspects of Aicardi syndrome. *Am J Med Genet A.* 146A(22):2871-8, 2008
9. Glasmacher MA et al: Phenotype and management of Aicardi syndrome: new findings from a survey of 69 children. *J Child Neurol.* 22(2):176-84, 2007
10. Aicardi J: Aicardi syndrome. *Brain Dev.* 27(3):164-71, 2005
11. Rosser T: Aicardi syndrome. *Arch Neurol.* 60(10):1471-3, 2003
12. Rosser TL et al: Aicardi syndrome: spectrum of disease and long-term prognosis in 77 females. *Pediatr Neurol.* 27(5):343-6, 2002





(Left) Coronal US shows a complex interhemispheric cyst , asymmetric cerebral hemispheres, and a posterior fossa cyst . (Right) Axial postnatal MR in the same infant confirms a complex brain malformation with ACC  (denotes where it should be seen), a complex interhemispheric cyst , choroid plexus cyst , asymmetric cerebral hemispheres, and cortical dysplasia .



(Left) Sagittal color Doppler image shows abnormal branching of the anterior cerebral artery , which should normally give rise to branches running posteriorly along the CC. There is an interhemispheric cyst  in association with the ACC in this case. (Right) Sagittal T2WI shows an enlarged cisterna magna  and abnormal vermian rotation (black lines; normal angle is 0°) in a fetus with ACC and large interhemispheric cyst .



(Left) 3D surface-rendered image of the face in a fetus with a complex brain malformation is suspicious for shallow orbits . (Right) Clinical photograph of the same case shows microphthalmia . The prenatal constellation of findings, including callosal dysgenesis, choroid plexus cysts, interhemispheric cyst, microphthalmia, and vertebral segmentation anomalies, was highly suggestive of Aicardi syndrome. Postnatal retinal evaluation was diagnostic.

KEY FACTS

TERMINOLOGY

- Controversial as to etiology, but simplest concept is entrapment of fetal parts by disrupted amnion

IMAGING

- Asymmetric distribution of defects is hallmark of syndrome
- Craniofacial deformities often severe
- Abdominal wall defects are large, complex, often complete evisceration
- Edema of extremity distal to constricting band may progress to limb amputation
 - Doppler flow distal to constriction used to identify potential cases for fetal surgery
 - Abnormal, but present blood flow distal to band may identify cases suitable for fetal surgery
 - 50% salvage rate in largest review to date
- Amniotic band may be tightly adherent and difficult to see
 - Look for restricted movement of involved area

- Change of maternal position may "float" fetus away from uterine wall, revealing short band

TOP DIFFERENTIAL DIAGNOSES

- Body stalk anomaly
- Developmental craniofacial or abdominal wall defects
 - All have defined anatomic distributions from embryologic development

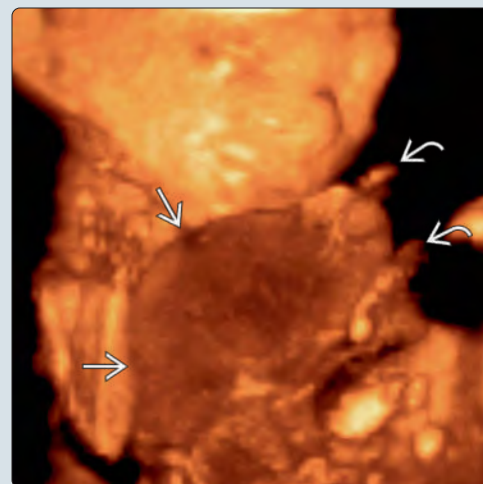
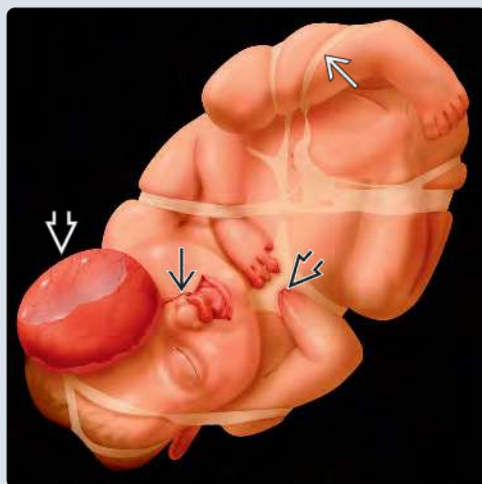
CLINICAL ISSUES

- Defects range from minor to lethal
 - Termination offered for major defects (cranial defects, large abdominoschisis)
 - In utero lysis of bands for at-risk extremity
- Risk of premature rupture of membranes, prematurity, and low birth weight

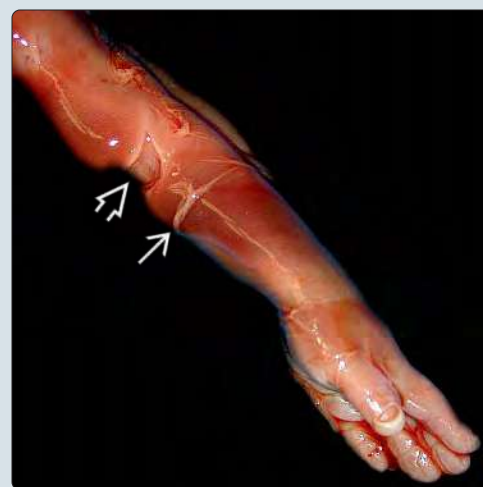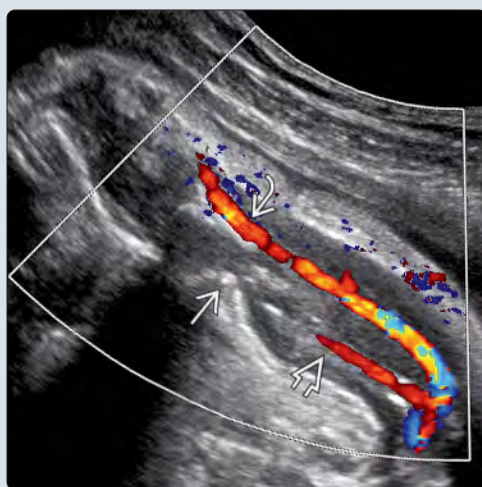
DIAGNOSTIC CHECKLIST

- Always consider amniotic band syndrome with unusual abdominal wall or cranial defects

(Left) Graphic shows various manifestations of amniotic band syndrome (ABS); these include deformations like extremity constriction and amputation and disruptions like facial cleft and cephalocele. (Right) 3D reconstruction in a case with abdominoschisis (considered a malformation within the spectrum of findings seen in ABS) shows the fetus with its chin resting on extruded liver. Note the bands adhering to the edges of the abdominal wall defect and floating within the amniotic fluid.



(Left) Color Doppler US at 37 weeks shows a tight constriction band around the left calf with compromised flow in the posterior tibial artery. The anterior tibial artery is unaffected with good flow distal to the constriction. The infant had only extremity involvement and has done well with plastic surgery. (Right) Gross pathology from another case shows skin necrosis from a constriction band. Another band is seen encircling the forearm.



TERMINOLOGY

Synonyms

- ADAM (amniotic deformity, adhesion, mutilation)

Definitions

- Controversial but simplest concept is entrapment of fetal parts by disrupted amnion

IMAGING

General Features

- Isolated or multiple defects with no specific pattern
 - Cranium, body wall with bizarre "slash" defects
- Asymmetric distribution of defects is hallmark of syndrome

Ultrasonographic Findings

- Bands in amniotic fluid appear as multiple thin membranes
 - May be difficult to discern, especially with oligohydramnios
 - May restrict fetal motion
- Extremity defects are most common manifestation
 - Usually involve fingers and toes
 - Easily missed if isolated
 - Constriction with edema of distal extremity
 - Clubbed feet and hands
 - Multiple joint contractures
 - Pseudosyndactyly (fusion of distal digits)
- Face and head
 - Facial clefts
 - Single orbital involvement typical
 - Cephaloceles in location other than along sutures
- Chest wall defects
 - Ectopia cordis, rib clefts
- Abdominal wall defects
 - Gastroschisis-like bowel extrusion, omphalocele-like liver herniation, bladder exstrophy
- Oligohydramnios attributed to resorption of fluid leaking between amnion and chorion

Imaging Recommendations

- If unusual distribution of defects, look carefully for bands
 - Scan patient in varying positions
 - Fetus stays in fixed position
 - Bands restrict movement of involved area
 - Change of maternal position may "float" fetus away from uterine wall, revealing short band
- Use color Doppler to assess extremity perfusion
 - Measure pulsatility index proximal to, at, and distal to constriction band
 - In normal conditions, flow should be symmetrical and reproducible between both sides
 - Abnormal but present blood flow distal to constricted area may identify cases suitable for fetal surgery
 - Pitfalls to Doppler analysis include growth restriction (IUGR) or single umbilical artery
 - IUGR → asymmetric upper extremity (UE) flow
 - Left UE flow < right UE flow as "brain sparing" increases flow through brachiocephalic and left common carotid arteries
 - Single umbilical artery
 - Asymmetric flow in iliac, femoral arteries

- Careful surveillance of monozygotic twins after treatment for twin-to-twin transfusion
 - Up to 2% incidence of extremity or cord entrapment by iatrogenic bands

DIFFERENTIAL DIAGNOSIS

Body Stalk Anomaly

- Fetal abdominal wall adherent to placenta
- Amnion in continuity with peritoneum
- Absent or short umbilical cord
- Scoliosis major finding

Other "Open" Defects

- All have defined anatomic distributions from embryologic development
 - Anencephaly
 - Both orbits remain
 - Cephalocele
 - Cleft lip
 - Gastroschisis
 - Omphalocele

Amniotic Sheets

- Amnion wrapping around synechiae, thick at base with thin free edge
- Fetus structurally normal, freely mobile

Chorioamniotic Separation

- Normal in early pregnancy, never entrap fetal parts
- May occur post procedure
- May be associated with aneuploidy

PATHOLOGY

General Features

- Genetics
 - Sporadic, not associated with aneuploidy
 - Rare recurrence risk in association with Ehlers-Danlos syndrome and epidermolysis bullosa
- Described risk factors
 - Drugs: Methadone, lysergic acid diethylamide
 - Maternal trauma, intrauterine device, amniocentesis
 - Ehlers-Danlos syndrome, osteogenesis imperfecta, epidermolysis bullosa
- Etiology incompletely understood; proposed theories do not completely explain all findings
 - Amnion rupture theory
 - Fetus parts pass through defect, become entrapped between amnion and chorion
 - Loss of fluid through defect → oligohydramnios
 - Vascular constriction → edema → deformity or amputation
 - Severity of defects thought to correlate with gestational age at occurrence (early = more severe)
 - Estimated gestational age at time of insult 6-18 weeks
 - Focal developmental error of limb connective tissue
 - Does not explain cranial, abdominal wall defects
 - Vascular hypoperfusion/bleed
 - Hemorrhage/ischemia as etiology of defect
 - Bands due to adhesions between necrotic fetal tissue and amnion

Definitions for Types of Defects Seen in Amniotic Band Syndrome

Terminology	Definition
Disruption	Morphologic defect of organ, part of organ or larger region of body resulting from extrinsic breakdown of, or interference with, originally normal developmental process
Deformation	Abnormal form, shape, or position of part of body caused by mechanical forces
Malformation	Morphological defect of organ, or larger region of body resulting from intrinsically abnormal developmental process

The exact etiology of amniotic band syndrome is unclear and it may well be multifactorial. Careful documentation of findings and analysis of groups of similar cases is needed for elucidation of risk factors, mechanism of injury and development of treatment strategies.

Staging, Grading, & Classification

- Prenatal classification system
 - Class 1: Amniotic bands without signs of constriction
 - Class 2: Constriction without vascular compromise (normal Doppler compared to opposite side)
 - 2A: No or only mild lymphedema
 - 2B: Severe lymphedema
 - Class 3: Progressive arterial compromise
 - Flow measured proximal to, at, and distal to constriction band
 - 3A: Abnormal distal Doppler studies when compared to contralateral extremity
 - 3B: No vascular flow to extremity
 - Class 4: Bowing or fracture of long bones
 - Class 5: Intrauterine amputation
 - Median time between procedure and PROM 6 weeks (4 days-14.3 weeks)
 - Median time between procedure and delivery is 11.8 weeks (5-17)
- 2013 review of 14 cases treated with in-utero lysis
 - PROM in 57%, preterm birth in 7%
 - 50% preserved limb function
- Summarized data indicate perfusion distal to constriction as most important fetal prognostic factor
 - In cases with normal vascular flow, fetal intervention is probably not required
- Postnatal management of constriction rings by plastic surgery
 - Complete excision of all scarred tissue, closure with Z-plasty vs. direct circular closure
 - May require muscle flaps to reconstruct tissues in some areas
- Ideally, affected fetuses should be reported to central registry using classification system described
 - Better assessment of natural history
 - Development of criteria to select cases where risk of prenatal intervention is merited for nonlethal condition

CLINICAL ISSUES**Demographics**

- 1:1,200-15,000 live births with no gender predilection
- Series of 28 cases at 1 referral center
 - Extremity involvement in 71.5%
 - Umbilical cord in 25% (confers significant risk of adverse outcome)
 - Complex abdominal wall defects in 17.9%

Natural History & Prognosis

- Defects range from minor to lethal
 - Constriction alone → good prognosis with normal life expectancy
 - Spontaneous resolution of constriction defects has been described
- Risk of premature rupture of membranes (PROM)
 - Prematurity, low birth weight
 - Without abdominoschisis
 - Mean gestational age (GA) at delivery is 36.9 weeks
 - Mean birth weight between 25-50th percentile
 - With abdominoschisis
 - Mean GA at delivery is 33.6 weeks
 - Mean birth weight < 5th percentile

Treatment

- Termination offered for major defects (cranial defects, large abdominoschisis)
- Successful in utero lysis of bands for at-risk extremity reported (series of 7 cases)
 - Median GA at diagnosis was 21.3 weeks; at procedure was 23 weeks
 - PROM occurred in 71.4%

DIAGNOSTIC CHECKLIST**Image Interpretation Pearls**

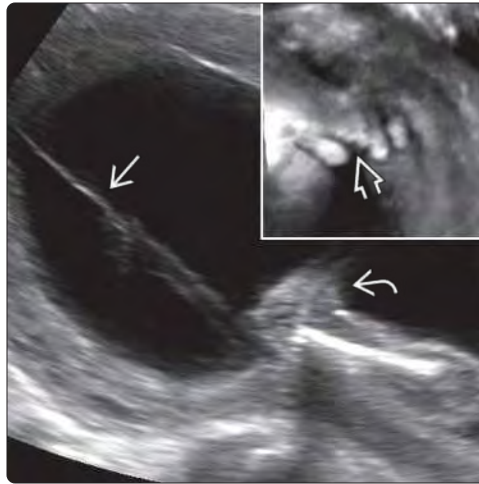
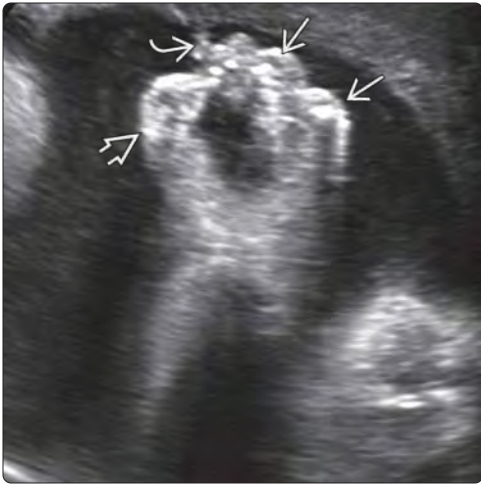
- Always consider amniotic band syndrome with unusual abdominal wall or cranial defects

Reporting Tips

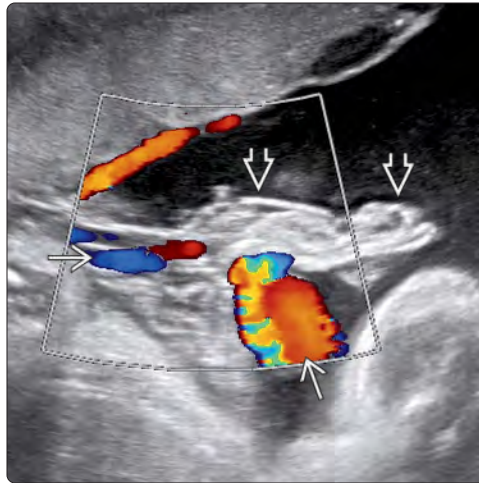
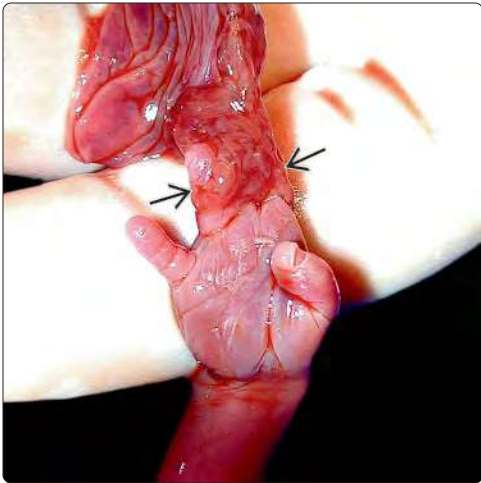
- May suggest diagnosis even if bands not seen

SELECTED REFERENCES

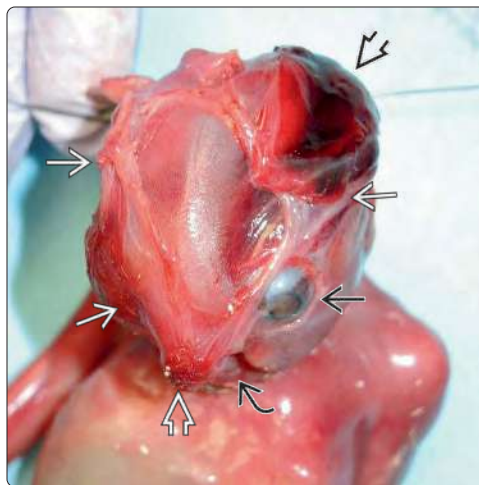
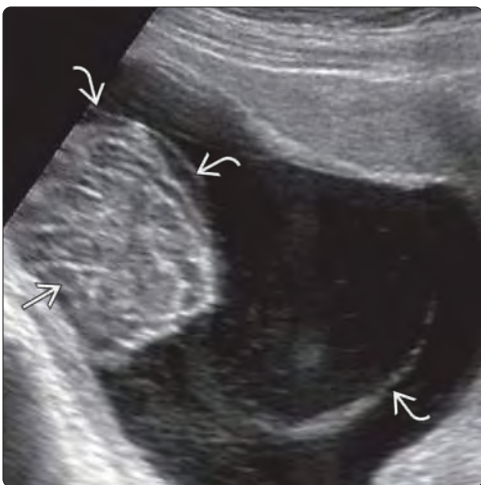
1. Iqbal CW et al: Amniotic band syndrome: a single-institutional experience. *Fetal Diagn Ther.* 37(1):1-5, 2015
2. Mathis J et al: Fetal laser therapy: applications in the management of fetal pathologies. *Prenat Diagn.* 35(7):623-36, 2015
3. Ting YH et al: Pseudoamniotic band syndrome after in utero intervention for twin-to-twin transfusion syndrome: case reports and literature review. *Fetal Diagn Ther.* ePub, 2015
4. Javadian P et al: Perinatal outcome after fetoscopic release of amniotic bands: a single-center experience and review of the literature. *Ultrasound Obstet Gynecol.* 42(4):449-55, 2013
5. Cignini P et al: Epidemiology and risk factors of amniotic band syndrome, or ADAM sequence. *J Prenat Med.* 6(4):59-63, 2012
6. Hunter AG et al: Limb-body wall defect. Is there a defensible hypothesis and can it explain all the associated anomalies? *Am J Med Genet A.* 155A(9):2045-59, 2011
7. Hüsler MR et al: When is fetoscopic release of amniotic bands indicated? Review of outcome of cases treated in utero and selection criteria for fetal surgery. *Prenat Diagn.* 29(5):457-63, 2009



(Left) US shows the fingertips tethered to each other (pseudosyndactyly) and to the thumb by a short band, which was best seen on real time evaluation. (Right) 2D US shows a band wrapping the fingers of 1 hand. The inserted 3D reconstruction shows digital amputations on the other hand.



(Left) Gross pathology in a similar case shows the fingers trapped in a band. As an isolated finding, this would be of little consequence, but, in this case, the only other area involved was the umbilical cord, which was occluded by a band, resulting in intrauterine fetal demise. (Right) Color Doppler shows a "clump" of umbilical cord loops near the placental cord insertion site with an adherent mass of bands. The fetus was normal. Due to the reported risk of cord avulsion in labor, the patient was delivered by cesarean section.



(Left) Transabdominal US in a singleton pregnancy shows brain tissue outside the cranial vault with adherent amniotic band. This defect is lethal, whereas isolated limb constrictions/amputations are not. (Right) Autopsy image shows a sheet of amnion covering the fetal head, looped under the nose, adjacent to a large facial cleft. There was a single orbit and a single, exposed cerebral hemisphere.

Apert Syndrome

KEY FACTS

TERMINOLOGY

- Synonym: Acrocephalosyndactyly type I

IMAGING

- Abnormal calvarial shape often with frontal bossing
- Severe syndactyly of hands and feet on midtrimester ultrasound
- Midface hypoplasia

TOP DIFFERENTIAL DIAGNOSES

- Other syndromes with craniosynostosis and syndactyly
 - Pfeiffer syndrome
 - Carpenter syndrome
 - Saethre-Chotzen syndrome

PATHOLOGY

- Due to mutations in fibroblast growth factor receptor 2 gene (*FGFR2*)
 - Most due to activating point mutations

- Autosomal dominant; most new mutations
- Associated with increased paternal age

CLINICAL ISSUES

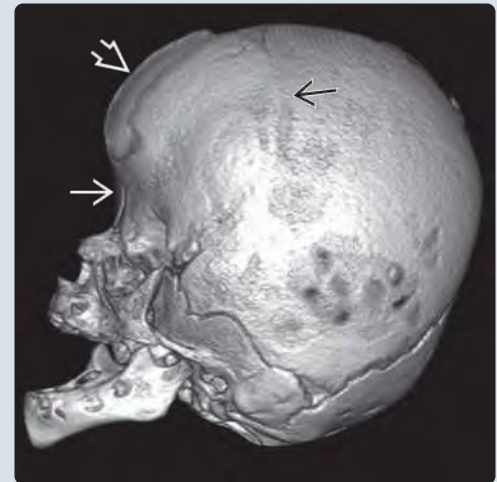
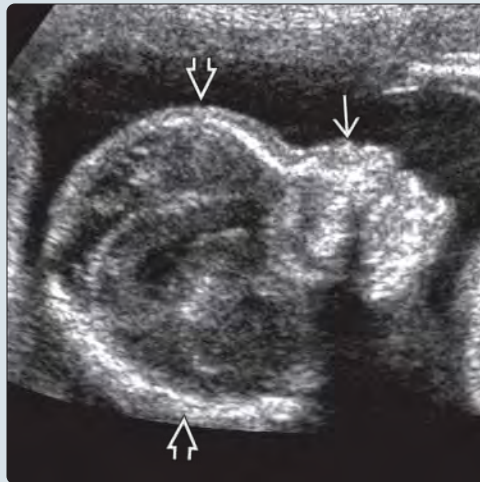
- Bilateral coronal suture synostosis
- Exophthalmos, hypertelorism
- Malocclusion, dental abnormalities
- Complex syndactyly of hands and feet
- Intellectual impairment common (IQ 44-90)
- Treatment issues
 - Extensive/complex surgical management of syndactyly with goal of increasing functionality
 - Early repair of craniosynostosis does not prevent intellectual impairment

DIAGNOSTIC CHECKLIST

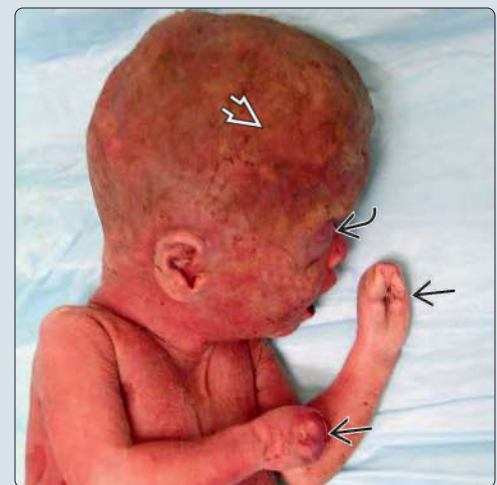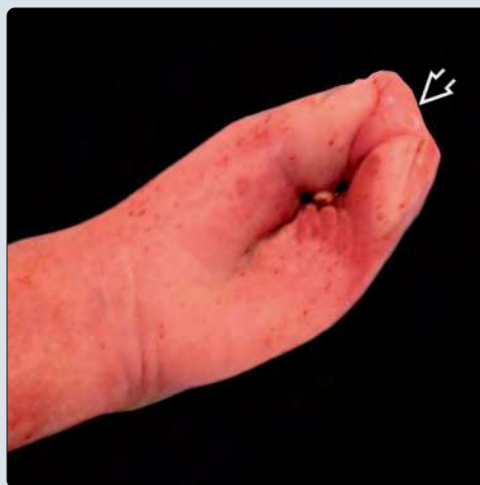- 3D ultrasound to evaluate extremities, face when calvarial abnormality identified

(Left) Sagittal ultrasound of a midtrimester fetus with Apert syndrome demonstrates hypoplastic midface and frontal bossing. The calvarial shape is abnormal due to coronal craniosynostosis.

(Right) Lateral 3D reformation of the skull in a 3-month-old boy with Apert syndrome shows bilateral coronal craniosynostosis resulting in brachyurricephaly. There is characteristic wide patency of the metopic and sagittal sutures as well as midface hypoplasia and depression of the nasal bridge. (From: *SI: Temporal Bone.*)



(Left) Clinical photograph shows the hand of a 3rd-trimester stillborn with Apert syndrome. Severe mitten syndactyly is apparent with both soft tissue and bony fusion of the digits. (Right) Clinical photograph of the same stillborn fetus shows the typical facial phenotype of Apert syndrome. Bilateral severe mitten syndactyly of the hands is seen. There is a tower shape to the calvarium due to coronal craniosynostosis. Note also the midface hypoplasia as well as proptosis due to shallow orbits.



TERMINOLOGY

Synonyms

- Acrocephalosyndactyly type I

Definitions

- Craniofacial dysostosis characterized by craniosynostosis, midface hypoplasia, and syndactyly of hands and feet

IMAGING

General Features

- Best diagnostic clue
 - Abnormal calvarial shape and severe syndactyly of hands and feet on midtrimester ultrasound

Ultrasonographic Findings

- Craniosynostosis with brachyurricephaly
 - Fusion of coronal sutures ± other sutures, resulting in conical tower skull shape
- Mitten syndactyly
 - Extensive soft tissue and (often) bony, fusion of fingers and toes
- Proptosis due to shallow orbits
- Central nervous system abnormalities in 60%
 - Ventriculomegaly, megalencephaly, agenesis of corpus callosum, absent cavum septi pellucidi
- Cardiac defects (10%)
 - Pulmonic stenosis, ventricular septal defect
- Genitourinary defects (10%)
 - Hydronephrosis, müllerian anomalies, cryptorchidism

Imaging Recommendations

- Best imaging tool
 - Midtrimester ultrasound
 - 3D/4D ultrasound helpful in delineating phenotype, counseling families

DIFFERENTIAL DIAGNOSIS

Pfeiffer Syndrome

- Severe craniosynostosis; kleeblattschädel (cloverleaf) skull, severe exophthalmos
- Broad distal thumbs, toes with central syndactyly

Carpenter Syndrome

- Craniosynostosis of multiple sutures
- Preaxial polydactyly, soft tissue syndactyly
- Cardiac and ventral wall abnormalities

Saethre-Chotzen Syndrome

- Coronal suture synostosis
- Shallow orbits, dysplastic ears
- Partial cutaneous syndactyly of fingers, toes

Crouzon Syndrome

- Craniosynostosis involving multiple sutures
- Severe proptosis with hypertelorism

PATHOLOGY

General Features

- Etiology

- Gain-of-function mutations in fibroblast growth factor receptor 2 (*FGFR2*) induce dysregulation of osteoblast function
 - Most due to point mutations *S252W* or *P253R*
- Genetics
 - Autosomal dominant; most are new mutations

CLINICAL ISSUES

Presentation

- Postnatal findings
 - Craniofacial
 - Bilateral coronal suture synostosis, variable other sutures
 - Midface hypoplasia, maxillary hypoplasia
 - Exophthalmos, hypertelorism, downslanting palpebral fissures, supraorbital horizontal groove
 - Malocclusion, dental abnormalities
 - Complex syndactyly of hands and feet: Mitten syndactyly
 - Short broad thumb in valgus position
 - Bony fusion involving digits 2-4, symphalangism (synostosis of joints)
 - Involves muscles, tendon insertions, and neurovascular bundles of hand
 - Intellectual impairment common (IQ 44-90)

Demographics

- Epidemiology
 - Associated with increased paternal age
 - Incidence 1/64,500 births with M:F = 1:1

Natural History & Prognosis

- Early repair of craniosynostosis does not prevent intellectual impairment
- Hearing loss due to chronic otitis, fixation of stapes
- Upper and lower airway compromise may be responsible for early death

Treatment

- Surgical correction of craniosynostosis, craniofacial reconstruction
- Extensive/complex surgical management of syndactyly with goal of increasing functionality

DIAGNOSTIC CHECKLIST

Image Interpretation Pearls

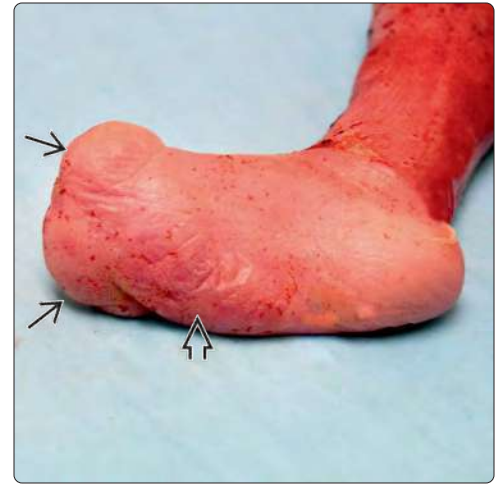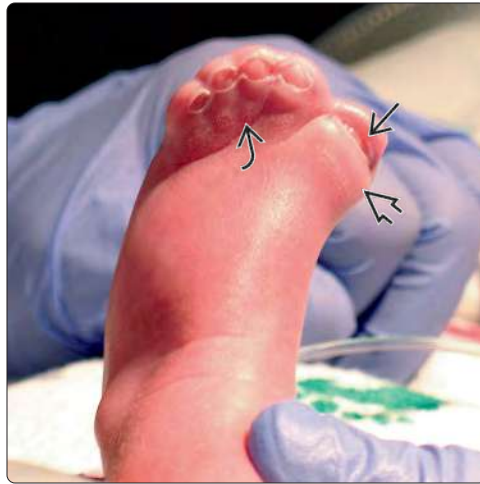- Prenatal diagnosis possible by midtrimester with abnormal calvarial shape, syndactyly
- 3D ultrasound to evaluate extremities, face when calvarial abnormality identified

SELECTED REFERENCES

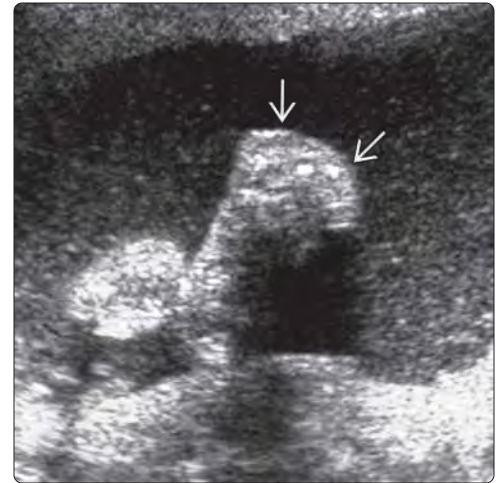
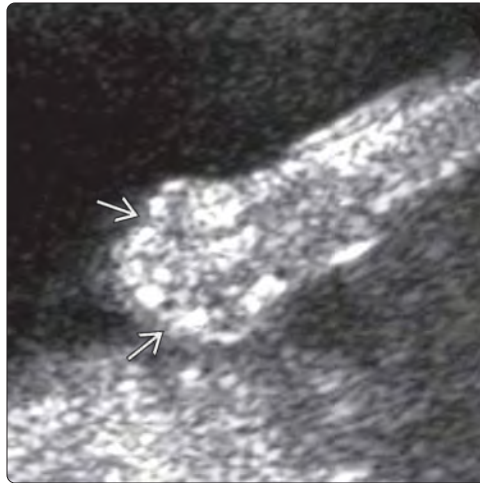
1. Giacotti A et al: Comparison of ultrasound and magnetic resonance imaging in the prenatal diagnosis of Apert syndrome: report of a case. *Childs Nerv Syst.* 30(8):1445-8, 2014
2. Au PK et al: Detection of the S252W mutation in fibroblast growth factor receptor 2 (*FGFR2*) in fetal DNA from maternal plasma in a pregnancy affected by Apert syndrome. *Prenat Diagn.* 31(2):218-20, 2011
3. Patel B et al: Postmortem computed tomography in a case of Apert Syndrome: correlation with conventional autopsy and prenatal ultrasound. *Ultrasound Q.* 26(4):249-53, 2010

Apert Syndrome

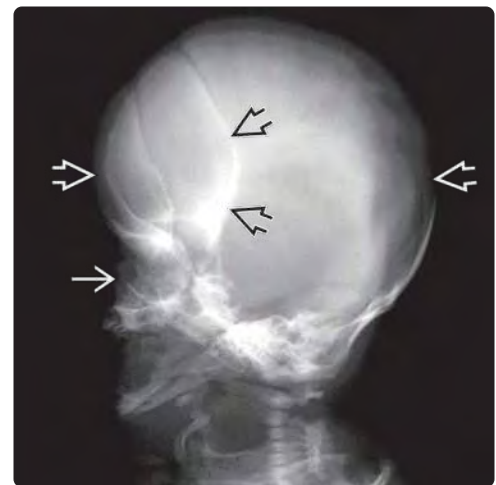
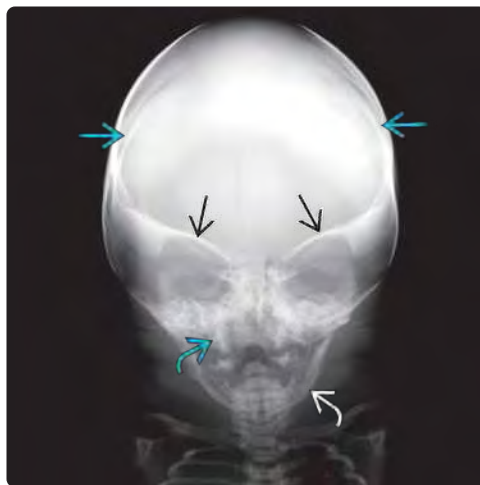
(Left) Clinical photograph of the foot of a newborn infant with Apert syndrome shows classic extensive syndactyly. Note the complete soft tissue syndactyly, as well as the broad, medially deviated great toe. Nail hypoplasia is also seen. **(Right)** Clinical photograph of the plantar surface of the foot of a stillborn with Apert syndrome reveals complete syndactyly of the toes, as well as the apparent absence of normal plantar creases. Soft tissue edema is also noted.

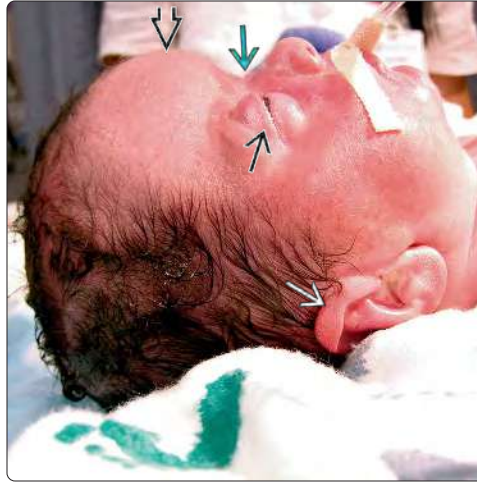
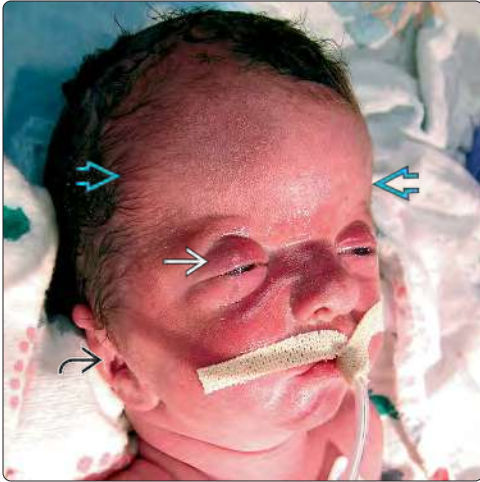
(Left) Ultrasound of the hand of a midtrimester fetus shows apparent absent digits. In fact, the digits are shortened and fused. Syndactyly is very difficult to ascertain on prenatal ultrasound. **(Right)** Ultrasound of the foot of the same fetus shows complete syndactyly of all the toes. The individual bony digits cannot be seen. Syndactyly of the toes is especially difficult to visualize on prenatal ultrasound.

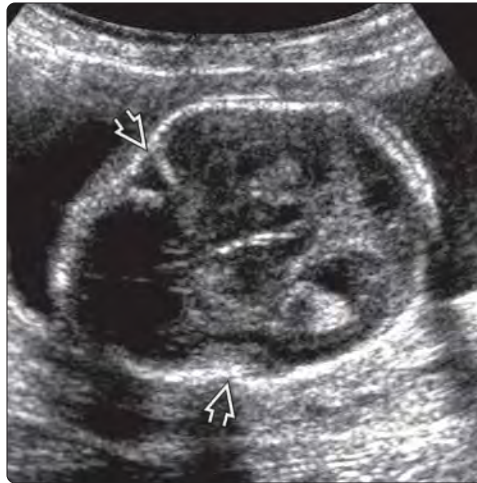
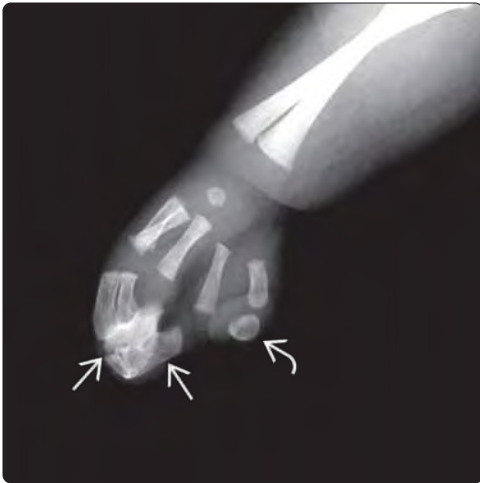
(Left) Anteroposterior radiograph of an infant with Apert syndrome shows the prominent supraorbital ridges, maxillary and mandibular hypoplasia, and the sclerotic, fused coronal sutures. **(Right)** Lateral radiograph of the same infant shows the distinctive shape (tower skull) of the calvarium of a newborn with Apert syndrome. Severe midface hypoplasia is noted. Sclerotic change is seen in the coronal suture, which is fused.

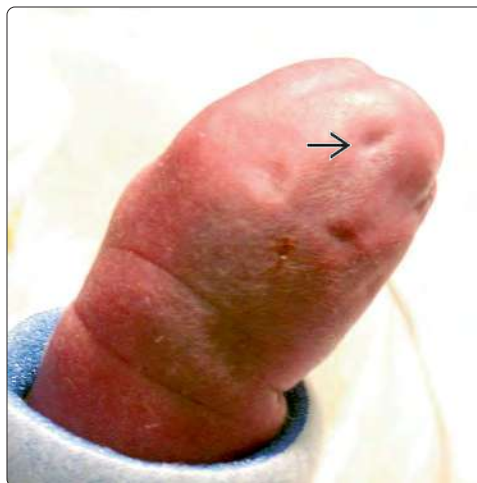
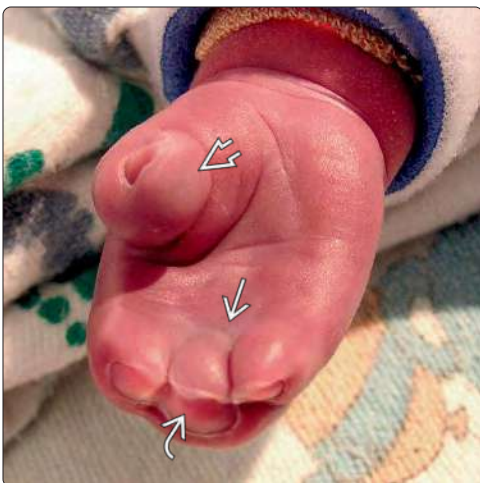



(Left) Clinical photograph of a term newborn infant with Apert syndrome shows the brachyuricephaly due to coronal suture craniosynostosis, proptosis due to shallow orbits, and low-set ears. **(Right)** Profile view of the same infant shows the significant frontal bossing with midface hypoplasia, depressed nasal bridge, and proptosis. The ears are low set with thickened helices.



(Left) Radiograph of the hand of an infant with Apert syndrome shows the classic features of complex complete bony and soft tissue syndactyly. Note the broad distal thumb. Lack of ossification of the carpal bones is normal at this age. **(Right)** Axial ultrasound shows the unusual calvarial shape of a midtrimester fetus with Apert syndrome. Craniosynostosis of the coronal sutures is present.



(Left) Clinical photograph of the hand of a newborn infant with Apert syndrome shows the extensive soft tissue and bony syndactyly with apparent oligodactyly. The nails are unusual, appearing large and deep set. Nail fusion can often be seen. The broad thumb with valgus deformity is also apparent. **(Right)** Clinical photograph of the dorsal surface of the same hand shows the extensive cutaneous mitten syndactyly of this infant with Apert syndrome.

KEY FACTS

TERMINOLOGY

- Imprinting disorder with principle features, including macrosomia, macroglossia, and omphalocele

IMAGING

- Macroglossia is most consistent finding
 - Persistent protruding tongue during exam with inability to close mouth
- Kidneys are large but often normal echogenicity with hypoechoic pyramids preserved
- Hepatomegaly common
- Large abdominal circumference: Combination of nephromegaly and hepatomegaly
- Omphalocele, usually small
- Placental mesenchymal dysplasia

TOP DIFFERENTIAL DIAGNOSES

- Macrosomia associated with maternal diabetes

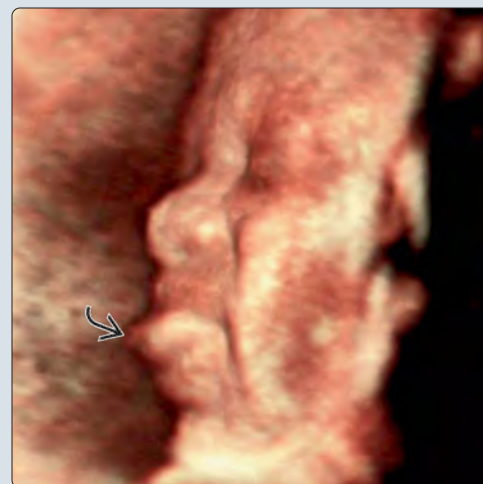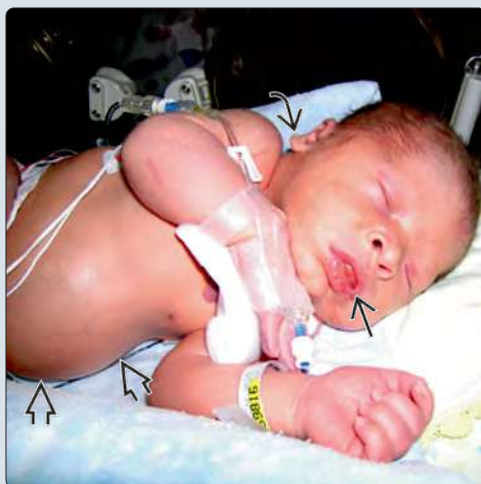PATHOLOGY

- Multigenic disorder due to epigenetic alterations in growth regulatory genes at 11p15.5
- 10-15% are familial and inherited in autosomal dominant fashion
- 10-20% with paternal uniparental disomy

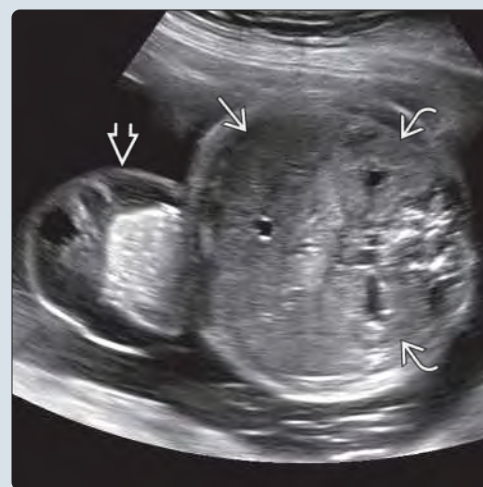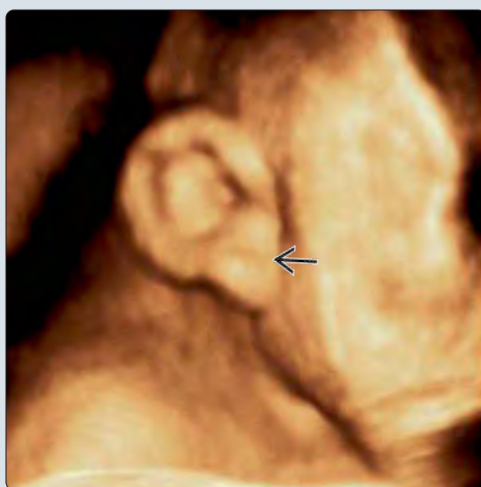CLINICAL ISSUES

- Increased frequency in monozygotic twins
- Reported increased incidence of infants with Beckwith-Wiedemann syndrome born to couples who have undergone various assisted reproductive technologies
- Neonatal hypoglycemia, often severe
- Airway difficulties; potentially life-threatening at delivery if macroglossia is severe
- Increased risk of embryonal tumors, including Wilms tumor, hepatoblastoma, neuroblastoma, rhabdomyosarcoma, adrenocortical carcinoma

(Left) Clinical photograph of a term infant with Beckwith-Wiedemann syndrome (BWS) shows several characteristic features of the disorder. Note the macrosomic appearance with protuberant abdomen secondary to markedly enlarged liver and kidneys. There is macroglossia with the tongue protruding through the mouth. The earlobe is upturned, and there was a transverse crease. **(Right)** 3D US shows the face of a fetus at 32 weeks with BWS. Note the large mouth with protruding tongue due to macroglossia.



(Left) 3D surface-rendered view of the ear in a different case of BWS shows a transverse crease. Always use 3D to examine subtle facial features, as well as macroglossia. **(Right)** This axial US through the abdomen of a macrosomic fetus shows classic features of BWS, including an omphalocele, large, mildly echogenic kidneys (> 95th percentile for gestational age), and hepatomegaly with the liver extending into the pelvis on coronal views.



TERMINOLOGY

Abbreviations

- Beckwith-Wiedemann syndrome (BWS)

Definitions

- Imprinting disorder characterized by macrosomia, hemihyperplasia, macroglossia, ventral wall defects, predisposition to embryonal tumors, and neonatal hypoglycemia

IMAGING

General Features

- Best diagnostic clue
 - Large-for-dates fetus with enlarged kidneys, omphalocele, and protruding tongue on midtrimester ultrasound

Ultrasonographic Findings

- Macroglossia in 97%
 - Persistent protruding tongue during exam with inability to close mouth
 - Polyhydramnios from obstruction of swallowing
- Kidneys are large, but often normal echogenicity with hypoechoic pyramids is preserved
- Hepatomegaly common
- Macrosomia in 88%
 - Large abdominal circumference: Combination of nephromegaly and hepatomegaly
- Omphalocele, usually small
 - May just be umbilical hernia
- Placental mesenchymal dysplasia in 19%
 - Thickened cystic placenta

Imaging Recommendations

- Best imaging tool
 - Use 3D/4D ultrasound to better delineate facial features
 - Look for subtle findings, including earlobe pits and creases, as well as macroglossia

DIFFERENTIAL DIAGNOSIS

Macrosomia Associated With Maternal Diabetes

- Macrosomia may be seen in poorly controlled gestational or pregestational diabetes
- Poor control in pregestational diabetes also increases risk of cardiac, central nervous system, and extremity malformations
- Omphalocele uncommon in diabetic embryopathy

Other Rarer Overgrowth Syndromes

- **Simpson-Golabi-Behmel syndrome**
 - Macroglossia, polyhydramnios, craniofacial abnormalities, including broad nose, visceromegaly, congenital diaphragmatic hernia, umbilical hernia, postaxial polydactyly
 - Additional postnatal findings include coarse facies, palatal abnormalities, dental issues, supernumerary nipples, abnormal genitalia
 - X-linked recessive disorder
- **Sotos syndrome**

- Increased risk of trisomy 21 on serum screen, macrosomia, macrocephaly, central nervous system abnormalities including ventriculomegaly and agenesis of corpus callosum, polyhydramnios
- Additional postnatal findings include inverted pear-like head with characteristic facial features, learning disabilities
- Autosomal dominant disorder
- **Weaver syndrome**
 - Skeletal abnormalities including camptodactyly, clubfoot, and arthrogyposis
 - Weak, hoarse cry as newborns; delayed development of motor skills, such as sitting, standing, and walking in early childhood
 - Autosomal dominant disorder
- **Pelman syndrome**
 - Also called renal hamartomas, nephroblastomatosis, and fetal gigantism
 - Macrocephaly, macrosomia, polyhydramnios, and hypoglycemia
 - Distinctive facial features including deep-set eyes, depressed nasal bridge, everted upper lip, and macrocephaly differentiates it from BWS

PATHOLOGY

General Features

- Etiology
 - Multigenic disorder due to epigenetic alterations in growth regulatory genes at 11p15.5
 - Many imprinted genes in this region
 - Genomic imprinting is one of most important epigenetic mechanisms of gene regulation and functions via methylation as well as modification of histone and nonhistone proteins
 - Imprinted genes maintain their methylation pattern throughout development and are expressed differentially depending upon parent of origin
 - Pattern of expression is controlled via imprinting control regions (ICRs)
 - Perturbation of DNA methylation in area of ICR is implicated in several human diseases, including BWS
 - In addition, 5-10% of BWS cases have mutation in *CDKN1C*, kinase inhibitor that functions as negative regulator of cellular growth and proliferation
- Genetics
 - Genetically heterogeneous: 85% are sporadic with normal karyotype
 - 10-15% are familial and inherited in autosomal dominant fashion
 - 10-20% with paternal uniparental disomy
 - Both copies of 11p15 derived from father
 - < 1% of cases with chromosome translocation, inversion, or duplication involving 11p15 region
 - As high as 50% recurrence risk if translocation is maternal in origin

Staging, Grading, & Classification

- Williams et al proposed provisional diagnosis made by 2 major or 1 major and 2 minor findings
 - Major findings: Macrosomia, macroglossia, and omphalocele

- Minor findings: Nephromegaly, renal dysgenesis/dysplasia, adrenal cytomegaly, polyhydramnios, abnormal loci

Microscopic Features

- Adrenal cytomegaly characteristic feature
 - Hyperplastic adrenal gland with unusual, large, polyhedral cells
- Perilobar nephrogenic rests of embryonal kidney cells (nephroblastomatosis) that persist abnormally into postnatal life
 - At risk for developing Wilms tumor

CLINICAL ISSUES

Presentation

- Most common signs/symptoms
 - Fetal: Macrosomia, macroglossia, omphalocele
- Postnatal
 - Characteristic facies
 - Macroglossia: Neonatal airway obstruction if severe
 - Nevus flammeus over forehead, eyelids
 - Midface hypoplasia, prognathism, malocclusion, infraorbital creases
 - Ears with creased lobules, pits in posterior helices
 - Enlarged kidneys, pancreas, adrenals, liver
 - Renal medullary dysplasia, nephrocalcinosis, medullary sponge kidney
 - Abdominal wall defects
 - Omphalocele, diastasis recti, umbilical hernia
 - Advanced skeletal maturation
 - Hemihyperplasia: May affect whole limb or part of body or segmental areas
 - Variable developmental delay

Demographics

- Epidemiology
 - 1/13,000 births
 - Increased frequency of monozygotic twins in BWS
 - Most affected twins are female; most are discordant for BWS
 - Theory that methylation error may trigger twinning process in these cases
 - Reported increased incidence associated with assisted reproductive technologies (ART)
 - Controversial
 - Does ART destabilize or otherwise alter genomic imprinting
 - Do subfertile couples have genetic predisposition to disorder and ART "bypasses" natural selection

Natural History & Prognosis

- **Pregnancy with fetal BWS**
 - Polyhydramnios
 - Increased premature delivery
 - Maternal risk of preeclampsia
 - Potential for fetal contribution to maternal disease
 - One study found 3 infants with similar *CDKN1C* mutations born to mothers with preeclampsia/HELLP syndrome
- **Neonatal period**

- Airway difficulties; potentially life-threatening at delivery if macroglossia is severe
- Hypoglycemia, often severe
- Feeding issues
- Apnea
- High infant mortality rate (20%), primarily due to complications of prematurity

Childhood

- Increased risk of embryonal tumors including: Wilms tumor, hepatoblastoma, neuroblastoma, rhabdomyosarcoma, adrenocortical carcinoma
 - Overall tumor risk: 7.5-10%
 - Wilms tumor accounts for 60% of all tumors in BWS
 - Only ~ 5% of children with BWS actually develop Wilms tumor
 - Average age of onset at 42-47 months in unilateral cases; 30-33 months in bilateral cases
 - 5-10% of children with Wilms tumor have bilateral or multicentric tumors
 - Strict tumor surveillance protocol
- Macrosomia and macroglossia usually present at birth; rarely may develop in childhood
- Rate of growth generally slows by age 7-8 years

Treatment

- Delivery in tertiary care center with availability of pediatric surgery, neonatal intensive care
 - Preparation for potential airway obstruction due to macroglossia
- Genetic counseling
- Treatment of hypoglycemia in infancy
- Protocol involving α -fetoprotein (hepatoblastoma surveillance) and abdominal ultrasound (Wilms tumor surveillance) every 3 months until age 8 years
- Speech therapy
- Orthopedic management in cases of limb-length discrepancy
- Pediatric nephrology management in cases of nephrocalcinosis

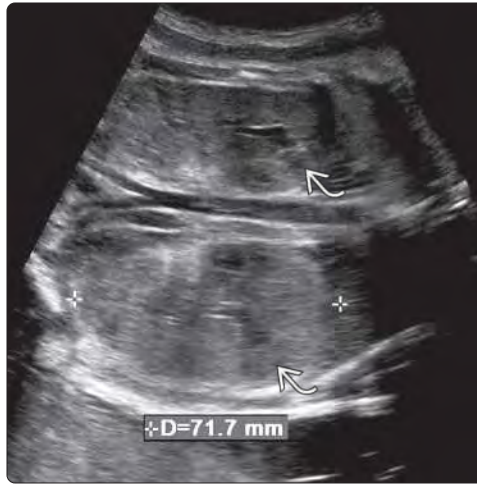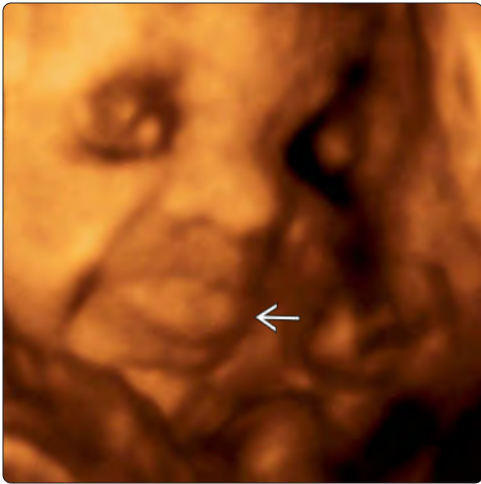DIAGNOSTIC CHECKLIST



Image Interpretation Pearls

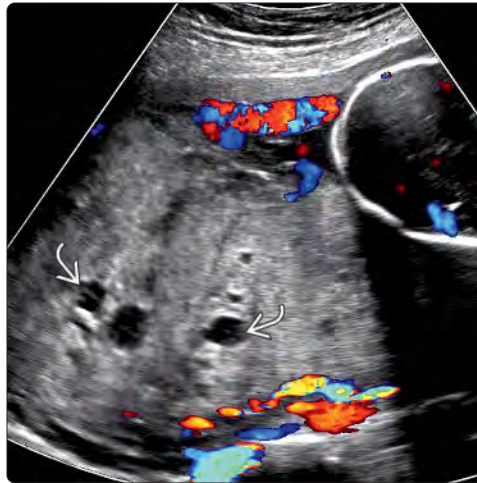
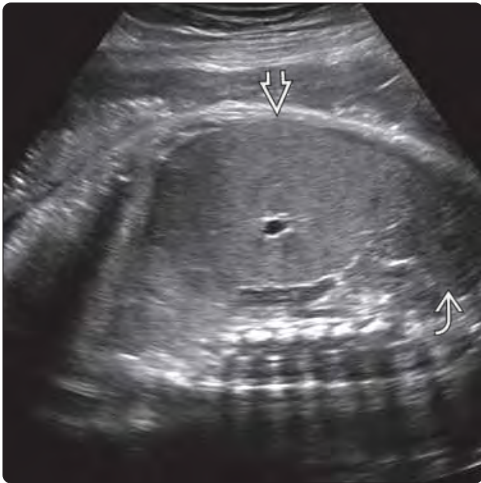
- Accelerated fetal growth in presence of characteristic anomalies is suggestive of BWS




SELECTED REFERENCES

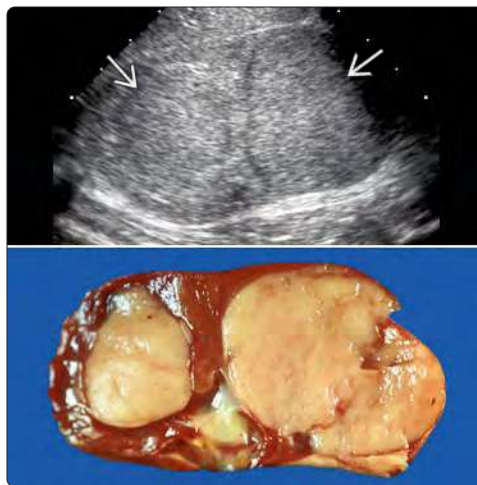
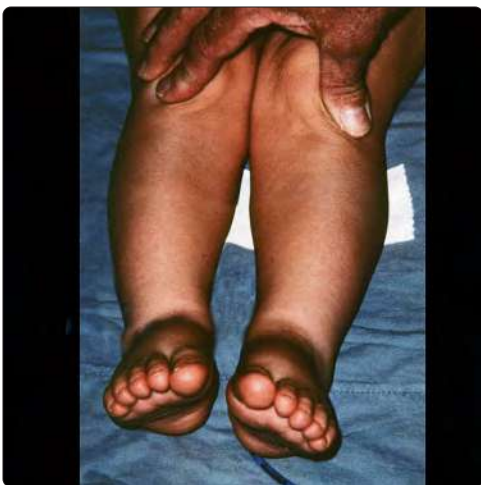1. Mussa A et al: Fetal growth patterns in Beckwith-Wiedemann syndrome. Clin Genet. ePub, 2016
2. Kagan KO et al: Novel fetal and maternal sonographic findings in confirmed cases of Beckwith-Wiedemann syndrome. Prenat Diagn. 35(4):394-9, 2015
3. Paganini L et al: Beckwith-Wiedemann syndrome prenatal diagnosis by methylation analysis in chorionic villi. Epigenetics. 10(7):643-9, 2015
4. Pappas JG: The clinical course of an overgrowth syndrome, from diagnosis in infancy through adulthood: the case of Beckwith-Wiedemann syndrome. Curr Probl Pediatr Adolesc Health Care. 45(4):112-7, 2015
5. Ibrahim A et al: Methylation analysis and diagnostics of Beckwith-Wiedemann syndrome in 1,000 subjects. Clin Epigenetics. 6(1):11, 2014
6. Armes JE et al: The placenta in Beckwith-Wiedemann syndrome: genotype-phenotype associations, excessive extravillous trophoblast and placental mesenchymal dysplasia. Pathology. 44(6):519-27, 2012




(Left) Coronal 3D US shows macroglossia in a fetus with BWS. The tongue  was persistently protruded through the lips during the entire exam. (Right) Coronal US at 32 weeks shows the characteristic finding of markedly enlarged kidneys (calipers). There is preservation of the normal renal architecture with corticomedullary differentiation and hypoechoic pyramids  seen in both kidneys.



(Left) Longitudinal view of the abdomen in a fetus with BWS shows a very protuberant abdomen secondary to marked hepatomegaly . There was also nephromegaly, which is partially visualized on this image . Both of these findings contribute to the enlarged abdominal circumference. (Right) Color Doppler US through the placenta shows marked thickening with cystic change . Placental mesenchymal dysplasia is strongly associated with BWS.



(Left) This photograph shows hemihypertrophy of the left leg, a classic feature seen in childhood but rare in the fetus. (Right) Sagittal US, with gross correlation, of the right kidney in an infant with BWS shows 2 uniform hypoechoic masses . This was nephroblastomatosis, a precursor to Wilms tumor. Children with BWS are at increased risk of developing embryonal tumors with Wilms being the most common. Fetal Wilms tumor has been reported but is exceedingly rare.

KEY FACTS

TERMINOLOGY

- Acrocephalopolysyndactyly type II
- Characterized by preaxial polydactyly, soft tissue syndactyly, cardiac defects, ventral wall abnormalities, and craniosynostosis of multiple sutures

IMAGING

- Abnormal calvarial shape with proptosis
- Preaxial polydactyly, partial syndactyly of hands and feet
- Craniosynostosis of sagittal, lambdoid, coronal sutures
- Cardiac defects in 30-50%
- Abdominal wall defects

TOP DIFFERENTIAL DIAGNOSES

- Apert syndrome
- Pfeiffer syndrome
- Crouzon syndrome
- Saethre-Chotzen syndrome

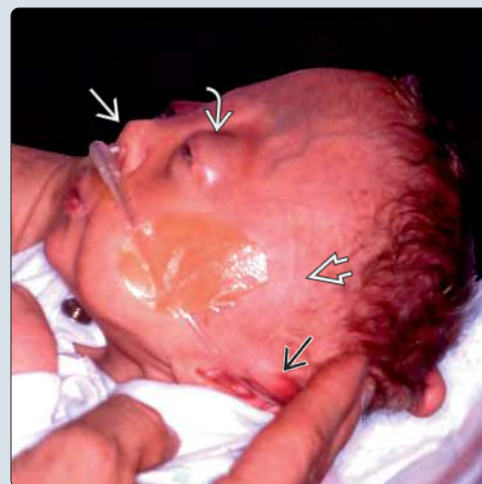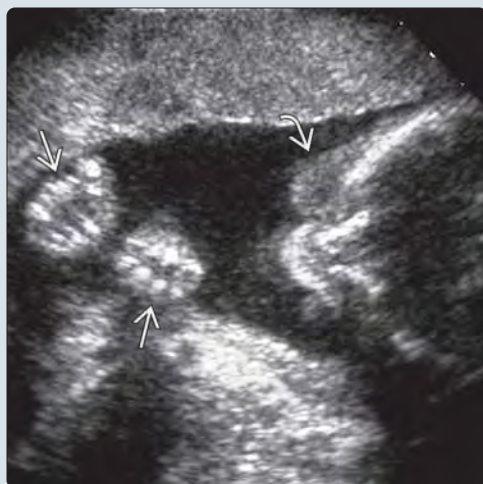
PATHOLOGY

- Autosomal recessive but genetically heterogeneous
 - Homozygous mutations in *RAB23* gene
- Features of Carpenter syndrome associated with defective laterality; due to homozygous or compound heterozygous mutations in *MEGF8* gene

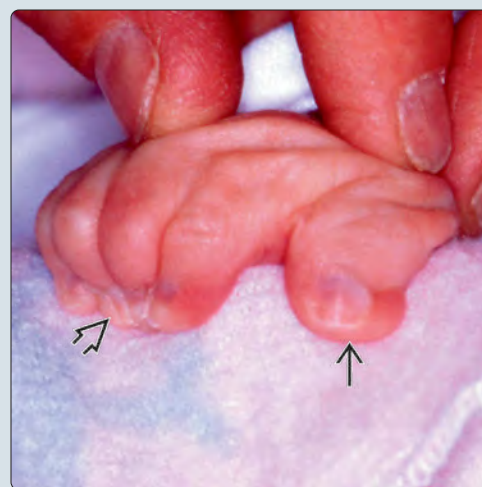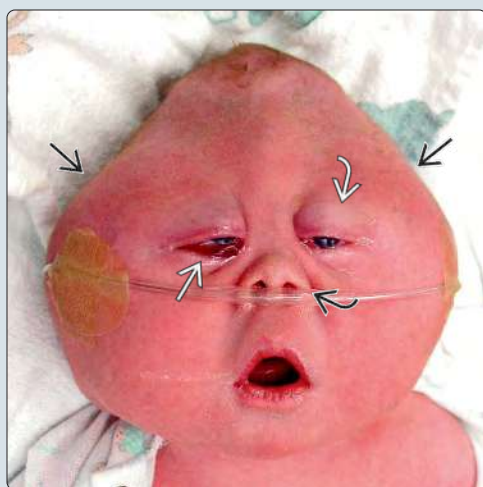CLINICAL ISSUES

- Postnatal findings
 - Brachydactyly with broad thumbs, soft tissue syndactyly of fingers
 - Dystopia canthorum (lateral displacement of inner canthi), downslanting palpebral fissures
 - Dental abnormalities with delayed eruption, prolonged retention of primary teeth, hypodontia
 - Hypogonadism
 - Intellectual function variable (IQ range: 52-104)
 - Obesity

(Left) Ultrasound shows persistently clenched hands in a midtrimester fetus with Carpenter syndrome. Polysyndactyly was found at birth. Note the shallow orbits with proptosis, also a common feature in this disorder. (Right) Clinical photograph of a preterm infant with Carpenter syndrome shows typical features of the syndrome, including severe proptosis, prominent nasal root with short nose, and low-set ears due to parietal prominence caused by craniosynostosis.



(Left) Photograph of a newborn infant with Carpenter syndrome again shows the typical phenotype. Severe craniosynostosis results in abnormal skull shape. Note the proptosis with lower lid ectropion and the small nose with anteverted nares. The mouth is also small. (Right) Clinical photograph shows complex polysyndactyly in Carpenter syndrome. Note the broad thumb (which was duplicated on x-ray) and syndactyly of the remaining fingers.



TERMINOLOGY

Synonyms

- Acrocephalopolysyndactyly type II

Definitions

- Characterized by preaxial polydactyly, soft tissue syndactyly, cardiac defects, ventral wall abnormalities, and craniosynostosis of multiple sutures

IMAGING

General Features

- Best diagnostic clue
 - Abnormal calvarial shape with proptosis and polysyndactyly of hands and feet on midtrimester ultrasound

Ultrasonographic Findings

- Craniosynostosis results in shallow orbits, causing prominent proptosis
- Cardiac defects in 30-50%
 - Septal defects, pulmonic stenosis, tetralogy of Fallot
- Preaxial polydactyly with partial syndactyly
 - Hands may appear clenched
 - Polysyndactyly not absolute requirement for syndrome
 - Brachydactyly
- Abdominal wall defects
 - Omphalocele, hernia

Radiographic Findings

- Postnatal radiographs important for diagnosis
 - Craniosynostosis of sagittal, lambdoid, coronal sutures
 - Variable calvarial shape, may see kleeblattschädel (cloverleaf skull)
 - Genu valgum, lateral patellar displacement, flared ilia, flat acetabula
 - Shortened/hypoplastic middle phalanges, duplicated 2nd phalanx of thumb

Imaging Recommendations

- Protocol advice
 - Evaluation of extremities to exclude skeletal dysplasia
 - Careful search for evidence of cardiac and abdominal wall defects

DIFFERENTIAL DIAGNOSIS

Apert Syndrome

- Acrocephalosyndactyly type I
- Complex syndactyly of fingers and toes ("mitten syndactyly")
- Craniosynostosis with brachyuricephaly
- Broad thumbs held in valgus position
- Intellectual impairment

Pfeiffer Syndrome

- Acrocephalosyndactyly, Pfeiffer type
- Severe craniosynostosis, kleeblattschädel common
- Broad distal thumbs, toes with syndactyly of central digits

Crouzon Syndrome

- Severe proptosis, hypertelorism

- Craniosynostosis of multiple sutures
- Syndactyly not prominent feature

Saethre-Chotzen Syndrome

- Craniosynostosis of coronal, lambdoid sutures
- High flat forehead, dysplastic ears
- Partial syndactyly of fingers, toes

Bardet-Biedl Syndrome

- Postaxial polydactyly, syndactyly, brachydactyly
- Renal cysts
- Retinal dystrophy
- Intellectual impairment, obesity, hypogonadism

PATHOLOGY

General Features

- Genetics
 - Autosomal recessive, but genetically heterogeneous
 - Homozygous mutations in *RAB23* gene on 6p11
 - Features of Carpenter syndrome associated with defective laterality; due to homozygous or compound heterozygous mutations in *MEGF8* gene on 19q13

CLINICAL ISSUES

Presentation

- Postnatal
 - Brachydactyly with broad thumbs, soft tissue syndactyly of fingers
 - Dystopia canthorum (lateral displacement of inner canthi), downslanting palpebral fissures
 - Dental abnormalities with delayed eruption, prolonged retention of primary teeth, hypodontia
 - Hypogonadism

Natural History & Prognosis

- Truncal obesity common
- Intellectual function variable (IQ range: 52-104)
- Articulation problems and fine motor impairment

Treatment

- No prenatal treatment
- Referral for genetic counseling
- Neurosurgical repair of craniosynostosis
 - Impact on intellectual functioning variable
- Surgical correction of cardiac, abdominal wall defects
- Surgical management of polysyndactyly centers on improving functionality of hands

SELECTED REFERENCES

1. Haye D et al: Prenatal findings in carpenter syndrome and a novel mutation in *RAB23*. *Am J Med Genet A*. 164A(11):2926-30, 2014
2. Kadakia S et al: Carpenter syndrome: a review for the craniofacial surgeon. *J Craniofac Surg*. 25(5):1653-7, 2014
3. Victorine AS et al: Prenatal diagnosis of Carpenter syndrome: looking beyond craniosynostosis and polysyndactyly. *Am J Med Genet A*. 164A(3):820-3, 2014
4. Bhardwaj M et al: Caesarean section in a parturient with Carpenter syndrome and corrected Tetralogy of Fallot. *Int J Obstet Anesth*. 22(3):251-4, 2013

KEY FACTS

TERMINOLOGY

- CHARGE syndrome refers to nonrandom cluster of malformations including
 - Coloboma
 - Heart malformation
 - Choanal atresia
 - Retardation of growth &/or development
 - Genital anomalies
 - Ear anomalies

IMAGING

- Absent semicircular canal is very specific feature

PATHOLOGY

- 2/3 of cases due to mutations within *CHD7* gene

CLINICAL ISSUES

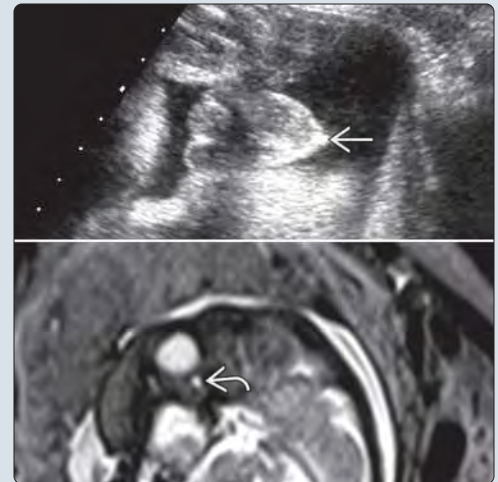
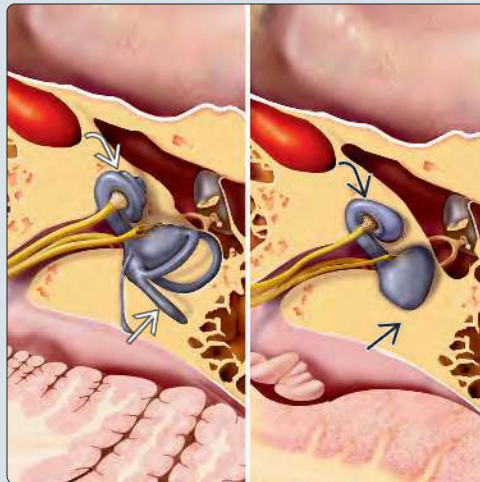
- Fetal presentation differs from that seen in children

- External ear abnormalities are the only constant feature (can be asymmetric)
- 85% with congenital heart disease
- 41% vascular anomalies
- 59% hindbrain anomalies (1/3 with vermian hypoplasia)
- 44% thymic agenesis/hypoplasia
- Prognosis is poor
 - 82% developmental delay
 - 40% autism/atypical autism
- Recurrence risk ~ 3%, possibly higher with advanced paternal age

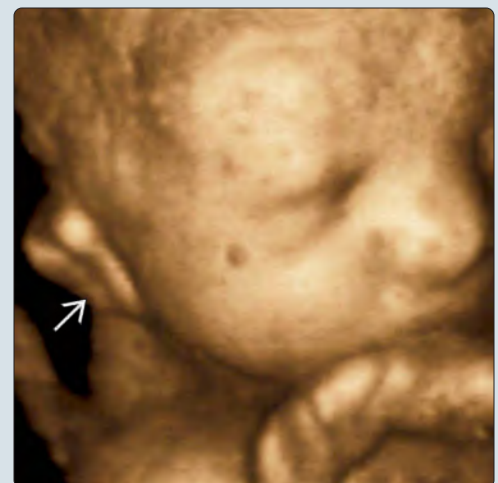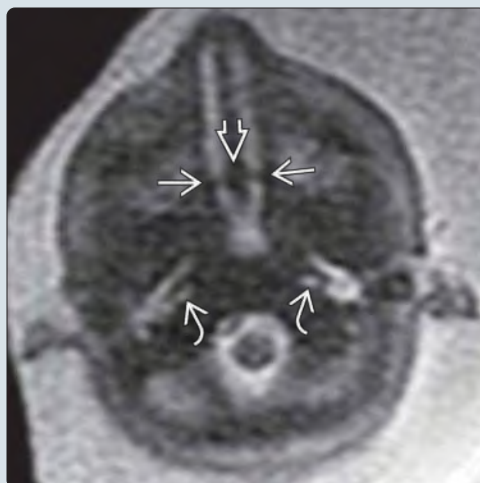DIAGNOSTIC CHECKLIST

- Look carefully at eyes, inner ear when performing fetal brain MR
- Use 3D US to look for external ear abnormalities

(Left) Composite graphic shows normal cochlea and semicircular canal (SCC) (left) vs. cochlear dysplasia and absent SCC (right) seen with CHARGE syndrome. (Right) US shows the tulip configuration of ambiguous-appearing genitalia; T2WI MR shows a coloboma (the other globe was present but out of plane). Middle ear anomalies and coloboma can be seen on fetal MR. Such an observation may clinch the diagnosis of a specific syndrome in a euploid fetus with multiple anomalies.



(Left) Fetal MR at 32 weeks shows bilateral choanal atresia with linear hypointensity extending from the thickened vomer to the lateral nasal walls, outlined by amniotic fluid. A single cochlear turn is seen bilaterally. Postnatal imaging confirmed that the dysplastic cochleae were isolated from the internal auditory canals. (From SI: Temporal Bone.) (Right) 3D US in the same case shows a low-set, cupped ear. Ear abnormalities are a constant feature of CHARGE syndrome.



TERMINOLOGY

Definitions

- CHARGE refers to nonrandom cluster of malformations seen in children including
 - Coloboma, heart malformation, choanal atresia, retardation of growth &/or development, genital anomalies &/or hypogonadism, ear anomalies &/or deafness

IMAGING

Ultrasonographic Findings

- Usually nonspecific findings of congenital heart disease (CHD), facial cleft, or brain malformation
- Abnormal ears on 3D images

MR Findings

- Absent semicircular canal is very specific feature
- Coloboma may be seen

DIFFERENTIAL DIAGNOSIS

22q11 Deletion Syndrome

- External ear anomalies are not part of 22q11 deletion

Fetal Alcohol Syndrome

- Expect microcephaly, fetal growth restriction

PATHOLOGY

General Features

- Genetics
 - 2/3 of cases due to mutations within *CHD7* gene, multiple different mutations, all apparently de novo

CLINICAL ISSUES

Presentation

- Fetal presentation differs from that seen in children
 - 36% polyhydramnios
 - Craniofacial dysmorphism
 - External ear abnormalities are only constant feature (can be asymmetric)
 - 47.5% choanal atresia, 32% cleft lip or palate

- CHD in 85%
 - 53% conotruncal
 - 24% atrioventricular septal defect
 - 18% left heart obstruction
- 41% vascular anomalies
 - Aberrant subclavian artery, right-sided aortic arch
- Craniofacial
 - 95% agenesis/hypoplasia of semicircular canals
 - 90% absent olfactory tracts (arrhinencephaly)
 - 59% hindbrain anomalies (1/3 with vermian hypoplasia)
 - Agenesis/dysgenesis of corpus callosum
 - 48% coloboma (~ 1/3 associated with microphthalmia)
- 46% of males, 36% of females had genital anomalies
- 44% thymic agenesis/hypoplasia
- 28% renal anomalies

Demographics

- 1:8,500 to 1:12,000 live births

Natural History & Prognosis

- Prognosis is poor: Problems in balance, speech, and eating are common
 - 82% developmental delay, 40% autism/atypical autism
 - Endocrine dysfunction
- Recurrence risk ~ 3%, possibly higher with advanced paternal age

DIAGNOSTIC CHECKLIST

Reporting Tips

- Look carefully at inner ear on fetal brain MR exams
- Use 3D US to look at ears in fetuses with CHD

SELECTED REFERENCES

1. Legendre M et al: Antenatal spectrum of CHARGE syndrome in 40 fetuses with *CHD7* mutations. *J Med Genet.* 49(11):698-707, 2012
2. Kosaki K: Role of rare cases in deciphering the mechanisms of congenital anomalies: CHARGE syndrome research. *Congenit Anom (Kyoto).* 51(1):12-5, 2011
3. Blustajn J et al: Olfactory anomalies in CHARGE syndrome: imaging findings of a potential major diagnostic criterion. *AJNR Am J Neuroradiol.* 29(7):1266-9, 2008

Diagnostic Criteria for CHARGE Syndrome at Fetal or Neonatal Autopsy

Major Criteria	Minor Criteria
External ear anomalies	CNS anomalies other than arrhinencephaly
Semicircular canal agenesis/hypoplasia	Limb anomaly
Arrhinencephaly (absent olfactory bulb and tracts)	Genital anomalies
Coloboma	Thymic hypoplasia/agenesis
Choanal atresia or cleft	Polyhydramnios
	Renal anomaly
	Skeletal anomaly
	Esophageal anomalies

For diagnosis, there must be at least 4 major criteria or 3 major and 2 minor criteria in the absence of growth restriction.

Antenatal spectrum of CHARGE syndrome in 40 fetuses with *CHD7* mutations. *J Med Genet.* 49(11):698-707, 2012.

KEY FACTS

TERMINOLOGY

- Rare multisystem disorder with characteristic facial features, growth restriction, intellectual impairment, limb defects, gastrointestinal abnormalities, cardiac defects, and hypertrichosis

IMAGING

- Upper limb reduction defects, monodactyly
- Micrognathia with protruding upper lip/philtrum
 - Best seen in profile
- Congenital diaphragmatic hernia, occasionally bilateral
 - Broad array of other gastrointestinal abnormalities
- Severe FGR, often early onset

TOP DIFFERENTIAL DIAGNOSES

- Fryns syndrome
- Chromosome aneuploidy
 - Pallister-Killian syndrome (mosaic tetrasomy 12p)
 - Partial duplication of 3q









- Trisomy 18

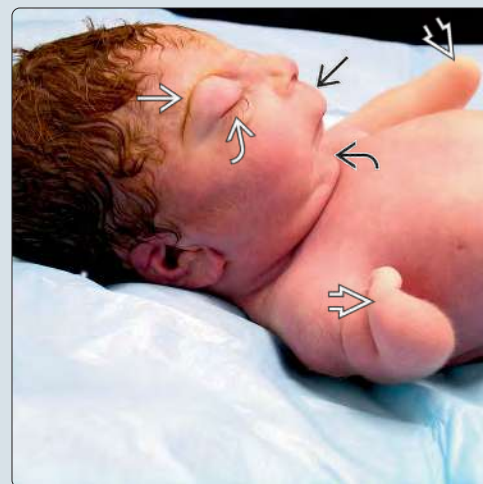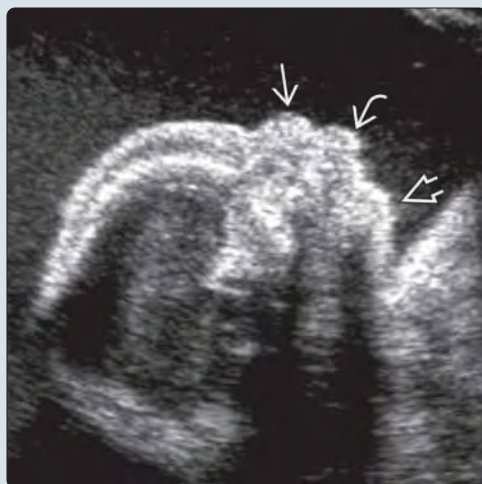PATHOLOGY



- Most common example of disorders of cohesin complex, or cohesinopathies

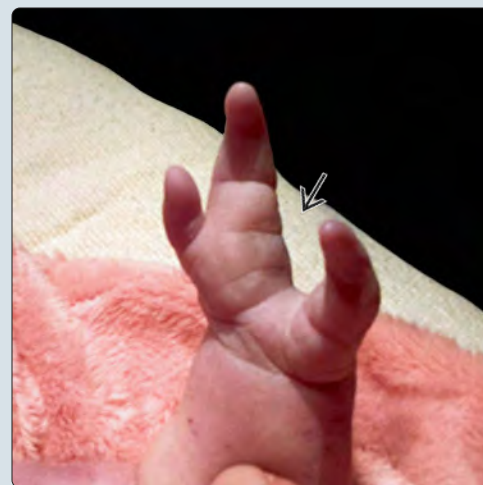
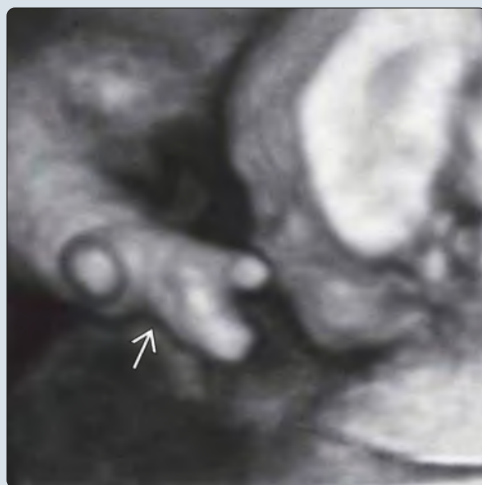CLINICAL ISSUES

- Distinctive facial phenotype
 - Fine, arched eyebrows (penciled in); long, smooth philtrum; thin lips; crescent-shaped mouth; synophrys (fused eyebrows); long lashes; ptosis; downslanting eyes; depressed nasal bridge; anteverted nares; micrognathia
- Wide spectrum of severity
- Intellectual impairment (moderate to profound)
- Significant speech and language delay (some nonverbal), hearing loss, seizures (11-23%)
- Behavioral phenotype: Self-injury, aggression, sleep disturbance, autistic behaviors

(Left) Sagittal ultrasound of a midtrimester fetus with Cornelia de Lange syndrome (CdLS) shows the flat midface with short nose , prominent philtrum , and micrognathia . (Right) Clinical photograph of a term newborn with CdLS illustrates several typical features of the syndrome. Note the fine brows  with long eyelashes , prominent philtrum , and micrognathia . Bilateral limb reduction defects are also apparent .



(Left) 3D ultrasound of a 3rd-trimester fetus shows a strikingly abnormal limb . This, with other anomalies and severe progressive growth restriction, was suggestive of CdLS by the midtrimester. (Right) Clinical photograph of the same patient shows the limb reduction defect . The defect is reminiscent of a split hand malformation. Limb defects in CdLS can be highly variable.



TERMINOLOGY**Abbreviations**

- Cornelia de Lange syndrome (CdLS)

Synonyms

- Brachmann-de Lange, de Lange

Definitions

- Rare multisystem disorder with characteristic facial features, growth restriction, intellectual impairment, limb defects, gastrointestinal abnormalities, cardiac defects, and hypertrichosis

IMAGING**General Features**

- Best diagnostic clue
 - Severe fetal growth restriction (FGR) with limb defects and visceral anomalies

Ultrasonographic Findings

- Upper limb reduction defects, often severe
- Micrognathia with protruding upper lip/philtrum
- Congenital diaphragmatic hernia (CDH): Reported association, not required for diagnosis
- Severe FGR, usually early onset

Imaging Recommendations

- Protocol advice
 - Consider 3D ultrasound to evaluate craniofacial, limb anatomy when CdLS suspected

DIFFERENTIAL DIAGNOSIS**Fryns Syndrome**

- CDH (89%), distal limb hypoplasia (75%), coarse facies
- Polyhydramnios, normal fetal growth

Chromosome Aneuploidy

- **Pallister-Killian syndrome**
 - Tissue mosaicism with supernumerary isochromosome 12p (mosaic tetrasomy 12p)
 - CDH, polyhydramnios
 - Rhizomelic limb shortening, rare acral hypoplasia
- **Partial duplication of 3q**
 - Craniosynostosis, cardiac, renal anomalies
 - Normal fetal growth/postnatal growth failure
 - Low anterior hairline, bushy eyebrows, long lashes
- **Trisomy 18**
 - FGR, radial ray defects, overlapping digits
 - CDH occasional finding

Fetal Alcohol Syndrome

- Pre- and postnatal growth restriction
- Microcephaly, cardiac defects, developmental delay
- Short palpebral fissures, smooth philtrum, thin upper lip

Isolated Congenital Diaphragmatic Hernia

- Look carefully for other malformations, especially cardiac

Limb Reduction Defects

- Isolated vs. syndromic

PATHOLOGY**General Features**

- Etiology
 - 60-65% with mutation in 1 of 3 cohesin proteins
 - *NIPBL*: Cohesin regulator and human homolog of *Drosophila nipped-B*
 - *SMC1A* and *SMC3*: Code for components of cohesin ring structure
 - Cohesin regulates cohesion of sister chromatids during mitosis and meiosis; plays critical role in regulation of gene expression
- Genetics
 - Autosomal dominant
 - Most cases sporadic (99%); rare familial cases

CLINICAL ISSUES**Presentation**

- Distinctive facial phenotype
 - Fine, arched eyebrows (penciled in); long, smooth philtrum; thin lips; crescent-shaped mouth; synophrys (fused eyebrows); long lashes; ptosis; downslanting eyes; anteverted nares; small jaw
- Limb defects important component but variable
 - Short arms/small hands to severe limb reduction defects, monodactyly
- Microbrachycephaly, short neck, low posterior hairline, anterior hairline extends over forehead
- FGR, postnatal short stature
- Cardiac defects (25%): Pulmonary stenosis, ventricular septal defect most common
- Diaphragmatic hernia: Confers poor prognosis
- Other gastrointestinal anomalies: Malrotation, colonic duplication, cecal volvulus, pyloric stenosis, reflux

Demographics

- Prevalence estimated to be as high as 1/10,000 births

Natural History & Prognosis

- Wide spectrum of severity
 - Perinatal lethality → milder cases of adults capable of living independently
- Intellectual impairment (moderate to profound)
- Significant speech and language delay (some nonverbal), hearing loss, seizures (11-23%)
- Behavioral phenotype: Self-injury, aggression, sleep disturbance, autistic behaviors

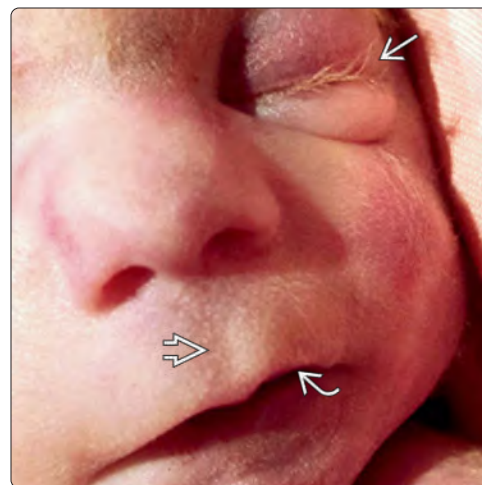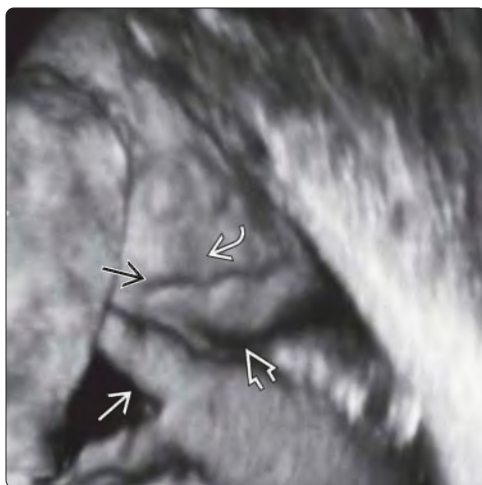
DIAGNOSTIC CHECKLIST**Image Interpretation Pearls**

- Consider CdLS when CDH found in association with limb anomalies

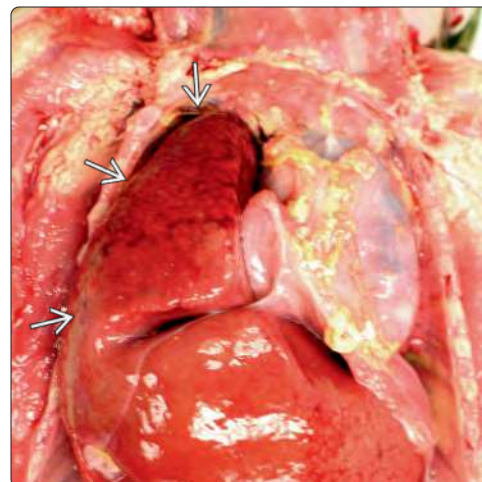
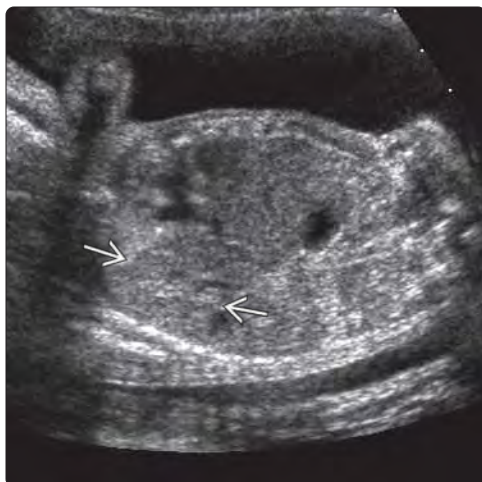SELECTED REFERENCES

1. Kline AD et al: Clinical, developmental and molecular update on Cornelia de Lange syndrome and the cohesin complex: Abstracts from the 2014 Scientific and Educational Symposium. *Am J Med Genet A*. 167(6):1179-92, 2015
2. Muto A et al: Nipbl and mediator cooperatively regulate gene expression to control limb development. *PLoS Genet*. 10(9):e1004671, 2014

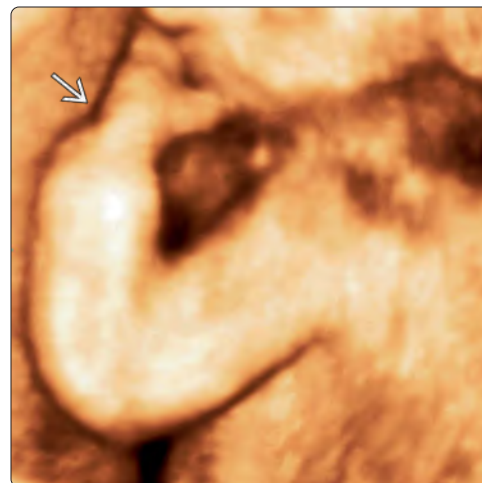
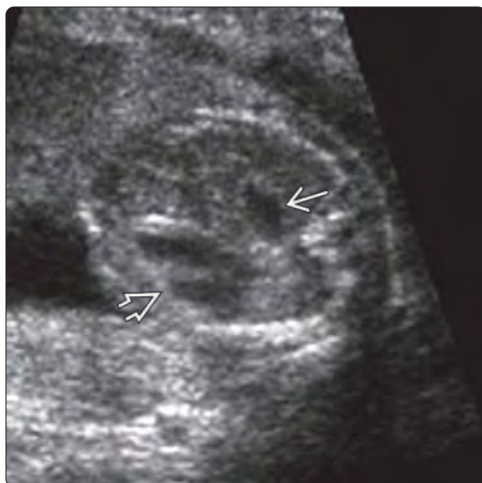(Left) This partial view of the face in a 3rd-trimester fetus with CdLS illustrates the thin lips with prominent philtrum and recessed jaw. The limb defect is also seen. **(Right)** Clinical photograph of a newborn with CdLS illustrates several features of the disorder, including long lashes and thin lips with a prominent philtrum.

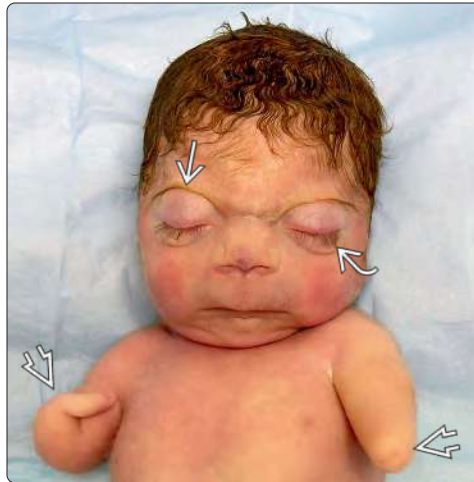
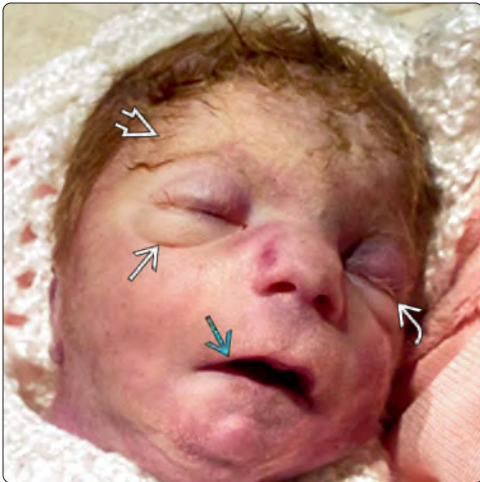
(Left) Coronal ultrasound of a midtrimester fetus with CdLS shows a right-sided diaphragmatic hernia with the liver in the chest. The presence of a diaphragmatic hernia in CdLS confers a very poor prognosis. **(Right)** Postmortem photograph of the same patient shows the large right-sided congenital diaphragmatic hernia (CDH), with the liver occupying almost all of the right chest. Always consider CdLS when a CDH is found in association with limb anomalies.

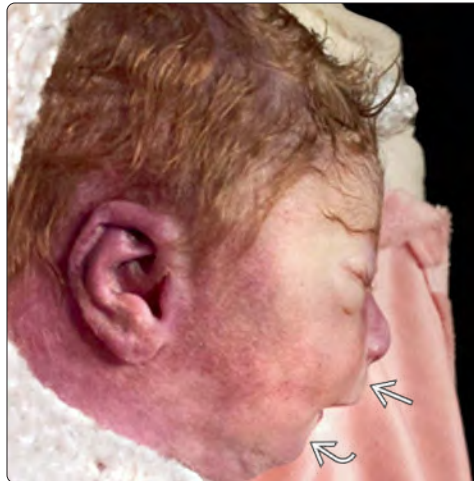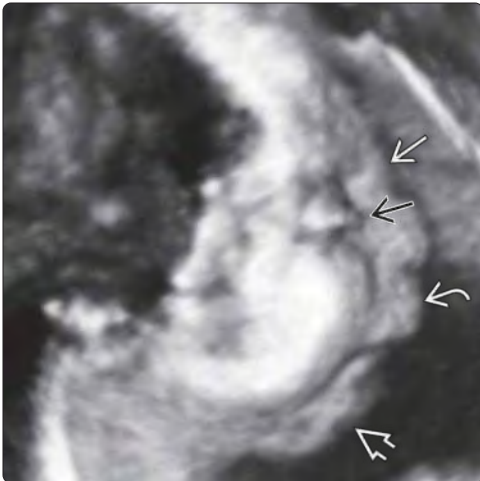


(Left) Ultrasound of a 14-week fetus with findings concerning for a diaphragmatic hernia is shown. The gastric fundus is in the chest, and the heart is at the left chest wall. The posterior position of the stomach suggests liver in the chest as well. This fetus was later diagnosed with CdLS. **(Right)** 3D ultrasound of a limb reduction defect in a 3rd-trimester fetus with CdLS is shown. Limb defects are usually bilateral, often asymmetrical, and affect the upper limbs preferentially.

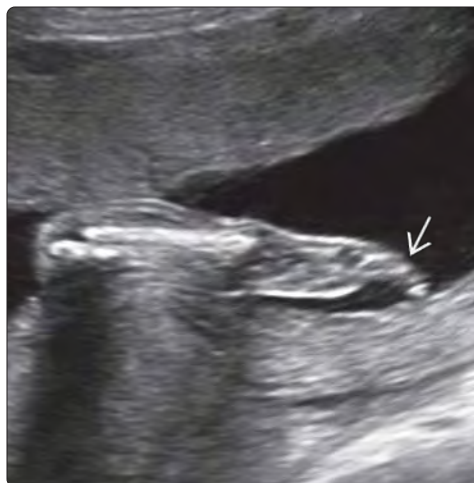
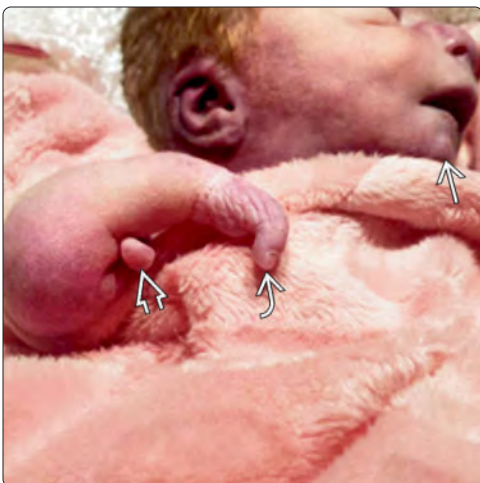



(Left) Typical facial features in a stillborn infant with CdLS are shown. There is hirsutism but distinct thin, fine eyebrows. The eyelashes are characteristically long. Downslanting palpebral fissures and infraorbital creases are seen. The lips are thin, the philtrum is prominent, and there is micrognathia. (Right) Note the similar phenotypic features in this unrelated infant. The fine, penciled eyebrows and long lashes are particularly evident. Note the asymmetrical severe limb defects.



(Left) Third-trimester fetus with CdLS is shown. 3D imaging is often used in these cases to help visualize phenotypic features in a multiple malformation syndrome. The prominent glabella, protuberant philtrum, and micrognathia are readily apparent. Even long eyelashes can be seen in the late 3rd trimester. (Right) Profile image of the same infant after birth is shown. The ears appear large, primarily due to the small size of the head. The prominent philtrum and micrognathia are seen.



(Left) Photograph of a stillborn infant at term with CdLS shows significant micrognathia. Note the fairly typical monodactyly type of limb reduction defect. A fleshy skin tag can also be seen. (Right) Midtrimester ultrasound shows an upper limb of a fetus with CdLS. Note the apparent monodactyly type of defect. The contralateral extremity had no digits or distal long bones. This asymmetry of the limb defects is very common.

KEY FACTS

TERMINOLOGY

- Autosomal recessive multisystem disorder caused by dysfunctional chloride ion transport across epithelial surfaces

IMAGING

- Echogenic bowel in 2nd trimester, often progressing to bowel dilation in 3rd trimester
 - Echogenicity greater than bone considered abnormal
- Meconium ileus
 - Dilated, echogenic small bowel
 - Appearance often indistinguishable from ileal atresia

TOP DIFFERENTIAL DIAGNOSES

- Other causes of echogenic bowel
 - Aneuploidy, especially trisomy 21
 - Infection
 - Swallowed blood
- Ileal atresia

PATHOLOGY




- Caused by mutations in gene that encodes cystic fibrosis transmembrane conductance regulator (*CFTR*)
- > 1,700 mutations identified to date
- Autosomal recessive (25% recurrence risk)

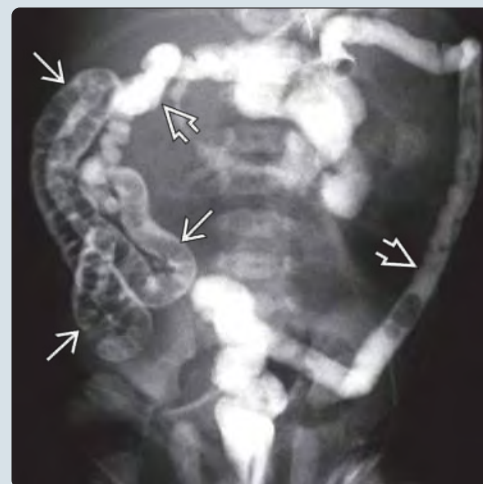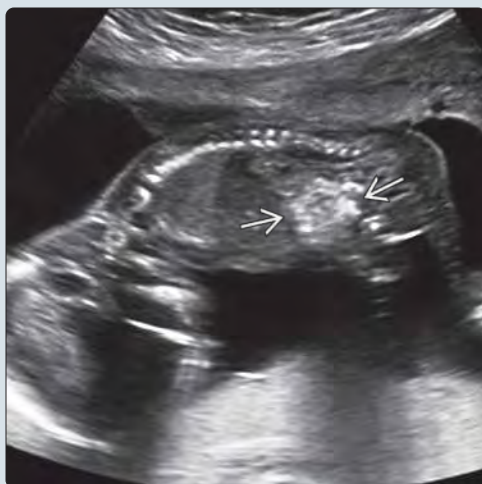CLINICAL ISSUES






- CF testing is part of newborn screening in many states
- May present in neonatal period with failure to pass meconium or in infancy with severe failure to thrive
- Respiratory, GI systems most commonly affected
- Male infertility
- Median survival late 30s

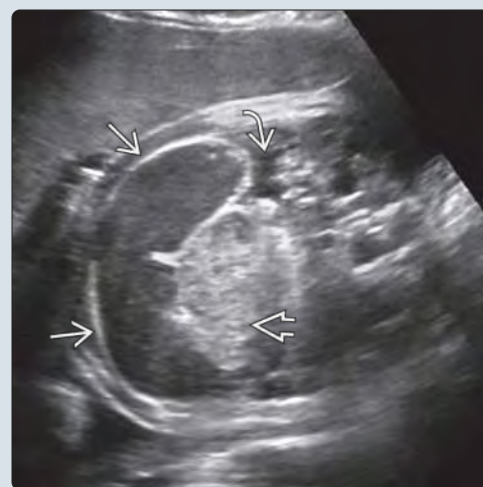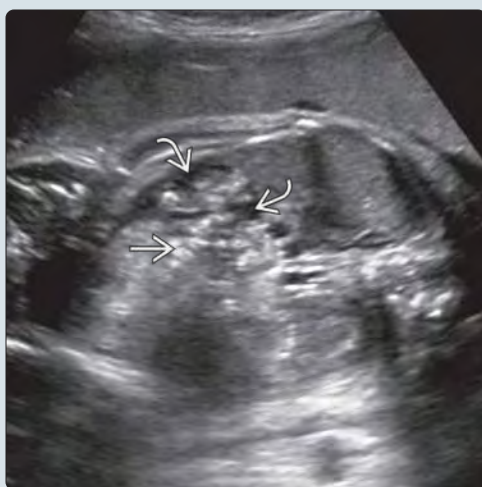DIAGNOSTIC CHECKLIST

- Normal US exam does not rule out CF
- Negative mutation screen does not eliminate carrier risk
- Offer work-up for cystic fibrosis in all cases of fetal bowel obstruction, echogenic bowel

(Left) Sagittal US of a fetus at 17-weeks gestation shows echogenic bowel ("bright as bone") . Echogenic bowel should prompt an evaluation for possible etiologies including cystic fibrosis (CF), aneuploidy, infection, bowel abnormality, and history of bleeding (swallowed blood). **(Right)** Water-soluble contrast enema in a newborn failing to pass meconium shows a microcolon  and multiple filling defects from inspissated meconium  in the distal ileum. This appearance is diagnostic of meconium ileus in CF.



(Left) US at 33 weeks in a fetus with a 25% risk for CF shows a small volume of ascites  and mildly echogenic bowel . **(Right)** Another image in the same patient shows a loop of dilated bowel , as well as the ascites  and echogenic bowel , all features of bowel perforation with meconium peritonitis. Fetus was confirmed to have CF and a meconium ileus postnatally. Although the US appearance can be identical to ileal atresia, CF should always be considered in the differential of dilated distal small bowel.



TERMINOLOGY**Abbreviations**

- Cystic fibrosis (CF)

Definitions

- Autosomal recessive multisystem disorder caused by dysfunctional chloride ion transport across epithelial surfaces

IMAGING**General Features**

- Best diagnostic clue
 - Echogenic bowel in 2nd trimester progressing to bowel dilation in 3rd trimester

Ultrasonographic Findings

- Echogenic bowel in 2nd trimester
 - Echogenicity greater than bone considered abnormal
 - Increased echogenicity likely secondary to inspissated mucus in bowel lumen
 - Risk of fetus with echogenic bowel having CF varies between studies
 - In large study where CF was common, 9.9% with echogenic bowel had CF
- Meconium ileus
 - Dilated, echogenic small bowel
 - Appearance often indistinguishable from ileal atresia
- Perforation with meconium peritonitis
 - 8% of fetuses with meconium peritonitis have CF

DIFFERENTIAL DIAGNOSIS**Other Causes of Echogenic Bowel**

- Aneuploidy, especially trisomy 21
 - Look for associated findings, soft markers
- Infection
 - CMV most common
- Bowel ischemia
- Swallowed blood

Ileal Atresia

- May be indistinguishable from CF on prenatal US

PATHOLOGY**General Features**

- Etiology
 - Caused by mutations in gene that encodes CF transmembrane conductance regulator (*CFTR*)
 - > 1,700 mutations identified to date
- Genetics
 - Autosomal recessive (25% recurrence risk)

CLINICAL ISSUES**Presentation**

- CF testing is part of newborn screening in many states
 - Leads to earlier diagnosis, earlier treatment with prevention of severe nutritional deficiencies
- May present in neonatal period with failure to pass meconium or in infancy with severe failure to thrive

- Respiratory system most common affected
 - Recurrent infections, mucus plugging
 - Bronchiectasis, hyperinflation, cystic disease, spontaneous pneumothorax
 - Nasal polyps, sinusitis
- GI system
 - Malabsorption from pancreatic insufficiency; diabetes (lifetime risk 40-50%)
- Male infertility secondary to congenital bilateral absence of vas deferens
 - Vas deferens blocked by mucus

Demographics

- 1:2,500 births in non-Hispanic whites; 30,000 children and adults in USA have CF (70,000 worldwide)
- Carrier rate 1/24 (Ashkenazi Jewish); 1/25 (non-Hispanic white) to 1/94 in (Asian American)
- Highest prevalence in Caucasians of northern European origin
 - Delta F508, most commonly occurring mutation of *CFTR* gene, is found in 85% of Caucasians with CF

Natural History & Prognosis

- Median survival currently 37.4 yr, although life expectancy continues to improve
 - Life expectancy of children will exceed 40 yr; individuals with adequate pancreatic function may survive into 50s

Treatment

- Echogenic bowel on US → mutation screen in parents
- Amniocentesis for detection of mutation in fetus
 - Noninvasive testing in development
- Genetic counseling
 - Chorionic villus sampling or preimplantation genetic diagnosis may be offered in future pregnancies if mutations known
 - Standard of care: Offer CF screening to anyone who is pregnant or planning pregnancy
 - Sensitivity of screening test varies among ethnic groups, ranging from < 50% (Asian) to 94% (Ashkenazi Jewish)

DIAGNOSTIC CHECKLIST**Consider**

- Normal US exam does not rule out CF
 - Echogenic bowel/meconium ileus only seen in 11% of cases
- Negative mutation screen does not eliminate carrier risk
 - Non-Hispanic white with negative screen (1/25 a priori risk) still has 1/200 residual risk of being carrier
- Meconium ileus may be indistinguishable from ileal atresia
 - Offer work-up for CF in all cases of fetal bowel obstruction

SELECTED REFERENCES

1. Langfelder-Schwind E et al: Molecular testing for cystic fibrosis carrier status practice guidelines: recommendations of the National Society of Genetic Counselors. *J Genet Couns*. 23(1):5-15, 2014
2. American College of Obstetricians and Gynecologists Committee on Genetics: ACOG Committee Opinion No. 486: Update on carrier screening for cystic fibrosis. *Obstet Gynecol*. 117(4):1028-31, 2011

Diabetic Embryopathy

KEY FACTS

TERMINOLOGY

- Pregestational diabetes (type I or II): Diabetes mellitus diagnosis predates pregnancy
- Controversy exists regarding risk of anomalies in gestational diabetes
 - Anomalies may reflect an undiagnosed type II diabetic

IMAGING

- Central nervous system anomalies: 3-20x increase over nondiabetic
 - Anencephaly, spina bifida
 - Holoprosencephaly
- Caudal dysplasia/regression sequence
- Cardiac anomalies: 5x increase over nondiabetic
- Extremities
 - Preaxial polydactyly of feet, syndactyly
 - Femoral hypoplasia, angulated bones
- Genitourinary and gastrointestinal anomalies
- Polyhydramnios common

- Imaging recommendations



- Monthly ultrasound to evaluate fetal growth, amniotic fluid volume
- Thorough evaluation of fetal anatomy in every diabetic
- Endovaginal ultrasound for better early anatomic evaluation
- Fetal echocardiography to evaluate heart

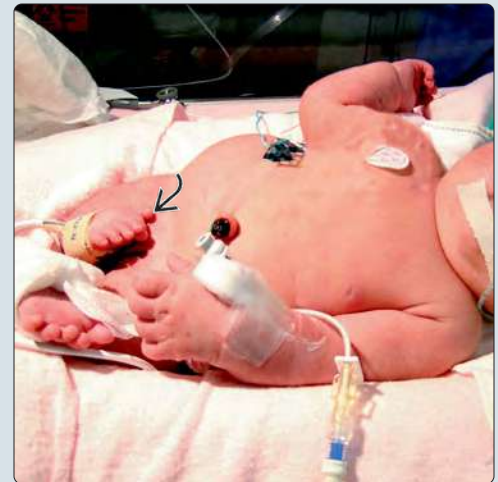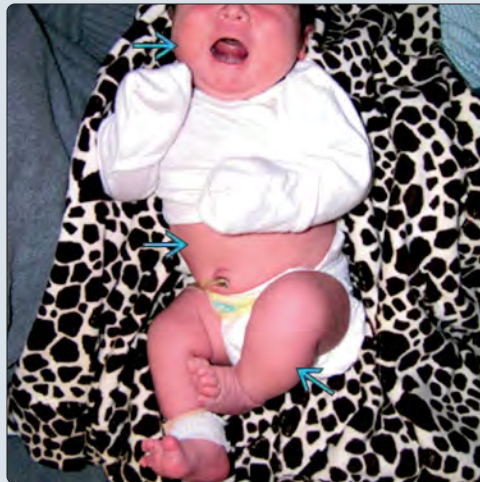PATHOLOGY




- Major malformations in 6-10% of infants born to diabetic mothers
 - 2-5x higher rate than in nondiabetics
 - Poor metabolic control, especially in 1st trimester, increases risk of malformations
 - Structural anomalies, especially cardiac, account for 50% of perinatal deaths

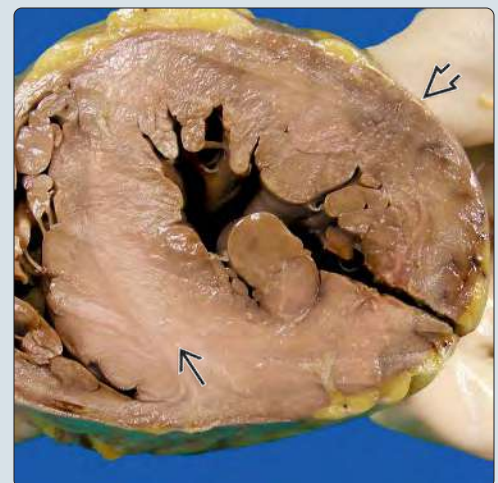
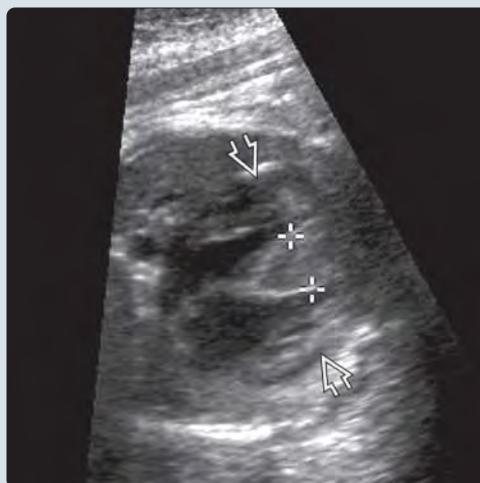
CLINICAL ISSUES

- Preconceptional planning is critical, with goal of euglycemia to minimize malformation risk

(Left) Clinical photo shows macrosomic newborn of a longstanding diabetic who weighed 5,240 grams at birth at 38-week gestation. Despite excellent glycemic control, overgrowth is evident. Note the increased fat distribution . (Right) In comparison, this near-term infant with diabetic embryopathy has severe anomalies of the pelvis, lower extremities, spine, and kidneys. Preaxial duplication of the hallux  is often seen in diabetic embryopathy. The infant died shortly after birth.



(Left) Four-chamber view of the heart of a 3rd trimester fetus of a poorly controlled diabetic shows changes associated with diabetic cardiomyopathy; there are biventricular myocardial hypertrophy  and a very thick interventricular septum (calipers). (Right) Short-axis section of the left ventricle in a similar case shows dramatic thickening of the interventricular septum , as well as the free wall . (From DP: Nonneoplastic Pediatrics.)



TERMINOLOGY

Definitions

- Pregestational diabetes (type I or II): Diabetes mellitus diagnosis predates pregnancy
- Gestational diabetes mellitus (GDM): Any degree of glucose intolerance initially diagnosed during pregnancy
 - Diagnosis by oral glucose tolerance test from 24-28 weeks gestation
 - GDM, by definition, resolves following pregnancy, although recurrence in subsequent pregnancies is common
 - Increased risk of developing type II diabetes (40-50% within 10 years)
 - Controversy exists regarding risk of anomalies in GDM
 - Anomalies in GDM may reflect undiagnosed type II diabetic

IMAGING

General Features

- Best diagnostic clue
 - Abnormal growth + structural anomalies in fetus of diabetic mother
 - May be macrosomic (> 90th percentile), large for gestational age (LGA), or growth restricted
 - Common anomalies include cardiac, central nervous system (CNS), renal, and skeletal

Ultrasonographic Findings

- In GDM, fetus often macrosomic
 - Accelerated growth apparent by late 2nd trimester
 - Disproportionate increase in abdominal and head circumferences
 - Increased skin thickness of trunk, head
 - Polyhydramnios common
- Fetal growth restriction more common in pregestational diabetics
- Caudal dysplasia/regression sequence
 - Malformation complex characterized by varying degrees of developmental failure involving legs, lumbar, sacral and coccygeal vertebrae, and corresponding segments of spinal cord
 - Lower extremity malposition ("tailor's posture" or "Buddha pose")
 - 16% of cases due to maternal diabetes
- CNS anomalies: 3-20x increase over nondiabetic
 - Anencephaly, spina bifida
 - Holoprosencephaly
- Cardiac anomalies: 5x increase over nondiabetic
 - Transposition of great arteries
 - Truncus arteriosus
 - Heterotaxy
 - Cardiomyopathy (may be transient)
 - May be seen in poorly controlled gestational diabetic
- Extremities
 - Preaxial polydactyly of feet, syndactyly
 - Femoral hypoplasia, angulated bones
- GU
 - Renal agenesis
 - Multicystic kidneys

- GI
 - Anorectal malformation/atresia
- Single umbilical artery (6%)
- Polyhydramnios common
 - Seen in both pregestational and gestational diabetics
 - Often associated with macrosomic fetuses
- Oligohydramnios more common in pregnancies of longstanding diabetics
 - Often associated with fetal growth restriction

Imaging Recommendations

- Thorough evaluation of fetal anatomy in every diabetic
 - Maternal obesity makes detection of subtle anomalies difficult
- Endovaginal ultrasound for better early anatomic evaluation
 - Significant malformations often detectable by late 1st trimester
 - Holoprosencephaly, anencephaly
 - Increased nuchal translucency associated with increased risk of cardiac defects
- Monthly ultrasound to evaluate fetal growth, amniotic fluid volume
- Fetal echocardiography to evaluate heart
 - Justifiable even with normal glycosylated hemoglobin
- Consider fetal MR to evaluate intracranial anomalies or when maternal body habitus precludes complete ultrasound examination

DIFFERENTIAL DIAGNOSIS

Aneuploidy

- Findings vary according to condition
- Often growth restricted not macrosomic

Macrosomia

- May be seen without diabetes ± polyhydramnios
- Overgrowth syndromes: Beckwith-Wiedemann, Weaver, Soto, Marshall-Smith

Congenital Heart Defects

- Isolated or syndromal

Caudal Regression Sequence

- Although rare, also found in nondiabetics

Neural Tube Defects (NTDs)

- Isolated vs. syndromal

PATHOLOGY

General Features

- Major malformations in 6-10%
 - 2-5x higher rate than in nondiabetics
 - Poor metabolic control, especially in 1st trimester, increases risk of malformations
 - Structural anomalies, especially cardiac, account for 50% of perinatal deaths
- Glycosylated hemoglobin (HbA_{1c}) provides retrospective index of glycemic status over preceding 8-12 weeks and correlates with risk of malformations
 - < 6.9% → minimal increased risk over baseline
 - 7-8.5% → 5% anomalies

- > 10% → 22% anomalies
- Even with excellent glycemic control, risk of malformations greater than that in nondiabetic
- Controversy over whether malformation risk increased in true GDM
 - Overt diabetic first recognized during pregnancy has similar risk for embryopathy as known pregestational diabetic
- Cystic fibrosis-related diabetes (CFRD)
 - Uncertain malformation risk due to rarity of pregnancy in this condition
- Epidemiology of diabetes in pregnancy
 - Pregestational
 - 25.3 per 1,000 pregnant women; 13% of all diabetes in pregnancy
 - Prevalence increasing in USA, in parallel with ↑ obesity rate
 - Rate varies with ethnic group (greatest for Native Americans) and age (higher with older women)
 - GDM
 - According to CDC, GDM is estimated to affect 1-14% of pregnancies in USA, depending upon population studied and diagnostic test used
 - Risk factors include older age, multiple gestation, obesity, previous GDM or macrosomic infant
- Etiology of diabetic embryopathy
 - Metabolic derangements associated with hyperglycemia contribute to teratogenesis
 - Exact mechanism uncertain but likely multifactorial
 - Many theories center on role of hyperglycemia in increasing oxidative stress
 - Hyperglycemia triggers apoptotic signaling pathways
 - Inhibit cell survival pathways → embryonic malformations
 - Caspases (cysteine proteases active in cascade of apoptosis) currently under investigation for their role in pathogenesis of diabetic embryopathy
 - Inhibitors of caspase activation may have protective effect against high glucose-induced NTDs

Staging, Grading, & Classification

- Classification system developed over 50 years ago by White and Pedersen identified diabetic pregnancies at increased risk for perinatal mortality; no longer commonly used
- Classification based on age at diagnosis, years of duration
 - Longer duration or earlier onset → ↑ risk of vascular disease, including placenta

Microscopic Features

- Abnormal placenta
 - Thickened basal membrane, decreased vascular surface of terminal villi
 - Fibrinoid necrosis, villous immaturity, chorangiomas

CLINICAL ISSUES

Presentation

- Major malformation in known diabetic

Natural History & Prognosis

- Increased spontaneous abortions with poor glycemic control

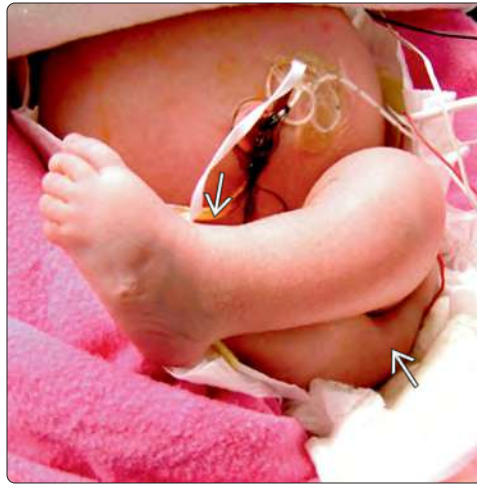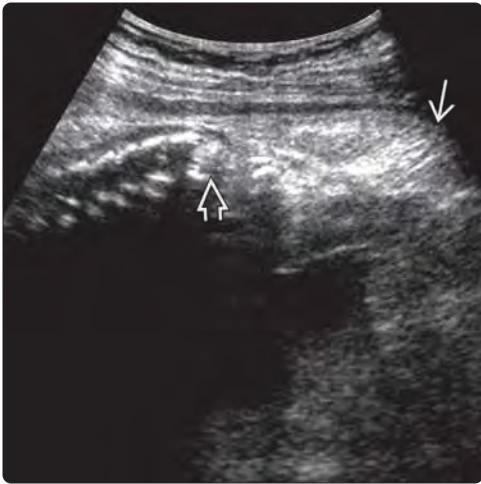
- Increased incidence of stillbirth: 4x more likely than nondiabetics
 - Higher if mother has fasting hyperglycemia
- Perinatal mortality: Infant death 1.9x more likely than nondiabetic
- Increased birth trauma and cesarean section rate, especially in macrosomic infants
 - Dystocia during delivery unpredictable but likely related to truncal obesity
 - Nerve injury/palsy may be transient or permanent
- Newborn complications
 - Hypoglycemia
 - Hyperbilirubinemia
 - Hypothermia
- Long-term prognosis dependent upon presence, type of structural malformations
 - Some, like alobar holoprosencephaly and caudal dysplasia, are lethal or life-limiting
- LGA infants exposed to diabetic milieu in utero are at increased risk for development of metabolic diseases later in life
 - Obesity, hypertension, dyslipidemia, glucose intolerance
 - Epigenetic modification of gene expression influences intrauterine programming

Treatment

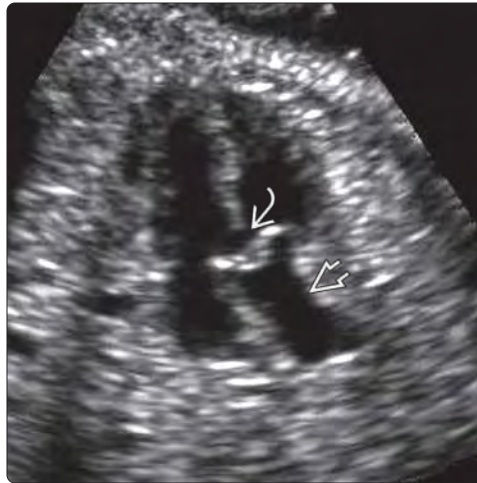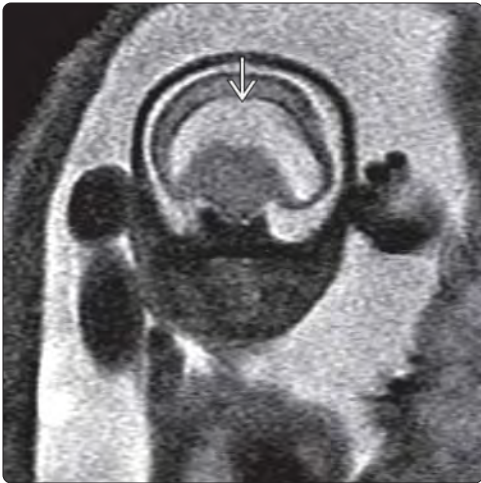- Maternal
 - Preconceptional planning is critical, with goal of euglycemia to minimize malformation risk
 - Strict metabolic control throughout pregnancy with goal of HbA_{1c} < 6
 - Assess for evidence of maternal end-organ disease or dysfunction
 - Renal, hypertension, cardiac, ophthalmologic
 - Preconceptional folic acid, while recommended for all women of reproductive age, is of uncertain efficacy in preventing diabetes-associated NTD
 - Pregnancy termination an option with multiple or severe malformations
- Fetal
 - Thorough ultrasound evaluation of fetal anatomy
 - Fetal echocardiogram
 - Close fetal surveillance
 - Non-stress testing, biophysical profiles, serial ultrasounds for growth

SELECTED REFERENCES

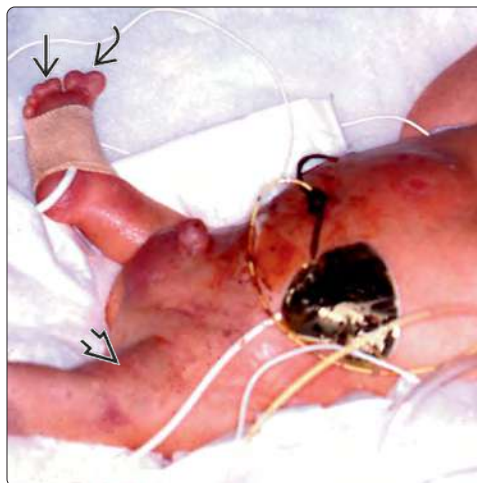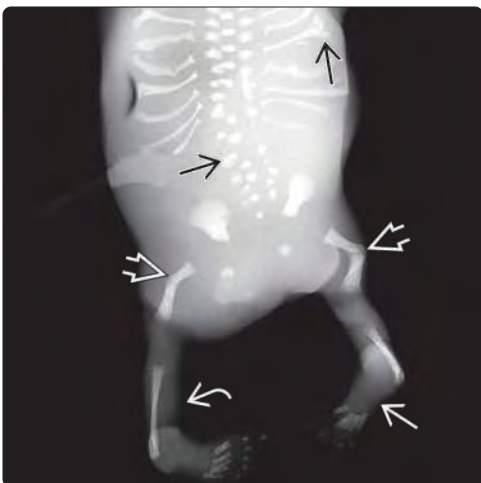
1. Bohuslavova R et al: Gene expression profiling of changes induced by maternal diabetes in the embryonic heart. *Reprod Toxicol.* 57:147-56, 2015
2. Dong D et al: New development of the yolk sac theory in diabetic embryopathy: molecular mechanism and link to structural birth defects. *Am J Obstet Gynecol.* 214(2): 192-202, 2015
3. Dong D et al: Maternal diabetes triggers DNA damage and DNA damage response in neurulation stage embryos through oxidative stress. *Biochem Biophys Res Commun.* 467(2):407-12, 2015
4. Gabbay-Benziv R et al: Birth defects in pregestational diabetes: Defect range, glycemic threshold and pathogenesis. *World J Diabetes.* 6(3):481-8, 2015
5. López-Escobar B et al: The effect of maternal diabetes on the Wnt-PCP pathway during embryogenesis as reflected in the developing mouse eye. *Dis Model Mech.* 8(2):157-68, 2015



(Left) Sagittal ultrasound of a 3rd-trimester fetus of a poorly controlled pregestational diabetic shows a severe spine abnormality. Lumbosacral agenesis is noted with the spine ending at L1. The skin edge over the buttocks is also seen. (Right) Clinical photograph of a term infant of a poorly controlled diabetic shows fixed, abnormally crossed legs (the so-called tailor's posture) associated with caudal regression. No spontaneous movement of the legs was noted. The infant also had a heart defect.



(Left) Coronal T2WI MR of a fetus of a diabetic mother shows lack of midline differentiation and a monoventricle, diagnostic of alobar holoprosencephaly. (Right) This fetus of a diabetic mother had truncus arteriosus. There is a small ventricular septal defect and a single great vessel exiting the heart. Fetal cardiac defects occur 5x more often in diabetics than in the nondiabetic population. Fetal echocardiography is warranted even in well-controlled patients.



(Left) Radiograph of a stillborn with severe diabetic embryopathy shows multiple skeletal anomalies. Note vertebral and rib segmentation abnormalities as well as bilateral dysplastic angulated femora, fibular aplasia, and clubfeet. (Right) Clinical photograph in another case shows femoral hypoplasia and a complex pattern of polysyndactyly, which is often seen with diabetic embryopathy. Note the preaxial duplication of the hallux and the syndactyly of toes 2-3.

KEY FACTS

TERMINOLOGY

- Cryptophthalmos-syndactyly syndrome

IMAGING

- Small, absent eyes
 - Measure ocular diameter and compare to normative data
- Urinary tract anomalies
- Syndactyly
- Laryngeal/tracheal anomalies may cause airway narrowing resulting in congenital high airway obstruction

TOP DIFFERENTIAL DIAGNOSES

- Anophthalmia/microphthalmia
 - Trisomy 13, Walker-Warburg, and CHARGE syndrome
- Multiple syndromes are associated with congenital anomalies of kidney or urinary tract and extrarenal manifestations

- Branchio-oto-renal, Wolf-Hirschhorn, Bardet-Biedl, Smith-Lemli-Opitz, and renal coloboma syndrome

PATHOLOGY




- Mutations in *FRAS1*, *FREM2*, and *GRIP1* genes
 - All function in interaction of ureteric bud and metanephric mesenchyme

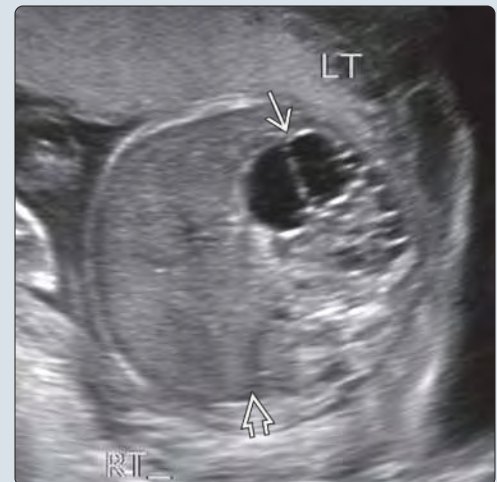
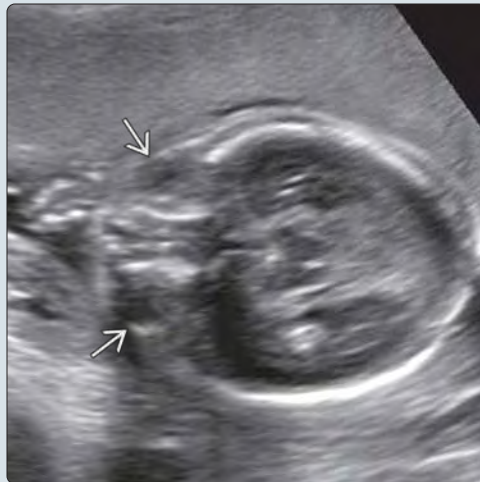
CLINICAL ISSUES



- Often lethal when diagnosed prenatally
- Long-term survival dependent on number and severity of anomalies

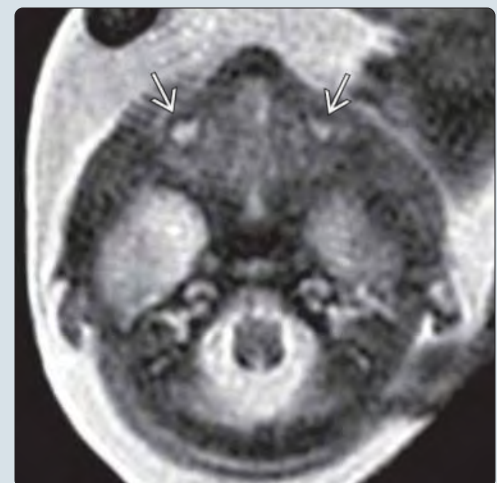
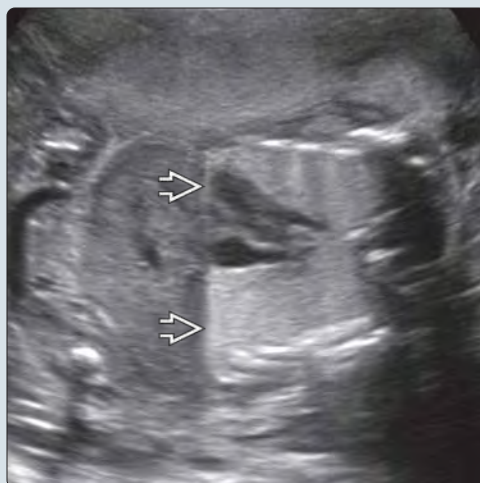
DIAGNOSTIC CHECKLIST

- Fetal renal/urinary tract anomalies are common and may be isolated, but always evaluate for extrarenal findings
- Renal and facial abnormalities are common association in many syndromes

(Left) Axial US through the orbits at 20 weeks shows microphthalmia . Note the intraocular diameter appears large (remember a 3rd eye should fit in this space). This can be because the eyes are small, as in this case, or there is hypertelorism. **(Right)** Axial US through the abdomen, in the same case, shows a multicystic dysplastic kidney on the left side , with no kidney seen in the right renal fossa . When there are both eye and renal anomalies present, Fraser syndrome should be considered.



(Left) Coronal US through the chest, in the same case, shows hyperexpanded, echogenic lungs from a congenital high airway obstruction, another associated finding. Note the flattening of the diaphragms . The renal anomalies will result in oligohydramnios. **(Right)** Axial T2WI MR of a 27-week fetus shows severe bilateral microphthalmia . This is one of the hallmark findings in Fraser syndrome.



TERMINOLOGY

Synonyms

- Cryptophthalmos-syndactyly syndrome (OMIM 219000)

IMAGING

Ultrasonographic Findings

- Small, absent eyes
 - Anophthalmia, microphthalmia, cryptophthalmia
 - Axial view at level of eyes
 - Evaluate bony orbit and globes
 - Measure ocular diameter (OD) and compare to normative data
 - Rule of thirds for normal biometry
 - Normal intraocular diameter (IOD) = OD
 - 3rd eye should fit between orbits
 - If IOD is large, either globe is small (as in Fraser syndrome) or there is hypertelorism
- Urinary tract anomalies
 - Renal agenesis/hypoplasia
 - Multicystic dysplastic kidneys
- Syndactyly
- Laryngeal/tracheal anomalies
 - May cause airway narrowing resulting in congenital high airway obstruction
 - Enlarged echogenic lungs
 - Eversion of diaphragm
 - Compression of heart
 - Ascites common and may be severe
- Oligohydramnios secondary to renal anomalies
- 3D US helpful for evaluating face but often limited if oligohydramnios present

DIFFERENTIAL DIAGNOSIS

Anophthalmia/Microphthalmia

- Trisomy 13
- Walker-Warburg syndrome: Congenital muscular dystrophy associated with brain and eye abnormalities
 - Persistent hyperplastic primary vitreous may present as hyperechoic bands or mass within globe
- CHARGE syndrome: Coloboma, heart anomaly, choanal atresia, retardation, genital, and ear anomalies
- SOX2-related eye disorders

CAKUT Syndromes

- Defective urinary tract development often referred to as congenital anomalies of kidney or urinary tract (CAKUT)
- Multiple syndromes have CAKUT and extrarenal manifestations, many of which have overlapping features
- Wolf-Hirschhorn or 4p deletion syndrome: Deletion of end of 4p; dysmorphic facial features, delayed growth, intellectual disability, CAKUT
- Renal hypoplasia: *BMP4*, *SIX2*; microphthalmia, cleft lip, renal hypoplasia/dysplasia
- Bardet-Biedl syndrome: Many cilia genes; retinopathy, digital anomalies, obesity, male hypogonadism, renal dysplasia
- Smith-Lemli-Opitz syndrome: Cholesterol biosynthesis (*DHCR7*); dysmorphic facial features, microcephaly, syndactyly, intellectual impairment, dysplastic kidneys

- Branchio-oto-renal syndrome: *EYA1*, *SIX1*, *SIX5*, *MYOG*; deafness, branchial cysts, CAKUT
- Renal coloboma syndrome: *PAX2*; retinal coloboma, CAKUT

PATHOLOGY

General Features

- Genetics
 - Autosomal recessive
 - Consanguinity in many cases
 - Mutations in *FRAS1*, *FREM2*, and *GRIP1* genes
 - All function in interaction of ureteric bud and metanephric mesenchyme

CLINICAL ISSUES

Presentation

- Most common signs/symptoms
 - Renal anomaly most obvious
 - Look carefully for other findings
- Postnatal diagnosis made by combination of major and minor findings
 - Major criteria
 - Cryptophthalmos spectrum
 - Urinary tract abnormalities
 - Ambiguous genitalia
 - Laryngeal and tracheal anomalies
 - Positive family history
 - Minor criteria
 - Anorectal defects
 - Dysplastic ears
 - Skull ossification defects
 - Cleft lip/palate
 - Umbilical hernia

Demographics

- 1:200,000 live borns
- 1:10,000 fetus

Natural History & Prognosis

- Often lethal
- Long-term survival dependent on number and severity of anomalies
- Developmental delay and low IQ seen in many survivors

DIAGNOSTIC CHECKLIST

Image Interpretation Pearls

- Fetal renal/urinary tract anomalies are common and may be isolated, but always evaluate for extrarenal findings
- Renal and facial abnormalities are common association in many syndromes

SELECTED REFERENCES

1. Ozemri Sag S et al: A novel mutation in the *FRAS1* gene in a patient with Fraser syndrome. *Genet Couns.* 26(1):21-7, 2015
2. Kohl S et al: Mild recessive mutations in six Fraser syndrome-related genes cause isolated congenital anomalies of the kidney and urinary tract. *J Am Soc Nephrol.* 25(9):1917-22, 2014
3. Barisic I et al: Fraser syndrome: epidemiological study in a European population. *Am J Med Genet A.* 161A(5):1012-8, 2013
4. Mesens T et al: Congenital high airway obstruction syndrome (CHAOS) as part of Fraser syndrome: ultrasound and autopsy findings. *Genet Couns.* 24(4):367-71, 2013

KEY FACTS

TERMINOLOGY

- Autosomal recessive multiple congenital anomaly syndrome characterized by congenital diaphragmatic hernia (CDH) with pulmonary hypoplasia, characteristic facial appearance, distal digital hypoplasia

IMAGING

- CDH most obvious finding and should prompt search for other features
- 3D/4D ultrasound may be useful in delineating facial and digital abnormalities, especially in high-risk families
 - Micrognathia, hypertelorism
- Cardiac anomalies
- Polyhydramnios
- Digital hypoplasia may not be apparent on ultrasound
- Fryns syndrome identified in up to 10% of syndromic CDH

TOP DIFFERENTIAL DIAGNOSES

- Pallister-Killian syndrome

- Trisomy 18
- Cornelia de Lange syndrome
- Isolated diaphragmatic hernia

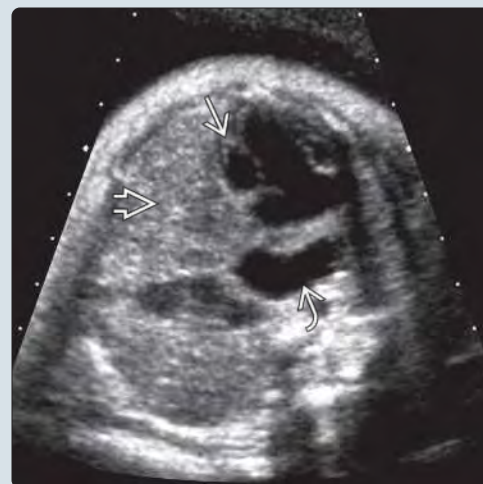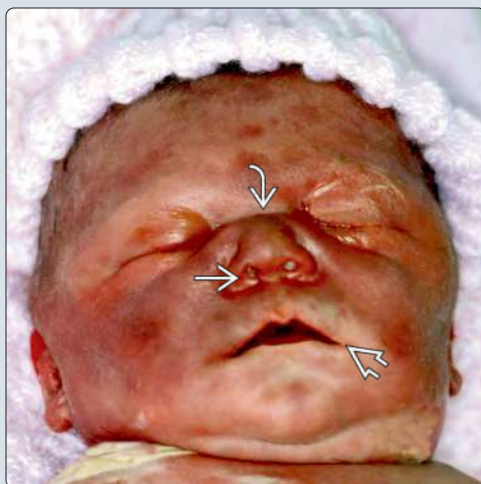PATHOLOGY

- Autosomal recessive
- No genes or loci have been identified or mapped to date

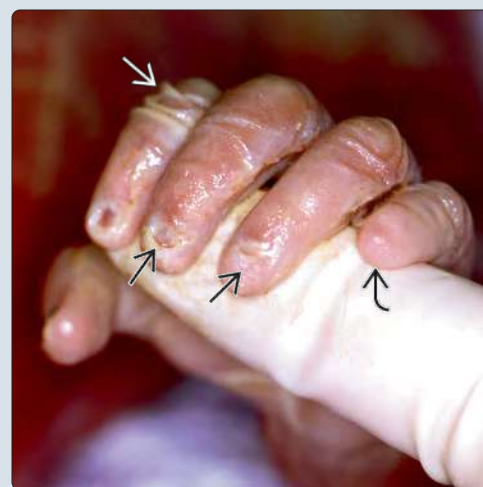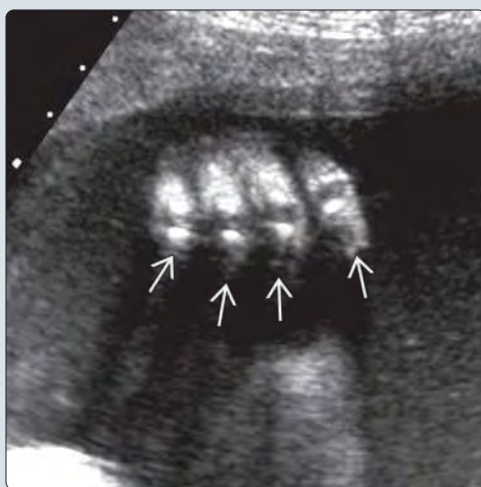
CLINICAL ISSUES

- Most are stillborn or die in neonatal period
- CDH most obvious in utero finding (89%)
- Other prenatal/postnatal findings
 - Craniofacial: Coarse facies (100%), broad nasal bridge
 - Extremities: Distal digital hypoplasia (near 100%)
 - Cardiac defects in ~ 50% of cases
 - Genitourinary abnormalities (86%)
 - Central nervous system abnormalities (50%)
 - Gut malrotation, pulmonary hypoplasia, anorectal anomalies

(Left) Clinical photograph shows a preterm stillborn infant with Fryns syndrome. Note the coarse face, broad depressed nasal bridge, anteverted nares, thin lips, and downturned mouth. Characteristic digital abnormalities were noted postnatally. **(Right)** Transverse ultrasound of an early 3rd-trimester fetus with Fryns syndrome shows a large congenital diaphragmatic hernia with liver and stomach in the chest. A hypoplastic left heart is also seen.



(Left) Ultrasound of the hand of a fetus with Fryns syndrome shows apparent distal hypoplasia of all the digits. This is a common feature in this syndrome but is difficult to ascertain prenatally. **(Right)** Clinical photograph of the hand of an infant who was stillborn and diagnosed postnatally with Fryns syndrome shows the varying degrees of distal digital and nail hypoplasia. Both hands and feet may be affected. The skin slippage is due to intrauterine fetal demise, which is also common in Fryns.



TERMINOLOGY**Definitions**

- Autosomal recessive multiple congenital anomaly syndrome characterized by congenital diaphragmatic hernia (CDH) with pulmonary hypoplasia, characteristic facial appearance, distal digital hypoplasia

IMAGING**Ultrasonographic Findings**

- CDH most obvious finding and should prompt search for other features
- Micrognathia, hypertelorism, cardiac defects
- Polyhydramnios
- Digital hypoplasia may not be apparent on ultrasound
- Fryns syndrome identified in up to 10% of syndromic CDH

Imaging Recommendations

- Best imaging tool
 - 3D/4D ultrasound may be useful in delineating facial and digital abnormalities, especially in high-risk families
 - MR used to confirm and characterize CDH location, liver involvement

DIFFERENTIAL DIAGNOSIS**Pallister-Killian Syndrome**

- Tissue-specific mosaic tetrasomy 12p due to supernumerary isochromosome 12p
- CDH, polyhydramnios, rhizomelia, cardiac malformations, polydactyly
- Coarse facies, severe intellectual impairment, pigmentary abnormalities
- Diagnosis generally made in older infant with developmental delay and coarse facies in contrast to perinatal lethality in Fryns

Trisomy 18

- Fetal growth restriction (FGR), radial ray defects, cardiac defects
- CDH occasional finding

Cornelia de Lange Syndrome

- Characteristic facies: Fine arched eyebrows, long smooth philtrum, thin lips, crescent-shaped mouth
- Limb defects variable from small hands to severe limb reduction abnormalities
- CDH
- Cardiac defects, intellectual impairment, FGR, gastrointestinal abnormalities, hypertrichosis

Isolated Diaphragmatic Hernia

- Must carefully exclude other anomalies
- Most are sporadic, but dominant, recessive, and X-linked familial cases reported

PATHOLOGY**General Features**

- Genetics
 - Autosomal recessive
 - No genes or loci have been identified or mapped to date

- Variety of chromosome translocations found in Fryns patients

CLINICAL ISSUES**Presentation**

- CDH most obvious in utero finding (89%)
- Polyhydramnios
- Other prenatal/ postnatal findings
 - Craniofacial
 - Coarse facies (100%), broad nasal bridge, hypertelorism, macrostomia, micrognathia, anteverted nares, poorly formed ears, orofacial cleft, thin lips
 - Extremities
 - Distal digital hypoplasia (near 100%): Hypoplastic/absent nails and hypoplastic distal phalanges (brachytelephalangy)
 - Cardiac defects in ~ 50% of cases (ASD, VSD, conotruncal, aortic arch abnormalities)
 - Central nervous system (50%)
 - Agenesis of corpus callosum, hypoplasia of optic/olfactory tracts, microphthalmia, cloudy cornea
 - Neurologic impairment with intellectual impairment in survivors
 - Genitourinary (86%)
 - Müllerian anomalies, hypospadias, cryptorchidism, cystic renal dysplasia (54%)
 - Gut malrotation, pulmonary hypoplasia/agenesis, anorectal anomalies
 - Cystic hygroma, hydrops, pterygia in early fetal life

Demographics

- Epidemiology
 - Estimated 1/15,000 births

Natural History & Prognosis

- Most are stillborn or die in neonatal period
- Rare reports of survival into late infancy, early childhood with severe intellectual impairment
 - Survivors less likely to have CDH or cardiac defect; less severe pulmonary hypoplasia

Treatment

- No prenatal treatment
- Pregnancy termination should be offered

DIAGNOSTIC CHECKLIST**Consider**

- 3D ultrasound for evaluation of face and distal extremities when Fryns syndrome suspected

SELECTED REFERENCES

1. Peron A et al: Prenatal and postnatal findings in five cases of Fryns syndrome. *Prenat Diagn.* 34(12):1227-30, 2014
2. Slavotinek AM: The genetics of common disorders - congenital diaphragmatic hernia. *Eur J Med Genet.* 57(8):418-23, 2014
3. Kantarci S et al: Characterization of the chromosome 1q41q42.12 region, and the candidate gene *DISP1*, in patients with CDH. *Am J Med Genet A.* 152A(10):2493-504, 2010
4. Slavotinek AM: Fryns syndrome: a review of the phenotype and diagnostic guidelines. *Am J Med Genet A.* 124(4):427-33, 2004

Goldenhar Syndrome

KEY FACTS

TERMINOLOGY

- Oculo-auriculo-vertebral spectrum (OAVS)
- Developmental disorder involving structures derived from 1st and 2nd pharyngeal arches
- Microtia (small external ear) or hemifacial microsomia + ear malformations suggested as minimal criteria

IMAGING

- Prenatal diagnosis mostly based on detection of facial anomalies, especially if part of multiple anomaly complex
- "Hemifacial" terminology implies unilateral but majority have bilateral, asymmetric involvement
- 3D US very helpful in evaluation of ears/ear tags, asymmetric facies

TOP DIFFERENTIAL DIAGNOSES

- CHARGE syndrome
 - Characteristic ear shape, semicircular canal abnormalities
- Treacher Collins syndrome

- Severe micrognathia, downward-sloping eyes

PATHOLOGY

- Usually sporadic but reports of autosomal dominant/recessive cases
- 2-3% empiric recurrence risk if normal chromosomes, no family history

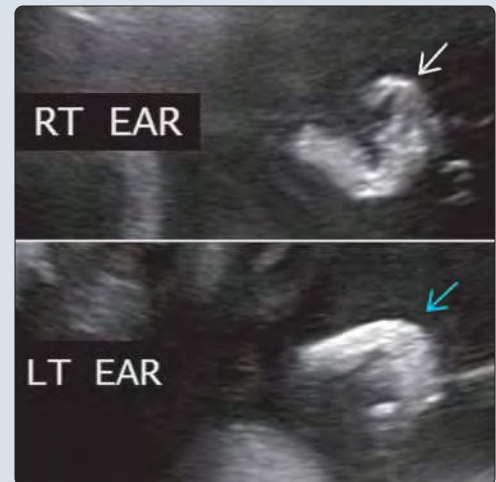
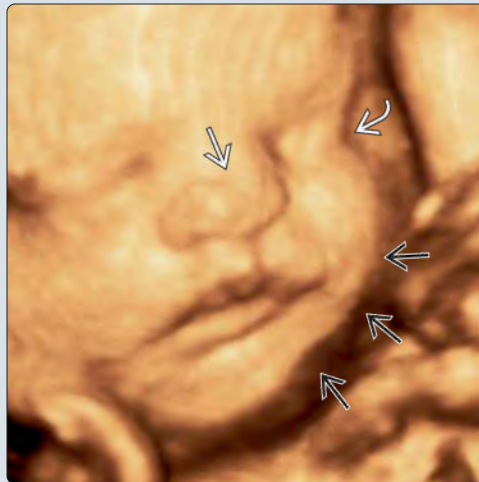CLINICAL ISSUES

- Prognosis determined by associated abnormalities
- Hearing loss, feeding difficulties, speech impediment, sleep disorder
- Adverse psychological impact of abnormal appearance on child and family

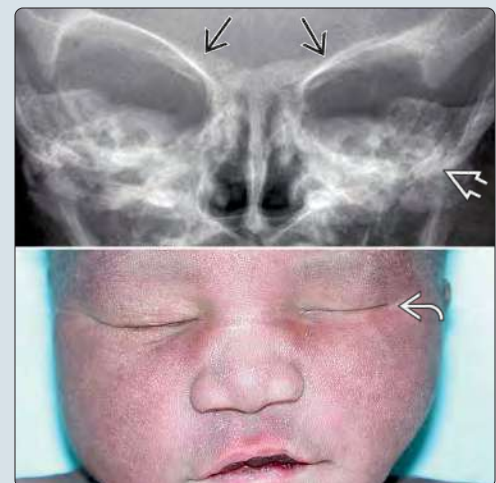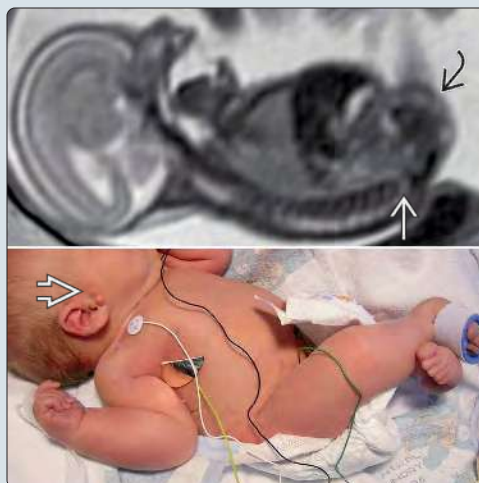DIAGNOSTIC CHECKLIST

- Fetal cases represent most severe end of spectrum
- Very broad phenotype, fetal diagnosis may be impossible even with positive family history

(Left) 3D US in a patient referred with cleft lip shows that there is no cleft; rather, there is facial asymmetry with a shallow orbit on the left as well as a distorted nasal tip. **(Right)** The ears were asymmetric with a normal pinna on the right but a small flattened ear on the left. Facial and ear anomalies are common findings in Goldenhar syndrome. In this case, there were also subtle findings of agenesis of the corpus callosum manifested solely by absent cavum septi pellucidi and confirmed on fetal MR.



(Left) Sagittal T2WI MR in a fetus suspected to have caudal regression (maternal obesity limited US evaluation) confirms abrupt termination of the spine at L4 with small pelvis. Clinical photograph at birth confirms the short torso, and abnormal leg position and shows preauricular skin tags. Final diagnosis was OAVS. **(Right)** Autopsy radiograph shows asymmetry of the orbits and nonpatent external auditory canal. The left half of the face is small with associated unilateral microphthalmia.



TERMINOLOGY

Synonyms

- Oculo-auriculo-vertebral spectrum (OAVS)
 - Many now favor this as more precise term

Definitions

- Developmental disorder involving structures derived from 1st and 2nd pharyngeal arches
- No consensus on minimum diagnostic criteria
 - Microtia (small external ear) or hemifacial microsomia + ear malformations suggested as minimal criteria
 - Strict definition of microtia includes absence of external auditory meatus
 - Isolated hemifacial microsomia with family history of OAVS may be sufficient
 - ~ 50% of cases have additional cardiac, brain, pulmonary, or genitourinary abnormalities

IMAGING

MR Findings

- Can be helpful in ocular evaluation (e.g., coloboma)
- T2WI for facial architecture if limited acoustic access for 3D surface reconstruction
- Characterize suspected brain/spine malformations

Ultrasonographic Findings

- Prenatal diagnosis mostly based on detection of facial anomalies (52.4 %) especially if part of multiple anomaly complex with
 - Cardiac anomalies (19%)
 - Tetralogy of Fallot, transposition, septal defects, situs inversus, dextrocardia, arch anomalies
 - Cerebral malformation (47.6%)
 - Microcephaly, neural tube defects, callosal abnormalities, holoprosencephaly
 - Genitourinary anomalies
 - Unilateral renal agenesis, urinary tract dilation
 - Radial ray malformation

Imaging Recommendations

- Best imaging tool
 - 3D US very helpful in evaluation of ears/ear tags, asymmetric facies

DIFFERENTIAL DIAGNOSIS

CHARGE Syndrome

- Characteristic ear shape, semicircular canal abnormalities

Treacher Collins Syndrome

- Severe micrognathia, downward-sloping eyes

PATHOLOGY

General Features

- Maxillary ± mandibular hypoplasia, asymmetry of zygomatic arch, malar/temporal bones, external/middle ear, facial muscles
 - ± malformations of other branchial arch derivatives (e.g., eye, vertebrae, upper heart)
 - ± malformations of non-arch derivatives (e.g., kidneys)

- "Hemifacial" terminology implies unilateral but majority have bilateral, asymmetric involvement

Genetics

- Usually sporadic but reports of autosomal dominant/recessive cases
- Associated with many chromosomal abnormalities, genomic imbalances
- 2-3% empiric recurrence risk if normal chromosomes, no family history

CLINICAL ISSUES

Presentation

- Most common signs/symptoms
 - Majority have some facial asymmetry
 - Most unilateral but bilateral can occur usually with right side more severely involved
- Other signs/symptoms
 - Asymmetric ear anomalies
 - Orofacial clefts rare, macrostomia frequent
 - Ocular defects include epibulbar dermoids (common postnatal finding), microphthalmia
 - Vertebral anomalies

Demographics

- Epidemiology
 - 1:3-5,000 births

Natural History & Prognosis

- Prognosis determined by associated abnormalities
- Hearing loss, feeding difficulties, speech impediment, sleep disorder
- Adverse psychological impact of abnormal appearance on child and family

Treatment

- Supportive management in pregnancy
- Careful audiologic evaluation of infant
- Maxillofacial surgeries in attempt to correct asymmetry, restore more normal facial appearance

DIAGNOSTIC CHECKLIST

Consider

- Fetal cases represent most severe end of spectrum

Image Interpretation Pearls

- Very broad phenotype, fetal diagnosis may be impossible even with positive family history

SELECTED REFERENCES

1. Beleza-Meireles A et al: Oculo-auriculo-vertebral spectrum: Clinical and molecular analysis of 51 patients. *Eur J Med Genet.* 58(9):455-65, 2015
2. Puvabanditsin S et al: 7q21.11 Microdeletion in a neonate with Goldenhar syndrome: Case report and a literature review. *Cleft Palate Craniofac J.* 53(2):249-52, 2015
3. Beleza-Meireles A et al: Oculo-auriculo-vertebral spectrum: a review of the literature and genetic update. *J Med Genet.* 51(10):635-45, 2014
4. Guzelmansur I et al: Prenatal diagnosis of Goldenhar syndrome with unusual features by 3D ultrasonography. *Genet Couns.* 24(3):319-25, 2013
5. Vendramini-Pittoli S et al: Oculoauriculovertrebral spectrum: report of nine familial cases with evidence of autosomal dominant inheritance and review of the literature. *Clin Dysmorphol.* 18(2):67-77, 2009
6. Chi T et al: Prenatal sonographic imaging of Goldenhar syndrome associated with cystic eye. *Prenat Diagn.* 28(4):362-3, 2008

KEY FACTS

TERMINOLOGY

- Heart and hand syndrome characterized by upper extremity and cardiac malformations

IMAGING

- Radial ray defects may be seen in 1st trimester
 - 1st and most obvious finding in fetus with positive family history
- Variable degrees of radial deficiency, usually asymmetric
- Atrial septal defect most common cardiac anomaly but often not diagnosed on prenatal imaging
 - Fetal echocardiography recommended in fetus at high risk even without obvious limb defects

TOP DIFFERENTIAL DIAGNOSES

- Fanconi anemia
- Thrombocytopenia-absent radius (TAR)
- VACTERL association
- Isolated thumb hypoplasia

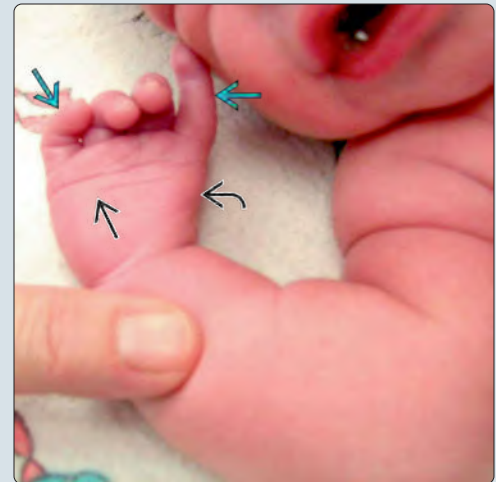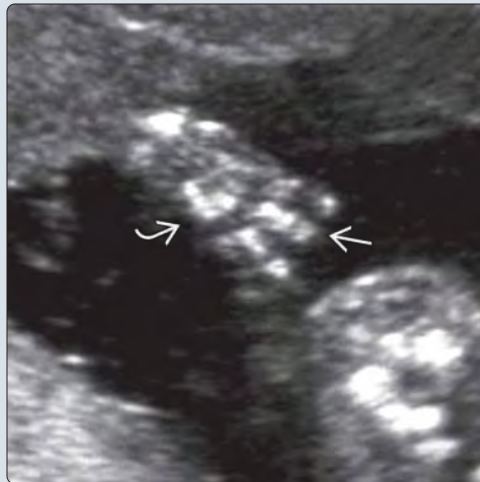
PATHOLOGY

- Caused by mutations in T-box transcription factor gene *TBX5* (12q24.21)
 - Function of *TBX5* is critical for initiation of forelimb growth

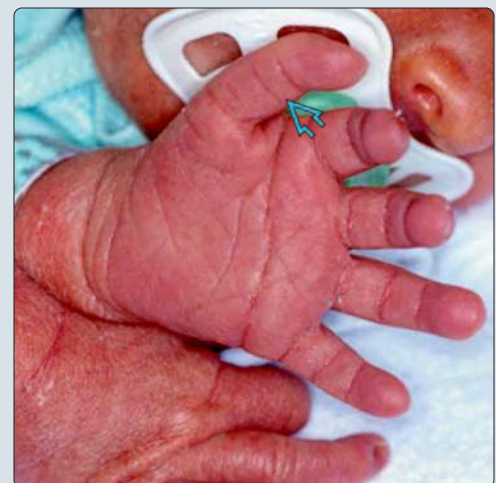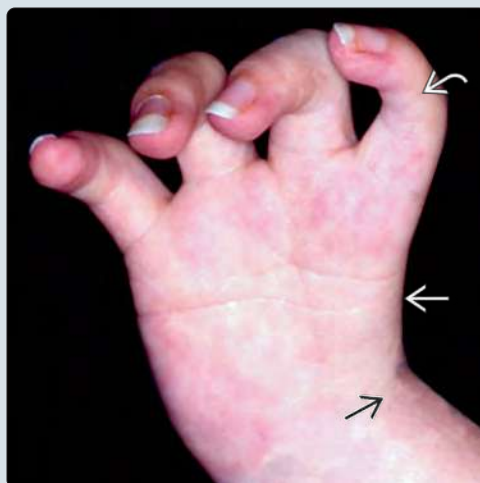CLINICAL ISSUES

- 1 in 100,000 live births
- ~ 85% result from de novo mutations
- Autosomal dominant with complete penetrance, variable expressivity
- Prenatal diagnosis by amniocentesis or chorionic villus sampling possible if *TBX5* mutation known
- Overall prognosis dependent upon severity of cardiac defect and degree of upper extremity malformation
 - Repair of cardiac abnormalities
 - Orthopedic repair of hand anomalies with goal of optimizing function

(Left) Midtrimester ultrasound of the hand of a fetus with Holt-Oram syndrome shows 4 digits and an absent thumb. A radial ray defect was also noted. (Right) Clinical photograph of the corresponding hand confirms that the thumb is absent and that the hand is radially deviated with only 4 digits. Clinodactyly is noted involving 2 of the fingers. The radius is mildly hypoplastic. Note the hypoplastic palmar creases. This is usually the result of decreased movement of the hand in utero.



(Left) Clinical photograph of the hand of a woman with Holt-Oram syndrome illustrates characteristic findings of radial deviation of the wrist due to a severely hypoplastic radius. The thumb is absent, and only 4 digits are seen. Clinodactyly of the radial digit allows the finger some limited function as a thumb-like appendage. (Right) Clinical photograph of the same woman's affected newborn shows very subtle hand abnormalities, including bilateral triphalangeal thumbs.



TERMINOLOGY

Definitions

- Heart and hand syndrome characterized by upper extremity and cardiac malformations

IMAGING

General Features

- Best diagnostic clue
 - Radial ray defect in fetus with family history of Holt-Oram syndrome

Ultrasonographic Findings

- Radial ray defects may be seen in 1st trimester
 - 1st and most obvious finding in fetus with positive family history
- Variable degrees of radial deficiency, usually asymmetric
- Rarer lower extremity anomalies
- Cardiac anomalies
 - Atrial septal defect most common anomaly but often not diagnosed on prenatal imaging
 - Ventricular septal defect less common

Imaging Recommendations

- Protocol advice
 - 3D/4D ultrasound useful for delineating limb defects
 - Fetal echocardiography in fetus at high risk even without obvious limb defects

Radiographic Findings

- Upper extremity involvement including variable hypoplasia/aplasia of radial, thenar, and carpal bones

DIFFERENTIAL DIAGNOSIS

Radial Ray Defects, Syndromic or Isolated

- **Fanconi anemia**
 - Radial deficiency
 - Variable degree of thumb abnormality
- **Thrombocytopenia-absent radius (TAR)**
 - Thumb is always present
 - Radial deficiency
- **VACTERL association**
 - Vertebral anomalies, anal atresia, cardiac anomalies, tracheoesophageal fistula, esophageal atresia, renal agenesis, variable limb defects including radial ray defects
- **Isolated thumb hypoplasia/triphalangeal thumb**

Isolated Atrial Septal Defect

- Difficult to diagnose in utero

PATHOLOGY

General Features

- Etiology
 - Mutations in T-box transcription factor gene *TBX5* (12q24.21)
 - Mutations lead to functional haploinsufficiency with reduced transcription activation of target genes
 - Function of *TBX5* is critical for initiation of forelimb growth

- Genetics
 - Autosomal dominant
 - Offspring of affected individuals at 50% risk
 - Near complete penetrance
 - Variable expressivity
 - *TBX5* genotyping has high sensitivity and specificity for Holt-Oram syndrome only if strict diagnostic criteria are met
 - At least 70% of individuals with Holt-Oram syndrome and preaxial radial ray malformation of upper extremity have identifiable *TBX5* mutation

CLINICAL ISSUES

Presentation

- Most common signs/symptoms
 - Radial ray deficiencies of variable severity
 - Cardiac defect
- Other postnatal signs/symptoms
 - Atrial septal defects, ostium secundum
 - Conduction abnormalities, dysrhythmias

Demographics

- 1 in 100,000 live births
- ~85% of affected individuals are result of de novo mutations

Natural History & Prognosis






- Overall prognosis dependent upon severity of cardiac defect and degree of upper extremity malformation
- Normal life span possible
- No increased developmental impairment

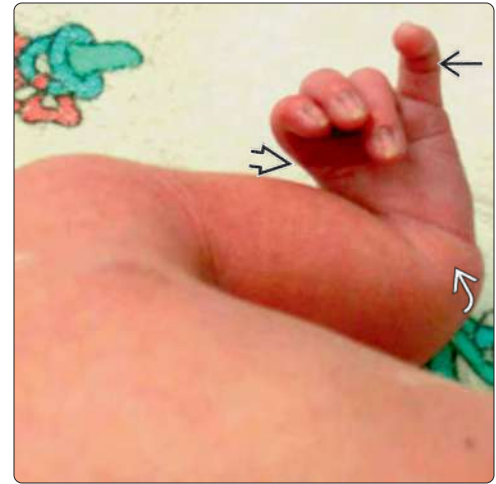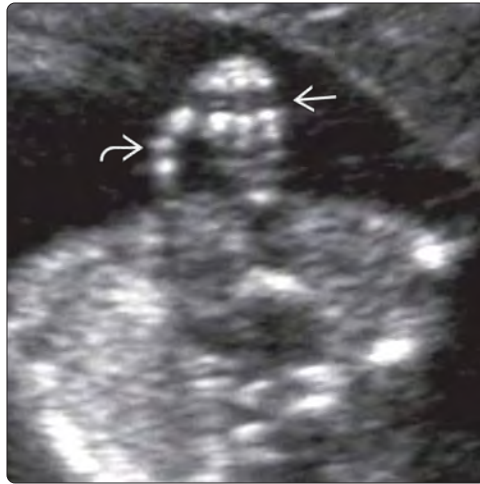
Treatment




- Prenatal
 - Genetic counseling
 - Prenatal diagnosis by amniocentesis or chorionic villus sampling is possible if *TBX5* mutation is known
 - Preimplantation genetic diagnosis (PGD) is possible if mutation is known
- Postnatal
 - Multidisciplinary team management
 - Repair of cardiac abnormalities
 - Orthopedic repair of hand anomalies with goal of optimizing function
 - Pollicization of index finger or toe to create neo-thumb
 - Surveillance
 - Annual ECG
 - Annual Holter monitor for those with conduction defects
 - Echocardiography every 1-5 yr

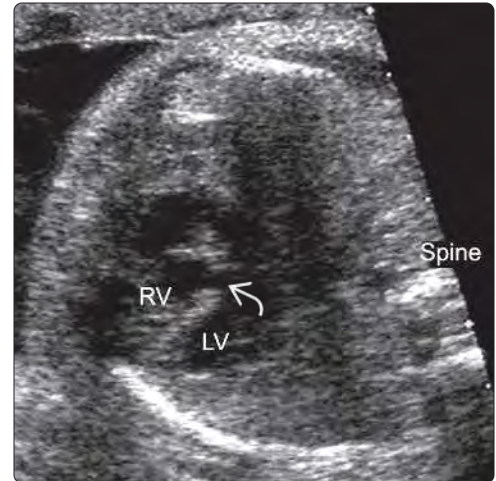
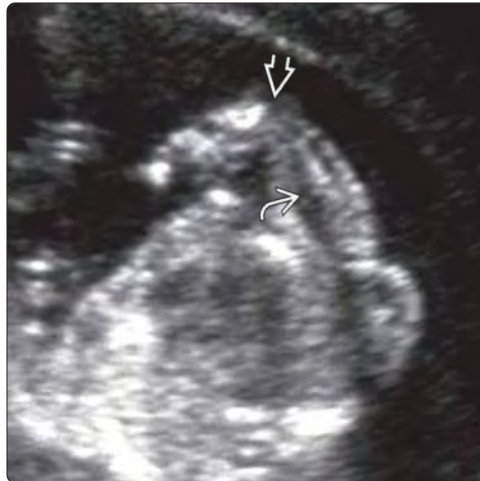SELECTED REFERENCES







1. Al-Qattan MM et al: Molecular basis of the clinical features of Holt-Oram syndrome resulting from missense and extended protein mutations of the *TBX5* gene as well as *TBX5* intragenic duplications. *Gene*. 560(2):129-36, 2015
2. Wall LB et al: Defining features of the upper extremity in Holt-Oram syndrome. *J Hand Surg Am*. 40(9):1764-8, 2015
3. Barisic I et al: Holt Oram syndrome: a registry-based study in Europe. *Orphanet J Rare Dis*. 9:156, 2014

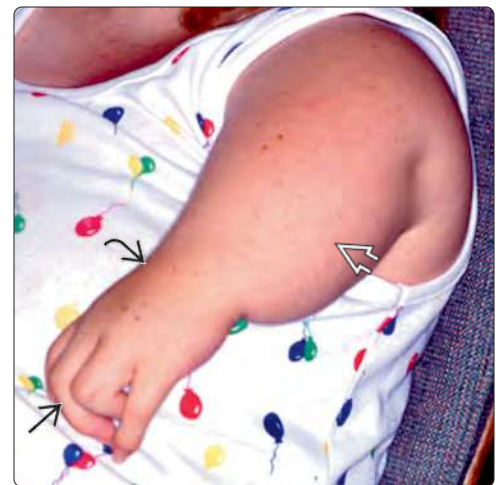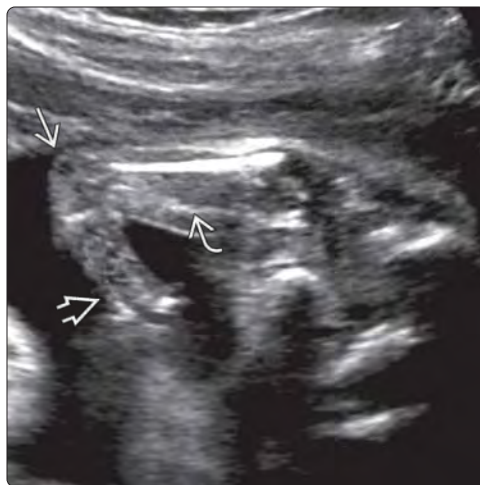
(Left) Ultrasound of a fetus with Holt-Oram syndrome at 19 weeks shows a hand with 4 digits and an absent thumb . Note the clinodactyly  of the 5th finger. **(Right)** Clinical photograph shows the same infant's hand at birth. The radially deviated wrist is caused by an absent radius . In addition, the ulna and humerus are both hypoplastic. The thumb is absent , and 4 digits are seen. Clinodactyly of the 5th digit is also noted , which correlates with the ultrasound findings.



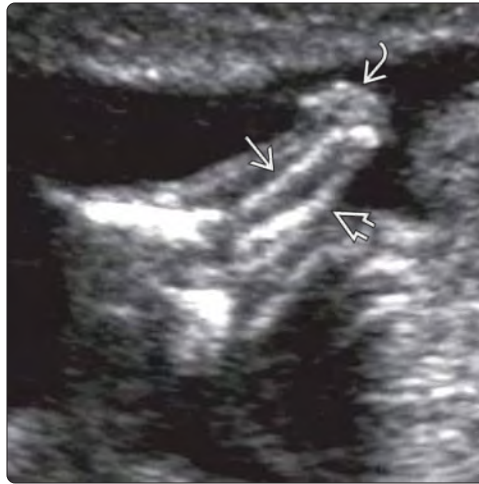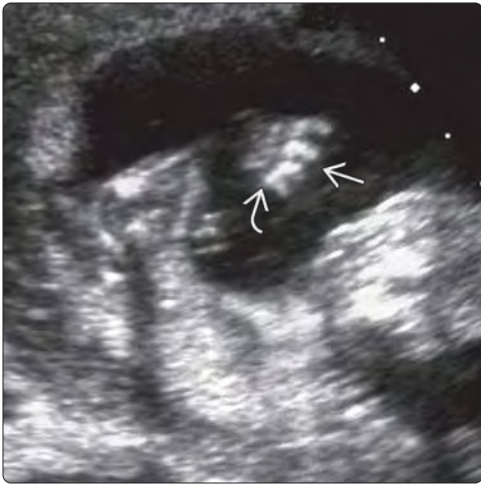
(Left) US shows a radial ray defect in a midtrimester fetus with Holt-Oram syndrome. Hypoplasia of the radius  with radial deviation of the wrist  is noted. Initially the thumb was thought to be absent by prenatal imaging; however, at birth it was found to be present but severely hypoplastic. **(Right)** 4-chamber view in the 3rd trimester shows a small ventricular septal defect . The most common cardiac defect in Holt-Oram syndrome is an atrial septal defect, which is often difficult to detect prenatally.



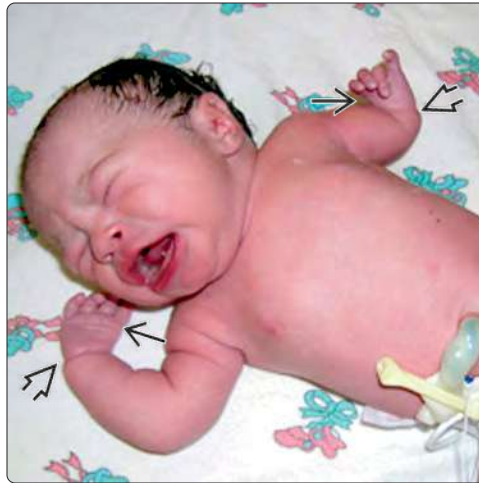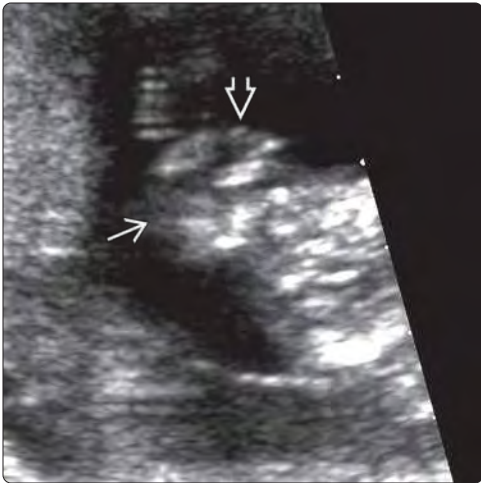
(Left) Ultrasound at 26 weeks of the upper extremity of a fetus with Holt-Oram syndrome shows a severely hypoplastic radius  with radial deviation of the wrist  and oligodactyly . The thumb is absent. **(Right)** Clinical photograph of the arm of a woman severely affected by Holt-Oram syndrome is shown. Note the 4 digits with camptodactyly  and the significantly shortened arm due to radial aplasia  and a hypoplastic humerus .



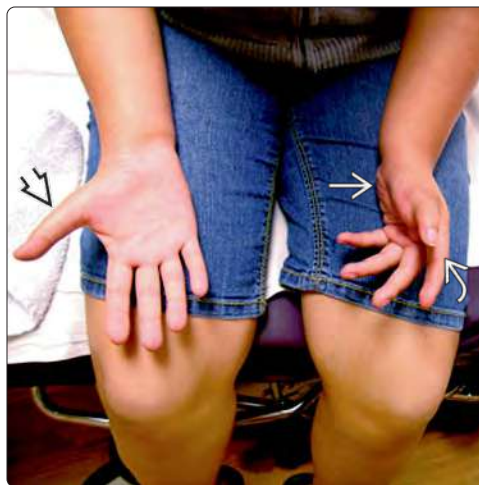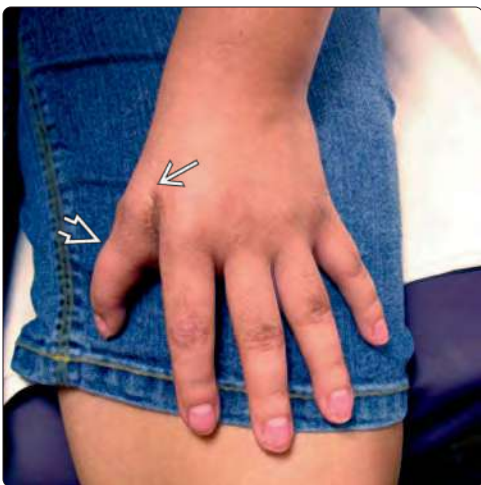Holt-Oram Syndrome



(Left) Late 1st-trimester ultrasound shows 4 digits and a presumed absent thumb on the hand of a fetus with upper extremity radial ray deficiency due to Holt-Oram syndrome. **(Right)** Ultrasound of a midtrimester fetus with Holt-Oram syndrome shows a mildly hypoplastic radius, radial deviation of the wrist, and a significantly hypoplastic hand. The ulna is mildly curved.



(Left) Ultrasound of the fetus of a woman with Holt-Oram syndrome reveals evidence of a radial ray defect and clubbed hand at 12 weeks. This finding, given the maternal diagnosis, raises suspicion for an affected fetus. **(Right)** Clinical photograph of the same infant at term confirms the clinical impression of Holt-Oram syndrome. Note the bilateral radial ray defects with the left more severe than the right. Both thumbs are absent. Both the fetal and neonatal echocardiograms were normal.



(Left) Clinical photograph of the left hand of the mother of the prior infant is shown. Note the proximally implanted, hypoplastic thumb and the scar from tendon surgery. **(Right)** Clinical photograph shows both hands of the same mother. Note the long, triphalangeal thumb on the right hand. The patient regards this as her normal hand. The left hand, by comparison, is smaller and the arm exhibits limited supination. She had a ventricular septal defect repaired in childhood.

KEY FACTS

TERMINOLOGY

- Idiopathic infantile arterial calcification (IIAC) is part of clinical spectrum of ectopic calcification with multiorgan pathology
 - Features overlap with pseudoxanthoma elasticum

IMAGING

- Calcification of major vessels
 - Image along long axis of vessel
- Pericardial effusion common
- Progression to hydrops due to myocardial ischemia
- Polyhydramnios

TOP DIFFERENTIAL DIAGNOSES

- Echogenic cardiac focus
 - Rounded focus, not linear
 - Intraventricular, not in outflow tracts
- Other more common causes of hydrops
 - Nonimmune and immune

PATHOLOGY

- IIAC is autosomal recessive
 - Mutations in *ENPP1* gene known to cause generalized arterial calcification
- Hydroxyapatite deposition in elastic fibers of large, medium-sized arteries
- Postmortem CT may be used to confirm diagnosis in lieu of autopsy

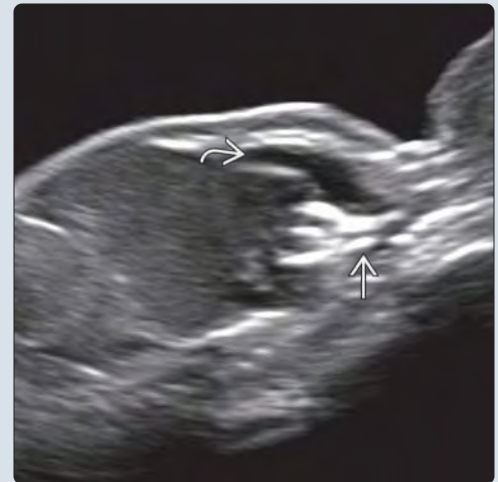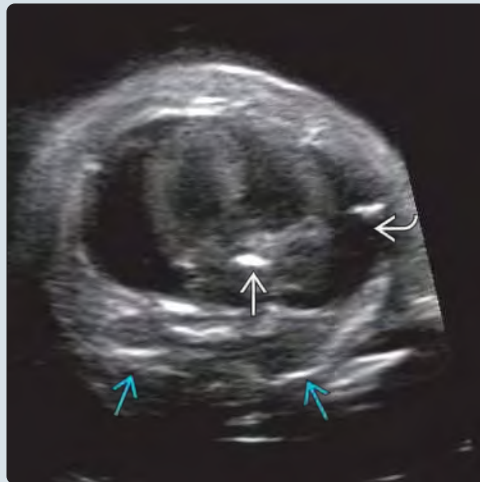
CLINICAL ISSUES

- Untreated, 85% die within 1st 6 months from cardiac ischemia → congestive heart failure

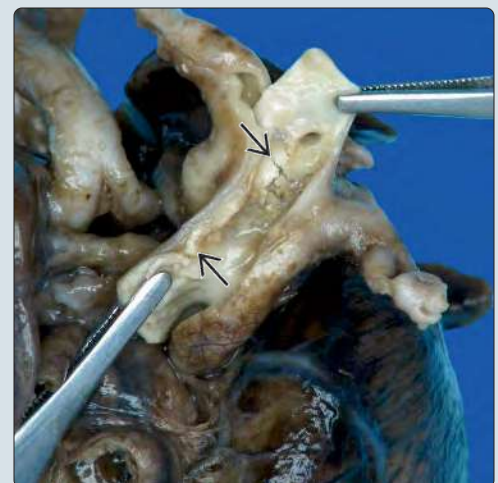
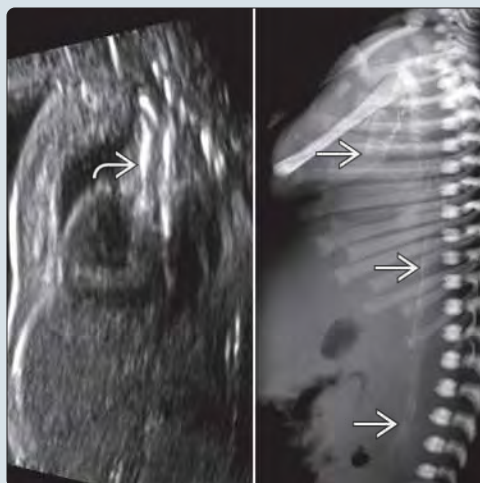
DIAGNOSTIC CHECKLIST

- Hallmark finding is markedly increased echogenicity of great arteries
- Very unusual before 3rd trimester; look for other causes of hydrops in 2nd trimester

(Left) Four-chamber view in a 27-week fetus shows an echogenic focus [red arrow] at the crux of the heart with polyhydramnios and a large pericardial effusion [red arrow] displacing the lungs [red arrow] posteriorly. **(Right)** An orthogonal plane to the 4-chamber view shows that the echogenic area seen was a cross section of the aorta [red arrow]. The pericardial effusion [red arrow] is also visible. Always evaluate abnormal findings in multiple planes.



(Left) Sagittal fetal US (L) and postmortem radiograph (R) show the correlation of the linear, bright sonographic echoes [red arrow] with the densely calcified aorta. Calcification along the length of the aorta [red arrow] is seen. **(Right)** Autopsy photo of the fixed, opened aorta shows dense calcification of the aortic root [red arrow]. The calcification can occlude the coronary arteries and cause ischemic heart disease, which is refractory to therapy. This accounts for the high mortality rate.



TERMINOLOGY

Abbreviations

- Idiopathic infantile arterial calcification (IIAC)
 - Part of clinical spectrum of ectopic calcification with multiorgan pathology
 - Considerable overlap in genotype/phenotype of IIAC and pseudoxanthoma elasticum (PXE)

Synonyms

- Generalized arterial calcification of infancy

IMAGING

General Features

- Best diagnostic clue
 - Calcification of major vessels

Ultrasonographic Findings

- Pericardial effusion common
 - Progresses to hydrops due to myocardial ischemia
- Very echogenic great vessel walls
 - Image along long axis of vessel
- Polyhydramnios
- Fetal growth restriction has been described

DIFFERENTIAL DIAGNOSIS

Echogenic Cardiac Focus

- Intraventricular, not in outflow tracts
- Rounded focus, not linear

Other Causes of Hydrops

- Immune
 - Check antibody screen
 - Measure middle cerebral artery peak systolic velocity for possible anemia
- Nonimmune
 - Cardiac arrhythmia, structural defect, cardiomyopathy
 - High-output states, infection, aneuploidy/syndromes

Infantile Myocardial Ischemia

- Abnormal coronary artery origin
- Myocarditis
- Perinatal asphyxia

PATHOLOGY

General Features

- Genetics
 - Genes *ENPP1*, *CD73*, and *ABCC6* must be in working order for normal suppression of arterial calcification
 - IIAC is autosomal recessive
 - Mutations in *ENPP1* gene are known to cause generalized arterial calcification of infancy
 - Homozygous missense mutation p.R1314W in *ABCC6* found in 2 siblings from nonconsanguineous family negative for *ENPP1* mutation
 - Overlap with PXE (classic form caused by *ABCC6* mutations)
 - Homozygous missense mutation p.Y513C in *ENPP1* in child with both PXE and IIAC

Gross Pathologic & Surgical Features

- Hydroxyapatite deposition in elastic fibers of large, medium-sized arteries
- Postmortem CT may be used to confirm diagnosis in lieu of autopsy
 - Shows extent of calcification better than plain radiographs

CLINICAL ISSUES

Presentation

- Most common signs/symptoms
 - Fetal
 - Abnormal echogenicity of great vessels
 - May present with hydrops fetalis
 - Neonatal
 - Unexplained cardiac failure
 - Vascular calcification on plain radiographs

Natural History & Prognosis

- Very poor prognosis
 - Untreated, 85% die within 1st 6 months from cardiac ischemia → congestive heart failure
 - 71% of cases with *ENPP1* mutations die in infancy (median: 30 days)
 - 50% of those without *ENPP1* mutations die in infancy (median: 9 days)

Treatment

- No formalized treatment approach exists
 - Ischemic cardiac failure does not respond to conventional therapy
 - Case report of peritoneal dialysis as treatment for refractory hypertension in case that presented with hydrops fetalis
 - Case reports of balloon valvuloplasty, valve replacement
 - Etidronate blocks mineralization
 - Reports of resolution of calcification without recurrence on cessation of drug administration
 - Potential serious skeletal complications; surveillance for toxicity crucial
 - Urinary phosphate wasting → rickets
 - Dental enamel hypoplasia is rare side effect

DIAGNOSTIC CHECKLIST

Image Interpretation Pearls

- Hallmark finding is markedly increased echogenicity of great arteries
- Very unusual before 3rd trimester; look for other causes of hydrops in 2nd trimester

SELECTED REFERENCES

1. Li Q et al: Mutations in the *ABCC6* gene as a cause of generalized arterial calcification of infancy: genotypic overlap with pseudoxanthoma elasticum. *J Invest Dermatol.* 134(3):658-65, 2014
2. Karthikeyan G: Generalized arterial calcification of infancy. *J Pediatr.* 162(5):1074.e1, 2013
3. Cansu A et al: Idiopathic infantile arterial calcification: prenatal diagnosis and postnatal presentation. *Clin Exp Obstet Gynecol.* 37(1):73-5, 2010
4. Heuser CC et al: Radiographic and pathologic evaluation of idiopathic infantile arterial calcification. *Obstet Gynecol.* 115(2 Pt 2):465-8, 2010

KEY FACTS

TERMINOLOGY

- Joubert syndrome and related disorders
 - Autosomal recessive genetic disorders with impaired ciliary function
 - 6 subtypes, all have molar tooth sign
- Requirements for diagnosis of classic Joubert syndrome
 - Hindbrain malformation presenting as molar tooth sign on MR
 - Intellectual impairment
 - Hypotonia
- One of ciliopathies
 - Group of hereditary defects of primary (nonmotile) cilia causing wide range of overlapping syndromes involving liver, kidneys, multiple organ systems

IMAGING

- Look for molar tooth sign
- Measurements of following parameters significantly altered in affected compared to normal fetuses

- Pontomesencephalic junction
- Ratio of AP diameter interpeduncular fossa to midbrain/isthmus
- Ratio of AP to transverse diameter of 4th ventricle

TOP DIFFERENTIAL DIAGNOSES





- Other posterior fossa malformations
 - Dandy-Walker malformation
 - Chiari malformation
 - Mega cisterna magna

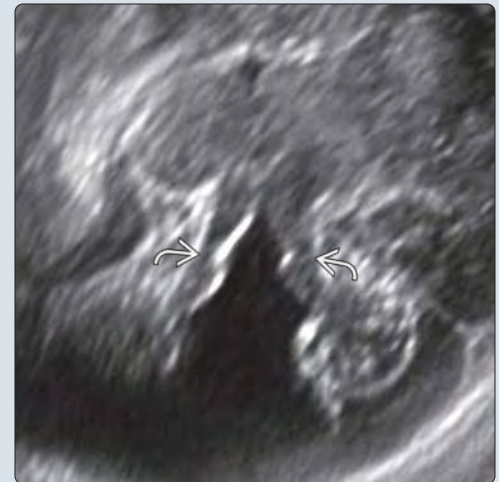
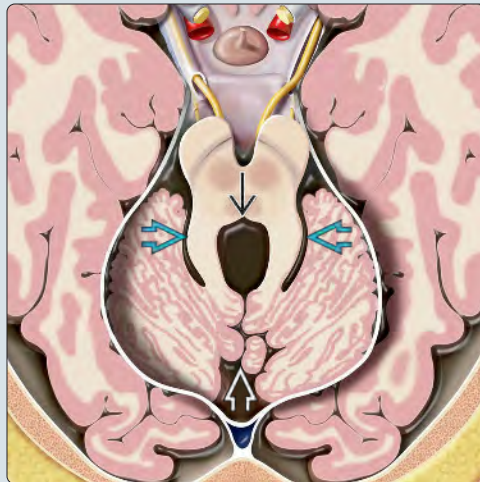
CLINICAL ISSUES





- Outcome independent of severity of imaging findings
- Clinical course variable, but most children survive infancy to reach adulthood
- Recurrence risk: 25%

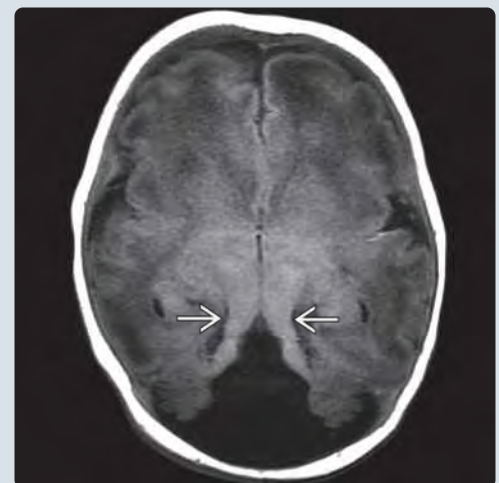
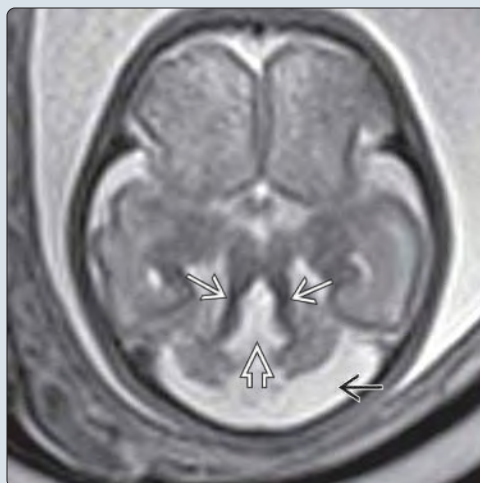
DIAGNOSTIC CHECKLIST

- Infants need complete neurological/ophthalmologic assessment

(Left) Graphic illustrates the typical abnormalities seen in Joubert syndrome. The thick superior cerebellar peduncles  are the roots of the tooth, the vermis  is small and dysplastic, and the 4th ventricle  has an abnormal, elongated configuration with increased AP diameter. **(Right)** Axial oblique abdominal US in the 3rd trimester shows the molar tooth appearance with elongated superior cerebellar peduncles  forming the roots of the molar tooth.



(Left) Fetal MR in the same case again demonstrates the molar tooth sign  as well as the abnormal shape of the 4th ventricle  and the increased retrocerebellar space in the posterior fossa . **(Right)** Postnatal MR confirms the prenatal imaging findings of the molar tooth sign . This case illustrates the importance of correlation of fetal and postnatal imaging.



TERMINOLOGY

Definitions

- Joubert syndrome and related disorders (JSRD)
 - Autosomal recessive genetic disorders with impaired ciliary function
 - 6 subtypes, all have molar tooth sign
 - Some dispute in literature regarding nomenclature as very heterogeneous phenotype
- Requirements for diagnosis of classic Joubert syndrome
 - Hindbrain malformation presenting as molar tooth sign on MR
 - Intellectual impairment
 - Hypotonia
- One of ciliopathies
 - Group of hereditary defects of primary (nonmotile) cilia causing a wide range of overlapping syndromes involving liver, kidneys, multiple organ systems
 - Primary cilium has many key roles in embryonic development, inherited diseases

IMAGING

Ultrasonographic Findings

- Abnormal nuchal translucency: Nonspecific but concerning in at-risk family
- Abnormal posterior fossa: Cerebellar cleft, vermian dysgenesis/rotation
- Abnormal 4th ventricle
 - Axial plane: Batwing shape at upper level of pons, AP diameter > transverse
 - Sagittal: Elongated, rounded roof with loss of sharp fastigial point
- May see additional small occipital cephalocele, abnormal corpus callosum
- Look at fetal breathing pattern: Episodic fetal hyperpnea (140-160 breaths/min) reported

MR Findings

- Molar tooth sign (described on axial MR but also visible on US)
 - Deepening of interpeduncular fossa
 - Dysgenesis of brainstem isthmus → elongation of pontomesencephalic junction
 - Thick, straight, long superior cerebellar peduncles
 - Hypoplastic vermis, may be rotated
- Anterior convexity to floor of 4th ventricle due to lack of decussation of cerebellar peduncles in tegmentum
 - Seen only on axial imaging at level of upper pons
- Midline cerebellar cleft
- Increased retrocerebellar space
- Measurements of following parameters significantly altered in affected compared to normal fetuses
 - Pontomesencephalic junction
 - Ratio of AP diameter interpeduncular fossa to midbrain/isthmus
 - Ratio of AP to transverse diameter of 4th ventricle
- Supratentorial findings include absent cavum, abnormal corpus callosum, cortical dysplasia

DIFFERENTIAL DIAGNOSIS

Other Posterior Fossa Malformations

- **Dandy-Walker malformation**
 - 4th ventricle communicates with cisterna magna
 - Molar tooth sign not a feature
 - Midbrain is normal vs. thinned in Joubert
- **Chiari malformation**
 - Obliteration of cisterna magna
 - Herniation of cerebellar tonsils with banana appearance to cerebellum
 - Usually associated with open neural tube defect
- **Mega cisterna magna**
 - Cisterna magna > 10 mm in depth
 - No associated structural malformation

PATHOLOGY

General Features

- Genetics
 - Variable phenotype possibly explained by oligogenic model of inheritance
 - Concurrent effect of ≥ 2 distinct genes on resulting phenotype
 - Autosomal recessive (21 gene mutations identified by 2014), including
 - *INPP5E, AHI1, NPHP1, CEP290, TMEM67/MKS3, RPGRIP1L, ARL13B, CC2D2A, INPP5E, KIF7, OFD1, TCTN1, TCTN2, TMEM2167*
 - French Canadians in Quebec carry multiple founder mutations (*C5orf42, CC2D2A, and TMEM231*)
 - Ashkenazi Jews have 1% carrier rate of founder mutation p.R73L in *TMEM216* gene
 - Hutterite population has 5.8% carrier rate for founder mutation p.R18X in *TMEM237* gene
 - X-linked forms described
- Associated abnormalities
 - Defects in structure ± function of primary cilium responsible for many features
 - Liver fibrosis, cystic renal disease
 - Meningoencephalocele
 - Ocular findings (coloboma, chorioretinal dysplasia)
 - Polydactyly
 - Cleft palate, tongue tumors
 - Facial dysmorphism
 - Cardiac malformations (rare)

Gross Pathologic & Surgical Features

- Abnormal deep cerebral nuclei and midbrain
- Abnormal fibers in cerebellar peduncles
- Diminished volume of oculomotor nucleus
- Vermian hypoplasia/aplasia

CLINICAL ISSUES

Presentation

- Fetal
 - Most initially present as abnormal posterior fossa on routine imaging ± polydactyly
 - Molar tooth hindbrain malformation
 - Occipital cephalocele

Simple Clinical Classification of JSRD Subgroups

Name	Criteria
Pure Joubert syndrome	Primary criteria only
Joubert + retinopathy	Primary criteria + retinal involvement
Joubert + renal	Primary criteria + renal involvement
Cerebrooculorenal syndrome (CORS) a.k.a. (Joubert Senior-Loken Syndrome)	Primary criteria + retinopathy + renal involvement
Coloboma, oligophrenia, ataxia, cerebellar vermis hypoplasia, hepatic fibrosis (COACH syndrome)	Primary criteria + intellectual impairment + liver + chorioretinal or optic nerve colobomas ± nephronophthisis
Orofaciodigital syndrome IV	Primary criteria + orofacial + polydactyly
Primary Criteria	
Typical neurological signs	Hypotonia evolving into ataxia
	Developmental delay
Typical neuroimaging	Molar tooth sign
<i>The term oligophrenia in the COACH acronym means developmental delay.</i>	

Valente EM et al: Genotypes and phenotypes of Joubert syndrome and related disorders. *Eur J Med Genet.* 51(1):1-23, 2008.

- Postnatal
 - Broad spectrum of other phenotypic findings
 - Irregular breathing pattern/abnormal eye movements are supportive but not required for diagnosis
 - Typical facies: High rounded eyebrows, upturned nostrils, triangular-shaped mouth, low-set ears

Demographics

- JSRD estimated 1:80-100,000 in United States
- True incidence unknown: Many cases likely misdiagnosed

Natural History & Prognosis

- Outcome independent of severity of imaging findings
- Most children survive infancy to reach adulthood
- Affected children have spectrum of abnormalities
 - Developmental delay/intellectual impairment
 - Average age of independent sitting is 19 months
 - Average age of walking is 4 years for those who could learn
 - Ataxia secondary to hindbrain malformation
 - Oculomotor apraxia, oral-motor and speech dyspraxia
 - Speech more impaired than comprehension
 - Hypotonia
 - Variable respiratory difficulties
 - Hyperpnea/apnea (sudden infant death attributed to apneic attacks)
 - Seizure disorder more likely if additional structural brain malformations
 - Compromises long-term survival when difficult to control
- Behavioral problems (impulsivity, perseveration, temper tantrums) seen in older children
- Recurrence risk 25% with widely variable presentation in siblings

Treatment

- Offer chorionic villus sampling or amniocentesis especially in high-risk populations
 - Offer termination of affected pregnancy
- Liveborn infant

- Once JSRD confirmed, infant requires careful, systematic evaluation for known complications
- Mutations in distinct genes → very high incidence of specific complications
 - Nephronophthisis occurs with *NPHP1*, *RPGRI1L*, *CEP290* mutations
 - Need nephrology follow-up for signs of renal dysfunction, management plan
 - *TMEM67* mutations are nearly invariably associated with congenital liver fibrosis
- Future pregnancies
 - Early ultrasound, 20- to 22-week MR
 - Prenatal diagnosis by DNA testing is feasible if disease-causing mutation is known
 - 50% of tested cases do not have known mutation

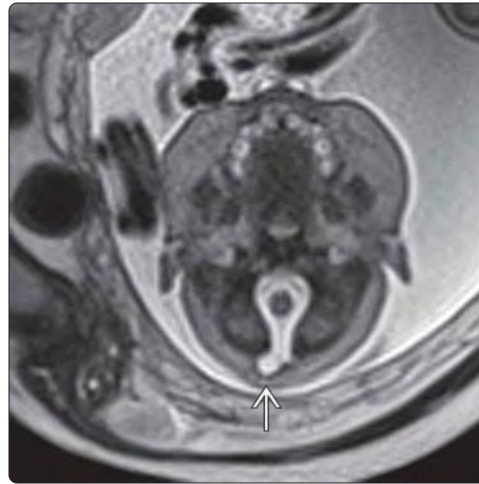
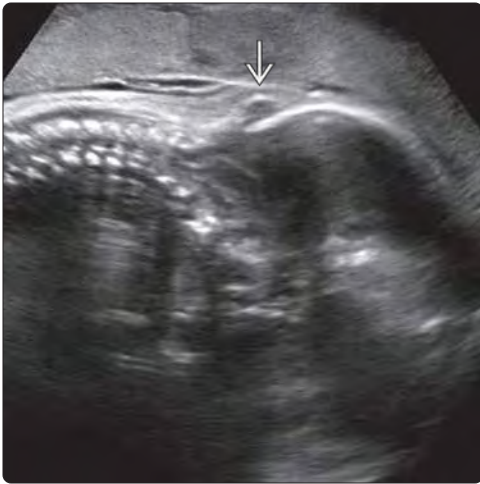DIAGNOSTIC CHECKLIST

Consider

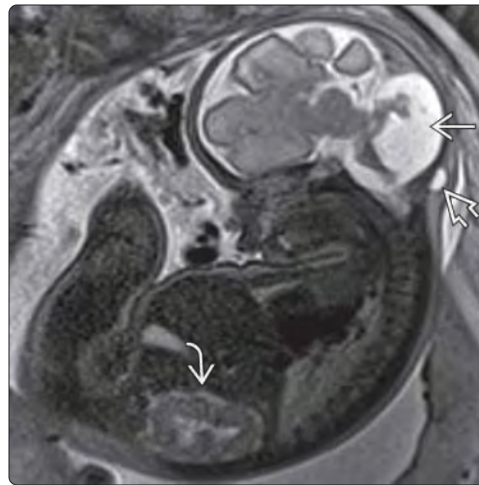
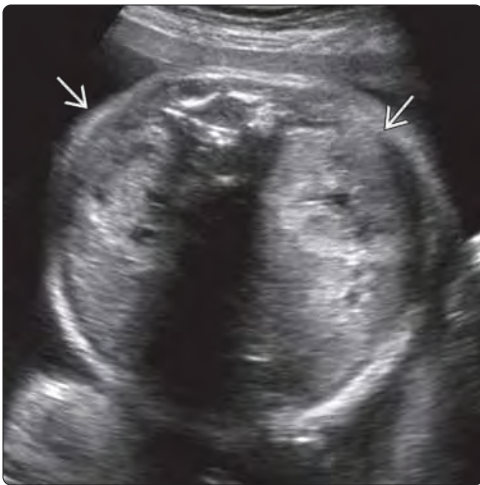- Fetal MR to characterize central nervous system anomalies, particularly of posterior fossa
 - Major pitfall is Dandy-Walker malformation
 - Accurate diagnosis is important as prognosis/recurrence risks are different
- Infants need complete evaluation and careful follow-up for complications

SELECTED REFERENCES

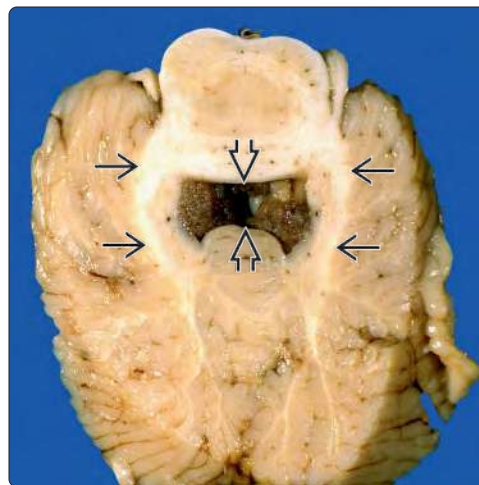
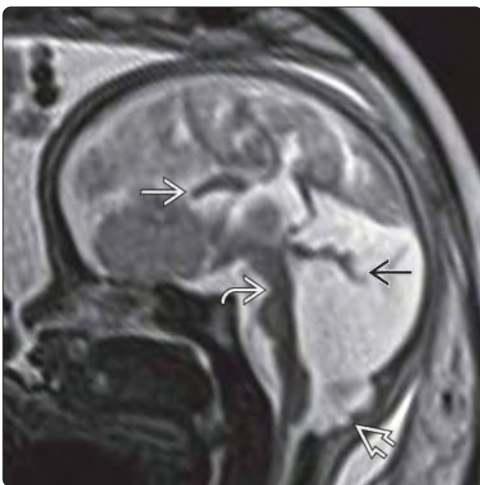
1. Quarello E et al: Prenatal abnormal features of the fourth ventricle in Joubert syndrome and related disorders. *Ultrasound Obstet Gynecol.* 43(2):227-32, 2014
2. Valente EM et al: Clinical utility gene card for: Joubert syndrome—update 2013. *Eur J Hum Genet.* 21(10), 2013
3. İncecik F et al: Joubert syndrome: report of 11 cases. *Turk J Pediatr.* 54(6):605-11, 2012
4. Poretti A et al: Joubert syndrome and related disorders: spectrum of neuroimaging findings in 75 patients. *AJNR Am J Neuroradiol.* 32(8):1459-63, 2011
5. Poretti A et al: Tecto-cerebellar dysraphism with occipital encephalocele: not a distinct disorder, but part of the Joubert syndrome spectrum? *Neuropediatrics.* 42(4):170-4, 2011



(Left) Sagittal US of the cervical spine shows an unexpected finding of a small occipital cephalocele. This was not appreciated prospectively but was visible on review after seeing the fetal MR in the same case. (Right) Axial T2WI image through the skull base in the same case beautifully demonstrates the small occipital cephalocele. This is a common finding in Joubert syndrome and related disorders (JSRD) but is easily overlooked on US, especially in cases seen for the 1st time in the 3rd trimester.



(Left) Abdominal US in the same fetus shows bilateral enlarged, echogenic kidneys. This suggests that the infant will have Joubert syndrome with renal involvement. (Right) Sagittal MR shows an abnormal posterior fossa, occipital cephalocele, and large kidney. Fetal MR studies are targeted to specific body parts (the brain in this case), but there is often additional information to be gained from reviewing the scout images.



(Left) Sagittal T2WI MR shows dysgenesis of the corpus callosum, thin brainstem isthmus, abnormal rotated vermis, and occipital cephalocele, all features that have been described in JSRD. (Right) Autopsy specimen of JSRD shows the pathological correlate for the molar tooth sign. Note the thick, straight superior cerebellar peduncles (the roots of the tooth) and the abnormal "bat wing" contour of the 4th ventricle.

KEY FACTS

TERMINOLOGY

- Definition: Capillary-lymphatic-venous malformation with overgrowth most often involving 1 lower extremity

IMAGING

- Ultrasound findings
 - Fetal cases tend to be large
 - Subcutaneous cystic lesions primarily of 1 leg
 - Surrounds femur, tibia, fibula
 - Amount of cystic vs. soft tissue echogenicity is variable
 - Variable vascularity with color Doppler
 - High-flow lesions with increased risk for heart failure
 - Hydrops from heart failure or lymphatic obstruction
 - Anemia from coagulopathy
 - Measure peak systolic velocity in middle cerebral artery and compare with gestational age nomograms
- MR is best modality to show extension of mass
 - Along subcutaneous tissue of back and flank
 - Deep extension into pelvis and abdomen

TOP DIFFERENTIAL DIAGNOSES

- Lymphangioma without Klippel-Trenaunay-Weber
- Sacrococcygeal teratoma
- Beckwith-Wiedemann syndrome

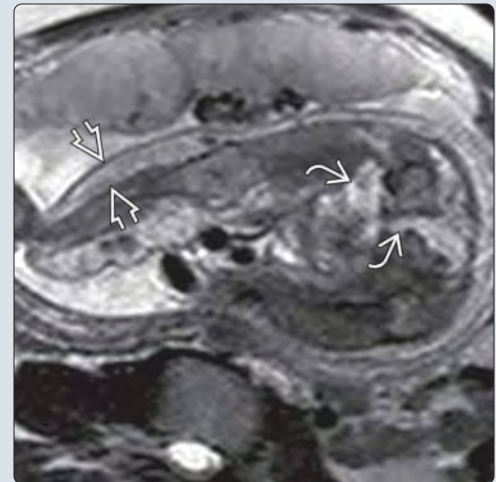
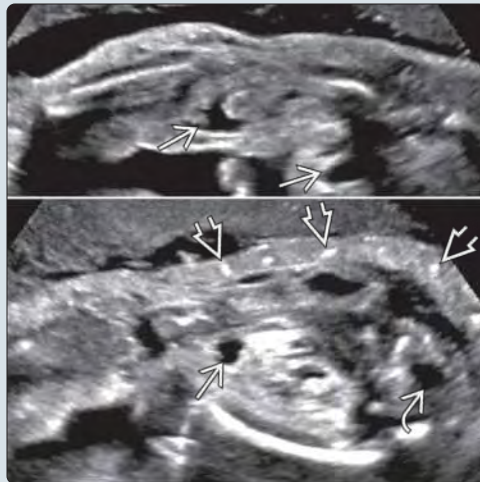CLINICAL ISSUES

- Sporadic incidence though genetic etiology suggested
- Not associated with aneuploidy
- Cesarean section delivery recommended
- Prognosis: Large masses with ↑ morbidity
- Treatment: Multiple procedures necessary
 - Debulking procedures (including amputation)
 - Embolization, laser treatment
 - Steroid therapy with prednisolone

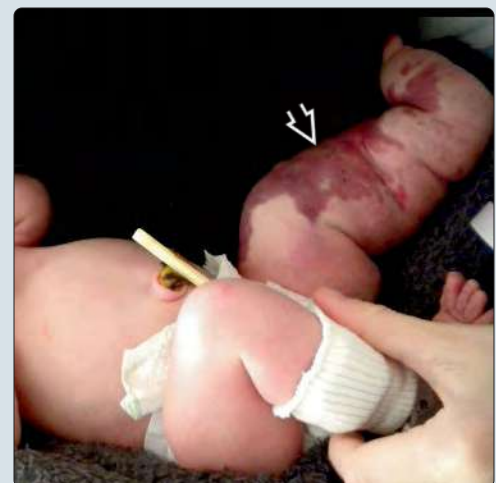
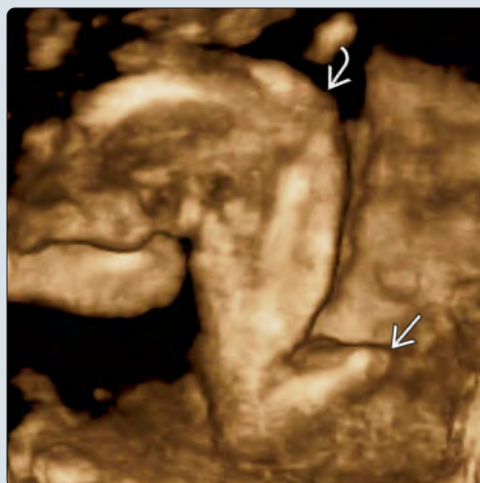
DIAGNOSTIC CHECKLIST

- Offer genetic counseling
- Offer surgical consultation before delivery to prepare family for treatment plans

(Left) Long-axis view of the shin (upper) and thigh (lower) of a fetus with Klippel-Trenaunay-Weber syndrome (KTW) shows an enlarged left leg with cystic lesions extending into the pelvis, as well as skin thickening with phleboliths from the hemangioma. **(Right)** Fetal MR at 31 weeks in the same fetus confirms the skin thickening and cystic infiltration of the lymphatic malformation into the pelvis. This fetus was monitored carefully and did not develop hydrops during the pregnancy.



(Left) The 3D surface-rendered view in the same patient shows the hallmark hypertrophy seen with KTW, secondary to infiltrating lymphangioma and hemangioma, as well as secondary overgrowth. Note the left knee and left foot. **(Right)** Clinical photograph of the same child after delivery shows the enlarged left leg with the hemangioma skin stigmata. Despite multiple interventions, this child developed sepsis and his left leg was amputated in order to save his life.



TERMINOLOGY

Abbreviations

- Klippel-Trenaunay-Weber (KTW)

Synonyms

- Angioosteohypertrophy syndrome
- Hemangiectatic hypertrophy

Definitions

- Capillary-lymphatic-venous malformation with overgrowth
- Mostly involves 1 lower extremity
 - Large cutaneous hemangiomas
 - Bony and soft tissue hypertrophy

IMAGING

General Features

- Best diagnostic clue
 - Asymmetric lower limb hypertrophy
 - Subcutaneous cystic lesions
- Location
 - Most often involving 1 whole leg
 - Thigh lesions can extend toward buttock
 - Mimic sacrococcygeal teratoma
 - Can extend/invade beyond leg
 - Pelvis and abdomen extension
 - Retroperitoneal
 - Intraperitoneal
- Size
 - Variable
 - Fetal cases tend to be large
- Morphology
 - Infiltrating cystic mass

Ultrasonographic Findings

- Subcutaneous cystic mass involving leg
 - Multiloculated cystic lesion
 - Surrounds femur, tibia, fibula
 - Amount of cystic vs. soft tissue echogenicity is variable
 - Depends on amount of soft tissue hypertrophy vs. amount of lymphatic malformation vs. amount vascular malformation
 - Variable vascularity with color Doppler
 - Low flow more common than high flow
 - High-flow lesions more likely to cause heart failure
 - Might see persistent embryonic lateral marginal vein
 - Large vein from lateral border of leg to lateral foot
 - Might see phleboliths
 - Calcifications in veins
 - Echogenic foci in subcutaneous tissue
- Extension from lower extremity common
 - Superficial extension
 - Along subcutaneous tissue of back and flank
 - Deep extension
 - Into pelvis and abdomen
- Complications include heart failure, anemia, and hydrops
 - Cardiomegaly
 - Hepatomegaly
 - Hydrops from heart failure or lymphatic obstruction
 - Fetal fluid accumulation

- Anasarca
- Ascites
- Pleural effusion
- Pericardial effusion
- Amniotic fluid abnormalities
 - Polyhydramnios
 - Oligohydramnios if renal compromise
- Thick placenta
- Anemia from coagulopathy
 - ↑ peak systolic velocity in middle cerebral artery

MR Findings

- Best modality to show deep extension
 - Define anatomic location
 - Bowel involvement
 - Compromise of other organs

Imaging Recommendations

- Best imaging tool
 - Routine evaluation of lower extremities at time of anatomy scan
 - Femur length view
 - Lower extremity/foot orientation view
 - Palmar Foot view
- Protocol advice
 - Monitor closely for development of hydrops
 - Monitor for fetal anemia
 - Measure peak systolic velocity in middle cerebral artery and compare with gestational age nomograms
 - Obtain MR to show extension of mass

DIFFERENTIAL DIAGNOSIS

Lymphangioma Without Klippel-Trenaunay-Weber

- Subcutaneous complex cystic mass
 - Similar to KTW but less likely to involve just 1 lower extremity
 - 70% in axilla but can occur anywhere
- No varicosities or skin stigmata
- Infiltration is common (similar to KTW)
 - Extension into mediastinum more common
 - Can extend into abdomen and retroperitoneum

Sacroccygeal Teratoma

- Sacral neoplasm derived from 3 germ cell layers
- Mixed cystic/solid mass extending from sacrum
 - Purely cystic in 15%
 - More likely to mimic KTW
 - Solid lesions often highly vascular
 - May cause hydrops
- Variable size
- Extension into pelvis common
 - Best seen with MR

Beckwith-Wiedemann Syndrome

- Multigenic disorder of alteration in growth regulatory gene
 - 5-10% with mutation in *CDKN1C*
- Hemihyperplasia can mimic KTW
 - May affect whole limb or part of limb
 - Usually not cystic overgrowth
- Other features

- Macroglossia
- Macrosomia, organomegaly
- Omphalocele
- Embryonal tumors

Proteus Syndrome (Rare)

- More often diagnosed in 1st year of life (not fetal life)
- Subcutaneous masses and overgrowth
 - Not just lymphohemangioma
 - Lipoma, hamartoma, epidermal nevus
- Other features
 - Hemihypertrophy
 - Macroductyly
 - Exostoses

PATHOLOGY

General Features

- Etiology
 - Mesodermal anomaly
 - Abnormal regulation or production of angiogenesis growth factors
 - Hydrops etiology with KTW
 - High-output cardiac failure in high-flow lesions
 - Lymphatic obstruction and fluid overload
 - Coagulopathy causes
 - Hemangioma associated diffuse intravascular coagulation
 - Intravascular hemolysis
- Genetics
 - Suggested genetic etiologies
 - Mutations or translocation involving *VG5Q* gene
 - *KTW* gene on chromosome arm 5q or 11p
 - Sporadic incidence and not associated with aneuploidy
 - Familial aggregates reported

Staging, Grading, & Classification

- Klippel and Trenaunay originally described triad in 1900
 - Port wine stain
 - Varicose veins
 - Soft tissue hypertrophy
- Weber added arteriovenous fistula in 1907

CLINICAL ISSUES

Presentation

- Most common signs/symptoms
 - Abnormal ultrasound at time of anatomy scan
 - Early diagnosis at 15 weeks reported
- Other signs/symptoms
 - Most often maternal screening results are normal
 - Cases reported with ↑ maternal serum human chorionic gonadotropin and α-fetoprotein

Demographics

- Gender
 - M = F
- Epidemiology
 - Sporadic and rare (1:100,000 reported)

Natural History & Prognosis

- Large masses with ↑ morbidity

- Can lead to Kasabach-Merritt syndrome
 - Hemangioma associated thrombocytopenia and consumption coagulopathy
 - 36% KTW with this complication in one series
 - 45% mortality rate in neonatal period reported
- Sepsis from skin ulcerations (can be fatal)

Treatment

- Cesarean section delivery often recommended
 - Risk for hemorrhage
- Small lesions can be observed (fetal cases are rarely small)
- Surgical treatment
 - Debulking procedures
 - Including amputation
 - High recurrence rates
- Less invasive treatment
 - Steroid therapy with prednisolone
 - Enhances thrombosis and inhibits subsequent fibrinolysis
 - Pulsed-dye laser treatment
 - Alpha interferon
 - Embolization
 - Antithrombin III

DIAGNOSTIC CHECKLIST

Consider

- Diagnosis when lymphangioma involves only 1 extremity

Image Interpretation Pearls

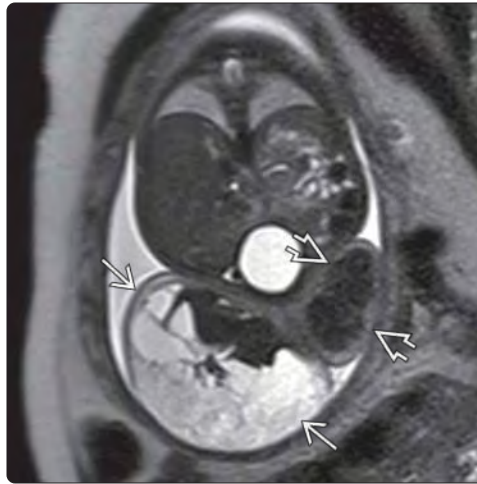
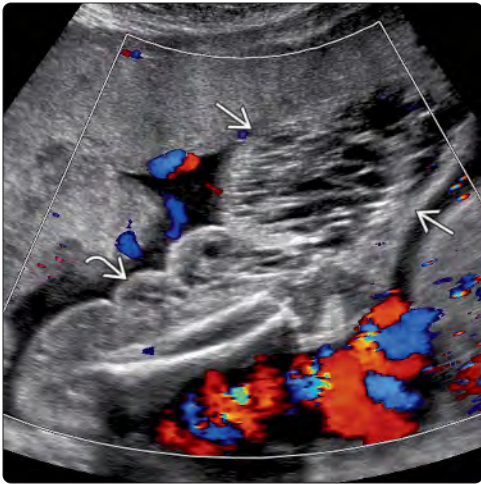- Look carefully for vascularity of mass to predict risk for hydrops
- Obtain MR to look for intracorporeal invasion

Reporting Tips

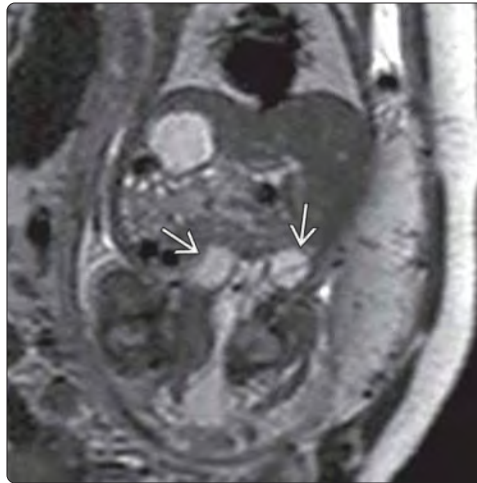
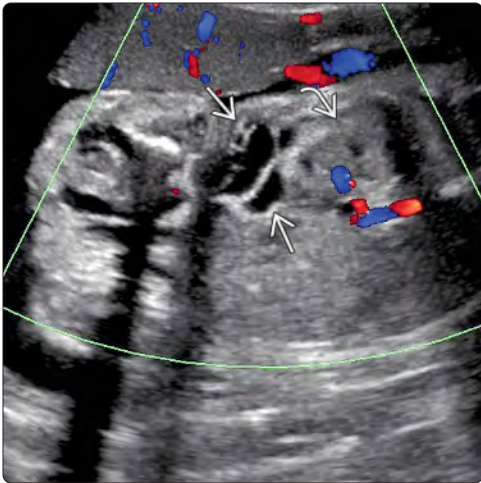
- Recommend genetic counseling for patients with suspicion of KTW
- Consider surgical consultation to educate parents about treatment plan after baby is born
 - Multiple procedures often needed and amputation is real possibility

SELECTED REFERENCES

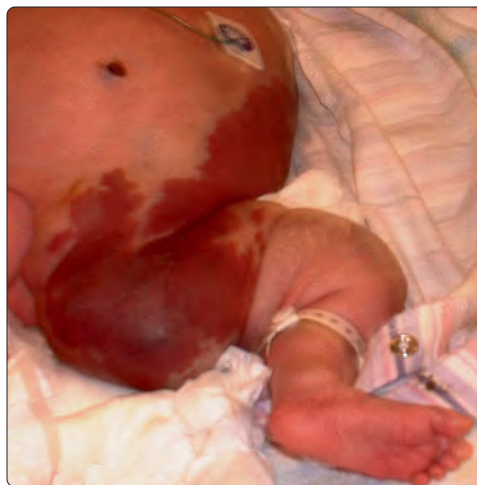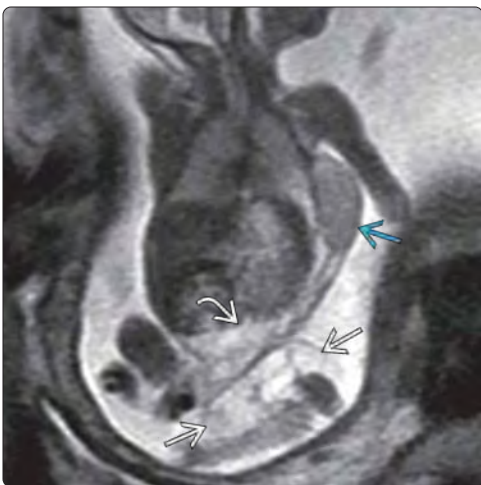1. Calvo-García MA et al: Imaging evaluation of fetal vascular anomalies. *Pediatr Radiol.* 45(8):1218-29, 2014
2. Cakiroglu Y et al: Sonographic identification of Klippel-trenaunay-weber syndrome. *Case Rep Obstet Gynecol.* 2013:595476, 2013
3. Chen CP et al: Prenatal sonographic findings of Klippel-Trénaunay-Weber syndrome. *J Clin Ultrasound.* 35(7):409-12, 2007
4. Peng HH et al: Klippel-Trenaunay-Weber syndrome involving fetal thigh: prenatal presentations and outcomes. *Prenat Diagn.* 26(9):825-30, 2006
5. Rebarber A et al: Obstetric management of Klippel-Trenaunay syndrome. *Obstet Gynecol.* 104(5 Pt 2):1205-8, 2004
6. Assimakopoulos E et al: Klippel-Trenaunay-Weber syndrome with abdominal hemangiomas appearing on ultrasound examination as intestinal obstruction. *Ultrasound Obstet Gynecol.* 22(5):549-50, 2003
7. Martin WL et al: Klippel-Trenaunay-Weber (KTW) syndrome: the use of in utero magnetic resonance imaging (MRI) in a prospective diagnosis. *Prenat Diagn.* 21(4):311-3, 2001



(Left) In this fetus with KTW, a multiloculated infiltrating cystic mass involves the thigh and shin. This mass is mostly avascular and cystic. **(Right)** Axial view through the thigh on MR shows the insinuating nature of the mass around the muscles. No significant intracorporeal extension was seen in this case. Notice the difference in size between the affected thigh and the normal thigh.



(Left) Coronal view of the pelvis and abdomen in a fetus with KTW involving the lower extremity shows retroperitoneal extension of the mass to the level of the kidney. **(Right)** Coronal T2WI MR in the same patient demonstrates more intracorporeal extension of the mass than suspected with ultrasound.



(Left) In this fetus with KTW, the cystic mass is seen involving the thigh and infiltrating into the abdomen, as well as extending along the subcutaneous tissue of the left lateral body wall, up to the axilla. This fetus subsequently developed hydrops. **(Right)** Clinical photograph of the same child after delivery shows the extensive involvement of the thigh and body wall. The baby died shortly after birth.

KEY FACTS

TERMINOLOGY

- Syndrome composed of classic triad of findings
 - Renal cystic dysplasia in 95-100%
 - Encephalocele or other central nervous system (CNS) abnormality in 90%
 - Postaxial polydactyly in 55-75%
- Should have at least 2 of 3 classic features

IMAGING

- Renal cystic dysplasia most consistent finding
 - Kidney appearance is variable
 - Most commonly grossly enlarged and echogenic but may be filled with macroscopic cysts
 - Renal size often massive, causing enlarged abdominal circumference
- Occipital encephalocele classic CNS finding (60-80%) but may have other malformations
 - Dandy-Walker malformation, microcephaly, holoprosencephaly, anencephaly

- Diagnosis can be made in 1st trimester
- Severe oligohydramnios or anhydramnios by 2nd trimester
 - Makes evaluation of polydactyly and other more subtle findings difficult

TOP DIFFERENTIAL DIAGNOSES

- Trisomy 13
 - Significant overlap in imaging features
 - Amniocentesis should be done for karyotype
 - Needed to counsel regarding different recurrence risk

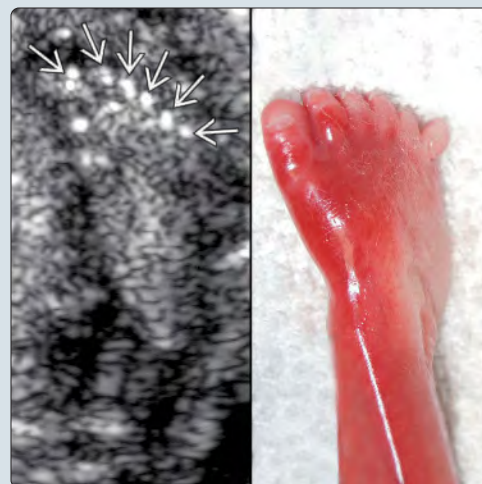
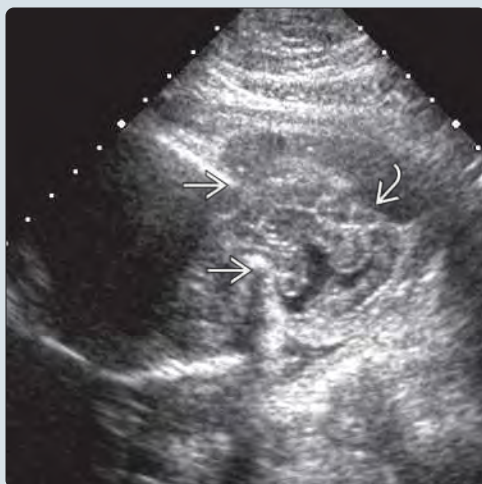
PATHOLOGY

- Genetically heterogeneous lethal ciliopathy
- Autosomal recessive with 25% recurrence risk

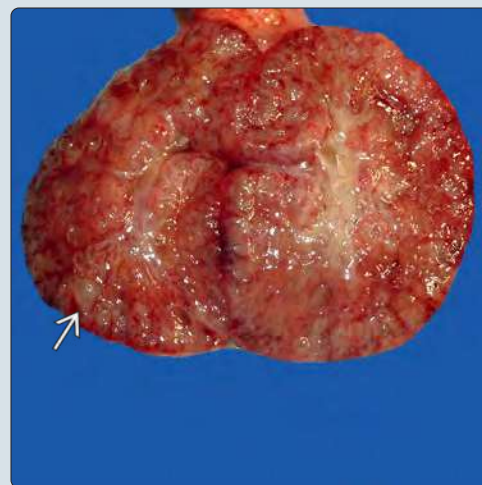
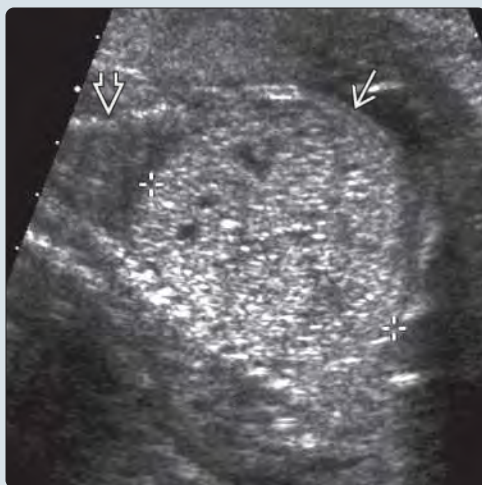
CLINICAL ISSUES

- Oligohydramnios leads to pulmonary hypoplasia
- Most stillborn or die within a few hours
- Needs genetic counseling for future pregnancies

(Left) US of the fetal brain shows a calvarial defect → with a large encephalocele → in a fetus with Meckel-Gruber syndrome. There is also oligohydramnios secondary to renal dysplasia. (Right) US of the foot in the same case shows polydactyly →. Polydactyly is the least consistent finding in Meckel-Gruber syndrome and can be easily missed secondary to oligohydramnios. Postaxial polydactyly is confirmed on the autopsy picture.



(Left) Sagittal US shows a massively enlarged, echogenic kidney (calipers) with a few scattered macroscopic cysts. There are severe oligohydramnios, a small, bell-shaped chest →, and protuberant abdomen →. (Right) At autopsy the bisected kidney shows innumerable small cysts → and complete lack of corticomedullary development. Cystic dysplasia is the most consistent finding in Meckel-Gruber syndrome with the kidneys often being massively enlarged, as in this case.



TERMINOLOGY

Definitions

- Initially described in 1822 by Johann Meckel in a pair of siblings
- Georg Gruber described fetuses with dysencephalia splanchnocystica in 1934
- Classic triad of findings
 - Renal cystic dysplasia in 95-100%
 - Encephalocele or other CNS abnormality in 90%
 - Postaxial polydactyly in 55-75%

IMAGING

General Features

- Best diagnostic clue
 - At least 2 of 3 classic features in fetus with normal karyotype

Ultrasonographic Findings

- **Genitourinary tract**
 - Renal cystic dysplasia most consistent finding
 - Variable sonographic appearance of kidneys
 - Grossly enlarged, echogenic kidneys most common
 - 10-20x normal size
 - Large, macroscopic cysts may be present
 - Abdominal circumference may be significantly increased
 - Rarely renal agenesis
 - Bladder may be small or absent
 - 2nd-trimester oligohydramnios
 - Often anhydramnios
 - Fluid normal in 1st trimester, before kidneys become major contributor to amniotic fluid production
- **CNS**
 - Occipital encephalocele (60-80%)
 - Dandy-Walker malformation
 - Microcephaly common
 - Agenesis of corpus callosum
 - Ventriculomegaly
 - Holoprosencephaly
- **Extremities**
 - Postaxial polydactyly
 - Extra digit may be small or angulated
 - Usually affects all 4 extremities similarly, although this is most variable finding in classic triad
 - May be difficult to see with oligohydramnios
 - Uncommonly preaxial
 - Clubbed feet common
 - Short limbs
 - Bowing of long bones
- **Facial malformations**
 - Cleft lip/palate
 - Micrognathia
 - Microphthalmia
 - Ear malformations
 - Sloping forehead
- **Heart**
 - Septal defects
 - Coarctation of aorta
- Other anomalies

- **Hepatic fibrosis**
 - Frequently seen at autopsy
 - Difficult to appreciate in utero
 - Look for hepatomegaly and poor intrahepatic flow if presenting in 3rd trimester
- Cryptorchidism
- Ambiguous genitalia

Imaging Recommendations

- Diagnosis can be made in 1st trimester
 - May first present with increased nuchal translucency
 - Use endovaginal US to search for anomalies if suspicious findings or positive family history
 - Early normal scan does not completely exclude Meckel-Gruber syndrome
 - Follow-up scan at 18-20 weeks if positive family history
- When one finding seen, carefully search for others
- MR helpful if oligohydramnios limits visualization

DIFFERENTIAL DIAGNOSIS

Trisomy 13

- Significant overlap in findings
- Renal anomalies in 50%
 - Cystic dysplasia
 - Echogenic kidneys with scattered cysts
 - Kidneys may be large but typically smaller than in Meckel-Gruber syndrome
 - Hydronephrosis
- Central nervous system
 - Holoprosencephaly sequence in 40%
 - Encephalocele reported, but less common
- Extremities
 - Postaxial polydactyly in 75%
 - Rocker-bottom foot
- Oligohydramnios less common
 - May have polyhydramnios
- Cardiac defect in 80%
 - Septal defects
 - Hypoplastic left heart
 - Aortic/mitral atresia
- Fetal growth restriction
- Omphalocele

Smith-Lemli-Opitz Syndrome

- Central nervous system
 - Microcephaly, holoprosencephaly, hydrocephalus, agenesis of corpus callosum
- Cardiac defects
 - Atrioventricular canal, ventricular septal defect, hypoplastic left heart
- Genitourinary tract
 - Ambiguous genitalia, cystic renal disease
- Postaxial polydactyly
- Severe forms overlap with Meckel-Gruber syndrome
- Facial features distinctive
 - Hypertelorism, short up-turned nose, low-set ears, micrognathia, broad high forehead, epicanthal folds

Autosomal Recessive Polycystic Kidney Disease

- Enlarged echogenic kidneys
- Does not have cephalocele or polydactyly
- Variable degrees of oligohydramnios

Bilateral Multicystic Dysplastic Kidneys

- No other features of Meckel-Gruber syndrome

Hydroletharus (Salonen-Herva-Norio) Syndrome

- Polydactyly (often duplicated big toe), hydrocephalus, cardiac anomalies
- Does not have cystic kidneys

Bardet-Biedl Syndrome

- Polydactyly, progressive renal dystrophy, liver anomalies, truncal obesity
- Does not have encephalocele

PATHOLOGY

General Features

- Genetics
 - Genetically heterogeneous lethal ciliopathy
 - Autosomal recessive
 - 25% recurrence risk
 - At least 11 genes now implicated with more being discovered
 - *MKS1*, *TMEM216* (*MKS2*), *TMEM67* (*MKS3*), *CEP290* (*MKS4*), *RPGRI1L* (*MKS5*), *CC2D2A* (*MKS6*), *NPHP3* (*MKS7*), *TCTN2* (*MKS8*), *B9D1* (*MKS9*), *B9D2* (*MKS10*), *TMEM231* (*MKS11*)
 - Involvement of multiple different chromosomes explains phenotypic variability

Microscopic Features

- Kidneys
 - Cystic dysplasia
 - Nephrons severely deficient
 - Poor/absent corticomedullary differentiation
 - May be 10-20x normal size
- Myofibroblastic cells in liver and kidney
- Hepatic fibrosis (ductal plate malformation)
 - Arrested development of intrahepatic biliary system
 - Reactive bile duct proliferation
 - Bile duct dilation
 - Periportal fibrosis
 - Leads to portal vascular obliteration

CLINICAL ISSUES

Presentation

- Most common signs/symptoms
 - Most should be recognized on 1st-trimester screening exam
 - 90% diagnosed by 14.3 ± 2.6 weeks
 - Oligohydramnios in 2nd and 3rd trimester
- Other signs/symptoms
 - May have history of prior affected child
 - Elevated maternal serum α-fetoprotein from encephalocele
 - May be normal if covered by membrane
 - Wide phenotypic variability

- Associated findings vary significantly among cases

Demographics

- 2.6 per 100,000 births with regional differences
 - Belgian population 1:3,000
 - Finnish population 1:9,000
- M = F
- 5% of of fetuses with encephaloceles have Meckel-Gruber syndrome

Natural History & Prognosis

- Lethal
 - Oligohydramnios leads to pulmonary hypoplasia
 - Most stillborn or die within a few hours

Treatment

- Karyotype to exclude trisomy 13
- Termination offered
- Fetal monitoring and C-section to be avoided if pregnancy continued
- Enlarged abdominal circumference may cause abdominal dystocia
- External examination and autopsy by experienced pathologist/geneticist to confirm diagnosis
- Genetic counseling for future pregnancies
 - 25% recurrence risk

DIAGNOSTIC CHECKLIST

Consider

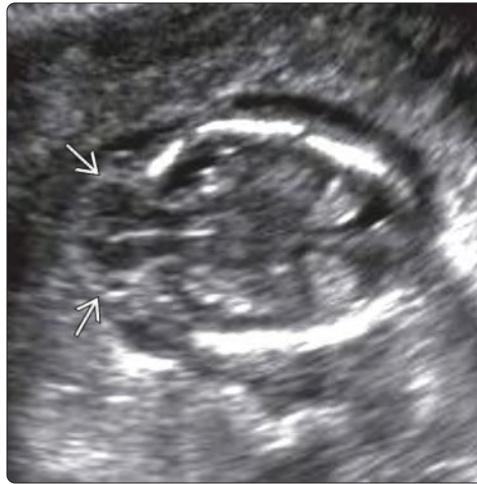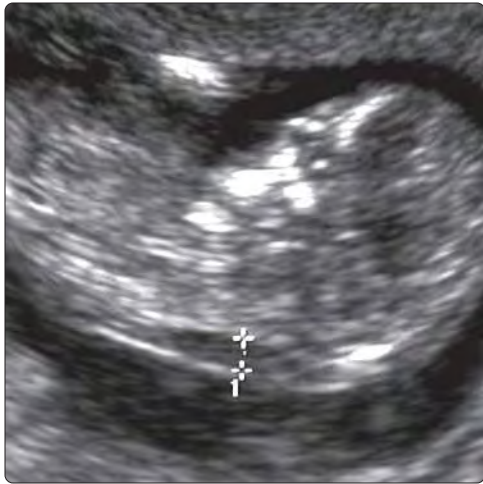- MR when anatomic visualization compromised by oligohydramnios
- Look carefully for other findings when one of major abnormalities is seen

Image Interpretation Pearls

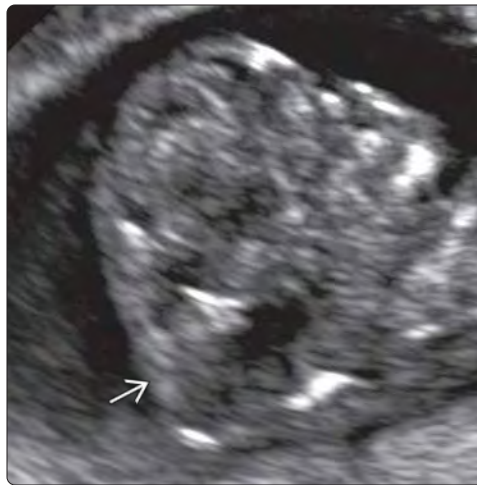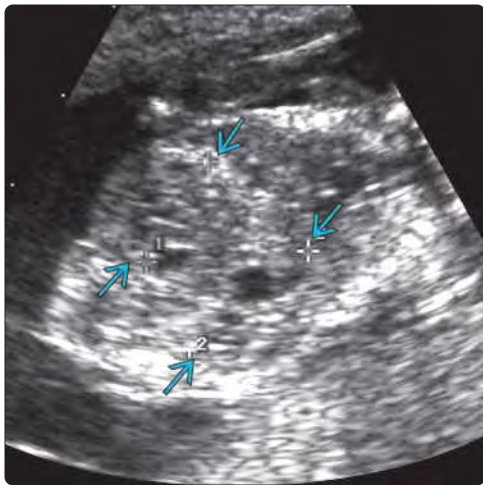
- Significant overlap in imaging features with trisomy 13
 - Amniocentesis should be done for karyotype to appropriately counsel for future pregnancies
 - 1% recurrence risk for trisomy 13 vs. 25% for Meckel-Gruber syndrome
- Renal appearance is variable, from large, echogenic kidneys to kidneys completely replaced by macroscopic cysts
 - Renal size is often massive, causing enlarged abdominal circumference

SELECTED REFERENCES

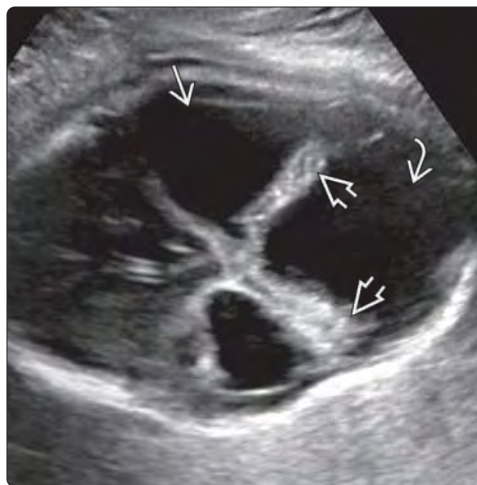
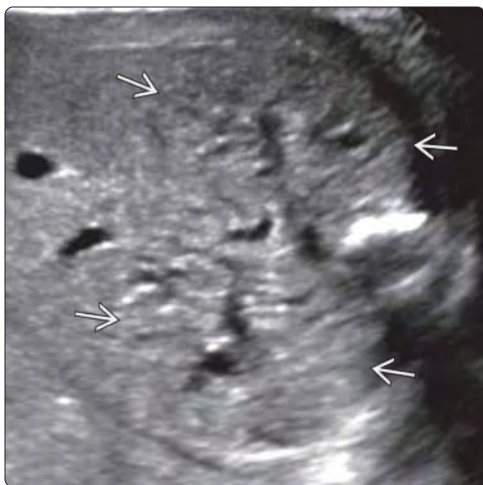
1. Barisic I et al: Meckel-Gruber Syndrome: a population-based study on prevalence, prenatal diagnosis, clinical features, and survival in Europe. *Eur J Hum Genet.* 23(6):746-52, 2015
2. Barker AR et al: Meckel-Gruber syndrome and the role of primary cilia in kidney, skeleton, and central nervous system development. *Organogenesis.* 10(1):96-107, 2014
3. Jones D et al: First-trimester diagnosis of Meckel-Gruber syndrome by fetal ultrasound with molecular identification of *CC2D2A* mutations by next-generation sequencing. *Ultrasound Obstet Gynecol.* 44(6):719-21, 2014
4. Eckmann-Scholz C et al: Earliest ultrasound findings and description of splicing mutations in Meckel-Gruber syndrome. *Arch Gynecol Obstet.* 286(4):917-21, 2012
5. Venkatachala S et al: Meckel syndrome with Caroli disease and choledochal cysts. *Fetal Pediatr Pathol.* 30(5):350-4, 2011
6. Gupta P et al: MRI in a fetus with Meckel-Gruber syndrome. *Pediatr Radiol.* 38(1):122, 2008
7. Alexiev BA et al: Meckel-Gruber syndrome: pathologic manifestations, minimal diagnostic criteria, and differential diagnosis. *Arch Pathol Lab Med.* 130(8):1236-8, 2006



(Left) Transabdominal 1st-trimester US shows a mildly increased nuchal translucency (calipers). During the exam, the posterior calvarium was noted to be irregular, so a transvaginal scan was performed. **(Right)** The transvaginal US confirms an occipital calvarial defect and a large posterior encephalocele containing the entire cerebellum \blacktriangleright . This should warrant a complete search for other anomalies.



(Left) Coronal view through the abdomen in the same 1st-trimester case shows bilateral enlarged cystic kidneys \blacktriangleright . Note that amniotic fluid is often normal in the 1st trimester, even with severe bilateral renal disease. **(Right)** A nuchal translucency scan for the next pregnancy in the same patient showed another encephalocele \blacktriangleright . Meckel-Gruber syndrome is an autosomal recessive disorder with a 25% recurrence risk.



(Left) Axial oblique US of a 3rd-trimester fetus with anhydramnios shows enlarged, echogenic kidneys \blacktriangleright . **(Right)** An image of the brain in the same case shows a Dandy-Walker malformation with splaying of the cerebellar hemispheres \blacktriangleright , an absent vermis, a large posterior fossa cyst \blacktriangleright , and ventriculomegaly \blacktriangleright . Although an occipital encephalocele is the classic finding, other CNS malformations are also associated with Meckel-Gruber syndrome.

Multiple Pterygium Syndromes

KEY FACTS

TERMINOLOGY

- Clinically and genetically heterogeneous group of syndromes characterized by multiple limb contractures (arthrogryposis) with soft tissue webbing across joints
- Lethal type also with associated cystic hygroma, hydrops, and pulmonary hypoplasia

IMAGING

- Increased nuchal translucency/cystic hygroma, absent limb movements, multiple joint contractures, and cutaneous webs
- Webbing more difficult to see in 3rd trimester because of crowding
- Pterygia often not seen on prenatal imaging

TOP DIFFERENTIAL DIAGNOSES

- Lethal type multiple pterygium syndrome (LMPS)
- Escobar variant multiple pterygium syndrome (EVMPS)
- Popliteal pterygium syndrome





- Pterygium colli
- Fetal akinesia deformation sequence

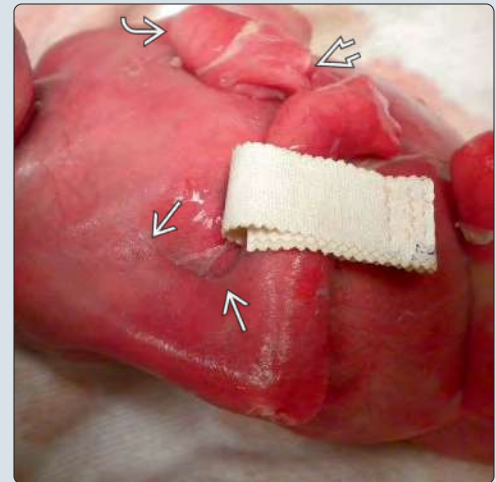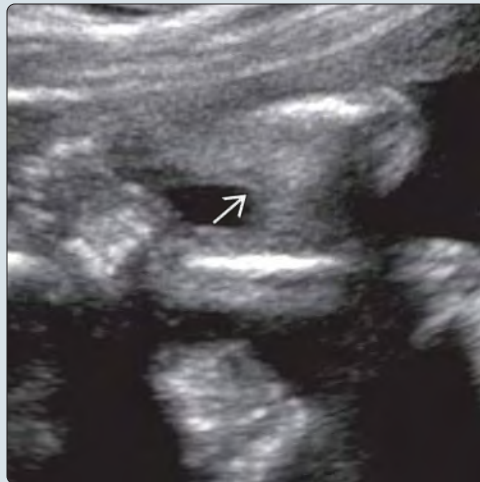PATHOLOGY





- LMPS and EVMPS: Autosomal recessive
- Popliteal pterygium syndrome: Autosomal dominant
 - Allelic with van der Woude syndrome with mutations in interferon regulatory factor 6 (*IRF6*)

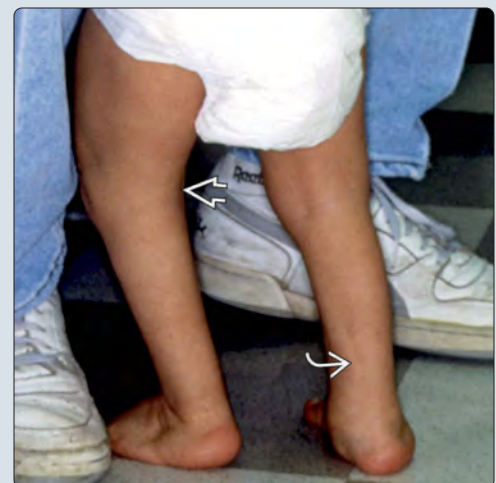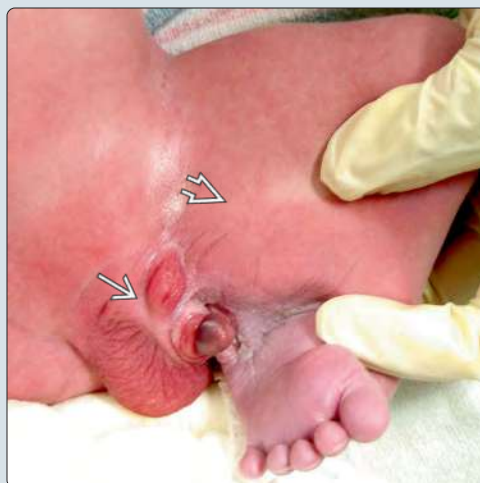CLINICAL ISSUES

- LMPS uniformly lethal in perinatal period due to pulmonary hypoplasia
- EVMPS
 - Progressive (severe) scoliosis is common and may result in restrictive lung disease
- Popliteal pterygium syndrome (nonlethal form)
 - Multiple early orthopedic procedures, intensive physical therapy

(Left) Midtrimester ultrasound shows a fetus with multiple pterygia. Skin web  is noted at the elbow. (Right) This is the same fetus after delivery. The fetus was stillborn and found to have multiple pterygia. Note the arthrogryptic posturing of the limbs, limited by the skin webs. Pterygia  are noted at the elbow and axilla. Mobility of the knees and hips was also affected. Note the ulnar deviation of both wrists  and camptodactyly  of the digits.



(Left) Clinical photograph of a newborn infant with a severe unilateral popliteal pterygium  shows a dysplastic scrotum , likely due to distortion by intracural webs that run from the posterior thigh to the base of the phallus. The infant also had a cleft palate. (Right) Clinical photograph shows a child with popliteal pterygium  syndrome. There is some mild leg length discrepancy. Note the posterior scar  from release of a pterygium. The child was ambulatory.



TERMINOLOGY

Definitions

- Multiple pterygium syndromes: Clinically and genetically heterogeneous group of syndromes characterized by multiple limb contractures (arthrogryposis) with soft tissue webbing across joints
- Lethal type (LMPS) also with associated cystic hygroma, hydrops, and pulmonary hypoplasia

IMAGING

General Features

- Best diagnostic clue
 - Increased nuchal translucency/cystic hygroma, absent limb movements, multiple joint contractures, and cutaneous webs on 1st- and 2nd-trimester ultrasounds
 - Pterygia often not seen on prenatal imaging

DIFFERENTIAL DIAGNOSIS

Lethal Type Multiple Pterygium Syndrome

- Prenatal growth restriction
- Flexion contractures of limbs with multiple extensive pterygia
- Cystic hygroma, hydrops
- Hypoplastic lungs

Escobar Variant Multiple Pterygium Syndrome

- Small stature with progressive scoliosis, kyphosis
- Multiple pterygia of neck, axillae, elbows, knees
- Micrognathia, downturned mouth, ptosis
- Camptodactyly, syndactyly, clubfeet
- Cryptorchidism, hypoplastic labia

Popliteal Pterygium Syndrome

- Orofacial clefting syndrome with popliteal pterygia
- Cleft palate ± cleft lip (90%)
- Lower lip pits (46%)
- Genital abnormalities (50%)
- Clubfeet

Fetal Akinesia Deformation Sequence

- Pena-Shokeir, type I
- Heterogeneous phenotype of fetal akinesia, fetal growth restriction, arthrogryposis, pulmonary hypoplasia
- Phenotypic overlap with LMPS
- Mutations in genes associated with congenital myasthenia syndromes (*RAPSN*, *DOK7*, *MUSK*)

Pterygium Colli

- Soft tissue webbing at lateral neck/base of neck
- Secondary to resolution of cystic hygroma; commonly seen in Turner, Down, and Noonan syndromes

Lethal-Type Popliteal Pterygium (Bartsocas-Papas Syndrome)

- Multiple popliteal pterygia, ankyloblepharon, filiform bands between jaws, orofacial cleft, syndactyly
- Autosomal recessive due to homozygous mutations in *RIPK4* gene

PATHOLOGY

General Features

- Etiology
 - LMPS may be phenotype resulting from early-onset severe fetal akinesia
- Genetics
 - LMPS and Escobar variant (EVMPS): Autosomal recessive
 - Neuromuscular junction genes including mutations in γ subunit of embryonal acetylcholine receptor (*CHRNA1*)
 - Mutations in *CHRNA1* and *CHRNA1* genes also cause LMPS
 - Rare X-linked recessive and autosomal dominant cases
 - Popliteal pterygium syndrome: Autosomal dominant
 - Allelic with van der Woude syndrome with mutations in interferon regulatory factor 6 (*IRF6*)
 - Variable expressivity, incomplete penetrance

Gross Pathologic & Surgical Features

- Variable histopathologic features including evidence of myopathy, neuromuscular disease, and, rarely, storage disease
- Pterygia often include contractile tissue, nerves, blood vessels

CLINICAL ISSUES

Natural History & Prognosis

- LMPS uniformly lethal in perinatal period due to pulmonary hypoplasia
 - Most are stillborn
- EVMPS
 - Progressive (severe) scoliosis is common and may result in restrictive lung disease
 - Pterygia involving oral cavity may obstruct airway and impair nutrition
 - Death in first 6 years of life in 6% due to respiratory insufficiency
- Popliteal pterygium syndrome (nonlethal form)
 - Normal intelligence; ambulatory

Treatment

- Multiple early orthopedic procedures, intensive physical therapy required
- Mixed results with resection of pterygia, which often grow back
- Lengthening of Achilles tendon may improve ability to ambulate
- Removal of ophthalmic pterygia may save vision

SELECTED REFERENCES

1. Chong JX et al: Autosomal-Dominant Multiple Pterygium Syndrome Is Caused by Mutations in MYH3. *Am J Hum Genet.* 96(5):841-9, 2015
2. Bissinger RL et al: Nonlethal multiple pterygium syndrome: Escobar syndrome. *Adv Neonatal Care.* 14(1):24-9, 2014
3. Barros FS et al: Prenatal Diagnosis of Lethal Multiple Pterygium Syndrome Using Two- and Three-Dimensional Ultrasonography. *J Clin Imaging Sci.* 2:65, 2012
4. Vogt J et al: CHRNA1 genotype-phenotype correlations in the multiple pterygium syndromes. *J Med Genet.* 49(1):21-6, 2012

KEY FACTS

TERMINOLOGY

- Lethal congenital disorder with fetal growth restriction, ichthyosis, microcephaly, abnormal facial findings, and limb contractures

IMAGING

- Fetal growth restriction, severe microcephaly
- Facial, extremity, genital, neurological abnormalities
- Scoliosis
- Skin edema
- Absence of normal 3rd-trimester breathing, sucking, swallowing, extremity movements
- Polyhydramnios

TOP DIFFERENTIAL DIAGNOSES

- Trisomy 18 and other causes of fetal growth restriction
- Anencephaly
- Multiple pterygium syndrome

PATHOLOGY

- Linked to serine deficiency due to mutations in *PHGDH*, *PHGDHD*, and *NLS1* on 1p12
- Other implicated genes (*PSAT*, *PSAT1*, *PSATD*, *EPIP*, *NLS2*) on 9q21.2

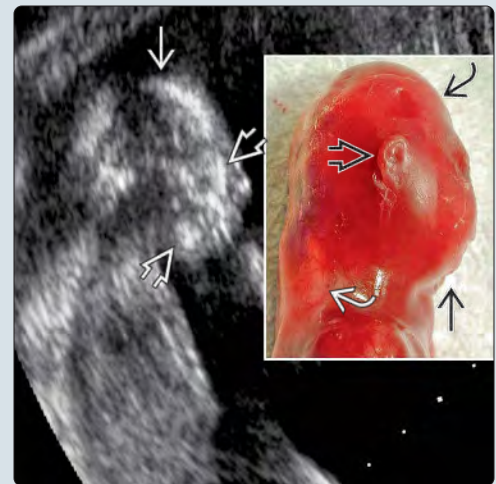
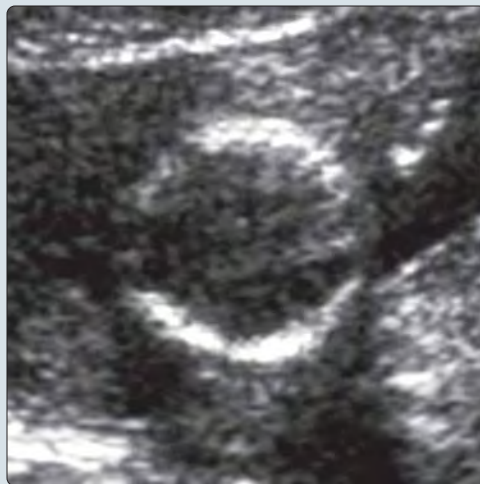CLINICAL ISSUES

- Lethal entity resulting in stillbirth or neonatal demise
- Autosomal recessive with 25% recurrence risk
 - Stress importance of autopsy for diagnosis to counsel for future pregnancies

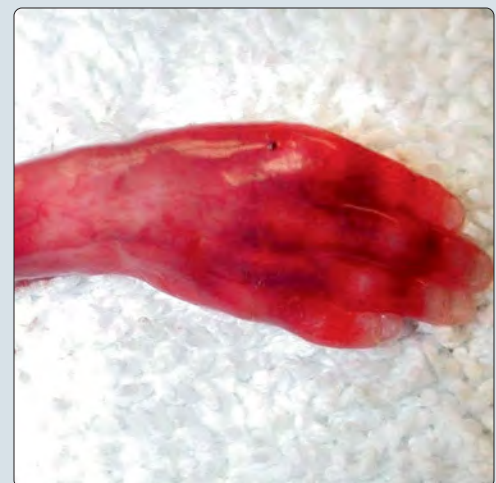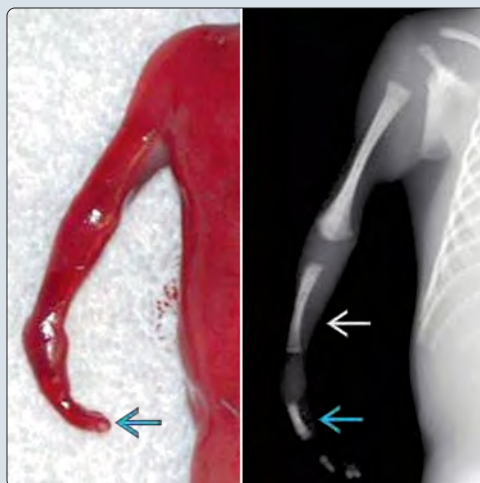DIAGNOSTIC CHECKLIST

- Absence of eyelids is a characteristic feature of this syndrome at birth
- Prenatal ultrasound findings of marked ocular proptosis in growth-restricted, edematous fetus should prompt consideration of Neu-Laxova

(Left) Axial US of the head at 18 weeks shows a rounded appearance with no normal intracranial structures visible. The head size was also much smaller than expected for dates and the rest of the fetus. (Right) Sagittal US in the same case shows severe microcephaly with ossified cranium appearing about the same size as the facial bony structures. Autopsy photograph shows the same findings as well as sloped forehead, microtia, flattened nasal bridge, micrognathia, and nuchal skin thickening.



(Left) Autopsy image and radiograph in the same case show a single forearm bone and an abnormal hand with a single digit. (Right) The other extremity had 4 digits with absent thumb but 2 forearm bones were seen on radiograph. Autopsy also showed necrosis of the eyelids, the precursor to the clinical hallmark feature of absent eyelids.



TERMINOLOGY

Definitions

- Lethal congenital disorder with fetal growth restriction (FGR), skin thickening/edema, microcephaly, abnormal facial findings, and limb abnormalities

IMAGING

Ultrasonographic Findings

- FGR
 - Small placenta, often short umbilical cord
 - Polyhydramnios (very unusual in growth restriction unless associated with trisomy 18)
- Microcephaly: Look for sloping forehead on sagittal view as well as abnormal biometry
- Facial abnormalities: Exophthalmos, hypertelorism, low-set ears, flat nasal bridge, and micrognathia
- Limb abnormalities and scoliosis
 - Syndactyly, camptodactyly, clinodactyly
 - Hyperextended knees, flexion contractures, pterygia
- Skin edema may be generalized or limited to scalp/extremities
- Absence of normal 3rd-trimester movements also described

DIFFERENTIAL DIAGNOSIS

Trisomy 18

- More likely to be associated with multiple structural anomalies

Other Causes of FGR

- Usually associated with oligohydramnios, Neu-Laxova associated with polyhydramnios

Anencephaly

- Coronal view may be mistaken for anencephaly due to prominent eyes and severe microcephaly
 - Presence of ossified cranium (no matter how small) excludes anencephaly
 - Different recurrence risk so important to avoid misdiagnosis

Multiple Pterygium Syndrome

- Cystic hygroma with flexion contractures due to pterygia ± clubfoot, syndactyly

PATHOLOGY

General Features

- Etiology
 - Neuroectodermal dysplasia vs. malformation syndrome secondary to severe skin restriction
- Genetics
 - Autosomal recessive inheritance with 25% recurrence risk in future pregnancies
 - Linked to serine deficiency due to mutations in the phosphoglycerate dehydrogenase gene (*PHGDH*) as well as *PHGDHD* and *NLS1* on 1p12
 - Genotype-phenotype correlation between degree of *PHGDH* inactivation and disease severity

- Other implicated genes (*PSAT*, *PSAT1*, *PSATD*, *EPIP*, *NLS2*) on 9q21.2

CLINICAL ISSUES

Presentation

- Other signs/symptoms
 - Ichthyosis in 50%
 - Central nervous system anomalies
 - Lissencephaly, hydranencephaly
 - Agenesis of corpus callosum
 - Cerebellar hypoplasia, Dandy Walker malformation
 - Abnormal facies
 - Absent eyelids characteristic of syndrome at term
 - Flat nasal bridge
 - Micrognathia, low-set ears, hypertelorism also common features
 - Genital abnormalities (cryptorchidism, uterine duplication)

Demographics

- Epidemiology
 - Extremely rare

Natural History & Prognosis

- Lethal entity resulting in stillbirth or neonatal demise

Treatment

- Offer amniocentesis (mainly to exclude trisomy 18)
- Offer termination
- Stress importance of autopsy for diagnosis in continuing pregnancies
- Early US with serial growth assessment in future pregnancies (microcephaly presents early)

DIAGNOSTIC CHECKLIST

Image Interpretation Pearls

- Absence of eyelids is a characteristic clinical feature of this syndrome; may not be evident in fetus
- Excessive subcutaneous tissue deposition with edema is a hallmark feature (developing ichthyosis)

Reporting Tips

- Prenatal ultrasound findings of marked ocular proptosis in growth-restricted, edematous fetus should prompt consideration of Neu-Laxova

SELECTED REFERENCES

1. Mattos EP et al: Identification of a premature stop codon mutation in the *PHGDH* gene in severe Neu-Laxova syndrome-evidence for phenotypic variability. *Am J Med Genet A*. 167(6):1323-9, 2015
2. Acuna-Hidalgo R et al: Neu-Laxova syndrome is a heterogeneous metabolic disorder caused by defects in enzymes of the L-serine biosynthesis pathway. *Am J Hum Genet*. 95(3):285-93, 2014
3. Roy S et al: Neu-Laxova syndrome: a case report. *Mymensingh Med J*. 23(1):167-9, 2014
4. Shaheen R et al: Neu-Laxova syndrome, an inborn error of serine metabolism, is caused by mutations in *PHGDH*. *Am J Hum Genet*. 94(6):898-904, 2014
5. Badakali M et al: Rare manifestations of Neu-Laxova syndrome. *Fetal Pediatr Pathol*. 31(1):1-5, 2012
6. Dhillon P et al: Neu-Laxova syndrome: a prenatal diagnosis. *J Miss State Med Assoc*. 52(10):307-9, 2011
7. Coto-Puckett WL et al: A spectrum of phenotypical expression OF Neu-Laxova syndrome: Three case reports and a review of the literature. *Fetal Pediatr Pathol*. 29(2):108-19, 2010

KEY FACTS

TERMINOLOGY

- Genetically heterogeneous syndrome characterized by congenital heart defects, webbed neck, pectus deformity of chest, short stature, characteristic facial appearance, and in males, cryptorchidism
- Caused by activating mutations in RAS-MAPK signaling pathway

IMAGING

- Cystic hygroma with polyhydramnios and normal karyotype should prompt evaluation for Noonan syndrome
- Increased nuchal translucency in 1st trimester; cystic hygroma in 2nd trimester
- Heart defects in up to 90%
- Polyhydramnios in 1/3 of cases
- Lymphatic abnormalities including skin and extremity edema, pulmonary lymphangiectasia, chylothorax

TOP DIFFERENTIAL DIAGNOSES

- Turner syndrome
- Aarskog-Scott syndrome (faciogenital dysplasia)
- Fetal alcohol syndrome
- Neurofibromatosis-Noonan association (NF-Noonan syndrome)

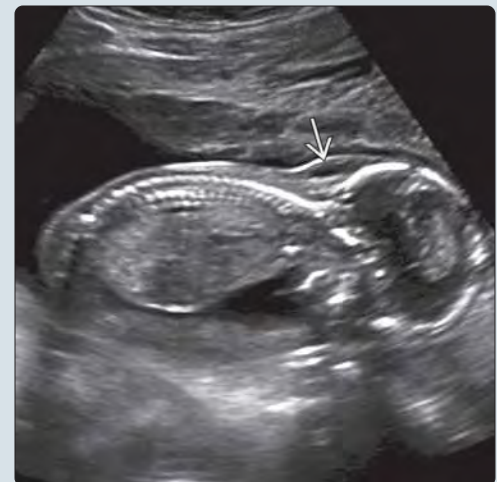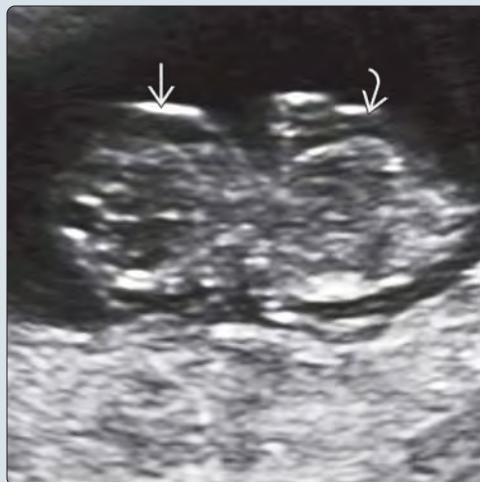
CLINICAL ISSUES

- Short stature, characteristic facies, pectus deformity, webbed neck, delayed puberty, learning disability
- Hematologic issues
- 8x increased risk of cancers in Noonan syndrome
 - RAS-MAPK signaling pathway well known for relationship with oncogenesis

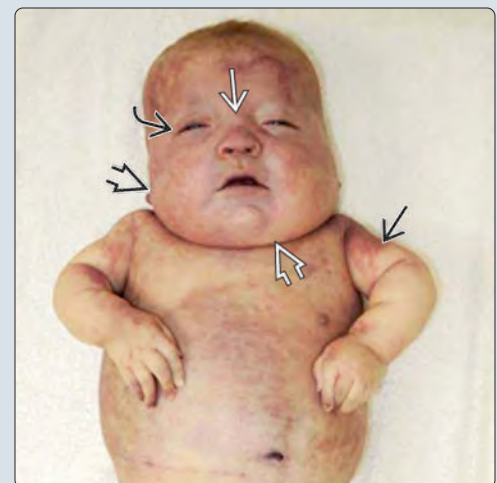
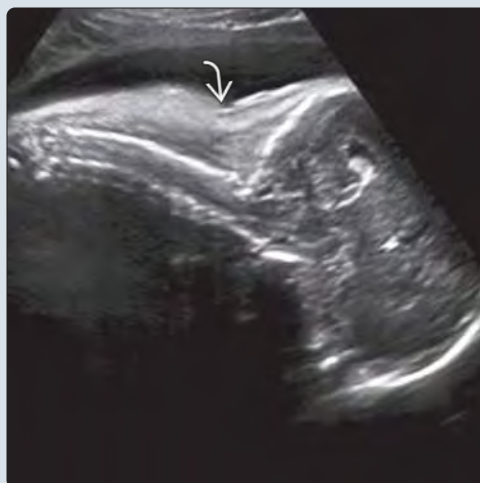
DIAGNOSTIC CHECKLIST

- Consider Noonan syndrome in euploid fetus with cystic hygroma or with cardiomyopathy

(Left) Ultrasound of an embryo at 9-week gestation shows a large cystic hygroma and body wall edema. **(Right)** Ultrasound of the same fetus at 16-week gestation shows persistence of a small cystic hygroma without other signs of hydrops. The fetus was a male, and a karyotype was normal 46,XY. No other structural defects were noted. Noonan syndrome is part of the differential diagnosis in a euploid fetus with a cystic hygroma ± hydrops. Molecular panels are available for testing.



(Left) Ultrasound at 28 weeks in the same patient shows thickened nuchal skin with resolution of the hygroma. Cardiomyopathy with biventricular dysfunction was noted, concerning for Noonan syndrome. Severe polyhydramnios was also seen. **(Right)** Autopsy photograph in the same patient shows typical features of Noonan syndrome. Wide-spaced eyes with a broad nasal root & down-slanting palpebral fissures are seen. The ears are low set. The neck is short with redundant skin, & there is mild rhizomelia.



TERMINOLOGY**Definitions**

- Genetically heterogeneous syndrome characterized by congenital heart defects, webbed neck, pectus deformity of chest, short stature, characteristic facial appearance, and in males, cryptorchidism
- Caused by activating mutations in RAS-MAPK signaling pathway (RASopathy)

IMAGING**General Features**

- Best diagnostic clue
 - Cystic hygroma with polyhydramnios and normal karyotype

Ultrasonographic Findings

- Increased nuchal translucency in 1st trimester; cystic hygroma in 2nd trimester
- Heart defects in up to 90%
 - Pulmonary stenosis in 50%
 - Hypertrophic cardiomyopathy in 20-33%
- Polyhydramnios in 1/3 of cases
- Lymphatic abnormalities including skin edema, pulmonary lymphangiectasia, chylothorax

DIFFERENTIAL DIAGNOSIS**Turner Syndrome**

- Monosomy X
- Short stature; webbed neck; left-sided cardiac defects; renal abnormalities; streak gonads

Aarskog-Scott Syndrome (Faciogenital Dysplasia)

- X-linked caused by mutations in *FGD1* gene
- Short stature, hypertelorism, shawl scrotum (scrotum surround penis), brachydactyly, neurobehavioral phenotype

Fetal Alcohol Syndrome

- Pre- and postnatal growth deficiency; cognitive delays; microcephaly; cardiac defects; characteristic facies; visual and hearing deficits; behavioral phenotype

Neurofibromatosis-Noonan Association (NF-Noonan Syndrome)

- Overlapping phenotype of Noonan syndrome with café au lait spots, neurofibromas and occasionally other characteristic tumors of NF
- May have mutations in both *PTPN11* and *NF1*

Watson Syndrome

- Caused by mutations in *NF1* gene
- Pulmonic stenosis, short stature, café au lait spots, and cognitive delay

Primidone Embryopathy

- Anticonvulsant; structural analog of phenobarbital and related to barbiturate-derivative anticonvulsants
- Pre- and postnatal growth deficiency, abnormal facies, microcephaly, cardiac defects

PATHOLOGY**General Features**

- Genetics
 - Very heterogeneous; most autosomal dominant
 - NS1: Caused by heterozygous mutations in *PTPN11* gene
 - NS3: Caused by mutations in *KRAS*, *NS4-RAF1*, *NS6-NRAS*, *NS7-BRAF*, *NS8-RIT1*, *NS9-SOS2*, *NS10-LZTR1*
 - NS2: Possible autosomal recessive with mutations in *SHOC2*
 - Overlapping features with neurofibromatosis (NF1)
 - Neurofibromatosis-Noonan: Mutations in neurofibromin (*NF1*) and *PTPN11*

CLINICAL ISSUES**Presentation**

- Most common signs/symptoms
 - Prenatal: Cystic hygroma, abnormal heart
 - Postnatal: Short stature, characteristic facies, pectus deformity, webbed neck, cryptorchidism

Demographics

- Epidemiology
 - Birth prevalence 1/1,000 to 1/2,500
 - Transmission by affected mother 3x more often than affected father, likely due to reduced male fertility

Natural History & Prognosis

- Birthweight usually normal
- Failure to thrive with development of short stature
- Learning disabilities, language delay, hearing loss
- Mild intellectual impairment in 1/3; more common in males
- Delayed puberty with cryptorchidism common in males; puberty and fertility usually normal in females
- Characteristic facial phenotype evolves as person ages
- Hematologic issues
 - Bleeding diathesis, leukopenia, thrombocytopenia, myeloproliferative disorder
- 8x increased risk of cancers in Noonan syndrome
 - RAS-MAPK signaling pathway well known for relationship with oncogenesis

DIAGNOSTIC CHECKLIST**Consider**

- Noonan syndrome in euploid fetus with cystic hygroma ± hydrops
- Also consider with evidence of cardiomyopathy in fetus with cystic hygroma

SELECTED REFERENCES

1. Aoki Y et al: Recent advances in RASopathies. *J Hum Genet.* 61(1):33-9, 2015
2. Ekvall S et al: Mutation in NRAS in familial Noonan syndrome - case report and review of the literature. *BMC Med Genet.* 16(1):95, 2015
3. Gelb BD et al: Cardiomyopathies in Noonan syndrome and the other RASopathies. *Prog Pediatr Cardiol.* 39(1):13-19, 2015
4. Kneitel AW et al: A Novel Mutation on RAF1 in Association with Fetal Findings Suggestive of Noonan Syndrome. *Fetal Pediatr Pathol.* 34(6):361-4, 2015

KEY FACTS

TERMINOLOGY

- Syndrome comprising
 - Posterior fossa malformations
 - Segmental hemangiomas
 - Arterial anomalies
 - Cardiac defects
 - Eye abnormalities
 - Sternal or ventral defects

IMAGING

- Unilateral cerebellar hypoplasia
- Cardiovascular abnormalities
- Sternal cleft



CLINICAL ISSUES

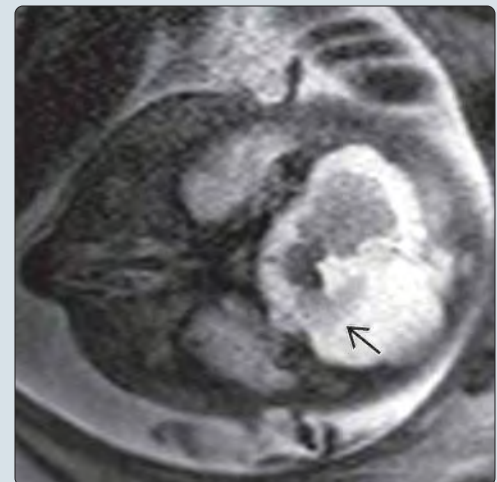
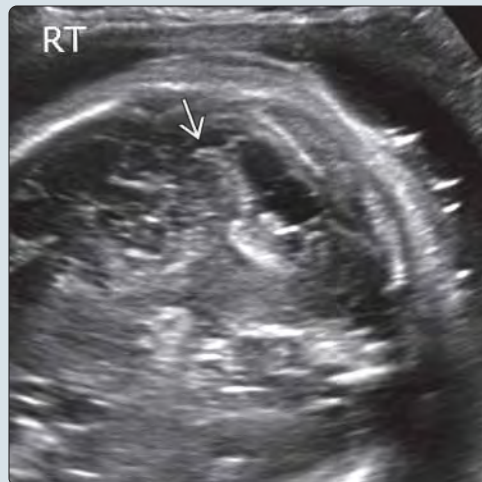
- Current literature suggests PHACES may be present in up to 2% of children with facial hemangiomas and 20% of children with "segmental" facial hemangiomas


- 70% of children have only 1 extracutaneous manifestation
- CNS malformations are commonest extracutaneous manifestation (45%)
- Cerebrovascular next commonest (35%)
- Structural CNS and cerebrovascular malformation often coexist
- Long-term prognosis remains unknown
 - At risk for developmental delay, intellectual impairment, seizures, and infarcts
- Appropriate management requires careful planning for each individual
- Propranolol, steroids, bleomycin, interferon, vincristine

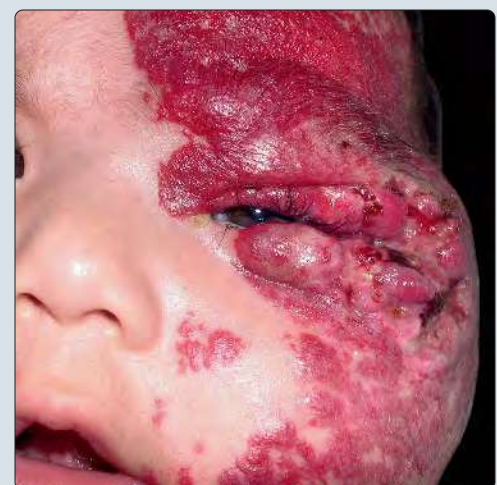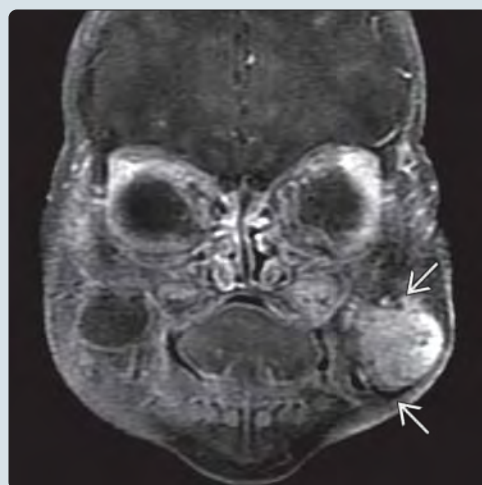
DIAGNOSTIC CHECKLIST

- Posterior fossa malformations in female fetus, especially if associated with supratentorial brain findings, should alert the sonographer to the possibility of syndromes such as Aicardi and PHACES

(Left) Oblique view of the posterior fossa in the 3rd trimester shows a small, dysplastic right cerebellar hemisphere . This is a common finding in PHACES syndrome. Other manifestations are hard to see on fetal imaging, so these infants require careful evaluation at birth. **(Right)** Axial T2WI shows unilateral left cerebellar hemihypoplasia . The referral diagnosis was Dandy-Walker malformation, but other images showed a normal-sized, rotated vermis and normal torcular excluding that entity.



(Left) Postnatal coronal T1WI MR post gadolinium in the same patient shows an enhancing hemangioma  in the left cheek, ipsilateral to the cerebellar hemispheric defect. The infant also had a scalp hemangioma noticed at birth. Neither was visible on fetal imaging, even in retrospect. **(Right)** Clinical photograph of a patient with PHACES shows a typical facial infantile hemangioma. Many of these lesions respond dramatically to propranolol \pm prednisolone administration. (From: Osborn's Brain.)



TERMINOLOGY

Definitions

- Syndrome comprising
 - Posterior fossa malformations
 - Segmental hemangiomas
 - Arterial anomalies
 - Cardiac defects
 - Eye abnormalities
 - Sternal or ventral defects

IMAGING

Ultrasonographic Findings

- CNS abnormalities
 - Posterior fossa anomalies particularly cerebellar hemispheric disruption
 - Dysgenesis of corpus callosum
 - Cortical dysplasia
- Cardiovascular abnormalities
 - Tetralogy of Fallot, ventricular septal defect, variant great vessel anatomy
- Sternal cleft

MR Findings

- Unilateral cerebellar hypoplasia
 - Dandy-Walker malformation, vermian dysgenesis also described
- Cortical dysplasia including pachygyria, subependymal and subcortical gray matter heterotopia
- Callosal dysgenesis
- Arachnoid cysts

DIFFERENTIAL DIAGNOSIS

Sturge-Weber Syndrome

- Abnormal development of fetal cortical veins → chronic venous ischemia
- Brain cortical calcification with ipsilateral choroid plexus enlargement
- Posterior fossa not involved

CLINICAL ISSUES

Presentation

- Prenatal diagnosis can be suggested but requires evaluation of infant
 - Cerebellar hemihypoplasia
 - Sternal cleft, face/neck hemangioma
- Children present with facial hemangiomas
 - PHACES may be present in up to 2% of children with facial hemangiomas and 20% of children with "segmental" facial hemangiomas
 - 70% of children have only 1 extracutaneous manifestation
- CNS malformations are commonest extracutaneous manifestation (45%)
- Cerebrovascular next commonest (35%)
 - Cerebellopontine angle hemangiomas
 - Hypoplasia or agenesis of major cerebral vessels
 - Persistence of embryonic vessels
 - Progressive vascular stenosis or occlusion

- Dolichoectasia of cerebral vasculature
- Structural CNS and cerebrovascular malformation often coexist

Demographics

- Female predominance (91% of reported cases)

Natural History & Prognosis

- Long-term prognosis remains unknown
- At risk for developmental delay, intellectual impairment, seizures, and infarcts secondary to progressive vasculopathy
 - Neurological sequelae in 50-90% if vascular or structural cerebral malformations present
 - Cortical dysplasias often associated with intractable seizures

Treatment

- Detailed postnatal evaluation
 - Recognition of associated vascular pathology allows preemptive treatment before potentially irreversible sequelae
 - Risk of progressive vasculopathy
 - Vessels become dilated, tortuous
 - Develop moyamoya-type collaterals
 - Vascular occlusion → stroke (described in children from 4 months to 14 years)
 - CNS arteriopathy may → aneurysm formation
 - Patients with large facial cutaneous hemangiomas at risk for CNS/cerebrovascular anomalies
 - S1 distribution (frontotemporal) for ocular anomalies
 - S3 distribution (mandibular) for airway and cardiac anomalies
 - Endocrine evaluation: Pituitary dysfunction described
 - Enroll child in PHACES registry (<http://www.phacesyndromecommunity.org>)
- Propranolol is effective for treatment of hemangiomas but potential risk of ischemic complications with reduced blood pressure + vascular anomalies
- Appropriate management requires careful planning for each individual
 - Propranolol, steroids, bleomycin, interferon, vincristine
- Sternal cleft repair: Ideally primary complete repair but may require prosthesis/muscle flap depending on extent

DIAGNOSTIC CHECKLIST

Image Interpretation Pearls

- Posterior fossa malformations in female fetus, especially if associated with supratentorial brain findings, should alert the sonographer to the possibility of syndromes, such as Aicardi and PHACES

SELECTED REFERENCES

1. Gnarr M et al: Propranolol and prednisolone combination for the treatment of segmental haemangioma in PHACES syndrome. *Br J Dermatol.* 173(1):242-6, 2015
2. Léauté-Labrèze C et al: A randomized, controlled trial of oral propranolol in infantile hemangioma. *N Engl J Med.* 372(8):735-46, 2015
3. Massoud M et al: Prenatal unilateral cerebellar hypoplasia in a series of 26 cases: significance and implications for prenatal diagnosis. *Ultrasound Obstet Gynecol.* 44(4):447-54, 2013
4. Torre M et al: Phenotypic spectrum and management of sternal cleft: literature review and presentation of a new series. *Eur J Cardiothorac Surg.* 41(1):4-9, 2012

KEY FACTS

TERMINOLOGY

- Acrocephalosyndactyly type V
- Craniosynostosis syndrome with characteristic hand and foot anomalies

IMAGING

- Abnormal calvarial shape suggestive of craniosynostosis
 - Kleeblattschädel skull common
- Shallow orbits with ocular proptosis, often severe
- Abnormal hands and feet with deviated broad thumbs and toes





TOP DIFFERENTIAL DIAGNOSES

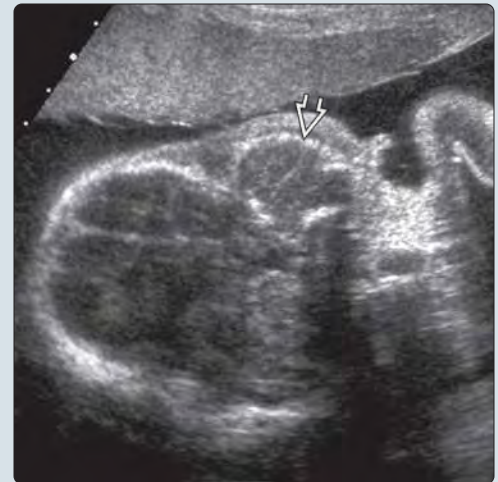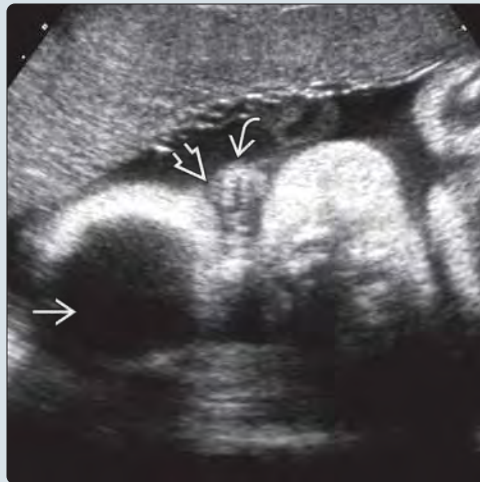
- *FGFR*-related craniosynostosis spectrum
 - Apert syndrome
 - Crouzon syndrome
 - Beare-Stevenson syndrome
 - *FGFR2*-related (isolated) coronal synostosis
 - Jackson-Weiss syndrome






- Crouzon syndrome with acanthosis nigricans
- Muenke syndrome
- Thanatophoric dysplasia, type 2
- Carpenter syndrome
- Saethre-Chotzen syndrome

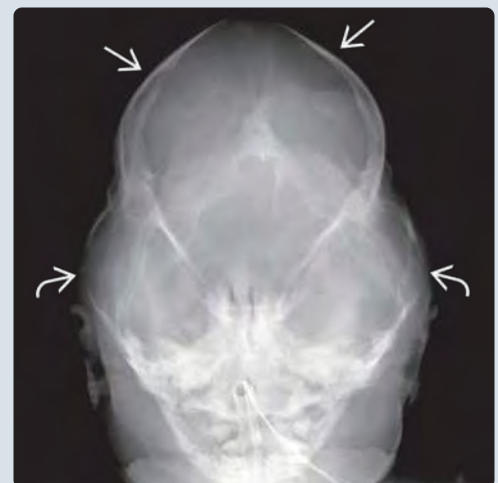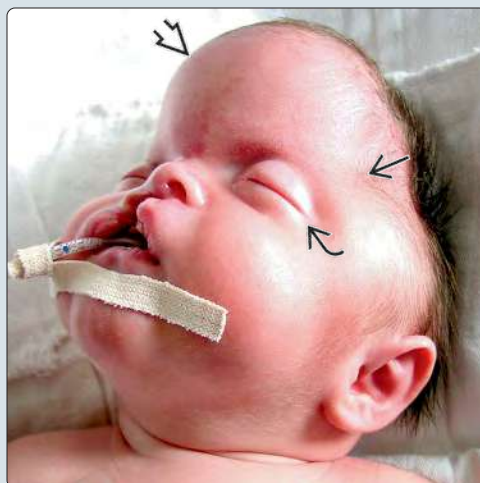PATHOLOGY

- Genetically heterogeneous
 - Most due to mutations in *FGFR1* gene (8p11.23) or in *FGFR2* gene (10q26.13)
- 3 subtypes based on clinical findings and associated prognosis
 - Subclasses do not necessarily correlate with molecular findings
 - Type 1: Compatible with survival, normal intelligence
 - Types 2 and 3: Generally do poorly and die early
- Type 1 autosomal dominant; types 2 and 3 generally sporadic
- Severe airway complications common

(Left) Coronal ultrasound of a 3rd-trimester fetus with Pfeiffer syndrome shows orbital proptosis . The lids are closed , not everted, which is often seen in the more severe forms of Pfeiffer syndrome. The prominent frontal bossing can also be appreciated . (Right) Coronal view through the brain shows bulging of the middle cranial fossa  (kleeblattschädel skull) secondary to craniosynostosis.



(Left) Clinical photograph of a newborn with Pfeiffer syndrome shows the abnormal calvarial shape due to complex craniosynostosis. Note the prominent frontal bossing  due to coronal suture synostosis  and proptosis  due to shallow orbits. A cleft lip, unusual in Pfeiffer, is also seen. (Right) AP radiograph shows the "towering" skull  in Pfeiffer syndrome. Also note the symmetrically protruding temporal fossae , which create the classic cloverleaf appearance or kleeblattschädel skull.



TERMINOLOGY

Synonyms

- Acrocephalosyndactyly type V; ACS5

Definitions

- Craniosynostosis syndrome with characteristic hand and foot anomalies

IMAGING

General Features

- Best diagnostic clue
 - Unusual calvarial shape suggestive of craniosynostosis with abnormal hands and feet

Ultrasonographic Findings

- Abnormal calvarial shape
 - Shallow orbits with ocular proptosis, often severe
 - Kleeblattschädel skull common
- Abnormal hands and feet with deviated broad thumbs and toes

Imaging Recommendations

- Best imaging tool
 - 3D ultrasound will help to define facial and limb abnormalities, assist in counseling families
 - Fetal MR may better define brain structure

DIFFERENTIAL DIAGNOSIS

FGFR-Related Craniosynostosis Spectrum

- With exception of Muenke and *FGFR2*-related coronal synostosis, diagnosis is clinical, based on bicoronal synostosis or cloverleaf skull with typical facial features and hand/foot findings
- *FGFR2*-related (isolated) coronal synostosis
- Muenke syndrome
 - Diagnosis by identification of p.Pro250Arg mutation in *FGFR3*
- Apert syndrome
 - Broad thumbs with complex syndactyly of fingers and toes
- Crouzon syndrome
 - Craniosynostosis of multiple sutures, severe proptosis, hypertelorism
- Beare-Stevenson syndrome
- Jackson-Weiss syndrome
- Crouzon syndrome with acanthosis nigricans

Thanatophoric Dysplasia Type 2

- Lethal skeletal dysplasia with kleeblattschädel skull, micromelia, small thorax
- *FGFR3* mutation

Carpenter Syndrome

- Craniosynostosis of multiple sutures, preaxial polydactyly with variable syndactyly, cardiac and ventral wall abnormalities

Saethre-Chotzen Syndrome

- Craniosynostosis of coronal and lambdoid sutures, syndactyly

PATHOLOGY

General Features

- Genetics
 - Genetically heterogeneous
 - Type 1 autosomal dominant; types 2 and 3 generally sporadic
 - Most due to mutations in *FGFR1* gene (8p11.23) or in *FGFR2* gene (10q26.13)

Staging, Grading, & Classification

- 3 clinical subtypes described by M.M. Cohen based on clinical findings and associated prognosis
 - Subclasses do not necessarily correlate with molecular findings

CLINICAL ISSUES

Presentation

- Most common signs/symptoms
 - **Type 1 ("classic" syndrome)**
 - Compatible with survival
 - Craniosynostosis of coronal ± sagittal sutures
 - Hypoplastic midface
 - Broad, medially deviated distal thumbs and great toes, brachydactyly and variable syndactyly
 - **Type 2**
 - Kleeblattschädel (cloverleaf) skull
 - Severe ocular proptosis, often with everted lids
 - Severe central nervous system abnormality
 - Broad thumbs and great toes
 - Ankylosis of elbows
 - Early death
 - **Type 3**
 - Similar to type 2 without kleeblattschädel skull
- Other signs/symptoms
 - Hearing loss common due to external and middle ear anatomic abnormalities (over 90%)
 - Choanal atresia
 - Abnormal airway with laryngo-, tracheo-, and bronchomalacia

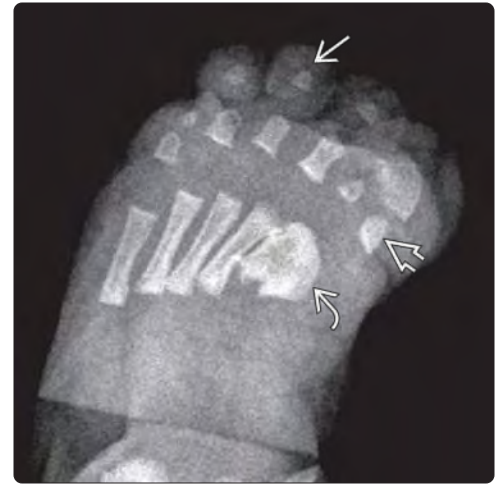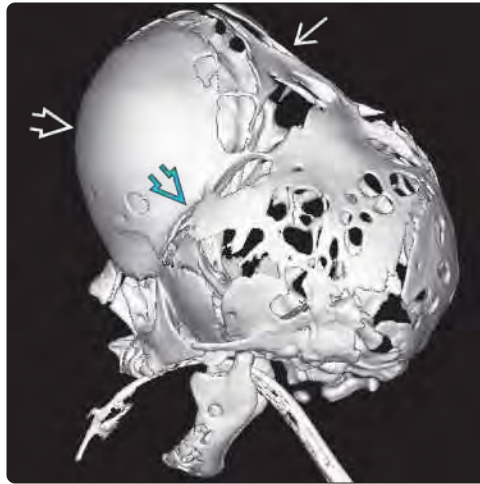
Natural History & Prognosis

- Incidence of 1/100,000 births
- Type 1: Compatible with survival and normal or near-normal intelligence
- Types 2 and 3: Early death is common
 - Aggressive medical and surgical therapy, especially with regard to airway issues, has been associated with improved prognosis
- Hand and foot malformations less severe in *FGFR1* mutations than in *FGFR2* mutations

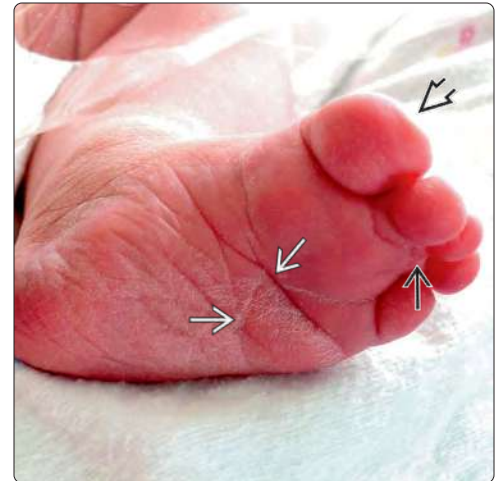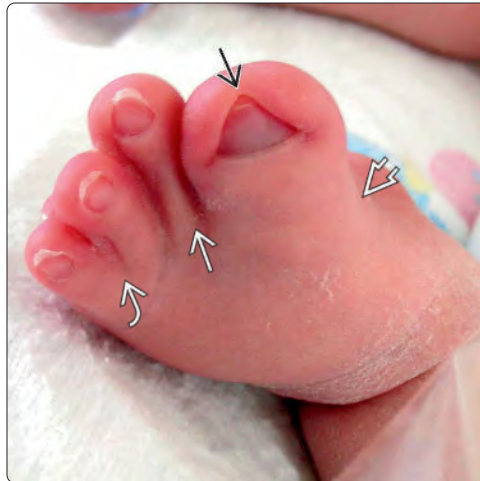SELECTED REFERENCES

1. Al-Adba B et al: Radiographic manifestations in Pfeiffer syndrome. *Arthritis Rheumatol.* 67(8):2282, 2015
2. Flöttmann R et al: *FGFR2* mutation in a patient without typical features of Pfeiffer syndrome—The emerging role of combined NGS and phenotype based strategies. *Eur J Med Genet.* 58(8):376-80, 2015
3. Nieuwenhuyzen-De Boer GM et al: Pfeiffer syndrome: the importance of prenatal diagnosis. *Eur J Obstet Gynecol Reprod Biol.* 181:339-40, 2014

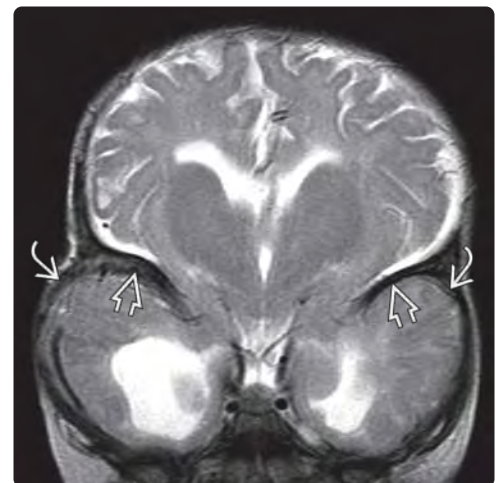
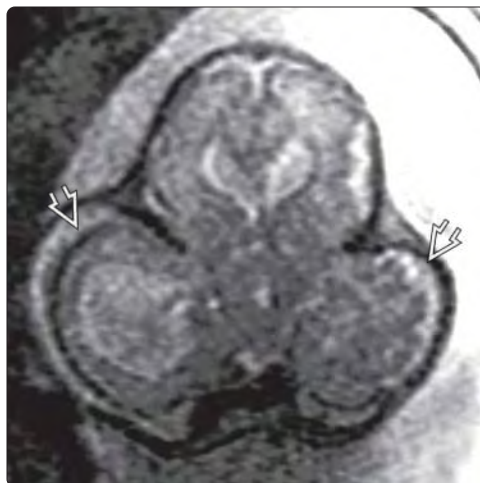(Left) 3D bone reconstruction, posterolateral view, shows the abnormal head shape with "towering" skull, frontal bossing, and protruding temporal fossae. Multiple holes are foci of thinned calvarium. (Right) Radiograph of the foot of an infant with Pfeiffer syndrome shows preaxial polydactyly of the great toe, which is the etiology of the broad appearance. Duplication of the 1st metatarsal is also noted. The distal phalanges are very hypoplastic.

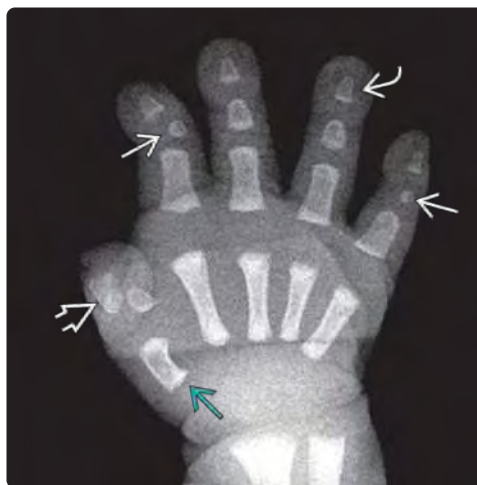
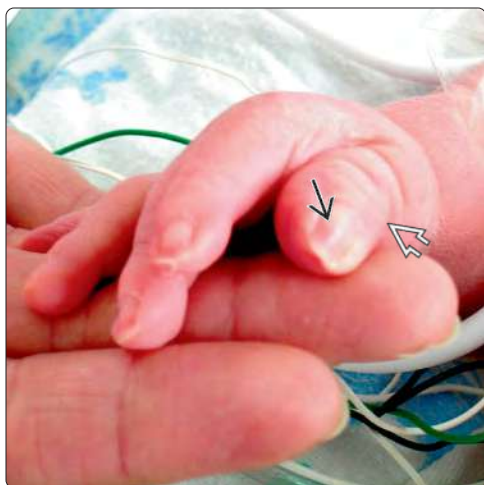

(Left) Clinical photograph of the foot of a newborn with Pfeiffer syndrome illustrates typical features of the syndrome. Note the broad, medially deviated great toe, stacked toes, partial syndactyly of the 3rd and 4th toes, and abnormal nails. (Right) Clinical photograph of the plantar surface of the same infant's foot shows the broad great toe, 3-4 soft tissue syndactyly, and abnormal crease pattern.

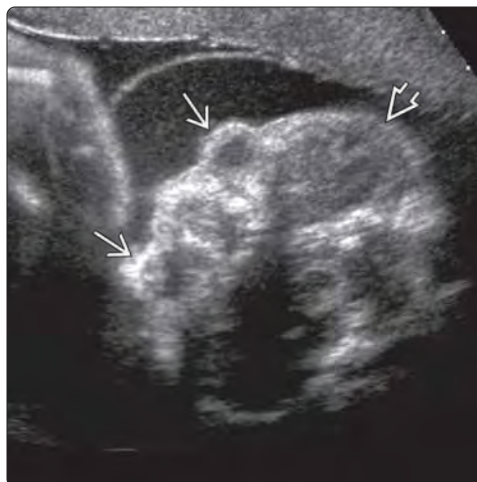
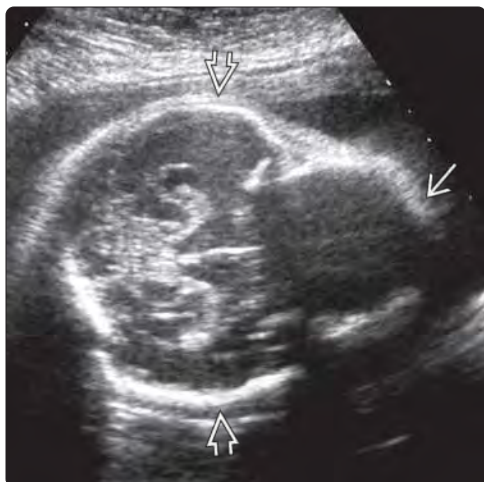


(Left) Coronal T2WI fetal MR shows a kleeblattschädel skull abnormality in a fetus with severe Pfeiffer syndrome. The shape is due to complex craniosynostosis. (Right) Postnatal MR in a different but similar case of Pfeiffer syndrome shows distortion of the intracranial contents with wedges of bone from craniosynostosis causing bulging of the middle cranial fossa.

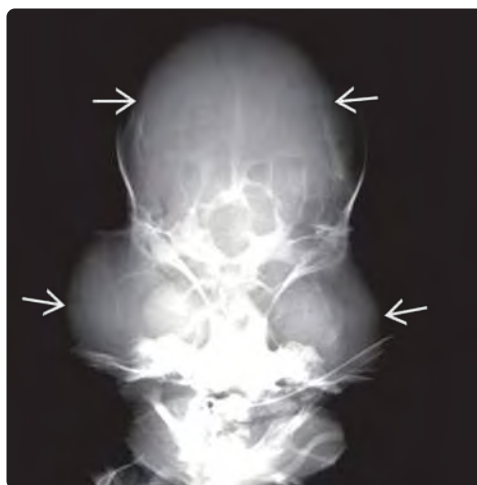
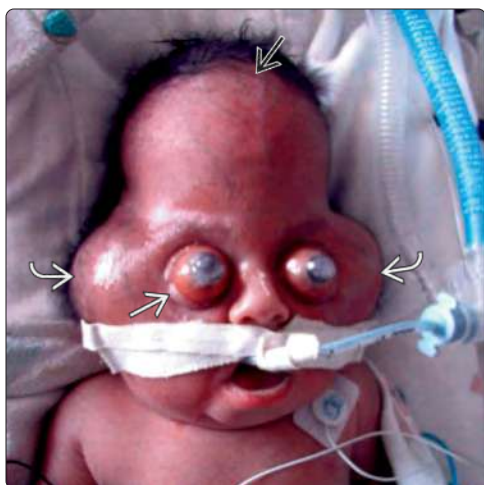


(Left) Clinical photograph shows the hand of a newborn infant with Pfeiffer syndrome. Note the broad, medially deviated thumb, a common feature of Pfeiffer syndrome. The nails are hyperconvex. **(Right)** Radiograph of the same hand shows preaxial polydactyly of the thumb, resulting in the broad appearance of the digit. Note also the hypoplastic middle and distal phalangeal segments. The 1st metacarpal is also hypoplastic. These are typical radiographic features of the hand in Pfeiffer syndrome.



(Left) Oblique axial ultrasound of a 3rd-trimester fetus with Pfeiffer syndrome shows a typical "cloverleaf" or kleeblattschädel skull due to complex craniosynostosis of multiple sutures. Note the very prominent anterior skull, corresponding to the commonly seen frontal bossing, and the prominence of the temporal skull. **(Right)** A scan through skull base shows the bulging of the middle cranial fossa and very shallow orbits causing proptosis of the eyes, which is often severe.



(Left) Clinical photograph of a newborn infant with severe type II Pfeiffer syndrome shows a very abnormal skull shape consistent with a kleeblattschädel skull. Note the "towering" of the skull with marked temporal prominence. There is severe exophthalmos with eversion of the eyelids. **(Right)** AP radiograph of the same infant shows the appearance typical of a kleeblattschädel skull.

Pierre Robin Sequence

KEY FACTS

TERMINOLOGY

- Mandibular hypoplasia with cleft palate and glossoptosis

IMAGING

- Severe micrognathia on midsagittal view in midtrimester
 - 1st-trimester diagnosis has been reported
- Specifically target palate to look for cleft when micrognathia is seen
 - Classic U shape seen on postnatal evaluation
- Polyhydramnios common in 3rd trimester

TOP DIFFERENTIAL DIAGNOSES

- Cleft palate, isolated
- Micrognathia, isolated
- Aneuploidy

PATHOLOGY

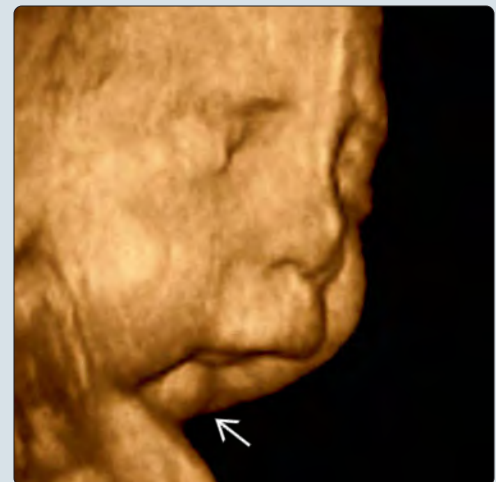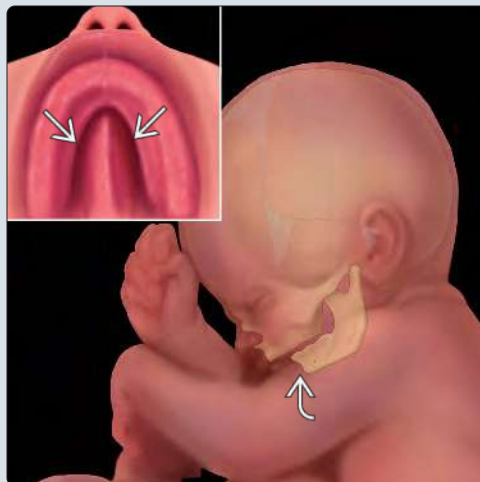- ~ 65% of cases with other anomalies

- Genetic syndromes with Pierre Robin (Pierre Robin sequence + additional findings)
 - Stickler syndrome
 - Treacher Collins syndrome
 - Goldenhar syndrome
 - Hemifacial microsomia
 - Seckel syndrome
 - Pena-Shokeir syndrome
 - 22q11 deletion syndrome (DiGeorge syndrome)
 - Diastrophic dysplasia

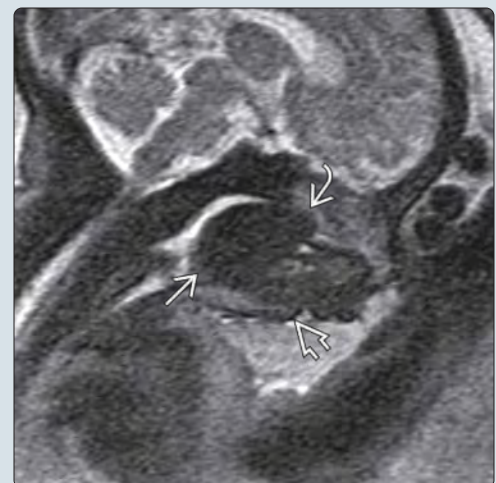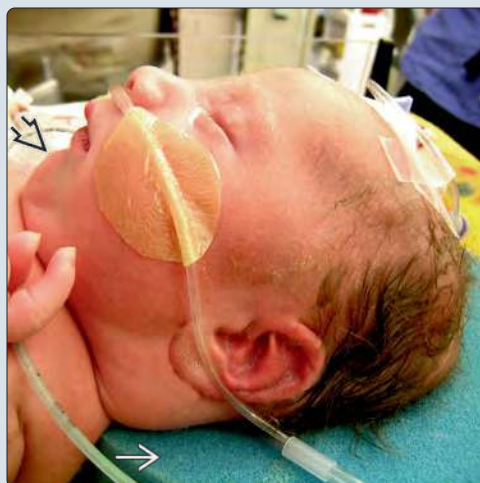CLINICAL ISSUES

- Airway obstruction due to glossoptosis may be life threatening
 - Airway protection critical in infants
- Up to 30% mortality with severe defects
- Mandibular growth often improves over time
 - Airway obstruction may lessen with development of mandible

(Left) Graphic shows the typical U-shaped palatal defect seen in Pierre Robin. Micrognathia is also a prominent feature of this condition. The position of the tongue within the small mandible prevents normal movement of the palatal shelves during embryogenesis, resulting in the cleft. (Right) 3D ultrasound shows the face of a fetus with severe micrognathia. Postnatally the infant was found to have a U-shaped cleft palate typical of Pierre Robin sequence.



(Left) Clinical photograph shows a newborn with severe micrognathia and a cleft palate typical of Pierre Robin. Note the foam pad under the neck for airway stabilization. Airway compromise due to an obstructing tongue is a concern in infants with this degree of micrognathia. (Right) Sagittal T2WI MR shows a fetus with Pierre Robin sequence. Note severe micrognathia and glossoptosis. The tongue can be seen protruding through the palatal defect.



TERMINOLOGY

Synonyms

- Robin sequence
- Pierre Robin syndrome

Definitions

- Mandibular hypoplasia with cleft palate and glossoptosis (downward displacement of the tongue), potentially leading to life-threatening airway obstruction

IMAGING

General Features

- Best diagnostic clue
 - Severe micrognathia on midsagittal view in midtrimester
 - 1st-trimester diagnosis has been reported
 - Cleft palate may be difficult to diagnose prenatally
 - Classic U shape seen on postnatal evaluation
 - Polyhydramnios common in 3rd trimester
 - Predicts increased potential for neonatal airway obstruction

Imaging Recommendations

- Protocol advice
 - Careful evaluation of fetal anatomy given significant association of other anomalies with micrognathia
 - Specifically target palate
 - Fetal karyotype when other anomalies present
 - Perform 3D ultrasound to enhance craniofacial evaluation
 - MR may be helpful in evaluating profile/palate
 - Tongue may protrude through palatal defect

DIFFERENTIAL DIAGNOSIS

Cleft Palate (Isolated)

- V-shaped defect as opposed to characteristic U shape seen in Pierre Robin sequence

Micrognathia (Isolated)

- Palate intact

Aneuploidy

- Trisomy 18, triploidy

PATHOLOGY

General Features

- Etiology
 - Unknown, but likely causally heterogeneous
 - Hypoplasia of mandible prior to 9-weeks gestation with posterior displacement of tongue
 - Prevents tongue from moving out of plane of palatine shelf closure, resulting in palatal defect
- Genetics
 - Usually sporadic, occasional familial cases
 - Some cases may be due to misexpression of *SOX9* due to disruption of regulatory elements
 - ~ 65% of cases with other anomalies
 - In syndromic cases, inheritance dependent upon underlying diagnosis

- **Genetic syndromes with Pierre Robin** (Pierre Robin sequence + additional findings)
 - **Stickler syndrome**
 - Severe myopia with retinal detachment, cataracts
 - Spondyloepiphyseal dysplasia, progressive arthropathy
 - **Treacher Collins syndrome**
 - Malar hypoplasia, microtia
 - **Goldenhar syndrome**
 - Microtia, macrostomia, cardiac anomalies, hemivertebrae
 - **Hemifacial microsomia**
 - Lower 1/2 of 1 side of face is underdeveloped, microtia
 - **Seckel syndrome**
 - Microcephaly (severe), abnormal profile with prominent nose
 - **Pena-Shokeir syndrome**
 - Multiple joint contractures
 - **22q11 deletion syndrome (DiGeorge syndrome)**
 - Cardiac anomalies, characteristic dysmorphic facies
 - **Diastrophic dysplasia**
 - Short limbs, clubfeet, hitchhiker thumbs

CLINICAL ISSUES

Presentation

- Most common signs/symptoms
 - Micrognathia most obvious finding
 - Can be seen as isolated finding or as manifestation of many different syndromes
- Postnatal
 - Mandibular hypoplasia with resultant micrognathia, often severe
 - Airway obstruction due to glossoptosis
 - May be life threatening
 - Feeding difficulties
 - U-shaped cleft palate on physical exam

Natural History & Prognosis

- Mandibular growth often improves over time
- Airway obstruction may lessen with development of mandible
- Up to 30% mortality with severe defects
- Feeding difficulties, hearing loss, sleep apnea

Treatment

- Airway protection critical in infants
 - Delivery in tertiary care center
 - Lip, tongue adhesion as temporizing procedure to protect airway
 - Intubation, tracheostomy for severe airway obstruction
- Surgical repair of cleft palate
- Distraction procedures to lengthen mandible

SELECTED REFERENCES

1. Gomez-Ospina N et al: Clinical, cytogenetic, and molecular outcomes in a series of 66 patients with Pierre Robin sequence and literature review: 22q11.2 deletion is less common than other chromosomal anomalies. *Am J Med Genet A.* 170(4):870-80, 2016
2. Kaufman MG et al: Prenatal identification of Pierre Robin sequence: a review of the literature and look towards the future. *Fetal Diagn Ther.* 39(2):81-9, 2015

KEY FACTS

TERMINOLOGY

- Rare, usually lethal malformation characterized by varying degrees of lower extremity fusion and other skeletal, gastrointestinal, and genitourinary abnormalities

IMAGING

- Single or fused lower extremities
- Absence of normally tapered lumbosacral spine with truncation of thorax
- Midtrimester anhydramnios due to severe renal anomaly
 - Bilateral renal agenesis most common
 - Bilateral cystic dysplastic kidneys may also be seen
- Single umbilical artery
- Color Doppler ultrasound for abdominal vessels
 - Demonstration of absence of renal arteries
 - Frequently lacks normal bifurcation of aorta into iliac arteries
- MR very useful for confirming renal agenesis
 - Better anatomic evaluation in setting of oligohydramnios

TOP DIFFERENTIAL DIAGNOSES

- Caudal regression/dysgenesis syndrome
- VACTERL association
- Arthrogryposis with fixed lower limb posture

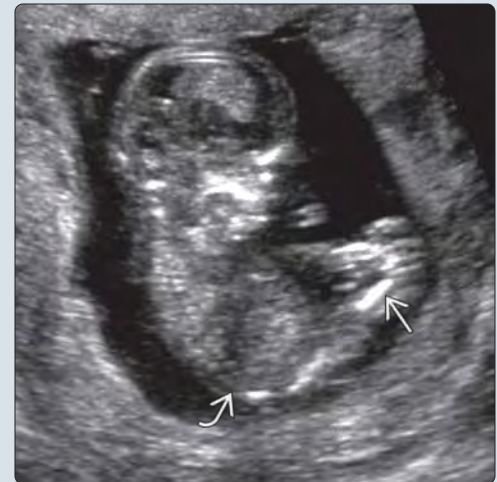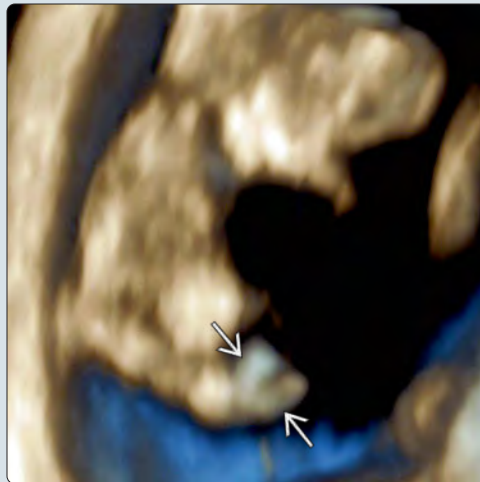
PATHOLOGY

- Several theories of pathogenesis; abnormal blastogenesis is predominant theory
 - Very early defect due to disruption of caudal mesoderm occurring during gastrulation (3rd gestational week)
- Usually sporadic with no increased recurrence risk

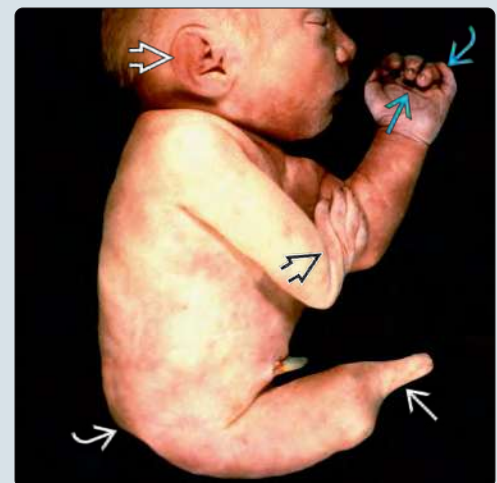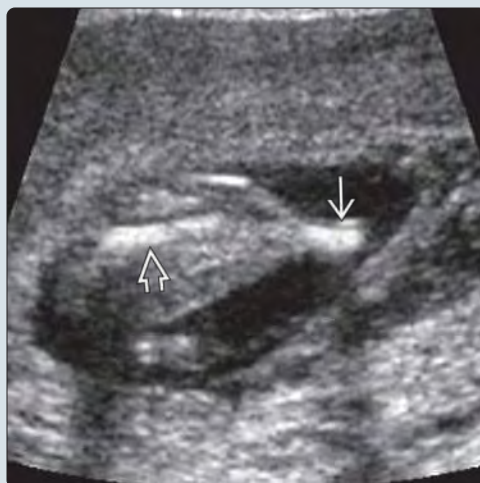CLINICAL ISSUES

- Because of anhydramnios, at least 50% of diagnoses missed prenatally
- Found in higher frequency in monozygotic twins
- Majority of cases lethal due to pulmonary hypoplasia
- In rare survivors, obstruction of genitourinary and gastrointestinal systems may be life limiting

(Left) 3D ultrasound at 11 weeks shows fused lower extremities in twin B of a dichorionic twin pregnancy. **(Right)** Sagittal ultrasound of the same fetus at 13 weeks shows a significantly truncated thoracic/lumbar spine and fused lower extremities, confirming the suspected diagnosis of sirenomelia. Selective reduction was performed on the abnormal twin.



(Left) Ultrasound of the lower extremities shows a single abnormal extremity with a single femur and a single distal long bone with a thin covering of skin and no surrounding musculature. **(Right)** Clinical photograph in the same case shows classic features of sirenomelia. The single fused lower extremity is evident, as well as a unilateral radial ray defect. The spine is truncated. The ears are large with unfurled helices. A single palmar crease and clinodactyly are also seen.



TERMINOLOGY**Synonyms**

- Sirenomelia sequence
- Symelia apus (absent feet)/dipus (rudimentary feet)
- Mermaid syndrome, originally described in 1542
- Note: Online Mendelian Inheritance in Man (OMIM) includes sirenomelia with caudal dysgenesis/regression, sacral agenesis, and sacral defect with anterior meningocele under single entry #600145

Definitions

- Rare, usually lethal malformation characterized by varying degrees of lower extremity fusion and other skeletal, gastrointestinal, and genitourinary abnormalities

IMAGING**General Features**

- Best diagnostic clue
 - Single/ fused lower extremity with shortened spine and renal agenesis

Ultrasonographic Findings

- Midtrimester anhydramnios due to bilateral renal agenesis
 - Bilateral cystic dysplastic kidneys may also be seen
- Single or fused lower extremities
 - Elucidation of extremity abnormality often very difficult due to lack of amniotic fluid
 - Single femur or single bone in distal lower extremities suggests diagnosis
- Absence of normally tapered lumbosacral spine
 - Lumbosacral or sacral agenesis common
- Single umbilical artery
- 3rd-trimester and late 2nd-trimester diagnoses usually hampered by lack of amniotic fluid required for adequate visualization
 - At least 50% of diagnoses missed prenatally
 - Diagnosis often made at delivery or at autopsy

MR Findings

- Very useful for confirming renal agenesis
- Better anatomic evaluation in setting of oligohydramnios

Imaging Recommendations

- Protocol advice
 - Endovaginal ultrasound particularly useful in 1st trimester
 - Several confirmed cases diagnoses as early as 10-11 weeks gestation
 - Color Doppler
 - Look for renal arteries
 - Look for branching of aorta
 - Frequently lacks normal bifurcation of aorta into iliac arteries
 - 3D ultrasound has been used in 1st and early 2nd-trimester diagnoses
 - Dependent on adequate amniotic fluid for visualization
 - Consider 3rd-trimester fetal MR to confirm renal agenesis

DIFFERENTIAL DIAGNOSIS**Caudal Regression (or Dysgenesis) Syndrome**

- Lower extremities in crossed-legged Buddha or tailor's posture
- Fluid usually normal or increased
- Kidneys present
- More common in diabetic mothers

VACTERL Association

- Nonrandom association of multiple anomalies, including vertebral anomalies, cardiac malformation, renal anomalies, limb defects (radial ray), and tracheoesophageal fistula ± esophageal atresia
- Several overlapping features
- Limb defects are more typically seen in upper rather than lower extremities

Arthrogryposis

- Limb malposition may mimic limb fusion
- Decreased fetal movement of joints is hallmark of condition
- Polyhydramnios more common than decreased fluid

Splenogonadal Fusion Limb Defect Syndrome

- Very rare
- Varying degrees of limb reduction/fusion
- Single umbilical artery

Other Lower Extremity Malformations

- Femoral hypoplasia
- Tibial hemimelia
- Fibular hemimelia
- Proximal femoral focal deficiency
- Limb reduction defects
- Split hand/foot malformation

Bilateral Renal Anomalies

- Renal agenesis
- Multicystic dysplastic kidneys
- Extremities are normal but evaluation is often difficult due to oligohydramnios

PATHOLOGY**General Features**

- Etiology
 - Several theories of pathogenesis
 - **Abnormality of blastogenesis**
 - Predominant theory
 - Very early defect due to disruption of caudal mesoderm occurring during gastrulation (3rd gestational week)
 - Interference with formation of notochord may disrupt further development of caudal structures
 - **Vascular steal theory**
 - Originally proposed by R. Stevenson et al. in 1986
 - Alteration in early vascular development, with abnormal persistence of vitelline artery
 - Vessel arises from aorta below diaphragm; no tributaries off aorta below this vessel

- Resulting blood flow is diverted via this vitelline artery steal to placenta, with subsequent hypoplasia of caudal embryonic structures
- Presence or absence of kidneys predicted by whether vessel is above or below location of renal arteries
- Limitations: Theory does not adequately explain other midline, noncaudal anomalies (e.g., radial ray defects, neural tube defect)
- Not all sirenomelics have pathologically demonstrable steal vessel
- Similar vessel has been described in case of normal fetus
- **Sirenomelia as severe form of caudal regression/dysgenesis**
 - Recent evidence suggests that these entities are likely part of a spectrum
 - Spine defect often similar with lumbosacral, sacral agenesis
 - Fusion of extremities, single umbilical artery uncommon in caudal dysgenesis
 - Association of diabetes much less common in sirenomelia
- **Teratogen**
 - Diabetes is minor risk factor
 - However sirenomelia is rare even in diabetics
- Genetics
 - Sporadic
 - No increased recurrence risk
- Associated abnormalities
 - Bilateral renal abnormalities
 - Renal agenesis
 - Multicystic dysplastic kidneys may be seen, but rare
 - Other defects of midline development
 - Neural tube defects
 - Lumbosacral dysgenesis/agenesis
 - Sacral agenesis
 - Genital ambiguity/absence of external genitalia
 - Müllerian anomalies
 - Anorectal atresia
 - Cloacal abnormalities
 - Single umbilical artery virtually always present
 - Vestigial tail
 - Skeletal
 - Varying degrees of limb reduction, soft tissue fusion of lower extremities, single lower extremity
 - Hypoplasia/aplasia of pelvic girdle
 - Complex fusion of feet (sympodia)
 - Absent feet
 - Radial ray abnormalities
 - Phocomelia
 - Rotational abnormalities of lower limbs
 - Hip dislocation
 - Less common: Cardiac, central nervous system anomalies

Gross Pathologic & Surgical Features

- In some cases, single large vessel arising from distal aorta can be demonstrated
 - No aortic bifurcation seen in these cases
- Varied renal anomalies, from complete absence of kidneys to multicystic dysplastic kidneys, secondary to obstruction

- Absence of bladder, ureters
- Cloacal malformations
- Abnormal spine

CLINICAL ISSUES

Presentation

- Most common signs/symptoms
 - Fused lower extremities
 - Severe oligohydramnios
 - Renal agenesis, bilateral
 - Respiratory compromise due to pulmonary hypoplasia

Demographics

- Gender
 - Preponderance of males
 - M:F = 2.7:1
- Epidemiology
 - 1/60,000-1/90,000 births
 - Found in higher frequency in monozygotic twins
 - Majority are discordant

Natural History & Prognosis

- Majority of cases lethal, either prenatally or shortly after birth
- If liveborn, death from pulmonary hypoplasia within few hours
- In rare survivors, obstruction of genitourinary and gastrointestinal systems may be life limiting

Treatment

- No prenatal treatment available
- Termination of pregnancy should be offered when diagnosis is confirmed
- In continuing pregnancies
 - No monitoring or intervention in labor
 - Perinatal hospice for family support

DIAGNOSTIC CHECKLIST

Consider

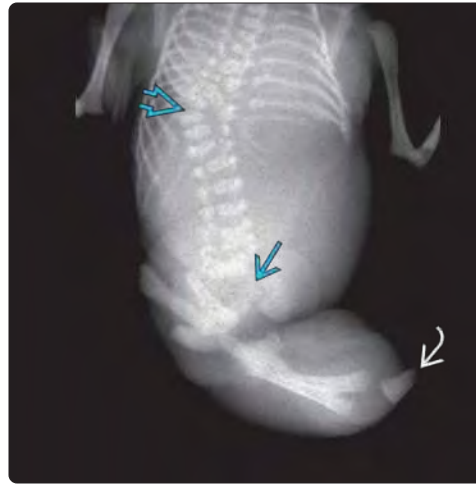
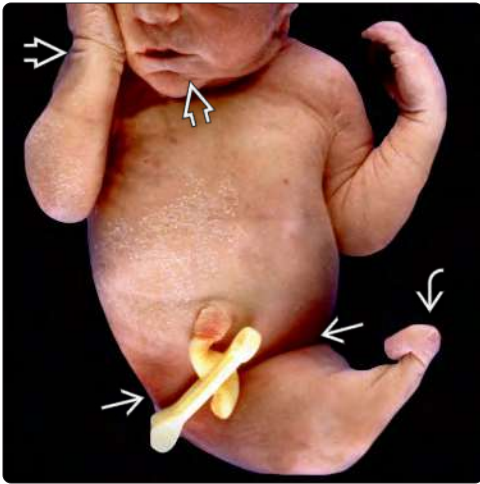- Fetal MR to evaluate lower extremities and renal agenesis
- 3D ultrasound may be helpful in 1st trimester (or later if sufficient amniotic fluid)

Image Interpretation Pearls

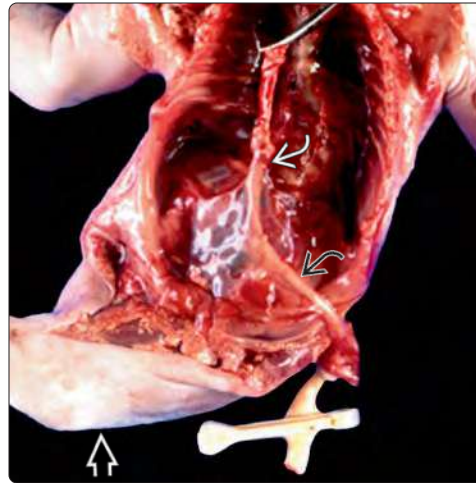
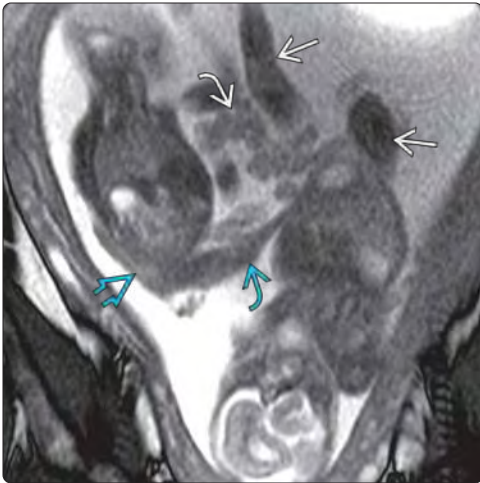
- Color Doppler ultrasound for abdominal vessels
 - Demonstration of absence of renal arteries
 - Confirmation of lack of branching of iliac arteries, frequently seen in sirenomelia (normal in renal agenesis without sirenomelia)

SELECTED REFERENCES

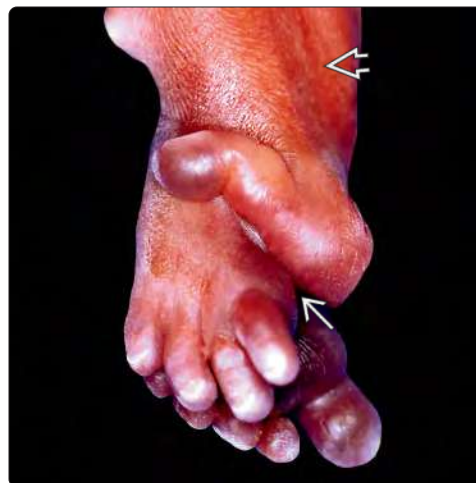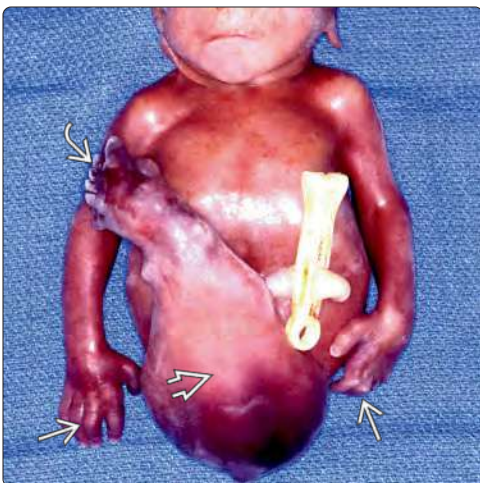1. López-Valdez JA et al: A fetus with hemifacial microsomia and sirenomelia. The same mesodermal defect spectrum? *Fetal Pediatr Pathol.* 32(2):152-7, 2013
2. Clemente CM et al: Sirenomelia with oligodactylia: early ultrasonographic and hysteroscopic embryoscopic diagnosis during the first trimester of gestation. *Fetal Diagn Ther.* 28(1):43-5, 2010
3. Thottungal AD et al: Caudal dysgenesis and sirenomelia-single centre experience suggests common pathogenic basis. *Am J Med Genet A.* 152A(10):2578-87, 2010



(Left) Clinical photograph of a stillborn infant with sirenomelia shows typical features including a narrow pelvis [A], fused single lower extremity, and abnormal rudimentary distal appendage [B]. Bilateral renal agenesis was also noted in this infant. The deep creases in the face and arms [C] are typical of Potter syndrome due to lack of amniotic fluid. (Right) Radiograph of the same stillborn shows an abnormal jumbled thoracic spine [D], a hypoplastic pelvis [E], fused lower extremities, and a single distal long bone [F].



(Left) MR of a monoamniotic twin gestation shows a fetus with sirenomelia on the maternal right with renal agenesis, abnormal pelvis [A], and a single rudimentary lower extremity [B]. Normal legs are seen in the co-twin [C]. Cord entanglement is also noted [D] in this monoamniotic gestation. (Right) Autopsy shows a vitelline artery steal vessel [E] arising from the aorta [F] in a stillborn with sirenomelia [G] (shows fused extremities). No renal or iliac arteries are identified. This is seen in many, but not all, cases of sirenomelia.



(Left) In this preterm stillborn with sirenomelia, extensive soft tissue fusion [A] of the lower extremities is seen. The feet are strikingly abnormal and fused [B]. Camptodactyly [C] of the digits is also noted. There was a vestigial tail and no external genitalia. (Right) Close-up clinical photograph of the same fetus shows syndactyly (complex fusion of the feet). Note the deep cleft between the 1st and 2nd toes on 1 foot [D]. The soft tissue fusion can be seen [E].

KEY FACTS

TERMINOLOGY

- Disorder of cholesterol biosynthesis characterized by fetal growth restriction (FGR), multiple congenital anomalies, and developmental delay

IMAGING

- Best diagnostic clue: Combination of early onset severe FGR, cardiac defects, polydactyly, genital ambiguity on midtrimester ultrasound
- 3D ultrasound helpful in delineating facial, limb anomalies
- 1st-trimester diagnosis possible, especially in high-risk families

TOP DIFFERENTIAL DIAGNOSES

- Aneuploidy
 - Trisomy 13
 - Trisomy 18
 - Triploidy

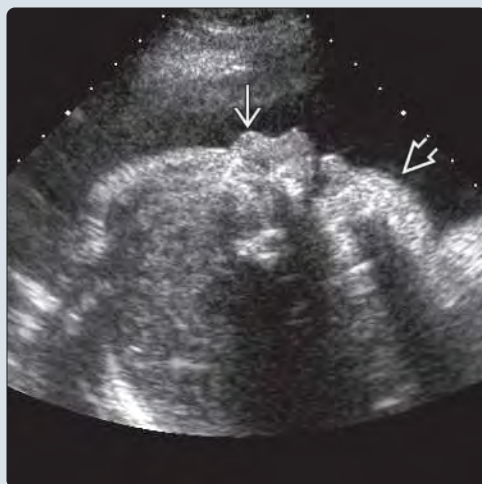
PATHOLOGY

- Mutations in the 3 beta-hydroxysterol delta (7)-reductase gene (*DHCR7*), which catalyzes terminal step in cholesterol biosynthesis
- Autosomal recessive

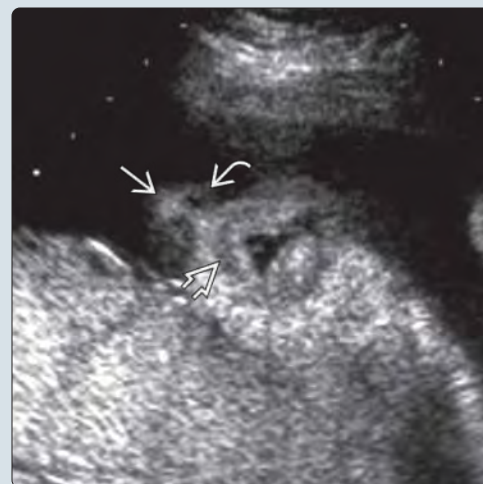
CLINICAL ISSUES

- Severe perinatal presentation is usually lethal
- Survivors with moderate to profound intellectual impairment, multiple medical problems
- Characteristic behavioral phenotype with autism, self injury, food aversions, extreme tactile sensitivity, abnormal sleep patterns, unusual upper body arching, irritability
- Low to undetectable levels of unconjugated estriol (MSuE₃) on maternal serum screen should prompt careful sonographic evaluation for characteristic anomalies
- Prenatal diagnosis possible by sterol analysis of amniotic fluid or molecular analysis by CVS or amniocentesis when specific mutation(s) known

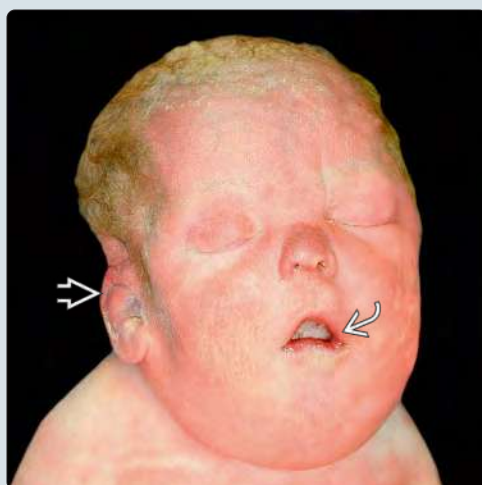
(Left) Sagittal ultrasound shows an abnormal profile with short upturned nose and severe micrognathia in a fetus with Smith-Lemli-Opitz syndrome (SLOS). This fetus also had severe early-onset growth restriction, another common feature of SLOS.



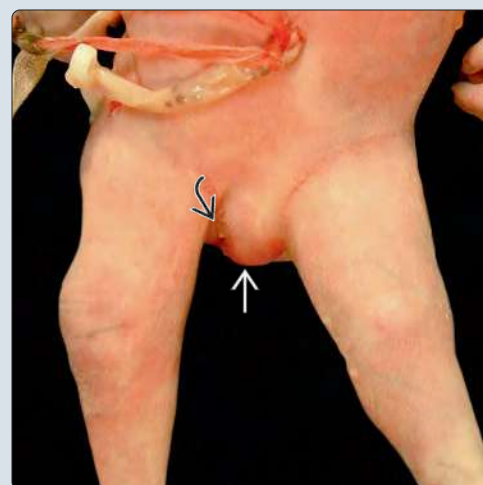
(Right) Ultrasound of the face shows hypoplastic alae nasi and anteverted nares in a fetus with SLOS at 30 weeks. The tented upper lip and gaping mouth associated with the very small jaw are also seen.



(Left) Clinical photograph shows an infant with severe SLOS. Note the short upturned nose with anteverted nares, short neck, low-set ears, and small open mouth.



(Right) Clinical photograph shows ambiguous genitalia in a stillborn male infant with severe SLOS. A microphallus can be seen. Sex reversal in males and genital ambiguity are features of SLOS. (Courtesy A. Putnam, MD and J. Szakacs, MD.)



TERMINOLOGY**Abbreviations**

- Smith-Lemli-Opitz syndrome (SLOS)

Synonyms

- RSH syndrome (initials of 1st 3 patients described by Opitz et al)
- SLOS/RSH syndrome

Definitions

- Disorder of cholesterol biosynthesis characterized by fetal growth restriction (FGR), multiple congenital anomalies, and developmental delay
 - SLOS I and II in older literature: Part of phenotypic spectrum of same disorder

IMAGING**General Features**

- Best diagnostic clue
 - Combination of early onset severe FGR, cardiac defects, polydactyly, genital ambiguity on midtrimester ultrasound

Ultrasonographic Findings

- Increased nuchal translucency common on 1st-trimester ultrasound
- Central nervous system (CNS)
 - Microcephaly
 - Holoprosencephaly
 - Ventriculomegaly
 - Cerebellar hypoplasia
 - Agenesis of corpus callosum
- Cardiac
 - Atrioventricular (AV) canal
- Genitourinary
 - Ambiguous genitalia
 - Cystic renal disease
- Postaxial polydactyly; "Y" syndactyly of toes
- Craniofacial
 - Hypertelorism
 - Short upturned nose, anteverted nares
 - Cleft palate
 - Micrognathia, small mouth
- Hydrops

Imaging Recommendations

- Best imaging tool
 - 3D ultrasound helpful in delineating facial, limb anomalies
 - 1st-trimester diagnosis possible, especially in high-risk families

DIFFERENTIAL DIAGNOSIS**Aneuploidy**

- Trisomy 13
 - Holoprosencephaly
 - Cardiac anomalies
 - Omphalocele
 - Cleft lip/palate

- Postaxial polydactyly
- Cryptorchidism
- Trisomy 18
 - FGR
 - Cardiac anomalies
 - Overlapping digits, rocker-bottom feet
 - Radial ray defects
 - Cleft lip, palate
- Triploidy
 - FGR
 - 2-3 toe/3-4 finger syndactyly
 - Genitourinary tract anomalies
 - Variable CNS anomalies
- Deletion 10q
 - Severe hypogonadism

Hydrolethalus

- Hydrocephalus
- Cardiac anomalies
- Cleft lip/palate
- Polydactyly
- Cryptorchidism
- Short limbs

Pseudotrismy 13

- Holoprosencephaly
- Postaxial polydactyly
- Ambiguous genitalia
- Normal karyotype

PATHOLOGY**General Features**

- Etiology
 - Disorder of cholesterol biosynthesis
 - Mutations in 3 beta-hydroxysterol delta (7)-reductase gene (*DHCR7*), which catalyzes terminal step in cholesterol biosynthesis, reduction of 7-dehydrocholesterol (7DHC) to cholesterol
 - Clinical diagnosis of SLOS is confirmed biochemically by elevated serum and tissue levels of 7DHC
 - ◻ Cholesterol usually low, but may be within normal range in 10% of affected individuals
 - Sterols are critical components in myelin, other central nervous system proteins, membranes
 - ◻ Altered sterol profile associated with abnormal intellectual, motor function
 - Sonic hedgehog and patched (embryonic signaling proteins) both rely on cholesterol for proper function
 - ◻ Abnormalities associated with holoprosencephaly
 - Decrease in testosterone and estrogen production result in hypogonadism in males
 - ◻ Low maternal serum unconjugated estriol (MSuE₃) in affected pregnancies
 - Carrier status may be determined by mutation analysis
 - Prediction of carrier status not possible by analysis of cholesterol and 7DHC due to wide range of normal levels
- Genetics
 - Autosomal recessive

- Sequence analysis of DHCR7 detects ~ 96% of known mutations

Microscopic Features

- Giant cells in pancreatic islets
- Thymic hypoplasia

CLINICAL ISSUES

Presentation

- Most common signs/symptoms
 - **Craniofacial:** Microcephaly (90%), narrow bifrontal diameter, ptosis (60%), downslanting palpebral fissures, anteverted nares, cleft palate (37-52%), tongue cysts, low-set ears
 - **Genitourinary (90%):** Sex reversal in males or genital ambiguity, micropenis, hypospadias, renal agenesis, cystic renal dysplasia, hydronephrosis
 - **Growth:** Pre- and postnatal growth restriction
 - **Extremities:** Postaxial polydactyly (50%), 2-3 "Y" syndactyly of toes (95%), high frequency of whorl dermal ridge pattern
 - **Cardiac (38%):** Atrioventricular (AV) canal defect, anomalous pulmonary venous return
- Other signs/symptoms
 - Moderate to profound intellectual impairment
 - Characteristic behavioral phenotype with autistic behaviors, self injury, food aversions, extreme tactile sensitivity, abnormal sleep patterns, unusual upper body arching, irritability, often extreme
 - Adrenal dysfunction, Hirschsprung disease, anorectal atresia

Demographics

- Gender
 - Excess of males
- Epidemiology
 - 1/20,000 births in North American Caucasians
 - Rare in individuals of African/Asian descent
 - More frequent in European Caucasians with carrier frequency as high as 1/30
 - Up to 7% of stillbirths may be due to SLOS/RSH
 - Common mutation found in about 60% of Caucasian cases (*1VS8-1G* → C)

Natural History & Prognosis

- Severe perinatal presentation is usually lethal
- Survivors with moderate to profound intellectual impairment, multiple medical problems, often severe behavioral problems
- Rare mild phenotype with delayed diagnosis, milder course
- Prenatal level of 7DHC correlates with clinical severity
- Postnatal clinical severity inversely correlated with level of plasma cholesterol or ratio of cholesterol to total sterols

Treatment

- Prenatal diagnosis possible
 - Sterol analysis of amniotic fluid in midtrimester (7DHC/total sterol ratio)
 - 7DHC content of tissue from chorionic villus sampling (CVS)
 - Molecular analysis by CVS, amniocentesis when specific mutation(s) known

- Preimplantation genetic diagnosis (PGD) possible when mutation(s) known
- Experimental analysis of sterols in maternal urine
- Genetic counseling with discussion of prenatal diagnosis options
- Offer pregnancy termination
- Case reports of prenatal treatment
 - Intravascular and intraperitoneal infusions of fresh frozen plasma
 - Resulted in improvement in fetal plasma cholesterol levels
 - Long-term outcome unchanged but demonstrated feasibility of intrauterine treatment
 - Other case of maternal dietary cholesterol supplementation less effective
 - Ingested cholesterol does not cross blood-brain barrier so is unlikely to affect fetal CNS development
- Postnatal dietary supplementation with cholesterol and bile acids
 - Variable results in developmental improvement
 - Some series suggest improvement in behavioral, feeding, and growth problems
 - Baseline cholesterol prior to treatment is better predictor of developmental potential
 - No prospective randomized controlled trials to date due to rarity of syndrome
 - Purported benefits based on small series and case reports
- Stress dose steroids for surgical procedures, severe illness
- Agents to avoid
 - Haloperidol therapy
 - Sun exposure

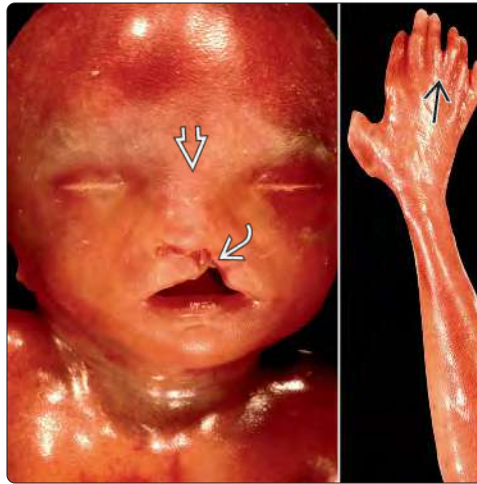
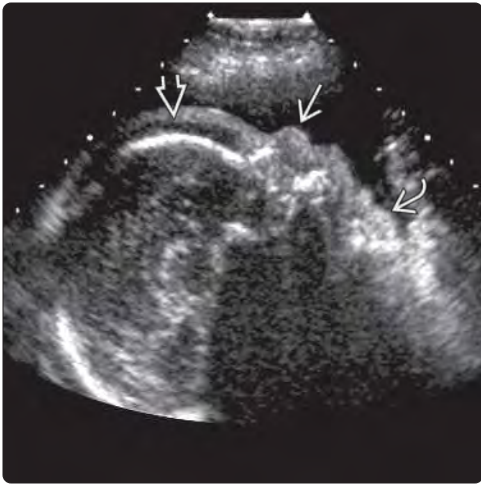
DIAGNOSTIC CHECKLIST







Image Interpretation Pearls

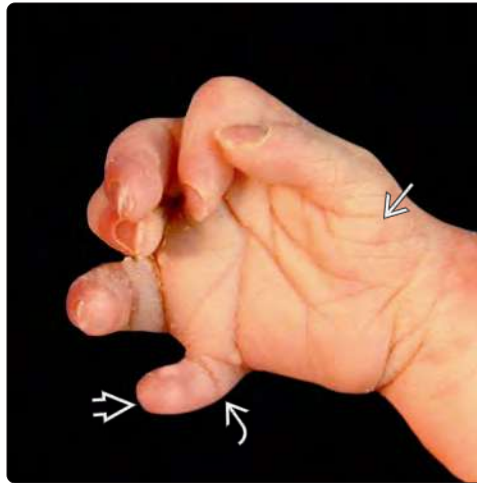
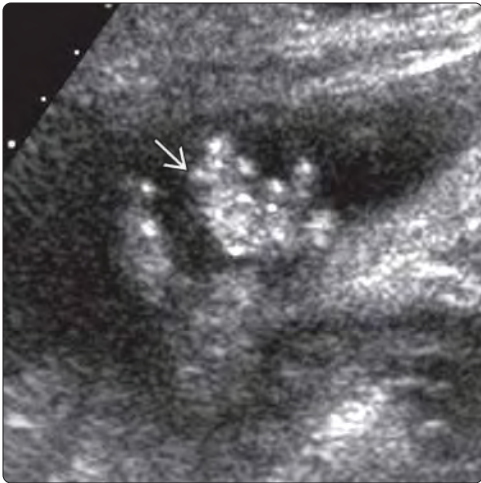- Low to undetectable levels of unconjugated estriol (MSuE_s) on maternal serum screen should prompt careful sonographic evaluation for characteristic anomalies
 - Diagnosis can be confirmed by amniocentesis or CVS





SELECTED REFERENCES

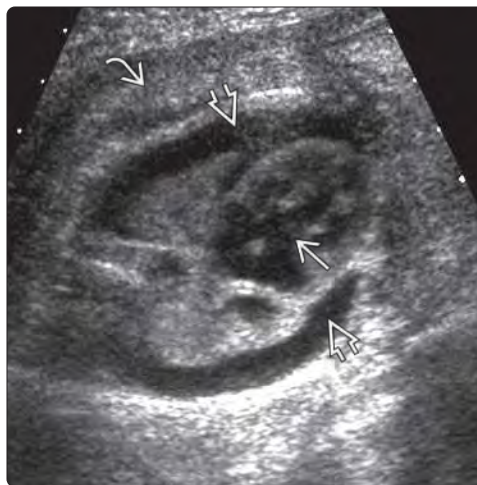
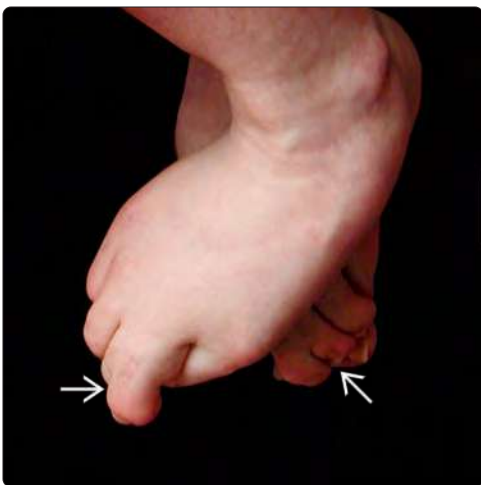1. Kanungo S et al: Sterol metabolism disorders and neurodevelopment—an update. *Dev Disabil Res Rev.* 17(3):197-210, 2013
2. Lee RW et al: Brain magnetic resonance imaging findings in Smith-Lemli-Opitz syndrome. *Am J Med Genet A.* 161A(10):2407-19, 2013
3. Diaz-Stransky A et al: Cognitive and behavioral aspects of Smith-Lemli-Opitz syndrome. *Am J Med Genet C Semin Med Genet.* 160C(4):295-300, 2012
4. Nowaczyk MJ et al: Smith-Lemli-Opitz syndrome: phenotype, natural history, and epidemiology. *Am J Med Genet C Semin Med Genet.* 160C(4):250-62, 2012
5. Opitz JM et al: The RSH/"Smith-Lemli-Opitz" syndrome: historical footnote. *Am J Med Genet C Semin Med Genet.* 160C(4):242-9, 2012
6. Orth M et al: Cholesterol: its regulation and role in central nervous system disorders. *Cholesterol.* 2012:292598, 2012
7. Svoboda MD et al: Treatment of Smith-Lemli-Opitz syndrome and other sterol disorders. *Am J Med Genet C Semin Med Genet.* 160C(4):285-94, 2012
8. Waterham HR et al: Mutational spectrum of Smith-Lemli-Opitz syndrome. *Am J Med Genet C Semin Med Genet.* 160C(4):263-84, 2012
9. Cohen MM Jr: Hedgehog signaling update. *Am J Med Genet A.* 152A(8):1875-914, 2010
10. Porter FD et al: Malformation syndromes caused by disorders of cholesterol synthesis. *J Lipid Res.* 52(1):6-34, 2010
11. Tint GS et al: Defective cholesterol biosynthesis associated with the Smith-Lemli-Opitz syndrome. *N Engl J Med.* 330(2):107-13, 1994







(Left) Sagittal ultrasound of a 3rd-trimester fetus with severe SLOS shows significant skin edema , short upturned nasal tip , and micrognathia . Significant microcephaly is also present. (Right) Gross images depict clinical manifestations of SLOS. Note the dysmorphic facial features (cleft lip and palate)  and broad nasal root . Complex syndactyly  and insertional polydactyly are also seen. (From DP: Kidney.)



(Left) Ultrasound shows postaxial polydactyly  in a 3rd-trimester fetus with SLOS. Note the unusual position of the fingers. This appeared to be a fixed posture during observation. (Right) Clinical photograph of the hand of the same infant with SLOS shows hexadactyly with postaxial polydactyly . Note the unusual finger posture seen on the prenatal ultrasound. Thenar hypoplasia  is also observed, as well as a single flexion crease in the 6th digit .



(Left) Clinical photograph shows typical 2-3 "Y" syndactyly of the toes in a young adult with SLOS . The foot posture is a withdrawal response to tactile stimulation, a common behavior in SLOS. (Right) Axial ultrasound of the chest of a fetus with severe SLOS shows bilateral, large pleural effusions  and significant skin thickening . An arteriovenous septal defect is also seen . The lungs were unilobate on postmortem.

Treacher Collins Syndrome

KEY FACTS

TERMINOLOGY

- Mandibulofacial dysostosis

IMAGING

- Findings on ultrasound
 - Abnormal profile with small chin
 - 3D best for facial features
 - Downward slope of eyelids
 - Small deficient ears
 - Shallow orbits
 - Protruding eyes or small/absent eyes
 - Polyhydramnios from poor swallowing
- MR best for cleft palate and auditory canal evaluation
 - Inner ear is usually normal
- Nonfacial anomalies are only occasionally present

PATHOLOGY

- Most often from autosomal-dominant disorder mapped to area on chromosome 5q termed treacle



- 60% de novo mutations vs. 40% familial

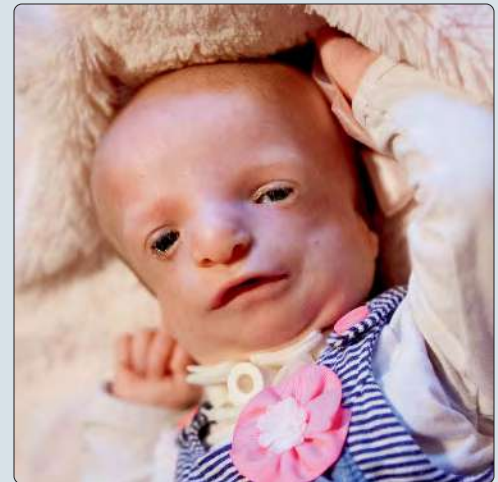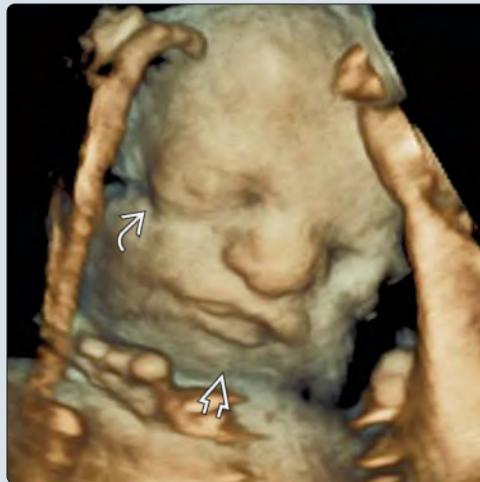CLINICAL ISSUES






- Characteristic features with variable expression
 - Mandible and zygomatic arch hypoplasia
 - Cleft palate
 - Conductive hearing loss
 - Downward slanting of palpebral fissures
 - Eyelid colobomas (lid notching)
- Normal intelligence without developmental delay or neurologic disease
- Treacher Collins syndrome children need multidisciplinary team for care
 - Early focus on airway management, feeding, growth

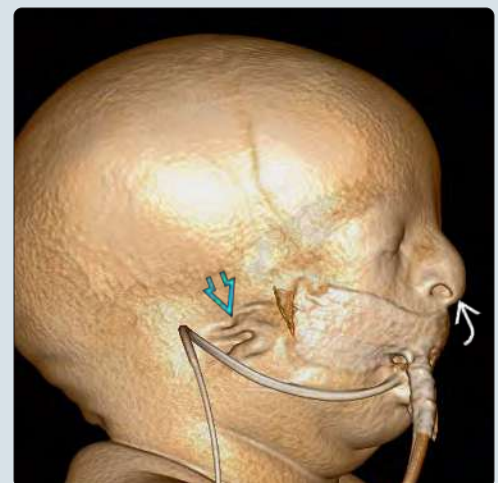
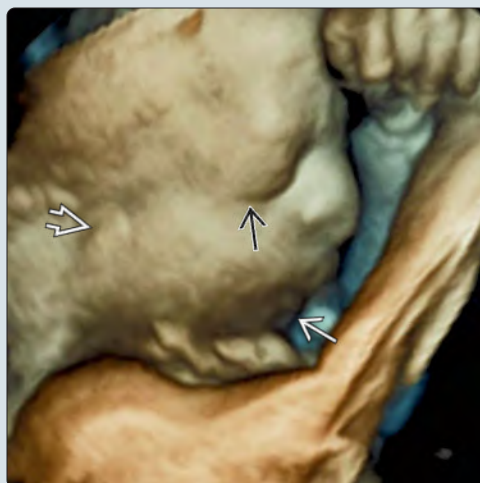
DIAGNOSTIC CHECKLIST

- Consider de novo diagnosis if orbit and ear anomalies are seen in fetus with small chin
- Refer family for genetic counseling

(Left) 3D surface-rendered ultrasound of a fetus with Treacher Collins syndrome (TCS) shows subtle downward slanting eyes , a small chin , and relative macrostomia (large mouth). (Right) Photograph of the same child after delivery shows classic TCS features of underdeveloped facial bones. This child is tracheostomy and G-tube dependent. It is important to understand and educate families that children with TCS are of normal intelligence. (Courtesy Redwine-Walter family.)



(Left) Profile view of a fetus with TCS shows a small chin , and markedly deficient ear . The downward slant of the eyelid  from malar hypoplasia is also appreciated on this view. (Right) Surface-rendered CT of the same child immediately after birth shows the malrotated, deficient, and low-lying external ear  diagnosed in utero. Notice that the nose looks beaked  on profile views. This finding is secondary to the otherwise deficient facial bones with relative sparing of the nose.



TERMINOLOGY

Abbreviations

- Treacher Collins syndrome (TCS)

Synonyms

- Franceschetti-Klein syndrome

Definitions

- Mandibulofacial dysostosis
- Characteristic facial features (variable expression)
 - Mandible and zygomatic arch hypoplasia
 - Abnormal shape, size, and position of auricles
 - Downward slanting of palpebral fissures
 - Eyelid colobomas (lid notching)

IMAGING

Ultrasonographic Findings

- Mandible and maxillary hypoplasia
 - Small chin
 - Relative protuberant nose
- Cleft palate often difficult to see with ultrasound
 - Use 3D multiplanar views
 - Look for fluid extending from oral into nasal cavity
- Abnormal ears (almost always bilateral)
 - Deficient malpositioned auricles
- Shallow orbits with occasional small or absent globes
- Typical facial features seen best with 3D
 - Downward slanting palpebral fissures
 - Protruding eyes
 - Lower lid coloboma
- Polyhydramnios from poor swallowing
- Nonfacial anomalies are only occasionally present

MR Findings

- Can show internal auditory canal findings
 - Middle ear may be deformed or deficient
 - Small tympanic cavity on T2 images
 - Inner ear is usually normal
- MR best to show palate defect
- Associated choanal atresia might be seen

DIFFERENTIAL DIAGNOSIS

Pierre Robin Anomaly

- Severe micrognathia
- Cleft palate (hard &/or soft)
- Isolated or syndromic

Goldenhar Syndrome (Hemifacial Microsomia)

- Oculoauriculovertebral spectrum
- Autosomal dominant or sporadic inheritance
- Only 1 ear is abnormal
- Asymmetric facial involvement
- More likely to have other anomalies
 - Cardiac, vertebral, central nervous system

PATHOLOGY

General Features

- Etiology

- Abnormal development of 1st and 2nd branchial arches
- Genetics
 - Most often from autosomal-dominant disorder mapped to area on chromosome 5q termed treacle
 - Heterozygous mutations on *TCOF1* gene on chromosome 5q32-q33.1
 - Gene rearrangements account for significant portion of TCS cases
 - 60% de novo mutations vs. 40% familial

CLINICAL ISSUES

Presentation

- Most common signs/symptoms
 - Typical facial features of TCS
 - Conductive hearing loss
 - Cleft palate
 - Impaired vision
 - 33% with vision loss
 - 37% with strabismus
 - Occasional microphthalmia or anophthalmia

Demographics

- Gender
 - Male = female
- Epidemiology
 - 1 in 50,000 live births

Natural History & Prognosis

- Normal intelligence without developmental delay or neurologic disease

Treatment

- Early focus on airway management, feeding and growth
- TCS children need multidisciplinary approach for treatment
 - Craniofacial team including plastic surgeon
 - Pediatric otolaryngologist and audiologist
 - Dental surgeon
 - Psychologist

DIAGNOSTIC CHECKLIST

Consider

- Consider de novo diagnosis if orbit and ear anomalies are seen in fetus with small chin
- Refer family for genetic counseling
 - Mildly affected parents may not have been diagnosed




Image Interpretation Pearls

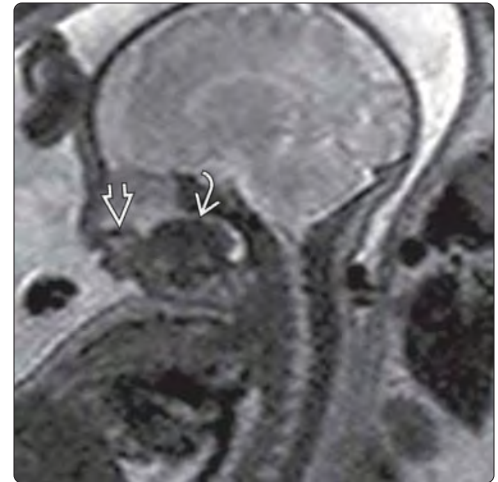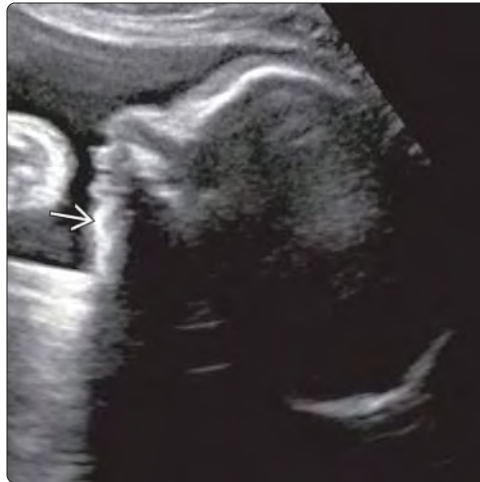- 3D ultrasound best to see subtle facial features
- Use MR to look at middle ear and inner ear anatomy




SELECTED REFERENCES

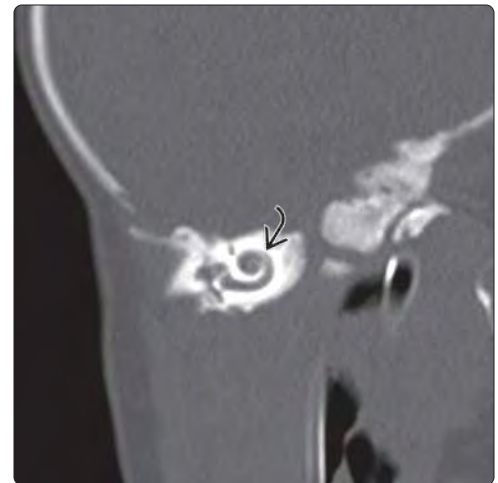
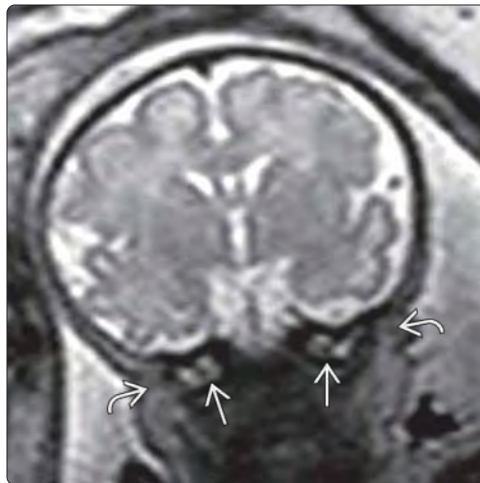
1. Kadakia S et al: Treacher Collins Syndrome: the genetics of a craniofacial disease. *Int J Pediatr Otorhinolaryngol.* 78(6):893-8, 2014
2. Renju R et al: Mandibulofacial dysostosis (Treacher Collins syndrome): A case report and review of literature. *Contemp Clin Dent.* 5(4):532-4, 2014
3. Konstantinidou AE et al: Mandibulofacial dysostosis (Treacher-Collins syndrome) in the fetus: novel association with Pectus carinatum in a molecularly confirmed case and review of the fetal phenotype. *Birth Defects Res A Clin Mol Teratol.* 97(12):774-80, 2013
4. Chang CC et al: Treacher collins syndrome. *Semin Plast Surg.* 26(2):83-90, 2012
5. Katorza E et al: Prenatal evaluation of the middle ear and diagnosis of middle ear hypoplasia using MRI. *Pediatr Radiol.* 41(5):652-7, 2011

Treacher Collins Syndrome

(Left) A small chin  is seen on a profile view of a fetus with de novo TCS (no family history). Hypognathia can be isolated or associated with additional facial and palate anomalies. Further imaging, including MR, is helpful. **(Right)** Fetal MR in the same patient shows a cleft palate (without cleft lip). The anterior hard palate is intact , and the tongue  is displaced superiorly through a large posterior palate defect. The presence of a cleft palate is common with TCS.

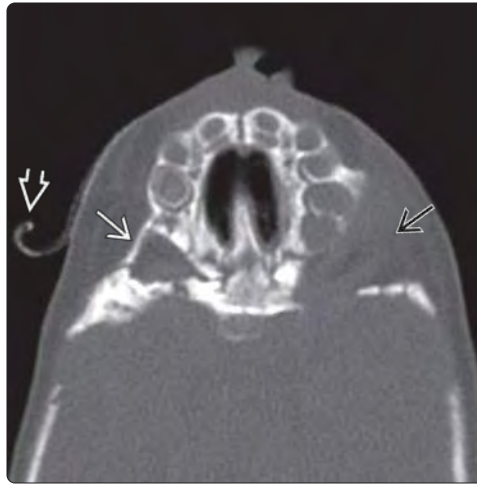
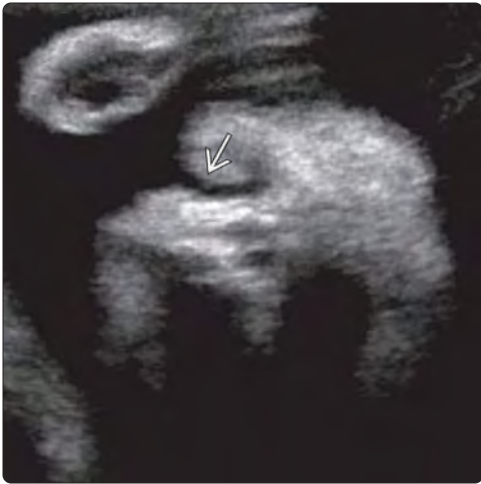




(Left) Coronal fetal MR of the brain and auditory canal of a fetus with TCS and deficient ears shows fluid in a relatively well-developed inner ear , although the external auditory canal is atretic  (no fluid extends from the inner ear to skin surface, where the auricles should be). **(Right)** Sagittal temporal bone CT of the same case after delivery confirms normal internal ear anatomy (cochlea ) but there was deficient middle ear and external auditory canal development. Children with TCS have conductive hearing loss.

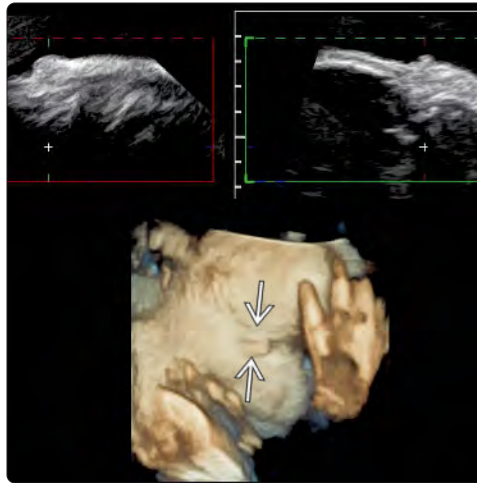
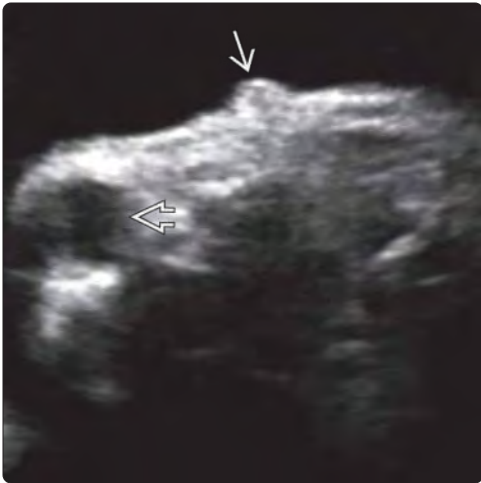




(Left) Clinical photograph of a child with TCS shows mild classic features. The diagnosis was suspected during fetal life because the father of the child has TCS. **(Right)** Photograph of the same child with her family exemplifies the autosomal dominant hereditary pattern with variable expression most commonly seen with hereditary TCS. Importantly, the photograph also shows the overall family well-being, which is typically experienced in families with TCS. (Courtesy Zingale family.)

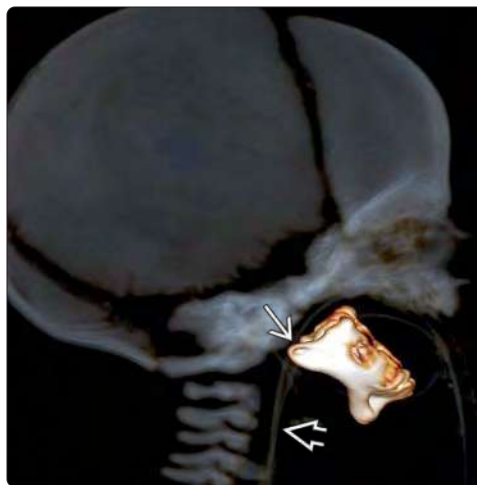
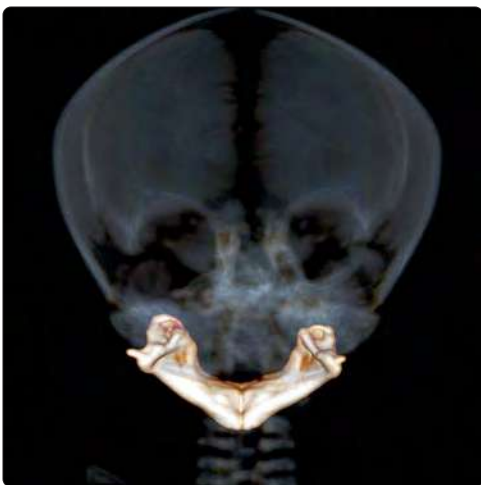




(Left) Grayscale face image shows the downward slanting of the eyelids  seen with TCS, exemplifying that the features described do not always require 3D ultrasound for diagnosis. (Right) Axial CT in the same child after delivery shows a hypoplastic zygomatic arch on the right  and absent zygomatic arch on the left . Malar hypoplasia is a hallmark finding with TCS. A portion of a malformed right ear  is also seen.



(Left) In this fetus with TCS, an axial view of the side of the head shows a minimal soft tissue protuberance  instead of a normal auricle of the ear ( points to an orbit, for orientation). (Right) 3D of the small abnormal ear was performed, and the surface-rendered image shows the small malformed ear  to better advantage. The 3D rendered images help with consultation for patients and maxillofacial providers, who often meet the family during the pregnancy.



(Left) 3D CT, with bone rendering of the mandible, was performed on this newborn with TCS to assess for feasibility and planning of mandibular distraction surgery. (Right) Sagittal view in the same patient shows the small mandible with bilateral hypoplastic rami . An endotracheal tube can be faintly seen . Affected infants often have both airway and feeding issues.

KEY FACTS

TERMINOLOGY

- Genetic tumor disorder with multiorgan hamartomas

IMAGING

- Cardiac rhabdomyomas most common prenatal finding
 - Multiple rhabdomyomas → virtually 100% will have tuberous sclerosis (TS)
 - Single rhabdomyoma → 50% will have TS
 - Well-defined, hyperechoic, intracardiac mass
 - Typically involves ventricles or interventricular septum
 - May detect as early as 22-weeks gestation
 - May cause arrhythmias or obstruction
- Central nervous system (CNS) findings may be subtle in utero
 - Irregularity of ventricular wall may be initial clue
- Fetal MR more sensitive than ultrasound for detection of CNS lesions
 - Subependymal nodules
 - Cortical/subcortical tubers

- Rarely may see renal cysts or angiomyolipomas

PATHOLOGY




- Autosomal dominant
 - 2/3 are due to de novo mutation
 - Variable expressivity

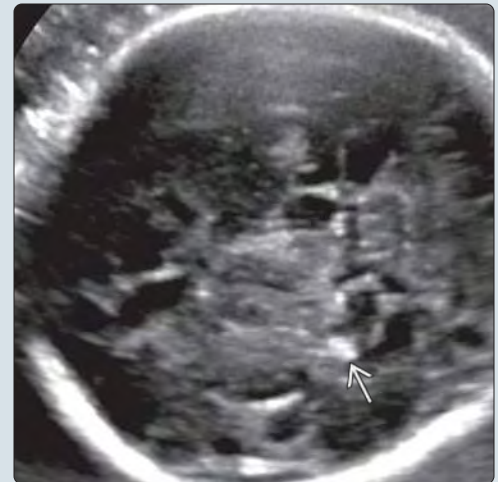
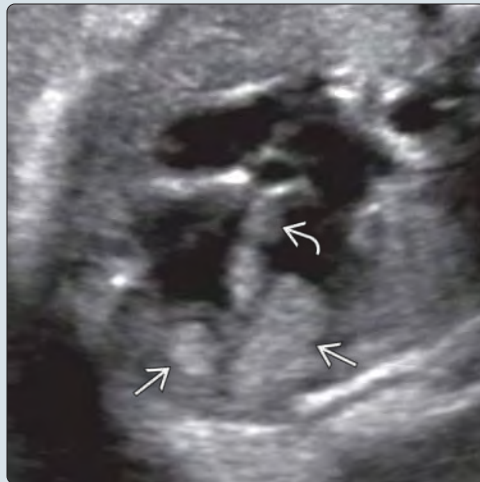
CLINICAL ISSUES



- Prenatal diagnosis possible by CVS or amniocentesis
- Rhabdomyomas may grow in conjunction with gestational age or remain stable
 - Usually spontaneously regress postnatally
 - Serial fetal echocardiography for cardiac function recommended
- Postnatal work-up for TS warranted in at-risk pregnancies, even if prenatal work-up negative

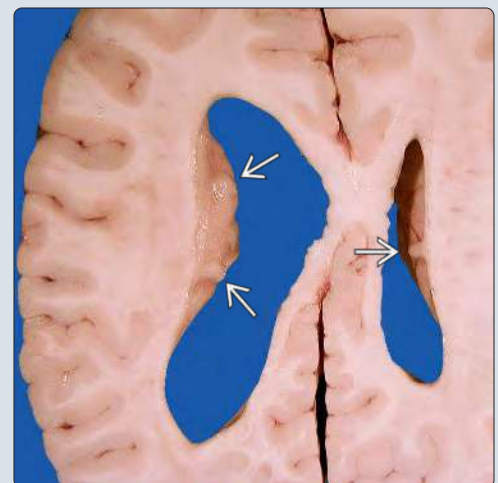
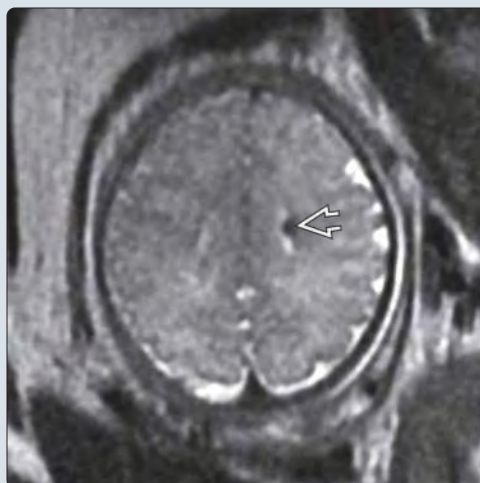
DIAGNOSTIC CHECKLIST

- Recommend fetal MR for screening at-risk patients (family history of TS)

(Left) Four-chamber view shows multiple echogenic rhabdomyomas , including a subtle thickening at the ventricular septum . Multiple rhabdomyomas are virtually diagnostic of tuberous sclerosis (TS). **(Right)** Axial ultrasound of the brain of the same fetus shows a suspicious echogenic nodule  in the subependymal region. Fetal MR should be considered in suspected TS cases, as it is more sensitive for the evaluation of intracranial findings.



(Left) Axial brain MR shows a hypointense subependymal nodule  in this fetus with rhabdomyomas and suspected TS. Postnatal MR is still recommended to assess for additional lesions. Subcortical tubers are difficult to diagnose prenatally. **(Right)** Axial section through the lateral ventricles shows the lumpy-bumpy appearance created by multiple subependymal nodules . Fetal findings are often subtle but may be suggested by a slightly irregular appearance of the ventricular lining. (From: Osborn's Brain.)



TERMINOLOGY

Abbreviations

- Tuberous sclerosis (TS)

Synonyms

- Bourneville disease
- Tuberous sclerosis complex

Definitions

- Genetic tumor disorder with multiorgan hamartomas
- Included in spectrum of phakomatoses
- Clinical triad: Facial angiofibromas, intellectual impairment, seizures

IMAGING

General Features

- Best diagnostic clue
 - Cardiac rhabdomyomas most common prenatal finding
 - Multiple rhabdomyomas → virtually 100% will have TS
 - Single rhabdomyoma → 50% will have TS

Ultrasonographic Findings

- **Cardiac rhabdomyoma**
 - Well-defined, hyperechoic, intracardiac mass
 - Tumor typically involves ventricles or interventricular septum
 - May appear as focal wall thickening if small
 - Most often affects septum or left ventricle
 - Often multiple
 - May detect as early as 22-weeks gestation
 - Requires close follow-up
 - Monitor for growth as size increases with advancing gestational age
 - Monitor cardiac function for potential complications
 - Arrhythmia
 - Atrioventricular valve dysfunction
 - Outflow or inflow tract obstruction
 - Associated dysrhythmias may result in hydrops
 - Compression of adjacent lung may occur due to size of tumor
 - Does not necessarily result in lung hypoplasia
- **Central nervous system (CNS)** findings may be subtle in utero
 - Subependymal hamartomas
 - Subependymal, echogenic nodules
 - Irregularity of ventricular wall may be initial clue
 - Subcortical tubers often not discernible
 - Subependymal giant cell astrocytoma
 - Located near foramen of Monro
 - Larger mass, which grows on subsequent scans
 - May present with hydrocephalus
 - Usually do not present in utero
- Rarely may see renal manifestations
 - Renal cysts
 - Echogenic angiomyolipomas

MR Findings

- Primarily for evaluation of intracranial abnormalities
 - MR more sensitive than ultrasound for detection of CNS lesions

- **Subependymal nodules**
 - Typically iso-hyperintense on T1WI
 - Low signal intensity on T2WI
 - Can be mistaken for hemorrhage
 - Located commonly along lateral ventricle margins, near caudate/thalamus
- **Cortical/subcortical tubers**
 - Most often supratentorial
 - High signal on T1WI, low signal on T2WI
- **Cortical/subcortical white matter lesions**
 - High signal on T2WI
 - Not routinely identified on prenatal scans
- If fetal MR negative in at-risk patient, consider postnatal MR
 - May detect more subtle findings
 - Gadolinium can be useful (postnatal)

DIFFERENTIAL DIAGNOSIS

Subependymal Gray Matter Heterotopia

- Isointense to normal cortical gray matter on MR
- Unlike hamartomas, do not calcify
- Associated with seizures and variable intellectual deficits

Bilateral Periventricular Nodular Heterotopia

- Recently identified as X-linked hereditary disease
 - Mutation within long arm of X chromosome, Xq28
- Sporadic or familial epilepsy with normal intelligence
- Primarily in females
- Associated with mega cisterna magna

Cortical Dysplasias

- Subcortical heterotopia
- Polymicrogyria
- Focal cortical dysplasia
 - Localized abnormality of lamination in cerebral cortex
- Most present postnatally with seizures &/or developmental delay

Normal Germinal Matrix

- Germinal matrix prominent in early brain development up to 26-weeks gestation
- Can be confused with nodular heterotopia or subependymal nodules because of location
 - Signal characteristics similar to gray matter on MR

Germinal Matrix Hemorrhage

- Because of location may be confused with subependymal giant cell astrocytoma
- Look for other signs of evolving hemorrhage
 - Intraventricular hemorrhage
 - Decreasing echogenicity with time
 - Porencephaly, hydrocephalus

PATHOLOGY

General Features

- Etiology
 - Abnormal differentiation of germinal matrix cells
- Genetics
 - Autosomal dominant
 - 2/3 are due to de novo mutation
 - Variable expressivity

- 2 separate genes localized
 - *TSC1* on chromosome 9q34
 - *TSC2* on chromosome 16p13.3
- No difference in clinical phenotype between *TSC1* and *TSC2* mutations
- Cardiac
 - Rhabdomyomas
 - Benign tumors
 - 50-85% are associated with TS
 - Multiple in 50% of cases
 - ~ 100% risk of TS if multiple
- Intracranial
 - Subependymal nodules
 - Nonprogressing hamartomas
 - Usually < 15 mm diameter
 - Cortical tubers
 - Lack central myelination
 - Unorganized neurons and glial cells
 - Subependymal giant cell astrocytoma
 - Occur in 15% of TS patients
 - Covered by ependymal layer
 - Cortical/subcortical white matter lesions
 - Bands of unmyelinated radial glial cells
- Poor prognostic indicator if associated with cardiac dysfunction
- CNS findings
 - Postnatal seizures, may be intractable
 - Number of CNS lesions may predict severity of cerebral dysfunction
 - Risk of cognitive impairment associated with number of tubers
 - May have normal intelligence
 - Watch for development of subependymal giant cell tumor
 - Slow-growing tumor, usually presenting in later childhood
 - Can rarely present in fetus/neonate, and is often highly aggressive in such cases

CLINICAL ISSUES

Presentation

- Most common signs/symptoms
 - Usually incidental finding of cardiac mass
 - Most commonly identified in 2nd trimester
 - Family history of TS
- Other signs/symptoms
 - Arrhythmias
 - Nonimmune hydrops secondary to cardiac involvement
- Postnatal work-up for TS warranted in at-risk pregnancies, even if prenatal work-up negative
- Check for other signs of TS after delivery
 - Retinal nodular hamartomas
 - Skin findings
 - Facial angiofibromas (adenoma sebaceum), shagreen patch, café au lait spots, subungual fibroma
 - Renal lesions
 - Cysts, angiomyolipoma
 - Lymphangiomyomatosis
- Look carefully at parents for TS
 - Family history and multifocality of lesions are strongest predictors of TS
 - Size of rhabdomyoma not directly linked to likelihood of TS
 - Affects counseling for future pregnancies

Demographics

- Epidemiology
 - 1:10,000-20,000

Natural History & Prognosis

- Cardiac rhabdomyomas
 - Often have benign clinical course prenatally
 - May grow in conjunction with gestational age or remain stable
 - Usually spontaneously regress postnatally

Treatment

- Cardiac rhabdomyomas
 - May infrequently require prenatal therapy with antiarrhythmics
 - Consider preterm cesarean section if hemodynamic obstruction becomes apparent
 - Resection may be warranted postnatally if cardiac function impaired
 - Cardiac echo after birth for baseline assessment
- CNS abnormalities
 - Postnatal therapy directed at seizure control
 - May require tuber resection if refractory to medication
 - Close postnatal imaging follow-up for developing subependymal giant cell tumor
 - Surgical resection usually curative
- Genetic counseling for parents
 - Prenatal diagnosis possible by CVS or amniocentesis

DIAGNOSTIC CHECKLIST

Consider

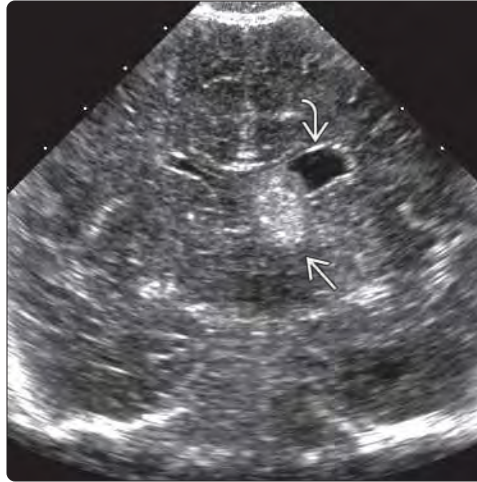
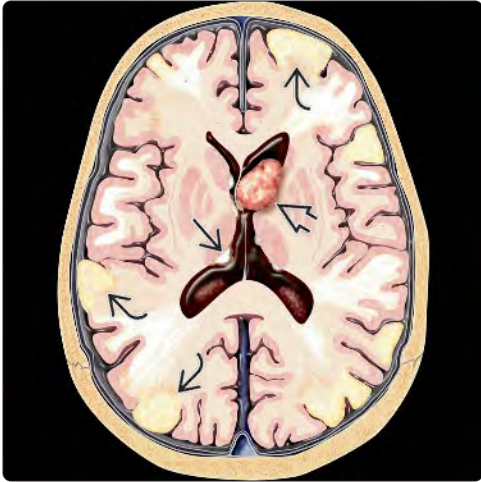- Serial fetal echocardiography to monitor cardiac function
- Fetal MR more sensitive than ultrasound for detection of CNS lesions
 - Even if prenatal scan is normal, postnatal MR should be considered for subtle cases
 - Recommended for screening at-risk patients (family history of TS)

Image Interpretation Pearls

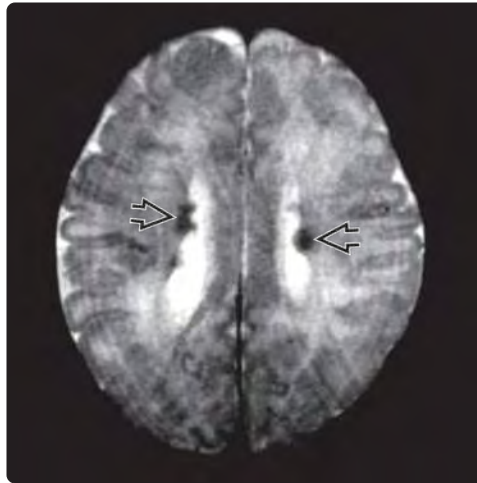
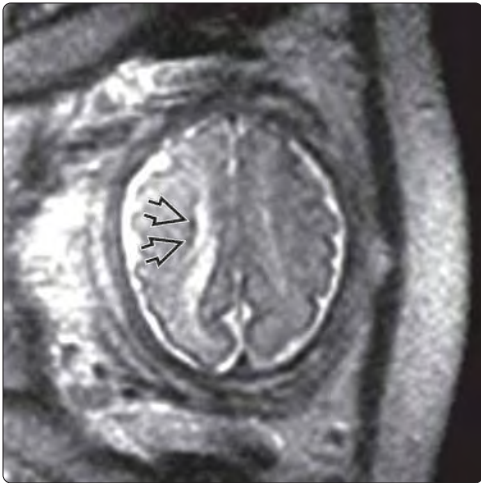- Multiple rhabdomyomas essentially diagnostic of TS

SELECTED REFERENCES

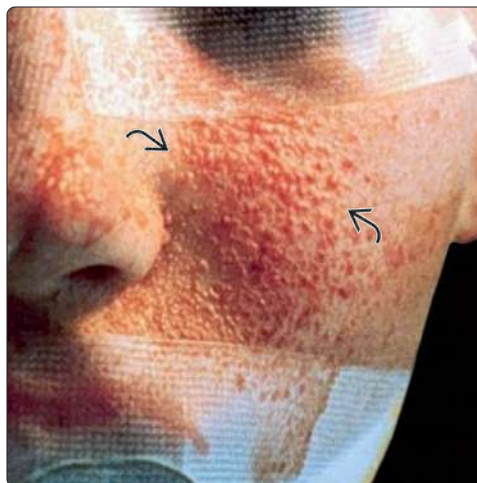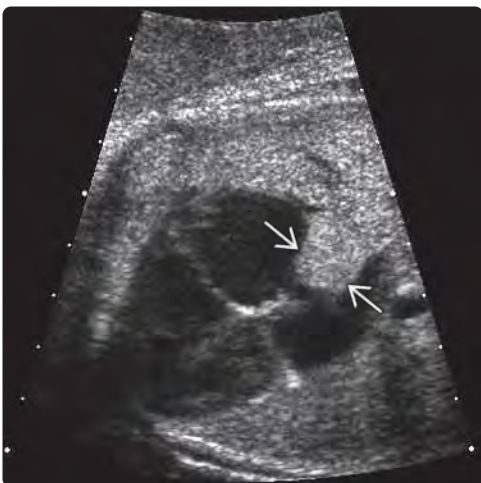1. Sciacca P et al: Rhabdomyomas and tuberous sclerosis complex: our experience in 33 cases. *BMC Cardiovasc Disord.* 14:66, 2014
2. Tyagi V et al: Fetal and Postnatal Magnetic Resonance Imaging of Unilateral Cystic Renal Dysplasia in a Neonate with Tuberous Sclerosis. *Pediatr Neonatol.* ePub, 2014
3. Lee KA et al: Molecular genetic, cardiac and neurodevelopmental findings in cases of prenatally diagnosed rhabdomyoma associated with tuberous sclerosis complex. *Ultrasound Obstet Gynecol.* 41(3):306-11, 2013
4. Prabowo AS et al: Fetal brain lesions in tuberous sclerosis complex: TORC1 activation and inflammation. *Brain Pathol.* 23(1):45-59, 2013
5. Gedikbasi A et al: Prenatal sonographic diagnosis of tuberous sclerosis complex. *J Clin Ultrasound.* 39(7):427-30, 2011



(Left) Axial graphic shows the typical locations of subependymal hamartomas [A], subcortical tubers [B], and giant cell astrocytoma [C]. Giant cell astrocytomas are uncommon in fetal TS cases but aggressive when present. (Right) Coronal ultrasound in a neonate shows a large subependymal giant cell astrocytoma [A] in the region of the foramen of Monro, causing ipsilateral lateral ventricular enlargement [B]. MR also showed multiple small subependymal nodules.



(Left) Axial T2WI MR of the brain shows 2 small hypointense, subependymal nodules [A] in this fetus with TS. These findings are subtle and often missed by ultrasound. (Right) Postnatal T2WI MR confirms the nodules and also shows other nodules that were not seen prenatally [B]. Subependymal nodules are typically high signal on T1WI and low signal on T2WI.



(Left) A homogeneous echogenic rhabdomyoma is present within the atrial septum [A]. Atrial rhabdomyomas are far less common than those arising in the ventricles. With a single rhabdomyoma, about 50% are associated with TS. (Right) Clinical photograph shows the typical appearance of adenoma sebaceum [A]. The classic clinical triad for TS is facial angiofibromas, intellectual impairment, and seizures.

KEY FACTS

TERMINOLOGY

- Nonrandom association of 6 core abnormalities
 - Vertebral defects
 - Anal atresia
 - Cardiac anomalies
 - Tracheoesophageal fistula with Esophageal atresia
 - Renal anomalies
 - Limb defects (primarily radial ray)

IMAGING

- Renal, limb, and vertebral anomalies most easily identified
- Cardiac anomalies most common defect (~ 80%)
- Esophageal atresia ± TE fistula in 50-60% but often difficult to diagnose in utero
- Systematic search for associated anomalies when 1 defect identified

TOP DIFFERENTIAL DIAGNOSES

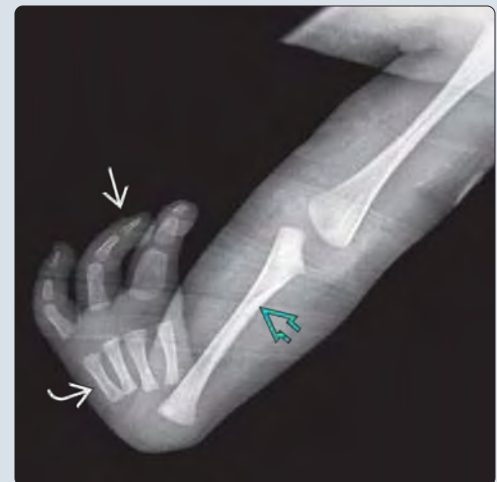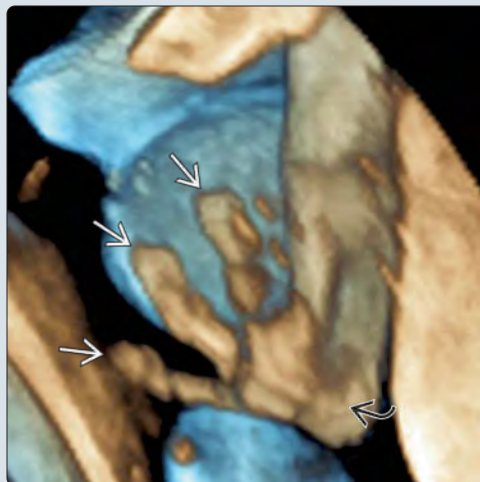
- Trisomy 18

- Arthrogryposis
- Syndromes with overlapping features
 - Holt-Oram syndrome
 - Diabetic embryopathy
 - Thrombocytopenia absent radius (TAR)
 - MURCS association
 - CHARGE syndrome
- VACTERL with hydrocephalus (VACTERL-H)

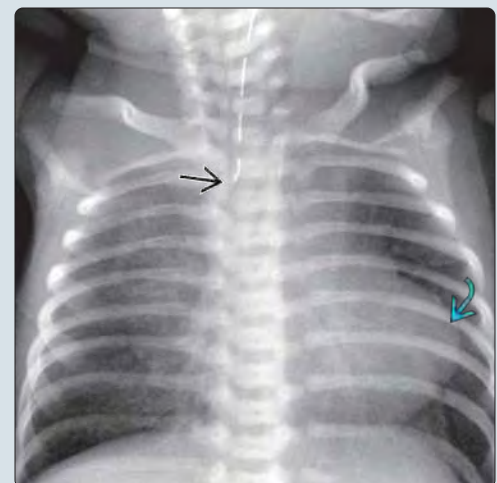
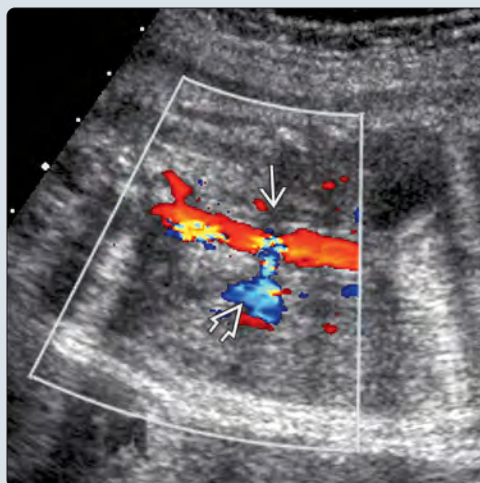
PATHOLOGY

- Multiple genes implicated to date including *FGF8*, *FOXF1*, *HOXD13*, *LPP*, *TRAP1*, *ZIC3*
- Not associated with chromosomal abnormality but shares many common features
- Diagnosis of exclusion
- All features found in VACTERL are commonly found in other syndromes as well as in isolation
- Risk factor: Maternal diabetes

(Left) 3D ultrasound shows the arm of a 3rd-trimester fetus with a radial ray defect. Notice the radially deviated wrist and oligodactyly. Only 3 digits are seen, and the thumb is absent. A single bone was seen in the lower arm in 2D imaging. Radial ray defects are the most common limb abnormalities found in the VATER/VACTERL association. (Right) Radiograph of the arm of the same infant after birth shows an ulna but no radius. Although only 3 digits are seen, 4 metacarpals are present. The thumb is absent.



(Left) This midtrimester fetus with VACTERL syndrome has unilateral left renal agenesis. Note the normal right renal artery, but none is seen on the left. (Right) Chest x-ray of a newborn with VACTERL association is shown. Severe polyhydramnios and a persistently absent stomach bubble on prenatal ultrasound raised concern for an esophageal atresia. Note the nasogastric tube in the esophageal pouch. The infant also had a tetralogy of Fallot. Note the uplifted cardiac apex (boot-shaped heart).



TERMINOLOGY**Synonyms**

- VATER/VACTERL association

Definitions

- Nonrandom association of 6 core abnormalities
 - Vertebral defects
 - Anal atresia
 - Cardiac anomalies
 - Tracheoesophageal fistula with Esophageal atresia
 - Renal anomalies
 - Limb defects (primarily radial ray)
- VATER includes vertebral, anal atresia, TE fistula with esophageal atresia, renal/radial defects
- At least 3 features should be present to consider diagnosis

IMAGING**General Features**

- Best diagnostic clue
 - Multiple anomalies on midtrimester ultrasound
 - Renal, limb, and vertebral anomalies most easily identified

Ultrasonographic Findings

- **Vertebral/segmentation abnormalities**
 - Hemivertebrae
 - Best demonstrated in coronal plane
 - Scoliosis: Originates at area of hemivertebra(e); often complex
 - Fusion of vertebral bodies or posterior elements (block vertebrae)
- **Anal atresia/imperforate anus**
 - Normal anus appears as hypoechoic ring with echogenic center ("anal dimple")
 - Absent in atresia
 - Colon can occasionally be dilated
 - Often not recognized prenatally
 - Imperforate anus associated with increased incidence of genital, urinary, and lumbosacral spine abnormalities
- **Cardiac malformations**
 - Cardiac anomalies most common defect, seen in approximately 80%
 - Ventricular septal defect (VSD) is most common defect in some studies
- **Esophageal atresia ± TE fistula**
 - Present in 50-60% of individuals with VACTERL
 - Often difficult to diagnose
 - Stomach absent or small
 - Look for esophageal pouch sign in 3rd trimester
 - Transient filling of proximal esophagus with swallowing
 - Polyhydramnios usually late finding (3rd trimester)
 - Persistent absent gastric fundus associated with increased amniotic fluid best sign
- **Renal anomalies**
 - Vesicoureteral reflux with additional structural defect (27%)
 - Unilateral renal agenesis (24%)
 - Multicystic/ dysplastic kidneys (18%)

- Duplicated collecting system (18%)
- Hydronephrosis
- Ectopic kidney
- Majority of infants with structural renal defect also have anorectal malformation

- **Limb malformation**

- Usually restricted to upper limbs
- Usually bilateral, may be asymmetric
- Radial ray malformation common
 - Hypoplasia/aplasia of thumbs
 - Hypoplasia/aplasia of radius with radial club hand

- **Other associated malformations/abnormalities**

- Polyhydramnios
 - Most often associated with esophageal atresia
- Rib anomalies (bifid, fused, absent)
 - Commonly associated with vertebral segmentation abnormalities
- Single umbilical artery often associated with renal anomalies
- Genital
 - Hypospadias, bifid scrotum, hypoplastic labia
 - More common in those with anorectal malformation
- Intrauterine growth restriction (FGR)
- Cleft lip/palate, high arched palate
- Oligohydramnios with bilateral renal anomalies

Imaging Recommendations

- Best imaging tool
 - Midtrimester ultrasound
 - 3D-4D imaging useful in delineating limb, spinal anomalies
- Protocol advice
 - Systematic search for associated anomalies when 1 defect is identified
 - Dedicated fetal echo
 - Karyotype to exclude chromosome abnormalities
 - Repeat ultrasound in 3rd trimester to evaluate fluid and growth

DIFFERENTIAL DIAGNOSIS**Trisomy 18**

- Significant overlap with VACTERL association with other anomalies
- Central nervous system (CNS) malformations
- FGR- often severe

Anal Atresia

- Isolated vs. syndromic
- High associated rate of genitourinary, lumbar spine abnormalities

Radial Ray Malformation

- Isolated vs. syndromic
- Wide range of thumb abnormalities
 - Absent thumb → hypoplastic → triphalangeal

Syndromes With Overlapping Features

- **Holt-Oram syndrome**
 - Radial ray anomalies, upper limb phocomelia
 - Cardiac defects (atrial septal and ventricular septal defects)

- Vertebral anomalies
- Thoracic scoliosis
- **Diabetic embryopathy**
 - Cardiac anomalies (transposition, septal defects)
 - Renal anomalies (agenesis, hydronephrosis)
 - CNS anomalies (neural tube defects, holoprosencephaly)
 - Limb anomalies (polydactyly, femoral hypoplasia, radial ray)
- **Thrombocytopenia absent radius (TAR)**
 - Bilateral radial ray abnormalities with normal thumbs
 - Cardiac, renal, other skeletal defects
 - High infant mortality due to hemorrhage, cardiac disease
- **Arthrogryposis**
 - Limb contractures may simulate radial/ulnar ray abnormalities
 - Extremities remain in fixed position during scan
 - Scoliosis
- **MURCS association**
 - Müllerian abnormalities, renal anomalies, and cervicothoracic vertebral dysplasia
- **CHARGE syndrome**
 - Colobomata, heart defects, choanal atresia, genital anomalies, growth abnormalities, ear anomalies
 - TE fistula ± esophageal atresia, anal atresia
- **Townes-Brock syndrome**
 - Dysplastic ears, triphalangeal thumbs, anal and renal anomalies
- **Roberts syndrome/Roberts SC/pseudothalidomide syndrome**
 - Tetrachomelia (90%), orofacial clefts, FGR
 - Wide phenotypic overlap with TAR
- **VACTERL with hydrocephalus (VACTERL-H)/VACTERL ± hydrocephalus (VACTERLX)**
 - X-linked and autosomal recessive types
 - Often poor prognosis with severe retardation
 - Given phenotypic overlap with Fanconi anemia, cases with suspected VACTERL-H should have chromosome breakage studies done to exclude Fanconi anemia

PATHOLOGY

General Features

- Etiology
 - Defective differentiation of mesoderm prior to 35 days of development
 - Possible association with mutations in genes in the sonic hedgehog pathway
 - Defective sonic hedgehog (Shh) signaling in mice leads to abnormalities very similar to those found in human cases of VACTERL
 - Multiple genes implicated to date including *FGF8*, *FOXF1*, *HOXD13*, *LPP*, *TRAP1*, *ZIC3*
 - Risk factor: Maternal diabetes
- Genetics
 - Sporadic
 - Rare report of parent to child transmission
 - Single features of VACTERL in siblings or parents of affected individuals found in up to 9% of cases if examined thoroughly
 - Recurrence risk < 1%

- Not associated with chromosomal abnormality but shares many common features

Staging, Grading, & Classification

- Diagnosis of exclusion
- No specific tests for confirmation of diagnosis
- No facial phenotype to aid in pattern recognition
- All features found in VACTERL are commonly found in other syndromes as well as in isolation
- Few patients have all features
 - Average of 3-4 findings per patient
 - At least 1 anomaly in limbs, thorax, and abdomen/pelvis needed to secure diagnosis

CLINICAL ISSUES

Presentation

- Most common signs/symptoms
 - Multiple anomalies on midtrimester scan

Demographics

- Epidemiology
 - 1.6/10,000 incidence

Natural History & Prognosis

- Variable based on type and number of anomalies
 - 28% neonatal mortality
- Potentially life-threatening anomalies include TE fistula, anal atresia, and cardiac abnormalities
- Survivors have good prognosis for normal intellect
- Severe scoliosis may be progressive, difficult to treat
- Life-long need for treatment, therapy in severely affected individual

Treatment

- Karyotype to rule out trisomy
- Pregnancy termination an option given multiple severe anomalies
 - Autopsy encouraged to establish diagnosis
- Delivery at tertiary care facility, if pregnancy continued
- Complete work-up with cardiac echo, renal ultrasound, spine and extremity radiographs
- All core features require surgical intervention for treatment

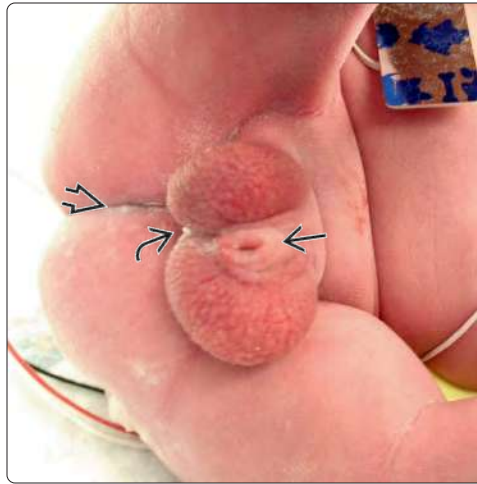
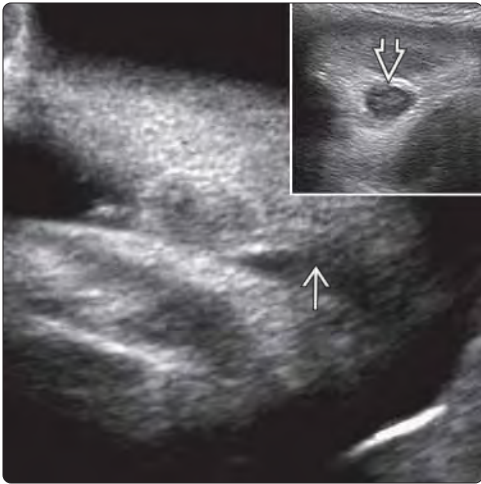
DIAGNOSTIC CHECKLIST

Image Interpretation Pearls

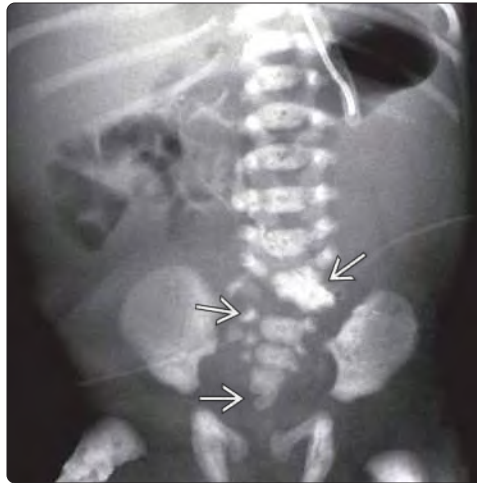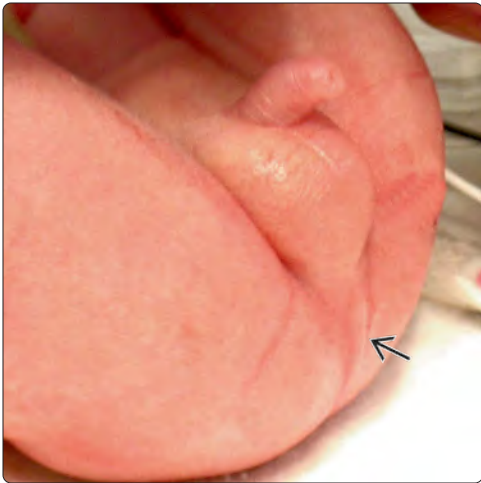
- 1 or more features should prompt thorough evaluation for other associated anomalies
 - Often, anomalies that are not as obvious (e.g., esophageal atresia and cardiac defects) have potential to be most serious complications

SELECTED REFERENCES

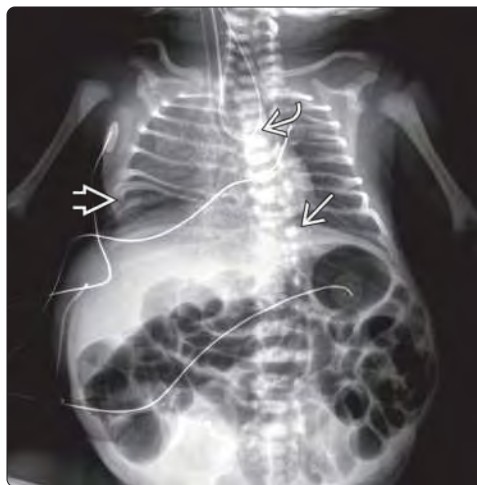
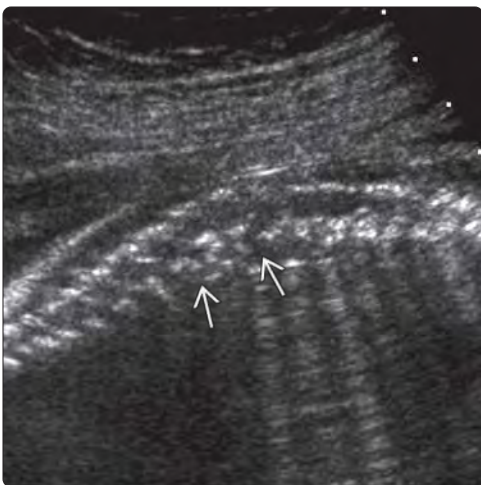
1. Reutter H et al: Underlying genetic factors of the VATER/VACTERL association with special emphasis on the "Renal" phenotype. *Pediatr Nephrol*. ePub, 2016
2. Cunningham BK et al: Analysis of renal anomalies in VACTERL association. *Birth Defects Res A Clin Mol Teratol*. 100(10):801-5, 2014
3. Brosens E et al: VACTERL Association Etiology: The Impact of de novo and Rare Copy Number Variations. *Mol Syndromol*. 4(1-2):20-6, 2013
4. Cunningham BK et al: Analysis of cardiac anomalies in VACTERL association. *Birth Defects Res A Clin Mol Teratol*. 97(12):792-7, 2013
5. Solomon BD et al: Clinical geneticists' views of VACTERL/VATER association. *Am J Med Genet A*. 158A(12):3087-100, 2012



(Left) The inset shows a normal anal dimple, with a hypoechoic muscular wall surrounding the echogenic mucosa. Compare that to the appearance when the dimple is absent in this fetus with anal atresia. (Right) Clinical photo shows the perineum of a newborn male with VATER/VACTERL association. Anal atresia is present as well as a bifid scrotum and micropenis. Genitourinary defects are often seen in association with anorectal malformations.



(Left) Clinical photo shows a newborn male with anal atresia. In this case, the genitalia are normal, but vertebral body anomalies were suspected on ultrasound. (Right) Anteroposterior radiograph of the same newborn infant with anal atresia shows multiple lumbosacral vertebral defects. Distal vertebral anomalies are commonly seen in association with anorectal malformations and are an important part of the VATER/VACTERL association.



(Left) Sagittal ultrasound of the spine shows a "jumbled" appearance caused by multiple vertebral segmentation defects. Hemivertebrae are the most common spine abnormalities in VATER/VACTERL association. (Right) Radiograph of a newborn with VACTERL association shows an orogastric tube curled at the site of esophageal atresia. A distal TE fistula accounts for gas in the bowel. There are vertebral anomalies and dilated bowel loops from anal atresia. Rib anomalies are also seen.

Valproate Embryopathy

KEY FACTS

TERMINOLOGY

- Fetal exposure to antiepileptic drug valproic acid (VPA), characterized by dysmorphic facial appearance, major and minor anomalies, central nervous system dysfunction

IMAGING

- Best diagnostic clue: Neural tube defect (NTD), limb anomalies, and FGR in an exposed fetus
- Neural tube defects: 1-2%
- Microcephaly: 15%
- Congenital heart defects: 25%
- Limb abnormalities: 45-65%
- Genitourinary: 20%
- Craniofacial anomalies
- Fetal growth restriction (FGR)

TOP DIFFERENTIAL DIAGNOSES

- Embryopathy due to other anticonvulsants (AED)
- Neural tube defects; isolated vs. syndromic

- Aneuploidy
- VACTERL association
- Cardiac & limb malformations; Isolated vs. syndromic

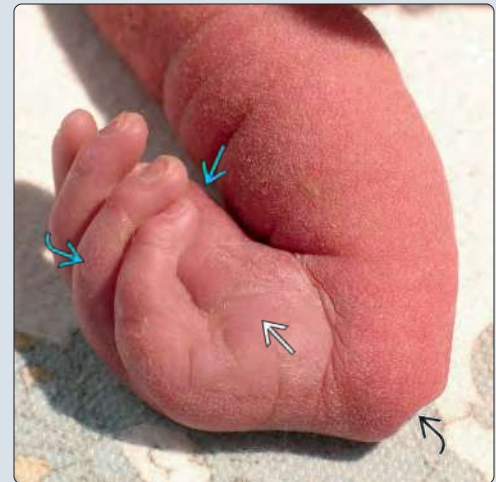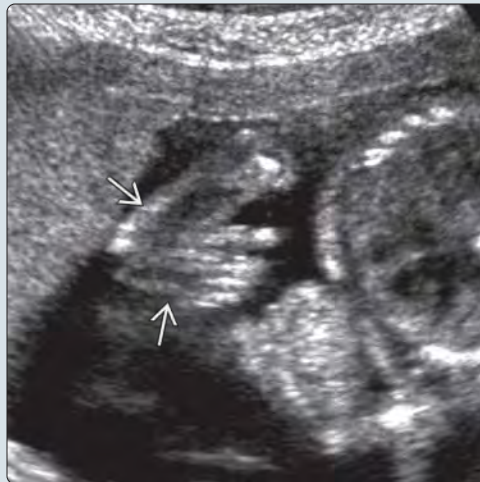
PATHOLOGY

- Mechanism of teratogenicity may be due to increased fetal oxidative stress vs. folic acid inhibitory action of VPA vs. changes in gene expression due to VPA inhibition of histone deacetylase

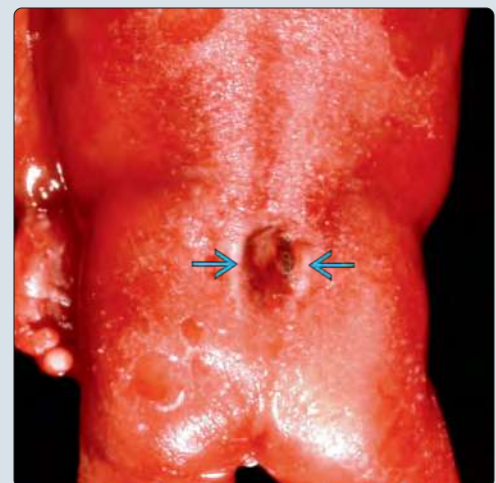
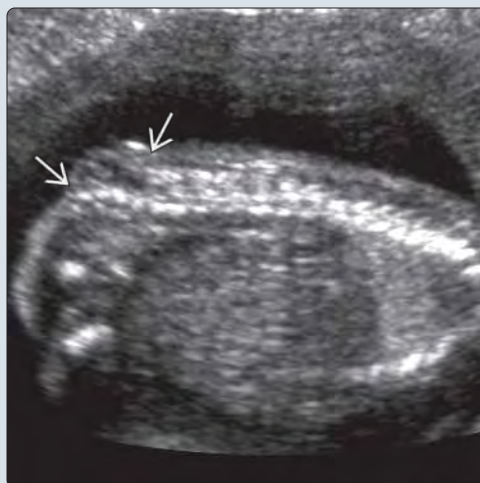CLINICAL ISSUES

- VPA exposure occurring at 17-30 days post fertilization confers risk of spina bifida of 1-2%
- Risk of other major malformation ~ 10% (2-3x that of unexposed pregnancy)
 - Minor anomalies in 1/3 of fetuses
- Increased risk with higher doses of VPA, polytherapy with other antiepileptic drugs
- Infant mortality 12%
- Developmental delay, intellectual impairment 29%

(Left) Ultrasound of a midtrimester fetus with suspected valproate embryopathy shows a radial ray defect [E]. **(Right)** Radial ray anomaly is in the same infant, born preterm with severe valproate embryopathy. The thumb was absent [E], and camptodactyly [E] of all digits was seen. Note the absence of normal palmar creases [E] due to lack of movement in utero. The nails were thin but otherwise normal. A prominent skin dimple was noted over the angled distal extremity [E].



(Left) Sagittal ultrasound of a midtrimester fetus with valproate embryopathy shows a sacral myelomeningocele [E], a hallmark finding of valproate embryopathy. The risk is generally 1-2% with early gestation exposure. **(Right)** Autopsy photograph shows a typical open NTD [E] from VPA exposure. Seizure control in maternal epilepsy is paramount for optimal pregnancy outcome but, due to the teratogenic risk, therapy should be directed at using a single drug at the lowest dose possible to control seizure activity.



TERMINOLOGY

Synonyms

- Valproic acid (VPA) embryopathy, fetal valproate syndrome

Definitions

- Fetal exposure to antiepileptic drug valproic acid (VPA), characterized by dysmorphic facial appearance, major and minor anomalies, central nervous system dysfunction

IMAGING

General Features

- Best diagnostic clue
 - Neural tube defect (NTD), limb anomalies, and FGR in an exposed fetus

Ultrasonographic Findings

- Neural tube defects 1-2%: Sacral, lumbosacral
- Microcephaly 15%
- Congenital heart defects 25%
 - Left-sided lesions, interrupted arch, septal defects
- Fetal growth restriction (FGR)
- Cleft lip/palate
- Limb abnormalities 45-65%
 - Radial ray defects
- Genitourinary (20%): Hypospadias

Imaging Recommendations

- Protocol advice
 - Monthly ultrasounds for interval growth, anatomy in patients on antiepileptic drugs (AED)
 - Fetal echocardiography

DIFFERENTIAL DIAGNOSIS

Embryopathy From Other Anticonvulsants

- Characteristic pattern of malformations, FGR and developmental delay seen in AED

Neural Tube Defects

- Isolated vs. syndromic

Aneuploidy

- FGR, other structural malformations

Cardiac Defects

- Isolated vs. syndromic

VACTERL Association

- Limb defects including radial ray common

Limb Defects

- Radial ray abnormalities (isolated vs. syndromic)

PATHOLOGY

General Features

- Etiology
 - Epilepsy most common neurologic disorder of reproductive-aged women
 - VPA most effective drug for petit mal seizures; also effective for bipolar disorder, migraine

- Mechanism of teratogenicity may be due to increased fetal oxidative stress vs. folic acid inhibitory action of VPA vs. changes in gene expression due to VPA inhibition of histone deacetylase

- Genetics
 - Recurrence in siblings due to repeated exposures in subsequent pregnancies, possible hereditary susceptibility

CLINICAL ISSUES

Presentation

- Most common signs/symptoms
 - Cardiac defect, microcephaly, neural tube defect
- Postnatal signs/symptoms other than major malformation
 - Neonatal hyperglycemia, afibrinogenemia, hyperbilirubinemia
 - Craniofacial
 - Bitemporal narrowing, midface hypoplasia, broad flat nasal bridge
 - Small palpebral fissures, hypertelorism, epicanthal folds, microphthalmia, hypoplastic optic nerves
 - Long flat philtrum, small mouth with thin lips, micrognathia
 - Thin fingers, hypoplastic nails, polydactyly
 - Developmental delay

Demographics

- Epidemiology
 - VPA exposure occurring at 17-30 days post fertilization confers risk of spina bifida of 1-2%
 - Risk of other major malformation ~ 10% (2-3x that of unexposed pregnancy)
 - Minor anomalies in 1/3 of fetuses
 - Increased risk with higher doses of VPA, polytherapy with other antiepileptic drugs
 - Even VPA monotherapy confers a significant risk of structural malformation of at least 6%

Natural History & Prognosis

- Infant mortality 12%
- Developmental delay, intellectual impairment 29%
- Variable severity among affected sibs

Treatment

- Seizure control in pregnancy is paramount
 - Use of a single drug at lowest possible dose
- Preconceptional folic acid 0.4-4.0 mg per day
 - Preconceptional folic acid 4 mg per day with history of previous affected child with NTD
- Pregnancy termination an option

SELECTED REFERENCES

1. Veiby G et al: Fetal growth restriction and birth defects with newer and older antiepileptic drugs during pregnancy. *J Neurol.* 261(3):579-88, 2014
2. Vajda FJ et al: Dose dependence of fetal malformations associated with valproate. *Neurology.* 81(11):999-1003, 2013
3. Holmes LB et al: Fetal effects of anticonvulsant polytherapies: different risks from different drug combinations. *Arch Neurol.* 68(10):1275-81, 2011
4. Tomson T et al: Dose-dependent risk of malformations with antiepileptic drugs: an analysis of data from the EURAP epilepsy and pregnancy registry. *Lancet Neurol.* 10(7):609-17, 2011

Warfarin (Coumadin) Embryopathy

KEY FACTS

TERMINOLOGY

- Fetal effects of early gestational exposure to warfarin, a vitamin K antagonist

IMAGING

- Severe nasal hypoplasia
- Rhizomelia
- Stippled epiphyses may be seen in 3rd trimester in coronal views of large joints and spine
- Postnatal radiography important for confirmation of skeletal findings

TOP DIFFERENTIAL DIAGNOSES

- Chondrodysplasia punctata
- Binder phenotype
- Skeletal dysplasias
- Trisomy 21
- Pseudo-warfarin embryopathy
- Maternal collagen vascular disease

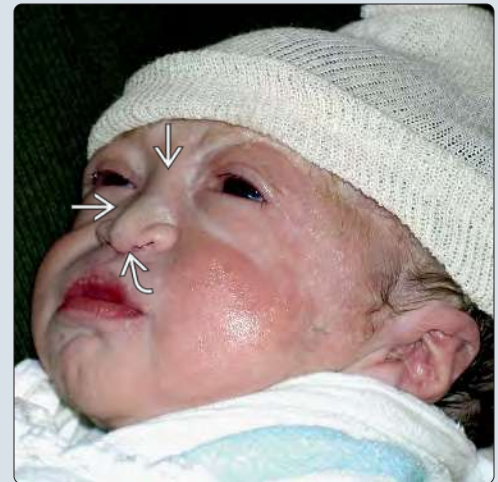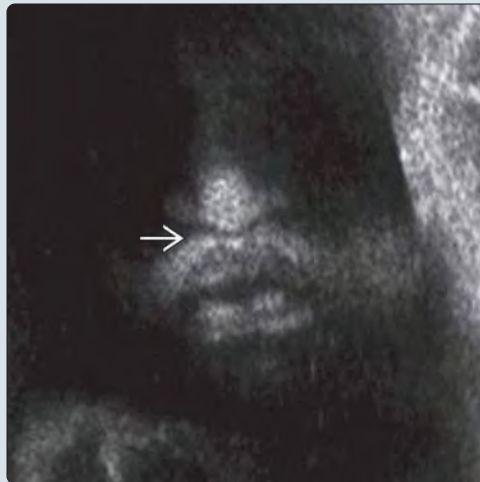PATHOLOGY

- Critical period is 6-9 weeks postfertilization
- Inhibition of vitamin K-dependent carboxylation of bone proteins
- Risk is higher with doses over 5 mg/day

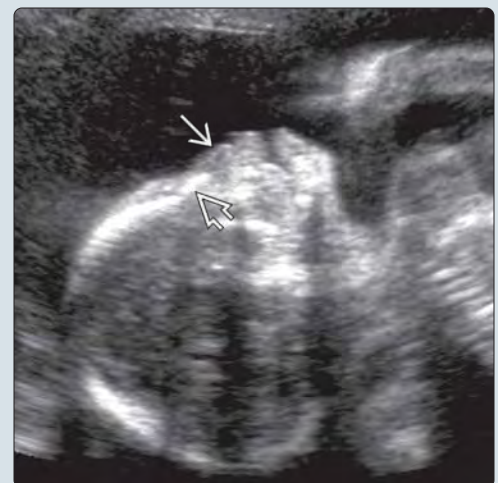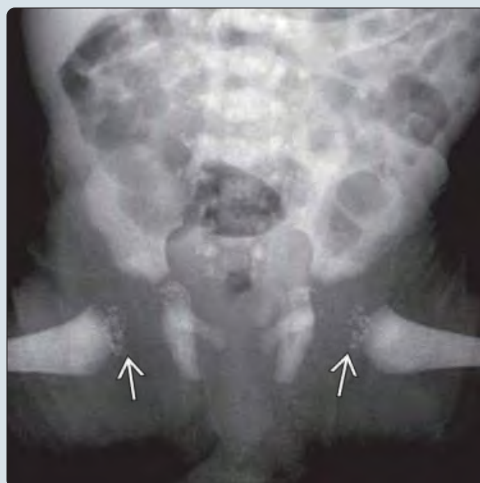CLINICAL ISSUES

- Embryopathy with 1st-trimester exposure in 6%
- Spontaneous abortion (25%), stillbirth (7%)
- Postnatal presentation
 - Neonatal respiratory distress
 - Severe nasal hypoplasia with depressed nasal bridge, deep grooves between alae nasi and nasal tip
 - Skeletal: Stippled epiphyses, short limbs, nail hypoplasia, vertebral anomalies
 - Ectopic calcifications of nose, tracheobronchial tree
- To decrease fetopathic risks of warfarin, usual practice is to switch to unfractionated heparin by week 6 postfertilization

(Left) Coronal image of the face of a 3rd-trimester fetus with warfarin embryopathy shows the flattened nose with the nasal tip at the level of the upper lip. (Right) Clinical photograph shows a newborn with warfarin embryopathy. Note the hypoplastic midface, nasal hypoplasia, and prominent grooves between the alae nasi and nasal tip.



(Left) Anteroposterior radiograph of the pelvis and hips of a newborn with warfarin embryopathy shows bilateral punctate calcifications in the femoral epiphyses. Calcifications were also noted in both shoulders. Stippled epiphyses can be identified in the fetus on a targeted 3rd-trimester scan. (Right) Sagittal ultrasound shows severe nasal hypoplasia in this late 2nd-trimester fetus with warfarin embryopathy. The nasal bridge is severely depressed. The nasal bone is present but hypoplastic.



TERMINOLOGY

Synonyms

- Fetal warfarin (Coumadin) syndrome

Definitions

- Fetal effects of early gestational exposure to warfarin, a vitamin K antagonist

IMAGING

General Features

- Best diagnostic clue
 - Severe nasal hypoplasia, rhizomelia in exposed fetus
 - Stippled epiphyses may be seen in 3rd trimester in coronal views of large joints, along spine

Imaging Recommendations

- Best imaging tool
 - 2nd- to 3rd-trimester 3D ultrasound of fetal face
 - Postnatal radiography
- Protocol advice
 - Careful search for corroborative epiphyseal calcifications in suspected embryopathy
 - Appropriate scanning technique important
 - Off-axis imaging of fetal profile can give impression of nasal hypoplasia

DIFFERENTIAL DIAGNOSIS

Chondrodysplasia Punctata

- Heterogeneous group of skeletal dysplasias
- Expanded epiphyses with punctate calcifications
- Rhizomelia, nasal hypoplasia

Vitamin K Deficiency

- Acquired abnormality from severe maternal malabsorption

Binder Phenotype

- Maxillonasal dysostosis

Skeletal Dysplasias

- Achondroplasia: Short limbs, midface hypoplasia
- Achondrogenesis (lethal): Severe rhizomelia, nasal hypoplasia

Trisomy 21

- Absent or hypoplastic nasal bone
- Occasional stippled epiphyses

Pseudo-Warfarin Embryopathy

- Epoxide reductase deficiency

Maternal Collagen Vascular Disease

- Reported in offspring of mothers with lupus, scleroderma, mixed connective tissue disease
- Attributed to transmission of autoantibodies across placenta affecting fetal growth plates

PATHOLOGY

General Features

- Etiology

- Inhibition of vitamin K-dependent carboxylation of bone proteins
- Critical period is 6-9 weeks postfertilization
 - Lower risk may extend into 2nd and 3rd trimesters (optic, central nervous system effects)
 - Risk is higher with doses over 5 mg/day
- Associated central nervous system abnormalities
 - Dandy-Walker continuum, agenesis of corpus callosum, microphthalmia, optic atrophy

CLINICAL ISSUES

Presentation

- Postnatal presentation
 - Neonatal respiratory distress common
 - Severe nasal hypoplasia with depressed nasal bridge, deep grooves between alae nasi and nasal tip
 - Skeletal: Stippled epiphyses, short limbs, nail hypoplasia, vertebral anomalies
 - Ectopic calcifications of nose, tracheobronchial tree

Demographics

- Epidemiology
 - Embryopathy with 1st-trimester exposure in 6%

Natural History & Prognosis

- Spontaneous abortion (25%), stillbirth (7%)
- Fetal intracranial hemorrhage
 - Rare, often fatal, occurs in 2nd or 3rd trimester
- Neonatal airway obstruction from nasal hypoplasia
- Increased risk of neonatal death
- Nasal hypoplasia significant cosmetic problem
- Stippled epiphyses not usually clinically significant
- Cervical vertebral abnormalities → myelopathy, spinal cord compression

Treatment

- Options, risks, complications
 - Indications for anticoagulation during pregnancy
 - Prosthetic heart valves
 - Prevention and treatment of venous thromboembolism
 - Unfractionated heparin and low-molecular weight heparin (LMWH) are mainstays of therapy in pregnancy
 - LMWH requires very close follow-up and excellent compliance for use with prosthetic valves
 - To decrease fetopathic risks of warfarin, usual practice is to switch to unfractionated heparin by week 6 postfertilization

SELECTED REFERENCES

1. Basu S et al: Low-dose maternal warfarin intake resulting in fetal warfarin syndrome: In search for a safe anticoagulant regimen during pregnancy. *Birth Defects Res A Clin Mol Teratol.* 106(2):142-7, 2015
2. Silveira DB et al: Importance of a multidisciplinary approach and monitoring in fetal warfarin syndrome. *Am J Med Genet A.* 167(6):1294-9, 2015
3. McLintock C: Anticoagulant choices in pregnant women with mechanical heart valves: balancing maternal and fetal risks—the difference the dose makes. *Thromb Res.* 131 Suppl 1:S8-10, 2013
4. Xie Y et al: Phenocopy of warfarin syndrome in an infant born to a mother with sickle cell anemia and severe transfusional iron overload. *J Pediatr Hematol Oncol.* 35(6):e265-8, 2013
5. Starling LD et al: Fetal warfarin syndrome. *BMJ Case Rep.* 2012, 2012

KEY FACTS

TERMINOLOGY

- Congenital muscular dystrophy associated with brain and eye abnormalities

IMAGING

- Hydrocephalus
- Cobblestone lissencephaly
 - Irregular, nodular, gray-white matter interface
 - Hard to appreciate on fetal MR with thin mantle secondary to hydrocephalus
- Agenesis/dysgenesis of corpus callosum
- Cerebellar hypoplasia
- Brainstem abnormalities (Z-shape)
- Eye abnormalities
 - Persistent hyperplastic primary vitreous (PHPV) may present as hyperechoic bands or mass within globe
 - PHPV often seen in combination with microphthalmia

TOP DIFFERENTIAL DIAGNOSES





- Muscle-eye-brain disease (MEBD)
- Fukuyama congenital muscular dystrophy (FCMD)

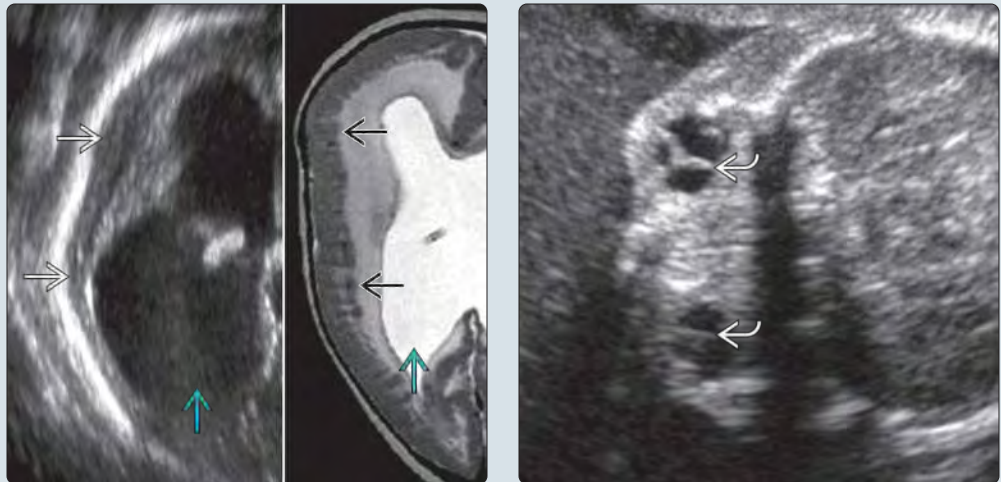
CLINICAL ISSUES



- Offer chorionic villus sampling/amniocentesis for microarray as well as karyotype
 - Up to 40% of cases can be confirmed by DNA analysis
- Most severe form of congenital muscular dystrophy
- Most children die before age 3

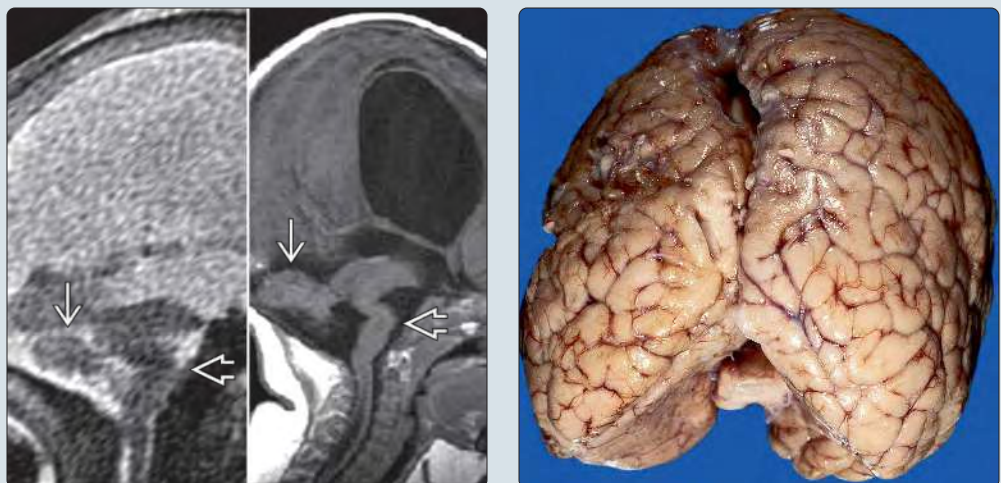
DIAGNOSTIC CHECKLIST

- In fetus with brainstem/cerebellar anomalies, look carefully at eyes for signs of retinal detachment, persistent hyperplastic primary vitreous, cataracts, coloboma
- Triad of hydrocephalus, cerebellar hypoplasia, and eye abnormality is common to FCMD, MEBD, and Walker-Warburg syndrome

(Left) Composite of 3rd-trimester US and postnatal MR shows ventriculomegaly  with abnormal lamination of the cerebral cortex  and complete lack of gyral/sulcal development. This correlates with the smooth cortex and cobblestone lissencephaly  seen on MR. **(Right)** Axial US through the orbits in late 3rd-trimester fetus shows bilateral echogenic bands  extending from the posterior lens to the back of the globe, consistent with persistent hyperplastic. It is important to evaluate both the face and eyes of fetuses with brain malformations.



(Left) Fetal (T2) and neonatal (T1) MR shows thin, Z-shaped brainstem  and abnormal cerebellum . The child was microphthalmic and blind and died within the 1st year of life. Z-shaped brain stem is associated with poor outcome, and demonstration may impact delivery plans (e.g., whether or not to perform C-section for fetal distress in labor). **(Right)** Cobblestone lissencephaly is named for the nodular, pebbly appearance of the brain surface, which resembles a cobblestone street. (From: Osborn's Brain.)



TERMINOLOGY**Abbreviations**

- Walker-Warburg syndrome (WWS)

Definitions

- Autosomal recessive syndrome of congenital muscular dystrophy associated with brain and eye abnormalities

IMAGING**General Features**

- Diagnosis established clinically on basis of 4 criteria
 - Congenital muscular dystrophy (with hypoglycosylation of α -dystroglycan and high creatine kinase level)
 - Anterior or posterior eye anomalies
 - Migrational brain defect with type II lissencephaly, hydrocephalus
 - Abnormal brainstem/cerebellum

Ultrasonographic Findings

- Hydrocephalus: Has been detected as early as at 13 weeks
- Cerebellar anomalies, occipital cephalocele, agenesis/dysgenesis of corpus callosum
- Eye anomalies
 - Persistent hyperplastic primary vitreous (PHPV)
 - Hyperechoic band between posterior pole of eye and posterior surface of lens
 - Hyperechoic, irregular mass extending from posterior surface of lens to posterior wall of globe
 - PHPV often seen in combination with microphthalmia, cataract
 - Retinal detachment (not seen until 3rd trimester)
 - Seen as V-shaped funnel behind lens on sagittal view, or concentric circles on coronal view
 - Rarely, buphthalmus (abnormally large globe due to increased intraocular pressure)
 - Coloboma

MR Findings

- Cobblestone lissencephaly (i.e., irregular, nodular, gray-white matter interface)
 - Hard to appreciate on fetal MR with thin mantle secondary to hydrocephalus
- Primitive, Z-shaped brainstem

Imaging Recommendations

- MR very helpful; assess brainstem and look for coloboma

DIFFERENTIAL DIAGNOSIS**Muscle-Eye-Brain Disease (MEBD)**

- Founder mutation in Finnish population (*POMGNT1* mutations most common)
- Pachygyria/polymicrogyria/agyria associated with cerebellar and brainstem abnormalities

Fukuyama Congenital Muscular Dystrophy (FCMD)

- Founder mutation in Japanese population (*FKTN* mutations most common)
- Brain shows polymicrogyria

PATHOLOGY**General Features**

- Genetics
 - Genetically heterogeneous condition with autosomal recessive inheritance
 - More severe phenotypes associated with highly disruptive homozygous mutations
 - ◻ Homozygous, segmental, intragenic microdeletion of *ISPD* at 7p21.2p21.1 → most severe phenotype
 - Mild compound heterozygous mutations in 1/both alleles → less severe phenotype, longer life span
 - Genome-wide linkage analysis in 10 consanguineous families indicated existence of at least 3 WWS loci
 - Several mutations found in *POMT1* (protein-O-mannosyltransferase 1) and *POMT2* genes
 - ◻ *POMT1* mutations in 9q34 chromosome region account for ~20% of cases
 - 1 mutation each in *FKTN*, *FKRP* genes
 - Other mutations found in *POMGNT1* (in mild/atypical forms of WWS), *FKTN*, *LARGE* genes
 - Ashkenazi Jews have founder mutation, c.1167insA in *FKTN*

CLINICAL ISSUES**Presentation**

- Presents at birth with generalized hypotonia, muscle weakness, occasional seizures
- Ocular abnormalities
- 5/8 genital anomalies in male patients (small penis, undescended testes)
- Low-set or prominent ears, cleft lip or palate

Natural History & Prognosis

- Most severe form of congenital muscular dystrophy; most children die before age 3

Treatment

- Offer chorionic villus sampling/amniocentesis for microarray as well as karyotype
 - Up to 40% of cases can be confirmed by DNA analysis of mutations in *POMT1*, *POMT2*, *FKTN*, *FKRP* genes
- Confirm diagnosis for counseling regarding recurrence risk
- Early US in future pregnancies

DIAGNOSTIC CHECKLIST**Image Interpretation Pearls**

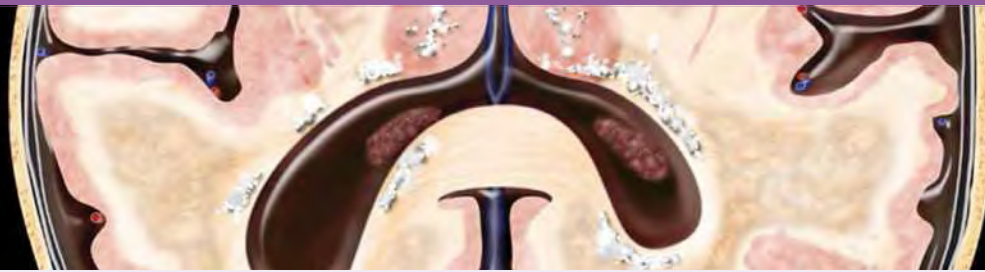
- In fetus with brainstem/cerebellar anomalies, look carefully at eyes for signs of retinal detachment, persistent hyperplastic primary vitreous, cataracts, coloboma
- Triad of hydrocephalus, cerebellar hypoplasia, and eye abnormality is common to FCMD, MEBD, and WWS

SELECTED REFERENCES

1. Trkova M et al: *ISPD* gene homozygous deletion identified by SNP array confirms prenatal manifestation of Walker-Warburg syndrome. *Eur J Med Genet.* 58(8):372-375, 2015
2. Shen O et al: Prenatal sonographic diagnosis of retinal nonattachment. *J Ultrasound Med.* 33(6):1095-7, 2014
3. Brasseur-Daudruy M et al: Walker-Warburg syndrome diagnosed by findings of typical ocular abnormalities on prenatal ultrasound. *Pediatr Radiol.* 42(4):488-90, 2012

This page intentionally left blank

SECTION 14
Infection



Cytomegalovirus	1016
Parvovirus	1020
Toxoplasmosis	1022
Varicella	1024

KEY FACTS

IMAGING

- Brain findings
 - Ventriculomegaly (moderate to severe in 45%)
 - Calcifications (often nonshadowing)
 - Intraparenchymal cysts, intraventricular adhesions
 - Microcephaly (up to 27%)
 - Cortical dysplasia
 - Signs of lenticulostriate vasculopathy
- Hepatosplenomegaly secondary to extramedullary hematopoiesis
- Anemia due to marrow suppression/hemolytic anemia
- Cardiomyopathy, nonimmune hydrops
- Fetal growth restriction


CLINICAL ISSUES

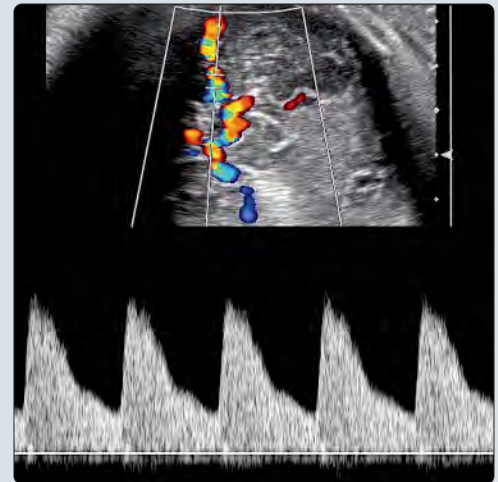
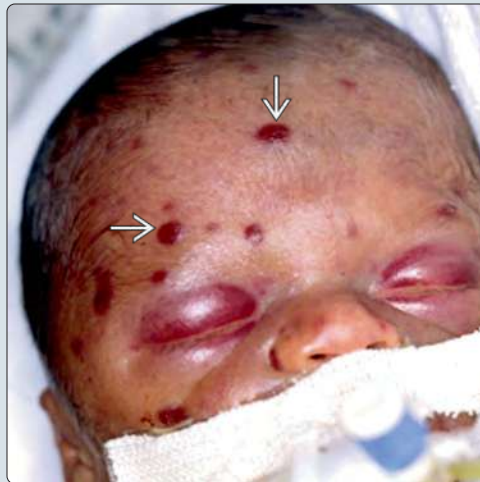- Cytomegalovirus (CMV) is most common congenital infection worldwide
 - Humans are only known host
 - Vertical transmission: Transplacental fetal infection




- Early exposure increases risk to fetus, although late infection increases transmission risk
- 40% vertical transmission with primary infection in pregnancy
- 75-80% transmission if primary infection occurs in 3rd trimester
- Diagnosis of primary maternal infection is based on
 - Development of CMV-specific IgG in previously seronegative woman
 - Or detection of specific CMV IgM antibody associated with low avidity CMV IgG
- Once fetal infection confirmed, scan every 2-4 weeks in an effort to detect extent of damage
- Incidence of congenital infection with CMV ~ 1% of live births (0.3-2.4% worldwide)

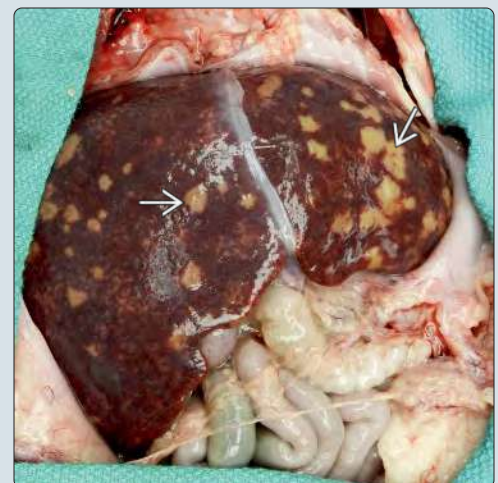
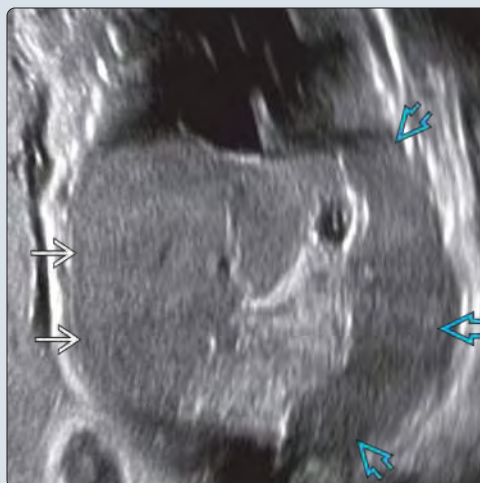
DIAGNOSTIC CHECKLIST

- Many cranial imaging findings are nonspecific if isolated; however, ≥ 2 should lead to CMV testing

(Left) Photograph of an infant with congenital CMV infection shows macular "blueberry muffin" spots  consistent with extramedullary hematopoiesis. CMV infection is associated with abnormal erythropoiesis and hemolytic anemia. **(Right)** Middle cerebral artery peak systolic velocity was 112 cm/sec in this 3rd-trimester fetus with anemia. The case was sent as alloimmune anemia but marked hepatosplenomegaly was noted. Infection work-up resulted in a diagnosis of CMV.



(Left) This fetus with hepatosplenomegaly from CMV infection shows a large liver , but what is most striking is the dramatic enlargement of the spleen . The enlargement is caused by extramedullary hematopoiesis secondary to fetal anemia. **(Right)** This neonate had symptomatic congenital CMV and survived for 4 months with persistent viremia despite antiviral therapy. The liver is markedly enlarged and shows numerous white areas from hepatic necrosis . (From DP: Placenta.)



TERMINOLOGY

Abbreviations

- Cytomegalovirus (CMV)

IMAGING

General Features

- In confirmed maternal infection, fetal infection presumed if any of the following
 - Progressive growth restriction
 - Microcephaly
 - Hepatomegaly/splenomegaly
 - Secondary to extramedullary hematopoiesis
 - Anemia due to marrow suppression/hemolytic anemia
 - Calcifications (visceral or cerebral)
 - Hydrops

Ultrasonographic Findings

- Brain
 - Ventriculomegaly (moderate to severe in 45% of infants with congenital infection)
 - Abnormal periventricular echogenicity
 - Intraventricular adhesions
 - Calcifications (often nonshadowing)
 - Echogenic intraparenchymal foci may be periventricular, cortical, in basal ganglia
 - Intraparenchymal cysts
 - Periventricular, anterior temporal, occipital, frontoparietal
 - In children, anterior temporal cysts with associated white matter disease is particularly suggestive of CMV infection
 - Same finding can be seen in fetus
 - Microcephaly (up to 27% of infants with congenital infection)
 - Cortical dysplasia
 - Cerebellar/cisterna magna abnormalities (cerebellar volume loss in 67% of infants with congenital infection)
 - Signs of lenticulostriate vasculopathy
 - Uni-/bilateral curvilinear echogenic streaks within basal ganglia, thalami
- Hepatosplenomegaly
- Cardiomyopathy, nonimmune hydrops
- Fetal growth restriction (FGR)

MR Findings

- Cortical dysplasia (present in up to 10% of children with congenital CMV)
 - Lissencephaly, pachygyria
 - Polymicrogyria (focal or diffuse)

Imaging Recommendations

- Protocol advice
 - If cephalic presentation, use transvaginal ultrasound for highest resolution brain images
 - Consider MR for additional information on brain (e.g., cortical dysplasia, cerebellar hypoplasia)
 - MR imaging higher sensitivity than ultrasound in detecting brain anomalies (92% vs. 38%) and in predicting symptomatic infection (83% vs. 33%)

- Ultrasound and MR appear to be complementary; they are not mutually exclusive in high-risk fetuses

DIFFERENTIAL DIAGNOSIS

Other Congenital Infections

- **Parvovirus**
 - Ascites common presenting finding in fetus
 - Fetal hydrops secondary to anemia
- **Toxoplasmosis**
 - Intracranial calcifications
 - Liver calcifications and hepatosplenomegaly
- **Varicella**
 - Calcifications (liver, heart, renal), skin lesions
- **Herpes simplex**
 - Echogenic bowel, ventriculomegaly
- **Syphilis**
 - Hepatosplenomegaly, dilated bowel, bowing of long bones, abnormal epiphyses
- **HIV**
 - FGR, intrauterine death in severe cases
- **Rubella**
 - Cardiac defects, microcephaly, microphthalmia, FGR

Other Causes of Nonimmune Hydrops

- Aneuploidy, anemia, tachydysrhythmia

Other Causes of Echogenic Bowel

- Aneuploidy, gastrointestinal anomalies including bowel obstructions, cystic fibrosis

PATHOLOGY

General Features

- CMV is DNA virus of herpes family
 - Like other herpes viruses, CMV capable of causing latent (reactivation) infection
 - Neurotropic, replicates in ependyma, germinal matrix, and capillary endothelium

Microscopic Features

- Immunohistochemical staining with CMV-specific antibodies reveals large multinucleated cells with intracytoplasmic and intranuclear inclusion bodies
- Inflammatory infiltrate almost always present in CMV-infected organs and bone marrow; severity of inflammatory response correlates with degree of damage

CLINICAL ISSUES

Presentation

- In symptomatic fetus/neonate
 - Spontaneous abortion, preterm birth, stillbirth
 - Microcephaly, ventriculomegaly, intracerebral calcifications
 - FGR, hydrops
 - Hepatosplenomegaly, visceral calcifications
 - Thrombocytopenia, anemia
 - Chorioretinitis, hearing loss
 - Intellectual impairment, seizures
- Adults are usually asymptomatic
 - May only be diagnosed when suspicious fetal findings noted on ultrasound

- May have malaise, fever, lymphadenopathy, hepatosplenomegaly

Demographics

- Epidemiology
 - Humans are only known hosts
 - Horizontal transmission by direct contact: Exposure to secretions, urine, blood, or by organ transplantation
 - Vertical transmission: Transplacental fetal infection
 - Early exposure increases risk to fetus, although late infection increases transmission risk
 - Most common congenital infection worldwide
 - Incidence of congenital infection with CMV ~ 1% of live births (0.3-2.4% worldwide)
 - Congenital CMV is most common infectious cause of intellectual impairment, sensorineural deafness, and visual impairment
 - Incidence of primary infection in pregnancy up to 2.2%
 - 40% vertical (transplacental) transmission rate to fetus
 - 75-80% transmission rate if primary infection in 3rd trimester
 - Nonprimary infection rate in pregnancy (i.e., reactivation of previous infection) 5%
 - Vertical transmission rate of 5-10%
 - Affected infants generally asymptomatic at birth but at risk for developing mild visual, auditory, developmental deficits
 - Estimated that 8,000 infants in USA are affected by CMV-related neurologic deficits each year

Natural History & Prognosis

- Primary infection during pregnancy
 - Detectable abnormalities in fetus associated with poor neurodevelopmental outcome in child
 - 5-15% of congenitally infected infants acutely symptomatic at birth
 - Mortality up to 30% within 2 years
 - Neurologic sequelae in up to 80% (sensorineural hearing loss, visual impairment, intellectual impairment)
 - Sensorineural hearing loss is present in 10-15% of those symptomatic at birth
 - Progressive in 50%, fluctuates in 20%
 - 85-95% of congenitally infected infants asymptomatic at birth
 - Even in absence of fetal sonographic findings, neurologic sequelae found in up to 30% in 1st year of life
 - 10-15% of initially asymptomatic children will develop neurologic, auditory or visual defects by school age
- Accurate diagnosis of congenital CMV infection is important because antiviral treatment is effective for minimizing hearing loss in symptomatic infants

Treatment

- **Diagnosis of primary maternal CMV infection**
 - Initial serology for CMV often difficult to interpret
 - IgM may remain positive for up to 1 year after acute infection
 - IgM may become positive in face of reactivation infection

- If suspected maternal infection, test for CMV-specific IgM, IgG and IgG avidity
 - IgG avidity is low in setting of acute infection
 - IgG avidity is high in setting of recurrent or reactivated infection
- Development of CMV-specific IgG in previously seronegative woman **or** detection of specific CMV IgM antibody associated with low avidity CMV IgG
- **Diagnosis of secondary maternal CMV infection**
 - Should be based on significant rise of IgG antibody titer ± presence of IgM and high IgG avidity
- **Amniocentesis for diagnosis of fetal infection**
 - Prenatal diagnosis of fetal CMV infection should be based on amniocentesis
 - Takes 5-7 weeks following fetal infection for detectable quantity of virus to be secreted into amniotic fluid
 - Cordocentesis impractical due to technical challenge prior to 20 weeks
 - If ultrasound is suggestive of fetal CMV infection, offer amniocentesis even if maternal serology does not support recent seroconversion
 - Polymerase chain reaction (PCR) for viral sequence
 - Viral load in maternal blood, amniotic fluid, and fetal blood important prognostic factors
 - Risk-benefit ratio of amniocentesis with secondary maternal infection different because of lower vertical transmission rate (5-10%)
- Pregnancy termination is option for confirmed infection after appropriate counseling
- Treatment with hyperimmune globulin is under investigation
- Following diagnosis of fetal CMV infection, perform serial scans every 2-4 weeks to detect sonographic abnormalities, predict extent of fetal damage
 - Absence of sonographic findings does not guarantee normal outcome
- CMV vaccine research and development ongoing

DIAGNOSTIC CHECKLIST

Image Interpretation Pearls

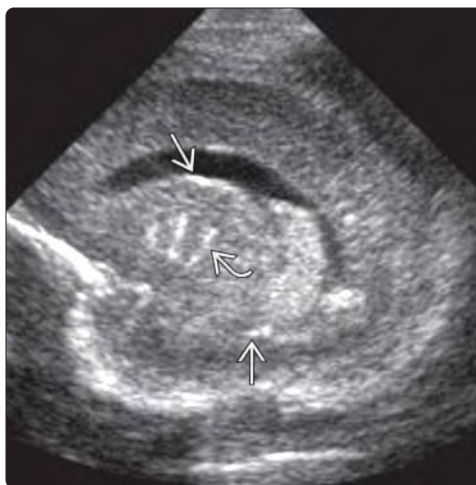
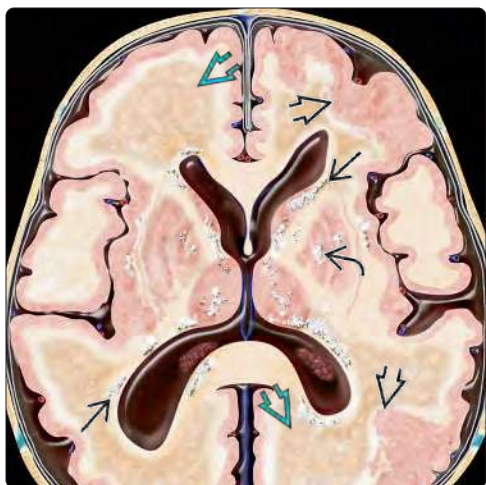
- Brain/basal ganglia calcifications are faint/punctate
- Absence of calcifications does not exclude congenital CMV infection

Reporting Tips

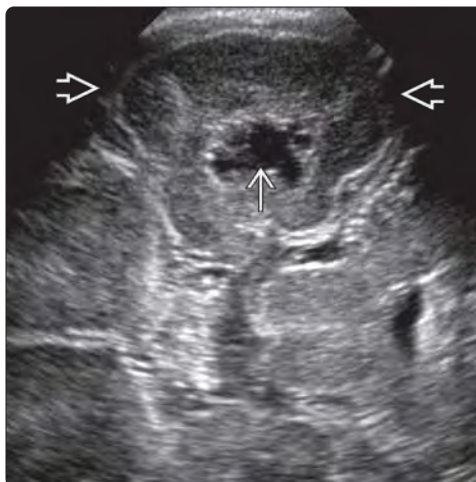
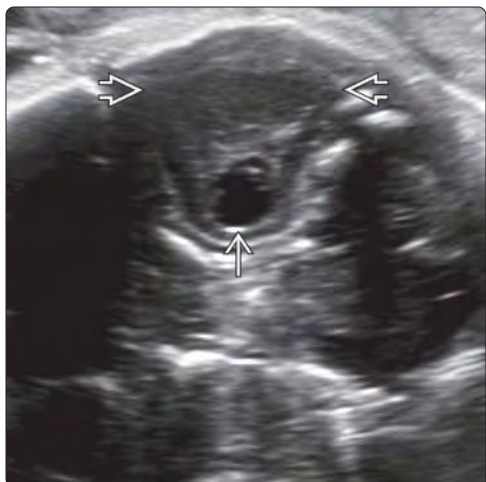- Many cranial imaging findings are nonspecific if isolated; however, ≥ 2 should lead to CMV testing

SELECTED REFERENCES

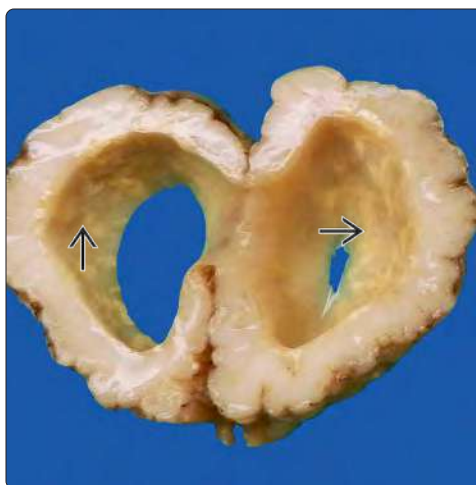
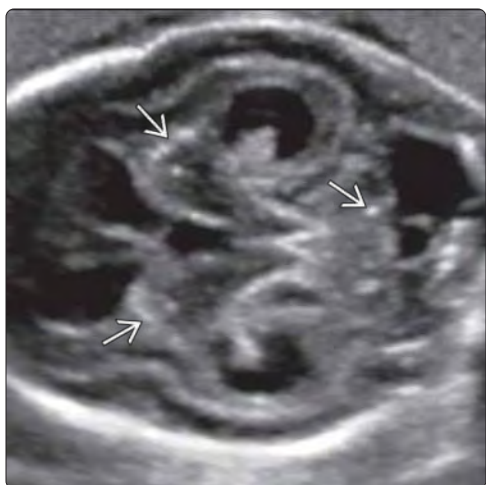1. Hadar E et al: Antenatal risk factors for symptomatic congenital CMV disease following primary maternal CMV infection. *J Perinat Med.* ePub, 2015
2. Hui L et al: Perinatal outcome after maternal primary cytomegalovirus infection in the first trimester: a practical update and counseling aid. *Prenat Diagn.* 35(1):1-7, 2015
3. McCormick AL et al: The immunological underpinnings of vaccinations to prevent cytomegalovirus disease. *Cell Mol Immunol.* 12(2):170-9, 2015
4. Naing ZW et al: Congenital cytomegalovirus infection in pregnancy: a review of prevalence, clinical features, diagnosis and prevention. *Aust N Z J Obstet Gynaecol.* 56(1):9-18, 2015



(Left) Graphic shows numerous periventricular and basal ganglia calcifications. There are areas of cortical dysplasia and the yellowish white matter abnormalities reflect regions of edema, demyelination, &/or gliosis. Ventricular dilation reflects volume loss. (Right) Sagittal head ultrasound of a premature infant with congenital CMV infection shows subtle periventricular calcifications. Multiple linear calcifications are in the lenticulostriate vessels. These create the candelabra sign of congenital infection.



(Left) Third trimester scan through the brain of a fetus with known CMV infection shows a new, irregularly shaped parenchymal cyst in the right temporal lobe. (Right) Mastoid view neonatal head ultrasound in the same infant confirms the parenchymal cyst within the temporal lobe. CMV infection causes inflammation and release of neurotoxic factors leading to focal parenchymal necrosis. The finding of anterior temporal cysts with associated white matter disease is particularly suggestive of CMV infection.



(Left) Ultrasound of the brain in a fetus with known CMV infection at 25-weeks gestation shows ventriculomegaly and multiple periventricular and intraparenchymal calcifications. These calcifications were not visible at the 22-week scan. (Right) Gross pathology in a similar case shows hydrocephalus and multiple yellow subependymal calcifications. (From DP: Placenta.)

KEY FACTS

TERMINOLOGY

- Fetal infection with human parvovirus B19
- Major clinical triad of anemia, heart failure, hydrops

IMAGING

- Best diagnostic clue: Hydrops in fetus at risk for parvovirus infection based on maternal seroconversion
- US
 - Ascites most common presenting finding
 - Progression to hydrops in severe cases
 - Cardiac failure secondary to severe fetal anemia, myocarditis
 - Placentomegaly, polyhydramnios
- Noninvasive assessment for fetal anemia using middle cerebral artery peak systolic velocity (MCA-PSV)

TOP DIFFERENTIAL DIAGNOSES

- Other congenital infections
 - Significant overlap in imaging findings

- Requires maternal/fetal serology to make definitive diagnosis
- Hydrops
 - Nonimmune (aneuploidy, lymphatic, arrhythmia)
 - Immune (alloimmunization)
- Isolated ascites

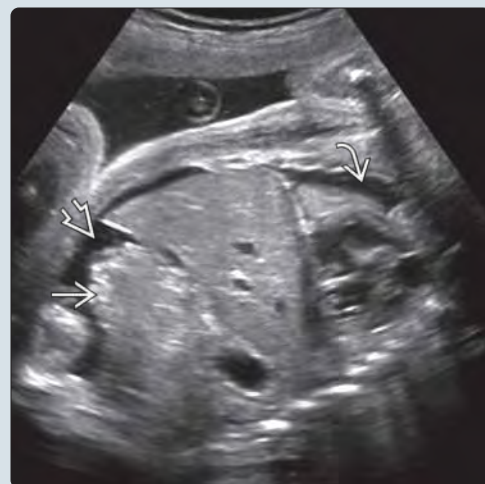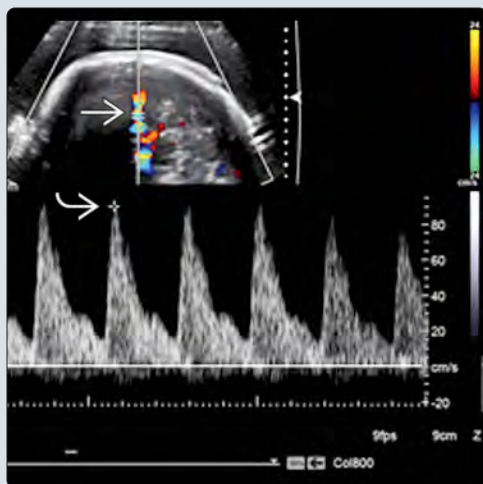
PATHOLOGY

- Parvovirus attacks erythroid progenitor cells → anemia
- Involvement of cardiac myocytes → viral myocarditis → hydrops

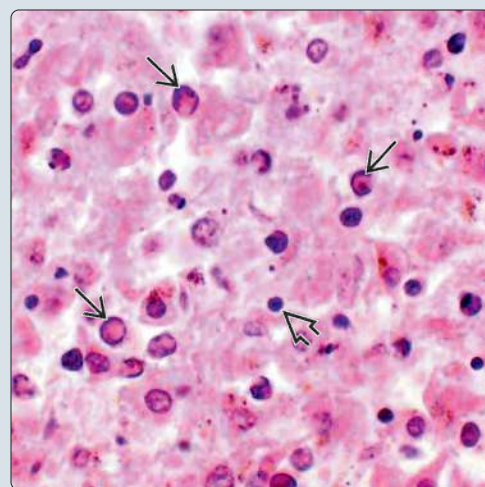
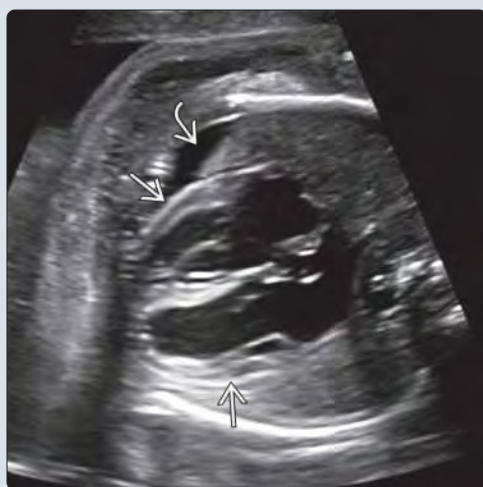CLINICAL ISSUES

- Infection usually self-limited in mothers
- 17-33% of women who become infected during pregnancy transmit infection to fetus
- Risk of fetal loss 8-17% (before 20 wk); 2-6% (after 20 wk)
- Stillbirth may occur from 1 through 11 wk after maternal seroconversion

(Left) Pulsed Doppler US shows an elevated peak systolic velocity (PSV) of 90 cm/sec in the middle cerebral artery (MCA) of a fetus with severe anemia. MCA-PSV monitoring is used to screen for fetal anemia in many conditions, including infection with parvovirus B19. **(Right)** US of the abdomen in a hydropic fetus shows a pleural effusion, ascites, and mildly echogenic bowel, all of which are common findings in fetal infection with parvovirus B19.



(Left) A moderate pleural effusion and cardiomegaly are seen in a fetus with parvovirus infection. Fetal blood sampling showed a hematocrit of 7 and thrombocytopenia of 10,000, which are common findings in parvovirus B19 infection. **(Right)** Histology shows intranuclear inclusions within erythroid cells in the liver, typical of parvovirus B19 infection in the fetus. A normal erythroid cell is shown for comparison. (Courtesy J. Szakacs, MD.)



TERMINOLOGY**Definitions**

- Erythema infectiosum (fifth disease in children)
- Major clinical manifestation of fetal infection with parvovirus B19; triad of anemia, heart failure, hydrops
 - Parvovirus B19 infection causal in 8-27% of cases of nonimmune hydrops

IMAGING**General Features**

- Best diagnostic clue
 - Hydrops in fetus at risk for parvovirus infection based on maternal seroconversion

Ultrasonographic Findings

- Ascites most common presenting finding
- Progression to hydrops in severe cases
 - Cardiac failure secondary to severe fetal anemia, myocarditis
- Placentomegaly, polyhydramnios

Imaging Recommendations

- Noninvasive assessment for fetal anemia using middle cerebral artery peak systolic velocity (MCA-PSV)
 - MCA-PSV is elevated in fetal anemia and predicts potential need for intrauterine transfusion

DIFFERENTIAL DIAGNOSIS**Other Congenital Infections**

- Significant overlap in imaging findings
 - Requires maternal/fetal serology to make definitive diagnosis
- **Cytomegalovirus**
 - Most common intrauterine infection
 - Calcifications, microcephaly, echogenic bowel
- **Toxoplasmosis** (*Toxoplasma gondii*)
 - Human infection from undercooked meats, contaminated soil, water
 - Calcifications, hepatosplenomegaly
- **Varicella**
 - Primary maternal infection with chickenpox
 - Calcification, skin lesions, limb anomalies
- **Herpes simplex virus type 2**
 - Most infections occur during vaginal delivery
 - Echogenic bowel, ventriculomegaly

Hydrops

- Nonimmune (aneuploidy, lymphatic, dysrhythmia)
- Immune (alloimmunization)

Ascites

- Isolated, without other signs of hydrops

PATHOLOGY**General Features**

- Etiology
 - Parvovirus attacks erythroid progenitor cells → aplastic anemia
 - Thrombocytopenia also common and may be severe

- Involvement of cardiac myocytes leading to viral myocarditis may cause hydrops

CLINICAL ISSUES**Presentation**

- Adults (maternal presentation)
 - Transient, migratory maculopapular rash
 - Polyarthrits, polyarthralgia occurs in 60% of symptomatic adults
 - Aplastic crisis in immunocompromised, chronic hemolytic anemia
- Children
 - "Slapped cheek" rash in children
 - Mild febrile illness, upper respiratory symptoms

Demographics

- Epidemiology
 - 30-50% of adult women are nonimmune to parvovirus
 - Main reservoir: School-aged children, day care facilities

Natural History & Prognosis

- Infection usually self-limited in mothers
 - Immunocompromised individuals may become severely ill or die
 - May be fatal in individual with sickle cell anemia
- 17-33% of women who become infected during pregnancy transmit infection to fetus
 - Risk of fetal loss 8-17% (before 20-wk gestation); 2-6% (after 20-wk gestation)
 - Stillbirth may occur from 1 through 11 wk after maternal seroconversion
 - Reports of spontaneous recovery without transfusion in less severe hydrops
- Normal developmental outcome in most children who survive intrauterine infection with parvovirus, although more recent studies suggest increased risk of neurodevelopmental delays in survivors that required transfusion

Treatment

- Maternal infection in pregnancy should prompt referral to high-risk specialist
- Maternal serology for parvovirus B19 specific IgG and IgM
- Amniocentesis for viral polymerase chain reaction
- Weekly US to exclude hydrops up to 11 wk following seroconversion
- Monitor fetal anemia with MCA peak systolic velocity
- Intrauterine transfusion for fetal anemia when MCA-PSV > 1.5 multiples of the median (MoM)
 - Posttransfusion hematocrit drop very rapid in parvovirus B19 infection, possibly due to hemolytic process

SELECTED REFERENCES

1. American College of Obstetricians and Gynecologists: Practice bulletin no. 151: Cytomegalovirus, parvovirus B19, varicella zoster, and toxoplasmosis in pregnancy. *Obstet Gynecol.* 125(6):1510-25, 2015
2. Melamed N et al: Fetal thrombocytopenia in pregnancies with fetal human parvovirus-B19 infection. *Am J Obstet Gynecol.* 212(6):793.e1-8, 2015
3. Crane J et al: Parvovirus B19 infection in pregnancy. *J Obstet Gynaecol Can.* 36(12):1107-16, 2014
4. Macé G et al: Clinical presentation and outcome of 20 fetuses with parvovirus B19 infection complicated by severe anemia and/or fetal hydrops. *Prenat Diagn.* 34(11):1023-30, 2014

KEY FACTS

TERMINOLOGY

- Toxoplasmosis is T in TORCH infections
- Transplacental infection with protozoan *Toxoplasma gondii*

IMAGING

- Nonshadowing intracranial and intrahepatic calcifications
- Fetal growth restriction, ventriculomegaly, echogenic bowel
- Monthly ultrasound when suspected or confirmed infection to look for sequelae
- Fetal MR to evaluate brain
- Confirm fetal infection by amniocentesis or cord blood sampling for viral polymerase chain reaction

TOP DIFFERENTIAL DIAGNOSES




- Cytomegalovirus
- Varicella (chickenpox)
- Herpes simplex virus type 2

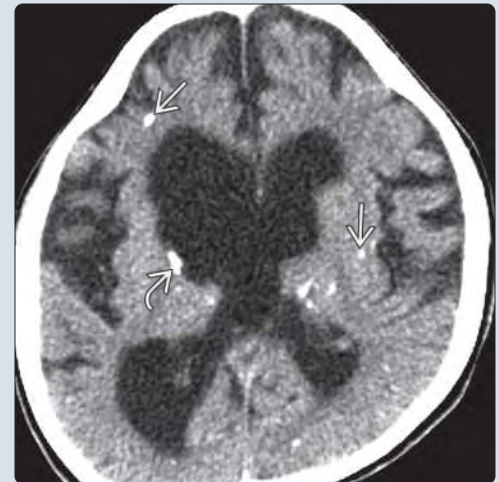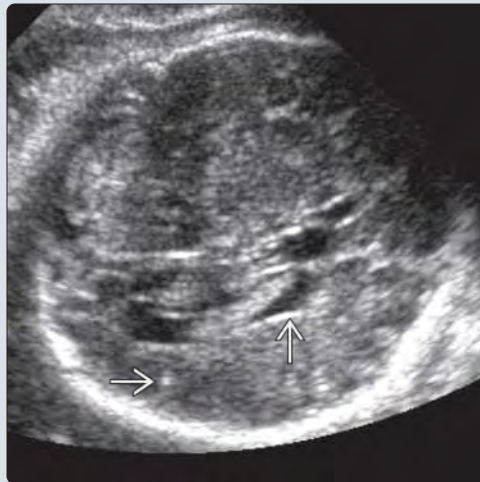
PATHOLOGY




- 3 principal routes of infection in humans
 - Ingestion of inadequately cooked (infected) meat
 - Ingestion of oocytes from contaminated soil or water
 - Transplacental

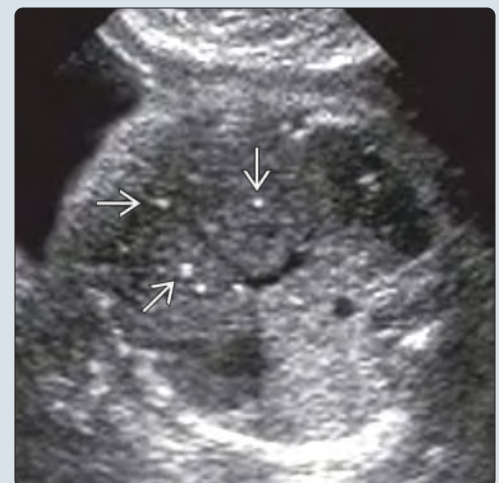
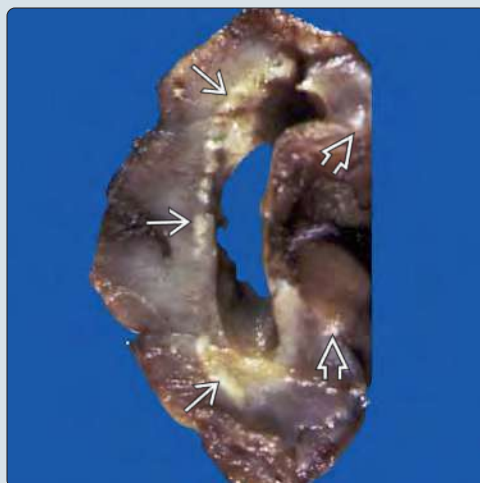CLINICAL ISSUES

- All positive screening tests in pregnancy should be confirmed in toxoplasmosis reference lab
- Overall risk of congenital infection without maternal treatment = 20-50%
- 1st-trimester infection less likely to result in congenital infection (10-15%) but more likely to be severe
- Later infection with much higher congenital infection rate (up to 60% in 3rd trimester) but generally less severe
- Sequelae of congenital infection include blindness, epilepsy, intellectual impairment
 - Most infected infants asymptomatic at birth; up to 90% develop sequelae

(Left) Axial oblique ultrasound shows subtle periventricular and intraparenchymal calcifications . Calcifications are nonspecific and can be seen with most congenital infections. Diagnosis of suspected cases of toxoplasmosis should be confirmed by amniocentesis or cord blood sampling. (Right) Axial NECT shows punctate calcifications in an infant with congenital toxoplasmosis. Calcifications may either be periventricular  or scattered throughout the parenchyma . Ventriculomegaly is also present.



(Left) This is a cross section of a cerebral hemisphere in a case of congenital toxoplasmosis. There are heavy calcifications around the ventricle  but also generalized in the tissue . This is in contrast to cytomegalovirus where the calcifications are only in the ependyma and periventricular area. (From DP: Placenta.) (Right) Transverse abdominal ultrasound shows multiple punctate nonshadowing calcifications  in the liver of a midtrimester fetus with confirmed toxoplasmosis infection.



TERMINOLOGY

Abbreviations

- Toxoplasmosis is T in TORCH infections

Definitions

- Transplacental infection with protozoan *Toxoplasma gondii*

IMAGING

Ultrasonographic Findings

- Nonshadowing intracranial and intrahepatic calcifications
 - Intracranial calcifications may be periventricular or random in distribution
 - May be subtle and easily missed
- Fetal growth restriction
- Ventriculomegaly, echogenic bowel

Imaging Recommendations

- Monthly ultrasound when suspected or confirmed infection to look for brain abnormalities, calcifications, follow growth
- Fetal MR to evaluate brain, assist in prognostic counseling

DIFFERENTIAL DIAGNOSIS

Other Congenital Infections

- Significant overlap in imaging findings
 - Intrahepatic and intracranial calcifications most common finding
- Requires maternal/fetal serology to make definitive diagnosis
- **Cytomegalovirus**
 - Most common in utero infection
 - Calcifications, microcephaly, echogenic bowel
- **Varicella (chickenpox)**
 - Calcifications, skin lesions, limb anomalies
- **Herpes simplex virus type 2**
 - Echogenic bowel, ventriculomegaly

Echogenic Bowel, Abdominal Calcifications

- Multiple etiologies, including aneuploidy, bowel obstruction, meconium ileus

PATHOLOGY

General Features

- Etiology
 - *Toxoplasma gondii* is unicellular protozoan
 - Cats are definitive hosts: Oocysts shed in feces → soil contamination
 - Detection of IgM not sufficient to prove recent infection; high titer IgM often detectable for years
 - 3 principal routes of infection in humans
 - Ingestion of inadequately cooked (infected) meat
 - Ingestion of oocytes from contaminated soil or water
 - Transplacental

CLINICAL ISSUES

Presentation

- Maternal infection most often asymptomatic; symptoms occur in 10-20% of infected adults
- If immunocompromised, including HIV, may be fatal

- Transplacental passage in HIV-infected women enhanced and may result in higher risk of congenital infection

- Congenital infection causes classic triad of hydrocephalus, intracranial calcifications, chorioretinitis
 - Fetal death, abortion common

Demographics

- Epidemiology
 - Estimated 400-4,000 cases of congenital toxoplasmosis per year in USA with 750 deaths
 - Seroprevalence 10-40% in developed countries; 60-75+% in developing countries

Natural History & Prognosis

- Overall risk of congenital infection without maternal treatment = 20-50%
- 1st-trimester infection less likely to result in congenital infection (10-15%); more likely to be severe or result in abortion
- The later in gestation, the higher the transmission rate: 25% in 2nd trimester, 60+% in 3rd trimester
- Host immune response protective but can also result in inflammatory damage
- Sequelae of congenital infection include blindness, epilepsy, intellectual impairment
 - Most infected infants asymptomatic at birth; up to 90% develop sequelae
 - Effect of prenatal therapy variable
 - May decrease fetal infection rate or ameliorate severity of neurologic sequelae

Treatment

- All positive screening tests in pregnancy should be confirmed in toxoplasmosis reference lab
- Confirm fetal infection by amniocentesis or cord blood sampling for viral PCR
 - Real-time PCR improves detection in amniotic fluid
- Therapy with folate synthesis inhibitors (pyrimethamine/sulfadiazine or sulfadoxine) ± spiramycin in confirmed prenatal and congenital infections
 - Severe side effects including pancytopenia
- Termination of pregnancy is option in confirmed prenatal infection
- Serologic screening of all pregnant women in USA not currently recommended due to low disease prevalence
 - French program established in 1978: Seroprevalence rate has decreased due to screening, education efforts
- Prevention of infection aimed at education
 - Avoidance of raw, undercooked meat

SELECTED REFERENCES

1. American College of Obstetricians and Gynecologists: Practice bulletin no. 151: Cytomegalovirus, parvovirus B19, varicella zoster, and toxoplasmosis in pregnancy. *Obstet Gynecol.* 125(6):1510-25, 2015
2. Dhakal R et al: Significance of a positive Toxoplasma Immunoglobulin M test result in the United States. *J Clin Microbiol.* 53(11):3601-5, 2015
3. Mouri O et al: The impact of lowering the cut-off value on the sensitivity of the Platelia Elisa IgG (Bio-Rad) test for toxoplasmosis diagnosis. *Parasite.* 22:22, 2015
4. Tanimura K et al: The IgG avidity value for the prediction of Toxoplasma gondii infection in the amniotic fluid. *J Infect Chemother.* 21(9):668-71, 2015

KEY FACTS

TERMINOLOGY

- Fetal varicella syndrome/embryopathy
- Transplacental infection of fetus following maternal chickenpox infection

IMAGING

- Intrahepatic and intracranial calcifications
- Polyhydramnios due to neurologic impairment of swallowing
- Limb hypoplasia, contractures

TOP DIFFERENTIAL DIAGNOSES

- Other limb reduction defects
 - Terminal transverse defects, oligodactyly
 - Amniotic bands
- Other congenital infections
 - Significant overlap in imaging findings
 - Intrahepatic and intracranial calcifications most common findings

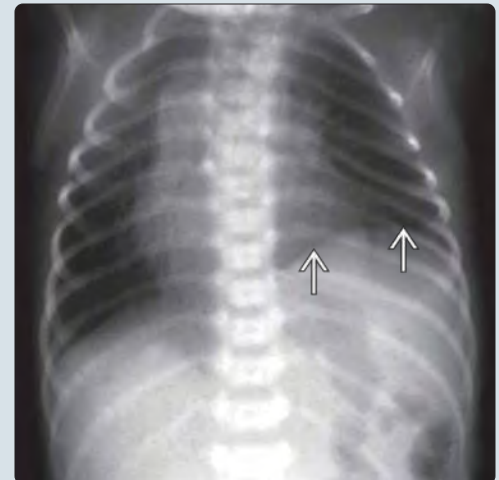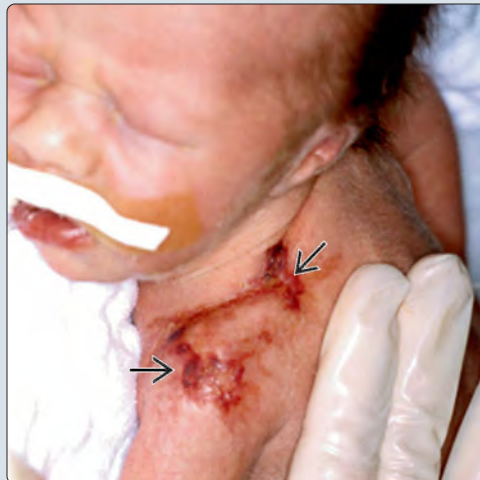PATHOLOGY

- Neurotropic virus: Sequelae due to neurologic damage in utero
- After recovery, virus remains dormant in dorsal root ganglia in the spinal cord; reactivated as shingles (herpes zoster)

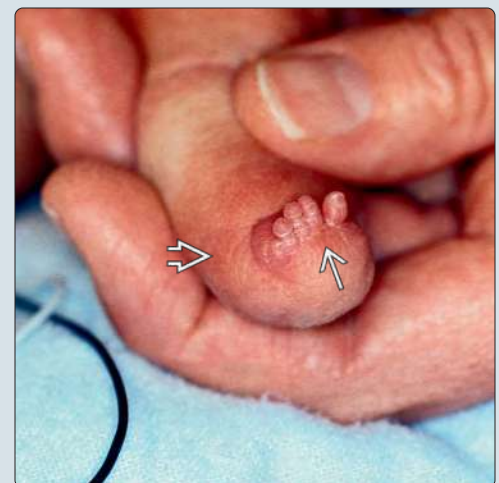
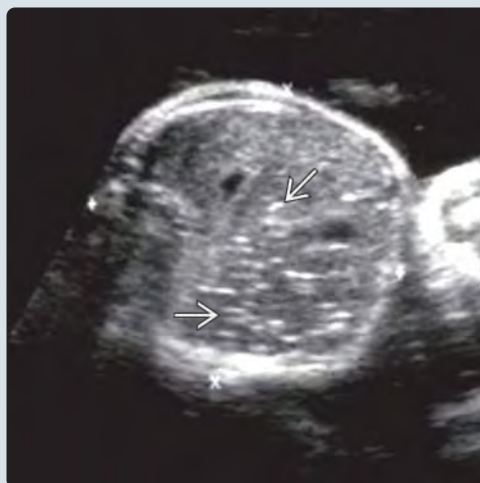CLINICAL ISSUES

- Maternal varicella infection before 20-weeks gestation ~ 6% fetal transmission
 - 1/3 of infected fetuses have clinical manifestations, usually cutaneous
 - 1-2% of infected fetuses will have severe clinical stigmata of fetal varicella syndrome
- Peripartum maternal chickenpox associated with 25% risk of life-threatening neonatal infection
- Maternal zoster outbreak in pregnancy **not** associated with risk of fetal infection or malformation
- Immunization now recommended for school-aged children under age 13, other nonimmune individuals

(Left) Clinical photograph shows a preterm infant born at 32-weeks gestation with fetal varicella syndrome. Preterm labor was triggered by massive polyhydramnios. Note the zoster lesion on the left shoulder. Ipsilateral diaphragmatic paralysis was noted. **(Right)** Anteroposterior radiograph shows the elevated hemidiaphragm in the same neonate with diaphragmatic paralysis secondary to fetal varicella syndrome. Bulbar dysphagia was also noted in this infant.



(Left) Axial ultrasound through the fetal abdomen shows multiple nonshadowing hepatic calcifications in a 3rd-trimester fetus. The mother had been seriously ill with chickenpox at 15-weeks gestation. Massive polyhydramnios was also present. **(Right)** Clinical photograph of the arm of a preterm infant with fetal varicella syndrome shows a terminal transverse limb defect. The arm was mildly atrophic. Note the tiny digital "nubbins".



TERMINOLOGY

Abbreviations

- Varicella-zoster virus (VZV)

Synonyms

- Fetal varicella syndrome/embryopathy

Definitions

- Transplacental infection of fetus following maternal chickenpox infection
 - Highest risk when acquired at 8- to 20-weeks gestation

IMAGING

Ultrasonographic Findings

- Intrahepatic and intracranial calcifications
- Polyhydramnios due to neurologic impairment of swallowing
- Limb hypoplasia, contractures
- Paradoxical diaphragmatic motion on real-time sonography due to unilateral paralysis

Imaging Recommendations

- Monthly ultrasound for assessment of late findings of fetal varicella syndrome

DIFFERENTIAL DIAGNOSIS

Other Limb Reduction Defects

- Terminal transverse defects, oligodactyly
- Amniotic bands

Other Congenital Infections

- Significant overlap in imaging findings
 - Intrahepatic and intracranial calcifications most common
- Requires maternal/fetal serology to be definitive
- **Cytomegalovirus**
 - Most common in utero infection
 - Calcifications, microcephaly, echogenic bowel
- **Parvovirus B19 (5th disease)**
 - Attacks red blood cell precursors → anemia
 - Ascites, hydrops
 - Calcifications would be unusual
- **Toxoplasmosis (*Toxoplasma gondii*)**
 - Human infection from undercooked, infected meats, contaminated soil or water
 - Calcifications, hepatosplenomegaly
- **Herpes simplex virus type 2**
 - Most infections occur during vaginal delivery
 - Echogenic bowel, ventriculomegaly

PATHOLOGY

General Features

- Etiology
 - Neurotropic virus
 - Sequelae due to neurologic damage in utero
 - After recovery, virus remains dormant in dorsal root ganglia; reactivated as shingles (herpes zoster)
 - Maternal zoster outbreak in pregnancy (shingles) **not** associated with risk of fetal infection or malformation

CLINICAL ISSUES

Presentation

- Maternal pruritic pustular rash
 - While most cases are mild and resolve in 5-10 days, serious, even life-threatening complications can occur, including in pregnant women
- Elevated maternal serum and amniotic fluid α-fetoprotein and amniotic fluid acetylcholinesterase
 - May correlate with fetal skin, muscle, and nerve damage from VZV
- Neonate with fetal varicella syndrome with multiple abnormalities
 - Cutaneous lesions in dermatomal distribution, limb hypoplasia/atrophy, chorioretinitis, segmental intestinal atresia, varying degrees of neurologic dysfunction

Demographics

- Epidemiology
 - Majority of reproductive-aged women (> 90%) immune
 - Immunization now recommended for school aged children under age 13, other nonimmune individuals
 - Up to 90% effective in preventing chickenpox
 - Maternal varicella infection before 20-weeks gestation ~ 6% fetal transmission
 - 1/3 of infected fetuses have clinical manifestations, usually cutaneous
 - 1-2% of infected fetuses will have severe clinical stigmata of fetal varicella syndrome
 - Peripartum maternal chickenpox associated with 25% risk of life-threatening neonatal infection

Natural History & Prognosis

- Increased incidence of fetal/neonatal death
- Asymptomatic, structurally normal children usually neurodevelopmentally normal
- Neurologic impairment dependent upon location, extent of lesions

Treatment

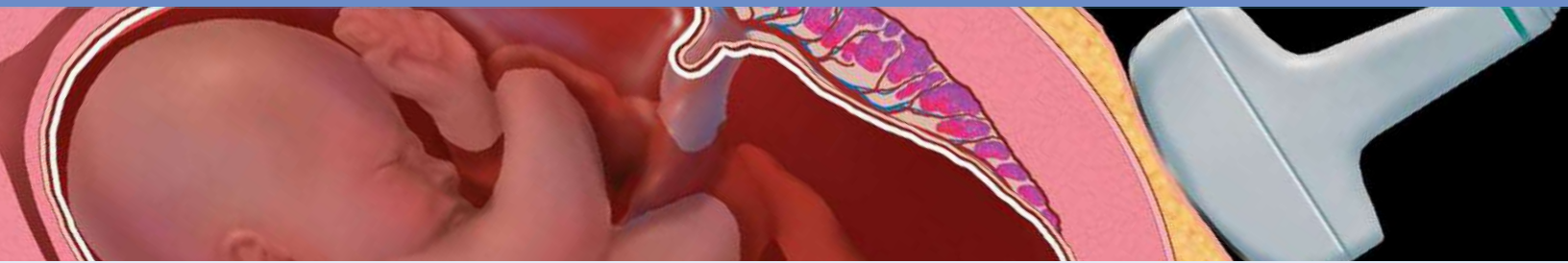
- Documentation of fetal infection
 - Amniocentesis/cordocentesis for viral polymerase chain reaction
- Exposure of seronegative pregnant woman to chickenpox
 - Passive immunization with varicella-zoster immunoglobulin (VZIG)
 - Reduces maternal complications; may prevent fetal varicella syndrome
 - Serious complications at any gestational age → hospitalization, intravenous Acyclovir
 - Delay delivery at least 5 days after onset of maternal rash to decrease risk of neonatal varicella
 - Treatment of infant with VZIG if delivered less than 5-7 days after onset of maternal rash

SELECTED REFERENCES

1. Mandelbrot L: Fetal varicella - diagnosis, management, and outcome. *Prenat Diagn.* 32(6):511-8, 2012
2. Tongsong T et al: Prenatal sonographic diagnosis of congenital varicella syndrome. *J Clin Ultrasound.* 40(3):176-8, 2012
3. Lamont RF et al: Varicella-zoster virus (chickenpox) infection in pregnancy. *BJOG.* 118(10):1155-62, 2011

This page intentionally left blank

SECTION 15
Fluid, Growth, and Well-Being



Approach to Fetal Well-Being	1028
Fetal Growth Restriction	1034
Macrosomia	1038
Fetal Anemia	1040
Pertinent Differential Diagnoses	
Polyhydramnios	1044
Oligohydramnios	1048
Hydrops	1052

Introduction

Assessment of fetal well-being is designed to identify fetuses at risk for in utero death or asphyxia-mediated damage and affect expeditious and safe delivery. Using the biophysical profile score, a 60-70% reduction in stillbirth rates has been shown in tested populations. Perinatal fetal hypoxemia leads to irreversible tissue damage and is related to a myriad of problems for the neonate, child, and adult. Fetal asphyxia is proposed to be a contributor to cerebral palsy, learning disability, and adult-onset hypertension and cardiovascular disease. The goal of ultrasound surveillance of the viable fetus is to identify potentially damaging degrees of fetal asphyxia and initiate timed intervention. Maternal and fetal conditions that place the pregnancy at risk for fetal hypoxia include hypertension, preeclampsia, fetal growth restriction, maternal diabetes, maternal collagen vascular disease, umbilical cord anomalies, infection, and postdate pregnancy. Evaluation of fetal growth, amniotic fluid, fetal biophysical profile score, and cardiovascular/placental function are the ultrasound tools used for assessment of fetal well-being.

Fetal Growth

Accurate dating of a pregnancy is essential for evaluating fetal growth. Last menstrual period dates are often unreliable. First trimester crown rump length measurement is the most accurate way to determine gestational age (\pm 5-7 days). Using fetal biometry to date pregnancies is accurate in the second trimester (\pm 7-10 days) but not the third trimester (\pm 3-4 weeks). In a situation of unknown dates, it is helpful to use nontraditional biometric measurements, such as transcerebellar diameter (TCD ~ gestational age between 18-24 weeks), or look for long bone ossification centers (distal femoral epiphysis seen at \geq 32 weeks and proximal tibial epiphysis seen at \geq 35 weeks). Extreme care should be taken when changing "age" of the fetus later in pregnancy, as you may miss the diagnosis of fetal growth restriction or macrosomia.

Estimated fetal weight (EFW) is calculated from fetal biometry measurements. The standard fetal biometric measurements are biparietal diameter, head circumference, abdominal circumference (AC), and femur length. EFW formulas are heavily weighted toward the AC, and a small AC is a strong predictor for fetal growth restriction (FGR).

A fetus is considered small for gestational age (SGA) if the EFW is $<$ 5th or 10th percentile. Not all SGA fetuses are growth restricted. The SGA fetus may be constitutionally small but healthy and normal; however, the FGR fetus is at risk for hypoxia. Placental insufficiency results in \downarrow glucose delivery to the fetus. Compensatory glycogenolysis leads to \downarrow fetal liver size and \downarrow AC. This asymmetric growth restriction pattern is a hallmark finding in FGR presenting in the 3rd trimester. Early onset, often symmetric, growth restriction is concerning for a chromosomal abnormality.

Amniotic Fluid

Amniotic fluid volume (AFV) is evaluated in every second and third-trimester study. AFV can be assessed subjectively or semiquantitatively by measuring fluid pockets. The maximum vertical pocket (MVP) measurement is the anterior to posterior distance of the largest fluid pocket within the uterus, void of fetal parts and cord. The more commonly utilized amniotic fluid index (AFI) measurement is the sum of MVPs in four quadrants of the uterus. AFV changes with

advancing gestational age. In general, MVP values of 2-8 and AFI values of 5-20 are considered normal. AFI $<$ 5 cm is associated with a higher risk of fetal morbidity.

AFV also reflects fetal cardiovascular well-being. With normal placentation and normal cardiac output, the fetal kidneys are well perfused, and urine output is normal. However, in the presence of hypoxemia, reflex redistribution of cardiac output leads to redistribution of blood to the fetal brain, heart, thymus, and placenta. There is vasoconstriction to other organs, such as the kidneys, leading to decreased urine output. Oligohydramnios is considered a feature of chronic hypoxemia, and it is postulated that the amount of time needed to see moderate to severe AFI change in the setting of hypoxemia is three weeks. More acute indicators of hypoxemia are detectable with fetal biophysical profile (BPP) score and Doppler assessment.

Biophysical Profile

The BPP tests four parameters over a 30-minute observation period. The fetus receives a score of zero or two points for each parameter, and the sum is the BPP score. A score of 6/8 or 8/8 is normal. Most fetuses that score \leq 6/8 need additional monitoring. A complete BPP includes the addition of electronic fetal monitoring (nonstress test) for a total score of 10 points. A score of 8/10 or 10/10 is considered normal. A score of 6/10 is equivocal and \leq 4/10 is abnormal. A fetus may score 8/8 or 10/10 in $<$ 30 minutes, but any other score requires a full 30 minutes of observation.

A normal BPP score is almost never associated with abnormal fetal pH and is a reliable and accurate measure of normal tissue oxygenation. An abnormal BPP score suggests a higher risk for fetal acidemia and is a strong predictor of intrauterine death within a week. Equivocal BPP tests are most often repeated. Cessation of fetal movement follows a predictable course: Thoracic movements ("breathing") disappear first, followed by loss of tone and finally gross trunk and spine movement. Low fluid is a sign of chronic hypoxemia.

Doppler

Doppler assessment of the placental and fetal circulation is essential for evaluating fetal well-being. The umbilical artery (UA), middle cerebral artery (MCA), uterine artery (Ut Art), ductus venosus (DV), and umbilical vein (UV) are commonly investigated vessels. UA flow is low resistive with decreasing systolic/diastolic ratios (S/D) with advancing gestational age. The MCA has relatively less diastolic flow than the UA. The DV waveform is distinctive with systolic, diastolic, and atrial contraction waves. Umbilical venous flow is uniform and may demonstrate fetal respiratory variation. Ut Art flow is low resistive after 24 weeks.

In the setting of hypoxemia or poor placentation, Doppler waveform abnormalities may predate changes in AFV and growth. Absent or reversed diastolic flow in the UA reflects placental vascular dysfunction. Compensatory \uparrow cardiac output to the fetal brain results in \uparrow MCA diastolic flow. The resultant \downarrow UA diastolic flow and \uparrow MCA diastolic flow is a reversal of the normal relationship between these vessels. In the DV, reversed A-wave flow reflects right heart stress with venous flow reversal during atrial contraction. UV pulsatile flow also reflects \uparrow right atrial pressures. Ut Art shows \uparrow resistive flow and a postsystolic notch, reflecting \uparrow spiral artery flow resistance.

AFI vs. Gestational Age

Gestation Age (Weeks)	5th Percentile AFI (cm)	50th Percentile AFI (cm)	95th Percentile AFI (cm)
24	9.8	14.7	21.9
25	9.7	14.7	22.1
26	9.7	14.7	22.3
27	9.5	14.6	22.6
28	9.4	14.6	22.8
29	9.2	14.5	23.1
30	9.0	14.5	23.4
31	8.8	14.4	23.8
32	8.6	14.4	24.2
33	8.3	14.3	24.5
34	8.1	14.2	24.8
35	7.9	14.0	24.9
36	7.7	13.8	24.9
37	7.5	13.5	24.4
38	7.3	13.2	23.9
39	7.2	12.7	22.6
40-42	6.9-7.1	11-12.3	17.5-21.4

Modified from Moore TR et al: The amniotic fluid index in normal human pregnancy. *Am J Obstet Gynecol.* 162:1168-73, 1990.

Umbilical Artery S:D Ratio Percentile

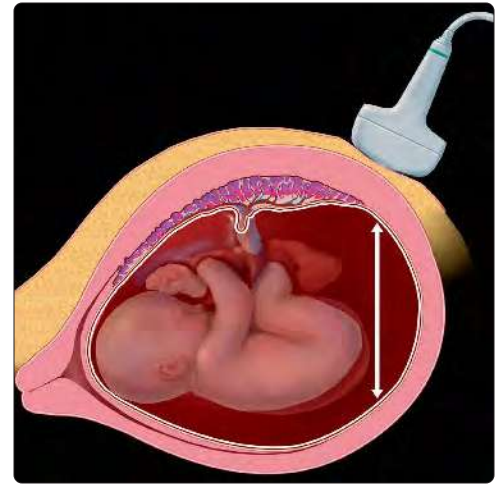
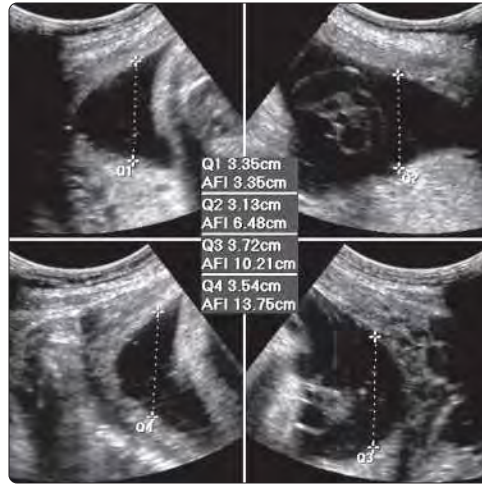Gestational Age	5th Percentile	10th Percentile	50th Percentile	90th Percentile	95th Percentile
24-27	2.17-2.41	2.35-2.62	3.12-3.48	4.15-4.63	4.50-5.02
28	2.09	2.27	3.02	4.02	4.36
29	2.03	2.20	2.92	3.89	4.22
30	1.96	2.13	2.83	3.78	4.10
31	1.90	2.06	2.75	3.67	3.98
32	1.84	2.00	2.67	3.57	3.87
33	1.79	1.94	2.60	3.48	3.77
34	1.73	1.88	2.53	3.39	3.68
35	1.68	1.83	2.46	3.30	3.59
36	1.64	1.78	2.40	3.23	3.51
37	1.59	1.73	2.34	3.15	3.43
38	1.55	1.69	2.28	3.08	3.36
39	1.51	1.64	2.23	3.02	3.29
40	1.47	1.60	2.18	2.96	3.22

Modified from Acharya G et al: Reference ranges for serial measurements of umbilical artery Doppler indices in the second half of pregnancy. *Am J Obstet and Gynecol.* 192:937-44, 2005.

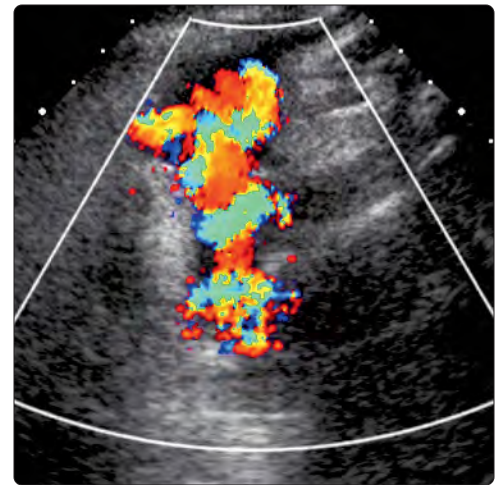
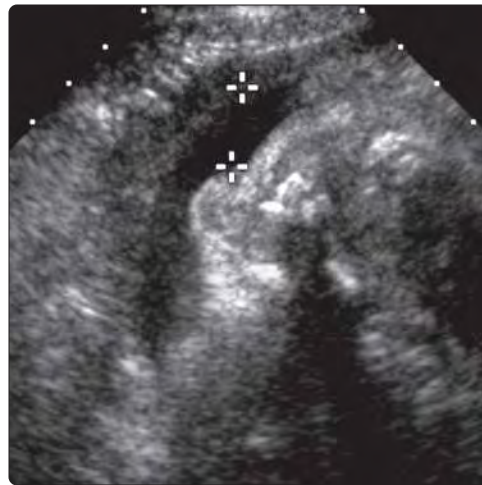
Biophysical Profile Score

Parameter	Condition Met for Score = 2 (Otherwise Score = 0), Observation Time = 30 Minutes
Thoracic movement ("breathing")	≥ 1 episode 30-second continuous breathing (hiccups acceptable)
Gross body movement	≥ 3 discrete body movements (trunk roll, spine flexion/extension, gross limb movement)
Fetal tone	≥ 1 episode active extension then flexion of 1 limb (hand open and close acceptable)
Amniotic fluid	≥ 1 pocket of fluid measuring ≥ 2 cm in vertical axis
Fetal monitor (nonstress test)	≥ 2 heart rate accelerations (> 15 BPM for 15 sec) + 1 fetal movement

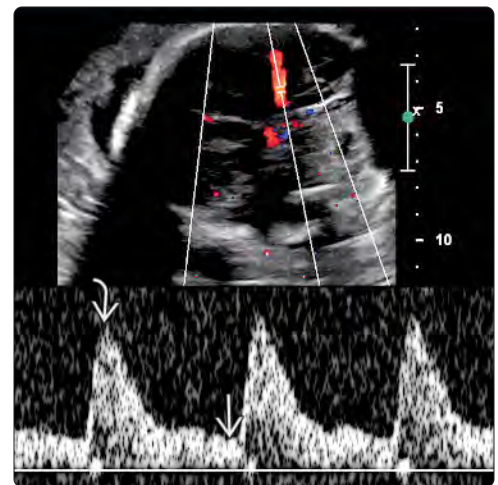
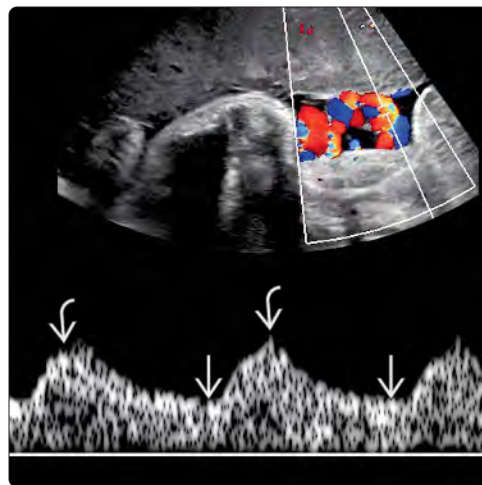
(Left) Amniotic fluid index (AFI) calculation involves measuring the anterior-to-posterior depth of the largest pockets of fluid in the 4 uterine quadrants (calipers) and calculating the sum of the 4 measurements. Care is taken not to include umbilical cord or fetal parts in the measurement. **(Right)** Another objective measurement of fluid is the maximum vertical pocket. The largest uterine fluid collection is found, and the maximum anterior-to-posterior distance is measured.

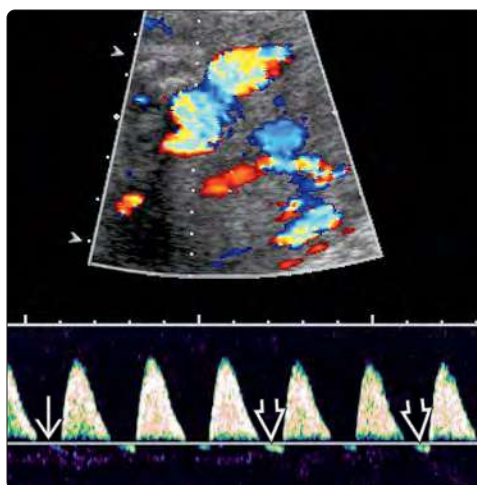
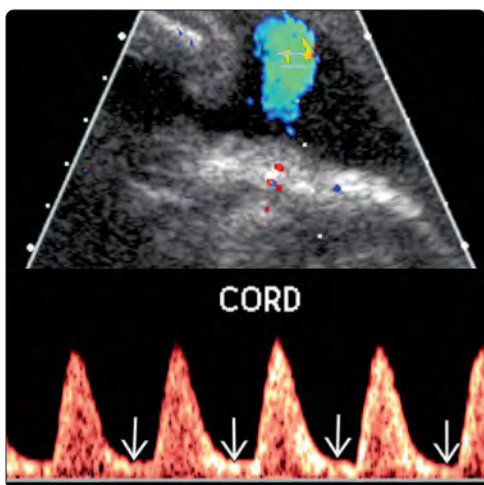


(Left) Transverse ultrasound of a fetus with oligohydramnios shows what initially is thought to represent a small pocket of fluid (calipers). **(Right)** However, color Doppler ultrasound of the same area shows that the pocket of fluid is actually a space filled with umbilical cord. Using color Doppler when measuring fluid pockets leads to more accurate assessment of amniotic fluid volume.

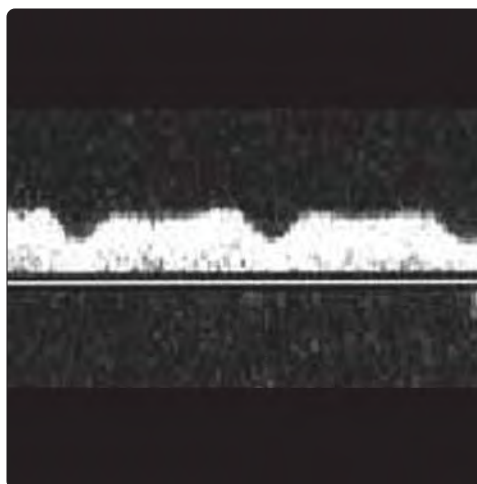
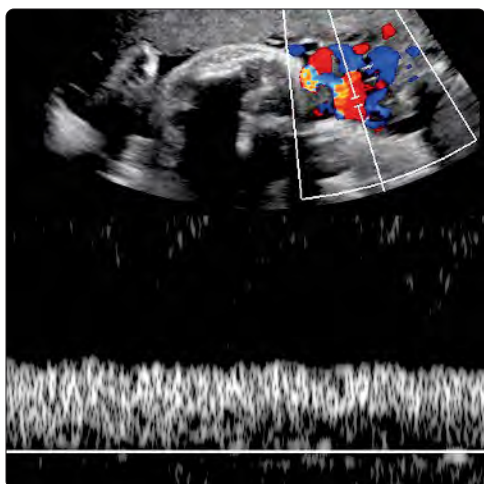


(Left) The normal umbilical artery waveform has low resistive flow with continuous diastolic flow. The systolic/diastolic ratio is calculated by dividing the peak systolic velocity by the end-diastolic velocity. **(Right)** In contrast, the normal middle cerebral artery waveform, seen here in the same fetus, is relatively high resistance with less diastolic flow compared to systolic flow.

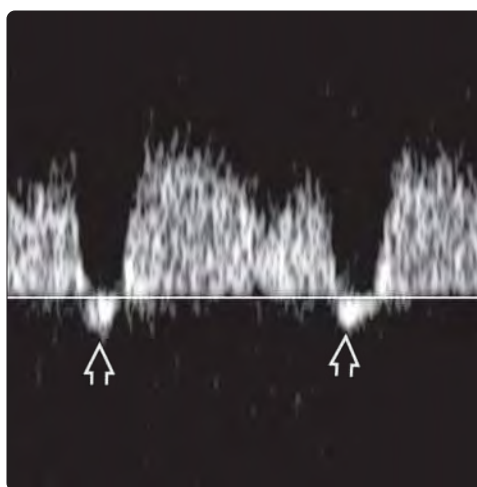
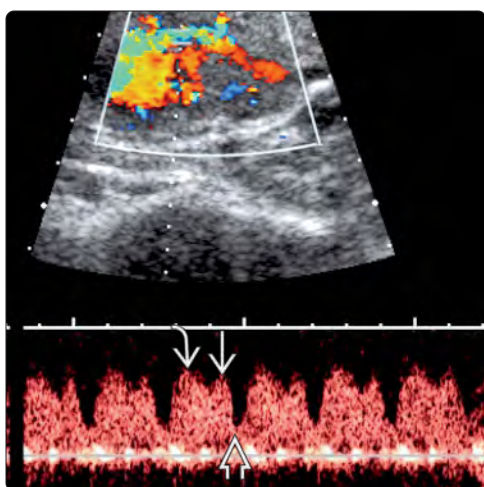




(Left) In a 3rd-trimester pregnancy complicated by fetal growth restriction (FGR), the cord Doppler waveform demonstrates a high-resistance pattern with little diastolic flow \Rightarrow . The finding suggests placental insufficiency as a cause for the FGR. **(Right)** In another fetus with oligohydramnios and severe FGR, the diastolic flow is occasionally absent \Rightarrow and often reversed \Rightarrow . This finding is associated with a higher risk for impending intrauterine fetal demise, and delivery should be considered.

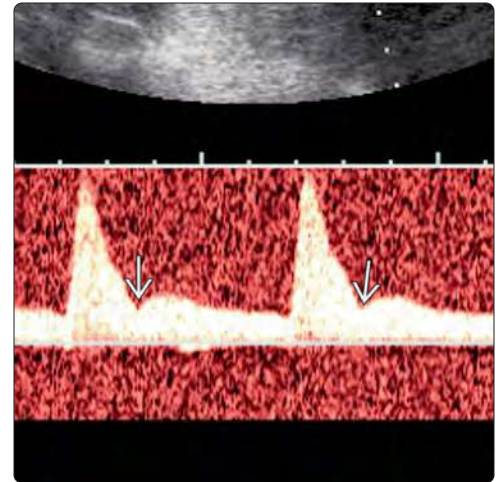
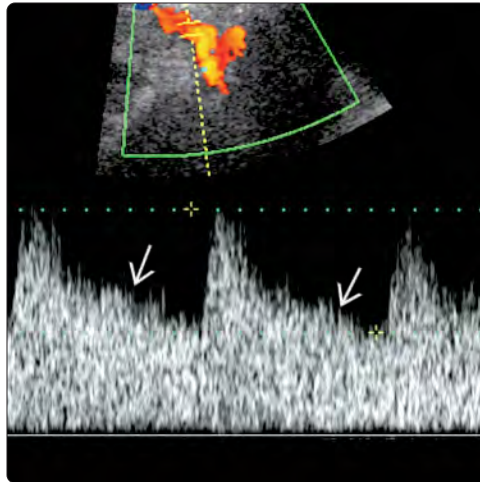


(Left) Pulsed Doppler ultrasound of the normal umbilical vein shows continuous nonpulsatile antegrade venous flow toward the fetus. Umbilical venous flow showing respiratory variability is also normal. **(Right)** Pulsed Doppler ultrasound of the umbilical vein in a fetus with FGR from placental insufficiency shows pulsatile flow in the umbilical vein. This finding reflects an increased right heart pressure gradient secondary to increased cardiac work against an increasingly resistive placenta.

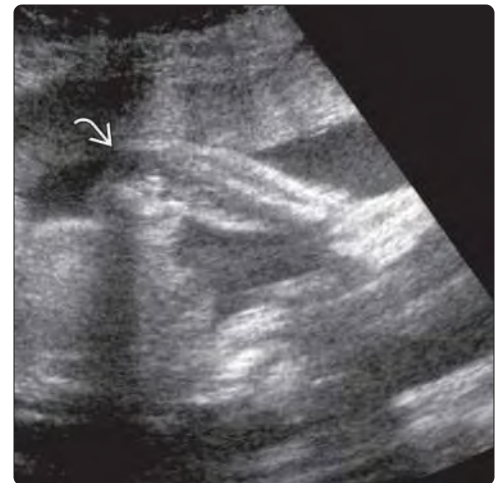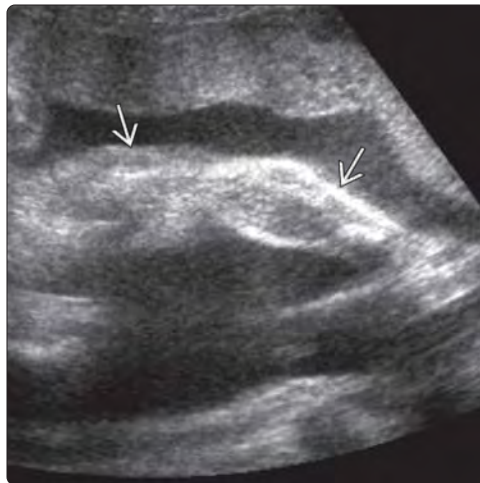


(Left) Normal ductus venosus waveform demonstrates low-resistive systolic \Rightarrow , diastolic \Rightarrow , and atrial \Rightarrow components with antegrade flow toward the fetal heart throughout the cardiac cycle. **(Right)** Abnormal ductus venosus flow is seen in this case. The atrial contraction component (A-wave) shows reversal of flow \Rightarrow . This finding is secondary to right heart stress, often from cardiac decompensation associated with FGR.

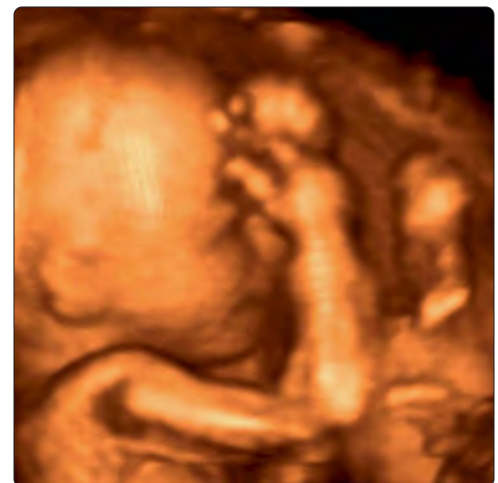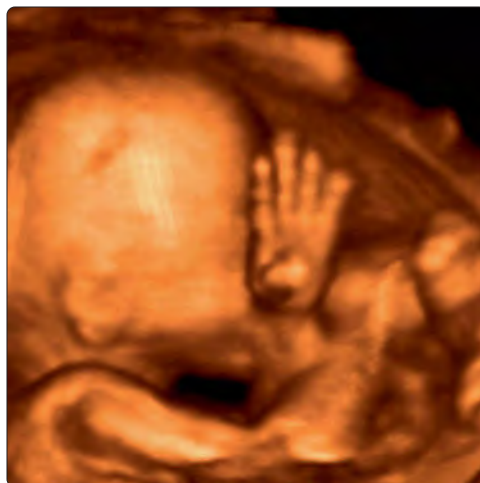(Left) Normal uterine artery Doppler waveform in the 3rd trimester shows low resistive flow with considerable and gently sloping diastolic flow. **(Right)** In a 28-week pregnancy complicated by FGR, the uterine artery Doppler waveform is highly resistive (little diastolic flow), and there is a postsystolic notch. This pattern is abnormal after 24 weeks and reflects increased spiral artery flow resistance and poor placentation.

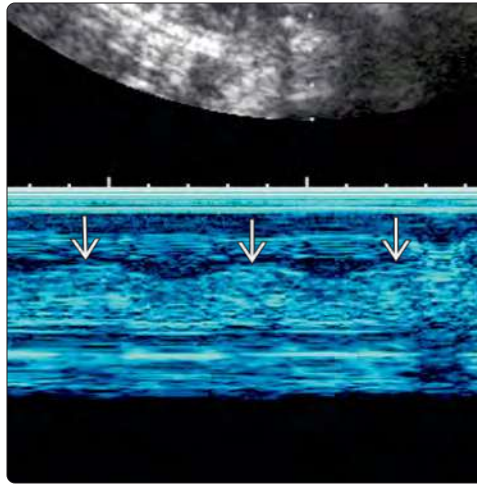
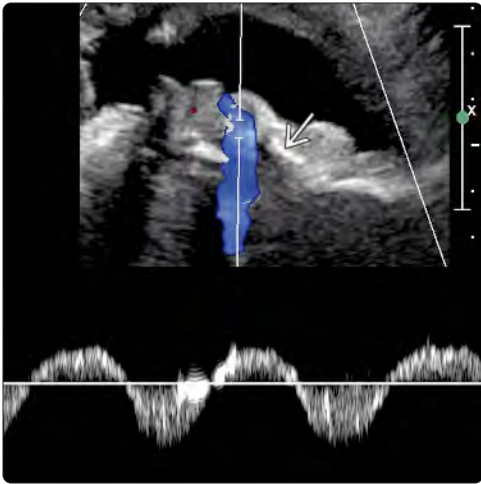


(Left) Longitudinal ultrasound of the lower extremities shows that the near-field fetal limb is extended. **(Right)** A few moments later, the leg is now flexed at the knee. Fetal tone is measured by the ability of the fetus to extend then flex a limb. The normal resting posture is flexion.

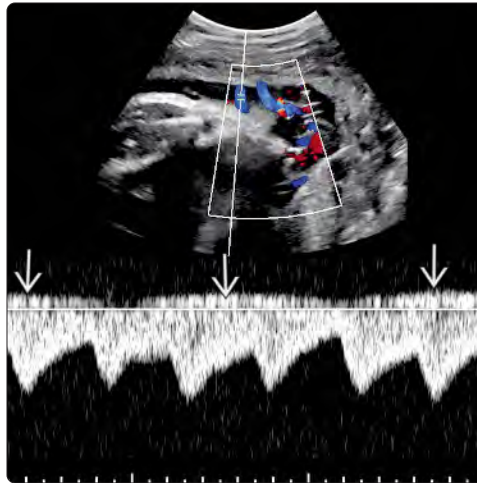
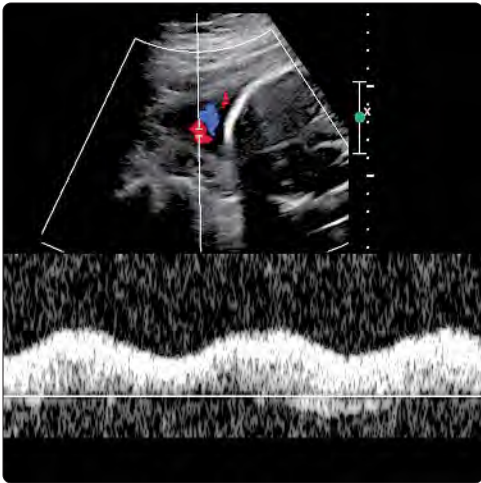


(Left) 3D ultrasound shows the fetal hand in an open position. **(Right)** The hand is now closed. One or more episodes of opening and closing the hand or extending and flexing a limb would be necessary in order to score a 2 for tone for biophysical profile assessment.



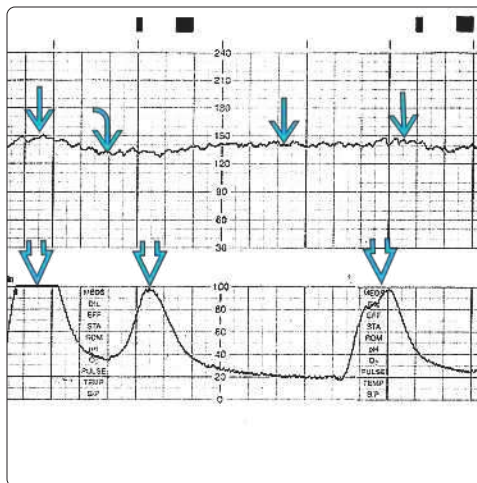


(Left) Documentation of nasal fetal breathing in this case is done with Doppler. Note nasal bone \blacktriangleright . Color Doppler shows flow through the nasal passage (blue flow from inhalation, amniotic fluid moves away from the transducer). Pulse Doppler shows continuous rhythmic inhalation and expiration over a period of time. (Right) M-mode ultrasound over the diaphragm can also be used to document thoracic cage movement. Rhythmic continuous diaphragm motion \blacktriangleright is shown.



(Left) Rhythmic or irregular fetal breathing can be reflected in the umbilical vein Doppler waveform and should not be confused with pulsatile umbilical vein flow. (Right) Fetal motion and breathing can lead to irregular umbilical artery flow. In this case, the overlapping umbilical vein rhythmic motion \blacktriangleright , from breathing, is also seen. Umbilical artery and venous flow assessment should be done during fetal rest.

BPD	29w5d \pm 15d
HC	29w2d \pm 14d
AC	26w1d \pm 15d
FL	29w1d \pm 15d



(Left) Asymmetric FGR is demonstrated here by the small abdominal circumference (AC) compared to other measurements in a fetus with placental insufficiency. The AC is the first measurement to lag secondary to glycogenolysis and decreased liver size. (Right) Abnormal fetal monitoring nonstress test strip shows lack of cardiac acceleration \blacktriangleright and a mild deceleration \blacktriangleright during 3 uterine contractions \blacktriangleright in a nonlaboring patient.

KEY FACTS

TERMINOLOGY

- Small for gestational age (SGA) is not always fetal growth restriction (FGR)
 - SGA: Fetus is small but healthy, not growth restricted
 - FGR: Fetus is pathologically small, growth restricted

IMAGING

- Best clue for uteroplacental insufficiency as cause of FGR
 - EFW < 10th percentile + AC < 10th percentile + abnormal Dopplers + oligohydramnios
- Umbilical artery (UA) findings
 - Initial ↑ systolic/diastolic ratio
 - Eventual absent end diastolic flow
 - Final reversed end diastolic flow
- Umbilical vein pulsatile flow
- Ductus venosus shows reversed A-wave
- Tricuspid regurgitation
- Uterine artery postsystolic notch
- ↓ middle cerebral artery systolic/diastolic ratio


- Other FGR associations
 - Twin-twin transfusion
 - Triploidy (early severe FGR)
 - Trisomy 18, trisomy 13
 - Anomalies

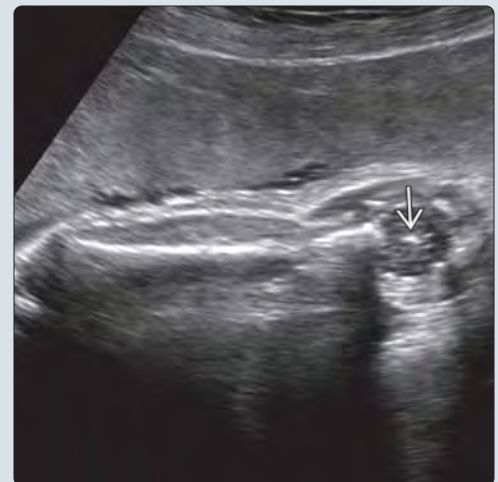
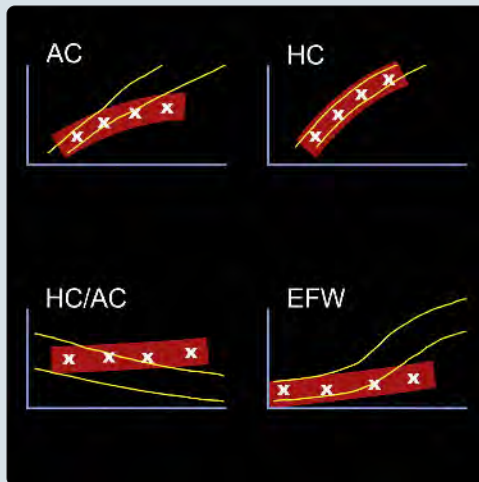
TOP DIFFERENTIAL DIAGNOSES




- Constitutionally small fetus
- Oligohydramnios without placental insufficiency
- Mild skeletal dysplasia

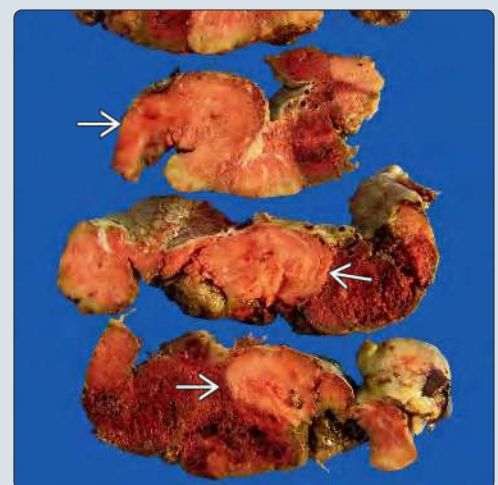
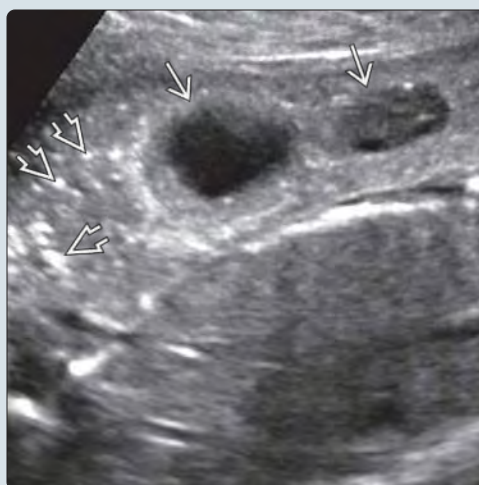
CLINICAL ISSUES

- Is pregnancy dated correctly?
- Treat maternal conditions aggressively
- FGR fetuses have 4x ↑ in adverse outcome
- Preterm management difficult; risk of preterm delivery balanced with risk of intrauterine demise
- Consider karyotype if early FGR

(Left) Chart of biometric measurements shows estimated fetal weight (ESW) < 10th percentile with most marked growth delay involving AC. Pattern is typical for fetal growth restriction (FGR) from uteroplacental insufficiency. (Right) Dating was uncertain in this fetus with late entry to care & oligohydramnios. Ossification of proximal humeral epiphysis  indicates the fetus should be at least 38 wk but is only measuring 33 wk. Evaluating epiphyseal ossification centers can be helpful in cases when dating is unknown.



(Left) US of the placenta at 27 weeks in a pregnancy complicated by FGR, oligohydramnios, and maternal preeclampsia shows early placental calcifications  and increased sonolucencies , which did not have internal flow. (Right) Placental causes of FGR affect large areas of the parenchyma. These areas of villous pallor  occupy > 50% of the parenchyma. Lesions such as these are often not seen with ultrasound.



TERMINOLOGY

Abbreviations

- Fetal growth restriction (FGR)

Synonyms

- Intrauterine growth restriction (IUGR)

Definitions

- Estimated fetal weight (EFW) < 10th percentile for gestational age (GA)
 - **Asymmetric FGR:** Small abdominal circumference (AC) compared with head circumference (HC)
 - **Symmetric FGR:** Uniformly small
- Small for gestational age (SGA) is not always FGR
 - SGA: Fetus is small but healthy, not growth restricted
 - FGR: Fetus is pathologically small, growth restricted

IMAGING

General Features

- Best diagnostic clue
 - EFW < 10th percentile + AC < 10th percentile + abnormal Dopplers + oligohydramnios

Ultrasonographic Findings

- Grayscale ultrasound
 - Abnormal biometry
 - AC < 5-10th percentile with poor interval growth
 - EFW calculations heavily weighted to AC
 - HC/biparietal diameter (BPD) relatively preserved
 - Oligohydramnios (from ↓ renal perfusion)
 - **Anomalies and FGR**
 - Aneuploidy
 - Triploidy (early severe FGR)
 - Trisomy 18, trisomy 13 typically with FGR
 - Anomalies associated with FGR
 - Single umbilical artery
 - Echogenic bowel
 - Gastroschisis
 - Cardiovascular anomalies
 - Velamentous cord insertion
 - Multiple gestations
 - Twin-twin transfusion
 - Donor twin with oligohydramnios and FGR
 - Unequal placental sharing in monochorionic gestation
 - Look for marginal/velamentous cord insertion
- Pulsed Doppler
 - Umbilical artery (UA) flow findings with FGR
 - ↑ placental resistance → ↓ diastolic flow
 - Initial ↑ systolic/diastolic (S/D) ratio
 - Eventual absent end diastolic flow (AEDF)
 - Final reversed end diastolic flow (REDF)
 - ↑ cardiac work to perfuse ↑ resistive placenta
 - ↑ atrial pressures → tricuspid regurgitation
 - ↑ ductus venosus (DV) flow resistance
 - Reversal of A-wave
 - Pulsatile flow in umbilical vein
 - ↑ uterine artery resistive index (RI) is early finding
 - RI > 0.6 (after 20-24 weeks)
 - Postsystolic notch after 1st trimester

- ↓ middle cerebral artery (MCA) resistance
 - ↑ MCA diastolic flow
 - MCA S/D ratio becomes < UA S/D ratio
 - "Brain-sparing" physiology

Imaging Recommendations

- Best imaging tool
 - Doppler to identify placental insufficiency
 - Fetal anatomic survey to identify nonplacental causes
- Protocol advice
 - Monitor growth carefully (ideal interval is 3 weeks)
 - Monitor amniotic fluid volume (AFV)
 - Monitor viable fetus response to hostile environment
 - Biophysical profile
 - Acute hypoxia → ↓ movement and tone
 - Chronic hypoxia → ↓ amniotic fluid volume
 - Fetal monitoring (nonstress test)
 - Fetal echocardiography for cardiac decompensation surveillance

DIFFERENTIAL DIAGNOSIS

Constitutionally Small Fetus

- Fetus is small, but interval growth is normal
- Often from normal hereditary pattern (look at parents)

Oligohydramnios Without Placental Insufficiency

- Premature rupture of membranes
- Severe genitourinary (GU) anomaly
 - Renal agenesis, bilateral renal anomaly, GU obstruction
- Consider amnioinfusion or fetal MR for better visualization

Mild Skeletal Dysplasia

- Long bones affected more than other biometry
- Look for minor findings
 - Bone ossification, fractures, bowing
 - Presence of scapula/clavicles
- AFV more likely normal or increased
- Most often with normal Doppler findings

PATHOLOGY

General Features

- Etiology
 - Utero-placental insufficiency
 - Abnormal uterine perfusion (< 0.6 mL/kg/min)
 - ↓ amino acid and glucose delivery to fetus
 - Abnormal placental hormone factors
 - Fetal response to ↓ substrates
 - Glycogenolysis leads to small liver size (↓ AC)
 - Down regulation of insulin and other hormones
 - Hypoxemia response
- Genetics
 - Triploidy with most severe/early FGR
 - Appearance depends on source of extra set of chromosomes
 - Digynic triploidy (maternal extra set)
 - Small placenta + severe early asymmetric FGR
 - Diandric triploidy (paternal extra set)
 - Thick/cystic placenta + symmetric FGR
 - Trisomy 18, trisomy 13, other syndromes

Fetal Growth Restriction Doppler Findings

Vascular Structure	Early Finding	Late Finding	Pathophysiology
Umbilical artery (UA)	↑ UA S/D ratio	Absent diastolic flow Reversed diastolic flow	Villous vascular tree dysfunction
Umbilical vein (UV)	↓ UV flow	Pulsatile UV flow	↑ atrial pressure
Uterine artery	RI > 0.6 after 24 weeks	Postsystolic notch after 24 weeks	↑ spiral artery flow resistance
Ductus venosus	High resistive flow	Reversed a-wave	Flow reversal during atrial contraction
Middle cerebral artery (MCA)	↑ diastolic flow	MCA S/D ratio < UA S/D ratio	Redistribution of cardiac output; "brain-sparing" physiology
Heart	Holosystolic TR; RVFS/LVFS < 0.28	Holosystolic MR or TR; TR dP/dT < 400; monophasic atrioventricular filling	↑ systemic venous pressure

TR = tricuspid regurgitation; MR = mitral regurgitation; RVFS/LVFS = right to left ventricular fractional shortening; dP/dT = change in pressure over time in TR waveform; S/D = systolic/diastolic ratio; RI = resistive index.

CLINICAL ISSUES

Presentation

- Most common signs/symptoms
 - Small fundal height
 - Patient presents with high-risk maternal factors
 - Hypertension
 - Preeclampsia with 4x increased risk for FGR
 - Collagen vascular disease
 - Diabetes mellitus
 - Drugs/alcohol/cigarette smoking
 - Malnutrition

Demographics

- Epidemiology
 - Recurrent FGR risk up to 25%

Natural History & Prognosis

- FGR fetuses with 4x ↑ in adverse outcome
 - Examples: Stillbirth, neonatal death, hypoxic ischemic encephalopathy, cerebral palsy
- Long-term neurodevelopmental morbidity reported
- ↑ risk of hypertension, diabetes, stroke as adults

Treatment

- Delivery guidelines correlate FGR with UA Doppler findings
 - 37-week delivery if ↑ UA S/D ratio
 - 39-week delivery if normal UA S/D ratio
 - Preterm delivery if AEDF or REDF
- Preterm management difficult
 - Risk of preterm delivery balanced with risk of intrauterine fetal demise
- Consider maternal testing for thrombophilic disorders
 - Antiphospholipid syndrome, protein C deficiency
- Consider karyotype and infection testing for early FGR
- Aggressive treatment of maternal condition
 - Treat hypertension, control diabetes

DIAGNOSTIC CHECKLIST

Consider

- Is the pregnancy dated accurately?
 - EFW percentiles are based on GA

- Early US is more accurate than menstrual history or clinical findings
- Consider nonconventional biometry for dating unknown and GA is in question
 - Transverse cerebellar diameter
 - Fetal foot length
 - Epiphyseal ossification centers (EOS)
 - Distal femur EOS present > 32 weeks
 - Proximal tibia EOS present > 36 weeks
 - Proximal humeral EOS present > 38 weeks
- Management decisions are based on multiple factors
 - Gestational age
 - Interval growth and AFI
 - Nonstress testing and BPP
 - Maternal factors

Image Interpretation Pearls

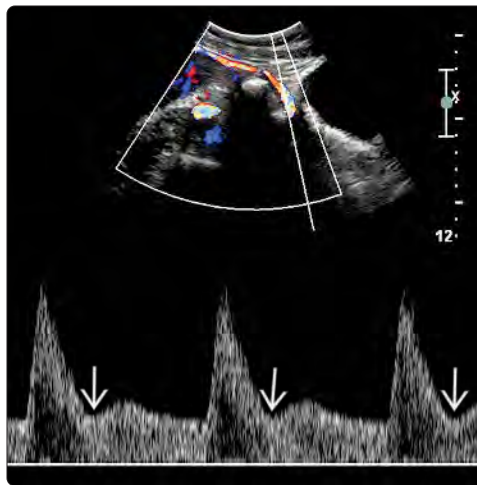
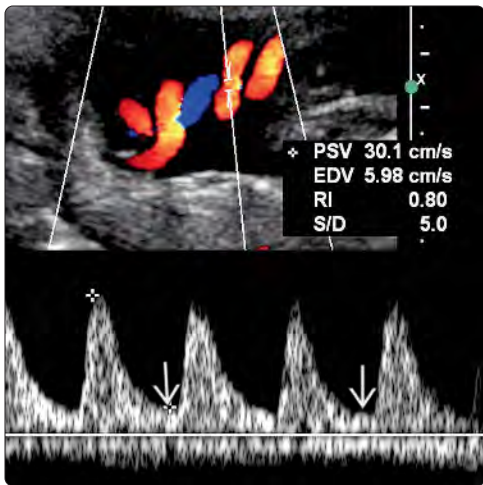
- Small AC is biggest predictor for FGR from placental insufficiency
- UA Doppler is "tip of iceberg" with respect to fetal hemodynamic status
 - 60-70% of placental vascular bed obliterated before AEDF or REDF is seen
- Addition of venous Doppler → more information about fetal response to adverse conditions

Reporting Tips

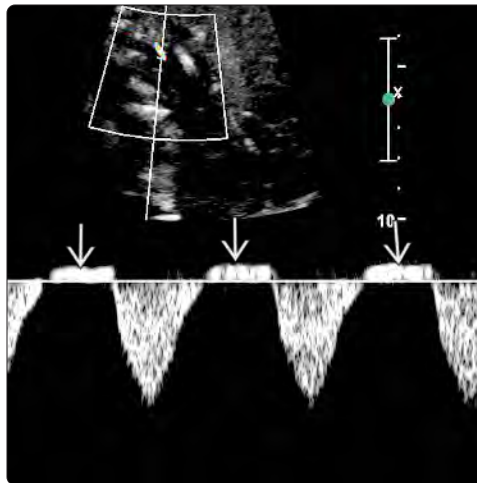
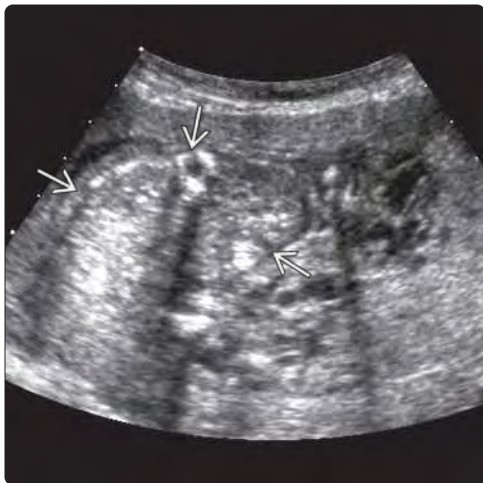- Alert provider about FGR suspicion before patient leaves ultrasound clinic
 - Patient may need fetal monitoring or admission

SELECTED REFERENCES

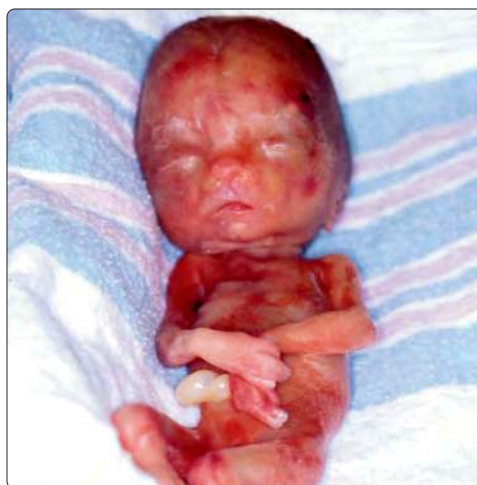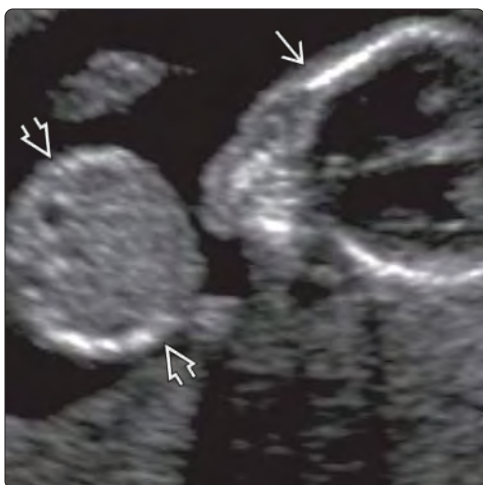1. Kovo M et al: Pregnancy outcome and placental findings in pregnancies complicated by fetal growth restriction with and without preeclampsia. *Reprod Sci.* 22(3):316-21, 2015
2. Maggio L et al: Perinatal outcomes with normal compared with elevated umbilical artery systolic-to-diastolic ratios in fetal growth restriction. *Obstet Gynecol.* 125(4):863-9, 2015
3. Sovio U et al: Screening for fetal growth restriction with universal third trimester ultrasonography in nulliparous women in the Pregnancy Outcome Prediction (POP) study: a prospective cohort study. *Lancet.* 386(10008):2089-97, 2015
4. Zhang J et al: Defining normal and abnormal fetal growth: promises and challenges. *Am J Obstet Gynecol.* 202(6):522-8, 2010
5. Miller J et al: Fetal growth restriction. *Semin Perinatol.* 32(4):274-80, 2008



(Left) Increased umbilical artery systolic/diastolic ratio of 5.0 is seen in this 30-week pregnancy with FGR. The elevation in the ratio is secondary to low-velocity diastolic flow \Rightarrow , reflecting increased resistance of the utero-placental circulation. (Right) Uterine artery waveform, in the same case, is also abnormal. The presence of a postsystolic notch \Rightarrow is not normal after the 1st trimester and suggests abnormal placentation as the cause of FGR in this case.



(Left) Severe oligohydramnios at 29 weeks is exemplified by the presence of a compressed fetal abdomen \Rightarrow and no amniotic fluid. This fetus also had abnormal Doppler parameters suspicious for FGR, and a nonreactive nonstress test. Pathologic evaluation of the placenta showed > 70% infarction. (Right) Umbilical artery Doppler shows reversal of diastolic flow \Rightarrow in a fetus with oligohydramnios and FGR. The reversed flow is seen well because the sweep speed has been increased in order to "widen" the umbilical artery waveform.



(Left) In this fetus with triploidy and FGR US through the head \Rightarrow and abdomen \Rightarrow shows the asymmetry of growth restriction affecting the abdomen to a greater degree than the fetal head. Other anomalies were also seen. (Right) Clinical photograph of another fetus with triploidy shows that the body growth is more restricted than the head growth. Aneuploidy should be suspected when FGR is seen early.

KEY FACTS

TERMINOLOGY

- Birth weight > 4,000 g or 4,500 g (or 10 lb)
- Estimated fetal weight (EFW) > 90th percentile

IMAGING

- Fetal biometry used to estimate weight
 - Large abdominal circumference (AC) is often first clue
 - AC is heavily weighted in all EFW calculations
 - Growth graphs are useful visual tools
 - Most often 3rd-trimester diagnosis
- Accuracy for EFW > 4,500 g is only 50%
 - High false-positive rates
 - Positive predictive value only 30-44%
 - Negative predictive value of 97-99%
- Associated findings
 - Polyhydramnios
 - ↑ subcutaneous adipose tissue

TOP DIFFERENTIAL DIAGNOSES

- Beckwith-Wiedemann syndrome
- Hydrops

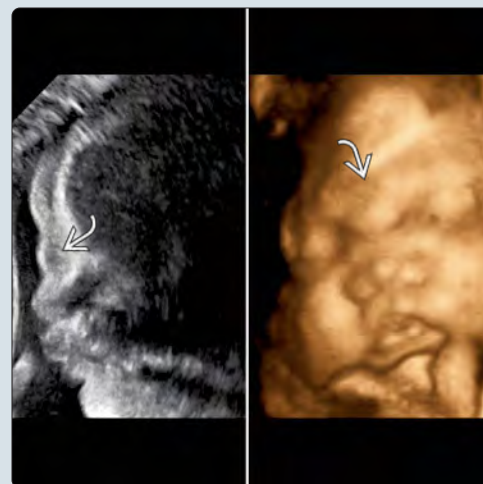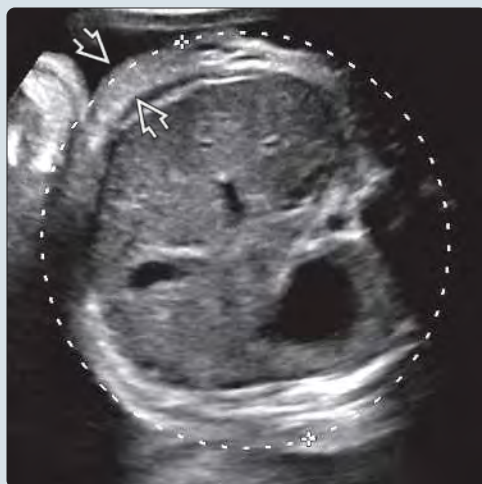
CLINICAL ISSUES

- Maternal complications
 - Protracted/arrested labor
 - Cesarean deliver
- Fetal complications
 - Shoulder dystocia
 - Neonatal hypoglycemia, hypocalcemia
- Consider prophylactic cesarean delivery if EFW > 5,000 g and patient is not diabetic
- Consider prophylactic cesarean delivery if EFW > 4,500 g and patient is diabetic

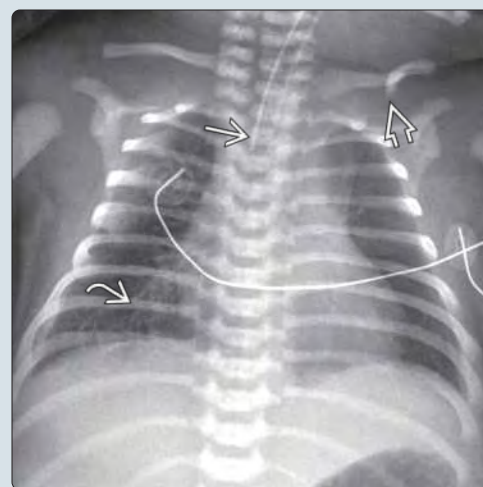
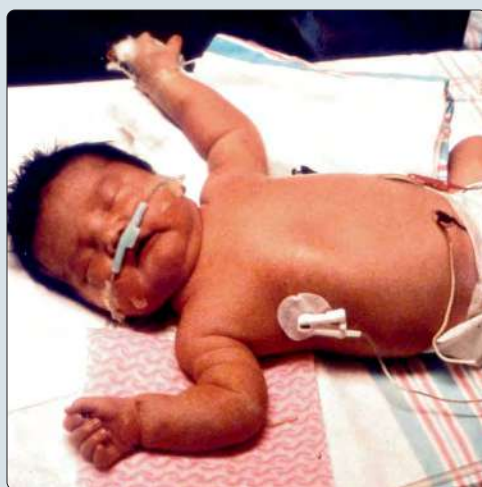DIAGNOSTIC CHECKLIST

- Call provider if unexpected LGA is diagnosed
 - Considered critical finding

(Left) The abdominal circumference in this fetus measured > 95th percentile, placing it at risk for macrosomia. Notice the abundant echogenic subcutaneous fat. **(Right)** In this macrosomic fetus, there is abundant subcutaneous fat involving the head and face, particularly overlying the bridge of the nose, in the forehead. This finding should not be confused with anasarca, which tends to be more hypoechoic.



(Left) Clinical photograph shows the large baby of a patient with diabetes. Excessive adipose deposition in trunk, arms, and face is apparent. These babies are at risk for shoulder dystocia, asphyxia, and hypoglycemia. **(Right)** A newborn with macrosomia needed intubation secondary to hypoxia and meconium aspiration. The left clavicle is fractured. Prenatal identification of macrosomia is considered a critical finding since there is increased morbidity for both the mother and the newborn.



TERMINOLOGY

Synonyms

- Large for gestational age (LGA)

Definitions

- Birth weight (BW) > 4,000 g or 4,500 g (or 10 lb)
 - American College of Obstetrics and Gynecology supports > 4,500 g because morbidity to mother and child sharply increases beyond this weight
- LGA: Estimated fetal weight (EFW) or BW > 90th percentile

IMAGING

Ultrasonographic Findings

- EFW > 90-95% using routine fetal biometry
 - AC is heavily weighted in all EFW calculations
 - AC often 1st measurement to ↑
 - > 35-38 cm considered large
 - Risk for macrosomia < 1% if AC < 35 cm
 - Risk for macrosomia = 37% if AC > 37 cm
- EFW accuracy for fetal weight > 4,500 g is only 50%
 - High false-positive rates
 - 22-44% sensitivity, 99% specificity
 - Positive predictive value only 30-44%
 - Negative predictive value of 97-99%
- Macrosomia often manifests in 3rd trimester
- Other findings
 - ↑ subcutaneous adipose tissue
 - Truncal obesity common
 - Seen best on routine AC view
 - Adipose tissue is diffusely echogenic
 - Might be mistaken for anasarca
 - Polyhydramnios
 - Independently associated with diabetes
 - Also seen in LGA fetus in absence of diabetes
 - Placentomegaly (thick placenta)

Imaging Recommendations

- Best imaging tool
 - Accurate AC measurement
- Protocol advice
 - Growth graphs are useful visual tools

DIFFERENTIAL DIAGNOSIS

Beckwith-Wiedemann Syndrome

- Early excessive growth
- Macrosomia + anomalies common
 - Macroglossia, omphalocele, large kidneys

Hydrops (Immune and Nonimmune)

- Excessive fluid collection
 - Skin edema more hypoechoic than fat
 - Pleural effusion, ascites, pericardial effusion

CLINICAL ISSUES

Presentation

- Most common signs/symptoms
 - Larger than expected fundal height measurement
 - Pregnancies at risk for macrosomia

- Diabetes (less risk with better control)
- Maternal obesity
- Postterm pregnancy (> 42 weeks)
- Prior child with macrosomia

Demographics

- Epidemiology
 - ≥ 4,000 g: 9% worldwide prevalence
 - ≥ 5,000 g: 0.1% worldwide prevalence
 - USA prevalence of LGA baby in nondiabetics
 - If normal maternal weight: 7.7%
 - If maternal obesity: 12.7%
 - USA prevalence of LGA baby in diabetic women
 - If normal maternal weight: 13.6%
 - If maternal obesity: 22.3%

Natural History & Prognosis

- Maternal complications
 - Protracted/arrested labor
 - Cesarean delivery
 - Genital tract lacerations
 - Postoperative hemorrhage
 - Uterine rupture
- Fetal complications
 - Birth trauma
 - Shoulder dystocia in 10%
 - > 50% if > 4,500 g and forceps delivery
 - Brachial plexus injury, facial nerve palsy
 - Clavicle/humerus fracture
 - Asphyxia
 - Neonatal hypoglycemia, hypocalcemia
- Long-term risks in offspring
 - Obesity, metabolic syndrome, cardiovascular disease

Treatment

- Consider prophylactic cesarean delivery if suspect EFW > 5,000 g in women without diabetes and > 4,500 g in women with diabetes
 - American College of Obstetrics and Gynecology, Practice Bulletin #22, reaffirmed in 2015

DIAGNOSTIC CHECKLIST

Consider

- Diagnosis of macrosomia is imprecise but important to identify fetus at risk
- Macrosomia associated with polyhydramnios
- Large AC is most predictive measurement for macrosomia

Reporting Tips

- Recommend follow-up for macrosomia if large AC seen in 2nd trimester
- Call provider if unexpected LGA is diagnosed (considered critical finding)

SELECTED REFERENCES

1. Black MH et al: The relative contribution of prepregnancy overweight and obesity, gestational weight gain, and IADPSG-defined gestational diabetes mellitus to fetal overgrowth. *Diabetes Care*. 36(1):56-62, 2013
2. Denny MC et al: Macrosomia: defining the problem worldwide. *Lancet*. 381(9865):435-6, 2013

KEY FACTS

TERMINOLOGY

- Abnormal or decreased fetal red blood cells
- Most commonly due to Rhesus (Rh) or other minor red cell antigen/protein incompatibility
 - Maternal antibodies cross placenta and cause lysis of fetal red blood cells

IMAGING

- Elevated middle cerebral artery (MCA) peak systolic velocity (PSV)
 - Doppler gate should be placed near origin of MCA
 - Angle of insonation should be zero
- Several MCA PSV measurements should be obtained
 - Best measurement chosen, not average
- Assess for fetal hydrops, cardiomegaly, polyhydramnios



TOP DIFFERENTIAL DIAGNOSES

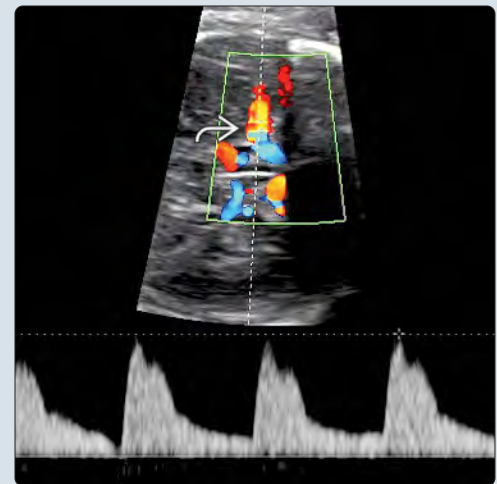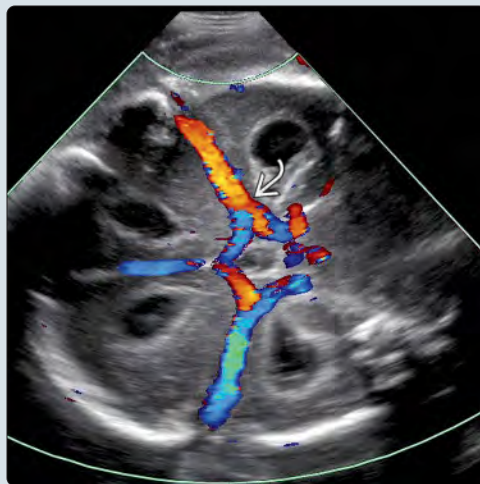
- Parvovirus infection
 - Virus attacks red blood cell precursors → anemia



- Fetal hemorrhage
- Twin anemia-polycythemia sequence
 - Chronic feto-fetal transfusion in monochorionic twins
- α -thalassemia

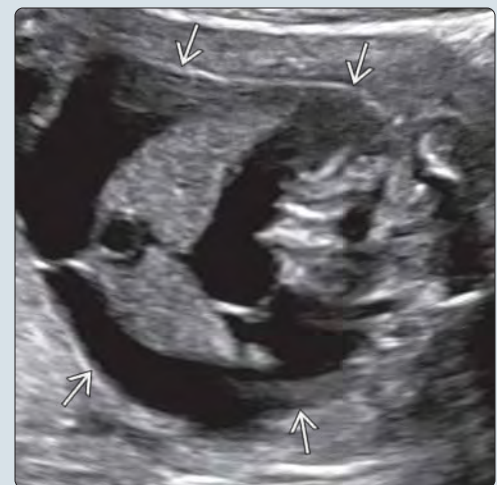
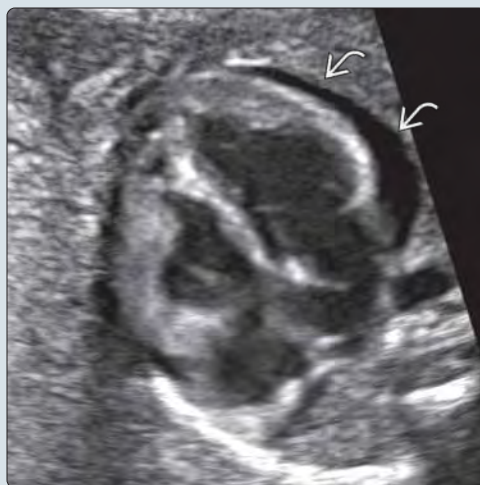CLINICAL ISSUES

- For Rh-alloimmunized patients, fetal hemolytic disease similar or more severe in subsequent pregnancies
- Serial MCA Doppler measurement utilized to monitor fetal anemia risk
- Need for intervention generally based on relationship of MCA PSV to gestational age
 - Risk of anemia high if MCA PSA ≥ 1.50 MoM
 - After 35-weeks gestation, increased false-positive rate for prediction of anemia
- Look for fetal hydrops/high-output heart failure
- Ultrasound guidance used to access fetal circulation for cordocentesis and intrauterine transfusion
 - Complication rate of 2-5% reported

(Left) Axial color Doppler ultrasound of the fetal brain shows the circle of Willis. The optimal site of sampling for accurate Doppler measurements is near the origin of the middle cerebral artery (MCA)  from the internal carotid artery. **(Right)** The Doppler sample volume should be 1-2 mm , and no angle correction should be used to obtain the peak systolic velocity. Measurements are more accurate in the absence of fetal movement or breathing, which can cause variations in the peak velocity.



(Left) Four-chamber view shows massive enlargement of the fetal heart, which fills the chest. There is also a pericardial effusion . **(Right)** Coronal ultrasound of the fetal abdomen shows the liver floating in diffuse ascites . These findings together are consistent with hydrops. Hemoglobin Bart syndrome was discovered after cordocentesis.



TERMINOLOGY**Definitions**

- Abnormal or decreased fetal red blood cells
- Most commonly due to Rhesus (Rh) or other minor red cell antigen/protein incompatibility
 - Maternal antibodies cross placenta and cause lysis of fetal red blood cells, leading to fetal anemia
 - Sensitization can be from prior pregnancy

IMAGING**Ultrasonographic Findings**

- Elevated middle cerebral artery (MCA) peak systolic velocity (PSV)
 - Color Doppler used to identify circle of Willis
 - Doppler gate should be placed near origin of MCA
 - Use MCA closest to transducer (nearfield) if possible
 - Sample volume 1-2 mm
 - Far-field vessel likely acceptable alternative if necessary
 - Angle of insonation should be zero
 - No angle correction allowed
 - Several MCA PSV measurements should be obtained
 - Best measurement chosen, not average
 - Velocity samples should be similar
 - Avoid waveforms distorted by breathing or fetal motion
- Look for fetal hydrops
 - Pericardial fluid
 - Pleural effusion
 - Ascites
 - Skin edema
 - Placental thickening
- Also assess for other signs of fetal distress
 - Cardiomegaly
 - Secondary to high-output physiology
 - Polyhydramnios

DIFFERENTIAL DIAGNOSIS**Minor Antigen Alloimmune Syndromes**

- Kell, Duffy, Kidd, E, C, c, and many others
 - Most are variably present in different ethnic populations
 - Most sensitizations caused by incompatible blood transfusions
 - Relative frequency rising since Rh-immune globulin prophylaxis developed
 - Decreasing incidence of Rh sensitization
 - Management of pregnancy same as for Rh alloimmunization

Parvovirus Infection

- Transplacental transmission in about 1/3 of cases
- Parvovirus attacks red blood cell precursors → anemia
- Hydrops uncommonly seen
 - May be secondary to anemia or viral myocarditis

Fetal Hemorrhage

- Usually transient anemia due to blood loss
- Rare, but can occur with fetal tumors, vascular malformations, trauma, fetomaternal hemorrhage

Twin Anemia-Polycythemia Sequence

- Chronic fetofetal transfusion in monochorionic twins
 - Occurs in uncomplicated monochorionic diamniotic twins or after laser ablation
 - Results in large intertwin hemoglobin differences without all criteria for twin-twin transfusion syndrome
 - MCA PSV > 1.5 multiples of the median (MoM) in the donor and < 0.8-1.0 MoM in recipient
 - Usually late 2nd or 3rd trimester

 α -Thalassemia

- Hemoglobin (Hb) Bart → most severe form of anemia
 - Autosomal recessive inheritance
 - All 4 α -globin alleles deleted
 - Results in γ -globin tetramers (Hb Bart)
 - No normal hemoglobin synthesis
- Hb Bart is incompatible with survival
 - Presents with fetal hydrops
 - High-output cardiac failure
 - Look for signs in late 1st trimester
 - Increased nuchal translucency
 - Cardiac enlargement
 - Hepatosplenomegaly ± extramedullary hematopoiesis
- Carriers have less severe red blood cell changes (at least 1 α -globin allele present)
 - Hb H has 15-30% Hb Bart production
 - May have symptoms in utero with hydrops
- More common in those of Chinese, Southeast Asian, Mediterranean, African, Middle Eastern, Central American descent

 β -Thalassemia

- Autosomal recessive disorder
 - More common in those of Mediterranean, Middle Eastern, Asian descent
 - Homozygous form has reduced or absent β -globin synthesis
- Fetus protected from severe disease by α -chain production
- Protection fades rapidly after birth
 - Anemia results by 6 months of age
 - Splenomegaly

PATHOLOGY**General Features**

- Etiology
 - Fetomaternal hemorrhage
 - Variable amount to cause alloimmunization
 - Most commonly occurs at delivery
 - Abortion, ectopic pregnancy, and amniocentesis can also cause alloimmunization
 - Maternal immune response (Rh example)
 - Fetus has Rh D(+) erythrocytes and mother has Rh D(-) erythrocytes
 - Fetal erythrocytes gain access to maternal circulation
 - Maternal immune response generates antibodies against fetal D antigen
 - Maternal anti-D antibodies cross placenta
 - Lead to fetal erythrocyte destruction
 - Hydrops develops as fetal cardiac output attempts to compensate for decreased oxygen delivery

Expected Peak MCA Velocity Measurements During Gestation

Week of Gestation	1.00 (Median)	1.29 MoM*	1.50 MoM	1.55 MoM
18	23.2	29.9	34.8	36.0
20	25.5	32.8	38.2	39.5
22	27.9	36.0	41.9	43.3
24	30.7	39.5	46.0	47.5
26	33.6	43.3	50.4	52.1
28	36.9	47.6	55.4	57.2
30	40.5	52.2	60.7	62.8
32	44.4	57.3	66.6	68.9
34	48.7	62.9	73.1	75.6
36	53.5	69.0	80.2	82.9
38	58.7	75.7	88.0	91.0
40	64.4	83.0	96.6	99.8

*MoM = multiples of the median. Velocities reported in cm/sec. Adapted from Mari G: Noninvasive diagnosis by Doppler ultrasonography of fetal anemia due to maternal red-cell alloimmunization. *N Engl J Med.* 342(1):9-14, 2000.

- Genetics
 - Most cases of Rh alloimmunization causing serious hemolytic disease in fetus/newborn result from maternal-fetal incompatibility to red cell D antigen
 - Rh(+) = presence of D antigen
 - Rh(-) = absence of D antigen

CLINICAL ISSUES

Presentation

- Many fetuses have no sonographic abnormalities
- Look for fetal hydrops/high-output heart failure

Natural History & Prognosis

- Obstetric history important for management of Rh-alloimmunized patient
 - Fetal hemolytic disease similar or more severe in subsequent pregnancies
 - 80% risk of hydropic Rh-incompatible fetus, if prior history of hydrops due to Rh-incompatibility
 - Hemolysis and hydrops develop at similar gestational age or earlier in subsequent pregnancies
- Hydrops uncommon in 1st sensitized pregnancy

Treatment

- Serial MCA Doppler measurement to monitor fetal anemia risk
 - Need for intervention generally based on relationship of MCA PSV to gestational age
 - Risk of anemia high if MCA PSA \geq 1.50 MoM
 - Below 1.50 MoM, fetus not anemic or has mild anemia
 - MCA velocity may be influenced by red cell indices other than hematocrit
 - Leads to elevated velocity without anemia
 - High sensitivity for moderate to severe anemia with false-positive rate of 12-15%
 - After 35-weeks gestation, MCA measurements less reliable for prediction of anemia
- MCA PSV vs. amniocentesis with Δ OD450 measurement

- Δ OD450 = amount of shift in optical density (OD) from linearity at 450 nm
 - Estimates degree of fetal red cell hemolysis
 - Not accurate if anemia due to \downarrow production
- MCA Doppler less invasive with similar accuracy of diagnosis
- MCA PSV may actually be more reliable for diagnosis of anemia
- Fetal blood sampling and transfusion
 - Cordocentesis used to check for fetal anemia
 - Gold standard for measuring fetal hematocrit
 - Typical access sites for intrauterine transfusion
 - Umbilical vein
 - Placental cord insert
 - Intraabdominal
 - Intraperitoneal
 - Used if access to vein limited
 - Complication rate of 2-5% reported
 - Fetal bradycardia, premature rupture of membranes, infection, air embolism, emergency cesarean section, fetal death

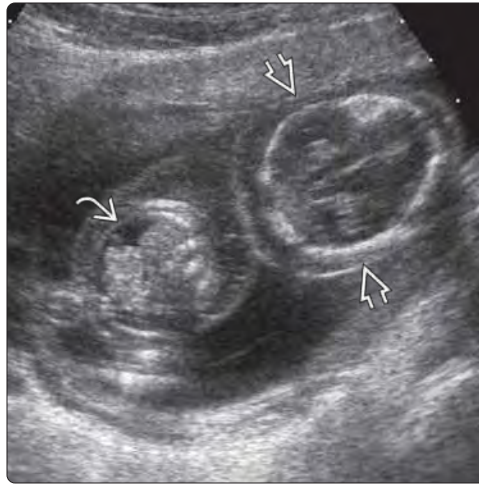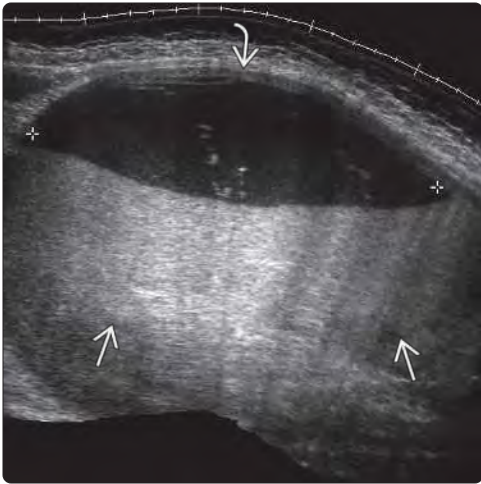
DIAGNOSTIC CHECKLIST

Image Interpretation Pearls

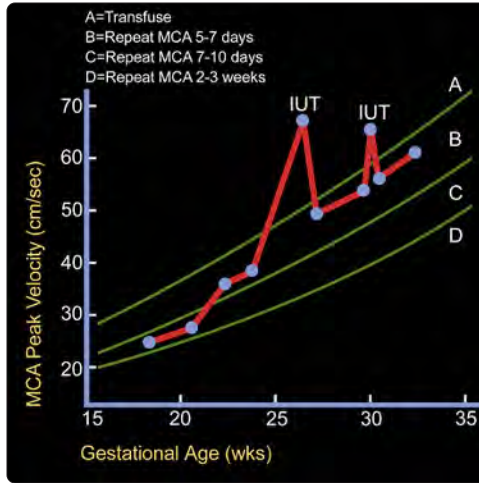
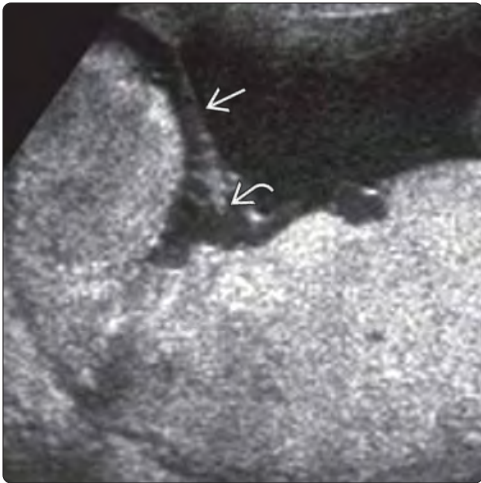
- MCA velocity should be measured with 0° angle of insonation near origin

SELECTED REFERENCES

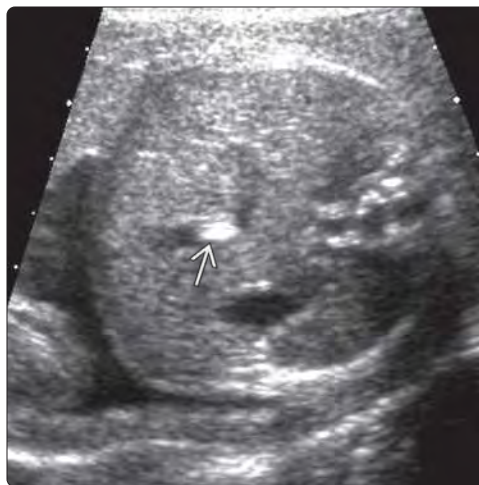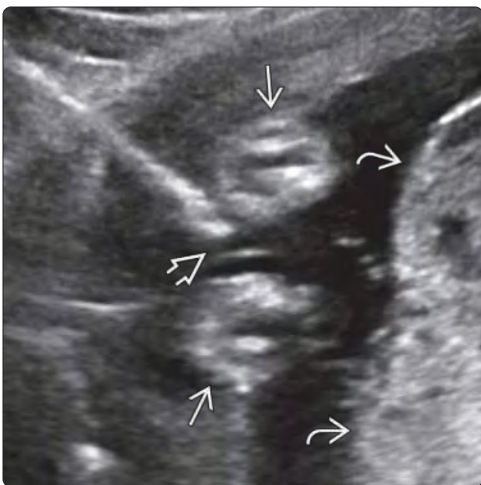
1. Jain V et al: Guidelines for the management of a pregnant trauma patient. *J Obstet Gynaecol Can.* 37(6):553-74, 2015
2. Salvi S et al: Reliability of Doppler assessment of the middle cerebral artery in the near and far fields in healthy and anemic fetuses. *J Ultrasound Med.* 34(11):2037-42, 2015
3. Slaghekke F et al: Middle cerebral artery peak systolic velocity to predict fetal hemoglobin levels in twin anemia-polycythemia sequence. *Ultrasound Obstet Gynecol.* 46(4):432-6, 2015
4. Hermann M et al: Cerebral Doppler velocimetry to predict fetal anemia after more than three intravenous fetal exchange transfusions. *Transfusion.* 54(11):2968-73, 2014



(Left) Following maternal trauma, placental abruption can uncommonly cause fetal anemia. In this case, a 17-cm retroplacental hematoma (calipers) displaces the placenta away from the uterine wall. (Right) Parvovirus infection is another less common cause of fetal anemia and can cause fetal hydrops (shown here with diffuse skin edema and ascites).



(Left) Transabdominal ultrasound during an intrauterine transfusion (IUT) shows the needle traversing the amniotic fluid, with the tip terminating at the base of the umbilical cord at the placental insertion site. Since the cord is fixed at this location, it is the preferred access site for transfusion. (Right) Chart shows the MCA velocities from an Rh-sensitized fetus. Two IUTs were required during gestation. The fetus was delivered at 35 weeks without complication.



(Left) If the placenta is posterior with an inaccessible cord insertion, the needle can be placed in a free loop of the cord. In this case, the tip of the needle is in the umbilical vein between the fetal extremities, and the transfusion was performed at that site. (Right) The intraabdominal umbilical vein may also be used as an access point for an IUT, as in this case. A transverse view of the abdomen shows the needle within the hepatic portion of the umbilical vein.

DIFFERENTIAL DIAGNOSIS

Common

- Idiopathic
- Macrosomia
- Diabetes
- Hydrops
- Twin-Twin Transfusion Syndrome
- Fetal Bowel Obstruction

Less Common

- Arthrogryposis, Akinesia Sequence
- Skeletal Dysplasia, Severe
- Placental Chorioangioma
- Congenital Pulmonary Airway Malformation

Rare but Important

- Mesoblastic Nephroma
- Unilateral Ureteropelvic Junction Obstruction

ESSENTIAL INFORMATION

Key Differential Diagnosis Issues

- Idiopathic cause is diagnosis of exclusion
 - Rule out fetal anomalies 1st
 - Anomalies affecting fetal swallowing
 - Gastrointestinal anomalies
 - Central nervous system anomalies
 - Chest masses compressing esophagus
 - Anomalies affecting fetal movement
 - Musculoskeletal anomalies
 - Anomalies affecting fetal circulation
 - Consider formal echocardiography
 - Consider genetic testing when anomalies seen
- Amniotic fluid index (AFI) technique
 - Divide uterus into 4 equal quadrants
 - Measure maximum vertical pocket (MVP) of each quadrant
 - Avoid fetal parts/cord in MVP
 - Add 4 MVPs to calculate AFI
 - ≥ 25 -cm AFI = polyhydramnios
 - AFI/gestational age tables available
 - Surveillance for AFI > 20 cm recommended
- MVP technique
 - Measure single largest pocket of fluid in uterus
 - ≥ 8 cm = polyhydramnios
- Twin fluid assessment
 - Measure MVP for each fetus
 - Preferably on image where membrane is also seen
 - ≥ 8 cm = polyhydramnios
 - Often 1st clue of twin-twin transfusion

Helpful Clues for Common Diagnoses

- **Idiopathic**
 - Most common cause (50-70%)
 - Mild, stable finding
 - Normal patient and fetus
 - No diabetes
 - No fetal anomalies
 - 2/3 are male fetuses
 - 28% with fetal macrosomia

- **Macrosomia**
 - Estimated fetal weight > 90 th percentile
 - Large abdominal circumference is hallmark finding
 - \uparrow truncal echogenic fat
 - Causes
 - Hereditary characteristics
 - Maternal obesity
 - Diabetes
 - Beckwith-Wiedemann syndrome
- **Diabetes**
 - Gestational diabetes (most common)
 - Glucose intolerance during pregnancy
 - Oral glucose tolerance test given between 24-28 wk
 - Pregestational diabetes (type 1 or 2)
 - Polyhydramnios associated with poor glucose control
 - May be 1st finding in pregnancy
 - Associated with macrosomia
- **Hydrops**
 - Excessive fetal fluid accumulation in 2 or more body cavities
 - Anasarca (skin edema)
 - Pleural effusion (\pm pericardial)
 - Ascites
 - Immune hydrops (10%)
 - Hemolytic disease \rightarrow fetal anemia
 - Anemia surveillance with middle cerebral artery peak systolic velocity
 - Rh incompatibility is most common cause
 - Nonimmune (90%)
 - Any fetal cause that disrupts fluid management
 - Infection
 - Any cause of fetal anemia
 - Any cause of fetal heart failure
 - Lymphatic obstruction
 - Aneuploidy associations
 - Turner syndrome (cystic hygroma)
 - Trisomy 21
 - Trisomy 18
 - Amniotic fluid may be \uparrow or \downarrow with hydrops
- **Twin-Twin Transfusion Syndrome**
 - Monochorionic twinning
 - Artery to vein anastomoses in shared placenta
 - Donor twin partly perfuses recipient twin
 - Fluid discrepancy may be 1st sign of developing twin-twin transfusion syndrome (need to follow carefully)
 - Close surveillance to assess for need of intervention
 - Amnioreduction and laser treatment of vessels
 - Recipient twin with polyhydramnios
 - Larger twin
 - Donor twin with oligohydramnios
 - Smaller "stuck" twin
- **Fetal Bowel Obstruction**
 - Late polyhydramnios (> 24 wk)
 - Any cause of obstruction to swallowed amniotic fluid
 - Esophageal atresia
 - Absent or small stomach
 - 1/3 with trisomy 18 or 21
 - Associated with VACTERL syndrome
 - Duodenal atresia

- Double-bubble appearance
- 1/3 with trisomy 21
- o Jejunal, ileal atresia
 - Sausage-shaped bowel loops
- o Oral mass or obstruction
 - Teratoma most common

Helpful Clues for Less Common Diagnoses

- **Arthrogryposis, Akinesia Sequence**
 - o Heterogeneous group of disorders
 - Lack of extremity motion
 - Contractures
 - o ↓ fetal movement and swallowing
 - o Associations
 - Trisomy 18
 - Autosomal dominant and recessive syndromes
- **Skeletal Dysplasia, Severe**
 - o Common dysplasias
 - Thanatophoric
 - Achondroplasia
 - Achondrogenesis
 - Osteogenesis imperfecta
 - o Common skeletal findings
 - Short limbs
 - Poor ossification
 - Bowed or broken bones
 - Craniosynostosis
 - o Polyhydramnios common in 3rd trimester
- **Placental Chorioangioma**
 - o Benign, vascular placental tumor
 - o Large masses (> 5 cm): ↑ complications
 - o Polyhydramnios
 - Transudate from leaky vessels
 - o Hydrops
 - Arteriovenous shunting in mass
 - Fetal anemia from hemolysis
- **Congenital Pulmonary Airway Malformation**
 - o Developmental disorder of pulmonary morphogenesis

- Segmental lung tissue with abnormal bronchial proliferation
- o Microcystic and macrocystic
- o Polyhydramnios etiology
 - Esophagus compression
 - Mass may make fluid

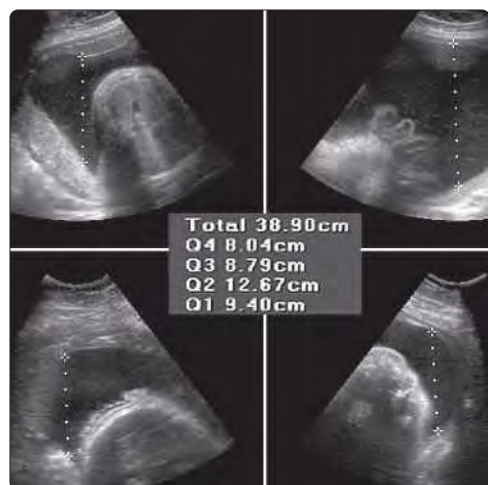
Helpful Clues for Rare Diagnoses

- **Mesoblastic Nephroma**
 - o Benign solid mesenchymal tumor
 - o 70% with polyhydramnios
 - Often progressive and severe
 - o Proposed etiologies for polyhydramnios
 - Hypercalcemia → polyuria
 - Renal hyperemia → ↑ urine output
 - Bowel obstruction (large mass)
- **Unilateral Ureteropelvic Junction Obstruction**
 - o Dilated renal pelvis is hallmark finding
 - Distention ends abruptly at ureteropelvic junction
 - Normal ureters and bladder
 - o Polyhydramnios in 1/3 of cases
 - Apparent paradox that obstruction would lead to polyhydramnios, but etiology thought to be from impaired renal concentrating ability, which causes ↑ urine output
 - o Contralateral renal anomaly in 25%
 - ↓ fluid if severe

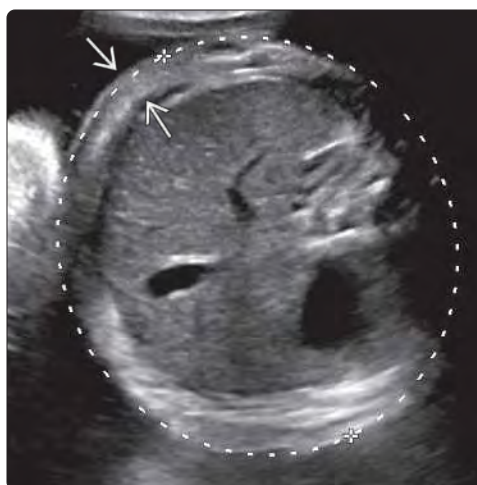
Other Essential Information

- Incidence: 1-2% of all pregnancies
- Complications of significant polyhydramnios
 - o Placenta abruption
 - o Cord prolapse
 - o Premature birth
 - o Membrane rupture
- Amniocentesis for polyhydramnios
 - o Not indicated if idiopathic etiology
 - o Polyhydramnios + growth restriction has ↑ risk for aneuploidy/syndromes
 - Trisomy 18 most common

Macrosomia



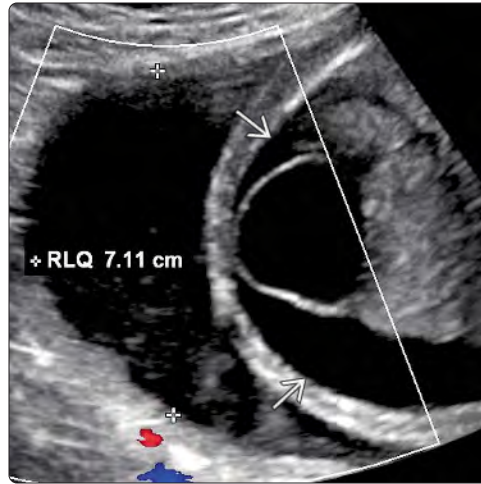
Macrosomia



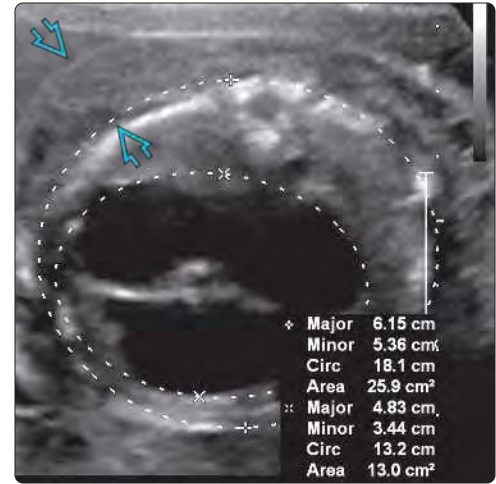
(Left) The amniotic fluid index in this case is diagnostic of polyhydramnios. The sum of the 4-quadrant maximum vertical pocket measurement is 38.9 cm. Fetal anatomic survey was normal; however, the fetus was large for gestational age (macrosomia). (Right) In this fetus with macrosomia, the abdominal circumference measured > 90th percentile, and increased subcutaneous fat (➡) is well seen. Trunk obesity is a feature of macrosomia, with or without maternal diabetes association.

Hydrops

(Left) Fetal ascites is seen in this fetus with heart failure from a severe congenital cardiac defect. In addition, 1 of several large pockets of fluid is measured here as 7.1 cm. (Right) Axial ultrasound through the chest in the same fetus shows cardiomegaly and skin edema. The heart circumference should be $\leq 50\%$ of thoracic circumference but is 73% here (13.2 cm/18.1 cm). Fetal heart failure is a common cause of hydrops and polyhydramnios.

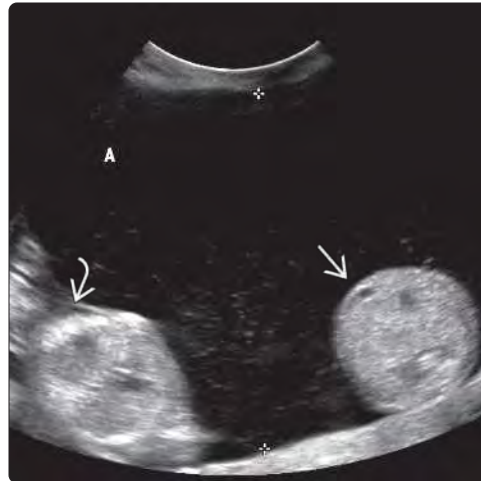

Hydrops

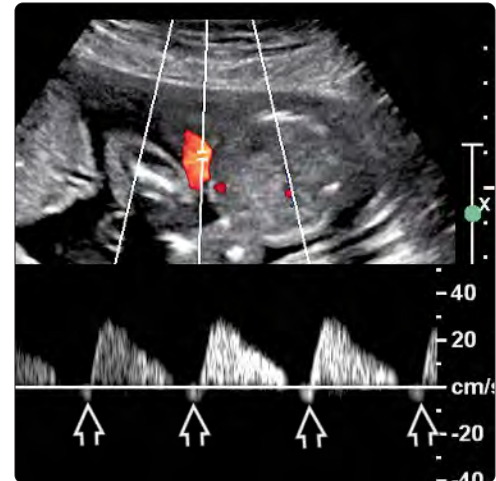


Twin-Twin Transfusion Syndrome

(Left) Axial ultrasound shows a large amount of fluid surrounding fetus A and a barely visible thin separating membrane between the monozygotic twins. (Right) In another pregnancy with twin-twin transfusion, the donor twin (oligohydramnios/stuck twin) umbilical artery Doppler waveform shows reversal of diastolic flow. This finding is associated with a poor prognosis, and the pregnancy may benefit from a therapeutic procedure such as laser ablation of vessel anastomoses.

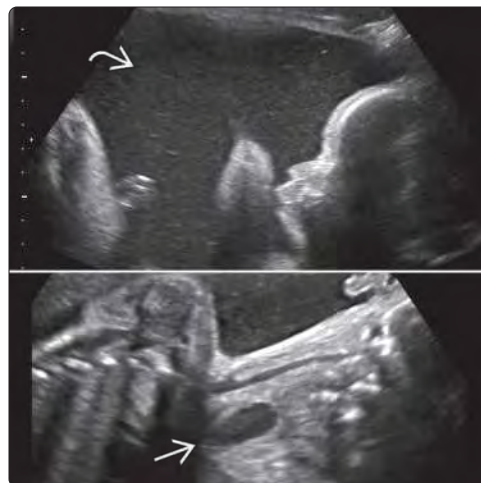


Twin-Twin Transfusion Syndrome

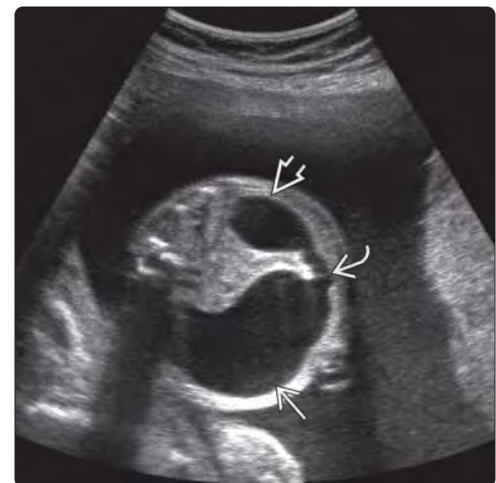

Fetal Bowel Obstruction

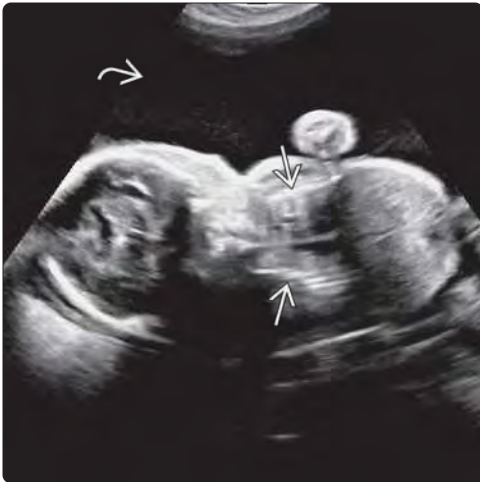(Left) In this pregnancy with excessive fluid, a blind-ending esophageal pouch is seen in the fetal neck. The fetal stomach is also small. Esophageal atresia with tracheoesophageal fistula was the reason for polyhydramnios in this case. (Right) A dilated stomach and duodenum (double bubble) with a connection in-between (the pylorus) are diagnostic of duodenal obstruction. Duodenal atresia is a common cause for bowel obstruction causing polyhydramnios.



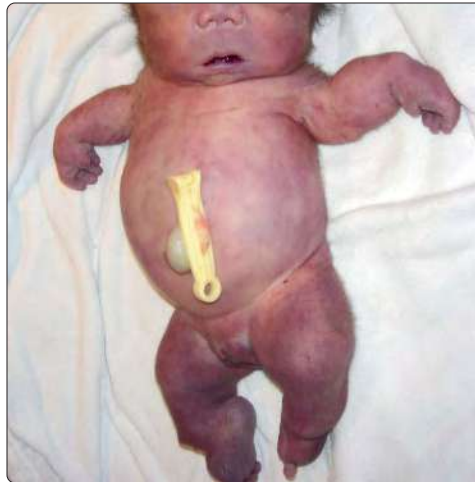Fetal Bowel Obstruction



Skeletal Dysplasia, Severe

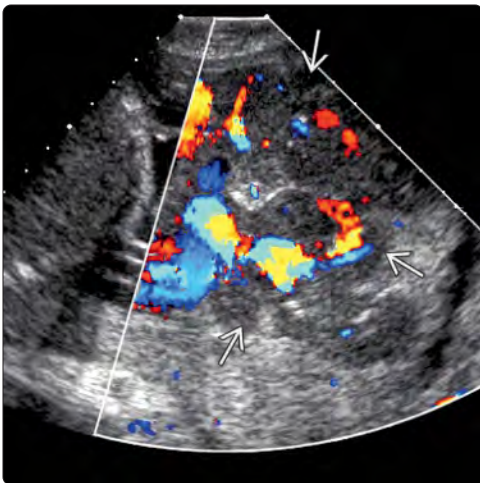


Skeletal Dysplasia, Severe

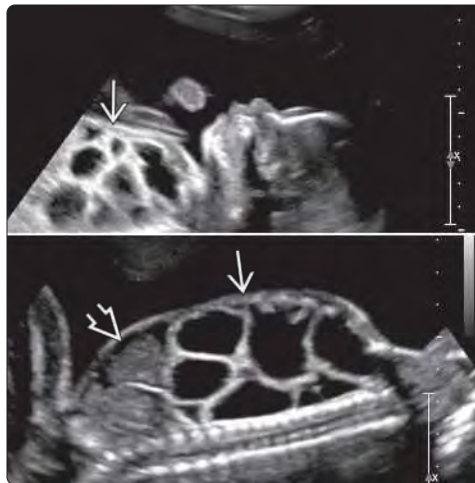


(Left) Notice the small chest [arrow] in this fetus with polyhydramnios [arrow]. All the long bones were markedly short in this fetus with severe skeletal dysplasia (specific type unknown, even after delivery). (Right) In the same case, severe limb shortening and bowing are seen after delivery. Fetuses with severe musculoskeletal anomalies, such as skeletal dysplasia and arthrogyriposis, often develop polyhydramnios in the 3rd trimester.

Placental Chorioangioma

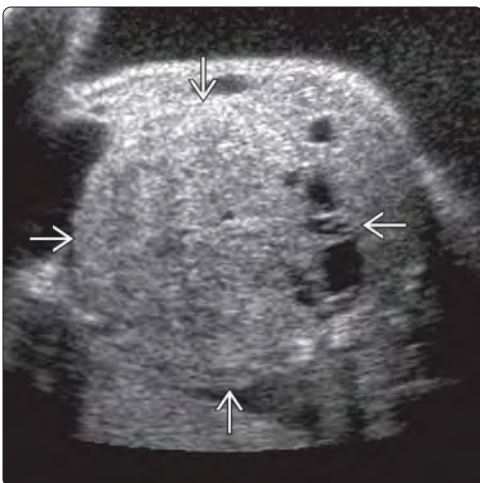


Congenital Pulmonary Airway Malformation

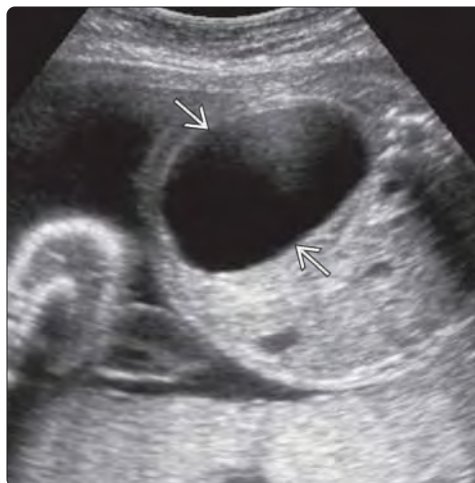


(Left) In this pregnancy complicated by polyhydramnios and fetal hydrops, a large vascular placental mass [arrow] is seen. Chorioangiomas are most often small and cause no harm, but, if large (> 5 cm), there should be follow-up for complications (hydrops, polyhydramnios, fetal anemia). (Right) A large multiseptated cystic chest mass (macrocytic CPAM) [arrow] is seen in this fetus with polyhydramnios. In addition, a small amount of ascites [arrow] and skin edema are also present, diagnostic of hydrops.

Mesoblastic Nephroma



Unilateral Ureteropelvic Junction Obstruction



(Left) Axial ultrasound shows a large, predominantly solid renal mass [arrow], typical of a mesoblastic nephroma. The contralateral kidney was normal. There was severe polyhydramnios, necessitating therapeutic amniocentesis. (Right) Axial ultrasound shows a massively distended renal pelvis [arrow] from UPJ obstruction. The pregnancy was also complicated by mild polyhydramnios. Unilateral renal anomalies are sometimes associated with polyhydramnios secondary to impaired renal concentrating ability.

DIFFERENTIAL DIAGNOSIS

Common

- Preterm Prelabor Rupture of Membranes
- Fetal Growth Restriction

Less Common

- Bilateral Renal Anomaly
 - Renal Agenesis
 - Ureteropelvic Junction Obstruction
 - Multicystic Dysplastic Kidney
 - Autosomal Recessive Polycystic Kidney Disease
- Bladder Outlet Obstruction
 - Posterior Urethral Valves
 - Prune-Belly Syndrome
- Twin-Twin Transfusion Syndrome

ESSENTIAL INFORMATION

Key Differential Diagnosis Issues

- Oligohydramnios complicates 4-5% of all pregnancies
 - 2 incidence peaks
 - Between 13-21 weeks
 - More likely fetal GU causes
 - Between 34-42 weeks
 - More likely placental/maternal causes
- Ultrasound diagnosis of oligohydramnios
 - Objective (measure fluid pockets)
 - Severe oligohydramnios associated with unfavorable outcomes
 - Maximum vertical pocket < 2 cm
 - Amniotic fluid index (AFI) < 5 cm
 - Borderline oligohydramnios: Perinatal outcomes generally favorable
 - AFI of 6-8 cm
 - Subjective assessment rarely used after 1st trimester
 - Subjective note of ↓ fluid pockets
 - Fetus:fluid ratio > 1:1 in mid gestation
- Role of ultrasound at time of diagnosis
 - Rule out fetal genitourinary anomaly cause
- Role of follow-up ultrasound is for surveillance
 - Worsening oligohydramnios may lead to early delivery or fetal intervention
- Morbidity and mortality most often from pulmonary hypoplasia in severe cases, regardless of cause
 - Canalicular phase of lung development at 16-28 weeks vulnerable to effects of low fluid

Helpful Clues for Common Diagnoses

- **Preterm Prelabor Rupture of Membranes**
 - Clinical diagnosis
 - Etiology
 - Spontaneous PPROM
 - Ascending infection most likely cause
 - Spontaneous sealing in only 6-11%
 - Iatrogenic preterm prelabor rupture of membranes (PPROM) (post procedure)
 - 0.5-1.2% incidence after amniocentesis
 - Better prognosis than spontaneous
 - Worse prognosis if PPROM early or prolonged
 - Early: PPROM < 25 weeks

- Prolonged: PPROM > 14 days
- Survival rates for infants born alive increases with ↑ gestational age
 - 26% survival at 23 weeks
 - 84% survival at 26 weeks
- **Fetal Growth Restriction**
 - Estimated fetal weight < 10th percentile
 - Oligohydramnios often earliest finding
 - Causes
 - Placental insufficiency
 - Fetal aneuploidy/syndrome
 - Doppler assessment of placental insufficiency
 - ↑ umbilical artery resistance
 - ↑ uterine artery resistance
 - ↓ middle cerebral artery resistance

Helpful Clues for Less Common Diagnoses

- **Renal Agenesis**
 - Ultrasound findings
 - Anhydramnios (no fluid)
 - Absent kidneys and bladder
 - No renal arteries (color Doppler)
 - Clubfeet, other joint contractures
 - Pitfalls
 - May have normal fluid early (< 17 weeks)
 - Bladder secretions may mimic urine
 - Adrenal gland may mimic kidney
 - Bowel in renal fossa may mimic kidney
 - Fatal prognosis
 - Pulmonary hypoplasia
- **Ureteropelvic Junction Obstruction**
 - Ultrasound findings
 - ↑ renal pelvis is hallmark finding
 - Renal pelvis ≥ 7 mm after 32 weeks
 - Bullet-shaped renal pelvis
 - + peripheral calyceal dilation often present
 - No distended ureter or bladder
 - Evaluate contralateral kidney
 - Bilateral ureteropelvic junction (UPJ) obstruction in 10%
 - UPJ + contralateral renal anomaly in 25%
 - Prognosis
 - Depends on severity of obstruction
 - Early oligohydramnios → pulmonary hypoplasia
 - Postobstructive cystic dysplasia
- **Multicystic Dysplastic Kidney**
 - Renal tissue replaced by cysts
 - Ultrasound findings
 - Multiple variable-sized cysts
 - Kidney may lose reniform shape
 - ↑ renal size initially, then ↓
 - Severe oligohydramnios if bilateral
 - 20% of multicystic dysplastic kidneys are bilateral (anhydramnios)
 - 40% have contralateral renal anomaly
 - Poor prognosis if bilateral anomalies
- **Autosomal Recessive Polycystic Kidney Disease**
 - Distal tubule/collecting duct dilatation
 - Single gene disorder
 - Ultrasound findings

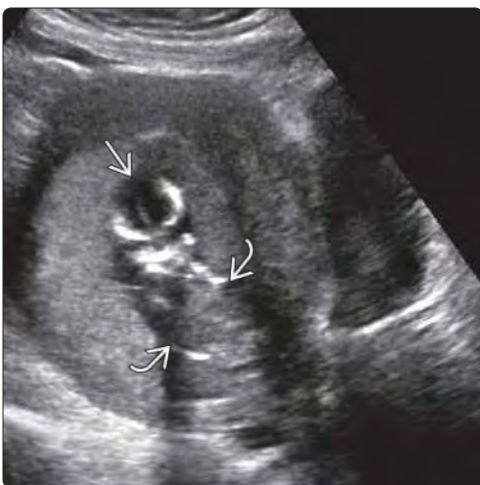
- Enlarging echogenic kidneys
 - May see relatively spared hypoechoic cortex
 - Macrocysts rarely seen: May see tubular ectasia
- Majority detected > 24 weeks
- Variable oligohydramnios
- Perinatal, neonatal, infantile, and juvenile presentations
 - Perinatal form with 30-50% mortality
 - Severe oligohydramnios → pulmonary hypoplasia
 - Hepatic fibrosis (rarely in utero)
- **Posterior Urethral Valves**
 - Partial or complete obstruction
 - Bladder distention + wall thickening
 - Dilated posterior urethra gives keyhole appearance
 - Variable upper tract and ureter dilation
 - ± postobstructive renal cystic dysplasia
 - Spontaneous decompression may occur
 - Bladder rupture → urinary ascites
 - Renal calyx rupture → urinoma
 - Consider in utero treatment if severe oligohydramnios
 - Serial bladder drainage to assess electrolytes
 - Vesicoamniotic shunt
 - May help with pulmonary function (not renal function)
- **Prune-Belly Syndrome**
 - Triad of findings
 - Deficient abdominal musculature
 - Collecting system dilation
 - Cryptorchidism (almost all cases are male)
 - Gross dilatation of collecting system is hallmark finding
 - Large, thin-walled bladder
 - Bilateral hydroureter
 - Bilateral hydronephrosis
 - Variable oligohydramnios
 - Difficult to differentiate from posterior urethral valves
 - Less likely keyhole bladder
 - Key finding: Entire urethra may be dilated
- **Twin-Twin Transfusion Syndrome**
 - Complication of monochorionic twinning
 - Artery to vein anastomosis in placenta
 - Donor twin partly perfuses recipient twin

- Donor twin with oligohydramnios and absent bladder
 - "Stuck" twin if severe
 - FGR seen later than oligohydramnios
 - ↑ resistive flow in umbilical artery
- Recipient twin with polyhydramnios
 - Larger twin

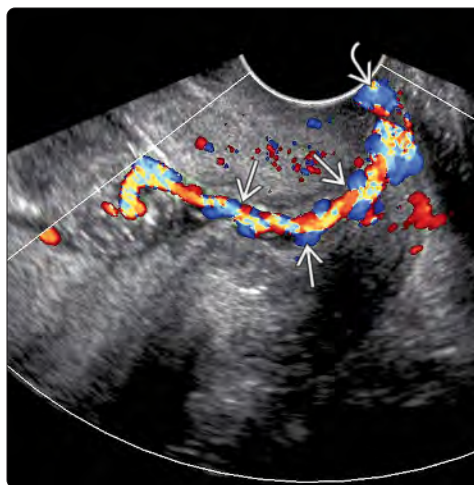
Other Essential Information

- Extreme early persistent oligohydramnios (< 22-24 weeks) associated with near 80% perinatal mortality
- Late worsening oligohydramnios → worse prognosis
 - Associated with fetal acidosis and death
 - Further fetal assessment indicated
 - Fetal growth and Doppler
 - Nonstress test
 - Biophysical profile
 - Reassess fetal anatomy carefully
- Biophysical profile (BPP) fluid assessment
 - Score of 0 or 2 for fluid
 - 2: At least 1 pocket of fluid measures ≥ 2
 - 0: No fluid pocket measures ≥ 2
 - Key fact: BPP is **not** same as AFI
 - Can have BPP score of 2 for fluid and still have significant oligohydramnios
- Role of amnioinfusion
 - Diagnostic role: Better visualization of fetal anomalies
 - Amnioinfusion for treatment of oligohydramnios has not been studied in controlled manner
 - 250 mL is presumed to increase AFI by 4 cm
 - Aim to reestablish a normal AFI of ≥ 8 cm
- Role of amniopatch for iatrogenic PPRM
 - Novel technique to achieve artificial membrane seal
 - Infusion of saline + cross-matched allogenic platelets + cryoprecipitate
 - Doubling of survival rates reported
 - Low neonatal and maternal risk reported

Preterm Prelabor Rupture of Membranes



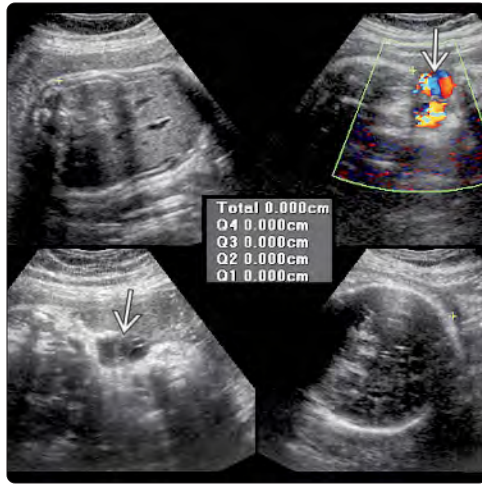
Preterm Prelabor Rupture of Membranes



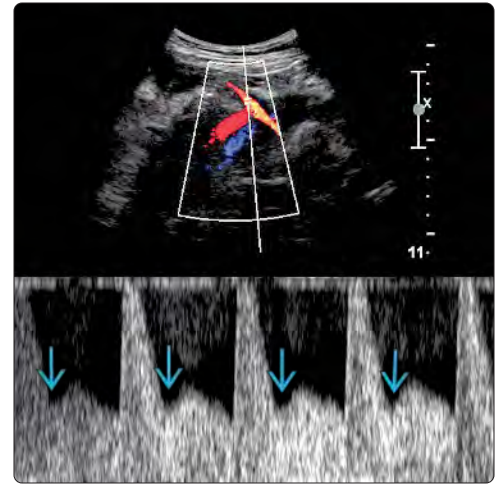
(Left) This 17-week pregnancy is complicated by iatrogenic PPRM from amniocentesis. The fetal head ➡ and body ➡ are compressed by the uterus and there is no measurable amniotic fluid. (Right) TVUS in the same patient shows the umbilical cord prolapsed through the cervical canal ➡ and into the vagina ➡. TVUS is not routinely performed with PPRM because of ↑ risk of infection. However, this prolapse was seen during sterile speculum exam, and ultrasound confirmation was requested.

Fetal Growth Restriction

(Left) Four-quadrant US shows no measurable pockets of fluid in a pregnancy complicated by maternal hypertension and fetal growth restriction (FGR) from placental insufficiency. All the hypoechoic "pockets" contain umbilical cord. (Right) In another patient with preeclampsia, oligohydramnios, and FGR, the uterine artery Doppler waveform is abnormal. The waveform shows high resistive flow and a postsystolic notch in the 3rd trimester, suggestive of placental insufficiency.

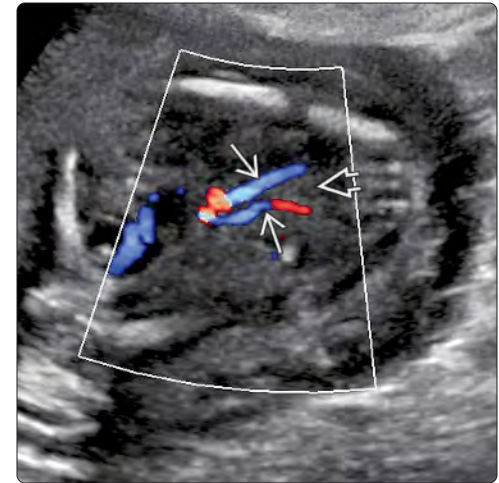
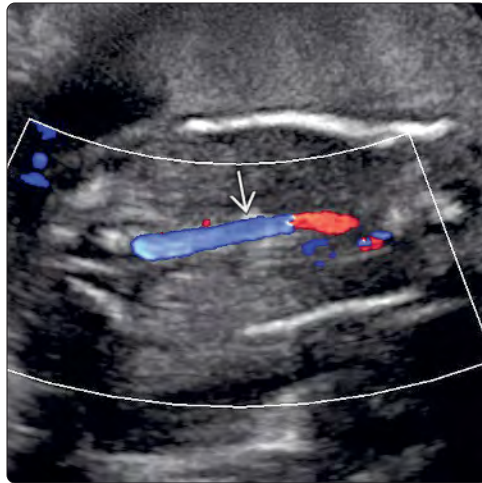


Fetal Growth Restriction



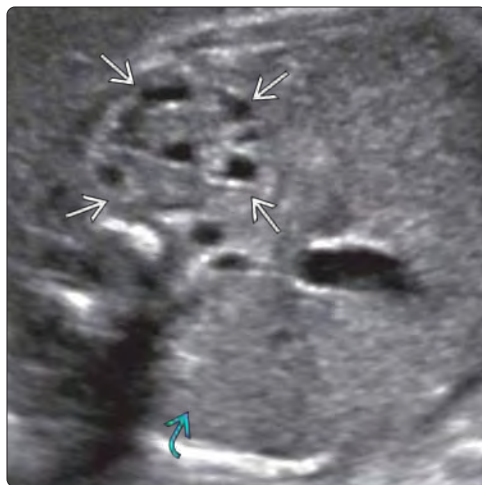
Renal Agenesis

(Left) This fetus with no amniotic fluid (anhydramnios) has bilateral renal agenesis. Color Doppler of the aorta shows absence of renal arteries. (Right) Axial view through the fetal pelvis in the same patient shows an empty fetal bladder. The umbilical arteries arise from the iliac arteries and flank either side of the bladder.

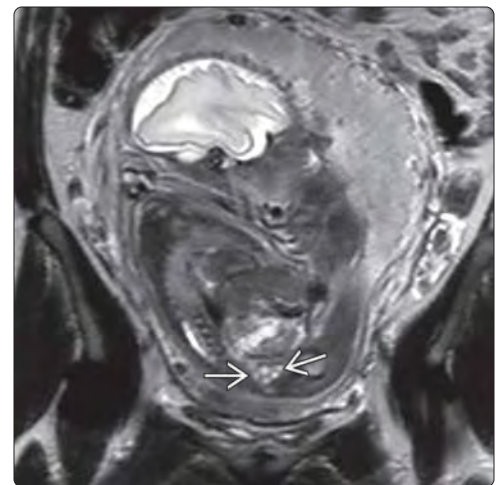


Multicystic Dysplastic Kidney

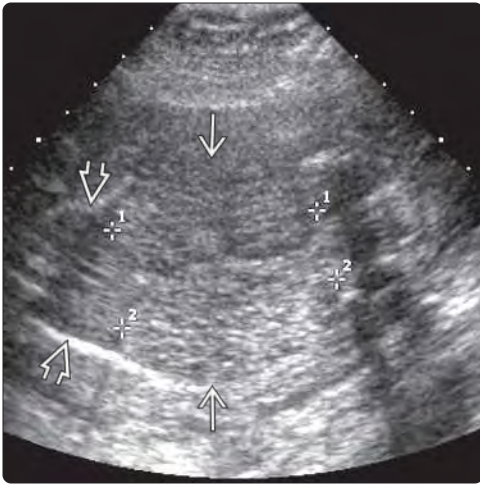
(Left) In this fetus with anhydramnios, there are a left renal agenesis multicystic dysplastic kidney (MCDK) and right renal agenesis. The right flank contains liver. 40% of fetuses with an MCDK have a contralateral renal anomaly. (Right) MR in another fetus with left MCDK and absent right kidney shows anhydramnios. Since the MCDK has no renal function, the prognosis for the fetus is dependent on the functional capacity of the contralateral kidney.



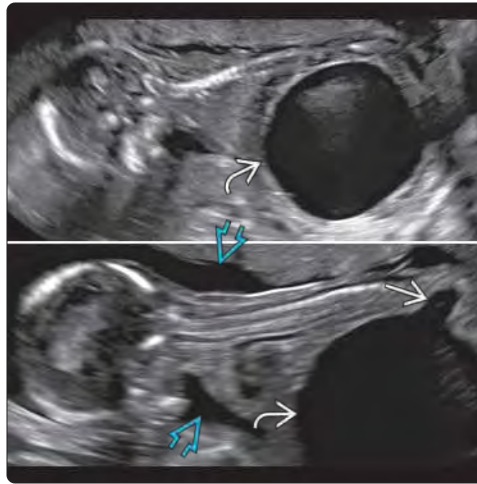
Multicystic Dysplastic Kidney



Autosomal Recessive Polycystic Kidney Disease

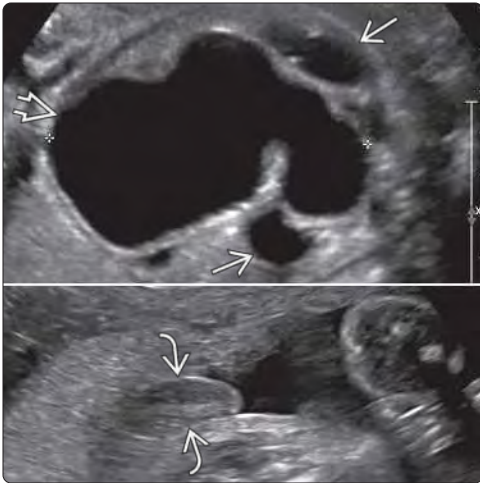


Posterior Urethral Valves

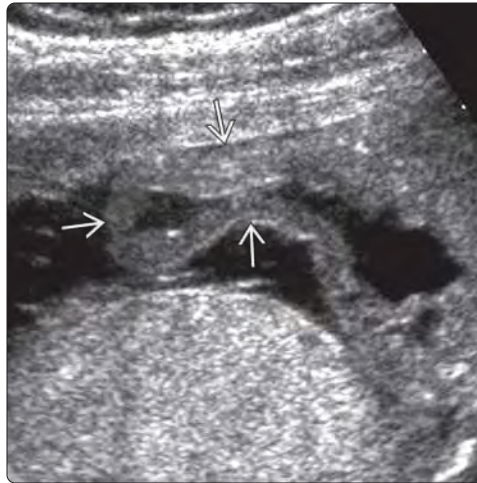

(Left) Coronal US shows bilateral enlarged echogenic kidneys and a small bell-shaped chest. There is no amniotic fluid in this case, but ARPKD can have variable degrees of oligohydramnios, depending on the severity of renal disease. (Right) In this case, the fetal bladder is markedly dilated, and there is distention of the posterior urethra, which gives the bladder an old-fashioned keyhole appearance. Note that some amniotic fluid is present, suggesting partial posterior urethral valve obstruction.

Prune-Belly Syndrome

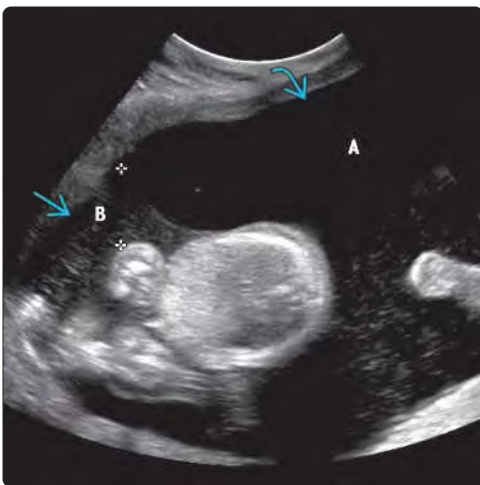


Prune-Belly Syndrome

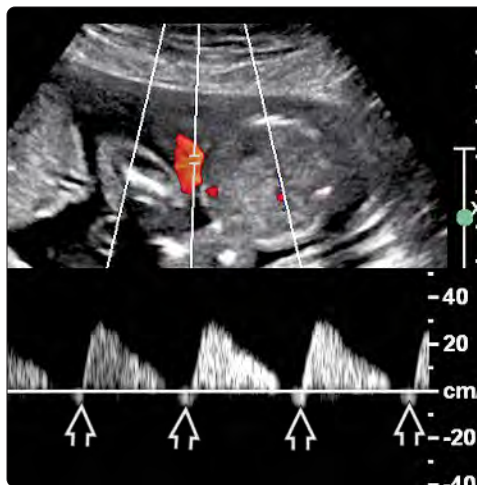


(Left) An enlarged bladder, dilated ureters, and empty scrotal sac are the key findings in this male fetus with prune-belly syndrome. Note the undulating bladder wall and the presence of some amniotic fluid. (Right) In another fetus with prune-belly syndrome, an image post bladder drainage shows laxity of the abdominal wall due to lack of abdominal wall musculature. This finding was not obvious before the vesicocentesis procedure, and posterior urethral valves as a cause for bladder distention were initially suspected.

Twin-Twin Transfusion Syndrome



Twin-Twin Transfusion Syndrome



(Left) There are oligohydramnios for twin B and polyhydramnios for twin A in this monochorionic diamniotic twin gestation complicated by TTTS. Discrepancy of fluid and absent fluid-filled bladder of the "donor" twin are initial findings. (Right) In another pregnancy with TTTS, the umbilical artery waveform shows reversed diastolic flow. This abnormal Doppler finding suggests advanced-stage TTTS, and treatment, such as laser ablation of vessel anastomoses, should be considered.

DIFFERENTIAL DIAGNOSIS**Common**

- Nonimmune Hydrops
 - Idiopathic
 - Cardiac
 - Structural Cardiac Defect
 - Tachyarrhythmia
 - Bradyarrhythmia
 - Chromosome Abnormalities
 - Turner Syndrome (XO)
 - Trisomy 21
 - Infection
 - Twin-Twin Transfusion Syndrome
- Immune Hydrops
 - Rh Incompatibility
 - Other Antibodies

Less Common

- Fetal Masses
 - Teratoma
 - Chest Masses
 - Congenital Hepatic Hemangioma
- Placental Chorioangioma
- Vascular Malformations
- Metabolic

ESSENTIAL INFORMATION**Key Differential Diagnosis Issues**

- Defined as fluid accumulation in 2 or more body cavities
 - Skin/subcutaneous edema (skin thickness > 5 mm)
 - Scalp edema often first sign
 - Ascites
 - Pleural effusion
 - Pericardial effusion
 - Other findings
 - Placentomegaly (placenta thickness > 40 mm in 2nd trimester, > 60 mm in 3rd)
 - Polyhydramnios
 - Hepatosplenomegaly
- Broadly classified as immune (hemolytic disease → fetal anemia) and nonimmune (all others)
 - 90% are nonimmune hydrops
 - 10% immune

Helpful Clues for Common Diagnoses

- **Idiopathic**
 - Over 50% of cases will not have identifiable cause
 - 2015 metaanalysis showed that ~ 30% of idiopathic NIH cases would be reclassified as lysosomal storage disease (LSD) if comprehensive work-up performed
 - LSDs occur in 5.2% of all NIH cases
 - Inborn error of metabolism; ~ 14 types associated with nonimmune hydrops (NIH)
 - Mucopolysaccharidosis type VII, Gaucher disease, and GM1-gangliosidosis most common
 - Most are autosomal recessive → 25% recurrence risk in future pregnancies
- **Structural Cardiac Defect**
 - Poor contractility → heart failure → hydrops

- May be accompanied by bradycardia
- **Tachyarrhythmia**
 - Sustained heart rate > 200 BPM (supraventricular tachycardia most common)
 - Hydrops develops in 50-75% fetuses with sustained tachycardia
 - Increased risk of ischemic brain injury when hydrops is present
- **Bradyarrhythmia**
 - 50% associated with cardiac malformation, particularly atrioventricular septal defects
 - 50% of cases seen in mothers with connective tissue disease
 - Increased mortality with heart rate < 50 BPM
- **Turner Syndrome (XO)**
 - Female fetus with large, septated cystic hygroma
 - Hydrops secondary to fluid overload from lymphatic obstruction
 - Edema is diffuse and may be dramatic
 - Dorsal pedal edema prominent feature
 - Hydrops can be seen in 1st trimester
 - Prognosis with hydrops is dismal
- **Trisomy 21**
 - Small cystic hygroma (increased nuchal translucency in 1st trimester) becomes nuchal thickening in 2nd trimester
- **Infection**
 - Parvovirus most common but can occur with any severe infection
 - Infection → anemia, myocarditis
 - Look for associated intracranial and liver calcifications, ventriculomegaly, hepatosplenomegaly, echogenic bowel, growth restriction
- **Twin-Twin Transfusion Syndrome**
 - Monochorionic twins with artery-to-vein anastomoses in placenta
 - Recipient is volume overloaded; at risk for hydrops
 - Larger twin with polyhydramnios
 - Donor in high-output state
 - Smaller twin with oligohydramnios ± growth restriction
 - Twin-twin transfusion syndrome (TTTS) staging
 - Stage 1: Donor bladder visible, normal Doppler
 - Stage 2: Donor bladder empty, normal Doppler
 - Stage 3: Donor bladder empty, abnormal Doppler
 - Stage 4: Hydrops in recipient
 - Stage 5: Demise of 1 or both
- **Immune Hydrops**
 - Maternal antibodies cross placenta and cause lysis of fetal red blood cells, leading to fetal anemia
 - Anemia causes elevated middle cerebral artery (MCA) peak systolic velocity (PSV)
 - Need for intervention (transfusion) generally based on relationship of MCA PSV to gestational age
 - **Rh Incompatibility**
 - Maternal lack of D antigen on erythrocyte membrane (Rh -)
 - Sensitization 2° to fetal-maternal hemorrhage
 - Fetal D antigen causes maternal antibody response (< 1 cc fetal cells can lead to anti-D antibody response)

- With subsequent pregnancy, maternal antibodies attack fetal red blood cells
- Causes anemia, may progress to hydrops if left untreated
- o **Other Antibodies**
 - Non-D antigen causes alloimmunization (usually from incompatible blood transfusion)
 - Kell, Duffy, Kidd, E, C, c, and others
- **Fetal Masses**
 - o Any mass causing increased cardiac output may lead to hydrops
 - Teratomas most common
 - Congenital hepatic hemangioma may cause thrombocytopenia in addition to arteriovenous shunting
 - o Chest masses may also impede cardiac return
- **Placental Chorioangioma**
 - o Benign, vascular placental tumor
 - o Fetal hydrops from arteriovenous shunting or from fetal anemia secondary to hemolysis
 - Hydrops uncommon if mass is < 5 cm

- o Polyhydramnios common with large masses
- **Vascular Malformation**
 - o Arteriovenous shunting causes high output
 - o Brain lesions (e.g., vein of Galen malformation) may cause brain ischemia due to vascular steal

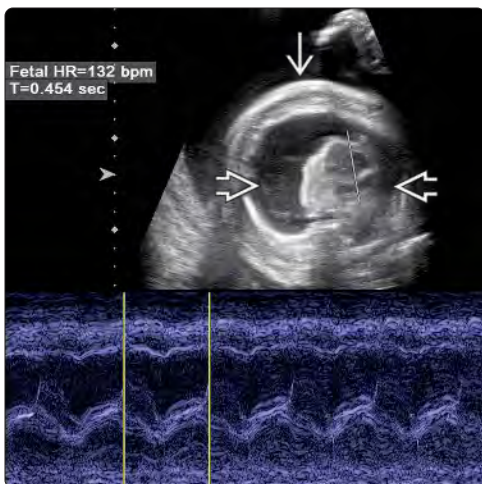
Other Essential Information

- 1st-trimester hydrops highly associated with aneuploidy
- Nonimmune hydrops
 - o Over 50% have no unifying diagnosis or directly identifiable cause
 - o 22% have cardiac defect
 - o 16% have aneuploidy; Turner syndrome > trisomy 21
- Screen for lysosomal disorders in apparently idiopathic hydrops

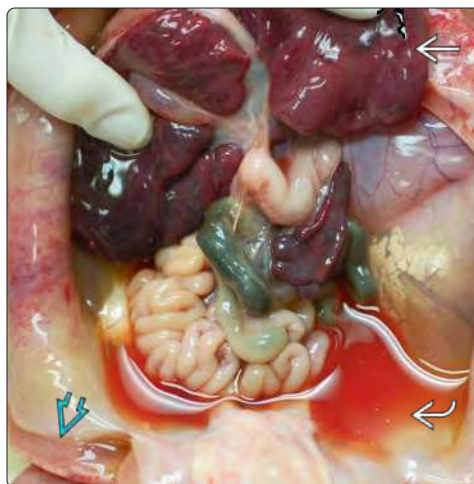
SELECTED REFERENCES

1. Gimovsky AC et al: Lysosomal storage disease as an etiology of nonimmune hydrops. *Am J Obstet Gynecol.* 212(3):281-90, 2015
2. Society for Maternal-Fetal Medicine (SMFM) et al: Society for maternal-fetal medicine (SMFM) clinical guideline #7: nonimmune hydrops fetalis. *Am J Obstet Gynecol.* 212(2):127-39, 2015

Idiopathic

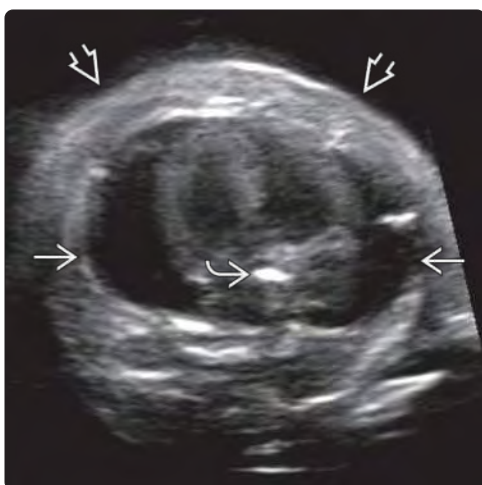


Idiopathic

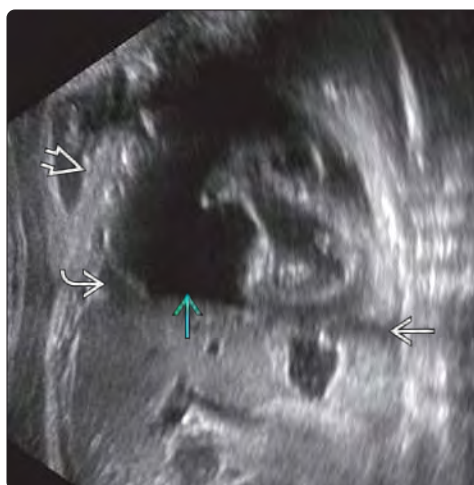


(Left) Axial image through the chest shows skin edema and pleural effusions. The heart structure, rate, and rhythm were normal. Amniocentesis showed normal chromosomes, and all other testing was negative. This is a case of idiopathic hydrops. (Right) This is a picture from the autopsy performed on 1 of a pair of dichorionic twins. Note the congested liver, ascites, and severe skin edema. The co-twin was normal. This is another case of idiopathic hydros.

Structural Cardiac Defect



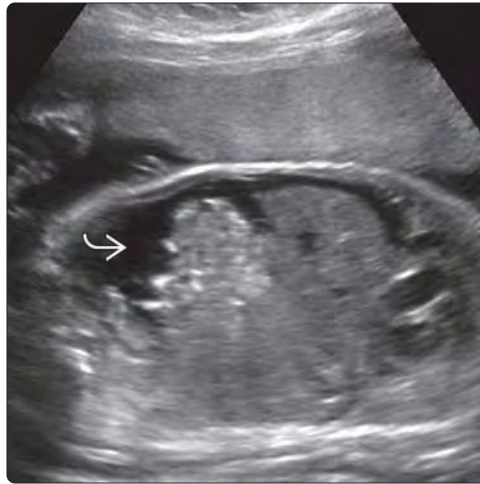Structural Cardiac Defect



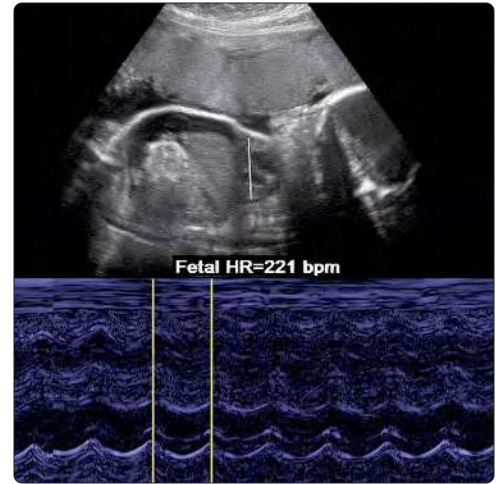
(Left) Transabdominal ultrasound shows a massive pericardial effusion and skin thickening in this fetus with idiopathic arterial calcification of infancy. Note the calcified aortic root. This was an IVF twin pregnancy; the co-twin was normal. (Right) Coronal image through the chest shows skin edema and pleural and pericardial effusions in a fetus with Ebstein anomaly. The wall-to-wall heart fills the thorax; this is mainly due to the markedly enlarged right atrium.

Tachyarrhythmia

(Left) Sagittal US through the fetal abdomen confirms the referring physician's concern for ascites. The differential diagnosis for ascites is broad, so further evaluation is required. (Right) M-mode ultrasound through the fetal heart (same case) showed intermittent runs of supraventricular tachycardia. Highest rate documented was 221 beats per minute (BPM). Ascites is often the 1st sign of impending hydrops in fetuses with tachycardia. In this case, medical management was successful before onset of full-blown hydrops.

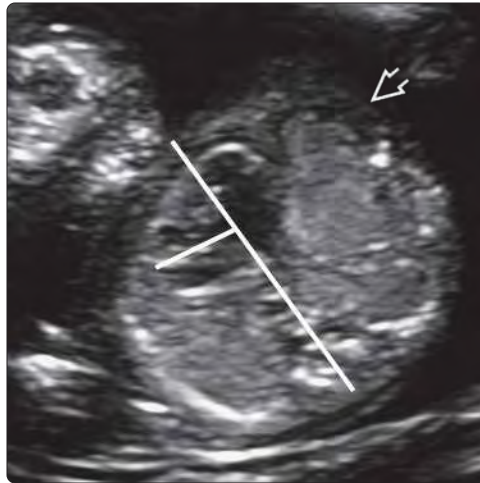


Tachyarrhythmia

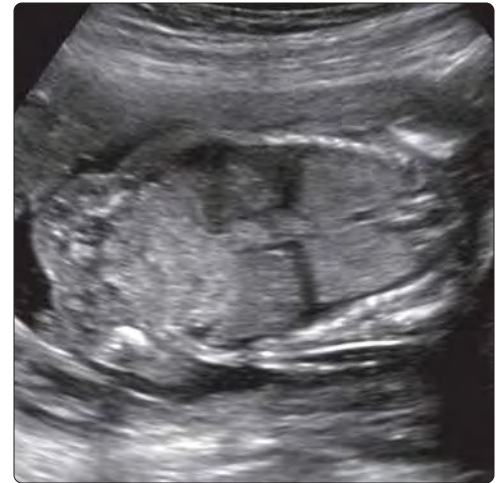

Bradycardia

(Left) This image through the thorax of a 14-week fetus shows an abnormal cardiac axis, close to 90°. The appearance of the heart was suspicious for an atrioventricular septal defect (AVSD), and the heart rate was slow. There is also the suggestion of skin thickening. (Right) Hydrops developed by 17 weeks, and intrauterine demise occurred shortly after this scan. Autopsy confirmed unbalanced AVSD and left atrial appendage isomerism. Complete heart block is frequently associated with this condition.

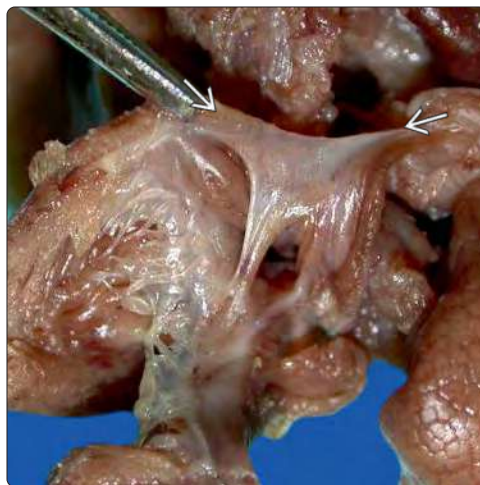

Bradycardia

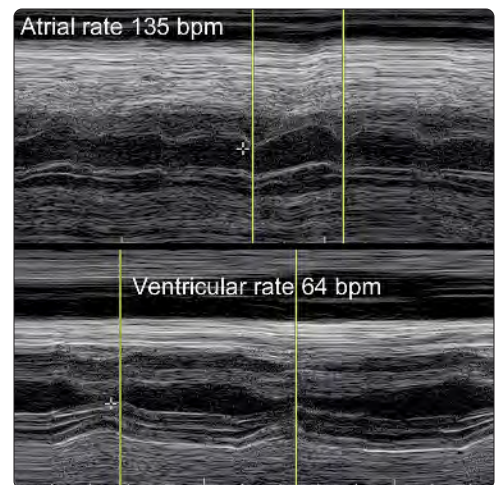


Bradycardia

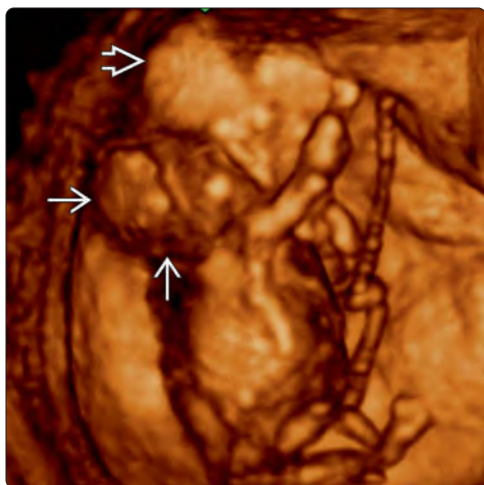
(Left) Autopsy shows the common atrioventricular valve seen with AVSDs. The lack of the normal crux of the heart results in an abnormal conducting system. Hence, complete heart block is associated with AVSDs. (Right) M-mode ultrasound shows a ventricular rate of 65 BPM compared to an atrial rate of 135 BPM in this fetus with complete heart block.



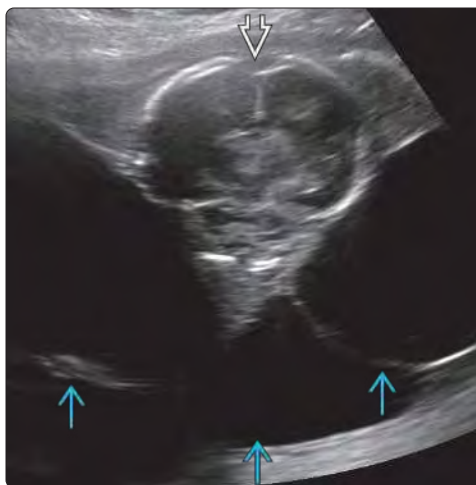
Bradycardia



Turner Syndrome (XO)

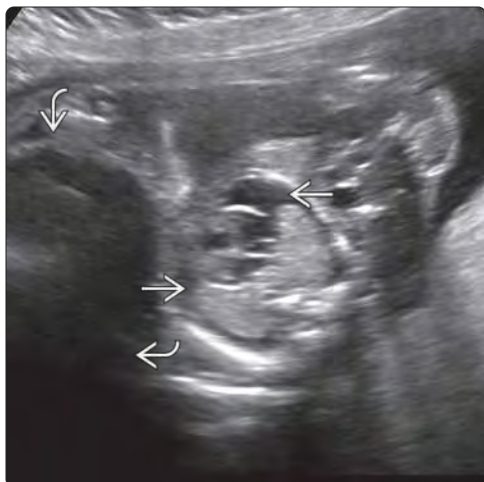


Turner Syndrome (XO)

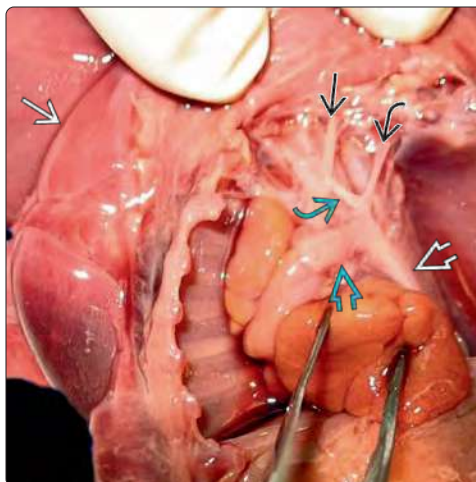


(Left) 3D ultrasound in a late 1st-trimester fetus shows a cystic hygroma behind the head. Chorionic villus sampling revealed Turner syndrome. (Right) Coronal image through the fetal head in a different case of Turner syndrome shows a massive cystic hygroma with the multiloculated mass filling the uterine cavity.

Turner Syndrome (XO)

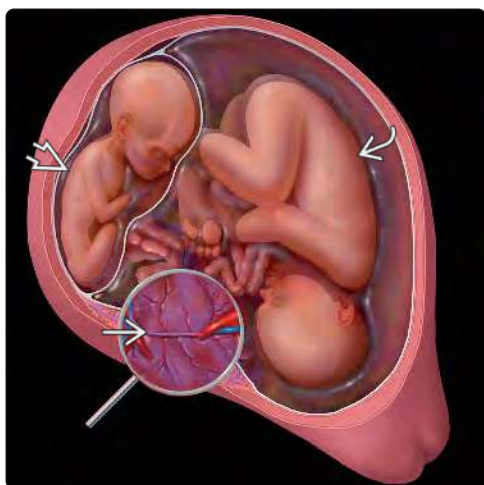


Turner Syndrome (XO)

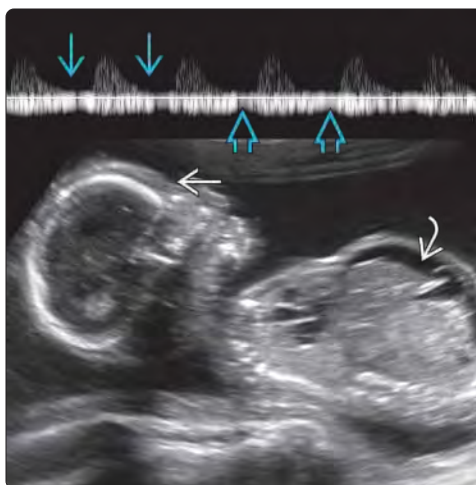


(Left) Axial image through the chest of the same fetus shows bilateral pleural effusions and marked soft tissue thickening and lymphangiectasia. (Right) Autopsy shows a portion of a large cystic hygroma. Dissection of the outflow tracts shows severe coarctation of the aorta between the left carotid and left subclavian arteries. The distal aorta reconstitutes from the ductus arteriosus. Left heart outflow obstruction is a common finding in Turner syndrome.

Twin-Twin Transfusion Syndrome



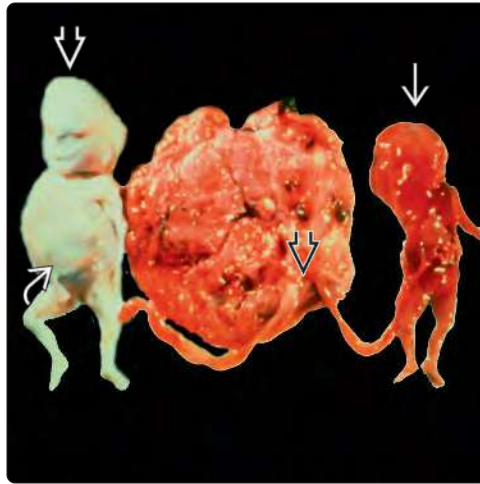
Twin-Twin Transfusion Syndrome



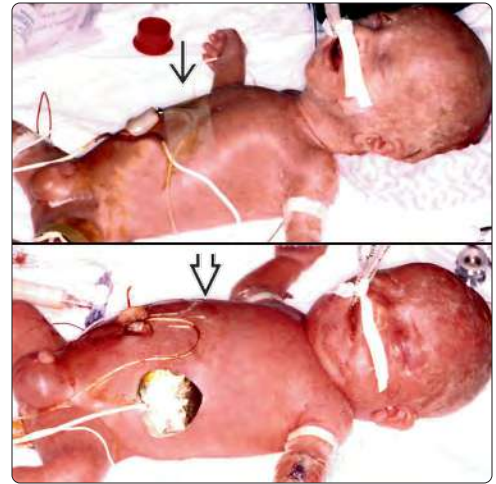(Left) Graphic shows discordant monozygotic twins with a unidirectional arteriovenous shunt of deoxygenated blood from the oligemic, poorly grown donor to the hypervolemic recipient with oligohydramnios to the hypervolemic recipient with polyhydramnios. (Right) Image through torso of recipient twin at 19 weeks shows ascites & skin edema. Also note very abnormal cord Doppler with absent end-diastolic flow & pulsatile venous flow. She was treated with laser ablation but unfortunately ruptured membranes at 21 weeks.

Twin-Twin Transfusion Syndrome

(Left) Gross pathology from a different case shows a hydropic recipient twin with edema and ascites and a small donor twin. Note the close proximity of the cord insertions. (Right) Liveborn premature twins show the difference between the oligemic, growth-restricted donor twin and the hydropic, plethoric volume-overloaded recipient twin in another example of twin-twin transfusion syndrome.

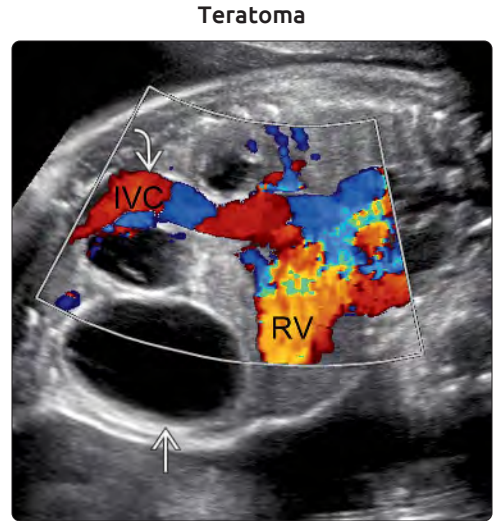
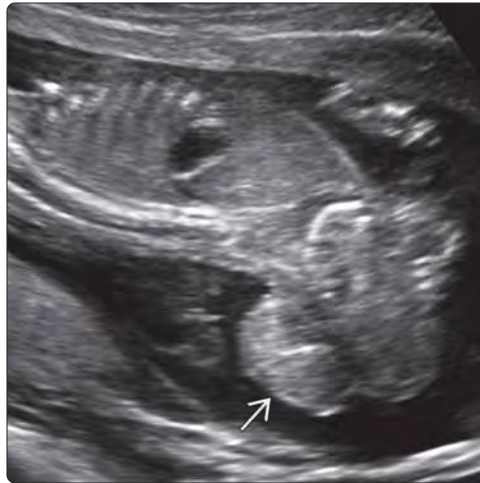

Twin-Twin Transfusion Syndrome



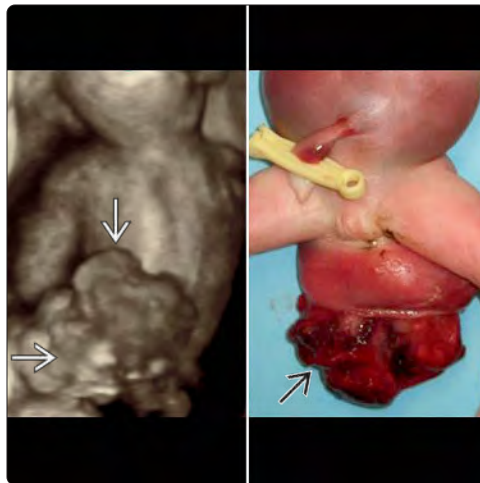
Teratoma

(Left) Sagittal image through the pelvis in a 17-week fetus shows a large, primarily exophytic, solid mass. (Right) Sagittal color Doppler of the abdomen just a few weeks later shows a very dilated inferior vena cava (IVC) returning to the heart (RV = right ventricle). The sacrococcygeal teratoma had grown dramatically, obstructed the bladder, and become hypervascular. Arteriovenous shunting explains the large IVC. The fetus became hydropic and died in utero.

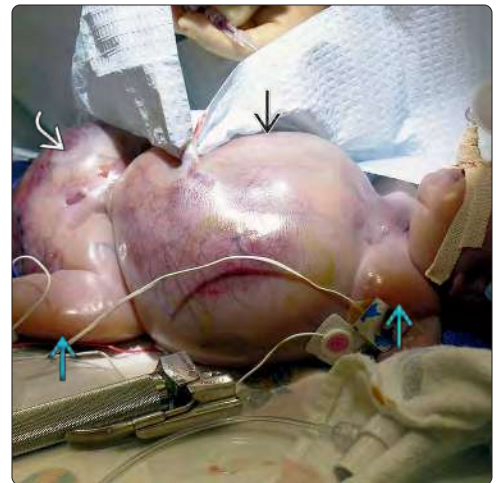

Teratoma

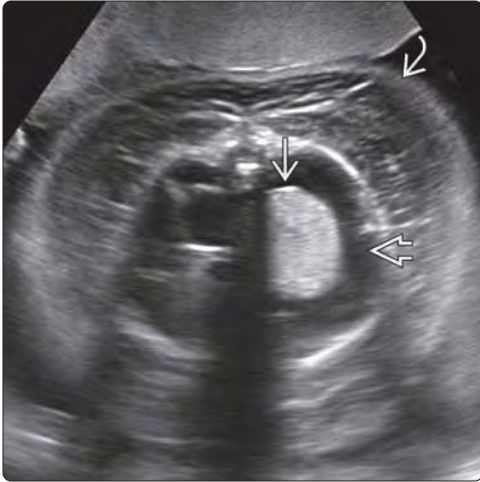(Left) Rarely, sacrococcygeal teratomas may rupture in utero. The 3D ultrasound shows very irregular contour to the mass, and there was debris in the amniotic fluid. Bleeding and anemia exacerbate cardiac failure. The autopsy image shows the ruptured mass. (Right) Clinical photograph during neonatal resuscitation shows severe skin edema and marked abdominal distension due to ascites in an infant with hydrops secondary to a vascular sacrococcygeal teratoma.



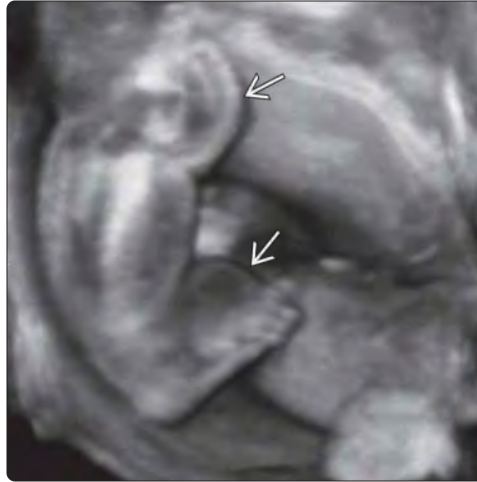Teratoma



Chest Masses

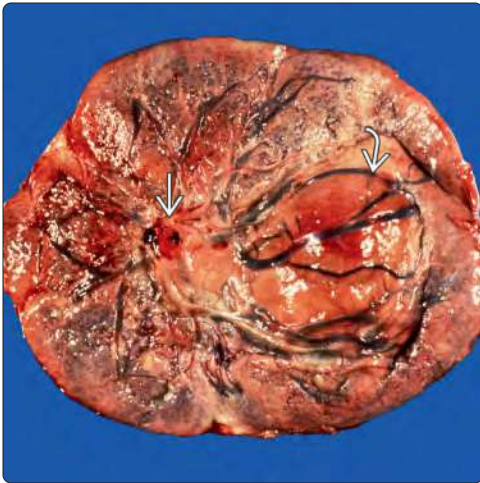


Chest Masses

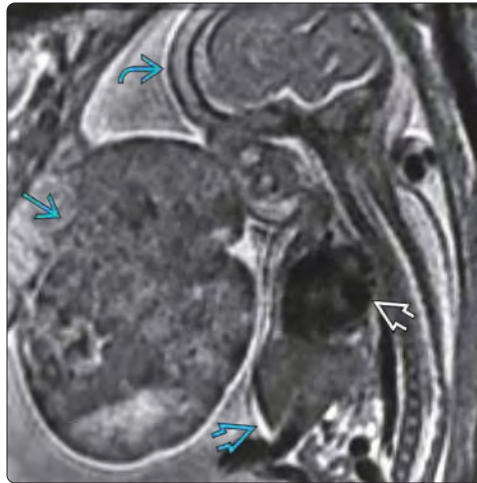


(Left) Axial image through the chest shows an echogenic mass with convex borders surrounded by pleural fluid in a fetus with dramatic skin edema. Collapsed lung is not hyperechoic and should have concave or flat borders. Doppler confirmed a feeding vessel from the aorta. This is a bronchopulmonary sequestration with tension hydrothorax and hydrops. (Right) 3D surface rendering demonstrates the diffuse skin edema in the same case; even the feet are extremely swollen.

Placental Chorioangioma

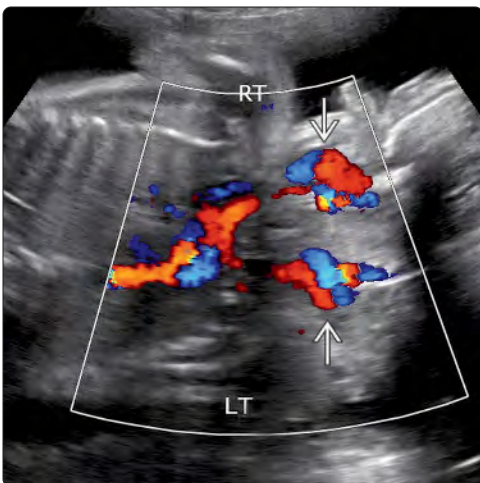


Placental Chorioangioma

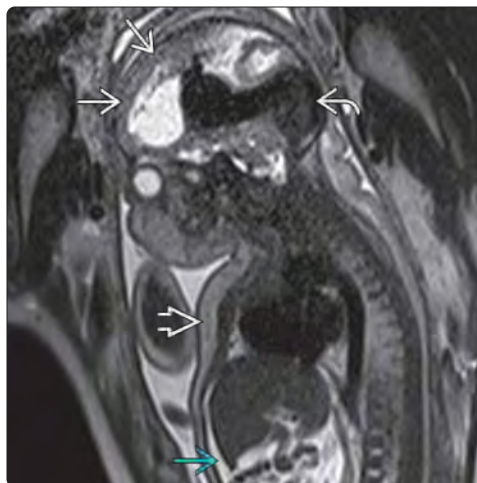


(Left) Gross photograph shows a chorioangioma bulging the fetal surface of the placenta near the cord insertion site. This is a very typical appearance of a chorioangioma. If > 5 cm in diameter, they can be associated with hydrops, as they are often hypervascular. (Right) T2WI MR shows inhomogeneous signal in a large chorioangioma. In this case, the fetus is hydropic with cardiomegaly, skin edema, and ascites.

Vascular Malformations



Vascular Malformations

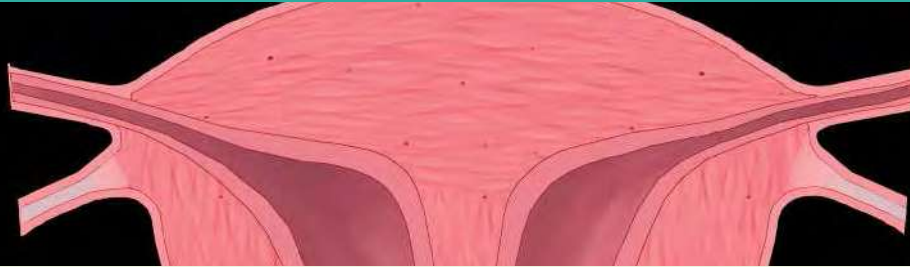


(Left) Coronal color Doppler ultrasound shows dramatic enlargement of both carotid arteries and jugular veins in this fetus with a vein of Galen malformation. The arteriovenous shunting causes high output, and the increased venous return adds volume overload. Hydrops, if it occurs, confers poor prognosis. (Right) Sagittal T2WI MR in the same case shows the vein of Galen malformation as well as skin edema and ascites, indicating hydrops. The MR was done to confirm the diffuse ischemic encephalomalacia.

This page intentionally left blank

SECTION 16

Maternal Conditions in Pregnancy



Cervical Insufficiency/Short Cervix	1060
Myoma in Pregnancy	1066
Müllerian Duct Anomalies in Pregnancy	1070
Synechiae	1074
Uterine Rupture	1076
Retained Products of Conception	1080
Pertinent Differential Diagnoses	
Acute Abdomen in Pregnancy	1082
Intrauterine Linear Echoes	1086

Cervical Insufficiency/Short Cervix

KEY FACTS

TERMINOLOGY

- Cervical insufficiency (CI): Inability of cervix to retain pregnancy in absence of contractions or labor
 - Clinical diagnosis
- Short cervix: Cervical length (CL) < 10th percentile for gestational age
 - Sonographic observation; < 25 mm at < 24 weeks

IMAGING

- Dilated internal os (IO): Measure anterior-posterior diameter
- Check CL at beginning of exam as cervix is dynamic; length is shortest in patients who have recently been upright
 - Observe for 3-5 minutes with TVUS
 - Avoid excessive vaginal transducer pressure
 - Use fundal pressure to unveil short cervix

TOP DIFFERENTIAL DIAGNOSES

- Normal hypoechoic cervical canal can mimic fluid

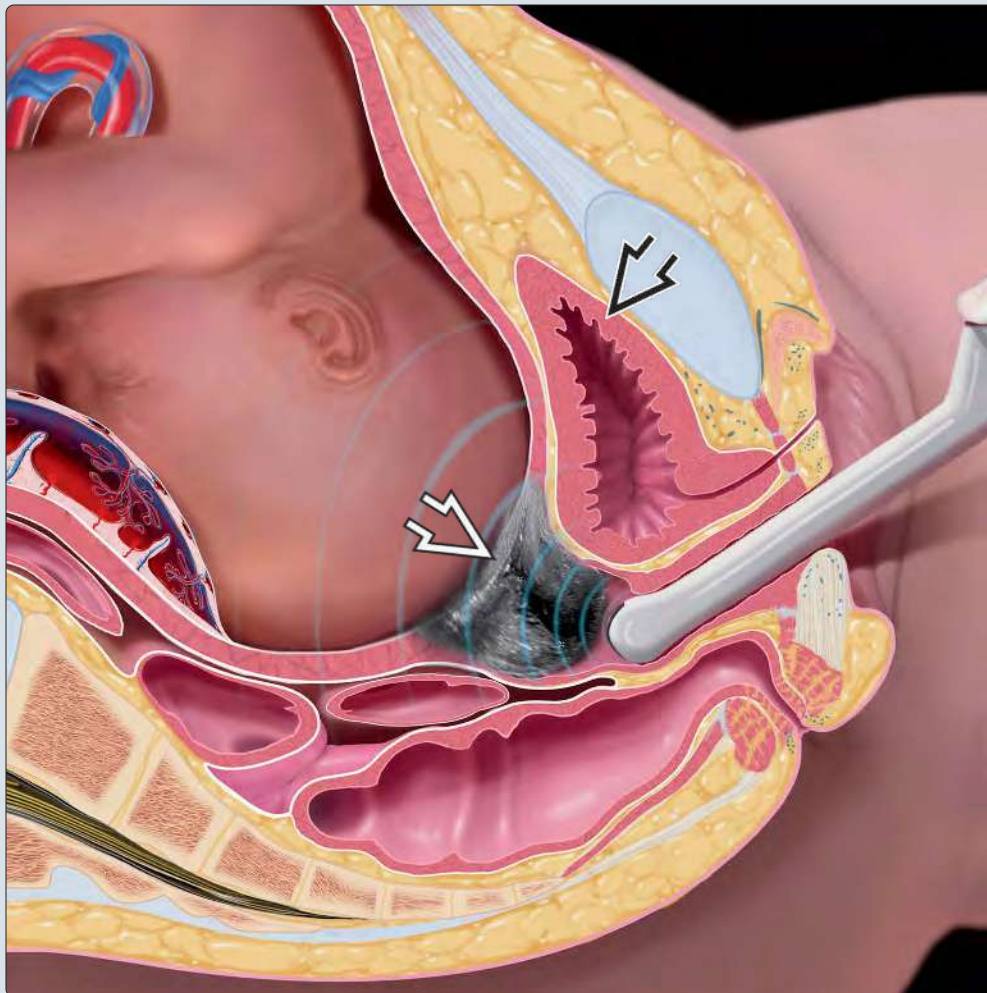
- Nabothian cyst

CLINICAL ISSUES

- US more sensitive to cervical shortening than manual exam at < 32 weeks
- Most patients at risk for CI can be safely monitored with serial TVUS examinations
- Look for preterm labor/infection if CL ↓
- Progesterone administration is an ongoing area of investigation regarding optimal dose and route
- Cervical cerclage limited to 2nd-trimester pregnancies, usually before viability
- Cerclage potentially harmful in multiple gestations

DIAGNOSTIC CHECKLIST

- TVUS is best, most reproducible technique for evaluation of CL
- Report single best, shortest CL, widest IO, measured on TVUS



This graphic illustrates the 3rd-trimester cervix. The transducer is placed in the vagina and withdrawn until the cervix is just in focus. In this way, the cervix is not compressed by the transducer, as doing so can cause artificial elongation and obscure a short cervix or dynamic changes. The position where the transducer is placed for an abdominal US is not sufficient for evaluation of cervical length as the image quality is compromised by the pubic symphysis and presenting fetal parts. If full, the bladder can compress the lower uterine segment to mimic a long, closed cervix. Correct technique is crucial in assessment of cervical length.

TERMINOLOGY

Synonyms

- Cervical incompetence

Definitions

- **Cervical effacement:** Process of softening, shortening, and thinning of cervix in preparation for delivery
- **Cervical dilation:** Progress enlargement of cervical canal to fully dilated at 10 cm
- **Cervical insufficiency (CI):** Inability of uterine cervix to retain pregnancy in 2nd-trimester, in absence of uterine contractions
 - Clinical diagnosis usually based on history of midtrimester loss without painful contractions
- **Short cervix:** Cervical length (CL) < 10th percentile for gestational age (GA)
 - Sonographic observation: Length of < 25 mm at < 24 weeks
- **Funneling:** Protrusion of amniotic membranes into cervical canal
- **Preterm birth (PTB):** Delivery before 37th week of pregnancy

IMAGING

General Features

- Best diagnostic clue
 - CL < 10th percentile for GA on transvaginal ultrasound (TVUS) indicates short cervix
 - < 25 mm at < 24 weeks is short
 - 25 mm is 50th percentile at 32 weeks

Ultrasonographic Findings

- Dilated internal os (IO): Measure anterior-posterior diameter
- Progressive dilation with changing shape of IO/cervical canal from T → Y → V → U
 - Normal membranes create T shape at IO
- Membranes may funnel through dilated cervix to external os (EO) or beyond
- Check CL at beginning of exam as cervix is dynamic
 - Length is shortest in patients who have recently been upright
- Amniotic fluid "sludge" (attributed to inflammatory debris)

Imaging Recommendations

- Best imaging tool
 - TVUS essential in high-risk patients or if CL < 30 mm on transabdominal ultrasound (TAUS)
 - Consider transperineal ultrasound if TVUS is contraindicated
- Protocol advice
 - TVUS technique; have patient empty bladder completely
 - Carefully insert probe while watching screen, advance until cervix clearly seen
 - Find midline sagittal plane, withdraw transducer until cervix just in focus
 - Avoids excessive vaginal transducer pressure, which may falsely increase length
 - Magnify image so cervix occupies 75% of screen
 - Measure from IO to EO

- Obtain measurements over 3-5 minutes
- Apply fundal pressure for 15 seconds
- Perform serial evaluation of CL from 16-24 weeks in high-risk patients
 - Prior 2nd-trimester loss, PTB (biggest risk factor for PTB is prior history)
 - Prior cervical surgery, diethylstilbestrol exposure, müllerian duct anomaly
 - Multiple gestations

DIFFERENTIAL DIAGNOSIS

Normal Cervix

- Hypochoic cervical canal can mimic fluid in cervical canal

Nabothian Cyst

- Can mimic fluid in cervical canal

PATHOLOGY

General Features

- CI is multifactorial (inflammation, infection, uterine overdistention, prior trauma/surgery, loss of stromal resistance)
 - Intrinsic weakness
 - Connective tissue disease

CLINICAL ISSUES

Presentation

- Most common signs/symptoms
 - Painless cervical dilation leading to delivery in 2nd-trimester
 - Short cervix can be incidental finding in low-risk patient or be found during screening of high-risk patient
- Ultrasound more sensitive to cervical shortening than manual exam at < 32 weeks

Demographics

- Short cervix seen in 1% of singleton pregnancies, 6% of twins, 20% of triplets

Natural History & Prognosis

- PTB (12% of all pregnancies in USA) is leading cause of perinatal morbidity and mortality
 - CI is one of many causes
 - Short cervix is marker of increased risk for PTB
 - CL ≤ 25 mm at 16-24 weeks associated with ↑ PTB rates
 - 18% in low risk, 55% in high risk, 60% in twins
- PTB risk increases with shorter CL, progressive shortening
 - 0.2% risk at CL > 40 mm vs. 78% if CL = 5 mm
 - Risk increases 3% for each additional 1 mm of CL change from 24 to 28 weeks
- Worse prognosis if short cervix + funneling
 - Funneling > 50% of CL is most significant (79% risk PTB)
- Worse if intraamniotic inflammation or infection (IAI)
 - Look for amniotic fluid sludge, independent risk factor for PTB
- Qualitative fetal fibronectin (fFN) test is positive or negative
 - + fFN result of chorion/decidua disruption
 - - fFN has high negative predictive value; ↓ unnecessary interventions

Cervical Cerclage

Type	Indication	GA placed	Risk of Complications
Prophylactic			
Vaginal	Prior PTB or CI	12-14 weeks	Low
Abdominal	Trachelectomy, prior failed vaginal cerclage	12-14 weeks	Moderate if placed in pregnancy, low if placed in nonpregnant uterus
Medically Indicated			
Ultrasound	Prior spontaneous PTB + asymptomatic short cervix < 15mm	16-23 weeks	Moderate
Rescue	Dilated cervix (NOT just short) ± funneled, ballooned membranes	16-23 weeks	High even though only performed in absence of signs of labor or infection

Complications of cerclage placement include bleeding, infection, preterm labor, preterm birth (PTB), iatrogenic preterm premature rupture of membranes, cervical laceration, vesicovaginal fistula. CI = cervical insufficiency.

- Ongoing research into role of quantitative fetal fFN measurement in combination with CL measurement

Noninvasive Treatment

- Most patients at risk for CI can be safely monitored with **serial TVUS examinations**
 - Duration of surveillance 16-24 weeks
 - May avoid history-indicated cerclage in > 50% if CL normal
- Evaluate patients with short cervix for preterm labor, infection
- **Progesterone administration is ongoing and active area of investigation regarding optimal dose and route**
 - Intramuscular 17-hydroxyprogesterone may be given to women with history of prior PTB
 - Vaginal progesterone (VP) is given to women with short cervix and no history of prior PTB
- VP as effective as cervical cerclage in reducing PTB in women with singleton, prior PTB, short cervix
- Pessary placement has potential benefit in high-risk patients but is not FDA approved for use in USA
- Activity restriction, bed rest, and pelvic rest have not been proved to be effective for treatment of CI, and their use is discouraged

Cerclage

- Cervical cerclage limited to 2nd-trimester pregnancies almost always before viability
 - Indications: Prophylactic, US indicated or rescue
 - Placement: Vaginal or abdominal
- **Transvaginal cerclage** suture placed as cranial as possible for longest CL, removed at 36-38 weeks
 - McDonald: Pursestring or cloverleaf configuration
 - Shirodkar technique aims for higher placement on cervix
- **Transabdominal cerclage (TAC)** placed around lower uterine segment; cesarean delivery required
 - If transvaginal cerclage not possible or prior failure
 - TAC outcomes equivalent for open and laparoscopic placement
- If prior PTB at < 34 weeks + CL < 15 mm, cerclage seems to be effective for prevention of PTB
 - Cerclage not effective for prevention of PTB in patients with short cervix and no prior PTB history
 - Interaction of cerclage and VP is unclear

- Rescue cerclage may prolong pregnancy by 4-5 weeks
 - 2x reduction in PTB prior to 34 weeks
 - No large randomized trials to prove benefit, therefore, must counsel patients about potential risks
 - Greater risk of failure when EO > 4 cm or hourglass membranes
- **Cerclage potentially harmful in multiple gestations**
- **Cerclage monitoring** is controversial
 - American College Obstetrics and Gynecology bulletin says not required
 - Proponents argue that it helps counsel patients regarding prognosis if signs of stitch failure
 - Membranes at or beyond level of suture
 - In women with history-indicated cerclage, funneling is independent risk factor for PTB < 34 weeks
 - Odds ratio 10.6 if membranes to stitch < 15 mm at 18-24 weeks

DIAGNOSTIC CHECKLIST

Consider

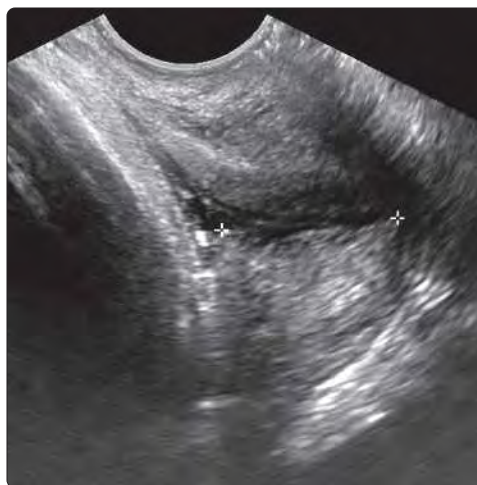
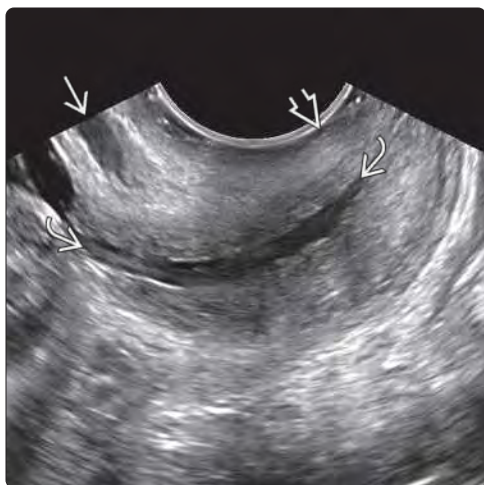
- TVUS is best, most reproducible technique for evaluation of CL
- Offer nuchal translucency and 1st-trimester screening for patients receiving early, history-indicated cerclage

Reporting Tips

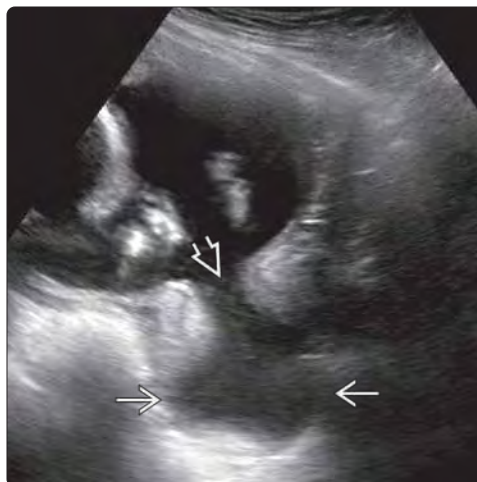
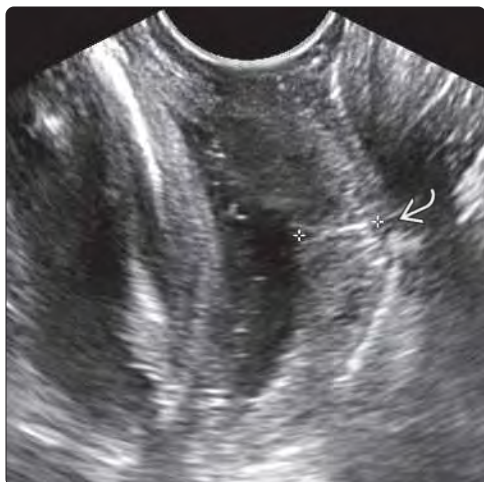- Report single best, shortest CL, widest IO, measured on TVUS
 - Note GA, history of prior PTB
 - Note shape, depth, width of funnel (extent of funneling)
- If scan performed for cerclage follow-up
 - Look for circumferential, echogenic sutures
 - Measure functional CL (length of closed cervix regardless of sutures)
 - Measure length from end of funnel to suture
 - Document funneling to or beyond suture

SELECTED REFERENCES

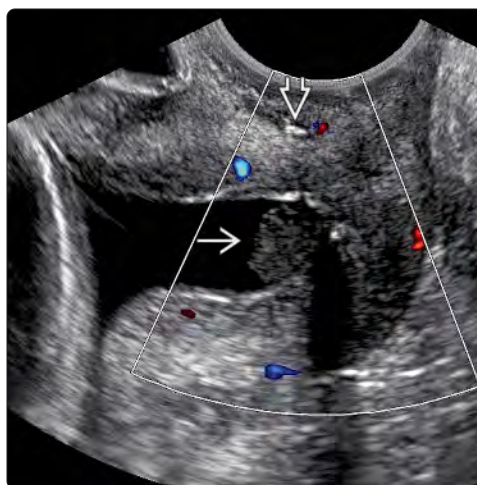
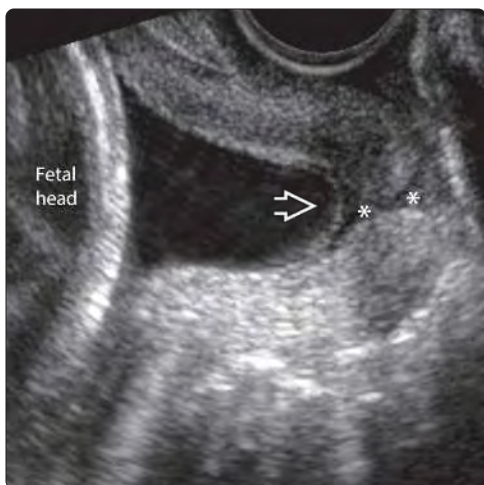
1. American College of Obstetricians and Gynecologists: ACOG Practice Bulletin No.142: Cerclage for the management of cervical insufficiency. *Obstet Gynecol.* 123(2 Pt 1):372-9, 2014



(Left) Sagittal TVUS at 20 weeks shows a long, closed, normal cervix with a prominent hypoechoic endocervical canal. The bladder is empty. The anterior lip of the cervix is slightly compressed by transducer pressure in this example performed for evaluation of vaginal bleeding and placental location. (Right) TVUS at 32 weeks shows a shorter cervical length (calipers). This is normal as the cervix softens in preparation for delivery. A short cervix is defined as length < 10th percentile for gestational age.

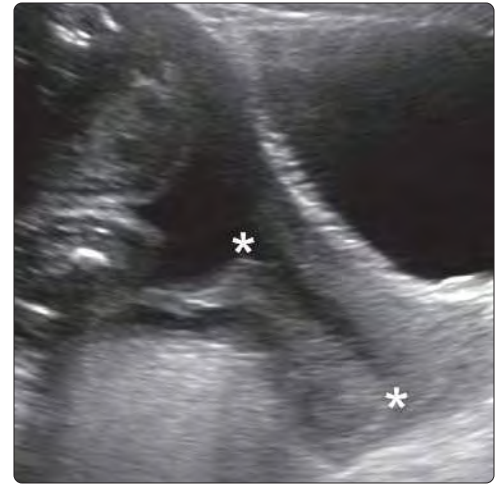
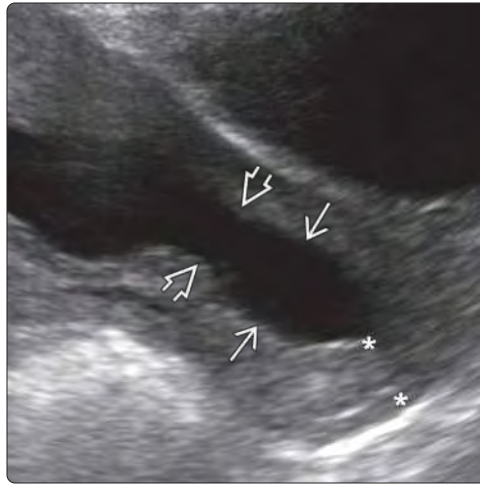


(Left) TVUS in a patient with preterm labor at 32 weeks shows a fully effaced, short cervix (calipers). Note that clinical evaluation only evaluates the external os, which is still closed in this case. (Right) Transabdominal US in an asymptomatic patient at 22 weeks shows cervical insufficiency with the membranes ballooned into the vagina through the dilated cervix, which forms the waist of the hourglass membranes.

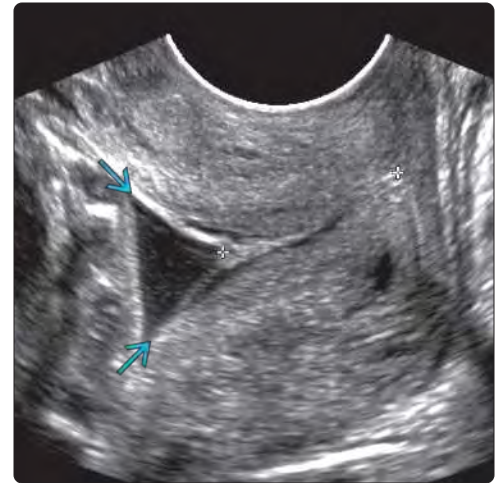
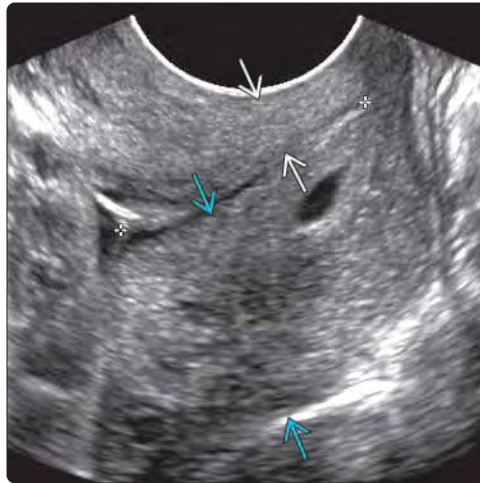


(Left) TVUS shows the membranes funneling into a U-shaped, dilated cervix with functional length of 6mm (calipers) at 32 weeks. This finding confers increased risk of preterm birth (PTB). (Right) TVUS in a similar case with funneled membranes shows the additional finding of amniotic fluid sludge, an independent risk factor for preterm birth. The membranes are at the level of the cerclage stitch. This places the patient at further increased risk of PTB.

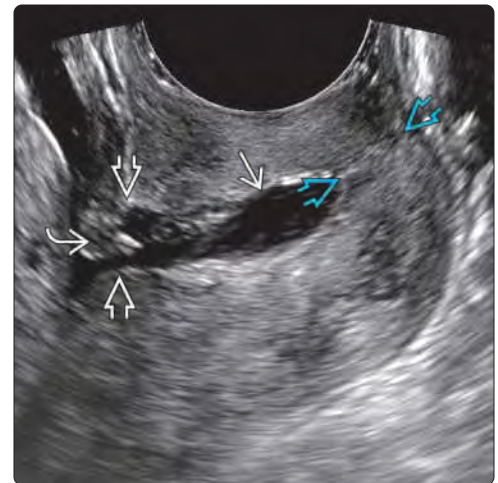
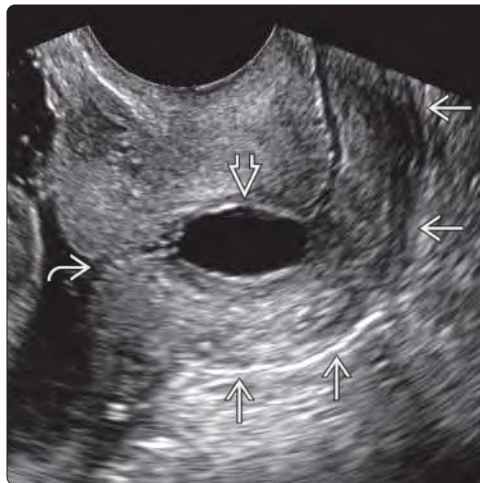
(Left) This transabdominal image of the cervix was taken at the start of the exam. The cervix (calipers = 10 mm) is short, the internal os is dilated, and the membranes are funneled over > 50% of the cervical length. **(Right)** Later in the same study, the cervix looked long and closed. This case illustrates the dynamic nature of cervical insufficiency and the importance of measuring cervical length when the patient has recently been up and active.

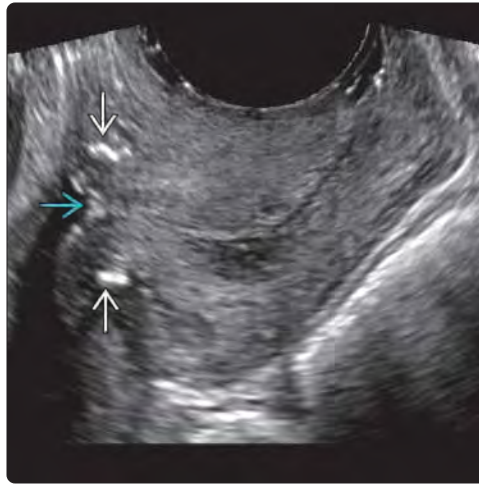
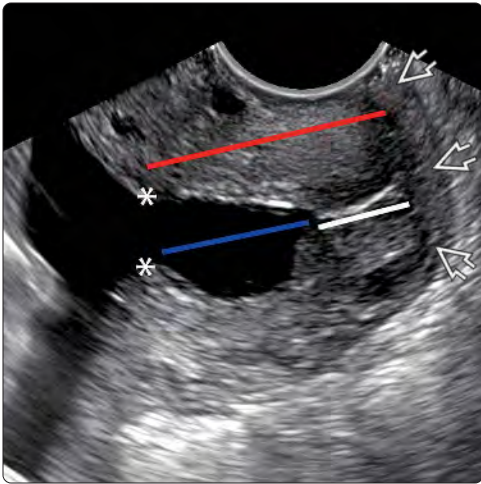


(Left) TVUS shows that the anterior lip of the cervix is much thinner than the posterior lip because the transducer is pressing on the cervix. The pressure upon the cervix will falsely elongate the cervix and may hide cervical shortening. **(Right)** Sagittal image of the same cervix without excessive pressure shows the anterior and posterior lips of the cervix to be equal in thickness and reveals funneling and a short cervix (calipers). Notice how the membranes form a V shape at the internal os.

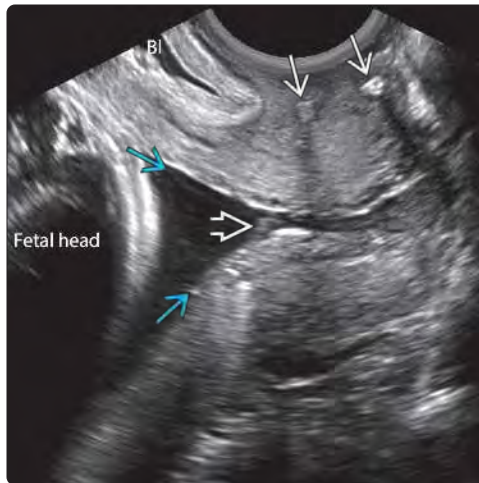
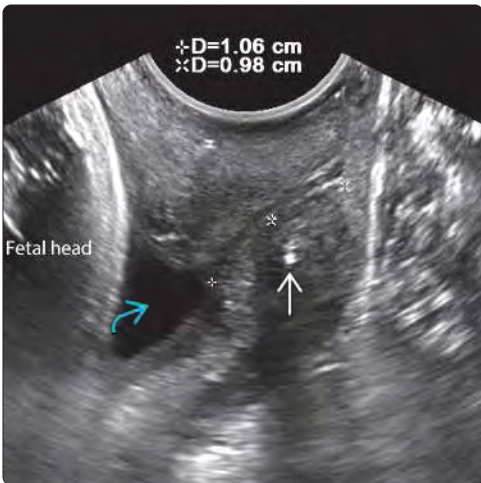


(Left) TVUS shows an oval, well-circumscribed fluid collection in the cervix. This is a nabothian cyst, which is an important pitfall. The cervix is long enough to still be curved and the internal os is closed. The cervix straightens before it shortens so the curved shape here is a clue that this is not cervical insufficiency. **(Right)** Contrast the prior case with this one in which sagittal TVUS shows funneled membranes and short cervix. The fetal foot was seen moving in and out of the dilated internal os in real time.

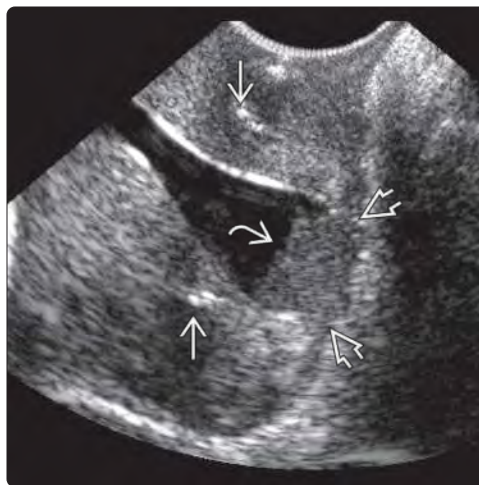
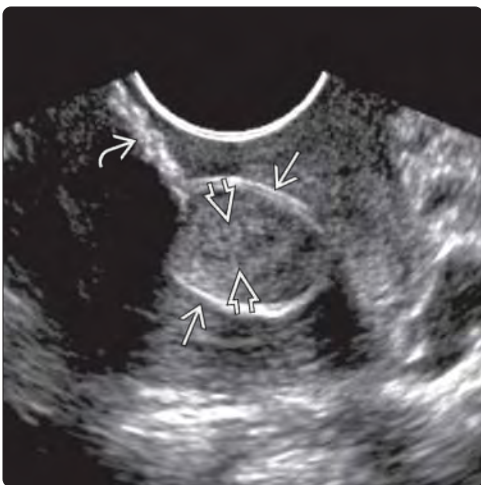




(Left) Sagittal TVUS shows how to document findings of cervical insufficiency. The calipers measure the internal os diameter, the blue line is the length of the funnel, the white line is the functional cervical length. Comparing the red (total cervical length) to blue line it is clear that the funnel is > 50% of total cervical length. Visualization of the vaginal fornix [red box] proves that the entire length of the cervix has been measured. (Right) In abdominal cerclage, the suture [red box] is in the lower uterine segment at the level of the internal os [blue box].



(Left) TVUS shows a vaginal cerclage suture [red box], which will always be "lower" than an abdominal cerclage where the stitch is placed through the lower uterine segment. Functional cervical length is 2.04 cm [sum of membranes to stitch (+) and stitch to external os (x)]. There is a short, V-shaped funnel [blue box] at the internal os. (Right) TVUS shows poor stitch placement. Suture material [red box] was only visible in the anterior lip of the cervix. The membranes are funneled [blue box] and there is a small amount of amniotic fluid sludge [red box]. (Bl = bladder)



(Left) Axial TVUS shows the ring of cerclage suture material [red box] and the knot [red box]. The cervical mucosa [red box] is visible centrally. Axial views can be additive if there is suspicion for cerclage malposition or slippage. (Right) Sagittal TVUS shows the appearance of cerclage failure despite correct placement. The membranes have ballooned through the stitch [red box] to the level of the external os [red box], which has started to dilate. The presence of amniotic fluid sludge [red box] is another ominous finding.

KEY FACTS

TERMINOLOGY

- Fibroid, leiomyoma
- Benign uterine tumor composed of smooth muscle

IMAGING

- Note location, type, and size
 - Fundus, body, lower uterine segment (LUS), cervix
 - Intramural, subserosal, submucosal, pedunculated
 - Measure in 3 orthogonal planes
 - Note relationship with placenta
- Ultrasound
 - Well-defined, hypoechoic myometrial mass
 - Degenerated fibroids are often cystic and heterogeneous
- MR helpful for complicated cases
 - T2WI: Homogeneous, ↓ signal intensity
 - Degeneration causes variable signal

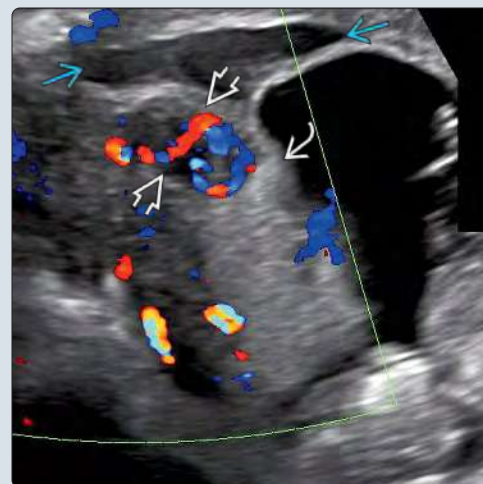
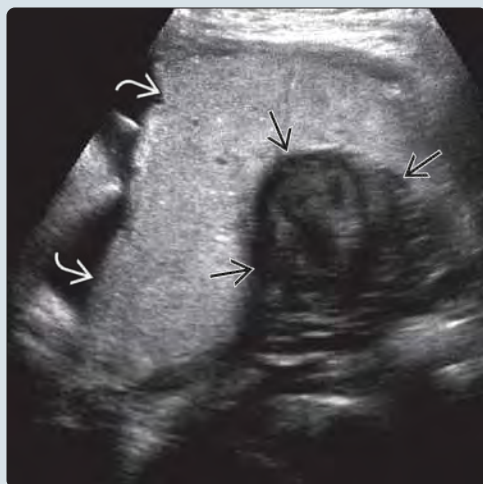
TOP DIFFERENTIAL DIAGNOSES

- Focal myometrial contraction
- Placental abruption

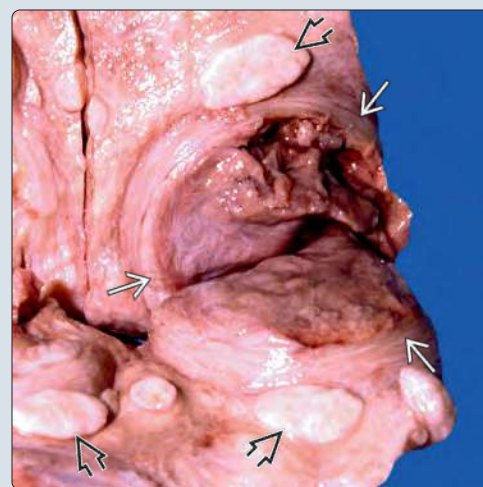
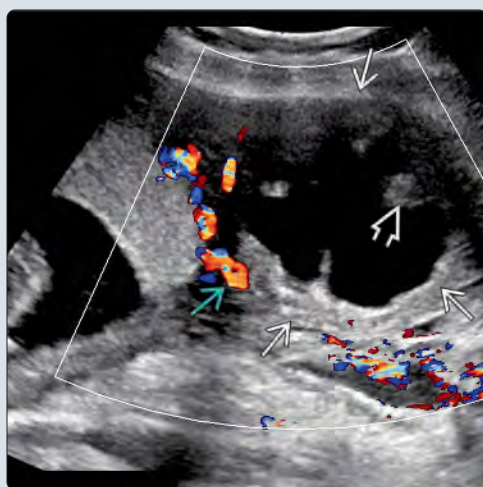
CLINICAL ISSUES

- Usually incidental finding on routine scan
- Acute pain, low-grade fever associated with hemorrhagic degeneration
- ↑ estrogen levels promotes growth in pregnancy
- Complications related to size and location
 - LUS myoma with ↑ rates of malpresentation, cesarean section, and postpartum hemorrhage
 - Retroplacental location with ↑ likelihood of placental insufficiency, spontaneous abortion, preterm labor, abruption, and postpartum hemorrhage
- Recommend follow-up for fetal growth when large or numerous myomas are seen

(Left) In this asymptomatic pregnant patient, the placenta implants upon a submucosal myoma. The fibroid is homogeneous and hypoechoic. Subplacental location of myomas are associated with pregnancy complications. This patient had a normal pregnancy. **(Right)** In this pregnancy complicated by early 2nd-trimester bleeding, the placental edge is implanted upon a vascular submucosal myoma. This is most likely why a marginal abruption occurred in this pregnancy.



(Left) In this pregnancy with cystic degeneration of a subserosal myoma, the avascular central cystic region and wall nodularities mimic an ovarian neoplasm. However, the myoma blood supply is shown coming from the uterus and a separate ovary was seen (not shown). **(Right)** Gross pathology in a different case shows a degenerated fibroid, which histologically had areas of both cystic and hemorrhagic degeneration. Smaller uncomplicated fibroids are also seen.



TERMINOLOGY

Synonyms

- Fibroid
- Leiomyoma/leiomyomata
- Fibroleiomyoma

Definitions

- Common benign smooth muscle tumor

IMAGING

General Features

- Best diagnostic clue
 - Well-defined, round or oval, hypoechoic myometrial mass
- Location
 - Classified by type
 - Intramural (35%): Within myometrium
 - Distorts neither internal or external uterine contour
 - Subserosal (42%): Distorts external contour of uterus
 - > 50% projects outside myometrium
 - Submucosal (18%): Distorts uterine cavity
 - > 50% projects into uterine cavity
 - Covered by endometrium
 - Pedunculated (5%): Attached to uterus with stalk
 - Location in uterus
 - Fundus, corpus, lower uterine segment (LUS)
 - Cervical
 - Multiple sites common
 - Position: Anterior, posterior, lateral
- Size
 - Variable size and growth in pregnancy common

Ultrasonographic Findings

- Typically well circumscribed
 - Homogeneous, hypoechoic mass
- Degenerated fibroids
 - More heterogeneous and variable in appearance
 - Cystic, often with thick, irregular septations
 - Borders often less well defined
 - Hyperechoic if acute hemorrhage
 - Calcified with dense shadowing if chronic
- Color Doppler
 - Peripheral flow: Variable amount of vascularity
 - May see uterine vessels splayed around mass
 - Vascular pedicle to pedunculated myoma

MR Findings

- Nondegenerated fibroid
 - T1WI: Intermediate signal (isointense to uterus)
 - T2WI: Homogeneous, ↓ signal intensity
- Degeneration causes variable signal
 - Cystic: ↓ T1 signal, ↑ T2 signal
 - Hemorrhagic
 - T1WI: Diffuse ↑ signal (early), ↑ signal rim (late)
 - T2WI: Variable, usually ↓ signal intensity, ↓ signal rim

Imaging Recommendations

- Protocol advice
 - Document fibroid number, location and type

- Measure in 3 orthogonal planes
- Document all fibroids when possible
 - Top 3 if innumerable fibroids present
- Note relationship of fibroid with placenta
 - ↑ complication if placenta implants on fibroid
- Note relationship with LUS
 - Cervical or LUS myoma may obstruct delivery
- Note relationship with adnexa
 - Subserosal lateral myoma may mimic ovarian mass
- Surveillance for fetal growth if multiple or large myomas
- Test for focal pain on myoma if suspect hemorrhagic degeneration
- MR helpful for complicated cases
 - Differentiating fibroid from adnexal mass
 - Look for signs of degeneration to explain pain

DIFFERENTIAL DIAGNOSIS

Focal Myometrial Contraction

- Transient myometrial thickening (resolves)
- Mass-like: Affects inner myometrium > outer

Placental Abruption

- Retroplacental abruption can mimic retroplacental myoma
- Appearance related to time of hemorrhage
 - Isoechoic to placenta → hypoechoic with time
- No blood flow by color Doppler in hematoma

Chorioangioma

- Vascular intraplacental mass
- More commonly on fetal side, near cord insertion

Complex Adnexal Mass

- Sex-cord stromal tumors are solid
 - Fibroma, fibrothecoma
- Ovarian neoplasms are cystic with wall nodularity
 - Mimic subserosal degenerated myomas

PATHOLOGY

General Features

- Etiology
 - ↑ estrogen of pregnancy → fibroid growth
- Genetics
 - No hereditary factor clearly defined
 - Does run in families

Gross Pathologic & Surgical Features

- Benign, smooth muscle tumor
 - Whirling fascicles of bland smooth muscle cells
 - Cut surface has whorled, trabeculated appearance
 - Complicated with 2° hemorrhage, necrosis and degeneration
- Types of degeneration (↑ risk with ↑ size of myoma)
 - Hyaline (most common)
 - Myxoid: Liquefied hyaline
 - Fatty: Advanced hyaline degeneration
 - Hemorrhagic (carneous, red)
 - Presents acutely with ↑ incidence in pregnancy
 - Cystic
 - Chronic changes from necrosis
 - May see cystic + hemorrhagic components

- Calcific: Usually older women
- Sarcomatous (rare)
 - More common in perimenopausal women

Microscopic Features

- Clonal proliferation of smooth muscle cells

CLINICAL ISSUES

Presentation

- Most common signs/symptoms
 - Incidental finding on routine scan (most common)
 - Subserosal myomas may be palpable
 - Acute pain if hemorrhagic degeneration

Demographics

- Age
 - ↑ incidence with age
 - Prevalence by age 35
 - 15% of Caucasian women have myoma
 - 40% of African-American women have myoma
- Epidemiology
 - 20-50% of women with fibroids suffer symptoms at some stage of life
 - Prevalence in pregnancy reported as 1-4%
 - 10.7% in 1st-trimester screening study
 - 10-40% have obstetric complications
 - 1:50 women with fibroids are admitted to hospital during pregnancy
 - ↑ incidence with obesity

Natural History & Prognosis

- Most fibroids remain asymptomatic in pregnancy and do not increase in size
- Fibroid growth during pregnancy is trimester dependent
 - 1st trimester
 - Stable or growth of fibroids of all sizes
 - From ↑ estrogen in 1st trimester
 - 2nd trimester
 - Small fibroids (2-6 cm) are stable or grow
 - > 6-cm fibroids are stable or become smaller
 - From estrogen receptor down regulation in 2nd trimester
 - 3rd trimester
 - Stable or decrease size of fibroids
 - After delivery
 - 36% of fibroids seen in pregnancy can not be identified
 - 79% of remaining fibroids decrease in size
- Morbidity related to number, size, location of myoma
 - Submucosal location associated with pregnancy loss
 - Secondary to defective implantation
 - Relative risk of 1.68 reported
 - Retroplacental location associations
 - Abruptio
 - Preterm labor
 - Postpartum hemorrhage
 - Reported rates: 8% with myoma vs. 3% without myoma
 - Pedunculated myoma
 - Torsion of vascular pedicle → infarcted myoma

- Large or multiple myomas
 - Abnormal fetal lie and presentation
 - Breech in 13% with myoma vs. 8% without myoma
 - Preterm labor
 - 19% rate with myoma vs. 13% without
 - Cesarean section
 - 49-61% vaginal delivery rates recently reported
 - Hospitalization for pain in 5-15%
 - Associated with myoma size > 5 cm
- Postpartum hemorrhage
 - 2.5% rate with myoma vs. 1.4% without
 - Associated with myomas > 3 cm
 - From uterine atony after vaginal delivery
- Red or carneous degeneration in 5%
 - 2 etiologies suggested
 - Myoma outgrows blood supply → ischemia → necrosis → prostaglandin release
 - Myoma changes orientation with advancing pregnancy → kinking or obstruction of vascular supply
 - Most often in 1st and early 2nd trimester
 - Nonspecific symptoms
 - Focal pain
 - Fever
 - Nausea and vomiting
- Rare complications
 - Fixed uterine retroversion (pelvic incarceration)
 - Large posterior myoma → uterus can not rise out of pelvis
 - Parasitic fibroid
 - Pedunculated myoma develops alternative blood supply from omentum
 - Pelvic venous thrombosis: From mass effect
 - Prolapse into vagina: Pedunculated submucosal

Treatment

- Red degeneration treatment
 - Hospitalization, rest, analgesia, hydration, assurance
- Cesarean myomectomy to be avoided
 - Bleeding may lead to emergent cesarean hysterectomy
- Surgery during pregnancy for torsed myoma

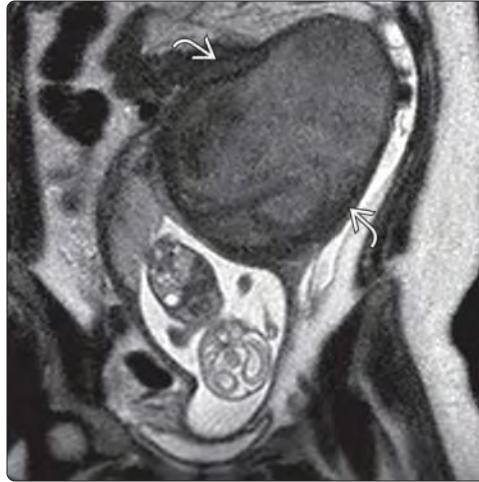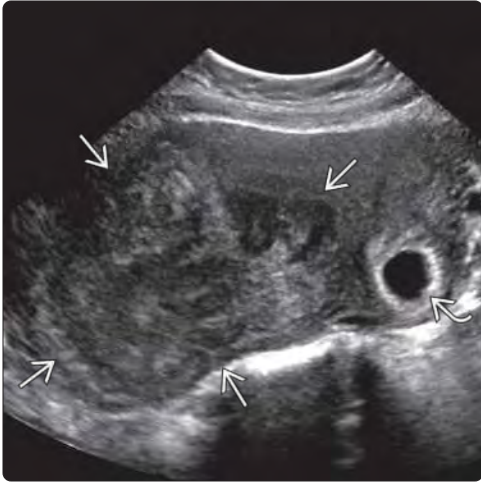
DIAGNOSTIC CHECKLIST

Image Interpretation Pearls

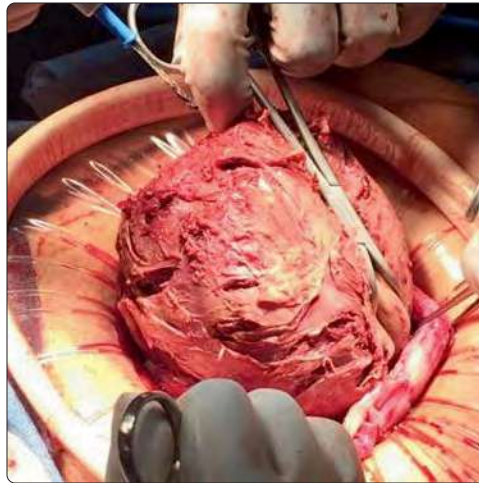
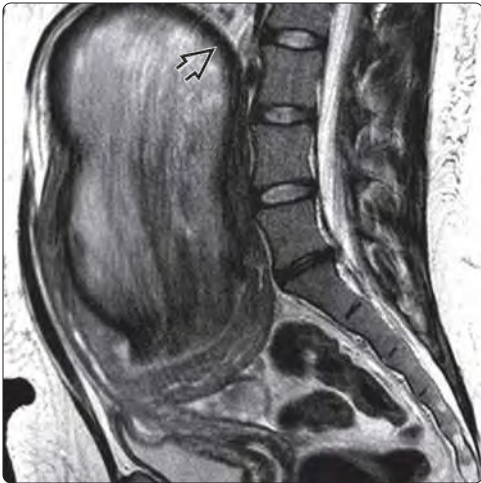- If adnexal mass is seen, look for separate ovary anyway
 - Degenerated myomas mimic ovarian neoplasm

SELECTED REFERENCES

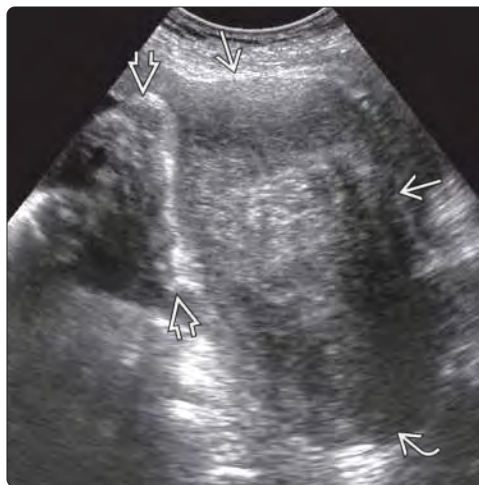
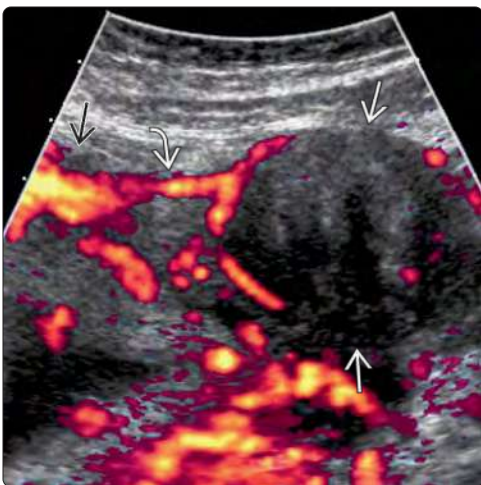1. Muezzinoglu B et al: Pathological characteristics and clinical outcome of uterine leiomyomas associated with pregnancy. *Pathol Res Pract.* 207(11):691-4, 2011
2. Munro MG: Uterine leiomyomas, current concepts: pathogenesis, impact on reproductive health, and medical, procedural, and surgical management. *Obstet Gynecol Clin North Am.* 38(4):703-31, 2011
3. Zaima A et al: Fibroid in pregnancy: characteristics, complications, and management. *Postgrad Med J.* 87(1034):819-28, 2011
4. Laughlin SK et al: Pregnancy-related fibroid reduction. *Fertil Steril.* 94(6):2421-3, 2010
5. Stout MJ et al: Leiomyomas at routine second-trimester ultrasound examination and adverse obstetric outcomes. *Obstet Gynecol.* 116(5):1056-63, 2010
6. Turan V et al: Assessment of pregnancy outcomes with uterine leiomyomas larger than 10 cm; antepartum and postpartum complications. *J Pediatr Adolesc Gynecol.* 23(1):57-8, 2010



(Left) During a 6-week viability scan, an intrauterine gestational sac and a large left fundal myoma were seen. The myoma is heterogeneous but the patient had no symptoms at this time. (Right) The same patient presented at 17 weeks with severe left lower quadrant pain. Ultrasound showed increased fibroid size and echogenicity. MR shows the myoma with mixed internal signal intensity, from red degeneration. The patient was admitted and had premature rupture of membranes and loss of the pregnancy.



(Left) Repeat MR after pregnancy loss shows further fibroid degeneration with increased heterogeneous signal centrally and low-signal hemosiderin within the wall. The myoma did not enhance with contrast. (Right) Clinical photograph of the myomectomy procedure in the same case shows the resection of the hemorrhagic fibroid. Pathology confirmed the diagnosis of carneous red degenerated myoma.



(Left) Axial power Doppler US shows a pedunculated fibroid connected by a vascular stalk to the lateral edge of the uterus. Pedunculated fibroids are at risk for torsion and can be confused with adnexal masses. (Right) Sagittal transabdominal ultrasound shows a very large anterior lower uterine segment myoma that involves the cervix. Myomas such as this one are associated with obstructed labor and breech presentation. Note that the fetal foot is the presenting part at the time of the scan.

Müllerian Duct Anomalies in Pregnancy

KEY FACTS

TERMINOLOGY

- Spectrum of congenital uterine malformations
 - Unicornuate uterus (20%)
 - Uterus didelphys (5%)
 - Bicornuate uterus (10%)
 - Septate uterus (55%)

IMAGING

- Most important image plane is parallel to long axis of uterus to show fundal contour
 - Septate uterus: Fundus mildly convex to mildly concave
 - Bicornuate: Concave or heart-shaped external fundal contour
- 3D ultrasound provides improved spatial delineation
 - Volume acquisition allows reconstruction of true coronal plane
- MR scan plane set off sagittal scout to ensure coronal view of uterus, not coronal view of pelvis

TOP DIFFERENTIAL DIAGNOSES

- Interstitial ectopic
- Leiomyoma

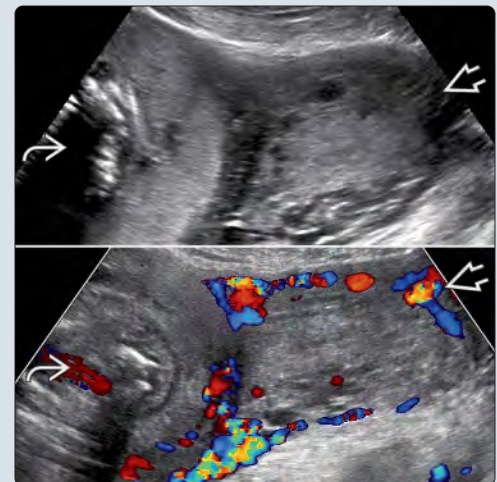
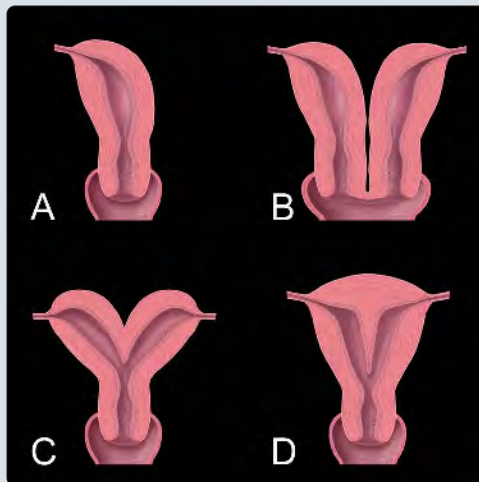
PATHOLOGY

- Renal anomalies occur in ~ 30%

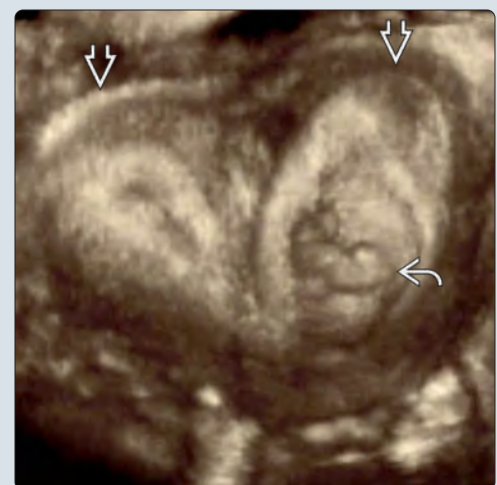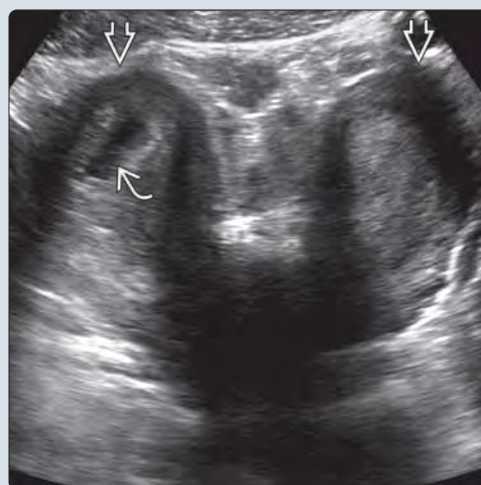
CLINICAL ISSUES

- Chances of live birth relative to type of müllerian duct anomaly (MDA)
 - Unicornuate, didelphys (~ 40%)
 - Bicornuate uterus (62.5%)
 - Septate uterus (62%)
- Uterine septum treated with hysteroscopic resection
- Ultrasound guidance important for dilatation and evacuation/curettage

(Left) Graphic shows müllerian duct anomalies, any of which may be seen in pregnancy. Unicornuate (A) has 1 horn; didelphys (B) has 2 nonfused horns; bicornuate (C) has a concave external contour; septate (D) has a normal external contour. A unicornuate uterus may have an accessory rudimentary uterine horn. (Right) Grayscale (top) and color Doppler (bottom) show a rudimentary horn adjacent to the pregnancy in a unicornuate uterus. There is a risk of implantation in a rudimentary horn with subsequent rupture.



(Left) Transverse transabdominal ultrasound shows the widely separated uterine horns of a uterus didelphys. They are similar in size excluding a unicornuate uterus with a rudimentary horn. The gestational sac is in the right horn. (Right) 3D ultrasound in the same patient's next pregnancy shows the separate horns of the didelphys uterus with the pregnancy in the left horn. The cervixes are not visible in either image as they are out of the scan plane.



TERMINOLOGY

Abbreviations

- Müllerian duct anomaly (MDA)

Definitions

- Spectrum of congenital uterine malformations
 - **Agenesis/hypoplasia** (10%)
 - Combined agenesis of uterus, cervix, and upper portion of vagina most common
 - **Unicornuate uterus** (20%)
 - Single uterine horn; may have rudimentary horn
 - **Uterus didelphys** (5%)
 - 2 separate, noncommunicating horns
 - 2 cervixes
 - **Bicornuate uterus** (10%)
 - Concave or heart-shaped external contour
 - 2 horns with variable fusion
 - May have 1 cervix (bicornis unicollis) or 2 cervixes (bicornis bicolis)
 - **Septate uterus** (55%)
 - Normal external contour
 - Septum may extend for variable lengths
 - Complete (to external os) or partial
- **Arcuate uterus**
 - Argued whether this should be classified as congenital anomaly or anatomic variant

IMAGING

Ultrasonographic Findings

- Ultrasound is primary modality for evaluation of uterine duplication in pregnancy
- 3D ultrasound allows volume acquisition with reconstruction of true coronal plane through uterus
- Key to diagnosis is visualization of external uterine contour
 - Didelphys
 - 2 separate uteri that never join together
 - Bicornuate
 - Concave or heart-shaped external fundal contour
 - Septate
 - Fundus mildly convex to mildly concave
 - Mildly concave defined as < 1 cm external indentation and at least 5 mm of myometrium above line connecting tubal ostia
 - Unicornuate uterus may not be distinguishable from normal uterus in pregnancy

MR Findings

- Image plane parallel to long axis of uterus
 - Optimal assessment of fundal contour
- T2WI
 - Zonal anatomy well depicted
 - High-signal endometrium
 - Low-signal junctional zone
 - Intermediate-signal myometrium

Imaging Recommendations

- Best imaging tool
 - 3D ultrasound in pregnant patient
 - 3D ultrasound or MR in nonpregnant patient

- Protocol advice
 - Check kidneys in every patient with MDA
 - 3D ultrasound provides improved spatial delineation
 - Very helpful in 1st trimester if anatomy confusing

DIFFERENTIAL DIAGNOSIS

Interstitial Ectopic Pregnancy

- May give false appearance of septate or bicornuate uterus
 - Interstitial line sign
 - Echogenic line can be followed from endometrium to ectopic sac
 - Myometrium thinned over gestational sac
 - Color Doppler shows trophoblastic flow around sac

Leiomyoma

- May distort endometrial cavity, giving appearance of duplication
- Hypoechoic, well-defined mass

PATHOLOGY

General Features

- Etiology
 - Primary congenital malformation
 - Exposure to diethylstilbestrol (DES), thalidomide, radiation, intrauterine infection also implicated
- Associated abnormalities
 - Renal anomalies in ~ 30%
 - Most common with didelphys and unicornuate
 - Renal agenesis in majority
 - Vaginal septum
 - Seen most commonly in didelphys (75%)
 - Obstruction of any component can occur
 - Present with pain ± pelvic mass at menarche
 - Hematometra: Blood-filled uterus
 - Hematometrocolpos: Blood-filled uterus and vagina
 - May involve only single horn of duplicated system
- Embryology
 - Uterus forms from paired, paramesonephric (müllerian) ducts
 - Failure of both to form → agenesis
 - Failure of 1 to form → unicornuate
 - Ducts grow in bidirectional manner and join
 - Failure to fuse → didelphys
 - Partial lower fusion → bicornuate
 - Septal resorption occurs between fused horns
 - Failure of resorption → septate uterus
 - Paramesonephric ducts also form majority of vagina
 - Distal vagina forms from urogenital sinus
 - Ovaries form from genital ridges and are not affected by abnormal uterine development

Staging, Grading, & Classification

- American Fertility Society classification
 - Class I: Segmental agenesis, hypoplasia
 - Class II: Unicornuate uterus
 - Class III: Uterus didelphys
 - Class IV: Bicornuate uterus
 - Class V: Septate uterus
 - Class VI: Arcuate uterus

- Class VII: DES exposure
- Does not fully explain some anomalies
 - Other classification schemes have been proposed
 - Important to emphasize these represent developmental spectrum, not discrete, unique anomalies

CLINICAL ISSUES

Presentation

- Incidental finding during 1st-trimester ultrasound
- Work-up for repeated pregnancy loss
- Abnormal fetal lie

Demographics

- Epidemiology
 - ~ 1% of general population
 - Septate most common in 1:100 fertile women
 - ~ 3% of women with repeated pregnancy loss
 - ~ 25% of women with uterine anomalies have reproductive problems

Natural History & Prognosis

- Infertile women have significantly higher incidence of MDA than fertile women
- Assisted reproduction patients with MDA have significantly lower ongoing pregnancy rate (8.3%) than controls (24.8%)
- ~ 15% of women evaluated for recurrent pregnancy loss have some uterine abnormality (e.g., MDA, fibroids, polyps)
- Chances of live birth relative to type of MDA
 - Unicornuate (40%)
 - Didelphys (40-55%)
 - Bicornuate uterus (62.5%)
 - Septate uterus (25-62%, depending on series)
- **Unicornuate**
 - Spontaneous abortion rate reported to be as high as 50%
 - Premature birth rate (15-20%)
 - Fetal survival (40-50%)
- **Didelphys**
 - Spontaneous abortion rate (45%)
 - Premature birth rate (38%)
 - Fetal survival (55%)
- **Bicornuate**
 - Spontaneous abortion rate (30%)
 - Premature birth rate (20%)
 - Fetal survival (60%)
- **Septate**
 - Spontaneous abortion rate (44-75%)
 - Premature birth rate (20%)
 - Fetal survival (25-62%, depending on series)
- **Arcuate** (considered anatomic variant rather than MDA by many authors)
 - Risk based on size of indentation
 - Draw line between top of horns and measure length
 - Height is measured from that line to bottom of myometrial indentation
 - Calculate ratio of height:length
 - If ratio is < 10%, no adverse effects

Treatment

- Management is controversial

- Septal resection recommended for recurrent pregnancy loss, malpresentation, preterm birth
- Prophylactic resection in infertile or asymptomatic women is controversial but may be recommended
 - To optimize pregnancy outcomes in women with prolonged infertility
 - In women older than 35 years
 - In women planning to pursue assisted reproductive technologies
- Hysteroscopic resection preferred
 - Decrease in spontaneous abortion rate
 - Increased live birth rate
 - Resection of cervical septum does not increase risk for cervical incompetence
- Metroplasty may be performed for recurrent pregnancy loss with bicornuate uterus
 - Wedge resection of medial portion of uterus, creating single cavity
 - Can be performed successfully with laparoscopic technique
- No specific treatment for unicornuate or didelphys
 - Some data suggest resection of rudimentary horn/prophylactic cervical cerclage may improve outcome in unicornuate
- Follow carefully for preterm labor
- Vaginal birth after cesarean section
 - Rate significantly lower among patients with MDA than in patients with normal uterus (37.6% vs. 50.7%)
 - Malpresentation is major indication for repeat cesarean delivery (58.3% vs. 14.4% in patients with normal uterus)
 - Not associated with ↑ rate of maternal morbidity or uterine rupture if fetus in cephalic presentation
- Ultrasound guidance important for dilatation and evacuation/curettage
 - Patients have increased risk of spontaneous abortion, intrauterine fetal demise
 - Ensure appropriate region of endometrial cavity is reached
 - Clarify surgical approach with difficult anatomy (e.g., atrophic uterine horn)

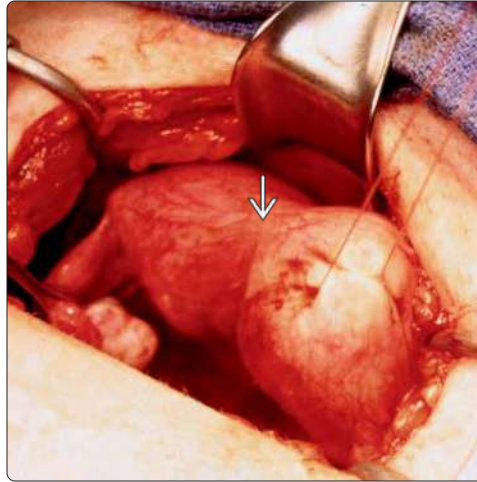
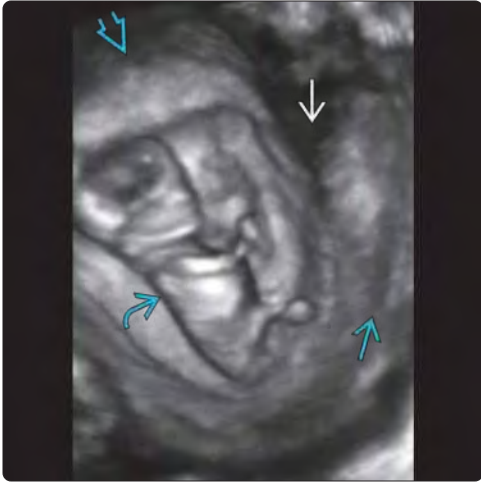DIAGNOSTIC CHECKLIST

Consider

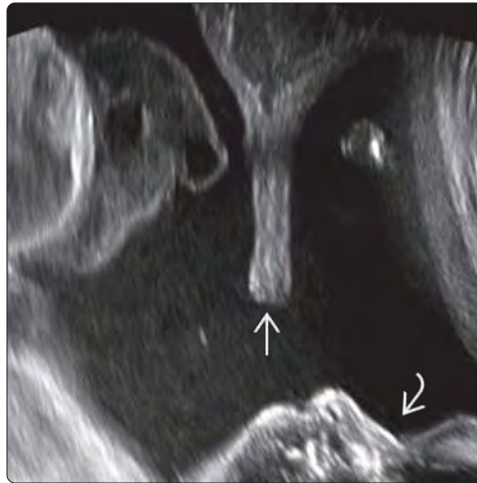
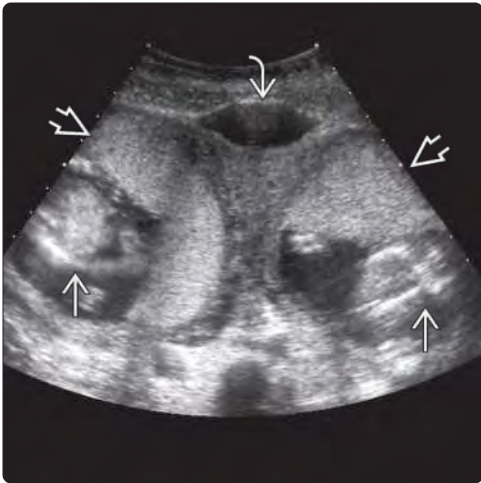- Septate uterus is most common congenital anomaly
- Resection of septum results in decreased spontaneous abortion rate

SELECTED REFERENCES

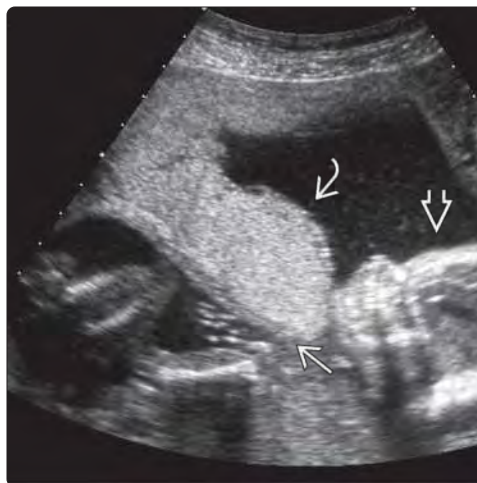
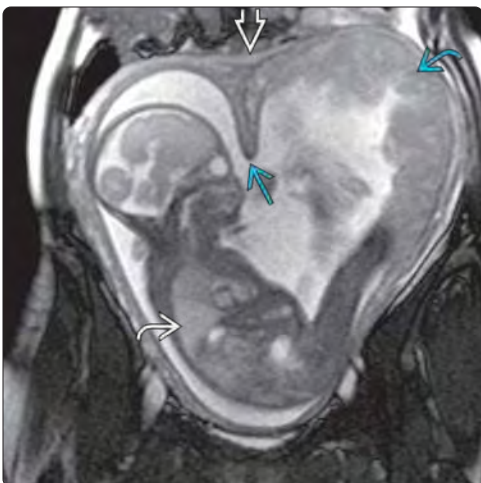1. Robbins JB et al: Müllerian duct anomalies: embryological development, classification, and MRI assessment. *J Magn Reson Imaging*. 41(1):1-12, 2015
2. Sadro CT: Pictorial review of complications of uterine anomalies. *Can Assoc Radiol J*. 66(4):368-76, 2015
3. Acien P et al: Reproductive outcome in uterine malformations with or without an associated unilateral renal agenesis. *J Reprod Med*. 59(1-2):69-75, 2014
4. Paradisi R et al: The techniques and outcomes of hysteroscopic metroplasty. *Curr Opin Obstet Gynecol*. 26(4):295-301, 2014
5. Lewis AD et al: Pregnancy complications in women with uterine duplication abnormalities. *Ultrasound Q*. 26(4):193-200, 2010



(Left) 3D ultrasound in the late 1st trimester shows the embryo in the right horn of a bicornuate uterus. The empty cavity of the left horn is visible at the edge of the picture. Note the cleft in the fundal contour, which proves that this is not a septate uterus. (Right) Intraoperative photograph shows the characteristic heart-shaped contour of a bicornuate uterus with the fundal cleft between the 2 horns. The fundal contour is either flat or convex outward in a septate uterus.



(Left) Transverse ultrasound of a bicornuate uterus shows a twin pregnancy with a fetus and placenta in each uterine horn (i.e., dizygotic twins in a bicornuate uterus). The anterior midline fluid collection is a urachal remnant that was removed at the time of cesarean section. (Right) Second trimester scan shows the fetus apparently "looking" at a uterine septum. Real-time evaluation showed the septum coming from the fundus, helping to differentiate it from other things that can cause linear echoes in the uterine cavity.



(Left) Coronal T2WI MR (for evaluation of a fetal lung mass) shows a uterine septum. The fundal contour of the uterus is normal. The placenta is implanted in the left portion of the cavity away from the septum. (Right) The placenta is largely implanted on the septum. The fetal head is to the left, and the torso and extremities are to the right of the septum. Despite the abnormal placentation, fetal growth was within normal.

KEY FACTS

TERMINOLOGY

- Uterine adhesions from scarring
 - Synechia covered by amnion and chorion
 - Form complete or incomplete amniotic sheets across uterine cavity

IMAGING

- Band-like structure crossing uterine cavity
 - Variable thickness, complete or incomplete
- Placenta commonly abuts or wraps around synechia
- Fetus moves freely around sheet

TOP DIFFERENTIAL DIAGNOSES






- Amniotic bands
 - Disruption of amnion with fetal entrapment
- Circumvallate placenta
 - Band attaches from placental margin to placental margin
- Uterine septum (duplication anomaly)
 - Midline, thick septum extends inferiorly from fundus

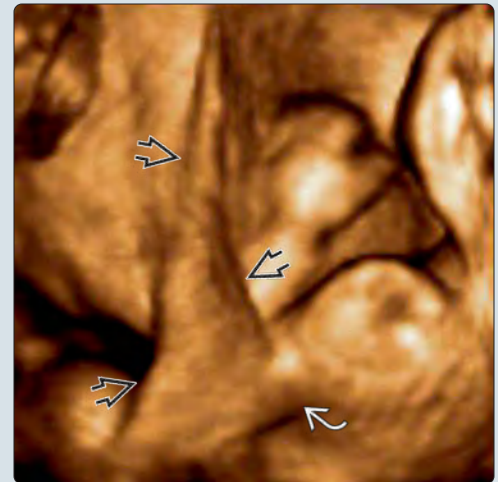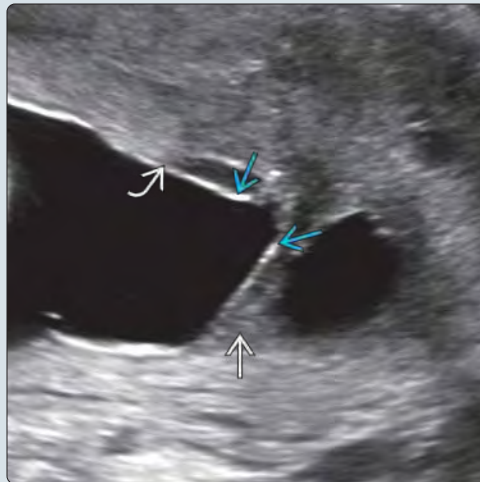
CLINICAL ISSUES



- 0.45-0.6% of pregnancies
- Associated with recurrent pregnancy loss
 - Hysteroscopic lysis is treatment of choice
- Often incidental finding in 2nd trimester but associated with increased risk of
 - Placental abruption
 - Premature rupture of membranes
 - Cesarean delivery for malpresentation
- No ↑ risk of placenta previa, fetal growth restriction, stillbirth, preterm birth
- Case reports of cord accident if cord prolapses through defect in sheet

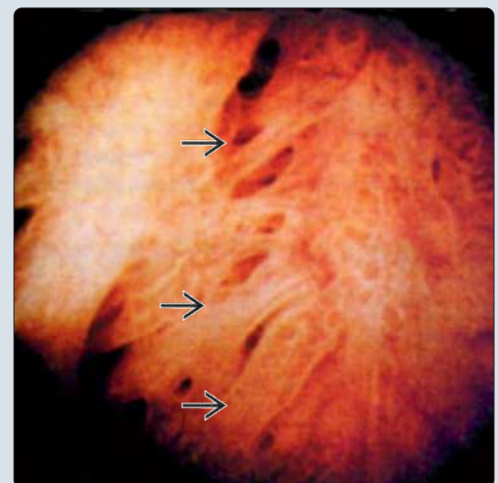
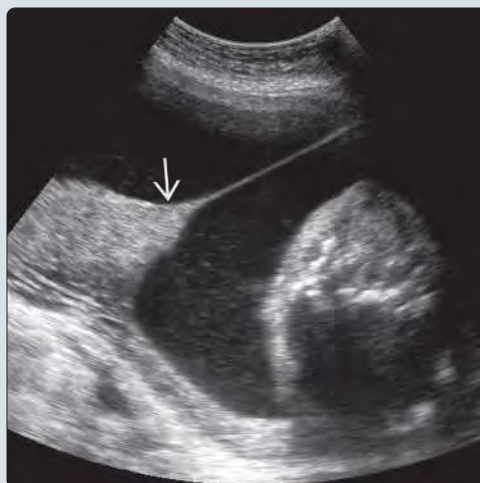DIAGNOSTIC CHECKLIST

- Synechia do not cause fetal structural defects
 - Document fetus moving freely around synechia
 - Document synechia attaches to uterus

(Left) TAUS shows a complete fibrous band crossing the uterine cavity. The amnion  drapes over the synechia  which is clearly separate from the placental margin . This should not be confused with a circumvallate placenta which is seen as a band from edge-to-edge of the placenta. **(Right)** This 3D US shows the sheet-like, triangular morphology  of the synechia. The upper extremity  was not fixed and moved freely on real-time evaluation.



(Left) US shows partial implantation of the placenta  on a synechia. This is frequently seen and does not negatively impact outcome. **(Right)** Hysteroscopic image shows fibrous bands  extending across the endometrial cavity. Synechia may cause infertility, and when extensive, they are lysed to improve chances for a successful pregnancy.



TERMINOLOGY

Synonyms

- Amniotic sheets

Definitions

- Uterine adhesions result from scarring
 - Synechia covered by amnion and chorion
 - Form complete or incomplete amniotic sheets across uterine cavity

IMAGING

General Features

- Best diagnostic clue
 - Shelf or band-like structure within uterine cavity
- Location
 - Extraamniotic: Membranes wrap over synechia

Ultrasonographic Findings

- Band-like structure crossing uterine cavity
 - Variable thickness
 - Bulbous free edge or extends completely across
 - Hypoechoic central area (scar) between more hyperechoic layers (membranes)
 - Y-shaped notch at attachment
- Placenta can abut or wrap around synechia (common)
- Fetus moves freely around sheet
- Color Doppler may demonstrate flow

Imaging Recommendations

- Protocol advice
 - Use 3D to better evaluate morphology
 - May have sheet-like triangular appearance

DIFFERENTIAL DIAGNOSIS

Amniotic Bands

- Disruption of amnion with fetal entrapment
 - Constrictions, amputations, slash defects
- Bands are thinner than synechiae
 - Difficult to see, no blood flow
 - Do not attach to both uterine walls

Circumvallate Placenta

- Band attaches from placental margin to placental margin
- Placental edge is elevated off uterine wall
 - Creates marginal shelf

Uterine Septum (Duplication Anomaly)

- Midline, thick septum extends inferiorly from fundus
- Fundal contour convex superiorly
- Composed of myometrium or fibrous tissue
- 2 distinct endometrial cavities

PATHOLOGY

General Features

- Etiology
 - Destruction of endometrial basal layer → adhesions
 - Curettage, trauma, infection
 - ↑ risk if curettage from 2-4 weeks postpartum
 - Retained placental/villous elements

- Fibroblastic proliferation before endometrial healing

CLINICAL ISSUES

Presentation

- Infertility and amenorrhea
- Recurrent pregnancy loss
 - Sonohysterogram or hysterosalpingogram finding during infertility work-up
- Abnormal fetal lie (↑ risk with lower uterine segment synechiae)
- Incidental finding in 2nd trimester
 - May rupture or be compressed by 3rd trimester

Demographics

- Epidemiology
 - 0.45-0.6% of pregnancies
 - 1.5% of women referred with infertility

Natural History & Prognosis

- Recent review shows increased risk of
 - Placental abruption: Adjusted odds ratio (OR) 3.25, 95% confidence interval (CI) 1.43-7.36
 - Premature rupture of membranes: Adjusted OR 2.51, 95% CI 1.51-4.18
 - Cesarean delivery for malpresentation: Adjusted OR 1.75, 95% CI 1.04-2.95
- No ↑ risk of placenta previa, fetal growth restriction, stillbirth, preterm birth
- Case reports of cord accident if cord prolapses through small defect in amniotic sheet
 - May see acute cord compression → acute fetal distress when membranes rupture

Treatment

- Synechiolysis: Hysteroscopic lysis of adhesions (for infertility)
 - Recurrence rate ~ 33% for mild to moderate and ~ 66% for severe
 - Hysteroscopy/hysterography recommended after 2-3 cycles following lysis to confirm restoration of cavity

DIAGNOSTIC CHECKLIST

Consider

- Synechiae do not cause fetal structural defects
 - Document fetus moving freely around synechia
 - Document synechia attaches to uterus

SELECTED REFERENCES

1. Ahmadi F et al: Role of 3D sonohysterography in the investigation of uterine synechiae/asherman's syndrome: pictorial assay. *J Med Imaging Radiat Oncol.* 58(2):199-202, 2014
2. Sato M et al: Antenatal 3-D sonographic features of uterine synechia. *J Obstet Gynaecol Res.* 39(1):395-8, 2013
3. Tuuli MG et al: Uterine synechiae and pregnancy complications. *Obstet Gynecol.* 119(4):810-4, 2012
4. AAGL Advancing Minimally Invasive Gynecology Worldwide: AAGL practice report: practice guidelines for management of intrauterine synechiae. *J Minim Invasive Gynecol.* 17(1):1-7, 2010
5. Deans R et al: Review of intrauterine adhesions. *J Minim Invasive Gynecol.* 17(5):555-69, 2010
6. Tan KB et al: The amniotic sheet: a truly benign condition? *Ultrasound Obstet Gynecol.* 26(6):639-43, 2005

KEY FACTS

TERMINOLOGY

- Uterine rupture: Full thickness tear of uterine wall
- Uterine dehiscence: Incomplete rupture, with disrupted myometrium but intact serosa

IMAGING

- Pregnant patient: Defect in myometrium ± fetal parts seen in peritoneal cavity
- Nonpregnant patient: Free intraperitoneal fluid after recent delivery or uterine instrumentation

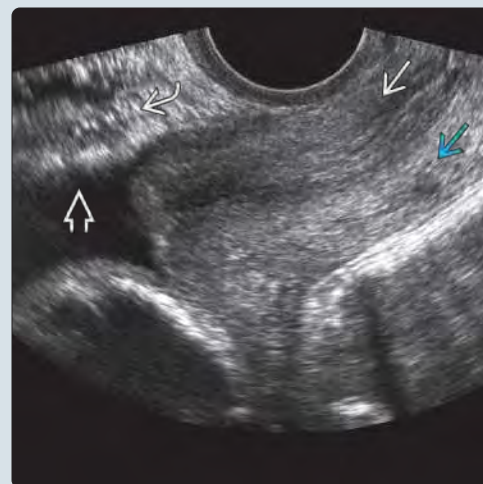
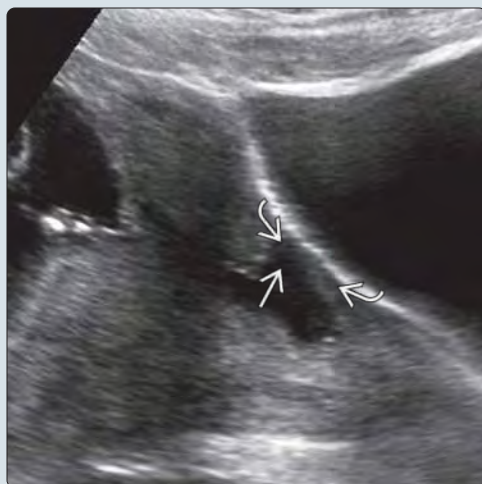
TOP DIFFERENTIAL DIAGNOSES

- Prenatal bleeding ± pain
 - Placental abruption
 - Placenta previa
 - Morbidly adherent placentation
- Postpartum bleeding ± pain
 - Retained products of conception
 - Endometritis

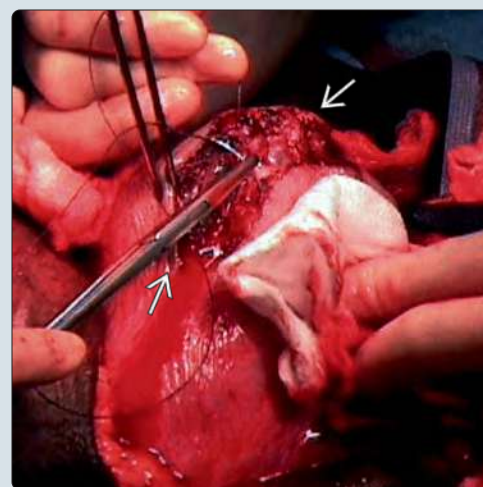
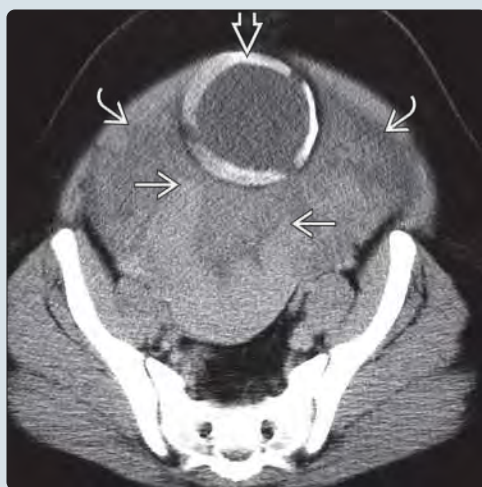
CLINICAL ISSUES

- Prior cesarean section in majority of cases (92%)
- Maternal Fetal Medicine Units Network quote 0.32% risk of rupture with prior low transverse cesarean section
 - 0.7% risk of rupture when attempting vaginal birth after prior cesarean section
 - 0.16% risk of rupture without labor in those planning repeat cesarean
- Primary uterine rupture (i.e., rupture of unscarred uterus) 0.005% risk in developed countries
- Rupture may occur during pregnancy, labor or postpartum
 - Rupture during labor has worst prognosis, especially if unscarred uterus as diagnosis may be delayed
 - Requires emergency laparotomy and possible hysterectomy to control bleeding
- Uterine dehiscence may be clinically silent or present with vague lower abdominal pain
 - Managed conservatively if patient stable

(Left) Sagittal TAUS shows a defect in the anterior myometrium at the level of the prior low transverse cesarean incision. This is not a focal myometrial contraction: The margins of contractions are rounded, not abrupt, and angular like the margins of this defect. The serosa is intact so this is a dehiscence. **(Right)** TVUS in another case shows the anterior and posterior lips of the cervix. Note the absence of myometrium posterior to the bladder at the site of dehiscence.



(Left) Axial CECT performed for abdominal trauma shows a defect in the uterine wall, with the fetal skull beyond the confines of the uterus, within the maternal peritoneal cavity. The large amount of mixed attenuation fluid is a mixture of blood, hematoma, and amniotic fluid. **(Right)** Intraoperative photo in the same case shows the large uterine defect being repaired. There were no other maternal injuries but the fetus was dead on arrival to the emergency room.



TERMINOLOGY

Definitions

- **Uterine rupture:** Full thickness tear of uterine wall
- **Uterine dehiscence:** Incomplete rupture, with disrupted myometrium but intact serosa

IMAGING

General Features

- Best diagnostic clue
 - Pregnant patient: Defect in myometrium ± fetal parts seen in peritoneal cavity
 - Nonpregnant patient: Free intraperitoneal fluid after recent delivery or uterine instrumentation
- Location
 - After low transverse cesarean section (LTCS) 92% rupture through lower uterus
 - Only ~ 4% involve parametrium
 - In primary rupture (i.e., no prior scar) ~ 50% involve broad ligament and uterine vessels

Ultrasonographic Findings

- Echogenic pelvic fluid may be most obvious finding in rupture
 - Anterior to cesarean section (CS) scar
 - Look for continuity of extrauterine fluid with endometrial cavity
- Beware bleeding into broad ligament
 - Patient rapidly unstable; usually intrapartum rupture
 - Lack of intraperitoneal fluid does not exclude rupture
- Disrupted myometrium
 - Usually in anterior lower uterine segment
 - If history of myomectomy or septoplasty, may be elsewhere

CT Findings

- Study of choice in setting of maternal trauma
 - Fetus in peritoneal cavity
 - Myometrial defect at site of tear
 - Free intraperitoneal fluid (amniotic fluid + blood)
 - Remember hemoperitoneum may be seen with other solid organ injury in setting of trauma

MR Findings

- Full thickness defect of myometrium in rupture
- Potential pitfalls with MR
 - Normal early postoperative appearance
 - Bladder flap hematoma
 - Degenerating fibroid
 - Abscess or hematoma

Imaging Recommendations

- During pregnancy or postpartum US is excellent; if any uncertainty, use MR as long as patient clinically stable
- Rupture in labor diagnosed clinically, imaging very rarely performed
 - Maternal abdominal pain, bleeding → hypotension → hypovolemic shock
 - Abnormal fetal heart rate → fetal distress → demise
 - Loss of fetal station
- **US**

- Transabdominal high-frequency, linear transducer much better than curved or vector
- Endovaginal very helpful with maternal bladder partly full
- Look for continuous myometrial band, measure thickness
- For sites other than LTCS (e.g., myomectomy bed) need high index of suspicion, use of a variety of transducers

MR

- Helpful with congenital uterine anomaly, fibroid, or any case when anatomy is not clearly delineated by US
- Rapid sequences prevent image degradation due to fetal motion
- Obtain axial and sagittal planes with both T1WI and T2WI
 - T1WI: Blood products are high signal
 - T2WI: Signal intensity of placenta > myometrium
- Detailed views of CS scar
 - Center pelvic coil over scar
 - Scan plane perpendicular to incision
- If other prior uterine surgery, try to set scan plane perpendicular to expected scar

CT

- May be used in setting of abdominal trauma or acute abdomen
- Always check myometrial integrity
- Normal pregnant uterus enhances symmetrically
 - Highly vascular, receiving 25% of cardiac output by term
 - Any defect should be regarded as highly suspicious
- Sagittal reconstructions recommended if using multidetector scanner

DIFFERENTIAL DIAGNOSIS

Prenatal Bleeding ± Pain

- Placental abruption
- Placenta previa
- Morbidly adherent placentation

Postpartum Bleeding ± Pain

- Retained products of conception
- Endometritis

Other Uterine Abnormality

- Morbidly adherent placentation
- Hemorrhagic/degenerated fibroid
 - Uncomplicated fibroid: Isointense to uterus on T1WI, low signal T2WI
 - Hemorrhagic fibroid: Usually mixed to high signal intensity on both sequences
 - May be difficult to differentiate from dehiscence with hematoma
- Bladder flap hematoma
- Scar endometriosis

PATHOLOGY

General Features

- Etiology
 - Prior CS in majority of cases (92%)
 - Classical incision > low transverse incision
 - Risk 8x that of unscarred uterus

- Vaginal birth after prior cesarean section (VBAC) candidates
 - Short interpregnancy interval → 2-3x increased risk for rupture
 - Indiscriminate use of oxytocin and malpresentation are major risk factors for rupture
- Other sources of uterine scar
 - Myomectomy, septoplasty, metroplasty, prior rupture or dehiscence
 - Risk after abdominal myomectomy < 1%, after laparoscopic myomectomy ~ 0.6%
 - Fetal surgery (e.g., repair of neural tube defect)
 - Reports of cases following high intensity focused US treatment (HIFU), endometrial ablation, cesarean scar pregnancy
- Congenital uterine anomaly (e.g., pregnancy in rudimentary horn)
 - Sporadic case reports of abdominal pregnancy attributed to undetected rupture of rudimentary horn pregnancy
- Abnormal placentation (abruption, placenta previa ± accreta)
- Uterine instrumentation
- Advanced maternal age
- Grand multiparity (≥ 4)
- Maternal trauma/obstructed labor may cause rupture of normal uterus
 - Obstructed labor major cause in low resource settings
- Inadequate treatment of endometritis may cause postpartum rupture

CLINICAL ISSUES

Presentation

- Most common signs/symptoms
 - Uterine dehiscence may be clinically silent or present with vague lower abdominal pain

Demographics

- Epidemiology
 - Maternal Fetal Medicine Units Network quote 0.32% risk of rupture with prior LTCS
 - 0.7% risk of rupture when attempting VBAC
 - 0.16% risk of rupture without labor in those planning repeat CS
 - Longitudinal or T-shaped incision
 - Up to 9% risk therefore VBAC contraindicated
 - 2015 NIH study compared trial of labor in women with 1 prior CS and found no increased risk of rupture comparing LTCS with unknown scar type
 - Primary uterine rupture 0.005% risk in developed countries
 - Risk factors include malpresentation, uterine anomaly, abnormal placentation, grand multiparity, macrosomia
 - Tends to occur in older, multiparous women in late labor (> 9 cm dilated) or immediately postpartum
 - Based on UK national data risk of rupture increased with number of CS, short interval since last CS, labor induction
 - USA series did not show increased risk with multiple prior CS

Natural History & Prognosis

- Uterine rupture during labor has worst prognosis especially if unscarred uterus as diagnosis may be delayed
 - High blood flow to uterus and placenta → catastrophic hemorrhage
 - Severe maternal morbidity and mortality
 - Significant risk of neonatal asphyxia with rare infant survival
- Population-based study in Netherlands documented no maternal mortality but 8.7% perinatal demise
- Complications of uterine repair include vesicouterine fistula

Treatment

- Rupture requires emergency exploratory laparotomy and delivery; often requires hysterectomy
 - Abdominal hysterectomy in 45% of 1 series
 - 55% had suture repair with more than 1/2 undergoing hypogastric artery ligation
 - Patients surviving rupture should avoid labor in future pregnancies
 - In this series, 91% of those who became pregnant again were delivered by planned cesarean section
 - 9% labored at home, ruptured, and died
- Dehiscence managed conservatively if patient stable
 - Deliver by elective CS before onset of labor
 - Reports of successful repair of uterine dehiscence with continuation of pregnancy

DIAGNOSTIC CHECKLIST

Consider

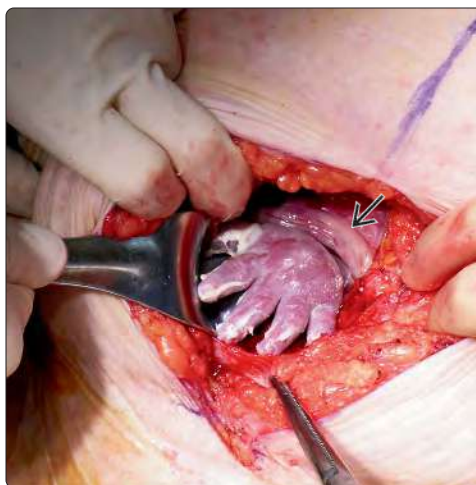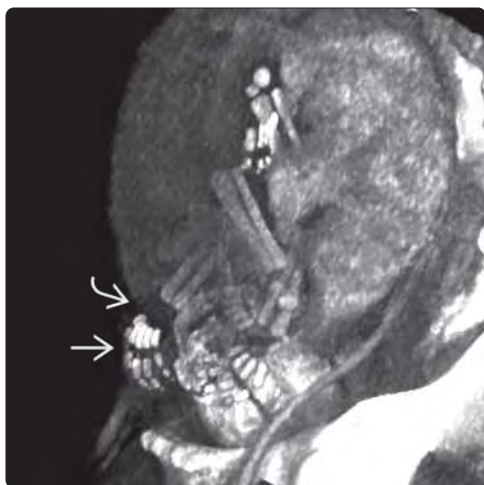- Always consider diagnosis if patient has history of prior CS or other uterine scarring

Image Interpretation Pearls

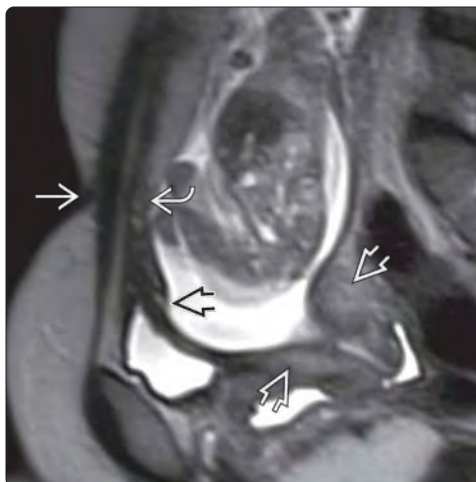
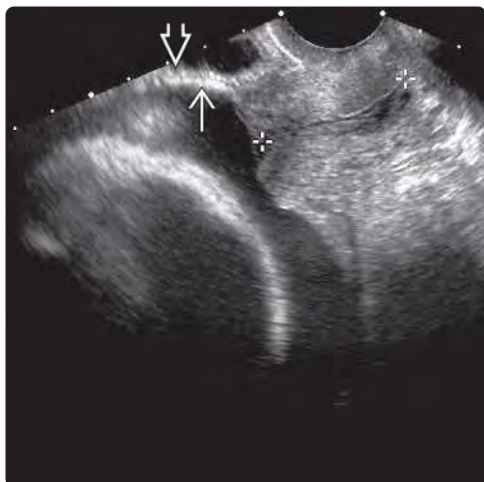
- Look at broad ligaments and pelvic sidewall as well; hemorrhage is not always intraperitoneal

SELECTED REFERENCES

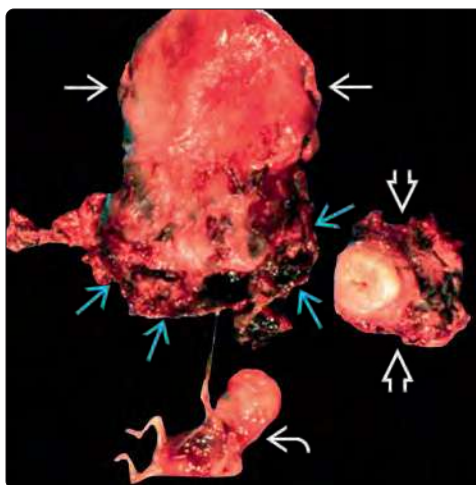
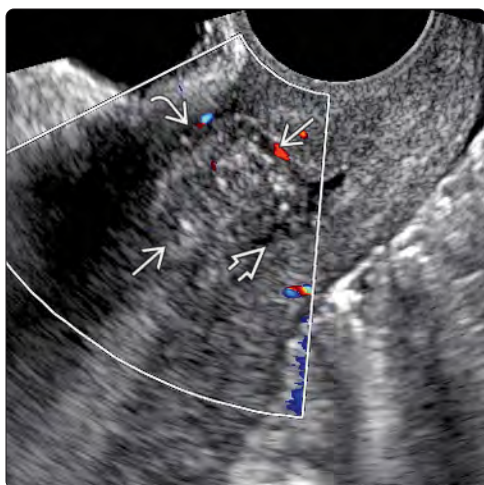
1. Eshkoli T et al: The significance of a uterine rupture in subsequent births. *Arch Gynecol Obstet.* 292(4):799-803, 2015
2. Flyckt RL et al: Editorial: Uterine rupture after laparoscopic myomectomy. *J Minim Invasive Gynecol.* 22(6):921-2, 2015
3. Gibbins KJ et al: Maternal and fetal morbidity associated with uterine rupture of the unscarred uterus. *Am J Obstet Gynecol.* 213(3):382, 2015
4. Koo YJ et al: Pregnancy outcomes and risk factors for uterine rupture after laparoscopic myomectomy: a single-center experience and literature review. *J Minim Invasive Gynecol.* 22(6):1022-8, 2015
5. Landon MB: Implications of the rising frequency of uterine rupture. *BJOG.* ePub, 2015
6. Singh A et al: Uterine Rupture: Still a Harsh Reality! *J Obstet Gynaecol India.* 65(3):158-61, 2015
7. Sentilhes L et al: Delivery for women with a previous cesarean: guidelines for clinical practice from the French College of Gynecologists and Obstetricians (CNGOF). *Eur J Obstet Gynecol Reprod Biol.* 170(1):25-32, 2013
8. American College of Obstetricians and Gynecologists: ACOG Practice bulletin no. 115: Vaginal birth after previous cesarean delivery. *Obstet Gynecol.* 116(2 Pt 1):450-63, 2010
9. Silver RM et al: Maternal morbidity associated with multiple repeat cesarean deliveries. *Obstet Gynecol.* 107(6):1226-32, 2006
10. Sambaziotis H et al: Second-trimester sonographic comparison of the lower uterine segment in pregnant women with and without a previous cesarean delivery. *J Ultrasound Med.* 23(7):907-11; quiz 913-4, 2004



(Left) Reconstructed view from a CT scan in a pregnant patient with clinical peritonitis who initially refused surgical exploration shows the fetal hand projecting out of a defect in the lower uterine segment. (Right) Intraoperative photograph in the same case shows the fetal hand free in the maternal peritoneal cavity (arrow denotes the edge of the myometrial defect). She had refused surgery until she was shown the CT images showing the uterine rupture.



(Left) TVUS of uterine dehiscence shows absence of the anterior myometrium with the uterine serosa and bladder mucosa forming 2 echogenic lines. The endocervical canal is marked by calipers. (Right) Sagittal T2WI MR at 22 weeks shows a uterine dehiscence. The edge of the placenta extends to the level of the prior cesarean section. The myometrium continues inferiorly where it tapers to a point at the bladder dome, well above the cervix.



(Left) TVUS for bleeding 6 weeks status post cesarean section shows an avascular hematoma extending from the endometrial canal to the uterine serosa. (Right) Gross pathology of uterine rupture from a cesarean scar pregnancy shows the cervix, uterine corpus, and 13-week fetus still attached to the placenta, which has invaded through the uterine wall. This case illustrates the importance of early diagnosis and treatment of cesarean scar pregnancy.

KEY FACTS

TERMINOLOGY

- Incomplete uterine evacuation with retention of placental/trophoblastic tissue within endometrial cavity

IMAGING

- Solid, heterogeneous, echogenic mass
 - Early loss often has small cystic areas
 - Postpartum appears more like placenta
- Persistent, thickened endometrium
 - > 10 mm usually considered abnormal, but no consensus exists
- Perform color Doppler to look for flow
 - High-velocity, low-resistance flow
- Lack of increased flow does not rule out RPOC
 - 40% of cases may have no or minimal flow

TOP DIFFERENTIAL DIAGNOSES

- Normal postpartum uterus
 - Small echogenic foci and fluid common



- Should decrease to < 8 mm with uterine involution
- Intrauterine blood/clot
 - Reported in up to 24% of postpartum patients
 - More hypoechoic than RPOC
 - No flow with Doppler

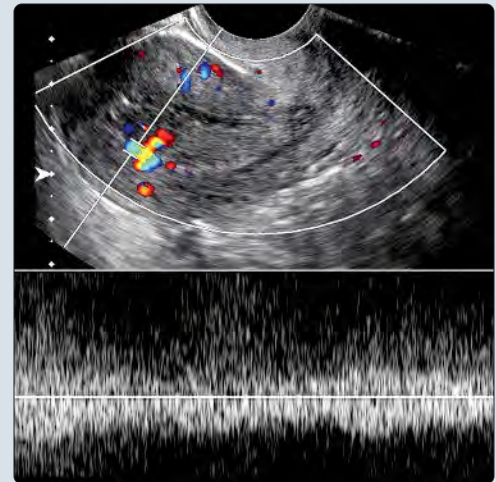
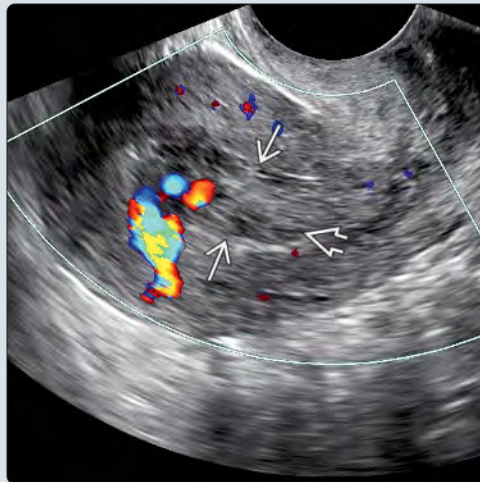
CLINICAL ISSUES



- Delayed postpartum bleeding
 - Most present within few days of delivery or abortion
- RPOC is risk factor for endometritis
 - Always consider RPOC in setting of postpartum fevers and pelvic pain
- Expectant management appropriate for those with little or no vascularity

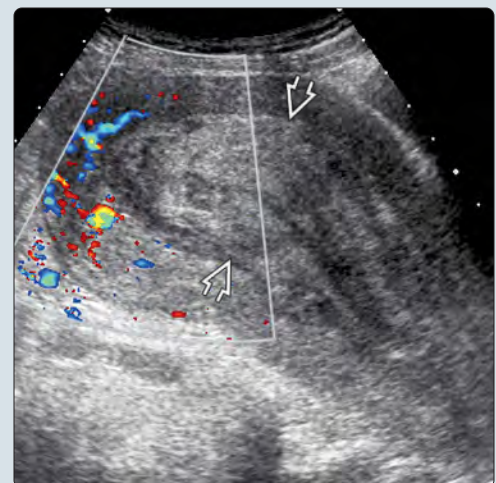
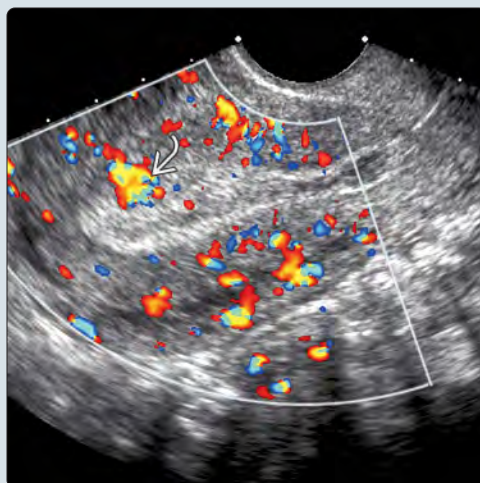
DIAGNOSTIC CHECKLIST

- If no mass or fluid and endometrial thickness < 10 mm without increased flow, RPOC extremely unlikely

(Left) Longitudinal transvaginal color Doppler ultrasound shows a complex, echogenic, vascular mass  in the endometrial cavity of a woman with a first-trimester pregnancy loss. Note the small cystic areas , which are common in RPOC after a spontaneous abortion. **(Right)** Pulsed wave Doppler ultrasound in the same case shows chaotic arterial and venous flow which can be confused with an arteriovenous malformation. This flow will resolve after evacuation of the retained products.



(Left) In this case of RPOC there is no endometrial mass, but there is diffuse endometrial thickening with an area of increased color flow . Increased vascularity within a thickened postpartum endometrium is highly suggestive of RPOC. **(Right)** In this case, there is marked thickening of the endometrium  but no flow on color Doppler. It is important to remember that in up to 40% of RPOC cases, there is little or no flow on Doppler imaging.



TERMINOLOGY

Abbreviations

- Retained products of conception (RPOC)

Definitions

- Incomplete uterine evacuation with retention of placental/trophoblastic tissue within endometrial cavity
 - May occur after abortion, vaginal delivery, or even cesarean section

IMAGING

General Features

- Best diagnostic clue
 - Echogenic endometrial mass with low-resistance, high-velocity flow
 - Early loss often has small cystic areas
 - Postpartum appears more like placenta

Ultrasonographic Findings

- Solid, heterogeneous, echogenic mass
 - Most sensitive (79%) and specific (89%) finding
- Persistent, thickened endometrium
 - > 10 mm usually considered abnormal, but no consensus exists
 - Cut-off of 8 mm has 34% positive rate
 - > 13 mm has 85% sensitivity, 64% specificity
- May have calcifications
- Intrauterine fluid common
- Color Doppler
 - High-velocity, low-resistance flow
 - Peak velocity highly variable: Reported from 10 cm/sec to > 100 cm/sec
 - Very high-velocity flow can be confused with arteriovenous malformation (AVM)
 - Lack of increased flow does not rule out RPOC
 - 40% of cases may have no or minimal flow

DIFFERENTIAL DIAGNOSIS

Uterine Atony

- Primary differential consideration for immediate postpartum hemorrhage
- Usually not imaged, but blood/clot may potentially be confusing

Normal Postpartum Uterus

- Significant overlap in ultrasound findings between normal postpartum uterus and RPOC
- Highly variable, from smooth to irregular endometrium
- Small echogenic foci and fluid common
- Foci of gas may be seen in up to 21%
- Should decrease to < 8 mm with uterine involution

Intrauterine Blood/Clot

- Reported in up to 24% of postpartum patients
- More hypoechoic than RPOC
- No flow with Doppler
- Changes/resolves on follow-up scans

Uterine Arteriovenous Malformation

- High flow within RPOC may simulate AVM

- Rare without history of prior instrumentation
- Within myometrium, not endometrium
- Persistent finding that remains after RPOC have been evacuated

CLINICAL ISSUES

Presentation

- Most common signs/symptoms
 - Delayed postpartum bleeding
 - Most present within few days of delivery or abortion
- Other signs/symptoms
 - Endometritis
 - Puerperal infection with postpartum fevers and pelvic pain
 - RPOC is risk factor for endometritis, so both may be present
 - May see gas in endometrium, nonspecific

Demographics

- Epidemiology
 - ~ 1% of all pregnancies
 - More frequent following termination
 - ↑ incidence with placenta accreta

Natural History & Prognosis

- Failure to evacuate → prolonged hemorrhage and infection

Treatment

- Expectant management appropriate for those with little or no vascularity
 - May repeat ultrasound to reevaluate
- Medical treatment (misoprostol) typically used for incomplete abortion
- Surgical treatment (dilation and curettage) for significant bleeding and associated endometritis

DIAGNOSTIC CHECKLIST

Consider

- Uterine atony vs. RPOC primary differential for postpartum hemorrhage
- RPOC in any patient presenting with endometritis

Image Interpretation Pearls

- If no mass or fluid and endometrial thickness < 10 mm without increased flow, RPOC extremely unlikely

SELECTED REFERENCES

1. Kamaya A et al: Variable color Doppler sonographic appearances of retained products of conception: radiologic-pathologic correlation. *Abdom Imaging*. 40(7):2683-9, 2015
2. Smorgick N et al: Hysteroscopic management of retained products of conception: meta-analysis and literature review. *Eur J Obstet Gynecol Reprod Biol*. 173:19-22, 2014
3. Atri M et al: Best predictors of grayscale ultrasound combined with color Doppler in the diagnosis of retained products of conception. *J Clin Ultrasound*. 39(3):122-7, 2011
4. Lee NK et al: Postpartum hemorrhage: Clinical and radiologic aspects. *Eur J Radiol*. 74(1):50-9, 2010
5. Kamaya A et al: Retained products of conception: spectrum of color Doppler findings. *J Ultrasound Med*. 28(8):1031-41, 2009

DIFFERENTIAL DIAGNOSIS

Common

- Placental Abruption
- Appendicitis
- Renal Stone Disease
- Pyelonephritis
- Cholecystitis

Less Common

- Ovarian Torsion
- Fibroid Degeneration
- Trauma

Rare but Important

- Uterine Rupture
- HELLP Syndrome

ESSENTIAL INFORMATION

Helpful Clues for Common Diagnoses

- **Placental Abruption**
 - Difficult diagnosis to make sonographically: Occult in up to 50% of cases
 - Acute clot is isoechoic to placenta, no flow on Doppler evaluation
 - Clot may be marginal, preplacental, retroplacental
- **Appendicitis**
 - Appendix often displaced out of pelvis by enlarging gravid uterus
 - US
 - Blind ending, noncompressible tube
 - Diameter > 6 mm
 - Look for appendicolith: Echogenic focus with distal acoustic shadowing
 - Inflamed periappendiceal fat is echogenic
 - May see focal fluid collection if ruptured
 - EV sonography very helpful if appendix remains in pelvis, behind pregnant uterus
 - Coronal images along psoas muscle may reveal retrocecal appendicitis or show appendix otherwise obscured by fetal parts
 - CT
 - Same anatomic features
 - More sensitive for focal perforation, presence of appendicolith, inflammation of fat
 - MR
 - No ionizing radiation
 - T1, T2, T2 FS sequences (Gadolinium contraindicated in pregnancy)
 - Same anatomic features as seen with US or CT
 - Make sure to scrutinize kidneys and gallbladder on scout views before focusing on appendix
 - American College of Radiology appropriateness criteria for imaging suspected appendicitis in pregnancy
 - Rating Scale: 1,2,3 usually not appropriate; 4,5,6 may be appropriate; 7,8,9 usually appropriate.
 - Abdominal US: 8
 - Pelvic US: 6 (appendix moves into abdomen with increasing size of uterus)
 - MR abdomen, pelvis without contrast: 7
- CT abdomen, pelvis with contrast: 6 (radiation exposure to fetus)
- CT abdomen, pelvis without contrast: 5 (same radiation exposure to fetus but decreased sensitivity for inflammation)
- **Renal Stone Disease**
 - Collecting system dilatation
 - Beware physiologic dilation of pregnancy
 - Ureteric dilatation, particularly suspicious for stone if dilatation stops abruptly
 - Physiologic dilatation tapers at pelvic brim
 - Use vaginal US to look at distal ureter for ureterovesical junction stones
 - Bladder partly full
 - Stones echogenic; most demonstrate acoustic shadowing, look for twinkle artifact with color Doppler
 - Look for ureteric jets with color Doppler
 - Have patient in decubitus position with side of concern elevated
 - Measure intrarenal resistive indices (RI)
 - Physiologic caliectasis does not cause elevated RI
 - Look for difference of > 0.1 side-to-side
 - Not specific for renal stone disease, as can also be seen with other acute renal conditions
 - MR urography
 - Coronal MR, with heavily T2-weighted sequences
 - Shows stone as low signal filling defects within column of high signal urine
- **Pyelonephritis**
 - US
 - Enlarged kidney ± parenchymal edema
 - Perinephric edema (well seen on coronal images along plane of psoas muscle)
 - Look for complicating conditions such as abscess or pyonephrosis (an obstructed, infected system), which require drainage
 - CT
 - Delayed ± striated nephrogram
 - Focal areas of diminished enhancement on delayed images
 - MR
 - Edematous kidney, focal areas of decreased signal
 - Diffusion-weighted imaging most sensitive to inflammation
- **Cholecystitis**
 - Gallstones
 - Gallbladder wall thickening
 - Pericholecystic fluid
 - Positive sonographic Murphy sign
 - Remember that right upper quadrant pain and abnormal liver function tests may indicate preeclampsia

Helpful Clues for Less Common Diagnoses

- **Ovarian Torsion**
 - Adnexal mass can undergo torsion in pregnancy
 - Maximum risk at 12-14 weeks and immediately postpartum
 - Adnexal structure most mobile when uterus pops out of pelvis at 12-14 weeks or when it returns to pelvis with postpartum involution

- Look for
 - Ovarian or paraovarian mass as lead point
 - Echogenic stroma, ovarian enlargement, peripheral follicles from edema
 - Hemorrhage/necrosis/infarction
- Use Doppler to assess flow
 - Lack of venous flow most suspicious finding
 - Documentation of flow does not exclude diagnosis in presence of strong clinical suspicion or other imaging findings of concern
- **Fibroid Degeneration**
 - Larger fibroids at greater risk for acute red (hemorrhagic) degeneration
 - Severe abdominal pain may mimic abruption
 - Often requires narcotic analgesia for control
 - Low-grade fever seen with hemorrhagic degeneration
 - Heterogenous, variable appearance
 - Cystic, often with thick irregular septations
 - Inhomogeneous echoes in center of fibroid
 - May be hyperechoic if acute hemorrhage
 - No flow in inhomogeneous area on Doppler interrogation
 - Placental implantation over large fibroid carries increased risk for abruption
 - Look for changes of abruption, as well as fibroid degeneration, in setting of acute pain
 - Pedunculated fibroids may undergo torsion
 - Look for bridging vessels
 - MR very helpful in confusing cases
- **Trauma**
 - Imaging evaluation should not be compromised because the patient is pregnant
 - When feasible, limit radiation exposure, or use US/MR if possible
 - Fetus at significant risk even if maternal injuries seem relatively minor
 - Placental shear injury → abruption, infarction
 - Maternal hypotension → decreased placental perfusion

- Most fetal ischemic injury takes time to be visible on imaging
- Wait 10-14 days post injury and consider performance of fetal MR to look for intracranial hemorrhage, ischemic encephalopathy

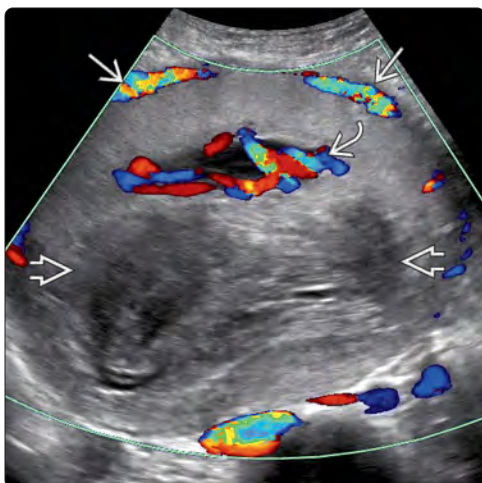
Helpful Clues for Rare Diagnoses

- **Uterine Rupture**
 - Most common in labor, uterus ruptures at site of old hysterotomy site
 - Emergency with acute maternal/fetal decompensation
 - Rarely imaged as patients go straight to surgery
 - May be complication of abdominal trauma
 - Look for disrupted myometrium, continuity of extrauterine fluid with endometrial cavity
 - **Uterine dehiscence**
 - Myometrium disrupted, but serosa is intact
 - Presents with grumbling lower abdominal pain rather than acute abdomen
 - Look for thinned, tapered myometrium at site of old scar
 - Peritoneal window may be apparent as focal bulge of uterine wall
 - Amniotic fluid contained by amnion/uterine serosa/peritoneum
 - Not clear if dehiscence progresses to rupture, but if seen, trial of labor generally avoided
- **HELLP Syndrome**
 - Patients present with preeclampsia and progress to more severe condition with following
 - Hemolysis
 - Elevated liver function tests
 - Low platelets
 - Low platelets → ↑ risk of spontaneous bleed → subcapsular liver hematoma

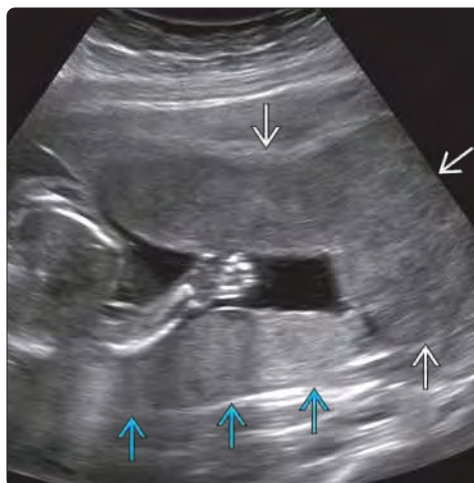
Other Essential Information

- Fetal well-being depends on maternal well-being
- Do not compromise evaluation because of pregnancy

Placental Abruption



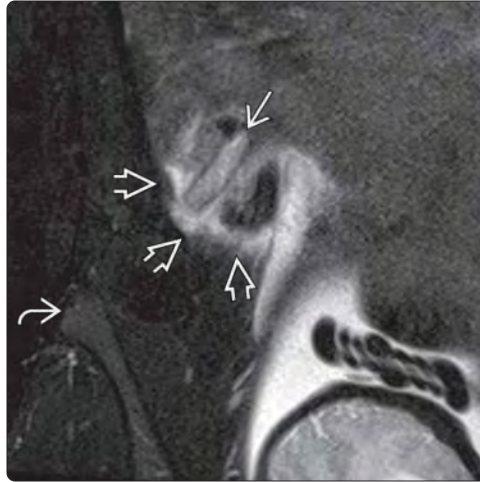
Placental Abruption



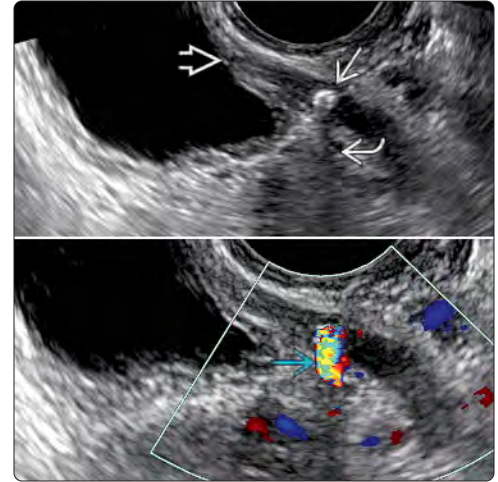
(Left) Transverse image through the uterine fundus shows a large, retroplacental abruption. There is normal subplacental blood flow anteriorly and in the cord insertion site. (Right) In another case there is a large marginal clot dissecting between the membranes as it extends from the placenta. Note how similar the echogenicity of the clot is to that of the placenta. As it ages, the clot will become more sonolucent. There is often echogenic debris in the amniotic fluid in cases with abruption.

Appendicitis

(Left) T2WI with fat suppression shows a 12-mm appendix with surrounding inflammation. Note that the appendix is well above the level of the iliac crest in this patient at 38-weeks gestation. (Right) Vaginal US is useful to look for distal ureteric stones as the ureters enter the bladder trigone. Acoustic shadowing can be quite subtle, but demonstration of twinkle artifact helps to confirm the presence of a stone.

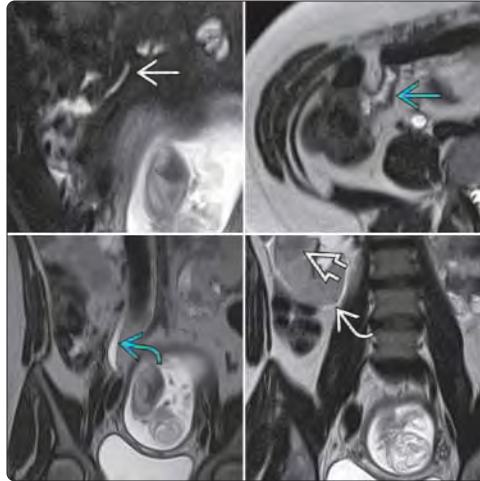


Renal Stone Disease

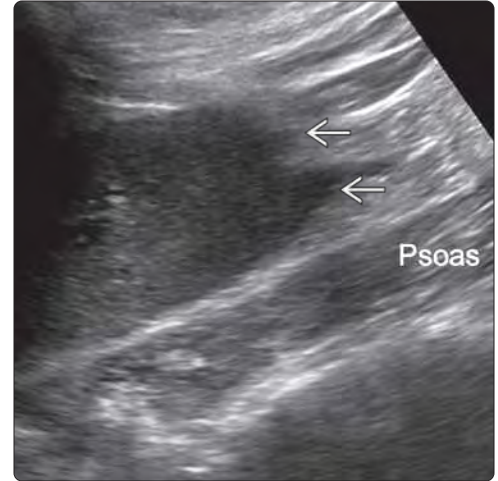


Pyelonephritis

(Left) T2WI performed in a patient with suspected appendicitis shows a normal appendix, terminal ileum, and distal right ureter. The scout view reveals an edematous right kidney and perinephric fluid. The actual diagnosis was pyelonephritis. It is important to look for all potential sources of pain. (Right) Coronal US images along the plane of the psoas muscle are best for showing perinephric edema in pyelonephritis. It is also helpful when looking for a retrocecal appendix.

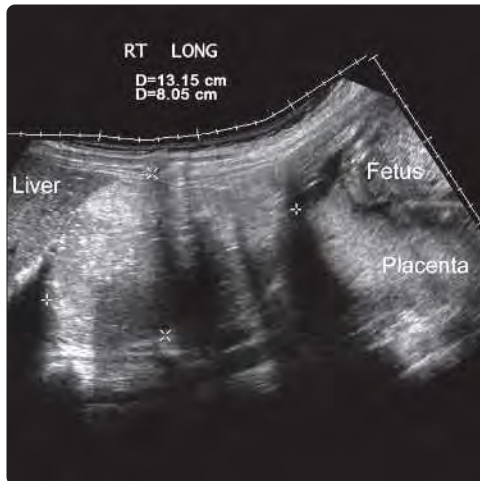


Pyelonephritis

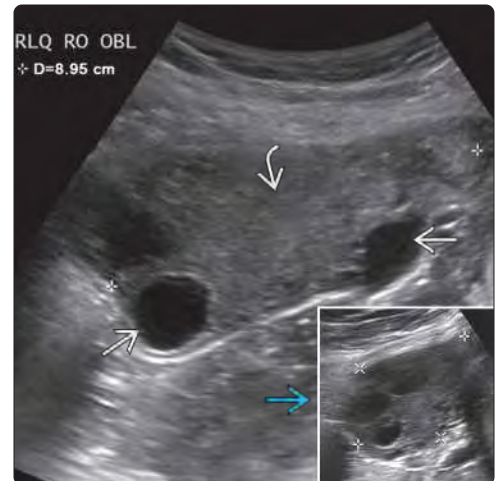


Ovarian Torsion

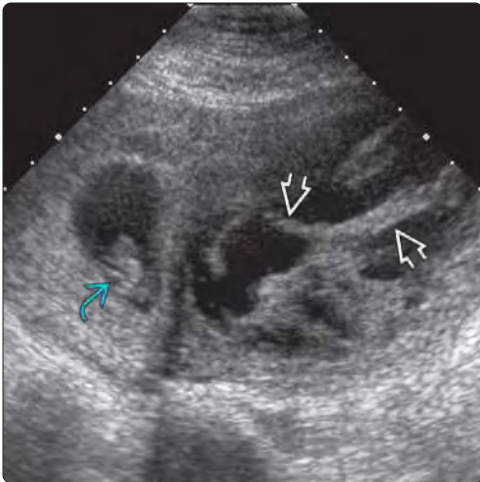
(Left) Extended FOV US shows a 13-cm dermoid between the liver and uterine fundus. The patient was warned she was at risk for torsion, but when this occurred in the puerperium, she did not tell the ER of the diagnosis! The mass was initially dismissed as gas-filled bowel. (Right) The right ovary measures ~ 9 cm in this IVF patient with severe acute pain. The follicles are pushed peripherally from central stromal edema. The inset shows a normal 5-cm ovary 1 week earlier. Torsion was surgically confirmed.



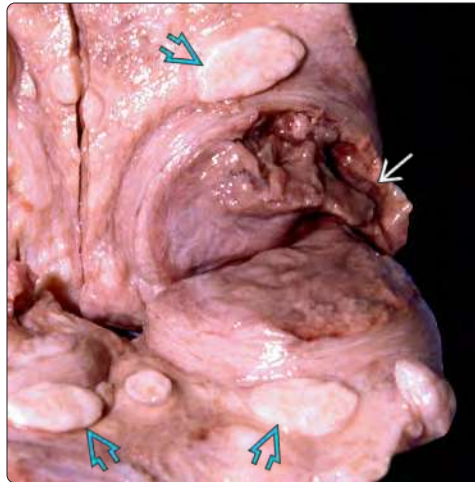
Ovarian Torsion







Fibroid Degeneration

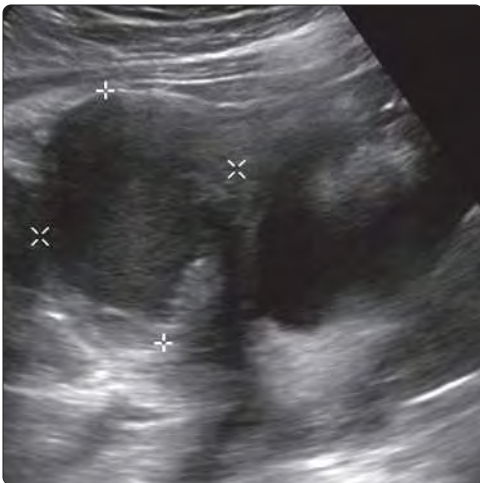


Fibroid Degeneration

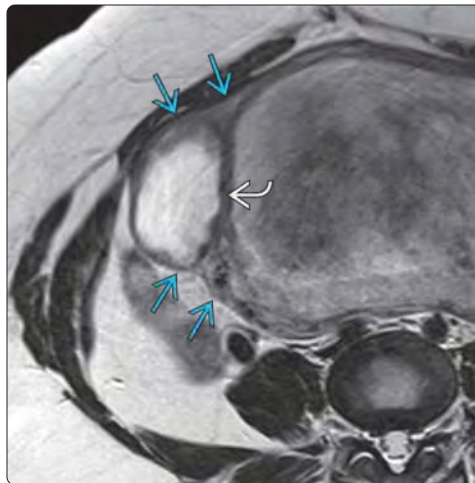




(Left) Transverse US through the uterus in the 1st trimester (embryo ) shows a large, degenerated fibroid with typical thick internal septations . She was asymptomatic but had acute pain in her last pregnancy when a solid fibroid was seen. (Right) This hysterectomy specimen shows a large degenerated fibroid  as well as multiple smaller, unremarkable ones .

Fibroid Degeneration

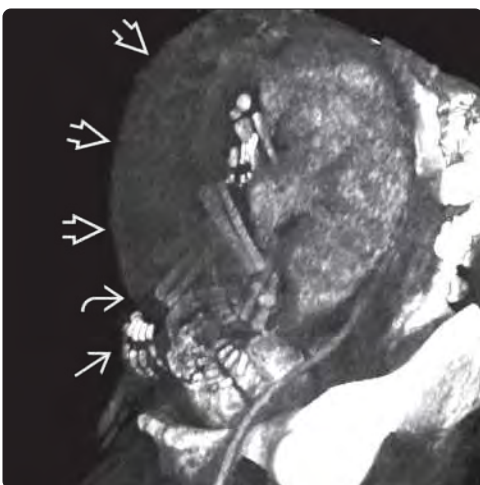


Fibroid Degeneration

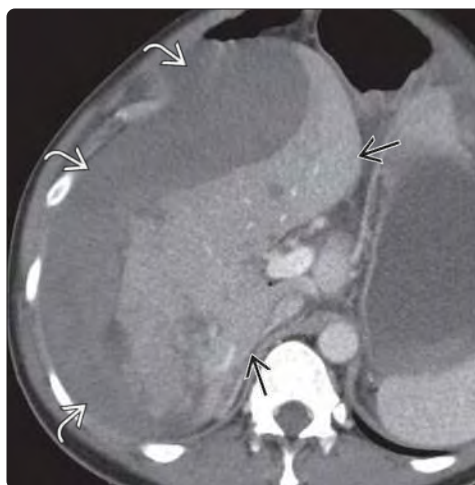







(Left) Transverse ultrasound shows a thick-walled, cystic mass in the right adnexa. The patient had pain and this mass had enlarged since the 1st-trimester scan where it had been called a corpus luteum. (Right) Axial T2WI confirms that the mass is a degenerated fibroid  within the right lateral myometrium  and not an enlarging ovarian mass or infarcted ovary due to torsion (the normal ovary was visible on other scan planes).

Uterine Rupture



HELLP Syndrome



(Left) Sagittal oblique CECT shows the fetal hand  extending through a defect  in the anterior myometrium  at the site of prior hysterotomies. The patient had had 8 prior C-sections. (Right) Axial CECT in a woman with HELLP syndrome shows a dramatic subcapsular hematoma  exerting mass effect on the liver . Spontaneous subcapsular bleeding is attributed to the low platelet count in this condition.

DIFFERENTIAL DIAGNOSIS

Common

- Membranes in Multiple Gestations
 - Dichorionic Diamniotic Twins
 - Monochorionic Diamniotic Twins
- Synechiae
- Uterine Duplication
 - Septate Uterus
 - Bicornuate Uterus

Less Common

- Circumvallate Placenta
- Chorioamniotic Separation (or Nonfusion)
- Amniotic Band Syndrome

Rare but Important

- Bleed Between Membranes
 - Multiple Gestations

ESSENTIAL INFORMATION

Key Differential Diagnosis Issues

- **Twin types**
 - 70% dizygotic
 - 2 separate fertilized ova
 - Always dichorionic
 - 30% monozygotic: Single zygote splits at various times
 - Zygote splits at < 3 days post conception (30%)
 - Dichorionic
 - Split occurs 4-8 days post conception
 - Monochorionic diamniotic (60-65%)
 - Split occurs 8-12 days post conception
 - Monochorionic monoamniotic (5-10%)
 - Split occurs > 13 days post conception
 - Conjoined twins (< 1%)
 - Dichorionic twins have best prognosis
 - Highest likelihood of 2 liveborn infants
 - Important to recognize monochorionic twins due to specific complications
 - Twin-twin transfusion syndrome (TTTS)
 - Twin reversed arterial perfusion (TRAP) sequence
 - Additional problems with monoamniotic
 - Cord entanglement
 - Best time to determine chorionicity is in 1st trimester
 - 2 separate gestational sacs (GS) in dichorionic
 - Yolk sacs reflect amnionicity in most cases
 - Triplets and above
 - Variable combinations of chorionicity and amnionicity
 - Variable appearance of membranes in uterus
- **Location of thick membrane in singletons** is important
 - Uterine duplication membrane fundal and central
 - Synechia membrane is uterine wall-to-wall and asymmetric
 - Circumvallate is from placenta to placenta
- **Location of thin membrane in singletons** is important
 - Amniotic bands entrap fetus
 - Chorioamniotic separation along uterine wall

Helpful Clues for Common Diagnoses

- **Dichorionic Diamniotic Twins**

- 1st-trimester appearance
 - 2 separate GS
 - Each with 1 yolk sac (YS), embryo and amnion
- Thick membrane in 2nd trimester
 - 2 layers chorion + 2 layers amnion = 4 layers
 - Consider high-frequency probe to count layers
- Twin peak or λ or δ sign
 - Echogenic chorionic tissue extends between amnion
 - Triangle shape with base on placental surface
 - Apex of triangle fades into intertwin membrane
- 2 placentas present in all cases
 - Can be difficult to see 2 separate placentas when they are side by side or fused
- Look at fetal genitalia
 - Twins of different sexes are always dizygotic and dichorionic
- **Monochorionic Diamniotic Twins**
 - 1st-trimester appearance
 - 1 GS, 2 YS, 2 amnion, 2 embryos
 - Count YS if amnion not yet visible
 - YS number usually but not always equals amnion number
 - Thin membrane
 - 2 layers of amnion + no chorion = 2 layers
 - T sign at junction with placenta
 - Thin membrane abuts placental surface at 90°
 - No triangle of chorionic tissue
 - Single placenta
 - Beware pitfall of fused placentas in dichorionic twins
 - Do not confuse succenturiate lobe with 2nd placenta
 - Look at fetal genitalia
 - Monochorionic twins must be same sex
- **Synechiae**
 - Most often seen in patient with history of prior surgeries
 - Synechiae crosses uterine cavity
 - Thick membrane from uterus wall to uterus wall
 - Anywhere in uterus
 - Fetus moves freely around synechia
 - Can straddle synechia
 - Placenta may implant upon synechia
 - Can "compartmentalize" uterus
 - 1st-trimester distorted GS shape if severe
 - Placenta on one side and fetus on other
 - No real association with untoward outcome
 - Some studies suggest increased incidence of fetal malpresentation and premature rupture of membranes
- **Uterine Duplication**
 - Septate uterus is more common than bicornuate
 - Look at fundal contour (3D may be helpful)
 - Normal contour with septate uterus
 - Septum is muscular or fibrous or both
 - Heart-shaped external contour with bicornuate
 - 2 complete uteri with didelphys
 - Note if placenta implants on septum
 - Can have duplicated cervix with any types

Helpful Clues for Less Common Diagnoses

- **Circumvallate Placenta**
 - Raised margin of placenta and membranes

- Appears as thick membrane from placenta edge to placenta edge when seen in cross section
- Placental cord insertion not affected
- Most often incidental finding
- Some association with placental dysfunction
 - Fetal growth restriction
 - Abruption
 - Preterm delivery
- **Chorioamniotic Separation (or Nonfusion)**
 - Amnion separated from chorion after 14-16 weeks
 - Chorion and amnion normally fuse by 15 weeks
 - Weak association with aneuploidy if delayed fusion
 - Thin membrane parallels margin of cavity
 - Does not divide cavity
 - Amnion can peel away from placenta surface
 - Does not lift placenta as subchorionic blood would
 - Often from complication of intervention
 - Amniocentesis
 - Amnioreduction
 - Hysteroscopic laser ablation for TTTS or TRAP
 - Thoracoamniotic or bladder shunt placement
- **Amniotic Band Syndrome**
 - Rupture of amnion entraps fetus
 - Variable presentation of defects
 - Extremity findings
 - Amputation, contracture, constriction with edema
 - Atypical body wall and facial defects
 - Doesn't follow embryology of classic defects
 - Short cord and tethered fetus common
 - Often fetus is tethered to placenta
 - Look for fine filaments in amniotic fluid
 - Often noncontiguous thin bands
 - Bands seen are often minimal compared to severity of fetal defects

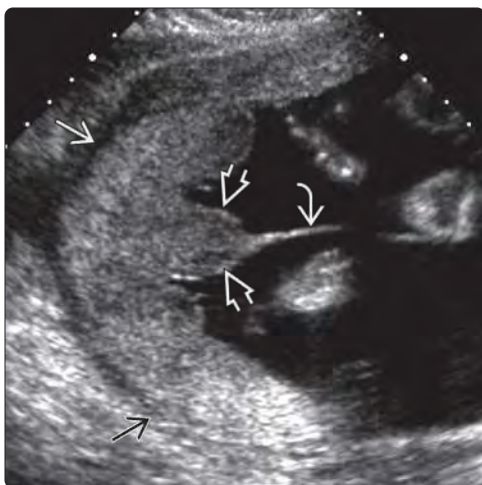
Other Essential Information

- Multiple gestations
 - Twins account for 1.1% of births in USA but 10% of perinatal morbidity and mortality
 - Prognosis relates to chorionicity
 - Best imaging tool for membrane assessment/determination of chorionicity is 1st-trimester transvaginal US
 - Twin peak sign is reliable indicator of dichorionicity but is not absolute
 - T sign most often seen in monochorionic twins but does not exclude dichorionicity
- Amniotic bands associated with ↑ fetal morbidity but other uterine linear echogenicities are not
 - Suggest amniotic band diagnosis carefully
 - Fetus moves freely around synechia, circumvallate placenta, chorioamniotic separation, and uterine septum
- Look at cervix and maternal kidneys if uterine duplication anomaly suspected
 - Look for 2 cervixes (nongravid cervix often compressed)
 - Determine gravid cervix appearance and length
 - Associated with preterm labor and short cervix
 - Uterine duplication anomalies associated with maternal renal anomalies, particularly agenesis
 - Document patient has 2 kidneys

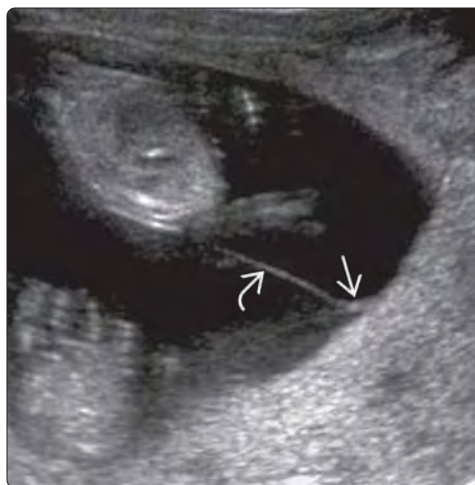
Helpful Clues for Rare Diagnoses

- **Bleed Between Membranes**
 - More common in dichorionic twins but can be seen in monochorionic; also in higher order multiples
 - Associated with placental abruption

Dichorionic Diamniotic Twins



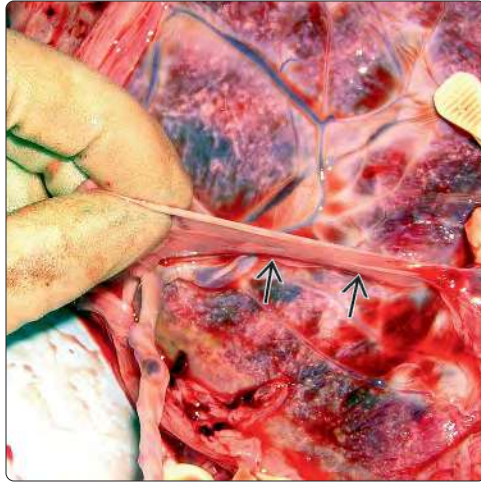
Monochorionic Diamniotic Twins



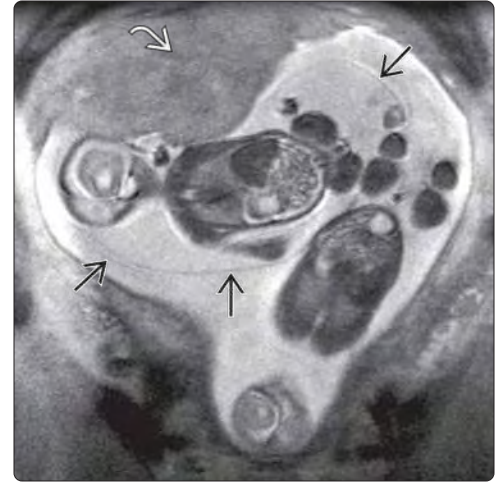
(Left) The anterior and posterior placentas in a dichorionic twin pregnancy meet centrally and form a chorionic build-up triangular "twin peak" . The resultant membrane is a 4-layer thick separating membrane. (Right) A thin separating membrane is seen between 2 fetuses and the insertion on the placenta is near 90°, forming a shape closer to a T than a λ or δ triangular shape.

Monochorionic Diamniotic Twins

(Left) Gross pathology of a thin monochorionic diamniotic membrane shows the direct 90° insertion on the placenta [red box], without any triangular chorionic build-up. (Right) T2WI MR of a thin membrane from monochorionic diamniotic twinning shows a single placental mass [red box] and a thin intertwin membrane [green box] without a twin peak sign.

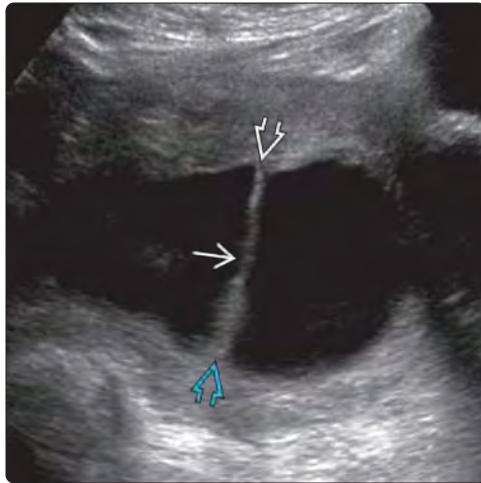


Monochorionic Diamniotic Twins

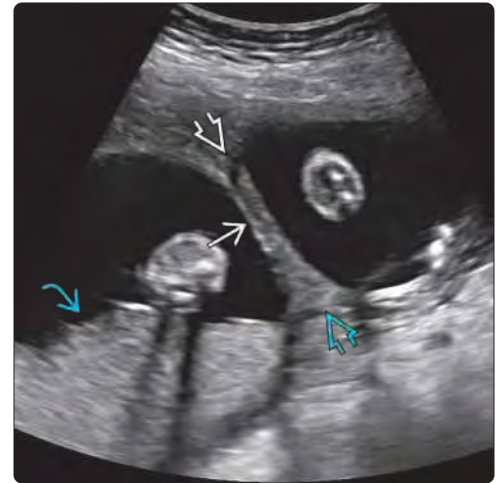


Synechia

(Left) A thick linear-echo synechia [red box] extends from the anterior [red box] to the posterior [green box] uterine wall. It was in the lower uterine segment (rules out septum) and the fetus moved freely around it (rules out amniotic bands). (Right) On this axial view at the fundus of the uterus, the uterine septum [red box] extends from the anterior [red box] to the posterior [green box] uterine wall. The placenta [blue box] does not implant upon the septum. The external contour of the uterus was smooth, diagnostic for septate uterus (bicornuate is heart-shaped).

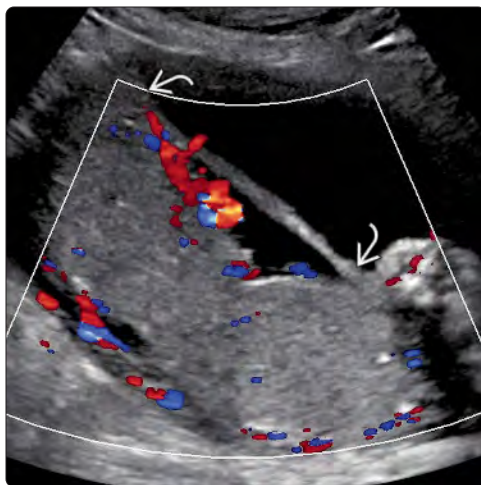


Uterine Duplication

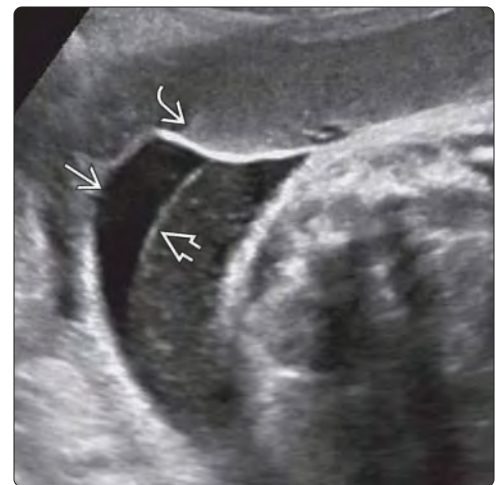


Circumvallate Placenta

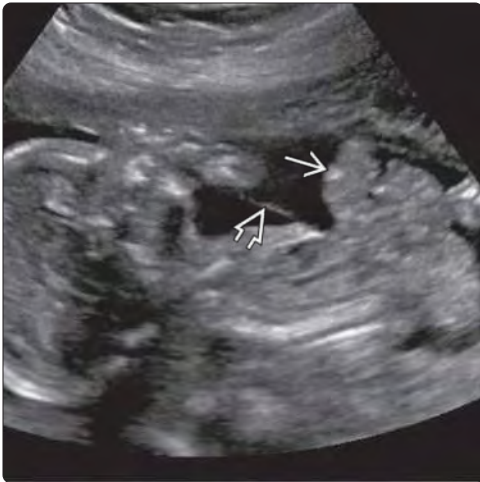(Left) A thick membrane extends from placental edge to placental edge [red box], representing the lifted membranes seen with circumvallate placenta. The lack of uterine attachment rules out synechia and its oblique positioning rules out a uterine septum (not at fundus). (Right) In this 3rd-trimester case, the amnion [red box] has detached from the uterine wall and chorion [green box]. The placenta remains well attached [blue box], and therefore the fluid collection is not subchorionic blood from abruption.



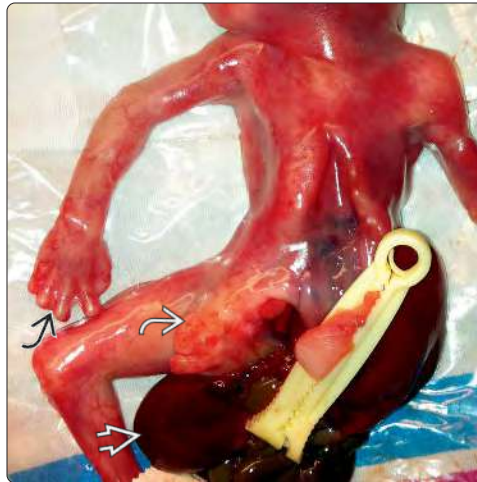
Chorioamniotic Separation (or Nonfusion)



Amniotic Band Syndrome

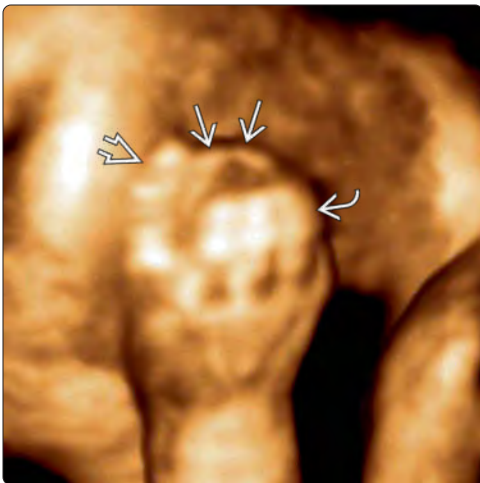

Amniotic Band Syndrome

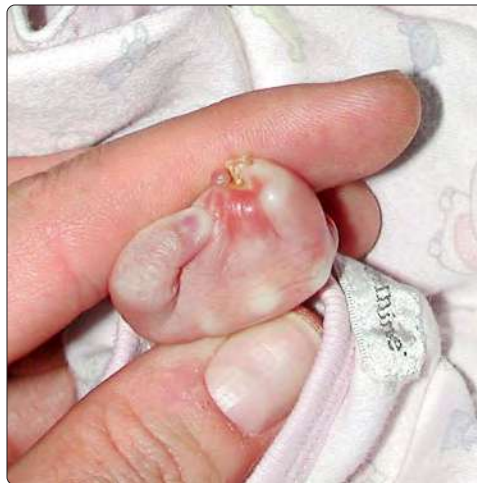

(Left) Sagittal view of a 20-week fetus with a large abdominal wall defect and extracorporeal bowel shows a subtle, thin intrauterine membrane attached to the fetus. Also, the abdominal wall defect did not look like a classic omphalocele or gastroschisis. (Right) Clinical photograph of the same fetus shows the large defect with extracorporeal liver and bowel. The hand also shows evidence for entrapment by bands.

Amniotic Band Syndrome

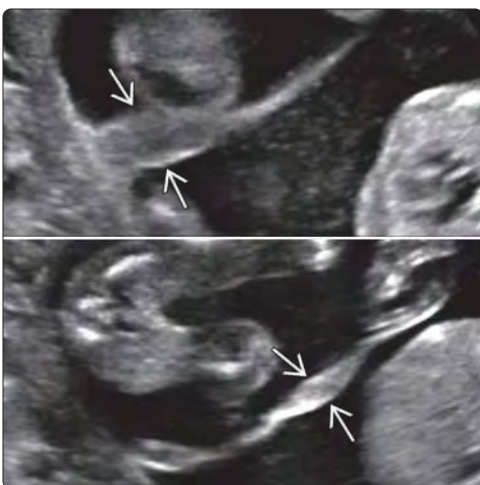


Amniotic Band Syndrome

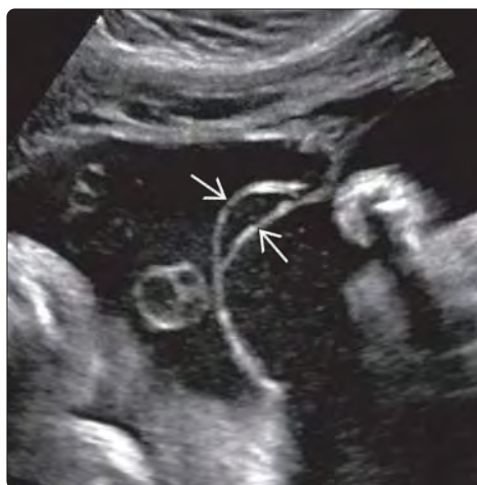

(Left) 3D surface-rendered view of a persistently contracted hand shows an amniotic band and 3 truncated contracted fingers with 1 normal finger. (Right) Clinical photograph of a left hand with amputations and contracture is typical for the damage that can occur when extremities are entrapped by amniotic bands. This newborn also had a facial slash defect. None of her anomalies were life threatening.

Bleed Between Membranes



Bleed Between Membranes



(Left) Focal areas of intertwin membrane thickening are seen in this dichorionic diamniotic pregnancy presenting with bleeding. Placental abruption was also seen from 1 of the 2 placentas and the fluid collection between the membranes is acute blood. (Right) An anechoic fluid collection between twin membranes could represent old blood from abruption, twin membrane separation, or primary membrane nonfusion. These intermembrane cysts are often idiopathic findings without clinical sequelae.

This page intentionally left blank

INDEX

A

- Aarskog-Scott syndrome, Noonan syndrome vs., **979**
 - Aase-Smith syndrome II, radial ray malformation vs., **742**
 - Abdomen
 - calcifications, **486**
 - normal size, **485**
 - Abdominal calcifications
 - causes of, meconium peritonitis/pseudocyst vs., **541**
 - toxoplasmosis vs., **1023**
 - Abdominal cavity, **476, 477**
 - Abdominal circumference (AC), **485**
 - Abdominal cord insertion site, **834**
 - Abdominal cysts
 - duodenal atresia vs., **521**
 - jejunal/ileal atresia vs., **526**
 - meconium peritonitis/pseudocyst vs., **541–542**
 - umbilical vein varix vs., **827**
 - urachal anomalies vs., **647**
 - Abdominal ectopic pregnancy, **50–51**
 - diagnostic checklist, **51**
 - differential diagnosis, **51**
 - prognosis, **51**
 - Abdominal mass, cystic, **562–567**
 - differential diagnosis, **562**
 - Abdominal situs, **485**
 - abnormality, **485**
 - Abdominal viscera, embryology and anatomy, **475**
 - Abdominal wall/gastrointestinal tract
 - anal atresia, **530–531**
 - approach to, **484–485**
 - clinical implications, **486**
 - imaging techniques and normal anatomy, **484**
 - ascites, **560–561**
 - bladder exstrophy, **508–511**
 - body stalk anomaly, **504–507**
 - choledochal cyst, **548–549**
 - cloacal exstrophy/OEIS syndrome, **512–515**
 - cloacal malformation/urogenital sinus, **532–535**
 - colonic atresia, **528–529**
 - congenital hepatic hemangioma, **550–551**
 - cystic abdominal mass, **562–567**
 - defects
 - algorithmic approach, **489**
 - colonic atresia and, **529**
 - differentiation of exstrophies from, **512–515**
 - duodenal atresia, **520–523**
 - echogenic bowel, **558–559**
 - embryology and anatomy, **474–483**
 - 2nd week, **474**
 - 3rd week, **474**
 - 4-week embryo, **477**
 - 4th week, **474**
 - 5th week, **474**
 - 6th to 7th week, **474**
 - 8th week, **474**
 - 9th week, **474**
 - 10th week, **474**
 - 18-day embryo, **476**
 - abdominal vessels, **474–475**
 - bowel rotation, **478, 479**
 - early embryologic events, **474**
 - fetal abdomen MR imaging, **482, 483**
 - fetal abdomen ultrasound, **483**
 - liver, portal and hepatic veins, **481**
 - mouth and anus formation, **480**
 - organs, **475**
 - selected defects in development, **475**
 - embryology and anatomy, organogenesis, **14**
 - enteric duplication cyst, **538–539**
 - esophageal atresia, **516–519**
 - gallstones, **546–547**
 - gastroschisis, **490–495**
 - jejunal, ileal atresia, **524–527**
 - malignant liver tumors, **554–557**
 - meconium peritonitis/pseudocyst, **540–543**
 - mesenchymal hamartoma, **552–553**
 - mesenteric lymphangioma, **544–545**
 - omphalocele, **496–501**
 - pentalogy of Cantrell, **502–503**
 - volvulus, **536–537**
- Abnormal biometry, fetal growth restriction, **1035**
- Abnormal cardiac axis, **462–467**
 - differential diagnosis, **462**
- Abnormal gait, hypophosphatasia and, **715**
- Abnormal joint angulation, angulated bones and, **774, 778**
- Abnormal ossification, **780–781**
 - differential diagnosis, **780**
- Abruption, placental, **790–793**
 - acute abdomen in pregnancy vs., **1082, 1083**
 - diagnostic checklist, **792**
 - differential diagnosis, **791**
 - encephalomalacia/porencephaly and, **159**
 - marginal, **791**
 - vasa previa vs., **799**
 - myoma in pregnancy vs., **1067**
 - placenta previa vs., **795**
 - placental cysts and masses vs., **830, 832**
 - retroplacental, **830, 831**
 - placental lake vs., **807**
 - placental lakes associated, **808**
 - preplacental, **791**
 - prognosis, **792**
 - retroplacental, **791**

INDEX

- risk factors, **791**
- signs and symptoms, **792**
- staging, grading, & classification, **792**
- succenturiate lobe vs., **811**
- twins, **791**
- uterine rupture vs., **1077**
- Absent cavum septi pellucidi, Chiari 3 malformation and, **173**
- Acampomelic campomelic dysplasia, campomelic dysplasia vs., **707**
- Acardiac Twin-in-Twin Reversed Arterial Perfusion (TRAP), placental teratoma vs., **821**
- Accessory placenta. *See* Succenturiate lobe.
- Accessory renal arteries, renal ascent and, **570**
- Acetylcholine receptor antibodies, arthrogryposis/akinesia sequence and, **760**
- Achondrogenesis/hypochondrogenesis, **688–693**
 - 1B, atelosteogenesis vs., **703**
 - abnormal ossification vs., **780, 781**
 - associated abnormalities, **690**
 - calvarium, abnormal vs., **217**
 - diagnostic checklist, **690**
 - differential diagnosis, **689**
 - genetics, **689–690**
 - micromelia vs., **699–700**
 - osteogenesis imperfecta vs., **719**
 - prognosis, **690**
 - staging, grading, & classification, **690**
 - thanatophoric dysplasia vs., **727**
 - type 1A, hypophosphatasia vs., **715**
 - type IA, **689**
 - type IB, **689**
 - type II, **689**
- Achondroplasia, **694–697**
 - calvarium, abnormal vs., **217, 221**
 - diagnostic checklist, **696**
 - differential diagnosis, **695–696**
 - genetics, **696**
 - heterozygous, mildly short femur/humerus and, **771, 773**
 - homozygous
 - achondrogenesis/hypochondrogenesis vs., **689**
 - achondroplasia vs., **695**
 - thanatophoric dysplasia vs., **727**
 - prognosis, **696**
 - warfarin embryopathy vs., **1011**
- Achondroplasia with developmental delay and acanthosis nigricans syndrome, severe, achondroplasia vs., **695**
- AChR clustering protein rapsyn, arthrogryposis/akinesia sequence and, **760**
- Acrania, occipital/parietal cephalocele vs., **101**
- Acrocephalopolysyndactyly type II. *See* Carpenter syndrome.
- Acrocephalosyndactyly
 - type I. *See* Apert syndrome.
 - type III, syndactyly vs., **751**
 - type V. *See* Pfeiffer syndrome.
- Acro-dermato-ungual-lacrima-tooth syndrome (ADULT), split hand/foot malformation and, **755**
- Acrofacial dysostosis, Nager, radial ray malformation vs., **742**
- Acromelia, **680**
- ACSS. *See* Pfeiffer syndrome.
- Acute abdomen in pregnancy, **1082–1085**
 - differential diagnosis, **1082**
- Acute placental abruption, succenturiate lobe vs., **811**
- ADAM (amniotic deformity, adhesion, mutilation). *See* Amniotic band syndrome.
- Adenomyosis, cesarean scar ectopic pregnancy vs., **49**
- Adenomyotic cyst, abnormal gestational sac and contents vs., **57**
- Adherent placentation, morbidly, uterine rupture vs., **1077**
- Adnexal mass
 - incidental, tubal ectopic pregnancy vs., **35**
 - in pregnancy, **62–65**
 - differential diagnosis, **62**
- Adrenal glands, **578, 579**
 - abnormal urinary tract, **581**
 - development of, **570**
 - normal, **575**
 - renal fossa, **575**
 - unilateral renal agenesis, **589**
 - ultrasound, **580**
- Adrenal hematoma, fetus-in-fetu vs., **879**
- Adrenal hemorrhage, **626–627**
 - associated abnormalities, **627**
 - bronchopulmonary sequestration vs., **342**
 - diagnostic checklist, **627**
 - differential diagnosis, **627**
 - neuroblastoma vs., **629**
 - prognosis, **627**
 - suprarenal mass vs., **674**
- Adrenal hyperplasia, **675**
 - congenital, **632–633**
 - differential diagnosis, **633**
 - DSD and, **651**
 - prognosis, **633**
 - suprarenal mass vs., **674**
- Adrenal lesions, mesoblastic nephroma vs., **623**
- Adrenal mass, complex, myoma in pregnancy vs., **1067**
- AEG syndrome, esophageal atresia and, **518**
- AFI (Amniotic fluid index). *See* Amniotic fluid index (AFI).
- AFV (Amniotic fluid volume). *See* Amniotic fluid volume (AFV).
- Agenesis
 - definition, **187**
 - Müllerian duct anomalies with, **1071**
- Agenesis/dysgenesis of corpus callosum, **108–111**
 - ± interhemispheric cyst, schizencephaly vs., **135**
 - Aicardi syndrome vs., **921–922**
 - Apert syndrome and, **929**
 - arachnoid cyst and, **152**
 - associated abnormalities, **110**
 - cavum septi pellucidi, absent vs., **208, 210**
 - conditions/syndromes associated with, **110**
 - diagnostic checklist, **110**
 - differential diagnosis, **110**
 - lobar holoprosencephaly vs., **125**
 - prognosis, **110**
 - semilobar holoprosencephaly vs., **123**

INDEX

- septo-optic dysplasia vs., **127**
- warfarin embryopathy and, **1011**
- Agyria, **139**
- Aicardi syndrome, **920–923**
 - agenesis of corpus callosum associated with, **110**
 - alobar holoprosencephaly associated with, **120**
 - arachnoid cyst and, **152**
 - associated abnormalities, **922**
 - coloboma and, **287**
 - diagnostic checklist, **922**
 - differential diagnosis, **921–922**
 - genetics, **922**
 - prognosis, **922**
- Airway cartilage, campomelic dysplasia and, **707**
- Airway epithelium, **326, 327**
 - primitive, **324**
- Airways
 - developing, **326, 327**
 - distal, development, **322**
- Akinesia sequence/arthrogryposis, **758–763**
 - associated abnormalities, **760**
 - diagnostic checklist, **760**
 - differential diagnosis, **759–760**
 - genetics, **760**
 - polyhydramnios vs., **1045**
 - prognosis, **760**
- Alagille syndrome
 - kyphosis/scoliosis and, **249**
 - tetralogy of Fallot and, **425**
- Alcohol embryopathy, chondrodysplasia punctata vs., **712**
- Allantoic duct cysts, **834, 836**
 - omphalocele vs., **497**
 - umbilical vein varix vs., **827**
 - urachal anomalies and, **648**
- Allantois, **570, 572, 573, 576, 577**
 - embryology and anatomy, **474, 477, 478, 480**
- Alobar holoprosencephaly
 - cavum septi pellucidi, absent vs., **208**
 - hydranencephaly vs., **163**
- Ambiguous genitalia. *See also* Disorders of sexual development (DSD).
 - cloacal malformation/urogenital sinus and, **533**
 - Smith-Lemli-Opitz syndrome vs., **993**
- Amelia/phocomelia, **698–701**
 - diagnostic checklist, **700**
 - differential diagnosis, **699–700**
 - genetics, **700**
 - prognosis, **700**
- Amniocentesis
 - amniotic band syndrome and, **925**
 - aqueductal stenosis and, **166**
 - complication, intracranial hemorrhage and, **156**
- Amnion, **786**
- Amnion rupture theory
 - amniotic band syndrome and, **925**
 - before obliteration of extraembryonic, **506**
- Amnionity, **840**
- Amniotic band syndrome, **924–927**
 - body stalk anomaly vs., **505**
 - calvarium, abnormal vs., **216**
 - circumvallate placenta vs., **813**
 - cleft lip, palate vs., **280**
 - cloacal exstrophy/OEIS syndrome vs., **513**
 - clubfoot vs., **733**
 - diagnostic checklist, **926**
 - differential diagnosis, **925**
 - ectopia cordis and, **385**
 - epignathus vs., **289**
 - exencephaly/anencephaly vs., **97**
 - gastroschisis vs., **491**
 - genetics, **925**
 - intrauterine linear echoes vs., **1087, 1089**
 - kyphosis/scoliosis and, **249**
 - micrognathia vs., **314**
 - occipital/parietal cephalocele vs., **101**
 - omphalocele vs., **497**
 - pentalogy of Cantrell vs., **503**
 - prognosis, **926**
 - rocker-bottom foot vs., **737**
 - split hand/foot malformation vs., **755**
 - staging, grading, & classification, **926**
 - types of defects seen, definitions, **926**
- Amniotic bands
 - amelia vs., **699**
 - sandal gap foot vs., **739**
 - syndactyly vs., **751**
 - synechiae vs., **1075**
- Amniotic cavity, **7, 476, 477**
- Amniotic fluid, **485**
 - AFI vs. gestational age, **1029**
 - approach to fetal well-being, **1028**
 - embryology and anatomy, **481**
 - findings, ureteropelvic junction obstruction and, **605**
 - requirements, lung development, **323**
 - ureterocele and, **643**
- Amniotic fluid index (AFI), **1028**
 - fetal genitourinary tract, **580**
 - gestational age vs., **1029**
 - hydronephrosis and, **664**
- Amniotic fluid volume (AFV), **1028**
 - fetal genitourinary tract, **580**
- Amniotic sheets. *See also* Synechiae.
 - amniotic band syndrome vs., **925**
 - circumvallate placenta vs., **813**
- Amniotocele. *See* Dacryocystocele.
- Amyoplasia, arthrogryposis/akinesia sequence vs., **759**
- Anal atresia, **530–531**
 - associated abnormalities, **531**
 - colonic atresia vs., **529**
 - diagnostic checklist, **531**
 - differential diagnosis, **531**
 - jejunal/ileal atresia vs., **525**
 - prognosis, **531**
 - tethered cord and, **251**
 - VACTERL association vs., **1005**
- Anal dimple
 - anal atresia and, **531**
 - embryology and anatomy, **483**
- Anal displacement, anal atresia vs., **531**
- Anchoring villus, **786**
- Anechoic structures, renal, **581**

INDEX

- Anemia
- Diamond-Blackfan, radial ray malformation vs., **742**
 - Fanconi, Holt-Oram syndrome vs., **957**
 - Fanconi, radial ray malformation vs., **741**
 - fetal, **1040–1043**
 - and chorioangioma, **817**
 - diagnostic checklist, **1042**
 - differential diagnosis, **1041**
 - expected peak MCA velocity measurements, **1042**
 - genetics, **1042**
 - prognosis, **1042**
 - intracranial hemorrhage and, **155**
 - twin, polycythemia sequence, fetal anemia vs., **1041**
- Anencephaly, **96–99**. *See also* Exencephaly.
- amniotic band syndrome vs., **925**
 - associated abnormalities, **98**
 - atelencephaly/aprosencephaly vs., **117**
 - calvarium, abnormal vs., **216, 219**
 - diagnostic checklist, **98**
 - differential diagnosis, **97**
 - Neu-Laxova syndrome vs., **977**
 - occipital/parietal cephalocele vs., **101**
 - prognosis, **98**
 - twin reversed arterial perfusion vs., **867**
- Aneuploidy
- chromosome, Cornelia de Lange syndrome vs., **941**
 - clubfoot and, **733**
 - cystic fibrosis vs., **945**
 - diabetic embryopathy vs., **947**
 - disorders of sexual development and, **651**
 - fetal growth restriction with, **1035**
 - gastroschisis and, **491**
 - genetic screening
 - 11 & 14 weeks, **886**
 - anomalies and markers, **885**
 - approach, **884–889**
 - guidelines, **884**
 - imaging techniques and normal anatomy, **884**
 - invasive, **884**
 - maternal age, **885**
 - serum results, **885**
 - strategies, **884**
 - increased risk of, **841**
 - mild ventriculomegaly vs., **212**
 - Pierre Robin sequence vs., **987**
 - radial ray malformation and, **740**
 - single umbilical cord and, **825**
 - Smith-Lemli-Opitz syndrome vs., **993**
 - syndactyly and, **752**
 - triploidy, **912–915**
 - trisomy 13, **902–907**
 - trisomy 18, **896–901**
 - trisomy 21, **890–895**
 - Turner syndrome, **908–911**
 - urinary tract dilation and, **585**
 - valproate embryopathy vs., **1009**
- Aneurysm of septum primum. *See* Atrial septal aneurysm.
- Angioosteohypertrophy syndrome. *See* Klippel-Trenaunay-Weber syndrome.
- Angulated bones, **774–779**
- differential diagnosis, **774–775**
- Angulation, abnormal joint, angulated bones and, **774, 778**
- Anhydramnios, 2nd-trimester, bilateral renal agenesis and, **602**
- Aniridia-Wilms syndrome, hypospadias and, **657**
- Annuloplasty, tricuspid dysplasia and, **401**
- Anomalies, fetal growth restriction with, **1035**
- Anomalous twin, twin reversal arterial perfusion vs., **867**
- Anophthalmia, **309**
- abnormal orbits/eyes vs., **305**
 - coloboma vs., **287**
 - Fraser syndrome vs., **951**
 - trisomy 13 and, **903**
- Anorectal malformations, hypospadias and, **657**
- Antenatal categories, urinary tract dilation, **586**
- Anterior fontanelle, **271**
- Anterior sacral meningocele, **229**
- Anterior-posterior renal pelvis diameter (APRPD), **580**
- Antigen alloimmune syndromes, minor, fetal anemia vs., **1041**
- Antiphospholipid syndrome, placental lakes associated, **808**
- Antral web/atresia, duodenal atresia vs., **521**
- Anuria, renal anomalies resulting in, bladder exstrophy vs., **509**
- Anus
- embryology and anatomy, **478**
 - formation, **480**
- Aorta, **231, 476, 477, 572, 574, 578, 579**
- embryology and anatomy, **365, 478, 481**
- Aorta straddles, truncus arteriosus vs., **433**
- Aortic arches, embryology and anatomy, **364**
- Aortic coarctation, hypoplastic left heart vs., **409**
- Aortic stenosis (AS), **416–419**
- diagnostic checklist, **418**
 - differential diagnosis, **417**
 - genetics, **418**
 - isolated, coarctation/interrupted aortic arch vs., **413**
 - prognosis, **418**
 - severe, hypoplastic left heart, **409**
- Aortic valve (AV)
- coarctation/interrupted aortic arch and, **413**
 - embryology and anatomy, **369**
 - hypoplastic left heart and, **409**
 - ventricular septal defect and, **389**
- AP RPD, urinary tract dilation, **585**
- Apert syndrome, **928–931**
- agenesis of corpus callosum associated with, **110**
 - Carpenter syndrome vs., **937**
 - diagnostic checklist, **929**
 - differential diagnosis, **929**
 - genetics, **929**
 - Pfeiffer syndrome vs., **983**
 - prognosis, **929**
 - syndactyly vs., **752**
- Aplastic kidney, unilateral renal agenesis vs., **589**
- Appendicitis, acute abdomen in pregnancy vs., **1082, 1084**
- Appendix, embryology and anatomy, **479**
- Aprosencephaly. *See also* Atelencephaly/aprosencephaly.
- exencephaly/anencephaly vs., **97**

INDEX

- Aqueductal stenosis, **164–167**
 - alobar holoprosencephaly vs., **119**
 - associated abnormalities, **166**
 - Chiari 2 malformation vs., **169**
 - diagnostic checklist, **166**
 - differential diagnosis, **165**
 - early, mild ventriculomegaly vs., **212, 214**
 - genetics, **166**
 - hydranencephaly vs., **163**
 - prognosis, **166**
- Arachnoid cyst (AC), **150–153**
 - Aicardi syndrome vs., **922**
 - associated abnormalities, **152**
 - Blake pouch cyst vs., **181**
 - cerebellar hypoplasia vs., **187**
 - Dandy-Walker malformation vs., **175**
 - differential diagnosis, **151**
 - dural sinus malformation vs., **201**
 - encephalomalacia/porencephaly vs., **159**
 - genetics, **152**
 - interhemispheric cyst/AVID vs., **113**
 - mega cisterna magna vs., **185**
 - posterior fossa cyst/fluid collection vs., **222, 224**
 - prognosis, **152**
 - schizencephaly vs., **135**
 - vein of Galen aneurysmal malformation vs., **195**
- Arcuate uterus, Müllerian duct anomalies in, **1071–1072**
- Arm, **273**
- ARPKD. *See* Autosomal recessive polycystic kidney disease.
- Arrhaphia theory, spina bifida and, **238**
- Arrhythmia
 - ascites vs., **560, 561**
 - assess for, **397**
 - irregular rhythm, **452–453**
 - rhabdomyoma and, **445**
- Arterial anomalies. *See* PHACES syndrome.
- Arteriovenous fistula, **198–199**
 - associated abnormalities, **199**
 - diagnostic checklist, **199**
 - differential diagnosis, **199**
 - prognosis, **199**
 - vein of Galen aneurysmal malformation vs., **195**
- Arteriovenous malformation, uterine, retained products of conception vs., **1081**
- Arthrogryposis/akinesia sequence, **758–763**
 - abnormal ossification vs., **780**
 - associated abnormalities, **760**
 - caudal regression sequence vs., **246**
 - clubfoot and, **733**
 - diagnostic checklist, **760**
 - differential diagnosis, **759–760**
 - distal
 - arthrogryposis/akinesia sequence vs., **759**
 - type 1A, arthrogryposis/akinesia sequence vs., **759**
 - genetics, **760**
 - kyphosis/scoliosis vs., **249**
 - polyhydramnios vs., **1045**
 - prognosis, **760**
 - rocker-bottom foot and, **737**
 - sirenomelia vs., **989**
 - trisomy 18 and, **897**
 - VACTERL association vs., **1006**
- Arthrogryposis multiplex congenita. *See* Arthrogryposis/akinesia sequence.
- AS. *See* Aortic stenosis (AS).
- Ascending aorta, embryology and anatomy, **369**
- Ascending colon, embryology and anatomy, **475, 481**
- Ascites, **486, 560–561**
 - cloacal malformation/urogenital sinus and, **533**
 - differential diagnosis, **560**
 - hydrops vs., **1052**
 - meconium peritonitis/pseudocyst vs., **541**
 - omphalocele and, **497**
 - parvovirus vs., **1021**
 - from perforation, colonic atresia and, **529**
 - urinary, **560, 561**
 - meconium peritonitis/pseudocyst vs., **541**
 - volvulus and, **537**
- Asphyxiating thoracic dystrophy, short rib-polydactyly syndrome and, **723**
- Assisted reproductive treatment (ART), triplets and, **875**
- Astrocytoma, brain tumors and, **203**
- Atelencephaly/aprosencephaly, **116–117**
 - alobar holoprosencephaly vs., **119**
 - associated abnormalities, **117**
 - diagnostic checklist, **117**
 - differential diagnosis, **117**
 - exencephaly/anencephaly vs., **97**
 - prognosis, **117**
- Atelosteogenesis, **702–705**
 - abnormal ossification vs., **780, 781**
 - associated abnormalities, **703**
 - differential diagnosis, **703**
 - genetics, **703**
 - micromelia vs., **700**
 - prognosis, **703**
 - type 1, **703**
 - type 2, **703**
 - type 3, **703**
 - type II, achondrogenesis/hypochondrogenesis vs., **689**
- Atresia
 - bowel, gastroschisis and, **492**
 - meconium peritonitis/pseudocyst and, **542**
 - pulmonary, **404–407**
 - tricuspid, **402–403**
 - chamber asymmetry and, **468, 470**
 - diagnostic checklist, **403**
 - differential diagnosis, **403**
 - prognosis, **403**
 - pulmonary stenosis/atresia vs., **405**
 - staging, grading, & classification, **403**
 - urethral
 - posterior urethral valves vs., **635**
 - prune-belly syndrome vs., **639**
- Atretic cephalocele, **104–105**
 - associated abnormalities, **105**
 - diagnostic checklist, **105**
 - differential diagnosis, **105**
 - prognosis, **105**
- Atria septum, embryology and anatomy, **368**
- Atrial bradycardia, bradyarrhythmia vs., **459**
- Atrial chambers, embryology and anatomy, **367**

INDEX

- Atrial ectopic tachycardia, **455**
- tachyarrhythmia vs., **455**
- Atrial flutter, **456**
- irregular rhythm vs., **453**
- tachyarrhythmia vs., **455**
- Atrial septa, ventricular septal defect and, **389**
- Atrial septal aneurysm, **394–395**
- associated abnormalities, **395**
- diagnostic checklist, **395**
- differential diagnosis, **395**
- genetics, **395**
- prognosis, **395**
- Atrial septal defects, **397**
- isolated, Holt-Oram syndrome vs., **957**
- large, atrioventricular septal defect vs., **391**
- prune-belly syndrome and, **640**
- Atrial septum, embryology and anatomy, **369, 371**
- Atrioventricular block
- 1st-degree, **459**
- 2nd-degree, **459**
- partial, bradyarrhythmia vs., **459**
- Atrioventricular canal. *See* Atrioventricular septal defect.
- Atrioventricular septal defect (AVSD), **375, 390–393**
- associated abnormalities, **392**
- complete (balance), **392**
- diagnostic checklist, **392**
- differential diagnosis, **391**
- echogenic cardiac focus vs., **439**
- genetics, **392**
- partial, **392**
- prognosis, **392**
- Rastelli classification of, **392**
- staging, grading, & classification, **392**
- unbalanced, **392**
 chamber asymmetry vs., **468–469, 471**
- unbalanced left dominant, tricuspid atresia vs., **403**
- ventricular septal defect vs., **389**
- Atrioventricular (AV) valves, **375**
- Atrium, approach to imaging, **85**
- Atrophy, definition, **187**
- Auricle, **265**
- Auricular hillocks, **265**
- Autopsy, CHARGE syndrome, **939**
- Autosomal dominant polycystic kidney disease, autosomal recessive polycystic kidney disease vs., **619**
- Autosomal dominant single-gene disorder, achondroplasia and, **696**
- Autosomal recessive polycystic kidney disease, **618–621, 672**
- diagnostic checklist, **620**
- differential diagnosis, **619**
- echogenic kidneys vs., **668**
- genetics, **619**
- Meckel-Gruber syndrome vs., **972**
- mesoblastic nephroma vs., **623**
- oligohydramnios vs., **1048–1049, 1051**
- prognosis, **620**
- unilateral enlarged kidney vs., **670**
- AV reentry, tachyarrhythmia vs., **455, 456**
- AVSD. *See* Atrioventricular septal defect (AVSD).
- Axial mesodermal dysplasia spectrum. *See* Caudal regression sequence (CRS).
- Axillary lymphangioma. *See* Lymphangioma.
- ## B
- Bacterial infection, intracranial hemorrhage and, **155**
- Balloon valvuloplasty, hypoplastic left heart and, **410**
- Banana sign, cavum septi pellucidi, absent and, **208**
- Bardet-Biedl syndrome
- Carpenter syndrome vs., **937**
- Fraser syndrome vs., **951**
- Meckel-Gruber syndrome vs., **972**
- polydactyly vs., **748**
- Barnes syndrome, short rib-polydactyly syndrome vs., **724**
- Bartsocas-Papas syndrome, multiple pterygium syndromes vs., **975**
- Basal plate, **786**
- BE. *See* Bladder exstrophy.
- Beckwith-Wiedemann syndrome, **319, 669, 672, 932–935**
- autosomal recessive polycystic kidney disease vs., **619**
- diagnostic checklist, **934**
- differential diagnosis, **933**
- duplicated collecting system vs., **591–592**
- echogenic kidneys vs., **668**
- genetics, **933**
- Klippel-Trenaunay-Weber syndrome vs., **967**
- macroglossia vs., **318**
- macrosomia vs., **1039**
- malignant liver tumors vs., **555**
- mesenchymal hamartoma and, **553**
- mesoblastic nephroma vs., **623**
- omphalocele and, **498**
- prognosis, **934**
- staging, grading, & classification, **933**
- treatment, **934**
- triploidy vs., **913**
- ultrasonographic findings, **933**
- unilateral enlarged kidney vs., **670**
- Benign transient bradycardia, bradyarrhythmia vs., **459**
- Benign vascular tumor, placental lake vs., **807**
- Beware pitfalls, bilateral renal agenesis, **601**
- Bickers-Adams syndrome, aqueductal stenosis and, **166**
- Bicornuate uterus, Müllerian duct anomalies in, **1071–1072**
- Bicuspid aortic valve, aortic stenosis and, **417**
- Bilaminar embryo, **7, 786**
- Bilateral cleft lip, echogenic kidneys and, **668**
- Bilateral left sidedness. *See* Heterotaxy/cardiosplenic syndromes.
- Bilateral multicystic dysplastic kidney
- bladder exstrophy vs., **509**
- Meckel-Gruber syndrome vs., **972**
- Bilateral periventricular nodular heterotopia, tuberous sclerosis vs., **1001**
- Bilateral renal anomaly
- oligohydramnios vs., **1048**
- sirenomelia vs., **989**
- Bilateral symmetric short femurs, proximal focal femoral dysplasia vs., **765**

INDEX

- Bilateral ureteropelvic junction, hydronephrosis and, **664**
- Biliary atresia, cystic, choledochal cyst vs., **549**
- Bilobated placenta. *See* Succenturiate lobe.
- Bilobed placenta. *See* Succenturiate lobe.
- Binder maxillofacial dysplasia, chondrodysplasia punctata vs., **712**
- Binder phenotype, warfarin embryopathy vs., **1011**
- Binocular distance, **267**
- Bioengineering, bladder exstrophy, **510**
- Biologic markers, neuroblastoma, **630**
- Biometry, abnormal, fetal growth restriction, **1035**
- Biophysical profile (BPP), **1028, 1029**
- Birth defects, cloacal exstrophy/OEIS syndrome and, **513**
- Bizarre abdominal wall defect, gastroschisis and, **491**
- Bladder, **573, 574, 575, 576, 577**
- abnormal urinary tract, **581**
 - absent
 - abnormal urinary tract, **581**
 - bladder exstrophy vs., **509**
 - causes for, bilateral renal agenesis vs., **601–602**
 - absent/decompressed, cloacal malformation/urogenital sinus and, **533**
 - development, **570, 573**
 - dilated, cloacal malformation/urogenital sinus and, **533**
 - distension, posterior urethral valves and, **635**
 - duplicated collecting system and, **591**
 - embryology and anatomy, **481, 483**
 - exstrophy, bilateral renal agenesis vs., **602**
 - full maternal, **785**
 - placenta previa vs., **795**
 - "hutch" diverticulum, ureterocele vs., **643–644**
 - rupture
 - bilateral renal agenesis vs., **602**
 - posterior urethral valves and, **635**
 - ureterocele and, **643**
- Bladder abnormalities, cloacal malformation/urogenital sinus and, **533**
- Bladder exstrophy, **508–511**
- associated abnormalities, **510**
 - cloacal exstrophy/OEIS syndrome vs., **513**
 - diagnostic checklist, **510**
 - differential diagnosis, **509**
 - differentiation, **514**
 - disorders of sexual development and, **651**
 - etiology, **509**
 - genetics, **509**
 - hypospadias vs., **657**
 - prognosis, **510**
 - urachal anomalies and, **648**
- Bladder flap hematoma, uterine rupture vs., **1077**
- Blake pouch cyst (BPC), **92, 180–183**
- associated abnormalities, **182**
 - Dandy-Walker malformation vs., **175**
 - diagnostic checklist, **182**
 - differential diagnosis, **181**
 - mega cisterna magna vs., **185**
 - posterior fossa cyst/fluid collection vs., **222, 224**
 - prognosis, **182**
 - vermian dysgenesis, **179**
- Blastema, metanephric, **570, 572**
- Blastocele cavity, within blastocyst, **6**
- Blastocyst, "naked," **6**
- Bleed, between membranes, intrauterine linear echoes vs., **1087, 1089**
- Block vertebra, kyphosis/scoliosis and, **249**
- Blocked premature atrial contractions, bradyarrhythmia vs., **459**
- Blue or gray sclerae, osteogenesis imperfecta and, **719**
- Body, front of, **273**
- Body ectoderm, **231**
- Body stalk, embryology and anatomy, **476, 478**
- Body stalk anomaly, **504–507**
- amniotic band syndrome vs., **925**
 - associated abnormalities, **506**
 - cloacal exstrophy/OEIS syndrome vs., **513**
 - diagnostic checklist, **506**
 - differential diagnosis, **505**
 - ectopia cordis associated with, **385**
 - epidemiology, **506**
 - etiology, **505–506**
 - gastroschisis vs., **491**
 - genetics, **506**
 - occipital/parietal cephalocele vs., **101**
 - omphalocele vs., **497**
 - pentalogy of Cantrell vs., **503**
 - prognosis, **506**
 - risk factors, **506**
 - spina bifida vs., **237**
- Bone growth, achondroplasia and, **695**
- Bone length charts, **686–687**
- lower extremity long bones, **686**
 - measurements, **687**
 - upper extremity long bones, **686–687**
- Bones
- morphology, **680**
 - short, **680**
- "Boomerang" dysplasia, atelosteogenesis vs., **703**
- Bourneville disease. *See* Tuberous sclerosis.
- Bowel
- approach to abdominal wall and gastrointestinal tract, **484**
 - dilatation, hydrocolpos vs., **663**
 - dilated
 - anal atresia and, **531**
 - enteric duplication cyst vs., **539**
 - loops, **485**
 - ovarian cyst vs., **659**
 - echogenic, **558–559**
 - causes of, meconium peritonitis/pseudocyst vs., **541**
 - cytomegalovirus vs., **1017**
 - toxoplasmosis vs., **1023**
 - ischemia, echogenic bowel vs., **558, 559**
- Bowel anomalies, meconium peritonitis/pseudocyst and, **542**
- Bowel atresia
- cystic abdominal mass vs., **562, 564**
 - gastroschisis and, **492**
 - mesenteric lymphangioma vs., **545**
- Bowel distention/obstruction, cloacal malformation/urogenital sinus and, **533**
- Bowel ischemia, cystic fibrosis vs., **945**
- Bowel loops, dilated, volvulus and, **537**

INDEX

- Bowel lumen, **486**
- Bowel obstruction
- fetal, polyhydramnios vs., **1044–1045, 1046**
 - polyhydramnios, **624**
- Bowel perforation, ascites vs., **560, 561**
- Bowel rotation, **478–479**
- Bowel-only omphalocele, omphalocele and, **497**
- Bowman capsule, **572**
- BPP (Biophysical profile). *See* Biophysical profile (BPP).
- Brachmann-de Lange syndrome. *See* Cornelia de Lange syndrome.
- Brachycephaly, **85**
- calvarium, abnormal vs., **216**
- Brachydactyly, approach to skeletal dysplasias and, **681**
- Brachyuricephaly, craniosynostosis with, Apert syndrome and, **929**
- Bradycardia, **458–461**
- ascites vs., **560**
 - diagnostic checklist, **460**
 - differential diagnosis, **459**
 - hydrops vs., **1052, 1054**
 - prognosis, **460**
- Bradycardia
- benign transient, **459**
 - bradycardia vs., **459**
 - sinus or low atrial, **459**
- Brain
- agenesis/dysgenesis of corpus callosum, **108–111**
 - associated abnormalities, **110**
 - conditions/syndromes associated with, **110**
 - diagnostic checklist, **110**
 - differential diagnosis, **110**
 - prognosis, **110**
 - alobar holoprosencephaly, **118–121**
 - abnormal facial features associated with, **120**
 - associated with multiple syndromes, **120**
 - diagnostic checklist, **120**
 - differential diagnosis, **119**
 - prognosis, **120**
 - approach to fetal spine and, **234**
 - approach to posterior fossa, **90–95**
 - abnormalities, imaging findings, **92**
 - clinical implications, **92**
 - imaging techniques and normal anatomy, **90**
 - pitfalls in evaluation, **92**
 - approach to supratentorial brain, **84–89**
 - clinical implications, **86**
 - fetal brain, **85**
 - fetal neurosonography, **86**
 - imaging techniques and normal anatomy, **84**
 - aqueductal stenosis, **164–167**
 - arachnoid cyst, **150–153**
 - arteriovenous fistula, **198–199**
 - atelencephaly/aprosencephaly, **116–117**
 - associated abnormalities, **117**
 - diagnostic checklist, **117**
 - differential diagnosis, **117**
 - prognosis, **117**
 - atretic cephalocele, **104–105**
 - associated abnormalities, **105**
 - diagnostic checklist, **105**
 - differential diagnosis, **105**
 - prognosis, **105**
 - Blake pouch cyst, **180–183**
 - brain tumors, **202–203**
 - calvarium, abnormal, **216–221**
 - cavum septi pellucidi, absent, **208–211**
 - cerebellar hypoplasia, **186–189**
 - Chiari 2 malformation, **168–171**
 - Chiari 3 malformation, **172–173**
 - choroid plexus cyst, **148–149**
 - diagnostic checklist, **149**
 - differential diagnosis, **149**
 - prognosis, **149**
 - choroid plexus papilloma, **204–205**
 - cytomegalovirus, **1017**
 - Dandy-Walker malformation, **174–177**
 - dural sinus malformation, **200–201**
 - embryology and anatomy, **68–83**
 - calcarine sulcus, **80**
 - cavum septi pellucidi, **74**
 - cerebrum, cerebellum, and ventricles, **68–69**
 - convexity sulci and gyri, **81**
 - corpus callosum, cingulate gyrus, **77–78**
 - 1st-trimester embryo, **71**
 - 1st-trimester fetus, **70, 72**
 - imaging issues, **69**
 - major events, **68**
 - parietooccipital sulcus, **79**
 - posterior fossa, **82–83**
 - 2nd-trimester fetus, **73**
 - sylvian fissure, **75**
 - telencephalon: cerebral hemispheres, **76**
 - encephalomalacia, **158–161**
 - exencephaly/anencephaly, **96–99**
 - associated abnormalities, **98**
 - diagnostic checklist, **98**
 - differential diagnosis, **97**
 - prognosis, **98**
 - frontal cephalocele, **106–107**
 - diagnostic checklist, **107**
 - differential diagnosis, **107**
 - prognosis, **107**
 - gray matter heterotopia, **142–143**
 - associated abnormalities, **143**
 - diagnostic checklist, **143**
 - differential diagnosis, **143**
 - prognosis, **143**
 - hydranencephaly, **162–163**
 - interhemispheric cyst/AVID, **112–115**
 - associated abnormalities, **114**
 - diagnostic checklist, **114**
 - differential diagnosis, **113–114**
 - prognosis, **114**
 - intracranial hemorrhage (ICH), **154–157**
 - intracranial lipoma, **206–207**
 - lissencephaly, **138–141**
 - classification systems, **140**
 - diagnostic checklist, **140**
 - differential diagnosis, **139**
 - gestational age milestones for sulcation, **140**
 - prognosis, **140**

INDEX

- lissencephaly, pachygyria/polymicrogyria vs., **145**
 - lobar holoprosencephaly, **124–125**
 - diagnostic checklist, **125**
 - differential diagnosis, **125**
 - prognosis, **125**
 - mega cisterna magna, **184–185**
 - occipital/parietal cephalocele, **100–103**
 - associated abnormalities, **102**
 - diagnostic checklist, **102**
 - differential diagnosis, **101–102**
 - prognosis, **102**
 - osteogenesis imperfecta and, **719**
 - pachygyria/polymicrogyria, **144–147**
 - associated abnormalities, **145**
 - diagnostic checklist, **145**
 - differential diagnosis, **145**
 - prognosis, **145**
 - porencephaly, **158–161**
 - posterior fossa cyst/fluid collection, **222–225**
 - rhombencephalosynapsis, **190–193**
 - schizencephaly, **134–137**
 - associated migrational anomalies, **136**
 - diagnostic checklist, **136**
 - differential diagnosis, **135–136**
 - prognosis, **136**
 - semilobar holoprosencephaly, **122–123**
 - diagnostic checklist, **123**
 - differential diagnosis, **123**
 - prognosis, **123**
 - septo-optic dysplasia
 - associated abnormalities, **128**
 - diagnostic checklist, **128**
 - differential diagnosis, **127**
 - fetal optic tract diameter, reference ranges, **128**
 - prognosis, **128**
 - vein of Galen aneurysmal malformation, **194–197**
 - ventriculomegaly, mild, **212–215**
 - vermian dysgenesis, **178–179**
 - Brain tumors, **202–203**
 - associated abnormalities, **203**
 - differential diagnosis, **203**
 - genetics, **203**
 - prognosis, **203**
 - Brainstem, approach to imaging, **91**
 - Branch pulmonary artery, embryology and anatomy, **369**
 - Branch pulmonary stenosis, transposition of great arteries and, **430**
 - Branchial arches, **324**
 - embryology and anatomy, **262**
 - Branchio-oto-renal dysplasia syndrome, bilateral renal agenesis and, **602**
 - Branchio-oto-renal syndrome, Fraser syndrome vs., **951**
 - Breath, 1st, **323**
 - Bronchial atresia, bronchopulmonary sequestration vs., **341**
 - Bronchial branches, **326**
 - Bronchial buds, **325**
 - primary, **324, 325**
 - and branches, development, **322, 324**
 - Bronchial obstruction, congenital pulmonary airway malformation vs., **337**
 - Bronchial stenosis/atresia
 - bronchopulmonary sequestration vs., **341**
 - solid/echogenic chest mass vs., **357, 358**
 - Bronchogenic cyst, **344–345**
 - congenital pulmonary airway malformation vs., **337**
 - cystic chest mass vs., **360, 361**
 - differential diagnosis, **345**
 - prognosis, **345**
 - Bronchopulmonary sequestration, **340–343**
 - abnormal cardiac axis vs., **462, 464**
 - associated abnormalities, **342**
 - congenital adrenal hyperplasia vs., **633**
 - with congenital pulmonary airway malformation (hybrid lesion)
 - congenital pulmonary airway malformation vs., **337**
 - differential diagnosis, **341**
 - congenital pulmonary airway malformation vs., **337**
 - differential diagnosis, **341–342**
 - extralobar, adrenal hemorrhage vs., **627**
 - genetics, **342**
 - heterotaxy/cardiosplenic syndromes and, **381**
 - mediastinal teratoma vs., **355**
 - pericardial teratoma vs., **451**
 - prognosis, **342**
 - pulmonary agenesis vs., **349**
 - solid/echogenic chest mass vs., **356, 358**
 - suprarenal mass vs., **674**
 - Bronchus
 - development, **322**
 - left lower lobe, **325**
 - left mainstem, **328**
 - left upper lobe, **325**
 - right mainstem, **328**
 - right upper lobe, **325**
 - Bronchus intermedius, **325**
 - Butterfly vertebra, kyphosis/scoliosis and, **249**
 - BWS (Beckwith-Wiedemann syndrome). *See* Beckwith-Wiedemann syndrome.
- ## C
- CA. *See* Colonic atresia.
 - CAH. *See* Congenital adrenal hyperplasia.
 - CAKUT syndromes, Fraser syndrome vs., **951**
 - Calcarine sulcus, embryology and anatomy, **80**
 - Calcifications
 - abdominal, toxoplasmosis vs., **1023**
 - cytomegalovirus with, **1017**
 - from infection, gallstones and, **547**
 - Callosal agenesis/dysgenesis
 - Aicardi syndrome and, **921**
 - Chiari 2 malformation and, **169**
 - Dandy-Walker malformation and, **175**
 - Calvarium
 - abnormal, **216–221**
 - differential diagnosis, **216**
 - approach to skeletal dysplasias and, **681**
 - thanatophoric dysplasia and, **727**
 - Campomelic dysplasia, **706–709**
 - acampomelic, campomelic dysplasia vs., **707**

INDEX

- angulated bones and, **774, 777**
- associated abnormalities, **707**
- diagnostic checklist, **707**
- differential diagnosis, **707**
- disorders of sexual development and, **651**
- genetics, **707**
- osteogenesis imperfecta vs., **719**
- prognosis, **707**
- thanatophoric dysplasia vs., **727**
- Capillaries, **326, 327**
- Cardiac abnormality, pericardial effusion and, **449**
- Cardiac anomalies
 - gastroschisis and, **492**
 - pentalogy of Cantrell and, **503**
 - prune-belly syndrome and, **640**
 - Smith-Lemli-Opitz syndrome vs., **993**
- Cardiac axis, **374**
 - abnormal, **462–467**
 - differential diagnosis, **462**
 - pulmonary agenesis vs., **349**
- Cardiac defects. *See also* PHACES syndrome.
 - omphalocele and, **498**
 - short rib-polydactyly syndrome and, **724**
 - structural, hydrops vs., **1052, 1053**
 - valproate embryopathy vs., **1009**
- Cardiac failure
 - high-output, arteriovenous fistula and, **199**
 - short rib-polydactyly syndrome and, **724**
- Cardiac focus, echogenic, **438–439**
 - diagnostic checklist, **439**
 - differential diagnosis, **439**
 - genetics, **439**
 - prognosis, **439**
 - rhabdomyoma vs., **445**
- Cardiac malformations, hydronephrosis and, **664**
- Cardiac prominence, embryology and anatomy, **480**
- Cardiac rhabdomyoma, tuberous sclerosis and, **1001–1002**
- Cardiac structural malformation, total anomalous pulmonary venous return and, **422**
- Cardiac total anomalous pulmonary venous return, **421**
- Cardinal findings, of cloacal exstrophy, **513**
- Cardinal veins, embryology and anatomy, **365**
- Cardiomegaly, **375, 397**
 - cardiac causes, **374–375**
 - tricuspid dysplasia and, **401**
 - vein of Galen aneurysmal malformation vs., **196**
- Cardiomyopathy, **440–443**
 - diagnostic checklist, **442**
 - differential diagnosis, **441**
 - dilated, **440–443**
 - hypertrophic, **440–443**
 - prognosis, **442**
 - twin-twin transfusion syndrome and, **863**
- Cardiovascular system, embryology and anatomy, **364–373**
 - adult circulation, **373**
 - arteries, **364–365**
 - cardiac anatomy, **365**
 - 4-chamber heart, **367**
 - normal, **365**
 - circulation, **366**
 - fetal circulation, **372**
 - left superior vena cava, **371**
 - organogenesis, **4–5**
 - overview, **364**
 - postnatal circulation, **373**
 - primitive heart tube, **366**
 - right ventricular outflow tract, **369**
 - systemic vein, **365**
 - umbilical cord and arteries, **372**
 - umbilical vein and ductus venosus, **372**
 - venoatrial connections, **370**
 - venous, **365**
 - ventricles, **368**
 - ventriculoarterial connections, **369**
- Carpenter syndrome, **936–937**
 - Apert syndrome vs., **929**
 - differential diagnosis, **937**
 - genetics, **937**
 - Pfeiffer syndrome vs., **983**
 - polydactyly vs., **747**
 - prognosis, **937**
 - syndactyly vs., **752**
 - thanatophoric dysplasia vs., **728**
- Cartilage oligomeric matrix protein-associated disorders, achondroplasia vs., **695–696**
- Cartilaginous stage, of vertebral body development, **229**
- Cauda equina, **229**
- Caudal cell mass, **228**
- Caudal dysgenesis syndrome, sirenomelia vs., **989**
- Caudal dysplasia, **680**. *See also* Caudal regression sequence (CRS).
- Caudal eminence, **231**
- Caudal neuropore, **231**
- Caudal regression, **228**
- Caudal regression sequence (CRS), **244–247**
 - arthrogryposis/akinesia sequence vs., **760**
 - diabetic embryopathy vs., **947**
 - diagnostic checklist, **246**
 - differential diagnosis, **245**
 - genetics, **246**
 - kyphosis/scoliosis vs., **249**
 - prognosis, **246**
 - staging, grading, & classification, **246**
- Caudal regression syndrome, sirenomelia vs., **989**
- Caudal urogenital sinus, **573, 576, 577**
- Cavum, absence, approach to imaging, **85**
- Cavum septi pellucidi
 - absent, **208–211**
 - differential diagnosis, **208**
 - schizencephaly vs., **135–136**
 - semilobar holoprosencephaly vs., **123**
 - septo-optic dysplasia vs., **127**
 - Apert syndrome and, **929**
 - embryology and anatomy, **74**
- Cavum septi pellucidi et vergae, cavum septi pellucidi, absent vs., **208**
- Cavum vergae, arachnoid cyst vs., **152**
- CB. *See* Chorionic bump (CB).
- CDH (congenital diaphragmatic hernia), heterotaxy/cardiosplenic syndromes vs., **381**

INDEX

- CdLS (Cornelia de Lange syndrome). *See* Cornelia de Lange syndrome.
- CE. *See* Cloacal exstrophy/OEIS syndrome.
- Cebocephaly, alobar holoprosencephaly associated with, **120**
- Cecoureterocele, **643**
- Cecum, embryology and anatomy, **478, 479**
- Celiac artery, embryology and anatomy, **478**
- Cell free fetal DNA (cfDNA) test, **884**
- 2-cell stage, **6**
- 4-cell stage, **6**
- 8-cell stage, **6**
- Central hyaloid artery, **266**
- Central nervous system
- abnormalities, thanatophoric dysplasia and, **728**
 - anomalies, gastroschisis and, **492**
 - embryology and anatomy organogenesis, **4**
- Cephalocele, amniotic band syndrome vs., **925**
- Cephalopolysyndactyly, Greig, polydactyly vs., **747**
- Cephalopolysyndactyly syndrome, Greig, syndactyly vs., **751**
- Cerclage
- cervical, **1062**
 - transabdominal, **1062**
 - transvaginal, **1062**
- Cerebellar atrophy, **92**
- Cerebellar biometry, **188**
- Cerebellar compression, Chiari 2 malformation and, **169**
- Cerebellar disruption
- cerebellar hypoplasia vs., **187**
 - Dandy-Walker malformation vs., **175**
 - unilateral, rhombencephalosynapsis vs., **191**
- Cerebellar hypoplasia, **186–189**
- associated abnormalities, **187**
 - Chiari 2 malformation vs., **170**
 - diagnostic checklist, **188**
 - differential diagnosis, **187**
 - genetics, **187**
 - posterior fossa cyst/fluid collection vs., **222, 225**
 - prognosis, **188**
 - rhombencephalosynapsis vs., **191**
 - trisomy 13 and, **903**
 - trisomy 18 and, **897**
- Cerebello-trigeminal-dermal dysplasia, rhombencephalosynapsis and, **191**
- Cerebellum
- approach to imaging, **91**
 - embryology and anatomy, **69**
- Cerebral atrophy, vein of Galen aneurysmal malformation vs., **196**
- Cerebral hemispheres, embryology and anatomy, **68, 76**
- Cerebro-oculo-facial syndrome, bilateral renal agenesis and, **602**
- Cerebrum, embryology and anatomy, **68–69**
- Cervical cerclage, **1062**
- Cervical dilation, **1061**
- Cervical ectopic pregnancy, **44–47**
- cesarean scar ectopic pregnancy vs., **49**
 - diagnostic checklist, **46**
 - differential diagnosis, **45**
 - prognosis, **46**
- Cervical effacement, **1061**
- Cervical hyperextension, isolated, iniencephaly vs., **243**
- Cervical insufficiency, **1060–1065**
- cervical cerclage, **1062**
 - definition, **1061**
 - diagnostic checklist, **1062**
 - differential diagnosis, **1061**
 - prognosis, **1061–1062**
- Cervical mass, cervical ectopic pregnancy vs., **45**
- Cervical nephrotomes, **572**
- Cervical neuroblastoma, goiter vs., **295**
- Cervical spine, iniencephaly and, **243**
- Cervical teratoma, **302–303**
- cystic hygroma vs., **299–300**
 - diagnostic checklist, **303**
 - differential diagnosis, **303**
 - epignathus vs., **289**
 - goiter vs., **295**
 - prognosis, **303**
 - staging, grading, & classification, **303**
- Cesarean scar ectopic pregnancy, **48–49**
- cervical ectopic pregnancy vs., **45**
 - diagnostic checklist, **49**
 - differential diagnosis, **49**
 - prognosis, **49**
- Cesarean section, prominent scar, cesarean scar ectopic pregnancy vs., **49**
- CF (Cystic fibrosis). *See* Cystic fibrosis.
- Chamber asymmetry, **375, 468–471**
- abnormal cardiac axis vs., **462, 465**
 - differential diagnosis, **468**
- CHAOS (congenital high airway obstruction sequence), **346–347**
- associated abnormalities, **347**
 - diagnostic checklist, **347**
 - differential diagnosis, **347**
 - genetics, **347**
 - prognosis, **347**
- CHARGE syndrome, **938–939**
- coloboma and, **287**
 - diagnostic checklist, **939**
 - diagnostic criteria, **939**
 - differential diagnosis, **939**
 - esophageal atresia and, **518**
 - genetics, **939**
 - Goldenhar syndrome vs., **955**
 - prognosis, **939**
 - tetralogy of Fallot and, **425**
 - VACTERL association vs., **1006**
- CHB. *See* Complete heart block (CHB).
- Chest
- approach to fetal chest, **330–331**
 - chest mass, **330–331**
 - imaging techniques and normal anatomy, **330**
 - approach to skeletal dysplasias, **681**
 - bronchogenic cyst, **344–345**
 - bronchopulmonary sequestration, **340–343**
 - CHAOS (congenital high airway obstruction sequence), **346–347**
 - congenital diaphragmatic hernia, **332–335**

INDEX

- congenital pulmonary airway malformation, **336–339**
- cystic chest mass, **360–361**
- embryology and anatomy, **322–329**
- lymphangioma, **350–353**
- mediastinal/pulmonary teratoma, pericardial teratoma vs., **451**
- mediastinal teratoma, **354–355**
- osteogenesis imperfecta and, **719**
- pleural effusion, pericardial effusion vs., **449**
- pulmonary agenesis, **348–349**
- solid/echogenic chest mass, **356–359**
- Chest mass
 - abnormal cardiac axis and, **462**
 - cystic, **360–361**
 - differential diagnosis, **360**
 - fetal, approach to, **330–331**
 - hydrops vs., **1053, 1057**
 - solid/echogenic, **356–359**
 - differential diagnosis, **356**
- Chiari 2 malformation, **168–171**
 - agenesis of corpus callosum associated with, **110**
 - aqueductal stenosis vs., **166**
 - cavum septi pellucidi, absent vs., **208, 210**
 - diagnostic checklist, **170**
 - differential diagnosis, **169**
 - early, mild ventriculomegaly vs., **212, 214**
 - genetics, **170**
 - prognosis, **170**
 - staging, grading, & classification, **170**
- Chiari 3 malformation, **172–173**
 - diagnostic checklist, **173**
 - differential diagnosis, **173**
 - occipital/parietal cephalocele vs., **102**
 - prognosis, **173**
- Chiari malformation, Joubert syndrome vs., **963**
- Chickenpox, toxoplasmosis vs., **1023**
- CHILD syndrome (congenital hemidysplasia, ichthyosis, limb defects), chondrodysplasia punctata vs., **711–712**
- Childbearing, delayed, triplets and, **875**
- Childhood, Beckwith-Wiedemann syndrome, **934**
- Cholecystitis, acute abdomen in pregnancy vs., **1082**
- Choledochal cyst, **548–549**
 - cystic abdominal mass vs., **562, 565**
 - diagnostic checklist, **549**
 - differential diagnosis, **549**
 - duodenal atresia vs., **521**
 - enteric duplication cyst vs., **539**
 - gallstones vs., **547**
 - mesenteric lymphangioma vs., **545**
 - ovarian cyst vs., **659**
 - persistent right umbilical vein vs., **829**
 - prognosis, **549**
 - staging, grading, & classification, **549**
 - umbilical vein varix vs., **827**
- Choledochocyst, meconium peritonitis/pseudocyst vs., **541**
- Chondrocranium, **270**
- Chondrodysplasia punctata, **710–713**
 - brachytelephalangi type, **711**
 - diagnostic checklist, **712**
 - differential diagnosis, **711–712**
 - prognosis, **712**
 - rhizomelic type, **711**
 - warfarin embryopathy vs., **1011**
- Chondroectodermal dysplasia, polydactyly vs., **747**
- Chorangiomas, placental mesenchymal dysplasia vs., **823**
- Chorioamnionitis, encephalomalacia/porencephaly and, **160**
- Chorioamniotic separation
 - amniotic band syndrome vs., **925**
 - intrauterine linear echoes vs., **1087, 1088**
 - perigestational hemorrhage vs., **25**
 - trisomy 21 and, **891**
 - vasa previa vs., **799**
- Chorioangioma, **816–819**
 - associated abnormalities, **818**
 - diagnostic checklist, **818**
 - differential diagnosis, **817–818**
 - gross pathologic and surgical features, **818**
 - myoma in pregnancy vs., **1067**
 - placental
 - hydrops vs., **1053, 1057**
 - polyhydramnios vs., **1045, 1047**
 - placental abruption vs., **791**
 - placental cysts and masses vs., **830, 832**
 - placental lake vs., **807**
 - placental teratoma vs., **821**
 - prognosis, **818**
- Chorioangiomas, **817**
- Choriocarcinoma, abnormal gestational sac and contents vs., **57**
- Chorionic bump (CB), **28–29**
 - abnormal gestational sac and contents vs., **57**
 - diagnostic checklist, **29**
 - differential diagnosis, **29**
 - prognosis, **29**
- Chorionic cavity, **7**
- Chorionic frondosum, **784**
- Chorionic plate, **786**
- Chorionic villi, **786**
- Chorionicity, **840, 851**
 - impact, **842**
- Choroid plexus cyst, **148–149**
 - arachnoid cyst vs., **151**
 - choroid plexus papilloma vs., **205**
 - diagnostic checklist, **149**
 - differential diagnosis, **149**
 - prognosis, **149**
 - trisomy 18 and, **897**
- Choroid plexus papilloma (CPP), **204–205**
 - associated abnormalities, **205**
 - choroid plexus cyst vs., **149**
 - diagnostic checklist, **205**
 - differential diagnosis, **205**
 - intracranial hemorrhage vs., **155**
 - prognosis, **205**
- Chromosomal abnormalities
 - omphalocele and, **498**
 - pentalogy of Cantrell and, **503**
- Chromosomal anomalies
 - duodenal atresia and, **521**

INDEX

- prune-belly syndrome and, **640**
- Chromosome 13q deletion syndrome, radial ray malformation vs., **741**
- Chromosome 22q11 deletion syndrome, clubfoot and, **733**
- Chromosome aneuploidy, Cornelia de Lange syndrome vs., **941**
- CI (Cervical insufficiency). *See* Cervical insufficiency.
- Cincinnati Children's Hospital experience, cloacal exstrophy/OEIS syndrome, **514**
- Cingulate gyrus, embryology and anatomy, **77–78**
- Circulatory requirements, lung development, **323**
- Circumvallate placenta, **812–813**
 - diagnostic checklist, **813**
 - differential diagnosis, **813**
 - gross pathologic and surgical features, **813**
 - intrauterine linear echoes vs., **1086–1087, 1088**
 - synechiae vs., **1075**
- Cisterna chyli, **272**
- Cisterna magna, **91**
- Clavicles, approach to skeletal dysplasias and, **681**
- Cleavage, **4, 7**
- Cleft clitoris, bladder exstrophy and, **510**
- Cleft lip/palate, **278–283**
 - amniotic band syndrome vs., **925**
 - associated abnormalities, **280**
 - atelosteogenesis and, **703**
 - bilateral, **279**
 - epignathus vs., **289**
 - epulis vs., **293**
 - diagnostic checklist, **280**
 - differential diagnosis, **280**
 - embryology, **263**
 - genetics, **280**
 - hypospadias and, **657**
 - isolated, Pierre Robin sequence vs., **987**
 - midline, **279**
 - or bilateral, trisomy 13 and, **903**
 - prognosis, **280**
 - Smith-Lemli-Opitz syndrome vs., **993**
 - thanatophoric dysplasia and, **728**
 - Treacher Collins syndrome (TCS) vs., **997**
 - 22q11 deletion syndrome and, **919**
- Cleft soft palate, achondrogenesis/hypochondrogenesis and, **690**
- Clefting, syndactyly and, **752**
- Clinodactyly, **744–745**
 - 5th finger, trisomy 21 and, **891**
 - diagnostic checklist, **745**
 - differential diagnosis, **745**
 - familial, **745**
 - genetics, **745**
 - prognosis, **745**
 - staging, grading, & classification, **745**
- Clitoris, **576**
- Clitoromegaly, **633**
 - disorders of sexual development and, **651**
 - hypospadias vs., **657**
- Cloaca, **572, 573**
 - embryology and anatomy, **478, 480**
- Cloacal anomalies, urachal anomalies and, **648**
- Cloacal dysgenesis. *See* Cloacal malformation/urogenital sinus.
- Cloacal exstrophy/OEIS syndrome, **512–515**
 - associated abnormalities, **514**
 - bladder exstrophy vs., **509**
 - body stalk anomaly vs., **505**
 - diagnostic checklist, **514**
 - differential diagnosis, **513**
 - differentiation, **514**
 - disorders of sexual development and, **651**
 - etiology, **513**
 - gastroschisis vs., **491**
 - genetics, **513–514**
 - omphalocele vs., **498**
 - prognosis, **514**
- Cloacal malformation/urogenital sinus, **532–535**
 - colonic atresia vs., **529**
 - cystic abdominal mass vs., **563, 567**
 - diagnostic checklist, **534**
 - differential diagnosis, **533**
 - female fetus, **581**
 - genetics, **534**
 - hydrocolpos vs., **663**
 - posterior urethral valves vs., **635**
 - prognosis, **534**
 - prune-belly syndrome vs., **639**
 - staging, grading, & classification, **534**
- Cloacal membrane, embryology and anatomy, **480**
- Closed spinal dysraphism, tethered cord and, **251**
- Clubfoot, **732–735**
 - associated abnormalities, **733**
 - atelosteogenesis and, **703**
 - Chiari 2 malformation and, **169**
 - diagnostic checklist, **733**
 - differential diagnosis, **733**
 - genetics, **733**
 - prognosis, **733**
 - rocker-bottom foot vs., **737**
 - spina bifida and, **237**
 - trisomy 13 and, **903**
 - trisomy 18 and, **897**
- CMV (Cytomegalovirus). *See* Cytomegalovirus.
- CoA. *See* Coarctation of aorta (CoA).
- COACH syndrome, coloboma and, **287**
- Coagulation disorders, intracranial hemorrhage and, **155**
- Coarctation, **375**
- Coarctation/interrupted aortic arch, **412–415**
 - aortic stenosis vs., **417**
 - associated abnormalities, **414**
 - diagnostic checklist, **414**
 - differential diagnosis, **413**
 - genetics, **413**
 - prognosis, **414**
 - staging, grading, & classification, **414**
- Coarctation of aorta (CoA), **412–415**
 - chamber asymmetry vs., **468, 470**
 - hypoplastic left heart vs., **409**
 - Turner syndrome and, **909**
- Cobblestone lissencephaly, **139**
- Coccyx
 - cartilaginous, **232**

INDEX

- unossified, **232**
- Coelomic cavity, **231**
- Coexistent mole, complete, placental lake vs., **807**
- COL1A1* gene mutations, osteogenesis imperfecta and, **719**
- COL1A2* gene mutations, osteogenesis imperfecta and, **719**
- COL4A1/A2* mutations, encephalomalacia/porencephaly and, **160**
- Collagen abnormalities, type I, achondroplasia vs., **695**
- Collagen vascular disease, maternal
 - chondrodysplasia punctata vs., **712**
 - warfarin embryopathy vs., **1011**
- Collecting system rupture, posterior urethral valves and, **635**
- Coloboma, **286–287, 309**
 - abnormal orbits/eyes vs., **304**
 - Aicardi syndrome and, **922**
 - diagnostic checklist, **287**
 - differential diagnosis, **287**
 - genetics, **287**
 - prognosis, **287**
- Colon
 - embryology and anatomy, **475**
 - normal, jejunal/ileal atresia vs., **525**
 - normal third-trimester, anal atresia vs., **531**
 - sigmoid colon mass effect, ureterocele vs., **643**
 - stool-filled, adnexal mass in pregnancy vs., **63**
- Colonic atresia, **528–529**
 - associated abnormalities, **529**
 - diagnostic checklist, **529**
 - differential diagnosis, **529**
 - prognosis, **529**
 - staging, grading, & classification, **529**
- Colonic haustra, embryology and anatomy, **483**
- Color Doppler, **375**
 - crossed fused ectopia, **599**
 - fetal genitourinary tract, **580**
 - horseshoe kidney and, **597**
 - neuroblastoma, **629**
 - pelvic kidney and, **595**
 - unilateral renal agenesis, **589**
- Colpocephaly, Aicardi syndrome and, **921**
- Combined first-& second-trimester screening, **884**
- Common arterial trunk. *See* Truncus arteriosus.
- Common AV valve, ventricular septal defect vs., **389**
- Compensatory hypertrophy
 - of contralateral kidney, **616**
 - renal, unilateral renal agenesis, **589**
 - unilateral renal agenesis with, **671**
 - unilateral enlarged kidney vs., **670**
- Complete heart block (CHB), **459**
- Complete hydatidiform mole, placental lake vs., **807**
- Complete situs inversus, heterotaxy/cardiosplenic syndromes and, **381**
- Complex adnexal mass, myoma in pregnancy vs., **1067**
- Complex "cysts," approach to imaging, **85**
- Complex hydrocele, scrotal mass vs., **676**
- Complex peritonitis, meconium peritonitis/pseudocyst and, **542**
- Compromised early embryonic blood flow, theory of, **506**
- Conception, retained products of. *See* Retained products of conception.
- Congenital adrenal hyperplasia (CAH), **632–633, 675**
 - differential diagnosis, **633**
 - disorders of sexual development and, **651**
 - prognosis, **633**
 - suprarenal mass vs., **674**
- Congenital cystic adenomatoid malformation. *See* Pulmonary airway malformation, congenital.
- Congenital diaphragmatic hernia, **332–335**
 - abnormal cardiac axis vs., **462, 463, 464**
 - cystic chest mass vs., **360**
 - diagnostic checklist, **334**
 - differential diagnosis, **333**
 - isolated, Cornelia de Lange syndrome vs., **941**
 - prognosis, **334**
 - solid/echogenic chest mass vs., **356, 358**
 - syndromes associated with, **334**
- Congenital duodenal obstruction. *See* Duodenal atresia.
- Congenital heart defects
 - diabetic embryopathy vs., **947**
 - hypospadias and, **657**
- Congenital heart disease
 - 22q11 deletion syndrome and, **919**
 - pulmonary agenesis vs., **349**
- Congenital hemidysplasia, ichthyosis, limb defects (CHILD syndrome), chondrodysplasia punctata vs., **711–712**
- Congenital hepatic hemangioma, **550–551**
 - diagnostic checklist, **551**
 - differential diagnosis, **551**
 - mesenchymal hamartoma vs., **553**
- Congenital high airway obstruction sequence (CHAOS), **346–347**
 - associated abnormalities, **347**
 - congenital pulmonary airway malformation vs., **337**
 - diagnostic checklist, **347**
 - differential diagnosis, **347**
 - genetics, **347**
 - prognosis, **347**
 - solid/echogenic chest mass vs., **357, 358**
- Congenital hydronephrosis. *See* Ureteropelvic junction obstruction.
- Congenital infection, mild ventriculomegaly vs., **213, 215**
- Congenital megaureter, ureterocele vs., **644**
- Congenital muscular dystrophies, cerebellar hypoplasia and, **187**
- Congenital obstructive uropathy. *See* Obstructive renal dysplasia.
- Congenital pulmonary airway malformation
 - abnormal cardiac axis vs., **462, 464**
 - congenital diaphragmatic hernia vs., **333**
 - heterotaxy/cardiosplenic syndromes and, **381**
 - microcystic, solid/echogenic chest mass vs., **356, 357**
 - polyhydramnios vs., **1045, 1047**
- Congenital rubella, chondrodysplasia punctata vs., **712**
- Congenital uterine anomalies, **571**
- Congenital vertical talus. *See* Rocker-bottom foot (RF).

INDEX

- Congenitally corrected transposition of great arteries (CTGA), **429, 430**. *See also* Transposition of great arteries (TGA).
- patients, **430**
 - postnatal circulation, **430**
- Conjoined twins, **840, 870–873**
- diagnostic checklist, **872**
 - differential diagnosis, **871**
 - fissure theory, **871**
 - fusion theory, **871**
 - minimally conjoined omphalopagus, **871**
 - monochorionic monoamniotic twins vs., **855**
 - parasitic, **871**
 - prognosis, **872**
 - staging, grading, & classification, **871**
 - thoracopagus, **871**
- Conotruncal heart defect, isolated, 22q11 deletion syndrome vs., **919**
- Conotruncal malformation, abnormal cardiac axis vs., **463, 465, 466**
- Conotruncus, embryology and anatomy, **364**
- Conradi-Hünermann syndrome (CDPX2), chondrodysplasia punctata vs., **711**
- Contralateral renal anomaly, **615**
- hydronephrosis and, **664**
- Conus medullaris, approach to fetal spine and, **234**
- Convexity sulci and gyri, embryology and anatomy, **81**
- Cord
- hemangioma, **836, 837**
 - hematoma, **835, 837**
 - hypercoiled, **835, 837**
 - knot, **835**
 - false, **835, 837**
 - true, **835**
 - thrombosis, **835, 837**
- Cornelia de Lange syndrome (CDLS), **317, 940–943**
- congenital diaphragmatic hernia associated with, **334**
 - diagnostic checklist, **941**
 - differential diagnosis, **941**
 - Fryns syndrome vs., **953**
 - genetics, **941**
 - micrognathia vs., **314**
 - prognosis, **941**
 - radial ray malformation vs., **742**
- Coronal suture, **271**
- Coronary sinus, embryology and anatomy, **371**
- Corpus albicans, **6**
- Corpus callosum
- abnormal, mild ventriculomegaly vs., **212, 214**
 - agenesis/dysgenesis of, **108–111**
 - ± interhemispheric cyst, schizencephaly vs., **135**
 - Aicardi syndrome vs., **921–922**
 - Apert syndrome and, **929**
 - associated abnormalities, **110**
 - conditions/syndromes associated with, **110**
 - diagnostic checklist, **110**
 - differential diagnosis, **110**
 - lobar holoprosencephaly vs., **125**
 - prognosis, **110**
 - semilobar holoprosencephaly vs., **123**
 - septo-optic dysplasia vs., **127**
 - warfarin embryopathy and, **1011**
 - destructive lesions, agenesis/dysgenesis of corpus callosum vs., **110**
 - dysgenesis, **108–111**
 - embryology and anatomy, **77–78**
- Corpus luteum, **6**
- Corpus luteum cyst
- adnexal mass in pregnancy vs., **62**
 - ovarian ectopic pregnancy vs., **53**
- Cortex, **570**
- adrenal, **578**
 - renal, **578**
- Cortical cysts, obstructive renal dysplasia and, **611**
- Cortical dysplasia
- cytomegalovirus and, **1017**
 - tuberous sclerosis vs., **1001**
- Cortical heterotopias, Aicardi syndrome and, **921**
- Cortical tubers, tuberous sclerosis with, **1001–1002**
- Cortical white matter lesions, tuberous sclerosis and, **1001–1002**
- Cortical/subcortical tubers, rhabdomyoma and, **445**
- Corticomedullary differentiation, **579**
- Coumadin therapy, intracranial hemorrhage and, **155**
- Cranioectodermal dysplasia, short rib-polydactyly syndrome vs., **724**
- Craniofacial and vertebral anomalies, pentalogy of Cantrell, **503**
- Craniofacial defects, body stalk anomaly and, **505**
- Craniopagus twins, **871**
- Craniopharyngioma, brain tumors and, **203**
- Craniorachischisis, **101**
- Cranioschisis, **101**
- Craniosynostosis, **85, 681**
- with brachyturriccephaly, Apert syndrome and, **929**
 - calvarium, abnormal vs., **216, 218**
 - hypophosphatasia and, **715**
 - syndactyly and, **752**
- CRASH, aqueductal stenosis and, **166**
- Crossed fused ectopia, **598–599, 672**
- associated abnormalities, **599**
 - diagnostic checklist, **599**
 - differential diagnosis, **599**
 - horseshoe kidney vs., **597**
 - mesoblastic nephroma vs., **623**
 - prognosis, **599**
 - renal ascent and, **570**
 - unilateral enlarged kidney vs., **670**
 - unilateral renal agenesis vs., **589**
- Cross-fused ectopic kidney. *See* Crossed fused ectopia.
- Crouzon syndrome
- Apert syndrome vs., **929**
 - Carpenter syndrome vs., **937**
 - Pfeiffer syndrome vs., **983**
- Cryptophthalmos-syndactyly syndrome, syndactyly vs., **751**
- Cryptorchidism, **571**
- Apert syndrome and, **929**
 - disorders of sexual development and, **651**
 - hypospadias and, **657**
 - prune-belly syndrome and, **639**
 - Smith-Lemli-Opitz syndrome vs., **993**
 - urachal anomalies and, **648**

INDEX

- Currarino syndrome, caudal regression sequence and, **246**
Current procedural terminology (CPT), **374**
Cushion defect, endocardial. *See* Atrioventricular septal defect.
Cutaneous lymphangioma. *See* Lymphangioma.
Cyclopia
- alobar holoprosencephaly associated with, **120**
- echogenic kidneys and, **668**
- trisomy 13 and, **903**
CYP21A2 gene, **633**
Cystadenoma, adnexal mass in pregnancy vs., **63**
Cystic abdominal mass, **562–567**
- differential diagnosis, **562**
Cystic biliary atresia, choledochal cyst vs., **549**
Cystic chest mass, **360–361**
- differential diagnosis, **360**
Cystic dysplasia, obstructive, **669**
- echogenic kidneys vs., **668**
- multicystic dysplastic kidney vs., **615**
Cystic fibrosis, **944–945**
- diagnostic checklist, **945**
- differential diagnosis, **945**
- echogenic bowel vs., **558, 559**
- genetic counseling, **542**
- genetics, **945**
- meconium peritonitis/pseudocyst and, **542**
- prognosis, **945**
Cystic hygroma, **298–301**
- associated abnormalities, **300**
- cervical teratoma vs., **303**
- coarctation/interrupted aortic arch and, **413**
- diagnostic checklist, **300**
- differential diagnosis, **299–300**
- embryology, **263, 273**
- genetics, **300**
- nuchal, lymphangioma vs., **351**
- occipital/parietal cephalocele vs., **101**
- polyhydramnios vs., **1044**
- prognosis, **300**
- trisomy 18 and, **897**
- trisomy 21 vs., **892**
- Turner syndrome and, **909**
- twin reversed arterial perfusion vs., **867**
Cystic kidneys
- multicystic dysplastic kidney and, **615**
- urachal anomalies vs., **647**
Cystic lymphangioma (CL). *See* Lymphangioma.
Cystic masses, **485**
- abnormal orbits/eyes vs., **304**
- congenital pulmonary airway malformation vs., **337**
Cystic pelvic mass, posterior to bladder, cloacal malformation/urogenital sinus and, **533**
Cystic renal dysplasia. *See also* Obstructive renal dysplasia.
- autosomal recessive polycystic kidney disease vs., **619**
Cystic teratoma, ovarian cyst vs., **659**
Cystic Wharton jelly, **835, 836**
Cysts
- abdominal, urachal anomalies vs., **647**
- allantoic, omphalocele vs., **497**
- bronchogenic. *See* Bronchogenic cyst.
- of cavum velum interpositum, arachnoid cyst vs., **152**
- choledochal, **548–549**
 ovarian cyst vs., **659**
- dermoid, epignathus vs., **289**
- enteric duplication
 ovarian cyst vs., **659**
 urachal anomalies vs., **647**
- gastric duplication, **675**
 suprarenal mass vs., **674**
- intraabdominal, ovarian cyst vs., **659**
- meconium peritonitis/pseudocyst, **540–543**
- mesenteric
 ovarian cyst vs., **659**
 urachal anomalies vs., **647**
- neurenteric, cystic chest mass vs., **360, 361**
- omphalomesenteric duct, omphalocele vs., **497**
- ovarian, **658–661**
 diagnostic checklist, **660**
 differential diagnosis, **659**
 hydrocolpos vs., **663**
 prognosis, **660**
 urachal anomalies vs., **647**
- umbilical cord, omphalocele vs., **497**
- urachal, ovarian cyst vs., **659**
- Wharton jelly, omphalocele vs., **497**
Cytomegalovirus (CMV), **1016–1019**
- diagnostic checklist, **1018**
- differential diagnosis, **1017**
- echogenic bowel vs., **558**
- infection
 congenital, pachygyria/polymicrogyria vs., **145**
 gray matter heterotopia vs., **143**
- parvovirus vs., **1021**
- pericardial effusion and, **449**
- prognosis, **1018**
- toxoplasmosis vs., **1023**
- varicella vs., **1025**
Cytotrophoblast, **7, 786**
- ## D
- DA. *See* Duodenal atresia.
Dacryocystocele, **284–285, 308**
- abnormal orbits/eyes vs., **304**
- associated abnormalities, **285**
- diagnostic checklist, **285**
- differential diagnosis, **285**
- genetics, **285**
- prognosis, **285**
Dandy-Walker complex. *See* Dandy-Walker malformation (DWM).
Dandy-Walker continuum, warfarin embryopathy and, **1011**
Dandy-Walker malformation (DWM), **174–177**
- agenesis of corpus callosum associated with, **110**
- Aicardi syndrome vs., **922**
- arachnoid cyst vs., **151**
- associated abnormalities, **176**
- Blake pouch cyst vs., **181**
- cerebellar hypoplasia vs., **187**
- diagnostic checklist, **176**

INDEX

- genetics, **176**
- Joubert syndrome vs., **963**
- mega cisterna magna vs., **185**
- posterior fossa cyst/fluid collection vs., **222, 223**
- prognosis, **176**
- rhombencephalosynapsis vs., **191**
- trisomy 13 and, **903**
- trisomy 18 and, **897**
- Dandy-Walker spectrum. *See* Dandy-Walker malformation (DWM).
- Dandy-Walker variant. *See* Vermian dysgenesis.
- DCM. *See* Dilated cardiomyopathy (DCM).
- De novo mutations, osteogenesis imperfecta and, **719**
- Decidua basalis, **786**
- Decidual lining, **7**
- Deep anastomosis, twin-twin transfusion syndrome and, **863**
- Deficient ear, abnormal ears vs., **311**
- Delayed childbearing, triplets and, **875**
- Delayed motor skills, Turner syndrome and, **910**
- Delayed walking, hypophosphatasia and, **715**
- Deletion 10q, Smith-Lemli-Opitz syndrome vs., **993**
- Dentinogenesis imperfecta, osteogenesis imperfecta and, **719**
- Depressed nasal bridge, midface hypoplasia with, atelosteogenesis and, **703**
- Dermatoglyphic abnormalities, syndactyly and, **752**
- Dermoid, dacryocystocele vs., **285**
- Dermoid cyst
 - epignathus vs., **289**
 - frontal cephalocele vs., **107**
- Dermopathy, restrictive, arthrogryposis/akinesia sequence vs., **760**
- Descending aorta, embryology and anatomy, **368, 369, 371, 372, 373**
- Descending colon, embryology and anatomy, **475, 479, 481**
- Descending thoracic aorta, **328**
- Developing liver, embryology and anatomy, **481**
- Developing urorectal septum, embryology and anatomy, **480**
- Developmental delay, truncus arteriosus and, **434**
- Dextrocardia, heterotaxy/cardiosplenic syndromes vs., **381**
- Dextrotransposition. *See* Transposition of great arteries (TGA).
- Diabetes, maternal
 - chondrodysplasia punctata vs., **712**
 - macrosomia associated with, Beckwith-Wiedemann syndrome vs., **933**
- Diabetic embryopathy, **316, 946–949**
 - angulated bones and, **774, 777**
 - differential diagnosis, **947**
 - micrognathia vs., **314**
 - polydactyly vs., **747**
 - prognosis, **948**
 - radial ray malformation vs., **741**
 - split hand/foot malformation vs., **756**
 - staging, grading, & classification, **948**
 - syndactyly vs., **752**
 - VACTERL association vs., **1006**
- Diamniotic twins
 - absent intertwin membrane, monochorionic monoamniotic twins vs., **855**
 - dichorionic, **846–849**
 - diagnostic checklist, **848**
 - differential diagnosis, **847**
 - intrauterine linear echoes vs., **1086, 1087**
 - monochorionic diamniotic twins vs., **851**
 - prognosis, **848**
 - monochorionic, **850–853**
 - diagnostic checklist, **852**
 - dichorionic diamniotic twins vs., **847**
 - differential diagnosis, **851**
 - embryology, **852**
 - genetics, **852**
 - intrauterine linear echoes vs., **1086, 1087, 1088**
 - prognosis, **852**
- Diamond-Blackfan anemia, radial ray malformation vs., **742**
- Diaphragm, **328, 329, 579**
 - approach to abdominal wall and gastrointestinal tract, **484**
 - development, **323**
 - embryology and anatomy, **478, 481, 483**
- Diaphragmatic hernia
 - congenital, **332–335**
 - congenital pulmonary airway malformation vs., **337**
 - diagnostic checklist, **334**
 - differential diagnosis, **333**
 - esophageal atresia vs., **517**
 - omphalocele and, **498**
 - prognosis, **334**
 - pulmonary agenesis vs., **349**
 - solid/echogenic chest mass vs., **356, 358**
 - syndromes associated with, **334**
 - volvulus and, **537**
 - isolated, Fryns syndrome vs., **953**
 - isolated congenital, Cornelia de Lange syndrome vs., **941**
 - trisomy 18 and, **897**
- Diastematomyelia, **252–253**
 - associated abnormalities, **253**
 - diagnostic checklist, **253**
 - differential diagnosis, **253**
 - prognosis, **253**
 - staging, grading, & classification, **253**
- Diastrophic dysplasia
 - atelosteogenesis vs., **703**
 - micromelia vs., **700**
 - Pierre Robin sequence vs., **987**
- Diastrophic dysplasia sulfate transporter gene [*SLC26A2* (DTDST)], achondrogenesis/hypochondrogenesis and, **688, 690**
- Dichorionic diamniotic twins, **846–849**
 - diagnostic checklist, **848**
 - differential diagnosis, **847**
 - intrauterine linear echoes vs., **1086, 1087**
 - monochorionic diamniotic twins vs., **851**
 - prognosis, **848**
- Dichorionic twinning, **840**
 - impact of chorionicity, **842**

INDEX

- sonographic monitoring, **842**
- Didelphys, uterus, **1071–1072**
- Diffuse brain insult, encephalomalacia/porencephaly and, **160**
- Diffusion imaging, supratentorial brain, **84**
- DiGeorge syndrome. *See* 22q11 deletion syndrome.
- Dilated calyces, ureteropelvic junction obstruction and, **605**
- Dilated cardiomyopathy (DCM), **440–443**
- Dilated coronary sinus, embryology and anatomy, **371**
- Diplomyelia, diastematomyelia vs., **253**
- Discordant growth
 - monochromatic diamniotic twins vs., **851**
 - triplets and, **875**
- Discordant twin growth, **858–861**
 - differential diagnosis, **859**
 - genetic counseling, **860**
 - impact, **860**
 - prognosis, **860**
 - twin-twin transfusion syndrome and, **863**
- Disomy 14 (paternal), uniparental, short rib-polydactyly syndrome vs., **724**
- Disorders of sexual development (DSD), **650–655**
 - associations, **651**
 - diagnostic checklist, **652**
 - genetics, **651**
 - prognosis, **652**
 - staging, grading, & classification, **652**
 - terminology update, **652**
- Distal arthrogryposis
 - arthrogryposis/akinesia sequence vs., **759**
 - type 1A, arthrogryposis/akinesia sequence vs., **759**
- Distal atresias, duodenal atresia vs., **521**
- Distal vitelline veins, embryology and anatomy, **481**
- Distended lymphatic sacs, **273**
- Diverticulum
 - bladder "hutch," ureterocele vs., **643–644**
 - metanephric, **570**
- DK-phocomelia, amelia vs., **699**
- DNA index, neuroblastoma, **630**
- Dolichocephaly, calvarium, abnormal vs., **216**
- Donnai-Barrow syndrome, congenital diaphragmatic hernia associated with, **334**
- Doppler ultrasound
 - approach to abdominal wall and gastrointestinal tract, **484**
 - approach to fetal well-being, **1028**
 - posterior fossa, **90**
 - supratentorial brain, **84**
- Dorsal dermal sinus, **228**
- Dorsal mesentery, **231, 476, 477**
 - of midgut, embryology and anatomy, **478**
- Dorsal mesogastrium, embryology and anatomy, **478**
- Dorsal neck cystic hygroma, **273**
- Dorsal pancreas, embryology and anatomy, **477, 478**
- DORV. *See* Double outlet right ventricle (DORV).
- Double bubble, duodenal atresia and, **521**
- Double decidual sac sign (DDSS), **9, 784**
- Double inlet left ventricle, tricuspid atresia vs., **403**
- Double outlet right ventricle (DORV), **436–437**
 - atrioventricular septal defect and, **391**
 - diagnostic checklist, **437**
 - differential diagnosis, **437**
 - prognosis, **437**
 - tetralogy of Fallot vs., **425**
 - transposition of great arteries vs., **429**
 - truncus arteriosus vs., **433**
 - ventricular septal defect vs., **389**
- Down syndrome. *See* Trisomy 21.
- DSD. *See* Disorders of sexual development (DSD).
- D-transposition. *See* Transposition of great arteries (TGA).
- D-transposition of great arteries, double-outlet right ventricle vs., **437**
- Duane-radial ray syndrome, radial ray malformation vs., **742**
- Ductus arteriosus, **374**
 - embryology and anatomy, **369, 372**
 - reversed flow, chamber asymmetry and, **468**
- Ductus venosus, **884, 886**
 - embryology and anatomy, **366, 372, 475, 481**
 - flow, abnormal, trisomy 21 and, **891**
- Duodenal atresia, **520–523**
 - associated abnormalities, **522**
 - diagnostic checklist, **522**
 - differential diagnosis, **521–522**
 - esophagus atresia and, **517**
 - etiology, **522**
 - genetics, **522**
 - jejunal/ileal atresia vs., **525**
 - prognosis, **522**
 - staging, grading, & classification, **522**
 - volvulus vs., **537**
- Duodenojejunal flexure, embryology and anatomy, **479**
- Duodenum, embryology and anatomy, **475, 477, 479, 481**
- Duplicate spinal cord, diastematomyelia vs., **253**
- Duplicated collecting system, **590–593, 671**
 - associated abnormalities, **592**
 - diagnostic checklist, **592**
 - differential diagnosis, **591–592**
 - genetics, **592**
 - mesoblastic nephroma vs., **623**
 - neuroblastoma vs., **629**
 - with obstruction, **666**
 - hydronephrosis vs., **664**
 - prognosis, **592**
 - unilateral enlarged kidney vs., **670**
- Duplication, renal, Weigert-Meyer rule in, **643**
- Duplication anomaly, uterine septum, synechiae vs., **1075**
- Duplication cyst, enteric, cloacal malformation/urogenital sinus vs., **533**
- Dural sinus malformation, **200–201**
 - diagnostic checklist, **201**
 - differential diagnosis, **201**
 - posterior fossa cyst/fluid collection vs., **222, 225**
 - prognosis, **201**
 - vein of Galen aneurysmal malformation vs., **195**
- Dutch series, cloacal exstrophy/OEIS syndrome, **514**
- Dysgenesis, of corpus callosum, Chiari 3 malformation and, **173**
- Dysjunction, **228**
- Dysmorphic facies, truncus arteriosus and, **434**

INDEX

Dysplasia

- acampomelic campomelic, campomelic dysplasia vs., **707**
 - binder maxillofacial, chondrodysplasia punctata vs., **712**
 - "boomerang," atelosteogenesis vs., **703**
 - campomelic, **706–709**
 - angulated bones and, **774, 777**
 - associated abnormalities, **707**
 - diagnostic checklist, **707**
 - differential diagnosis, **707**
 - genetics, **707**
 - osteogenesis imperfecta vs., **719**
 - prognosis, **707**
 - thanatophoric dysplasia vs., **727**
 - chondroectodermal, polydactyly vs., **747**
 - cortical, cytomegalovirus and, **1017**
 - cranioectodermal, short rib-polydactyly syndrome vs., **724**
 - diastrophic
 - atelosteogenesis vs., **703**
 - micromelia vs., **700**
 - dyssegmental, micromelia vs., **700**
 - Greenberg, chondrodysplasia punctata vs., **712**
 - kyphomelic
 - angulated bones and, **774–775, 779**
 - campomelic dysplasia vs., **707**
 - proximal focal femoral, **764–767**
 - associated abnormalities, **766**
 - diagnostic checklist, **766**
 - differential diagnosis, **765**
 - fibular/tibial hemimelia vs., **769**
 - genetics, **766**
 - prognosis, **766**
 - staging, grading, & classification, **766**
 - spondyloepiphyseal, achondroplasia vs., **696**
 - thanatophoric, **726–731**
 - achondrogenesis/hypochondrogenesis vs., **689**
 - achondroplasia vs., **695**
 - angulated bones and, **774, 775, 776**
 - associated abnormalities, **728**
 - diagnostic checklist, **728**
 - differential diagnosis, **727–728**
 - genetics, **728**
 - osteogenesis imperfecta vs., **719**
 - prognosis, **728**
 - tricuspid, **400–401**
 - coaptation point of, **397**
 - diagnostic checklist, **401**
 - differential diagnosis, **401**
 - Ebstein anomaly vs., **397**
 - prognosis, **401**
 - septal and posterior of, **397**
- Dysplastic kidney, multicystic
- oligohydramnios vs., **1048, 1050**
 - ovarian cyst vs., **659**
- Dyssegmental dysplasia, micromelia vs., **700**

E

- EA. *See* Esophageal atresia.
- Eagle-Barrett syndrome. *See* Prune-belly syndrome.
- Ear helix, top and bottom of, **268**
- Early obstruction theory, multicystic dysplastic kidney and, **616**
- Ears
- abnormal, **310–313**
 - differential diagnosis, **310**
 - anomalies, embryology, **263**
 - embryology and anatomy, **262, 265**
 - imaging techniques, **274**
- Ebstein anomaly, **396–399**
- chamber asymmetry and, **469, 471**
 - diagnostic checklist, **397**
 - differential diagnosis, **397**
 - prognosis, **397**
 - tricuspid dysplasia vs., **401**
- ECF. *See* Echogenic cardiac focus (ECF).
- Echocardiogram, hypoplastic left heart and, **409**
- Echogenic bowel, **486, 558–559**
- cystic fibrosis vs., **945**
 - differential diagnosis, **558**
 - toxoplasmosis vs., **1023**
 - trisomy 21 and, **891**
- Echogenic cardiac focus (ECF), **438–439**
- diagnostic checklist, **439**
 - differential diagnosis, **439**
 - genetics, **439**
 - idiopathic infantile arterial calcification vs., **961**
 - prognosis, **439**
 - rhabdomyoma vs., **445**
- Echogenic chest mass, **356–359**
- differential diagnosis, **356**
- Echogenic intracardiac focus (EIF). *See* Echogenic cardiac focus (ECF).
- Echogenic intraventricular mass, intracranial hemorrhage vs., **155**
- Echogenic kidneys, **668–669**
- differential diagnosis, **668**
 - trisomy 13 and, **903**
- Echogenicity of renal parenchyma, increased, obstructive renal dysplasia and, **611**
- Ectoderm, **228**
- cutaneous, **230**
- Ectodermal dysplasia, syndactyly and, **752**
- Ectodermal failure in early embryonic disc, theory of, **505–506**
- Ectopia, crossed fused, **598–599, 672**
- associated abnormalities, **599**
 - diagnostic checklist, **599**
 - differential diagnosis, **599**
 - horseshoe kidney vs., **597**
 - mesoblastic nephroma vs., **623**
 - prognosis, **599**
 - renal ascent and, **570**
 - unilateral enlarged kidney vs., **670**
 - unilateral renal agenesis vs., **589**

INDEX

- Ectopia cordis, **384–387**
- abnormal cardiac axis vs., **463, 467**
 - amniotic band syndrome and, **925**
 - associated abnormalities, **386**
 - diagnostic checklist, **386**
 - differential diagnosis, **385**
 - genetics, **385**
 - isolated, pentalogy of Cantrell vs., **503**
 - prognosis, **386**
 - staging, grading, & classification, **386**
- Ectopic beat, irregular rhythm and, **453**
- Ectopic kidney. *See* Crossed fused ectopia.
- Ectopic pregnancy (EP)
- abdominal, **50–51**
 - diagnostic checklist, **51**
 - differential diagnosis, **51**
 - prognosis, **51**
 - adnexal mass in pregnancy vs., **63**
 - cervical, **44–47**
 - cesarean scar ectopic pregnancy vs., **49**
 - diagnostic checklist, **46**
 - differential diagnosis, **45**
 - prognosis, **46**
 - cesarean scar, **48–49**
 - cervical ectopic pregnancy vs., **45**
 - diagnostic checklist, **49**
 - differential diagnosis, **49**
 - prognosis, **49**
 - interstitial, **40–43**
 - diagnostic checklist, **42**
 - differential diagnosis, **41–42**
 - Müllerian duct anomalies vs., **1071**
 - prognosis, **42**
 - tubal ectopic pregnancy vs., **35**
 - intrauterine sac-like structure associated with, abnormal gestational sac and contents vs., **56**
 - ovarian, **52–53**
 - associated abnormalities, **53**
 - diagnostic checklist, **53**
 - differential diagnosis, **53**
 - prognosis, **53**
 - staging, grading, & classification, **53**
 - tubal ectopic pregnancy vs., **35**
 - previous, ovarian ectopic pregnancy, **53**
 - pseudogestational sac, perigestational hemorrhage vs., **25**
 - tubal, **34–39**
 - abdominal ectopic pregnancy vs, **51**
 - diagnostic checklist, **36**
 - differential diagnosis, **35**
 - heterotopic pregnancy vs., **55**
 - ovarian ectopic pregnancy vs., **53**
 - prognosis, **36**
- Ectopic ureterocele, **644**
- Ectrodactyly. *See also* Split hand/foot malformation (SHFM).
- clubfoot vs., **733**
 - rocker-bottom foot vs., **737**
 - sandal gap foot vs., **739**
- Ectrodactyly-ectodermal dysplasia clefting syndrome (EEC), split hand/foot malformation and, **755**
- Edwards syndrome, trisomy 18, **896–901**
- EFW (Estimated fetal weight). *See* Estimated fetal weight.
- Ehlers-Danlos syndrome, amniotic band syndrome and, **925**
- Ellis-van Creveld syndrome
- polydactyly vs., **747**
 - short rib-polydactyly syndrome vs., **723–724**
- Embryo, **231**
- abnormal, abnormal gestational sac and contents vs., **57**
- Embryoblast, **7**
- Embryonic disc, embryology and anatomy, **366**
- Embryopathy. *See also* Varicella.
- alcohol, chondrodysplasia punctata vs., **712**
 - chondrodysplasia punctata vs., **712**
 - diabetic
 - angulated bones and, **774, 777**
 - polydactyly vs., **747**
 - radial ray malformation vs., **741**
 - split hand/foot malformation vs., **756**
 - syndactyly vs., **752**
 - hydantoin, chondrodysplasia punctata vs., **712**
 - from other anticonvulsants, valproate embryopathy vs., **1009**
 - pseudo-warfarin, warfarin embryopathy vs., **1011**
 - thalidomide, amelia vs., **699**
 - valproate, **1008–1009**
 - differential diagnosis, **1009**
 - genetics, **1009**
 - prognosis, **1009**
 - warfarin, **1010–1011**
 - chondrodysplasia punctata vs., **712**
 - differential diagnosis, **1011**
 - prognosis, **1011**
- Encephalocele
- achondrogenesis/hypochondrogenesis and, **690**
 - calvarium, abnormal vs., **216, 219**
 - exencephaly/anencephaly vs., **97**
 - frontal, cleft lip, palate vs., **280**
 - nasal, dacryocystocele vs., **285**
- Encephalomalacia, **86, 158–161**
- aqueductal stenosis vs., **166**
 - diagnostic checklist, **160**
 - differential diagnosis, **159**
 - mild ventriculomegaly vs., **213, 215**
 - prognosis, **160**
- Endocardial cushion defect. *See* Atrioventricular septal defect.
- Endoderm, **228**
- Endodermal-derived epithelium, **325**
- Endometrioma, adnexal mass in pregnancy vs., **62**
- Endometriosis
- ovarian ectopic pregnancy, **53**
 - scar, uterine rupture vs., **1077**
- Endometritis, uterine rupture vs., **1077**
- Endoscopic 3rd ventriculostomy, aqueductal stenosis and, **166**
- Enlarged cavum septi pellucidi, arachnoid cyst vs., **152**
- Enlarged kidney, unilateral, **670–673**
- differential diagnosis, **670–671**
- Enteric duplication cyst, **538–539**
- choledochal cyst vs., **549**

INDEX

- cloacal malformation/urogenital sinus vs., **533**
- cystic abdominal mass vs., **562, 565**
- diagnostic checklist, **539**
- differential diagnosis, **539**
- meconium peritonitis/pseudocyst vs., **541–542**
- mesenteric lymphangioma vs., **545**
- ovarian cyst vs., **659**
- umbilical vein varix vs., **827**
- urachal anomalies vs., **647**
- urinoma vs., **609**
- Enterolithiasis, cloacal malformation/urogenital sinus and, **533**
- Enteroliths, meconium peritonitis/pseudocyst vs., **541**
- EP. *See* Ectopic pregnancy (EP).
- Ependymal cyst. *See* Interhemispheric cyst/AVID.
- Ependymoma/ependyoblastoma, brain tumors and, **203**
- Epiblast, **7**
- Epidermolysis bullosa, amniotic band syndrome and, **925**
- Epignathus, **288–291, 319**
 - associated abnormalities, **290**
 - cleft lip, palate vs., **280**
 - diagnostic checklist, **290**
 - differential diagnosis, **289**
 - epulis vs., **293**
 - genetics, **290**
 - macroglossia vs., **318**
 - prognosis, **290**
 - staging, grading, & classification, **290**
- Epiphyses, calcific stippling, other conditions associated with, chondrodysplasia punctata vs., **712**
- Epispadias
 - bladder exstrophy and, **510**
 - disorders of sexual development and, **651**
- Epithelial ovarian carcinoma, adnexal mass in pregnancy vs., **63**
- Epulis, **292–293**
 - diagnostic checklist, **293**
 - differential diagnosis, **293**
 - epignathus vs., **289**
 - macroglossia vs., **318**
 - prognosis, **293**
- Escobar variant multiple pterygium syndrome, multiple pterygium syndromes vs., **975**
- Esophageal atresia (EA), **516–519**
 - associated anomaly, **518**
 - diagnostic checklist, **518**
 - differential diagnosis, **517**
 - duodenal atresia and, **521**
 - embryology, **517–518**
 - etiology, **517–518**
 - genetics, **518**
 - prognosis, **518**
 - staging, grading, & classification, **518**
 - trisomy 18 and, **897**
- Esophageal duplication cyst
 - bronchogenic cyst vs., **345**
 - congenital pulmonary airway malformation vs., **337**
- Esophagus
 - approach to abdominal wall and gastrointestinal tract, **484**
 - embryology and anatomy, **478**
 - primitive, **324**
- Estimated fetal weight, **1028**
- Ethmocephaly, alobar holoprosencephaly associated with, **120**
- Ethnic variation, proximal focal femoral dysplasia and, **765**
- Exencephaly, **96–99**. *See also* Anencephaly.
 - associated abnormalities, **98**
 - calvarium, abnormal vs., **216, 219**
 - diagnostic checklist, **98**
 - differential diagnosis, **97**
 - occipital/parietal cephalocele vs., **101**
 - prognosis, **98**
- Exstrophy
 - bladder, **508–511**
 - associated abnormalities, **510**
 - cloacal exstrophy/OEIS syndrome vs., **513**
 - diagnostic checklist, **510**
 - differential diagnosis, **509**
 - differentiation, **514**
 - disorders of sexual development and, **651**
 - etiology, **509**
 - genetics, **509**
 - hypospadias vs., **657**
 - prognosis, **510**
 - urachal anomalies and, **648**
 - cloacal, **512–515**
 - associated abnormalities, **514**
 - bladder exstrophy vs., **509**
 - body stalk anomaly vs., **505**
 - diagnostic checklist, **514**
 - differential diagnosis, **513**
 - differentiation, **514**
 - disorders of sexual development and, **651**
 - etiology, **513**
 - gastroschisis vs., **491**
 - genetics, **513–514**
 - omphalocele vs., **498**
 - prognosis, **514**
- Exstrophy epispadias complex (EEC), **513**
 - bladder exstrophy, **509**
- External oblique muscle, **577**
- Extrachorial placental. *See* Circumvallate placenta.
- Extracorporeal bowel dilation, gastroschisis and, **491**
- Extraembryonic coelom, **476, 477**
- Extralobar bronchopulmonary sequestration, adrenal hemorrhage vs., **627**
- Extralobar sequestration, neuroblastoma vs., **629**
- Extrarenal anomalies, hydronephrosis and, **664**
- Extremities, osteogenesis imperfecta and, **719**
- Eye abnormalities. *See* PHACES syndrome.
- Eyelids, **265**
- Eyes, **264, 265, 579**
 - abnormal, **304–309**
 - differential diagnosis, **304**
 - anomalies, embryology, **263**
 - embryology and anatomy, **262–263, 266–267**
 - imaging techniques, **274**
 - ocular and orbit diameters, **275**

INDEX

F

Face and neck

- abnormal ears, **310–313**
 - abnormal orbits/eyes, **304–309**
 - achondroplasia and, **695**
 - approach to fetal face and neck, **274–277**
 - anomalies, **274**
 - imaging techniques, **274**
 - mandible measurements, **275**
 - normal anatomy, **274**
 - ocular and orbit diameters, **275**
 - thyroid circumference, **275**
 - cervical teratoma, **302–303**
 - cleft lip/palate, **278–283**
 - coloboma, **286–287**
 - cystic hygroma, **298–301**
 - dacryocystocele, **284–285**
 - embryology and anatomy, **262–273**
 - common anomalies, **263**
 - cystic hygroma, **263, 273**
 - ears, **262, 265**
 - eyes, **262–263, 266–267**
 - face and ear, **265**
 - face and palate, **264**
 - general concepts, **262**
 - lips and palate, **262, 269**
 - lymphatics, **262, 263, 272**
 - nose, **262, 268**
 - palate, **262, 264, 268, 269**
 - skull and facial bones, **270**
 - skull and sutures, **271**
 - epignathus, **288–291**
 - epulis, **292–293**
 - goiter, **294–297**
 - iniencephaly and, **243**
 - macroglossia, **318–319**
 - micrognathia, **314–317**
- ### Facial bones, embryology and anatomy, **270**
- ### Facial clefts, amniotic band syndrome and, **925**
- ### Facial mass, cleft lip, palate vs., **280**
- ### Facio-genital dysplasia, Noonan syndrome vs., **979**
- ### Factor V deficiency, intracranial hemorrhage and, **155**
- ### Factor X deficiency, intracranial hemorrhage and, **155**
- ### Failed pregnancy in first trimester, **20–23**
- abnormal gestational sac and contents vs., **56**
 - chorionic bump vs., **29**
 - diagnostic checklist, **22**
 - differential diagnosis, **21**
 - ultrasound in, **22**
- ### Falci-form ligament, embryology and anatomy, **478, 479**
- ### Fallopian tube, **576**
- ### Falx, approach to imaging, **85**
- ### Falx cerebelli, approach to imaging, **91**
- ### Familial 2-3 toe syndactyly, **751**
- ### Familial clinodactyly, **745**
- ### Fanconi anemia
- Holt-Oram syndrome vs., **957**
 - radial ray malformation vs., **741**

Fasciculata, **570**

FCMD (Fukuyama congenital muscular dystrophy). *See* Fukuyama congenital muscular dystrophy.

Feet, approach to skeletal dysplasias and, **681**

Feingold syndrome

INDEX

- and chorioangioma, **817**
 - diagnostic checklist, **1036**
 - differential diagnosis, **1035**
 - Doppler findings, **1036**
 - duodenal atresia and, **521**
 - early onset, proximal focal femoral dysplasia vs., **765**
 - echogenic bowel vs., **558, 559**
 - esophageal atresia and, **517**
 - genetics, **1035**
 - hypospadias and, **657**
 - infection with, triploidy vs., **913**
 - jejunal/ileal atresia and, **525**
 - marginal/velamentous cord insertion associated, **815**
 - mildly short femur/humerus and, **770–771, 773**
 - oligohydramnios and, **1048, 1050**
 - placental lakes associated, **808**
 - prognosis, **1036**
 - severe, bilateral renal agenesis vs., **601**
 - trisomy 13 and, **903**
- Fetal heart, approach to, **374–379**
- clinical implications, **376**
 - images, **376–379**
 - imaging techniques and normal anatomy, **374**
- Fetal hemorrhage, fetal anemia vs., **1041**
- Fetal hydronephrosis. *See* Urinary tract dilation.
- Fetal hypotension, encephalomalacia/porencephaly and, **159**
- Fetal lobulation, **575**
- Fetal masses, hydrops vs., **1053**
- Fetal MR, face and neck anomalies, **274**
- Fetal position, determination, **374**
- Fetal profile, approach to skeletal dysplasias and, **681**
- Fetal renal disease, cardiomyopathy and, **442**
- Fetal renal hamartoma. *See* Mesoblastic nephroma.
- Fetal sex, assessment of, **580**
- Fetal spine, **232–233**
- approach to, **234–235**
 - embryology and anatomy, **369**
- Fetal tachyarrhythmia, tachyarrhythmia vs., **455**
- Fetal trauma, angulated bones and, **775, 779**
- Fetal valproate syndrome, radial ray malformation vs., **741**
- Fetal varicella syndrome. *See* Varicella.
- Fetal warfarin (Coumadin) syndrome. *See* Warfarin embryopathy.
- Fetal well-being, approach to, **1028–1033**
- AFI vs. gestational age, **1029**
 - amniotic fluid, **1028**
 - biophysical profile, **1028, 1029**
 - Doppler assessment, **1028**
 - fetal growth, **1028**
 - umbilical artery S/D ratio percentile, **1029**
- Fetomaternal alloimmune thrombocytopenia, encephalomalacia/porencephaly and, **160**
- Fetoplacental circulation, embryology and anatomy, **366**
- a-fetoprotein, elevate, placental lakes associated, **808**
- Fetus
- abnormal, abnormal gestational sac and contents vs., **57**
 - constitutionally small, fetal growth restriction vs., **1035**
 - freely mobile, **485**
 - truncus arteriosus and, **434**
- Fetus-in-fetu, **878–881**
- cystic abdominal mass vs., **563, 567**
 - diagnostic checklist, **879**
 - differential diagnosis, **879**
 - prognosis, **879**
- FGFR-related craniosynostosis spectrum, Pfeiffer syndrome vs., **983**
- FGFR3 mutation-associated disorders, achondroplasia vs., **695**
- FGR (Fetal growth restriction). *See* Fetal growth restriction (FGR).
- Fibrochondrogenesis
- micromelia vs., **700**
 - thanatophoric dysplasia vs., **728**
- Fibroid. *See also* Myoma, in pregnancy.
- degeneration, acute abdomen in pregnancy vs., **1083, 1085**
 - hemorrhagic, uterine rupture vs., **1077**
 - submucosal, chorioangioma vs., **817**
 - uncomplicated, uterine rupture vs., **1077**
- Fibroleiomyoma. *See* Myoma, in pregnancy.
- Fibroma, rhabdomyoma vs., **445**
- Fibromatosis
- cervical teratoma vs., **303**
 - epignathus vs., **289**
- Fibrosarcoma
- cervical teratoma vs., **303**
 - epignathus vs., **289**
- Fibular/tibial hemimelia, **768–769**
- campomelic dysplasia vs., **707**
 - diagnostic checklist, **769**
 - differential diagnosis, **769**
 - prognosis, **769**
 - staging, grading, & classification, **769**
- First trimester
- approach to, **16–19**
 - clinical implications, **18**
 - criteria to change menstrual dating, **17**
 - gestational age, **18**
 - imaging techniques and normal anatomy, **16**
 - location of pregnancy, **16**
 - milestones, **17**
 - nomenclature in first trimester, **17**
 - normal pregnancy, **18**
 - number of embryos, **17**
 - uterus and adnexa, **18**
 - embryology and anatomy, **4–15**
 - 6 weeks, **10**
 - 7–8 weeks, **11**
 - 8–9 weeks, **12**
 - 10–13 weeks, **13**
 - anatomy imaging issues, **5**
 - cleavage, **4, 7**
 - double decidual sac sign, **9**
 - embryology events, **4**
 - embryonic development, **4**
 - fertilization, **4, 6**
 - implantation, **4, 7**
 - intradecidual sac sign, **8**
 - organogenesis, **4–5**
 - ovulation, **4, 6**

INDEX

- placental development, **5**
 - umbilical cord development, **5, 15**
 - failed pregnancy, **20–23**
 - abnormal gestational sac and contents vs., **56**
 - chorionic bump vs., **29**
 - diagnostic checklist, **22**
 - differential diagnosis, **21**
 - ultrasound in, **22**
 - iniencephaly and, **243**
 - screening, **884, 886**
 - 1st branchial groove, **265**
 - Fissures, approach to imaging, **85**
 - FLNB-related disorders, atelosteogenesis vs., **703**
 - Fluid, growth, and well-being
 - fetal anemia, **1040–1043**
 - fetal growth restriction, **1034–1037**
 - hydrops, **1052–1057**
 - macrosomia, **1038–1039**
 - oligohydramnios, **1048–1051**
 - polyhydramnios, **1044–1047**
 - Fluid-filled renal pelvis, abnormal, urinary tract dilation, **585**
 - Focal cortical dysplasia, tuberous sclerosis vs., **1001**
 - Focal myometrial contraction, **785**
 - abnormal gestational sac and contents vs., **57**
 - myoma in pregnancy vs., **1067**
 - placenta previa vs., **795**
 - placental abruption vs., **791**
 - placental cysts and masses vs., **830, 831**
 - succenturiate lobe vs., **811**
 - Folate deficiency, spina bifida and, **238**
 - Follicle, dominant, **6**
 - Fontan, staging, hypoplastic left heart and, **410**
 - Foot
 - rocker-bottom, **736–737**
 - associated abnormalities, **737**
 - clubfoot vs., **733**
 - diagnostic checklist, **737**
 - differential diagnosis, **737**
 - genetics, **737**
 - prognosis, **737**
 - sandal gap, **738–739**
 - associated abnormalities, **739**
 - diagnostic checklist, **739**
 - differential diagnosis, **739**
 - genetics, **739**
 - Foramen ovale, **375**
 - embryology and anatomy, **368, 369, 372**
 - flap, **368, 369**
 - Foramen ovale aneurysm. *See* Atrial septal aneurysm.
 - Forebrain prominence, embryology and anatomy, **480**
 - Foregut, **324, 325**
 - Foregut-derived esophagus, **324**
 - Fornices, approach to imaging, **85**
 - 4p deletion syndrome, Fraser syndrome vs., **951**
 - 4p-syndrome, hypospadias and, **657**
 - Fourth ventricle, approach to imaging, **91**
 - Fowler syndrome, hydranencephaly and, **163**
 - Fragile X syndrome, cerebellar hypoplasia and, **187**
 - Franceschetti-Klein syndrome. *See* Treacher Collins syndrome (TCS).
 - Fraser syndrome, **950–951**
 - congenital high airway obstruction sequence associated with, **347**
 - diagnostic checklist, **951**
 - differential diagnosis, **951**
 - genetics, **951**
 - hypospadias and, **657**
 - prognosis, **951**
 - syndactyly vs., **751**
 - Freeman-Sheldon syndrome, arthrogryposis/akinesia sequence vs., **759**
 - Frontal bone, **268, 270, 271**
 - Frontal bone concavity, Chiari 2 malformation and, **169**
 - Frontal cephalocele, **106–107**
 - diagnostic checklist, **107**
 - differential diagnosis, **107**
 - epignathus vs., **289**
 - prognosis, **107**
 - Frontal encephalocele
 - abnormal orbits/eyes vs., **304**
 - cleft lip, palate vs., **280**
 - dacryocystocele vs., **285**
 - Frontal process, of maxilla, **268**
 - Frontonasal prominence, **264**
 - embryology and anatomy, **262**
 - Frontonasal prominence primordia, **265**
 - Fryns syndrome, **952–953**
 - alobar holoprosencephaly associated with, **120**
 - congenital diaphragmatic hernia associated with, **334**
 - Cornelia de Lange syndrome vs., **941**
 - diagnostic checklist, **953**
 - differential diagnosis, **953**
 - genetics, **953**
 - LEOPARD syndrome, cardiomyopathy and, **442**
 - Noonan syndrome, cardiomyopathy and, **442**
 - prognosis, **953**
 - Fukuyama congenital muscular dystrophy, Walker-Warburg syndrome vs., **1013**
 - Full maternal bladder, **785**
 - placenta previa vs., **795**
 - Funneling, **1061**
 - Fusion abnormalities, renal ascent and, **570**
 - Future urinary bladder, embryology and anatomy, **480**
- ## G
- Gallbladder, **579**
 - duplication, choledochal cyst vs., **549**
 - embryology and anatomy, **478, 483**
 - and umbilical vein varix, **827**
 - Gallstones, **546–547**
 - associated abnormalities, **547**
 - diagnostic checklist, **547**
 - differential diagnosis, **547**
 - genetics, **547**
 - meconium peritonitis/pseudocyst vs., **541**
 - Ganglioneuroblastoma, **630**
 - Ganglioneuroma, **630**
 - Gastric duplication cyst, **675**
 - suprarenal mass vs., **674**

INDEX

- Gastrointestinal abnormalities, ovarian cyst vs., **659**
- Gastrointestinal anomalies, gastroschisis and, **492**
- Gastrointestinal defects, omphalocele and, **498**
- Gastrointestinal/genitourinary dysfunction, Chiari 2 malformation and, **170**
- Gastrointestinal tract
- approach to, **485–489**
 - clinical implications, **486**
 - imaging techniques and normal anatomy, **484**
 - duodenal atresia, **520–523**
 - embryology and anatomy, **474–483**
 - 2nd week, **474**
 - 3rd week, **474**
 - 4-week embryo, **477**
 - 4th week, **474**
 - 5th week, **474**
 - 6th to 7th week, **474**
 - 8th week, **474**
 - 9th week, **474**
 - 10th week, **474**
 - 18-day embryo, **476**
 - abdominal vessels, **474–475**
 - arteries, **474**
 - bowel rotation, **478, 479**
 - early embryologic events, **474**
 - fetal abdomen MR imaging, **482**
 - fetal abdomen ultrasound, **483**
 - liver, portal and hepatic veins, **481**
 - mouth and anus formation, **480**
 - organogenesis, **5, 14**
 - organs, **475**
 - selected defects in development, **475**
 - veins, **475**
- Gastroschisis, **484, 490–495**
- amniotic band syndrome vs., **925**
 - associated abnormalities, **492**
 - body stalk anomaly vs., **505**
 - diagnostic checklist, **492**
 - differential diagnosis, **491**
 - differentiation, **514**
 - embryology, **475**
 - genetics, **492**
 - jejunal/ileal atresia and, **526**
 - omphalocele vs., **497**
 - prognosis, **492**
 - volvulus and, **537**
- Gastrulation, embryology, **474**
- Gaucher disease
- perinatal-lethal subtype, malignant liver tumors vs., **555–556**
 - type 2, perinatal lethal type, arthrogryposis/akinesia sequence vs., **760**
- Generalized arterial calcification of infancy. *See* Idiopathic infantile arterial calcification.
- Generalized osteochondrodystrophy, angulated bones and, **775**
- Genetic counseling, autosomal recessive polycystic kidney disease and, **620**
- Genetic screening, approach, **884–889**
- Genetic syndrome, esophageal atresia and, **518**
- Genital tract development
- female, **571, 576**
 - male, **571, 577**
- Genital tubercle, **573, 576, 577**
- embryology and anatomy, **478**
- Genitalia, **581**
- Genitourinary anomalies, cloacal malformation/urogenital sinus and, **533**
- Genitourinary tract
- adrenal hemorrhage, **626–627**
 - anomalies, Smith-Lemli-Opitz syndrome vs., **993**
 - bilateral renal agenesis, **600–603**
 - congenital adrenal hyperplasia, **632–633**
 - crossed fused ectopia, **598–599**
 - disorders of sexual development, **650–655**
 - duplicated collecting system, **590–593**
 - echogenic kidneys, **668–669**
 - embryology and anatomy, **570–579**
 - adrenal gland development, **570**
 - bladder development, **570, 573**
 - female genital tract development, **571, 576**
 - kidney development, **572**
 - male genital tract development, **571, 577**
 - organogenesis, **5**
 - renal ascent, **570, 574–575**
 - urinary tract development, **570**
 - fetal, approach to, **580–583**
 - abnormal urinary tract, **580–581**
 - clinical implications, **581**
 - imaging techniques and normal anatomy, **580**
 - horseshoe kidney, **596–597**
 - hydrocolpos, **662–663**
 - hydronephrosis, **664–667**
 - hypospadias, **656–657**
 - mesoblastic nephroma, **622–625**
 - multicystic dysplastic kidney, **614–617**
 - neuroblastoma, **628–631**
 - obstructive renal dysplasia, **610–613**
 - ovarian cyst, **658–661**
 - pelvic kidney, **594–595**
 - polycystic kidney disease, autosomal recessive, **618–621**
 - prune-belly syndrome, **638–641**
 - posterior urethral valves vs., **635**
 - scrotal mass, **676–677**
 - suprarenal mass, **674–675**
 - unilateral enlarged kidney, **670–673**
 - unilateral renal agenesis, **588–589**
 - urachal anomalies, **646–649**
 - ureterocele, **642–645**
 - ureteropelvic junction obstruction, **604–607**
 - urethral valves, posterior, **634–637**
 - urinary tract dilation, **584–587**
 - urinoma, **608–609**
- Germ cell theory, **821**
- Germ cells, **571**
- Germinal matrix
- hemorrhage, tuberous sclerosis vs., **1001**
 - normal, tuberous sclerosis vs., **1001**
- Gestation, skeletal abnormality and, **680**
- Gestational age, AFI vs., **1029**
- Gestational diabetes, triplets and, **875**

INDEX

- Gestational sac
- 1st trimester, **784**
 - abnormal, **56–61**
 - differential diagnosis, **56**
 - abnormal location, abnormal gestational sac and contents vs., **56**
- Gestational trophoblastic disease
- failed first-trimester pregnancy vs., **21**
 - placental cysts and masses vs., **831, 833**
- Gestational trophoblastic neoplasia, placental lake vs., **807**
- Gingival granular cell tumor of newborn. *See* Epulis.
- Glenn, staging, hypoplastic left heart and, **410**
- Glioependymal cyst. *See* Interhemispheric cyst/AVID.
- Glioma, nasal
- epignathus vs., **289**
 - frontal cephalocele vs., **107**
- Glomeruli, **572**
- Glomerulosa, **570**
- Gluteal muscles, **232**
- Goiter, **294–297**
- cervical teratoma vs., **303**
 - diagnostic checklist, **296**
 - differential diagnosis, **295**
 - genetics, **295**
 - prognosis, **296**
- Goldberg-Shprintzen syndrome with pachygyria, cerebellar hypoplasia and, **187**
- Goldenhar syndrome, **312, 954–955**
- abnormal ears vs., **310–311**
 - coloboma and, **287**
 - diagnostic checklist, **955**
 - differential diagnosis, **955**
 - genetics, **955**
 - intracranial lipoma and, **207**
 - Pierre Robin sequence vs., **987**
 - prognosis, **955**
 - Treacher Collins syndrome (TCS) vs., **997**
- Gómez-López-Hernández syndrome, rhombencephalosynapsis and, **191, 192**
- Gonadal mosaicism, osteogenesis imperfecta and, **719**
- Gray matter heterotopia, **142–143**
- associated abnormalities, **143**
 - diagnostic checklist, **143**
 - differential diagnosis, **143**
 - prognosis, **143**
 - subependymal, tuberous sclerosis vs., **1001**
- Grayscale ultrasound
- crossed fused ectopia, **599**
 - fetal growth restriction, **1035**
 - horseshoe kidney and, **597**
 - mesenchymal hamartoma, **553**
 - pelvic kidney and, **595**
 - unilateral renal agenesis, **589**
- Great arteries, **374**
- Great Ormond Street score (GOSE score), **397**
- Great vessel asymmetry, **375**
- Greater omentum, embryology and anatomy, **479**
- Greenberg dysplasia, chondrodysplasia punctata vs., **712**
- Greig cephalopolysyndactyly syndrome (GCPS)
- polydactyly vs., **747**
 - syndactyly vs., **751**
- Growth discordance, multiple gestations, **841**
- Growth restriction, fetal, **1034–1037**
- mildly short femur/humerus and, **770–771, 773**
- Gubernaculum, **571, 577**
- Gut, **572**
- Gut herniation, physiologic, **834**
- gastroschisis vs., **491**
 - omphalocele vs., **497**
- Gut tube, **231**
- Gynecological abnormalities, ureterocele and, **644**
- Gynecological anomalies, duplicated collecting system and, **592**
- Gyral and sulcal development, **68**

H

- Hamartoma, mesenchymal, **552–553**
- associated abnormalities, **553**
 - congenital hepatic hemangioma vs., **551**
 - diagnostic checklist, **553**
 - differential diagnosis, **553**
 - malignant liver tumors vs., **555**
 - prognosis, **553**
- Hand/foot malformation, split, **754–757**
- diagnostic checklist, **756**
 - differential diagnosis, **755–756**
 - genetics, **756**
 - long bone deficiency and, **755**
 - prognosis, **756**
 - staging, grading, & classification, **756**
 - syndactyly vs., **752**
- Hands
- approach to skeletal dysplasias and, **681**
 - thanatophoric dysplasia and, **727**
- HCM. *See* Hypertrophic cardiomyopathy (HCM).
- Head
- achondroplasia and, **695**
 - approach to skeletal dysplasias and, **683**
 - front of, **273**
 - thanatophoric dysplasia and, **727**
- Hearing impairment, Turner syndrome and, **910**
- Hearing loss, osteogenesis imperfecta and, **719**
- Heart, **477, 579**
- abnormal cardiac axis, **462–467**
 - abnormal position, heterotaxy/cardiosplenic syndromes and, **381**
 - aortic stenosis, **416–419**
 - isolated, coarctation/interrupted aortic arch vs., **413**
 - severe, hypoplastic left heart, **409**
 - approach to fetal heart, **374–379**
 - clinical implications, **376**
 - images, **376–379**
 - imaging techniques and normal anatomy, **374**
 - atrial septal aneurysm, **394–395**
 - atrioventricular septal defect, **390–393**
 - bradyarrhythmia, **458–461**
 - cardiomyopathy, **440–443**
 - chamber asymmetry, **468–471**
 - coarctation/interrupted aortic arch, **412–415**
 - aortic stenosis vs., **417**

INDEX

- D-transposition of great arteries, double-outlet right ventricle vs., **437**
 - dilated cardiomyopathy, **440–443**
 - double-outlet right ventricle, **436–437**
 - Ebstein anomaly, **396–399**
 - diagnostic checklist, **397**
 - differential diagnosis, **397**
 - prognosis, **397**
 - echogenic cardiac focus, **438–439**
 - rhabdomyoma vs., **445**
 - ectopia cordis, **384–387**
 - embryology and anatomy. *See* Cardiovascular system, embryology and anatomy.
 - enlargement, coarctation/interrupted aortic arch vs., **413**
 - fields, **364**
 - 4-chamber view, **374**
 - heterotaxy/cardiosplenic syndromes, **380–383**
 - heterotaxy syndromes, atrioventricular septal defect vs., **391**
 - hypertrophic cardiomyopathy, **440–443**
 - hypoplastic left heart, **408–411**
 - aortic stenosis vs., **417**
 - hypoplastic left heart syndrome, coarctation/interrupted aortic arch vs., **413**
 - irregular rhythm, **452–453**
 - pericardial effusion, **448–449**
 - pericardial teratoma, **450–451**
 - rhabdomyoma vs., **445**
 - rate, **376**
 - rhabdomyoma, **444–447**
 - side, **374**
 - size, **374**
 - tachyarrhythmia, **454–457**
 - tachycardia, supraventricular, irregular rhythm vs., **453**
 - tetralogy of Fallot, **424–427**
 - double-outlet right ventricle vs., **437**
 - total anomalous pulmonary venous return, **420–423**
 - transplant, hypoplastic left heart and, **410**
 - transposition of great arteries, **428–431**
 - tricuspid atresia, **402–403**
 - pulmonary stenosis/atresia vs., **405**
 - tricuspid dysplasia, **400–401**
 - Ebstein anomaly vs., **397**
 - truncus arteriosus, **432–435**
 - pulmonary stenosis/atresia vs., **405**
 - variable displacement of, pentalogy of Cantrell and, **503**
 - ventricular septal defect, **388–389**
 - wall-to-wall, **397**
- Heart block
- 1st degree, bradyarrhythmia vs., **459**
 - 2nd degree
 - bradyarrhythmia vs., **459**
 - irregular rhythm vs., **453**
 - complete, bradyarrhythmia vs., **459**
- Heart defects, congenital, diabetic embryopathy vs., **947**
- Heart failure, rhabdomyoma vs., **445**
- Heart tube, primitive, **364**
- Helix, **265**
- HELLP syndrome, acute abdomen in pregnancy vs., **1083, 1085**
- Hemangiectatic hypertrophy. *See* Klippel-Trenaunay-Weber syndrome.
- Hemangioendothelioma, fetus-in fetu vs., **879**
- Hemangioma
- calvarium, abnormal and, **221**
 - cervical teratoma vs., **303**
 - cleft lip, palate vs., **280**
 - congenital hepatic, **550–551**
 - diagnostic checklist, **551**
 - differential diagnosis, **551**
 - mesenchymal hamartoma vs., **553**
 - dacryocystocele vs., **285**
 - epignathus vs., **289**
 - gallstones vs., **547**
 - hepatic, congenital, malignant liver tumors vs., **555**
 - infantile, congenital hepatic hemangioma and, **551**
 - lymphangioma vs., **351**
 - rhabdomyoma vs., **445**
 - umbilical cord, **836, 837**
- Hematoma
- adrenal, fetus-in fetu vs., **879**
 - bladder flap, uterine rupture vs., **1077**
 - cord, **835, 837**
 - placental, chorioangioma vs., **817**
 - placental abruption, **791**
- Hemibladders, cloacal exstrophy/OEIS syndrome, **513**
- Hemifacial microsomia, Pierre Robin sequence vs., **987**
- Hemimelia, **699**
- fibular/tibial, **768–769**
 - campomelic dysplasia vs., **707**
 - diagnostic checklist, **769**
 - differential diagnosis, **769**
 - prognosis, **769**
 - staging, grading, & classification, **769**
- Hemivertebra, kyphosis/scoliosis and, **249**
- Hemivertebrae, Aicardi syndrome and, **922**
- Hemorrhage
- acute placental, **785**
 - adrenal
 - bronchopulmonary sequestration vs., **342**
 - suprarenal mass vs., **674**
 - fetal, fetal anemia vs., **1041**
 - germinal matrix, tuberous sclerosis vs., **1001**
 - perigestational, twins with, triplets vs., **875**
 - postpartum, placenta previa and, **796**
- Hemorrhagic cyst, adnexal mass in pregnancy vs., **62**
- Hemorrhagic fibroid, uterine rupture vs., **1077**
- Heparin therapy, intracranial hemorrhage and, **155**
- Hepatic diverticulum, **477**
- Hepatic dysfunction, Turner syndrome and, **910**
- Hepatic fibrosis, short rib-polydactyly syndrome and, **724**
- Hepatic metastases, neuroblastoma and, **629**
- Hepatic tumors. *See* Liver tumors.
- Hepatic vein plexus, embryology and anatomy, **481**
- Hepatic veins, embryology and anatomy, **370**
- Hepatic/renal insufficiency, short rib-polydactyly syndrome and, **724**
- Hepatoblastoma, **555**
- congenital hepatic hemangioma vs., **551**
 - diagnostic checklist, **556**
 - gallstones vs., **547**

INDEX

- genetics, **556**
- mesenchymal hamartoma vs., **553**
- prognosis, **556**
- Hepatomegaly, conditions causing, malignant liver tumors vs., **555**
- Hepatorenal fibrocystic diseases, **619, 620**
- Hepatosplenomegaly
 - encephalomalacia/porencephaly and, **159**
 - trisomy 21 and, **891**
- Hernia
 - congenital diaphragmatic, cystic chest mass vs., **360**
 - inguinal, **677**
 - scrotal mass vs., **676**
 - umbilical, omphalocele vs., **498**
- Herpes simplex virus type 2
 - parvovirus vs., **1021**
 - toxoplasmosis vs., **1023**
 - varicella vs., **1025**
- Heterotaxy, abdominal, volvulus and, **537**
- Heterotaxy/cardiosplenic syndromes, **380–383**
 - abnormal cardiac axis vs., **463, 466**
 - associated abnormalities, **382**
 - atrioventricular septal defect vs., **391**
 - chamber asymmetry and, **469**
 - diagnostic checklist, **382**
 - differential diagnosis, **381**
 - genetics, **381–382**
 - prognosis, **382**
- Heterotaxy syndromes. *See* Heterotaxy/cardiosplenic syndromes.
- Heterotopia
 - Chiari 2 malformation and, **169**
 - Chiari 3 malformation and, **173**
 - cortical, Aicardi syndrome and, **921**
 - Dandy-Walker malformation and, **175**
 - gray matter, **142–143**
 - associated abnormalities, **143**
 - diagnostic checklist, **143**
 - differential diagnosis, **143**
 - prognosis, **143**
 - subependymal, tuberous sclerosis vs., **1001**
 - periventricular nodular, bilateral, tuberous sclerosis vs., **1001**
 - subcortical, tuberous sclerosis vs., **1001**
 - thanatophoric dysplasia and, **728**
- Heterotopic pregnancy, **16, 54–55**
 - diagnostic checklist, **55**
 - differential diagnosis, **55**
 - prognosis, **55**
- Heterozygous achondroplasia, mildly short femur/humerus and, **771, 773**
- High anal atresia, **531**
- High-risk group, neuroblastoma, **630**
- Hindbrain herniation. *See* Chiari 3 malformation.
- Hindgut, **573**
 - embryology and anatomy, **477, 478, 480**
- Hip dislocation, spina bifida and, **237**
- Hirschsprung disease, colonic atresia and, **529**
- Histogenesis, **68**
- HIV, cytomegalovirus vs., **1017**
- HLHS (hypoplastic left heart syndrome). *See* Hypoplastic left heart.
- Holoprosencephaly
 - alobar, **118–121**
 - abnormal facial features associated with, **120**
 - associated with multiple syndromes, **120**
 - atelencephaly/aprosencephaly vs., **117**
 - diagnostic checklist, **120**
 - differential diagnosis, **119**
 - interhemispheric cyst/AVID vs., **114**
 - prognosis, **120**
 - semilobar holoprosencephaly vs., **123**
 - aqueductal stenosis vs., **165**
 - Dandy-Walker malformation and, **175**
 - echogenic kidneys and, **668**
 - lobar, **124–125**
 - agenesis/dysgenesis of corpus callosum vs., **110**
 - diagnostic checklist, **125**
 - differential diagnosis, **125**
 - prognosis, **125**
 - schizencephaly vs., **136**
 - semilobar holoprosencephaly vs., **123**
 - septo-optic dysplasia vs., **127**
 - syntelencephaly vs., **131**
 - middle interhemispheric variant. *See* Syntelencephaly.
 - semilobar, **122–123**
 - diagnostic checklist, **123**
 - differential diagnosis, **123**
 - prognosis, **123**
 - schizencephaly vs., **136**
 - syntelencephaly vs., **131**
 - Smith-Lemli-Opitz syndrome vs., **993**
 - syntelencephaly vs., **132**
 - trisomy 13 and, **903**
 - alobar, **903**
 - trisomy 18 and, **897**
 - without T13, trisomy 13 vs., **903**
- Holt-Oram syndrome, **956–959**
 - differential diagnosis, **957**
 - genetics, **957**
 - prognosis, **957**
 - radial ray malformation vs., **741**
 - VACTERL association vs., **1005**
- Homozygous achondroplasia
 - achondrogenesis/hypochondrogenesis vs., **689**
 - achondroplasia vs., **695**
 - thanatophoric dysplasia vs., **727**
- Horseshoe kidney, **596–597**
 - asymmetric
 - crossed fused ectopia vs., **599**
 - unilateral renal agenesis vs., **589**
 - diagnostic checklist, **597**
 - differential diagnosis, **597**
 - pelvic kidney vs., **595**
 - prognosis, **597**
 - renal ascent and, **570**
 - Turner syndrome and, **909**
- Humeral head, **579**
- Humerus length, short, trisomy 21 and, **891**
- Humerus/mildly short femur, **770–773**
 - differential diagnosis, **770–771**

INDEX

- idiopathic, **770, 771**
- "Hutch" diverticulum, bladder, ureterocele vs., **643–644**
- Hybrid palliation, hypoplastic left heart and, **410**
- Hydantoin embryopathy, chondrodysplasia punctata vs., **712**
- Hydatidiform mole, **831**
 - with coexistent fetus, triploidy vs., **913**
 - complete, **30–33**
 - abnormal gestational sac and contents vs., **57**
 - associated abnormalities, **32**
 - diagnostic checklist, **32**
 - differential diagnosis, **31**
 - placental lake vs., **807**
 - prognosis, **32**
 - invasive, abnormal gestational sac and contents vs., **57**
 - twin pregnancy with, placental mesenchymal dysplasia vs., **823**
- Hydranencephaly, **162–163**
 - alobar holoprosencephaly vs., **119**
 - aqueductal stenosis vs., **165**
 - atelencephaly/aprosencephaly vs., **117**
 - diagnostic checklist, **163**
 - differential diagnosis, **163**
 - genetics, **163**
 - prognosis, **163**
 - schizencephaly vs., **135**
- Hydrocele
 - complex, scrotal mass vs., **676**
 - scrotal mass vs., **676**
 - simple, scrotal mass vs., **676**
- Hydrocephalus
 - aqueductal stenosis and, **165, 166**
 - arachnoid cyst and, **152**
 - associated with spina bifida, cloacal exstrophy/OEIS syndrome and, **514**
 - Dandy-Walker malformation and, **175**
 - encephalomalacia/porencephaly and, **159**
 - severe, cavum septi pellucidi, absent vs., **208**
 - Smith-Lemli-Opitz syndrome vs., **993**
 - vein of Galen aneurysmal malformation vs., **196**
- Hydrocolpos, **662–663**
 - cystic abdominal mass vs., **563, 567**
 - diagnostic checklist, **663**
 - differential diagnosis, **663**
 - genetics, **663**
 - isolated, cloacal malformation/urogenital sinus vs., **533**
 - ovarian cyst vs., **659**
 - prognosis, **663**
- Hydroletharus, Smith-Lemli-Opitz syndrome vs., **993**
- Hydroletharus syndrome, Meckel-Gruber syndrome vs., **972**
- Hydrometrocolpos. *See* Hydrocolpos.
- Hydromyelic theory, spina bifida and, **238**
- Hydronephrosis, **664–667**
 - abnormal urinary tract, **581**
 - Apert syndrome and, **929**
 - differential diagnosis, **664–665**
 - fetal. *See* Urinary tract dilation.
 - ovarian cyst vs., **659**
 - posterior urethral valves and, **635**
 - severe, obstructive renal dysplasia vs., **611**
 - trisomy 18 and, **897**
 - urachal anomalies vs., **647**
- Hydrops, **1052–1057**
 - achondrogenesis/hypochondrogenesis and, **690**
 - ascites vs., **560**
 - and chorioangioma, **817**
 - differential diagnosis, **1052**
 - encephalomalacia/porencephaly and, **159**
 - fetal chest mass and, **331**
 - idiopathic, hydrops vs., **1052, 1053**
 - idiopathic infantile arterial calcification vs., **961**
 - immune
 - hydrops vs., **1052–1053**
 - malignant liver tumors vs., **555**
 - intracranial hemorrhage and, **155**
 - macrosomia vs., **1039**
 - meconium peritonitis/pseudocyst vs., **541**
 - neuroblastoma and, **629**
 - nonimmune
 - cytomegalovirus vs., **1017**
 - malignant liver tumors vs., **555**
 - Turner syndrome and, **909**
 - parvovirus vs., **1021**
 - polyhydramnios vs., **1044, 1046**
 - sacrococcygeal teratoma and, **255**
 - sign, rhabdomyoma and, **445**
 - volvulus and, **537**
- Hydrosalpinx, adnexal mass in pregnancy vs., **63**
- Hydroureter, posterior urethral valves and, **635**
- Hygroma, cystic. *See* Cystic hygroma.
- Hypercalcemia, hypophosphatasia and, **715**
- Hypercoiled cord, **835, 837**
- Hyperechoic bowel, trisomy 21 and, **891**
- Hyperparathyroidism, neonatal (severe form), hypophosphatasia vs., **715**
- Hyperplasia, congenital adrenal, **675**
 - disorders of sexual development and, **651**
 - suprarenal mass vs., **674**
- Hyperechoic luteinalis, dichorionic diamniotic twins and, **847**
- Hypertelorism, **307**
 - abnormal orbits/eyes vs., **304**
 - associations, **305**
 - trisomy 18 and, **897**
- Hypertension
 - triplets and, **875**
 - Turner syndrome and, **910**
- Hypertrophic cardiomyopathy (HCM), **440–443**
- Hypertrophic obstructive cardiomyopathy (HOCM). *See* Hypertrophic cardiomyopathy (HCM).
- Hypertrophy, hemangiectatic. *See* Klippel-Trenaunay-Weber syndrome.
- Hypoblast, **7**
- Hypocalcemia, truncus arteriosus and, **434**
- Hypochondrogenesis/achondrogenesis, **688–693**
 - abnormal ossification vs., **780, 781**
 - associated abnormalities, **690**
 - diagnostic checklist, **690**
 - differential diagnosis, **689**
 - genetics, **689–690**
 - prognosis, **690**

INDEX

- staging, grading, & classification, **690**
- Hypochondroplasia, achondroplasia vs., **695**
- Hypognathia, embryology, **263**
- Hypokinesia deformation sequence. *See* Arthrogryposis/akinesia sequence.
- Hypoperistalsis syndrome, megacystis-microcolon-intestinal, prune-belly syndrome vs., **639**
- Hypopharynx, fluid in, **269**
- Hypophosphatasia, **714–717**
 - abnormal ossification vs., **780, 781**
 - achondrogenesis/hypochondrogenesis vs., **689**
 - angulated bones and, **775, 779**
 - calvarium, abnormal vs., **217**
 - differential diagnosis, **715**
 - genetics, **715**
 - infantile, **715**
 - late onset (adult form), **715**
 - perinatal lethal, **715**
 - prognosis, **715**
- Hypophosphatemic rickets, hypophosphatasia vs., **715**
- Hypoplasia
 - definition, **187**
 - midface, trisomy 21 and, **891**
 - Müllerian duct anomalies and, **1071**
- Hypoplastic left heart, **408–411**
 - aortic stenosis vs., **417**
 - diagnostic checklist, **410**
 - differential diagnosis, **409**
 - genetics, **410**
 - prognosis, **410**
 - trisomy 13 and, **903**
 - Turner syndrome and, **909**
- Hypoplastic left heart syndrome
 - abnormal cardiac axis vs., **463**
 - chamber asymmetry vs., **468, 469**
 - coarctation/interrupted aortic arch vs., **413**
- Hypoplastic left ventricle. *See* Hypoplastic left heart.
- Hypospadias, **656–657**
 - associated abnormalities, **657**
 - diagnostic checklist, **657**
 - differential diagnosis, **657**
 - disorders of sexual development and, **651**
 - genetics, **657**
 - prognosis, **657**
 - severe, congenital adrenal hyperplasia vs., **633**
- Hypotelorism, **305–306**
 - abnormal orbits/eyes vs., **304**
 - associations, **305**
 - echogenic kidneys and, **668**
 - trisomy 13 and, **903**
- Hypotension, encephalomalacia/porencephaly and, **160**
- Hypothalamic pituitary axis dysfunction, rhombencephalosynapsis and, **192**
- Hypoxia, encephalomalacia/porencephaly and, **160**

I

IAA. *See* Interrupted aortic arch (IAA).
IABD. *See* Intraabdominal bowel dilation (IABD),
gastroschisis and.

- Idiopathic (normal variant) bowel, echogenic bowel vs., **558**
- Idiopathic hydrops, hydrops vs., **1052, 1053**
- Idiopathic hypertrophic subaortic stenosis (IHSS). *See* Hypertrophic cardiomyopathy (HCM).
- Idiopathic infantile arterial calcification, **960–961**
 - diagnostic checklist, **961**
 - differential diagnosis, **961**
 - genetics, **961**
 - prognosis, **961**
- Idiopathic/isolated ventriculomegaly, mild vs., **212, 213**
- Idiopathic macroglossia, **318**
- Idiopathic micrognathia, **314, 315**
- Idiopathic mildly short femur/humerus, **770, 771**
- IIAC (Idiopathic infantile arterial calcification). *See* Idiopathic infantile arterial calcification.
- Ileal atresia. *See also* Jejunal, ileal atresia.
 - cystic fibrosis vs., **945**
 - jejunal vs., **525**
- Iliac arteries, embryology and anatomy, **481**
- Iliac artery, **574, 578**
- Iliac crest, **232**
 - embryology and anatomy, **481**
- Iliac lymph sacs, **272**
- Immune hydrops, hydrops vs., **1052–1053**
- Impending hydrops, **486**
- Implantation, **4, 7**
 - abnormal, placenta previa and, **795**
- In utero, enteric duplication cyst, **539**
- Increased nuchal translucency, **273**
- Infant/child, truncus arteriosus and, **434**
- Infantile arterial calcification, idiopathic. *See* Idiopathic infantile arterial calcification.
- Infantile hemangioma, congenital hepatic hemangioma and, **551**
- Infantile hypophosphatasia, **715**
- Infantile myocardial ischemia, idiopathic infantile arterial calcification vs., **961**
- Infantile spasms, Aicardi syndrome and, **922**
- Infection
 - ascites vs., **560, 561**
 - congenital
 - pachygyria/polymicrogyria vs., **145**
 - pericardial effusion and, **449**
 - cytomegalovirus, **1016–1019**
 - echogenic bowel vs., **558**
 - encephalomalacia/porencephaly and, **159, 160**
 - gray matter heterotopia vs., **143**
 - hydrops vs., **1052**
 - intracranial hemorrhage vs., **155**
 - malignant liver tumors vs., **555**
 - meconium peritonitis/pseudocyst vs., **541**
 - parvovirus, **1020–1021**
 - toxoplasmosis, **1022–1023**
 - varicella, **1024–1025**
- Infection theory, multicystic dysplastic kidney and, **616**
- Inferior mesenteric artery, embryology and anatomy, **478**
- Inferior vena cava, **231**
 - embryology and anatomy, **369, 372, 373, 481**

INDEX

- Infracardiac total anomalous pulmonary venous return, **421**
- Ingested blood, echogenic bowel and, **558, 559**
- Inguinal hernia, **677**
- bladder exstrophy and, **510**
 - hypospadias and, **657**
 - scrotal mass vs., **676**
- lniencephaly, **242–243**
- associated abnormalities, **243**
 - Chiari 3 malformation vs., **173**
 - diagnostic checklist, **243**
 - differential diagnosis, **243**
 - genetics, **243**
 - occipital/parietal cephalocele vs., **102**
 - prognosis, **243**
- Inlet defect, ventricular septal defect and, **389**
- Intact ventricular septum
- pulmonary atresia, tricuspid atresia vs., **403**
 - pulmonary valve atresia with, chamber asymmetry and, **468, 470**
- Interhemispheric cyst/AVID, **112–115**
- arachnoid cyst vs., **151**
 - associated abnormalities, **114**
 - brain tumors vs., **203**
 - Chiari 2 malformation and, **169**
 - diagnostic checklist, **114**
 - differential diagnosis, **113–114**
 - prognosis, **114**
- Interhemispheric fissure, approach to imaging, **85**
- Intermaxillary segment fusion, philtrum of upper lip, **265**
- Intermediate risk group, neuroblastoma, **630**
- Internal iliac artery, embryology and anatomy, **373**
- Internal jugular veins, right and left, **272**
- Internal oblique muscle, **577**
- International Neuroblastoma Risk Group Staging System, **629–630**
- International Neuroblastoma Staging System, **629–630**
- International Society for Study of Vascular Anomalies, **551**
- Interocular distance, **267**
- Interrupted aortic arch (IAA), **375, 412–415**
- Interstitial ectopic pregnancy, **40–43**
- diagnostic checklist, **42**
 - differential diagnosis, **41–42**
 - Müllerian duct anomalies vs., **1071**
 - prognosis, **42**
 - tubal ectopic pregnancy vs., **35**
- Intertwin membrane rupture, mono chorionic monoamniotic twins vs., **855**
- Intervertebral disc, **232**
- Intervillous thrombi, chorioangioma vs., **817**
- Intestinal hypoperistalsis syndrome, megacystis-microcolon, prune-belly syndrome vs., **639**
- Intestine, small and large, embryology and anatomy, **475**
- Intraabdominal bowel dilation (IABD), gastroschisis and, **491**
- Intraabdominal cysts, ovarian cyst vs., **659**
- Intraabdominal neoplasms, ovarian cyst vs., **659**
- Intracardiac echogenic focus (IEF). *See also* Echogenic cardiac focus (ECF).
- trisomy 21 and, **891**
- Intracorporeal liver, omphalocele and, **498**
- Intracranial calcifications, encephalomalacia/porencephaly and, **159**
- Intracranial cyst, arteriovenous fistula vs., **199**
- Intracranial hemorrhage (ICH), **154–157**
- Aicardi syndrome vs., **922**
 - brain tumors vs., **203**
 - diagnostic checklist, **156**
 - differential diagnosis, **155**
 - gray matter heterotopia vs., **143**
 - mild ventriculomegaly vs., **213, 215**
 - of other cause, dural sinus malformation vs., **201**
 - prognosis, **156**
 - staging, grading, & classification, **156**
- Intracranial lipoma, **206–207**
- associated abnormalities, **207**
 - diagnostic checklist, **207**
 - differential diagnosis, **207**
 - prognosis, **207**
- Intracranial tumor, intracranial hemorrhage vs., **155**
- Intradecidual sac sign, **8**
- Intradural lipoma, **228**
- Intrahepatic plexus of vitelline veins, embryology and anatomy, **481**
- Intramural solid echogenic lesion, rhabdomyoma vs., **445**
- Intraparenchymal cysts, cytomegalovirus and, **1017**
- Intrarenal branches, **578**
- Intratumoral hemorrhage, sacrococcygeal teratoma and, **255**
- Intraurine growth restriction. *See* Fetal growth restriction.
- Intrauterine blood/clot, retained products of conception vs., **1081**
- Intrauterine device, amniotic band syndrome and, **925**
- Intrauterine fetal demise (IUFD), gastroschisis and, **492**
- Intrauterine linear echoes, **1086–1089**
- differential diagnosis, **1086**
- Intraventricular bleed, **155**
- Intraventricular hemorrhage (IVH)
- choroid plexus cyst vs., **149**
 - choroid plexus papilloma vs., **205**
 - fetal classification of, **156**
- Intraventricular lipoma, choroid plexus papilloma vs., **205**
- Intussusception
- meconium peritonitis/pseudocyst and, **542**
 - volvulus vs., **537**
- Involuting portion of left umbilical vein, embryology and anatomy, **481**
- Involuting renal artery, **574**
- Involuting right umbilical vein, embryology and anatomy, **481**
- Irregular rhythm, **452–453**
- differential diagnosis, **453**
 - prognosis, **453**
- Ischemia
- bowel, echogenic bowel vs., **558, 559**
 - intracranial hemorrhage vs., **155**
- Ischemic brain injury, arteriovenous fistula and, **199**
- Isolated anomalous pulmonary vein, total anomalous pulmonary venous return vs., **421**
- Isolated atrial septal defects, Holt-Oram syndrome vs., **957**

INDEX

Isolated cleft palate, **279**
Isolated congenital diaphragmatic hernia, Cornelia de Lange syndrome vs., **941**
Isolated conotruncal heart defect, 22q11 deletion syndrome vs., **919**
Isolated diaphragmatic hernia, Fryns syndrome vs., **953**
Isolated perimembranous, ventricular septal defect, tetralogy of Fallot vs., **425**
Isolated phocomelia/amelia, amelia vs., **699**
Isolated total anomalous pulmonary venous return, **422**
Isomerism, left and right atrial appendages associated with heterotaxy and cardiosplenic syndromes, **382**
IUCR (Intrauterine growth restriction). *See* Fetal growth restriction.
IUFD. *See* Intrauterine fetal demise (IUFD), gastroschisis and.

J

Jacobsen syndrome, aortic stenosis and, **418**
JAG1 mutations, tetralogy of Fallot and, **425**
Jarcho-Levin syndrome, iniencephaly vs., **243**
Jejunal, ileal atresia, **524–527**

- associated abnormalities, **526**
- colonic atresia vs., **529**
- diagnostic checklist, **526**
- differential diagnosis, **525–526**
- etiology, **526**
- genetics, **526**
- prognosis, **526**
- staging, grading, & classification, **526**
- volvulus vs., **537**

Jeune syndrome

- polydactyly vs., **747**
- short rib-polydactyly syndrome and, **723**

Johns Hopkins series, cloacal exstrophy/OEIS syndrome, **514**
Joint angulation, abnormal, angulated bones and, **774, 778**
Joint dislocations, atelosteogenesis and, **703**
Joubert syndrome, **91, 962–965**

- associated abnormalities, **963**
- Dandy-Walker malformation vs., **175**
- diagnostic checklist, **964**
- differential diagnosis, **963**
- genetics, **963**
- posterior fossa cyst/fluid collection vs., **223, 225**
- prognosis, **964**
- related disorders, **963**
- rhombencephalosynapsis vs., **191**
- simple clinical classification of, **964**
- vermian dysgenesis, **179**

JSRD (Joubert syndrome and related syndrome). *See* Joubert syndrome.
Jugular lymph sacs, **272**
Jugular lymphatic drainage sites, **272**
Junctional ectopic tachycardia, tachyarrhythmia vs., **455**
Juvenile form, autosomal recessive polycystic kidney disease, **620**

K

Kagami-Ogata syndrome, short rib-polydactyly syndrome vs., **724**
Kidney, **232, 573, 574, 576, 577, 578, 579**

- abnormal urinary tract, **580**
- cystic, urachal anomalies vs., **647**
- development, **572**
- duplicated collecting system and, **591**
- echogenic, **668–669**
 - differential diagnosis, **668**
- ectopic. *See* Crossed fused ectopia.
- formation, **570**
- horseshoe, **596–597**
- multicystic dysplastic, **614–617**
 - ovarian cyst vs., **659**
- pelvic, **594–595**
- renal ascent, **570**
- ultrasound, **580**
- unilateral enlarged, **670–673**
 - differential diagnosis, **670–671**
 - ureterocele and, **643**

Kleeblattschädel, **681**
Klippel-Feil syndrome, iniencephaly vs., **243**
Klippel-Trenaunay-Weber syndrome, **966–969**

- diagnostic checklist, **968**
- differential diagnosis, **967**
- genetics, **968**
- lymphangioma vs., **351**
- prognosis, **968**
- staging, grading, & classification, **968**

KTW (Klippel-Trenaunay-Weber syndrome). *See* Klippel-Trenaunay-Weber syndrome.
Kyphomelic dysplasia

- angulated bones and, **774–775, 779**
- campomelic dysplasia vs., **707**

Kyphosis/scoliosis, **248–249, 680**

- associated abnormalities, **249**
- Chiari 2 malformation and, **169**
- diagnostic checklist, **249**
- differential diagnosis, **249**
- genetics, **249**
- prognosis, **249**
- spina bifida and, **237**
- tethered cord and, **251**

L

Labia, embryology and anatomy, **483**
Labioscrotal fold, **571, 577**
Lacrimal duct cyst. *See* Dacryocystocele.
Lacuna, **786**
Lacunar network, **786**
Lamina, **232**
Large atrial septal defect, atrioventricular septal defect vs., **391**
Large for gestational age. *See* Macrosomia.
Large right atrium, abnormal cardiac axis and, **463**

INDEX

- Large stomach, **485**
- Larsen syndrome, atelosteogenesis vs., **703**
- Laryngeal stenosis, atelosteogenesis and, **703**
- Laryngotracheal groove, development, **322**
- Laryngotracheomalacia, atelosteogenesis and, **703**
- Larynx, development, **322**
- Laser coagulation of placental vessels, **863**
- Lateral nasal process, **264, 265**
- Lateral ventricles, approach to imaging, **85**
- Left atrial appendage (LA) isomerism. *See* Heterotaxy/cardiosplenic syndromes.
- Left atrial (LA) isomerism, appendages associated with heterotaxy and cardiosplenic syndromes, **382**
- Left atrium, embryology and anatomy, **368, 369, 373**
- Left heart obstruction, atrioventricular septal defect and, **391**
- Left heart outflow obstruction
- coarctation/interrupted aortic arch vs., **413**
 - spectrum, aortic stenosis vs., **417**
- Left hepatic vein, embryology and anatomy, **481**
- Left kidney, embryology and anatomy, **481**
- Left lobe of liver, embryology and anatomy, **481**
- Left portal vein, embryology and anatomy, **372**
- Left pulmonary artery, embryology and anatomy, **372**
- Left pulmonary vein, embryology and anatomy, **369**
- Left superior vena cava, embryology and anatomy, **371**
- Left umbilical vein, embryology and anatomy, **481**
- Left umbilical vein branch, embryology and anatomy, **481**
- Left ventricle
- embryology and anatomy, **367, 368, 369, 373**
 - developing, **367**
 - hypoplastic left heart and, **409**
- Leg, **273**
- left, **579**
 - right, **579**
- Leiomyoma. *See also* Myoma, in pregnancy.
- Müllerian duct anomalies vs., **1071**
- Leiomyomata. *See* Myoma, in pregnancy.
- Lemon-shaped calvarium, abnormal vs., **216, 217**
- Lemon sign
- cavum septi pellucidi, absent and, **208**
 - Chiari 2 malformation and, **169**
- Lens, **266, 267**
- Lens placode, embryology and anatomy, **262**
- Lens vesicle, **265**
- Lenticulostriate vasculopathy, cytomegalovirus and, **1017**
- LEOPARD syndrome, cardiomyopathy and, **442**
- Lesser omentum, embryology and anatomy, **478**
- Lethal osteochondrodysplasia. *See* Thanatophoric dysplasia (TD).
- Lethal skeletal dysplasia. *See* Thanatophoric dysplasia (TD).
- Lethal type multiple pterygium syndrome, multiple pterygium syndromes vs., **975**
- Lethal-type popliteal pterygium, multiple pterygium syndromes vs., **975**
- Leukemia, **555**
- diagnostic checklist, **556**
 - genetics, **556**
 - lymphoblastic, acute, **556**
 - prognosis, **556**
- Leukemic infiltration, malignant liver tumors, **555**
- Levotransposition. *See* Transposition of great arteries (TGA).
- LGA (Large for gestational age). *See* Macrosomia.
- Ligamentum arteriosum, embryology and anatomy, **373**
- Ligamentum teres, embryology and anatomy, **373**
- Ligamentum venosum, embryology and anatomy, **373**
- Likelihood ratio, **884, 891**
- Limb anomalies
- gastroschisis and, **492**
 - syndactyly and, **752**
- Limb defects, valproate embryopathy vs., **1009**
- Limb reduction defects, **699**
- Cornelia de Lange syndrome vs., **941**
 - split hand/foot malformation vs., **755**
- Limb-body wall complex. *See* Body stalk anomaly.
- Limb-mammary syndrome (LMS), split hand/foot malformation and, **755**
- Lipomeningocele, spina bifida and, **237**
- Lipomyelomeningocele, **228**
- spina bifida and, **237**
- Lips
- embryology and anatomy, **262, 269**
 - imaging techniques, **274**
- Lissencephaly, **138–141**
- classification systems, **140**
 - diagnostic checklist, **140**
 - differential diagnosis, **139**
 - gestational age milestones for sulcation, **140**
 - pachygyria/polymicrogyria vs., **145**
 - prognosis, **140**
- Liver, **328, 329, 578, 579**
- approach to abdominal wall and gastrointestinal tract, **484**
 - embryology and anatomy, **475, 478, 479, 481, 483**
 - intracorporeal, omphalocele and, **498**
 - surface, **486**
- Liver calcifications, encephalomalacia/porencephaly and, **159**
- Liver cyst, within liver parenchyma, choledochal cyst vs., **549**
- Liver echogenicities, gallstones vs., **547**
- Liver tumors, malignant, **554–557**
- diagnostic checklist, **556**
 - differential diagnosis, **555–556**
 - genetics, **556**
 - prognosis, **556**
- Lobar holoprosencephaly, cavum septi pellucidi, absent vs., **208, 210**
- Lobule, **265**
- Long bone deficiency, split hand/foot malformation and, **755**
- Long bone shortening, approach to skeletal dysplasias and, **682**
- Long bones
- achondroplasia and, **695**
 - hypophosphatasia and, **715**
 - lower extremity, **686**
 - thanatophoric dysplasia and, **727**
 - upper extremity, **686–687**
- Looping, embryology and anatomy, **366**

INDEX

- Lop ear, **313**
- abnormal ears vs., **311**
- Low abdominal wall defect, cloacal exstrophy/OEIS syndrome and, **513**
- Low anal atresia, **531**
- Low risk group, neuroblastoma, **630**
- Lower extremity
- long bones, **686**
 - malformations, sirenomelia vs., **989**
- Lower lip, **269**
- Lower urinary tract obstruction (LUTO), **485, 635**
- cystic abdominal mass vs., **562, 564**
 - obstructive renal dysplasia and, **611**
 - urachal anomalies vs., **647**
 - urinary tract dilation vs., **585**
- Lower vagina from urogenital sinus, **576**
- Low-set ear, abnormal ears vs., **311**
- L-transposition. *See* Transposition of great arteries (TGA).
- Lumbar spine, embryology and anatomy, **483**
- Lumbosacral anomalies, hydrocolpos vs., **663**
- Lung base, embryology and anatomy, **483**
- Lung bud, **477**
- development, **322**
- Lung development, **322–329**
- alveolar stage (36 weeks to 8 years), **323, 327**
 - canalicular stage (16–28 weeks), **322–323, 327**
 - embryonic stage (26 days to 6 weeks), **322**
 - general concepts, **322**
 - neonatal lung, **323**
 - other developmental requirements, **323**
 - pseudoglandular stage (6–16 weeks), **322, 326**
 - saccular stage (28–36 weeks), **323, 327**
- Lung masses
- mediastinal teratoma vs., **355**
 - pericardial teratoma vs., **451**
- Lung parenchyma, development, **322**
- Lung:head ratio (LHR), **333**
- Lungs, **329, 579**
- embryology and anatomy, **481, 483**
 - fetal, **328**
 - lobes of, **326**
 - primitive, **324**
- LUTO. *See* Lower urinary tract obstruction (LUTO).
- Lying down adrenal sign, **581**
- Lymph sacs, embryology and anatomy, **263**
- Lymphangioma, **350–353**
- abdominal/pelvic, cloacal malformation/urogenital sinus vs., **533**
 - associated abnormalities, **352**
 - body/trunk, cystic hygroma vs., **299**
 - chest or neck, Turner syndrome vs., **909**
 - cleft lip, palate vs., **280**
 - cystic abdominal mass vs., **562, 565**
 - cystic chest mass vs., **360, 361**
 - dacryocystocele vs., **285**
 - diagnostic checklist, **352**
 - differential diagnosis, **351**
 - embryology, **263**
 - genetics, **352**
 - mediastinal teratoma vs., **355**
 - mesenteric, mesenchymal hamartoma vs., **553**
 - ovarian cyst vs., **659**
 - prognosis, **352**
 - tongue, macroglossia vs., **318**
 - urinoma vs., **609**
 - without Klippel-Trenaunay-Weber, Klippel-Trenaunay-Weber syndrome vs., **967**
- Lymphatics, embryology and anatomy, **262, 263, 272**
- Lymphoblastic leukemia, acute, **556**
- Lymphovascular malformation, **309**
- abnormal orbits/eyes vs., **304**
 - mesenteric or abdominal. *See* Mesenteric lymphangioma.
- Lysergic acid diethylamide, amniotic band syndrome and, **925**
- ## M
- Macrocephaly
- arachnoid cyst vs., **151**
 - calvarium, abnormal vs., **217**
 - hydranencephaly and, **163**
 - intracranial hemorrhage vs., **155**
- Macrocystic congenital pulmonary airway malformation, cystic chest mass vs., **360, 361**
- Macroglossia, **318–319**
- differential diagnosis, **318**
 - epignathus vs., **289**
 - epulis vs., **293**
- Macrosomia, **1038–1039**
- associated with maternal diabetes, Beckwith-Wiedemann syndrome vs., **933**
 - diabetic embryopathy vs., **947**
 - diagnostic checklist, **1039**
 - differential diagnosis, **1039**
 - polyhydramnios vs., **1044, 1045**
 - prognosis, **1039**
- Magnetic resonance imaging
- approach to abdominal wall and gastrointestinal tract, **484**
 - posterior fossa, **90**
 - supratentorial brain, **84**
- Main portal vein, embryology and anatomy, **481**
- Main pulmonary artery, **374**
- embryology and anatomy, **369, 373**
- Main stem villus, **786**
- Mainzer-Saldino syndrome, short rib-polydactyly syndrome vs., **724**
- Majewski syndrome, polydactyly vs., **748**
- Malar bone, **271**
- Maldescended testes, bladder exstrophy and, **510**
- Malformation, cloacal
- hydrocolpos vs., **663**
 - posterior urethral valves vs., **635**
 - prune-belly syndrome vs., **639**
- Malrotation
- jejunal/ileal atresia and, **526**
 - omphalocele and, **498**
 - volvulus and, **537**
- Mammary artery, internal, **329**

INDEX

- Mammary vein, right internal, **329**
- Mandible, **268, 270**
- embryology and anatomy, **262**
 - imaging techniques, **274**
 - measurements, **275**
- Mandibular prominence, **264**
- embryology and anatomy, **480**
- Mandibular prominence primordia, **265**
- Mandibular symphysis, **271**
- Mandibulofacial dysostosis. *See* Treacher Collins syndrome (TCS).
- Marginal placental abruption, **791**
- vasa previa vs., **799**
- Marginal sinus placenta previa, **795**
- Marginal sinus previa, vasa previa vs., **799**
- Marginal/velamentous cord insertion, **814–815**
- associated abnormalities, **815**
 - diagnostic checklist, **815**
 - differential diagnosis, **815**
 - gross pathologic and surgical features, **815**
 - prognosis, **815**
- MASA, aqueductal stenosis and, **166**
- Masses
- chest, hydrops vs., **1053, 1057**
 - fetal, hydrops vs., **1053**
- Maternal age, genetic screening, **885**
- Maternal collagen vascular disease, warfarin embryopathy vs., **1011**
- Maternal conditions in pregnancy
- acute abdomen, **1082–1085**
 - cervical insufficiency, **1060–1065**
 - intrauterine linear echoes, **1086–1089**
 - Müllerian duct anomalies, **1070–1073**
 - myoma, **1066–1069**
 - short cervix, **1060–1065**
 - synechiae, **1074–1075**
 - uterine rupture, **1076–1079**
- Maternal diabetes
- cardiomyopathy and, **442**
 - macrosomia associated with, Beckwith-Wiedemann syndrome vs., **933**
- Maternal hypertensive disorders, placental lakes associated, **808**
- Maternal thrombocytopenia, intracranial hemorrhage and, **155**
- Maxilla, **268, 270, 271**
- imaging techniques, **274**
- Maxillary prominence, **264, 265**
- embryology and anatomy, **262, 480**
- Maxillary prominence primordia, **265**
- Maxillofacial dysplasia, binder, chondrodysplasia punctata vs., **712**
- Maximum vertical pocket (MVP), **1028**
- fetal genitourinary tract, **580**
- MCDK. *See* Multicystic dysplastic kidney.
- McKusick-Kaufman syndrome, hydrocolpos and, **663**
- Mean velocity, across any valve, **375**
- MEBD (Muscle-eye-brain disease). *See* Muscle-eye-brain disease.
- Meckel-Gruber syndrome, **669, 970–973**
- agenesis of corpus callosum associated with, **110**
 - alobar holoprosencephaly associated with, **120**
 - autosomal recessive polycystic kidney disease vs., **619**
 - Dandy-Walker malformation and, **176**
 - diagnostic checklist, **972**
 - differential diagnosis, **971**
 - echogenic kidneys vs., **668**
 - genetics, **972**
 - polydactyly vs., **747**
 - prognosis, **972**
 - trisomy 13 vs., **904**
 - unilateral enlarged kidney vs., **670**
- Meconium filled colon, approach to abdominal wall and gastrointestinal tract, **484**
- Meconium ileus
- jejunal/ileal atresia vs., **525**
 - meconium peritonitis/pseudocyst and, **542**
- Meconium peritonitis
- gallstones vs., **547**
 - jejunal/ileal atresia and, **525**
 - mimic, echogenic bowel vs., **558, 559**
 - pseudocyst, **540–543**
 - diagnostic checklist, **542**
 - differential diagnosis, **541**
 - etiology, **542**
 - genetics, **542**
 - prognosis, **542**
- Meconium pseudocyst, **485**
- choledochal cyst vs., **549**
 - cystic abdominal mass vs., **562, 564**
 - enteric duplication cyst vs., **539**
 - fetus-in fetu vs., **879**
 - mesenteric lymphangioma vs., **545**
 - ovarian cyst vs., **659**
 - umbilical vein varix vs., **827**
 - urachal anomalies vs., **647**
 - urinoma vs., **609**
- Meconium-filled rectum, anal atresia and, **531**
- Medial epicanthus of eye, **265, 267, 268**
- Medial nasal process, **264, 265**
- Medial umbilical ligaments, embryology and anatomy, **373**
- Median philtrum-premaxilla anlage, alobar holoprosencephaly associated with, **120**
- Median raphe, **571**
- Median umbilical ligament, **570**
- Mediastinal/pulmonary teratoma, pericardial teratoma vs., **451**
- Mediastinal teratoma, **354–355**
- diagnostic checklist, **355**
 - differential diagnosis, **355**
 - prognosis, **355**
 - solid/echogenic chest mass vs., **356, 357**
- Mediastinum, variable displacement of, pentalogy of Cantrell and, **503**
- Medulla, adrenal, **570, 578**
- Mega cisterna magna (MCM), **184–185**
- Blake pouch cyst vs., **181**
 - cerebellar hypoplasia vs., **187**
 - Dandy-Walker malformation vs., **175**
 - diagnostic checklist, **185**

INDEX

- differential diagnosis, **185**
- Joubert syndrome vs., **963**
- posterior fossa cyst/fluid collection vs., **222**
- prognosis, **185**
- trisomy 13 and, **903**
- vermian dysgenesis, **179**
- Megacystis
 - trisomy 13 and, **903**
 - trisomy 18 and, **897**
- Megacystis-microcolon, posterior urethral valves vs., **635**
- Megacystis-microcolon-intestinal hypoperistalsis syndrome, prune-belly syndrome vs., **639**
- Megalencephaly, Apert syndrome and, **929**
- Megaureter, congenital
 - duplicated collecting system vs., **591**
 - ureterocele vs., **644**
- Melanoma, chorioangioma vs., **818**
- Membranous atresia, jejunal/ileal atresia and, **526**
- Membranous defect, ventricular septal defect and, **389**
- Membranous neurocranium, **270**
- Membranous septum, embryology and anatomy, **369**
- Membranous viscerocranium, **270**
- Meningioma, brain tumors and, **203**
- Meningocele, spina bifida and, **237**
- Meningoencephalocele. *See* Frontal cephalocele.
- Menstrual dating, **17**
- Mermaid syndrome. *See* Sirenomelia.
- Mesenchymal connective tissue, **326, 327**
- Mesenchymal dysplasia, placental, **822–823**
 - associated abnormalities, **823**
 - diagnostic checklist, **823**
 - differential diagnosis, **823**
 - genetics, **823**
 - placental cysts and masses vs., **831, 833**
 - prognosis, **823**
 - triploidy vs., **913**
- Mesenchymal hamartoma, **552–553**. *See also* Mesoblastic nephroma.
 - associated abnormalities, **553**
 - diagnostic checklist, **553**
 - differential diagnosis, **553**
 - prognosis, **553**
- Mesenchyme, primitive, **324, 325**
- Mesenteric cyst. *See also* Mesenteric lymphangioma.
 - choledochal cyst vs., **549**
 - cystic abdominal mass vs., **562, 565**
 - duodenal atresia vs., **522**
 - enteric duplication cyst vs., **539**
 - meconium peritonitis/pseudocyst vs., **542**
 - ovarian cyst vs., **659**
 - urachal anomalies vs., **647**
 - urinoma vs., **609**
- Mesenteric lymphangioma, **544–545**
 - diagnostic checklist, **545**
 - differential diagnosis, **545**
 - mesenchymal hamartoma vs., **553**
 - prognosis, **545**
- Mesenteric or abdominal lymphovascular malformation. *See* Mesenteric lymphangioma.
- Mesoblastic nephroma, **622–625, 672**
 - associated abnormalities, **624**
 - congenital, polyhydramnios vs., **1045, 1047**
 - diagnostic checklist, **624**
 - differential diagnosis, **623–624**
 - duplicated collecting system vs., **591**
 - fetus-in fetu vs., **879**
 - genetics, **624**
 - prognosis, **624**
 - unilateral enlarged kidney vs., **670**
- Mesoderm, **228**
- Mesodermal-derived mesenchyme, **325**
- Mesomelia, **680**
- Mesonephric duct, **570, 571, 572, 573, 577**
- Mesonephric tubule, **572**
- Mesonephroi, **570, 572**
- Mesonephros, **573**
 - developing kidney, **576**
- Metabolic syndrome, Turner syndrome and, **910**
- Metanephric blastema, **570, 572**
- Metanephric diverticulum, **570**
- Metanephros, **572, 577**
- Metastases
 - malignant liver tumors, **555**
 - placental, chorioangioma vs., **817–818**
- Methadone, amniotic band syndrome and, **925**
- Metopic suture, **271**
- Microcephaly, **85**
 - calvarium, abnormal vs., **217, 220**
 - Chiari 3 malformation and, **173**
 - cytomegalovirus and, **1017**
 - severe, exencephaly/anencephaly vs., **97**
 - trisomy 13 and, **903**
- Microcystic congenital pulmonary airway malformation, solid/echogenic chest mass vs., **356, 357**
- Microdeletion of chromosome 22, truncus arteriosus and, **433**
- Micrognathia, **314–317**
 - atelosteogenesis and, **703**
 - differential diagnosis, **314**
 - isolated, Pierre Robin sequence vs., **987**
 - severe, Treacher Collins syndrome (TCS) vs., **997**
 - trisomy 18 and, **897**
- Micromelia, **680, 699**
- Micropenis, hypospadias vs., **657**
- Microphthalmia, **309**
 - abnormal orbits/eyes vs., **305**
 - Aicardi syndrome and, **921, 922**
 - coloboma vs., **287**
 - Fraser syndrome vs., **951**
 - trisomy 18 and, **897**
 - warfarin embryopathy and, **1011**
- Microphthalmos, trisomy 13 and, **903**
- Midbrain pons, **266**
- Midface, imaging techniques, **274**
- Midface hypoplasia
 - with depressed nasal bridge, atelosteogenesis and, **703**
 - trisomy 21 and, **891**
- Midgut, **477**
 - embryo, **476**
- Midline cleft lip, echogenic kidneys and, **668**
- Mild ventriculomegaly, arachnoid cyst vs., **151**

INDEX

- Mildly short femur/humerus, **770–773**
- differential diagnosis, **770–771**
- idiopathic, **770, 771**
- Miller-Dieker syndrome, **139**
- Mineralization, approach to skeletal dysplasias and, **682**
- Minimally conjoined omphalopagus twins, **871**
- Minor antigen alloimmune syndromes, fetal anemia vs., **1041**
- Mirror syndrome, sacrococcygeal teratoma and, **256**
- Mitral valve (MV)
- coarctation/interrupted aortic arch and, **413**
- embryology and anatomy, **368, 369**
- hypoplastic left heart and, **409**
- Mitten syndactyly, Apert syndrome and, **929**
- Mixed total anomalous pulmonary venous return, **421**
- M-mode, heart rate, **376**
- Moderator band, embryology and anatomy, **368**
- Modified McGoon index, **333**
- Mohr syndrome, polydactyly vs., **748**
- Mohr-Majewski syndrome, short rib-polydactyly syndrome vs., **724**
- Molar tooth sign, Joubert syndrome, **91**
- Mole, partial, placental lake vs., **807**
- Monitor abdominal circumference (AC), autosomal recessive polycystic kidney disease, **620**
- Monoamniotic twins, **840**
- monochorionic, dichorionic diamniotic twins vs., **847**
- Monochorionic diamniotic twins, **840, 850–853**
- diagnostic checklist, **852**
- dichorionic diamniotic twins vs., **847**
- differential diagnosis, **851**
- embryology, **852**
- genetics, **852**
- impact of discordant growth, **860**
- intrauterine linear echoes vs., **1086, 1087, 1088**
- prognosis, **852**
- Monochorionic monoamniotic twins, **854–857**
- associated anomalies, **855**
- conjoined twins vs., **871**
- diagnostic checklist, **856**
- dichorionic diamniotic twins vs., **847**
- differential diagnosis, **855**
- monochorionic diamniotic twins vs., **851**
- prognosis, **856**
- Monochorionic placentation, complications, **841**
- Monochorionic twin demise, encephalomalacia/porencephaly and, **159**
- Monochorionic twinning, **840**
- conjoined, **840**
- diamniotic, **840**
- impact of chorionicity, **842**
- monoamniotic, **840**
- sonographic monitoring, **842**
- Monosomy X. *See* Turner syndrome.
- Morbidly adherent placentation, uterine rupture vs., **1077**
- Morula, **6**
- Mouth
- anomalies, embryology, **263**
- formation, **480**
- MR, fetal genitourinary tract, **580**
- Mucocele. *See* Dacryocystocele.
- Muenke syndrome, Pfeiffer syndrome vs., **983**
- Müllerian anomalies, Apert syndrome and, **929**
- Müllerian duct anomalies in pregnancy, **1070–1073**
- associated abnormalities, **1071**
- diagnostic checklist, **1072**
- differential diagnosis, **1071**
- embryology, **1071**
- prognosis, **1072**
- staging, grading, & classification, **1071–1072**
- Müllerian inhibiting factor, **571**
- Multicystic dysplastic kidney, **614–617**
- bilateral, **615**
- bilateral, autosomal recessive polycystic kidney disease vs., **619**
- bilateral, bilateral renal agenesis vs., **601**
- bilateral, bladder exstrophy vs., **509**
- bilateral, Meckel-Gruber syndrome vs., **972**
- cloacal malformation/urogenital sinus and, **533**
- cystic abdominal mass vs., **562, 563**
- diagnostic checklist, **616**
- differential diagnosis, **615**
- duplicated collecting system vs., **591**
- genetics, **616**
- mesoblastic nephroma vs., **623**
- obstructive renal dysplasia vs., **611**
- oligohydramnios vs., **1048, 1050**
- ovarian cyst vs., **659**
- prognosis, **616**
- proposed mechanisms, **570**
- unilateral, **615, 616**
- ureteropelvic junction obstruction vs., **605**
- urinoma vs., **609**
- Multiple congenital anomaly disorders with single gene mutation, arachnoid cyst and, **152**
- Multiple congenital contractures. *See* Arthrogryposis/akinesia sequence.
- Multiple discrete cysts, **581**
- Multiple gestations
- approach to, **840–845**
 chorionicity/amnionicity, **840**
 conjoined fetuses, **841**
 embryology, **840**
 growth discordance or selective growth restriction, **841**
 imaging techniques, **840**
 major anomaly, **841**
 maternal complications, **842**
 normal anatomy, **840**
 number of embryos, **840**
 placental cord insertion sites, **841**
 preterm birth, **842**
 risk of aneuploidy, increased, **841**
 role of Doppler, **841**
 second and third trimester, anomalies, **841**
 sonographic monitoring, **842**
- conjoined twins, **870–873**
- dichorionic diamniotic twins, **846–849**
- discordant twin growth, **858–861**
- fetal growth restriction with, **1035**
- fetus-in-fetu, **878–881**
- monochorionic diamniotic twins, **850–853**

INDEX

- monochorionic monoamniotic twins, **854–857**
 - triplets and beyond, **874–877**
 - twin reversed arterial perfusion, **866–869**
 - twin-twin transfusion syndrome, **862–865**
 - Multiple pterygium syndromes, **974–975**
 - arthrogryposis/akinesia sequence vs., **759**
 - differential diagnosis, **975**
 - Escobar variant, multiple pterygium syndromes vs., **975**
 - genetics, **975**
 - lethal type, multiple pterygium syndromes vs., **975**
 - Neu-Laxova syndrome vs., **977**
 - prognosis, **975**
 - rocker-bottom foot and, **737**
 - MURCS association, VACTERL association vs., **1006**
 - Muscle-eye-brain disease, Walker-Warburg syndrome vs., **1013**
 - Muscular atrophy, spinal, arthrogryposis/akinesia sequence vs., **760**
 - Muscular defect, ventricular septal defect and, **389**
 - Musculoskeletal dysfunction, Chiari 2 malformation and, **170**
 - Musculoskeletal system
 - abnormal ossification, **780–781**
 - achondrogenesis/hypochondrogenesis, **688–693**
 - achondroplasia and, **694–697**
 - amelia/phocomelia, **698–701**
 - angulated bones, **774–779**
 - approach to skeletal dysplasias, **680–685**
 - key measurements, **681**
 - lethality vs. nonlethality, **680**
 - arthrogryposis/akinesia sequence, **758–763**
 - atelosteogenesis, **702–705**
 - micromelia vs., **700**
 - type II, achondrogenesis/hypochondrogenesis vs., **689**
 - campomelic dysplasia, **706–709**
 - osteogenesis imperfecta vs., **719**
 - thanatophoric dysplasia vs., **727**
 - chondrodysplasia punctata, **710–713**
 - clinodactyly, **744–745**
 - clubfoot, **732–735**
 - embryology and anatomy
 - organogenesis, **5**
 - fibular/tibial hemimelia, **768–769**
 - hypophosphatasia, **714–717**
 - mildly short femur/humerus, **770–773**
 - osteogenesis imperfecta, **718–721**
 - polydactyly, **746–749**
 - proximal focal femoral dysplasia, **764–767**
 - radial ray malformation, **740–743**
 - rocker-bottom foot, **736–737**
 - clubfoot vs., **733**
 - sandal gap foot, **738–739**
 - short rib-polydactyly syndrome, **722–725**
 - split hand/foot malformation, **754–757**
 - syndactyly, **750–753**
 - thanatophoric dysplasia, **726–731**
 - MVP (Maximum vertical pocket). *See* Maximum vertical pocket (MVP).
 - Myasthenia gravis, arthrogryposis/akinesia sequence vs., **760**
 - MYCN* amplification, neuroblastoma, **630**
 - Myelination, **68**
 - Myelocystocele, **228**
 - Myelocystocele, terminal, sacrococcygeal teratoma vs., **255**
 - Myeloid leukemia, associated with Down syndrome, **556**
 - Myelomeningocele, **228**
 - aqueductal stenosis vs., **166**
 - caudal regression sequence vs., **245**
 - sacrococcygeal teratoma vs., **255**
 - Myelopoiesis, transient abnormal, **556**
 - Myeloschisis, spina bifida and, **237**
 - Myoblastic myoma. *See* Epulis.
 - Myoblastoma, epignathus vs., **289**
 - Myocardial ischemia, infantile, idiopathic infantile arterial calcification vs., **961**
 - Myocardium, normal peripheral, pericardial effusion vs., **449**
 - Myofibromatosis
 - cervical teratoma vs., **303**
 - epignathus vs., **289**
 - Myoma
 - placental abruption vs., **791**
 - placental implantation on, placental cysts and masses vs., **830, 832**
 - in pregnancy, **1066–1069**
 - diagnostic checklist, **1068**
 - differential diagnosis, **1067**
 - genetics, **1067**
 - prognosis, **1068**
 - Myometrial contraction, focal, **785**
 - myoma in pregnancy vs., **1067**
 - placenta previa vs., **795**
 - placental abruption vs., **791**
 - placental cysts and masses vs., **830, 831**
 - succenturiate lobe vs., **811**
 - Myometrium, **786**
 - Myotomes, **229**
 - Myotonic dystrophy, clubfoot and, **733**
 - Myxoma, rhabdomyoma vs., **445**
- ## N
- Nabothian cyst
 - cervical ectopic pregnancy vs., **45**
 - cervical insufficiency vs., **1061**
 - short cervix vs., **1061**
 - Nager acrofacial dysostosis, radial ray malformation vs., **742**
 - Nager syndrome, micrognathia and, **315, 317**
 - Nares, **269**
 - Nasal bone, **266, 268, 270, 271, 884, 886**
 - absent, trisomy 21 and, **891**
 - Nasal encephalocele, dacryocystocele vs., **285**
 - Nasal glioma
 - epignathus vs., **289**
 - frontal cephalocele vs., **107**
 - Nasal pit, **264**
 - embryology and anatomy, **480**
 - on nasal plate, **264**

INDEX

- Nasal placodes, embryology and anatomy, **262**
- Nasal prominences, medial and lateral, embryology and anatomy, **262**
- Nasolacrimal groove, **264**
- Nasolateral prominence, embryology and anatomy, **480**
- Nasomedial prominence, embryology and anatomy, **480**
- Nasopharyngeal teratoma. *See* Epignathus.
- Neck. *See* Face and neck.
- Necrotizing enterocolitis, gastroschisis and, **492**
- Neonatal autopsy, CHARGE syndrome, **939**
- Neonatal circulation, embryology and anatomy, **365**
- Neonatal diagnosis, meconium peritonitis/pseudocyst, **542**
- Neonatal GMH grading system, **156**
- Neonatal hyperparathyroidism (severe form),
hypophosphatasia vs., **715**
- Neonatal period, Beckwith-Wiedemann syndrome, **934**
- Neoplasms, intraabdominal, ovarian cyst vs., **659**
- Nephrocalcinosis, hypophosphatasia and, **715**
- Nephroma, mesoblastic, **622–625, 672**
- associated abnormalities, **624**
 - congenital, polyhydramnios vs., **1045, 1047**
 - diagnostic checklist, **624**
 - differential diagnosis, **623–624**
 - duplicated collecting system vs., **591**
 - fetus-in fetu vs., **879**
 - genetics, **624**
 - prognosis, **624**
 - unilateral enlarged kidney vs., **670**
- Nephrotomes, cervical, **572**
- Neu-Laxova syndrome, **976–977**
- diagnostic checklist, **977**
 - differential diagnosis, **977**
 - genetics, **977**
 - micrognathia and, **315**
 - prognosis, **977**
- Neumann tumor. *See* Epulis.
- Neural arch ossification center, **232**
- Neural canal, **228**
- Neural crest, **231**
- Neural crest cells, **228, 230**
- Neural ectoderm, **230**
- Neural fold, **231**
- fusion of, **230**
- Neural groove, **230, 231**
- Neural plate, **228, 230**
- Neural tube, **476, 477, 572**
- closure, failure of, **229**
 - embryology, **230–231**
 - formation, **68–69, 228**
- Neural tube defects. *See also* Spina bifida.
- Dandy-Walker malformation and, **175**
 - diabetic embryopathy vs., **947**
 - hypospadias and, **657**
 - isolated open, iniencephaly vs., **243**
 - valproate embryopathy vs., **1009**
- Neurenteric cyst
- bronchogenic cyst vs., **345**
 - congenital pulmonary airway malformation vs., **337**
 - cystic chest mass vs., **360, 361**
- Neuroblastoma, **628–631, 675**
- adrenal hemorrhage vs., **627**
 - biologic markers, **630**
 - bronchopulmonary sequestration vs., **341–342**
 - cervical, goiter vs., **295**
 - cervical teratoma vs., **303**
 - chorioangioma vs., **818**
 - congenital adrenal hyperplasia vs., **633**
 - cystic abdominal mass vs., **563, 566**
 - diagnostic checklist, **630**
 - differential diagnosis, **629**
 - fetus-in fetu vs., **879**
 - gallstones vs., **547**
 - genetics, **629**
 - mediastinal teratoma vs., **355**
 - metastatic, **555**
 - congenital hepatic hemangioma vs., **551**
 - diagnostic checklist, **556**
 - prognosis, **556**
 - prognosis, **630**
 - staging, grading, & classification, **629–630**
 - suprarenal mass vs., **674**
- Neuroepithelial cyst. *See* Interhemispheric cyst/AVID.
- Neurofibromatosis-Noonan syndrome, Noonan syndrome vs., **979**
- Neurofibromatosis type 1, arachnoid cyst and, **152**
- Neuronal migration, **68**
- Neuronal proliferation, **68**
- Neuropores, **228**
- cranial, **230**
- Neurotropic virus, varicella and, **1025**
- Neurulation, **68**
- Nondysjunction, **228**
- Nongastrointestinal abnormalities, gastroschisis and, **492**
- Nonimmune hydrops, cytomegalovirus vs., **1017**
- Nonobstructive renal dysplasia, obstructive renal dysplasia vs., **611**
- Noonan syndrome, **978–979**
- cardiomyopathy and, **442**
 - diagnostic checklist, **979**
 - differential diagnosis, **979**
 - genetics, **979**
 - prognosis, **979**
 - Turner syndrome vs., **909**
- Normal cervix
- cervical insufficiency vs., **1061**
 - short cervix vs., **1061**
- Normal cord insertion, **484**
- Normal foramen ovale, atrial septal aneurysm vs., **395**
- Normal postpartum uterus, retained products of conception vs., **1081**
- "Normal" superior vena cava, embryology and anatomy, **371**
- Normal third-trimester colon, anal atresia vs., **531**
- Normal variant conus, tethered cord vs., **251**
- Norwood, staging, hypoplastic left heart and, **410**
- Nose
- anomalies, embryology, **263**
 - embryology and anatomy, **262, 268**
 - imaging techniques, **274**
 - skin, tip of, **268**
- Nosology Group of the International Skeletal Dysplasia Society, **680**

INDEX

- Nostrils, **264, 269**
NOTCH1 mutations, coarctation/interrupted aortic arch and, **413**
NOTCH2 associated with Alagille syndrome, tetralogy of Fallot and, **425**
Notochord, **229, 230, 231**
- abnormal separation from, enteric duplication cyst, **539**
- development, **68**
Nuchal cord, **785**
Nuchal cystic hygroma, lymphangioma vs., **351**
Nuchal fold thickness, trisomy 21 and, **891**
Nuchal lymphangioma. *See* Cystic hygroma.
Nuchal translucency, **884, 886**
- accurate measurement, **887**
- ## O
- OAVS (Oculo-auriculo-vertebral spectrum). *See* Goldenhar syndrome.
Obstructed total anomalous pulmonary venous return, **422**
Obstruction
- fetal bowel, polyhydramnios vs., **1044–1045, 1046**
- rhabdomyoma and, **445**
Obstructive cystic dysplasia, **669**
- echogenic kidneys vs., **668**
Obstructive hydrocephalus, Chiari 2 malformation and, **170**
Obstructive renal dysplasia, **610–613**
- associated abnormalities, **612**
- diagnostic checklist, **612**
- differential diagnosis, **611–612**
- prognosis, **612**
Occipital bone, **270**
- squama of, **270**
Occipital cephalocele, isolated/syndromic, Chiari 3 malformation vs., **173**
Occipital contour, approach to imaging, **90**
Occipital encephalocele
- cystic hygroma vs., **299**
- Dandy-Walker malformation and, **175**
Occipital/parietal cephalocele, **100–103**
- associated abnormalities, **102**
- diagnostic checklist, **102**
- differential diagnosis, **101–102**
- prognosis, **102**
Ocular and orbit diameters, **275**
Oculo-auriculo-vertebral spectrum. *See* Goldenhar syndrome.
Oculo-auriculo-vertebral syndrome, intracranial lipoma and, **207**
OEIS complex, **513**
OEIS syndrome. *See* Cloacal exstrophy/OEIS syndrome.
OEP. *See* Ovarian ectopic pregnancy (OEP).
OI. *See* Osteogenesis imperfecta (OI).
Oligohydramnios, **315, 1048–1051**
- causes for, bilateral renal agenesis vs., **601**
- cloacal malformation/urogenital sinus and, **533**
- clubfoot and, **733**
- differential diagnosis, **1048**
- duplicated collecting system and, **591**
- gastroschisis and, **491**
- hydronephrosis and, **664**
- micrognathia vs., **314**
- posterior urethral valves and, **635**
- prune-belly syndrome and, **639**
- sacrococcygeal teratoma and, **255**
- twin-twin transfusion syndrome and, **863**
- urachal anomalies vs., **647**
- without placental insufficiency, fetal growth restriction vs., **1035**
Oligohydramnios sequence, bilateral renal agenesis and, **602**
Omental cyst. *See* Mesenteric lymphangioma.
Omphalocele, **496–501, 835, 836**
- amniotic band syndrome vs., **925**
- approach to, **484–485**
- associated abnormalities, **498**
- body stalk anomaly vs., **505**
- diagnostic checklist, **498**
- differential diagnosis, **497–498**
- differentiation, **514**
- ectopia cordis associated with, **385**
- embryology, **475**
- gastroschisis vs., **491**
- genetics, **498**
- isolated
 cloacal exstrophy/OEIS syndrome vs., **513**
 pentalogy of Cantrell vs., **503**
- membrane, **497**
- prognosis, **498**
- Smith-Lemli-Opitz syndrome vs., **993**
- staging, grading, & classification, **498**
- syndromes, **498**
- trisomy 13 and, **903**
- trisomy 18 and, **897**
- urachal anomalies vs., **647**
- volvulus and, **537**
Omphalomesenteric arteries, embryology and anatomy, **474**
Omphalomesenteric duct cyst, **834**
- omphalocele vs., **497**
Omphalomesenteric remnant, urachal anomalies and, **648**
Omphalopagus twins, **871**
Oocyte
- extruded from ovary, **6**
- surrounded by cumulus cells, **6**
- swept into tube by fimbria, **6**
Open defects, amniotic band syndrome vs., **925**
Open eyelids, **267**
Open neural tube defect (ONTD), Chiari 2 malformation and, **168**
Open spinal dysraphism, tethered cord and, **251**
Open-lip schizencephaly, hydranencephaly vs., **163**
Operculization, **68**
Opitz-Frias syndrome, hypospadias and, **657**
Optic atrophy, warfarin embryopathy and, **1011**
Oral-facial-digital syndrome, type I (OFD1), syndactyly vs., **751–752**
Oral-facial-digital syndrome II, polydactyly vs., **748**

INDEX

- Orbital diameter, **267**
- Orbits, **266**
- abnormal, **304–309**
 - differential diagnosis, **304**
 - embryology and anatomy, **262–263**
 - ocular and orbit diameters, **275**
 - solid mass, abnormal orbits/eyes vs., **304**
- ORD. *See* Obstructive renal dysplasia.
- Organogenesis, **4–5**
- abdominal wall, **14**
 - cardiovascular system, **4–5**
 - central nervous system, **4**
 - gastrointestinal tract, **5, 14**
 - genitourinary system, **5**
 - musculoskeletal system, **5**
 - respiratory system, **5**
- Orofacial clefts, short rib-polydactyly syndrome and, **724**
- Oropharyngeal membrane, embryology and anatomy, **480**
- Oropharyngeal teratoma. *See* Epignathus.
- Orthotopic ureterocele, **644**
- Ossification, abnormal, **780–781**
- differential diagnosis, **780**
- Ossification stage, of vertebral body development, **229**
- Osteogenesis imperfecta (OI), **718–721**
- abnormal ossification vs., **780, 781**
 - achondrogenesis/hypochondrogenesis vs., **689**
 - achondroplasia vs., **695**
 - amniotic band syndrome and, **925**
 - angulated bones and, **774, 776**
 - associated abnormalities, **719**
 - calvarium, abnormal vs., **217, 220**
 - campomelic dysplasia vs., **707**
 - differential diagnosis, **719**
 - genetics, **719**
 - hypophosphatasia vs., **715**
 - mildly short femur/humerus and, **771, 773**
 - prognosis, **720**
 - staging, grading, & classification, **719–720**
 - thanatophoric dysplasia vs., **727**
 - type II, micromelia vs., **700**
- Otocephaly, micrognathia vs., **314**
- Outflow tract, embryology and anatomy, **367**
- Outlet defect, ventricular septal defect and, **389**
- Ovarian cyst, **485, 658–661**
- choledochal cyst vs., **549**
 - cloacal malformation/urogenital sinus vs., **533**
 - cystic abdominal mass vs., **562, 565**
 - diagnostic checklist, **660**
 - differential diagnosis, **659**
 - duodenal atresia vs., **521**
 - enteric duplication cyst vs., **539**
 - hydrocolpos vs., **663**
 - meconium peritonitis/pseudocyst vs., **542**
 - mesenteric lymphangioma vs., **545**
 - prognosis, **660**
 - umbilical vein varix vs., **827**
 - urachal anomalies vs., **647**
- Ovarian ectopic pregnancy (OEP), **52–53**
- associated abnormalities, **53**
 - diagnostic checklist, **53**
 - differential diagnosis, **53**
 - prognosis, **53**
 - staging, grading, & classification, **53**
 - tubal ectopic pregnancy vs., **35**
- Ovarian hyperstimulation syndrome, triplets and, **875**
- Ovarian mass, incidental, ovarian ectopic pregnancy vs., **53**
- Ovarian torsion, acute abdomen in pregnancy vs., **1082–1083, 1084**
- Ovaries, **571**
- Overgrowth syndromes, Beckwith-Wiedemann syndrome vs., **933**
- Ovulation, **4, 6**
- ## P
- PA (pulmonary valve atresia), **404–407**
- PA with intact ventricular septum (IVS) subtype, pulmonary stenosis/atresia and, **405, 406**
- PA with ventricular septal defect (VSD) subtype, pulmonary stenosis/atresia and, **405, 406**
- Pachygyria/polymicrogyria, **139, 144–147**
- Aicardi syndrome and, **921**
 - associated abnormalities, **145**
 - diagnostic checklist, **145**
 - differential diagnosis, **145**
 - prognosis, **145**
- Paired frontal bones, **268**
- Palate, **268**
- cleft. *See* Cleft lip/palate.
 - embryology and anatomy, **262, 264, 269**
- Palatine shelf, **264**
- Pallister-Hall syndrome
- esophageal atresia and, **518**
 - polydactyly vs., **747**
- Pallister-Killian syndrome
- congenital diaphragmatic hernia associated with, **334**
 - Cornelia de Lange syndrome vs., **941**
 - Fryns syndrome vs., **953**
- Pancreas, embryology and anatomy, **475, 478, 479**
- Pancreatic fibrosis, short rib-polydactyly syndrome and, **724**
- Pancreaticobiliary malfunction, choledochal cyst and, **549**
- PAPVR. *See* Partial anomalous pulmonary venous return (PAPVR).
- Paramesonephric (Müllerian) ducts, **576**
- Paraovarian cyst, adnexal mass in pregnancy vs., **63**
- Paraspinous mass, approach to fetal spine and, **234**
- Paraspinous muscles, **578, 579**
- Parietal bone, **271**
- Parietal peritoneum, **477**
- Parietooccipital sulcus, embryology and anatomy, **79**
- Partial anomalous pulmonary venous return (PAPVR), **420–423**
- total anomalous pulmonary venous return vs., **421**
- Partial atrioventricular block, bradyarrhythmia vs., **459**
- Partial duplication of 3q, Cornelia de Lange syndrome vs., **941**
- Partial mole. *See also* Triploidy.
- placental lake vs., **807**
 - placental mesenchymal dysplasia vs., **823**

INDEX

- Partial pulmonary venous connection (PAPVC), **420–423**
- Parvovirus, **1020–1021**
- cytomegalovirus vs., **1017**
 - differential diagnosis, **1021**
 - echogenic bowel vs., **558, 559**
 - prognosis, **1021**
- Parvovirus B19
- pericardial effusion and, **449**
 - varicella vs., **1025**
- Parvovirus infection, fetal anemia vs., **1041**
- Patau syndrome. *See* Trisomy 13.
- Patent ductus arteriosus, prune-belly syndrome and, **640**
- Patent urachus, **485, 647**
- PE. *See* Pericardial effusion (PE).
- Pedicle, **232**
- Pelvic inflammatory disease, ovarian ectopic pregnancy, **53**
- Pelvic kidney, **594–595**
- crossed fused ectopia vs., **599**
 - diagnostic checklist, **595**
 - differential diagnosis, **595**
 - obstructed, cloacal malformation/urogenital sinus vs., **533**
 - prognosis, **595**
 - unilateral renal agenesis vs., **589**
- Pelvic mass, pelvic kidney vs., **595**
- Pelvic organ prolapse common, bladder exstrophy and, **510**
- Pelviectasis. *See also* Urinary tract dilation.
- trisomy 21 and, **891**
- Pelvis
- maternal, **374**
 - thanatophoric dysplasia and, **727**
- Pena-Shokeir phenotype. *See* Arthrogryposis/akinesia sequence.
- Pena-Shokeir syndrome
- Pierre Robin sequence vs., **987**
 - trisomy 18 vs., **898**
- Pendred syndrome, goiter associated with, **295**
- Penile urethra, **577**
- Penis, **577**
- small, congenital adrenal hyperplasia vs., **633**
- Pentalogy of Cantrell, **502–503**
- abnormal cardiac axis and, **463**
 - associated abnormalities, **503**
 - body stalk anomaly vs., **505**
 - diagnostic checklist, **503**
 - differential diagnosis, **503**
 - ectopia cordis associated with, **385**
 - prognosis, **386**
 - embryology, **475**
 - etiology, **503**
 - genetics, **503**
 - omphalocele and, **498**
 - prognosis, **503**
 - staging, grading, & classification, **503**
- Percent predicted lung volume, **333**
- Pericardial effusion (PE), **448–449**
- differential diagnosis, **449**
 - hydrops vs., **1052**
 - prognosis, **449**
 - rhabdomyoma vs., **445**
- Pericardial teratoma, **450–451**
- diagnostic checklist, **451**
 - differential diagnosis, **451**
 - mediastinal teratoma vs., **355**
 - prognosis, **451**
 - rhabdomyoma vs., **445**
 - solid/echogenic chest mass vs., **356, 357**
- Pericardial tumor, rhabdomyoma vs., **445**
- Pericardium intact, ectopia cordis and, **385**
- Perigestational hemorrhage (PGH), **17, 24–27**
- abnormal gestational sac and contents vs., **57**
 - chorionic bump vs., **29**
 - diagnostic checklist, **25**
 - differential diagnosis, **25**
 - prognosis, **25**
 - staging, grading, & classification, **25**
 - twins with, triplets vs., **875**
- Perinatal form, autosomal recessive polycystic kidney disease, **620**
- Perinatal lethal hypophosphatasia, **715**
- Perineal body, embryology and anatomy, **480**
- Perineal orifice, cloacal malformation/urogenital sinus and, **534**
- Peritoneal spaces, embryology and anatomy, **475**
- Peritoneum, **577**
- Periventricular leukomalacia
- encephalomalacia/porencephaly and, **159**
 - intracranial hemorrhage vs, **155**
- Periventricular nodular heterotopia, bilateral, tuberous sclerosis vs., **1001**
- Periventricular white matter (PVWM) echogenicity, encephalomalacia/porencephaly and, **159**
- Pelzman syndrome, Beckwith-Wiedemann syndrome vs., **933**
- Persistent Blake pouch. *See* Blake pouch cyst (BPC).
- Persistent edge of ventral mesentery, **477**
- Persistent right umbilical vein, **828–829**
- associated abnormalities, **829**
 - diagnostic checklist, **829**
 - differential diagnosis, **829**
 - extrahepatic, **829**
 - genetics, **829**
 - intrahepatic, **829**
 - prognosis, **829**
- Persistent truncus arteriosus. *See* Truncus arteriosus.
- Pfeiffer syndrome, **982–985**
- Apert syndrome vs., **929**
 - Carpenter syndrome vs., **937**
 - differential diagnosis, **983**
 - genetics, **983**
 - prognosis, **983**
 - staging, grading, & classification, **983**
 - syndactyly vs., **752**
- PFFD. *See* Proximal focal femoral dysplasia (PFFD).
- PGH. *See* Perigestational hemorrhage (PGH).
- PHACES syndrome, **980–981**
- coloboma and, **287**
 - Dandy-Walker malformation and, **176**
 - diagnostic checklist, **981**
 - differential diagnosis, **981**

INDEX

- prognosis, **981**
- Pharyngeal arches, **270**
 - embryology and anatomy, **480**
- Pharynx, **477**
- Philtrum, **265, 269**
- Phocomelia/amelia, isolated, amelia vs., **699**
- Physiologic entities
 - arachnoid cyst vs., **151**
 - interhemispheric cyst/AVID vs., **113**
- Physiologic gut herniation, **834**
- Pierre Robin anomaly, Treacher Collins syndrome (TCS) vs., **997**
- Pierre Robin sequence, **313, 316, 986–987**
 - abnormal ears vs., **311**
 - differential diagnosis, **987**
 - genetics, **987**
 - micrognathia vs., **314**
 - prognosis, **987**
- Pierre Robin syndrome. *See* Pierre Robin sequence.
- Placenta, **579**
 - 1st-trimester, **784**
 - 2nd-trimester, **784**
 - 3rd-trimester, **784**
 - approach to, **784–789**
 - embryology of, **784**
 - imaging techniques, **784–785**
 - circumvallate, **812–813**
 - diagnostic checklist, **813**
 - differential diagnosis, **813**
 - gross pathologic and surgical features, **813**
 - circumvallate, synechiae vs., **1075**
 - embryology and anatomy, **372, 481**
 - hydropic change in fetal demise, triploidy vs., **913**
 - hydropic degeneration, complete hydatidiform mole vs., **31**
 - low-lying, follow-up, **785**
 - mesenchymal dysplasia
 - complete hydatidiform mole vs., **31**
 - triploidy vs., **913**
 - morbidly adherent, **800–805**
 - diagnostic checklist, **802**
 - differential diagnosis, **801**
 - prognosis, **802**
 - sonographic features, **802**
 - stages, **801**
 - Triple P procedure, **802**
 - US scoring for evaluation, **802**
 - pseudo-moles, triploidy vs., **913**
 - succenturiate lobe, **810–811**
 - associated abnormalities, **811**
 - diagnostic checklist, **811**
 - differential diagnosis, **811**
 - prognosis, **811**
 - thickness, **785**
 - variants, **841**
 - vasa previa, **798–799**
- Placenta, membranes, and umbilical cord
 - chorioangioma, **816–819**
 - circumvallate placenta, **812–813**
 - marginal/velamentous cord insertion, **814–815**
 - morbidly adherent placenta, **800–805**
 - persistent right umbilical vein, **828–829**
 - placenta previa, **794–797**
 - placental abruption, **790–793**
 - placental cysts and masses, **830–833**
 - differential diagnosis, **830**
 - placental mesenchymal dysplasia, **822–823**
 - placental teratoma, **820–821**
 - succenturiate lobe, **810–811**
 - umbilical artery, single, **824–825**
 - umbilical cord, cysts and masses, **834–837**
 - umbilical vein varix, **826–827**
 - vasa previa, **798–799**
- Placenta accreta, **841**
- Placenta accreta spectrum, placenta previa and, **795**
- Placenta percreta, morbidly adherent placenta and, **801**
- Placenta previa, **794–797**
 - associated abnormalities, **795**
 - complete, **795**
 - diagnostic checklist, **796**
 - differential diagnosis, **795**
 - low-lying, **795**
 - marginal, **795**
 - marginal sinus, **795**
 - placental abruption vs., **791**
 - prognosis, **796**
 - staging, grading, & classification, **795–796**
 - uncomplicated, morbidly adherent placenta vs., **801**
 - uterine rupture vs., **1077**
- Placenta twin, **579**
- Placenta-abdominal and placento-cranial phenotypes, **506**
- Placental abnormalities, intracranial hemorrhage and, **156**
- Placental abruption, **790–793**
 - acute abdomen in pregnancy vs., **1082, 1083**
 - diagnostic checklist, **792**
 - differential diagnosis, **791**
 - encephalomalacia/porencephaly and, **159**
 - marginal, **791**
 - vasa previa vs., **799**
 - myoma in pregnancy vs., **1067**
 - placenta previa vs., **795**
 - placental cysts and masses vs., **830, 832**
 - retroplacental, **830, 831**
 - placental lake vs., **807**
 - placental lakes associated, **808**
 - preplacental, **791**
 - prognosis, **792**
 - retroplacental, **791**
 - risk factors, **791**
 - signs and symptoms, **792**
 - staging, grading, & classification, **792**
 - succenturiate lobe vs., **811**
 - twins, **791**
 - uterine rupture vs., **1077**
- Placental band. *See* Circumvallate placenta.
- Placental chorioangioma
 - hydrops vs., **1053, 1057**
 - polyhydramnios vs., **1045, 1047**
- Placental cord insertion, **834**
 - sites, **841**
- Placental cysts and masses, **830–833**
 - differential diagnosis, **830**

INDEX

- Placental development, **5**
- Placental hematoma, chorioangioma vs., **817**
- Placental hemorrhage, acute, **785**
- Placental insufficiency
- severe, bladder exstrophy vs., **509**
 - single umbilical artery and, **825**
- Placental lake, intervillous thrombus, **806–809**
- associated abnormalities, **808**
 - diagnostic checklist, **808**
 - differential diagnosis, **807**
 - genetics, **808**
 - gross pathologic & surgical features, **808**
 - placental cysts and masses vs., **830, 831**
 - prognosis, **808**
 - staging, grading, & classification, **808**
 - triploidy vs., **913**
- Placental margin, elevated, circumvallate placenta, **813**
- Placental mesenchymal dysplasia, **822–823**
- associated abnormalities, **823**
 - diagnostic checklist, **823**
 - differential diagnosis, **823**
 - genetics, **823**
 - mesenchymal hamartoma and, **553**
 - placental cysts and masses vs., **831, 833**
 - prognosis, **823**
- Placental metastases
- chorioangioma vs., **817–818**
 - neuroblastoma and, **629**
- Placental migration, poor, placenta previa and, **795**
- Placental shelf. *See* Circumvallate placenta.
- Placental sonolucencies, **785**. *See also* Placental lake.
- morbidly adherent placenta vs., **801**
- Placental teratoma, **820–821**
- chorioangioma vs., **817**
 - diagnostic checklist, **821**
 - differential diagnosis, **821**
 - germ cell theory, **821**
 - gross pathologic and surgical features, **821**
 - placental cysts and masses vs., **831, 833**
 - prognosis, **821**
 - twin reversed arterial perfusion vs., **867**
- Placentation, monochorionic, complications, **841**
- Placentomegaly
- sacrococcygeal teratoma and, **255**
 - triploidy vs., **913**
- Platyspondyly, **680**
- Pleural development, **322**
- Pleural effusion
- abnormal cardiac axis vs., **462, 464**
 - hydrops vs., **1052**
 - pericardial effusion vs., **449**
 - rhabdomyoma vs., **445**
- Polycystic kidney disease
- autosomal dominant, autosomal recessive polycystic kidney disease vs., **619**
 - autosomal recessive, **618–621, 672**
 - bilateral renal agenesis vs., **601–602**
 - bladder exstrophy vs., **509**
 - diagnostic checklist, **620**
 - differential diagnosis, **619**
 - duplicated collecting system vs., **592**
 - echogenic kidneys vs., **668**
 - genetics, **619**
 - Meckel-Gruber syndrome vs., **972**
 - mesoblastic nephroma vs., **623**
 - multicystic dysplastic kidney vs., **615**
 - obstructive renal dysplasia vs., **612**
 - oligohydramnios vs., **1048–1049, 1051**
 - prognosis, **620**
 - unilateral enlarged kidney vs., **670**
- Polydactyly, **746–749**
- approach to skeletal dysplasias and, **681**
 - associated abnormalities, **748**
 - clinodactyly vs., **745**
 - diagnostic checklist, **748**
 - differential diagnosis, **747–748**
 - embryology, **748**
 - genetics, **748**
 - nonsyndromal, **747**
 - postaxial, **747**
 - trisomy 13 and, **903**
 - preaxial, **747**
 - prognosis, **748**
- Polyhydramnios, **1044–1047**
- achondrogenesis/hypochondrogenesis and, **690**
 - and chorioangioma, **817**
 - differential diagnosis, **1044**
 - duodenal atresia and, **521, 522**
 - esophageal atresia and, **517, 518**
 - hypotheses of, **624**
 - jejunal/ileal atresia and, **525**
 - monochorionic monoamniotic twins vs., **855**
 - omphalocele and, **497**
 - sacrococcygeal teratoma and, **255**
 - trisomy 18 and, **897**
 - twin-twin transfusion syndrome and, **863**
 - ureteropelvic junction obstruction and, **605**
- Polymicrogyria, **139**
- Aicardi syndrome and, **921**
 - Dandy-Walker malformation and, **175**
 - thanatophoric dysplasia and, **728**
 - tuberous sclerosis vs., **1001**
- Polysplenia. *See* Heterotaxy/cardiosplenic syndromes.
- Polyuria, polyhydramnios, **624**
- Pompe disease, cardiomyopathy and, **442**
- Pons, approach to imaging, **91**
- Pontocerebellar hypoplasia syndromes, cerebellar hypoplasia vs., **187**
- Pontocerebellar hypoplasias, cerebellar hypoplasia and, **187**
- Popliteal pterygium syndrome, multiple pterygium syndromes vs., **975**
- Porencephalic cyst, **86, 922**
- arachnoid cyst vs., **151**
 - encephalomalacia and, **159**
 - interhemispheric cyst/AVID vs., **113**
 - schizencephaly vs., **135**
- Porencephaly, **155, 158–161**
- aqueductal stenosis vs., **166**
 - diagnostic checklist, **160**

INDEX

- differential diagnosis, **159**
- prognosis, **160**
- vein of Galen aneurysmal malformation vs., **195**
- Portal sinus, embryology and anatomy, **475, 481**
- Portal veins, embryology and anatomy, **373**
- Portal venous branches, embryology and anatomy, **481**
- Postaxial polydactyly, Smith-Lemli-Opitz syndrome vs., **993**
- Posterior fossa
 - approach to, **90–95**
 - abnormalities, imaging findings, **92**
 - clinical implications, **92**
 - imaging techniques and normal anatomy, **90**
 - pitfalls in evaluation, **92**
 - approach to fetal spine and, **234**
 - embryology and anatomy, **82–83**
 - enlarged, cerebellar hypoplasia vs., **187**
- Posterior fossa cyst/fluid collection, **222–225**
 - differential diagnosis, **222**
- Posterior fossa malformations. *See* PHACES syndrome.
- Posterior ribs, **329**
- Posterior urethral valves (PUV), **634–637, 666**
 - associated malformations, **635**
 - diagnostic checklist, **636**
 - differential diagnosis, **635**
 - genetics, **636**
 - hydronephrosis vs., **664**
 - oligohydramnios vs., **1049, 1051**
 - prognosis, **636**
 - prune-belly syndrome vs., **639**
 - urachal anomalies and, **648**
- Postnatal circulation
 - CTGA, **430**
 - TGA, **430**
- Postobstructive renal dysplasia, ureteropelvic junction obstruction and, **605**
- Postpartum bleeding, uterine rupture vs., **1077**
- Postpartum hemorrhage, placenta previa and, **796**
- Potter sequence, bilateral renal agenesis and, **602**
- Potter syndrome, **601**. *See also* Renal agenesis, bilateral.
- Potter type II (bilateral MCDK). *See* Multicystic dysplastic kidney.
- Pouch sign, **517**
- Preauricular skin lesions, **313**
 - abnormal ears vs., **311**
- Preeclampsia, triplets and, **875**
- Preeclamptic toxemia (PET), intracranial hemorrhage and, **155**
- Pregnancy
 - adnexal mass in, **62–65**
 - differential diagnosis, **62**
 - angular, interstitial ectopic pregnancy vs., **41**
 - ectopic. *See* Ectopic pregnancy.
 - failed pregnancy in first trimester, **20–23**
 - abnormal gestational sac and contents vs., **56**
 - chorionic bump vs., **29**
 - diagnostic checklist, **22**
 - differential diagnosis, **21**
 - ultrasound in, **22**
 - with fetal Beckwith-Wiedemann syndrome, **934**
 - heterotopic, **16, 54–55**
 - diagnostic checklist, **55**
 - differential diagnosis, **55**
 - prognosis, **55**
 - intrauterine
 - probable, failed first-trimester pregnancy vs., **21**
 - of uncertain viability, failed first-trimester pregnancy vs., **21**
 - normal, with low uterine duplication, cervical ectopic pregnancy vs., **45**
 - osteogenesis imperfecta and, **720**
 - of unknown location, **16**
 - failed first-trimester pregnancy vs., **21**
 - in uterine duplication
 - abdominal ectopic pregnancy vs, **51**
 - heterotopic pregnancy vs., **55**
 - interstitial ectopic pregnancy vs., **41–42**
- Prelabor rupture, preterm, of membranes, oligohydramnios vs., **1048, 1049**
- Premature atrial contraction (PAC)
 - blocked, bradyarrhythmia vs., **459**
 - irregular rhythm and, **453**
- Premature dysjunction, **228**
- Premature rupture of membranes (PROM)
 - amniotic band syndrome and, **926**
 - bilateral renal agenesis vs., **601**
 - monochorionic monoamniotic twins vs., **855**
 - of one twin, twin-twin transfusion syndrome vs., **863**
- Premature shedding of teeth, hypophosphatasia and, **715**
- Premature ventricular contraction (PVC), irregular rhythm and, **453**
- Premaxillary agenesis, alobar holoprosencephaly associated with, **120**
- Prenatal bleeding, uterine rupture vs., **1077**
- Prenatal diagnosis, urinary tract dilation, **586**
- Prenatal vascular interruption, colonic atresia and, **529**
- Preplacental abruption, **791**
- Preterm birth, **1061**
 - multiple gestations, **842**
 - twin reversed arterial perfusion and, **868**
- Preterm delivery, triplets and, **875**
- Preterm prelabor rupture, of membranes, oligohydramnios vs., **1048, 1049**
- Primary cardiac crescent, embryology and anatomy, **366**
 - fusion of limbs, **366**
- Primary gut loop, embryology and anatomy, **478**
- Primary neurulation, **228, 230**
- Primary palate, **264**
- Primary ureterocele, **667**
 - hydronephrosis vs., **664–665**
- Primidone embryopathy, Noonan syndrome vs., **979**
- Primitive heart, **476**
- Primitive heart tube, embryology and anatomy, **366**
- Primitive neuroectodermal tumor, brain tumors and, **203**
- Primordial follicles, **6**
- Primordial heart, **324**
- Primordium
 - left ventricle, embryology and anatomy, **366**
 - outflow tract and right ventricle, embryology and anatomy, **366**
- Proboscis
 - alobar holoprosencephaly associated with, **120**

INDEX

- echogenic kidneys and, **668**
- Processus vaginalis, **571, 577**
- Products of conception, retained. *See* Retained products of conception.
- Progressive cardiomegaly, encephalomalacia/porencephaly and, **159**
- Pronephroi, **570, 572**
- Proptosis, **308**
 - abnormal orbits/eyes vs., **304**
 - Apert syndrome and, **929**
 - associations, **305**
- Prostate, **571, 577**
- Proteoglycan, abnormal, Turner syndrome and, **910**
- Proteus syndrome, Klippel-Trenaunay-Weber syndrome vs., **968**
- Protruding ear, abnormal ears vs., **311**
- Proximal bowel atresias, anal atresia vs., **531**
- Proximal focal femoral dysplasia (PFFD), **764–767**
 - associated abnormalities, **766**
 - diagnostic checklist, **766**
 - differential diagnosis, **765**
 - fibular/tibial hemimelia vs., **769**
 - genetics, **766**
 - mildly short femur/humerus and, **771, 773**
 - prognosis, **766**
 - staging, grading, & classification, **766**
- Prune-belly syndrome, **638–641, 667**
 - associated abnormalities, **640**
 - diagnostic checklist, **640**
 - differential diagnosis, **639**
 - hydronephrosis vs., **665**
 - oligohydramnios vs., **1049, 1051**
 - posterior urethral valves vs., **635**
 - prognosis, **640**
- PS (pulmonary valve stenosis). *See* Pulmonary stenosis/atresia.
- Pseudoachondroplasia, achondroplasia vs., **695**
- Pseudoascites, **486**
 - mimic, ascites vs., **560**
- Pseudocardiomegaly, cardiomyopathy vs., **441**
- Pseudocyst
 - meconium
 - fetus-in fetu vs., **879**
 - ovarian cyst vs., **659**
 - urachal anomalies vs., **647**
 - umbilical cord, **835**
- Pseudosyndactyly, amniotic band syndrome and, **925**
- Pseudothalidomide syndrome, VACTERL association vs., **1006**
- Pseudotrisonomy 13
 - polydactyly vs., **748**
 - Smith-Lemli-Opitz syndrome vs., **993**
- Pseudotrisonomy 18, trisomy 18 vs., **898**
- Pseudo-warfarin embryopathy, warfarin embryopathy vs., **1011**
- PTB (Preterm birth). *See* Preterm birth.
- Pterygium colli, multiple pterygium syndromes vs., **975**
- Pterygium syndrome, multiple, arthrogryposis/akinesia sequence vs., **759**
- Pulmonary agenesis, **348–349**
 - abnormal cardiac axis vs., **463, 467**
 - diagnostic checklist, **349**
 - differential diagnosis, **349**
 - genetics, **349**
 - prognosis, **349**
 - staging, grading, & classification, **349**
- Pulmonary airway malformation, congenital, **336–339**
 - associated abnormalities, **338**
 - bilateral, congenital high airway obstruction sequence vs., **347**
 - bronchogenic cyst vs., **345**
 - with bronchopulmonary sequestration (hybrid lesion), differential diagnosis, **337, 341**
 - bronchopulmonary sequestration vs., **341**
 - congenital diaphragmatic hernia vs., **333**
 - diagnostic checklist, **338**
 - differential diagnosis, **337–338**
 - genetics, **338**
 - mediastinal teratoma vs., **355**
 - pericardial teratoma vs., **451**
 - polyhydramnios vs., **1045, 1047**
 - prognosis, **338**
 - pulmonary agenesis vs., **349**
 - staging, grading, & classification, **338**
- Pulmonary aplasia, **349**
- Pulmonary artery, embryology and anatomy, **364–365**
- Pulmonary atresia-intact ventricular septum, tricuspid atresia vs., **403**
- Pulmonary blood flow, truncus arteriosus vs., **433**
- Pulmonary hypoplasia, **349**
 - atelosteogenesis and, **703**
 - fetal chest mass and, **331**
 - hydronephrosis and, **664**
 - obstructive renal dysplasia and, **612**
- Pulmonary stenosis/atresia, **397, 404–407**
 - abnormal cardiac axis vs., **463**
 - diagnostic checklist, **406**
 - differential diagnosis, **405**
 - genetics, **406**
 - prognosis, **406**
 - staging, grading, & classification, **406**
 - tetralogy of Fallot and, **426**
 - twin-twin transfusion syndrome and, **863**
 - with ventricular septal defect, tetralogy of Fallot vs., **425**
 - with ventricular septal defect, truncus arteriosus vs., **433**
- Pulmonary valve atresia, with intact ventricular septum, chamber asymmetry vs., **468, 470**
- Pulmonary veins, embryology and anatomy, **373**
- Pulmonary venous abnormalities, abnormal cardiac axis and, **463**
- Pulmonic stenosis, Apert syndrome and, **929**
- Pulsed Doppler, **375**
 - fetal growth restriction, **1035**
- PUV. *See* Posterior urethral valves (PUV).
- Pyelectasis. *See* Urinary tract dilation.
- Pyelonephritis, acute abdomen in pregnancy vs., **1082, 1084**

INDEX

Pyeloplasty, ureteropelvic junction obstruction and, **606**

Q

QUALEX (quality of life of bladder exstrophy) study, **510**

Qualitative lung index (QLI), **333**

R

RA. *See* Renal agenesis.

Radial ray defects

- Holt-Oram syndrome vs., **957**
- Smith-Lemli-Opitz syndrome vs., **993**

Radial ray hypoplasia/aplasia. *See* Radial ray malformation.

Radial ray malformation, **740–743**

- diagnostic checklist, **742**
- differential diagnosis, **741–742**
- embryology, **742**
- genetics, **742**
- prognosis, **742**
- trisomy 18 and, **897**
- VACTERL association vs., **1005**

Radial-ulnar deficiencies, split hand/foot malformation vs., **755**

Rapid T2-weighted sequences, supratentorial brain, **84**

Recanalization, abnormal, enteric duplication cyst, **539**

Recent Visser classification, choledochal cyst, **549**

Rectum, **573**

- embryology and anatomy, **478, 480, 481, 483**
- meconium-filled, anal atresia and, **531**

Redundant septum primum flap. *See* Atrial septal aneurysm.

Reflux

- duplicated collecting system vs., **591**
- vesicoureteral, **667**
 - hydronephrosis vs., **665**

Renal abnormalities, ovarian cyst vs., **659**

Renal agenesis, **570**

- bilateral, **600–603**
 - associated abnormalities, **602**
 - diagnostic checklist, **602**
 - differential diagnosis, **601–602**
 - genetics, **602**
 - oligohydramnios vs., **1048, 1050**
 - prognosis, **602**
- bladder exstrophy vs., **509**
- cloacal malformation/urogenital sinus and, **533**
- unilateral, **588–589**
 - associated abnormalities, **589**
 - crossed fused ectopia vs., **599**
 - diagnostic checklist, **589**
 - differential diagnosis, **589**
 - genetics, **589**
 - pelvic kidney vs., **595**
 - prognosis, **589**

Renal anomalies

- bilateral
 - oligohydramnios vs., **1048**

- sirenomelia vs., **989**

- developmental and secondary, hydrocolpos vs., **663**
- duplicated collecting system and, **592**
- gastroschisis and, **492**
- resulting in anuria, bladder exstrophy vs., **509**
- urachal anomalies and, **648**

Renal arteries

- embryology and anatomy, **481**
- main left, **578**
- new, developing, **574**

Renal ascent, **570, 574–575**

Renal coloboma syndrome

- coloboma and, **287**
- Fraser syndrome vs., **951**

Renal cystic dysplasia. *See* Multicystic dysplastic kidney.

Renal cysts, **581**

Renal duplicated collecting system, **675**

- suprarenal mass vs., **674**

Renal duplication, Weigert-Meyer rule in, **643**

Renal dysplasia

- nonobstructive, obstructive renal dysplasia vs., **611**
- obstructive, **610–613**
 - associated abnormalities, **612**
 - diagnostic checklist, **612**
 - differential diagnosis, **611–612**
 - prognosis, **612**

Renal echogenicity, **581**

Renal ectopia, renal ascent and, **570**

Renal enlargement, causes of, duplicated collecting system vs., **591–592**

Renal fossa

- adrenal gland in, **575**
- empty, pelvic kidney and, **595**

Renal hypoplasia, Fraser syndrome vs., **951**

Renal mass, adrenal hemorrhage vs., **627**

Renal obstruction

- associated severe, urinoma, **609**
- urinary tract dilation and, **585**

Renal parenchyma, normal, urinary tract dilation and, **585**

Renal pelvis, **578**

Renal pelvis dilation, mild, trisomy 21 and, **891**

Renal pelvis distention, hallmark finding, ureteropelvic junction obstruction and, **605**

Renal pyramid, **578**

- normal, ureteropelvic junction obstruction vs., **605**

Renal stone disease, acute abdomen in pregnancy vs., **1082, 1084**

Renal tumors, other, mesoblastic nephroma vs., **623**

Renal vein thrombosis, **673**

- adrenal hemorrhage and, **627**
- unilateral enlarged kidney vs., **671**

Respiratory diverticulum

- development, **322**
- 4 weeks, **324**

Respiratory system, embryology and anatomy, organogenesis, **5**

Restrictive dermatopathy, arthrogryposis/akinesia sequence vs., **760**

Retained products of conception, **1080–1081**

- abnormal gestational sac and contents vs., **56**
- diagnostic checklist, **1081**

INDEX

- differential diagnosis, **1081**
 - failed first-trimester pregnancy vs., **21**
 - prognosis, **1081**
 - Reticularis, **570**
 - Retinal degeneration, short rib-polydactyly syndrome and, **724**
 - Retroperitoneal lymph sac, **272**
 - Retroperitoneal teratoma, mesoblastic nephroma vs., **623**
 - Retroplacental abruption, **791, 830, 831**
 - Reverse flow ductus arteriosus, chamber asymmetry and, **468**
 - RF. *See* Rocker-bottom foot (RF).
 - Rhabdoid tumor, mesoblastic nephroma vs., **623**
 - Rhabdomyoma, **444–447**
 - cardiac, tuberous sclerosis and, **1001–1002**
 - cardiomyopathy vs., **441**
 - diagnostic checklist, **446**
 - differential diagnosis, **445**
 - echogenic cardiac focus vs., **439**
 - genetics, **446**
 - pericardial teratoma vs., **451**
 - prognosis, **446**
 - Rhabdomyosarcoma
 - cervical teratoma vs., **303**
 - epignathus vs., **289**
 - Rhizomelia, **680**
 - Rhombencephalon, **90**
 - Rhombencephalosynapsis (RES), **91, 190–193**
 - associated abnormalities, **191, 192**
 - cerebellar hypoplasia vs., **187**
 - Chiari 2 malformation vs., **169–170**
 - diagnostic checklist, **192**
 - differential diagnosis, **191**
 - genetics, **191**
 - prognosis, **192**
 - Rhythm abnormalities, rhabdomyoma and, **445**
 - Rhythm disturbances, heart, **376**
 - Rib clefts, amniotic band syndrome and, **925**
 - Ribs, **328**
 - embryology and anatomy, **483**
 - Rickets, hypophosphatemic, hypophosphatasia vs., **715**
 - Right atrial appendage isomerism. *See* Heterotaxy/cardiosplenic syndromes.
 - Right atrial (RA) isomerism, appendages associated with heterotaxy and cardiosplenic syndromes, **382**
 - Right atrium, embryology and anatomy, **368, 369, 371, 373**
 - Right heart enlargement, abnormal cardiac axis and, **462**
 - Right hepatic vein, embryology and anatomy, **481**
 - Right kidney, embryology and anatomy, **481**
 - Right lobe of liver, embryology and anatomy, **481**
 - Right pulmonary artery, embryology and anatomy, **372**
 - Right pulmonary vein, embryology and anatomy, **369**
 - Right umbilical vein, embryology and anatomy, **481**
 - Right upper quadrant cysts, choledochal cyst vs., **549**
 - Right ventricle (RV)
 - embryology and anatomy, **368, 369, 373**
 - developing, **367**
 - hypoplastic left heart and, **409**
 - and outflow tract, embryology and anatomy, **367**
 - Right ventricular outflow tract, **374**
 - Riley-Day syndrome, colonic atresia and, **529**
 - Risk-based management, urinary tract dilation, **586**
 - Robert syndrome/Roberts SC syndrome, VACTERL association vs., **1006**
 - Roberts SC syndrome, amelia vs., **699**
 - Roberts syndrome, amelia vs., **699**
 - Robin sequence. *See* Pierre Robin sequence.
 - Rocker-bottom foot (RF), **736–737**
 - associated abnormalities, **737**
 - clubfoot vs., **733**
 - diagnostic checklist, **737**
 - differential diagnosis, **737**
 - genetics, **737**
 - prognosis, **737**
 - spina bifida and, **237**
 - trisomy 13 and, **903**
 - trisomy 18 and, **897**
 - Round calvarium, abnormal vs., **216**
 - RPOC (Retained products of conception). *See* Retained products of conception.
 - RSH syndrome. *See* Smith-Lemli-Opitz syndrome.
 - Rubella
 - congenital, chondrodysplasia punctata vs., **712**
 - cytomegalovirus vs., **1017**
 - pericardial effusion and, **449**
 - Ruptured anal membrane, embryology and anatomy, **480**
 - Ruptured urogenital membrane, embryology and anatomy, **480**
- ## S
- S1 ossification center, **232**
 - Sacral agenesis. *See* Caudal regression sequence (CRS).
 - Sacrococcygeal teratoma (SCGT), **229, 254–259**
 - diagnostic checklist, **256**
 - differential diagnosis, **255**
 - genetics, **255**
 - Klippel-Trenaunay-Weber syndrome vs., **967**
 - prognosis, **256**
 - spina bifida vs., **237**
 - staging, grading, & classification, **256**
 - Sacrum, unossified, **232**
 - Saethre-Chotzen syndrome
 - Apert syndrome vs., **929**
 - Carpenter syndrome vs., **937**
 - Pfeiffer syndrome vs., **983**
 - syndactyly vs., **751**
 - Salonen-Herva-Norio syndrome, Meckel-Gruber syndrome vs., **972**
 - Salt wasting, **652**
 - Sandal gap foot (SGF), **738–739**
 - associated abnormalities, **739**
 - diagnostic checklist, **739**
 - differential diagnosis, **739**
 - genetics, **739**
 - trisomy 21 and, **891**
 - Scalp masses
 - atretic cephalocele vs., **105**
 - calvarium, abnormal vs., **217**
 - occipital/parietal cephalocele vs., **102**

INDEX

- Scan plane, incorrect
 - cavum septi pellucidi, absent and, **208, 209**
 - posterior fossa cyst/fluid collection vs., **222**
- Scan technique, calvarium, abnormal vs., **216, 217**
- Scapula, approach to skeletal dysplasias and, **681**
- Scar endometriosis, uterine rupture vs., **1077**
- Schizencephaly, **134–137**
 - arachnoid cyst vs., **151**
 - associated migrational anomalies, **136**
 - cavum septi pellucidi, absent vs., **208–209, 210**
 - diagnostic checklist, **136**
 - differential diagnosis, **135–136**
 - encephalomalacia/porencephaly vs., **159**
 - interhemispheric cyst/AVID vs., **113**
 - lobar holoprosencephaly vs., **125**
 - open-lip
 - semilobar holoprosencephaly vs., **123**
 - septo-optic dysplasia vs., **127**
 - prognosis, **136**
 - syntelencephaly vs., **131**
- Schizophrenia, 22q11 deletion syndrome and, **919**
- Scimitar syndrome, total anomalous pulmonary venous return vs., **421**
- Sclerotomes, **229, 231**
- Scoliosis, **680**. *See also* Kyphosis/scoliosis.
 - Aicardi syndrome and, **922**
 - body stalk anomaly and, **505, 506**
 - Chiari 2 malformation and, **169**
 - isolated, spina bifida vs., **237**
 - spina bifida and, **237**
- Scrotal mass, **676–677**
 - differential diagnosis, **676**
- Scrotum, **571, 579**
- Seckel syndrome, Pierre Robin sequence vs., **987**
- Second-trimester screening, **884**
- 2nd pharyngeal arch, **264**
- Secondary heart field, embryology and anatomy, **366**
- Secondary neurulation, **228**
- Secondary palate, **264, 269**
- Secondary sex cords, **571**
- Segmental hemangiomas. *See* PHACES syndrome.
- Segmental nomenclature, embryology and anatomy, **365**
- Segmental spinal dysgenesis, caudal regression sequence vs., **245**
- Seizure disorder, rhombencephalosynapsis and, **192**
- Selective fetal growth restriction, twin-twin transfusion syndrome vs., **863**
- Selective growth restriction, multiple gestations, **841**
- Selective multifetal pregnancy reduction, triplets and, **876**
- Selective termination, triplets and, **876**
- Semilobar holoprosencephaly, cavum septi pellucidi, absent vs., **208, 210**
- Semilunar valve, 2nd, truncus arteriosus vs., **433**
- Semilunar valve atresia, **375**
- Seminal vesicle, **577**
- Sensenbrenner syndrome, short rib-polydactyly syndrome vs., **724**
- Septal defect
 - atrioventricular, unbalanced left dominant, tricuspid atresia vs., **403**
 - isolated atrial, Holt-Oram syndrome vs., **957**
 - ventricular, **388–389**
 - ectopia cordis associated with, **386**
- Septate uterus
 - circumvallate placenta vs., **813**
 - Müllerian duct anomalies in, **1071–1072**
- Septations, **273**
 - embryology and anatomy, **366**
- Septo-optic dysplasia (SOD)
 - agenesis/dysgenesis of corpus callosum vs., **110**
 - associated abnormalities, **128**
 - cavum septi pellucidi, absent vs., **208, 210**
 - diagnostic checklist, **128**
 - differential diagnosis, **127**
 - fetal optic tract diameter, reference ranges, **128**
 - lobar holoprosencephaly vs., **125**
 - mild ventriculomegaly vs., **212–213, 215**
 - prognosis, **128**
 - rhombencephalosynapsis and, **191**
 - schizencephaly vs., **135–136**
 - semilobar holoprosencephaly vs., **123**
 - syntelencephaly vs., **131**
- Septum pellucidum, isolated agenesis, septo-optic dysplasia vs., **127**
- Septum primum, aneurysm of. *See* Atrial septal aneurysm.
- Sequestration, bronchopulmonary, **340–343**
 - abnormal cardiac axis vs., **462, 464**
 - associated abnormalities, **342**
 - congenital adrenal hyperplasia vs., **633**
 - with congenital pulmonary airway malformation (hybrid lesion)
 - congenital pulmonary airway malformation vs., **337**
 - differential diagnosis, **341**
 - congenital pulmonary airway malformation vs., **337**
 - differential diagnosis, **341–342**
 - extralobar, adrenal hemorrhage vs., **627**
 - genetics, **342**
 - heterotaxy/cardiosplenic syndromes and, **381**
 - mediastinal teratoma vs., **355**
 - pericardial teratoma vs., **451**
 - prognosis, **342**
 - pulmonary agenesis vs., **349**
 - solid/echogenic chest mass vs., **356, 358**
 - suprarenal mass vs., **674**
- Sertoli cells, **571**
- Severe achondroplasia with developmental delay and acanthosis nigricans syndrome, achondroplasia vs., **695**
- Severe aortic stenosis, hypoplastic left heart and, **409**
- Sex chromosome anomalies, clubfoot and, **733**
- Sex-cord stromal tumor, adnexal mass in pregnancy vs., **63**
- Sexual development, disorders of, **650–655**
 - associations, **651**
 - congenital adrenal hyperplasia vs., **633**
 - diagnostic checklist, **652**
 - genetics, **651**
 - prognosis, **652**
 - staging, grading, & classification, **652**
 - terminology update, **652**
- SGA (Small for gestational age). *See* Small for gestational age (SGA).
- SGF. *See* Sandal gap foot (SGF).
- SHFM. *See* Split hand/foot malformation (SHFM).

INDEX

- Shone syndrome
- aortic stenosis vs., **417**
 - hypoplastic left heart vs., **409**
- Short broad hands, atelosteogenesis and, **703**
- Short cervix, **1060–1065**
- cervical cerclage, **1062**
 - definition, **1061**
 - diagnostic checklist, **1062**
 - differential diagnosis, **1061**
 - prognosis, **1061–1062**
- Short femur/humerus, mildly, **770–773**
- differential diagnosis, **770–771**
 - idiopathic, **770, 771**
- Short rib-polydactyly syndrome (SRPS), **722–725**
- achondrogenesis/hypochondrogenesis vs., **689**
 - associated abnormalities, **724**
 - Beemer-Langer (SRPS type IV), **723**
 - differential diagnosis, **723–724**
 - genetics, **724**
 - Majewski (SRPS type II), **723**
 - polydactyly vs., **747**
 - prognosis, **724**
 - Saldino-Noonan (SRPS type I), **723**
 - types I and III, micromelia vs., **700**
 - Verma-Naumoff (SRPS type III), **723**
- Short rib-thoracic dysplasia ± polydactyly (SRTD). *See* Short rib-polydactyly syndrome (SRPS).
- Siamese twins. *See* Conjoined twins.
- Sigmoid colon, embryology and anatomy, **481**
- Sigmoid colon mass effect, ureterocele vs., **643**
- Sigmoid mesocolon, root, embryology and anatomy, **479**
- Simple hydrocele, scrotal mass vs., **676**
- Simple peritonitis, meconium peritonitis/pseudocyst and, **542**
- Simpson-Golabi-Behmel syndrome, Beckwith-Wiedemann syndrome vs., **933**
- Single bubble, duodenal atresia and, **521**
- Single orifice, cloacal malformation/urogenital sinus, **534**
- Single umbilical artery
- marginal/velamentous cord insertion and, **815**
 - trisomy 13 and, **903**
- Sinus bradycardia, bradyarrhythmia vs., **459**
- Sinus horns
- embryology and anatomy, **366**
 - right and left, embryology and anatomy, **366**
 - into right atrium, embryology and anatomy, **367**
- Sinus previa, marginal, vasa previa vs., **799**
- Sinus tachycardia, **455, 456**
- tachyarrhythmia vs., **455**
- Sinus venosus, embryology and anatomy, **365, 481**
- Sinusoid, maternal, **7**
- Sirenomelia, **988–991**
- associated abnormalities, **990**
 - bilateral renal agenesis and, **602**
 - caudal regression sequence vs., **245**
 - diagnostic checklist, **990**
 - differential diagnosis, **989**
 - genetics, **990**
 - prognosis, **990**
- Situs ambiguous. *See* Heterotaxy/cardiosplenic syndromes.
- Skeletal abnormality, gestation and, **680**
- Skeletal anomalies, duodenal atresia and, **521**
- Skeletal dysplasia
- approach to, **680–685**
 - key measurements, **681**
 - lethality vs. nonlethality, **680**
 - clubfoot and, **733**
 - micrognathia and, **315, 317**
 - mild, fetal growth restriction vs., **1035**
 - sandal gap foot and, **739**
 - severe, polyhydramnios vs., **1045, 1047**
 - warfarin embryopathy vs., **1011**
- Skin lesions, preauricular, **313**
- abnormal ears vs., **311**
- Skull, embryology and anatomy, **270, 271**
- SLOS (Smith-Lemli-Opitz syndrome). *See* Smith-Lemli-Opitz syndrome.
- Small bowel, **328, 578, 579**
- embryology and anatomy, **481, 483**
 - normal, jejunal/ileal atresia and, **525**
- Small bowel mesentery, root, embryology and anatomy, **479**
- Small for gestational age (SGA), **1028**
- Small intestine
- bowel rotation, **478**
 - embryology and anatomy, **475, 479**
- Small left ventricle, abnormal cardiac axis and, **463**
- Small right ventricle, abnormal cardiac axis and, **463**
- Small stomach, **485**
- Smith-Lemli-Opitz syndrome, **992–995**
- alobar holoprosencephaly associated with, **120**
 - chondrodysplasia punctata vs., **712**
 - diagnostic checklist, **994**
 - differential diagnosis, **993**
 - disorders of sexual development and, **651**
 - Fraser syndrome vs., **951**
 - genetics, **993–994**
 - hypospadias and, **657**
 - Meckel-Gruber syndrome vs., **971**
 - polydactyly vs., **747**
 - prognosis, **994**
 - syndactyly vs., **752**
 - trisomy 18 vs., **898**
- SOD. *See* Septo-optic dysplasia (SOD).
- Soft tissue masses, adnexal mass in pregnancy vs., **63**
- Soft tissue tumors
- cervical teratoma vs., **303**
 - epignathus vs., **289**
- Soft tissues, approach to fetal spine and, **234**
- Solid chest mass, **356–359**
- differential diagnosis, **356**
- Solid/echogenic chest mass, **356–359**
- differential diagnosis, **356**
- Solid fetal masses, fetus-in fetu vs., **879**
- Solid masses, **486**
- Solid tumors, sacrococcygeal teratoma vs., **255**
- Somatic mesoderm, **476**
- Somites, **231**
- Sonolucencies, placental, **785**
- morbidly adherent placenta vs., **801**
- Sotos syndrome, Beckwith-Wiedemann syndrome vs., **933**
- Spaulding sign, calvarium, abnormal vs., **216**

INDEX

- Spermatic cord, component layers of, **571**
Spermatozoa, fertilization, **6**
Sphenoid, **270**
Sphenoidal fontanelle, **271**
Spina bifida, **236–241**
 - associated anomalies, **237**
 - clubfoot and, **733**
 - diagnostic checklist, **238**
 - differential diagnosis, **237**
 - genetics, **238**
 - kyphosis/scoliosis and, **249**
 - prognosis, **238**
 - rocker-bottom foot and, **737**
 - trisomy 18 and, **897**Spina bifida occulta, spina bifida and, **237**
Spinal alignment, approach to fetal spine and, **234**
Spinal canal, **329, 579**
Spinal cord ascent, **229**
Spinal dysraphism. *See also* Spina bifida.
 - Chiari 3 malformation and, **173**Spinal lamina, **578**
 - embryology and anatomy, **483**Spinal muscular atrophy, arthrogryposis/akinesia sequence vs., **760**
Spine
 - abnormalities, in full OEIS complex, **513**
 - achondroplasia and, **695**
 - approach to fetal spine, **234–235**
 - caudal regression sequence, **244–247**
 - diastematomyelia, **252–253**
 - embryology and anatomy of, **228–233**
 - hypophosphatasia and, **715**
 - iniencephaly, **242–243**
 - kyphosis/scoliosis, **248–249**
 - normal, **680**
 - sacrococcygeal teratoma, **254–259**
 - spina bifida, **236–241**
 - tethered cord, **250–251**
 - thanatophoric dysplasia and, **727**Spinous process, cartilaginous, **232**
Splanchnic mesoderm, **476**
Spleen, **579**
 - embryology and anatomy, **475, 478, 479, 481, 483**Splenic cyst, cystic abdominal mass vs., **563, 566**
Splenogonadal fusion limb defect syndrome, sirenomelia vs., **989**
Split cord malformation (SCM). *See* Diastematomyelia.
Split hand/foot deformity. *See* Split hand/foot malformation (SHFM).
Split hand/foot malformation (SHFM), **754–757**
 - diagnostic checklist, **756**
 - differential diagnosis, **755–756**
 - genetics, **756**
 - long bone deficiency and, **755**
 - prognosis, **756**
 - staging, grading, & classification, **756**
 - syndactyly vs., **752**Spondyloepiphyseal dysplasia, achondroplasia vs., **696**
Spontaneous reduction, triplets and, **875**
Squamosal suture, **271**
SRPS. *See* Short rib-polydactyly syndrome (SRPS).
Stenogyria, cavum septi pellucidi, absent and, **208**
Stenosis, pulmonary, **404–407**
Sternal cleft, ectopia cordis vs., **385**
Sternal defects. *See* PHACES syndrome.
Stickler syndrome, Pierre Robin sequence vs., **987**
Stomach, **328**
 - abnormal position, heterotaxy/cardiosplenic syndromes and, **381**
 - approach to abdominal wall and gastrointestinal tract, **484**
 - embryology and anatomy, **477, 478, 479, 481, 483**
 - side, **374**
 - small or absent, causes of, esophageal atresia vs., **517**
 - and umbilical vein varix, **827**Stomodeum (primitive oral cavity), **264**
Strawberry-shaped calvarium, abnormal vs., **216, 218**
Structural cardiac defect, hydrops vs., **1052, 1053**
Stuck twin, twin-twin transfusion syndrome and, **863**
Sturge-Weber syndrome, PHACES syndrome vs., **981**
Styloid process, **270**
Subaortic stenosis, aortic stenosis and, **417**
Subchorionic hematoma. *See* Perigestational hemorrhage (PGH).
Subclavian vein, **272**
Subcortical band heterotopia, **139**
Subcortical heterotopia, tuberous sclerosis vs., **1001**
Subcortical tubers, tuberous sclerosis with, **1001**
Subcortical white matter lesions, tuberous sclerosis and, **1001–1002**
Subdural bleed, **155**
Subependymal giant cell astrocytoma
 - rhabdomyoma and, **445**
 - tuberous sclerosis and, **1001–1002**Subependymal gray matter heterotopia, tuberous sclerosis vs., **1001**
Subependymal nodules
 - rhabdomyoma and, **445**
 - tuberous sclerosis with, **1001**Submucosal fibroid, chorioangioma vs., **817**
Subvalvar aortic stenosis, **418**
 - aortic stenosis and, **417**Succenturiate lobe, **785, 810–811, 841**
 - associated abnormalities, **811**
 - diagnostic checklist, **811**
 - differential diagnosis, **811**
 - placenta previa and, **795**
 - prognosis, **811**
 - submembranous vessels from, **815**Sulci, approach to imaging, **85**
Sulfate transporter *SLC26A2*- (DTDST) related disorders, atelosteogenesis vs., **703**
Superficial anastomosis, twin-twin transfusion syndrome and, **863**
Superior mesenteric artery, embryology and anatomy, **478**
Superior orbit, **266**
Superior sinus venous ASD, total anomalous pulmonary venous return vs., **421**
Superior vena cava, **272**
 - embryology and anatomy, **369, 373**

INDEX

- Supracardiac total anomalous pulmonary venous return, **421**
- Suprarenal mass, **674–675**
- bronchopulmonary sequestration vs., **341–342**
 - differential diagnosis, **674**
 - other, congenital adrenal hyperplasia vs., **633**
 - unilateral, **581**
- Supratentorial anomalies, Chiari 2 malformation and, **169**
- Supraumbilical abdominal wall defect, pentalogy of Cantrell and, **503**
- Supravalvar aortic stenosis, **418**
- aortic stenosis and, **417, 418**
- Supraventricular tachycardia (SVT), **455**
- irregular rhythm vs., **453**
- Sutures, embryology and anatomy, **271**
- Swallowing, abnormal, esophageal atresia vs., **517**
- Sylvian fissure
- approach to imaging, **85**
 - embryology and anatomy, **75**
- Symelia apus. *See* Sirenomelia.
- Syncytiotrophoblast, **7, 786**
- Syndactyly, **750–753**
- approach to skeletal dysplasias and, **681**
 - associated abnormalities, **752**
 - classification, **751**
 - clinodactyly vs., **745**
 - diagnostic checklist, **752**
 - differential diagnosis, **751–752**
 - familial 2-3 toe, **751**
 - genetics, **752**
 - prognosis, **752**
 - sandal gap foot vs., **739**
 - split hand/foot malformation vs., **755**
- Syndromes and multisystem disorders
- Aicardi syndrome, **920–923**
 - amniotic band syndrome, **924–927**
 - Apert syndrome, **928–931**
 - Carpenter syndrome, **936–937**
 - CHARGE syndrome, **938–939**
 - Cornelia de Lange syndrome, **940–943**
 - cystic fibrosis, **944–945**
 - diabetic embryopathy, **946–949**
 - Fraser syndrome, **950–951**
 - Fryns syndrome, **952–953**
 - Goldenhar syndrome, **954–955**
 - Holt-Oram syndrome, **956–959**
 - idiopathic infantile arterial calcification, **960–961**
 - Joubert syndrome, **962–965**
 - Klippel-Trenaunay-Weber syndrome, **966–969**
 - Meckel-Gruber syndrome, **970–973**
 - multiple pterygium syndromes, **974–975**
 - Neu-Laxova syndrome, **976–977**
 - Noonan syndrome, **978–979**
 - Pfeiffer syndrome, **982–985**
 - PHACES syndrome, **980–981**
 - Pierre Robin sequence, **986–987**
 - sirenomelia, **988–991**
 - Smith-Lemli-Opitz syndrome, **992–995**
 - Treacher Collins syndrome (TCS), **996–999**
 - tuberous sclerosis, **1000–1003**
 - 22q11 deletion syndrome, **918–919**
 - VACTERL association, **1004–1007**
 - valproate embryopathy, **1008–1009**
 - Walker-Warburg syndrome (WWS), **1012–1013**
 - warfarin embryopathy, **1010–1011**
- Synechia, **1074–1075**
- circumvallate placenta vs., **813**
 - diagnostic checklist, **1075**
 - differential diagnosis, **1075**
 - intrauterine linear echoes vs., **1086, 1088**
 - prognosis, **1075**
- Syntelencephaly, **130–133**
- associated abnormalities, **132**
 - cavum septi pellucidi, absent vs., **209, 210**
 - diagnostic checklist, **132**
 - differential diagnosis, **131**
 - holoprosencephaly vs., **132**
 - lobar holoprosencephaly vs., **125**
 - prognosis, **132**
 - semilobar holoprosencephaly vs., **123**
- Syphilis
- cytomegalovirus vs., **1017**
 - pericardial effusion and, **449**
- Syringomyelia, Chiari 3 malformation and, **173**
- Systemic veins, embryology and anatomy, **365**
- Systemic venous abnormalities, abnormal cardiac axis and, **463**

T

T1-weighted images, supratentorial brain, **84**

TA. *See* Tricuspid atresia (TA).

TAC (Transabdominal cerclage). *See* Transabdominal cerclage.

Tachyarrhythmia, **454–457**

- ascites vs., **560**
- diagnostic checklist, **456**
- differential diagnosis, **455**
- genetics, **456**
- hydrops vs., **1052, 1054**
- prognosis, **456**

Tachycardia

- atrial ectopic, **455**
 - tachyarrhythmia vs., **455**
- junctional ectopic, tachyarrhythmia vs., **455**
- sinus, **455, 456**
 - tachyarrhythmia vs., **455**
- supraventricular, **455**
- supraventricular, irregular rhythm vs., **453**
- trisomy 13 and, **903**
- ventricular, tachyarrhythmia vs., **455**

Tailgut, **573**

TAPVC. *See* Total pulmonary venous connection (TAPVC).

Target sign, anal atresia and, **531**

T-cell malfunction, immune deficiencies due, truncus arteriosus and, **434**

TCS (Treacher Collins syndrome). *See* Treacher Collins syndrome (TCS).

TD. *See* Thanatophoric dysplasia (TD).

Technical micrognathia, **314, 315**

Teeth, premature shedding of, hypophosphatasia and, **715**

INDEX

- Tegmentovermian angle, **91**
- Temporal bone, squama of, **270**
- Teratogen exposure, encephalomalacia/porencephaly and, **160**
- Teratogens
- radial ray malformation vs., **741**
 - spina bifida and, **238**
- Teratoma, **677**
- abnormal cardiac axis vs., **462, 465**
 - adnexal mass in pregnancy vs., **62**
 - arachnoid cyst vs., **151**
 - brain tumors and, **203**
 - bronchopulmonary sequestration vs., **341**
 - cervical. *See* Cervical teratoma.
 - cleft lip, palate vs., **280**
 - congenital pulmonary airway malformation vs., **337–338**
 - cystic, ovarian cyst vs., **659**
 - cystic abdominal mass vs., **563, 567**
 - fetus-in fetu vs., **879**
 - gallstones vs., **547**
 - hydrops vs., **1053, 1056**
 - mediastinal, solid/echogenic chest mass vs., **356, 357**
 - mediastinal/pulmonary, pericardial teratoma vs., **451**
 - pericardial
 - mediastinal teratoma vs., **355**
 - rhabdomyoma vs., **445**
 - solid/echogenic chest mass vs., **356, 357**
 - placental, **820–821**
 - chorioangioma vs., **817**
 - diagnostic checklist, **821**
 - differential diagnosis, **821**
 - germ cell theory, **821**
 - gross pathologic and surgical features, **821**
 - placental cysts and masses vs., **831, 833**
 - prognosis, **821**
 - twin reversed arterial perfusion vs., **867**
 - retroperitoneal, mesoblastic nephroma vs., **623**
 - sacrococcygeal, Klippel-Trenaunay-Weber syndrome vs., **967**
 - scrotal mass vs., **676**
 - umbilical cord, **835**
- Terminal ileum, embryology and anatomy, **479**
- Terminal myelocystocele, **229**
- Terminal villogenesis, **784**
- Testes, **571, 577, 579**
- Testicular adrenal rest tumors (TART), **633**
- Testicular descent, **571**
- Testicular torsion, **677**
- scrotal mass vs., **676**
- Testis determining factor, **571**
- Tethered cord, **228, 250–251**
- Chiari 2 malformation and, **169**
 - Chiari 3 malformation and, **173**
 - diagnostic checklist, **251**
 - differential diagnosis, **251**
 - prognosis, **251**
- Tethered spinal cord (TSC). *See* Tethered cord.
- Tetra-amelia, amelia vs., **699**
- Tetralogy of Fallot (ToF), **424–427**
- atrioventricular septal defect and, **391**
 - diagnostic checklist, **426**
 - differential diagnosis, **425**
 - double-outlet right ventricle vs., **437**
 - prognosis, **426**
 - prune-belly syndrome and, **640**
 - pulmonary stenosis/atresia vs., **405**
 - staging, grading, & classification, **426**
 - transposition of great arteries vs., **429**
 - trisomy 18 and, **897**
 - truncus arteriosus vs., **433**
 - 22q11 deletion syndrome and, **919**
- Tetraploidy, **914**
- Tetrasomy 12p, congenital diaphragmatic hernia associated with, **334**
- TGA. *See* Transposition of great arteries (TGA).
- a-Thalassemia, fetal anemia vs., **1041**
- b-Thalassemia, fetal anemia vs., **1041**
- Thalidomide embryopathy, amelia vs., **699**
- Thanatophoric dwarfism. *See* Thanatophoric dysplasia (TD).
- Thanatophoric dysplasia (TD), **726–731**
- achondrogenesis/hypochondrogenesis vs., **689**
 - achondroplasia vs., **695**
 - angulated bones and, **774, 775, 776**
 - associated abnormalities, **728**
 - diagnostic checklist, **728**
 - differential diagnosis, **727–728**
 - genetics, **728**
 - osteogenesis imperfecta vs., **719**
 - prognosis, **728**
 - type I, **727**
 - type II, **727**
 - calvarium, abnormal vs., **217, 221**
 - Pfeiffer syndrome vs., **983**
- Theca lutein cyst
- adnexal mass in pregnancy vs., **62–63**
 - ovarian, complete hydatidiform mole, **32**
- Theory of compromised early embryonic blood flow, **506**
- Theory of early amnion rupture before obliteration of extraembryonic coelom, **506**
- Theory of primary ectodermal failure in early embryonic disc (ED), **505–506**
- Thoracic constriction, short rib-polydactyly syndrome and, **724**
- Thoracic ducts, **272**
- embryology and anatomy, **263**
- Thoracic insufficiency syndrome, kyphosis/scoliosis and, **249**
- Thorax
- approach to skeletal dysplasias and, **683**
 - thanatophoric dysplasia and, **727**
- 3D ultrasound
- approach to abdominal wall and gastrointestinal tract, **484**
 - posterior fossa, **90**
 - supratentorial brain, **84**
- Thrombocytopenia-absent radius (TAR) syndrome
- amelia vs., **699**
 - Holt-Oram syndrome vs., **957**
 - radial ray malformation vs., **741**

INDEX

- VACTERL association vs., **1006**
- Thrombosis
 - cord, **835, 837**
 - renal vein, **673**
 - unilateral enlarged kidney vs., **671**
 - of torcular Herophili. *See* Dural sinus malformation.
- Thumb defects, radial ray malformation vs., **741**
- Thy-box, **329**
- Thymic hypoplasia, 22q11 deletion syndrome and, **919**
- Thymus
 - development, **323**
 - fetal, **329**
 - solid/echogenic chest mass vs., **356, 357**
- Thyroid circumference, **275, 296**
- Tissue-engineered scaffolds, bladder exstrophy, **510**
- Todani modification of Alonso-Lej classification, choledochal cyst, **549**
- ToF with absent pulmonary valve (ToF-APV), **424–427**
- Tongue, **269**
- Tongue lymphangioma, macroglossia vs., **318**
- TORCH infections. *See* Toxoplasmosis.
- Torcular herophili, approach to imaging, **91**
- Torsion, testicular, **677**
 - scrotal mass vs., **676**
- Total anomalous pulmonary venous return (TAPVR), **420–423**
 - diagnostic checklist, **422**
 - differential diagnosis, **421**
 - prognosis, **422**
 - staging, grading, & classification, **422**
- Total fetal lung volume (TFLV), MR, **333**
- Total pulmonary venous connection (TAPVC), **420–423**
- "Total veins." *See* Total anomalous pulmonary venous return (TAPVR).
- Townes-Brock syndrome, VACTERL association vs., **1006**
- Toxoplasmosis, **1022–1023**
 - cytomegalovirus vs., **1017**
 - differential diagnosis, **1023**
 - echogenic bowel vs., **558**
 - parvovirus vs., **1021**
 - pericardial effusion and, **449**
 - prognosis, **1023**
 - varicella vs., **1025**
- Trachea, **326, 328**
 - development, **322**
 - primitive, **324**
- Tracheal bud, **324**
 - development, **322**
- Tracheobronchial development, **326**
- Tracheobronchial tree, **325**
- Tracheobronchomalacia, campomelic dysplasia and, **707**
- Tracheoesophageal fistula, esophagus atresia and, **517**
- Tracheoesophageal folds, **324**
 - midline fusion of, **324**
- Tracheoesophageal septum, development, **322**
- Tragus, **265**
- Transabdominal cerclage, **1062**
- Transabdominal ultrasound
 - approach to abdominal wall and gastrointestinal tract, **484**
 - supratentorial brain, **84**
- Transient abnormal myelopoiesis, **556**
- Transposition of great arteries (TGA), **428–431**
 - dextroposition, double-outlet right ventricle vs., **437**
 - diagnostic checklist, **430**
 - differential diagnosis, **429**
 - genetics, **429**
 - long term, **430**
 - prognosis, **430**
 - staging, grading, & classification, **429–430**
- Transvaginal cerclage, **1062**
- Transvaginal ultrasound (TVUS), **16**
 - approach to abdominal wall and gastrointestinal tract, **484**
 - posterior fossa, **90**
 - supratentorial brain, **84**
- Transversalis fascia, **577**
- Transverse aortic arch, embryology and anatomy, **372, 373**
- Transverse arch/isthmus hypoplasia, coarctation/interrupted aortic arch and, **413**
- Transverse colon, embryology and anatomy, **479, 483**
- Transverse mesocolon, embryology and anatomy, **479**
- Transverse process, **232**
- Transversus abdominis muscle, **577**
- Trauma
 - acute abdomen in pregnancy vs., **1083**
 - fetal, angulated bones and, **775, 779**
 - intracranial hemorrhage and, **155**
 - maternal, amniotic band syndrome and, **925**
- Treacher Collins syndrome (TCS), **312, 996–999**
 - abnormal ears vs., **310**
 - diagnostic checklist, **997**
 - differential diagnosis, **997**
 - genetics, **997**
 - Goldenhar syndrome vs., **955**
 - micrognathia vs., **314**
 - Pierre Robin sequence vs., **987**
 - prognosis, **997**
- Tricuspid, regurgitation, trisomy 13 and, **903**
- Tricuspid atresia (TA), **402–403**
 - chamber asymmetry vs., **468, 470**
 - diagnostic checklist, **403**
 - differential diagnosis, **403**
 - prognosis, **403**
 - pulmonary stenosis/atresia vs., **405**
 - staging, grading, & classification, **403**
- Tricuspid dysplasia, **400–401**
 - chamber asymmetry vs., **469, 471**
 - coaptation point of, **397**
 - diagnostic checklist, **401**
 - differential diagnosis, **401**
 - Ebstein anomaly vs., **397**
 - prognosis, **401**
 - septal and posterior of, **397**
- Tricuspid flow, abnormal, trisomy 21 and, **891**
- Tricuspid valve
 - chamber asymmetry and, **469**
 - embryology and anatomy, **368, 369, 371**
 - hypoplastic left heart and, **409**
- Trident hands, achondroplasia and, **695**
- Trilaminar germ disc, **228**

INDEX

- Triplets and beyond, **874–877**
 - diagnostic checklist, **875**
 - differential diagnosis, **875**
 - outcomes, **876**
 - prognosis, **875**
- Triploidy, **831, 912–915**
 - abnormal gestational sac and contents vs., **57**
 - chorioangioma vs., **817**
 - clubfoot and, **733**
 - complete hydatidiform mole vs., **31**
 - diagnostic checklist, **914**
 - diandric triploidy phenotype, **913**
 - differential diagnosis, **913**
 - digynic triploidy phenotype, **913**
 - disorders of sexual development and, **651**
 - genetics, **914**
 - placental lake vs., **807**
 - placental mesenchymal dysplasia vs., **823**
 - prognosis, **914**
 - Smith-Lemli-Opitz syndrome vs., **993**
 - syndactyly vs., **752**
 - trisomy 18 vs., **898**
- Trisomy 8, arachnoid cyst and, **152**
- Trisomy 9
 - cerebellar hypoplasia and, **187**
 - Dandy-Walker malformation and, **176**
- Trisomy 13, **669, 902–907**
 - arachnoid cyst and, **152**
 - atrioventricular septal defect and, **392**
 - autosomal recessive polycystic kidney disease vs., **619**
 - cardiac defects, **903**
 - cerebellar hypoplasia and, **187**
 - clubfoot and, **733**
 - Dandy-Walker malformation and, **176**
 - diagnostic checklist, **904**
 - differential diagnosis, **903–904**
 - disorders of sexual development and, **651**
 - double-outlet right ventricle and, **437**
 - echogenic cardiac focus and, **439**
 - echogenic kidneys vs., **668**
 - facial anomalies, **903**
 - gastrointestinal anomalies, **903**
 - hypoplastic left heart associated with, **410**
 - Meckel-Gruber syndrome vs., **971**
 - mild ventriculomegaly vs., **212**
 - musculoskeletal findings, **903**
 - polydactyly vs., **747**
 - prognosis, **904**
 - renal anomalies, **903**
 - rhabdomyoma and, **445**
 - Smith-Lemli-Opitz syndrome vs., **993**
 - tetralogy of Fallot and, **425**
 - triploidy vs., **913**
 - trisomy 18 vs., **898**
 - trisomy 21 vs., **892**
- Trisomy 18, **316, 896–901**
 - arachnoid cyst and, **152**
 - arthrogryposis/akinesia sequence vs., **759**
 - atrioventricular septal defect and, **392**
 - brain anomalies, **897**
 - cardiac defects, **897**
 - cerebellar hypoplasia and, **187**
 - chondrodysplasia punctata vs., **712**
 - clubfoot and, **733**
 - Cornelia de Lange syndrome vs., **941**
 - cystic hygroma, **897**
 - Dandy-Walker malformation and, **176**
 - diagnostic checklist, **898**
 - differential diagnosis, **898**
 - disorders of sexual development and, **651**
 - double-outlet right ventricle and, **437**
 - facial anomalies, **897**
 - Fryns syndrome vs., **953**
 - gastrointestinal anomalies, **897**
 - genetics, **898**
 - hypoplastic left heart associated with, **410**
 - mega cisterna magna and, **185**
 - micrognathia vs., **314**
 - mild ventriculomegaly vs., **212**
 - musculoskeletal anomalies, **897**
 - Neu-Laxova syndrome vs., **977**
 - prognosis, **898**
 - radial ray malformation vs., **741**
 - rocker-bottom foot and, **737**
 - single umbilical cord and, **825**
 - Smith-Lemli-Opitz syndrome vs., **993**
 - tetralogy of Fallot and, **425**
 - triploidy vs., **913**
 - trisomy 13 vs., **904**
 - trisomy 21 vs., **892**
 - urinary tract anomalies, **897**
 - VACTERL association vs., **1005**
- Trisomy 20, arachnoid cyst and, **152**
- Trisomy 21, **319, 890–895**
 - atrioventricular septal defect and, **392**
 - cardiac defects, **891**
 - central nervous system anomalies, **891**
 - chamber asymmetry and, **469**
 - chondrodysplasia punctata vs., **712**
 - cystic fibrosis vs., **945**
 - diagnostic checklist, **892**
 - differential diagnosis, **892**
 - double-outlet right ventricle and, **437**
 - echogenic bowel vs., **558**
 - echogenic cardiac focus and, **439**
 - gastrointestinal anomalies, **891**
 - genetics, **892**
 - hydrops vs., **1052**
 - macroglossia vs., **318**
 - markers, clinodactyly and, **745**
 - mild ventriculomegaly vs., **212, 213**
 - mildly short femur/humerus and, **770, 772**
 - myeloid leukemia associated with, **556**
 - prognosis, **892**
 - proximal focal femoral dysplasia vs., **765**
 - rhabdomyoma and, **445**
 - 2nd-trimester markers, **892**
 - tetralogy of Fallot and, **425**
 - Turner syndrome vs., **909**
 - warfarin embryopathy vs., **1011**
- Trophoblast, days 14–28 from last menstrual period, **784**

INDEX

- Trophoblastic disease, gestational, placental cysts and masses vs., **831, 833**
- Trophoblastic neoplasia, gestational, placental lake vs., **807**
- Trophotropism theory, **811**
- True benign vascular neoplasm, congenital hepatic hemangioma and, **551**
- Truncus arteriosus, **375, 432–435**
- diagnostic checklist, **434**
 - differential diagnosis, **433**
 - genetics, **433**
 - prognosis, **434**
 - pulmonary stenosis/atresia vs., **405**
 - 22q11 deletion syndrome and, **919**
- Truncus arteriosus communis. *See* Truncus arteriosus.
- Tubal ectopic pregnancy, **34–39**
- abdominal ectopic pregnancy vs, **51**
 - diagnostic checklist, **36**
 - differential diagnosis, **35**
 - heterotopic pregnancy vs., **55**
 - ovarian ectopic pregnancy vs., **53**
 - prognosis, **36**
- Tuberous sclerosis, **1000–1003**
- diagnostic checklist, **1002**
 - differential diagnosis, **1001**
 - genetics, **1001–1002**
 - gray matter heterotopia vs., **143**
 - prognosis, **1002**
 - rhabdomyoma and, **445**
- Tuberous sclerosis complex. *See* Tuberous sclerosis.
- Tuboovarian abscess, adnexal mass in pregnancy vs., **63**
- Tumors
- orbital, **309**
 - abnormal orbits/eyes vs., **304**
 - rhabdomyoma vs., **445**
- Turner syndrome, **908–911**
- aortic stenosis and, **418**
 - cardiovascular anomalies, **909**
 - coarctation/interrupted aortic arch and, **413**
 - Dandy-Walker malformation and, **176**
 - diagnostic checklist, **910**
 - differential diagnosis, **909**
 - genetics, **910**
 - genitourinary findings, **909**
 - hydrops vs., **1052, 1054**
 - hypoplastic left heart associated with, **410**
 - mildly short femur/humerus and, **770, 772**
 - Noonan syndrome vs., **979**
 - prognosis, **910**
 - proximal focal femoral dysplasia vs., **765**
 - survivors, marked phenotype variability, **910**
 - trisomy 21 vs., **892**
- TV (tricuspid valve) dysplasia, **400–401**
- 22q11 deletion syndrome, **918–919**
- CHARGE syndrome vs., **938–939**
 - coarctation/interrupted aortic arch and, **413**
 - diagnostic checklist, **919**
 - differential diagnosis, **919**
 - genetics, **919**
 - micrognathia and, **315**
 - Pierre Robin sequence vs., **987**
 - pulmonary stenosis/atresia and, **406**
 - tetralogy of Fallot and, **425**
 - truncus arteriosus and, **434**
- Twin
- anomalous
 - causing stuck appearance, twin-twin transfusion syndrome vs., **863**
 - twin reversal arterial perfusion vs., **867**
 - hydatidiform mole with, triploidy vs., **913**
 - stuck, twin-twin transfusion syndrome and, **863**
- Twin anemia-polycythemia sequence, fetal anemia vs., **1041**
- Twin anomaly, monochorionic monoamniotic twins vs., **855**
- Twin demise, **848**
- early, abnormal gestational sac and contents vs., **57**
 - monochorionic monoamniotic twins vs., **855**
- Twin embolization syndrome, monochorionic diamniotic twins and, **852**
- Twin gestation, perigestational hemorrhage vs., **25**
- Twin-in-Twin Reversed Arterial Perfusion (TRAP), acardiac, placental teratoma vs., **821**
- Twin pregnancy, with hydatidiform mole, placental mesenchymal dysplasia vs., **823**
- Twin reversed arterial perfusion, **866–869**
- conjoined twins vs., **871**
 - diagnostic checklist, **868**
 - differential diagnosis, **867**
 - genetics, **868**
 - prognosis, **868**
- Twin reversed arterial perfusion sequence (TRAP), monochorionic monoamniotic twins and, **855**
- Twin-twin transfusion syndrome (TTTS), **862–865**
- bladder exstrophy vs., **509**
 - cardiomyopathy and, **442**
 - differential diagnosis, **863**
 - discordant twin growth, **859**
 - evaluation, monochorionic monoamniotic twins and, **855**
 - hydrops vs., **1052, 1055, 1056**
 - monoamniotic monoamniotic twins vs., **855**
 - oligohydramnios vs., **1049, 1051**
 - polyhydramnios vs., **1044, 1046**
 - prognosis, **864**
 - staging, grading, & classification, **863, 864**
- Twinning
- dichorionic, **840**
 - impact of chorionicity, **842**
 - monoamniotic, **840**
 - conjoined, **840**
 - diamniotic, **840**
 - monoamniotic, **840**
 - sonographic monitoring, **842**
- Twins
- conjoined, **870–873**
 - diagnostic checklist, **872**
 - differential diagnosis, **871**
 - fissure theory, **871**
 - fusion theory, **871**
 - minimally conjoined omphalopagus, **871**

INDEX

- monochorionic monoamniotic twins vs., **855**
 - parasitic, **871**
 - prognosis, **872**
 - staging, grading, & classification, **871**
 - thoracopagus, **871**
 - craniopagus, **871**
 - dichorionic diamniotic, **846–849**
 - diagnostic checklist, **848**
 - differential diagnosis, **847**
 - intrauterine linear echoes vs., **1086, 1087**
 - prognosis, **848**
 - discordant growth, **858–861**
 - differential diagnosis, **859**
 - genetic counseling, **860**
 - impact, **860**
 - prognosis, **860**
 - fetus-in-fetu, **878–881**
 - diagnostic checklist, **879**
 - differential diagnosis, **879**
 - prognosis, **879**
 - monochorionic diamniotic, **850–853**
 - diagnostic checklist, **852**
 - dichorionic diamniotic twins vs., **847**
 - differential diagnosis, **851**
 - embryology, **852**
 - genetics, **852**
 - impact of discordant growth, **860**
 - intrauterine linear echoes vs., **1086, 1087, 1088**
 - prognosis, **852**
 - monochorionic monoamniotic, **854–857**
 - associated anomalies, **855**
 - conjoined twins vs., **871**
 - diagnostic checklist, **856**
 - dichorionic diamniotic twins vs., **847**
 - differential diagnosis, **855**
 - prognosis, **856**
 - omphalopagus, **871**
 - with perigestational hemorrhage, triplets vs., **875**
 - placental abruption, **791**
 - types, intrauterine linear echoes, **1086**
 - 2-vessel cord, **825**
 - Type I collagen abnormalities, achondroplasia vs., **695**
 - Type IA achondrogenesis, **689**
 - Type IB achondrogenesis, **689**
 - Type II achondrogenesis, **689**
 - Type II collagen gene COL2A1, achondrogenesis/hypochondrogenesis and, **689**
- ## U
- Ultrasound
 - 3D
 - approach to abdominal wall and gastrointestinal tract, **484**
 - face and neck anomalies, **274**
 - posterior fossa, **90**
 - supratentorial brain, **84**
 - fetal genitourinary tract, **580**
 - Umbilical arteries, **786**
 - embryology and anatomy, **372**
 - single umbilical cord vs, **825**
 - Umbilical artery, **574**
 - single, **824–825**
 - aneuploidy, **825**
 - associated abnormalities, **825**
 - differential diagnosis, **825**
 - marginal/velamentous cord insertion and, **815**
 - Umbilical artery (UA) Doppler, **841–842**
 - Umbilical artery S/D ratio percentile, **1029**
 - Umbilical cord
 - abnormalities, intracranial hemorrhage and, **156**
 - approach to, **784–789**
 - coiling, **789**
 - cord knot, **834–835**
 - cysts and masses, **834–837**
 - differential diagnosis, **834**
 - true, **834–835**
 - development, **5, 15**
 - embryology, **834**
 - and anatomy, **479, 481, 784**
 - entanglement, **855, 856**
 - false knot, **785**
 - fusion, **855**
 - hemangioma, **836, 837**
 - hematoma, **835, 837**
 - hernia, omphalocele vs., **498**
 - hypercoiled, **785, 835, 837**
 - insertion, **789**
 - morphology, evaluation, **834**
 - teratoma, **835**
 - thrombosis, **835, 837**
 - Umbilical cord cyst
 - omphalocele vs., **497**
 - umbilical vein varix vs., **827**
 - urachal anomalies and, **648**
 - Umbilical cord insertion (UCI), gastroschisis and, **491**
 - Umbilical vein, **574, 786**
 - at ductus venosus, embryology and anatomy, **483**
 - embryology and anatomy, **475, 479, 481, 483**
 - Umbilical vein varix, **826–827**
 - associated abnormalities, **827**
 - choledochal cyst vs., **549**
 - differential diagnosis, **827**
 - persistent right umbilical vein vs., **829**
 - prognosis, **827**
 - Umbilical veins, embryology and anatomy, **365, 372**
 - Umbilical vessel thrombosis, single umbilical artery vs., **825**
 - Unbalanced left dominant atrioventricular septal defect, tricuspid atresia vs., **403**
 - Uncomplicated fibroid, uterine rupture vs., **1077**
 - Uncomplicated placenta previa, morbidly adherent placenta vs., **801**
 - Unicornuate uterus, Müllerian duct anomalies in, **1071–1072**
 - Unilateral cleft lip
 - with cleft palate, **279**
 - without cleft palate, **279**
 - Unilateral enlarged kidney, **670–673**
 - differential diagnosis, **670–671**

INDEX

- Unilateral renal agenesis, with compensatory hypertrophy, **671**
- unilateral enlarged kidney vs., **670**
- Unilateral renal enlargement, **581**
- Unilateral suprarenal mass, **581**
- Unilateral ureteropelvic junction obstruction, congenital, polyhydramnios vs., **1045, 1047**
- Uniparental disomy 14 (paternal)/, short rib-polydactyly syndrome vs., **724**
- Unobstructed total anomalous pulmonary venous return, **422**
- UPJ. *See* Ureteropelvic junction obstruction.
- Upper extremity long bones, **686–687**
- Upper lip, **264, 269**
- Upper urinary tract anomalies, hypospadias and, **657**
- Upper vagina from paramesonephric ducts, **576**
- Urachal anomalies, **646–649**
- associated abnormalities, **648**
 - cystic abdominal mass vs., **562, 566**
 - diagnostic checklist, **648**
 - differential diagnosis, **647**
 - embryology, **648**
 - genetics, **648**
 - prognosis, **648**
- Urachal cyst, **647**
- enteric duplication cyst vs., **539**
 - meconium peritonitis/pseudocyst vs., **542**
 - mesenteric lymphangioma vs., **545**
 - ovarian cyst vs., **659**
- Urachal diverticulum, **647**
- Urachal sinus, **647**
- Urachus, **570, 576, 577**
- Ureter, **573, 575, 577**
- congenital megaureter, ureterocele vs., **644**
 - dilated, multicystic dysplastic kidney vs., **615**
 - ureterocele and, **643**
- Ureterectasis
- jejunal/ileal atresia vs., **525**
 - urachal anomalies vs., **647**
- Ureteric bud, **570, 572, 573**
- Ureteric bud theory, multicystic dysplastic kidney vs., **616**
- Ureterocele, **642–645**
- associated abnormalities, **644**
 - diagnostic checklist, **644**
 - differential diagnosis, **643–644**
 - ectopic, **644**
 - genetics, **644**
 - orthotopic, **644**
 - primary, **667**
 - hydronephrosis vs., **664–665**
 - prognosis, **644**
 - simple, duplicated collecting system vs., **591**
- Ureteropelvic junction obstruction, **604–607, 665**
- associated abnormalities, **605**
 - bilateral, oligohydramnios vs., **1048**
 - cystic abdominal mass vs., **562, 563**
 - diagnostic checklist, **606**
 - differential diagnosis, **605**
 - duplicated collecting system vs., **591**
 - genetics, **605**
 - hydronephrosis vs., **664**
 - with massive renal pelvis distention, urinoma vs., **609**
 - multicystic dysplastic kidney vs., **615**
 - obstructive renal dysplasia and, **611**
 - ovarian cyst vs., **659**
 - prognosis, **606**
 - staging, grading, & classification, **605–606**
 - unilateral, congenital, polyhydramnios vs., **1045, 1047**
 - urinary tract dilation vs., **585**
- Ureteropelvic obstruction, cloacal malformation/urogenital sinus and, **533**
- Ureterovesical junction obstruction, **666**
- hydronephrosis vs., **664**
- Ureters
- abnormal urinary tract, **581**
 - duplicated collecting system, **591**
 - ectopic, **591**
- Urethra, **576**
- Urethral atresia
- posterior urethral valves vs., **635**
 - prune-belly syndrome vs., **639**
 - urachal anomalies associated and, **648**
- Urethral valves, posterior, **634–637, 666**
- associated malformations, **635**
 - diagnostic checklist, **636**
 - differential diagnosis, **635**
 - genetics, **636**
 - hydronephrosis vs., **664**
 - oligohydramnios vs., **1049, 1051**
 - prognosis, **636**
 - prune-belly syndrome vs., **639**
- Urinary ascites, ascites vs., **560, 561**
- Urinary bladder, **573, 576, 577**
- embryology and anatomy, **478, 480**
- Urinary tract
- development, **570**
 - MR, **579**
 - ultrasound, **578**
- Urinary tract dilation (UTD), **584–587**
- antenatal categories by AP RPD, **586**
 - associated abnormalities, **585**
 - classification system, **605–606, 665**
 - diagnostic checklist, **586**
 - differential diagnosis, **585**
 - hydronephrosis vs., **664**
 - lower, ureteropelvic junction obstruction vs., **605**
 - prenatal diagnosis, **586**
 - prenatal follow-up recommendations, **606**
 - prognosis, **585–586**
 - risk-based management, **586**
 - trisomy 13 and, **903**
 - upper, obstructive renal dysplasia vs., **611**
- Urinary tract obstruction, lower
- urachal anomalies vs., **647**
 - urinary tract dilation vs., **585**
- Urine formation, bilateral renal agenesis and, **601–602**
- Urinoma, **608–609**
- cystic abdominal mass vs., **562, 564**
 - diagnostic checklist, **609**
 - differential diagnosis, **609**
 - with high-grade obstruction, ureteropelvic junction obstruction and, **605**

INDEX

- prognosis, **609**
 - Urogenital sinus, **576**
 - embryology and anatomy, **478, 480**
 - lower vagina from, **576**
 - Urogenital sinus malformation. *See* Cloacal malformation/urogenital sinus.
 - Urolithiasis, horseshoe kidney and, **597**
 - Urorectal septum, **573**
 - embryology and anatomy, **478**
 - UTD. *See* Urinary tract dilation.
 - Uterine cavity, **7, 786**
 - Uterine dehiscence, acute abdomen in pregnancy vs., **1083**
 - Uterine duplication
 - intrauterine linear echoes vs., **1086, 1088**
 - pregnancy in
 - abdominal ectopic pregnancy vs, **51**
 - heterotopic pregnancy vs., **55**
 - interstitial ectopic pregnancy vs., **41–42**
 - Uterine fibroids, pedunculated, adnexal mass in pregnancy vs., **63**
 - Uterine myomata, abnormal gestational sac and contents vs., **57**
 - Uterine rupture, **1076–1079**
 - acute abdomen in pregnancy vs., **1083, 1085**
 - diagnostic checklist, **1078**
 - differential diagnosis, **1077**
 - prognosis, **1078**
 - Uterine septum, duplication anomaly, synechiae vs., **1075**
 - Uterovaginal canal, **571, 576**
 - Uterus, **571, 576**
 - arteriovenous malformation, retained products of conception vs., **1081**
 - atony, retained products of conception vs., **1081**
 - Müllerian duct anomalies in
 - arcuate, **1071–1072**
 - bicornuate, **1071–1072**
 - didelphys, **1071–1072**
 - septate, **1071–1072**
 - unicornuate, **1071–1072**
 - normal postpartum, retained products of conception vs., **1081**
 - septate, circumvallate placenta vs., **813**
 - Uterus didelphys, bladder exstrophy and, **510**
- ## V
- VACTERL association, **1004–1007**
 - associated abnormalities, **1005**
 - bilateral renal agenesis and, **602**
 - caudal regression sequence vs., **245**
 - clubfoot and, **733**
 - diagnostic checklist, **1006**
 - differential diagnosis, **1005–1006**
 - genetics, **1006**
 - Holt-Oram syndrome vs., **957**
 - hydronephrosis and, **664**
 - kyphosis/scoliosis and, **249**
 - prognosis, **1006**
 - pulmonary agenesis associated with., **349**
 - radial ray malformation vs., **741**
 - rhombencephalosynapsis and, **191, 192**
 - sirenomelia vs., **989**
 - staging, grading, & classification, **1006**
 - tethered cord and, **251**
 - tetralogy of Fallot and, **425**
 - valproate embryopathy vs., **1009**
 - Vagina, duplicated, bladder exstrophy and, **510**
 - Valproate embryopathy, **1008–1009**
 - differential diagnosis, **1009**
 - genetics, **1009**
 - prognosis, **1009**
 - Valproate syndrome, fetal, radial ray malformation vs., **741**
 - Valvar aortic stenosis, **418**
 - aortic stenosis and, **417**
 - Varicella, **1024–1025**
 - cytomegalovirus vs., **1017**
 - differential diagnosis, **1025**
 - parvovirus vs., **1021**
 - prognosis, **1025**
 - toxoplasmosis vs., **1023**
 - Varicella-zoster virus. *See* Varicella.
 - Vas deferens, **577**
 - Vasa previa, **798–799, 841**
 - diagnostic checklist, **799**
 - differential diagnosis, **799**
 - placenta previa and, **795**
 - prognosis, **799**
 - staging, grading & classification, **799**
 - Vascular disease, maternal collagen, chondrodysplasia punctata vs., **712**
 - Vascular hypoperfusion, amniotic band syndrome and, **925**
 - Vascular liver lesion, pathogenesis of. *See* Congenital hepatic hemangioma.
 - Vascular malformation
 - encephalomalacia/porencephaly vs., **159**
 - hydrops vs., **1053, 1057**
 - intracranial hemorrhage and, **155**
 - Vascular tumor, arteriovenous fistula vs., **199**
 - Vascularity, fetus-in fetu vs., **879**
 - Vein of Galen aneurysmal malformation, **194–197**
 - arteriovenous fistula vs., **199**
 - diagnostic checklist, **196**
 - differential diagnosis, **195**
 - genetics, **195**
 - posterior fossa cyst/fluid collection vs., **223, 225**
 - prognosis, **196**
 - Vein-to-vein anastomoses, twin reversed arterial perfusion and, **868**
 - Veins, embryology and anatomy, **365**
 - cardinal veins, **365**
 - ductus venosus, **365**
 - sinus venosus, **365**
 - systemic vein, **365**
 - umbilical veins, **365**
 - vitelline veins, **365**
 - Velamentous cord insertion, discordant twin growth and, **859**
 - Velocardiofacial syndrome. *See also* 22q11 deletion syndrome.
 - lobar holoprosencephaly associated with, **120**

INDEX

- Venous lakes. *See also* Placental lake.
- chorioangioma vs., **817**
- Venous sinus engorgement, vein of Galen aneurysmal malformation vs., **195**
- Ventral defects. *See* PHACES syndrome.
- Ventral mesentery, embryology and anatomy, **476, 477**
- Ventral mesogastrium, **478**
- Ventral pancreas, embryology and anatomy, **478**
- Ventricles
- brain, embryology and anatomy, **69**
- heart, asymmetry, coarctation/interrupted aortic arch vs., **413**
- Ventricular inversion. *See* Transposition of great arteries (TGA).
- Ventricular loop, embryology and anatomy, **366**
- Ventricular outflow tract
- left, embryology and anatomy, **369**
- obstruction, left or right, cardiomyopathy vs., **441**
- right, embryology and anatomy, **369**
- Ventricular septal defect (VSD), **388–389, 397**
- chamber asymmetry and, **468**
- diagnostic checklist, **389**
- differential diagnosis, **389**
- ectopia cordis associated with, **386**
- genetics, **389**
- isolated perimembranous, tetralogy of Fallot vs., **425**
- large, atrioventricular septal defect vs., **391**
- prognosis, **389**
- prune-belly syndrome and, **640**
- pulmonary atresia
 tetralogy of Fallot vs., **425**
 truncus arteriosus vs., **433**
- staging, grading, & classification, **389**
- Ventricular septum, embryology and anatomy, **368, 369, 371**
- Ventricular shunting, aqueductal stenosis and, **166**
- Ventricular tachycardia, tachyarrhythmia vs., **455**
- Ventriculomegaly, **922**
- Apert syndrome and, **929**
- aqueductal stenosis and, **165**
- Chiari 2 malformation and, **169**
- cytomegalovirus and, **1017**
- encephalomalacia/porencephaly and, **160**
- mega cisterna magna and, **185**
- mild, **85, 212–215**
 agenesis/dysgenesis of corpus callosum vs., **110**
 alternative differential approaches, **213**
 differential diagnosis, **212**
- rhombencephalosynapsis and, **192**
- trisomy 21 and, **891**
- Vermian agenesis
- arachnoid cyst vs., **151**
- partial/complete
 mega cisterna magna vs., **185**
 rhombencephalosynapsis vs., **191**
- Vermian dysgenesis, **178–179**
- Aicardi syndrome and, **921**
- arachnoid cyst vs., **151**
- Blake pouch cyst vs., **181**
- Dandy-Walker malformation vs., **175**
- diagnostic checklist, **179**
- genetics, **179**
- posterior fossa cyst/fluid collection vs., **222, 223, 224**
- prognosis, **179**
- Vermis, approach to imaging, **91**
- Vertebral anomalies, pentalogy of Cantrell, **503**
- Vertebral body
- approach to fetal spine and, **234**
- development of, **229**
- ossified centrum of, **232**
- with shadowing, **578**
- Vesicles, brain
- primary, **69**
- secondary, **69**
- Vesicoureteral junction obstruction, obstructive renal dysplasia and, **611**
- Vesicoureteral reflux, **667**
- grading system, **665**
- hydronephrosis vs., **665**
- multicystic dysplastic kidney and, **615, 616**
- Villogenesis, terminal, **784**
- Viral infection, intracranial hemorrhage and, **155**
- Visceral heterotaxy. *See* Heterotaxy/cardiosplenic syndromes.
- Visceral peritoneum, **477**
- Viscerocranium, **270**
- Vitamin K deficiency
- chondrodysplasia punctata vs., **712**
- warfarin embryopathy vs., **1011**
- Vitelline veins, embryology and anatomy, **365, 475**
- distal, **481**
- proximal, **481**
- VLDL mutation, cerebellar hypoplasia and, **187**
- Volume requirements, lung development, **323**
- Volvulus, **536–537**
- associated abnormalities, **537**
- diagnostic checklist, **537**
- differential diagnosis, **537**
- etiology, **537**
- jejunal/ileal atresia vs., **525**
- meconium peritonitis/pseudocyst and, **542**
- prognosis, **537**
- VSD. *See* Ventricular septal defect (VSD).
- VZV (Varicella-zoster virus). *See* Varicella.

W

- Walker-Warburg syndrome (WWS), **139, 1012–1013**
- agenesis of corpus callosum associated with, **110**
- coloboma and, **287**
- Dandy-Walker malformation and, **176**
- diagnostic checklist, **1013**
- differential diagnosis, **1013**
- genetics, **1013**
- prognosis, **1013**
- Wall-to-wall heart, **397**
- Warfarin embryopathy, **1010–1011**
- differential diagnosis, **1011**
- prognosis, **1011**
- Warfarin (Coumadin) embryopathy, chondrodysplasia punctata vs., **712**

INDEX

Wasting, salt, **652**
Watson syndrome, Noonan syndrome vs., **979**
Weaver syndrome, Beckwith-Wiedemann syndrome vs.,
933
Weigert-Meyer rule, **591**
- in renal duplication, **643**
Wharton jelly, **784**
Wharton jelly cyst, omphalocele vs., **497**
White matter lesions, cortical/subcortical, tuberous
sclerosis and, **1001–1002**
Williams syndrome, aortic stenosis and, **417**
Wilms tumor, mesoblastic nephroma vs., **623**
Wolf Hirschhorn syndrome
- Fraser syndrome vs., **951**
- micrognathia and, **315, 317**
Wolf-Parkinson-White, **456**
WWS (Walker-Warburg syndrome). *See* Walker-Warburg
syndrome (WWS).

X

X-linked dystrophy, cardiomyopathy and, **442**
X-linked hydrocephalus, aqueductal stenosis and, **166**
XO (Turner syndrome). *See* Turner syndrome.
XX fetus, disorders of sexual development and, **651**
XY fetus, disorders of sexual development and, **651**

Y

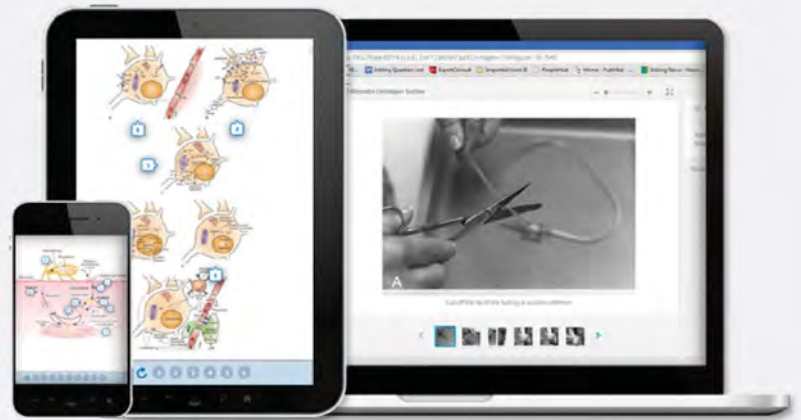
Yolk sac, **476, 477**
- abnormal
 abnormal gestational sac and contents vs., **57**
 chorionic bump vs., **29**
- primary, **7**
 involuting, **7**
- secondary, **7, 786**
Yolk stalk, **573**
- embryology and anatomy, **478, 479**

Z

Zellweger syndrome spectrum, chondrodysplasia punctata
vs., **712**
Zygomatic arch, **270**
Zygomatic bone, **271**
Zygosity, **851**
Zygote, surrounded by zona pellucida, **6**

Any screen. Any time. Anywhere.

Activate the eBook version
of this title at no additional charge.



Expert Consult eBooks give you the power to browse and find content, view enhanced images, share notes and highlights—both online and offline.

Unlock your eBook today.

- 1 Visit expertconsult.inkling.com/redeem
- 2 Scratch off your code
- 3 Type code into “Enter Code” box
- 4 Click “Redeem”
- 5 Log in or Sign up
- 6 Go to “My Library”

It's that easy!

Scan this QR code to redeem your eBook through your mobile device:



Place Peel Off
Sticker Here

For technical assistance:
email expertconsult.help@elsevier.com
call 1-800-401-9962 (inside the US)
call +1-314-447-8200 (outside the US)

ELSEVIER

Use of the current edition of the electronic version of this book (eBook) is subject to the terms of the nontransferable, limited license granted on expertconsult.inkling.com. Access to the eBook is limited to the first individual who redeems the PIN, located on the inside cover of this book, at expertconsult.inkling.com and may not be transferred to another party by resale, lending, or other means.